

Skeleton of extremities

Ivana Hradilová Svíženská

Skeleton of the upper limb (*ossa membri superioris*)

I. Shoulder girdle (*cingulum membri superioris*)

Clavicle, collar bone (*clavicula*)

Shoulder blade (*scapula*)

II. Bones of free part of the upper limb (*ossa membri superioris liberi*)

Arm: Arm bone (*humerus*)

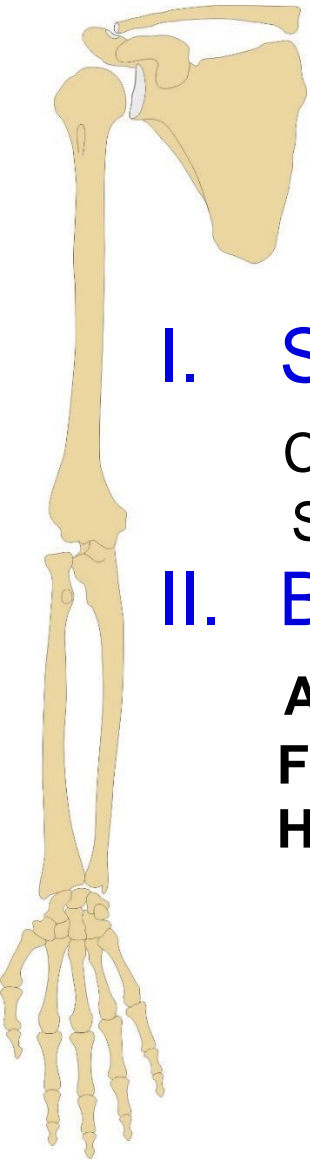
Forearm: Radius, Ulna

Hand: Carpal bones (*ossa carpi*) – 8

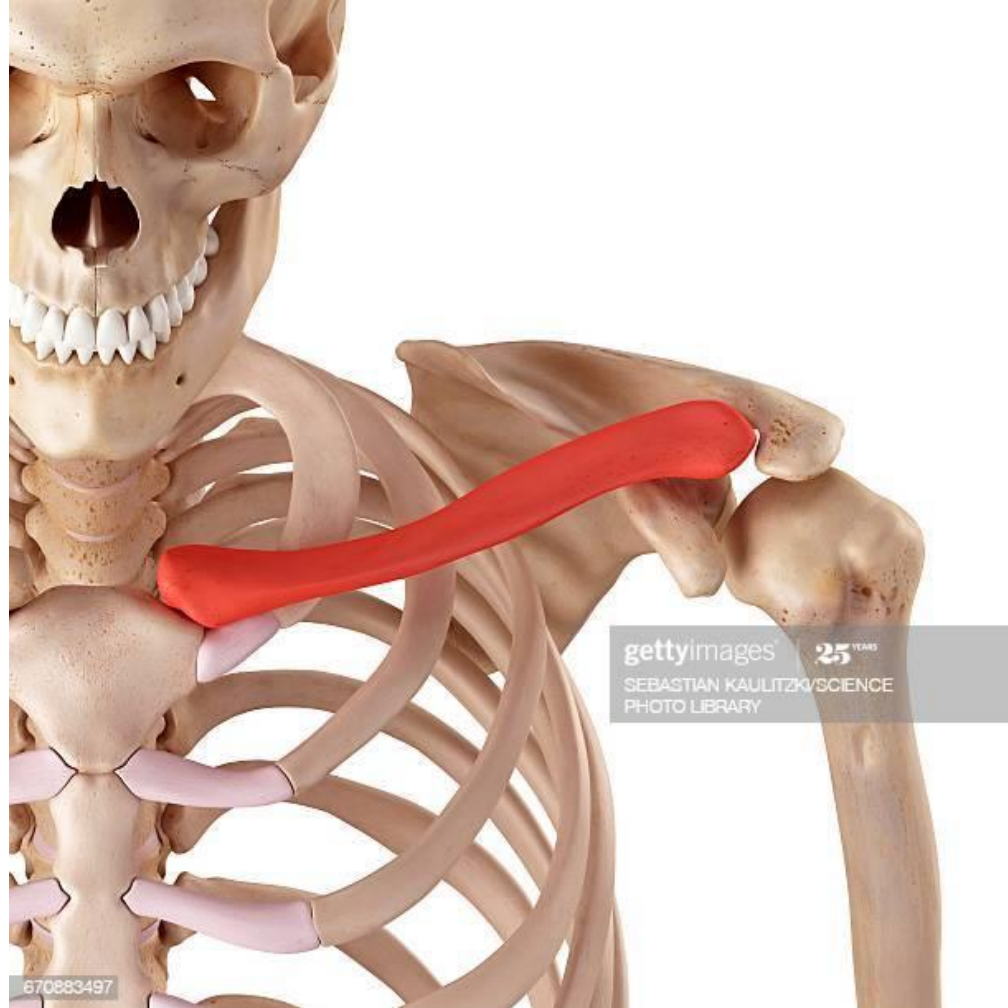Metacarpal bones (*ossa metacarpi*) – 5

Phalanges of hand digits (*ossa digitorum manus*) – 14

Sesamoid bones (*ossa sesamoidea*) – 2 or more



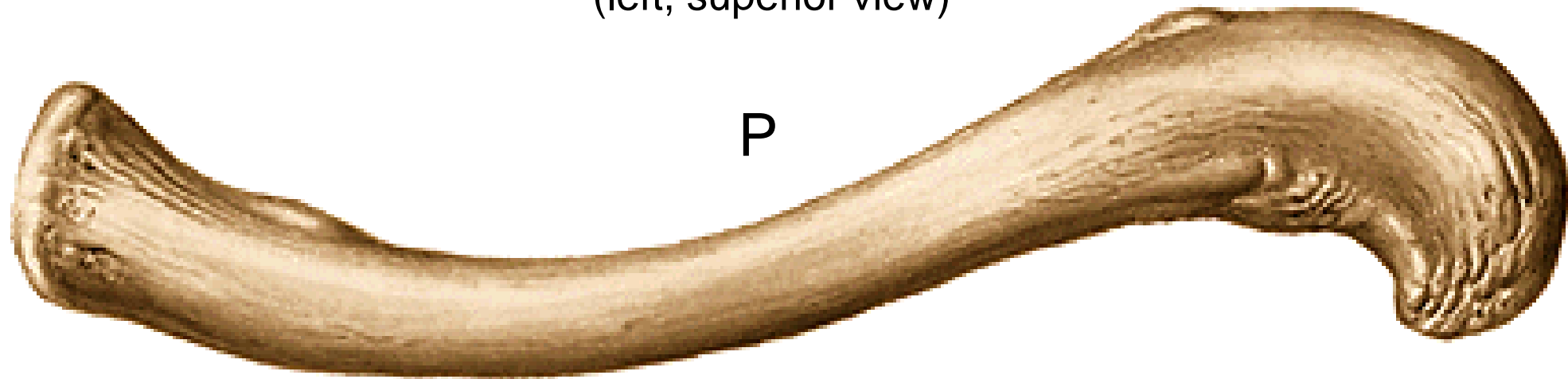
Clavicula (collar bone)



Clavicula (collar bone)

(left, superior view)

Extremitas acromialis
(facies articularis acromialis)

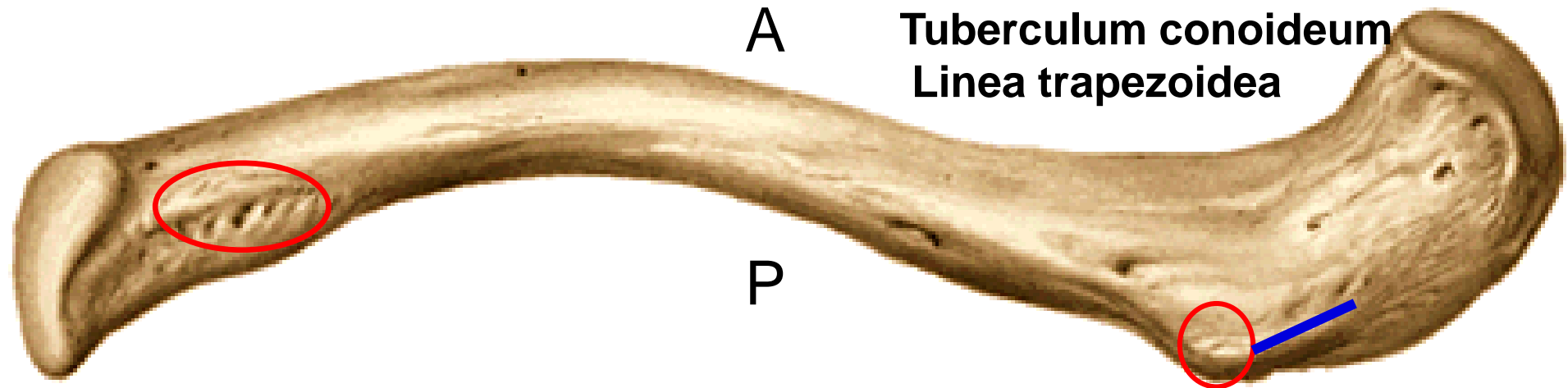


Extremitas sternalis
(facies articularis sternalis)

A

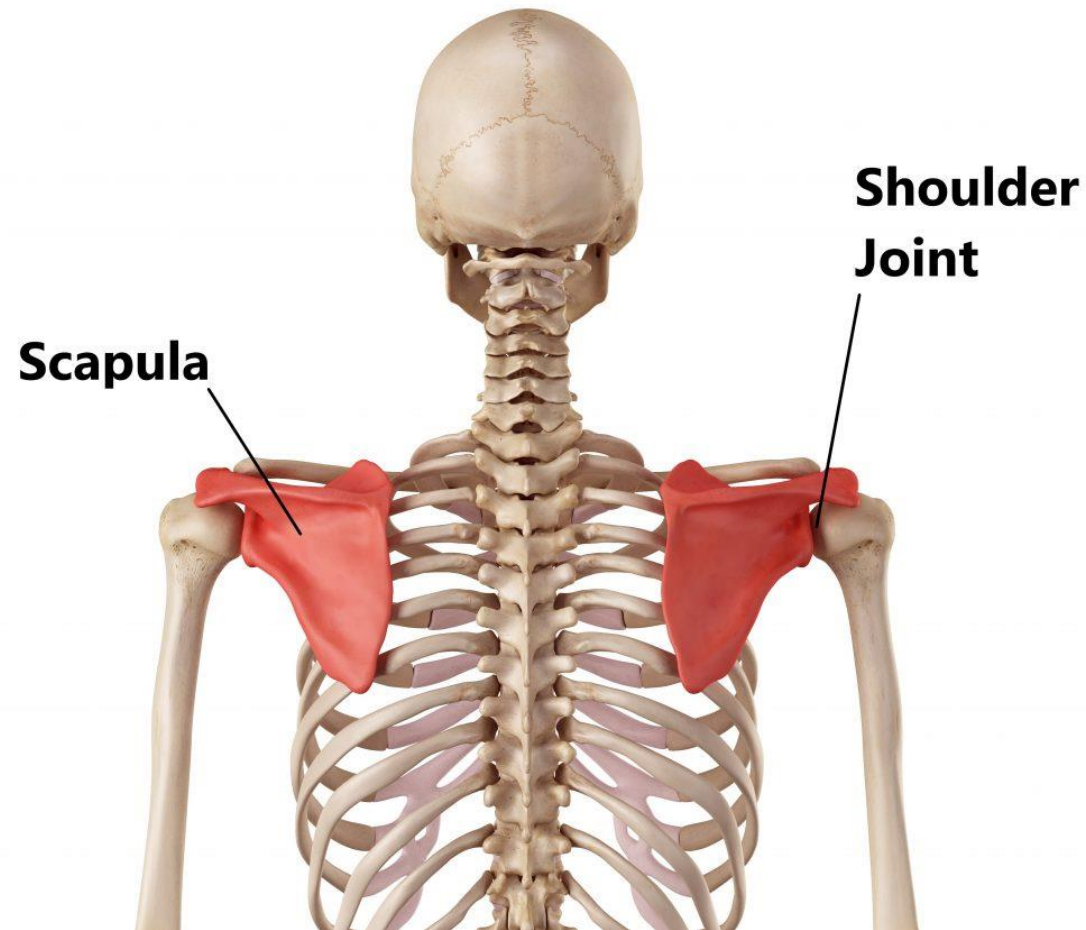
Clavicula (collar bone)

(left, inferior view)



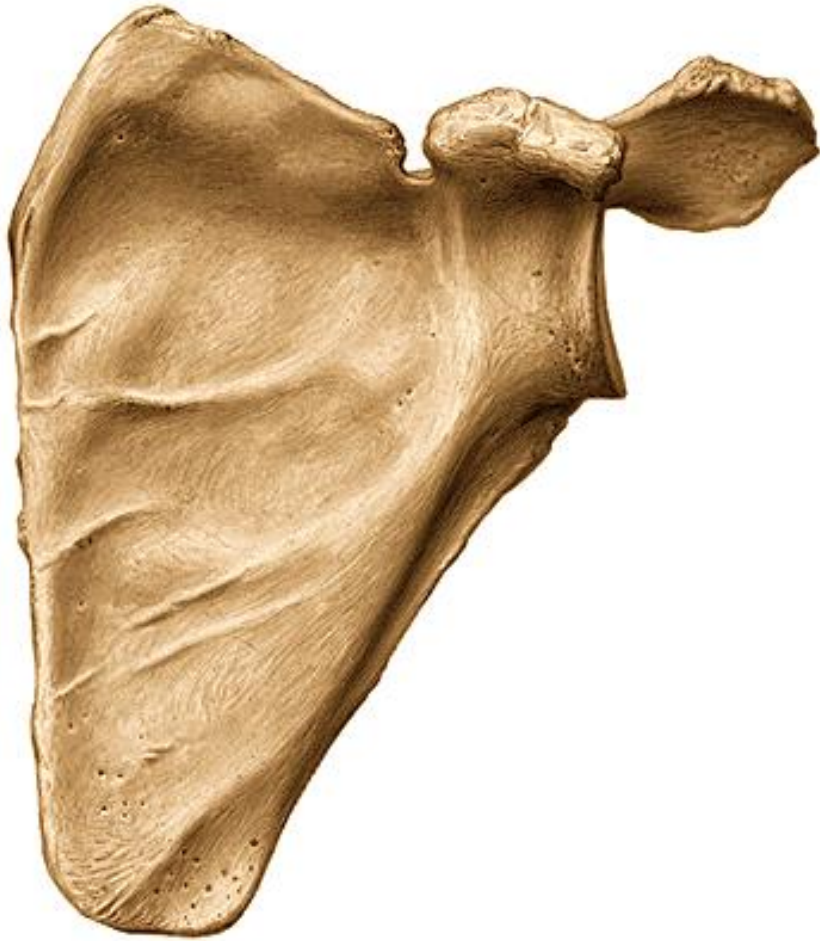Impressio ligamenti costoclavicularis

Scapula (shoulder blade)



Scapula (shoulder blade)

(left, anterior view)

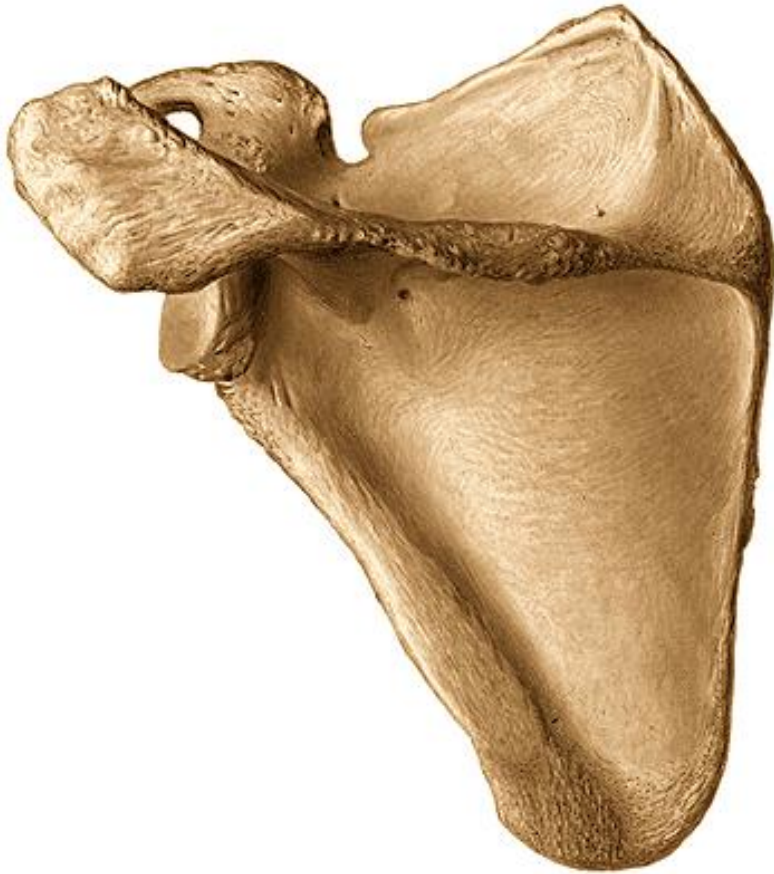

Facies costalis:

Fossa subscapularis

Scapula (shoulder blade)

(left, posterior view)



Facies dorsalis:

Spina scapulae

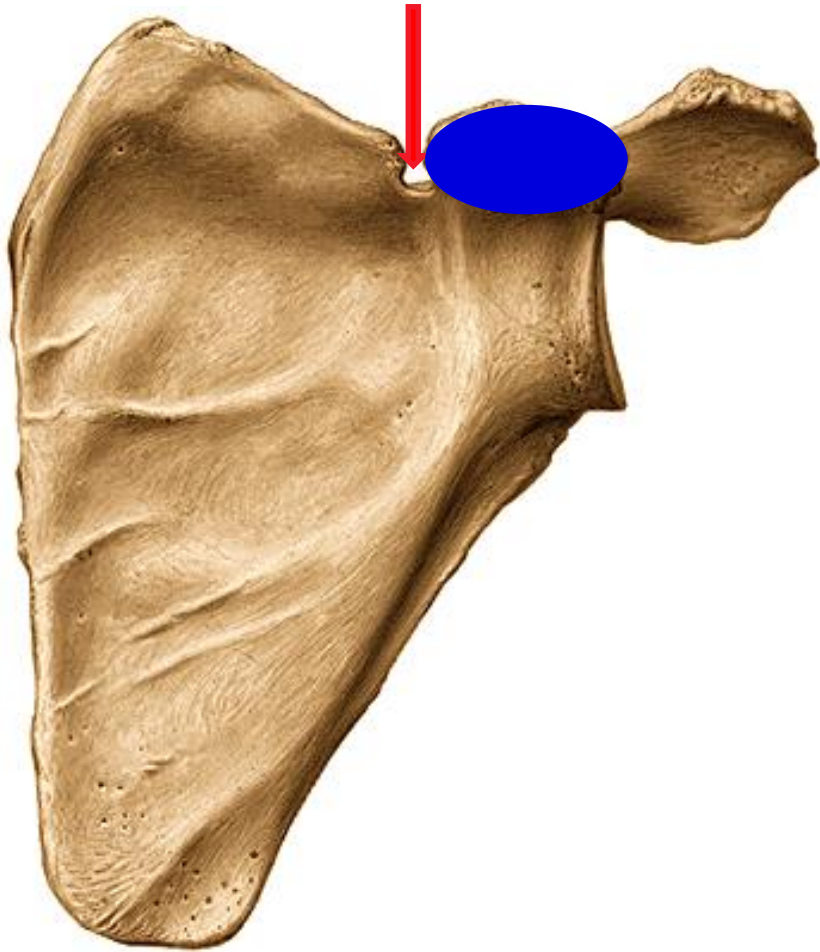
Fossa supraspinata

Fossa infraspinata

Acromion – facies articularis clavicularis

Scapula (shoulder blade)

(left, anterior view)



Margo superior:

Incisura scapulae

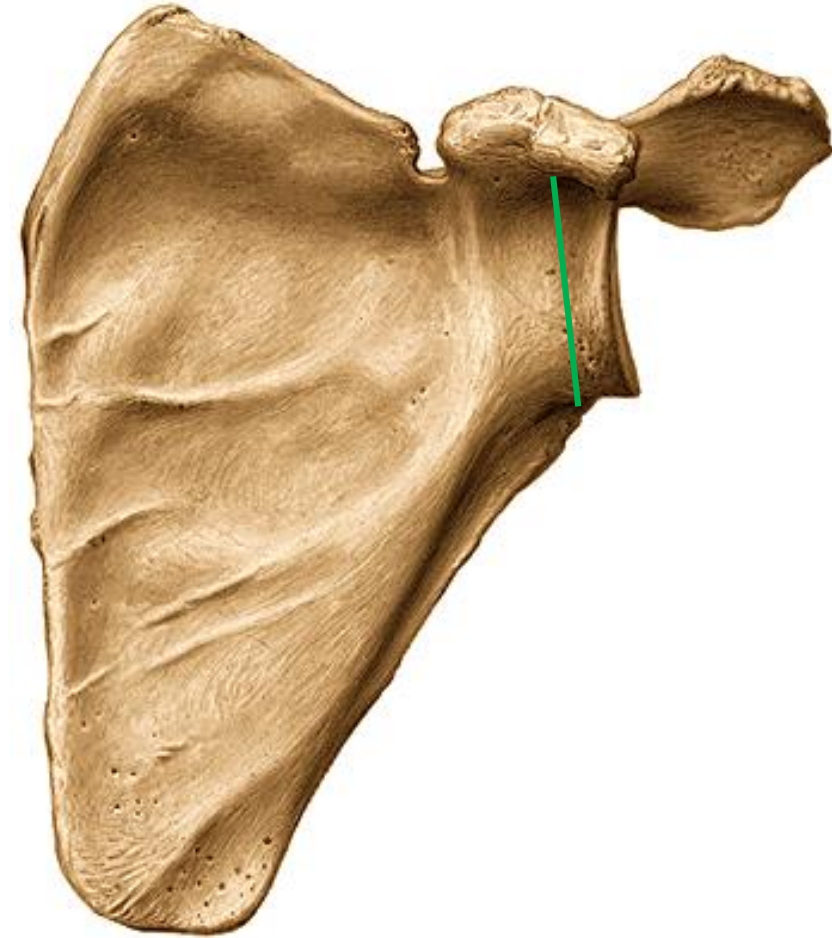
Processus coracoideus

Margo lateralis

Margo medialis

Scapula (shoulder blade)

(left, anterior and lateral view)

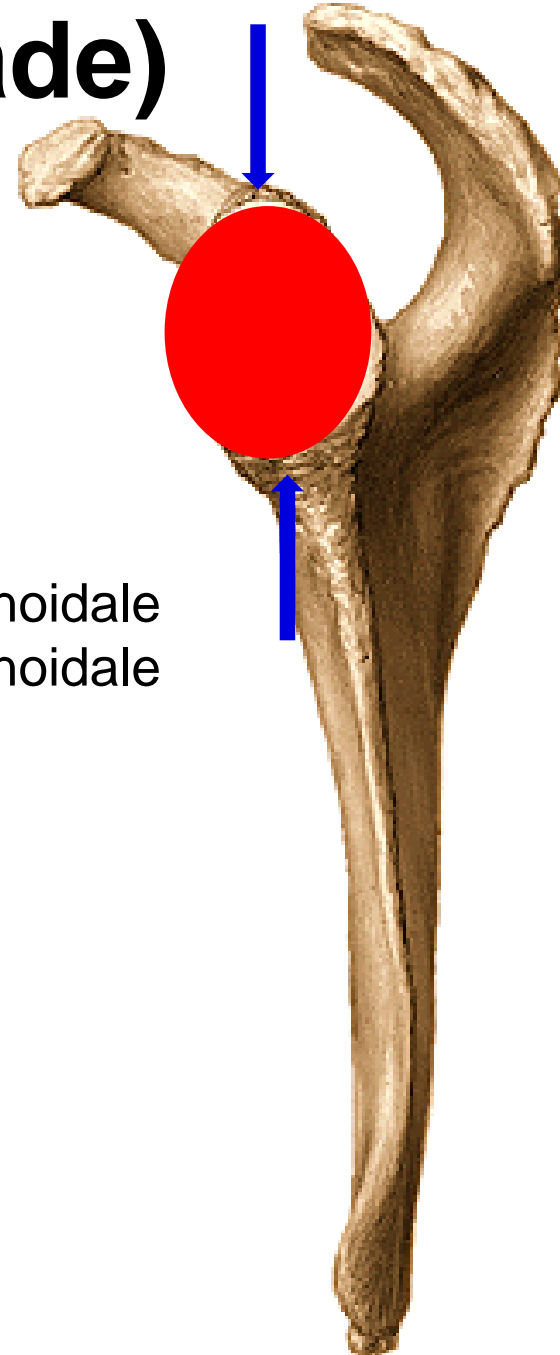


Angulus lateralis:

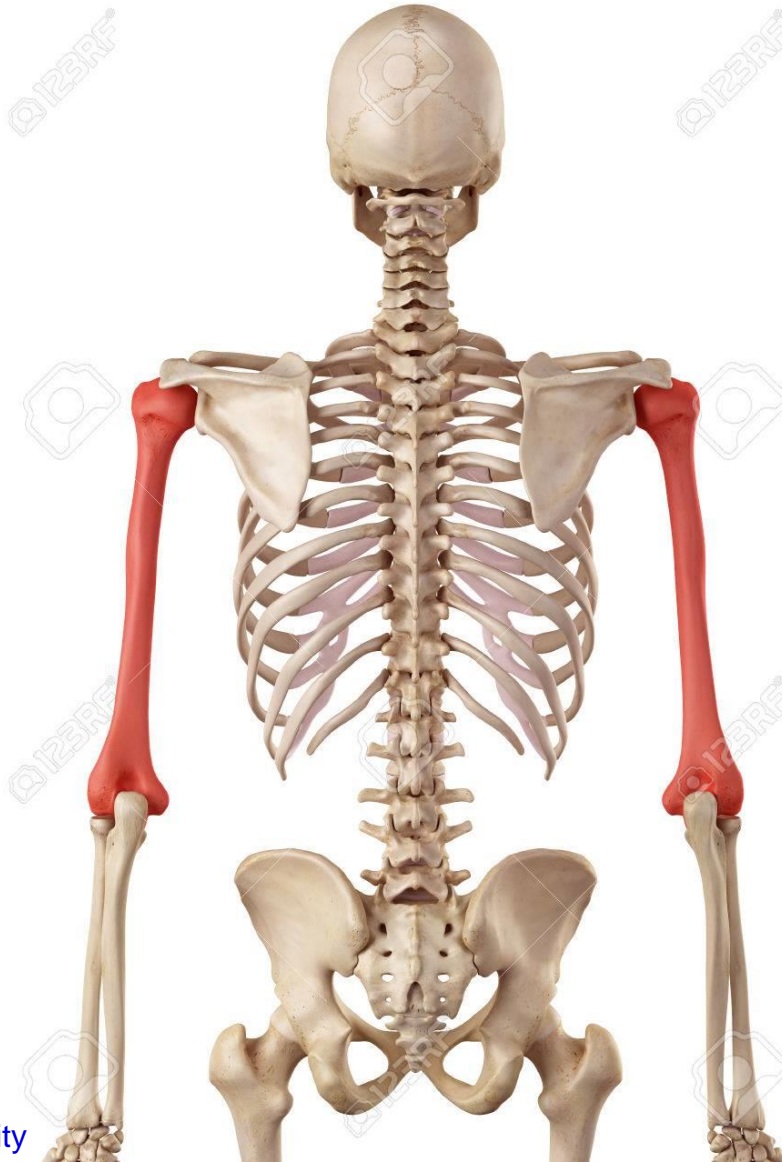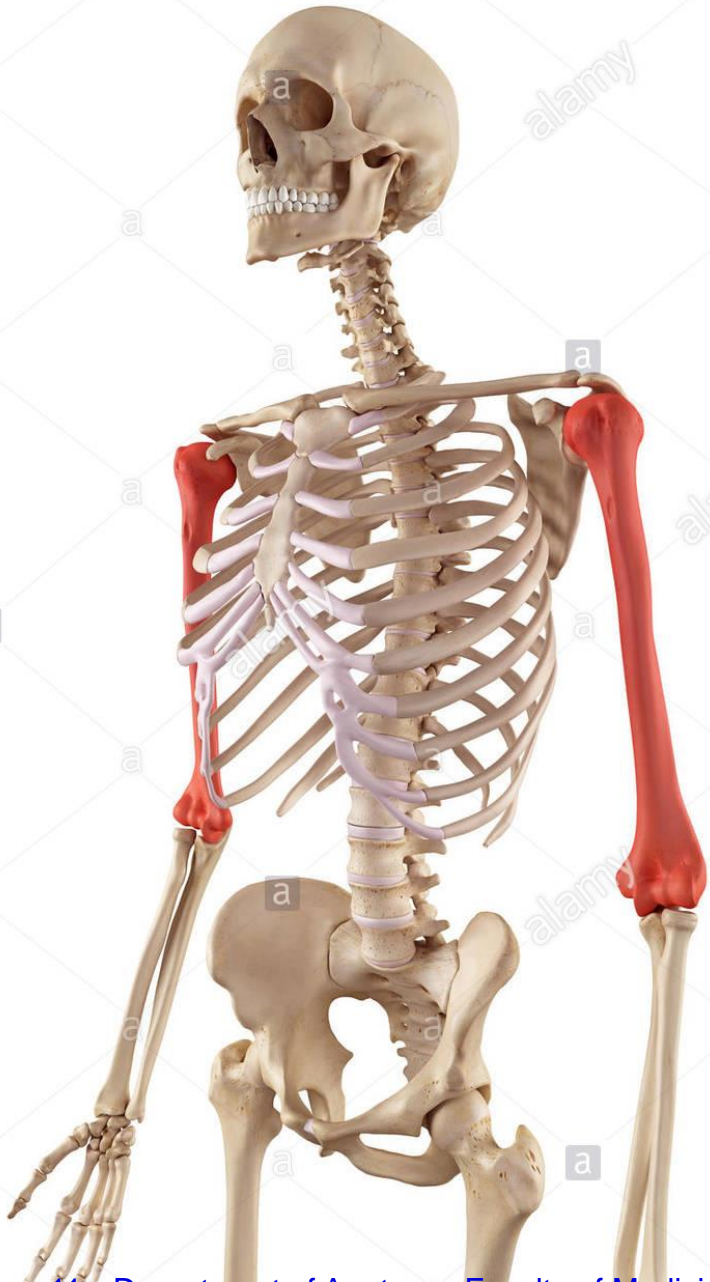Cavitas glenoidalis
Tuberculum supraglenoidale
Tuberculum infraglenoidale
Collum scapulae

Angulus superior

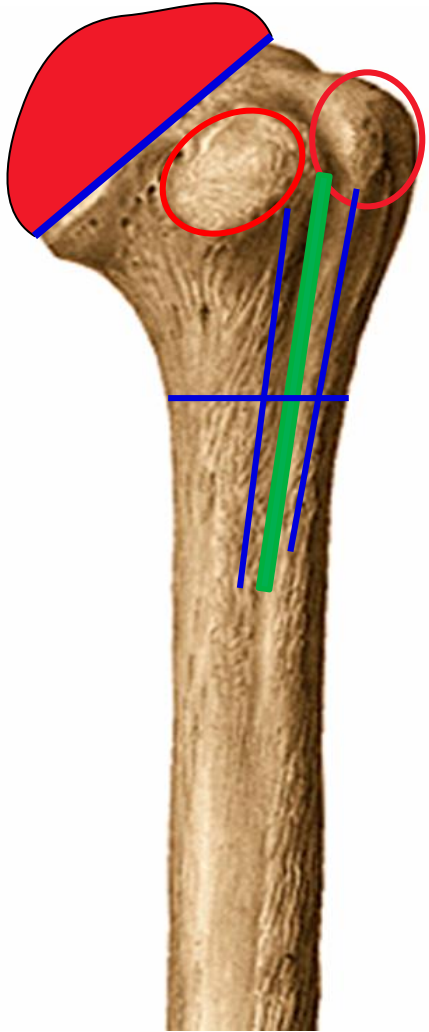
Angulus inferior



Humerus (arm bone)



(left, anterior view)

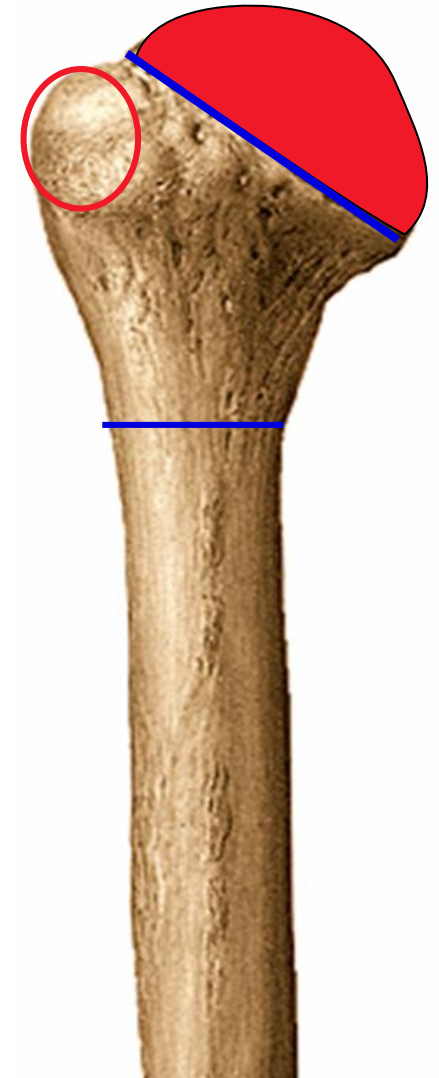


Humerus (arm bone)

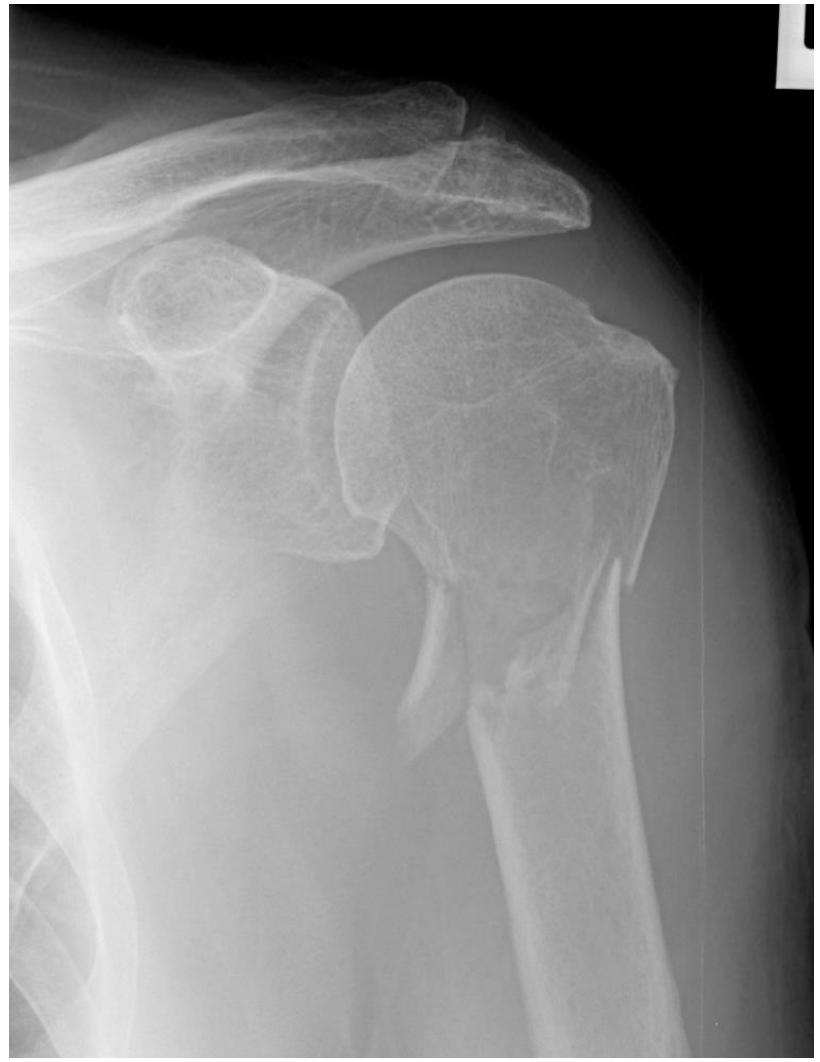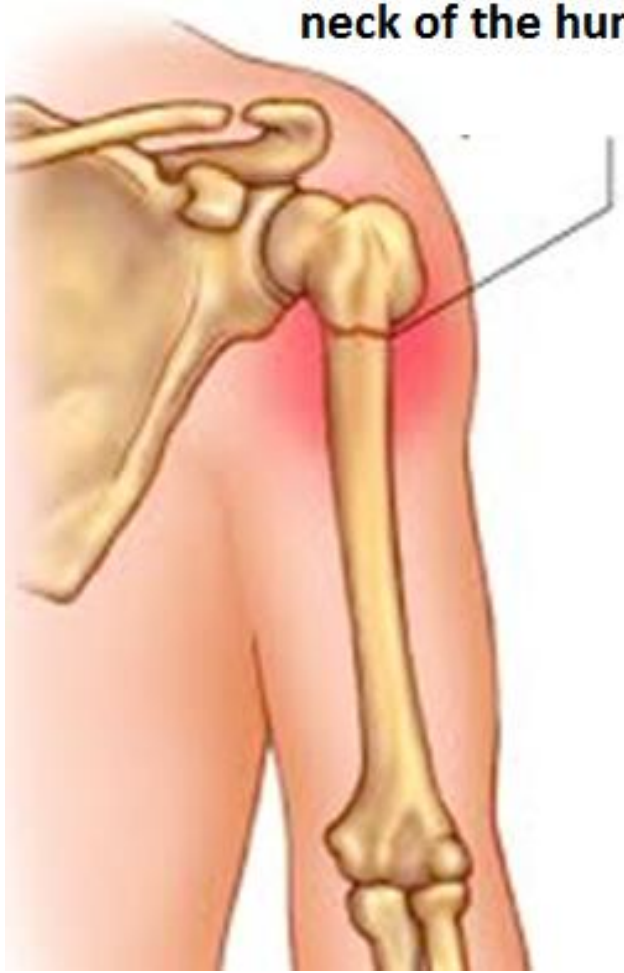Proximal end:

Caput
Collum anatomicum
Tuberculum majus
Tuberculum minus
Crista tuberculi majoris
Crista tuberculi minoris
Sulcus intertubercularis
Collum chirurgicum

(left, posterior view)



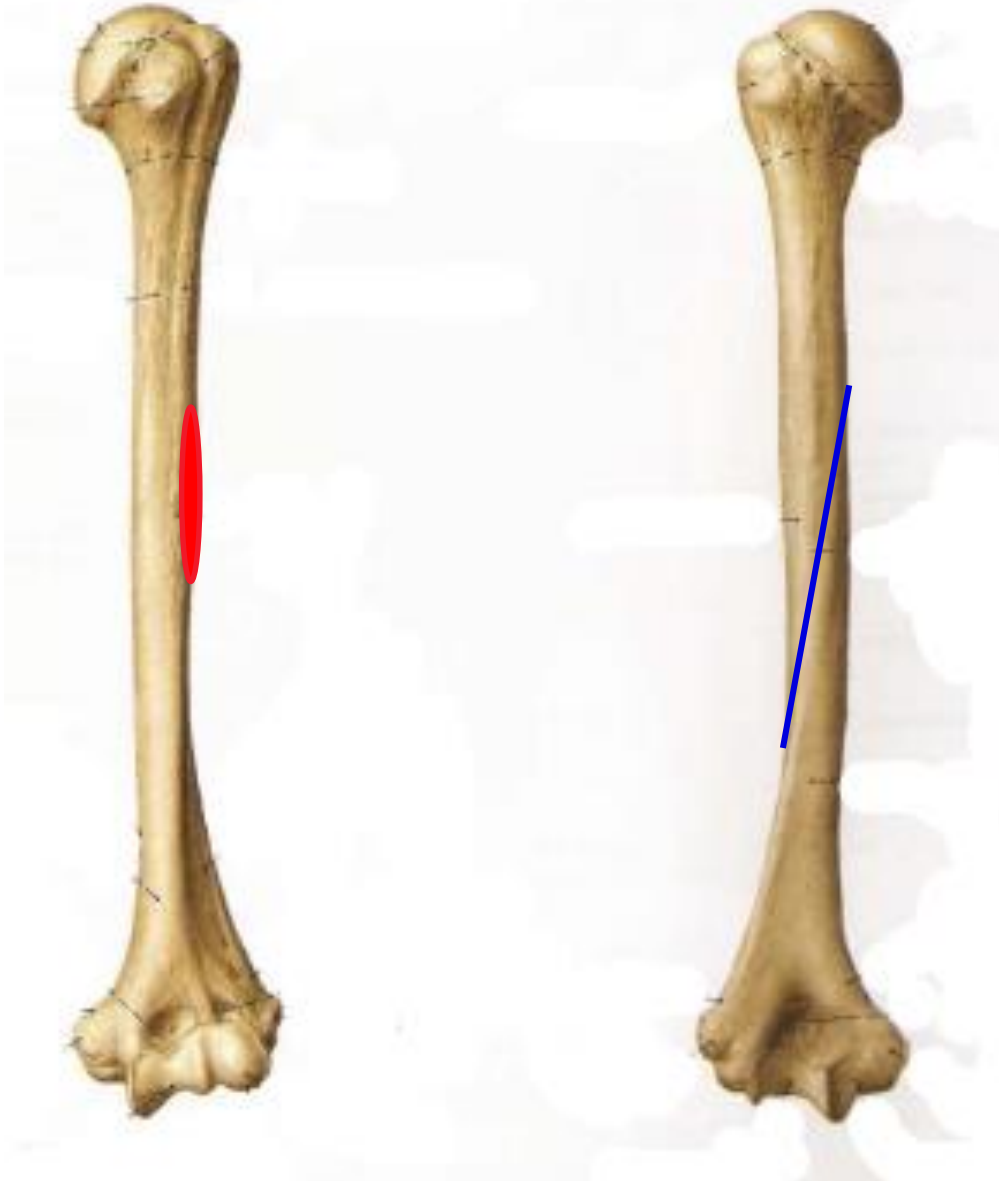
Fracture of the surgical neck of the humerus



(left, anterior view)

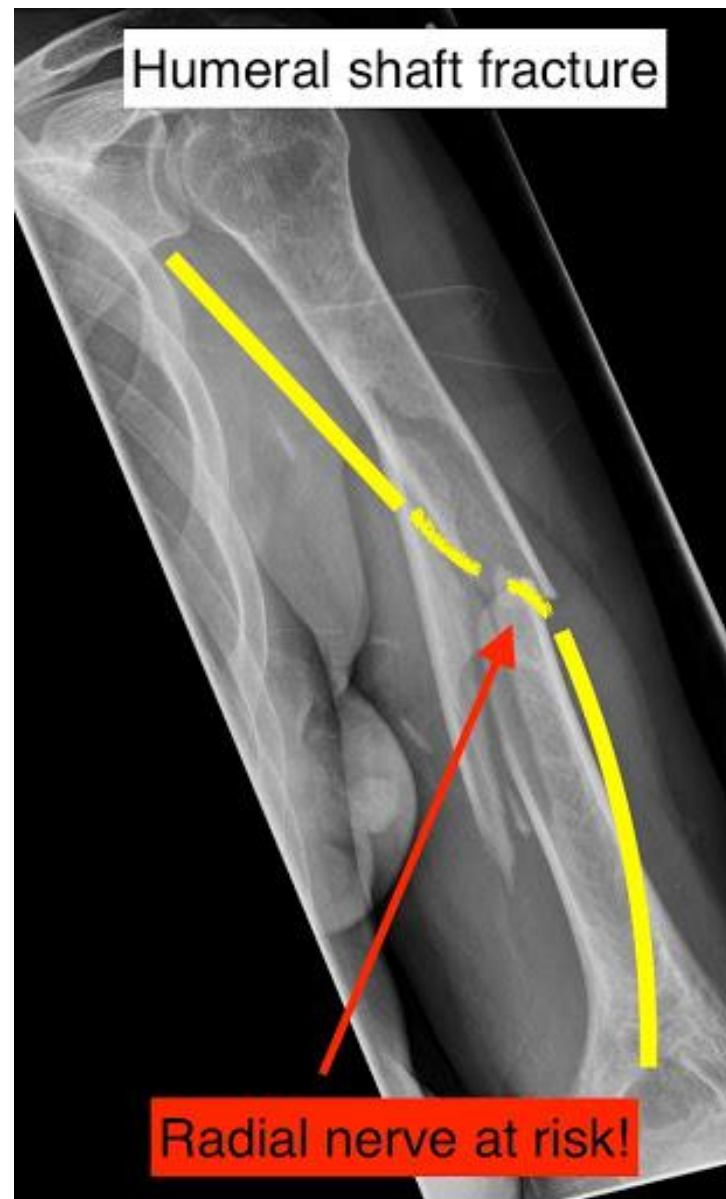(left, posterior view)

Humerus (arm bone)



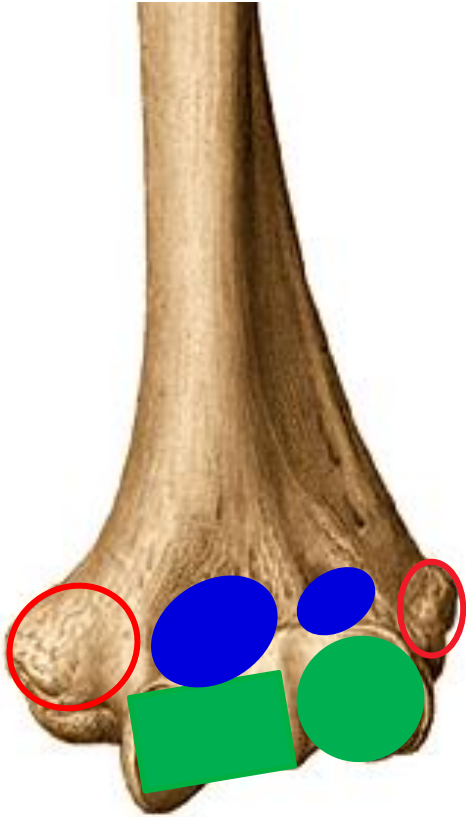
Corpus:

Tuberositas deltoidea
Sulcus nervi radialis

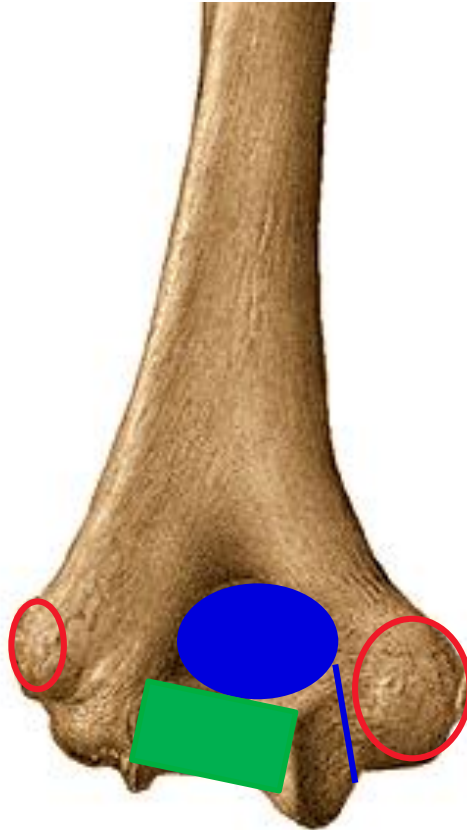


Humerus (arm bone)

(left, anterior view)

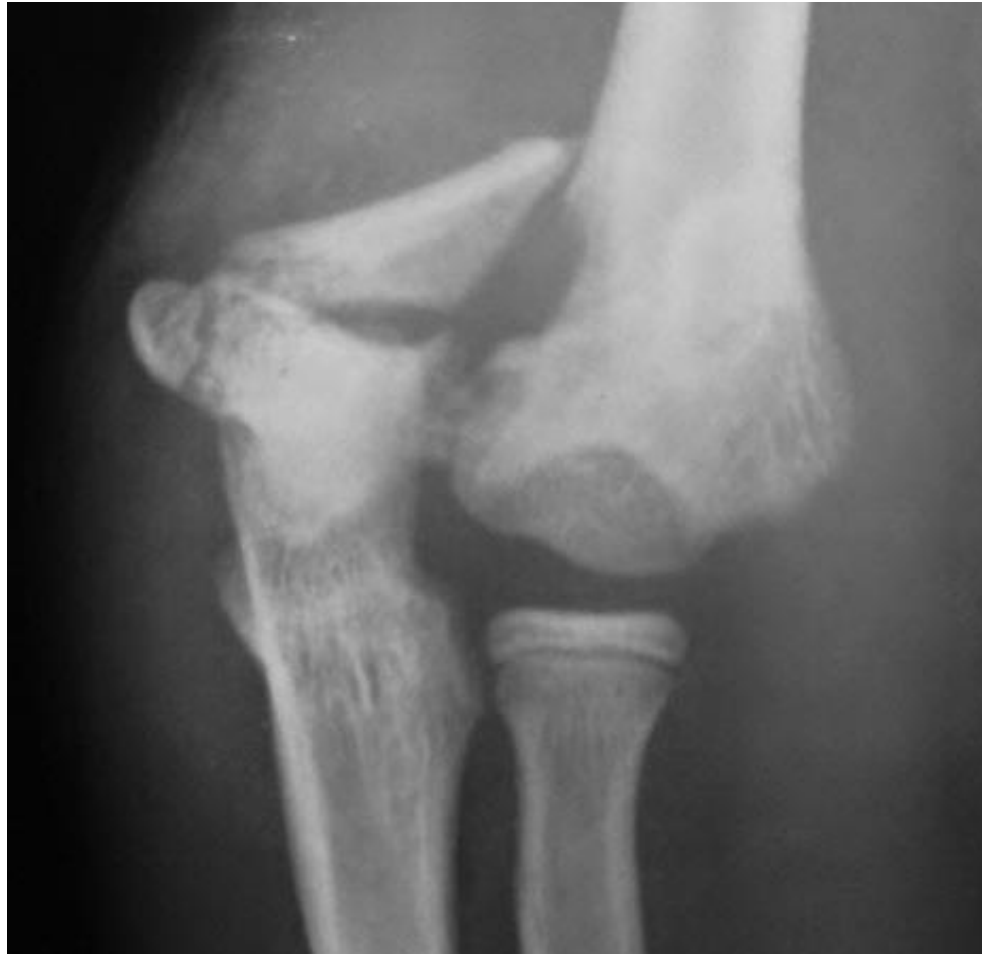
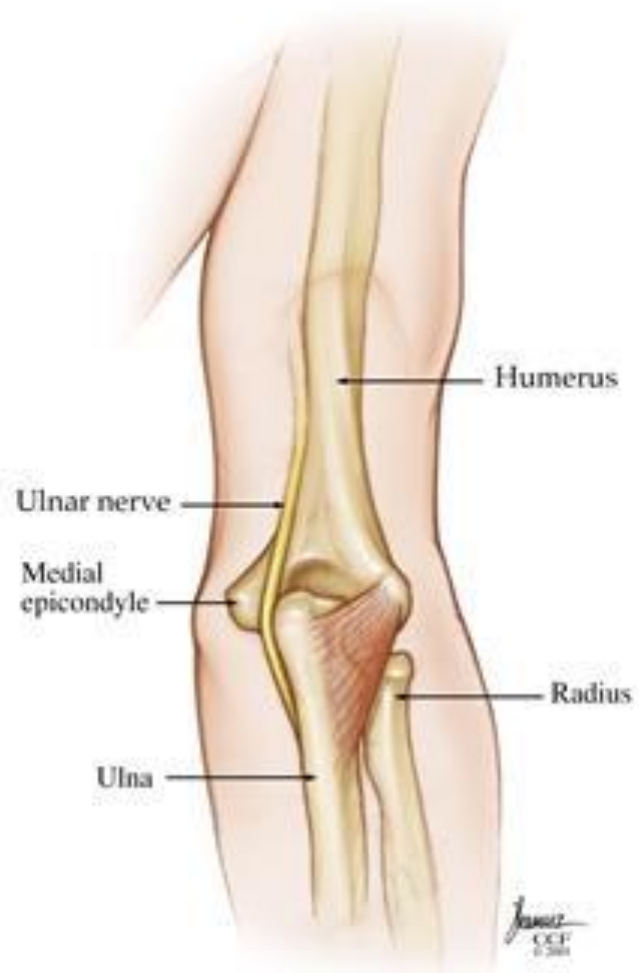
(left, posterior view)

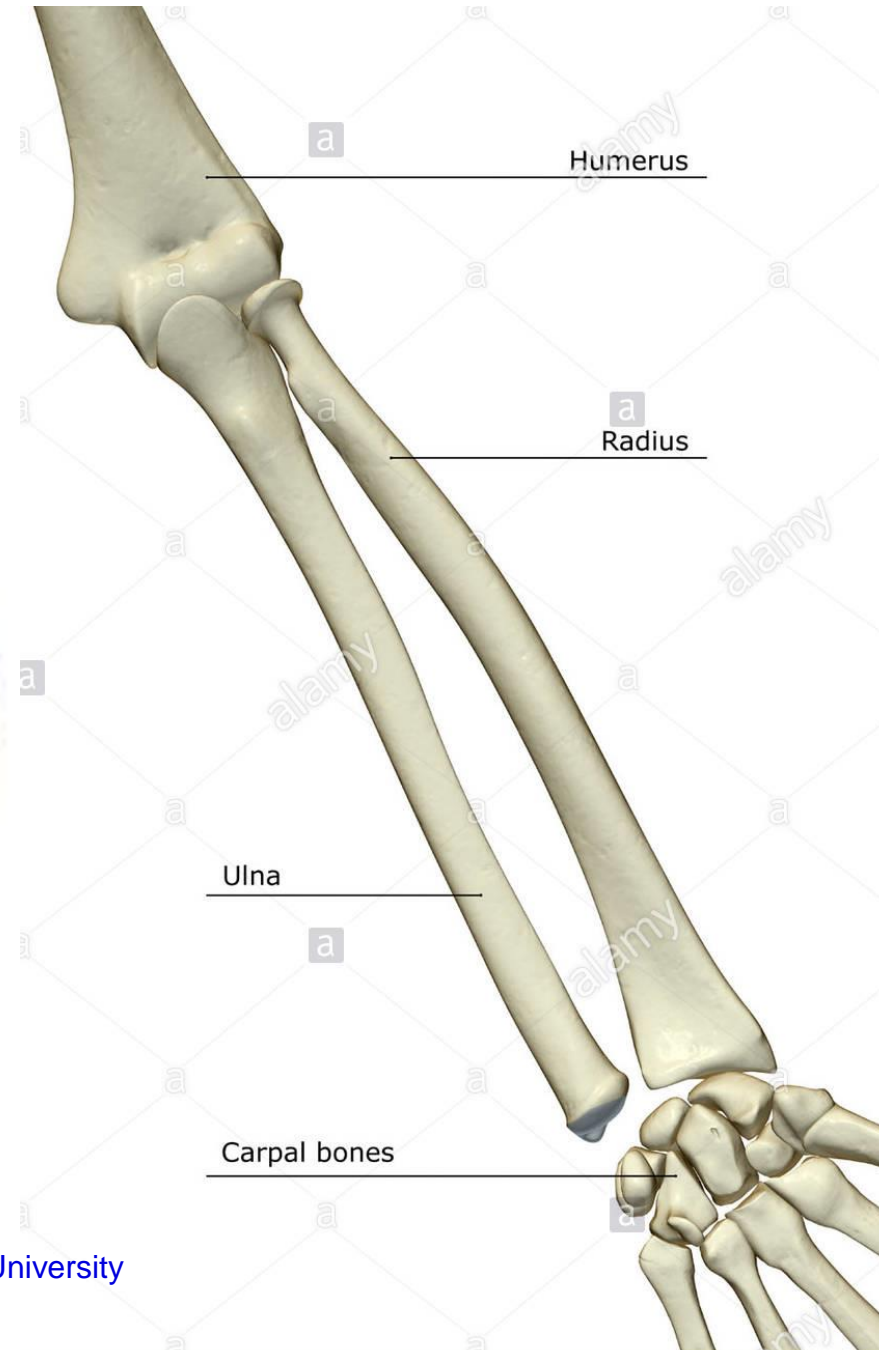
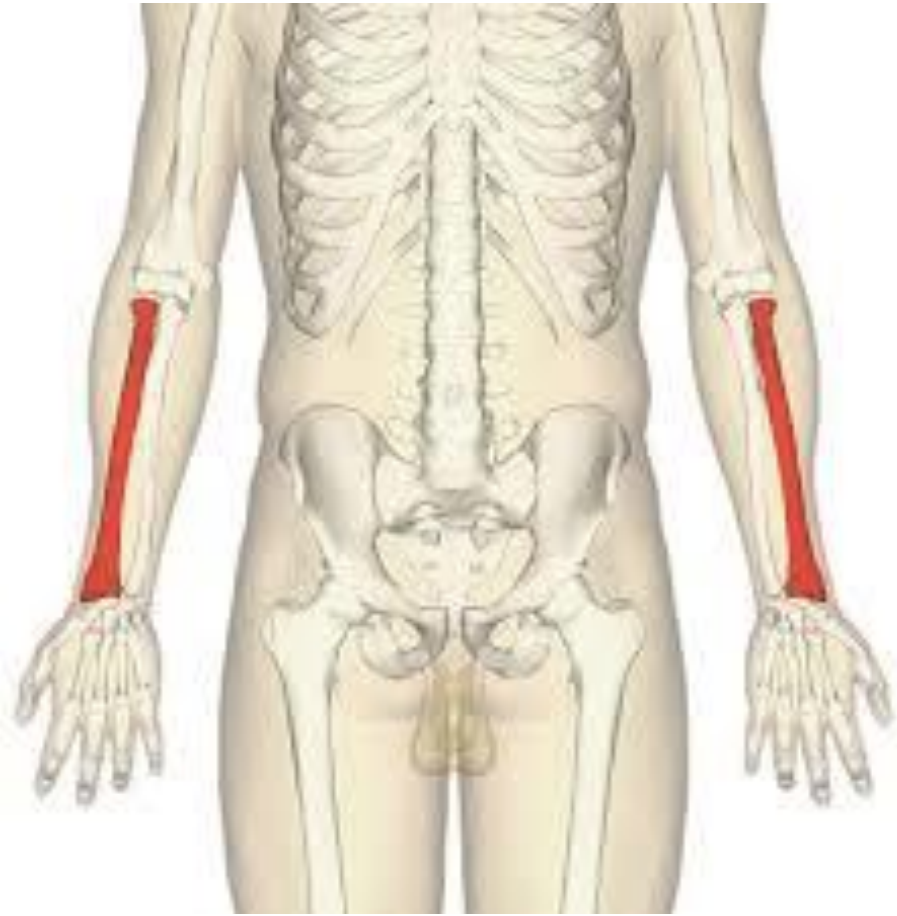

Distal end:

Trochlea humeri
Capitulum humeri
Epicondylus medialis
Epicondylus lateralis
Fossa coronoidea
Fossa radialis
Fossa olecrani
Sulcus nervi ulnaris




Radius



Radius


(left,
anterior view)



(left,
posterior view)



(left,
medial view)



Proximal end:

Caput radii

Circumferentia articularis capitis

Collum radii

Tuberositas radii

(left,
anterior view)



(left,
medial view)



Radius

Corpus radii:

Margo interosseus

Radius

(left,
anterior view)



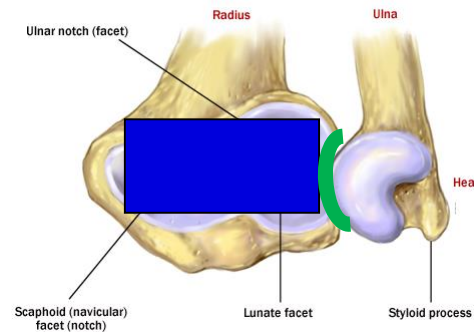
(left,
posterior view)



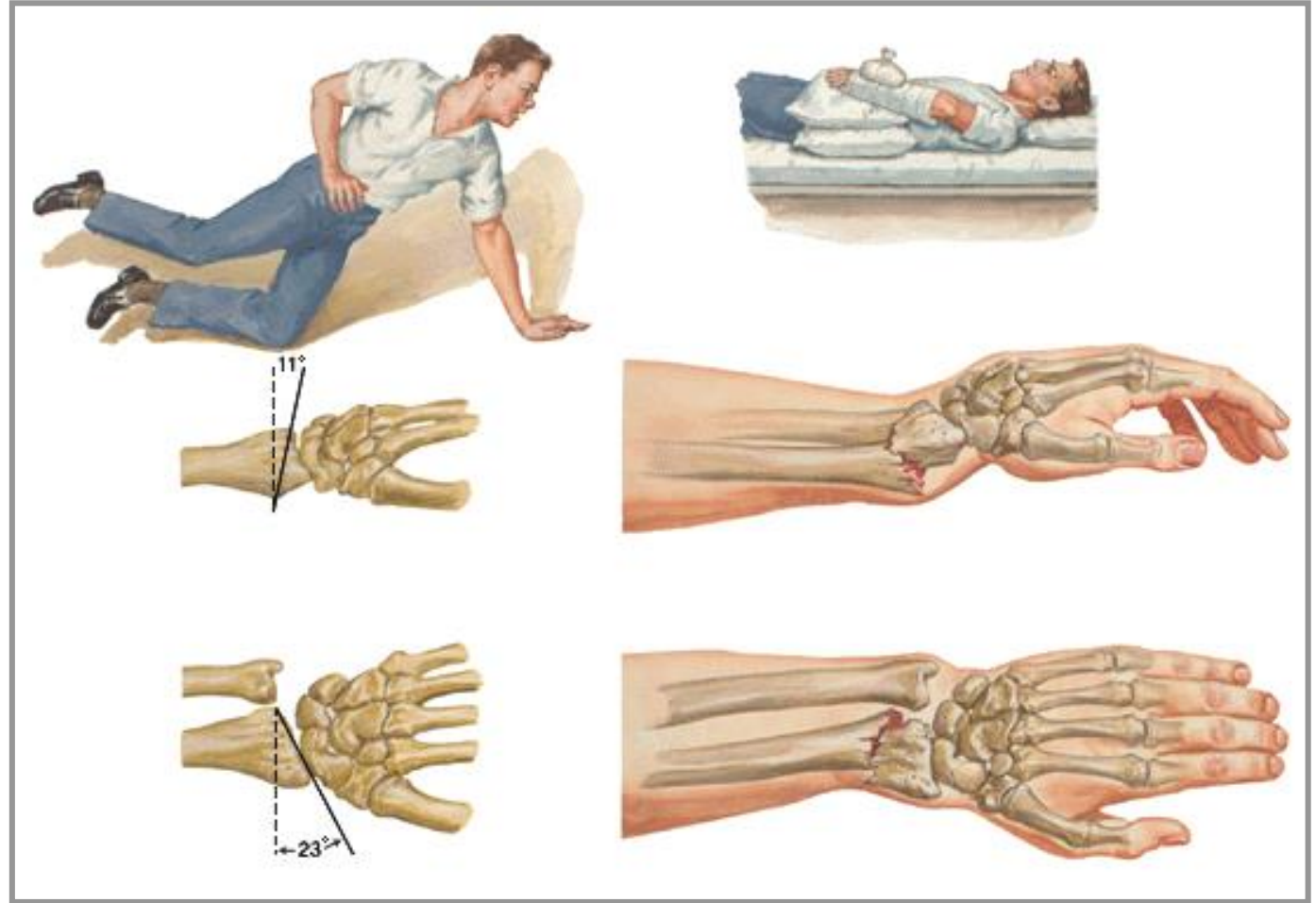
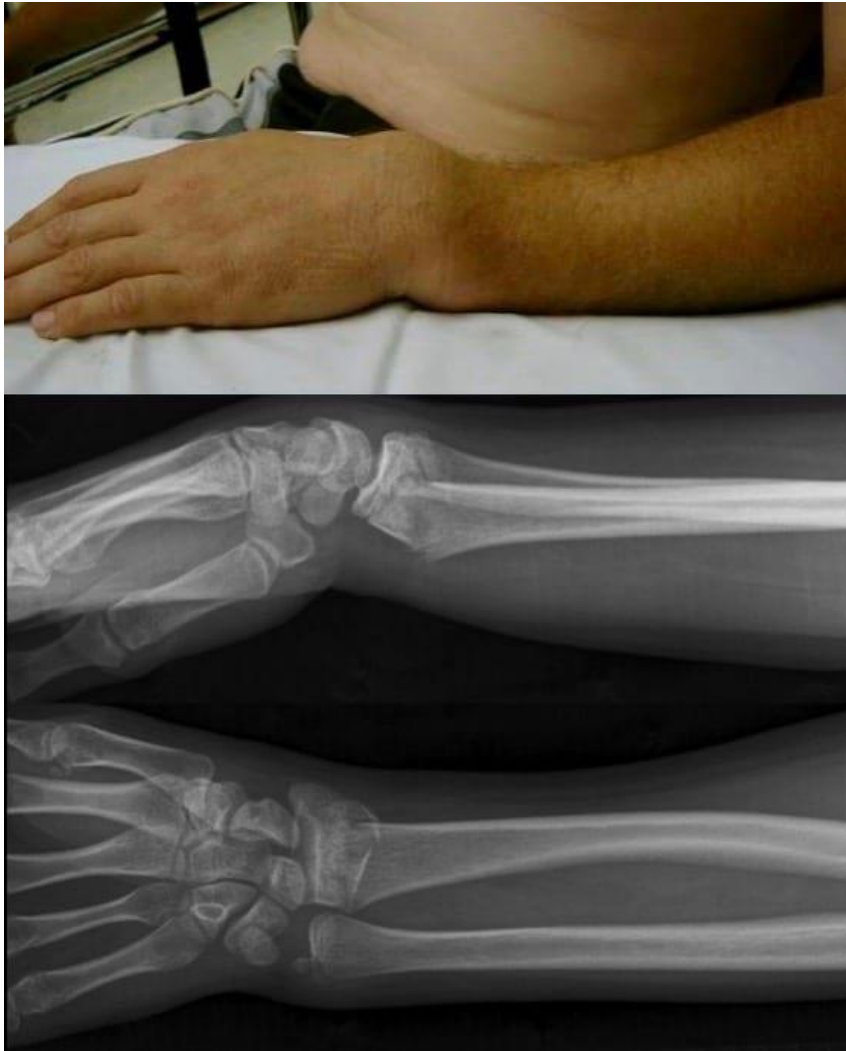Distal end:

- Processus styloideus radii
- Facies articularis carpalis radii
- Incisura ulnaris radii

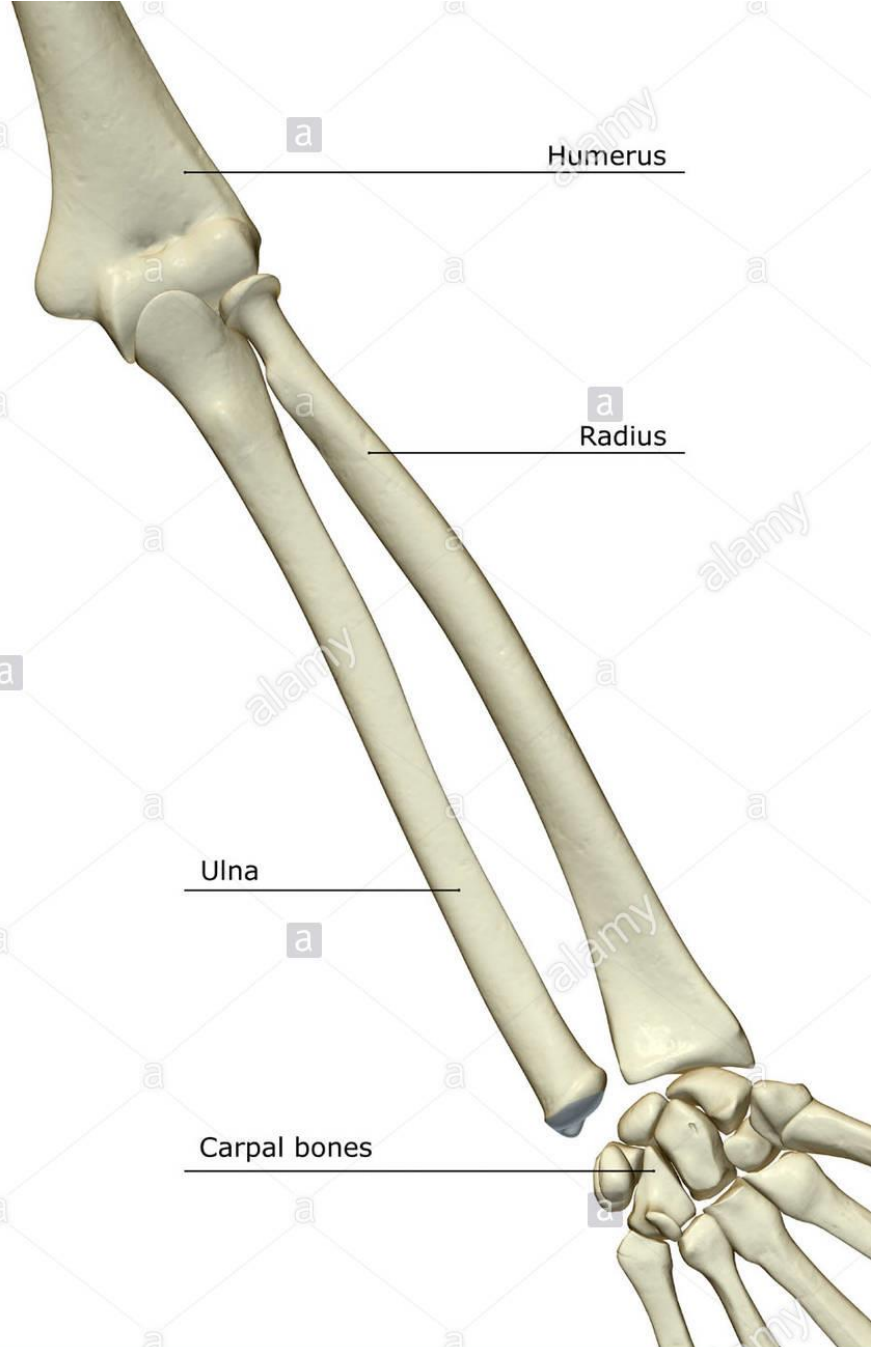
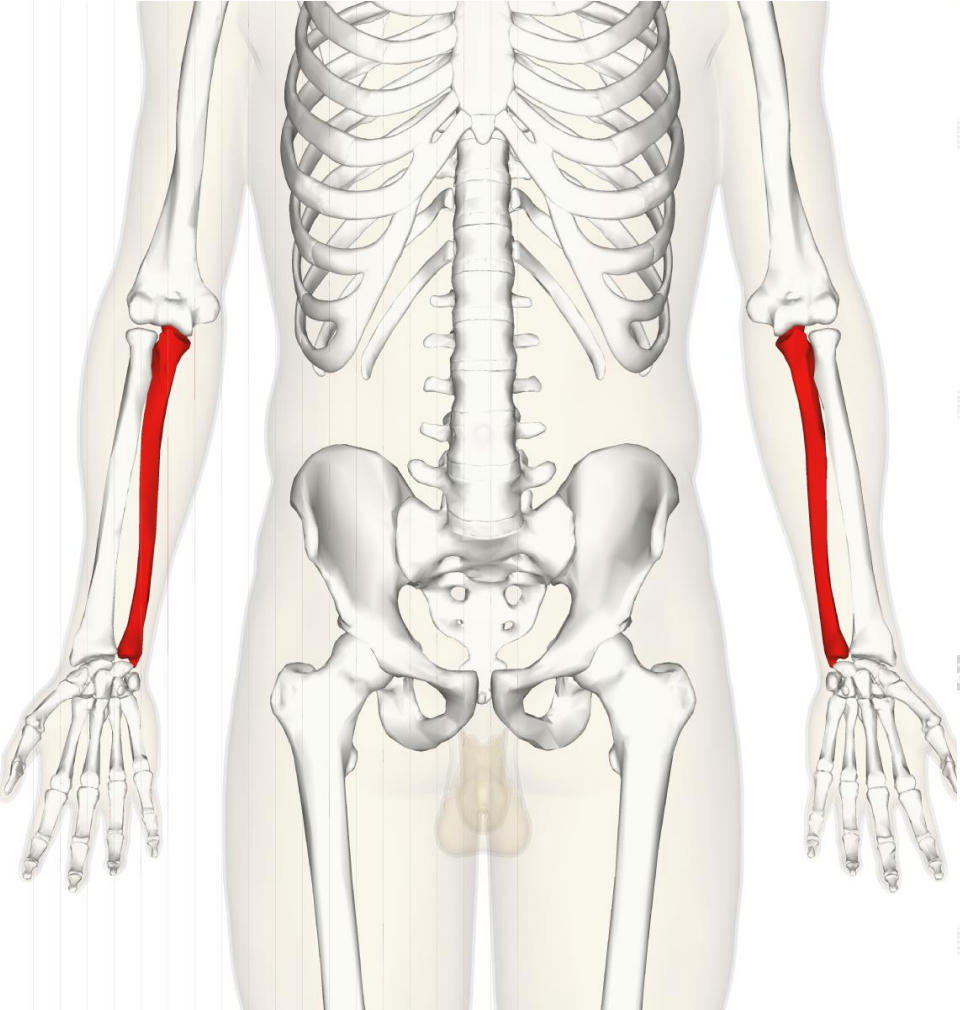
(right, distal view)



Colles fracture




Ulna



Ulna

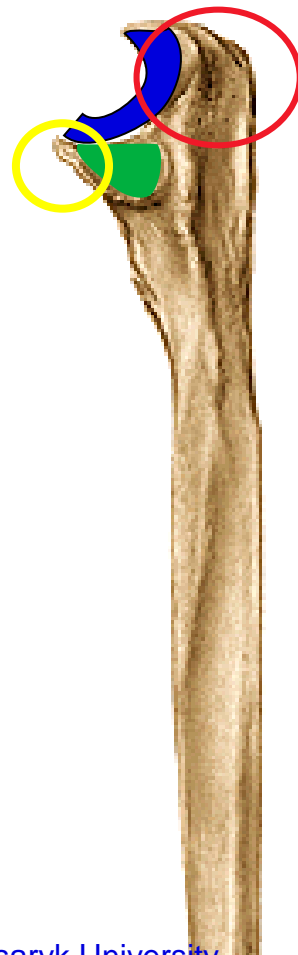(left,
anterior view)



(left,
posterior view)



(left,
lateral view)



Proximal end:

Olecranon ulnae
Processus coronoideus
Incisura trochlearis
Incisura radialis ulnae

(left,
anterior view)



(left,
lateral view)



Ulna

Corpus ulnae:

Margo interosseus

Ulna

Distal end:

Caput ulnae


Circumferentia articularis capitis ulnae

Processus styloideus

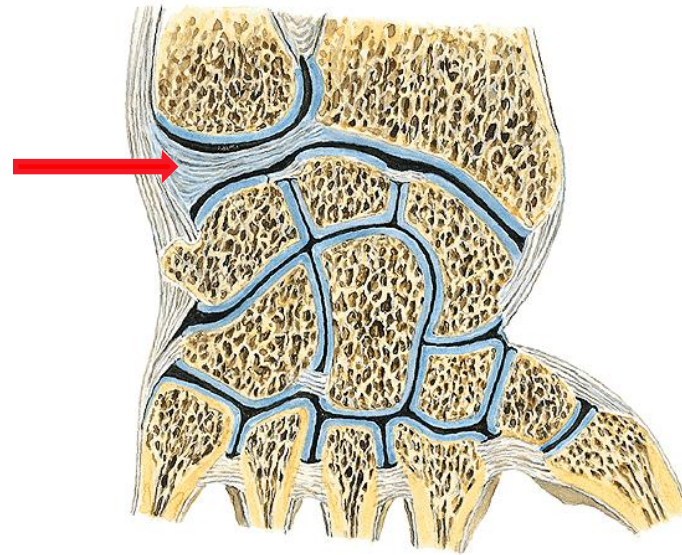
(left, anterior view)



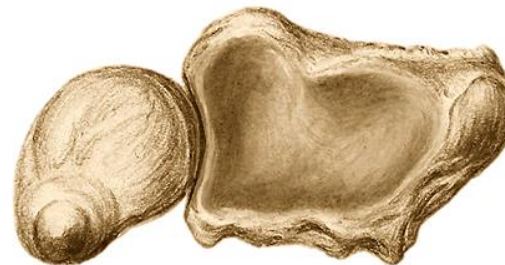(left, posterior view)



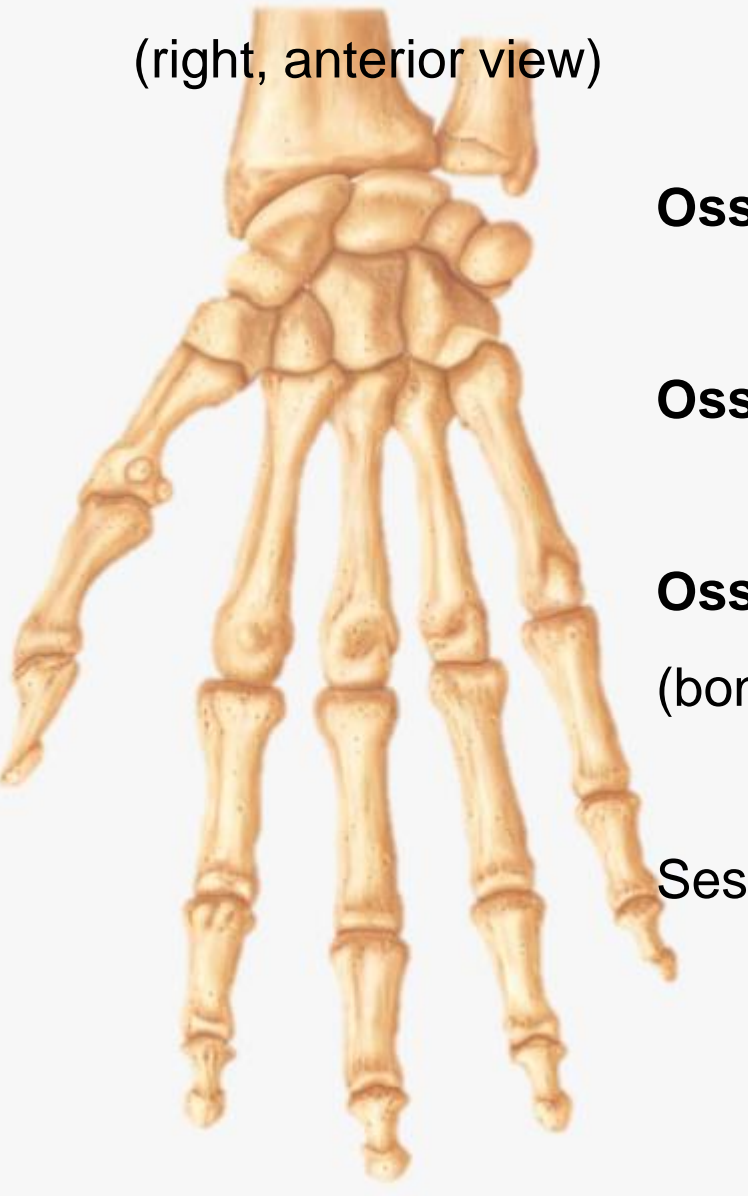(left, lateral view)



(left, distal view)



(right, anterior view)



Bones of the hand

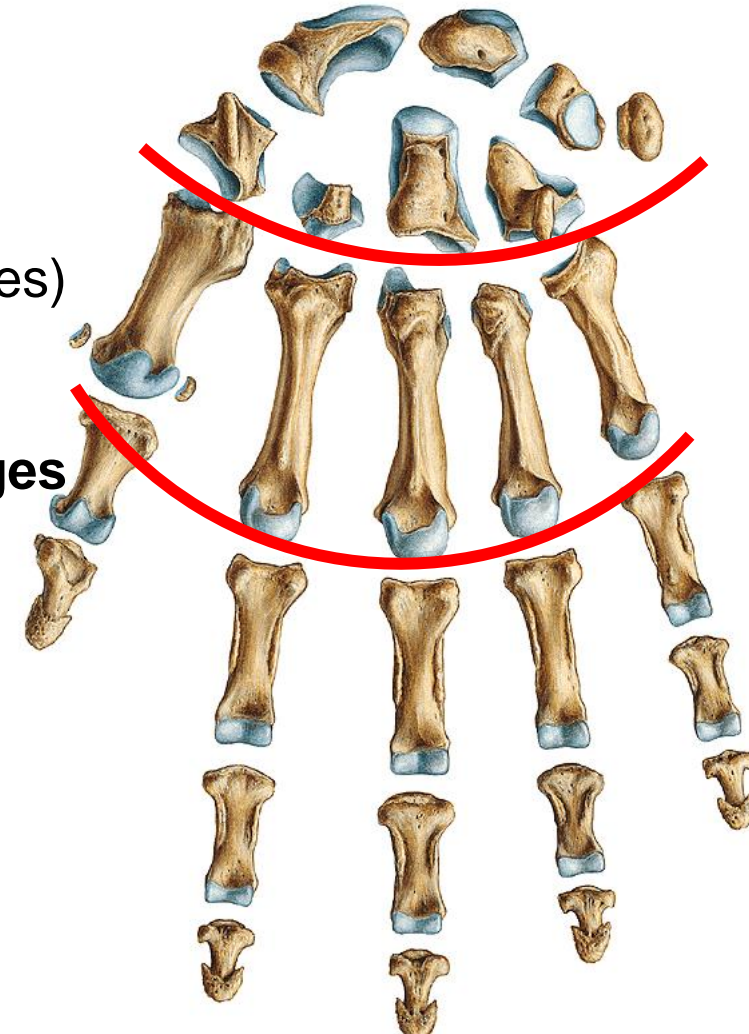
(right, anterior view)

Ossa carpi (bones of the wrist)

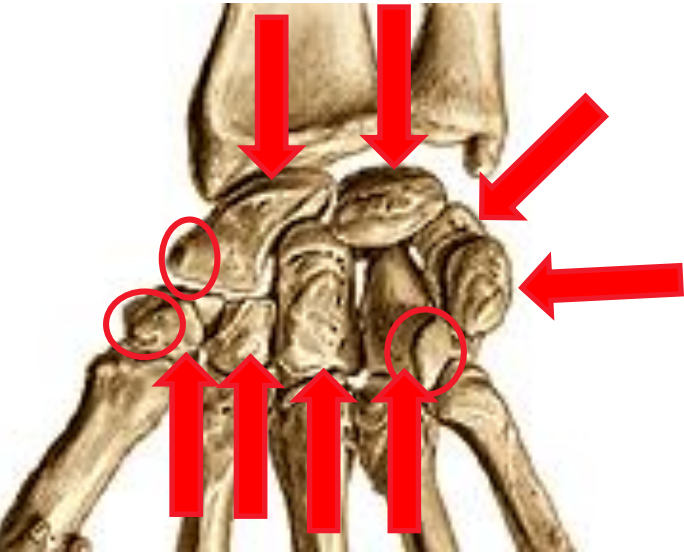
Ossa metacarpi (metacarpal bones)

Ossa digitorum manus, phalanges
(bones of digits)

Sesamoid bones



(right, anterior view)



Ossa carpi

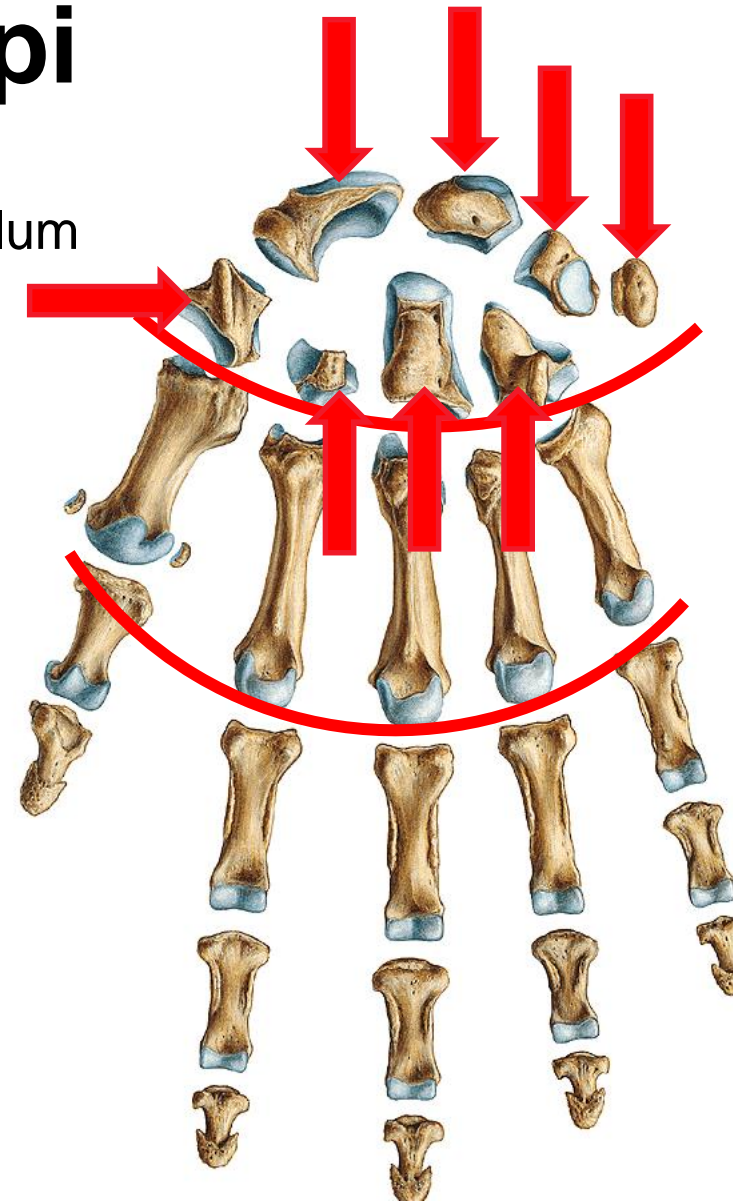
Proximal row:

- Os scaphoideum - tuberculum
- Os lunatum
- Os triquetrum
- Os pisiforme

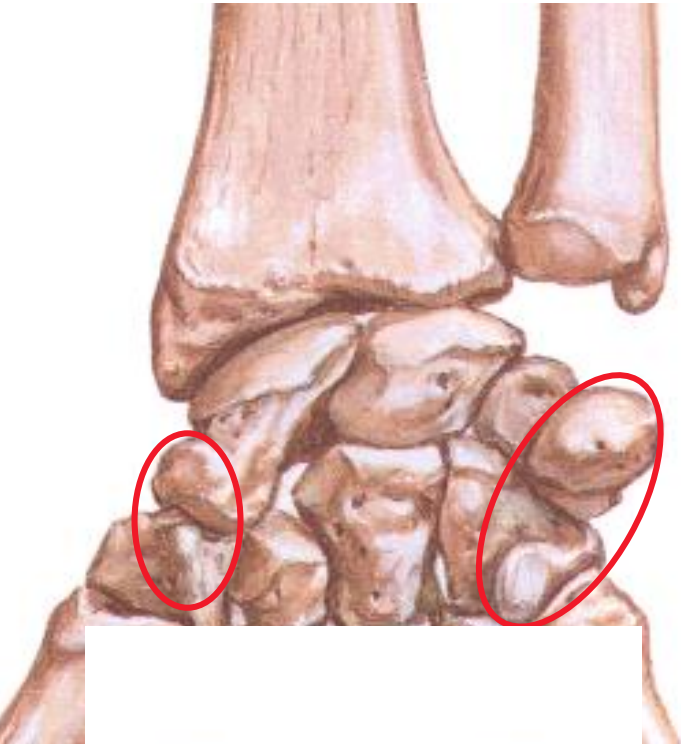
Distal row:

- Os trapezium - tuberculum
- Os trapezoideum
- Os capitatum
- Os hamatum - hamulus

(right, anterior view)



(right, anterior view)



Carpal arch

Sulcus carpi

Eminentia carpi radialis:

Tuberculum ossis scaphoidei

Tuberculum ossis trapezii

Eminentia carpi ulnaris:

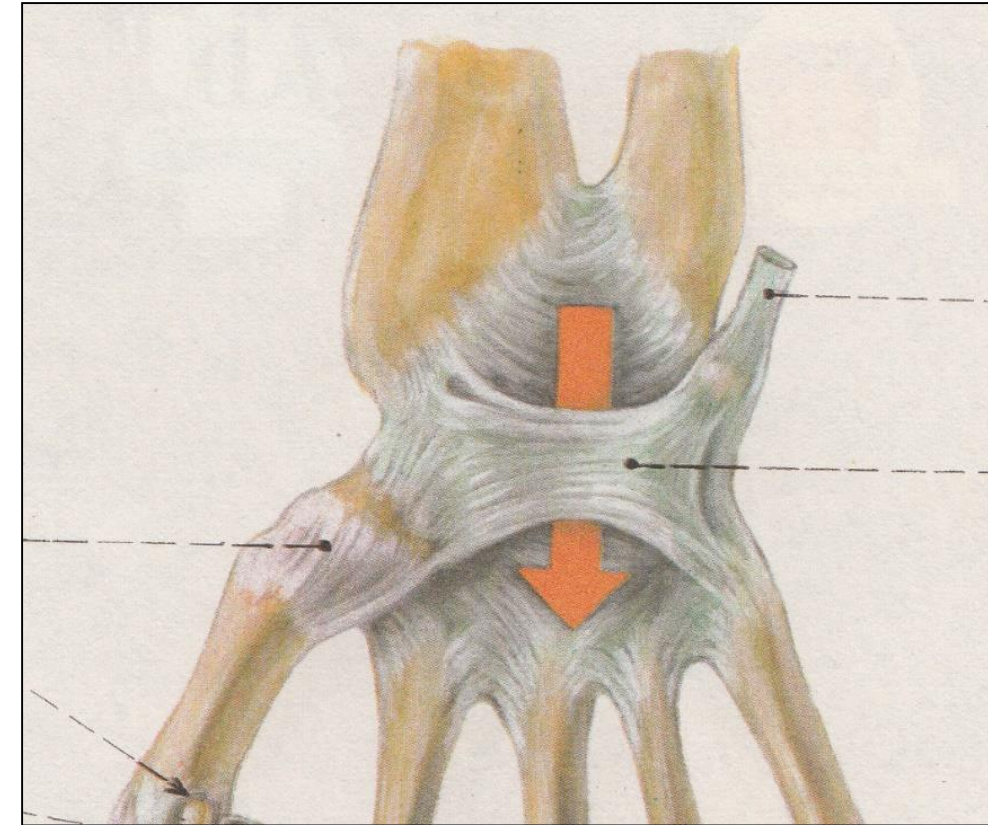
Os pisiforme

Hamulus ossis hamati

Retinaculum flexorum

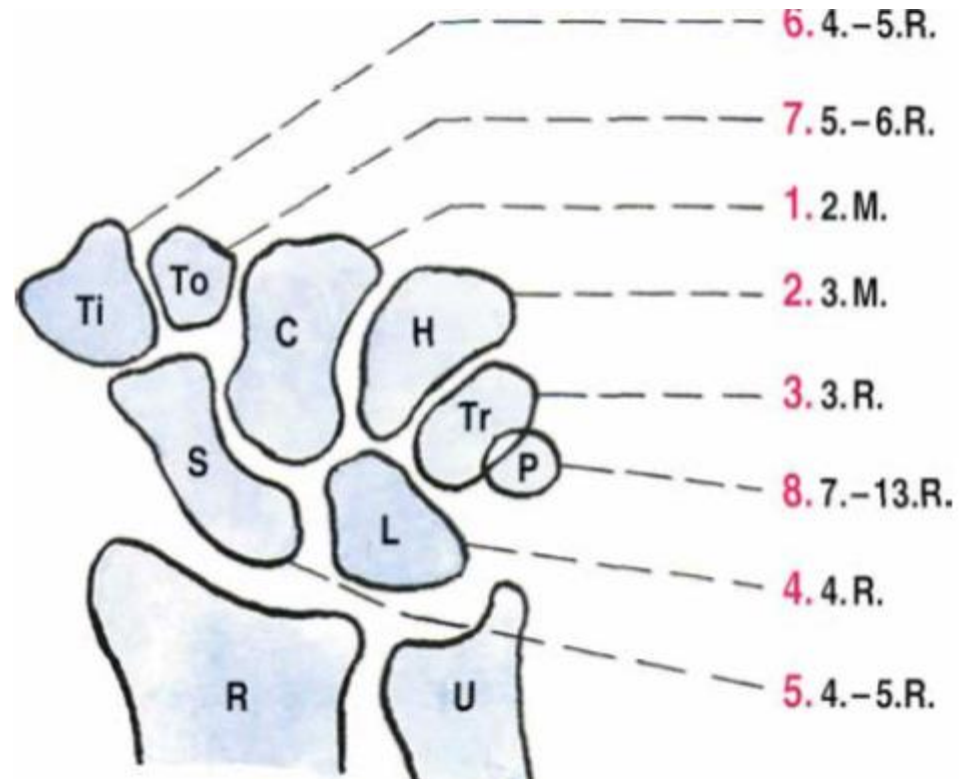
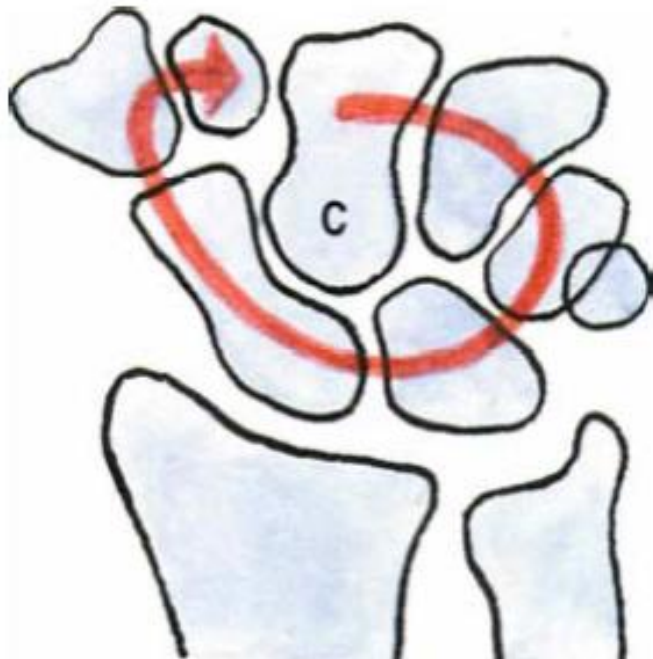→ canalis carpi

(right, anterior view)



Ossification of carpal bones

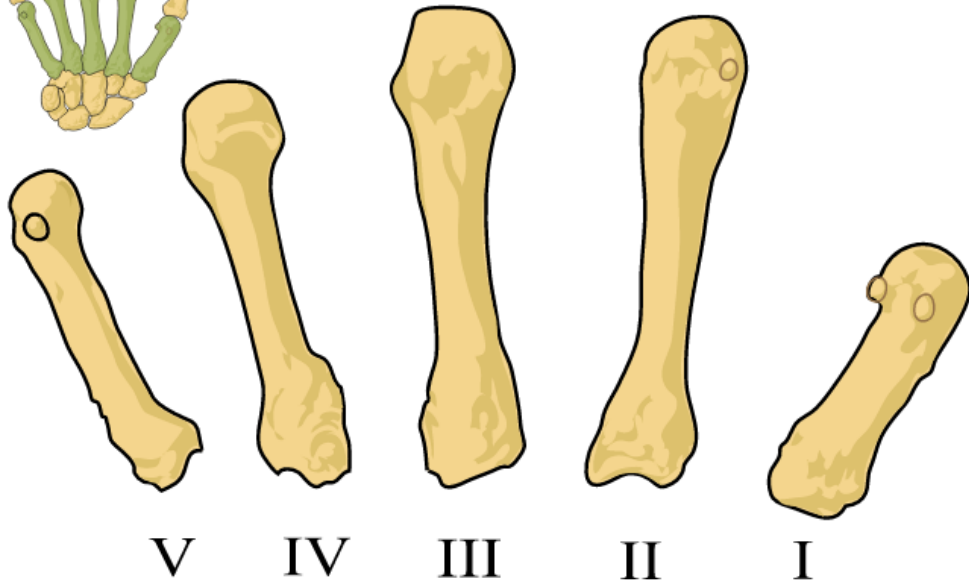
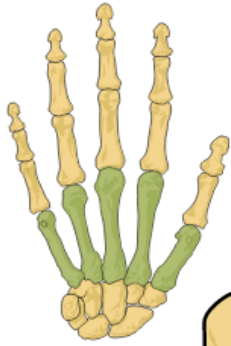
(left, anterior view)



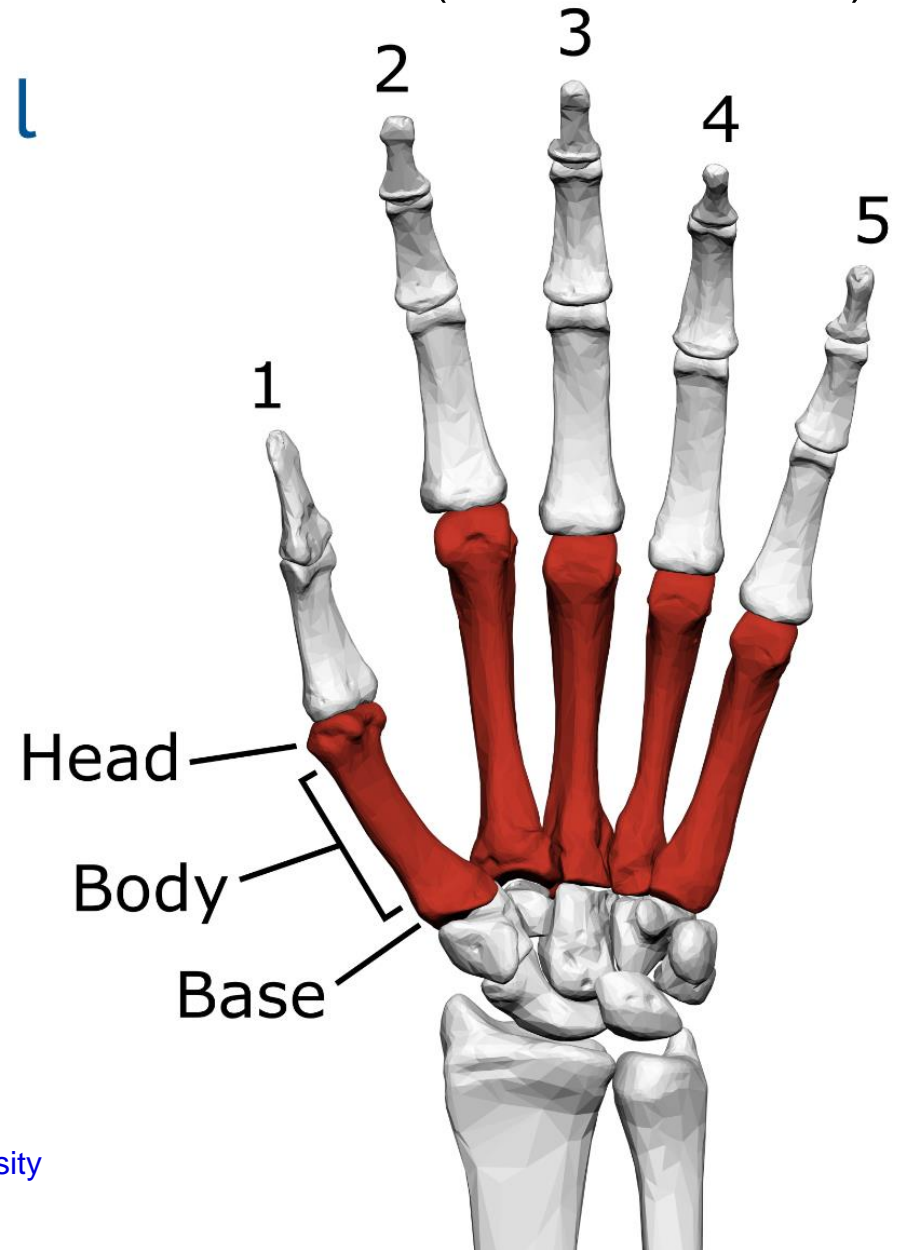
(right, anterior view)

Ossa metacarpi

(left, anterior view)



l



Phalanges

Tuberositas phalangis distalis (right, anterior view)

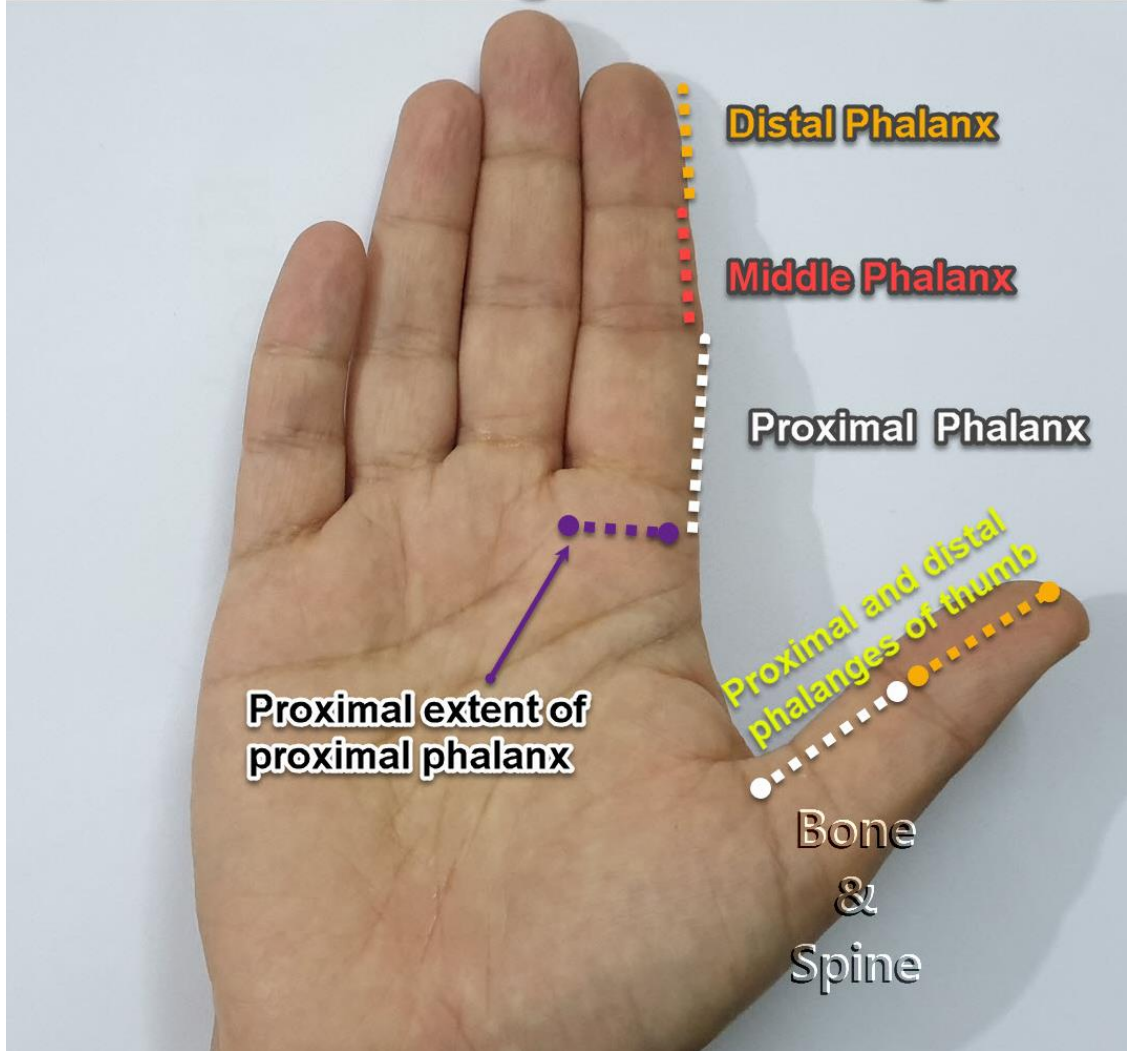
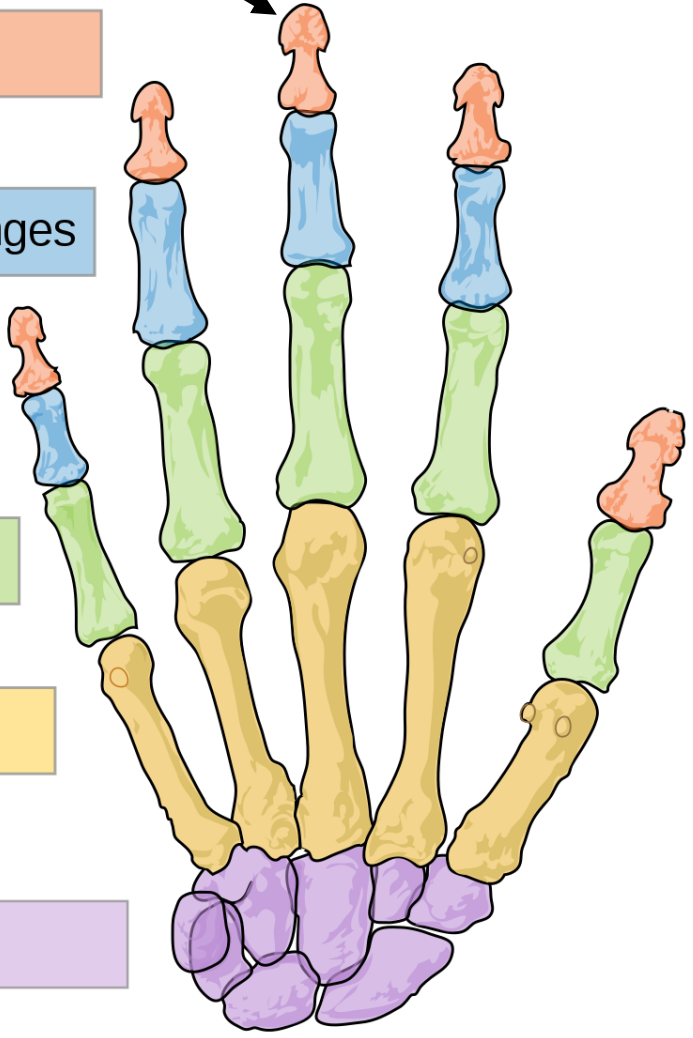
Distal phalanges

Intermediate phalanges

Proximal phalanges

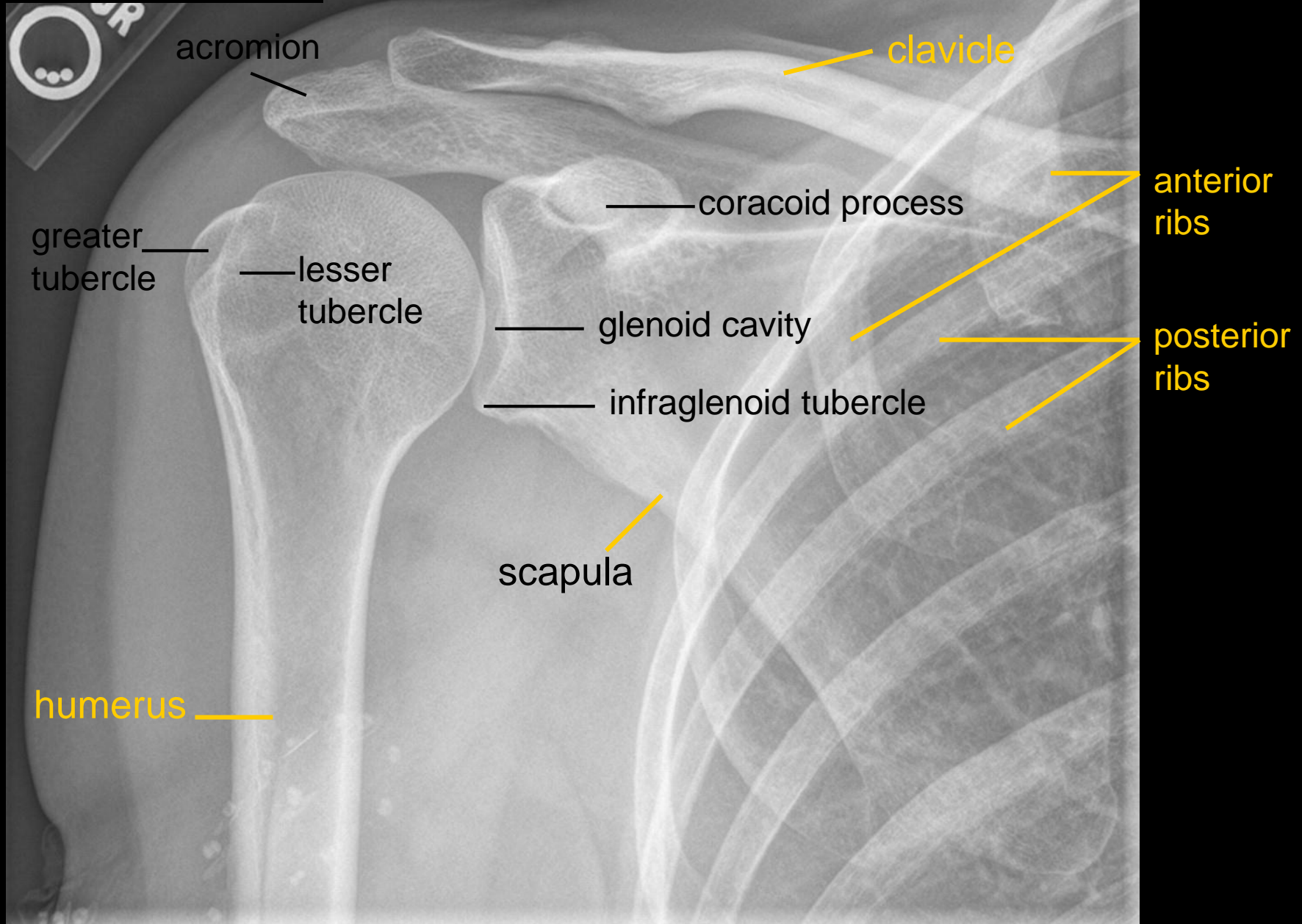
Metacarpals

Carpals



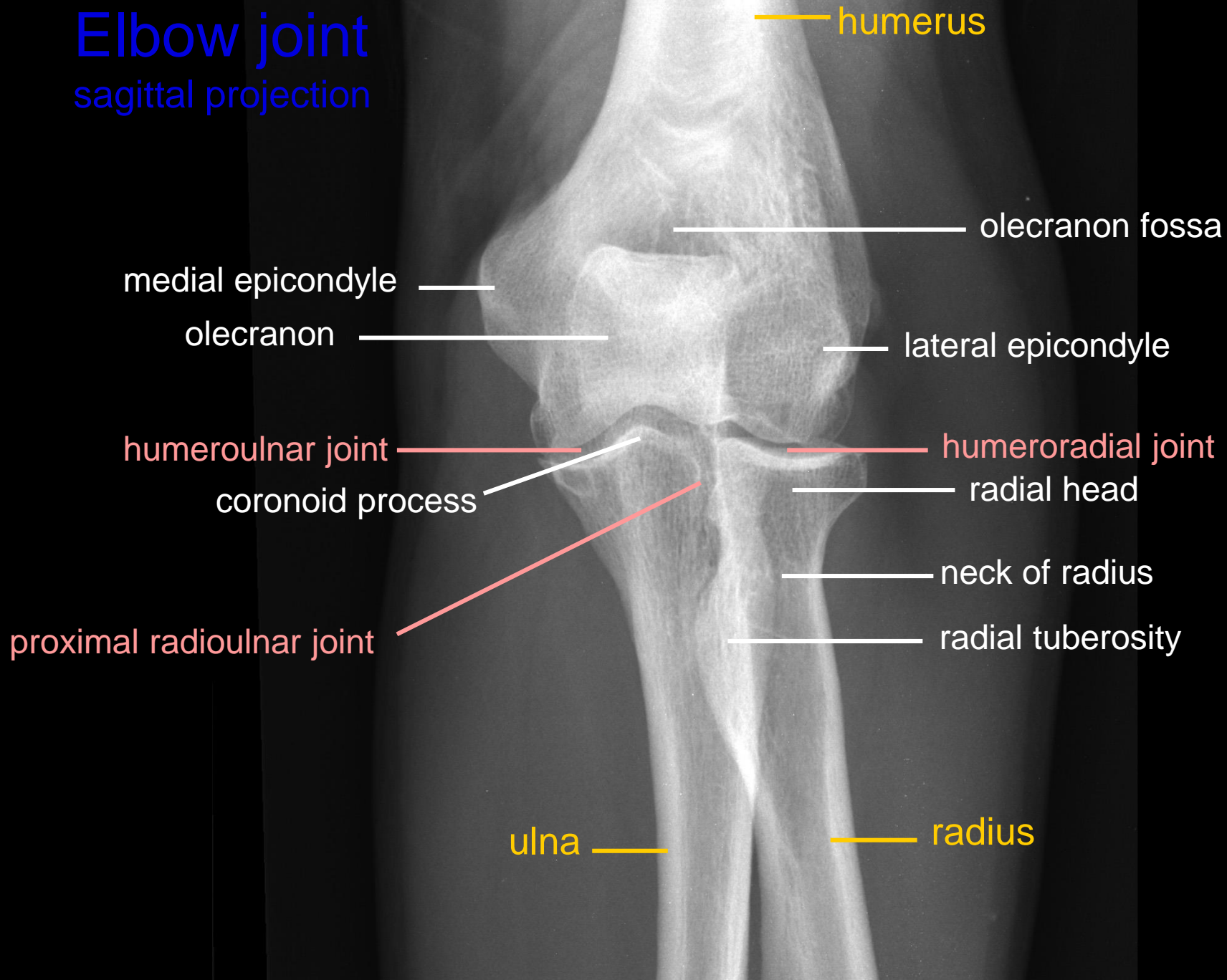
Shoulder joint

sagittal projection



Elbow joint

sagittal projection



Hand and wrist adult

phalanges

- distal
- middle
- proximal

- head
- body
- base

phalanx

sesamoid bone

metacarpals

- head
- body
- base

1 2 3 4 5

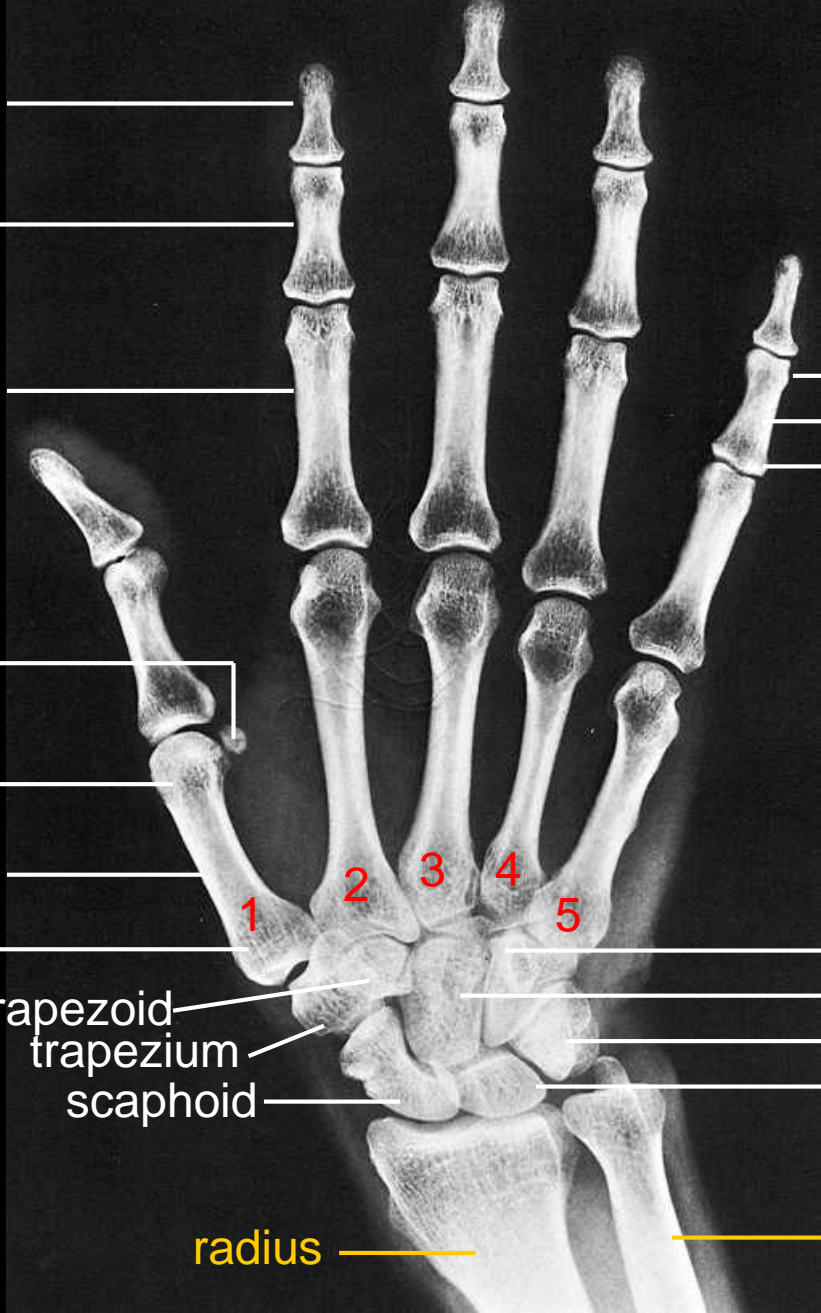carpals

- trapezoid
- trapezium
- scaphoid

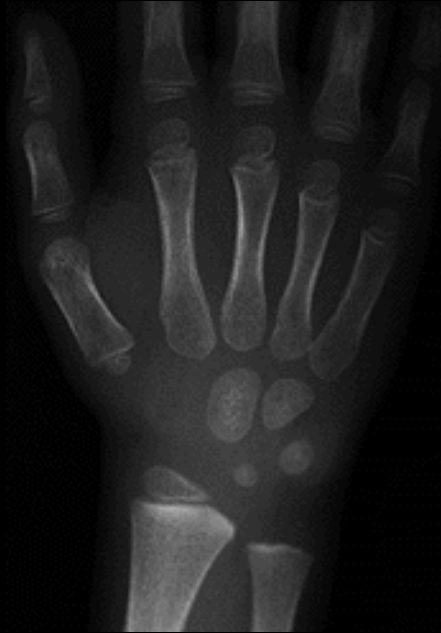- hamate (+hamulus)
- capitate
- triquetrum+pisiform
- lunate

radius

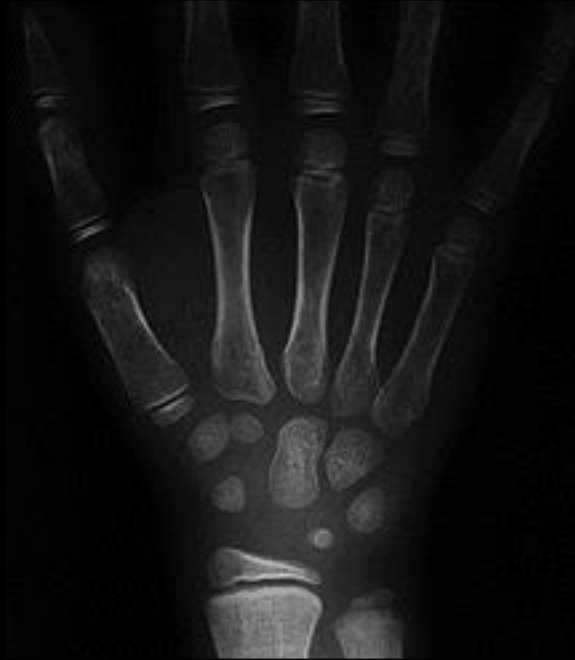ulna



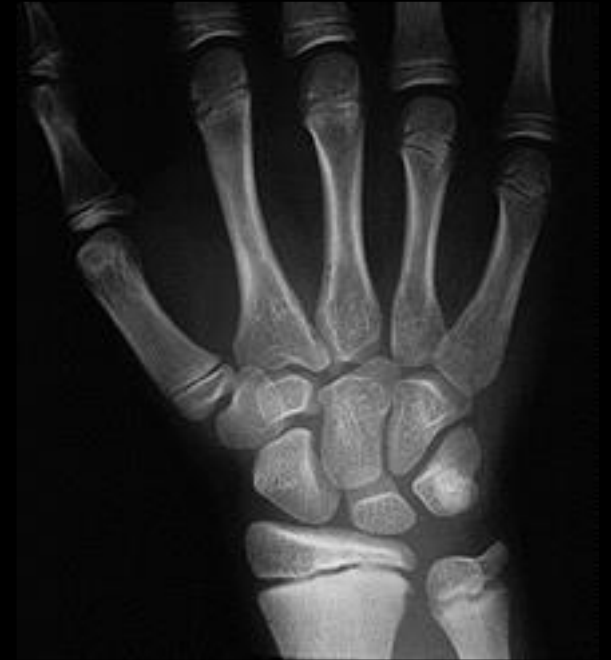Hand and wrist child



4,5 years old child
(4 carpal bones are ossificated)



7 years old child
(7 carpal bones are ossificated)



13 years old child

Skeleton of the lower limb (*ossa membri inferioris*)

I. Pelvic girdle (*cingulum membri inferioris*)

Hip bone (*os coxae*)

II. Bones of free part of the lower limb (*ossa membri inferioris liberi*)

Thigh: Thigh bone (*femur*)

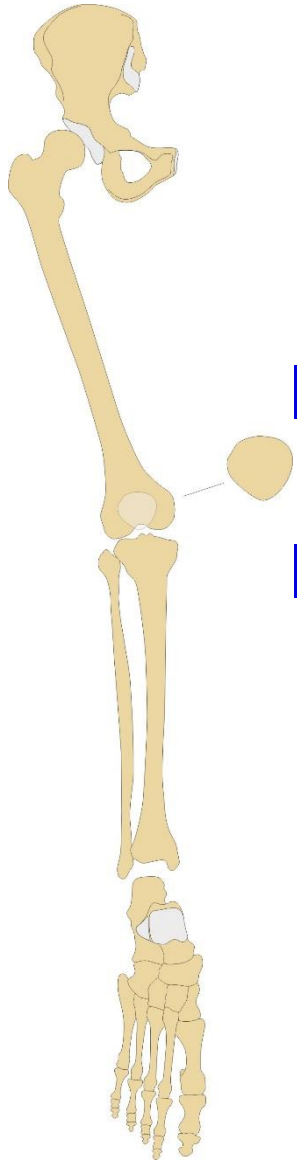
Leg: Shin bone (*tibia*), calf bone (*fibula*)

Foot: Tarsal bones (*ossa tarsi*) – 7

Metatarsal bones (*ossa metatarsi*) – 5

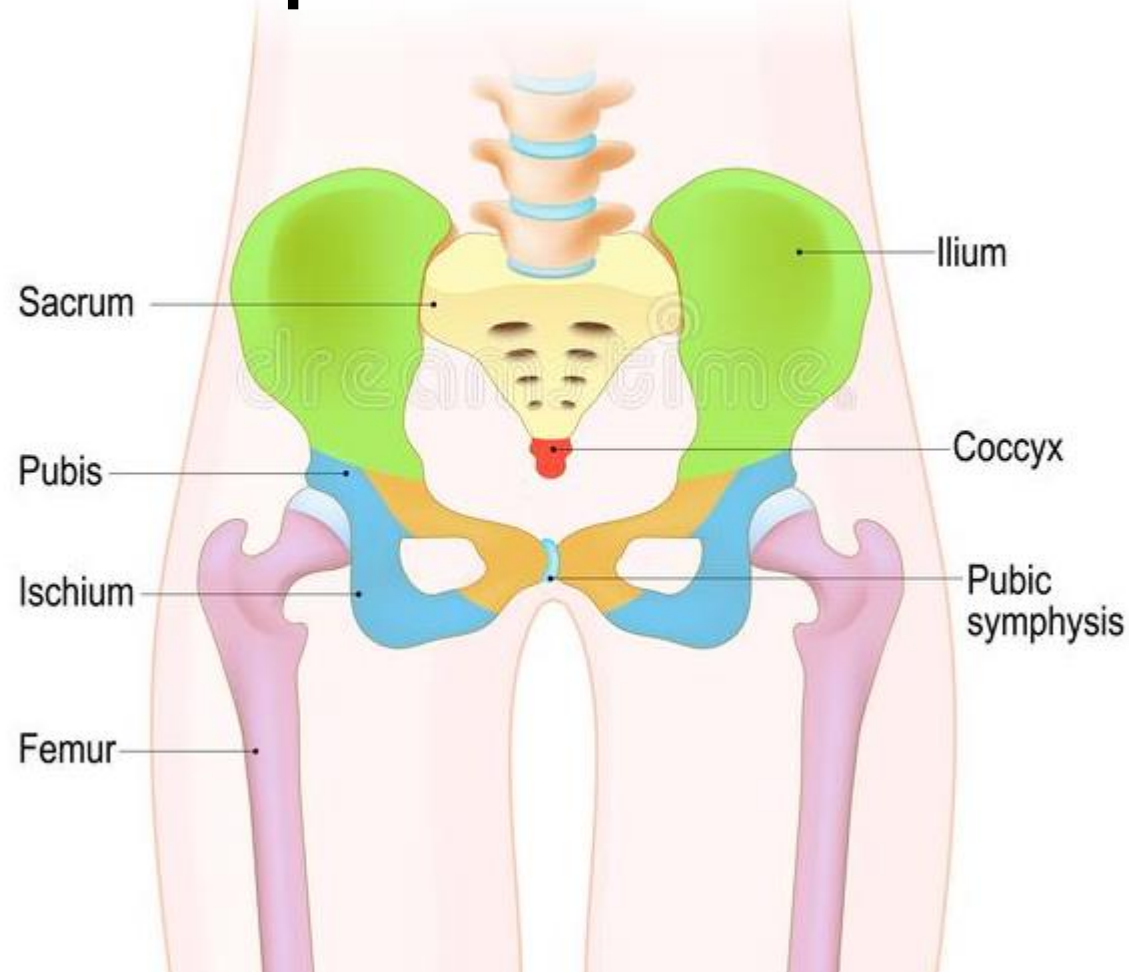
Phalanges of foot digits (*ossa digitorum pedis*) – 14

Sesamoid bones (*ossa sesamoidea*) – 2 or more



Pelvis

2 hip bones + sacrum



Os coxae (hip bone)

Os ilium

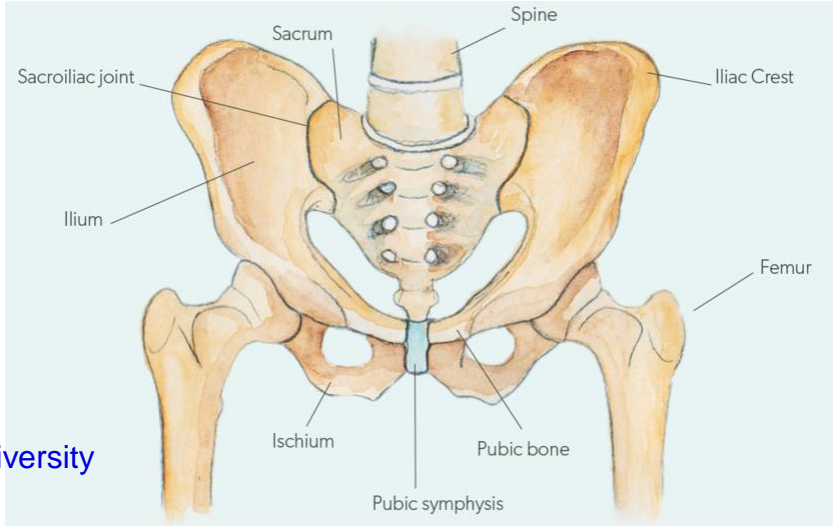
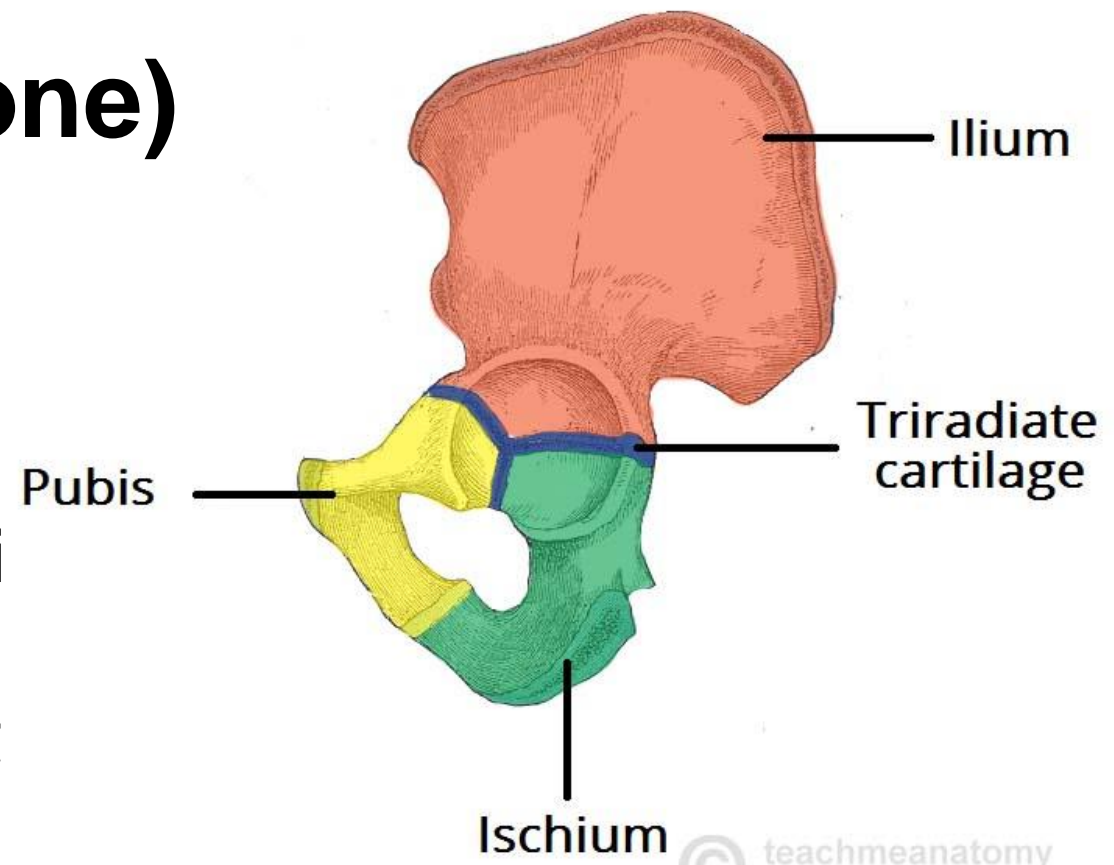
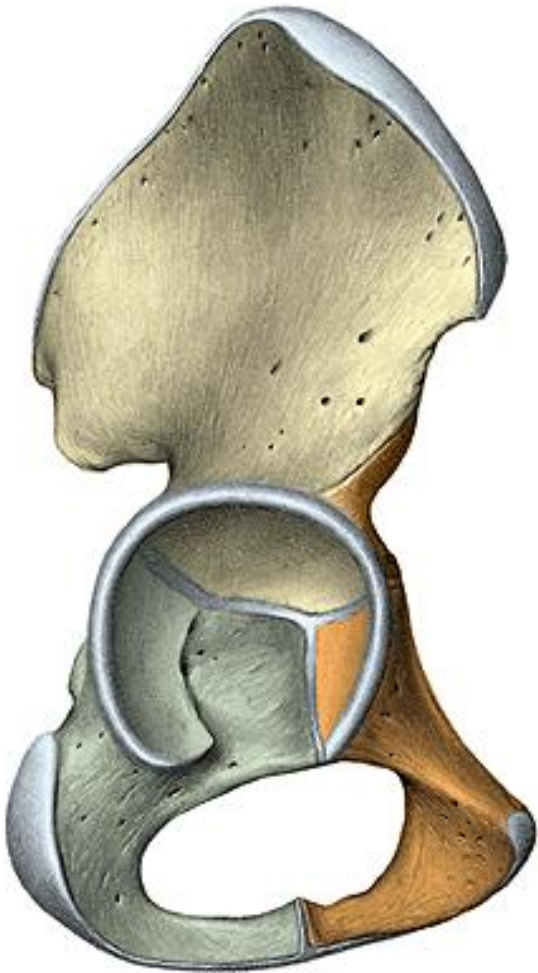
corpus, ala ossis ilii

Os ischii

corpus, ramus ossis ischii

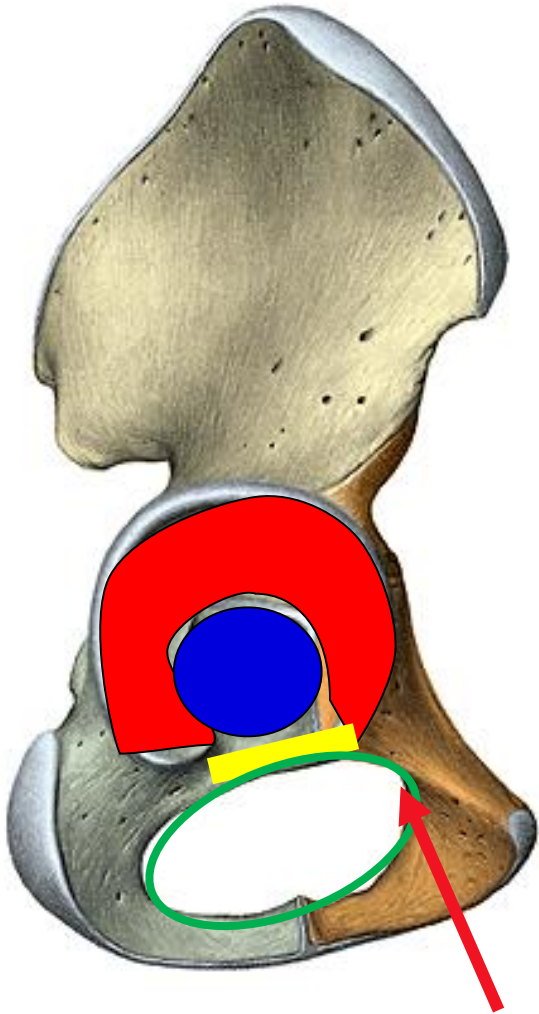
Os pubis

corpus, ramus superior et ramus inferior ossis pubis



© teachmeanatomy
The #1 Applied Human Anatomy Site on the Web

Os coxae (hip bone)



Ala ossis ilii

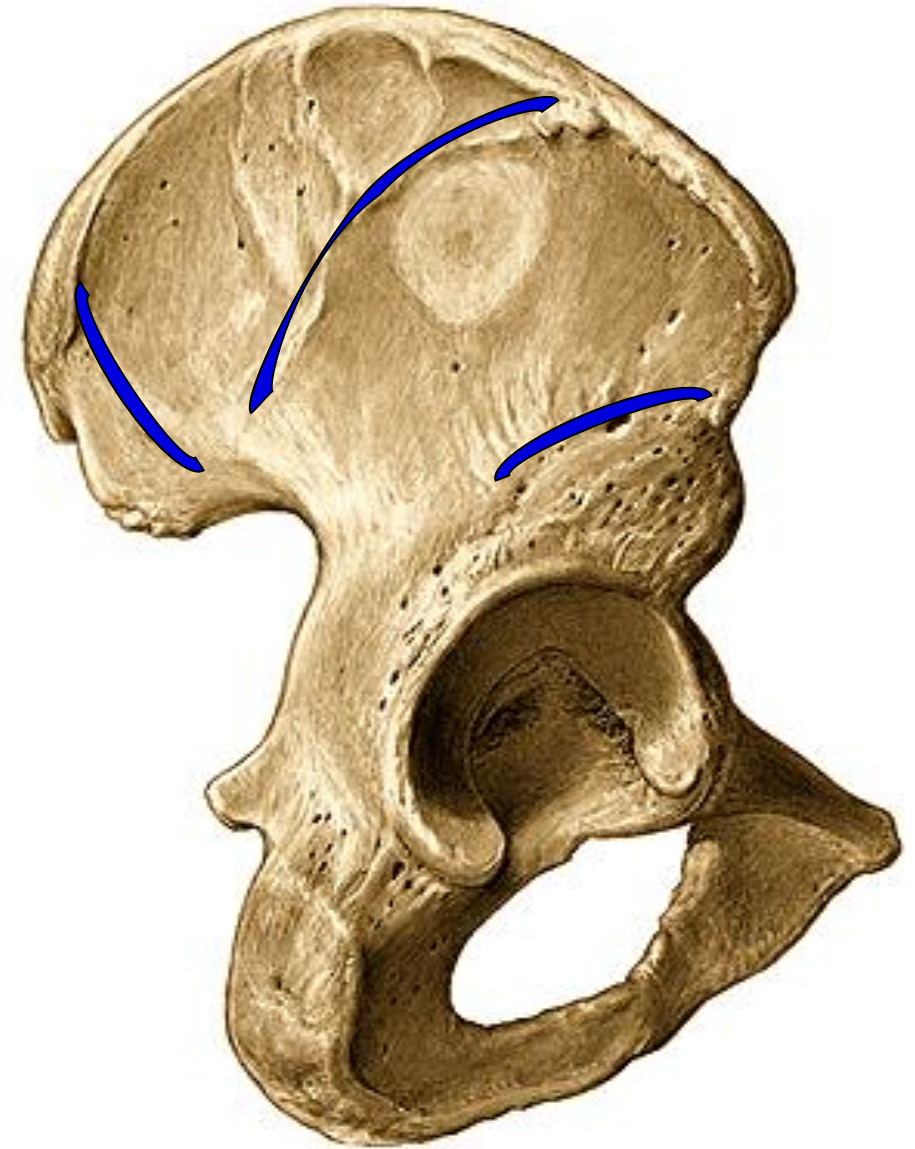
- linea glutea posterior
- linea glutea anterior
- linea glutea inferior

Acetabulum

- facies lunata
- incisura acetabuli
- fossa acetabuli

Foramen obturatum

- sulcus obturatorius

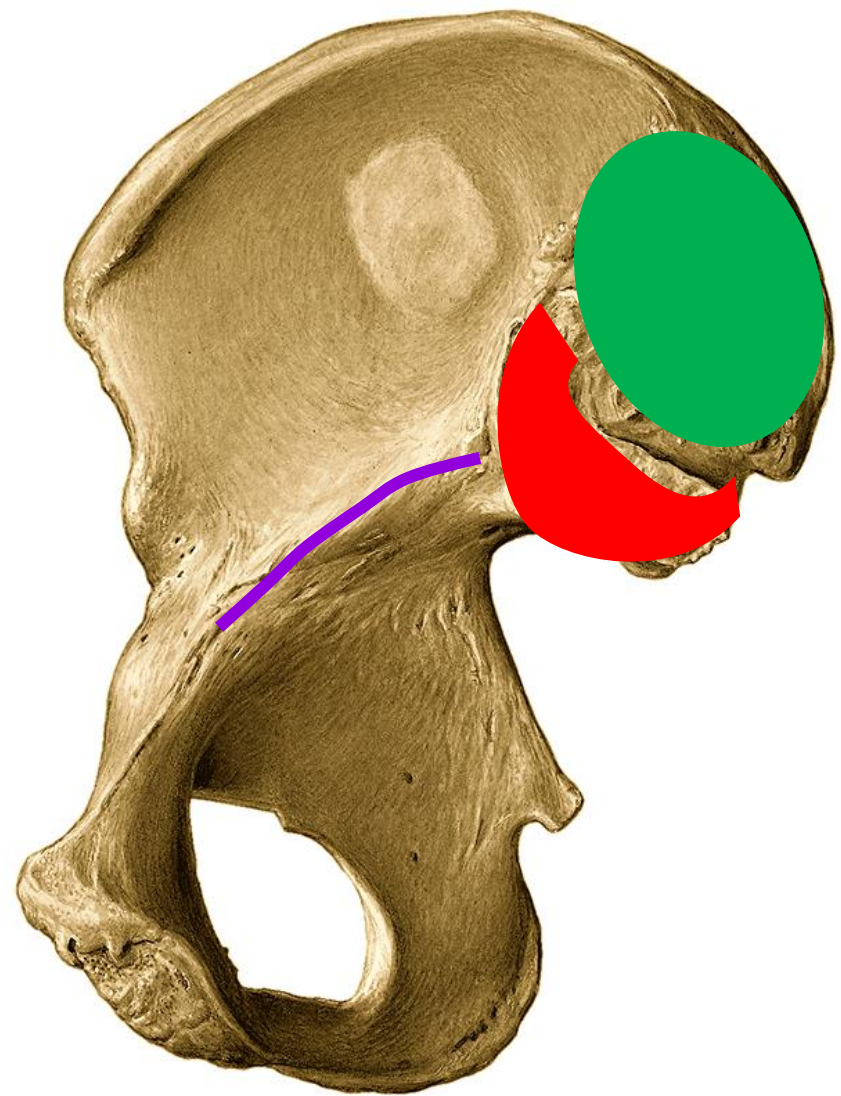


Os coxae (hip bone)

Ala ossis ilii:

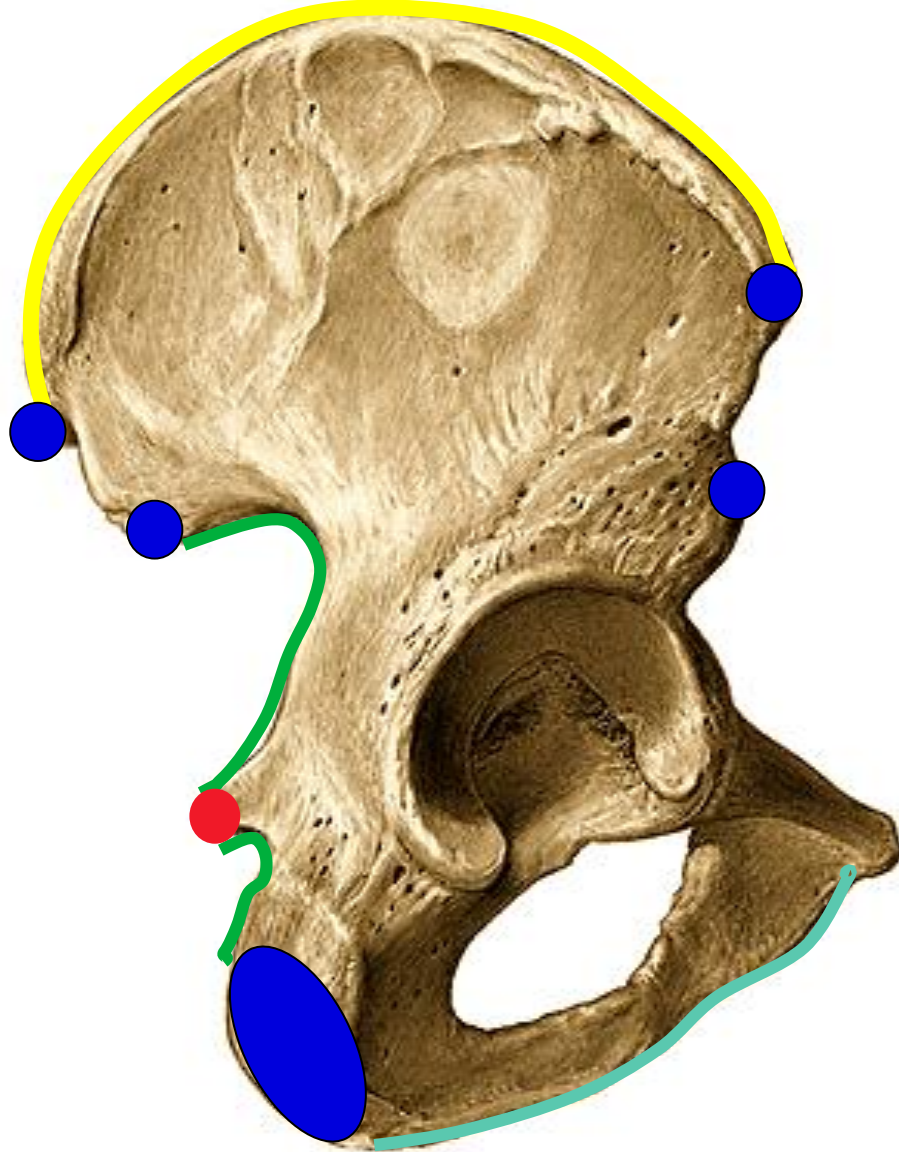
- fossa iliaca
- facies auricularis
- tuberositas iliaca

Linea arcuata



Os coxae (hip bone)

Lateral view



Superior border:

- crista iliaca
- spina iliaca anterior superior
- spina iliaca posterior superior

Posterior border:

- spina iliaca posterior inferior
- incisura ischiadica major
- spina ischiadica
- incisura ischiadica minor
- tuber ischiadicum

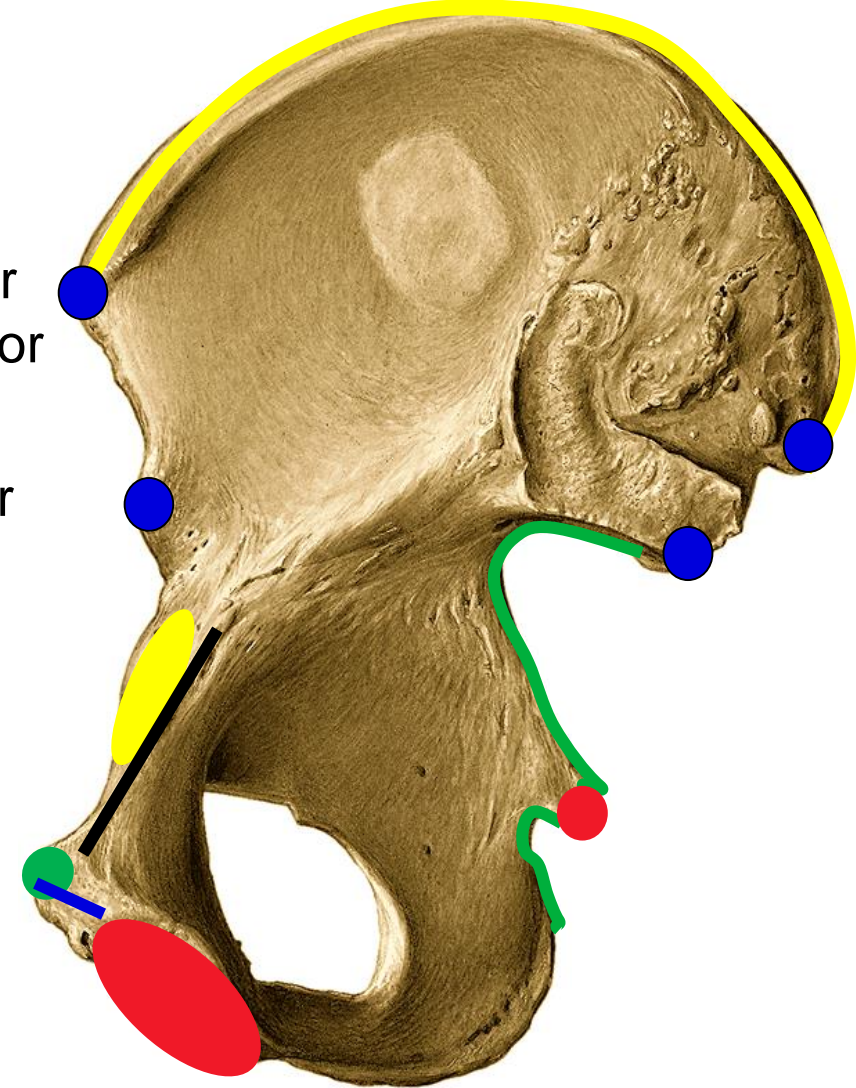
Inferior border:

- facies symphyialis

Anterior border:

- spina iliaca anterior inferior
- eminentia iliopubica
- pecten ossis pubis
- tuberculum pubicum
- crista pubica

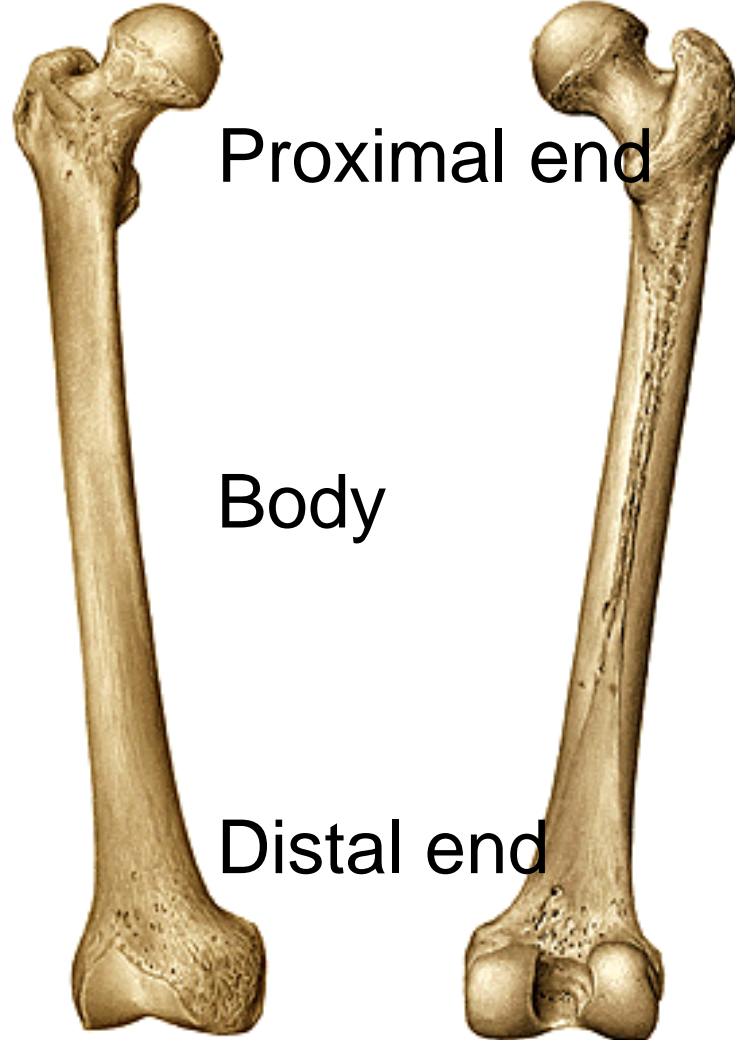
Medial view



Femur (thigh bone)

Right, anterior view

Right, posterior view



Proximal end

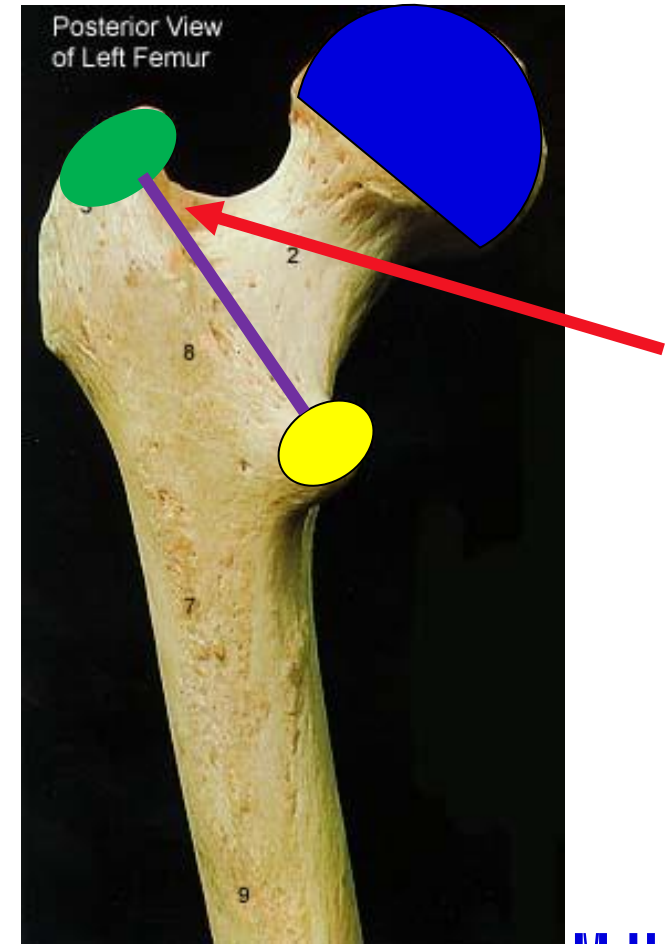
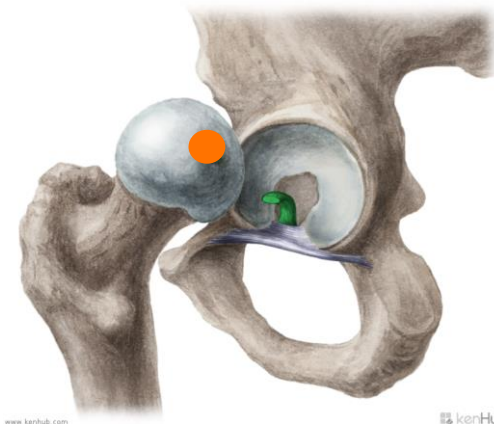
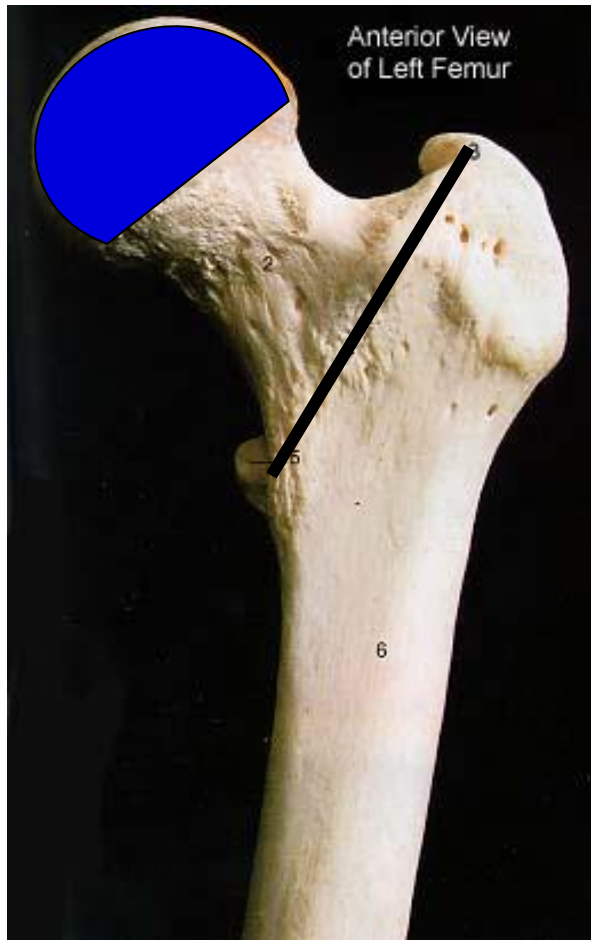
Body

Distal end

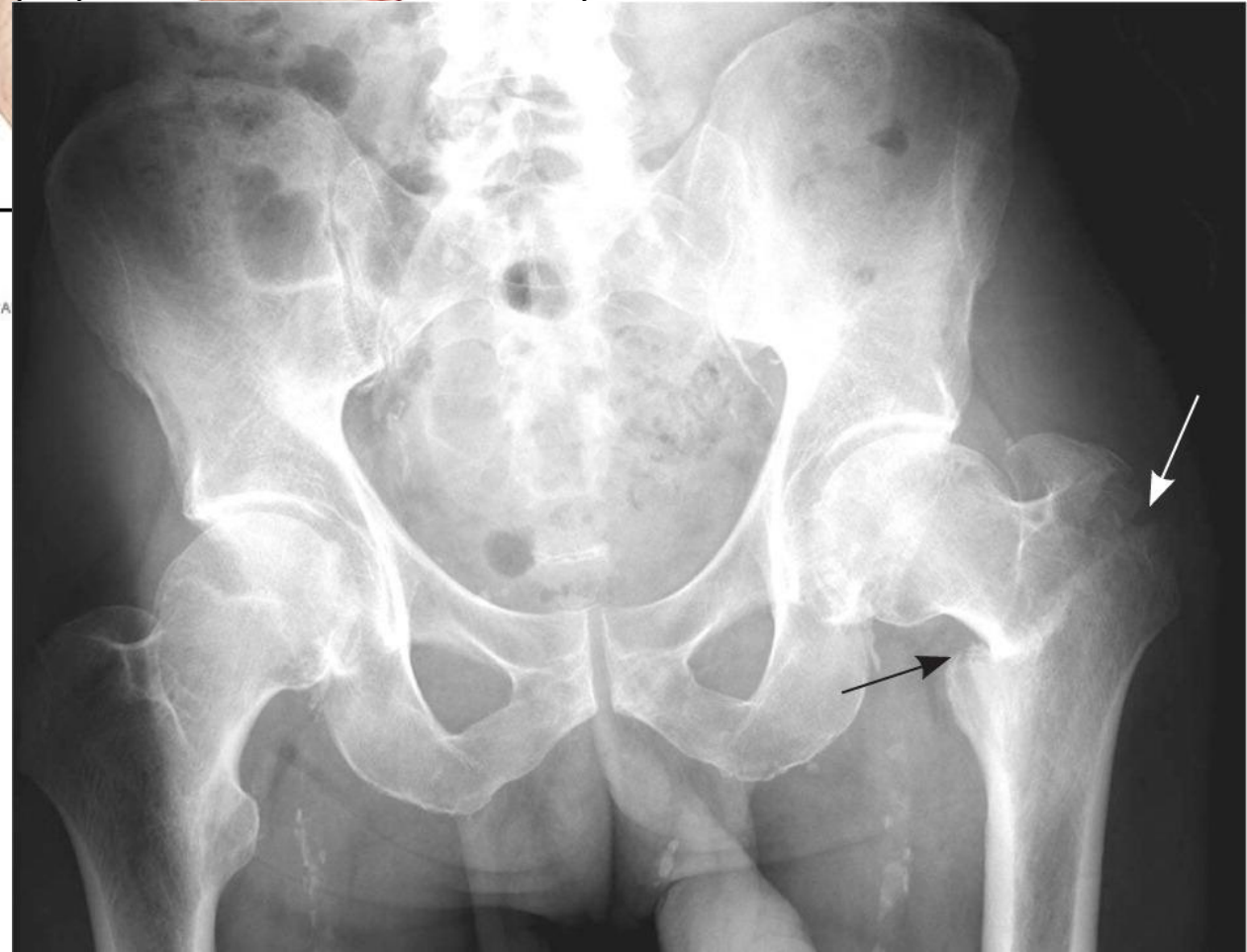
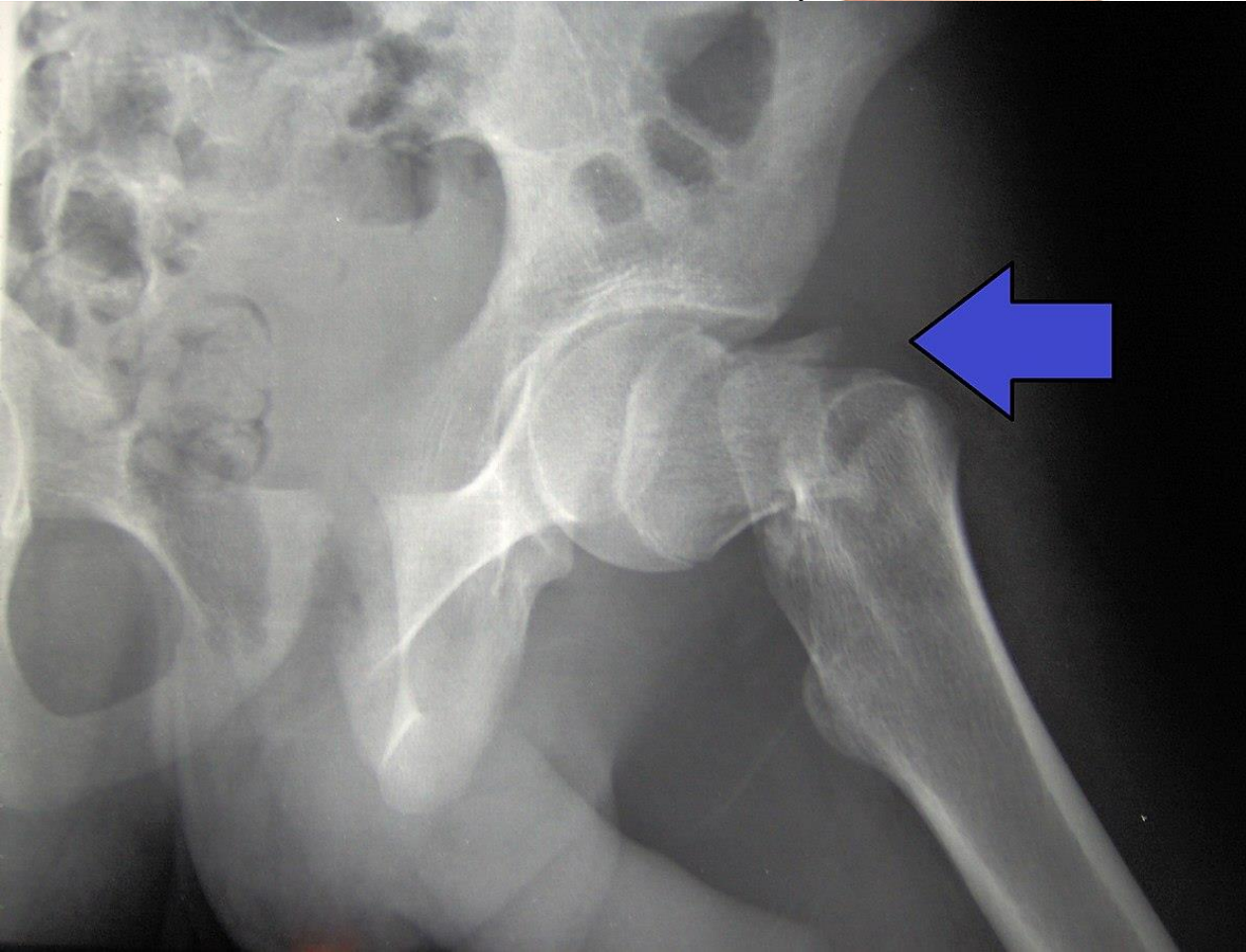
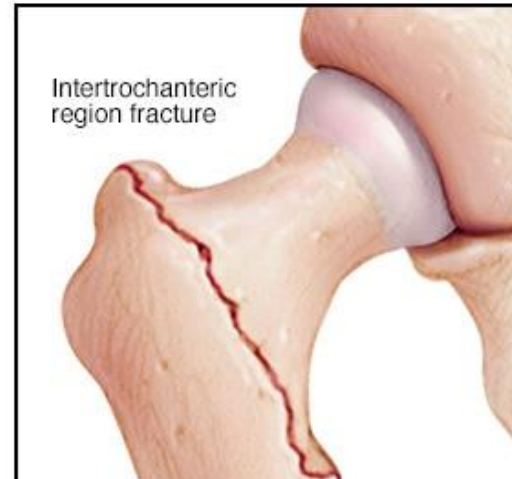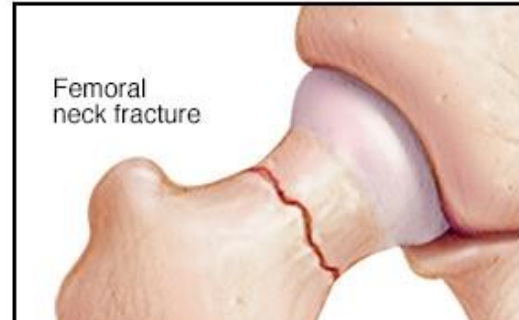Femur (thigh bone)

Proximal end:

- caput femoris
- fovea capitis femoris
- colum femoris
- trochanter major
- trochanter minor
- linea intertrochanterica
- crista intertrochanterica
- fossa trochanterica



Hip fracture




Femur (thigh bone)

Right, anterior view

Right, posterior view

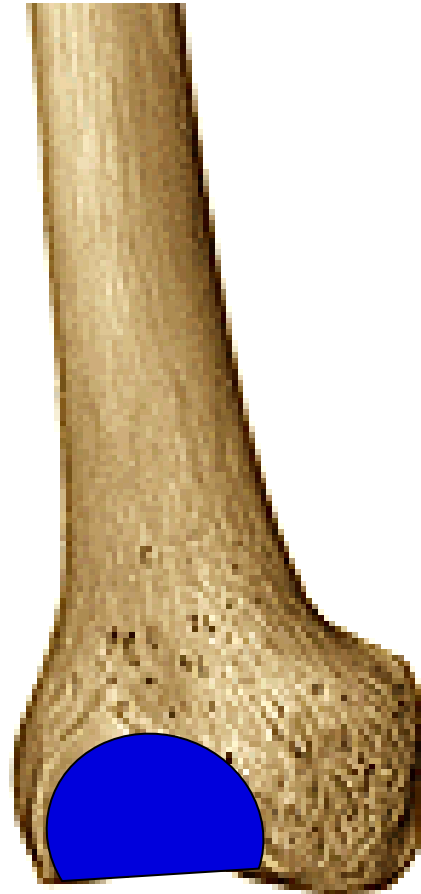Body:

- linea aspera
- labium laterale (tuberositas glutea)
- labium mediale (linea pectinea)
- facies poplitea



Femur (thigh bone)

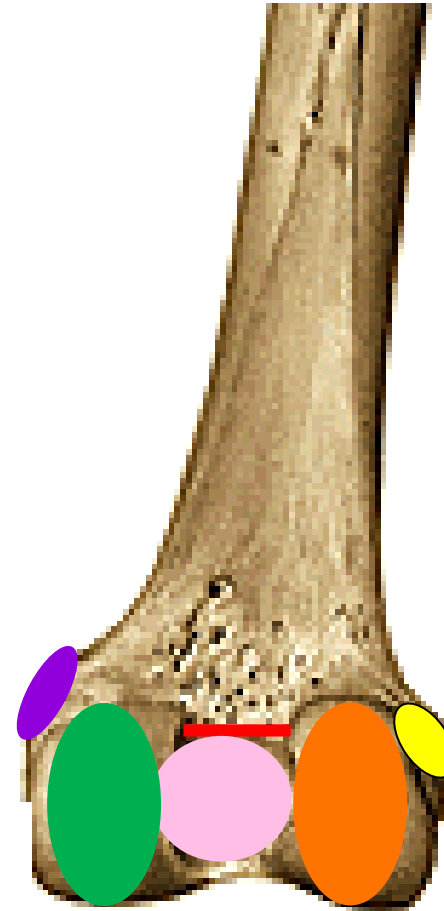
Right, anterior view



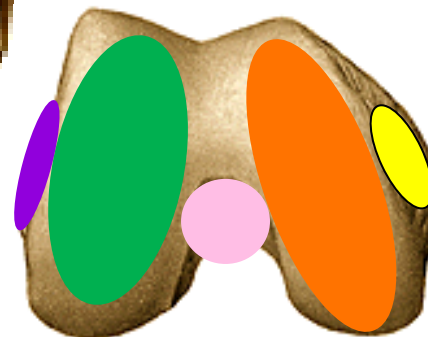
Distal end:

- facies patellaris
- condylus medialis
- condylus lateralis
- epicondylus medialis
- epicondylus lateralis
- fossa intercondylaris
- linea intercondylaris

Right, posterior view



Right, inferior view

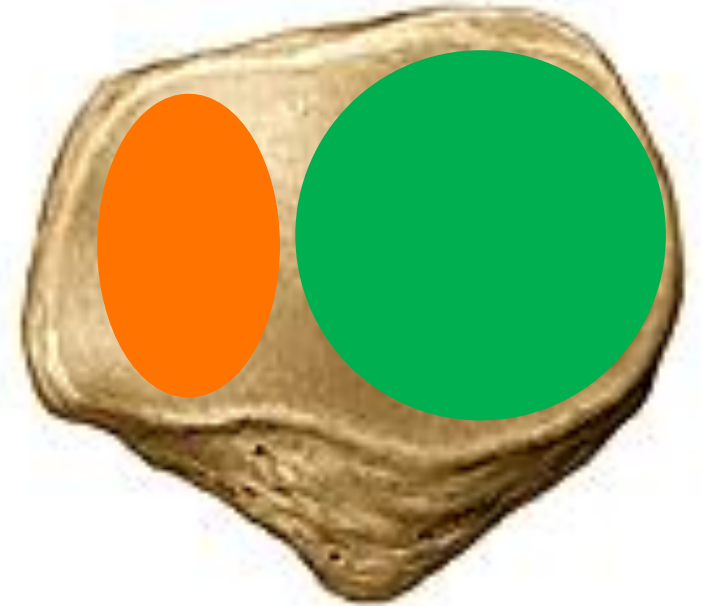


Patella (knee cap)

Right, anterior view



Right, posterior view



Basis

Apex

Facies anterior

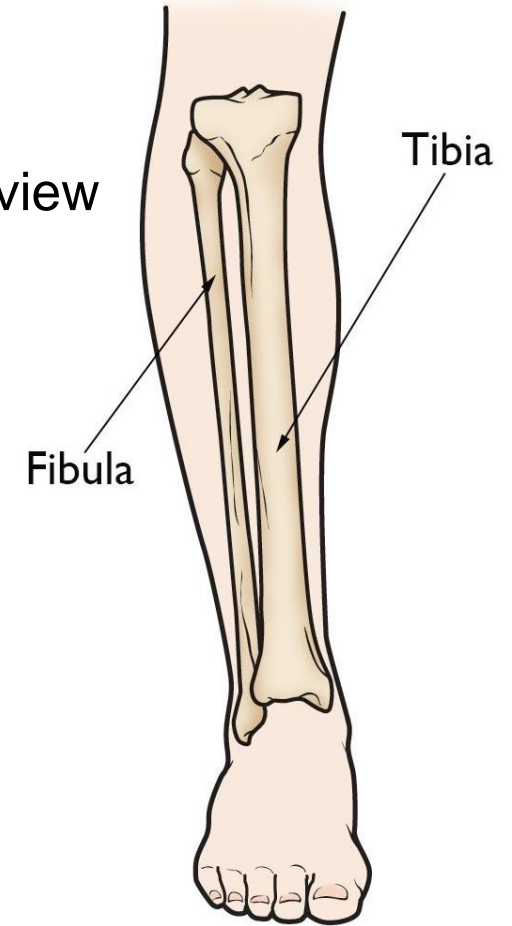
Facies posterior

Tibia (shin bone)

Right, anterior view

Right, lateral view

Right, posterior view



Proximal end

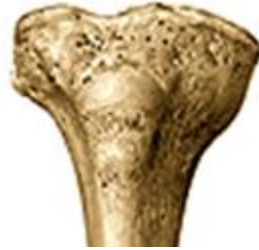Body

Distal end

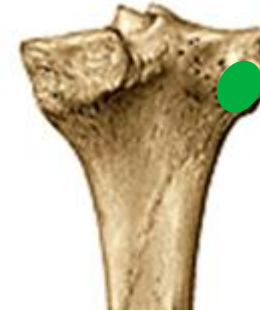

Tibia (shin bone)

Right, anterior view



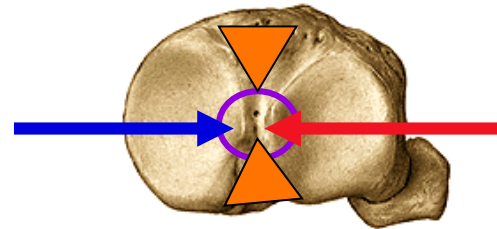
Right, posterior view



Proximal end:

- condylus medialis et lateralis
- eminentia intercondylaris
 - tuberculum intercondylare mediale
 - tuberculum intercondylare laterale
- area intercondylaris anterior et posterior
- facies articularis fibularis

Right,
superior view




Tibia (shin bone)

Right, anterior view



Right, lateral view



Right, posterior view




Body:

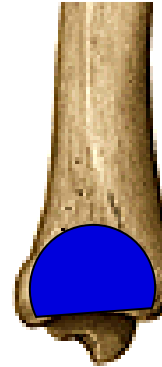
- margo anterior
- margo interosseus
- margo medialis
- tuberositas tibiae
- linea musculi solei

Tibia (shin bone)


Right, anterior view



Right, lateral view



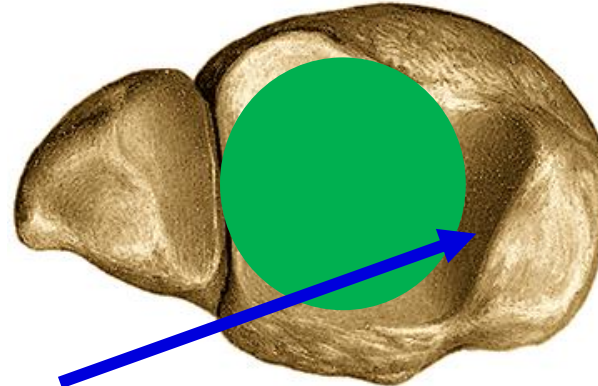
Right, posterior view



Distal end:

- malleolus medialis
- sulcus malleolaris
- facies articularis malleoli medialis
- facies articularis inferior tibiae
- incisura fibularis tibiae

Right, inferior view



Fibula (calf bone)

Right, anterior view

Right, medial view

Proximal end

Body

Distal end



Proximal end (caput fibulae):

- facies articularis capitis fibulae
- apex capitis fibulae



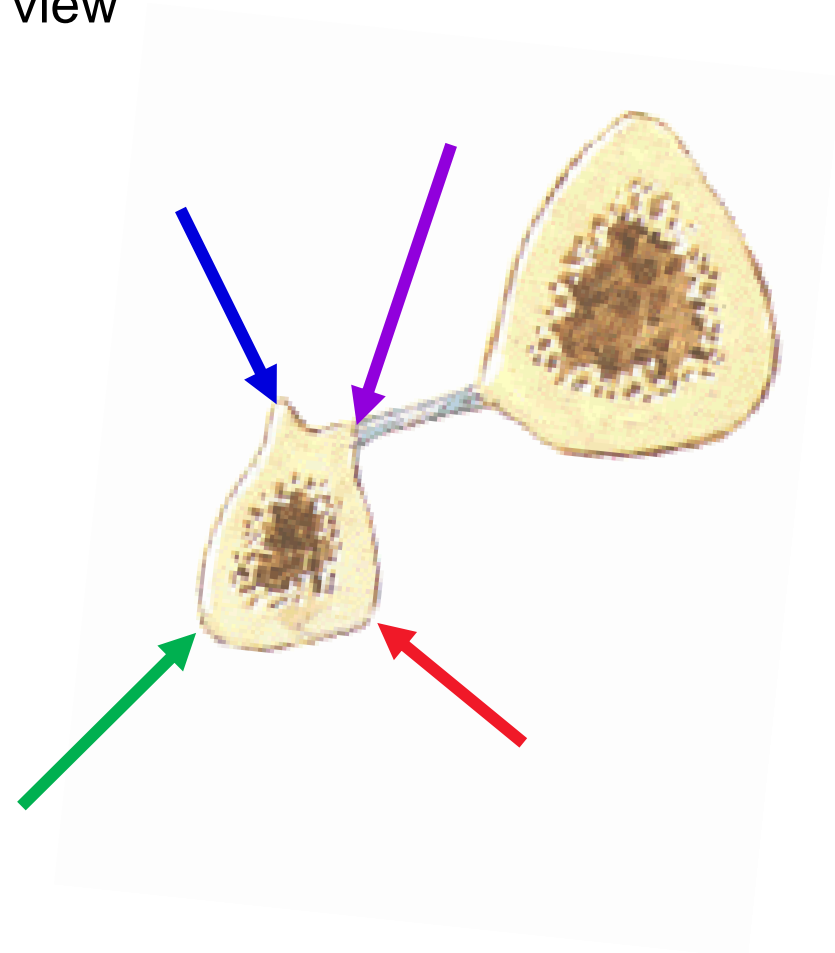
Fibula (calf bone)

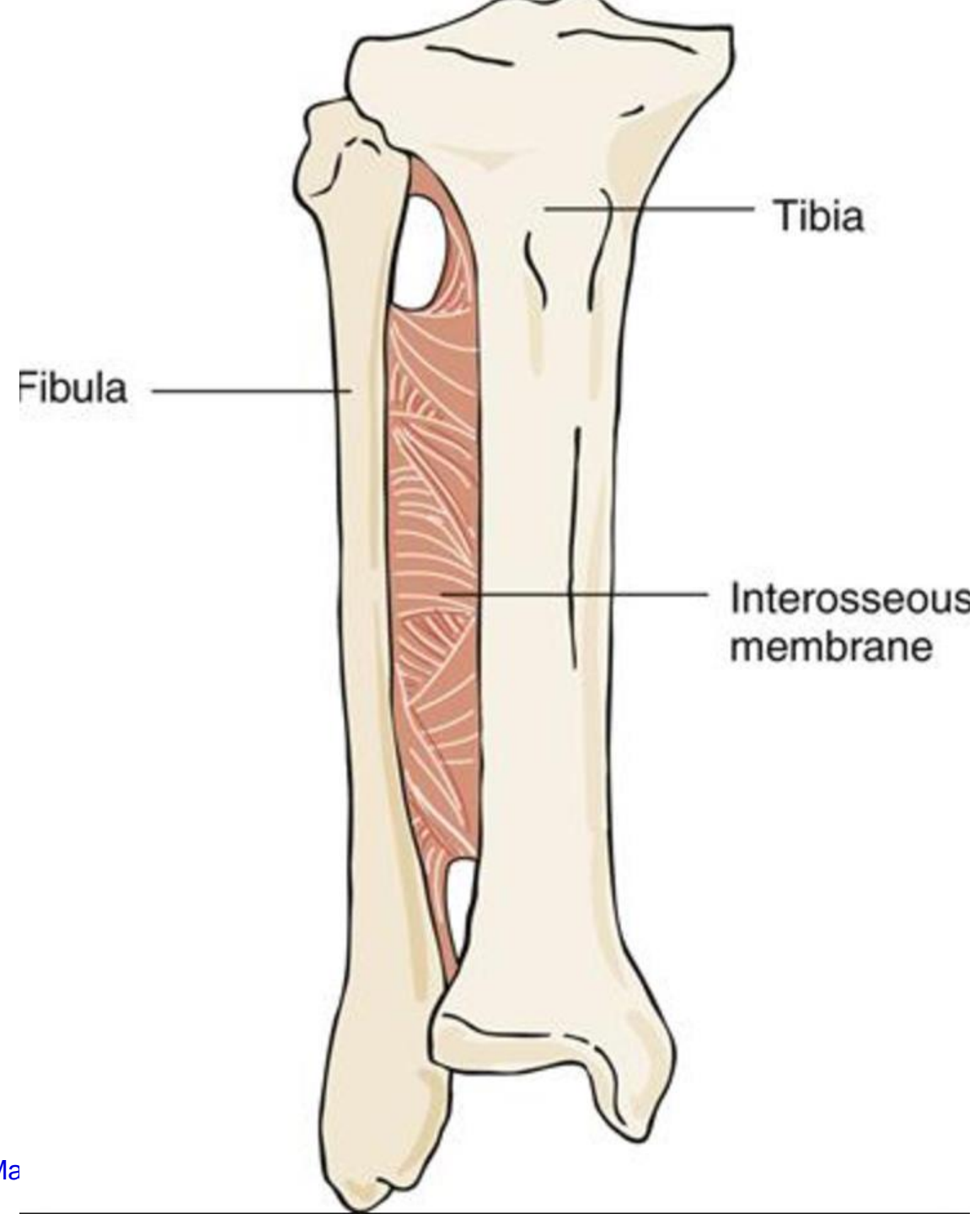
Right, anterior view

Right, medial view

Body:

- margo anterior
- margo posterior
- crista medialis
- margo interosseus





Fibula (calf bone)

Right, anterior view

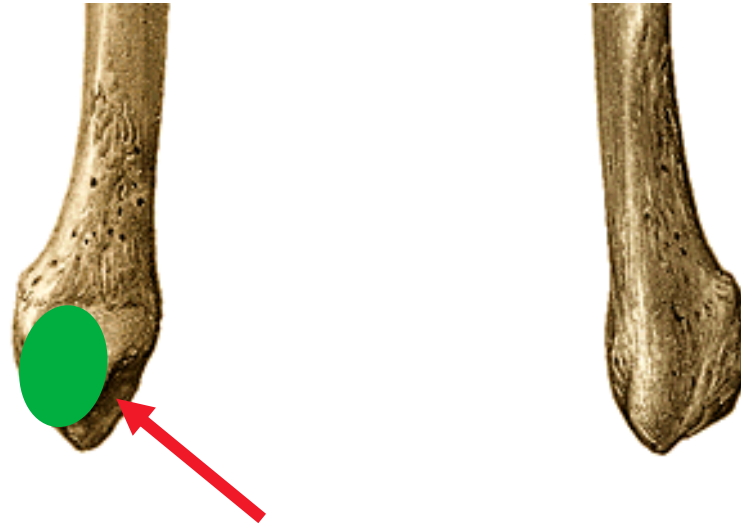


Right, medial view

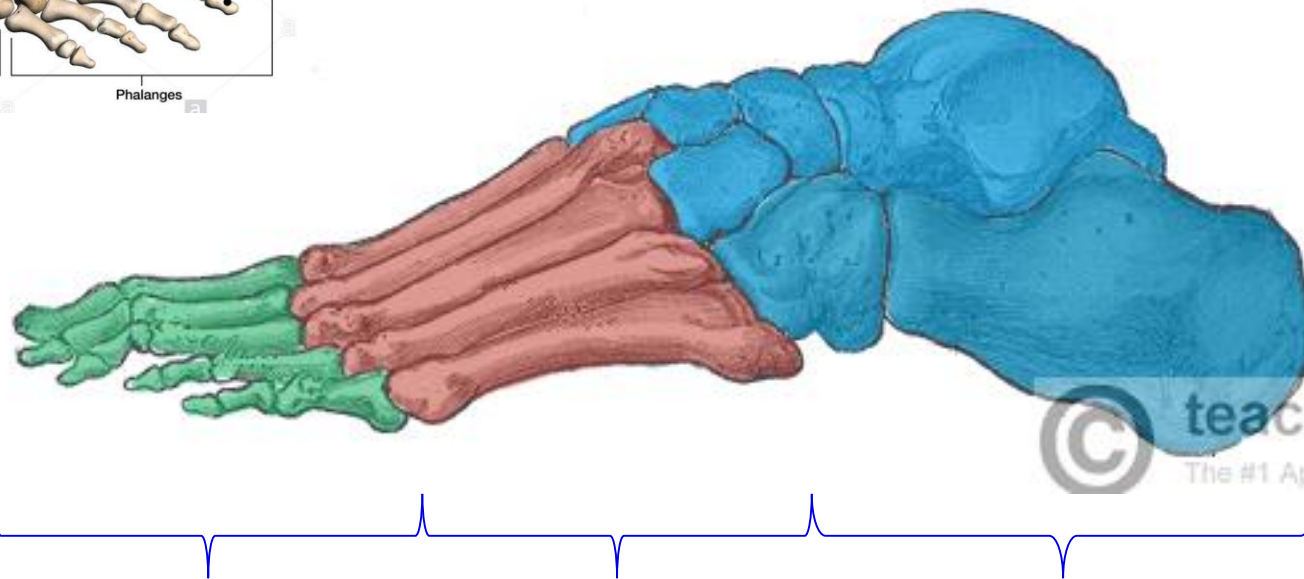
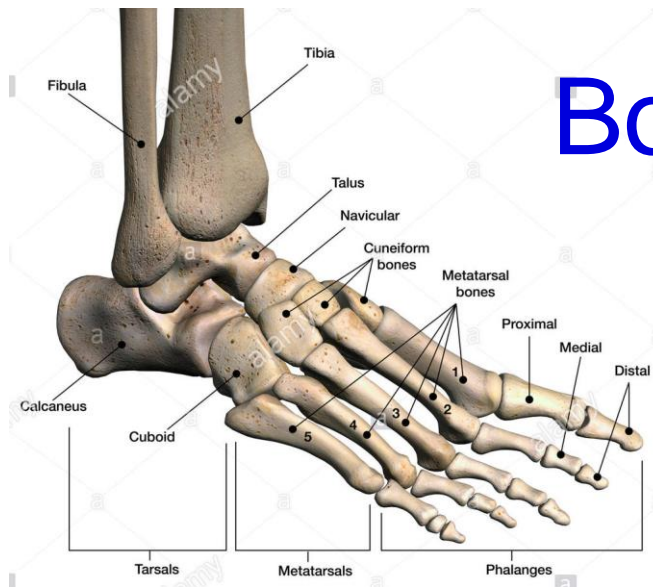




Distal end (malleolus lateralis):

- facies articularis malleoli lateralis
- sulcus malleolaris (mm.fibulares)
- fossa malleoli lateralis (lig. talofibulare post.)



Bones of the foot (ossa pedis)



-  Tarsals
-  Metatarsals
-  Phalanges

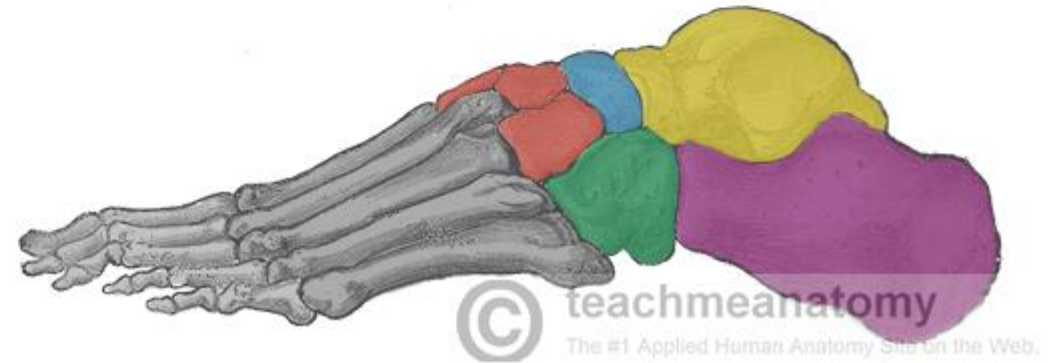
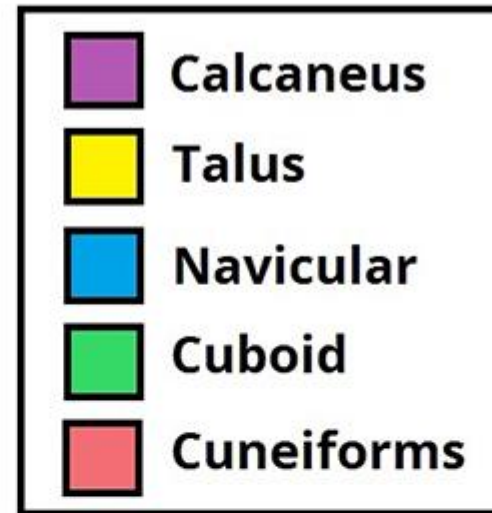
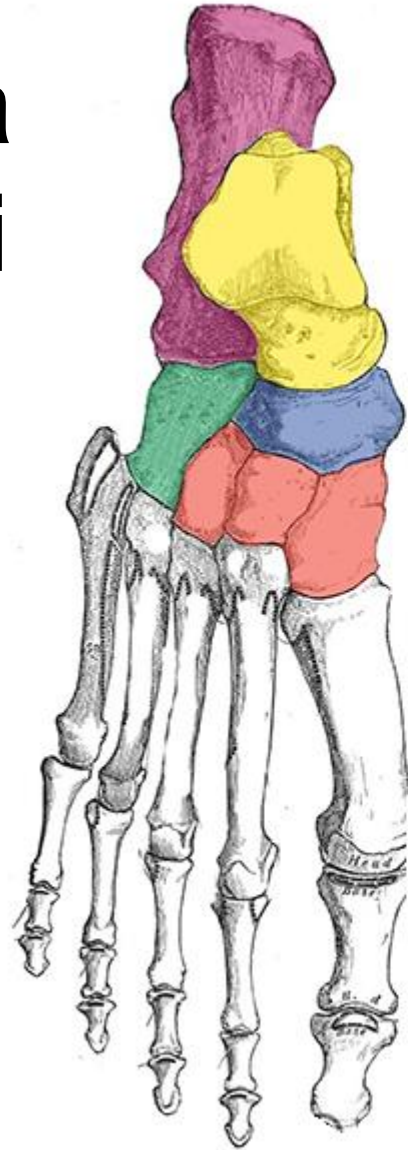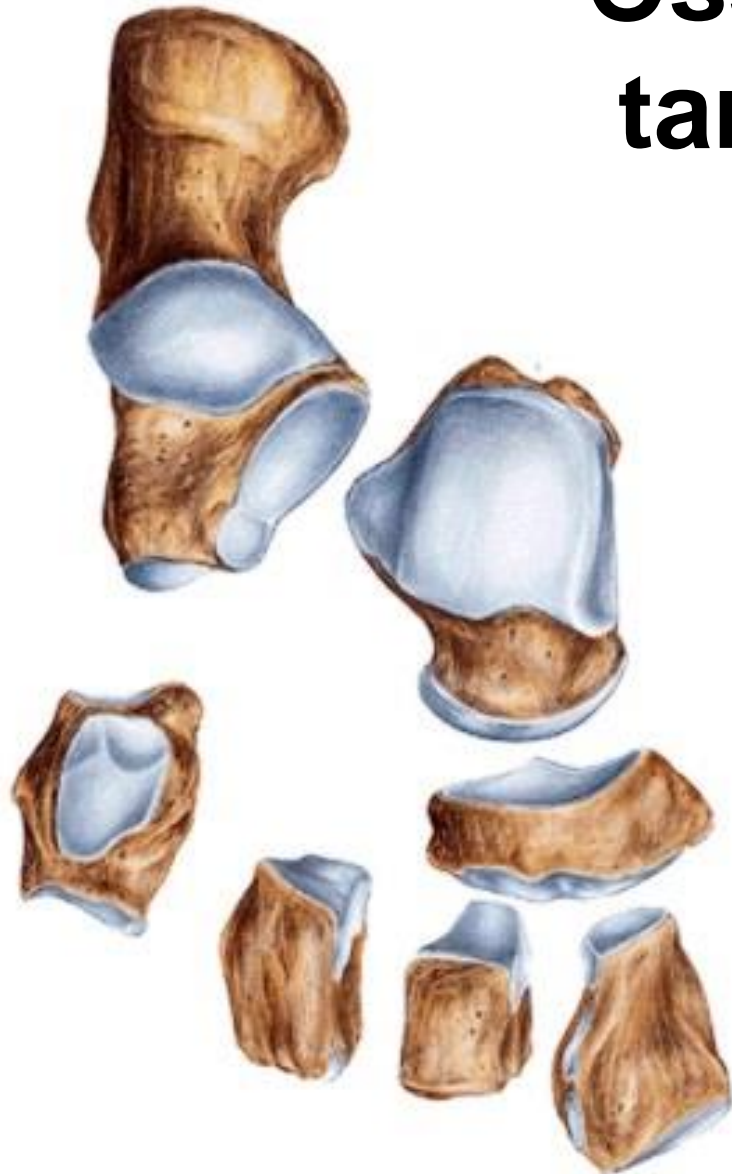Ossa digitorum pedis

Ossa metatarsi

Ossa tarsi

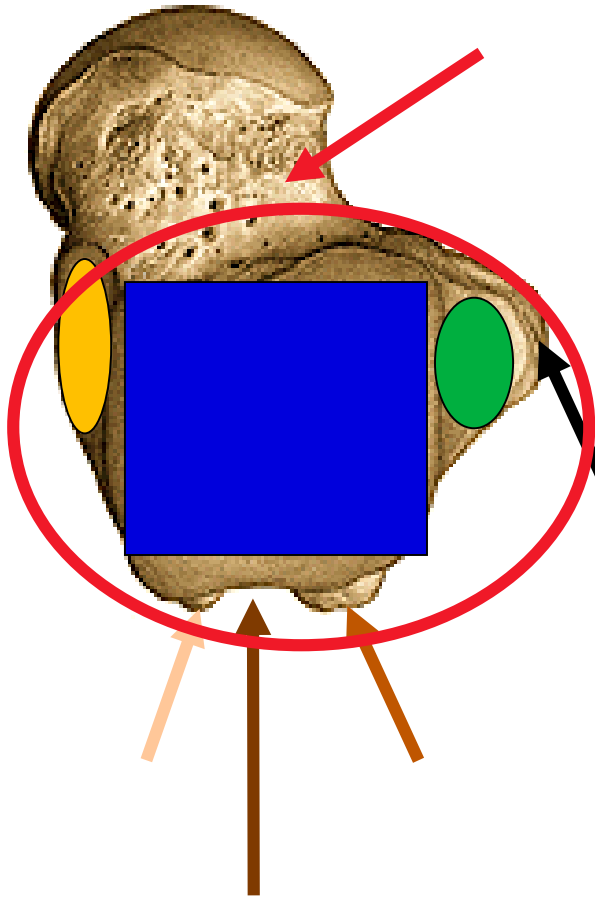
(right, superior view)

Ossa tarsi



Talus (ankle bone)

(right superior view)



Caput tali (facies articularis navicularis)

Collum tali

Corpus tali

- trochlea tali - facies articularis superior
- facies articularis malleolaris medialis
- facies articularis malleolaris lateralis

Facies articularis calcanea posterior, media, anterior

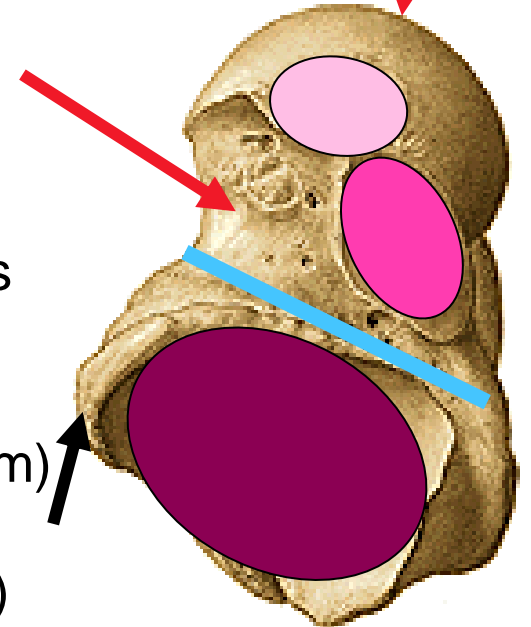
Sulcus tali (sinus tarsi - lig. talocalcaneare interosseum)

Processus lateralis tali

Processus posterior tali (tuberculum laterale, mediale)

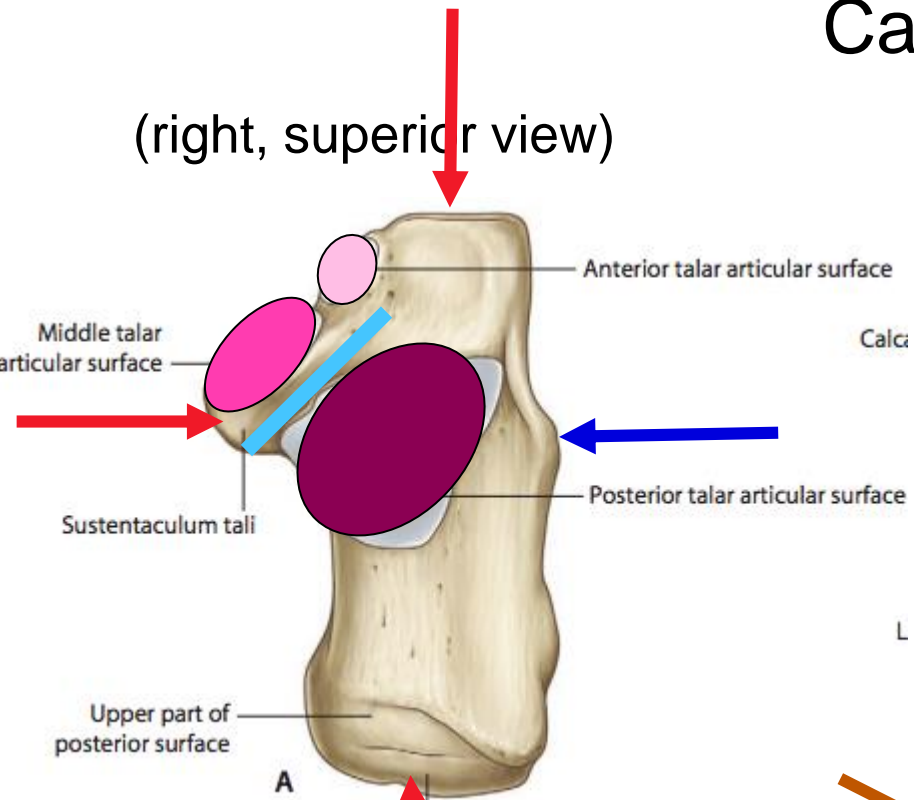
Sulcus tendinis musculi flexoris hallucis longi

(right, inferior view)



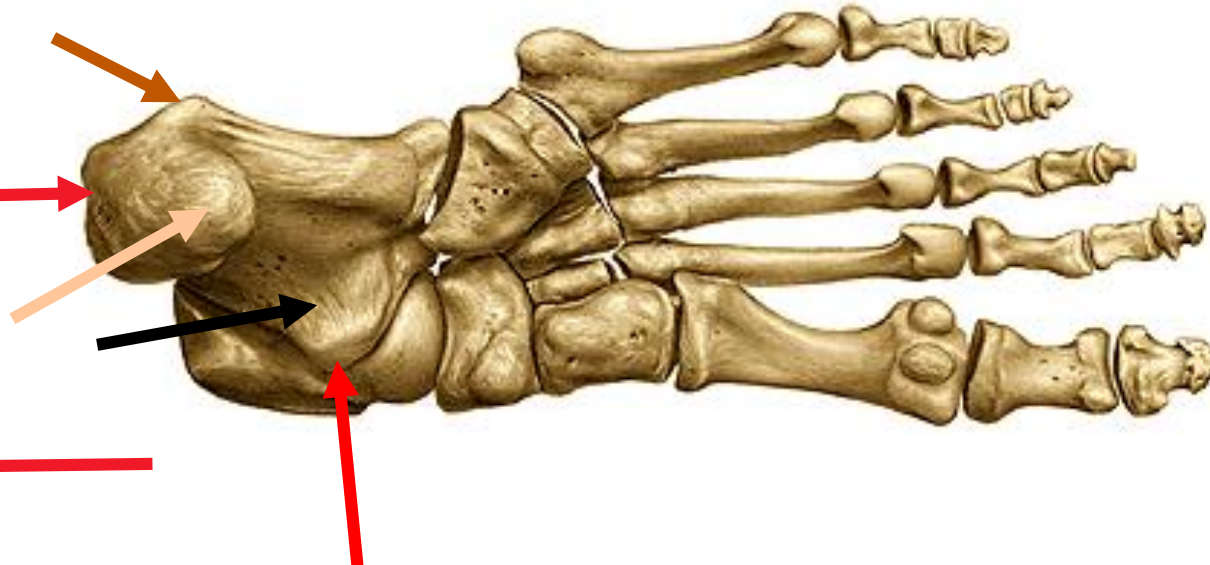
Calcaneus (heel bone)

(right, superior view)

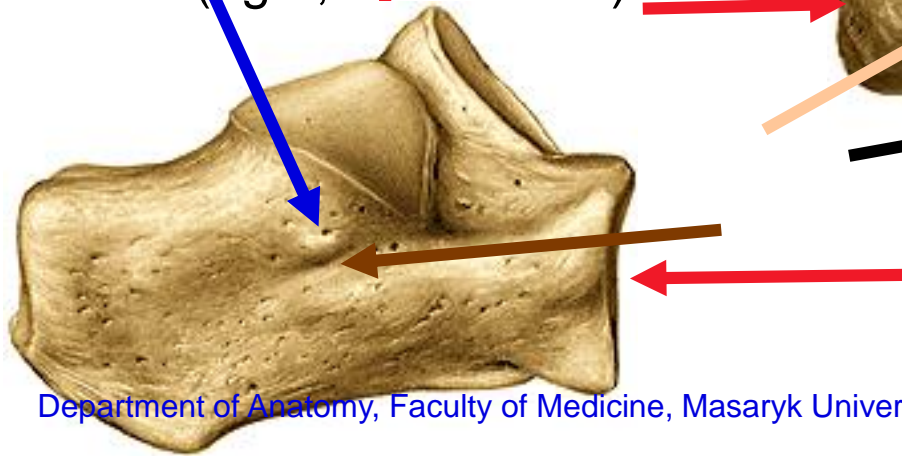


- Tuber calcanei (processus medialis et lateralis)
- Facies articularis talaris posterior, media et anterior
- Sulcus calcanei (sulcus calcanei + sulcus tali = sinus tarsi)
- Sustentaculum tali
- Sulcus tendinis musculi flexoris hallucis longi
- Trochlea fibularis
- Sulcus tendinis musculi fibularis longi
- Facies articularis cuboidea

(right, inferior view)

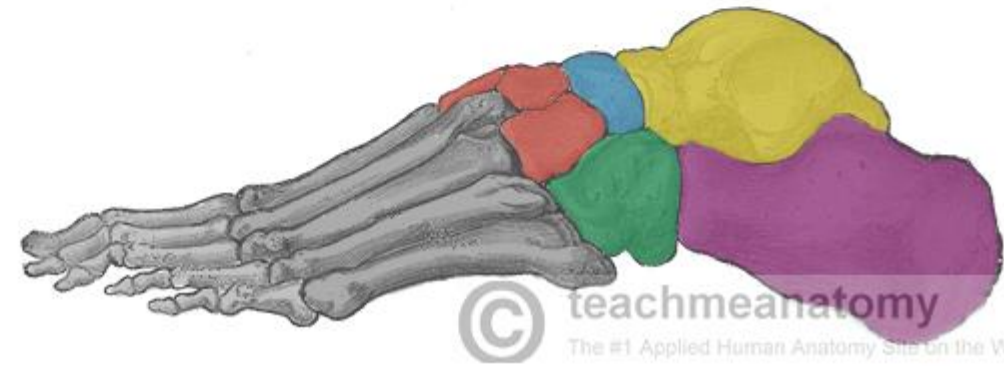
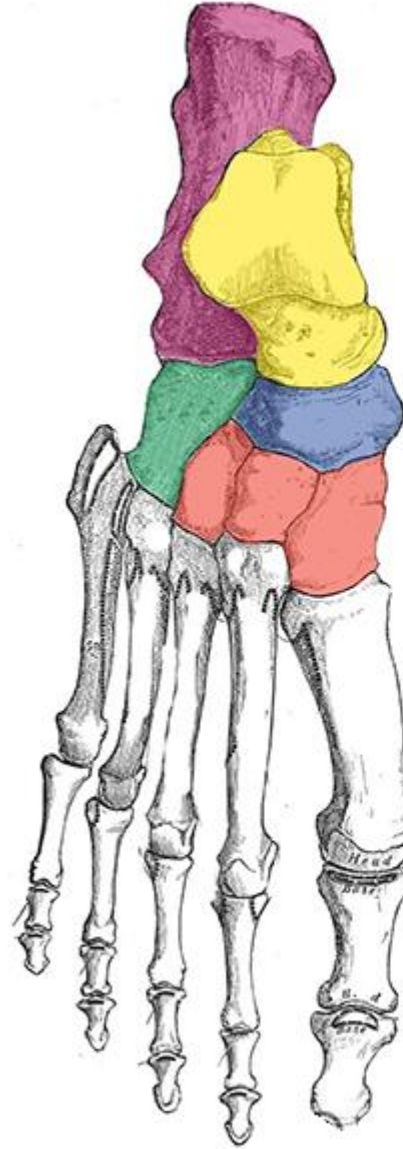
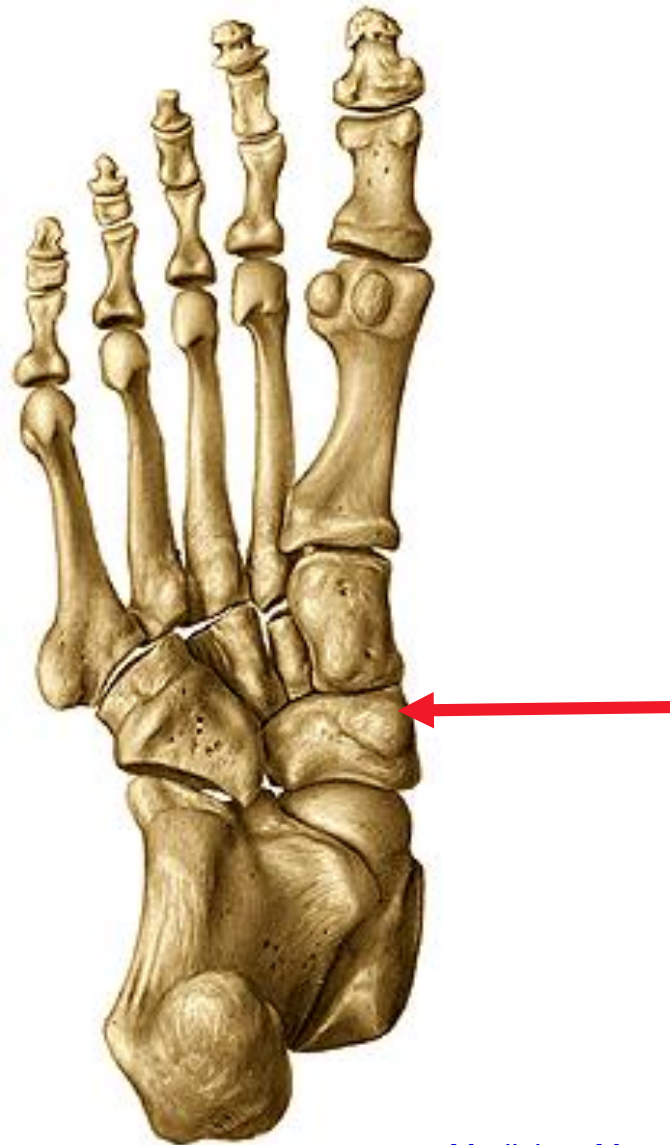


(right, lateral view)



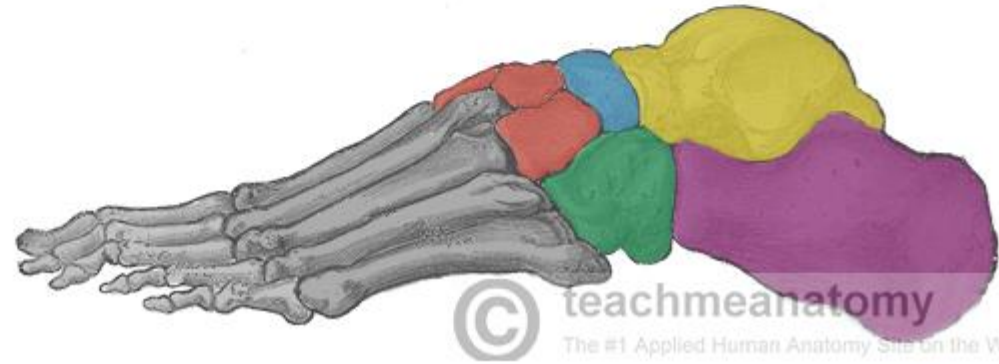
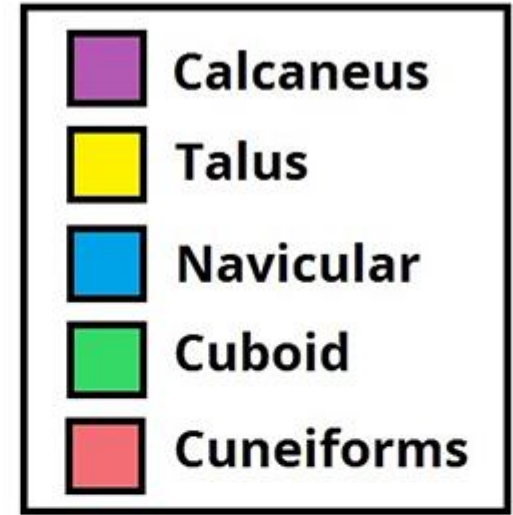
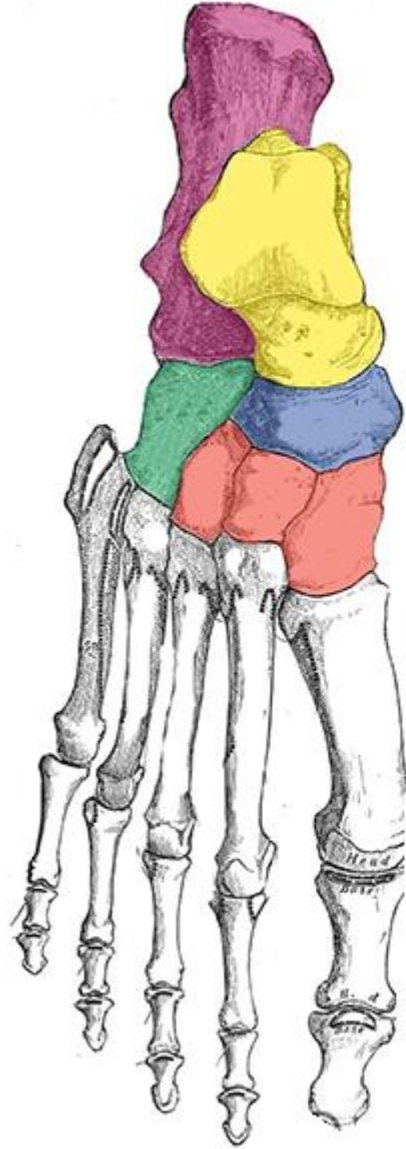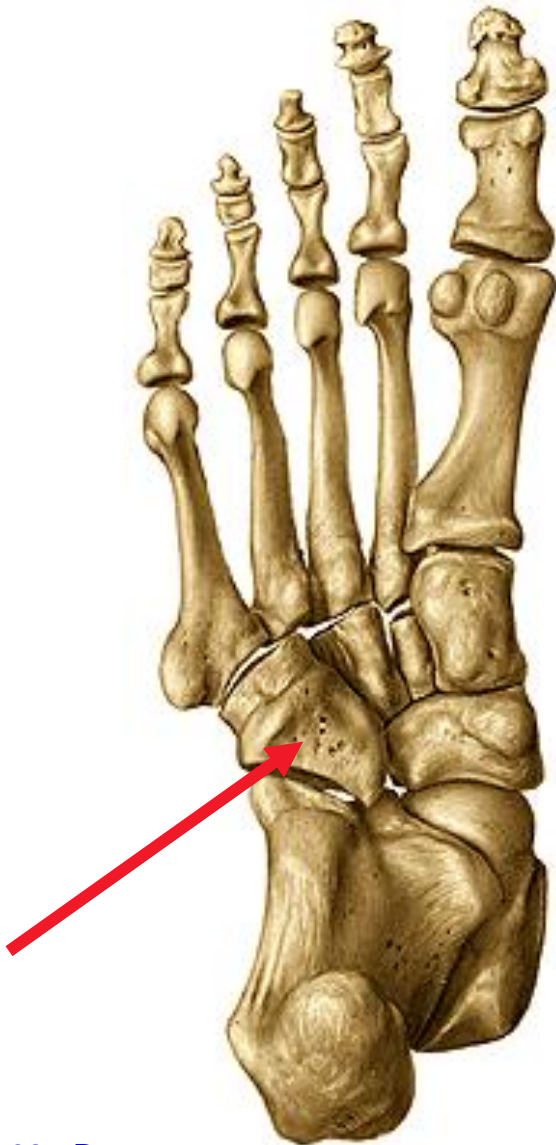
(right, inferior view)

Os naviculare - tuberositas ossis navicularis



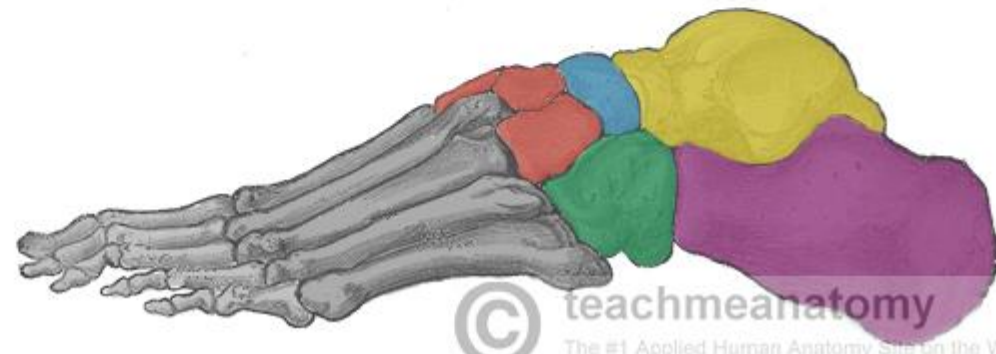
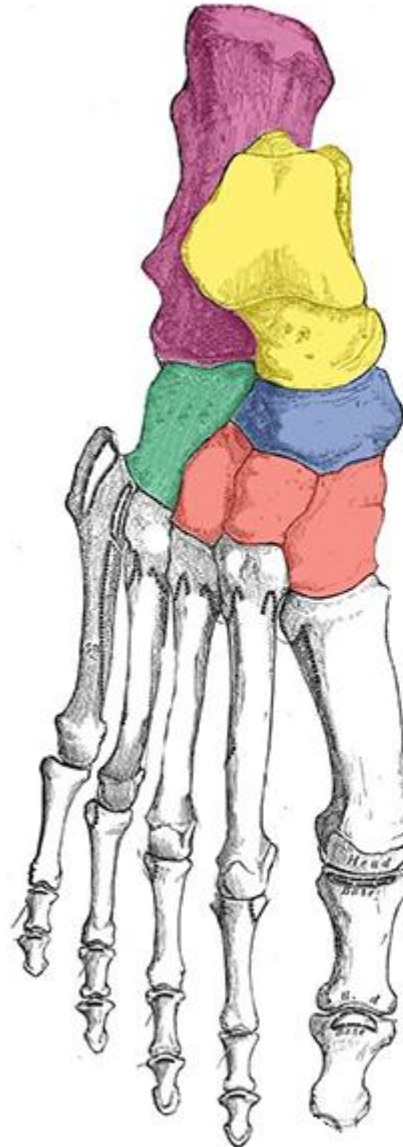
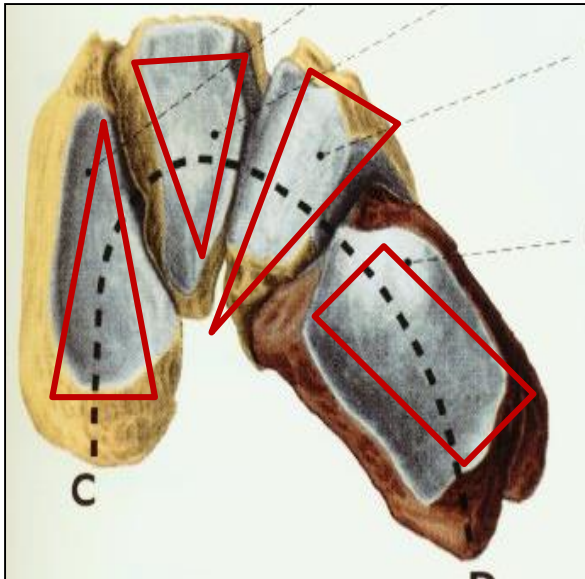
(right, inferior view)

Os cuboideum - sulcus tendinis musculi fibularis longi

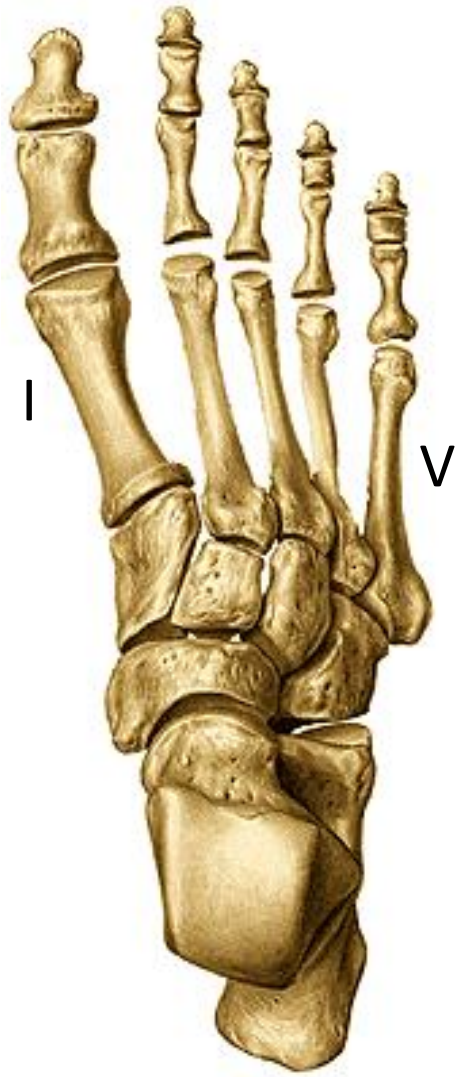

Ossa cuneiformia – mediale, intermedium, laterale

(right, posterior view)



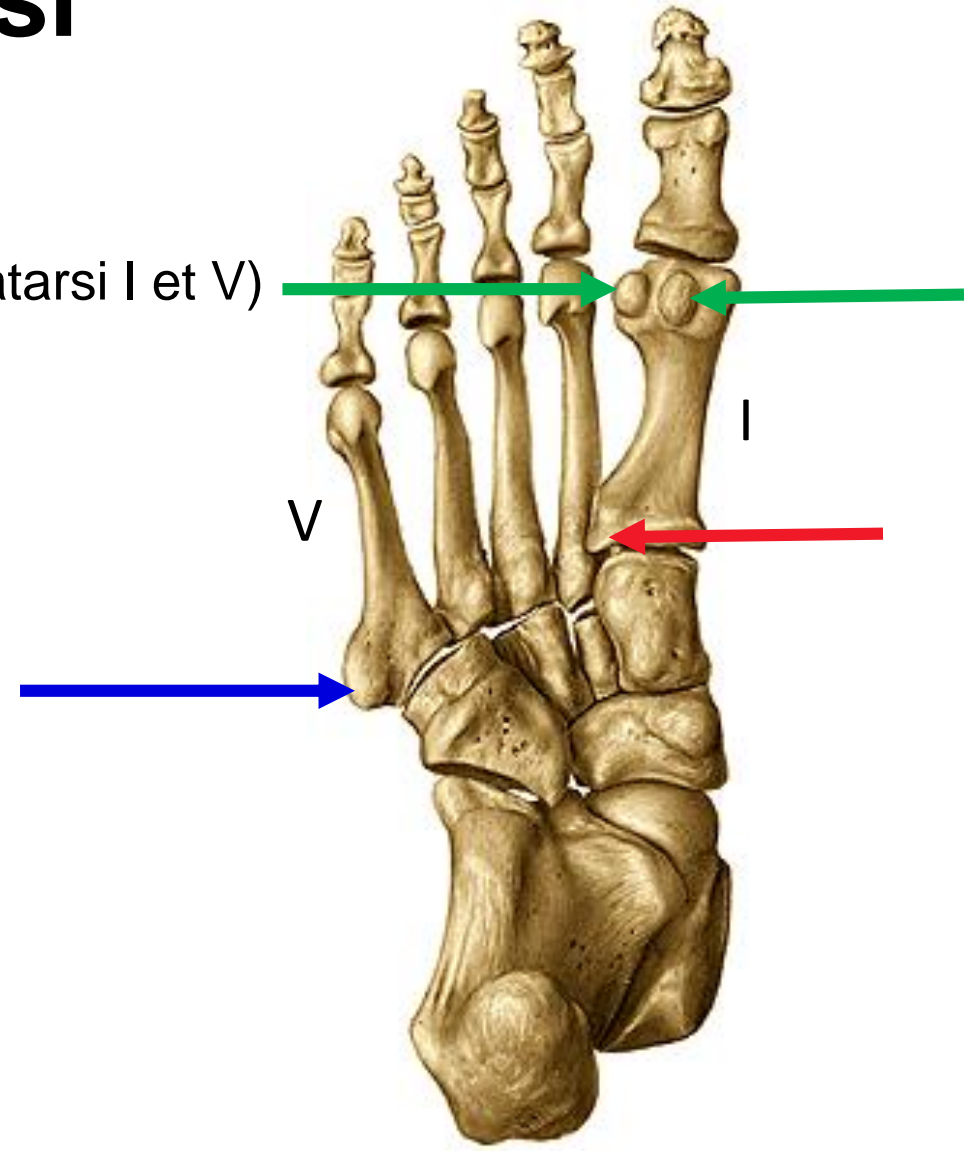
(right, superior view)



Ossa metatarsi

Basis (tuberositas ossis metatarsi I et V)
Corpus
Caput
Ossa sesamoidea

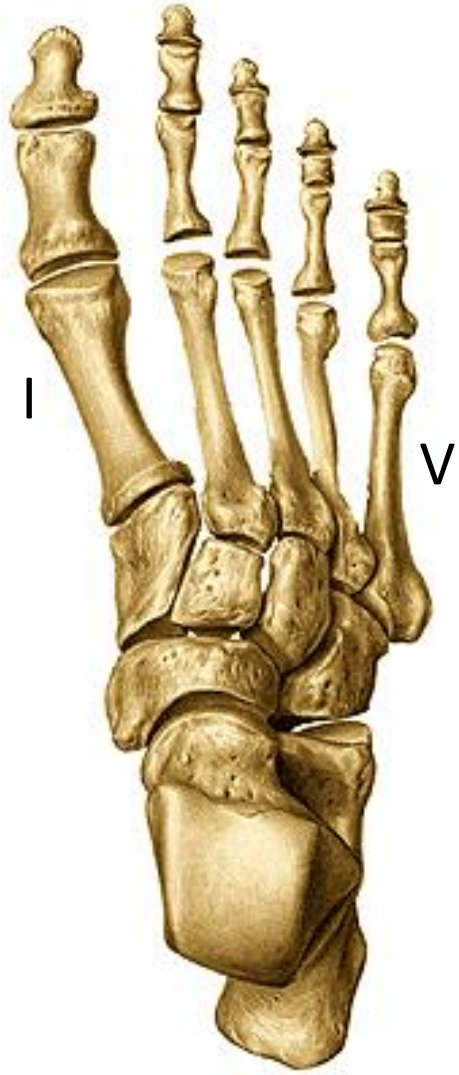(right, inferior view)



(right, superior view)

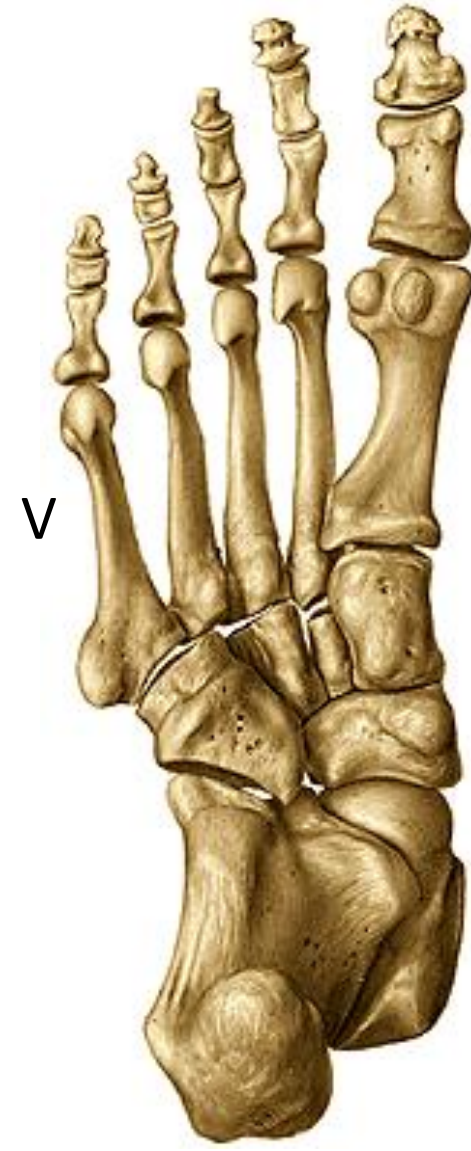Ossa digitorum pedis

(right, inferior view)

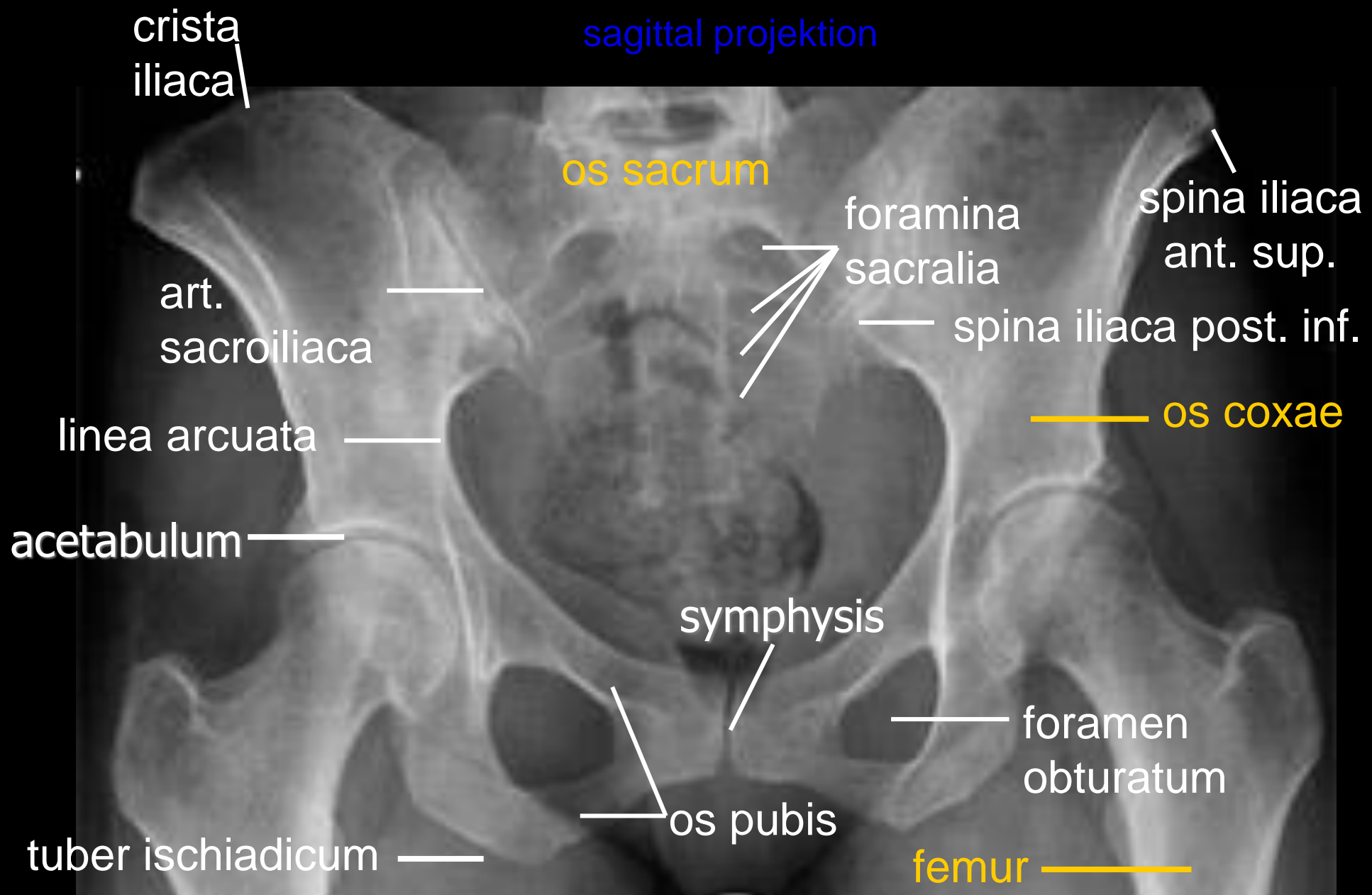


Hallux (big toe): phalanx proximalis et distalis
Digits II – V: phalanx proximalis, media et distalis

- basis phalangis
- corpus phalangis
- caput/trochlea phalangis
- tuberositas phalangis distalis



Pelvis
sagittal projektion



crista iliaca

os sacrum

foramina sacralia

spina iliaca ant. sup.

art. sacroiliaca

spina iliaca post. inf.

linea arcuata

os coxae

acetabulum

symphysis

foramen obturatum

tuber ischiadicum

os pubis

femur

Hip joint

sagittal projection

os coxae

acetabulum

caput femoris

trochanter major

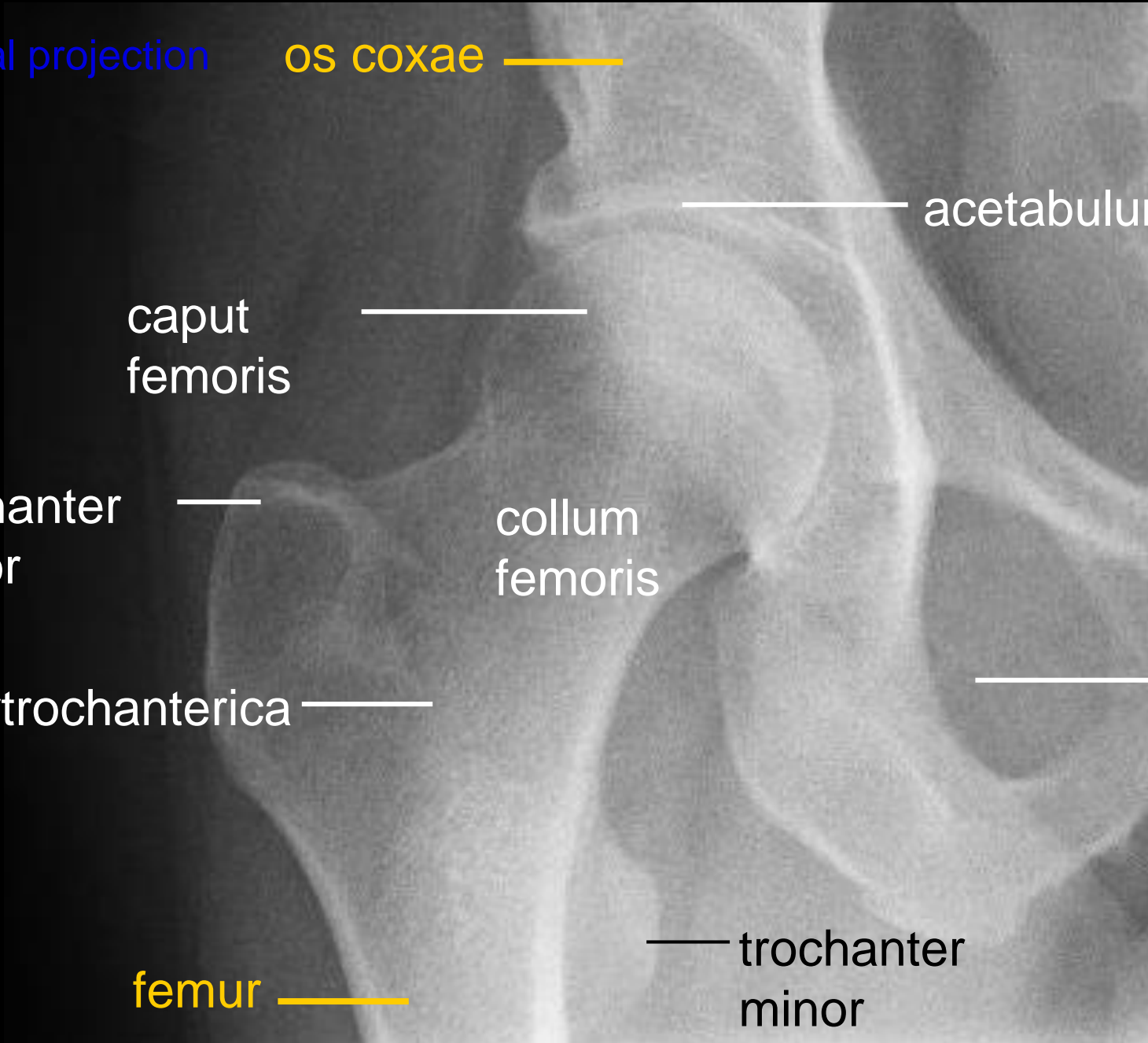
collum femoris

crista intertrochanterica

foramen obturatum

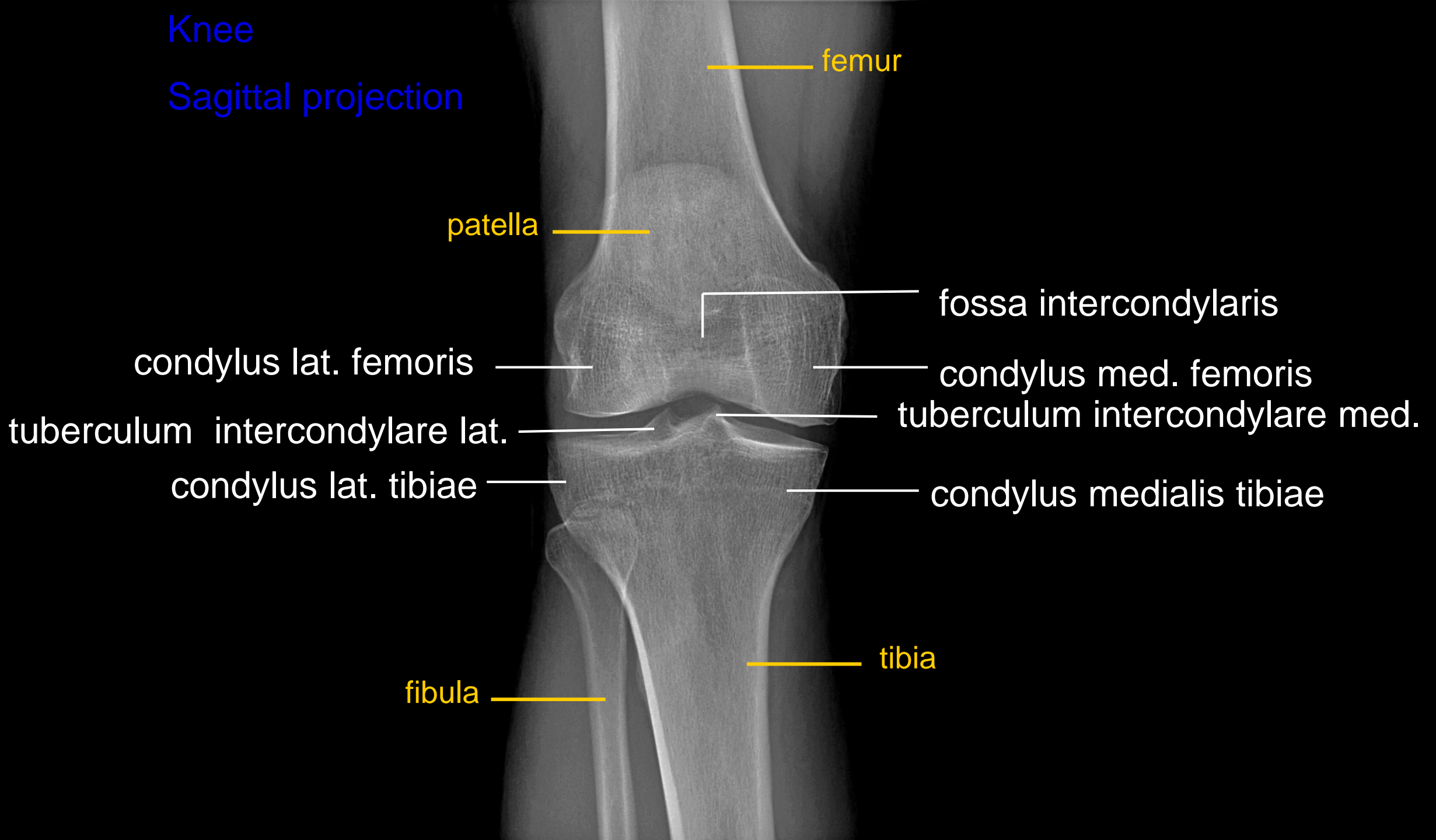
femur

trochanter minor



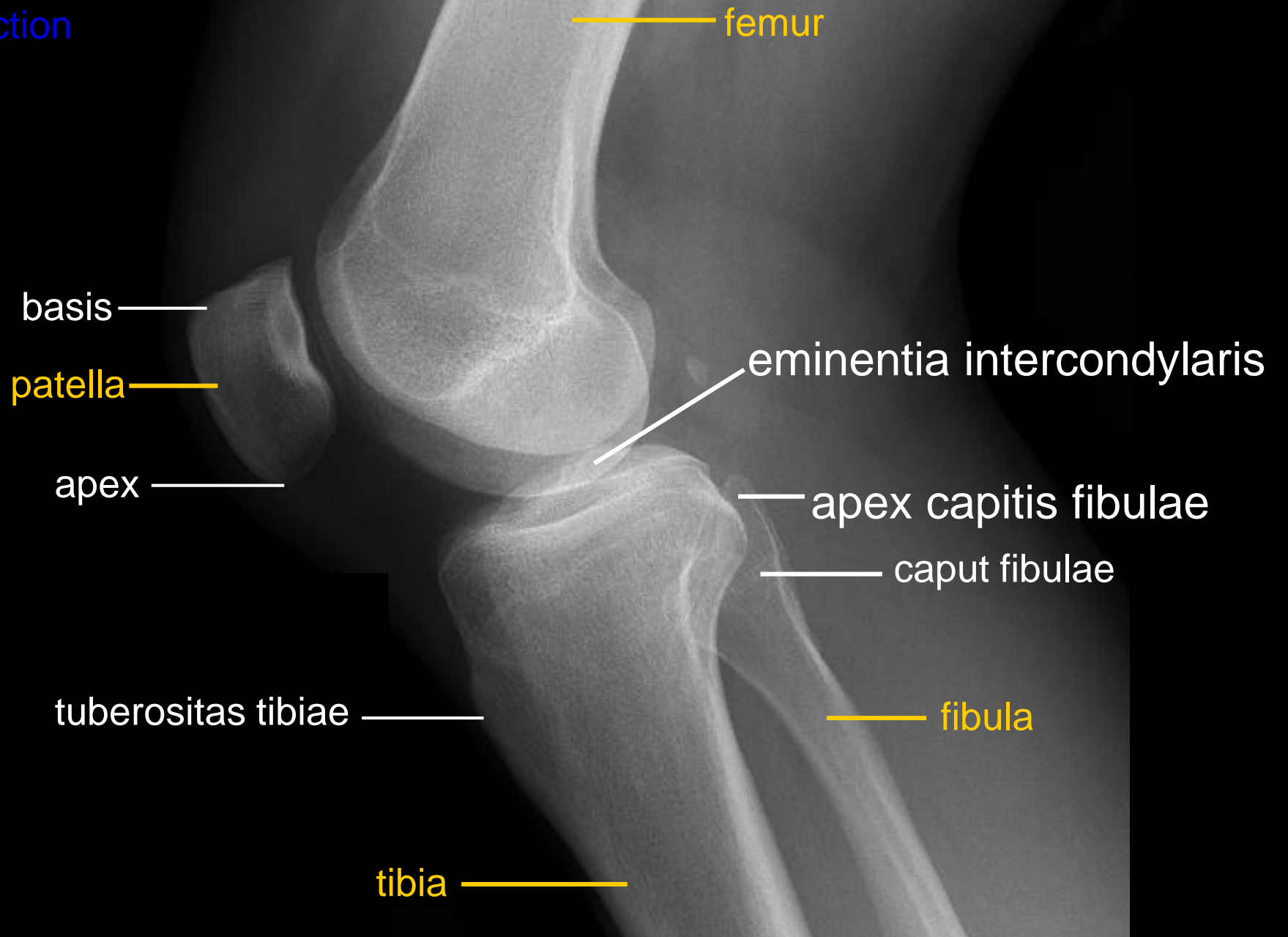
Knee

Sagittal projection



Knee

Lateral projection



FOOT

dorsoplantar
projection

phalanges

sesamoids

metatarsals

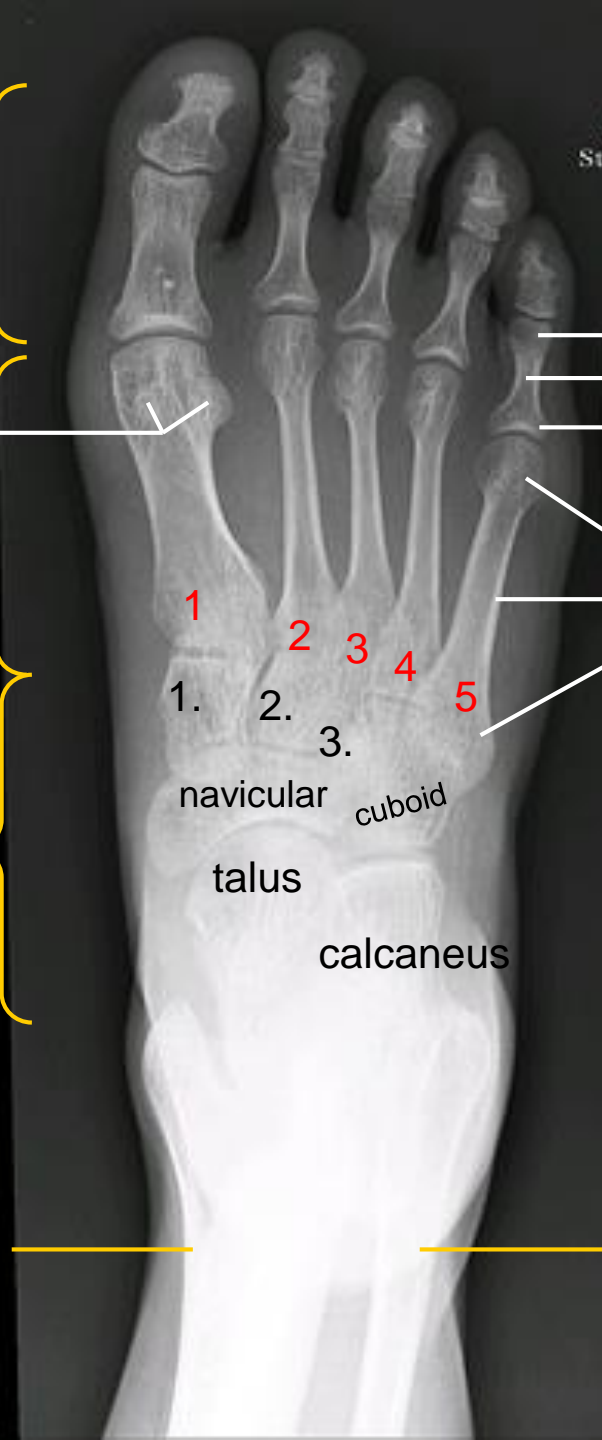tarsals

tibia

trochlea
corpus
basis

caput
corpus
basis

1., 2., 3. = os
cuneiforme mediale,
intermedium et
laterale



1

2

3

4

5

1.

2.

3.

navicular

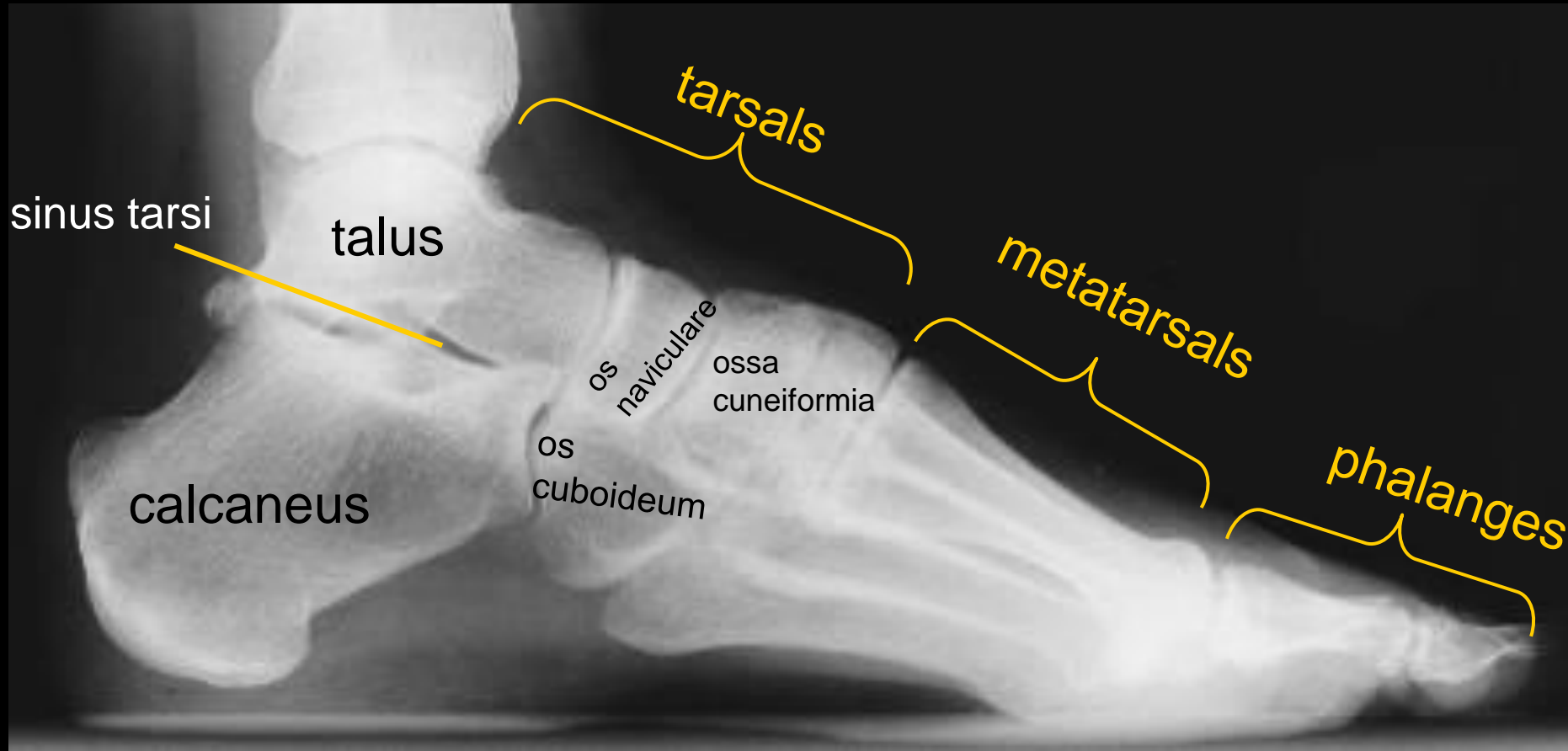
cuboid

talus

calcaneus

Foot

Lateral projection



The pictures used in this lecture were taken from following sources:

- **Atlas der Anatomie des Menschen/Sobotta. Putz,R., und Pabst,R. 20. Auflage. München:Urban & Schwarzenberg, 1993**
- **Netter: Interactive Atlas of Human Anatomy.**
- **Naňka, Elišková: Přehled anatomie. Galén, Praha 2009.**
- **Čihák: Anatomie I, II, III.**
- **Drake et al: Gray´s Anatomy for Students. 2010**
- **Sinelnikov: Atlas of Human Anatomy Vol I Moscow 1963**