

Nervous system

Cortex cerebri

Cerebellum (impregnation)

Spinal cord

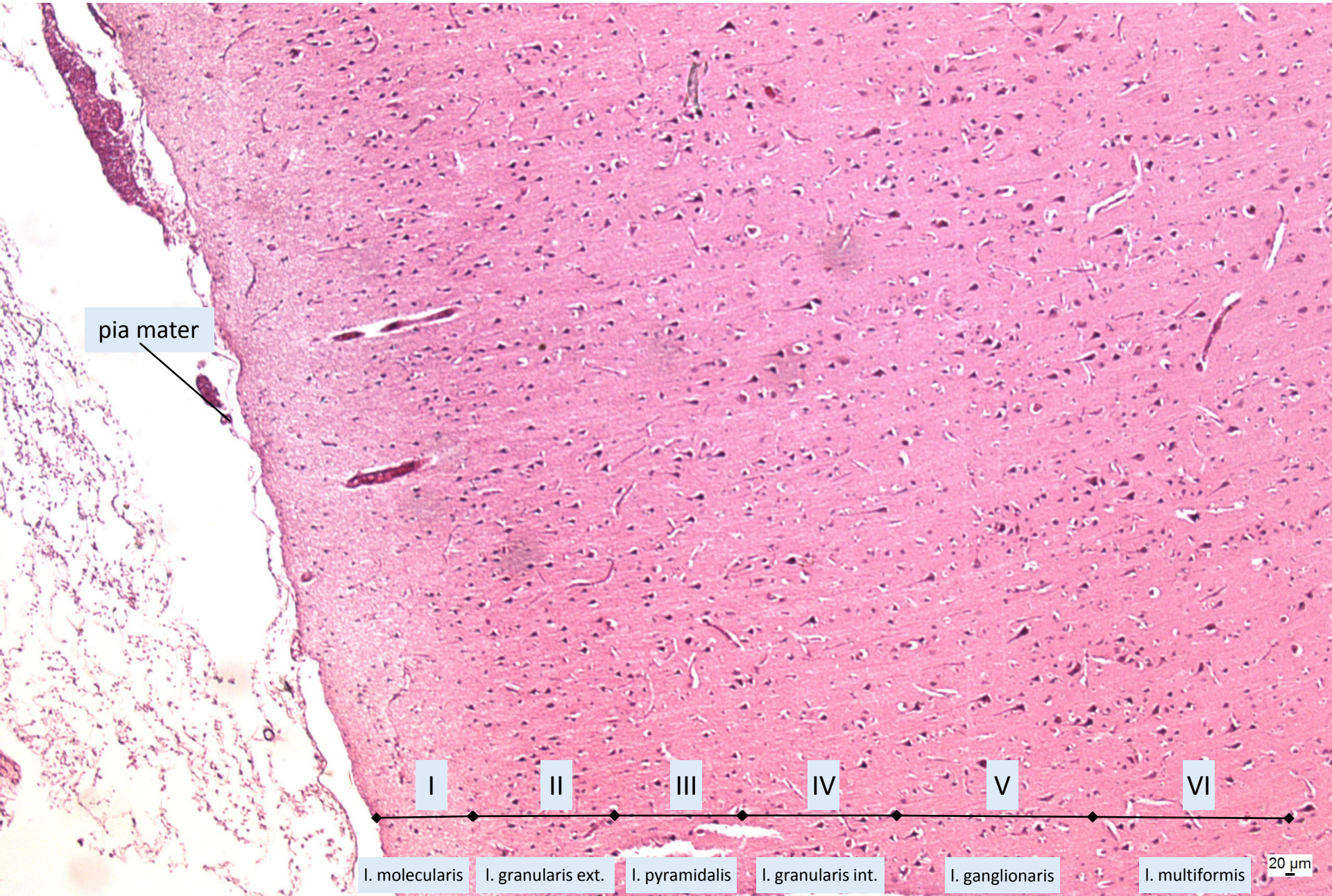
Plexus choroideus

Ganglion spinale

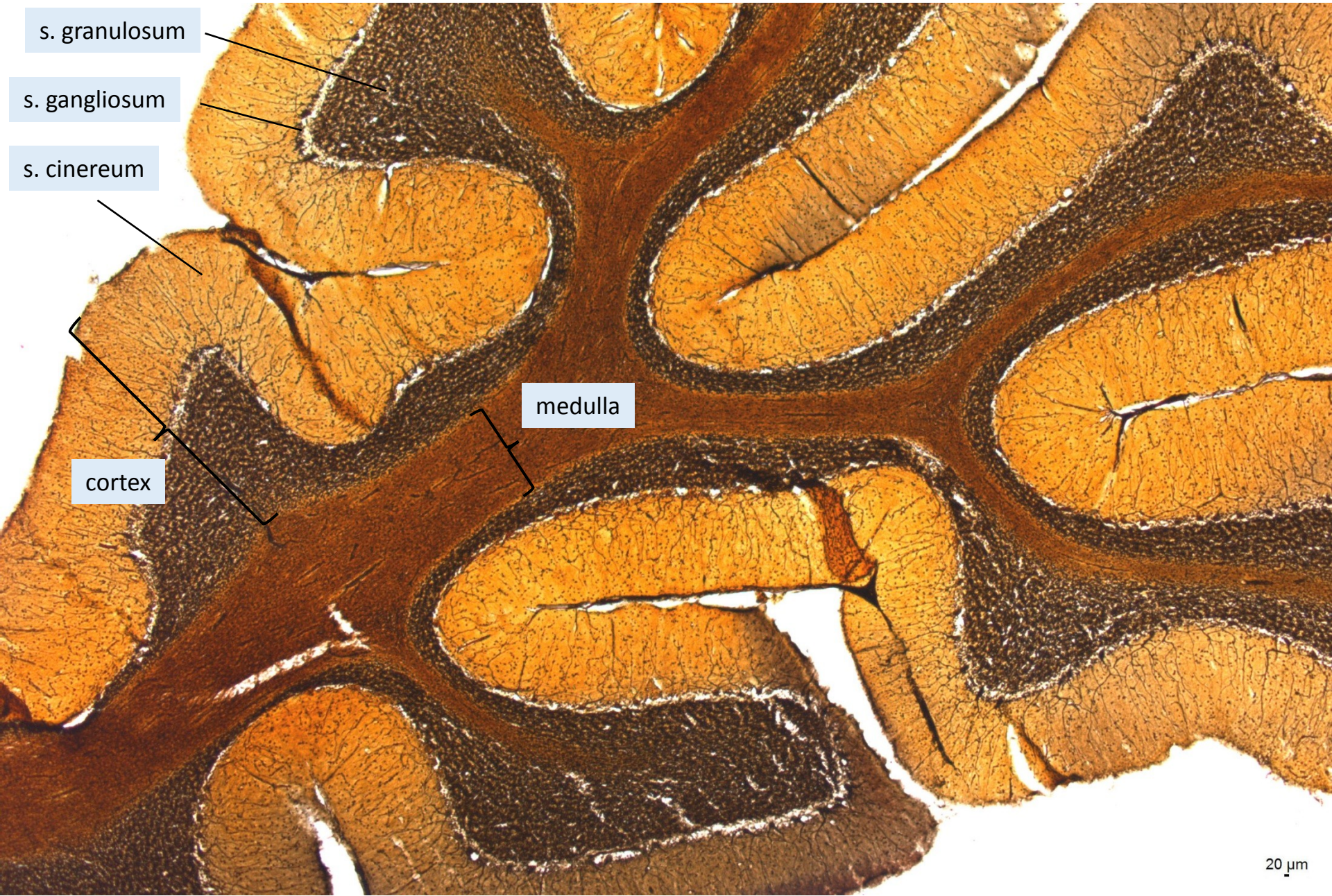
Autonomnic ganglion

Peripheral nerve

Cerebral cortex



Cerebellum



s. granulosum

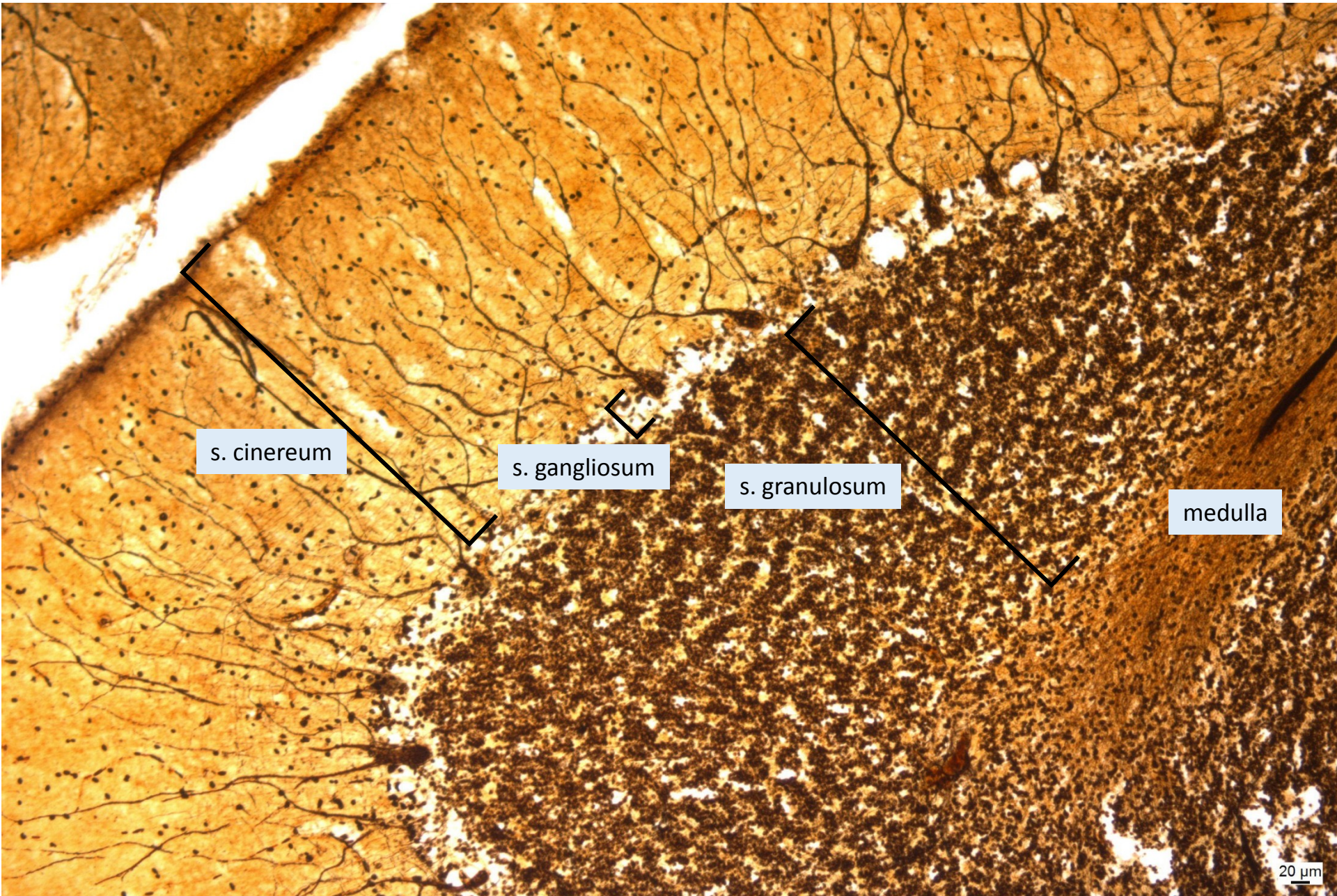
s. gangliosum

s. cinereum

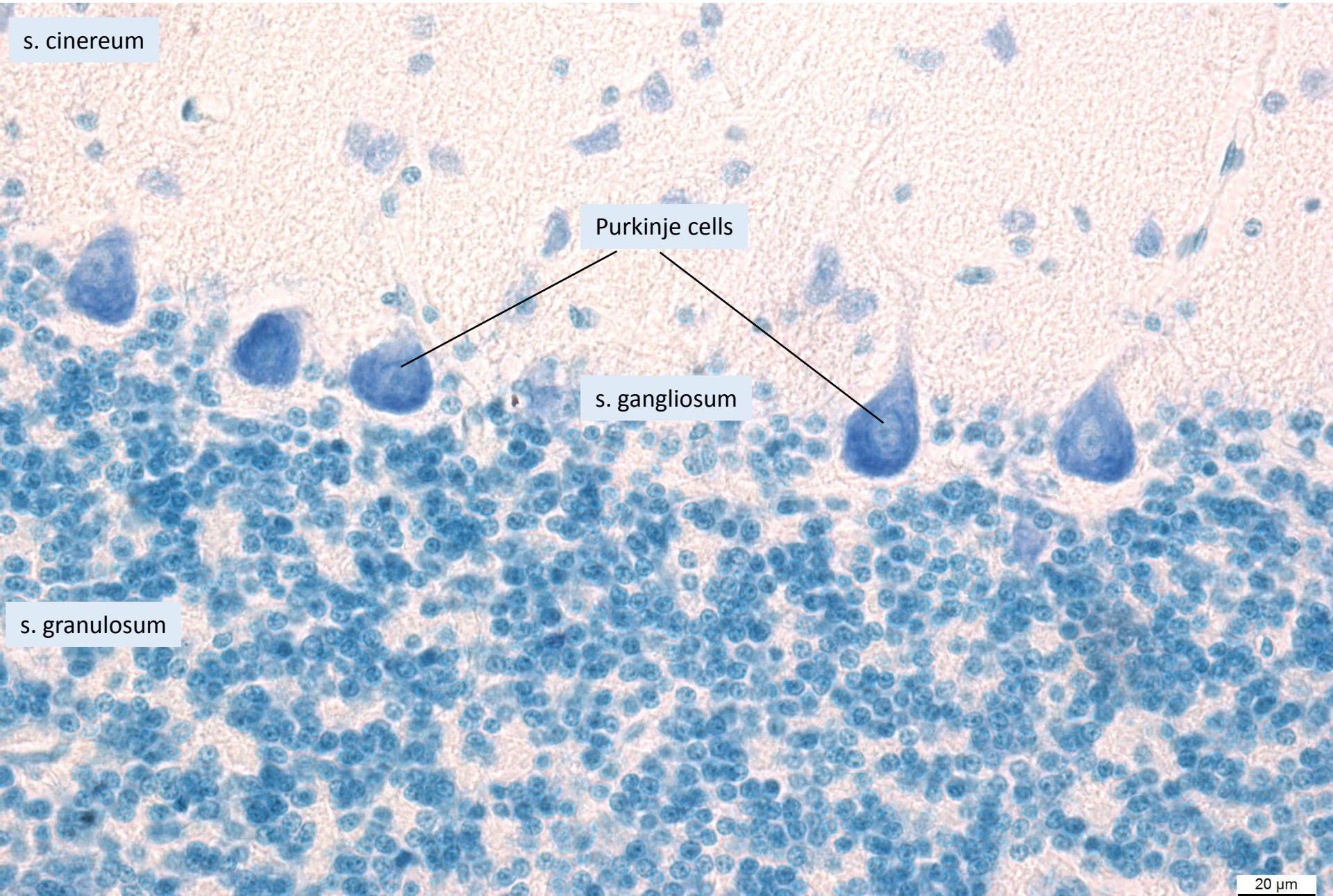
medulla

cortex

Cerebellar cortex



Cerebellar cortex – Purkinje cells



s. cinereum

Purkinje cells

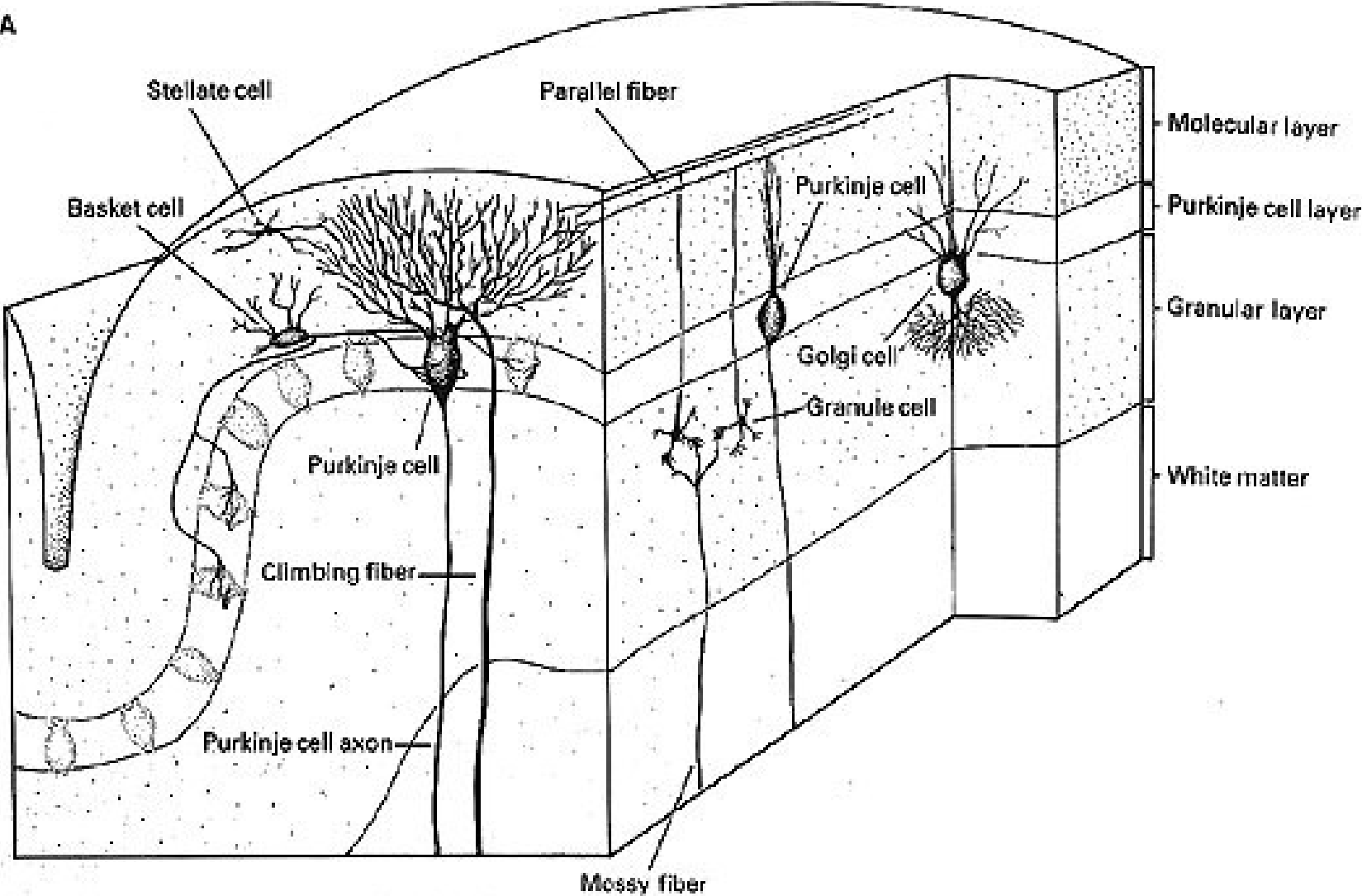
s. gangliosum

s. granulosum

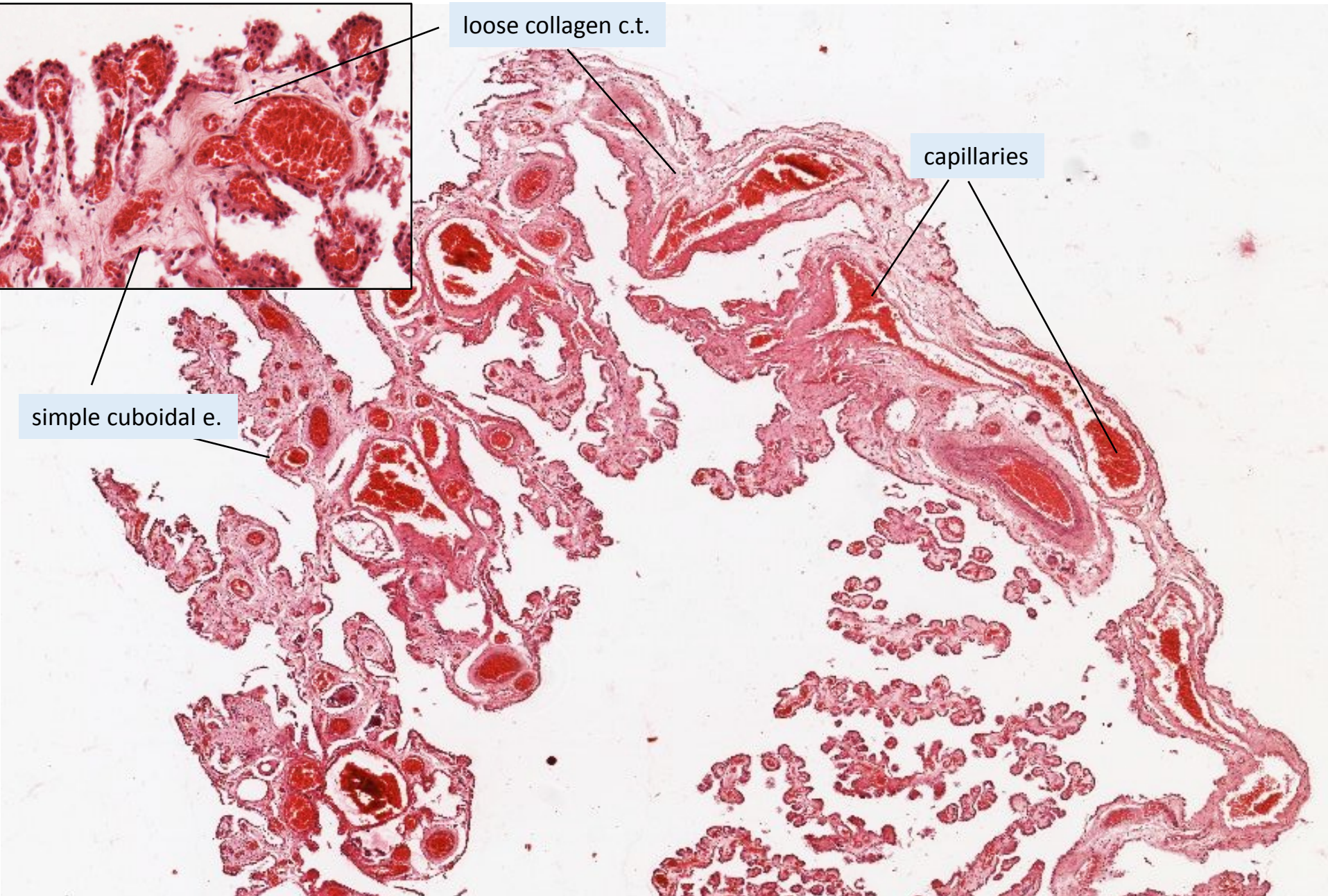
20 µm

Cerebellum – neuron synapses

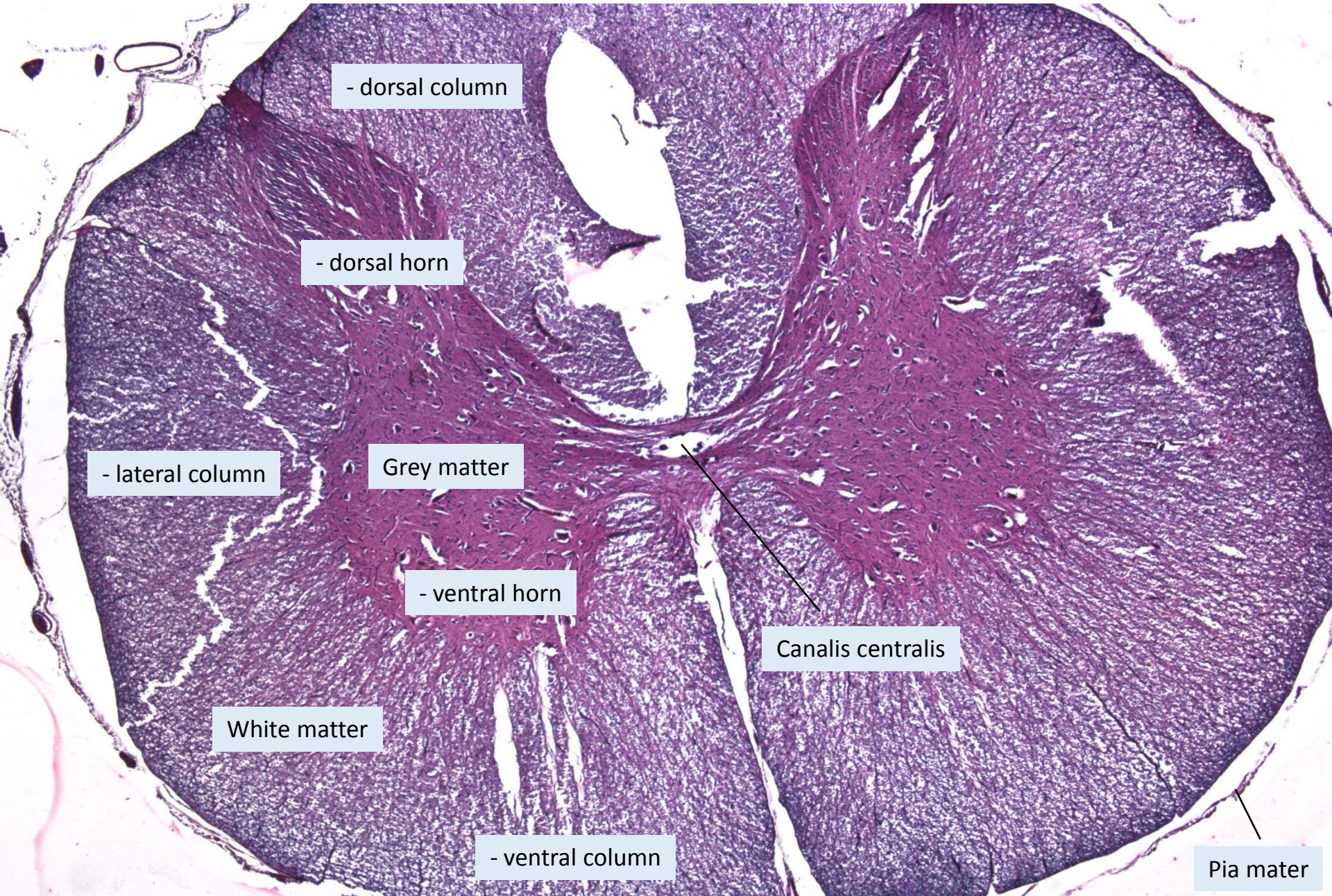
A



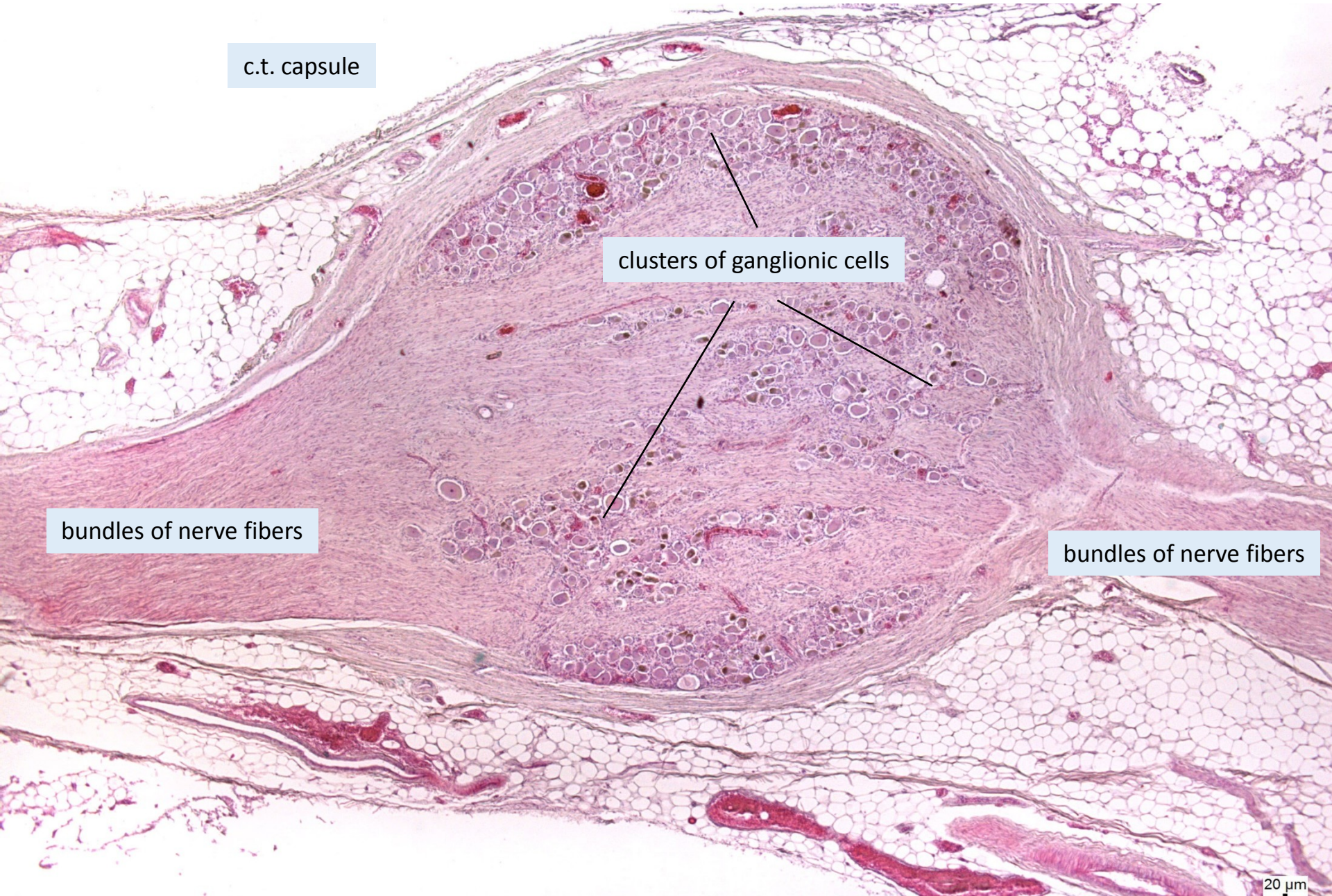
Choroid plexus



Spinal cord



Spinal ganglion



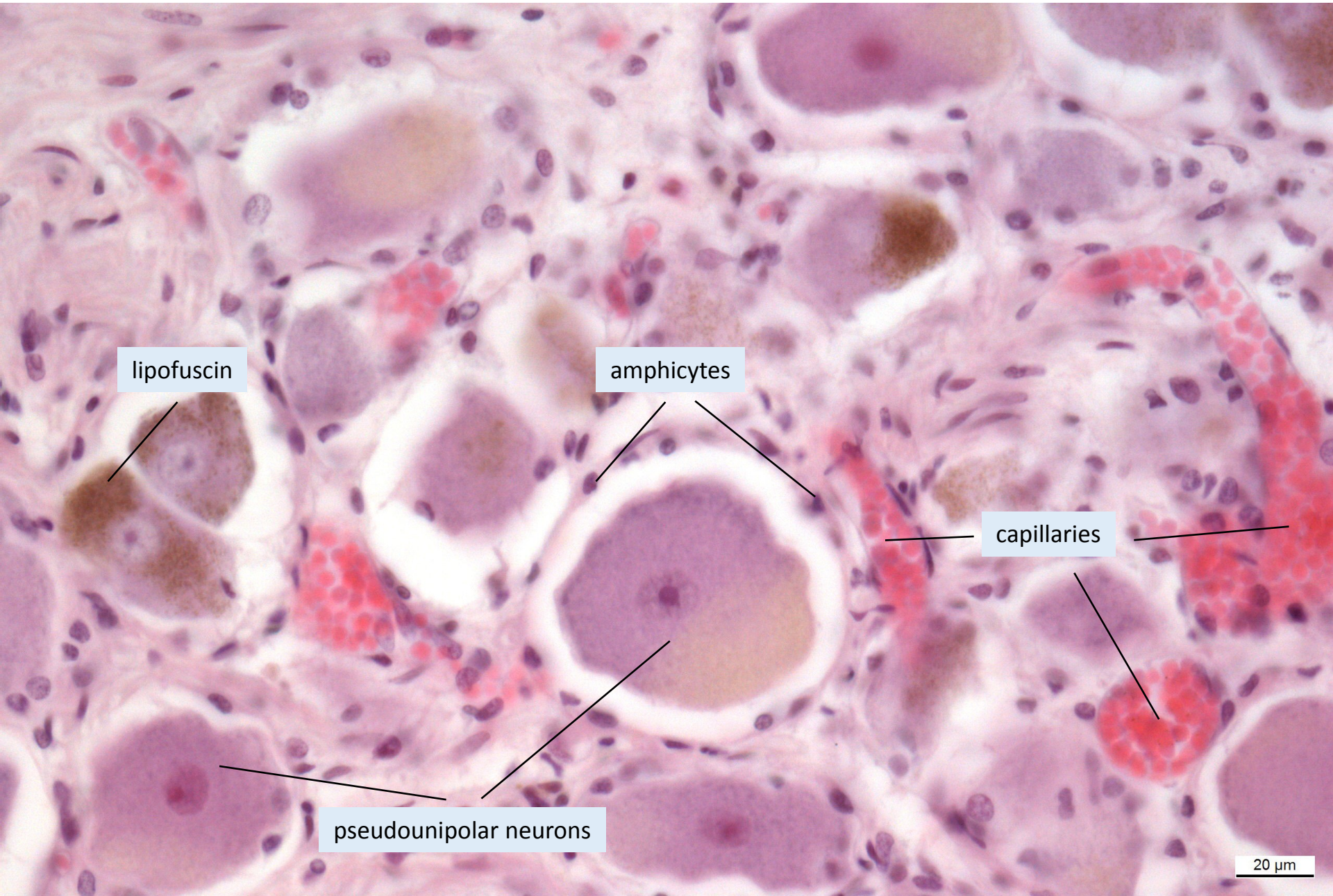
c.t. capsule

clusters of ganglionic cells

bundles of nerve fibers

bundles of nerve fibers

Spinal ganglion



lipofuscin

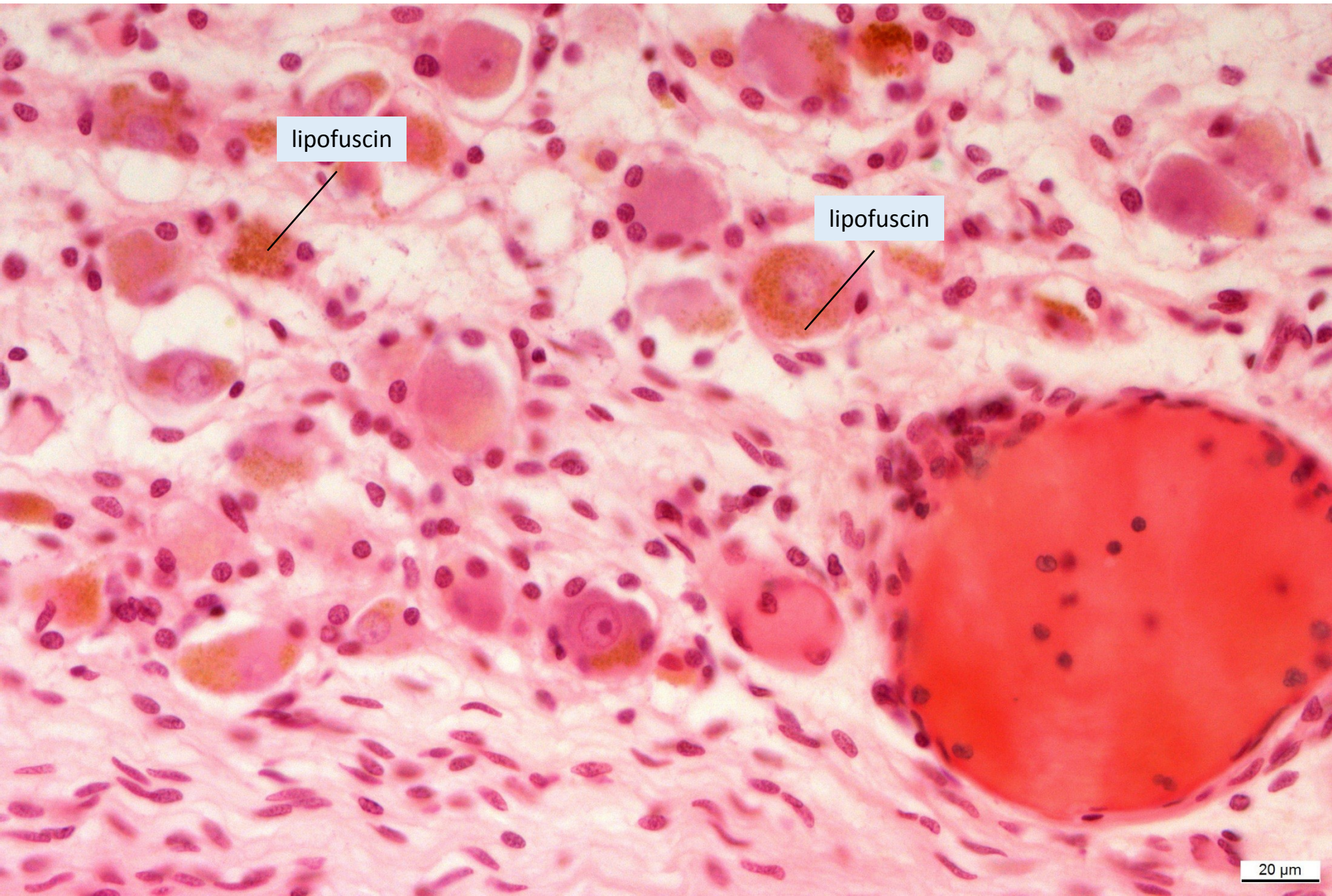
amphicytes

capillaries

pseudounipolar neurons

20 μ m

Spinal ganglion - lipofuscin

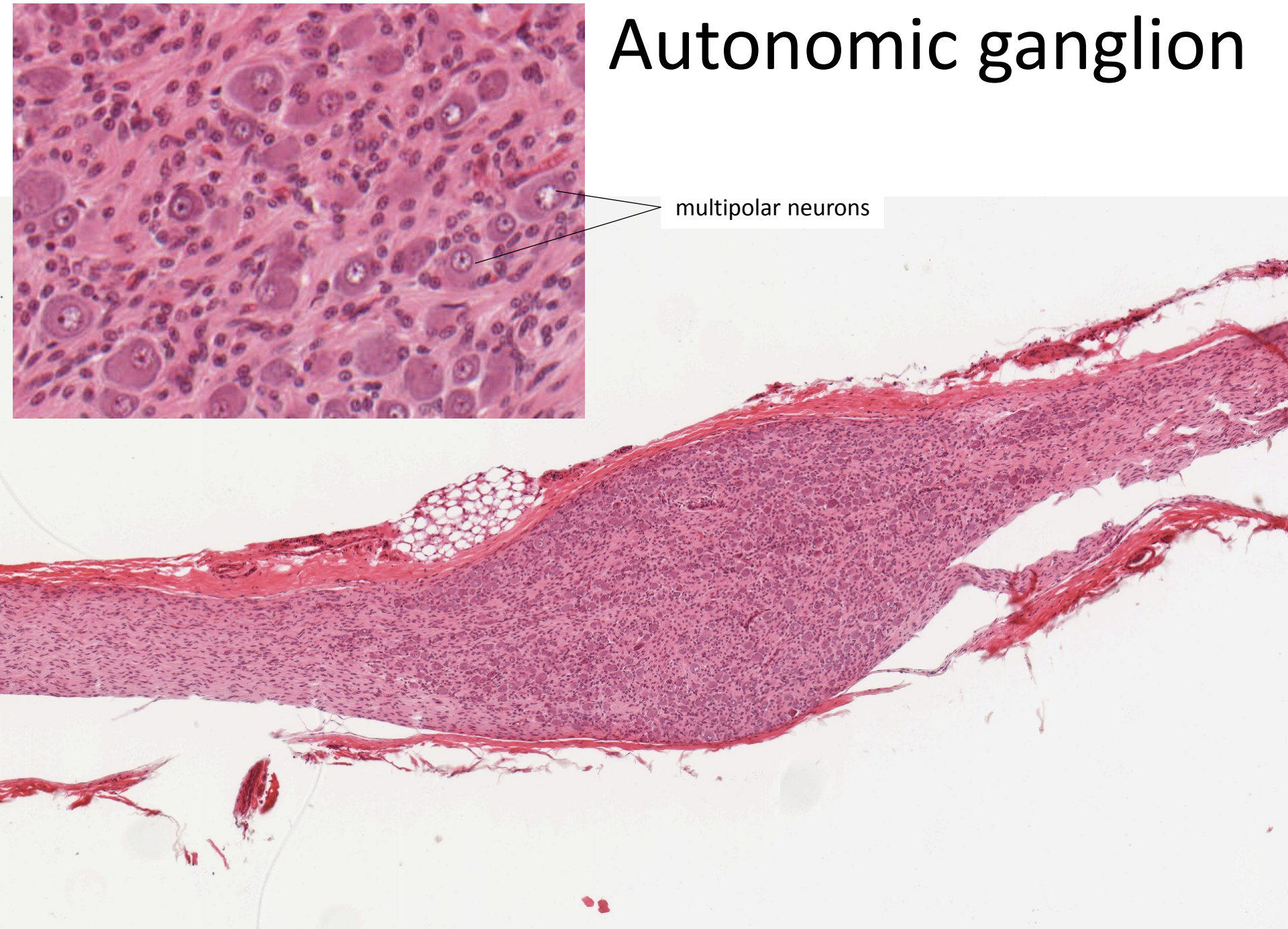


lipofuscin

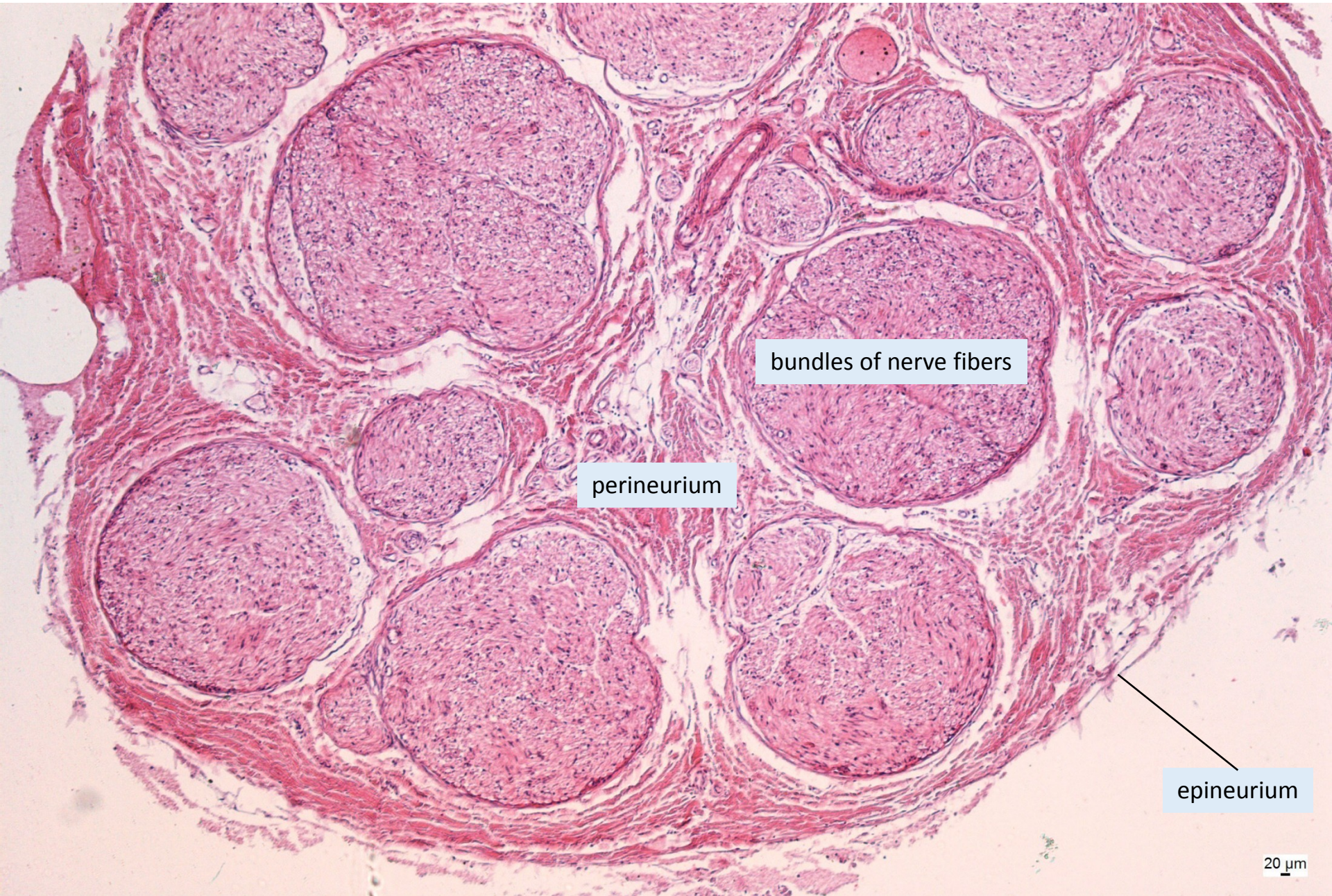
lipofuscin

Autonomic ganglion

multipolar neurons



Peripheral nerve



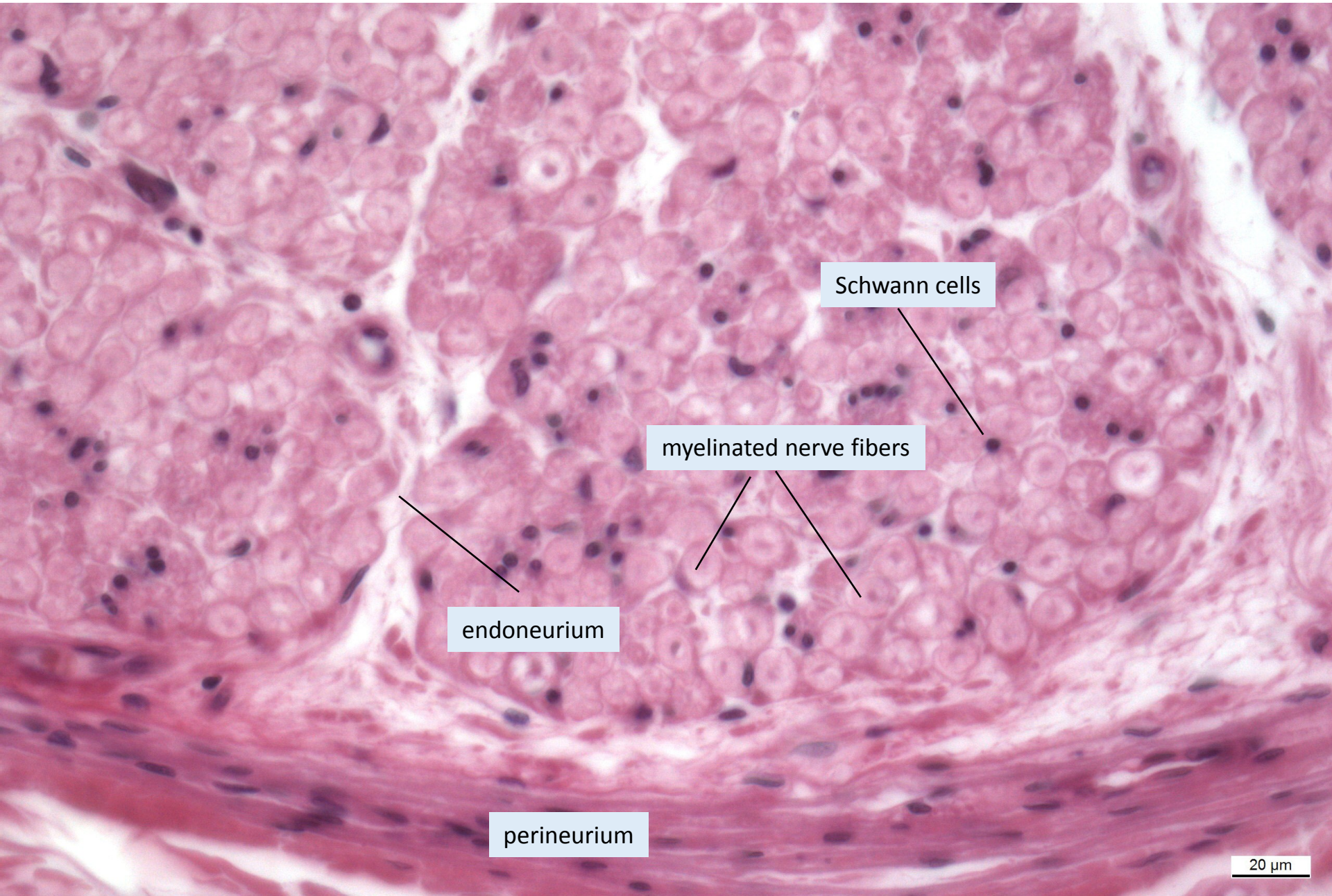
bundles of nerve fibers

perineurium

epineurium

20 μ m

Peripheral nerve



Schwann cells

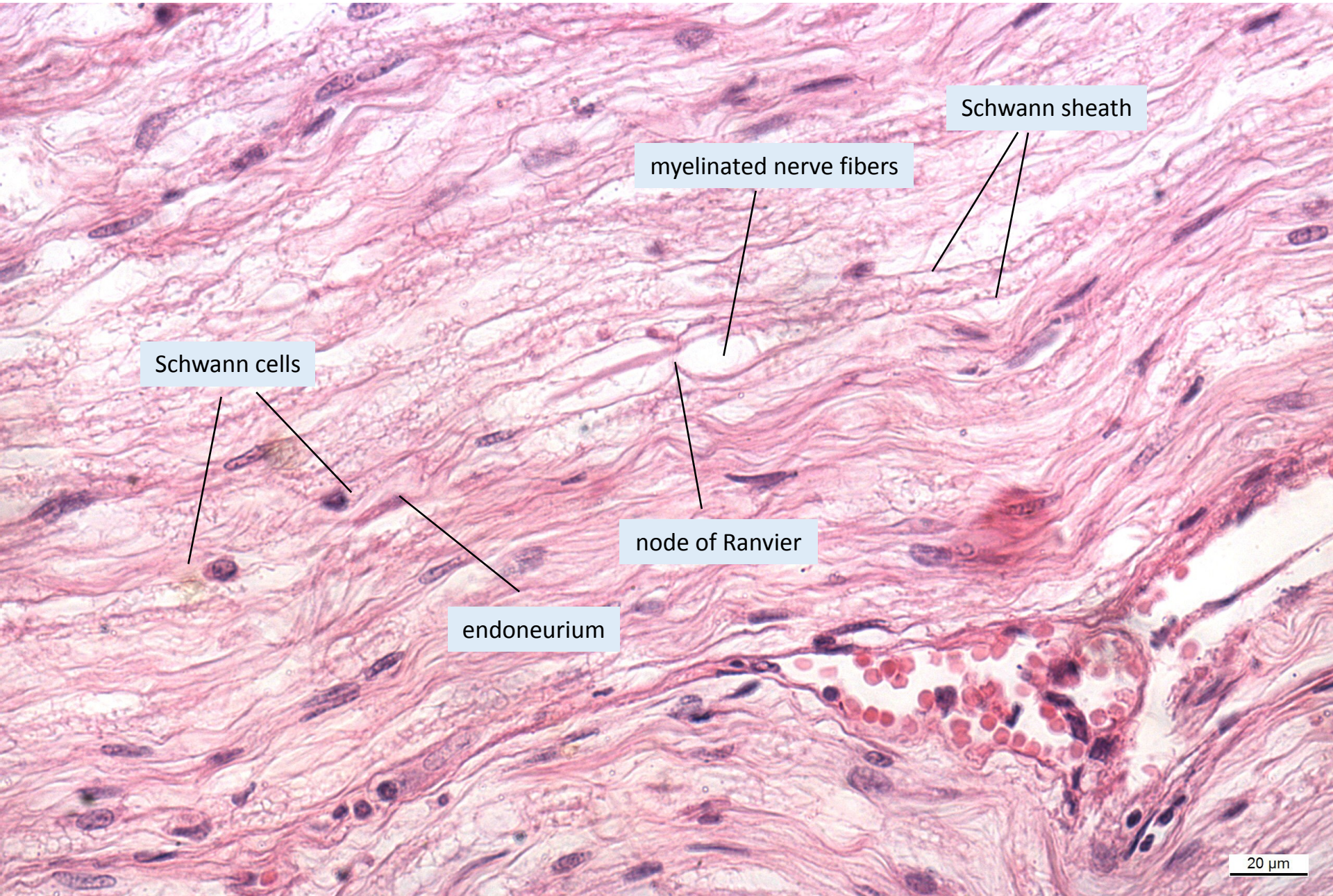
myelinated nerve fibers

endoneurium

perineurium

20 μ m

Peripheral nerve



Schwann sheath

myelinated nerve fibers

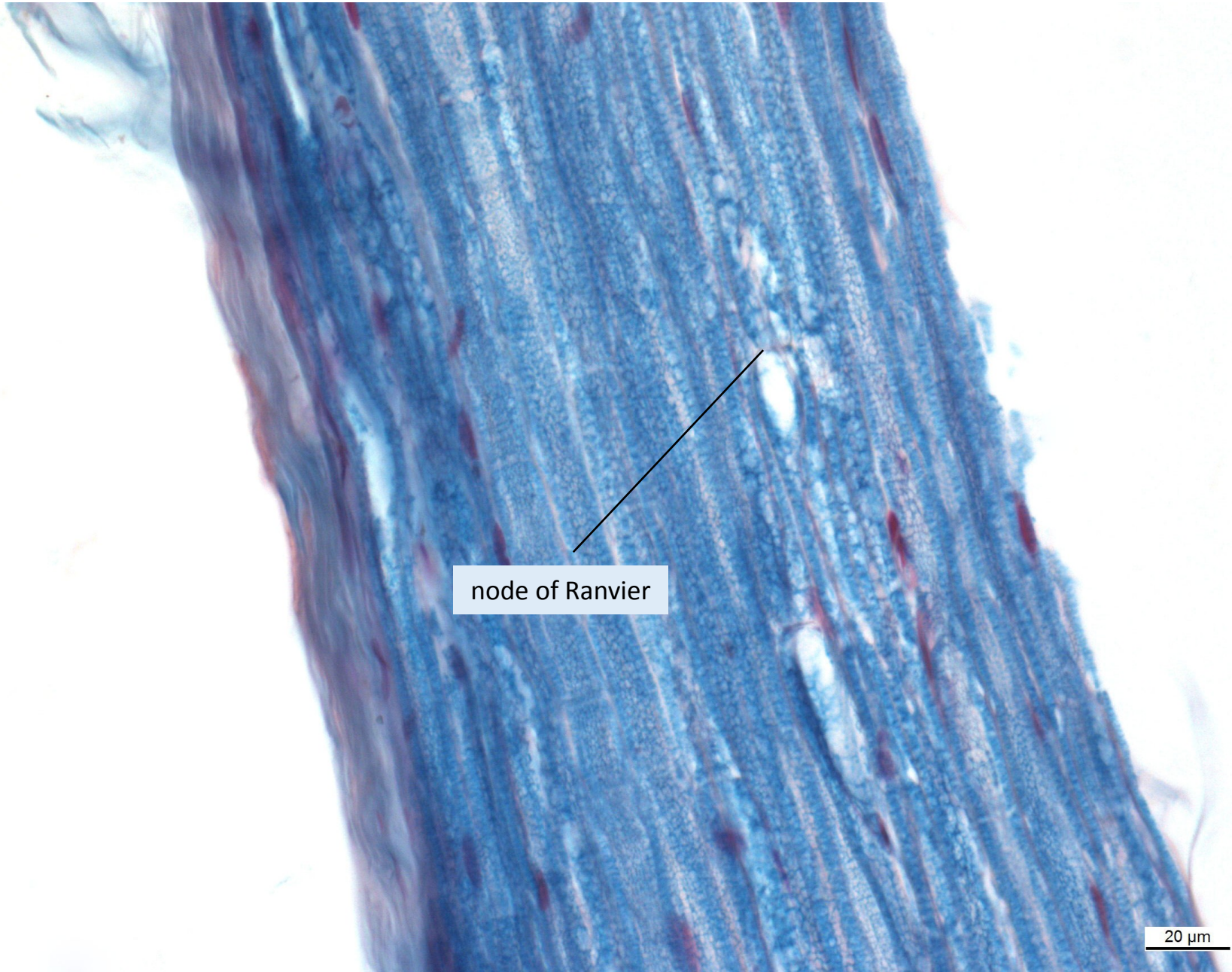
Schwann cells

node of Ranvier

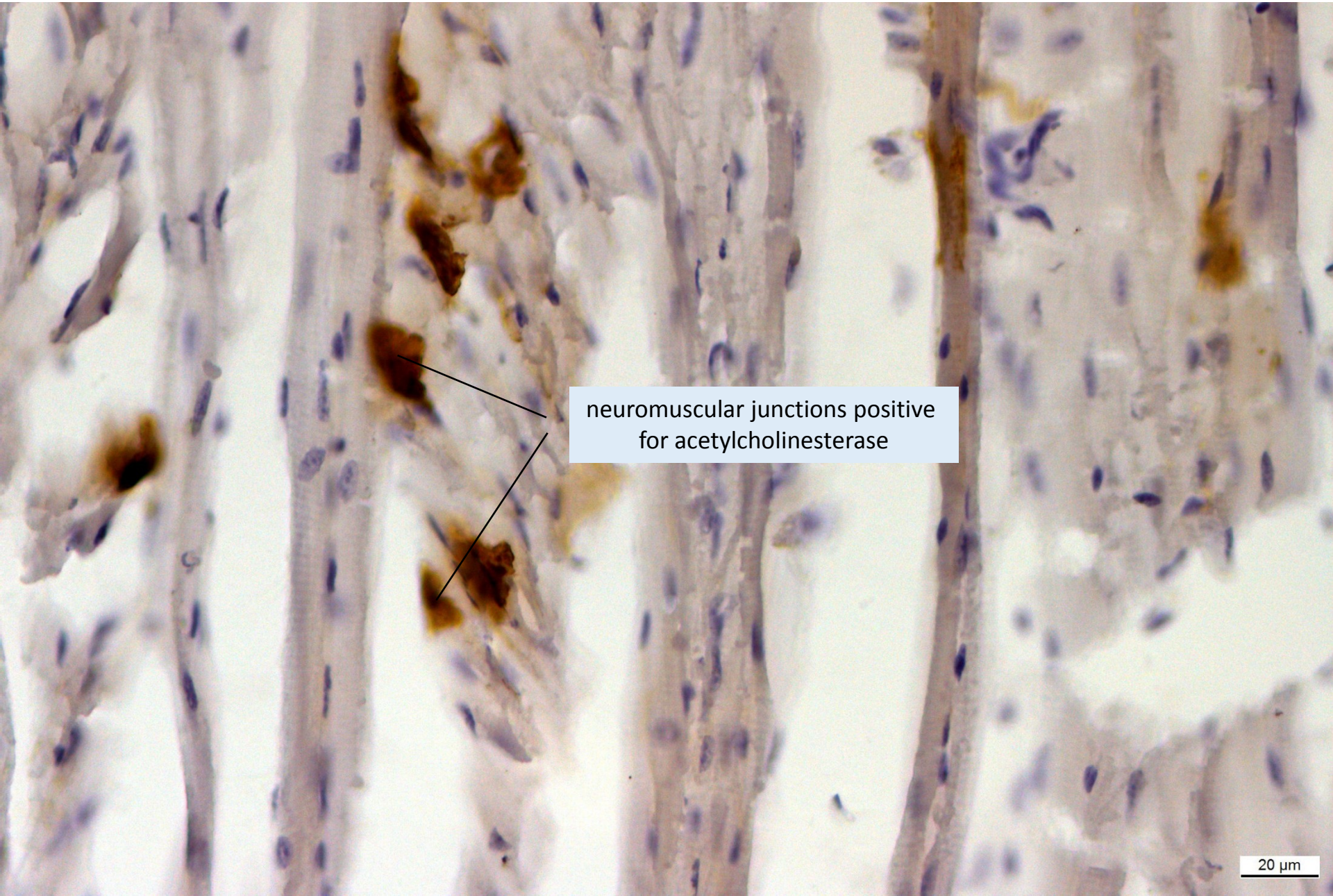
endoneurium

20 μm

Peripheral nerve



Neuromuscular junction

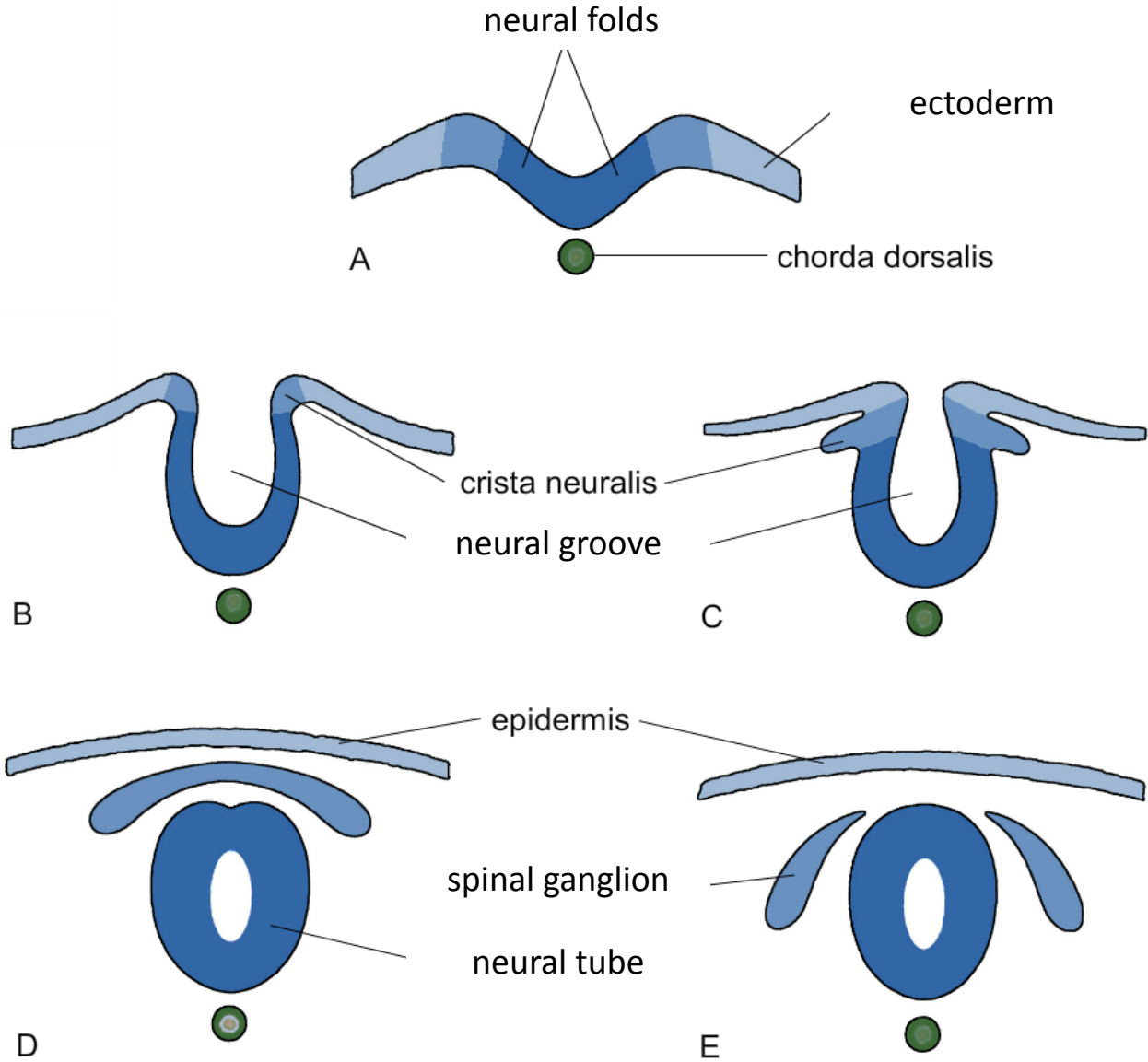


neuromuscular junctions positive
for acetylcholinesterase

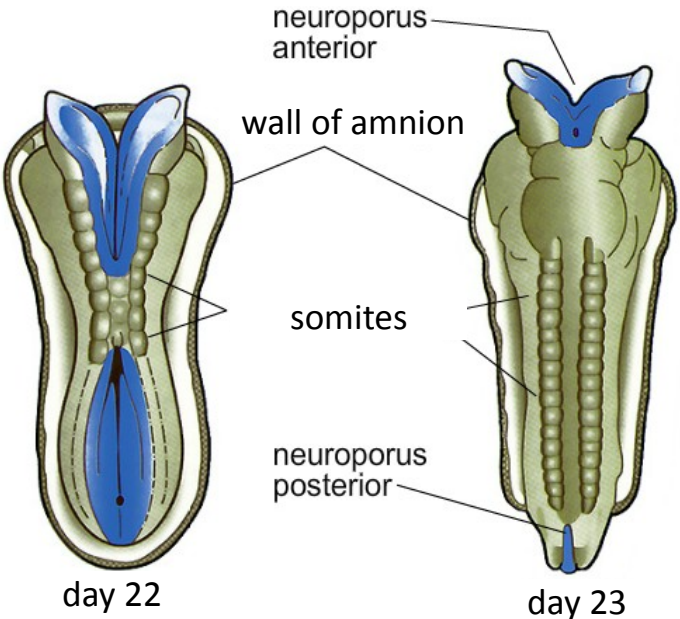
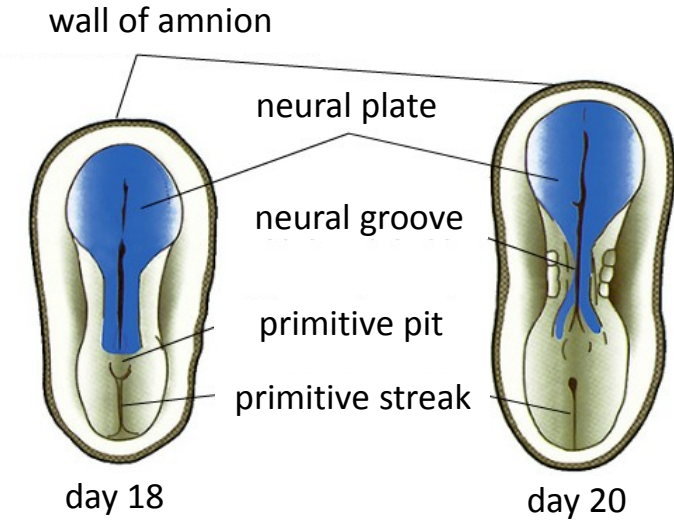
List of slides

- 75. Cortex cerebri
- 76. Cortex cerebri (impregnation)
- 77. Cerebellum (impregnation)
- 78. Cerebellum (Nissl substance)
- 79. Medulla spinalis
- 80. Plexus choroideus
- 81. Ganglion spinale
- 82. Ganglion spinale (impregnation)
- 83. Ganglion autonomic
- 84. Peripheral nerve – cross section
- 85. Peripheral nerve – cross section (myelin)
- 86. Peripheral nerve – longitudinal section
- 87. Peripheral nerve – longitudinal section (myelin)

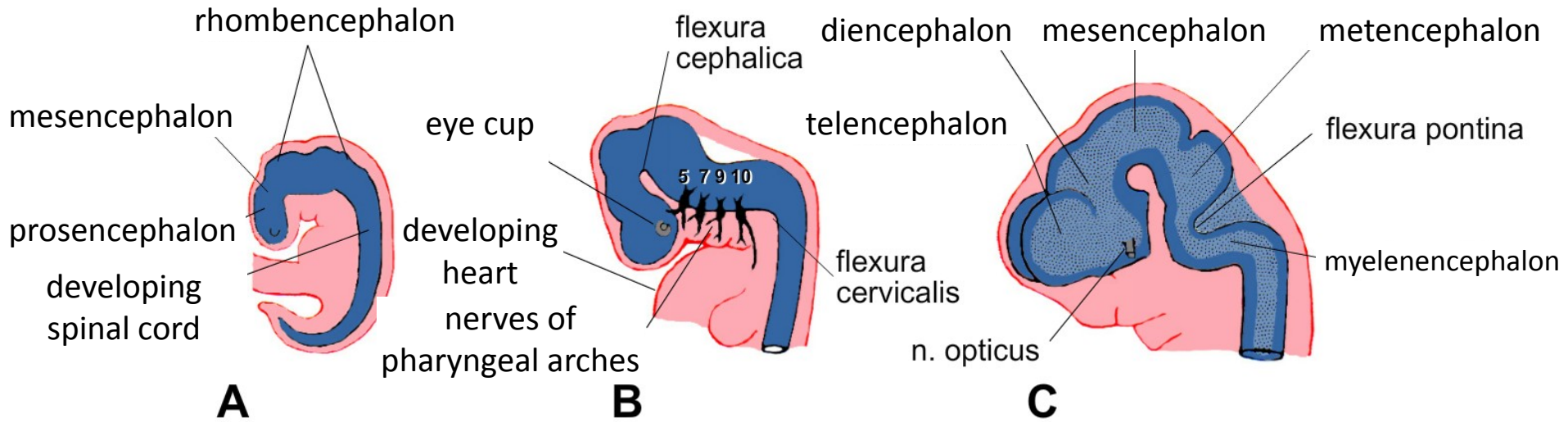
Development of neural tube



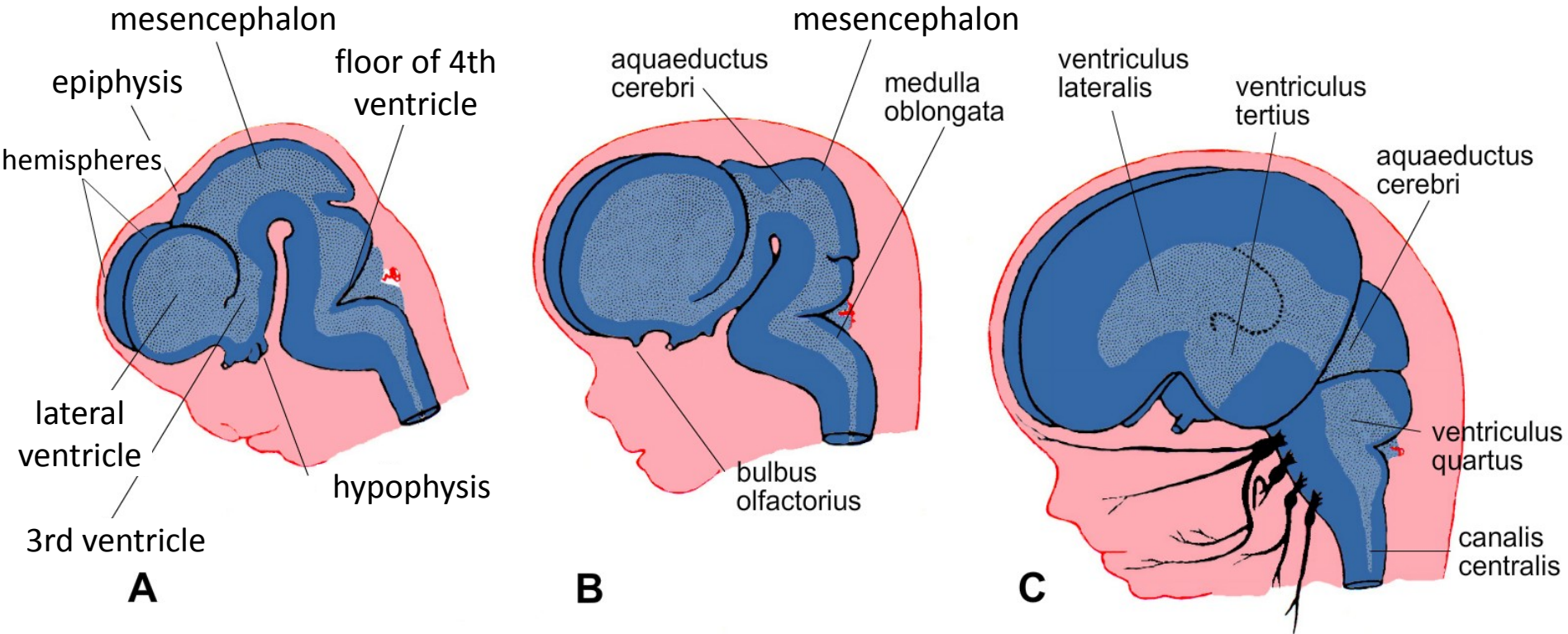
Closing of neural tube



Development of brain



Development of brain



Development of spinal cord

