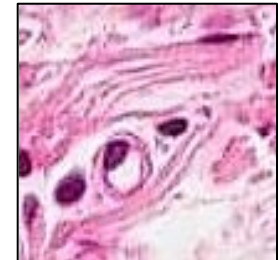

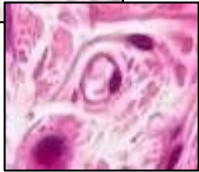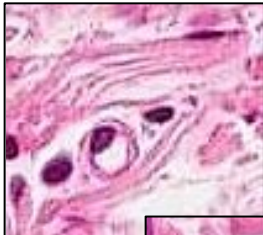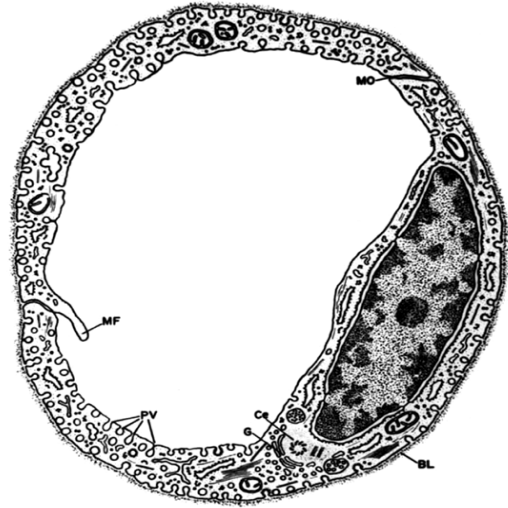


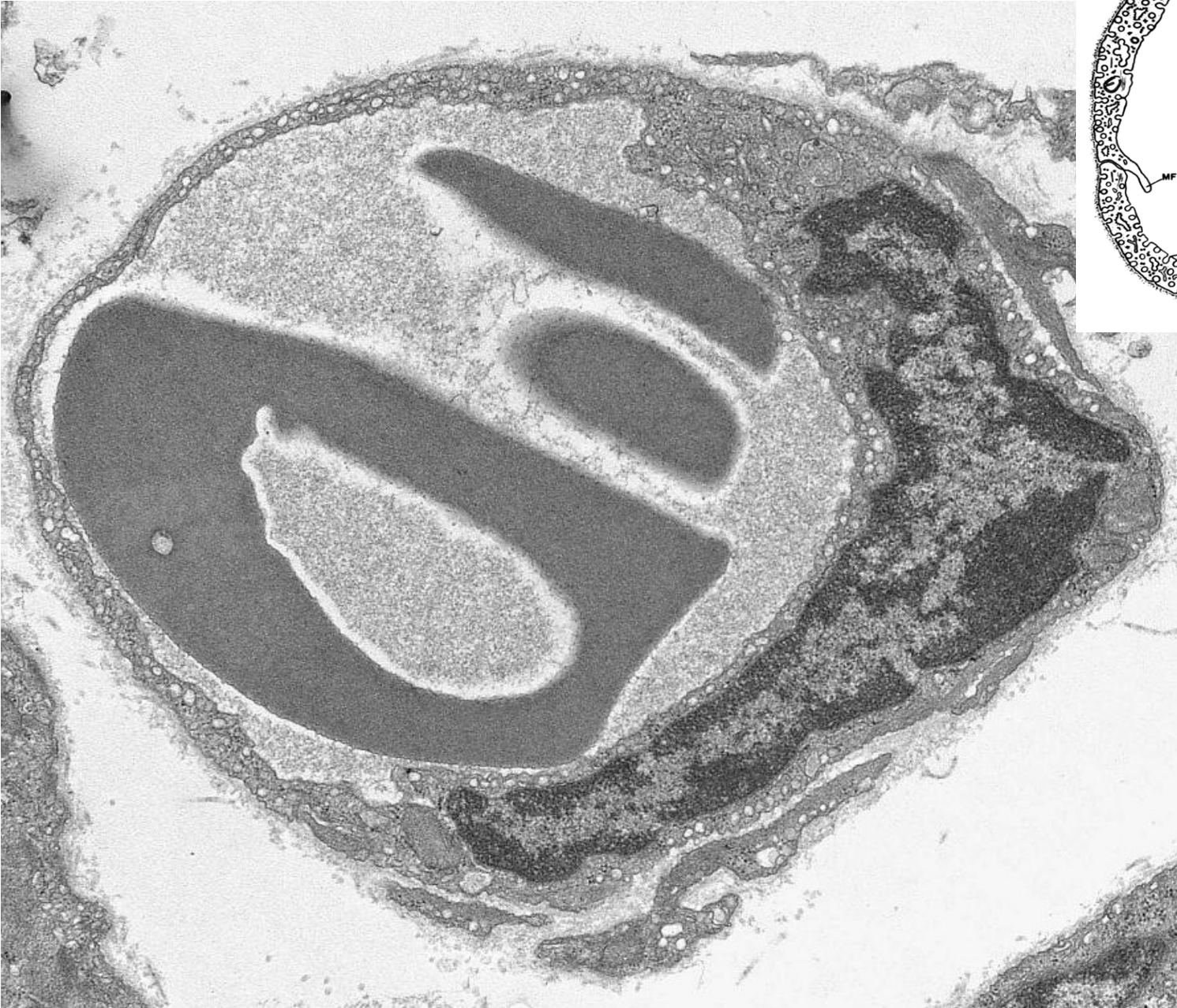# CARDIOVASCULAR SYSTEM

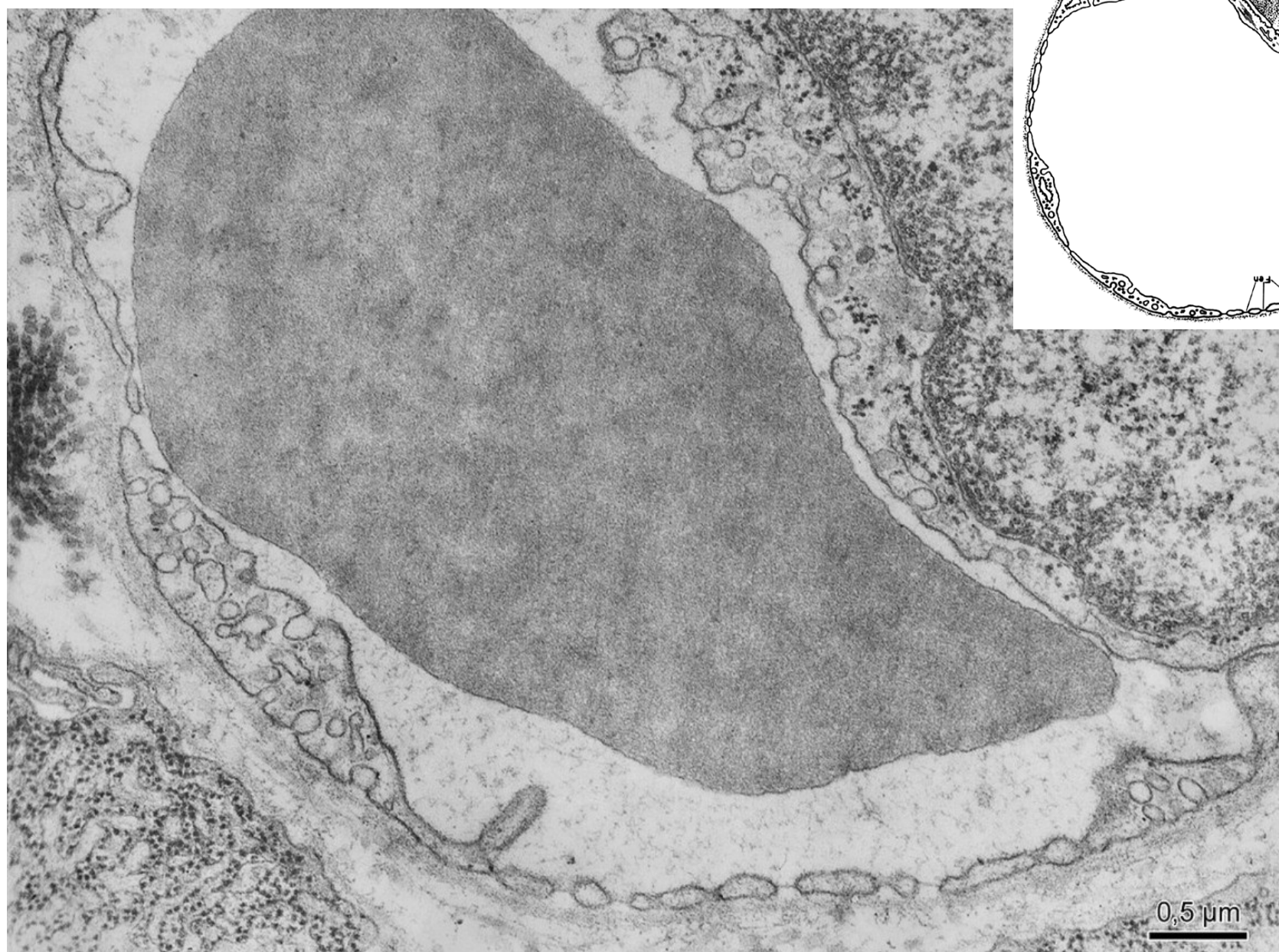
- Heart
- Vessels
  - arteries
  - veins
  - capillaries
    - continuous
    - fenestrated
    - sinusoids



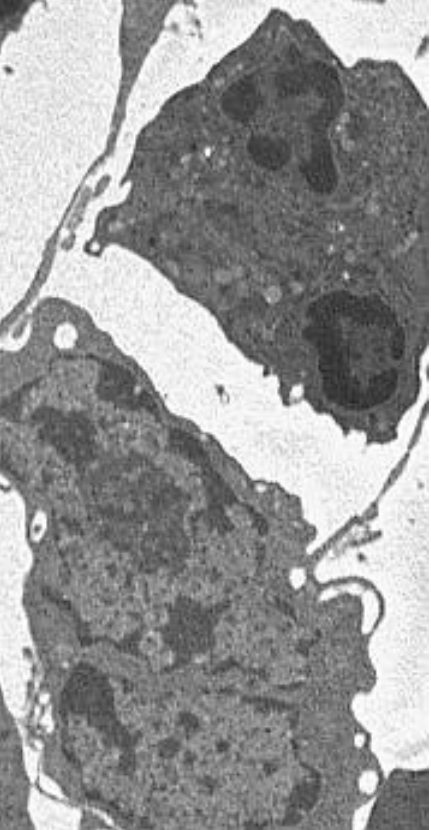
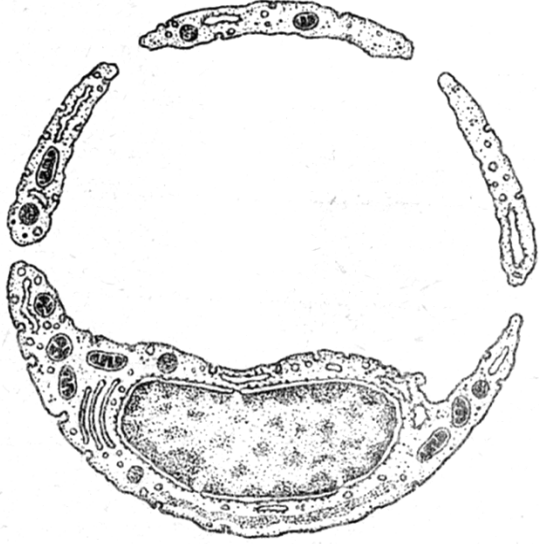
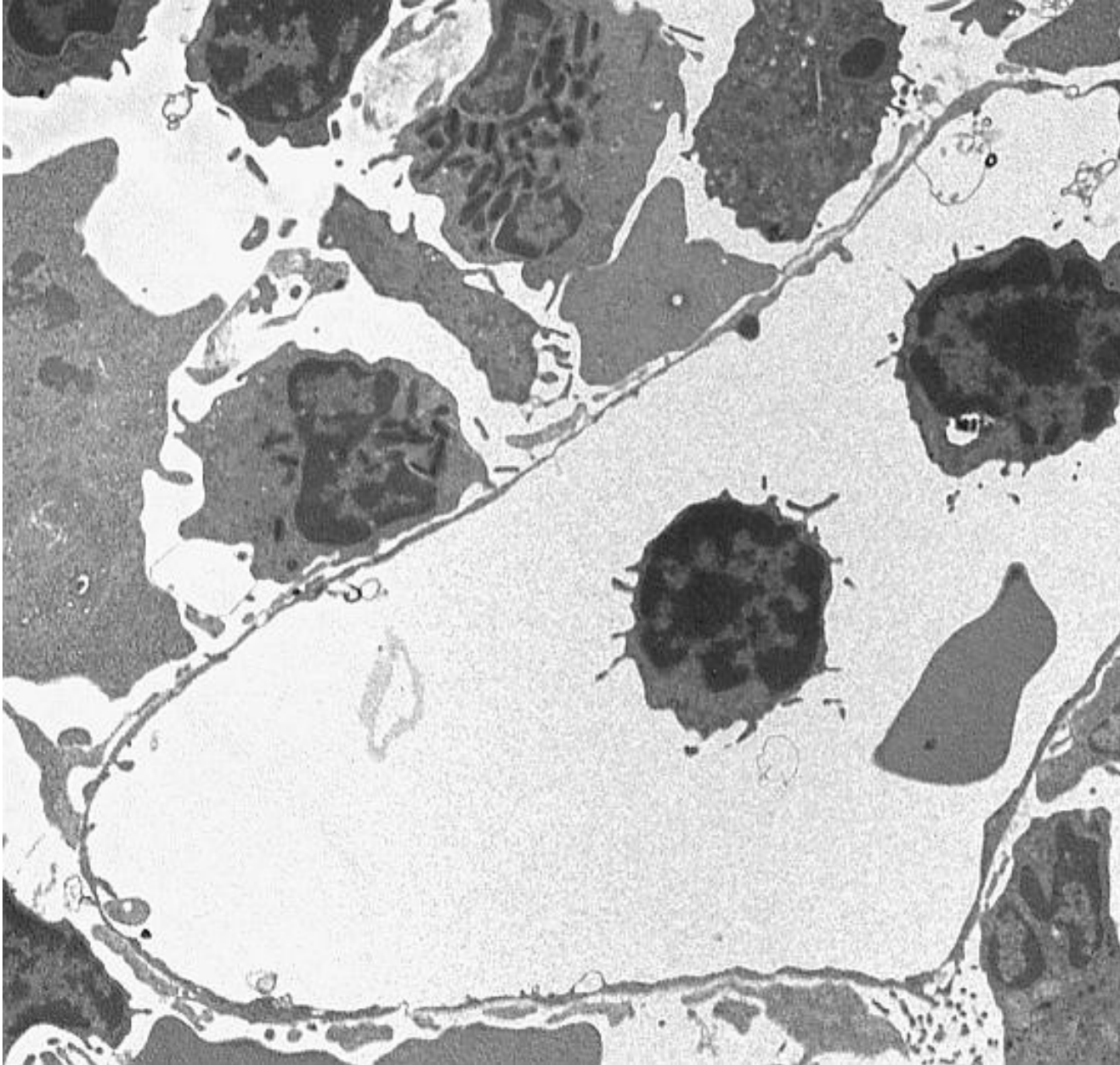
# Continuous capillary



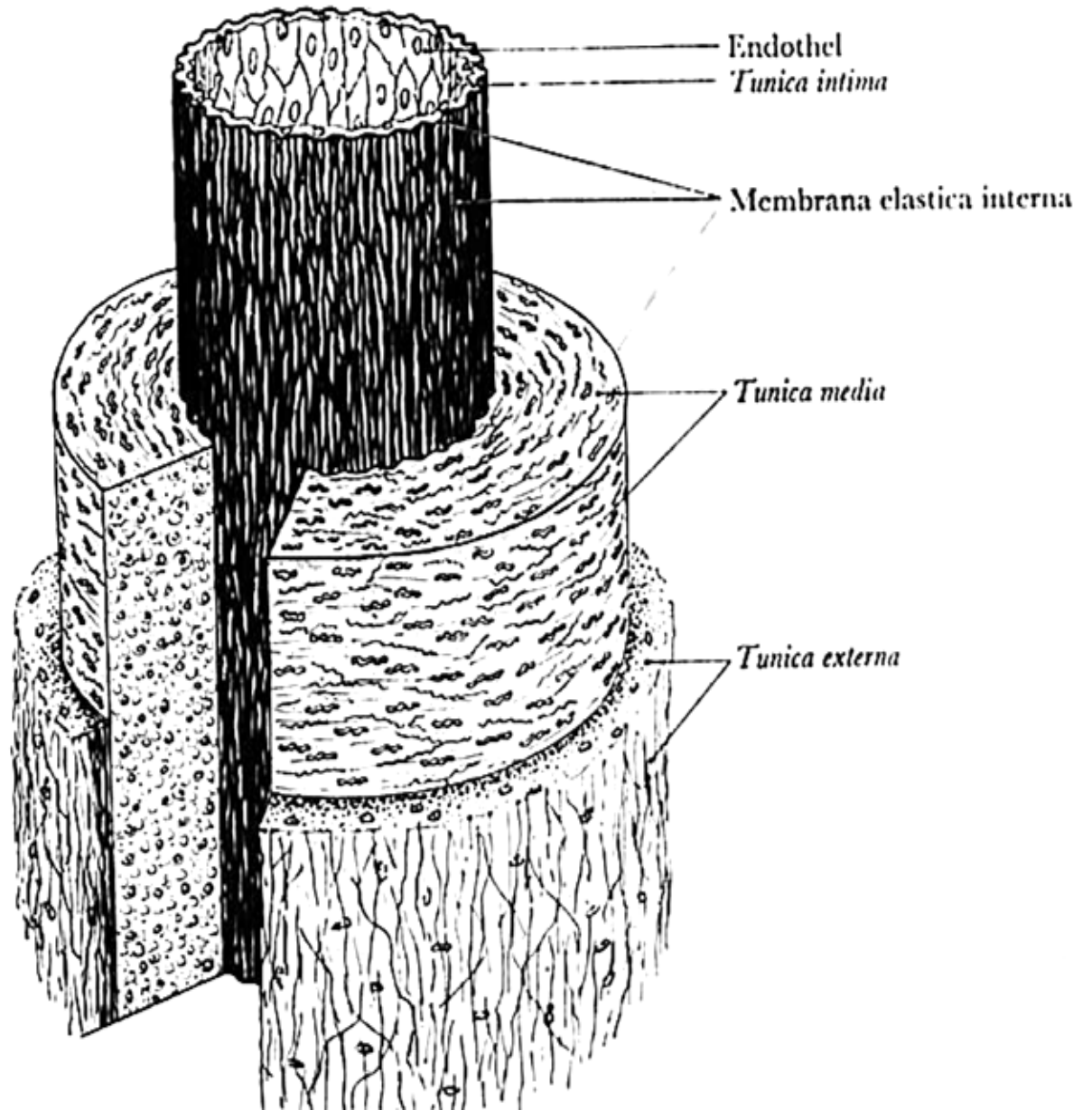
# Fenestrated capillary



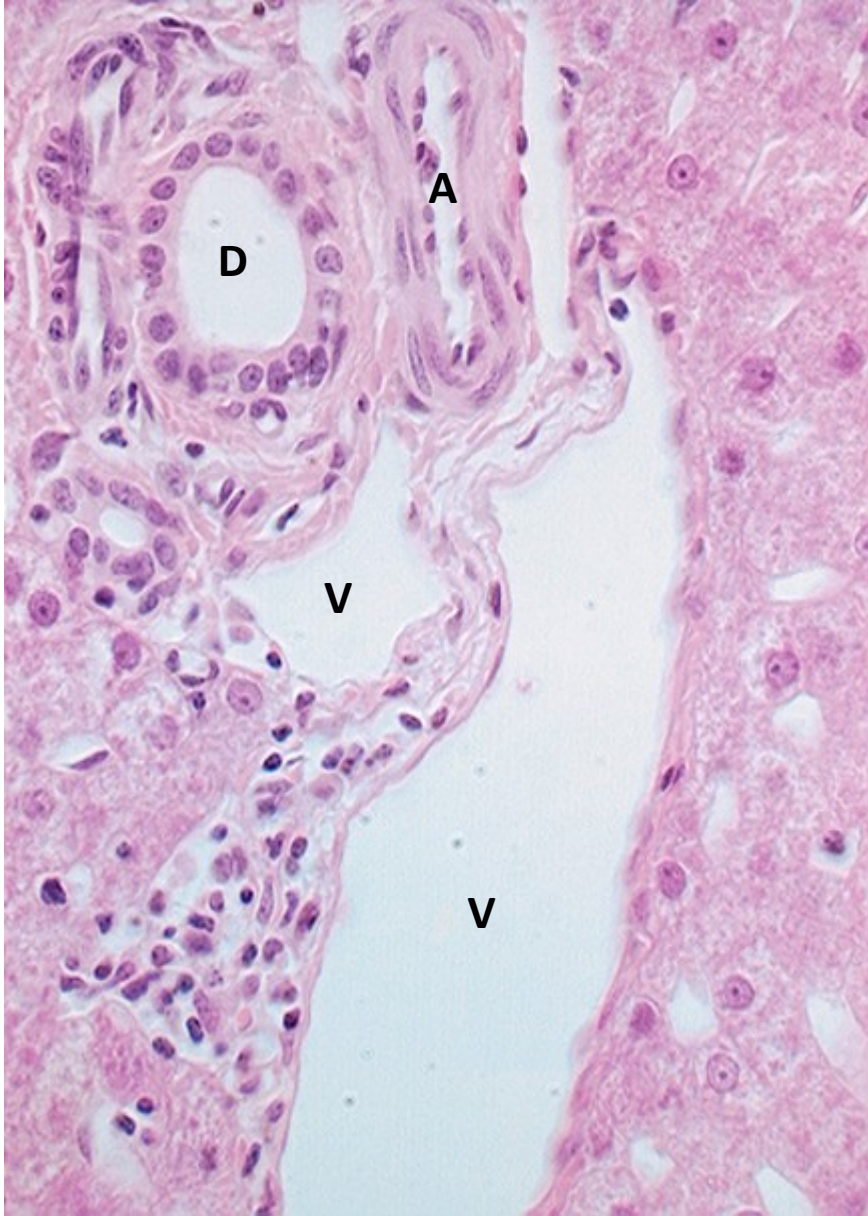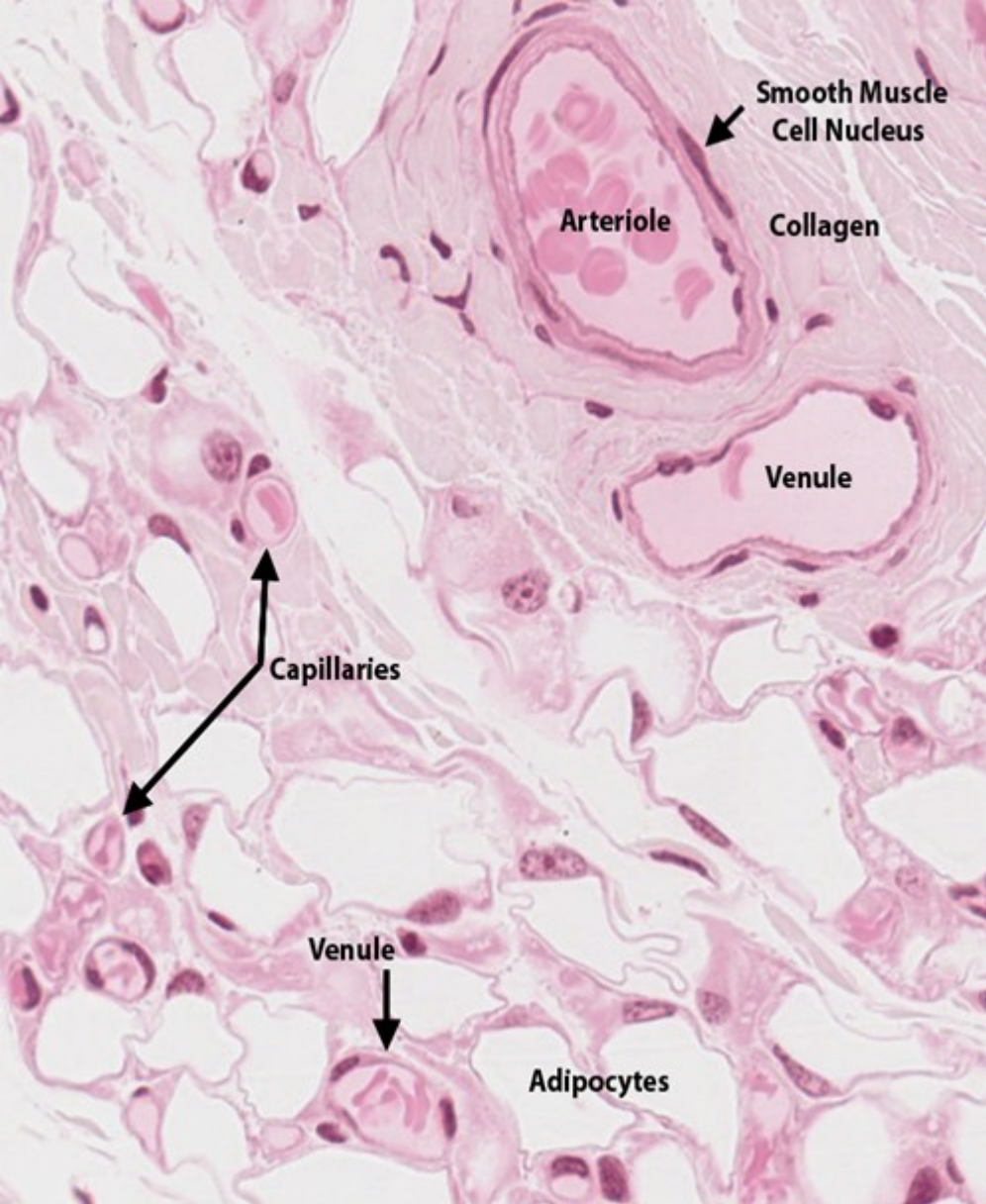
# Sinusoid



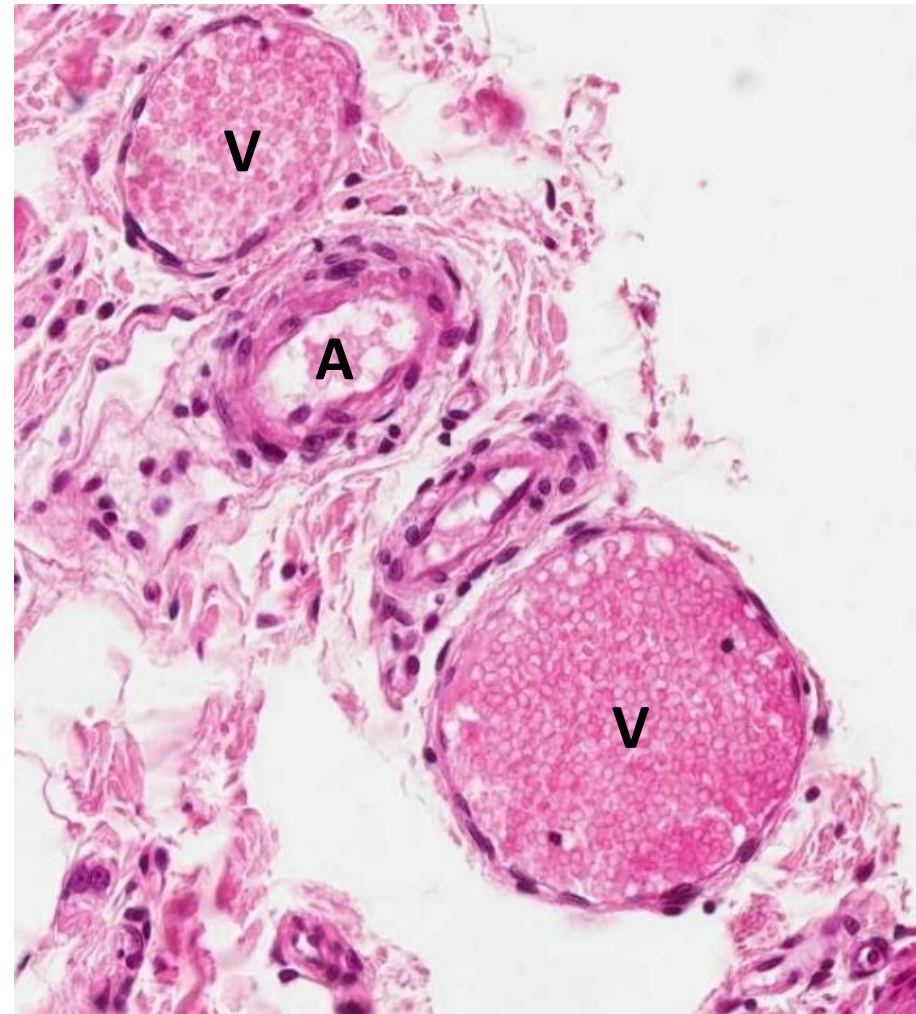
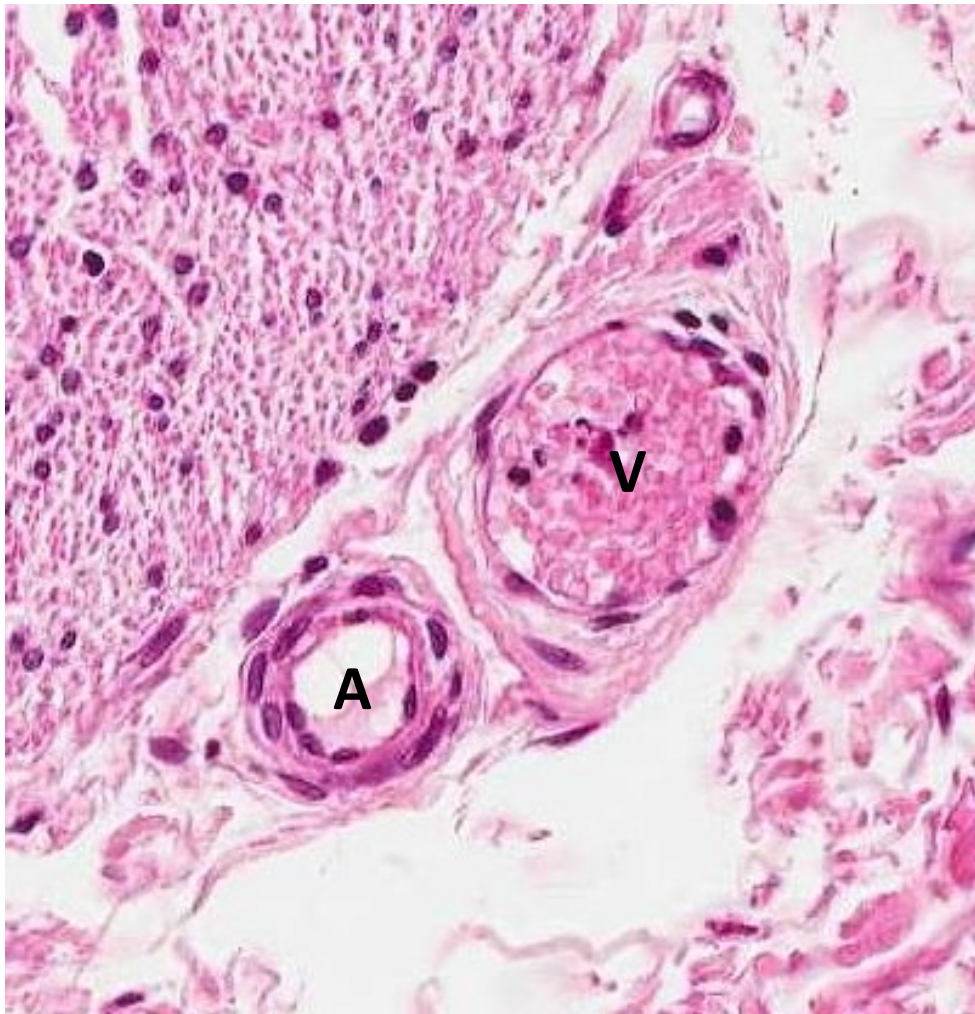
# General structure of blood vessels



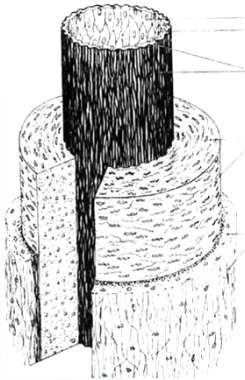
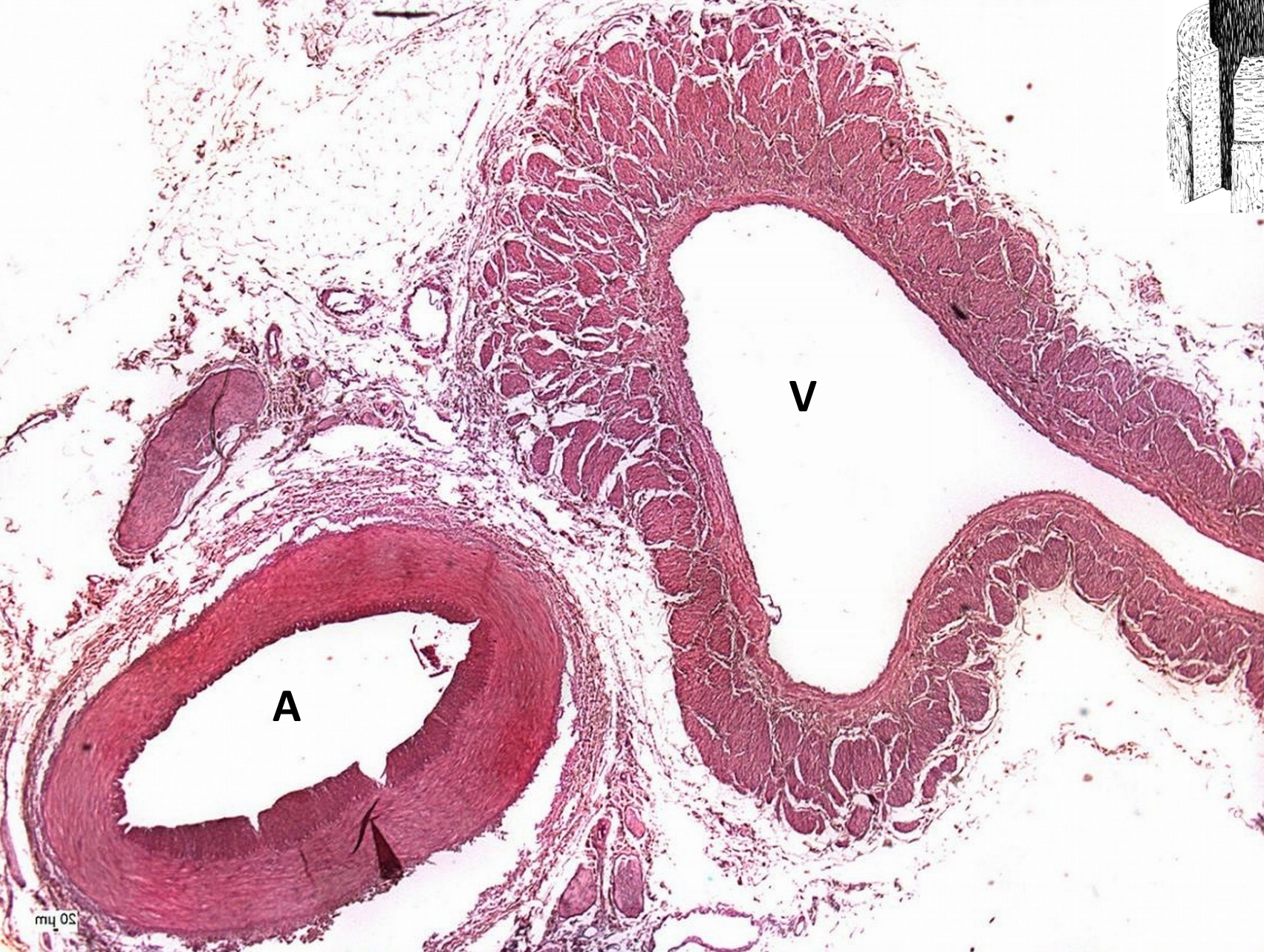capillaries, arterioles, venules [endothelium], ducts [epithelium]



# arteriole and venule

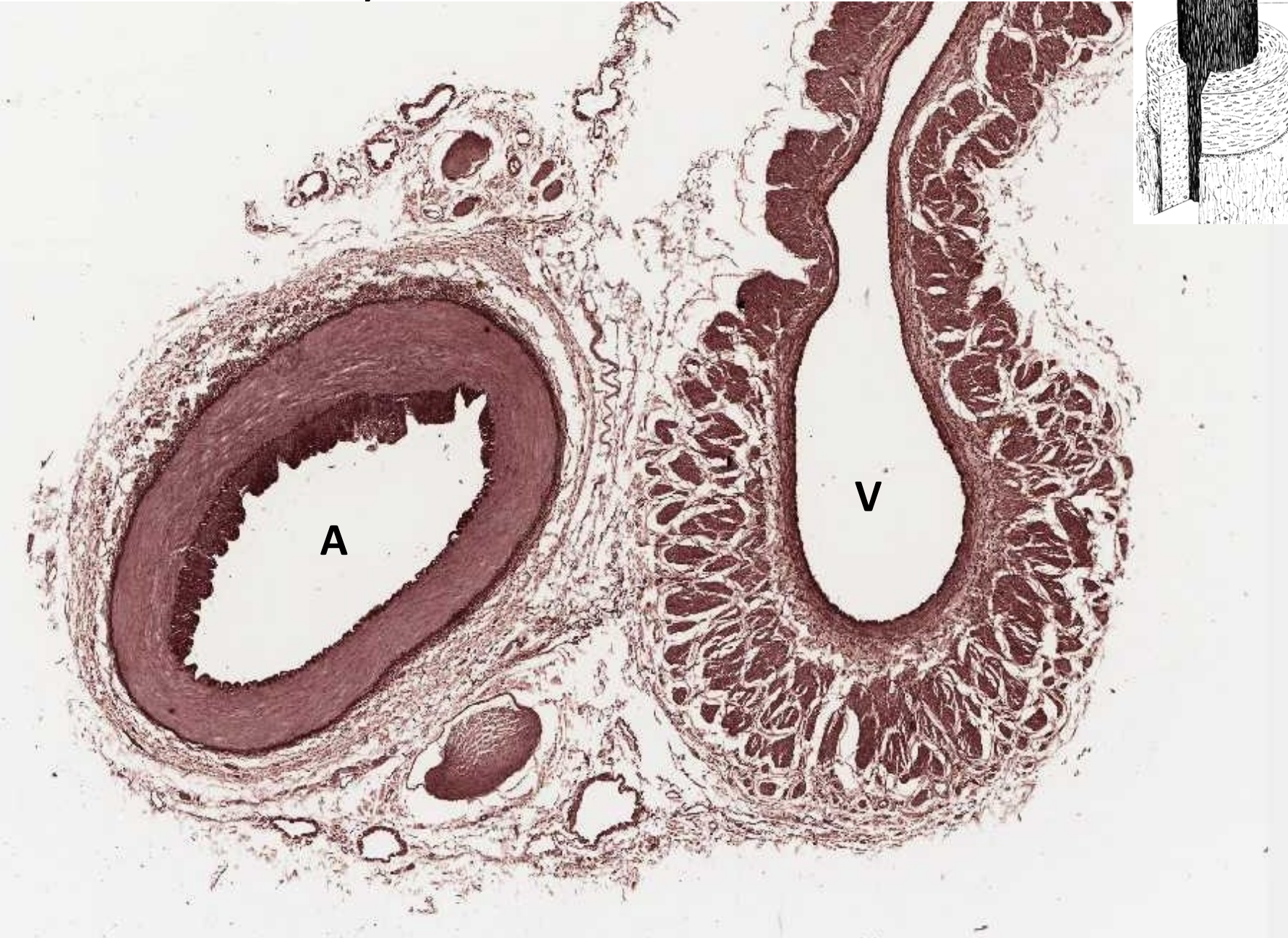


# muscular artery and vein - HE





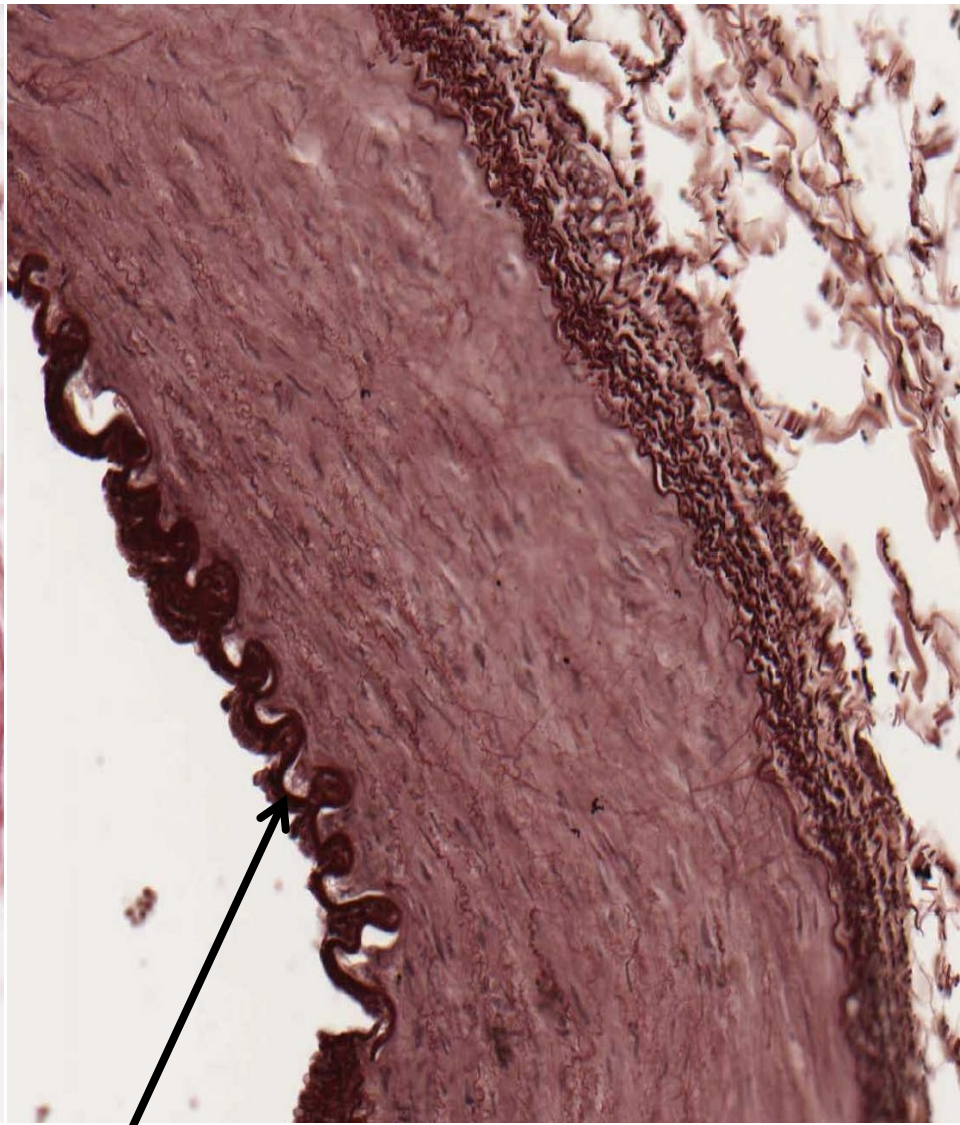
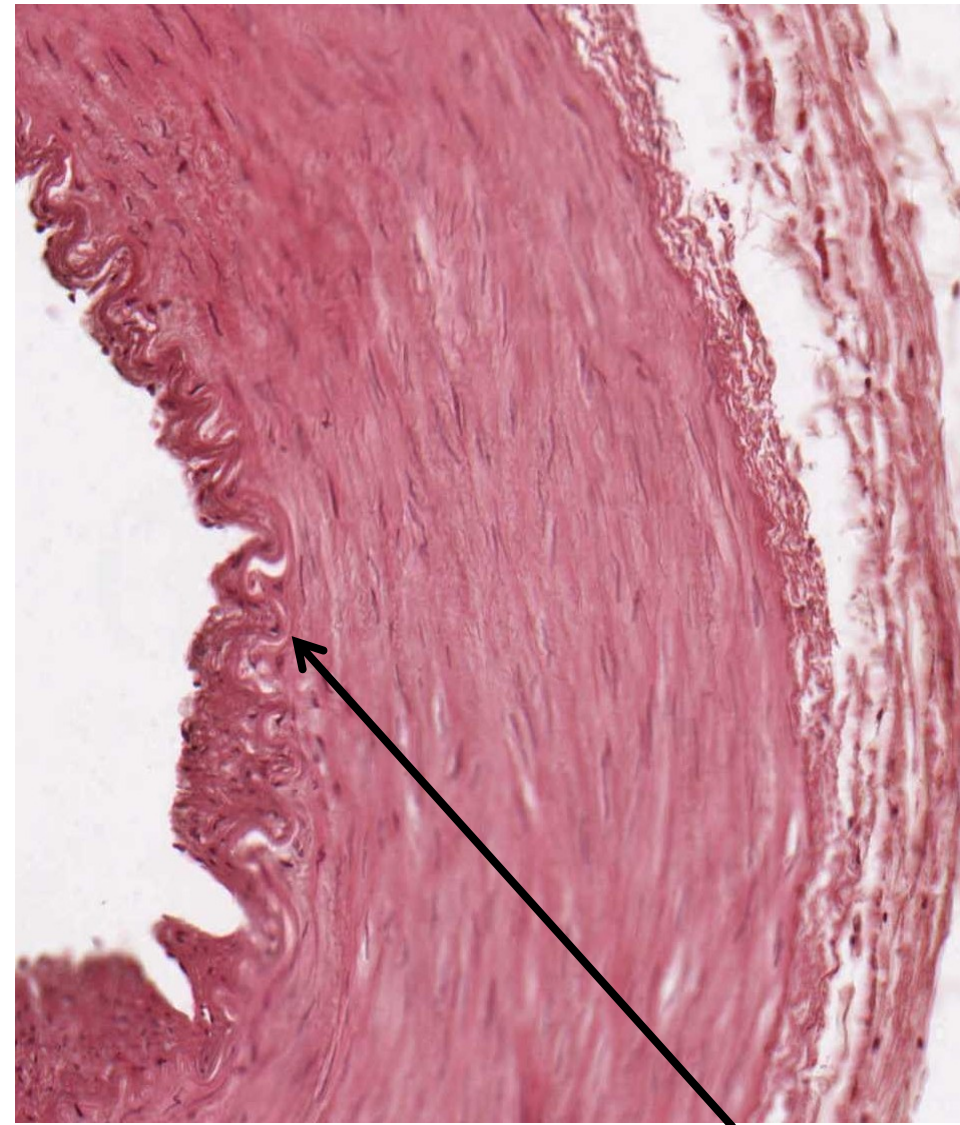muscular artery and vein - orcein



muscular artery

HE

orcein

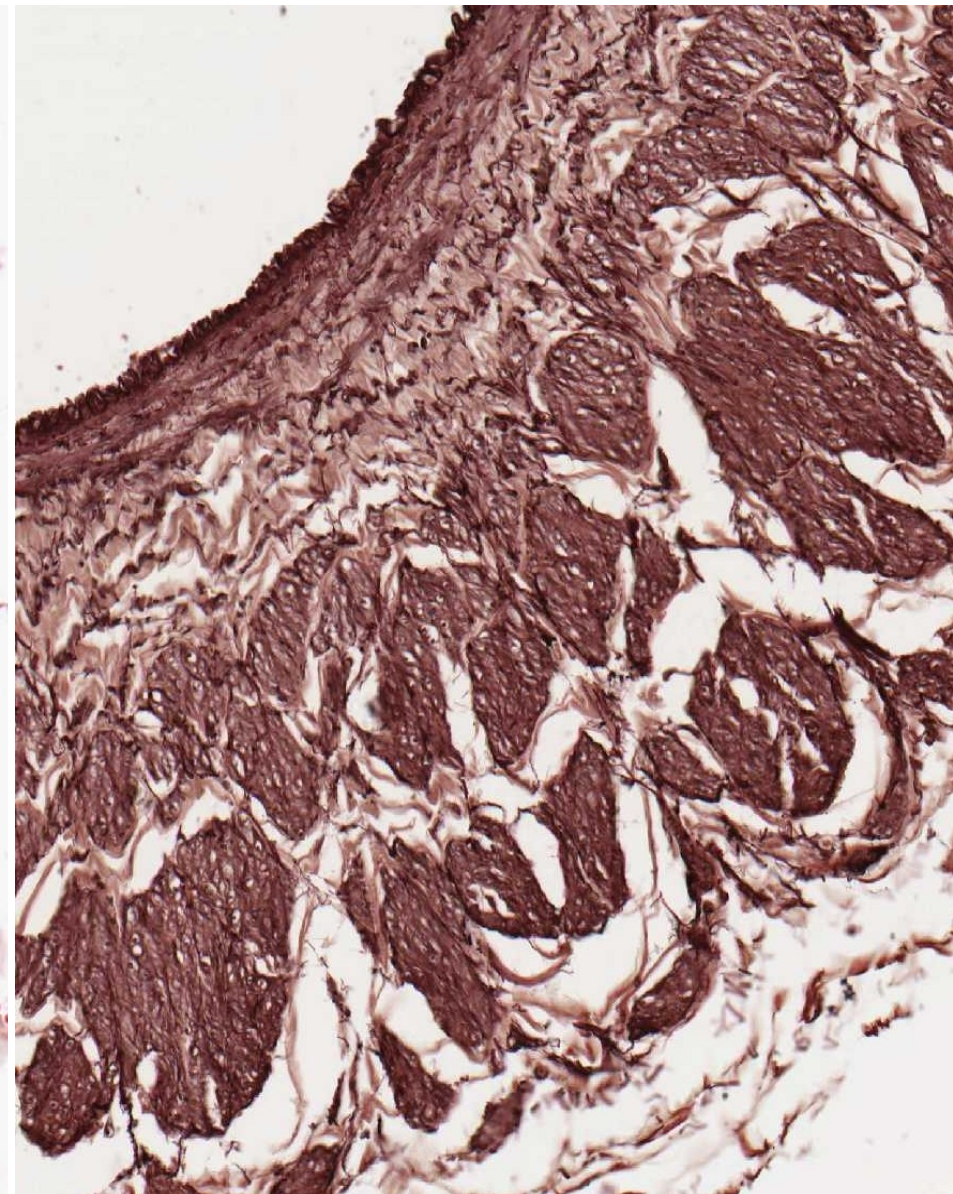
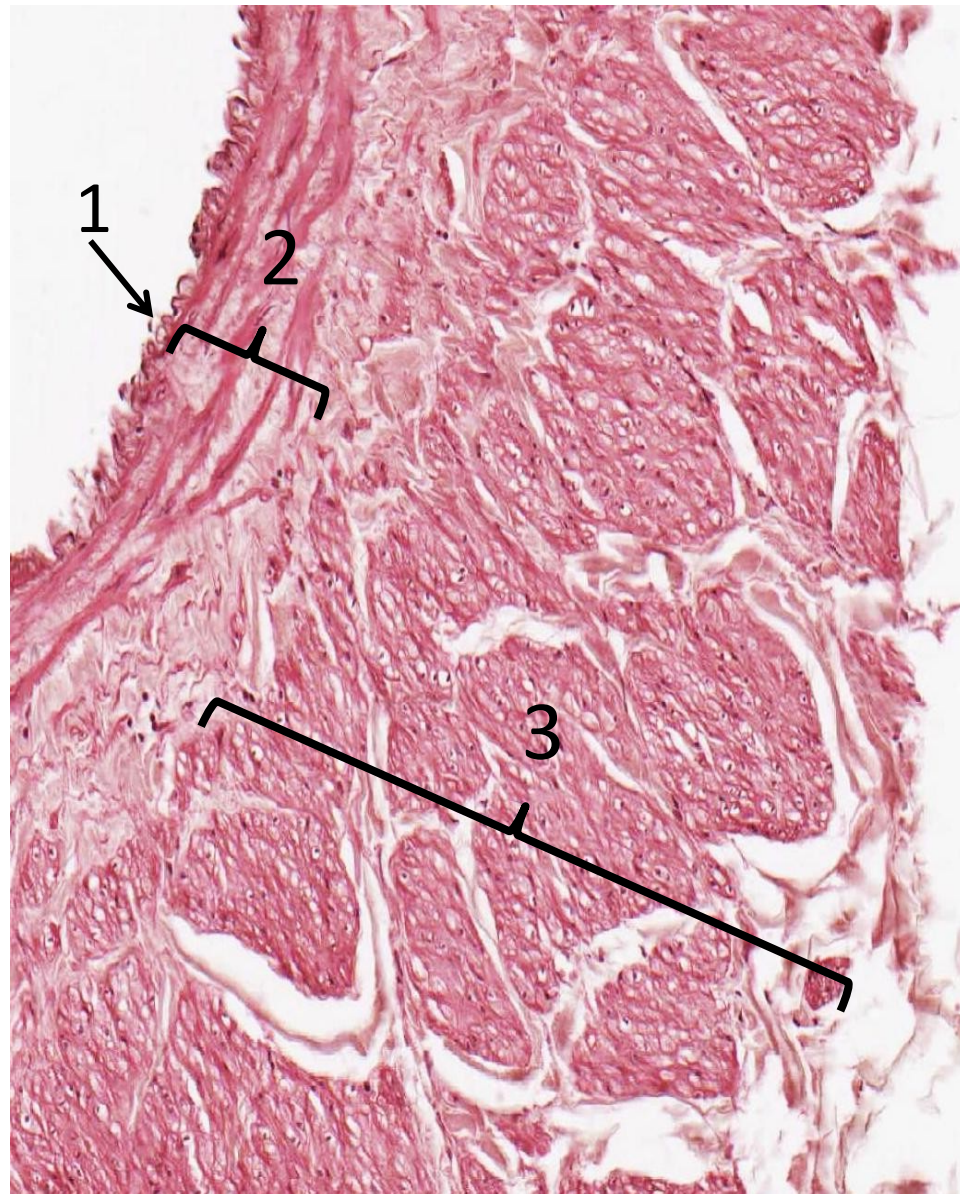


membrana elastica interna

vein (1-intima, 2-media, 3-adventitia)

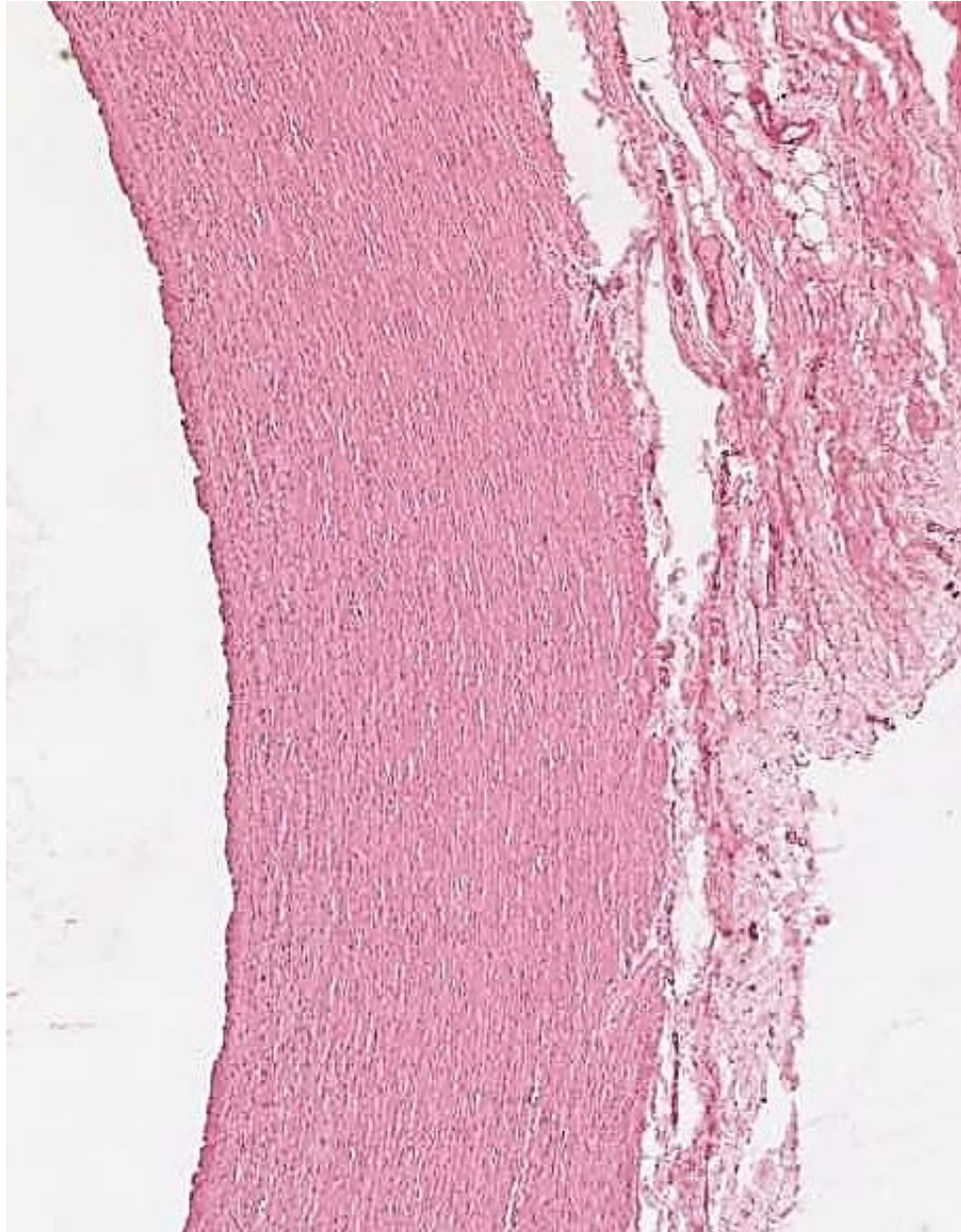
HE

orcein

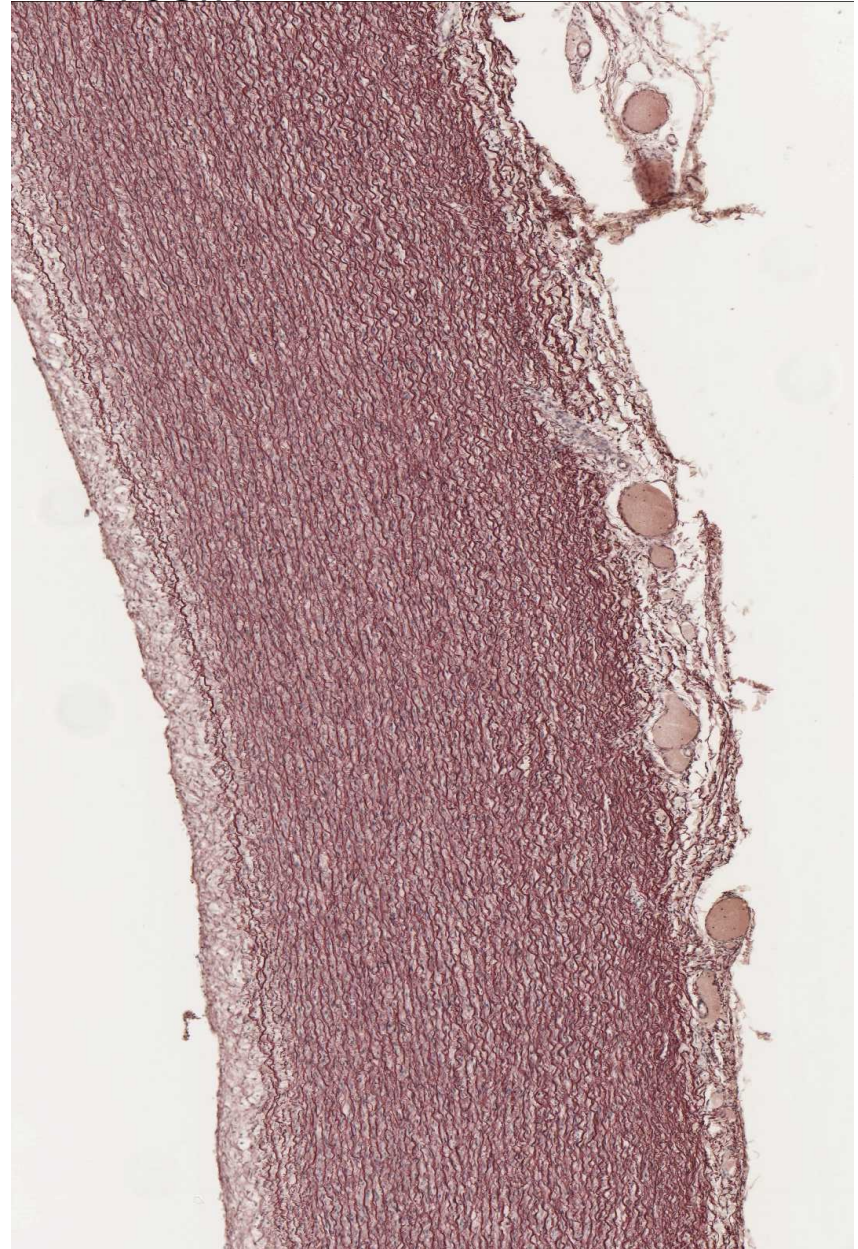


aorta

HE

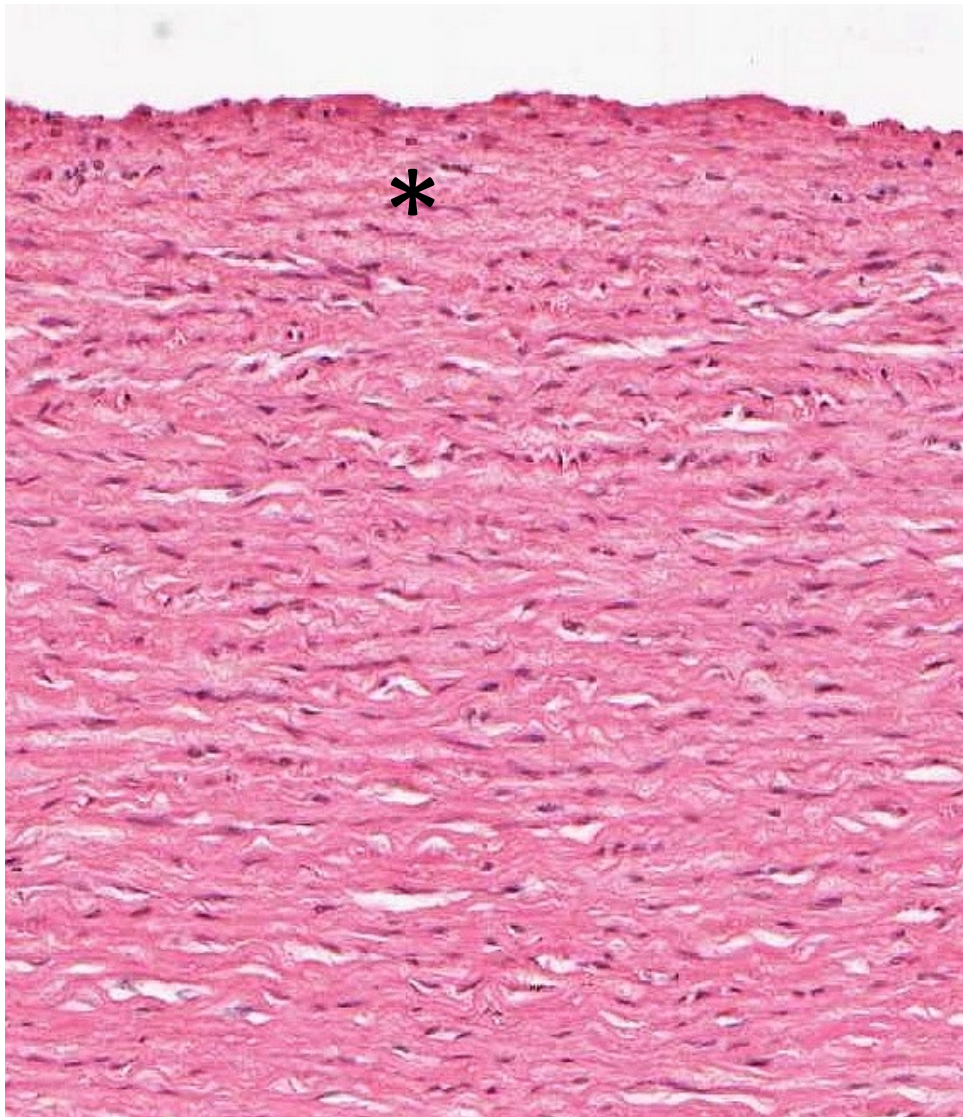


orcein

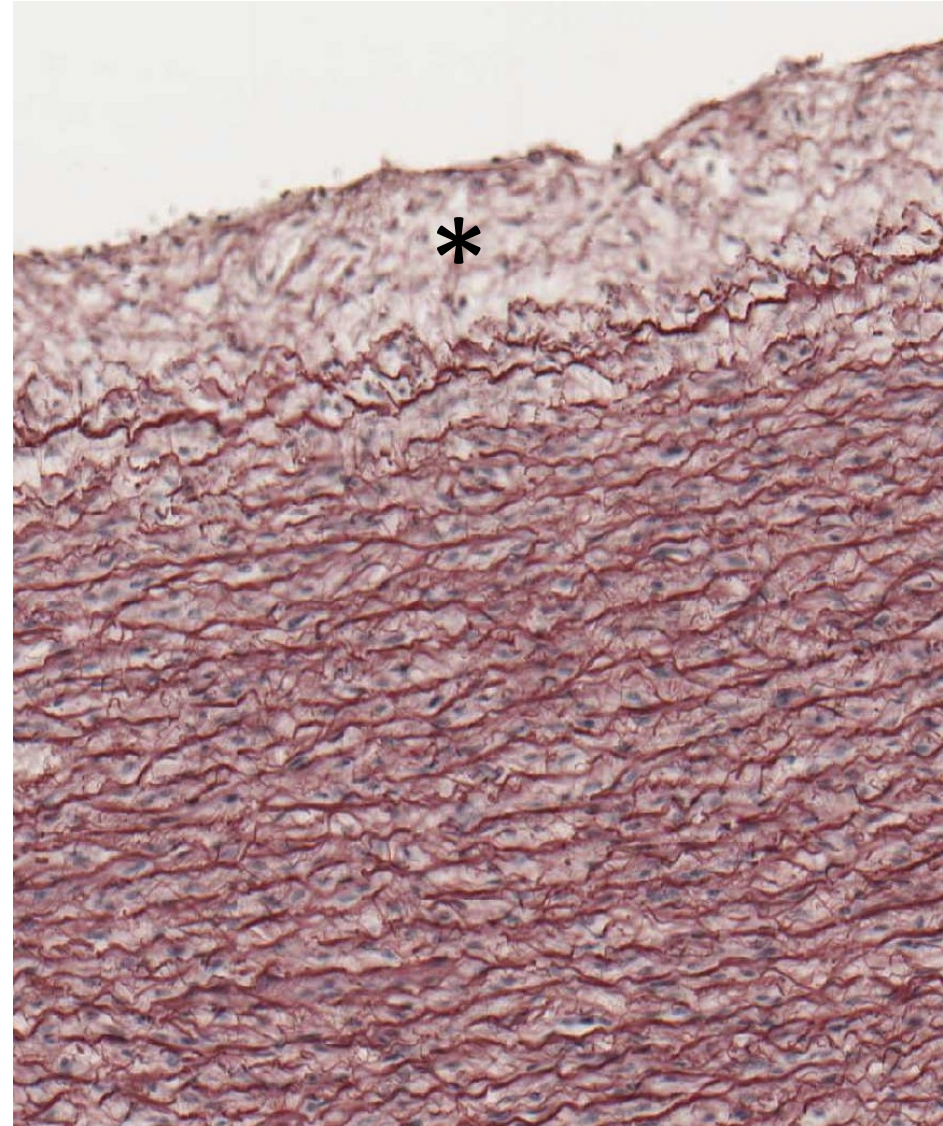


aorta – intima \*

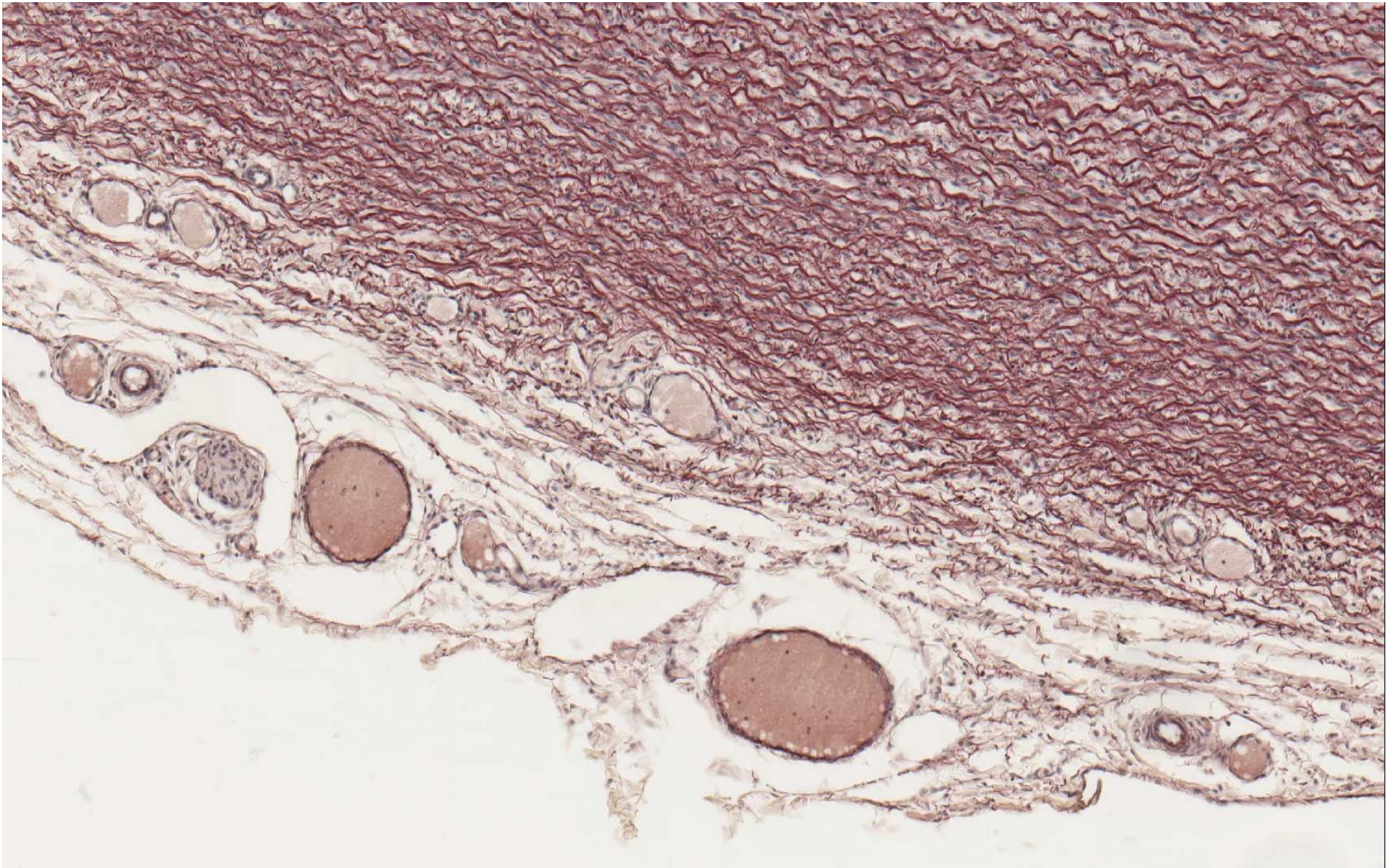
HE



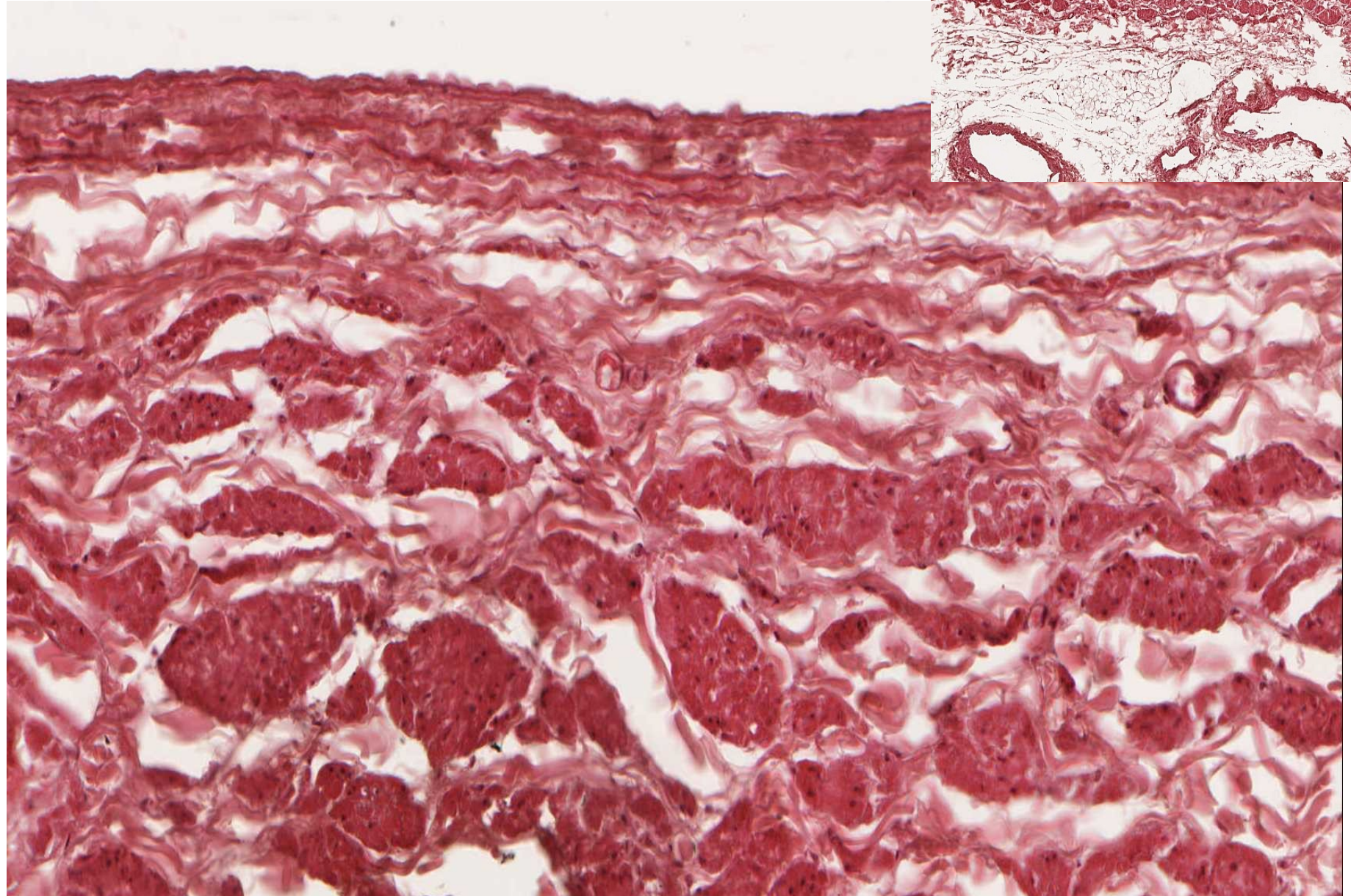
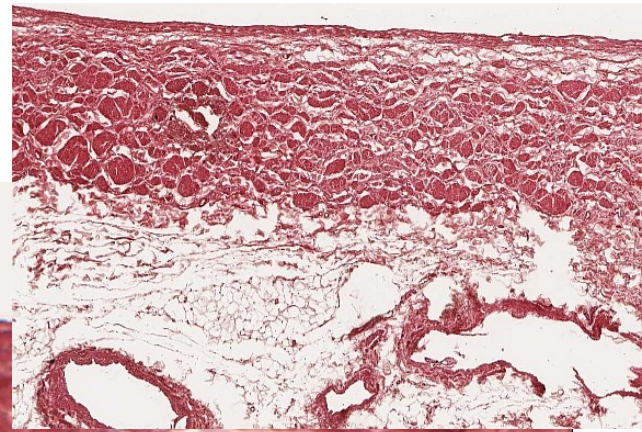
orcein



aorta (orcein) – adventitia, vasa vasorum, nervi vasorum

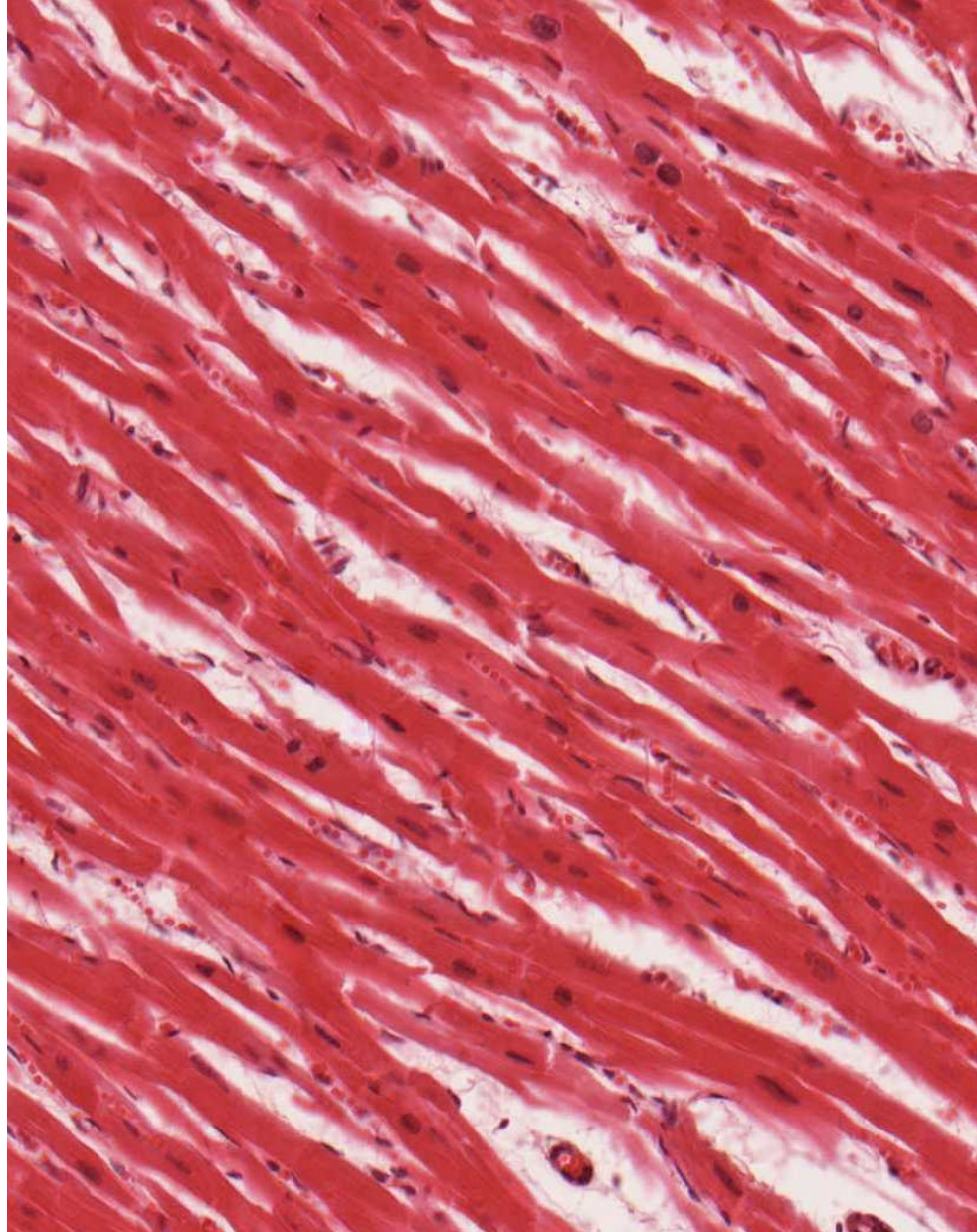


vena cava (HE)




myocardium

HE




Heidenhain

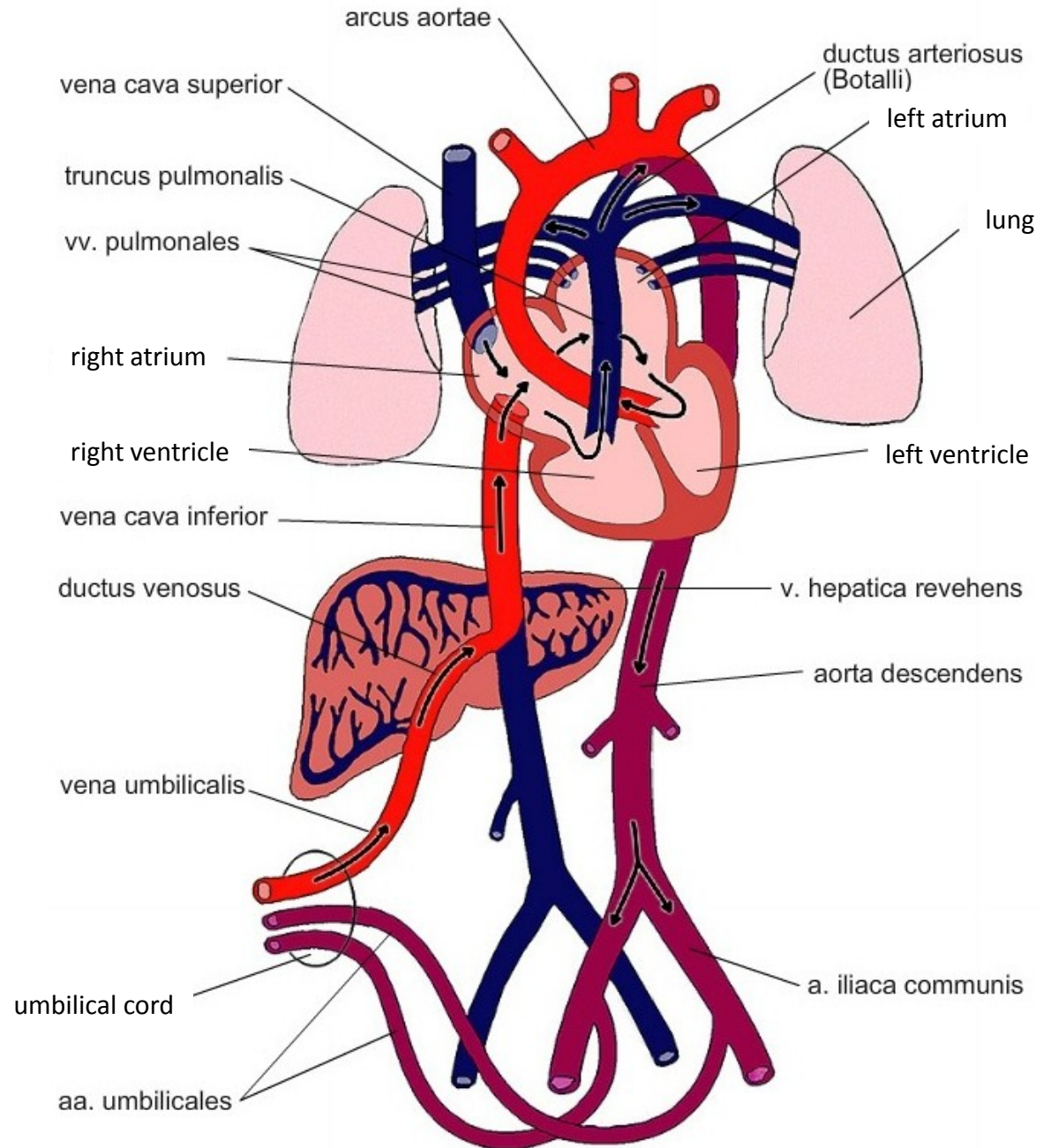




# cardiomyocyte (TEM)



# Fetal blood circulation





# CARDIOVASCULAR SYSTEM

## Slides

Muscular artery and vein (59 – HE, 60 - orcein)

Aorta (61 – HE, 62 - orcein)

Vena cava (63 - HE)

Myocardium (64 – HE, 65 - Heidenhain)

## Atlas EM:

Arteriole (59)

Continuous capillary (55)

Fenestrated capillary (56, 57)

Sinusoid capillary (58)

Cardiomyocyte (44-46)

Development of heart, embryonic and fetal blood circulation (91-93)