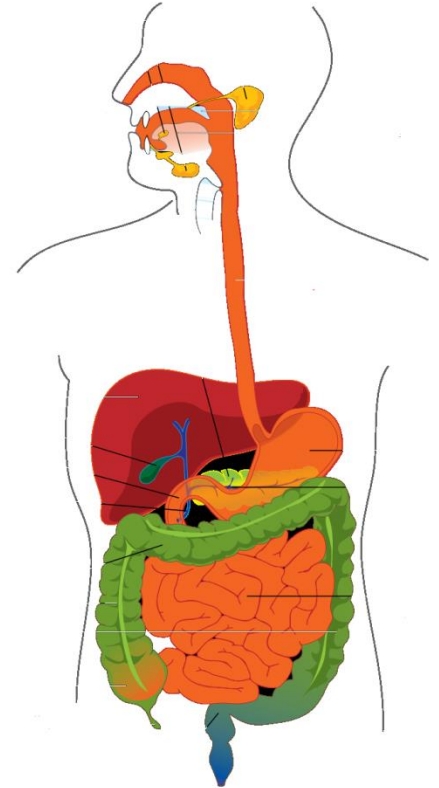


# Digestive system

**Microscopic anatomy of pancreas, liver,  
overview of GIT embryology**

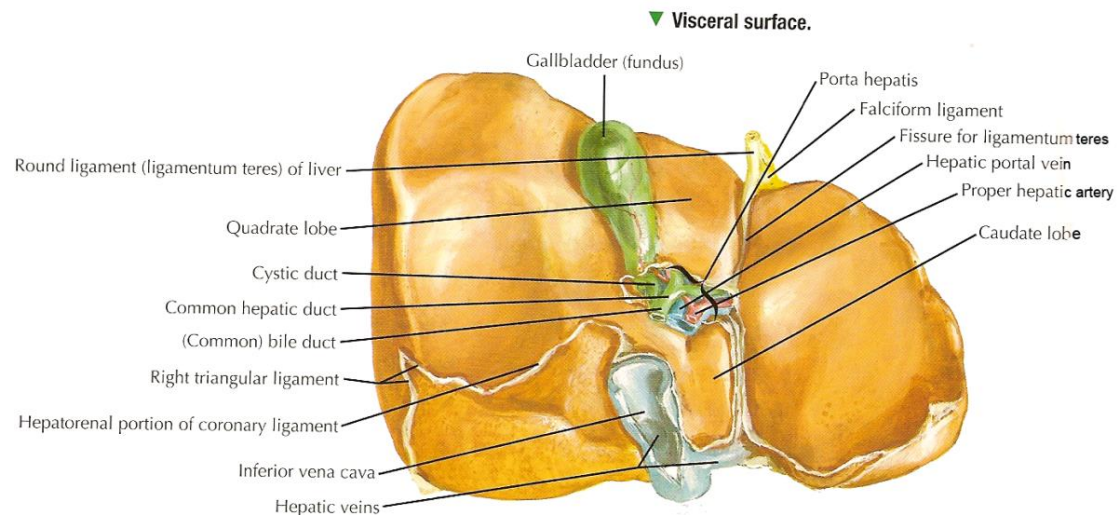
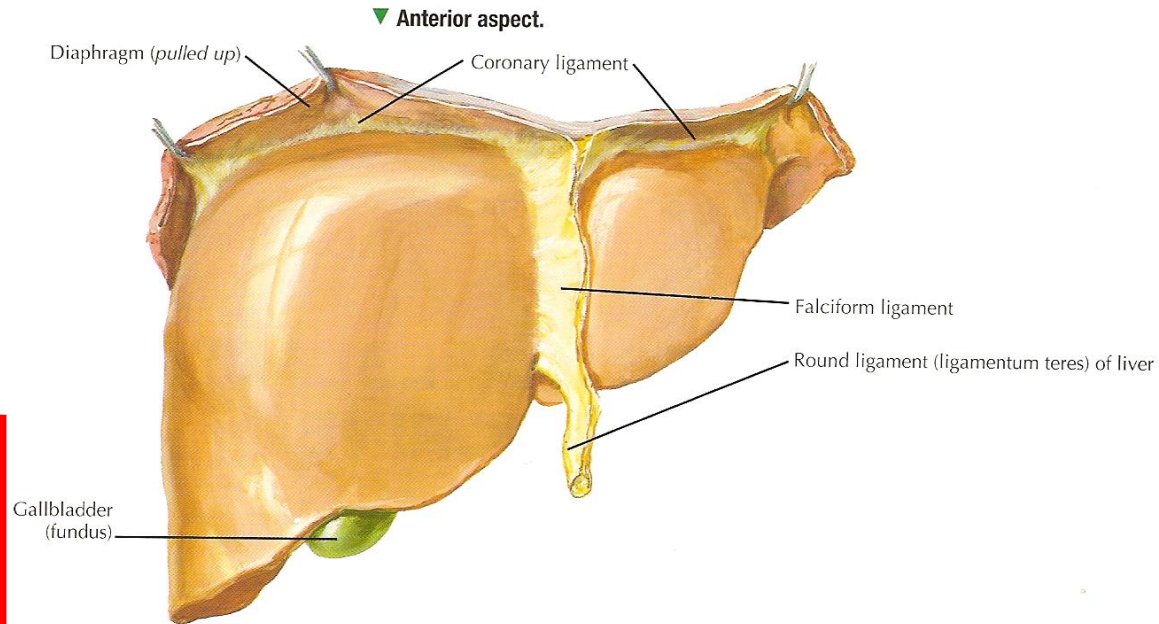


# LIVER (HEPAR)

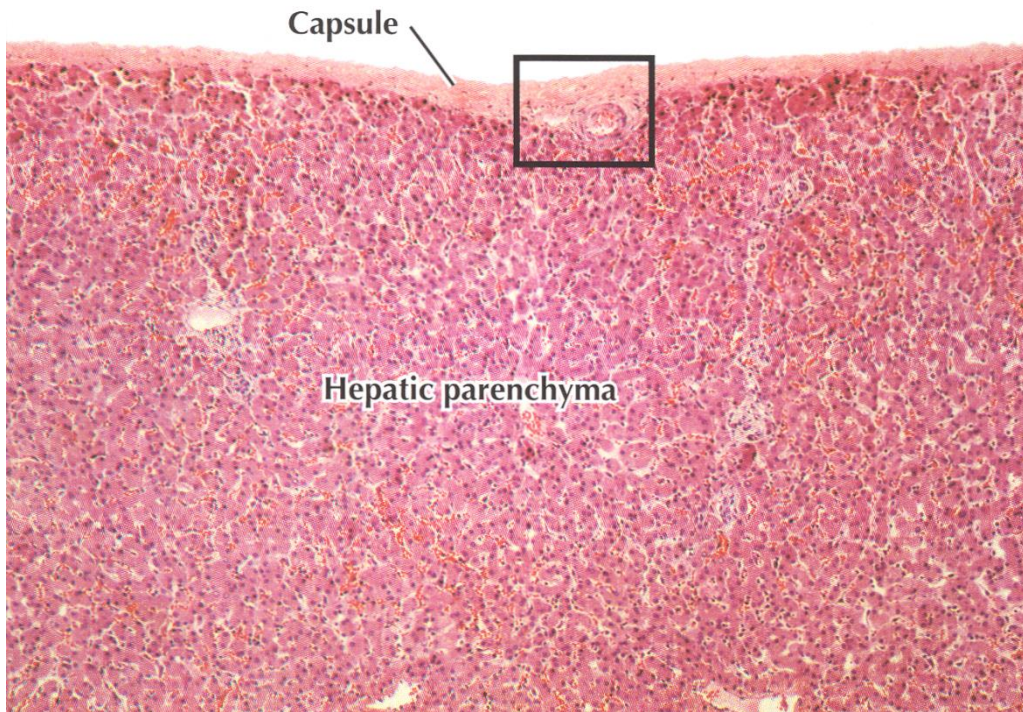
- Liver parenchyma – biggest gland in human body
- C.t. capsule
- Nutritive and functional blood supply
- Endocrine and exocrine function
- Uniform histology of all four major anatomic lobules and segments:

- Hepatocytes and other cell types
- C.t. stroma
- Blood and lymphatic vessels
- Sinusoids
- Innervation

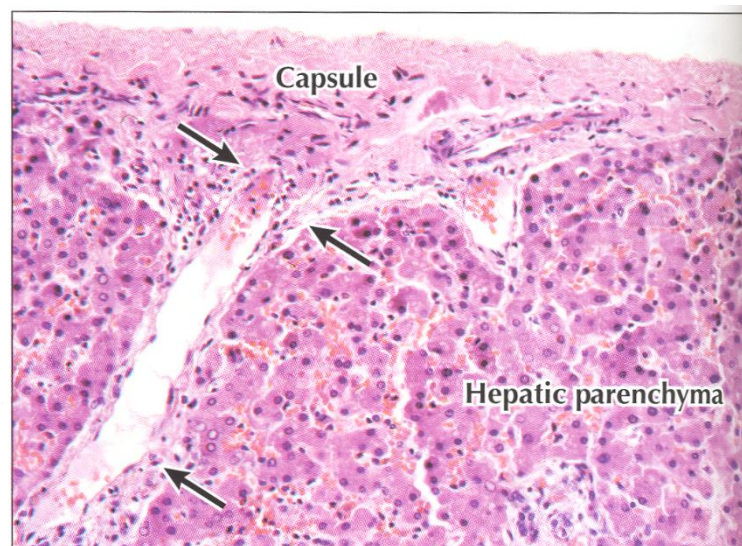
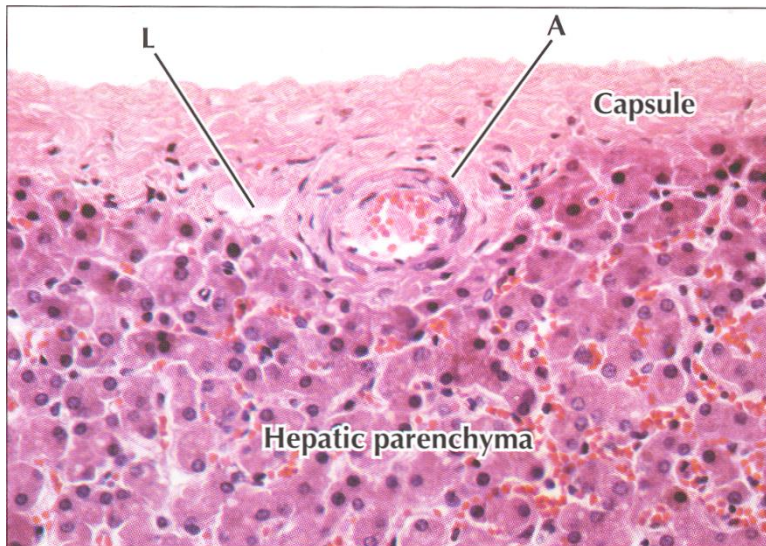
- C.t. capsule
- Serosa



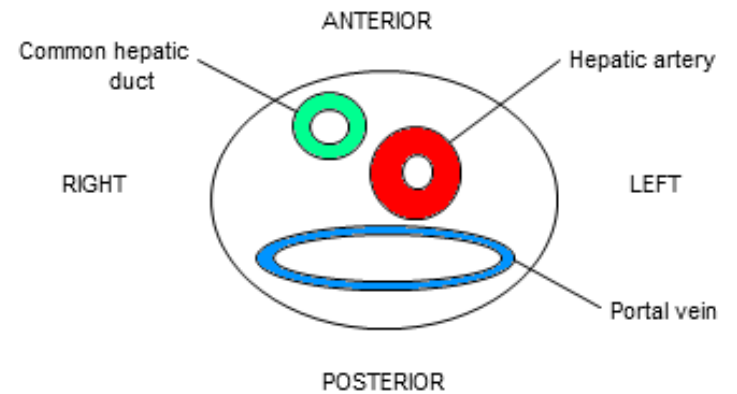

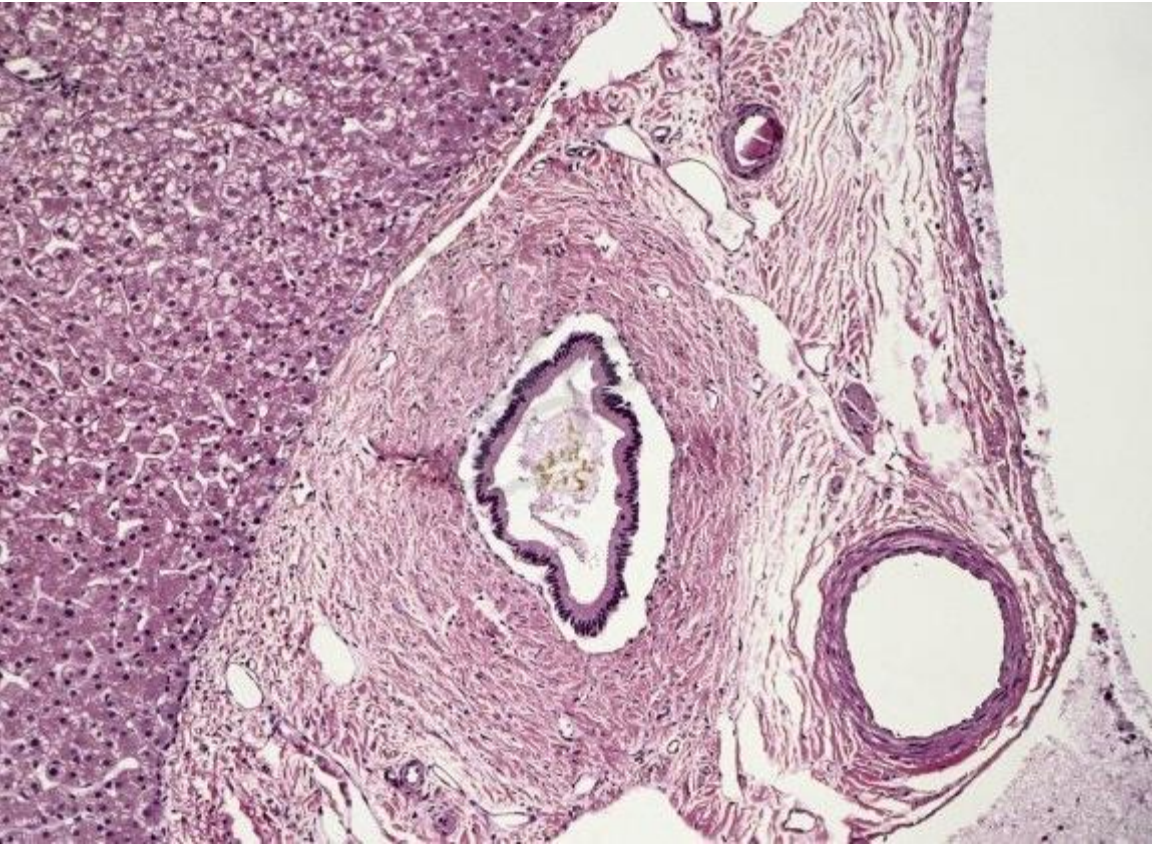
# CAPSULA FIBROSA HEPATIS



- Serous mesothelium
- C.t. – collagen and elastic fibers
- 70-100 $\mu$ m
- Porta hepatis



# CAPSULA FIBROSA HEPATIS




# VASCULARISATION

## FUNCTION

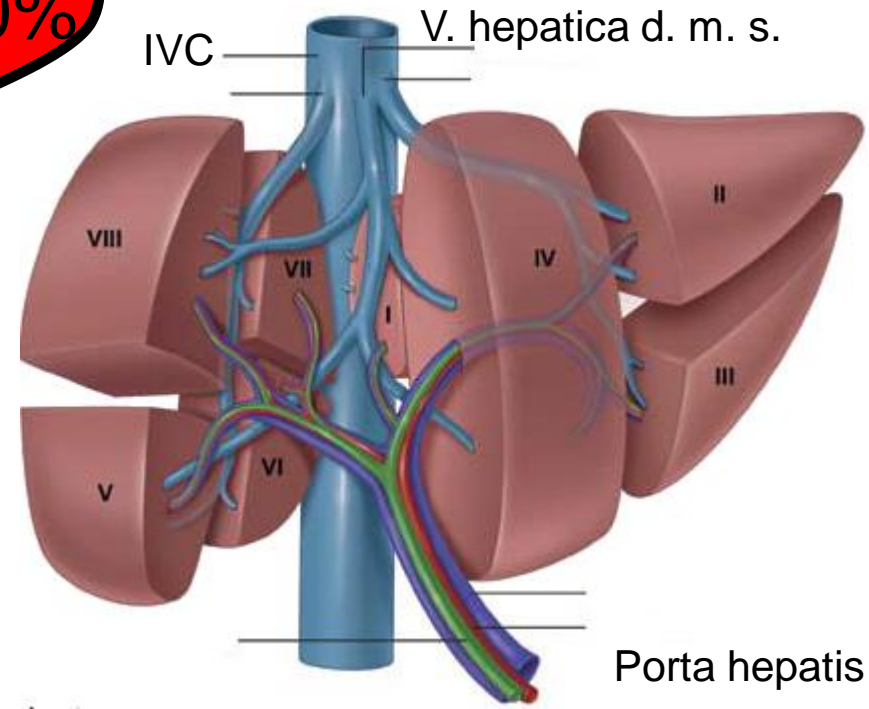
- capillary stream of stomach and intestine
- vena portae
- interlobular veins
- circumlobular venules

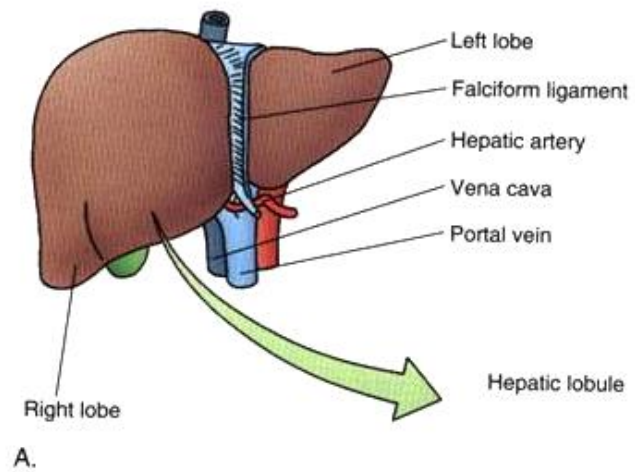
## NUTRITIVE

- aorta
- arteria hepatica
- segmental arteries
- interlobular arteries
- circumlobular arteriols



- **hepatic sinusoids**
- venae centrales hepatis
- venae sublobulares
- venae hepaticae
- vena cava inferior

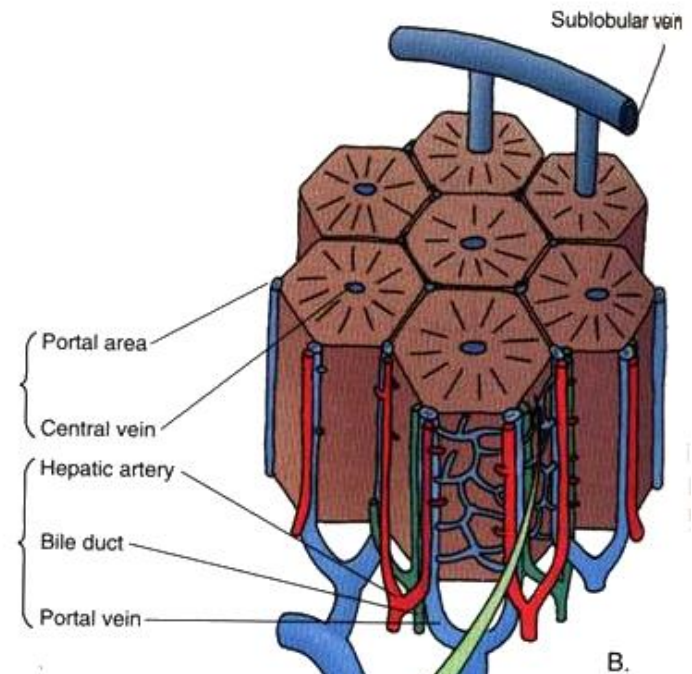




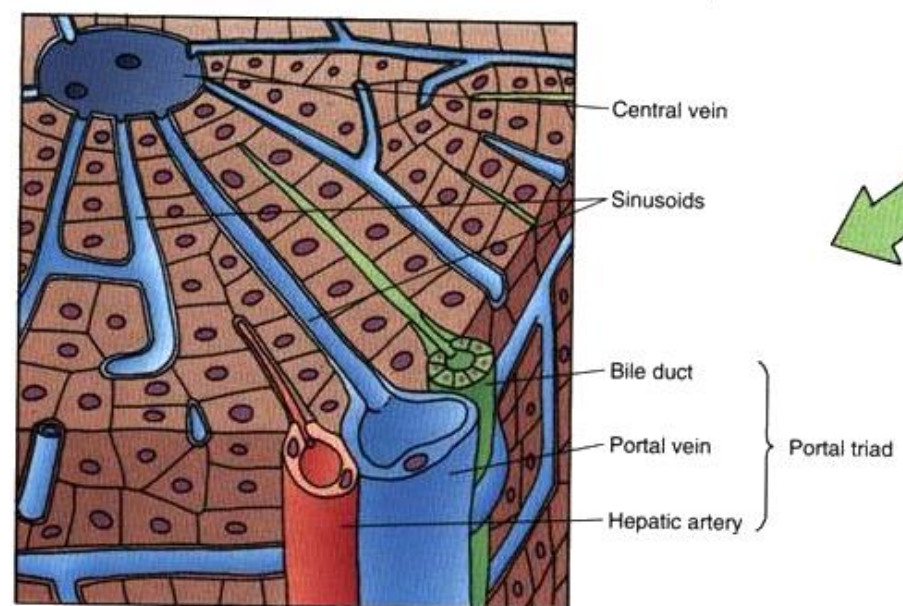
A.

Hepatic lobule

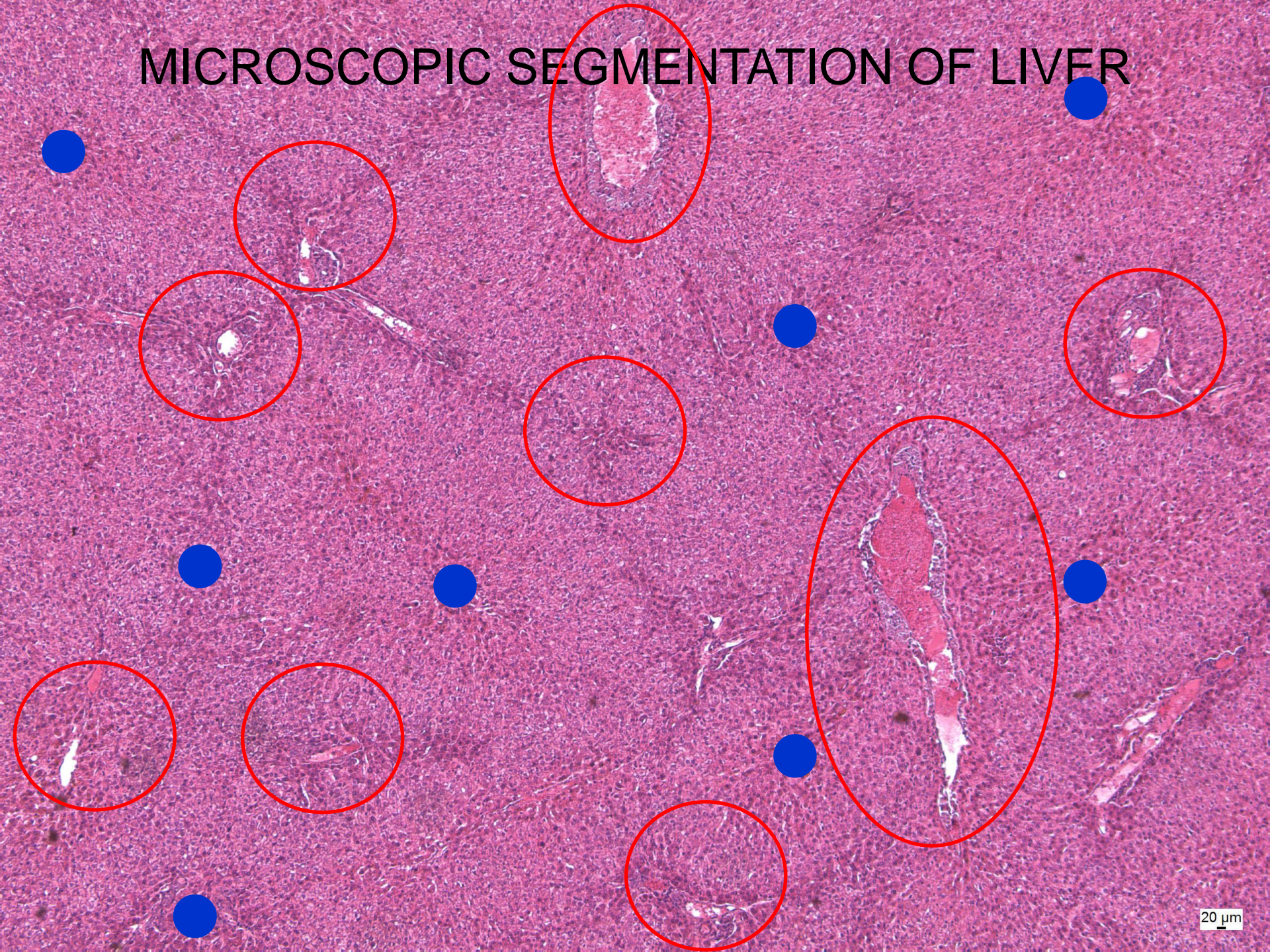
Portal triad



B.

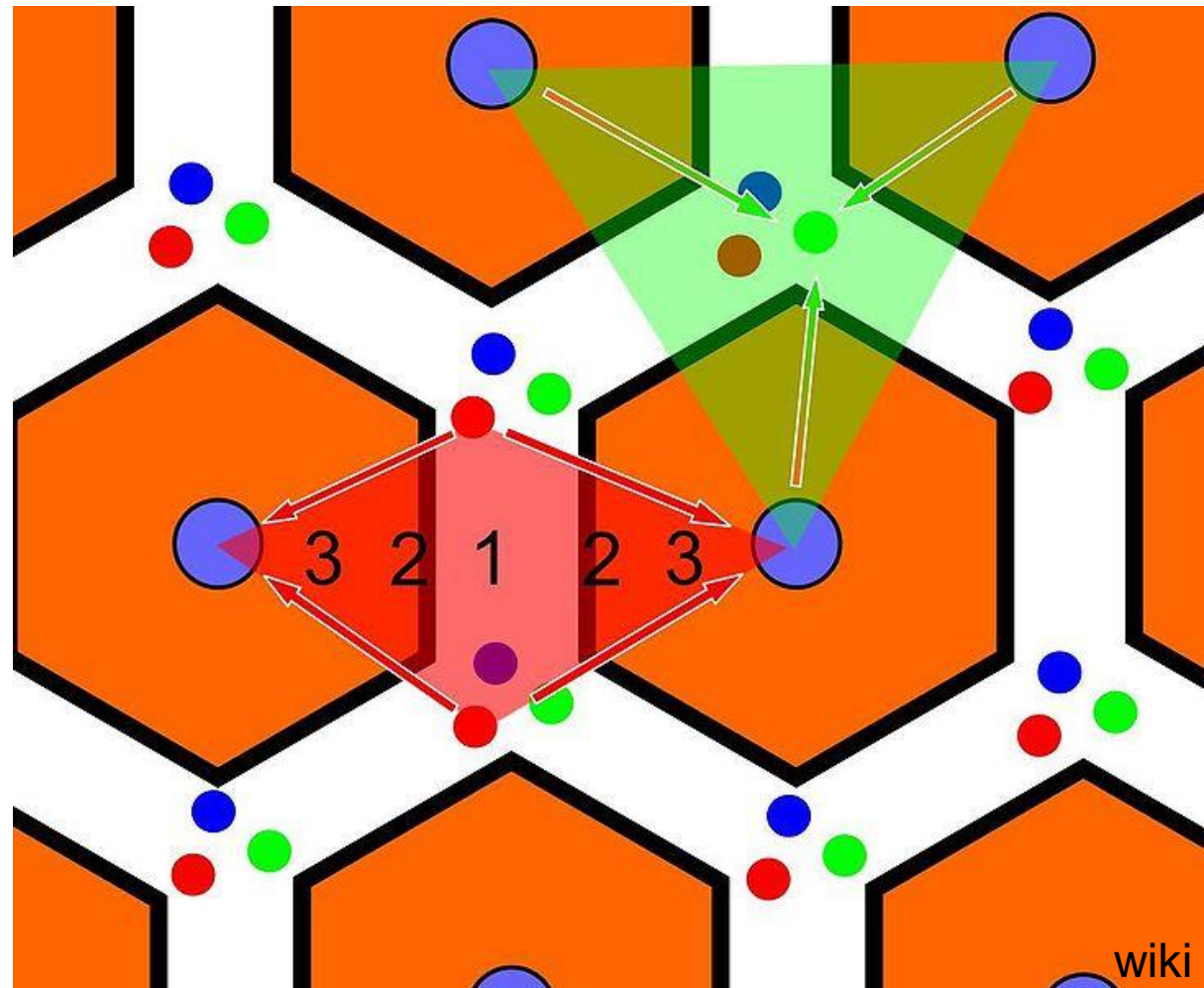
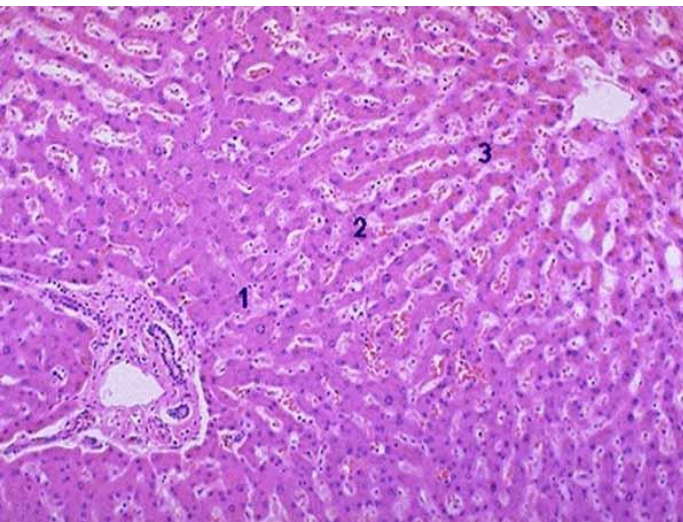


# MICROSCOPIC SEGMENTATION OF LIVER

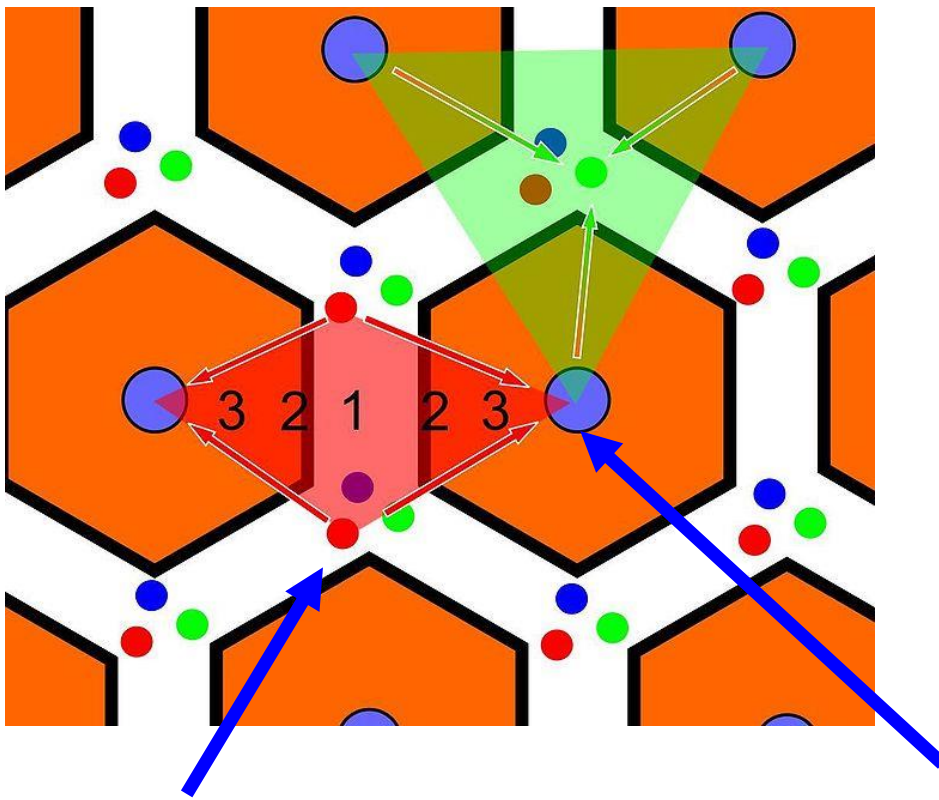


# MICROSCOPIC SEGMENTATION OF LIVER

- Three possible definitions
- Histological – **lobulus venae centralis**
- Metabolic – **liver acinus**
  - metabolic zone 1 – 3
  - oxygenation of hepatocytes
- Functional (physiological historical) unit
  - **lobulus venae interlobularis** (portal acinus)







# Liver acinus

metabolic divergence dependent on arterio-venous gradients

## Zone I (periportal)

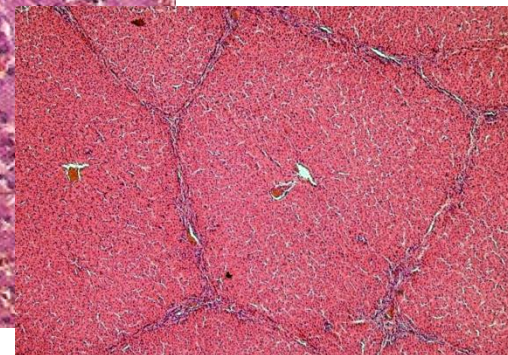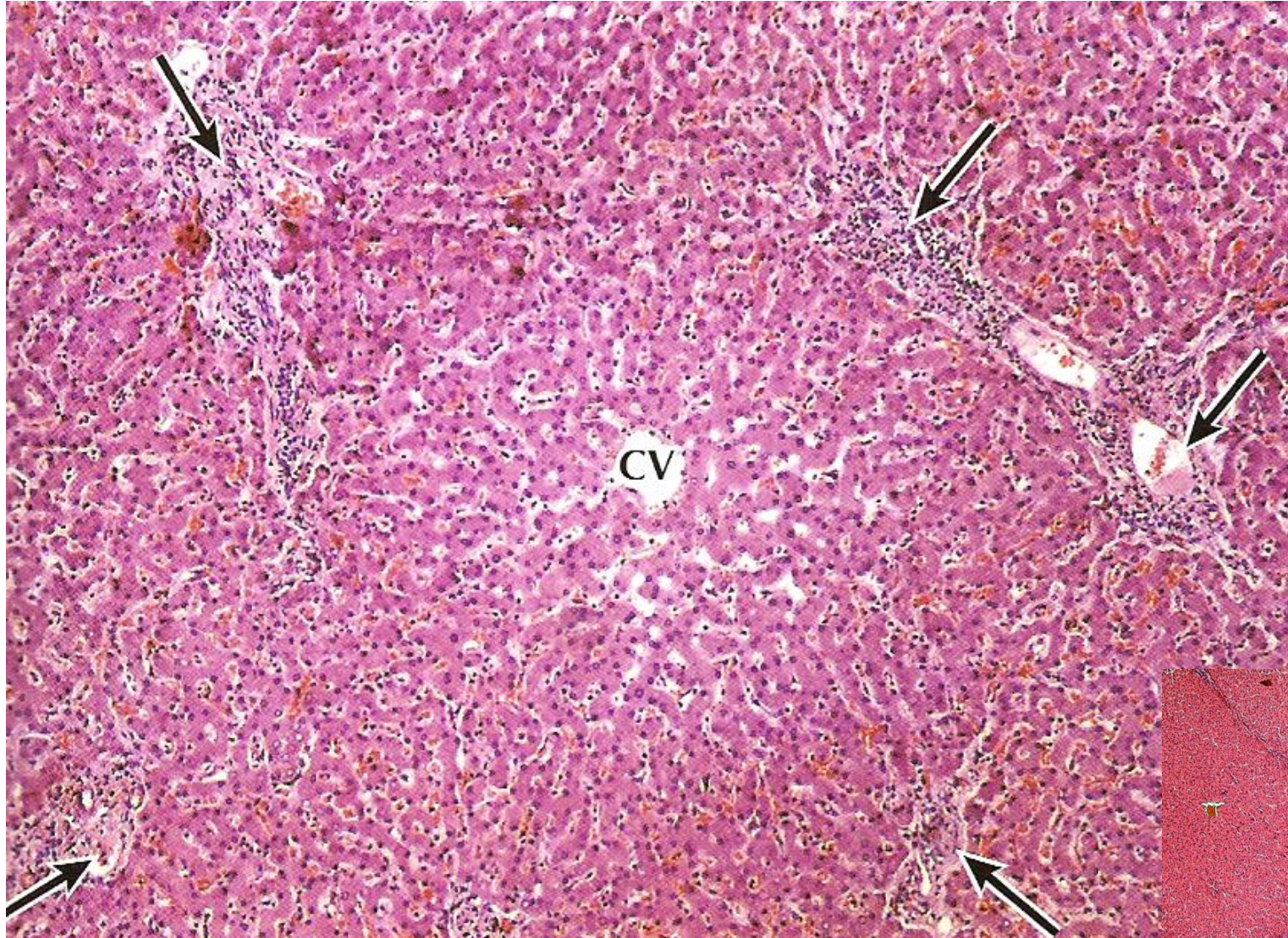
oxidative processes  
 beta-oxidation of fatty acids  
 catabolism of aminoacids  
 gluconeogenesis  
 production of urea  
 synthesis of cholesterol  
 glycogenolysis  
 production of bile

## Zone III (perivenous)

glycogen synthesis  
 glycolysis  
 lipogenesis  
 ketogenesis  
 production of glutamine  
 synthesis of bile acids  
 biotransformation

# CENTRAL VEIN LOBULUS

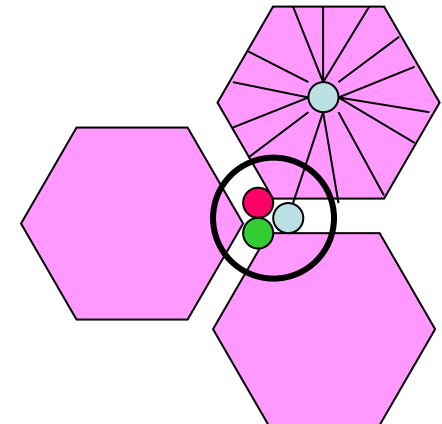
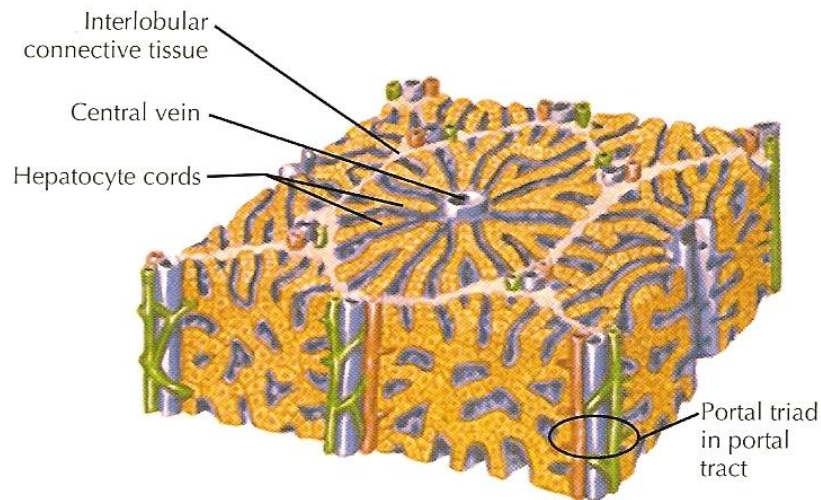
## Lobulus venae centralis



# CENTRAL VEIN LOBULUS

## Lobulus venae centralis

- Classical morphological unit
- Polygonal cells (hexagonal), 0.7 x 2mm
- Central vein
- Radial cords of hepatocytes
- Liver sinusoids
- Portal triad, portobilliary region



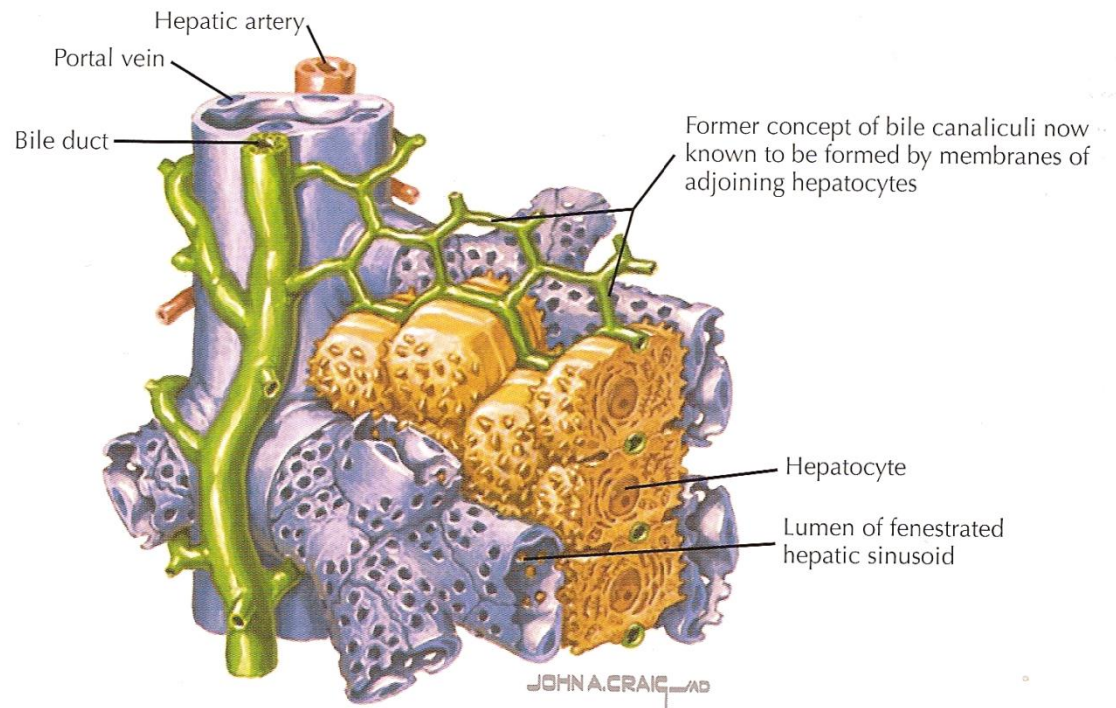
# CENTRAL VEIN LOBULUS

## Portal triad

### Contact of 3-4 neighboring lobuli

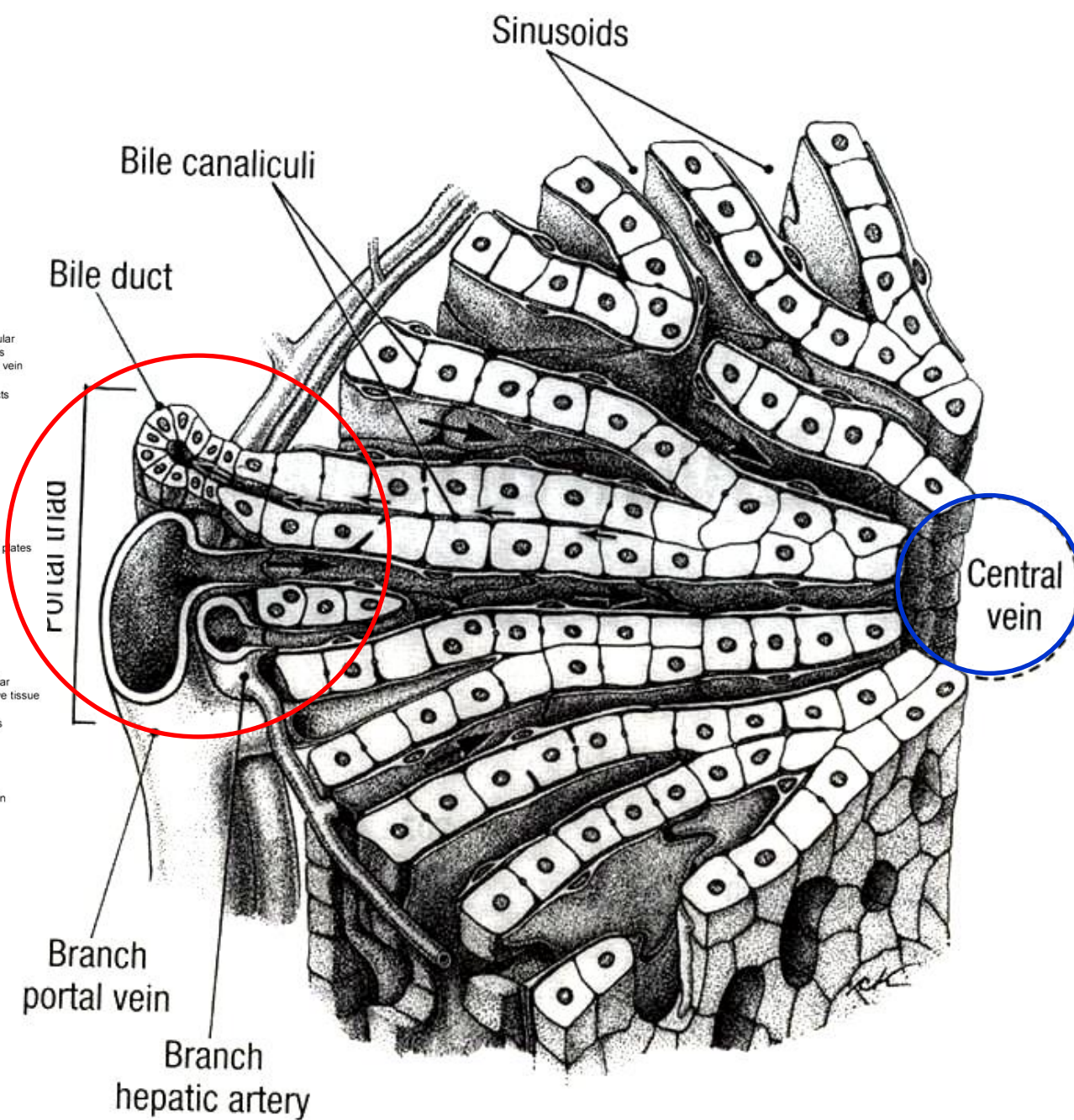
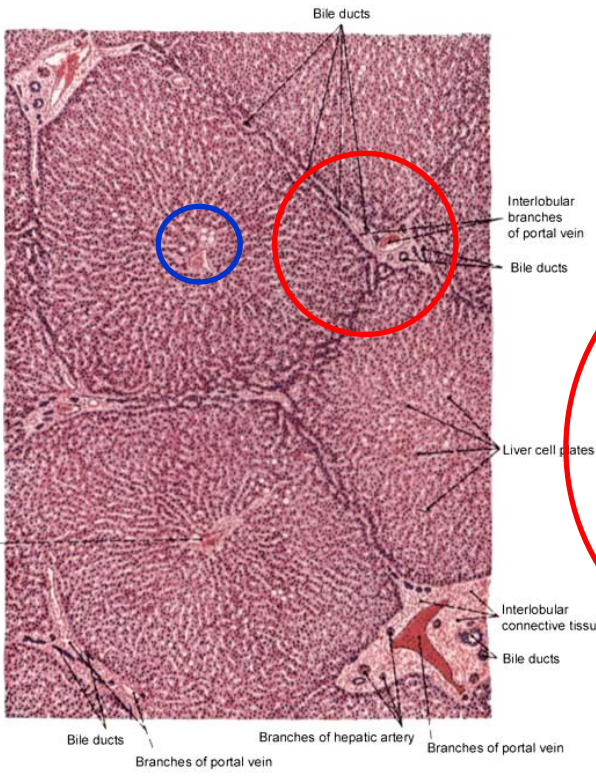
- Interlobular artery (*a. interlobularis*)
- Interlobular vein (*v. interlobularis*)
- Interlobular bile duct (*d. bilifer interlobularis*)
- Lymphatic vessels
- Innervation – *nervus vagus*

Loose interstitial c.t.

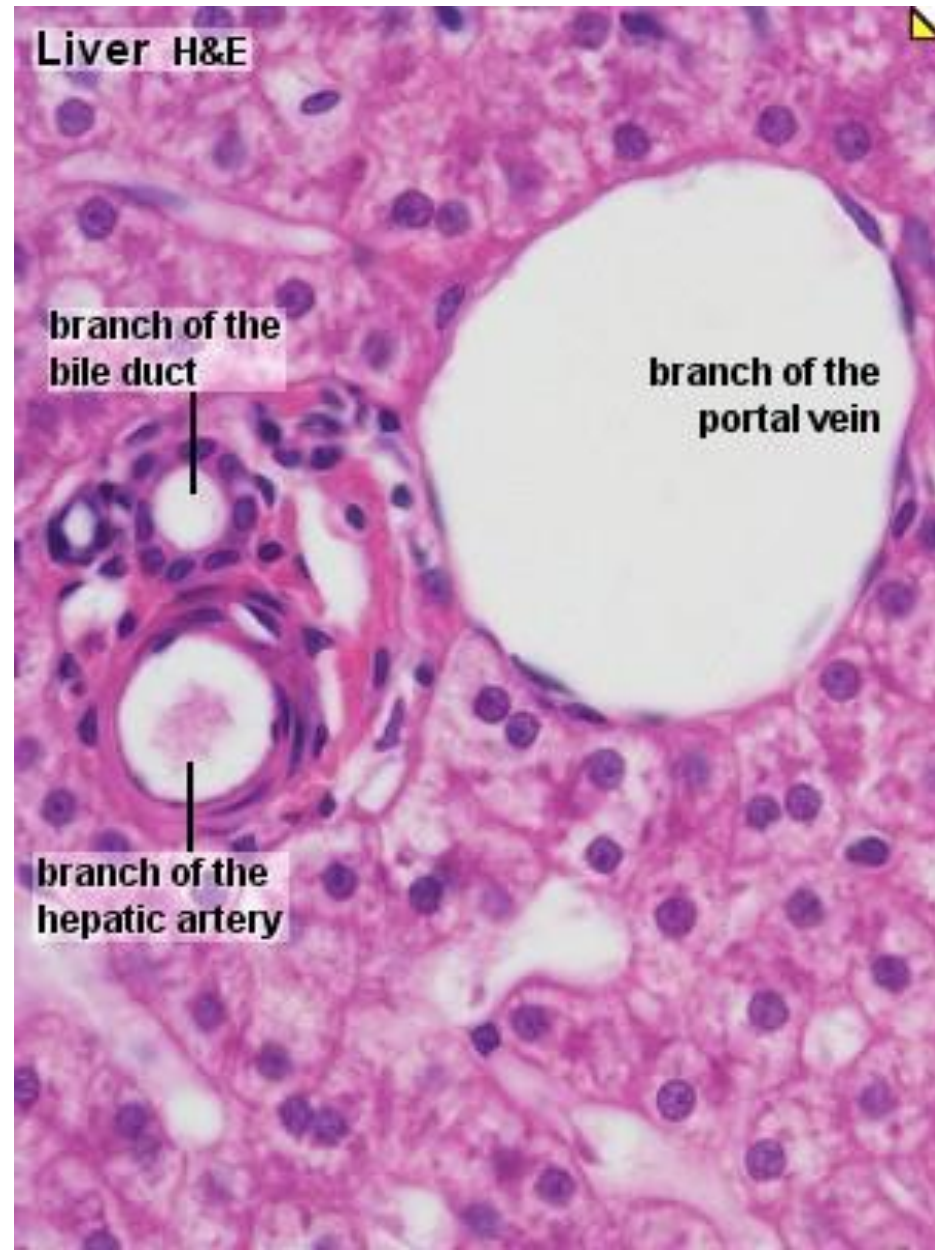
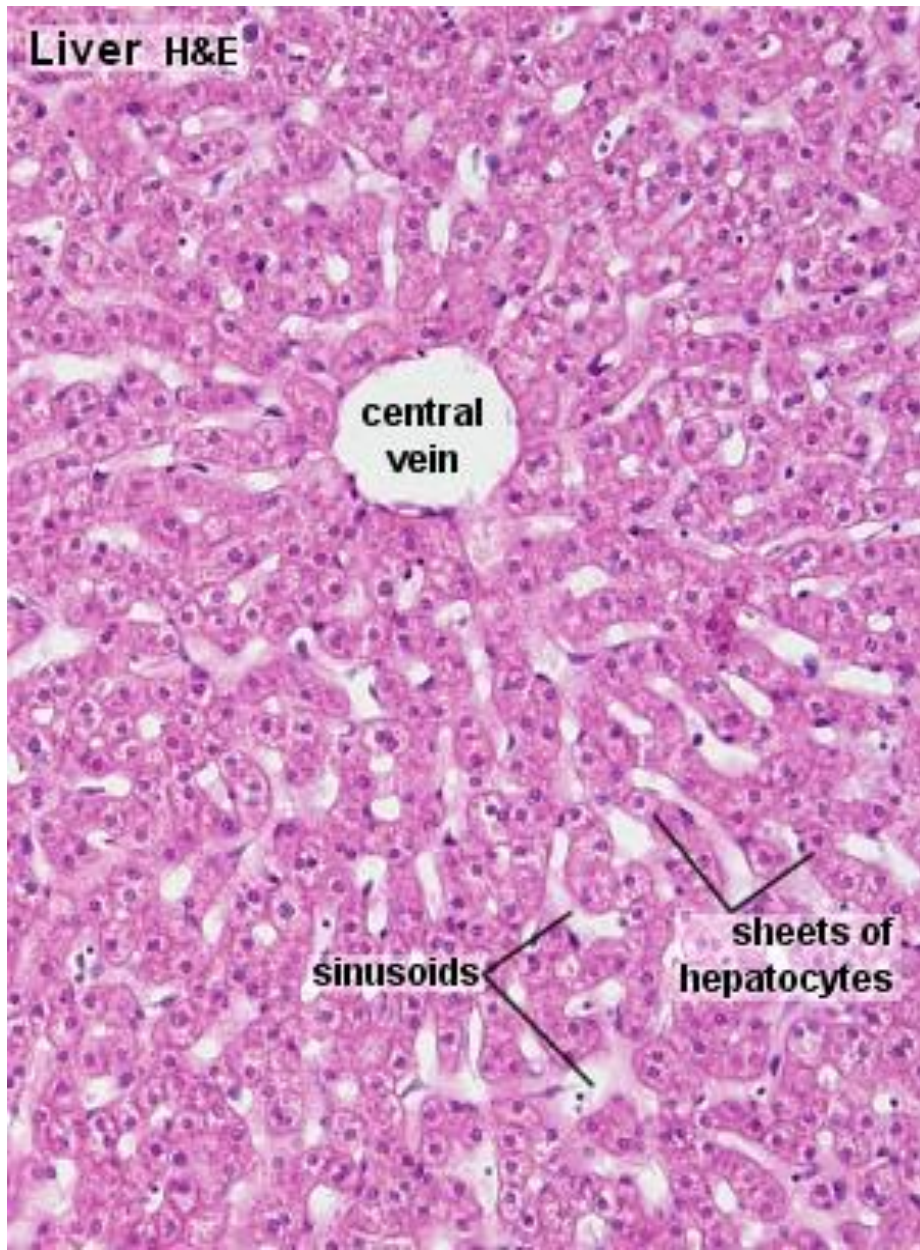


▲ Parts of hepatic lobule at portal triad (high magnification).

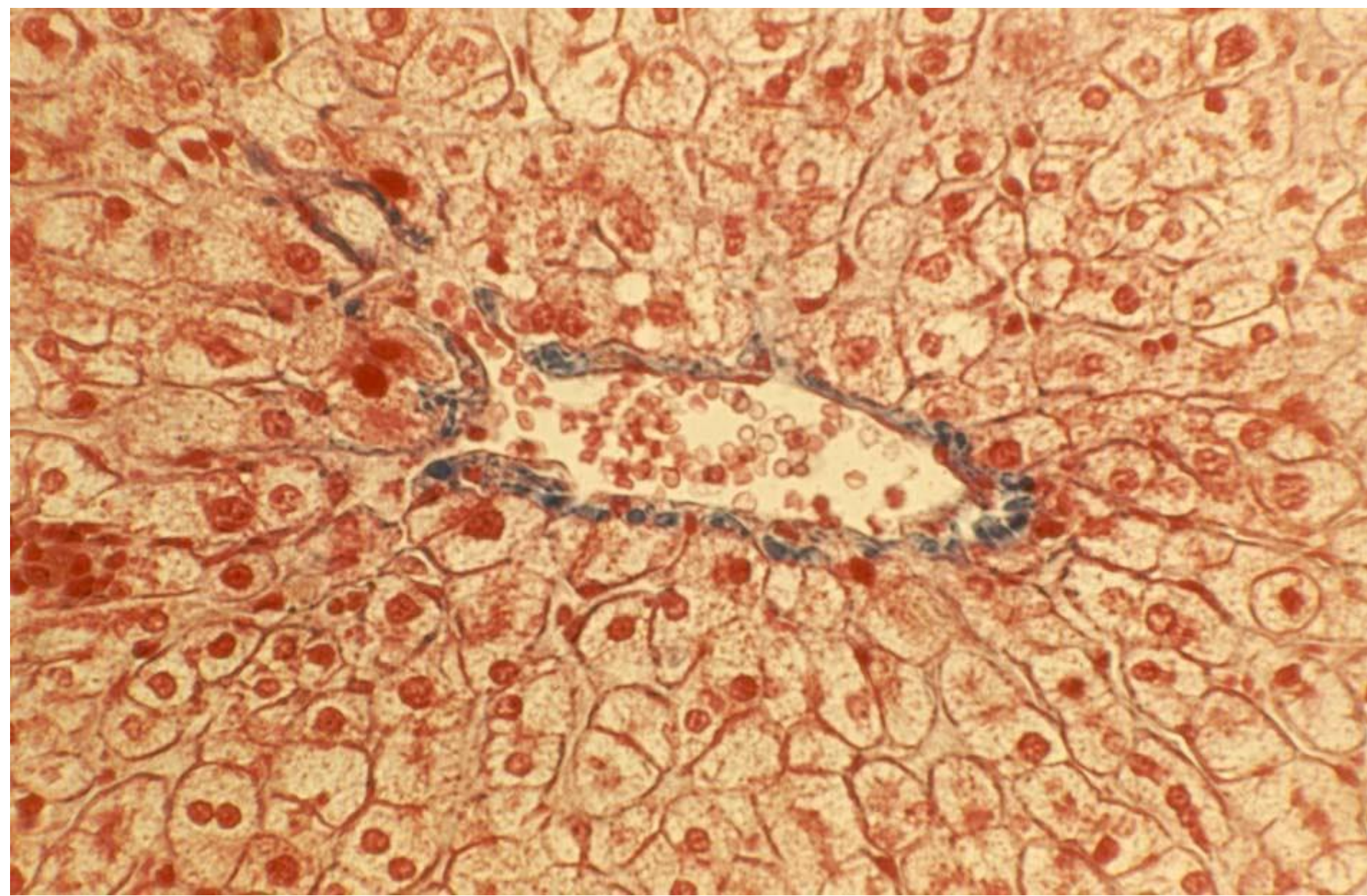
# Ham: Textbook of Histology



# PORTAL TRIAD

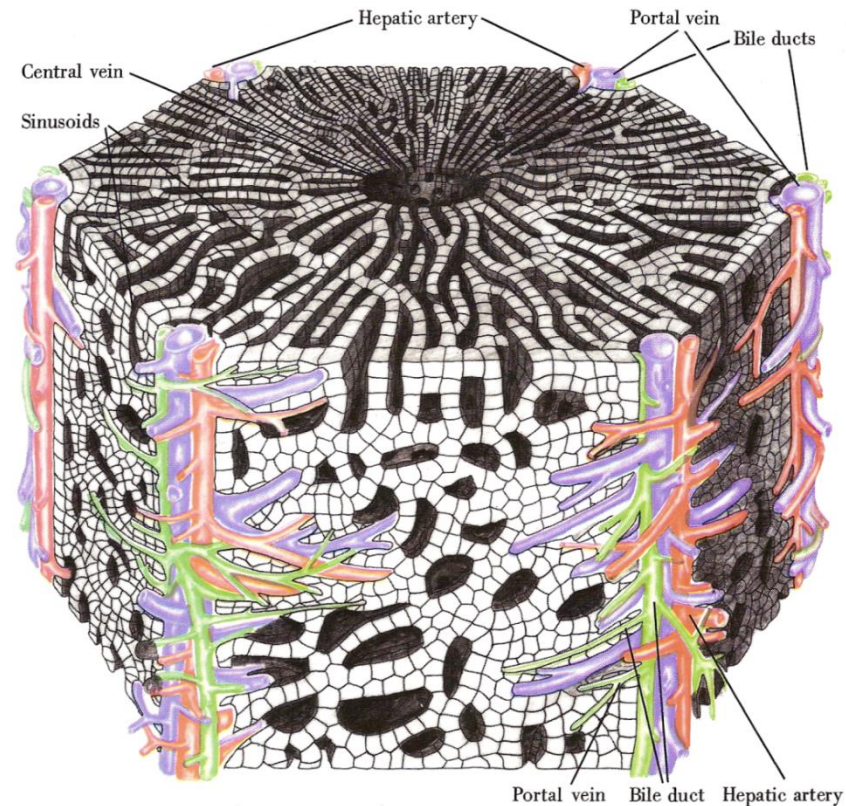


# CENTRAL VEIN



# HEPATOCYTES AND LIVER SINUSOIDS

- Hepatocytes arranged to cords, width 1-2 cells, often anastomoses
- Sinusoids
  - 9-15 $\mu$ m
  - Anastomosing network of flat endothelial cells
  - Basal membrane absent - no diffusion barrier
  - Fenestrations - 100nm, diaphragm absent
  - Intercellular space
  - Perisinusoidal (Dissé) space
  - Reticular fibers, perisinusoidal fibroblasts
  - Dispersed Kupfer cells (monocyte-macrophage system)
  - Perisinusoidal cells of Ito
- Vena centralis – thin-walled vessel, draining blood from sinusoids



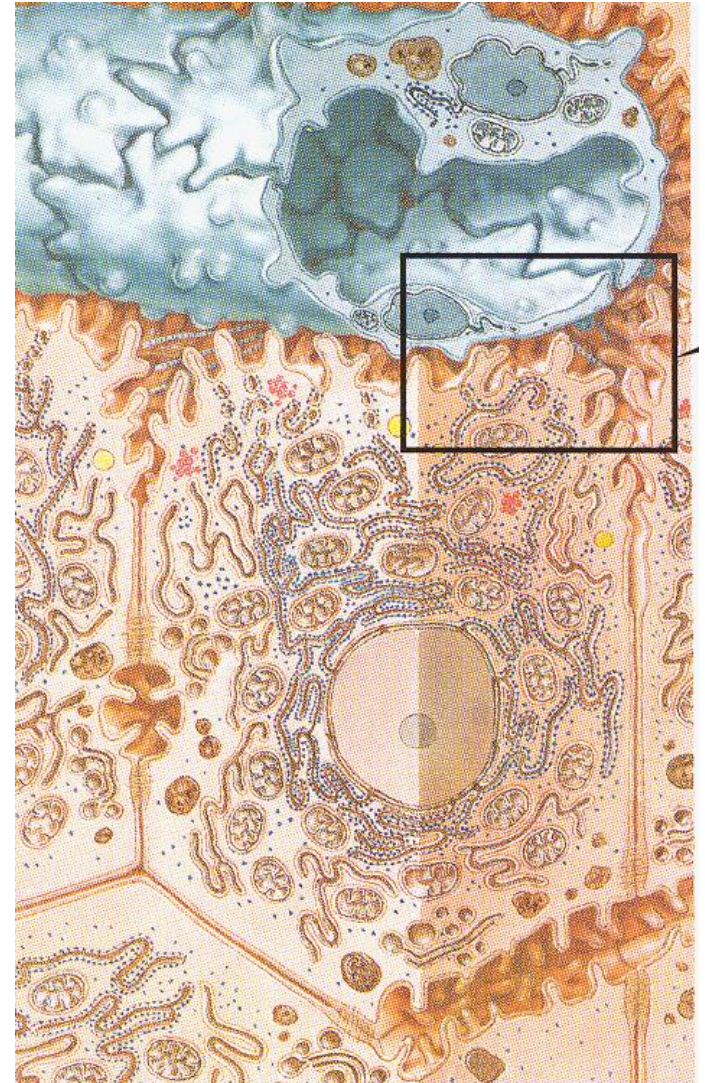
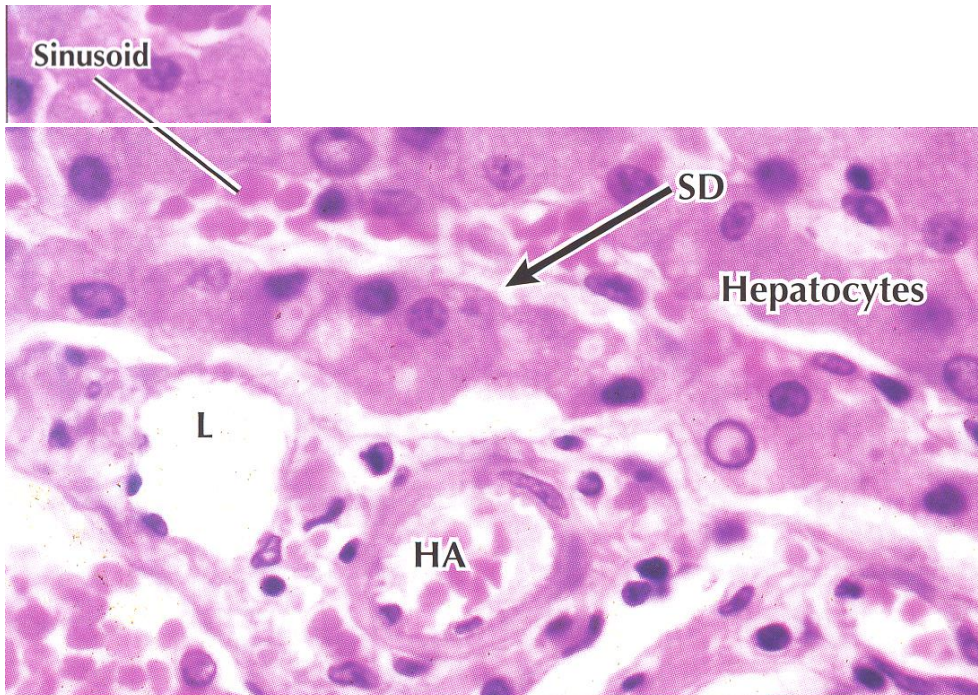


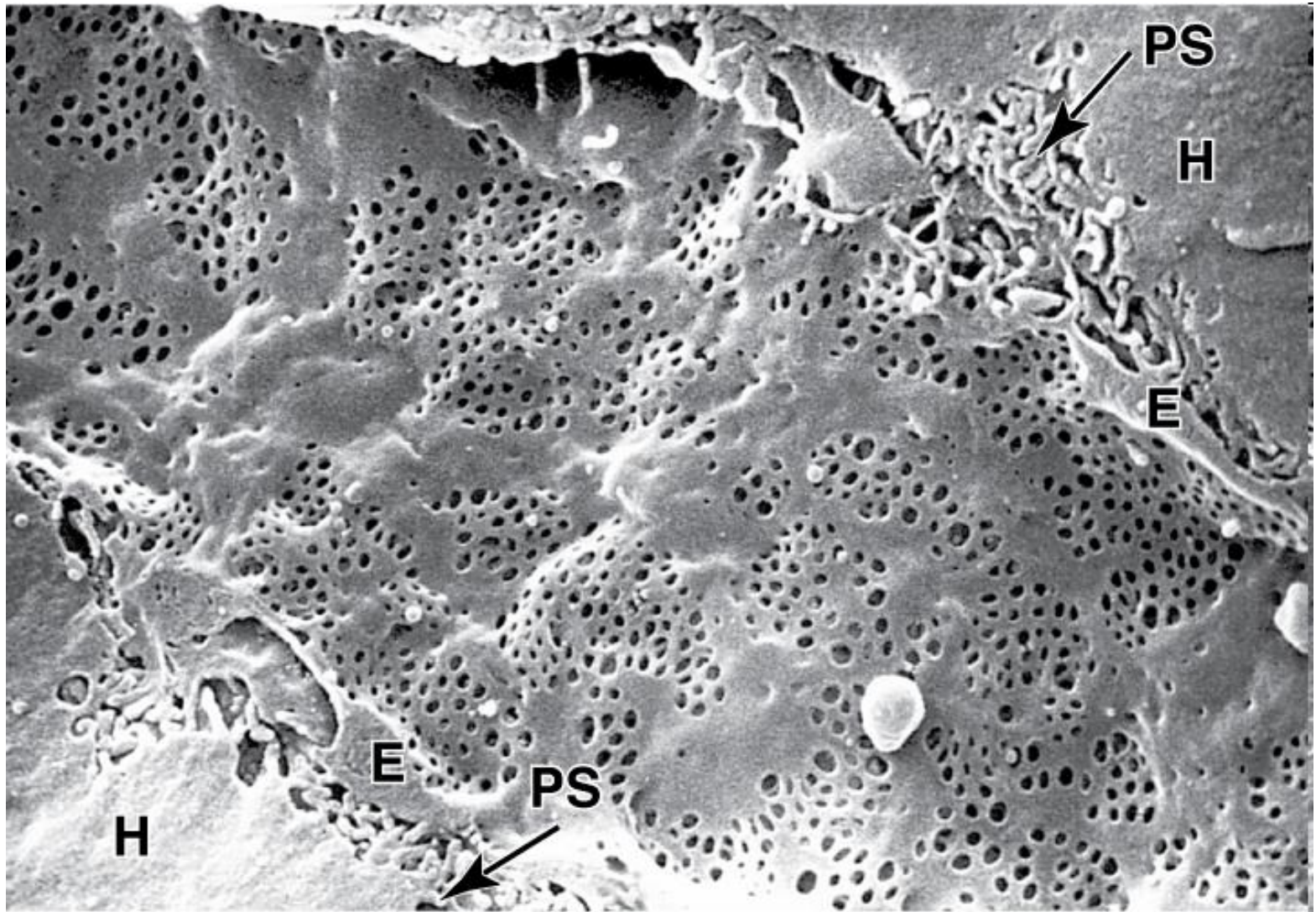
# LOBULUS VENAE CENTRALIS

## Hepatocytes and liver sinusoids

- Space of Disse

- Connection of space of Disse and sinusoidal lumen by fenestrated endothelium
- Hepatocytes in direct contact with plasma (microvilli)
- Cells of Ito

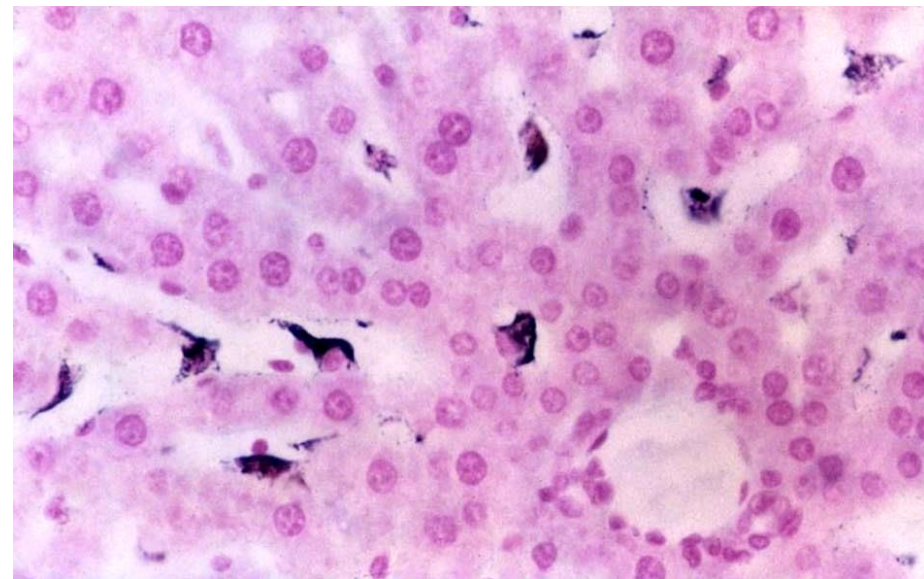
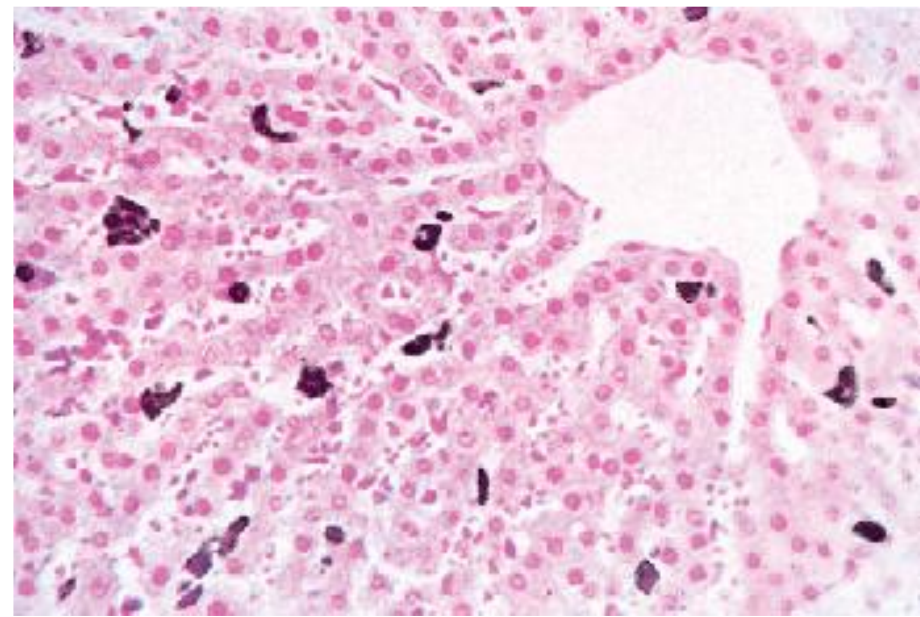




INNER SURFACE OF LIVER SINUSOID – SEM

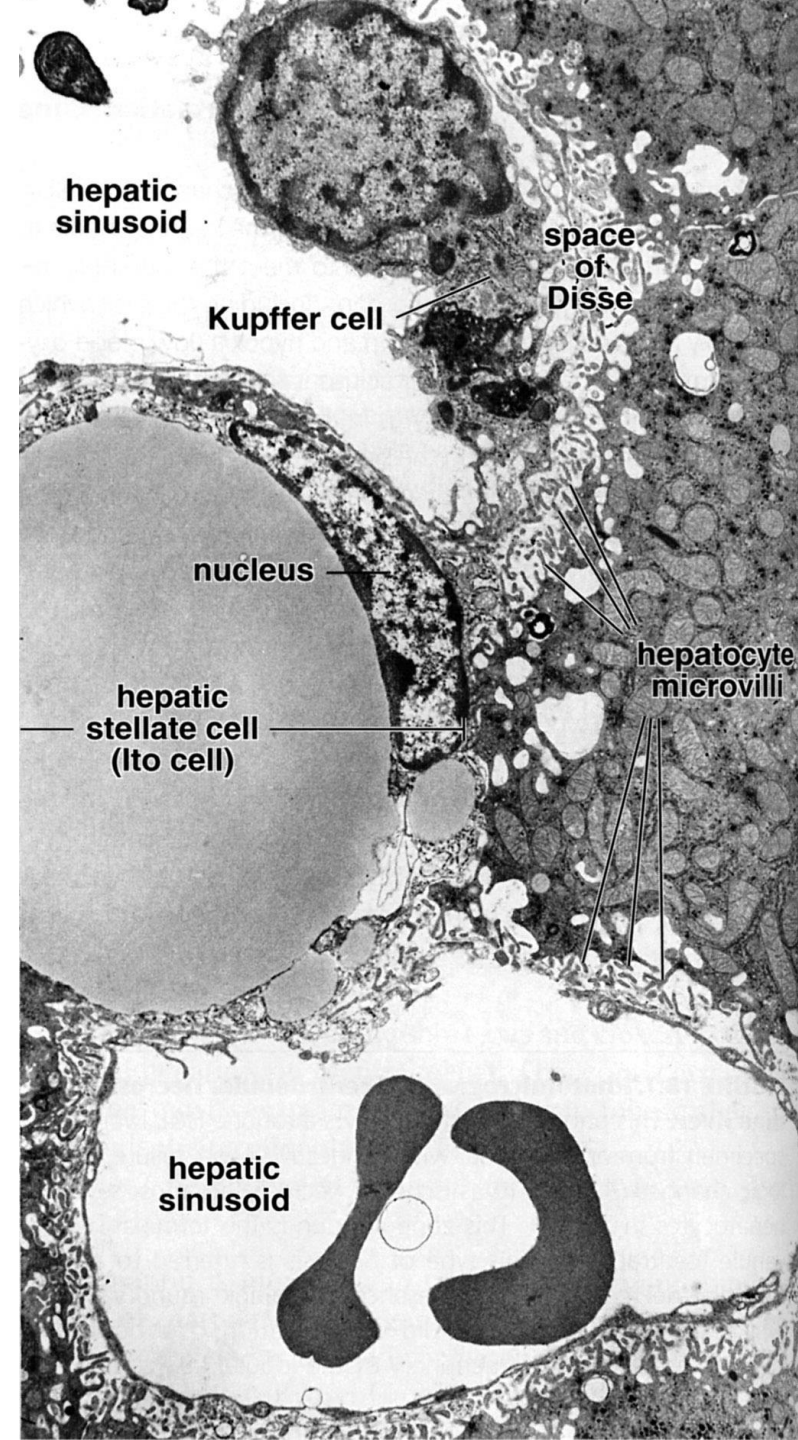
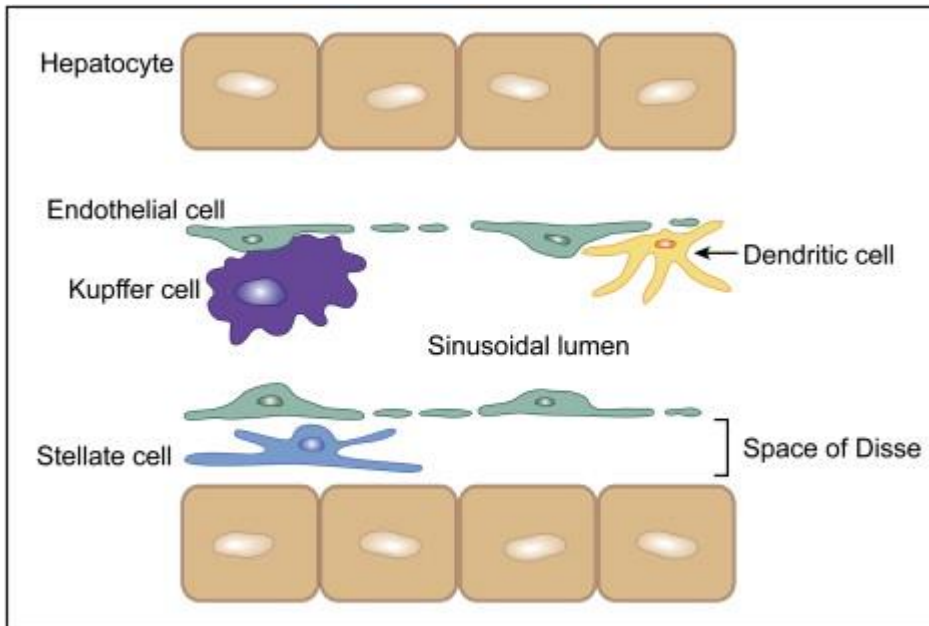
# KUPFFER CELLS

- Liver macrophages
- Mononuclear phagocyte system
- Phagocytosis of particles, damaged erythrocytes and pathogens



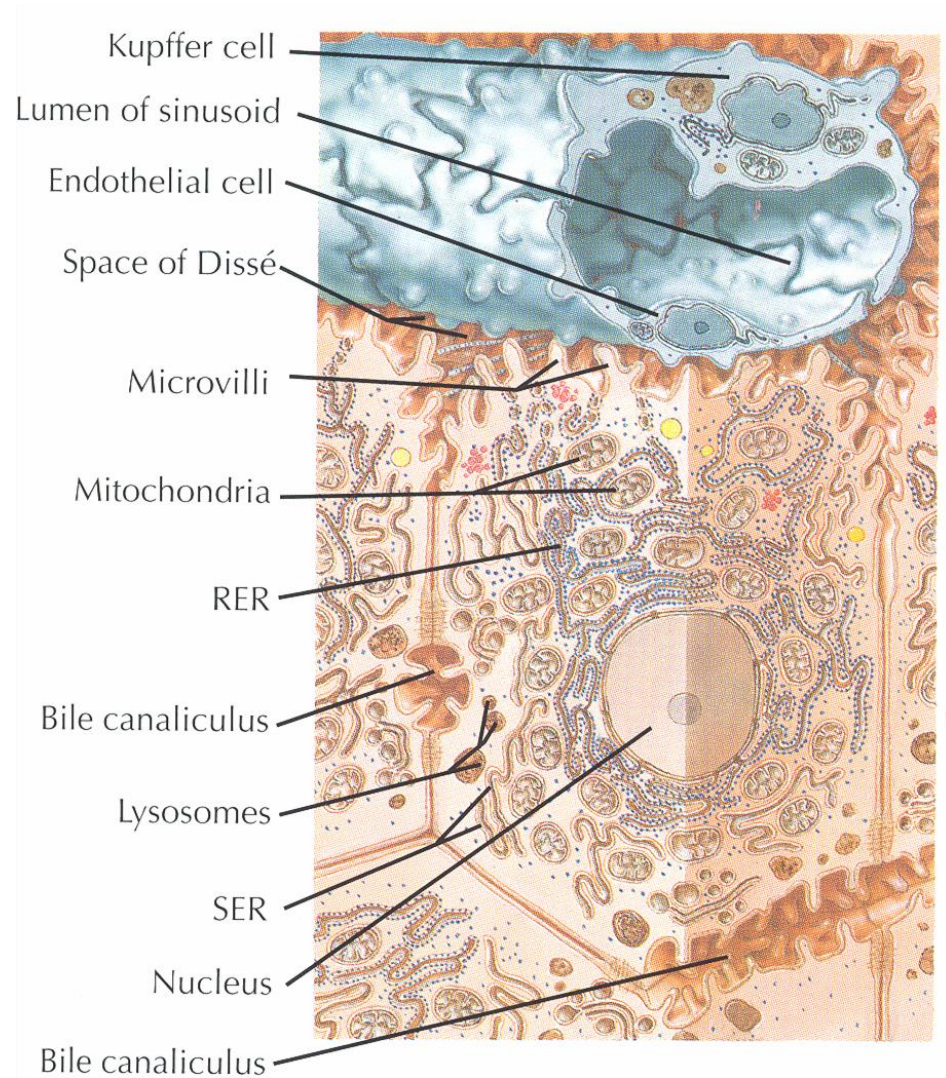
# CELLS OF ITO

- Star-shape (stellate, perisinusoidal) cells
- Lipid droplets
- Deposition of vitamin A
- fine reticular c.t.
- Antigen presenting cells (lipid antigens)

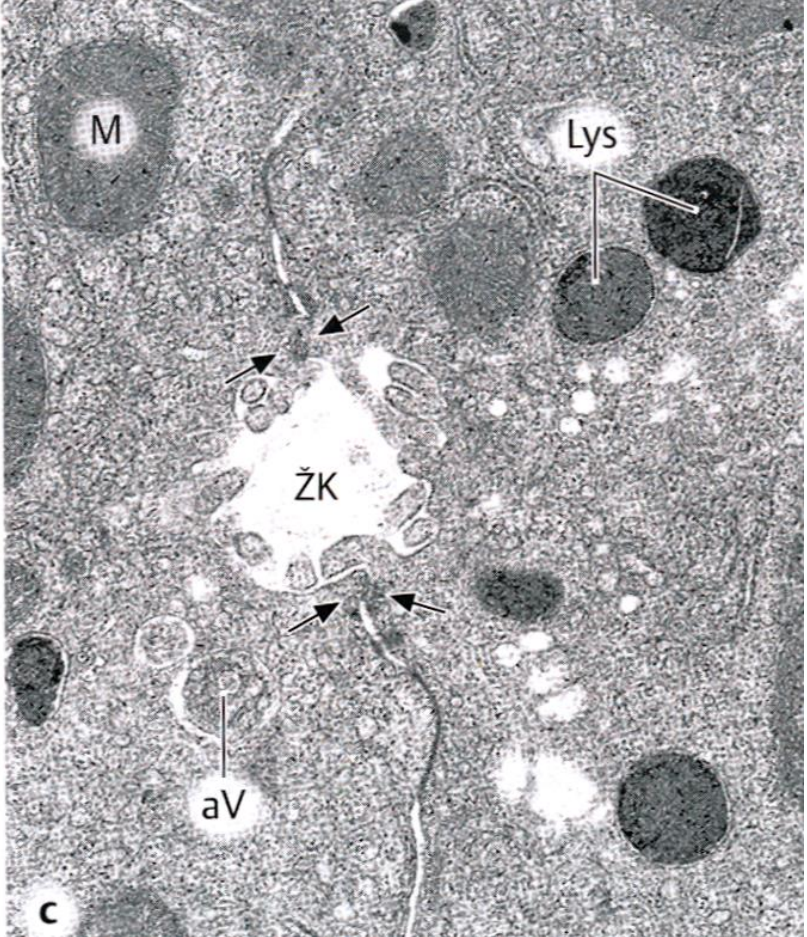
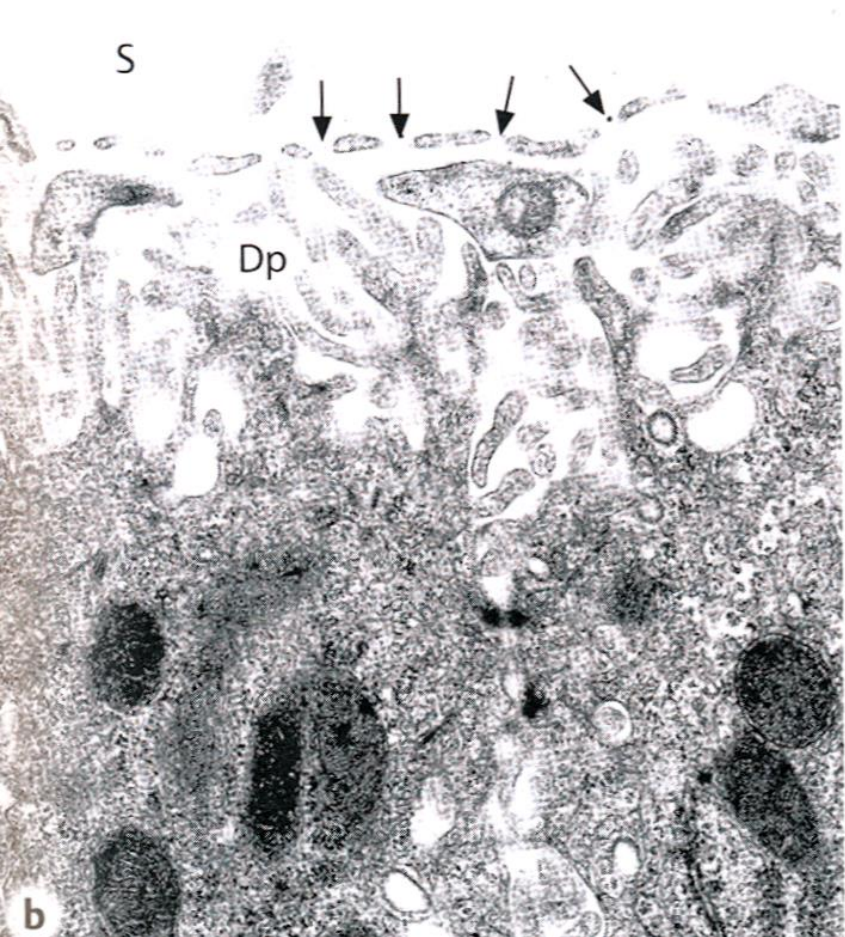


# HEPATOCYTES

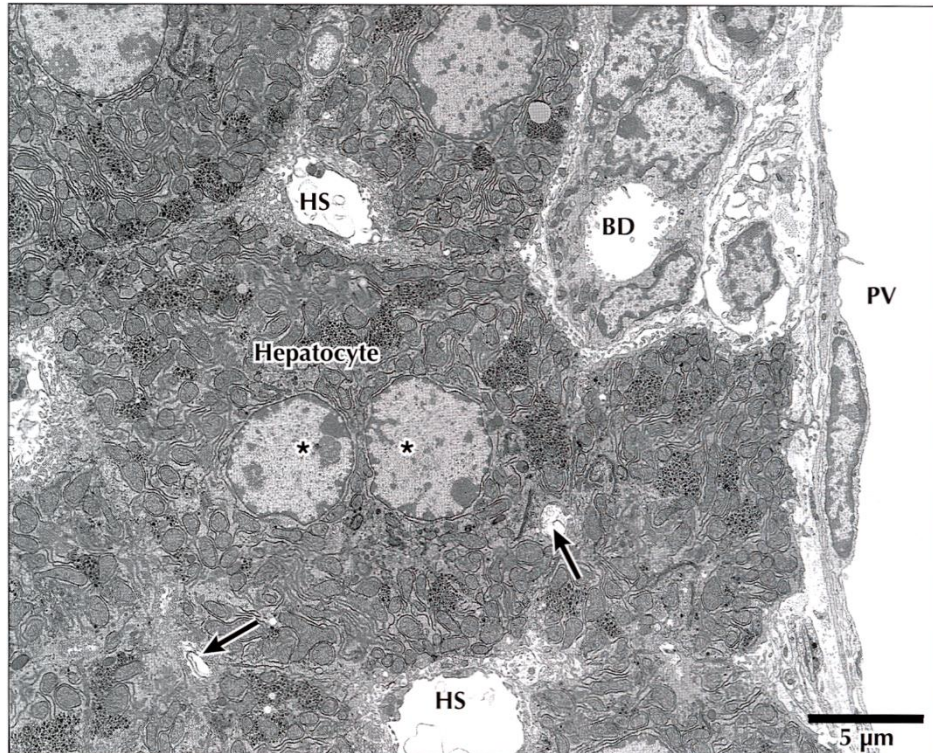
- Polygonal cells of liver parenchyma
- 20x30µm
- Irregular trabecules between sinusoids
- Usually one central nucleus. Bi- and multi-nuclear cells common (20%)
- Nucleoli
- Lysosomes
- Glycogen
- Functional surfaces:
  - **Bile pole** - secretory– membranes of neighboring hepatocytes form bile capillary
  - **Blood pole** - absorptive - sinusoidal – microvilli oriented to space of Dissé
  - Membranes with intercellular junctions



# BILIARY AND BLOOD POLE OF HEPATOCYTE



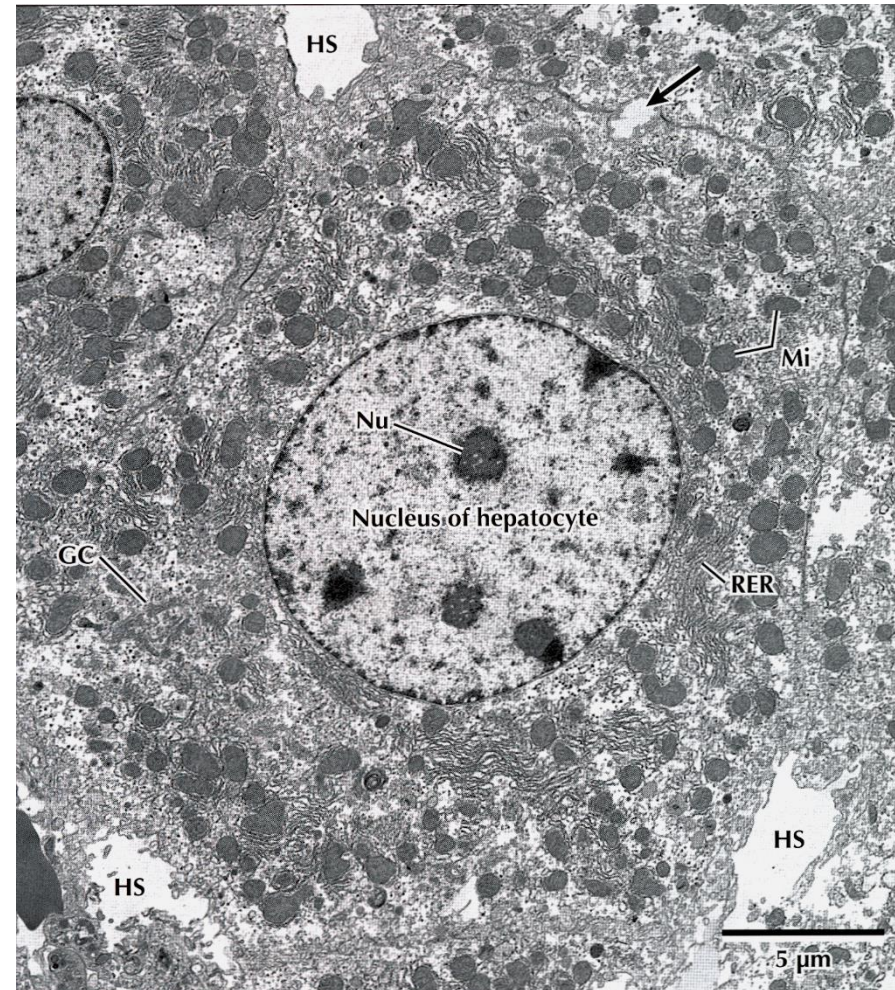
# ULTRASTRUCTURE OF HEPATOCYTES



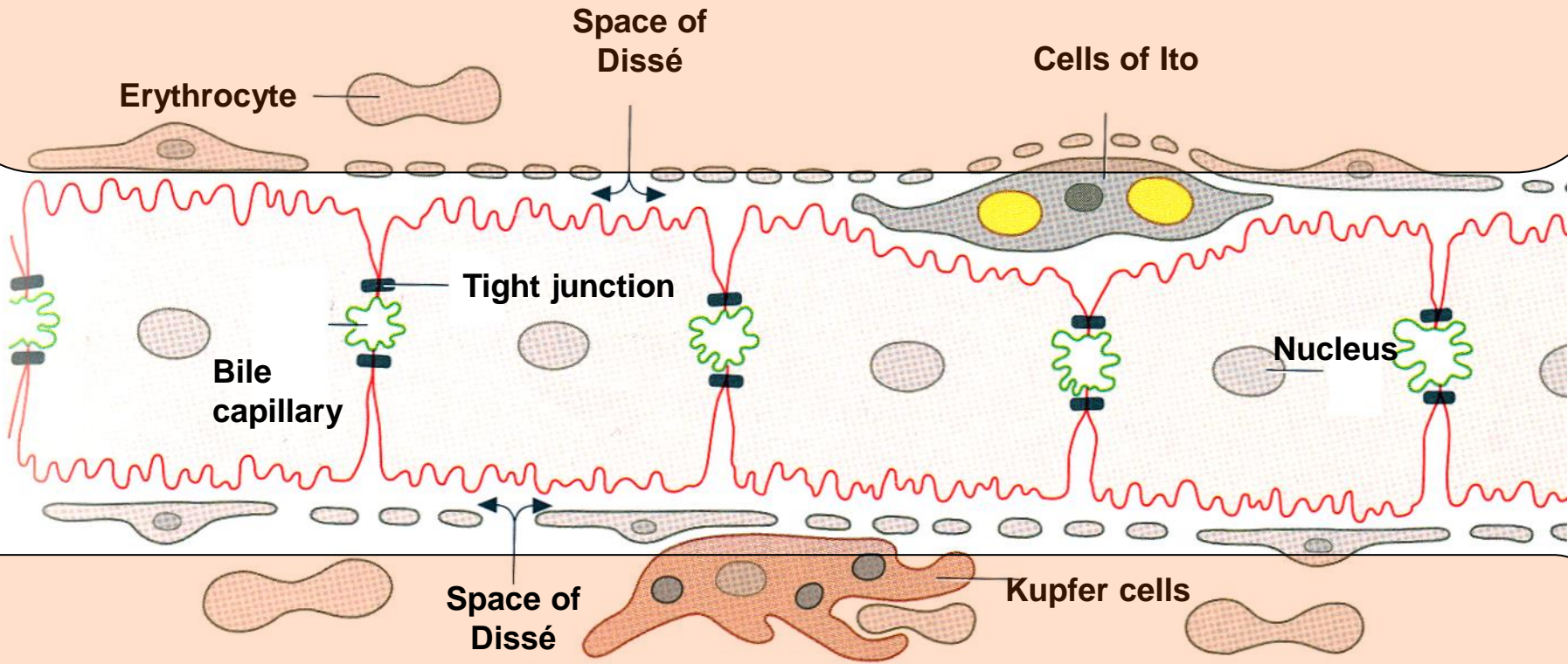
Long mitochondria with flat or tubular cristae

Apparent  $RER$ ,  $SER$  and Golgi

Glycogen, lipid droplets, lysosomes,  
peroxisomes



From plasma:  
Glucose, aminoacids, bile acids



Blood proteins (serum albumin, fibrinogen, prothrombin, complement, transferrin, etc.)



# INTRAHEPATIC AND EXTRAHEPATIC BILE DUCTS

## INTRAHEPATIC

### Bile capillaries (biliary canaliculi)

- intercellular space between hepatocytes
- 1-2 $\mu$ m
- no true wall, formed by membranes of hepatocytes
- intercellular junctions

### Canals of Herring

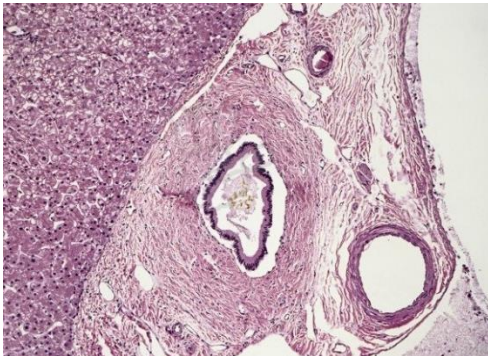
- simple squamous epithelium

### Interlobular bile ducts

- cholangiocytes
- cubic or low columnar epithelium + c.t.

### Lobar bile ducts


- ductus hepaticus dexter et sinister
- high simple columnar epithelium



## EXTRAHEPATIC

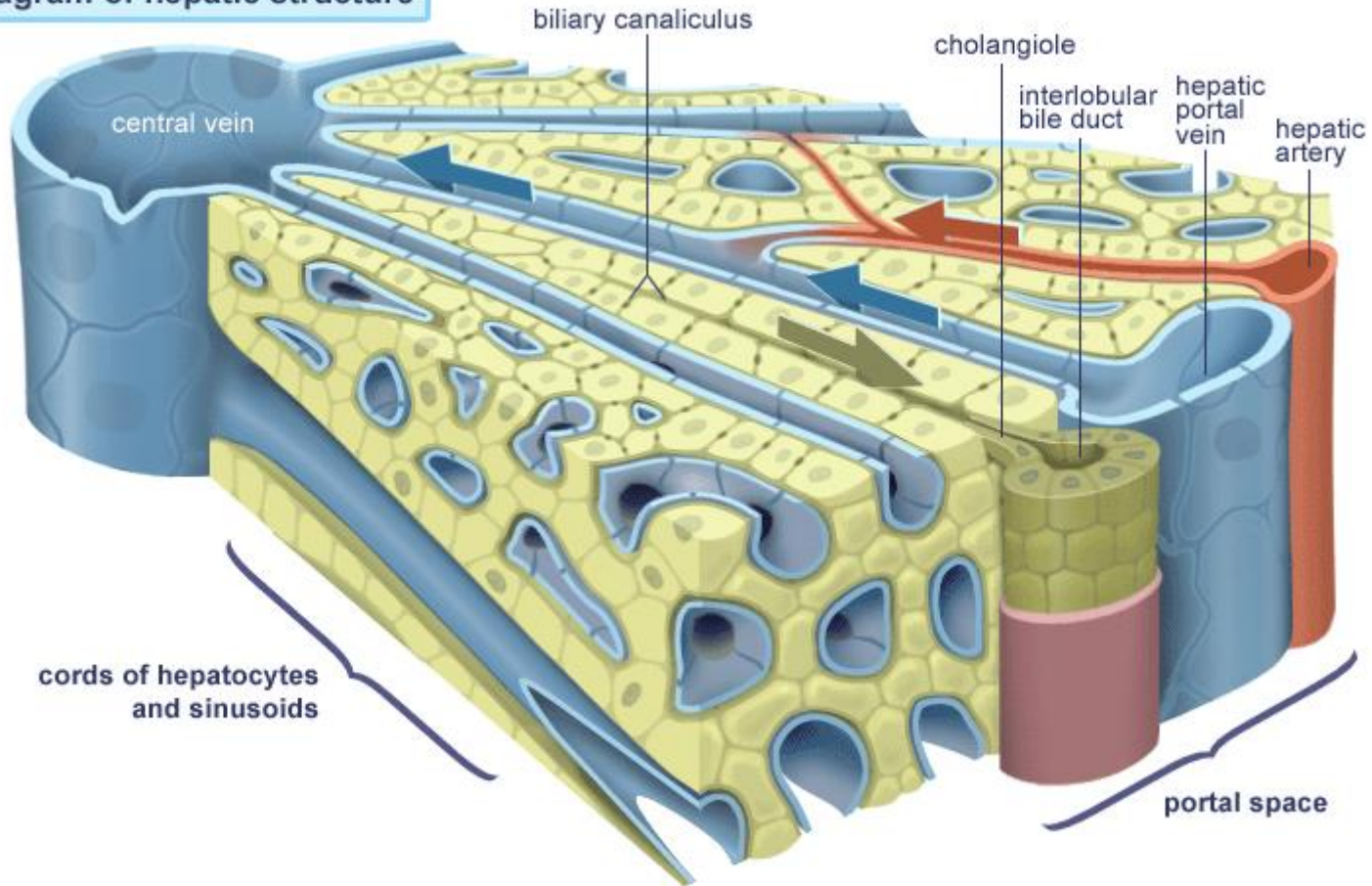
### Ductus hepaticus, ductus cysticus, ductus choledochus

- mucosa
- fibromuscular layer



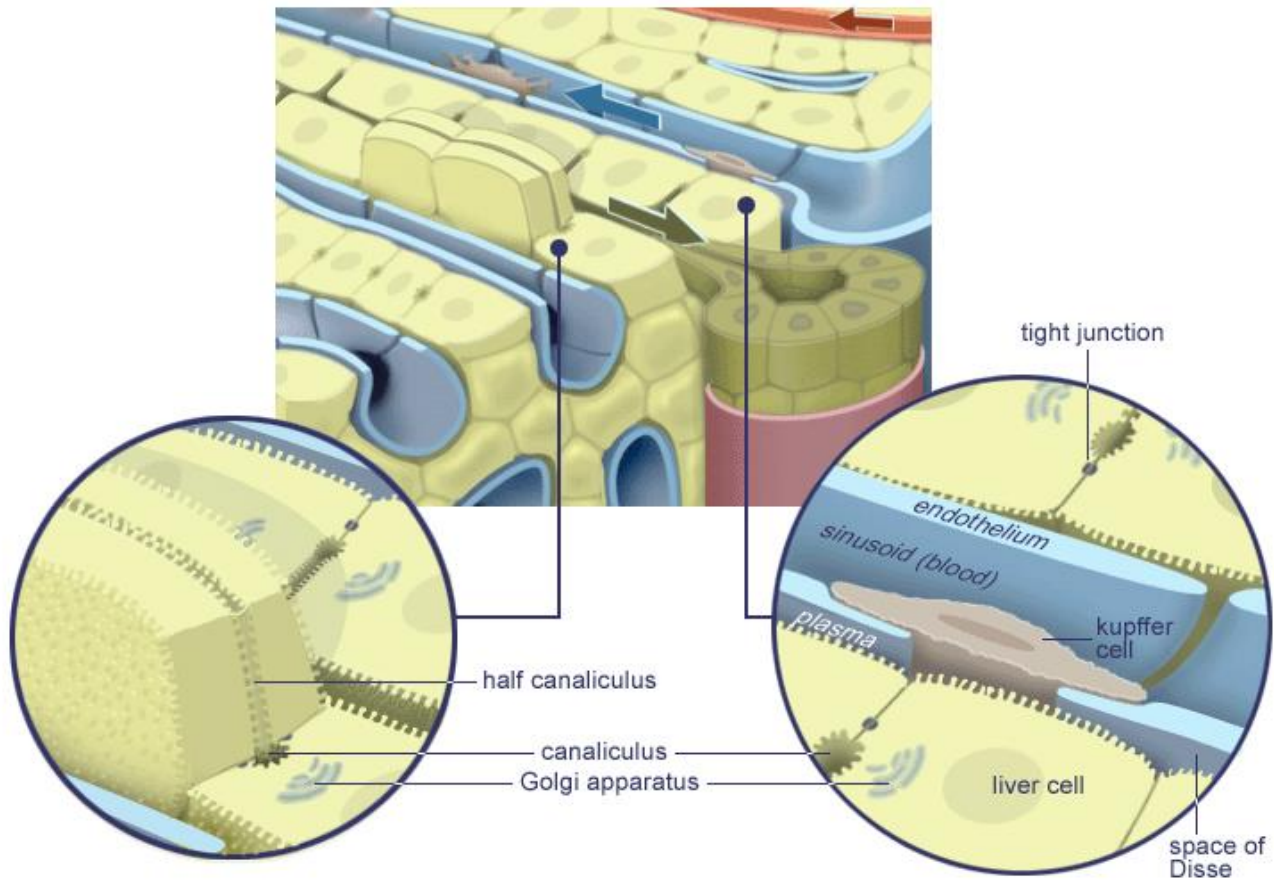
# INTRAHEPATIC BILE DUCTS

Diagram of hepatic structure



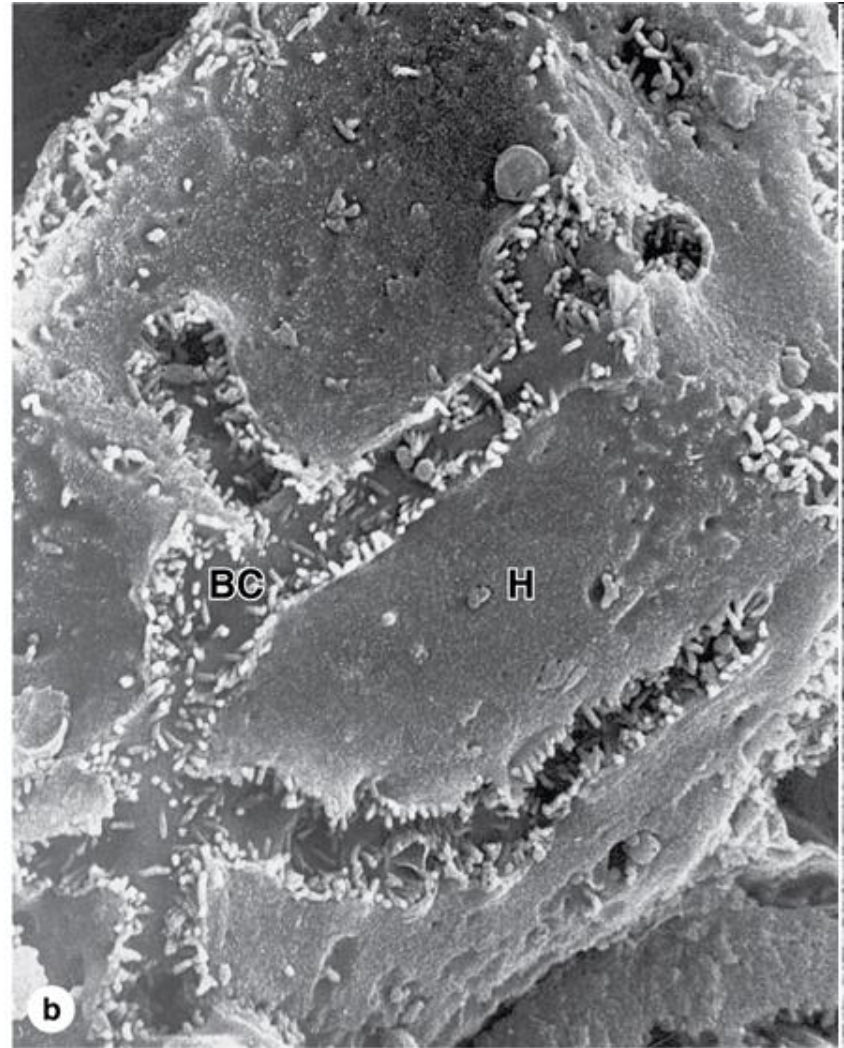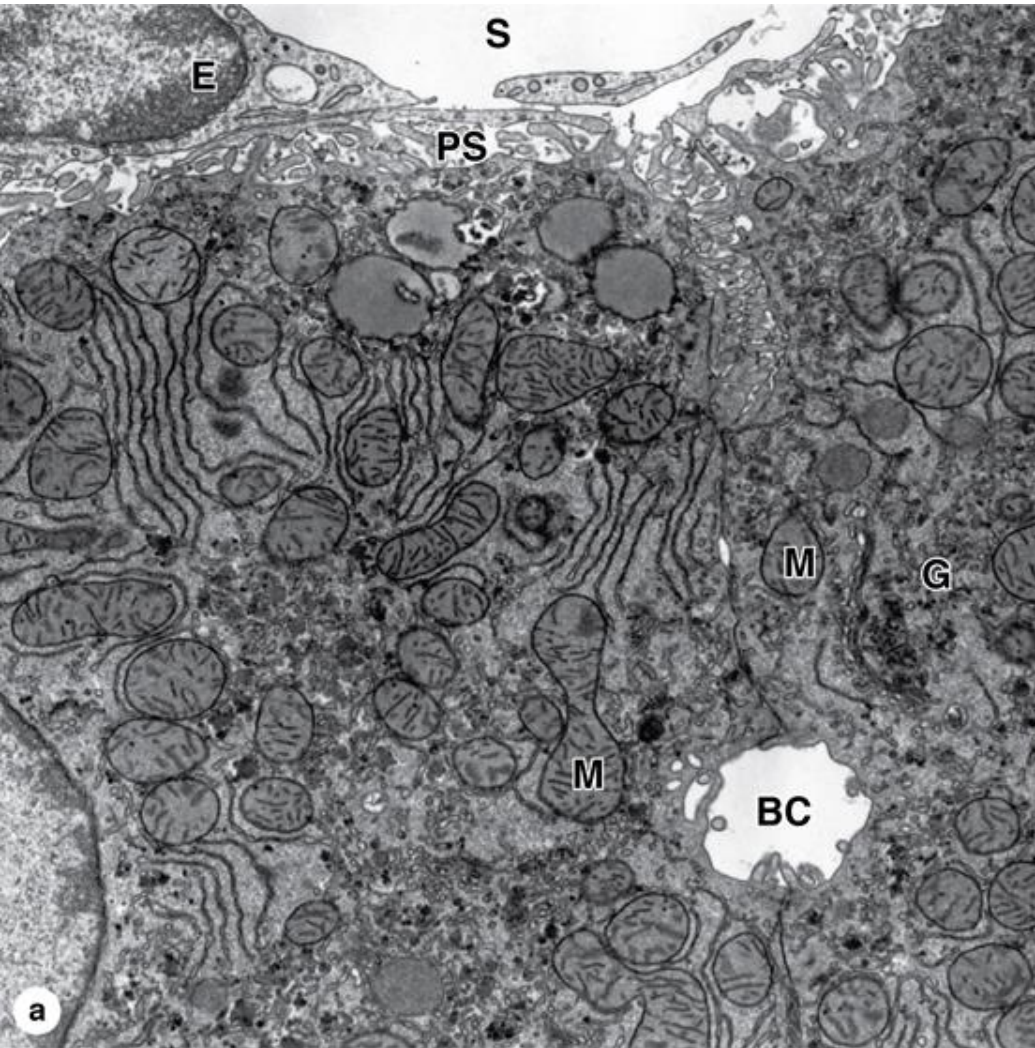
# INTRAHEPATIC BILE DUCTS

Hepatic structure (close-up)



# INTRAHEPATIC BILE DUCTS

## TEM/SEM





# EXTRAHEPATIC BILE DUCTS

d. hepaticus communis + d. cysticus → d. choledochus

papilla duodeni major

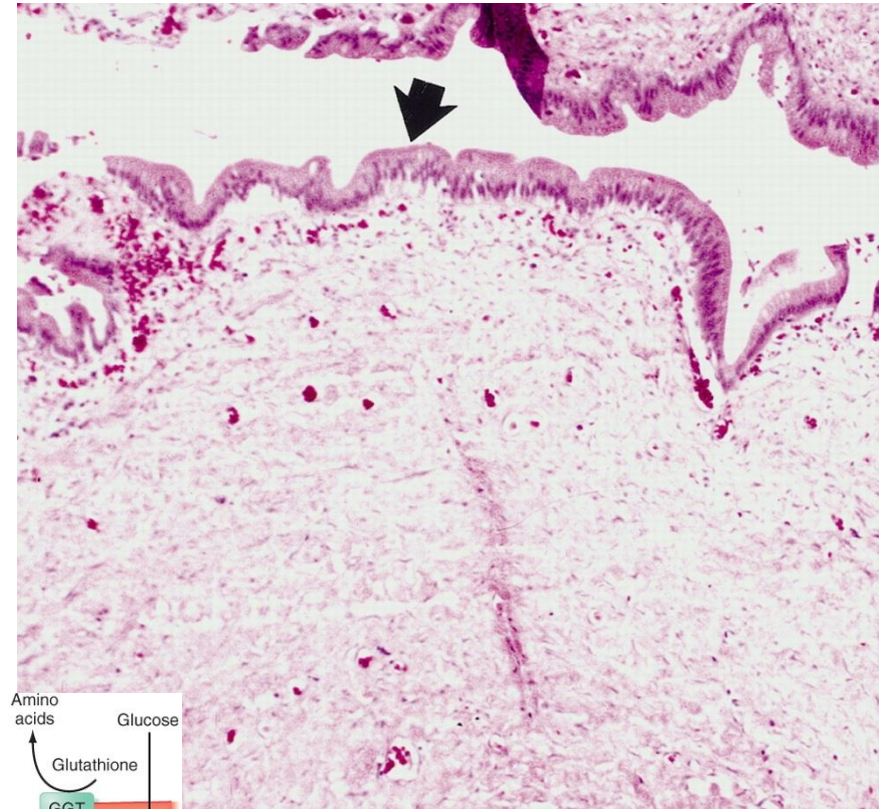
m. sphincter ampullae hepatoduodenalis (sphincter of Oddi)

## Mucosa

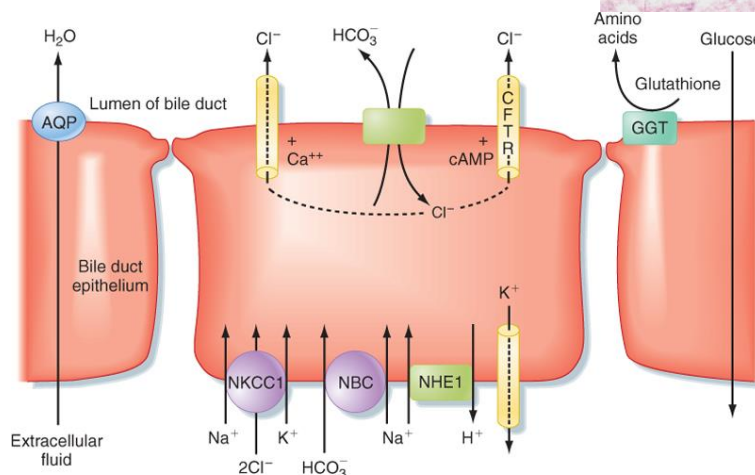
- lateral folds
- simple columnar epithelium (cholangiocytes)
- mucinous glands in c.t., goblet cells

## Fibromuscular layer

- dense network of collagen and elastic fibers
- leiomyocytes



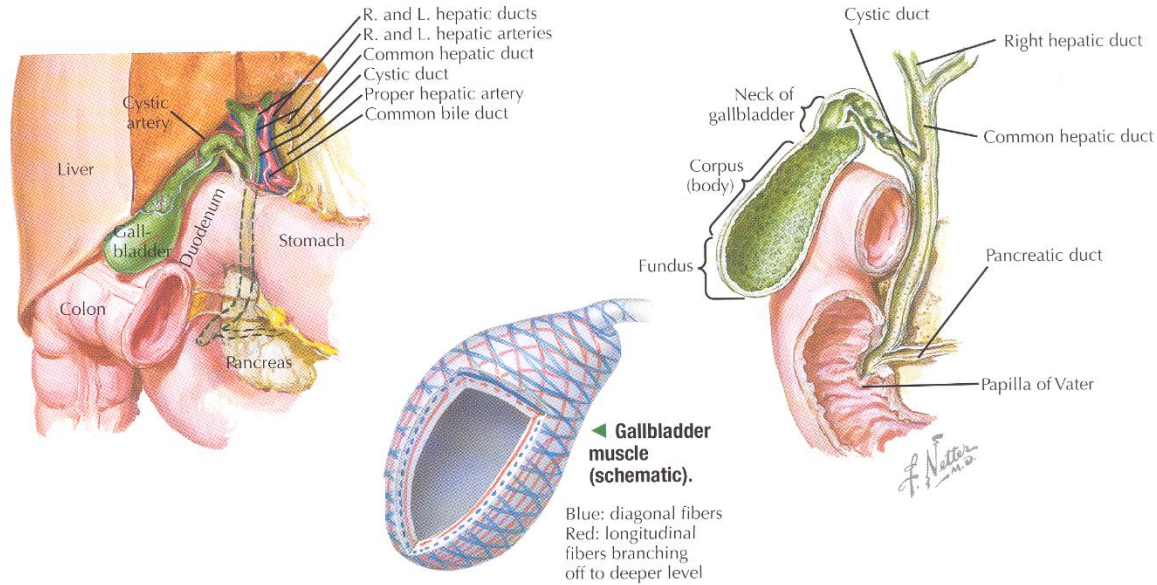
## Bile modification



# GALL BLADDER (VESICA FELLEA)

- Wall 1-2mm

- Mucous coat
- Muscle layer
- Serosa/adventitia



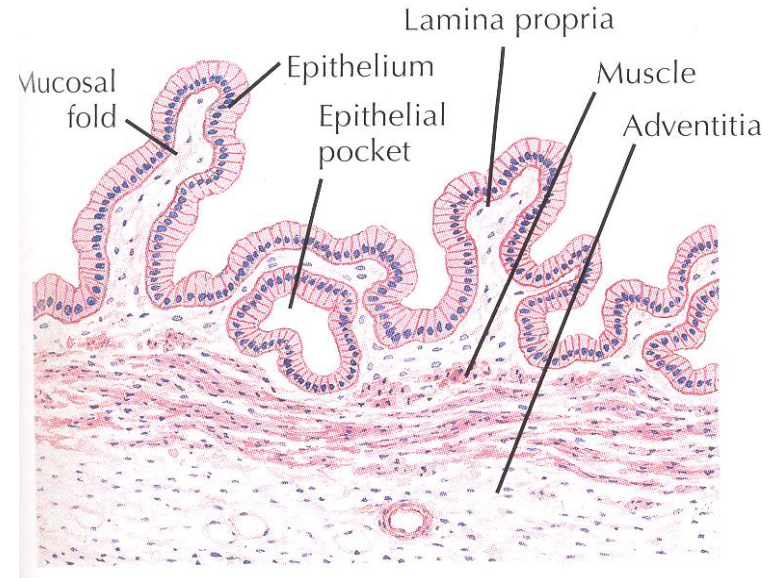
## Mucous coat

- mucosal folds
- 20-50 $\mu$ m simple columnar epithelium with microvilli
- intercellular junctions
- lamina propria mucosae - loose collagen c.t. with mucinous tuboalveolar glands
- lamina muscularis mucosae absent

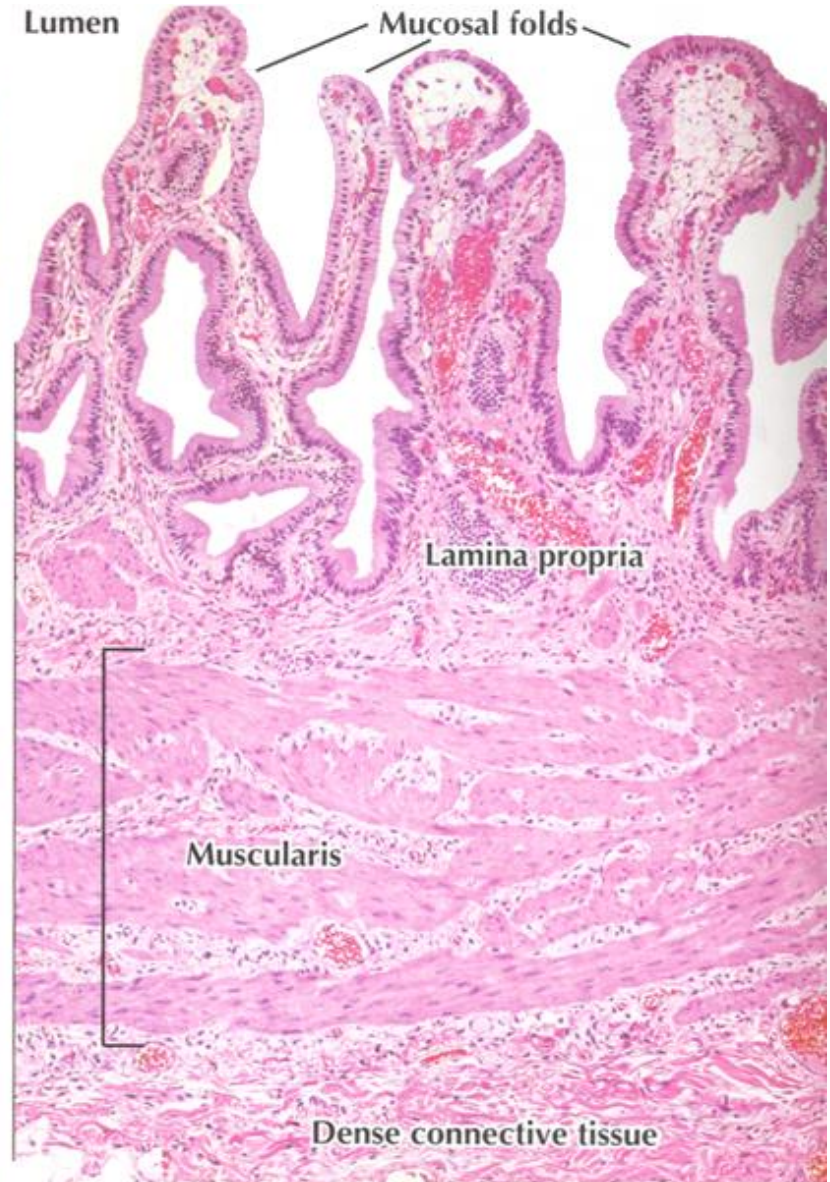
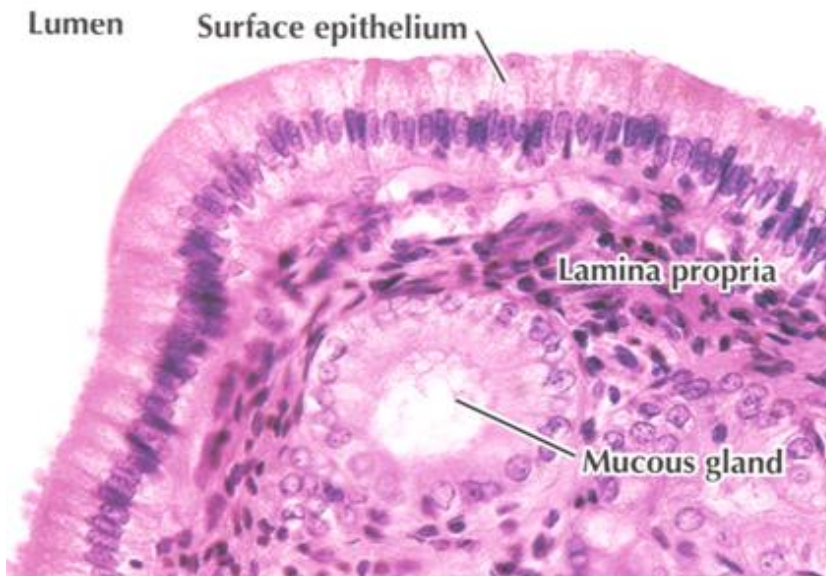
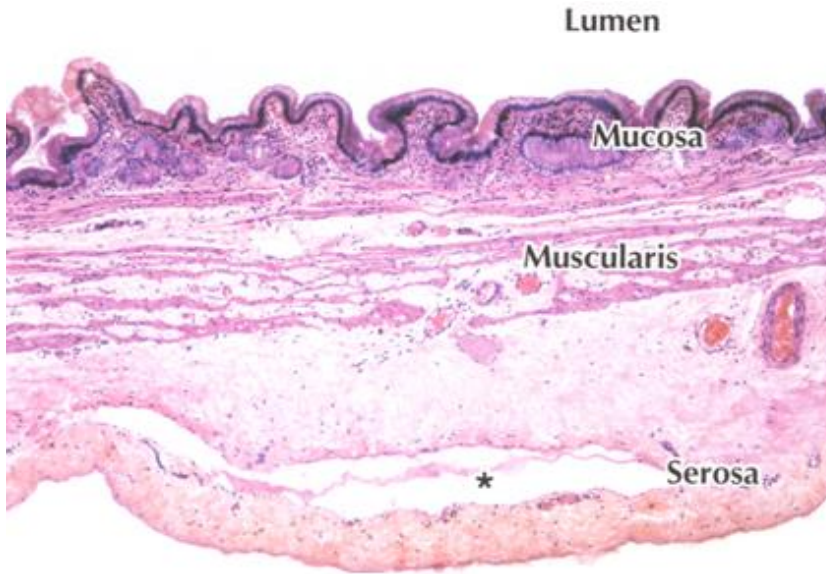
## Muscular layer (Muscularis propria)

- 3D network of smooth muscle cells,
- elastic fibers

Large layer of **subserous** c.t. (l. propria serosae)

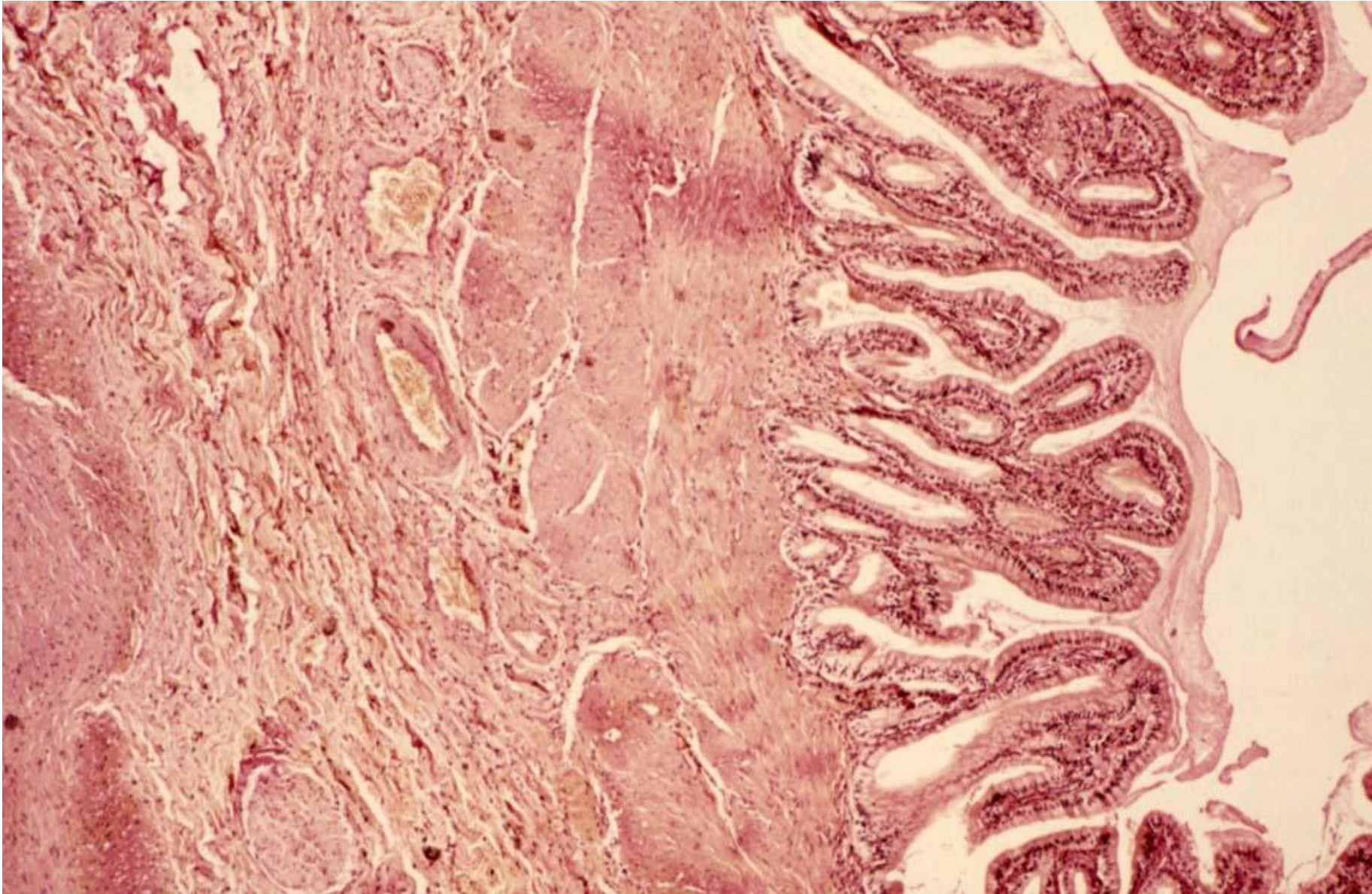


# GALL BLADDER (VESICA FELLEA)

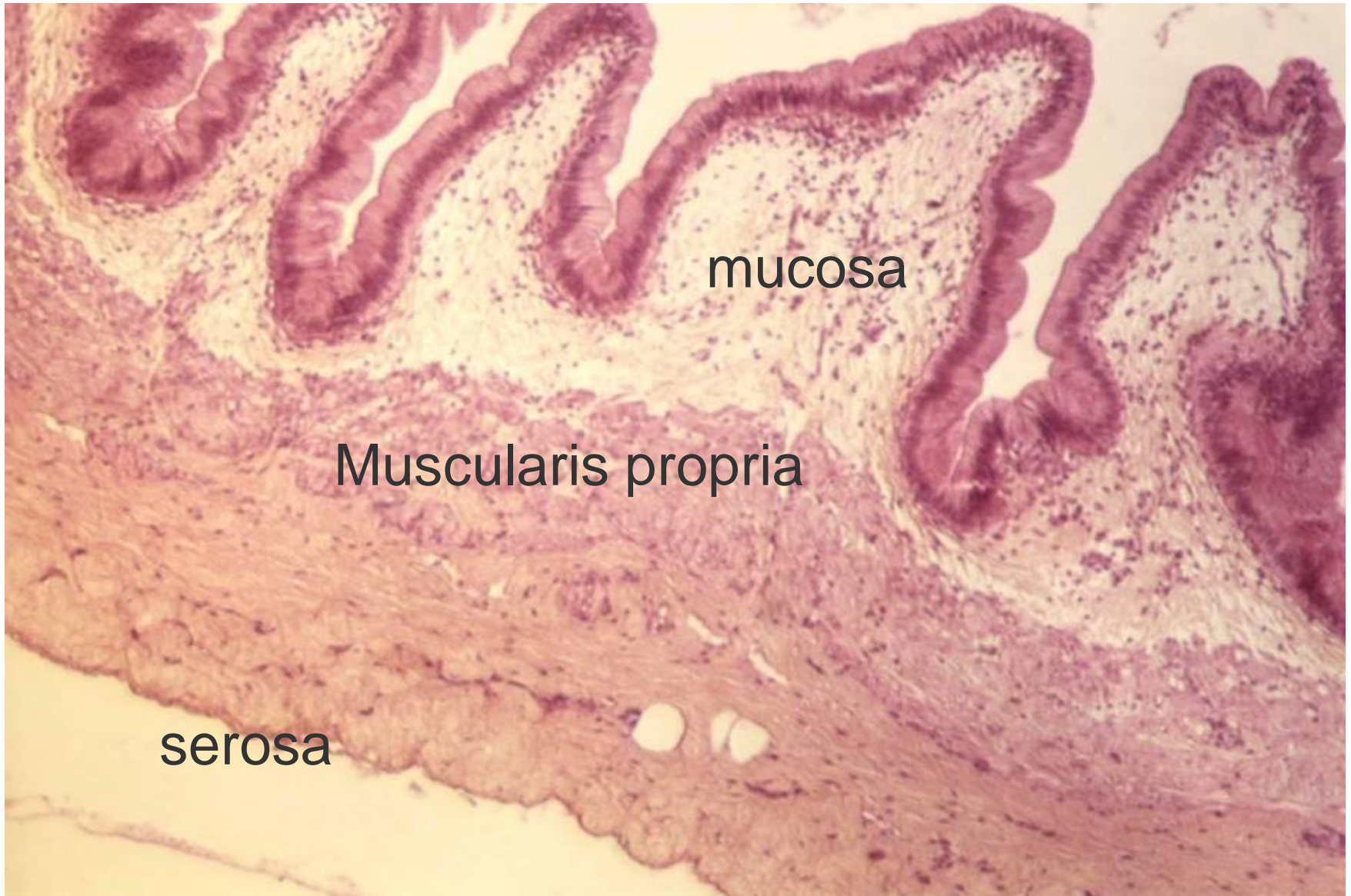




# GALL BLADDER (VESICA FELLEA)

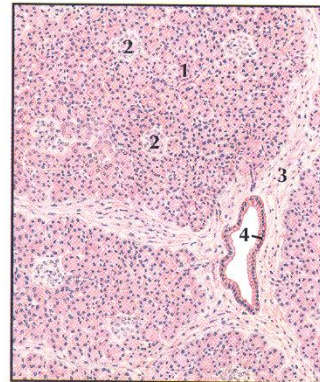
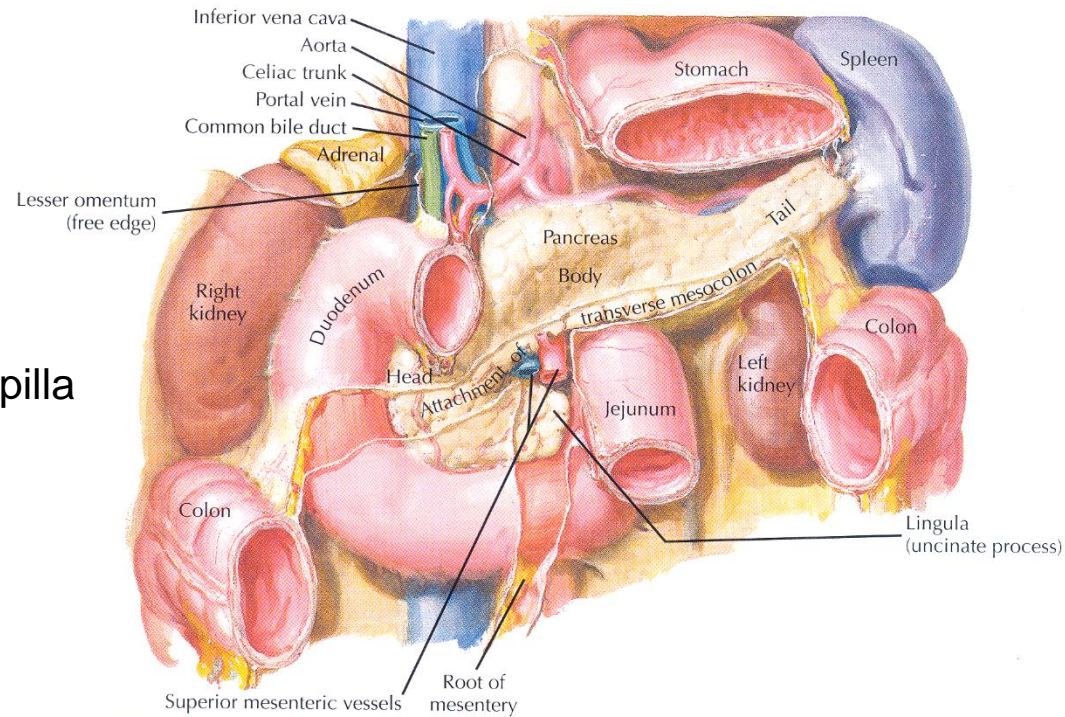


# GALL BLADDER (VESICA FELLEA)

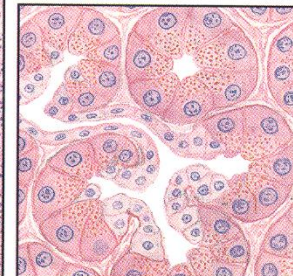


# PANCREAS

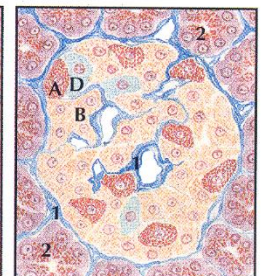
- Compound, serous, tuboalveolar gland
- Exocrine and endocrine character
  - pancreatic acinus
  - Islets of Langerhans
- Major duct (Wirsungi) opens to Vater papilla as a common bile and pancreatic duct
- Dense collagen c.t. capsule
- Septs – blood cells, innervation, and interlobular ducts



Low-power section of pancreas  
1. Acini, 2. islet, 3. interlobular septum, 4. interlobular duct



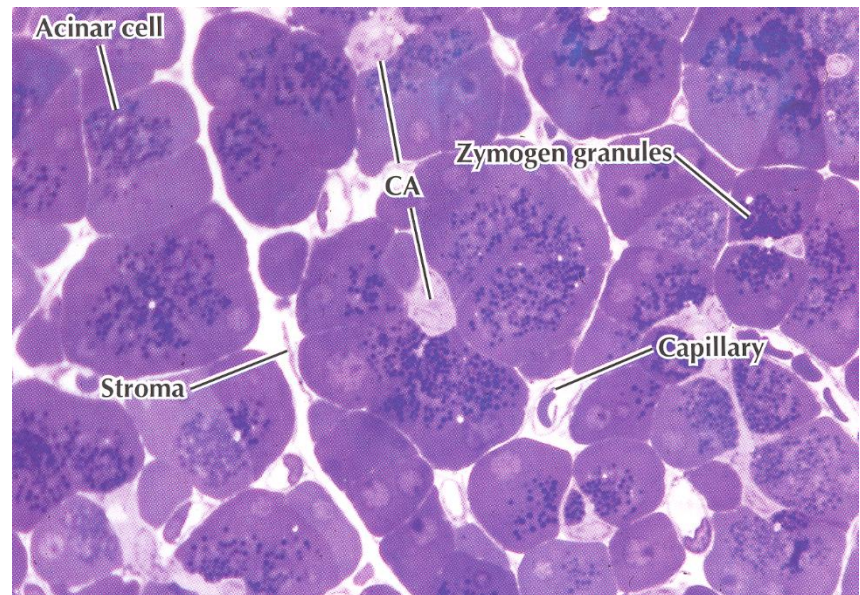
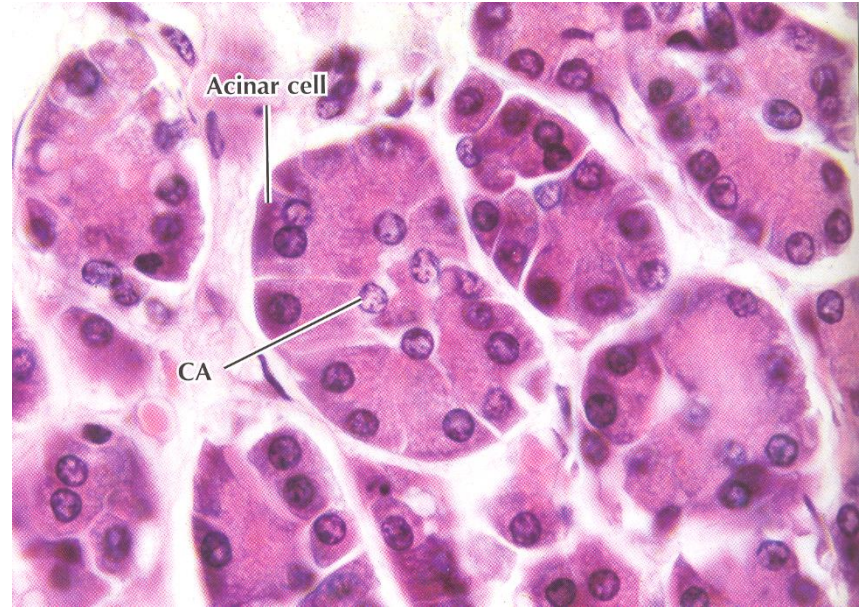
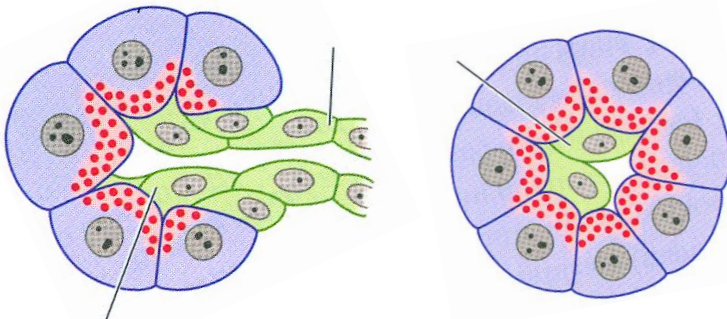
High magnification: acini, intercalated duct and zymogen granules



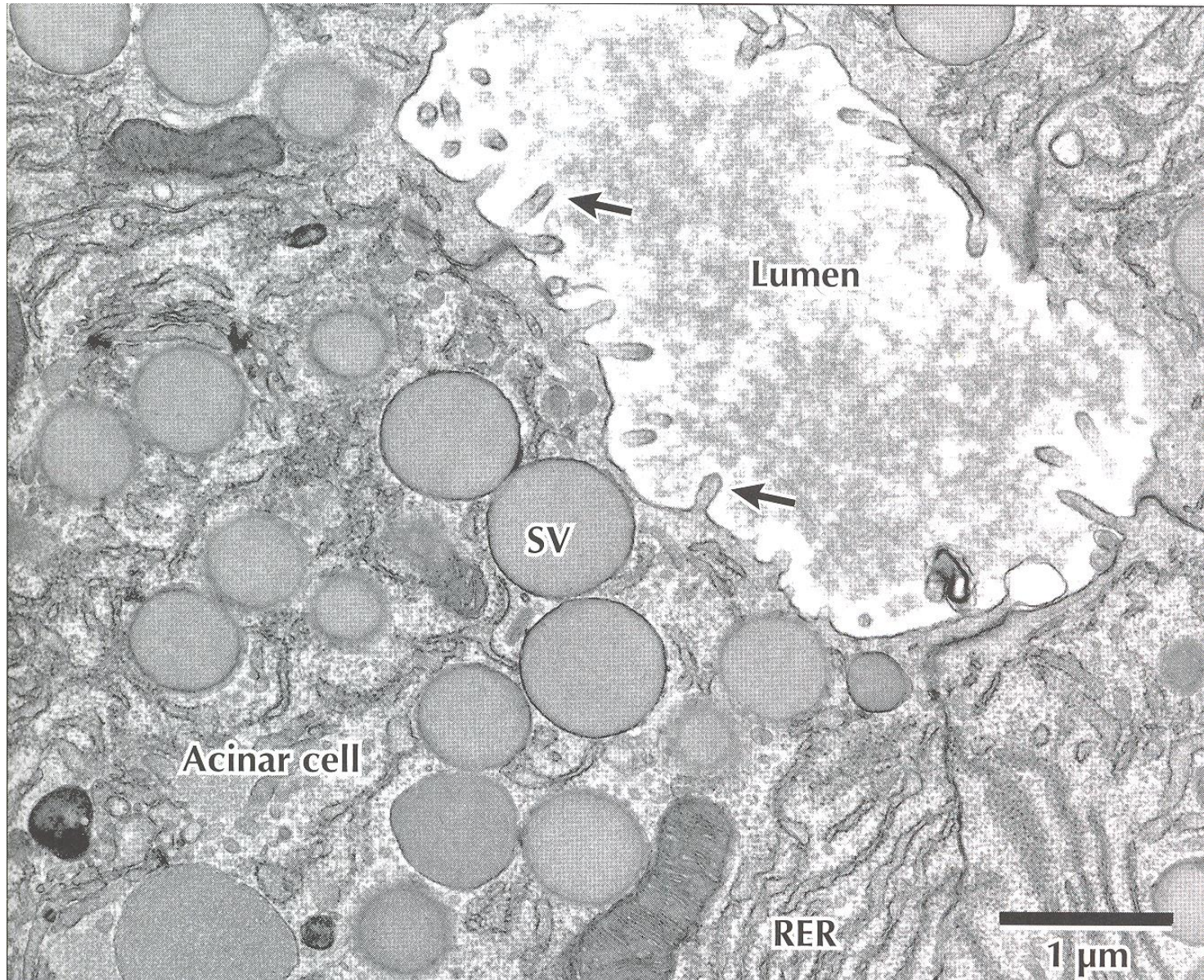
Pancreatic islet: A, B, and D cells. 1. Reticulum, 2. acini

# PANCREATIC ACINUS

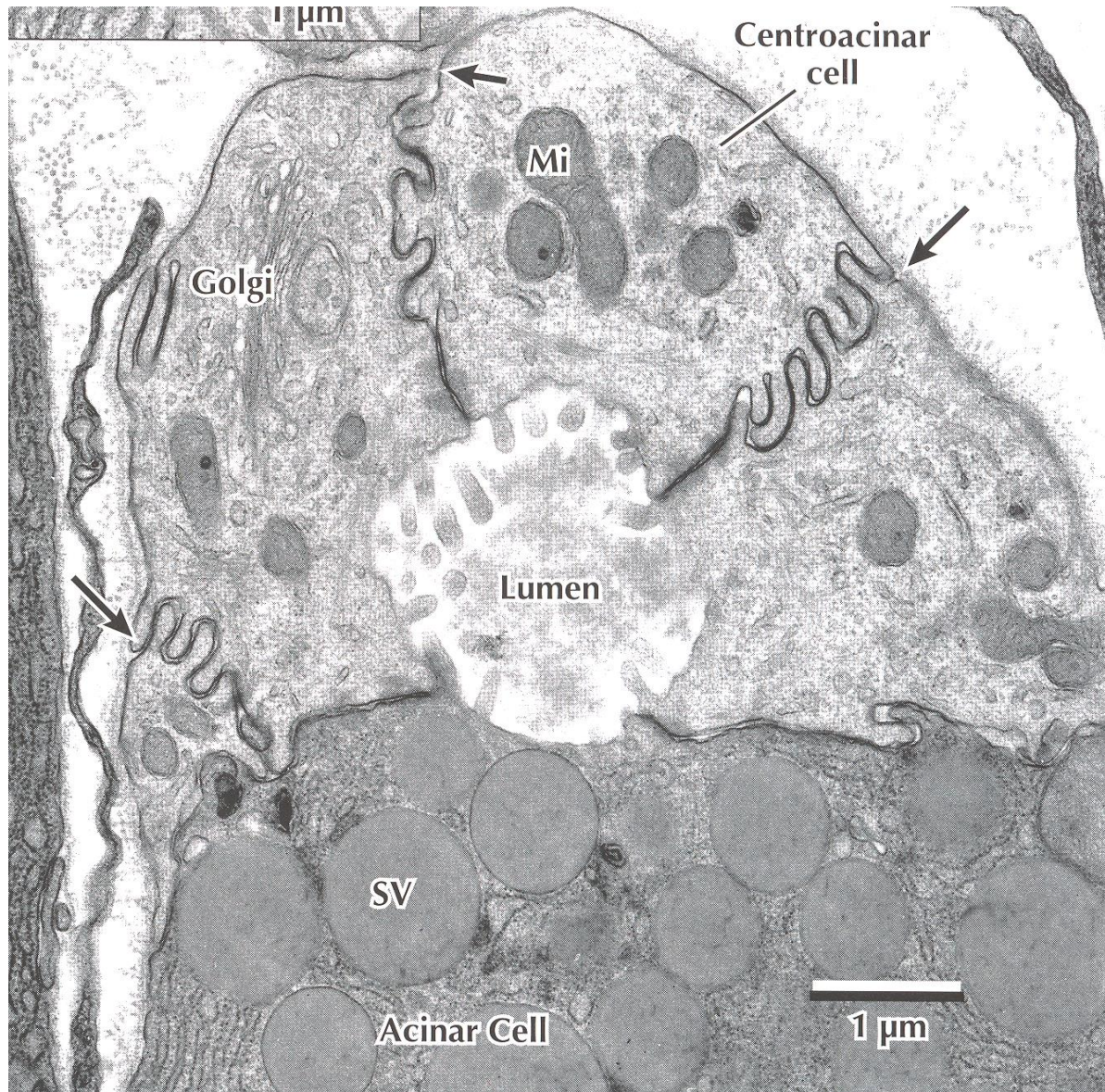
- Pyramidal epithelial cells
- Pancreatic digestive enzymes
- intercalated ducts
  
- Serous acinar cells
  - Polarized secretory cells
  - Basophilic
  - Apex – Golgi and zymogenic granules
  - Microvilli
  - Intercellular junctions
  
- Centroacinar cells
  - Centrally located nucleus, squamous character
  - Continuous with intercalated ducts



# PANCREATIC ACINUS

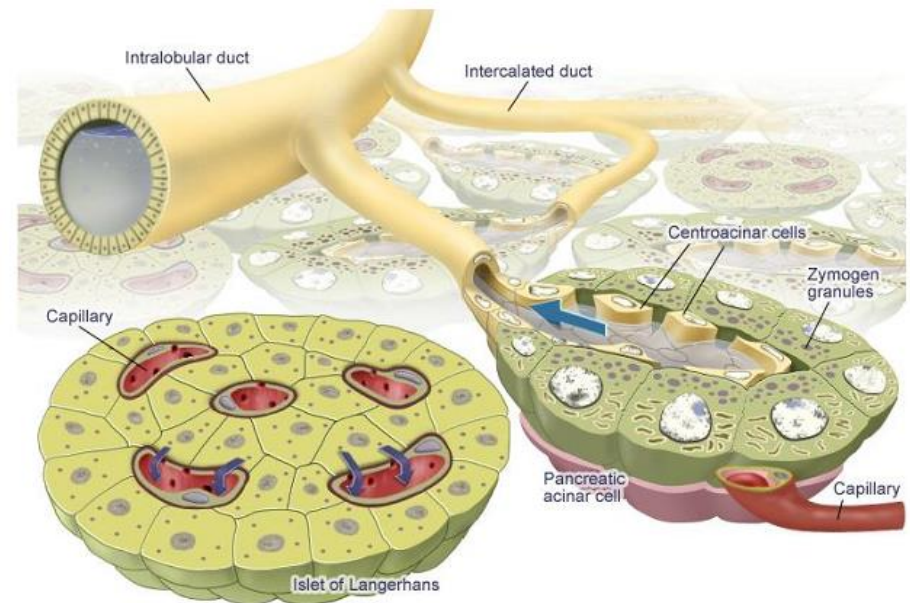
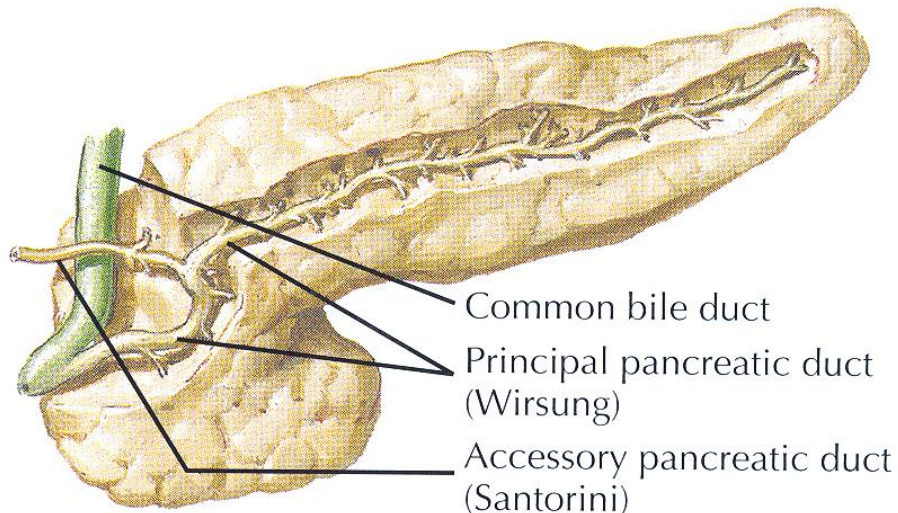


# PANCREATIC ACINUS



# PANCREATIC DUCTS

- Centroacinar cells
- Intercalated ducts
  - simple squamous epithelium + basal membrane
- Intralobular and interlobular ducts
  - simple cubic – low columnar epithelium
- Major pancreatic ducts
  - D. pancreaticus major – Wirsungi and D. pancreaticus accessorius - Santorini
  - bilayered columnar epithelium and dense collagen c.t.
  - intramural mucinous tubular glands, goblet cells, EC cells

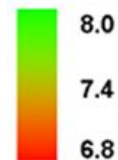
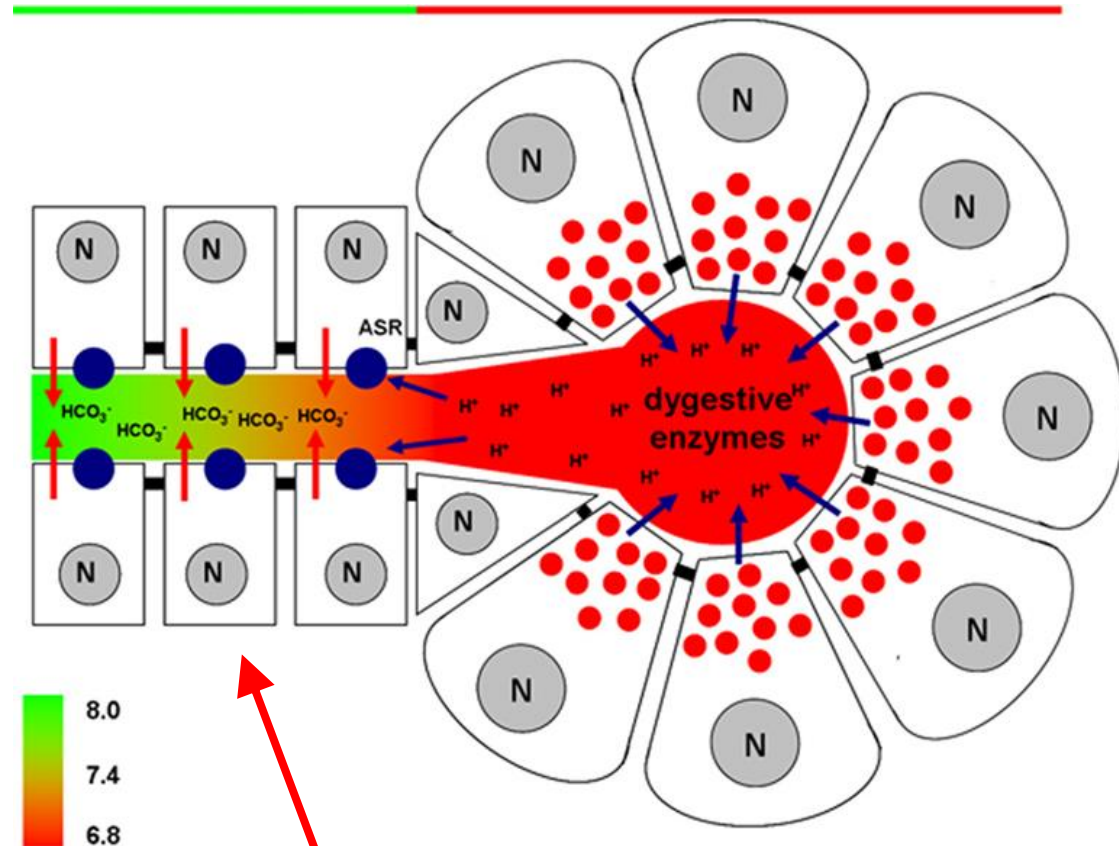
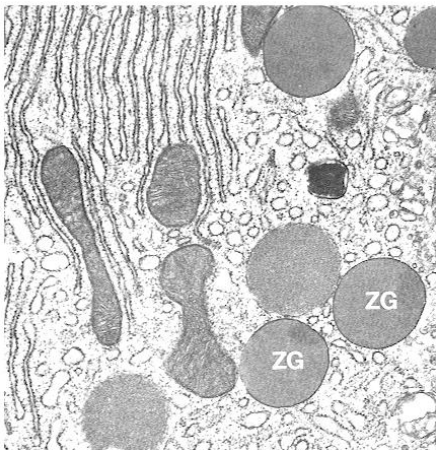


# EXOCRINE FUNCTION OF PANCREAS

- ca 1000-2000 ml daily
- alkalic pH (8.8),  $\text{HCO}_3^-$  (intercalated duct epithelium)
- mucin (epithelium of large ducts)

## Hydrolases

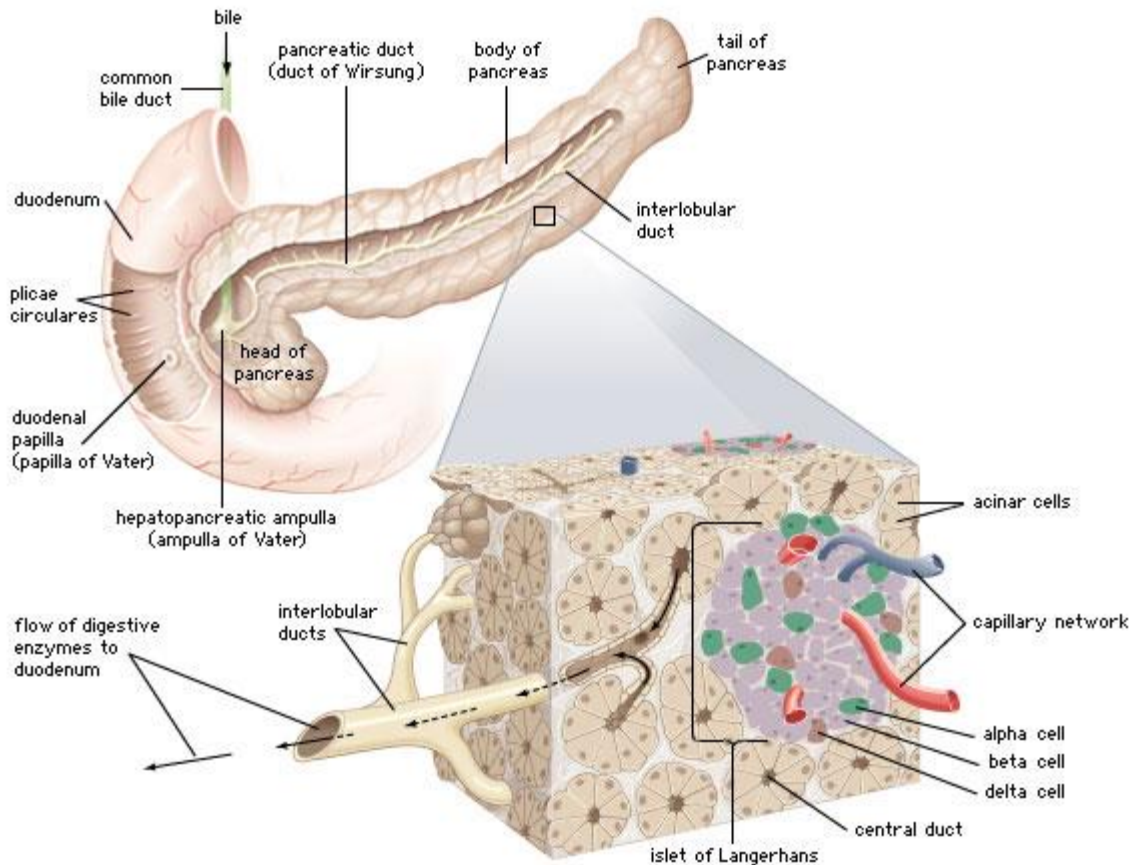
- Trypsinogen
- Chymotrypsinogen
- Proelastases
- Carboxypeptidases
- Pancreatic lipase
- Amylases
- ...



Hormonal regulation (secretin, cholecystkinin) + parasymphatikus



# ENDOCRINE FUNCTION OF PANCREAS



## Glucagon

- Glycogen consumption in tissues and muscles
- Increase of blood glucose

## Insulin

- Increase of membrane permeability for glucose
- Glucose oxidation in tissues
- Decrease of blood glucose
- Synthesis of glucan in muscles and liver

## Pancreatic polypeptide

- Autoregulation of pancreatic secretion

## Somatostatin

- Inhibition of GIT hormones

# ISLETS OF LANGERHANS

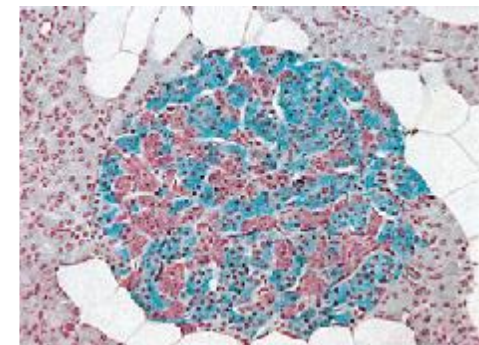
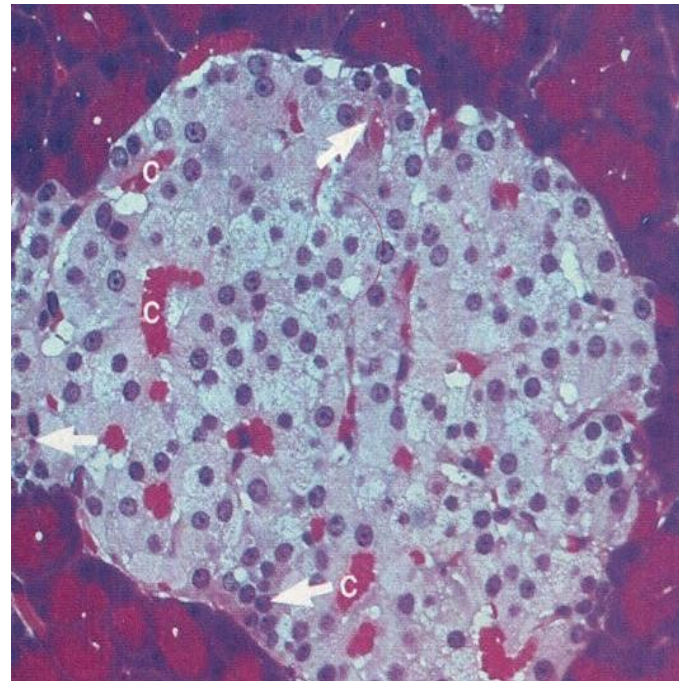
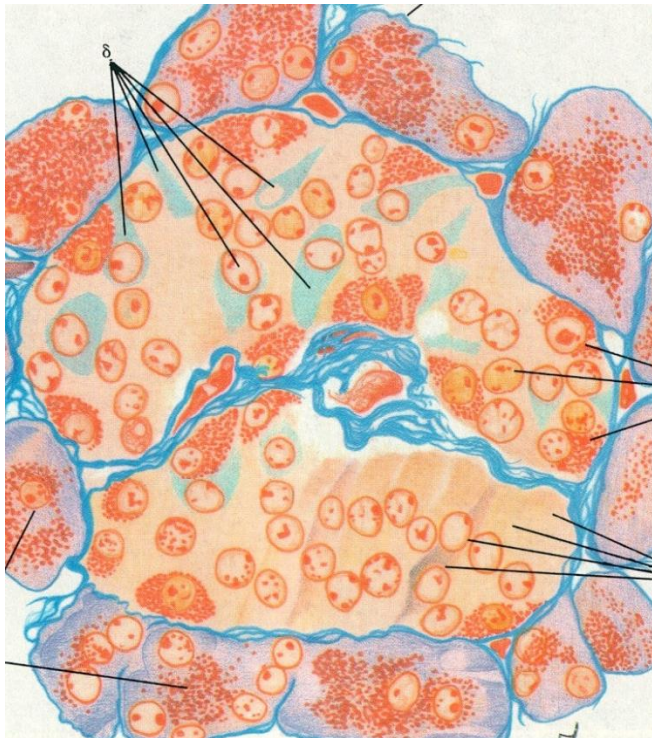
- Clusters of pale cells
- ca  $1,5 \times 10^6$
- Thin c.t. capsule
- Cords of epithelial cells
- Sinusoids
- General characteristics of APUD cells
- A, B, D, PP cells

A cells: 20%, glucagon

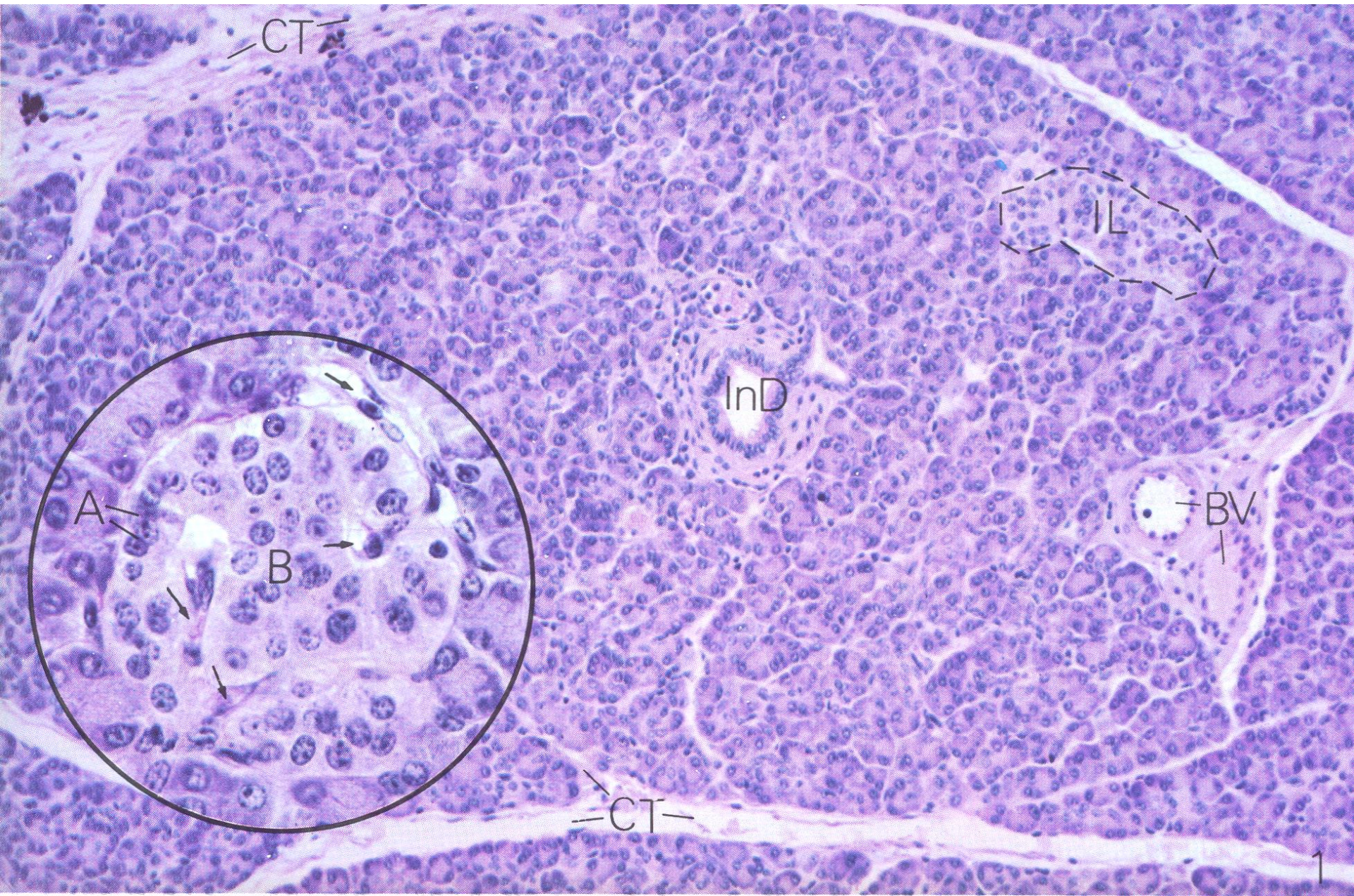
B cells: 60-70%, insulin

D cells: minor, somatostatin

PP cells: minor, pancreatic polypeptide

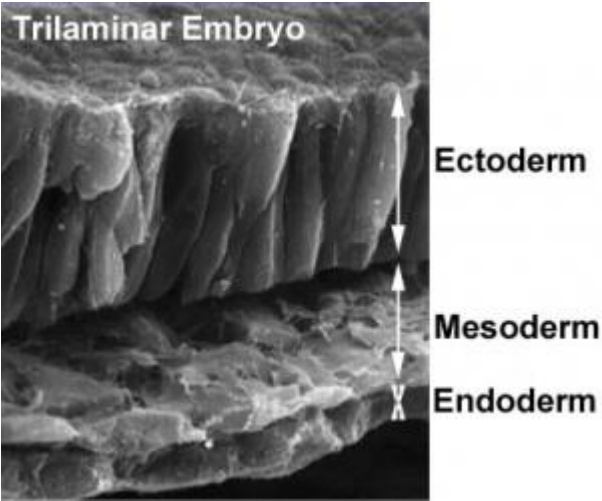
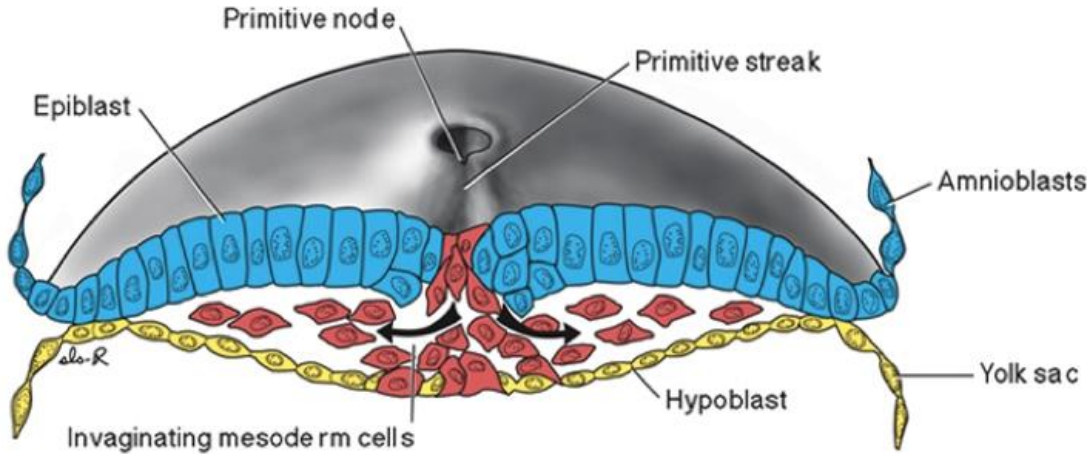
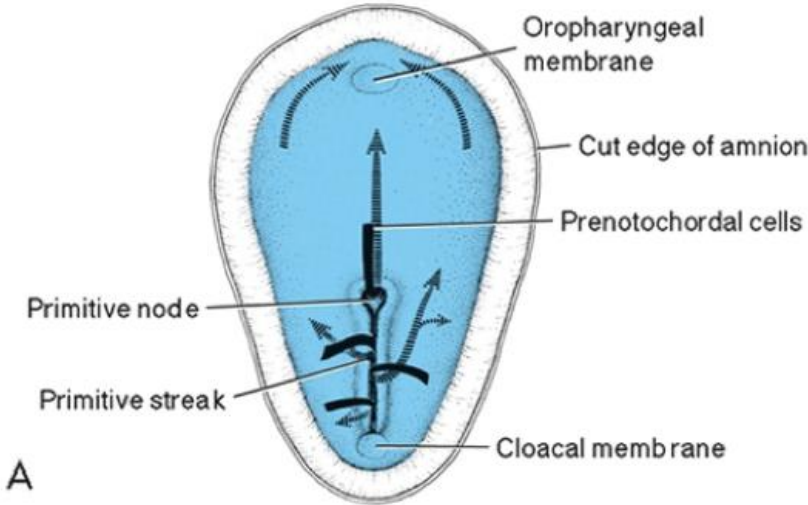


# ISLETS OF LANGERHANS

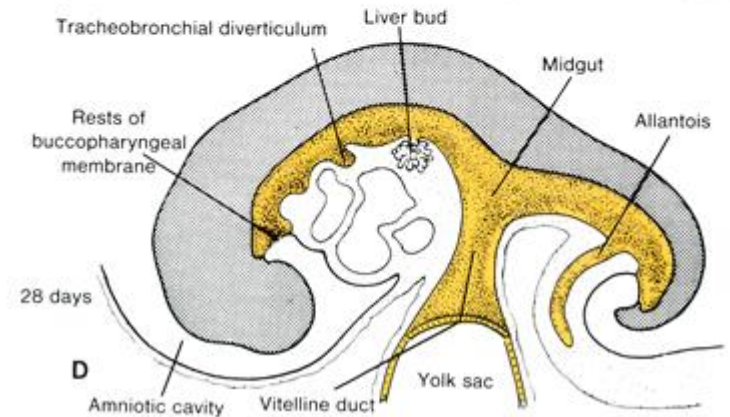
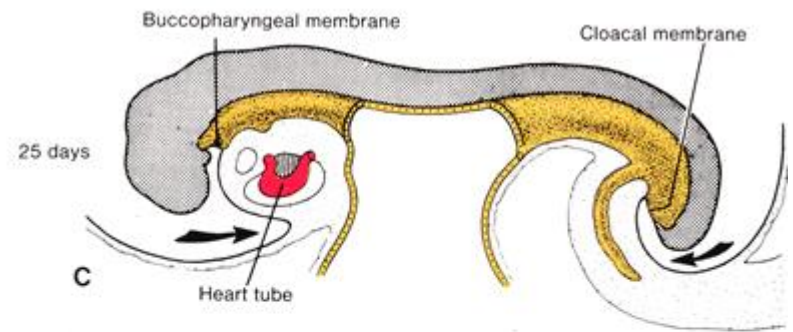
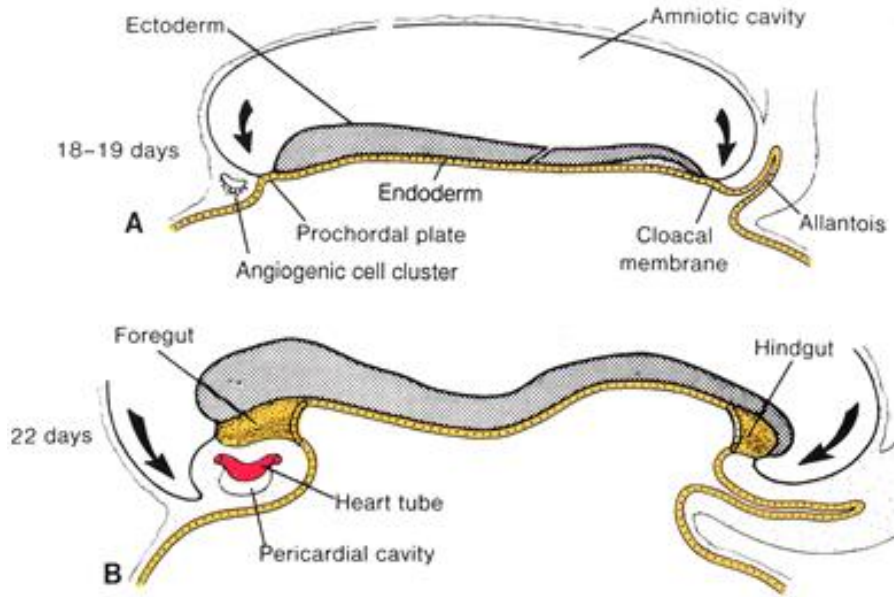


# DEVELOPMENT OF GIT

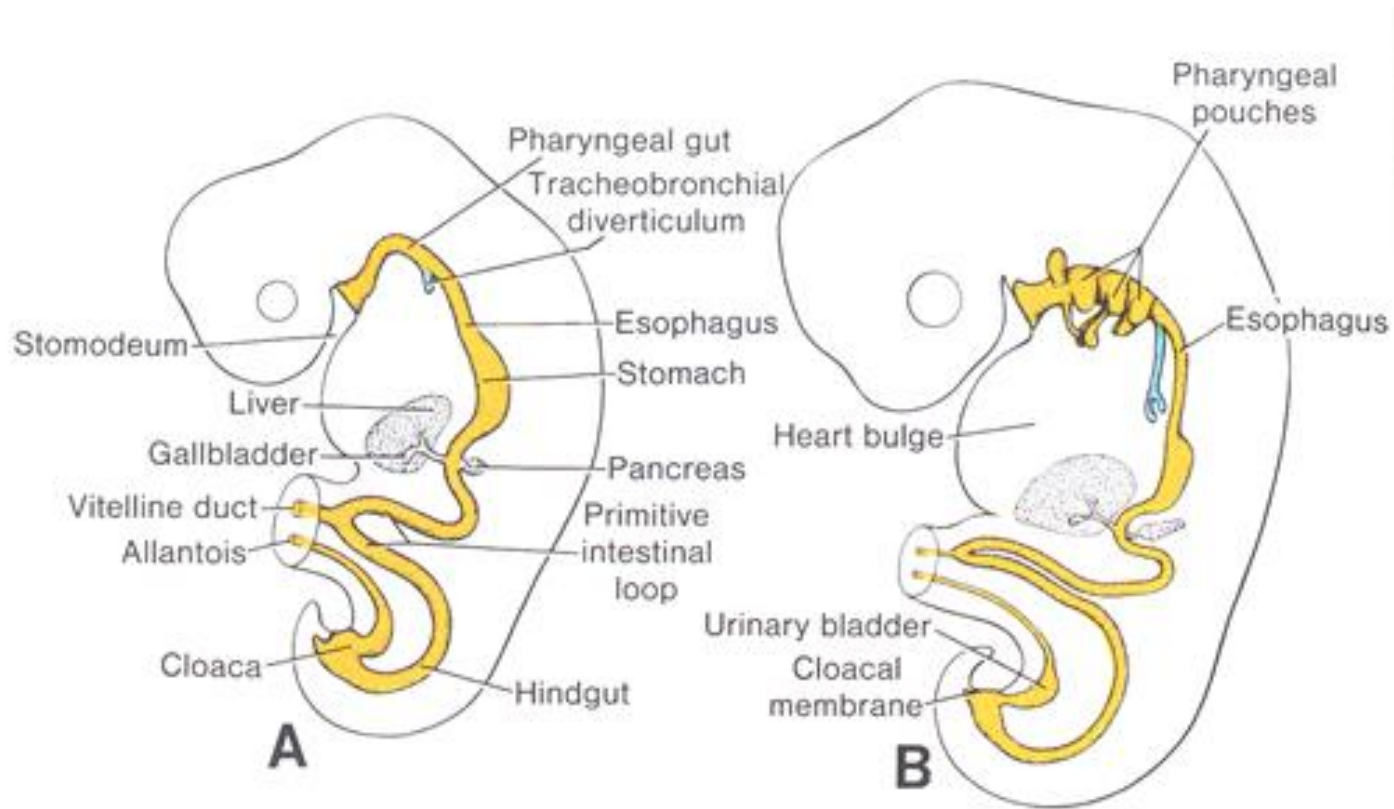
# EMBRYONIC DEVELOPMENT 2<sup>TH</sup> TO 3<sup>RD</sup> WEEK



# EMBRYONIC DEVELOPMENT 3<sup>RD</sup> TO 4<sup>TH</sup> WEEK



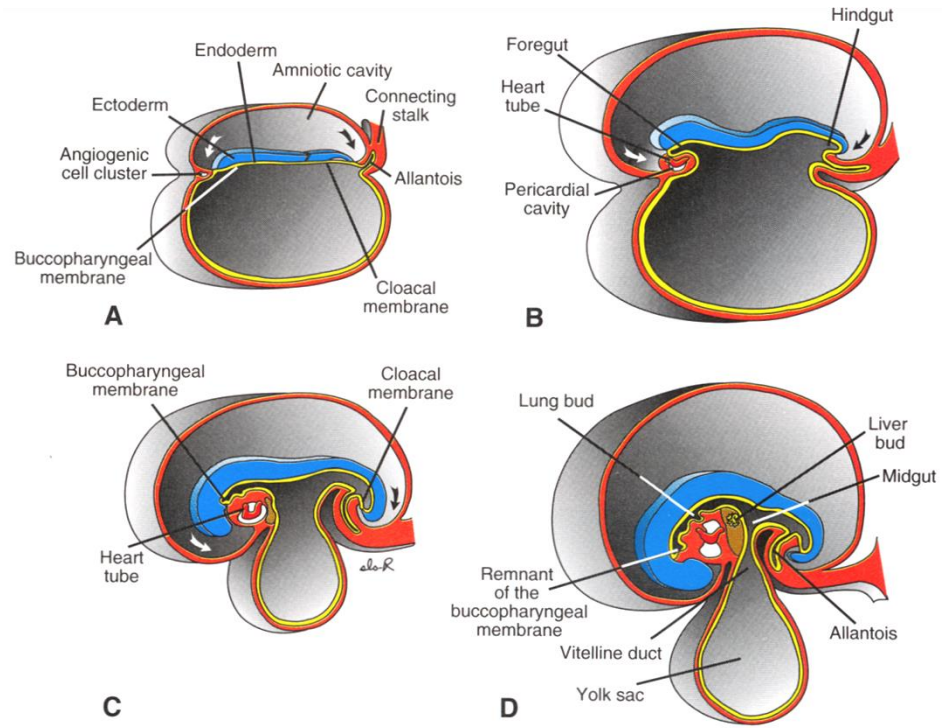
# 4<sup>TH</sup> AND 5<sup>TH</sup> WEEK OF EMBRYONIC DEVELOPMENT



# DEVELOPMENT OF PRIMITIVE GUT

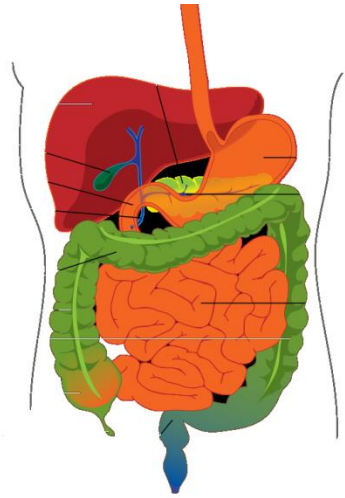
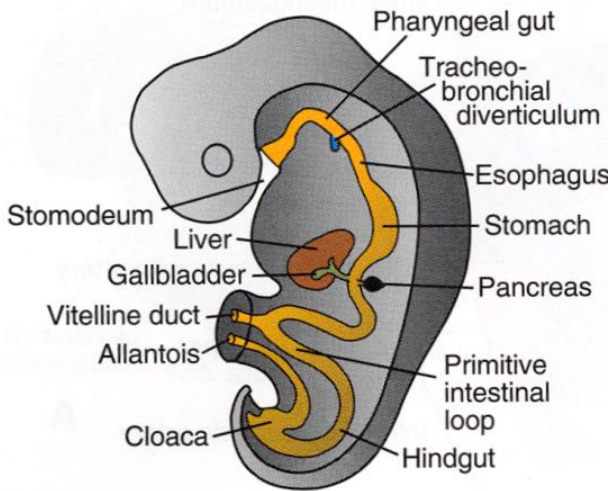
– cephalocaudal and lateral folding in 4<sup>th</sup> week

– primitive gut from buccopharyngeal membrane to cloacal membrane



## Three regions of primitive gut

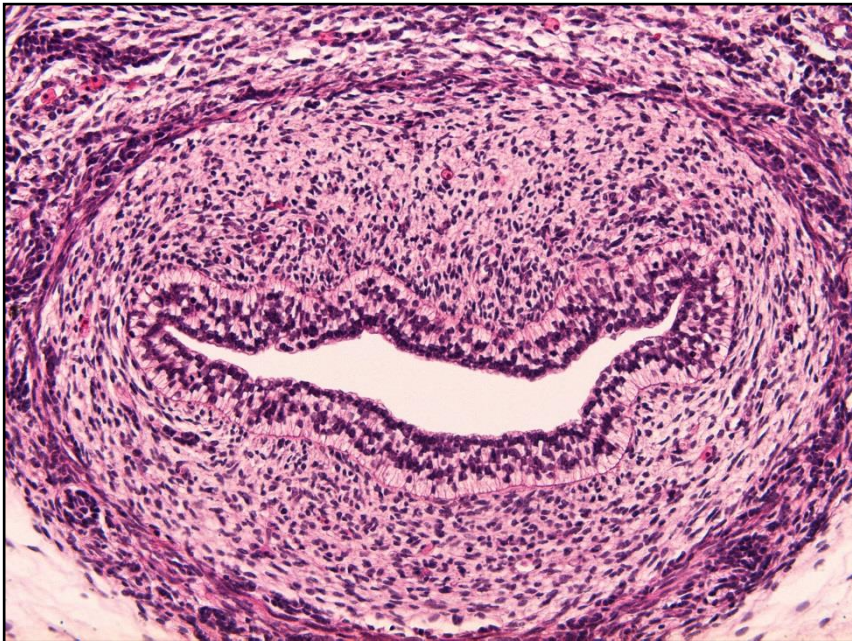
- foregut
- midgut
- hindgut



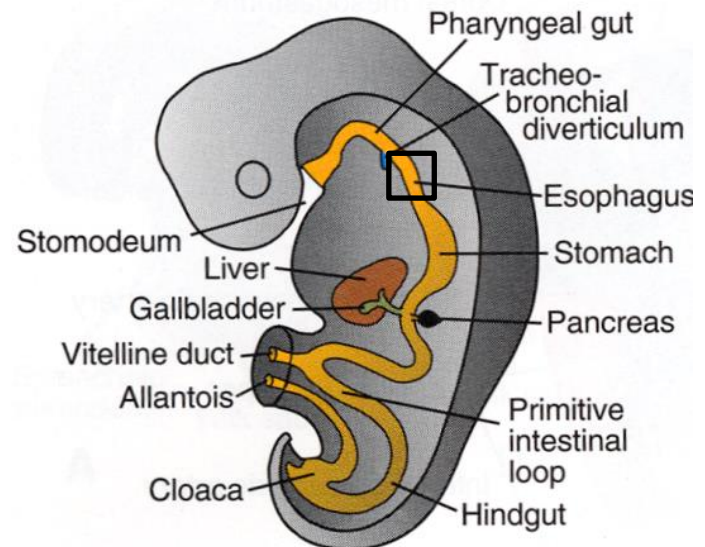


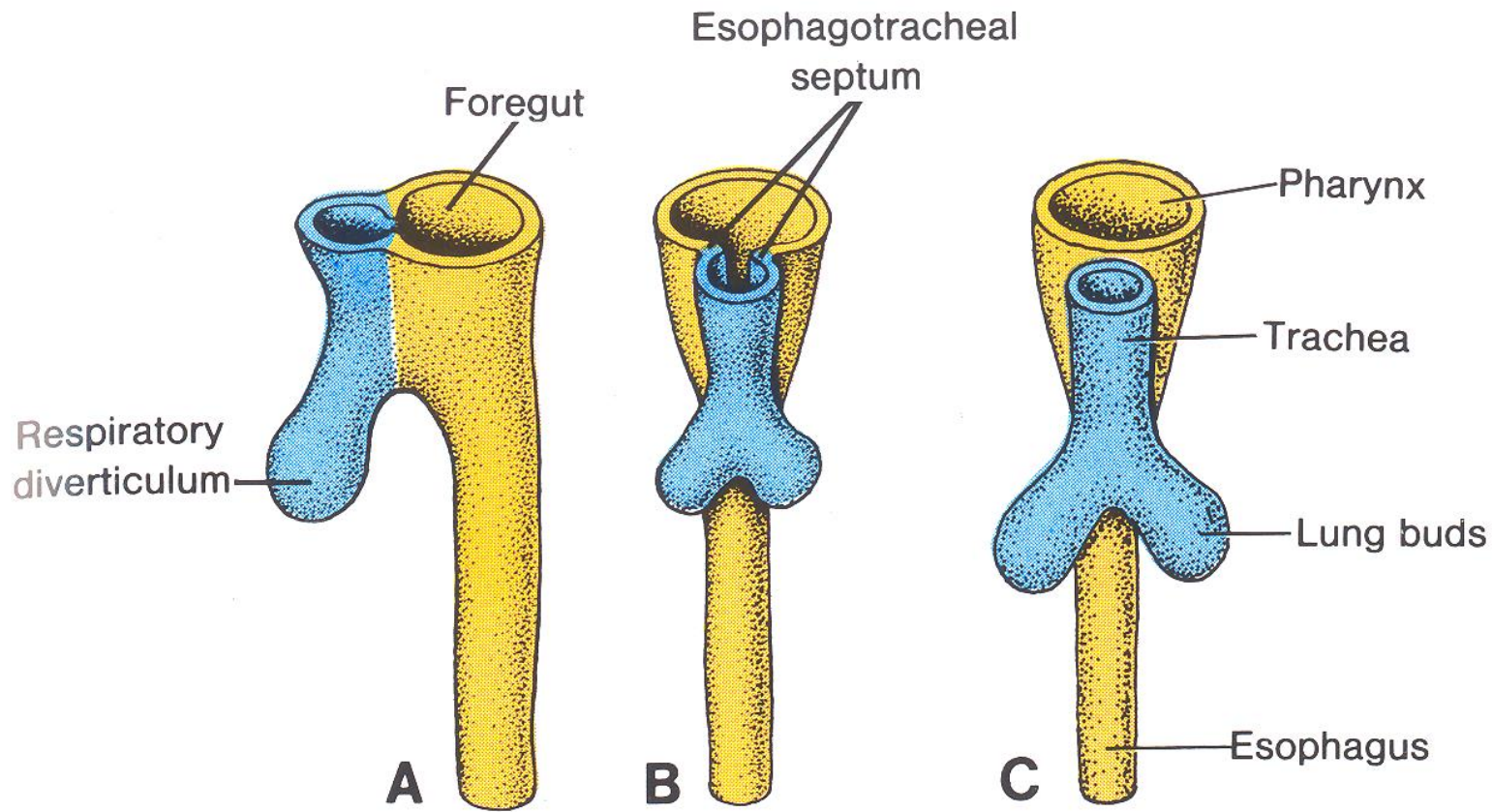
# DEVELOPMENT OF ESOPHAGUS

- region of foregut caudal of respiratory diverticulum
- tracheoesophageal septum
- rapid elongation: 7<sup>th</sup> week - final relative length
- rapid proliferation of endoderm (epithelium and glands) that obliterates lumen – recanalization about 8<sup>th</sup> week
- connective tissue and muscle tissue – mesenchyme of caudal pharyngeal arches and splanchnic mesenchyme
- innervation by branches of *n. vagus* (caudal pharyngeal arches)

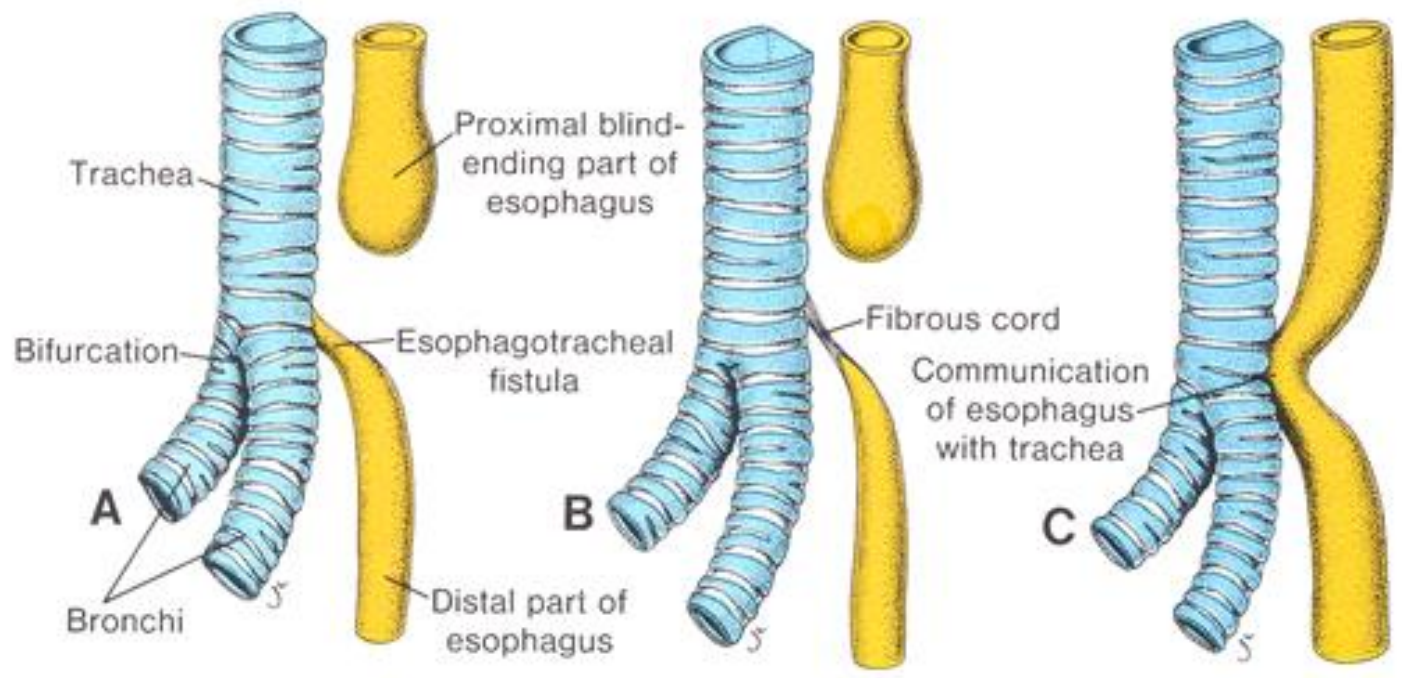


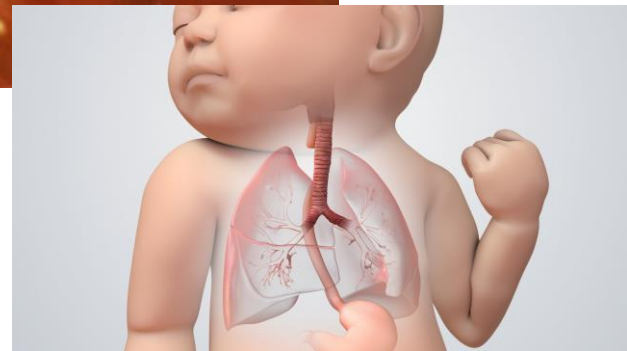
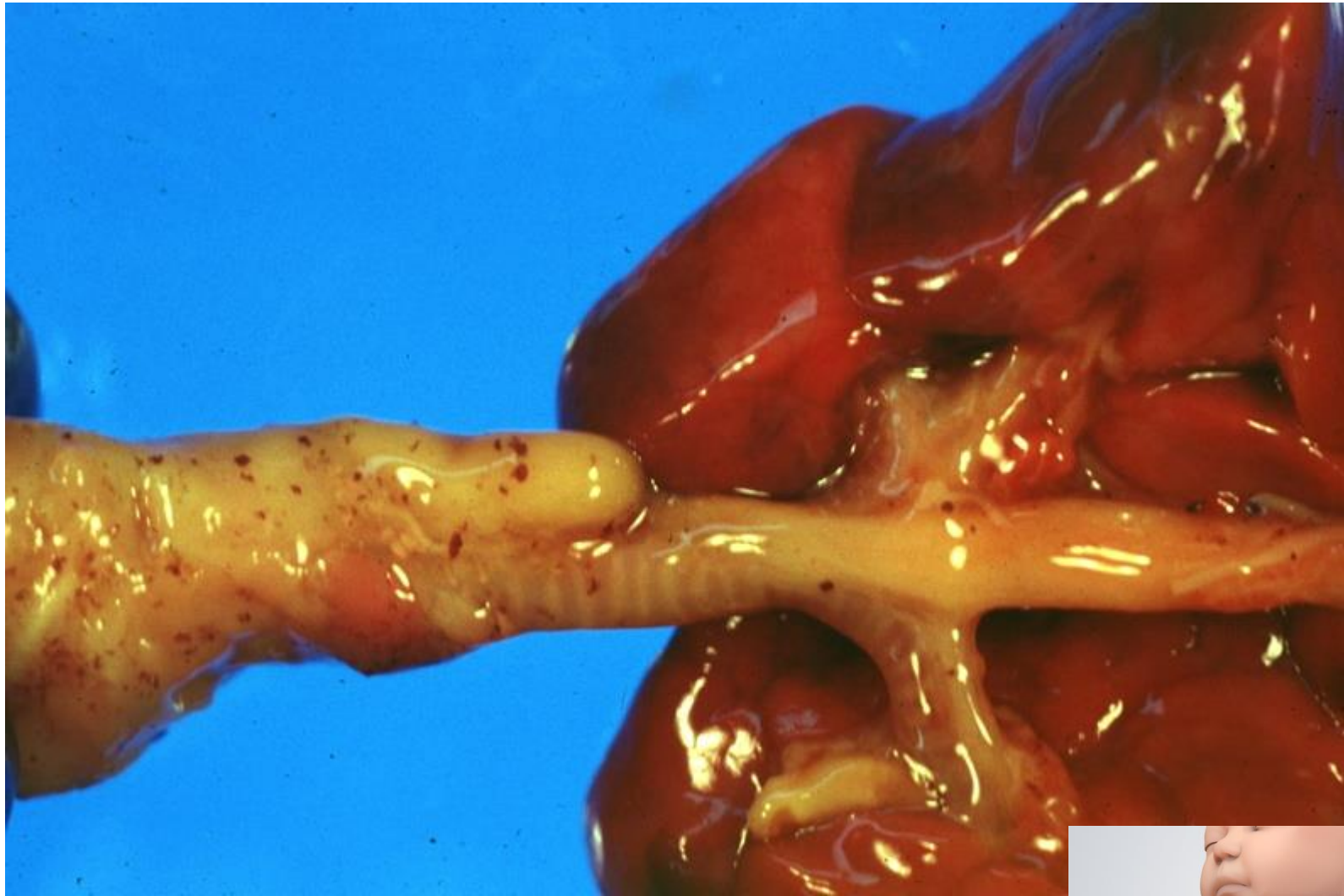
8<sup>th</sup> week





# ABNORMALITIES IN DEVELOPMENT OF ESOPHAGUS

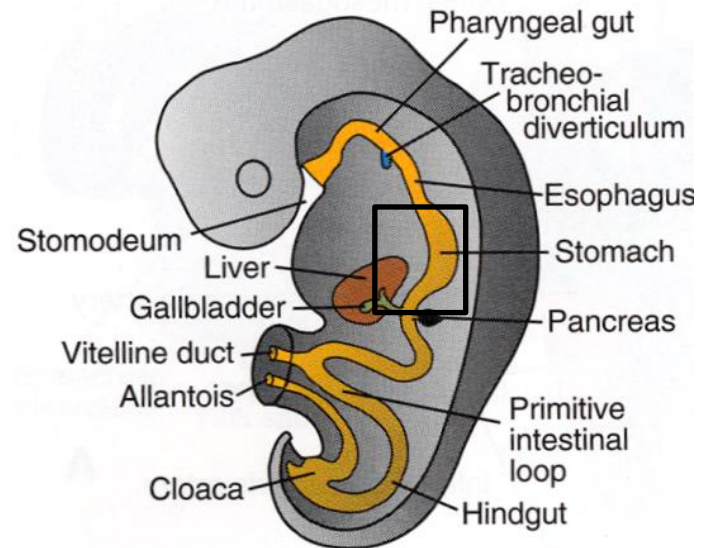
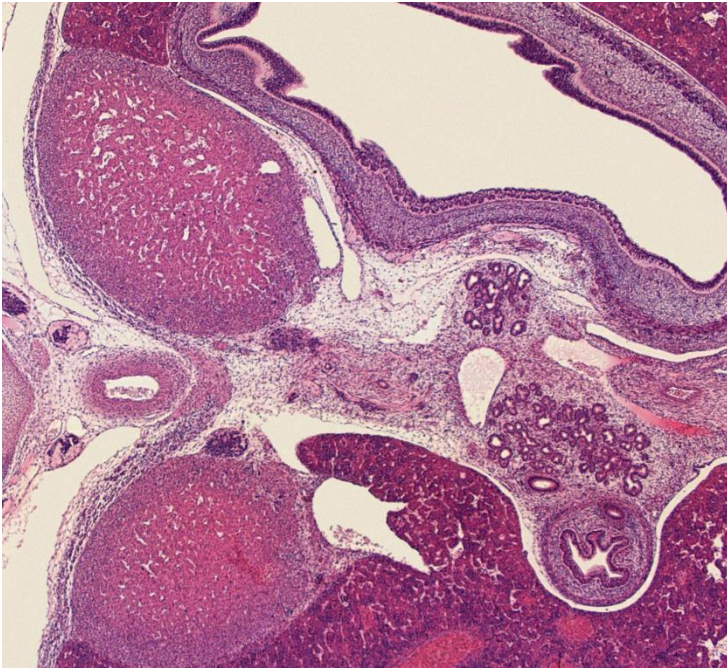




# DEVELOPMENT OF STOMACH

- fusiform dilatation of the foregut
- different growth rates in various regions → greater and lesser curvature
- rotation 90° clockwise around longitudinal and anteroposterior axis
- definitive location and shape - 2<sup>nd</sup> month i.u.

## 8<sup>th</sup> week

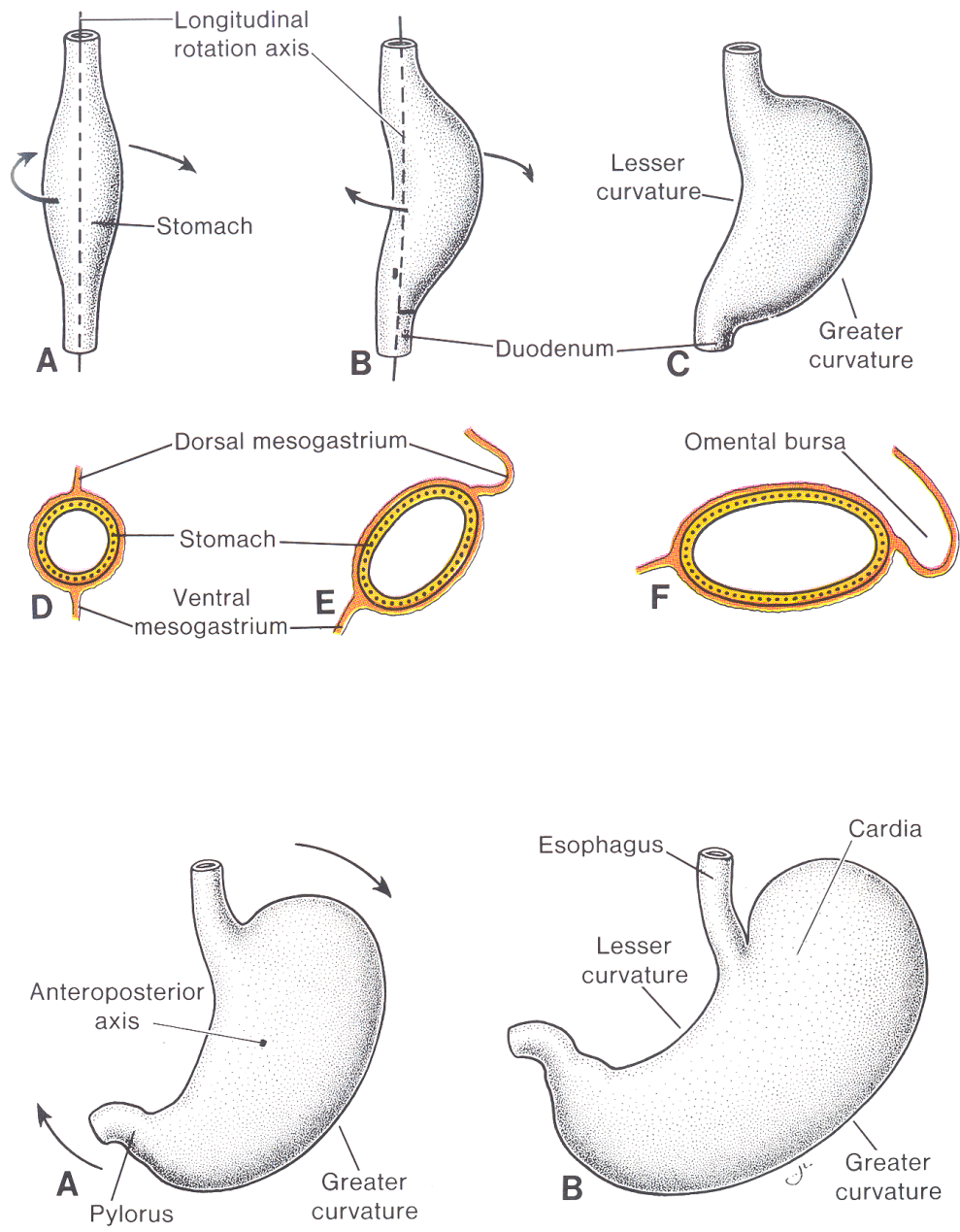


# STOMACH ROTATION

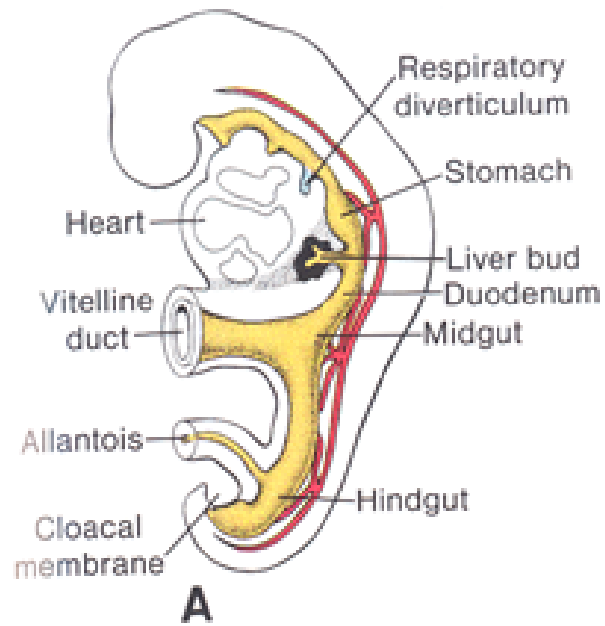
- 90°

ventral lesser curvature → right  
 dorsal greater curvature → left  
 left side → ventrally  
 right side → dorsally  
 cranial part → left caudally  
 caudal part → right cranially

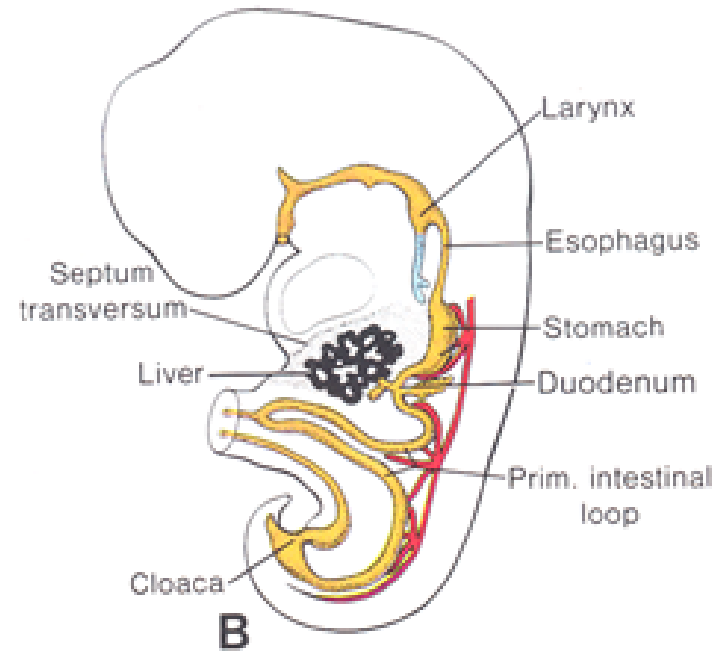
→ definitive anatomical position of  
 left and right *nervus vagus*



**WEEK cca 4th**



**5th**



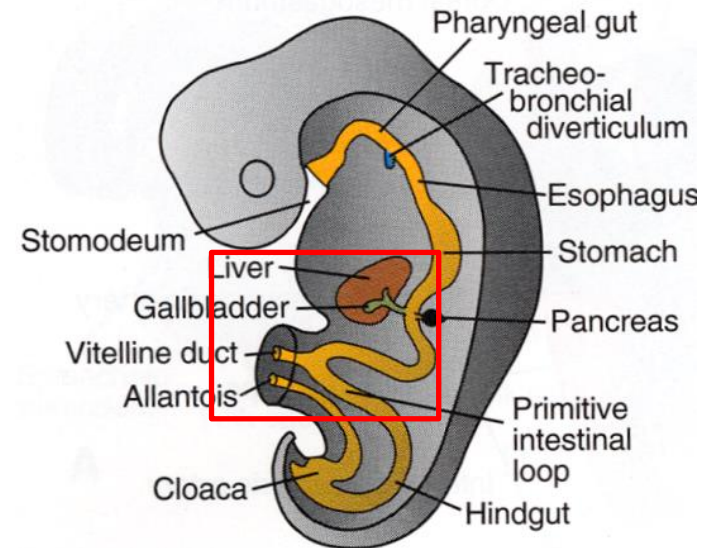
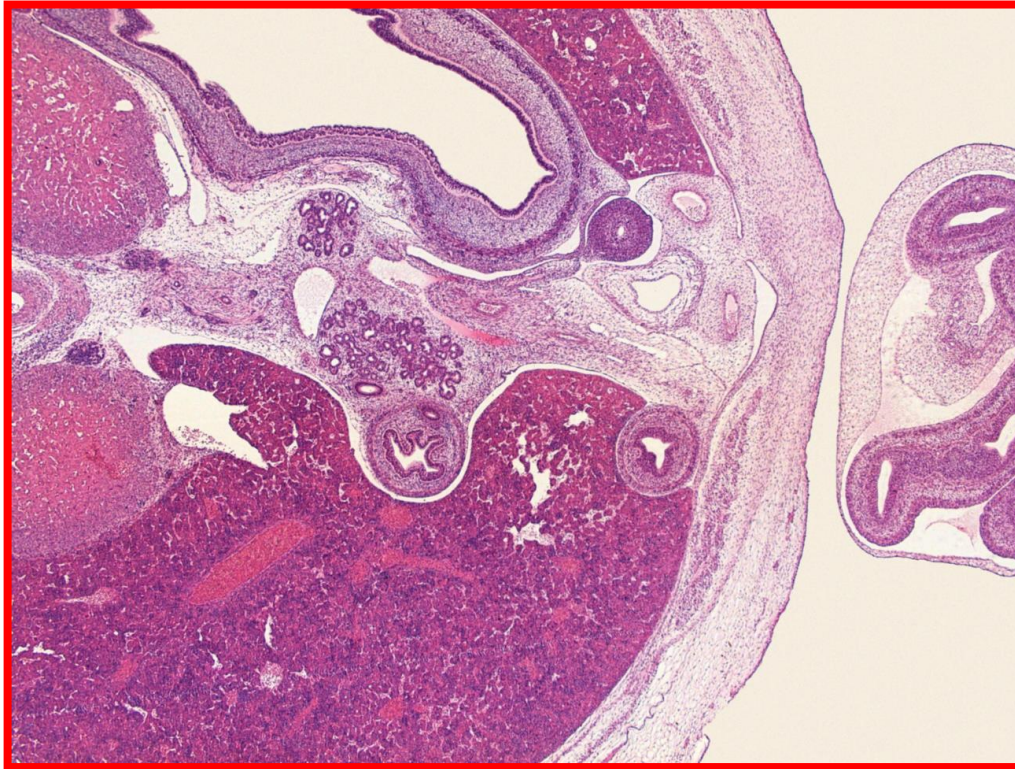
**EMBRYO SIZE 3 mm**

**5 mm**

# DEVELOPMENT OF INTESTINE

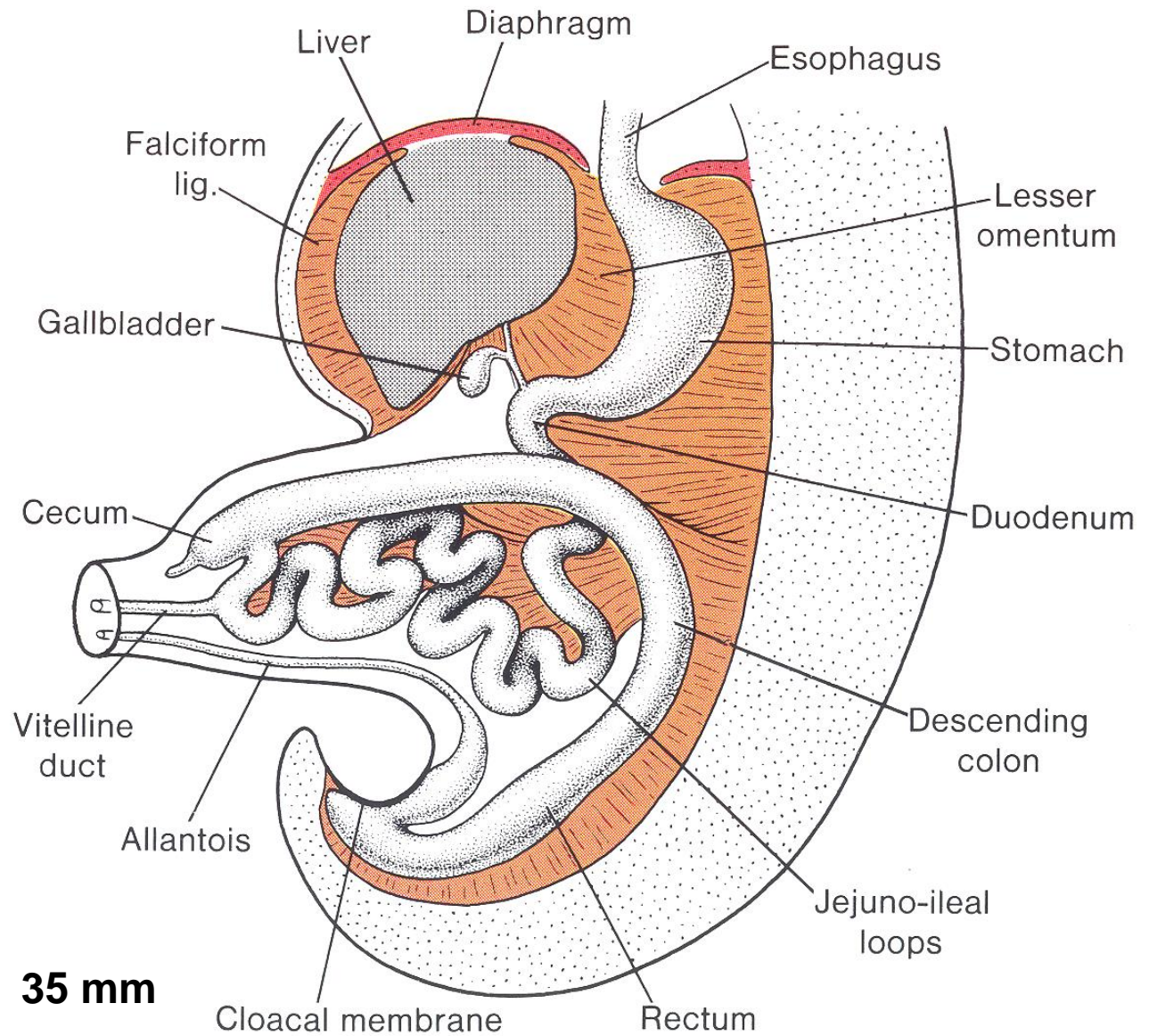
- midgut – primary intestinal loop
- rotation during development
- physiological umbilical herniation

**8<sup>th</sup> week**



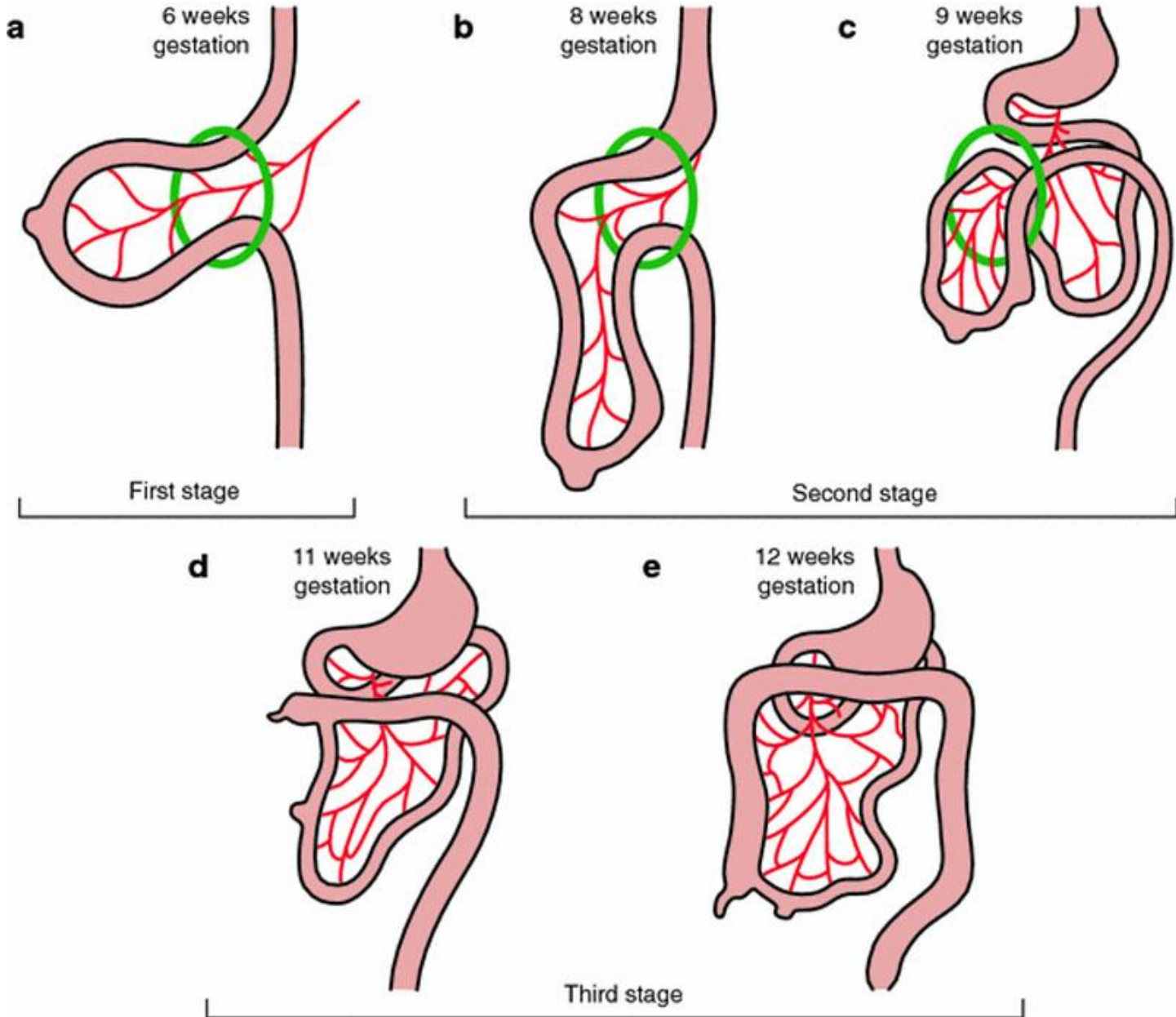


**WEEK: late 8th**

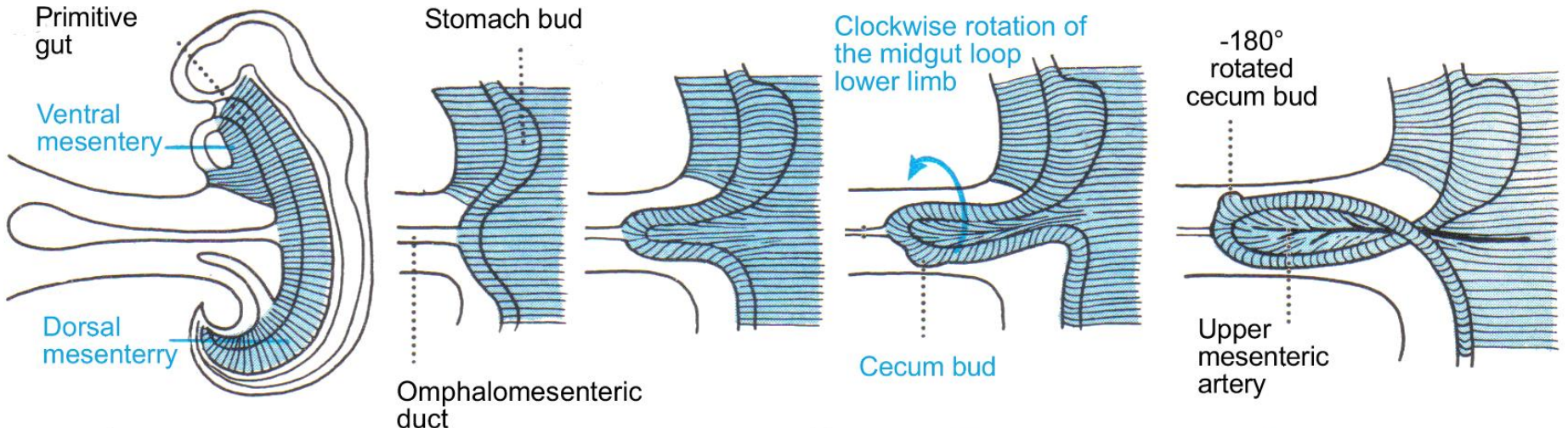


**EMBRYO SIZE 35 mm**

# INTESTINAL ROTATION

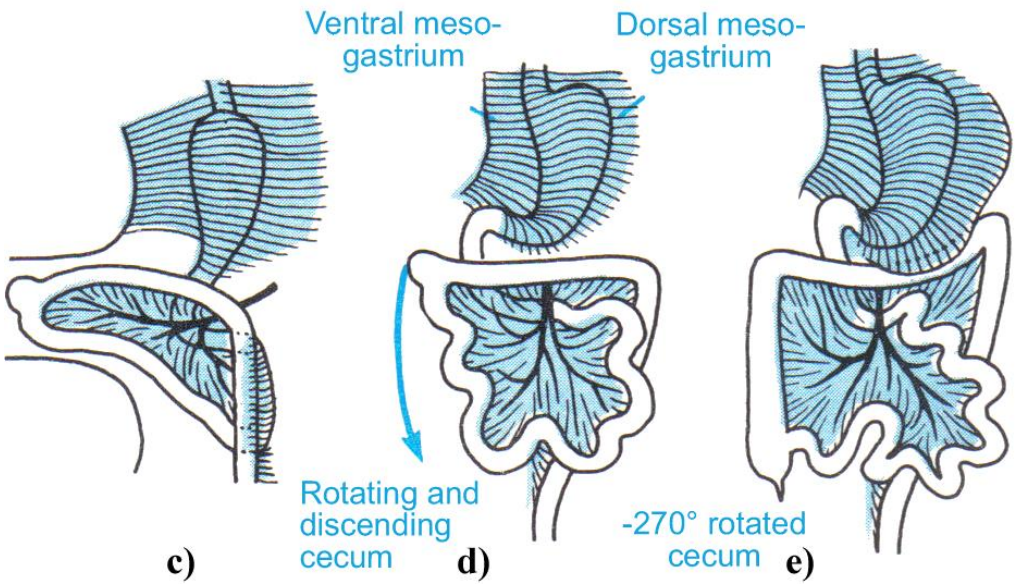


# INTESTINAL ROTATION AND ROTATION OF MESENTERIES



a)

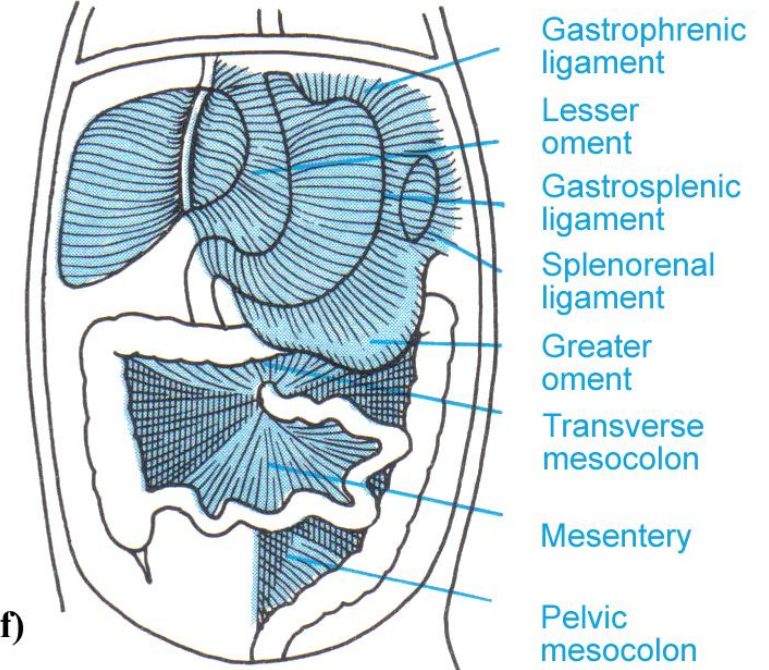
b)



c)

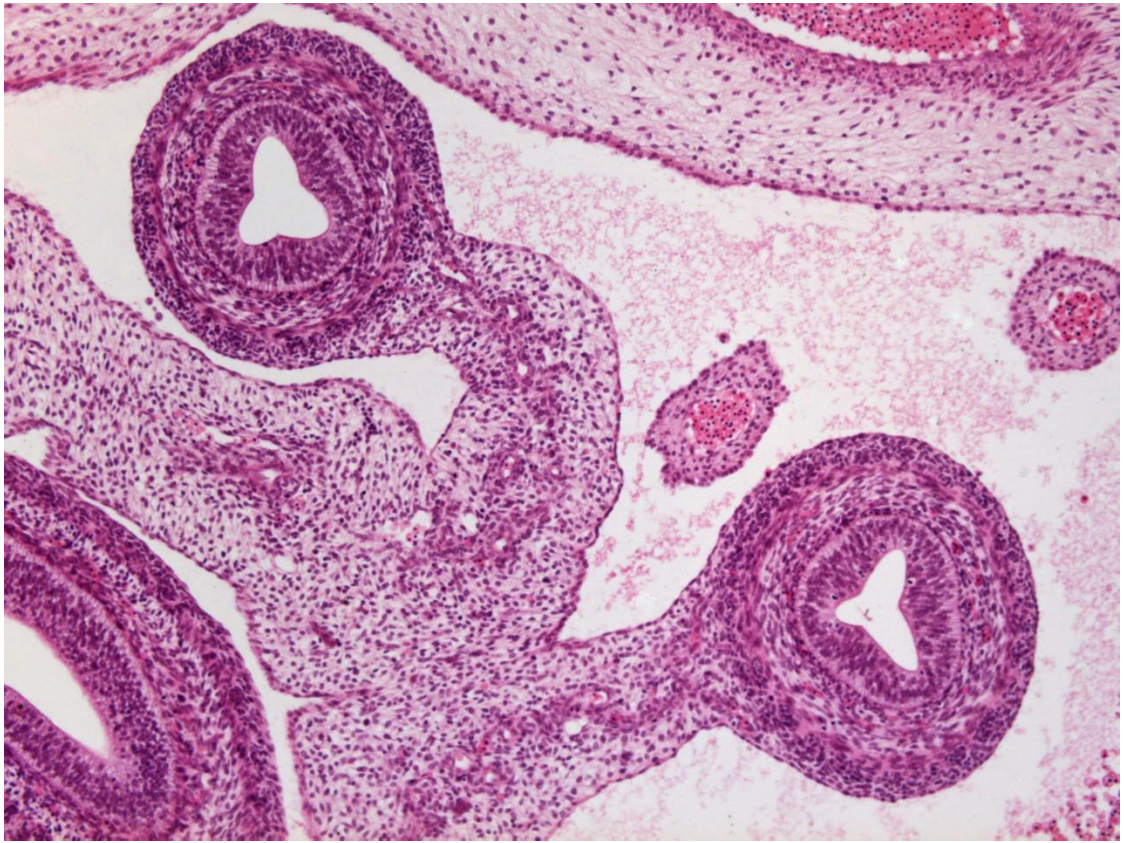
d)

e)



f)

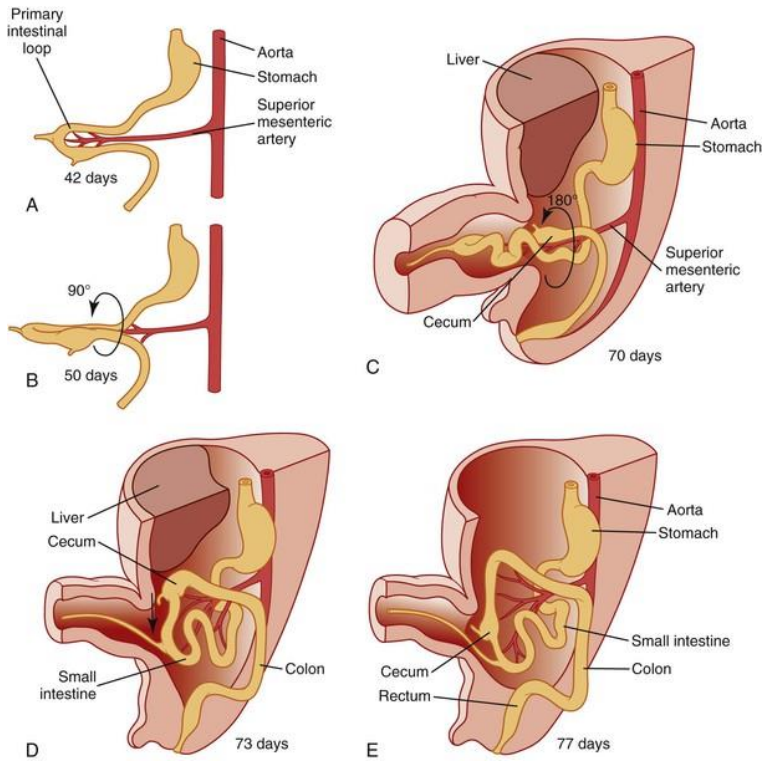
# INTESTINAL ROTATION AND UMBILICAL HERNIA



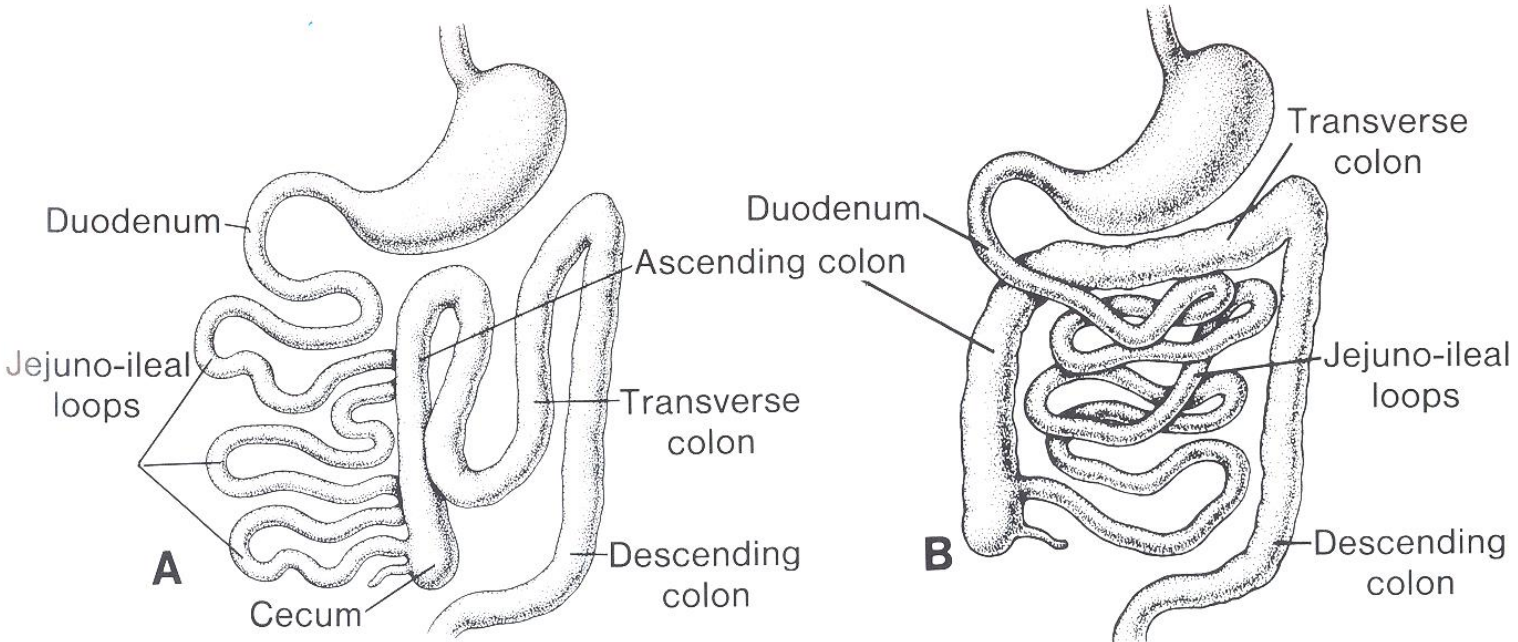
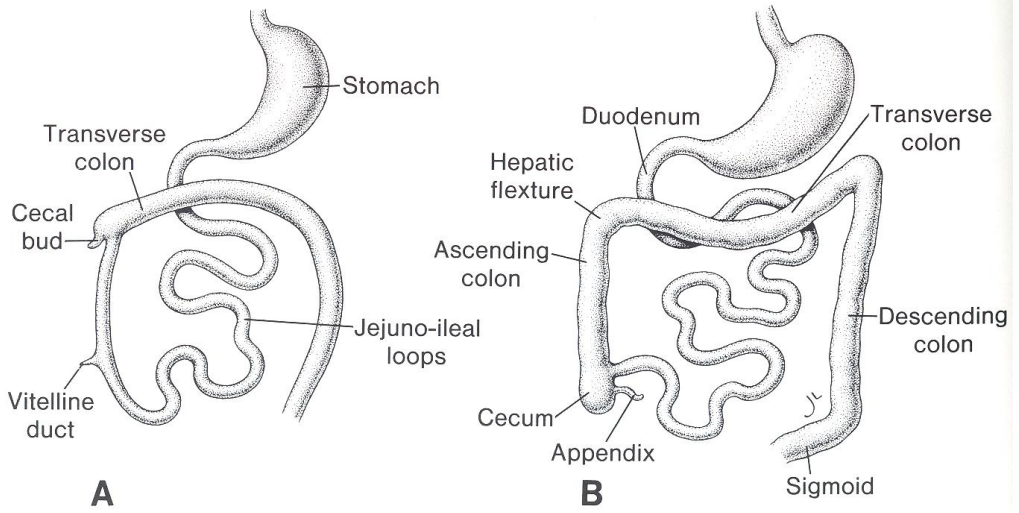
- 8th week
- Normal reposition in 10th week

### Abnormalities:

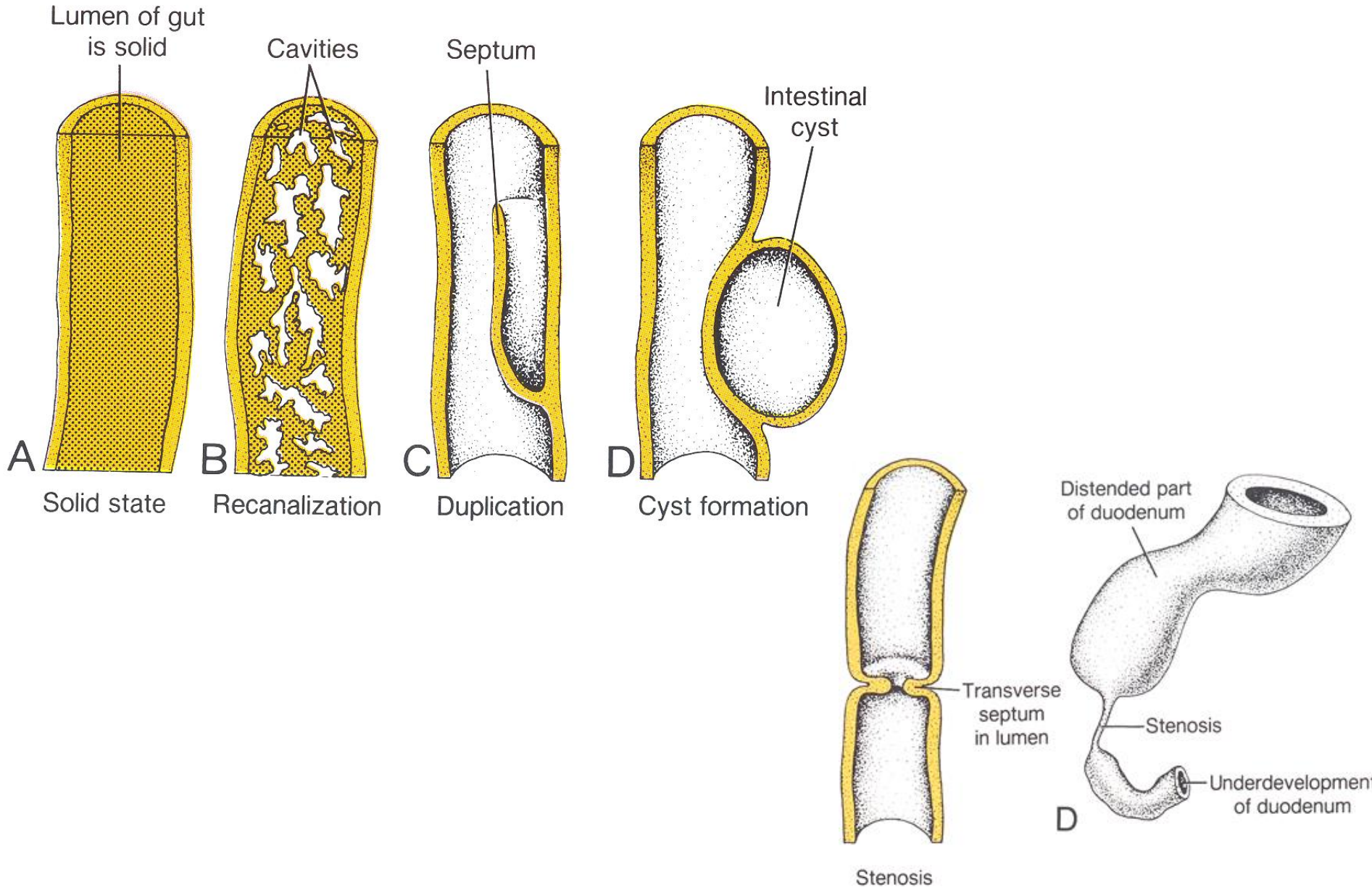
- Incomplete closure of umbilicus
- Including omentum majus and small intestine, skin and connective tissue
- Develops after birth, spontaneous reposition possible (X gastroschisis)



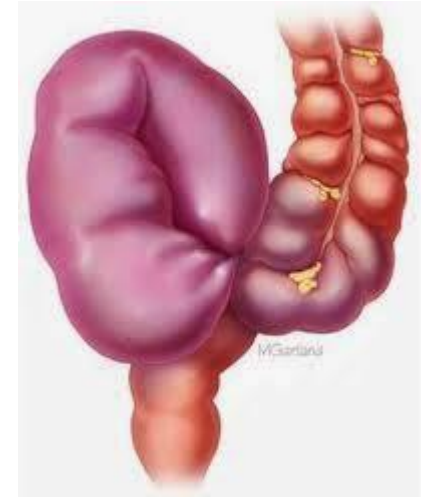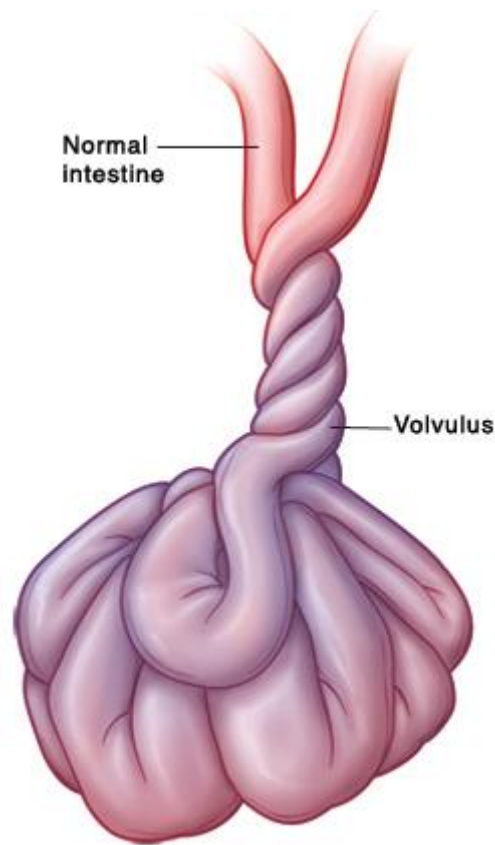
# ABNORMAL INTESTINAL ROTATION



# ILEUM DEVELOPMENT AND ABNORMALITIES

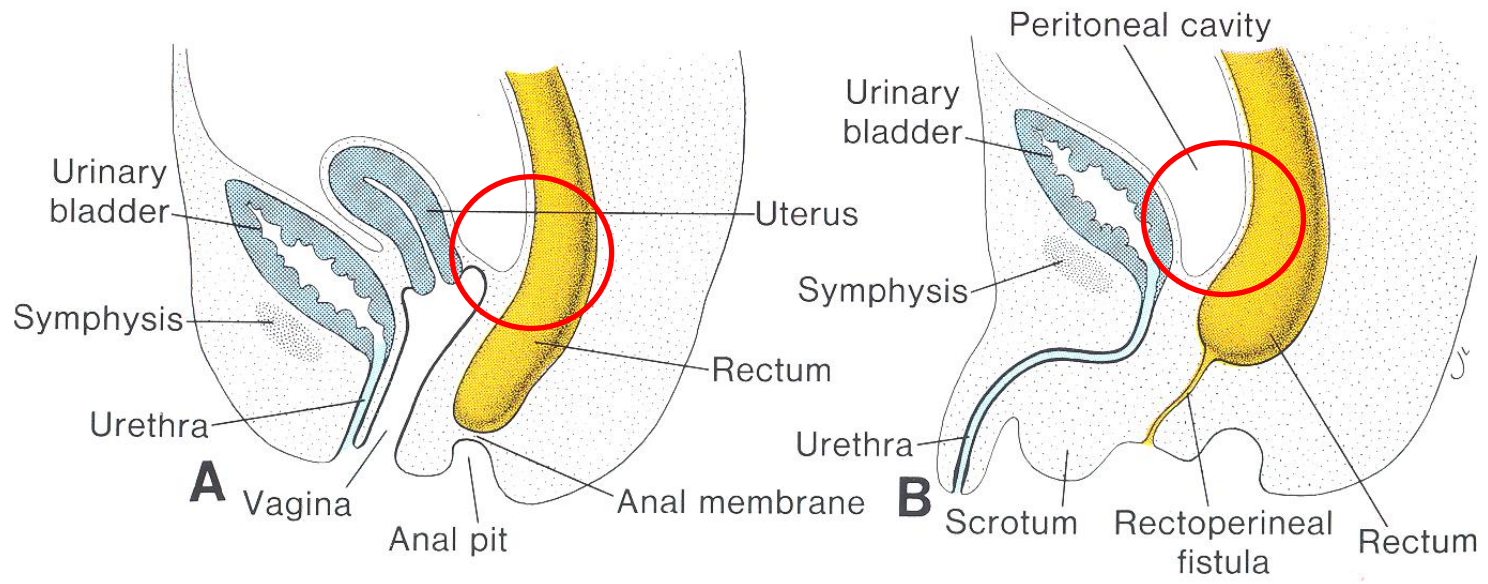
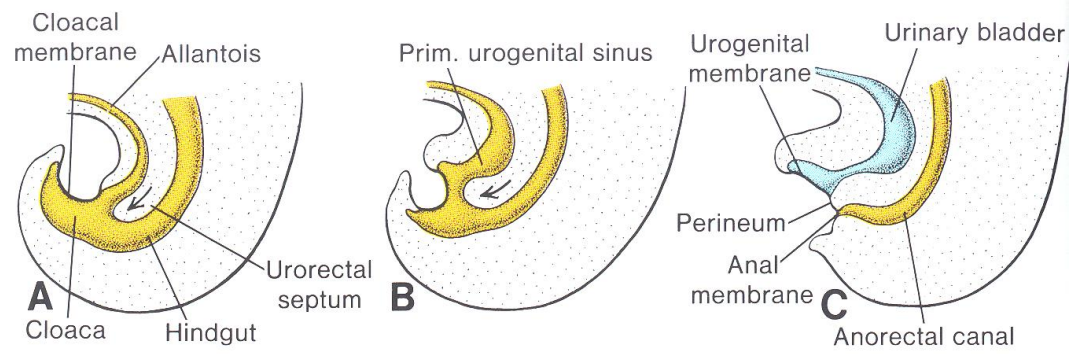


# VOLVULUS



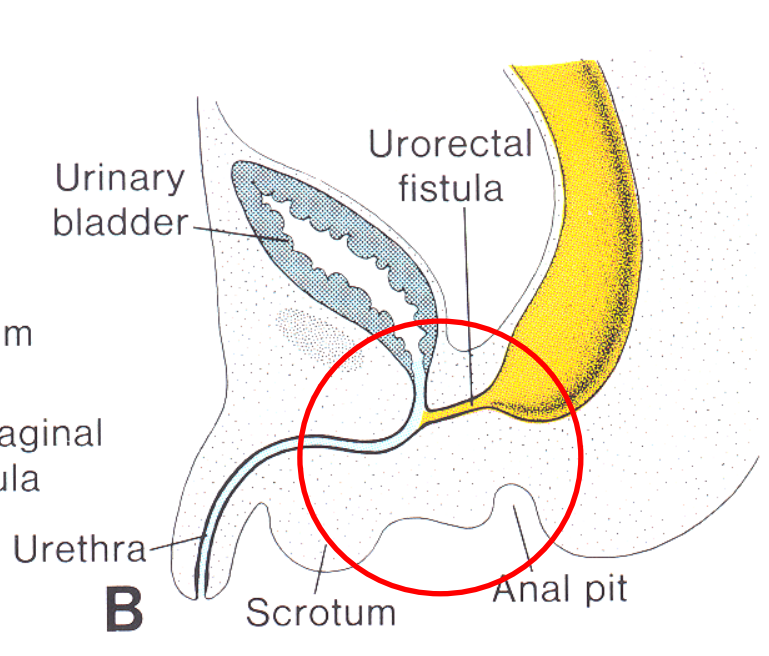
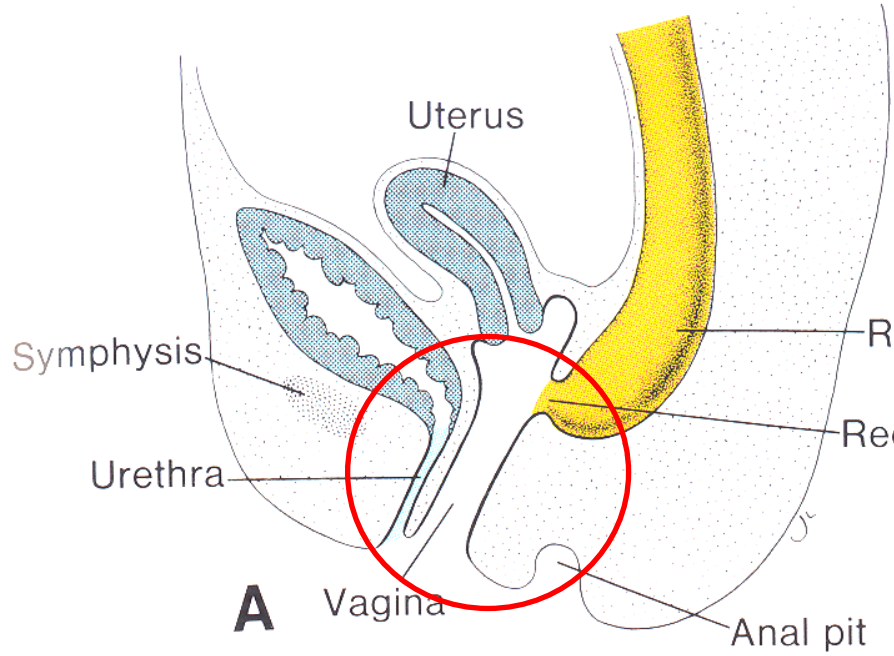
- malrotation of midgut and left colon (obstruction of a. mesenterica sup. and duodenum)
- reversed rotation (obstruction of colon)
- abnormal adhesion of caecum to liver (subhepatic caecu) - abnormal position of appendix
- caecum mobile

# ANUS DEVELOPMENT AND ITS ABNORMALITIES



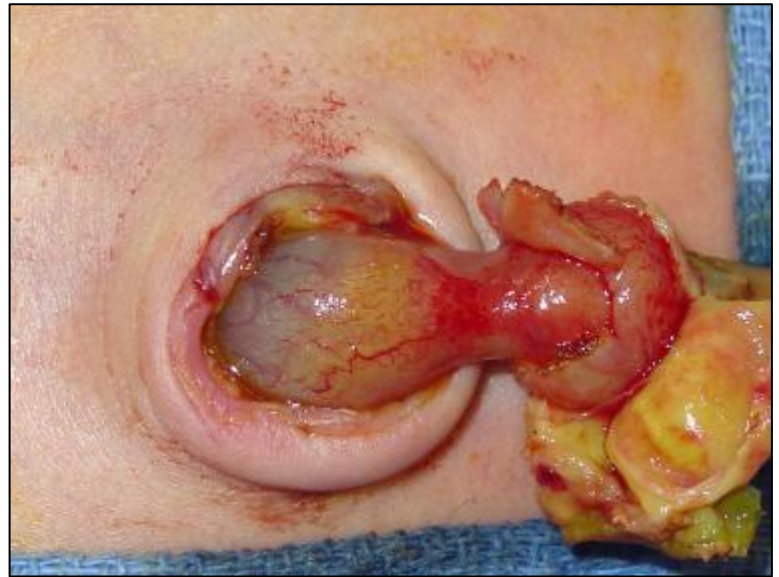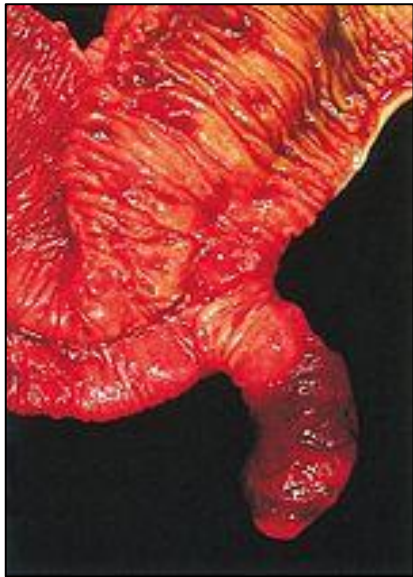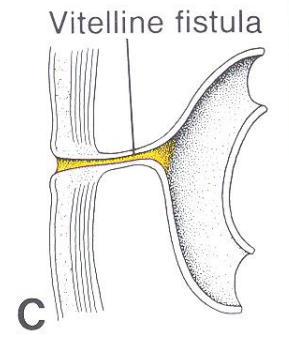
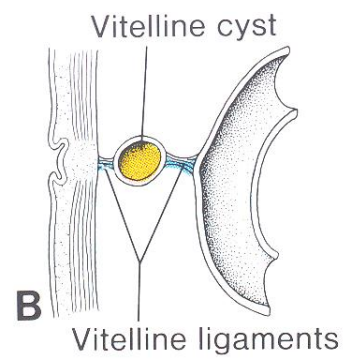
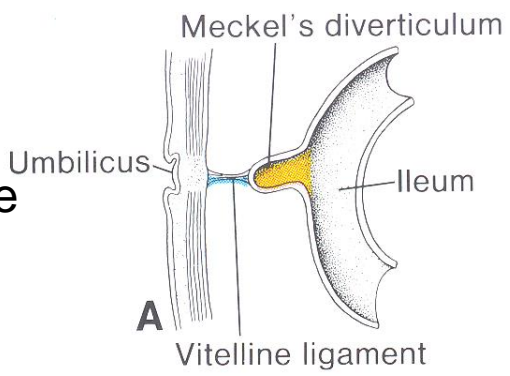


# ANUS DEVELOPMENT AND ITS ABNORMALITIES



# DIVERTICULUM MECKELI

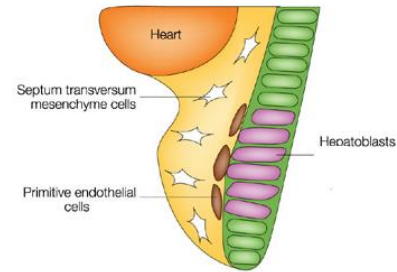
- often phenomenon (2-4%)
- clinically relevant
- vitelline cysts
- volvulus of diverticle



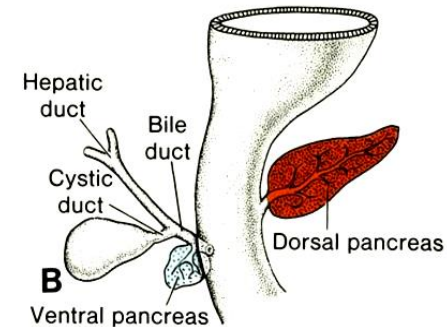
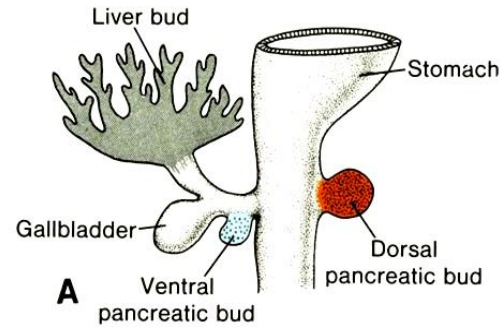
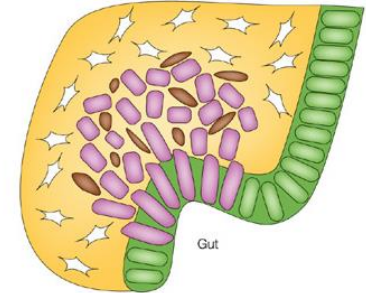
# EMBRYONIC DEVELOPMENT OF LIVER

- Diverticulum of embryonic duodenum - **liver diverticulum**
- **Pars hepatica** (parenchyma + ductus hepaticus) and **pars cystica** (ductus cysticus + gall bladder) form d. choledochus
- Rapidly proliferating cells penetrate septum transversum (mesodermal plate between pericardial cavity and yolk sac) and growth into ventral mesentery
- liver cords – parenchyma
- Interactions between cells of liver cords and vv. omphalomesentericae induce development **liver sinusoids**
- C.t. , Kupffer and hematopoietic cells – from mesoderm of septum transversum
- Surface mesoderm differentiate into visceral peritoneum

**a** Post-specification  
11-13-somite stage



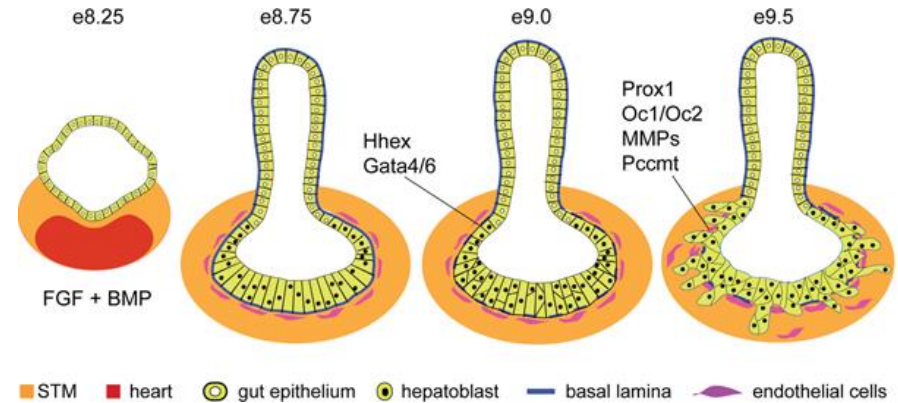
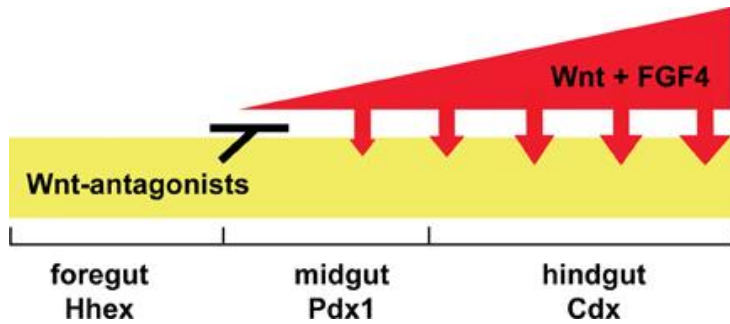
**b** Liver-bud stage  
18-25-somite stage



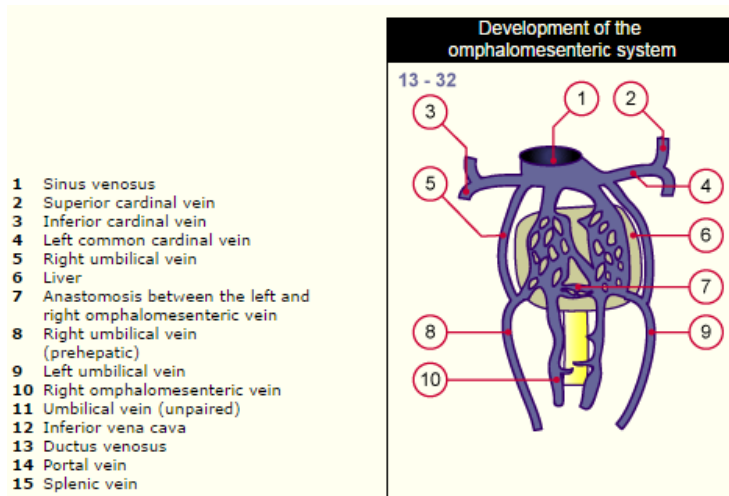
- 10th week
  - 10% of body volume
  - hematopoiesis
- 12th week
  - bile production

# EMBRYONIC DEVELOPMENT OF LIVER

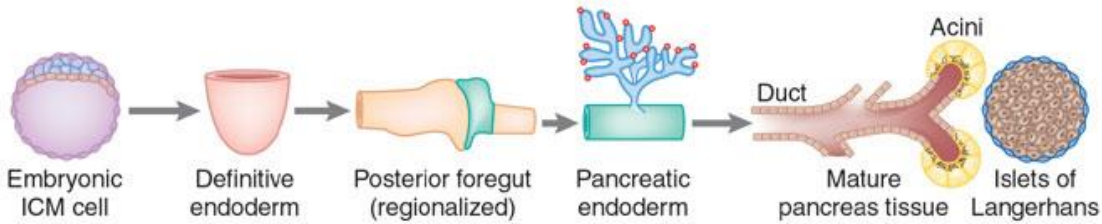
- Differentiation of endoderm and formation of primitive gut
- Growth factors of mesoderm determine identity of individual parts



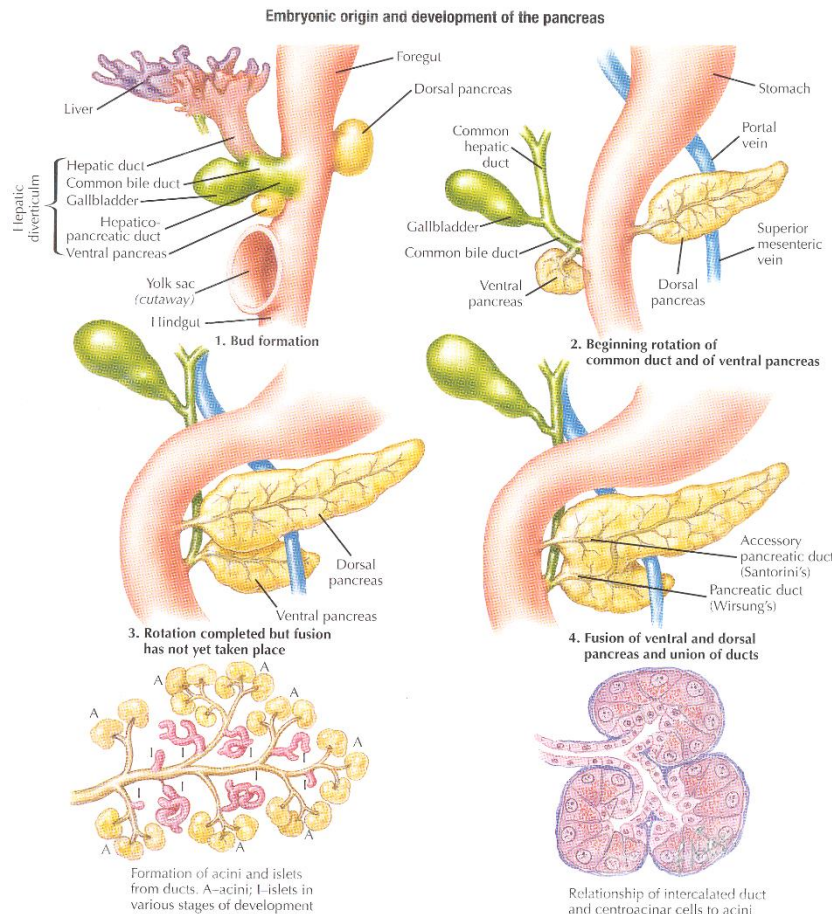
- Interactions with **mesoderm of septum transversum** and **vv. omphalomesentericae**



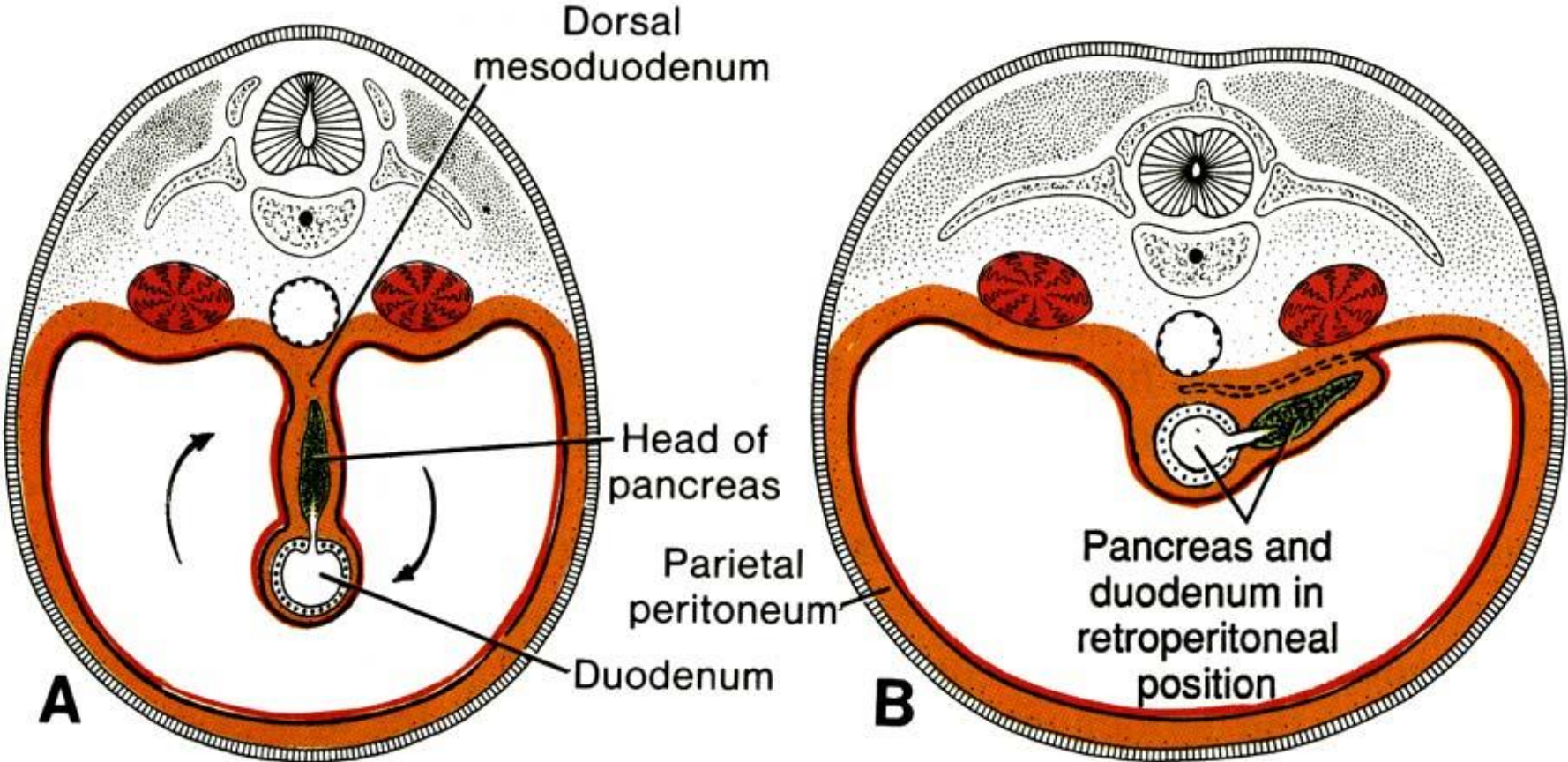
# EMBRYONIC DEVELOPMENT OF PANCREAS



- 6th week of development
- two endodermal diverticles
- dorsal and ventral duodenal diverticle (= pancreas dorsale et ventrale)
- after rotation of duodenal loop both diverticula fuse
- ducts persist (ventral - major and dorsal - accessorius)
- ductal system develops first, secretory acini follow
- cells that are not part of ductal structures differentiate into Islets of Langerhans
- since 4th month in utero - secretory activity



# EMBRYONIC DEVELOPMENT OF PANCREAS



# Summary of GIT II

- Microscopic anatomy of liver: endocrine and exocrine function of liver, vascularization, liver lobulus and its definition, liver cells, ultrastructure and function of hepatocytes, organization of intra- and extra-hepatic passages
- Microscopic anatomy of pancreas: endocrine and exocrine function, pancreatic acinus and its ducts, ultrastructure and function of acinar cells, Islets of Langerhans and their structure, cell types of Islet of Langerhans and their function
- Embryonic development and morphogenesis of digestive tube, liver and pancreas, primitive gut and its derivatives, esophagus, stomach, intestine. Flexion of embryo and rotation, liver and pancreatic diverticulum, differentiation of individual cell types.

# Thank you for attention

Petr Vaňhara, PhD  
Ústav histologie a embryologie LF MU

[\*pvanhara@med.muni.cz\*](mailto:pvanhara@med.muni.cz)  
<http://www.med.muni.cz/histology>