

Disaeses of the tongue

Manifestation of
systemic diseases on
the surface of the
tongue

MUDr. Hana Poskerová

Department of Stomatology,
Faculty of Medicine, Masaryk University
Brno, St. Anne's University Hospital Brno

THE TONGUE



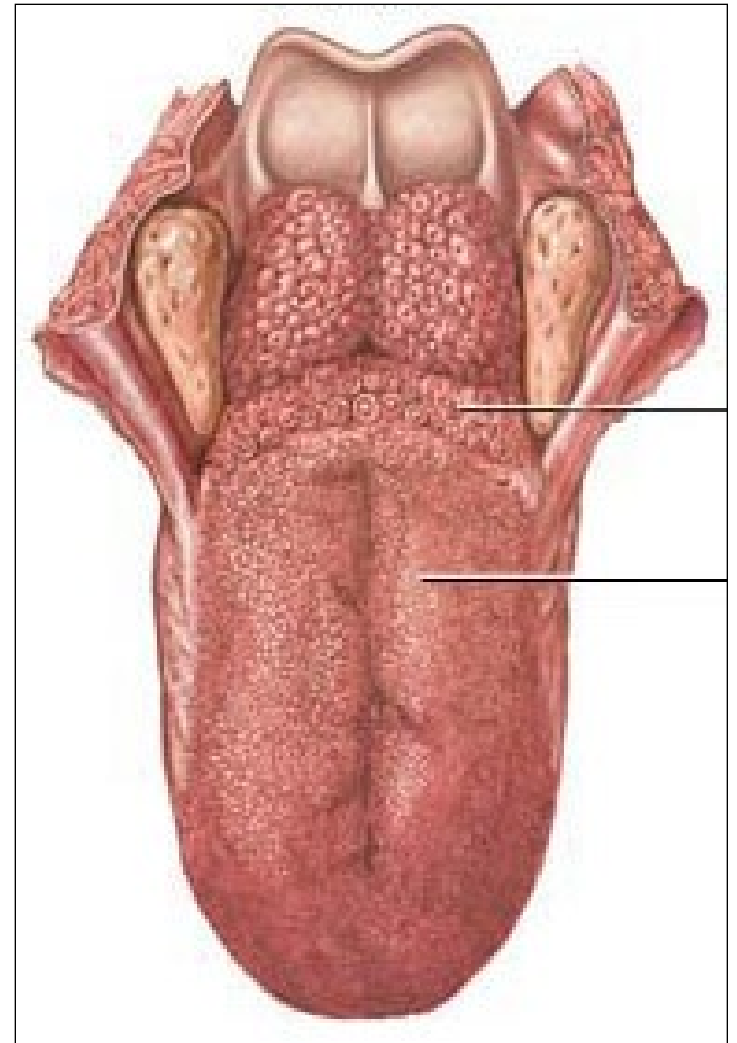
Edited by

Andreas Filippi, Prof Dr Med Dent

Irène Hitz Lindenmüller, Dr Med Dent

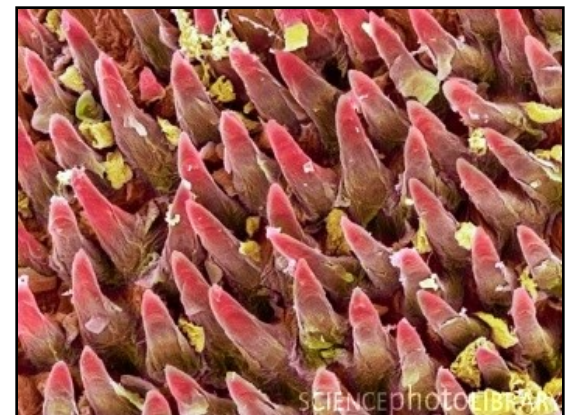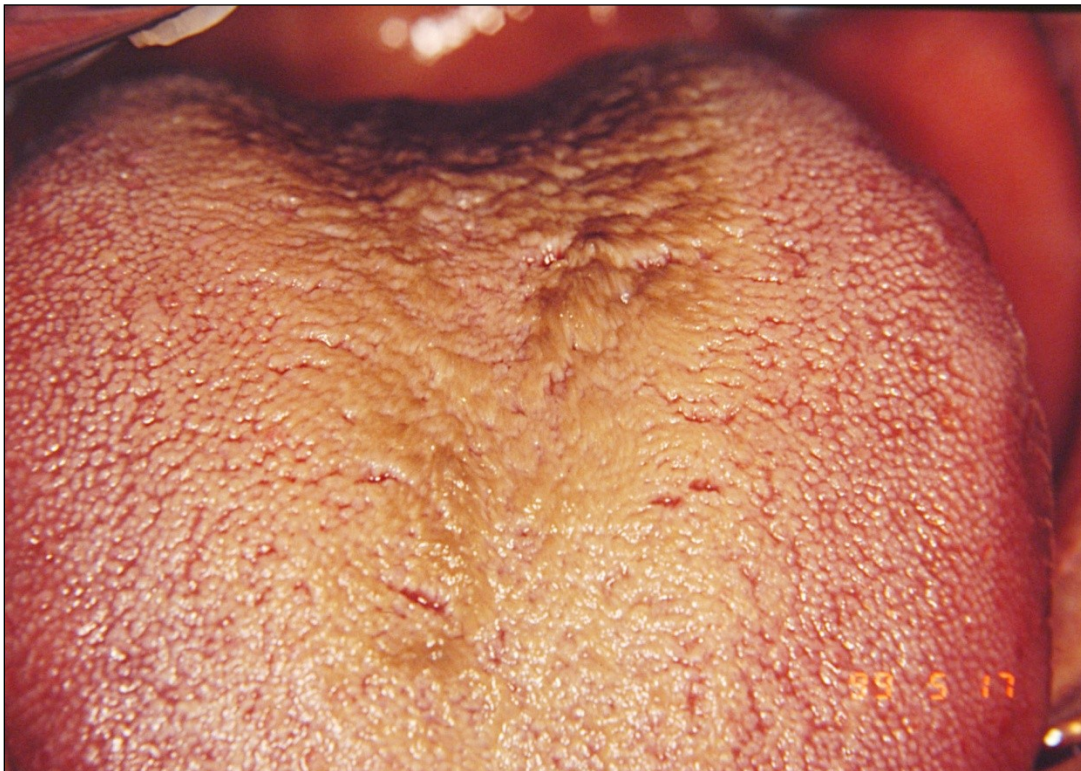Tongue examination

- Inspection, palpation
- Radix (root), body, tip
- Dorsal surface
- Lateral sides
- Inferior (ventral) surface



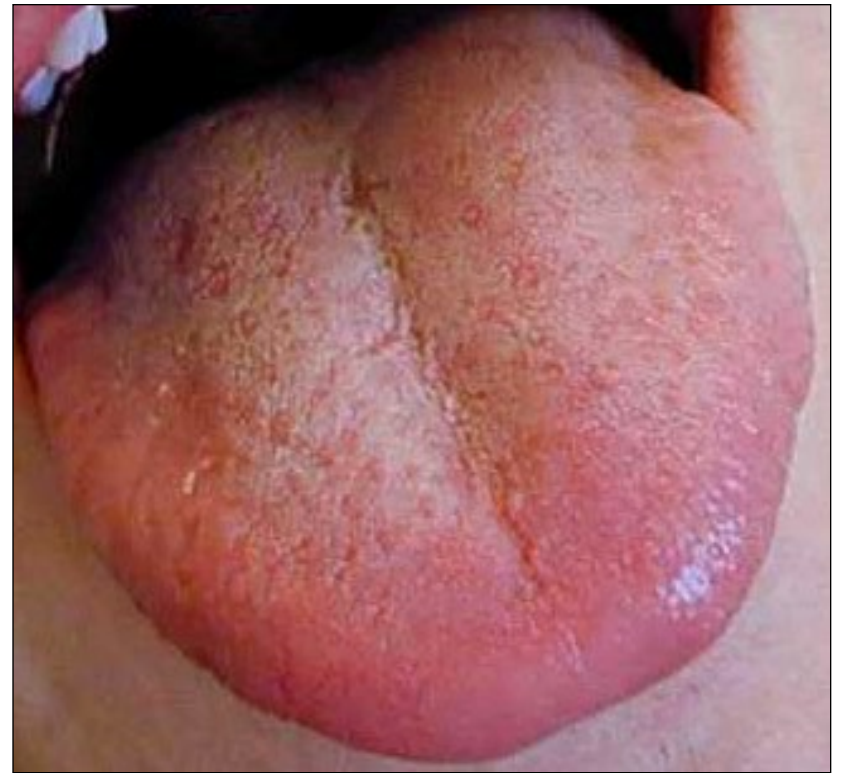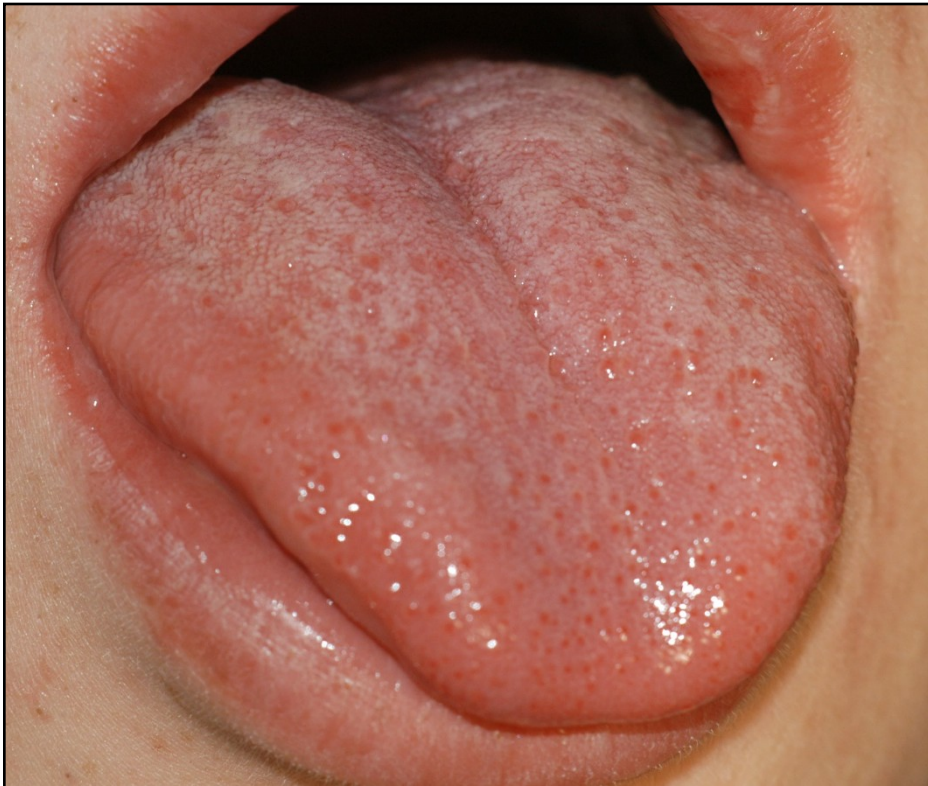Papillae of the surface of the tongue

- Papillae filiformes



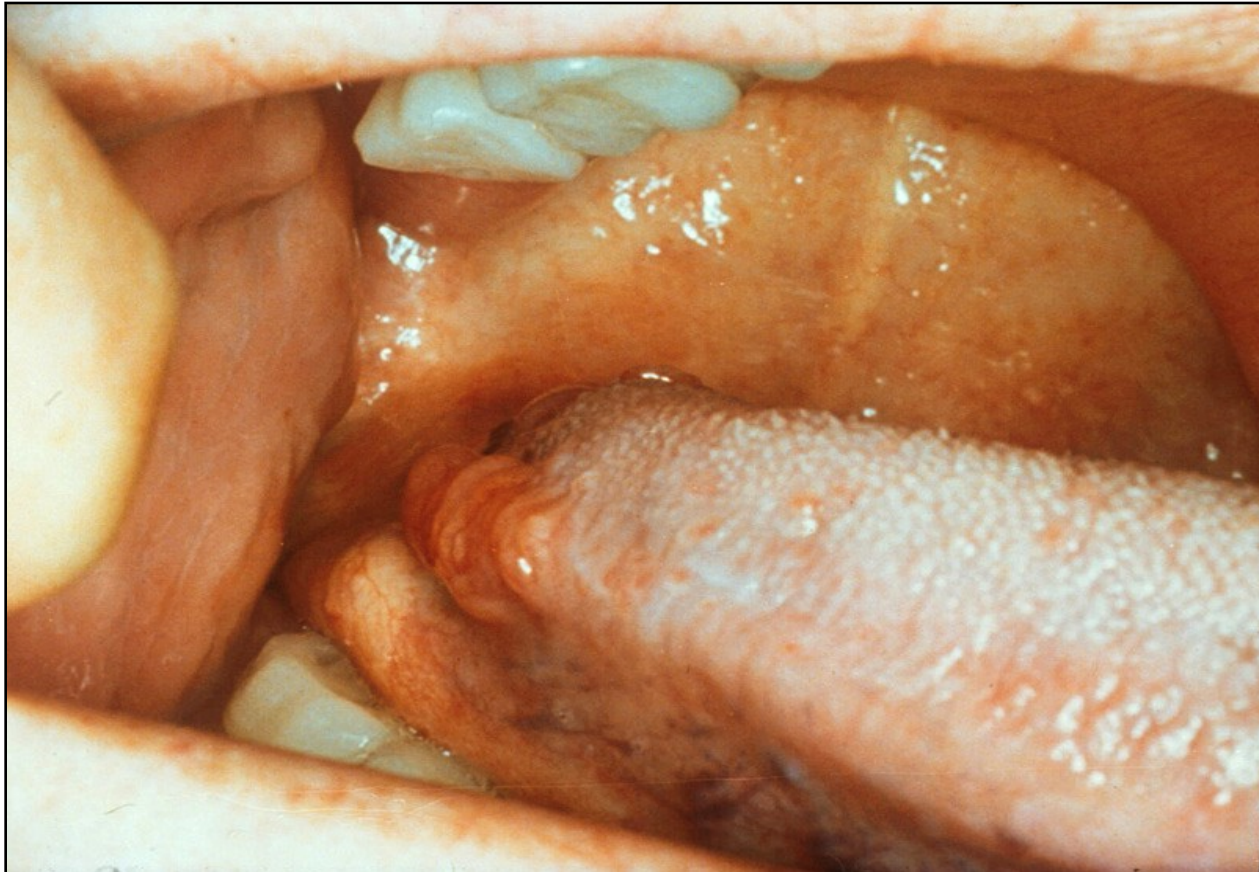
Papillae of the surface of the tongue

- Papillae fungiformes



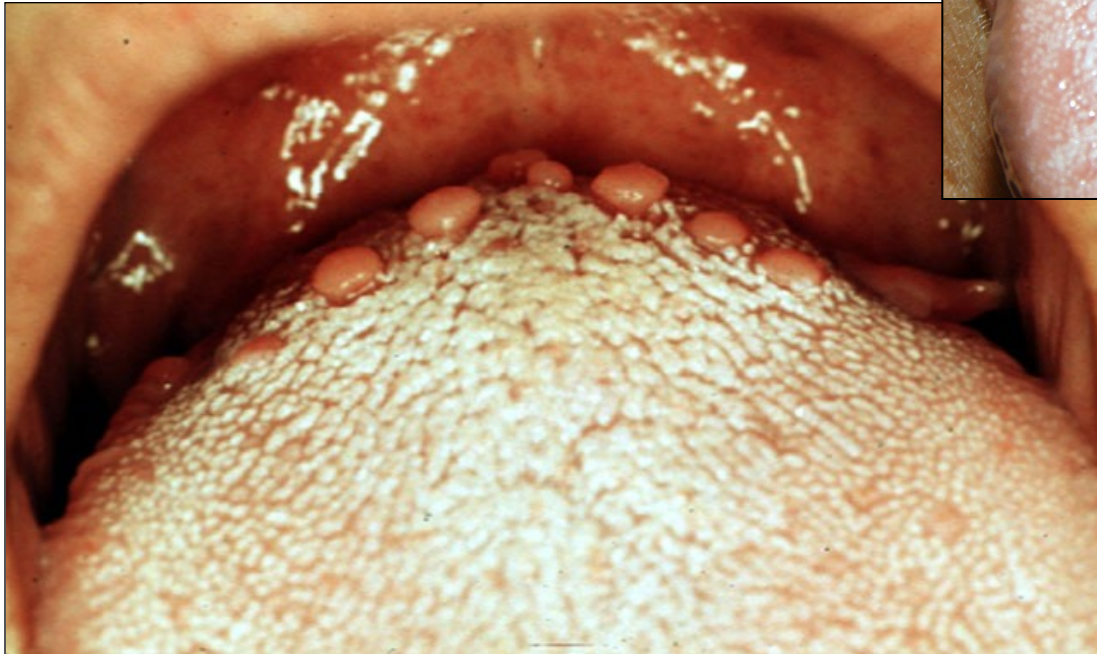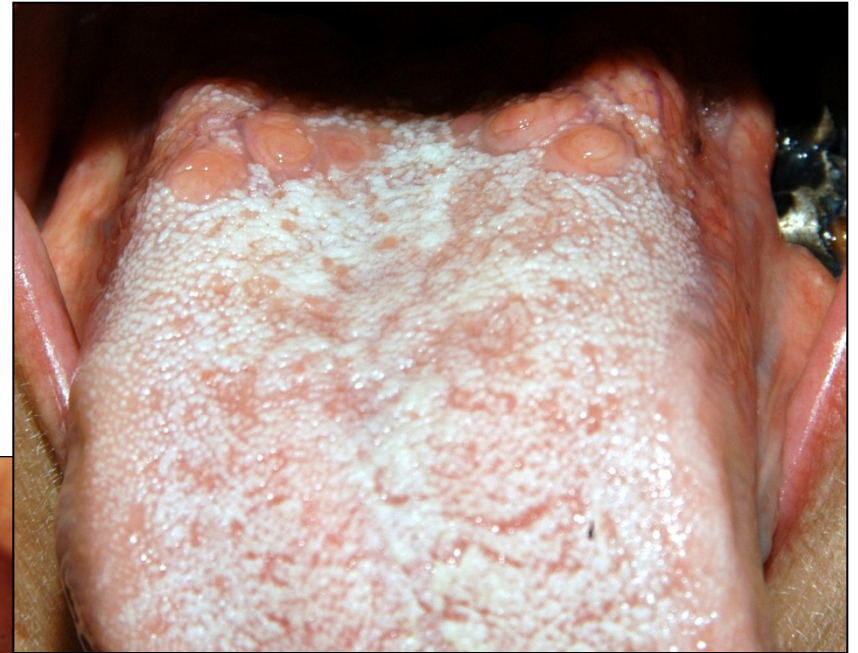Papillae of the surface of the tongue

- Papillae foliatae

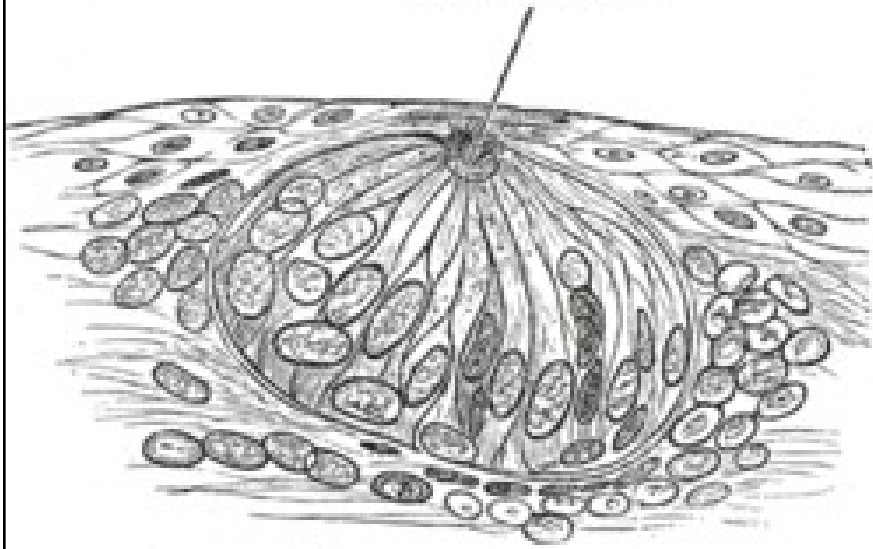


Papillae of the surface of the tongue

- Papillae circumvalatae



Gustatory pore and gustatory hairs



Taste buds -

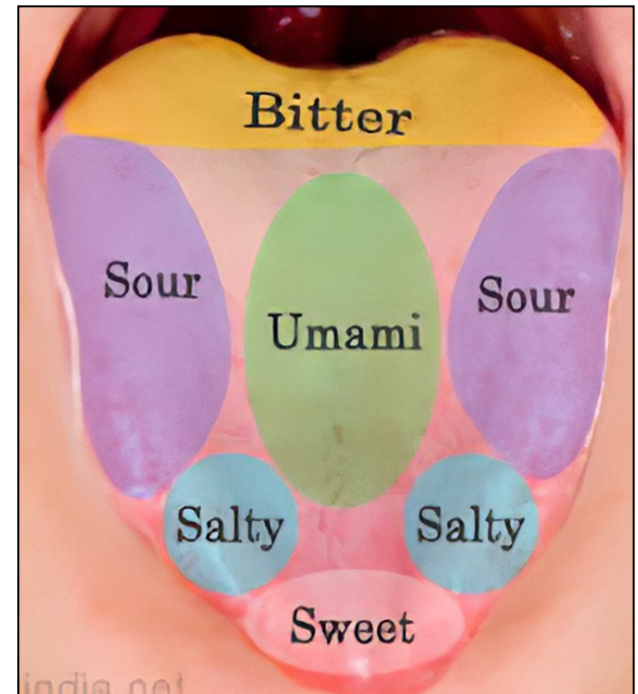

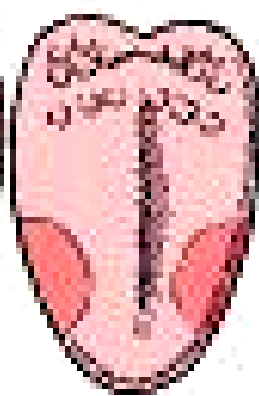
specialised receptors, are found over the entire dorsum of the tongue, along the sides of the tongue, the epiglottis, soft palate

Sweet

Salty

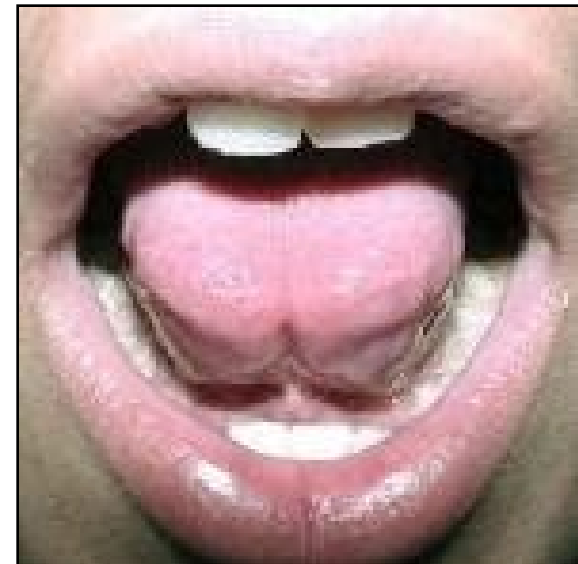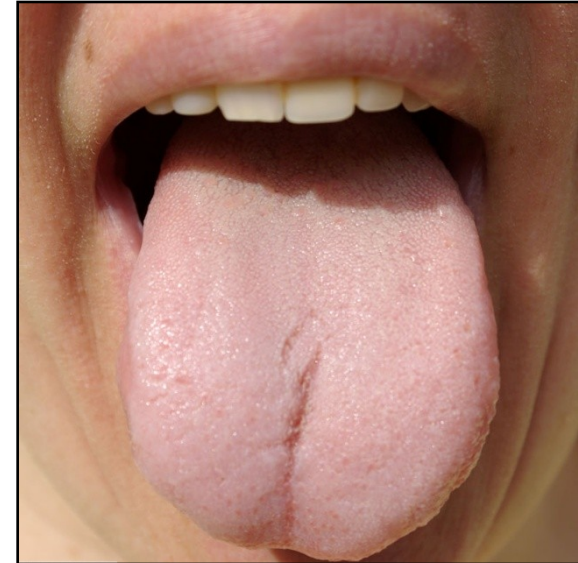Sour

Bitter



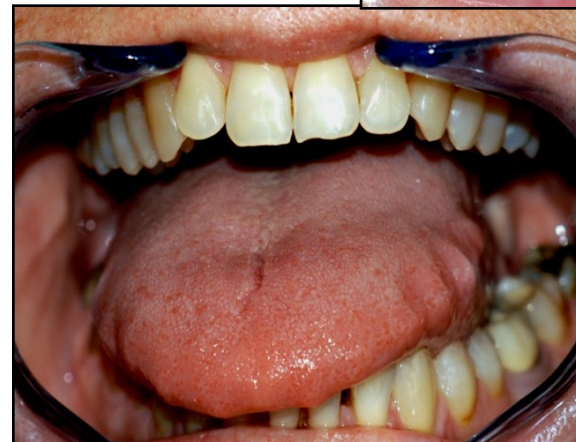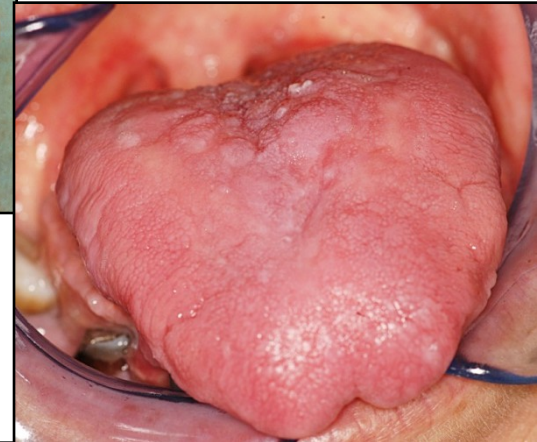
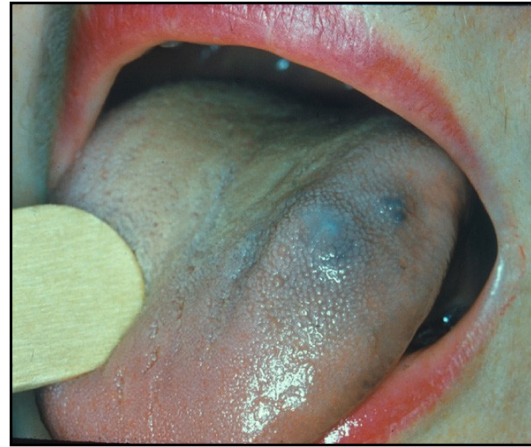
Tongue examination

- **Size**, asymetry
- **Coating** - color, amount
- **Humidity**
- Perfusion of blood
- **Surface** - grooves, furrows, impressions, lesions
 - solitary, multiple
- Sensitivity
- Localization and extent of changes
- Relationships to surrounding tissues
- Frenum of the tongue - ankyloglossia



Tongue examination

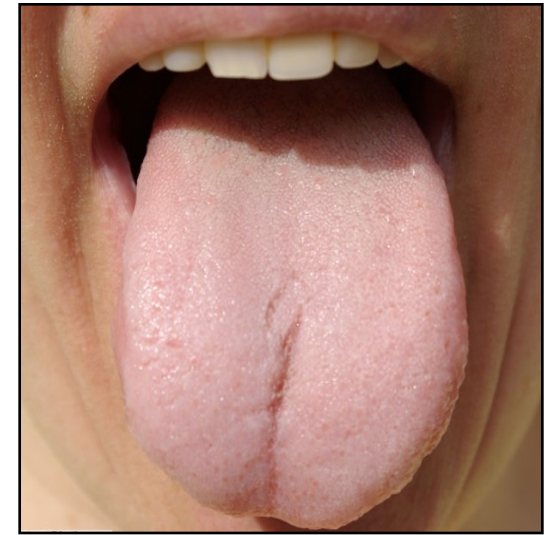
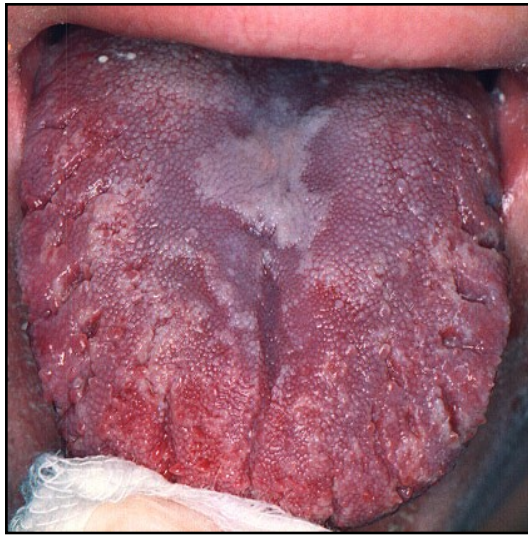
- **Large tongues**
 - acromegaly
 - hypothyroidism
 - Down s syndrome
 - hemangioma
 - muscular hypertrophy
 - amyloidosis
 - tumors
 - angio-neurotic oedema
 - Crohn's disease



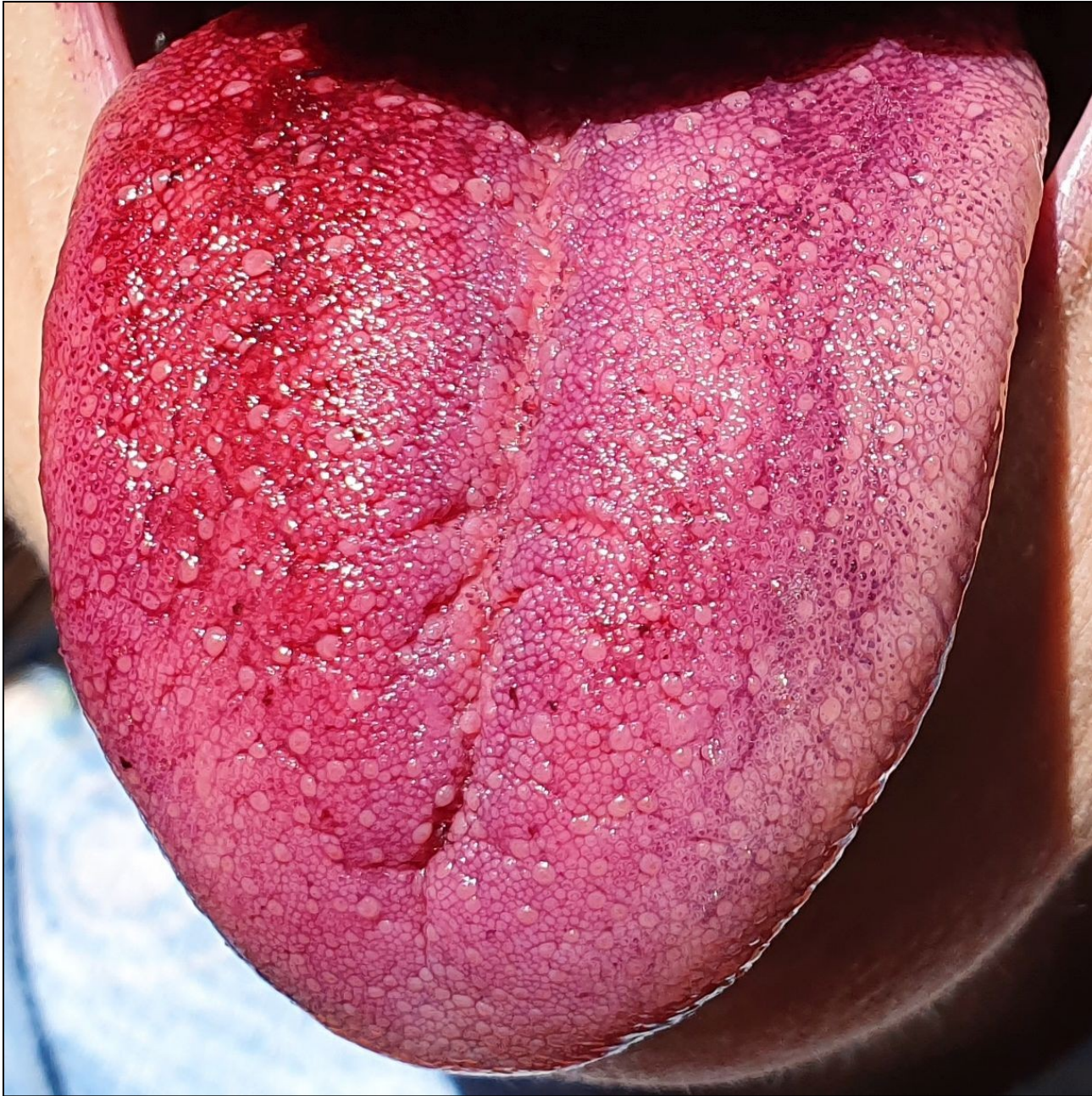Tongue examination

- Small tongues
 - congenital small mandible syndromes
 - lingual hypoplasia
 - other developmental disorders
 - pseudo-bulbar palsy (spastic tongue)

Colour changes



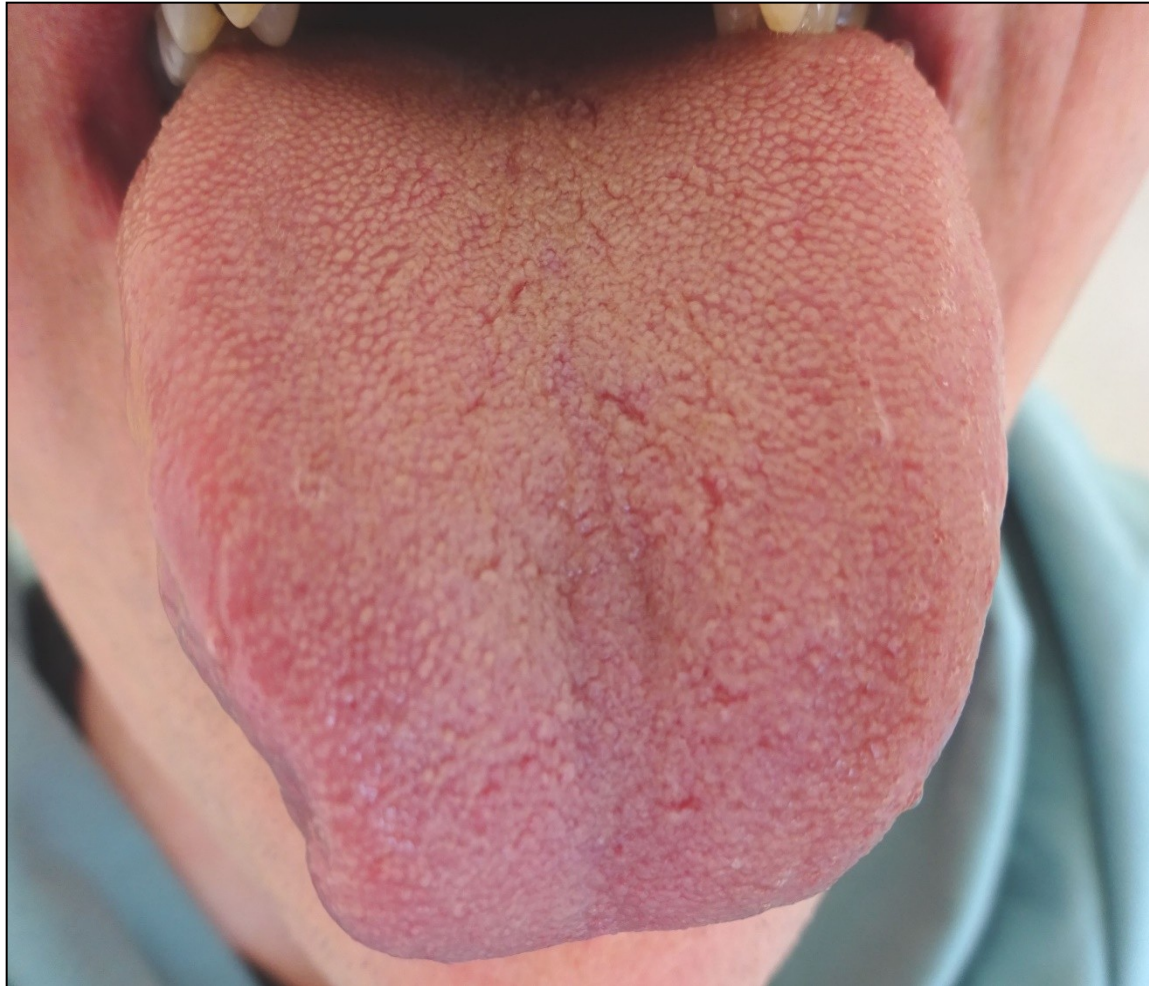- Pale - anaemia
- Yellow, orange - jaundice
- Strawberry red - scarlat fever, ATB, diarrhoea, pernicious anemia (beefy red)
- Blue - cyanosis, polycythemia
- Pigmented - racial, Addison's disease
- Black (hairy) - smoking, mouth rinses





Examination of tongue coating

- Fyziological



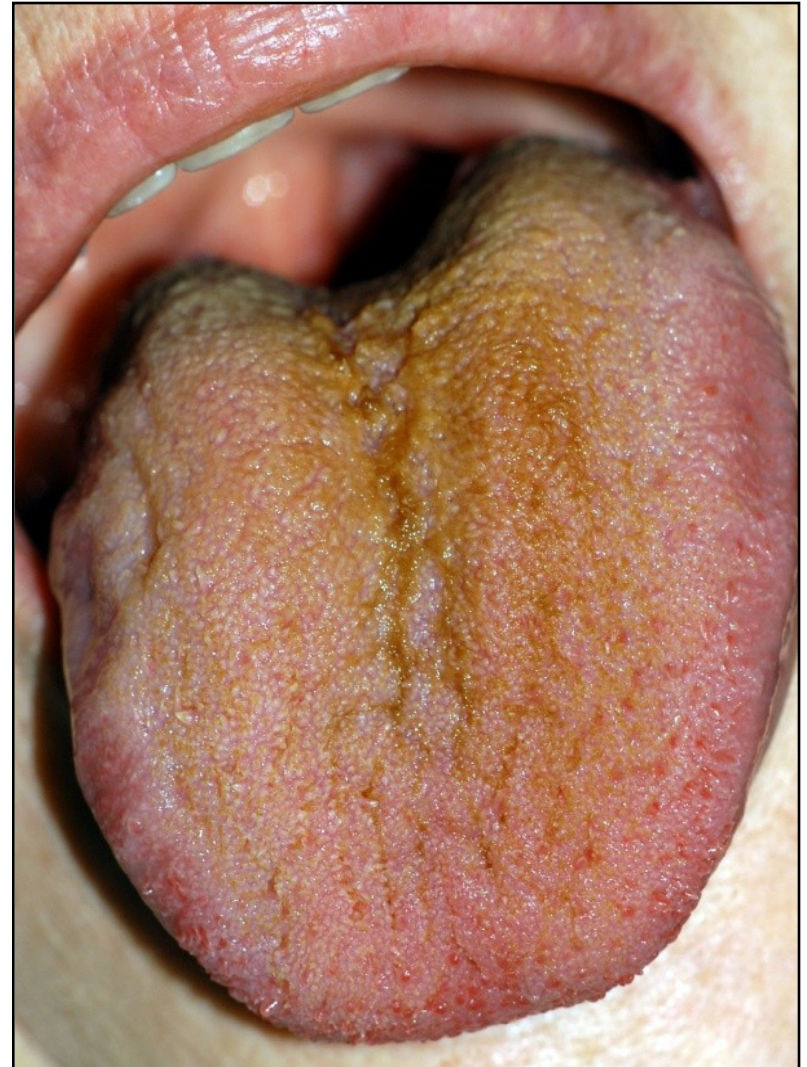Examination of tongue coating

daytime

- **Fysiological**
- **Patological acute multiplication**
 - acute upper respiratory tract infection (fresh coating)
 - serious illness with dehydration and shock (fuligo)
- **Patological **chronical multiplication****
 - chronic gastrointestinal disease (dyspeptic)
- **Patological **atrophy****
 - anemia, hypovitaminoses, Sjögren's syndrome, mitral stenosis, cirrhosis, intoxication

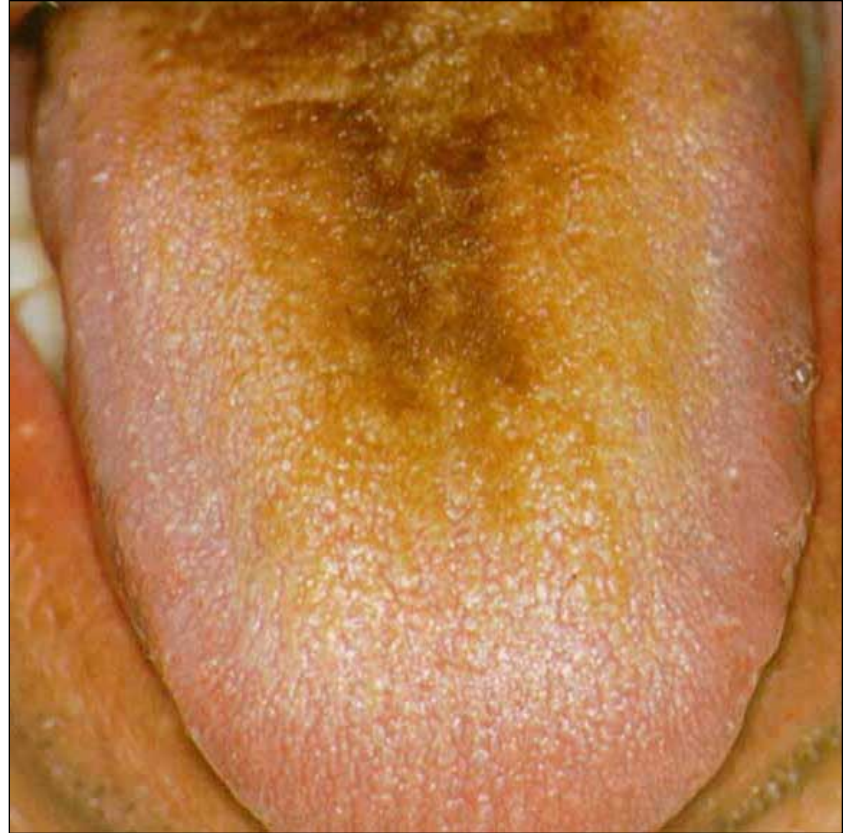Coatings of the Tongue

- elongated filiform papillae
- dead epithelial cells
- food residues, debris
- microorganisms



Coatings of the Tongue

- heavy smokers
- mouth rinses
- mouth breathers
- only soft foods,
- due to fasting
- ill fitting dentures



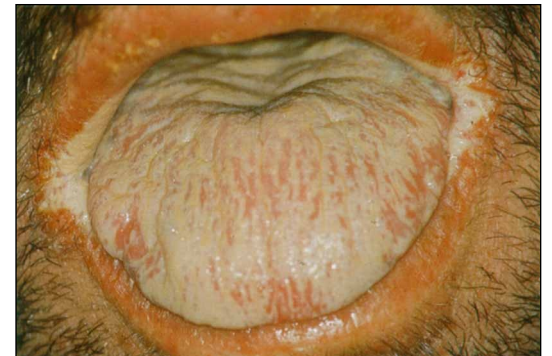
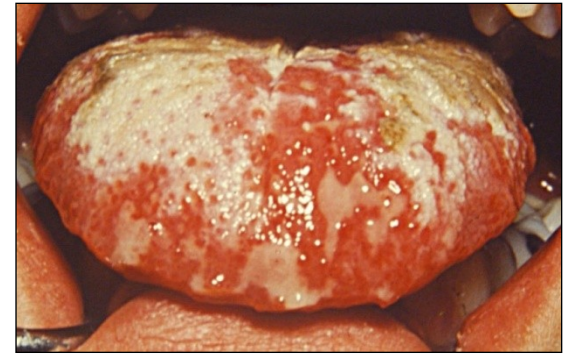Coatings of the Tongue

- **White** (yeast, acute viral inf, milk)

- **Gray** (renal failure, TBC)

- **Brown** (smoking, antibiotics and antiseptics, chromogenic bacteria)

- **Black** (smoking)

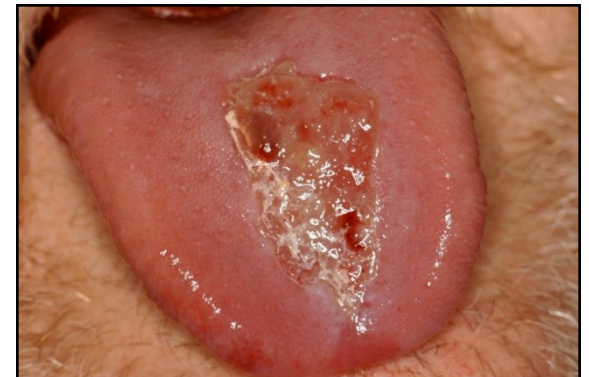

Differential Diagnosis - questions

- Acute - Chronic?
- Localization?
- Coating? Color?
- Size of language?
- Solitary lesion? Extensive diffuse lesions?
- Painful - not painful?
- Consistency?
- Overall symptoms
- Time data?

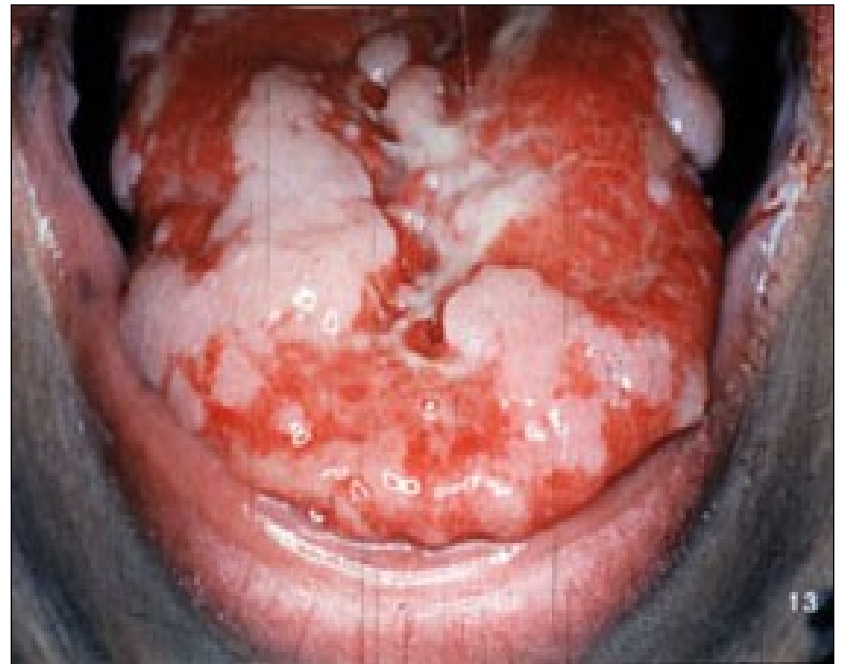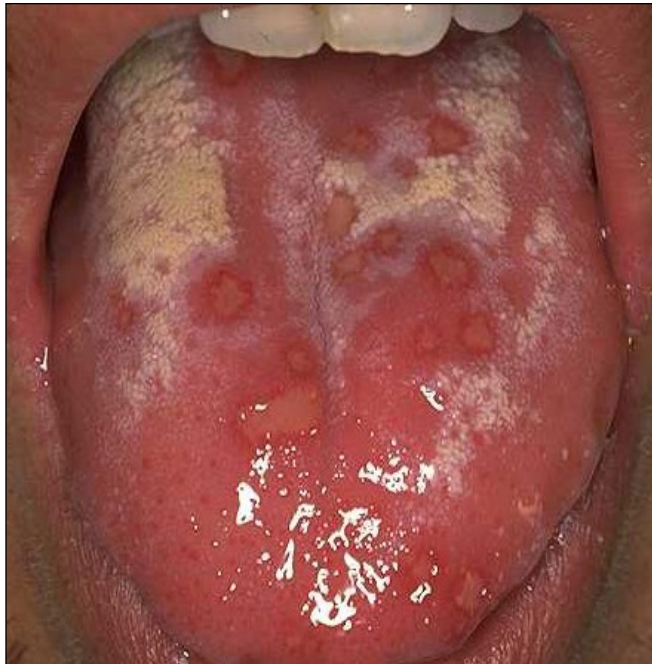Erosions/ulcers of the tongue

- trauma - aphthous ulcers - drugs
- nutritional disorders
- AI diseases (P-P) OLP, EEM
- specific gut diseases
- leukemia, agranulocytosis, neutropenia
- mucositis after oncology treatment
- malignant ulcers
- syphilis, TBC



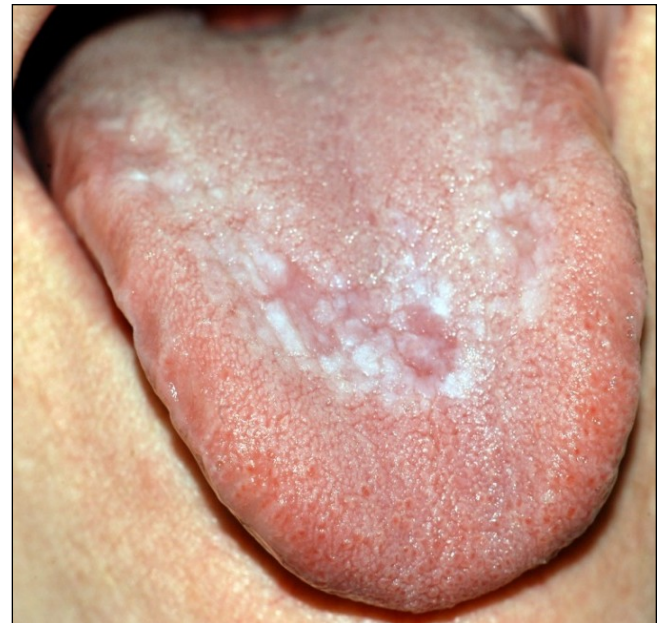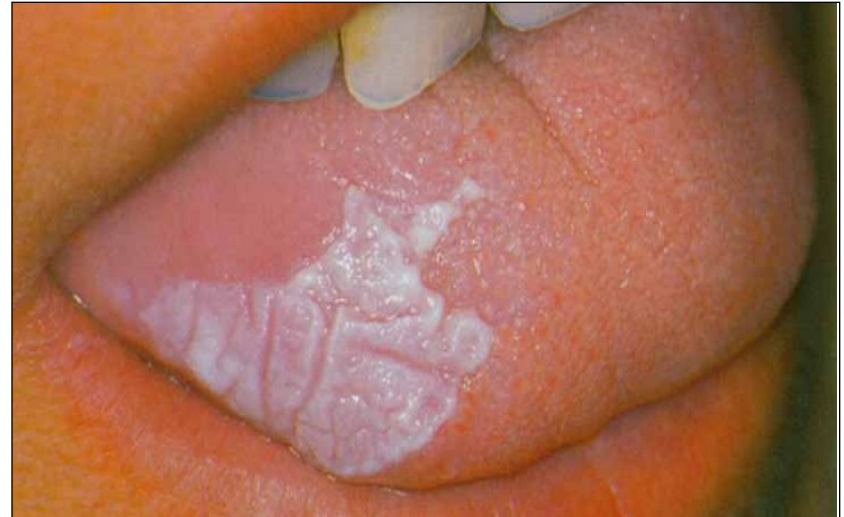Vesiculo - bullous diseases of the tongue

- acute viral infections (HSV, VZV, Coxackie)
- EEM, P-P



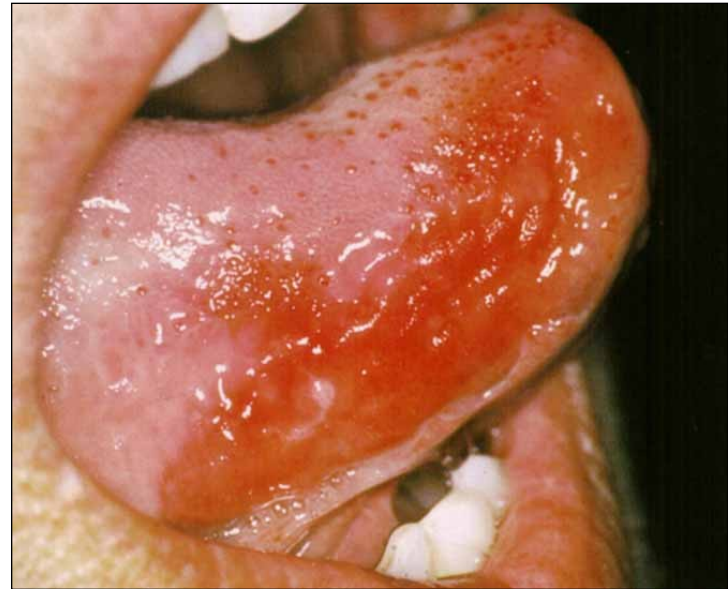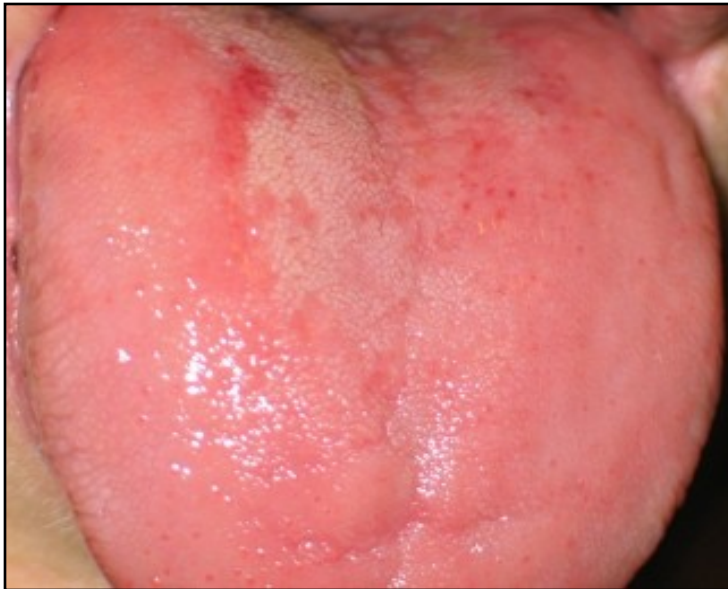White lesions

- frictional keratoses
- tobacco keratoses
- leukoplakia
- OLP
- candida infection
- psoriasis

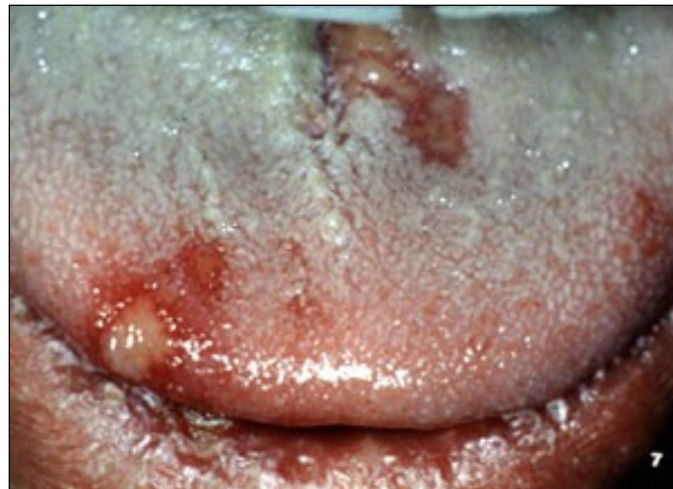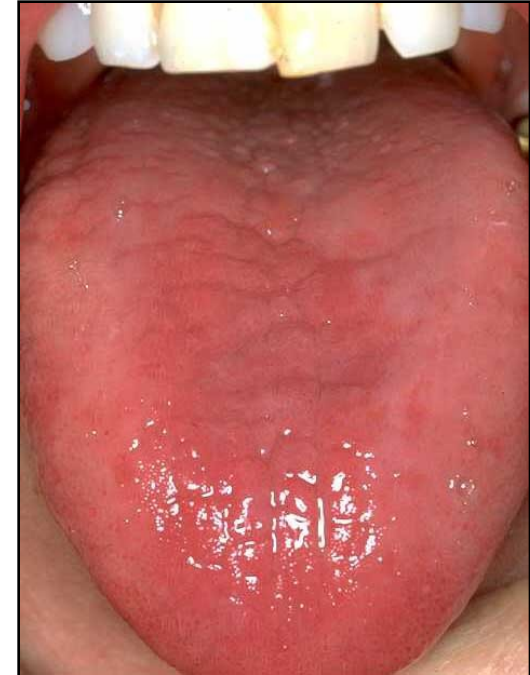
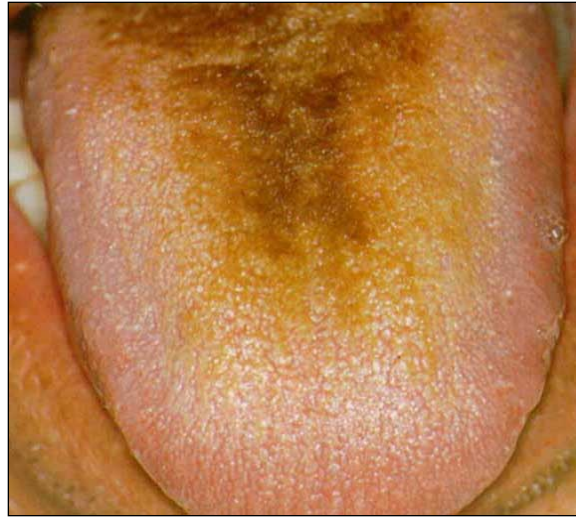

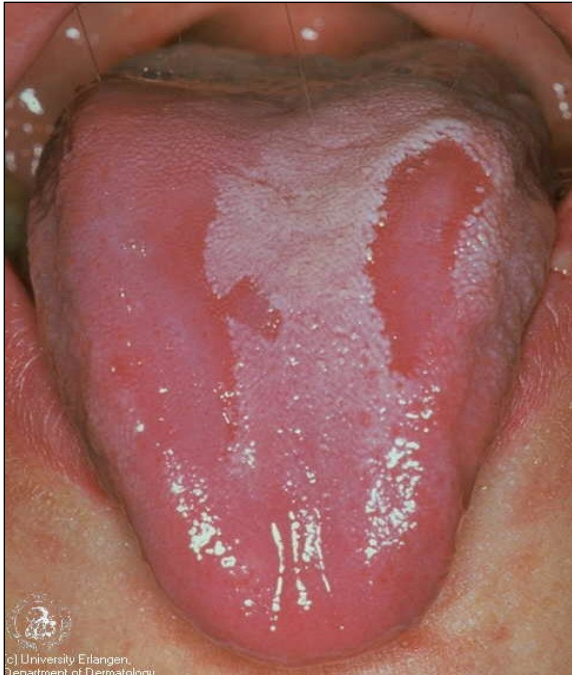
Acute (chronic) glossitis

- drug induced glossitis
- infections (bacterial, fungal, viral)
- allergic and toxic reactions
- nutritional (Fe, B12, folic acid, other B vit)



Examination of tongue coating

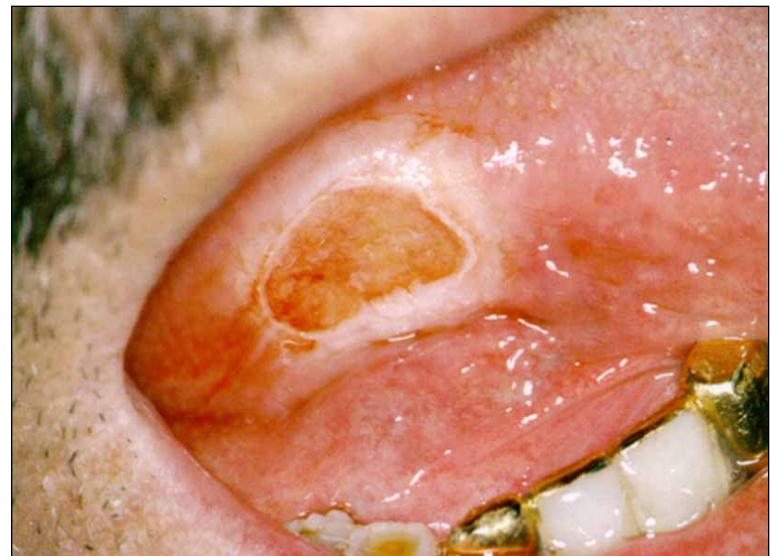

1/ Local changes of the tongue

2/ Manifestation of generalized
disease

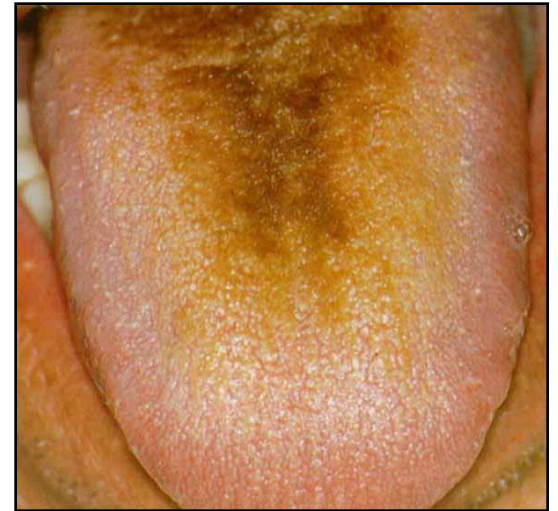
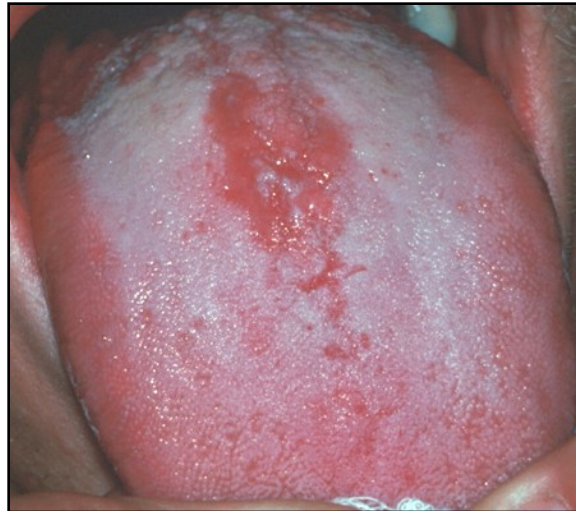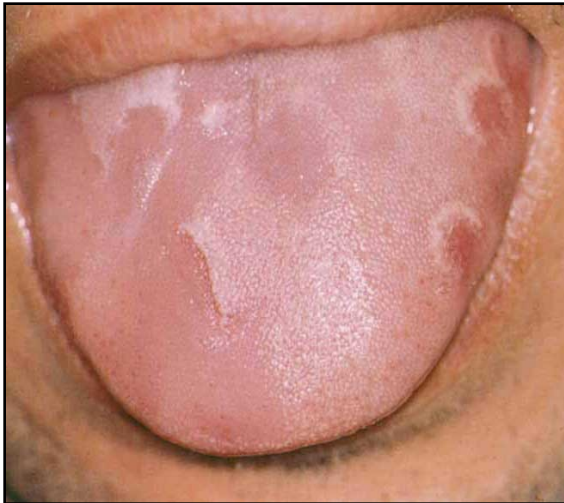
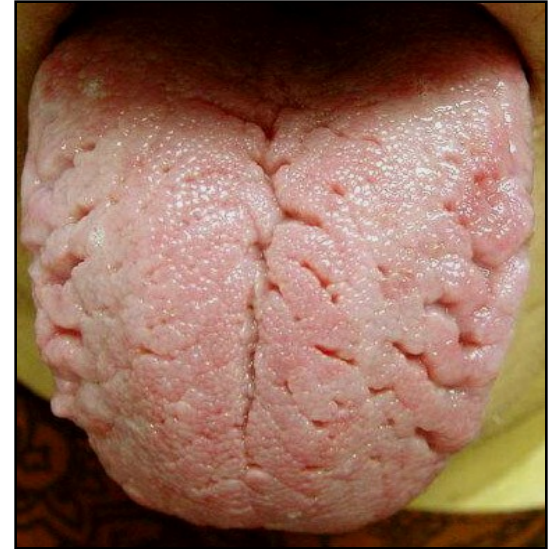1/ Local changes of the tongue

- Congenital or developmental disorders
- Environmental factors (trauma, bites into the tongue, foreign bodies, burns)
- Local infection
- RAS
- Tumor

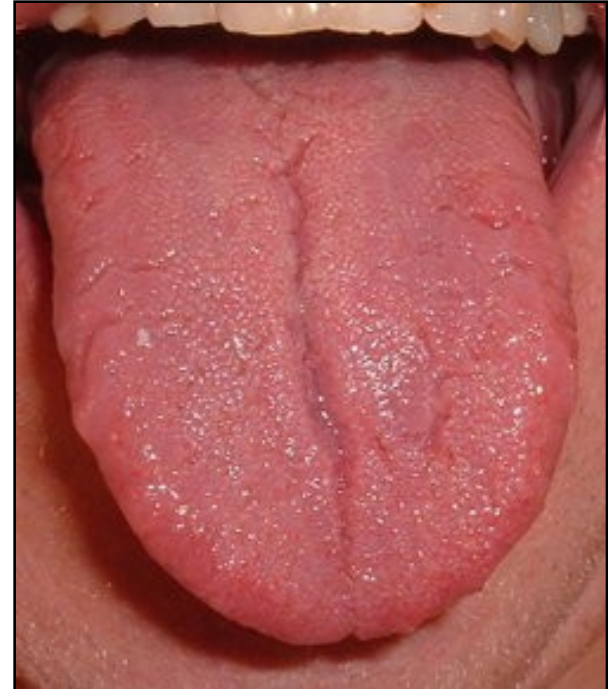
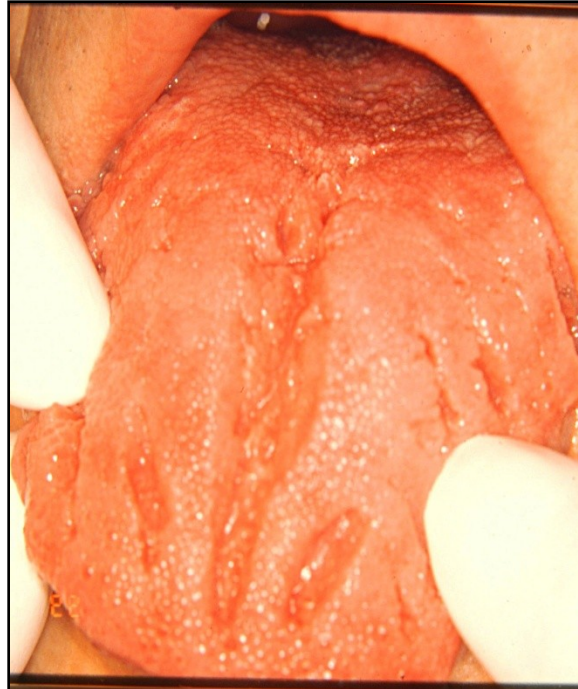
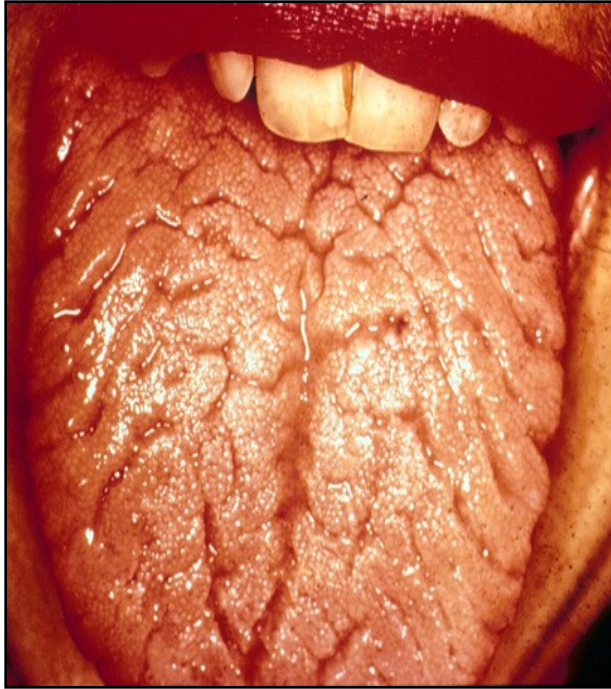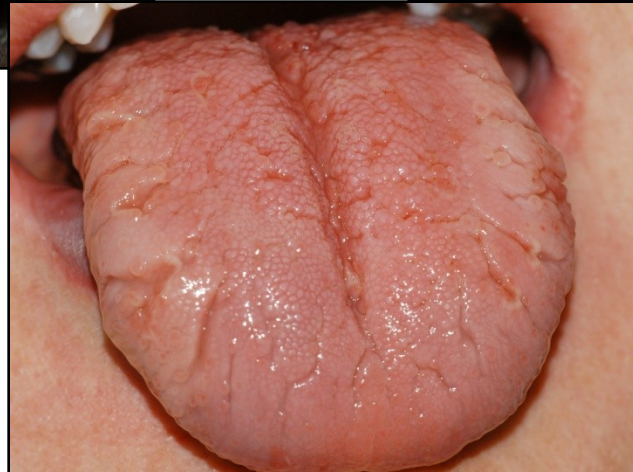
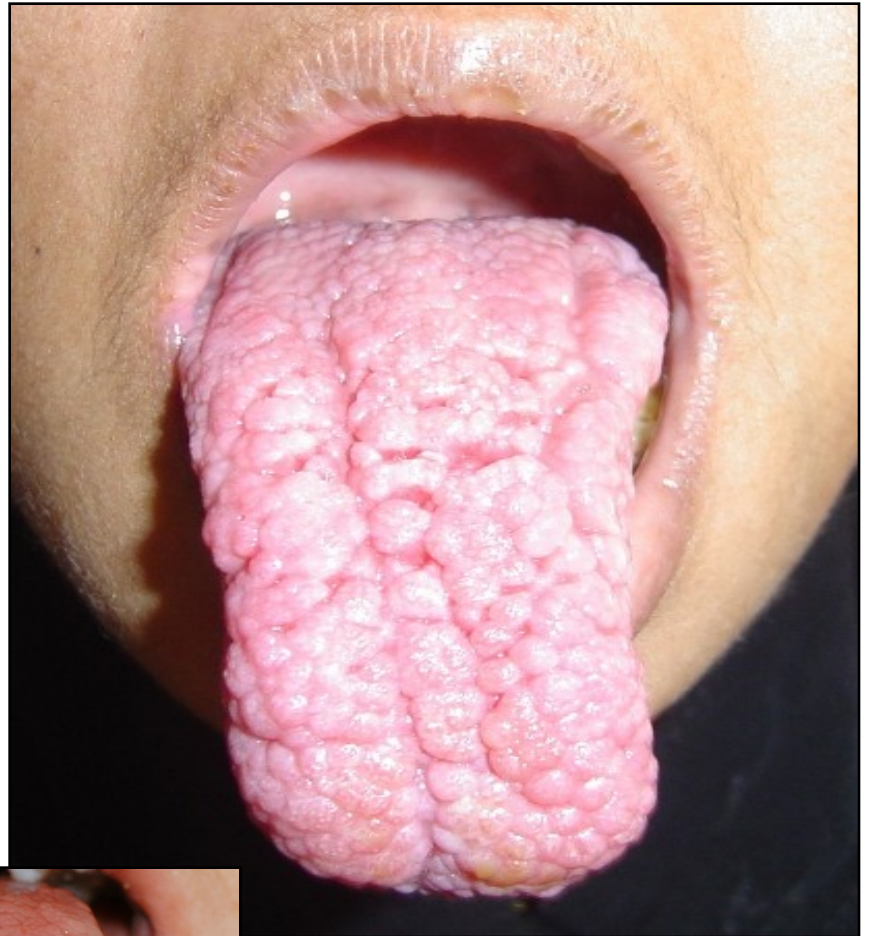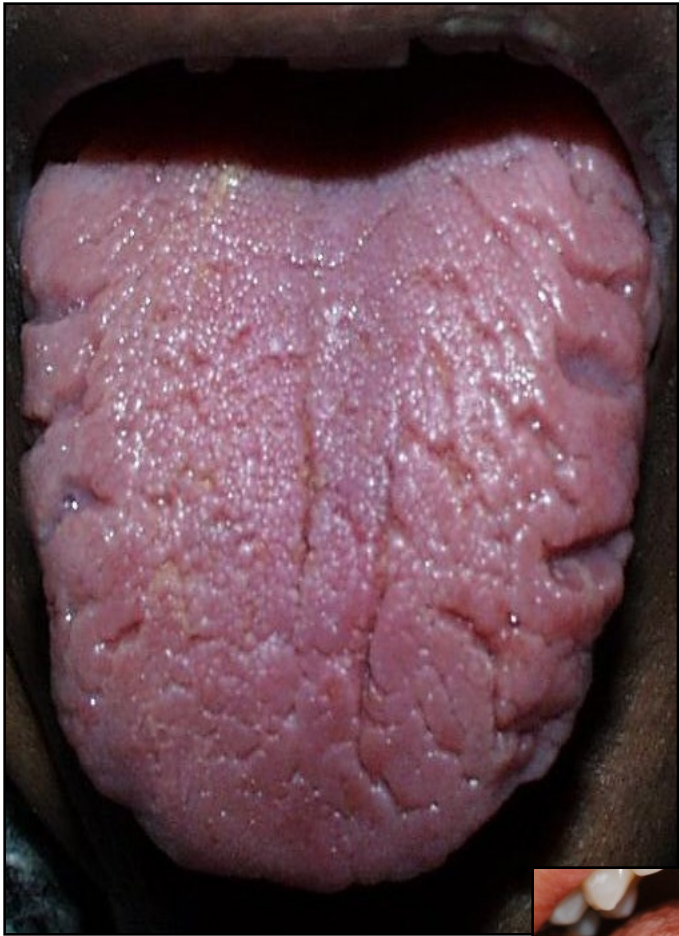1/ Local changes of the tongue

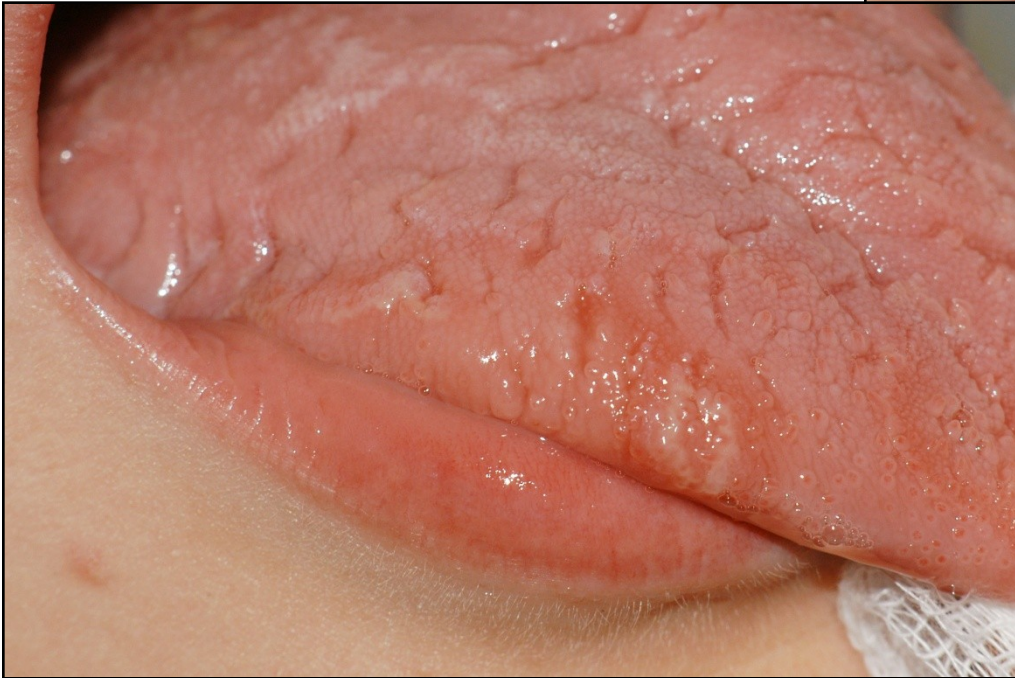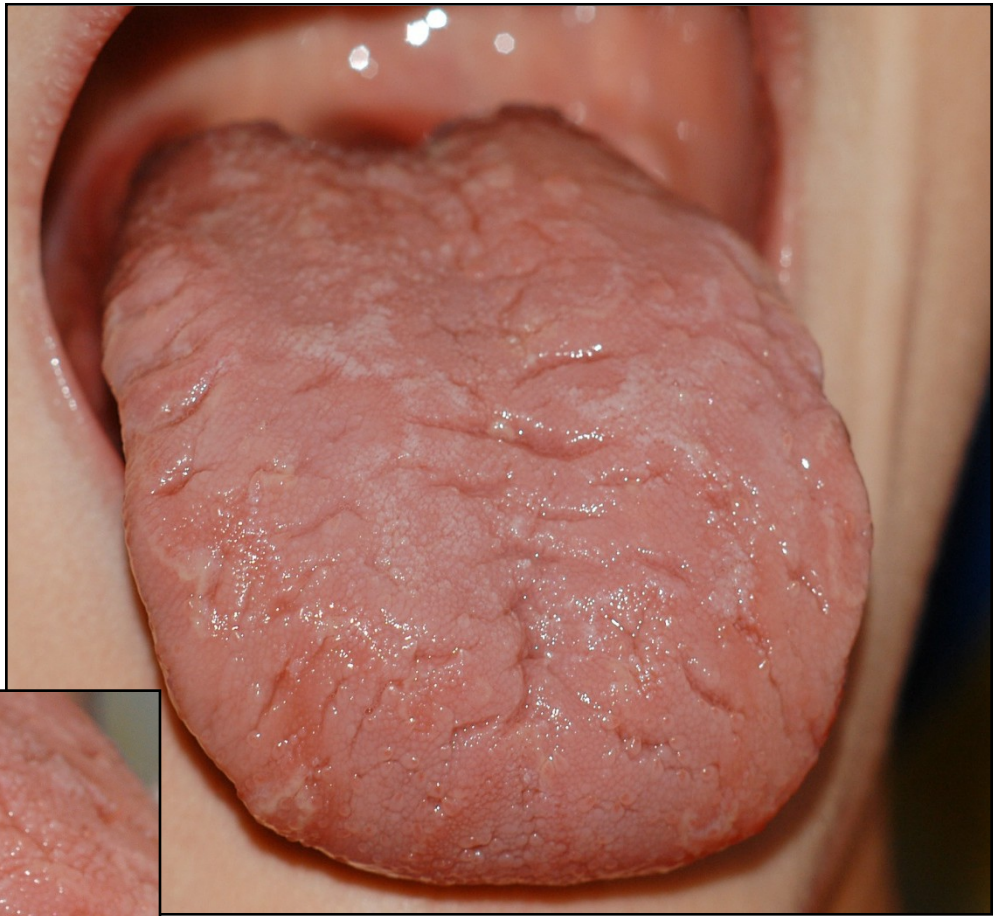- Lingua plicata
- Lingua geografica
- Glossitis rhombica mediana
- Lingua villosa nigra

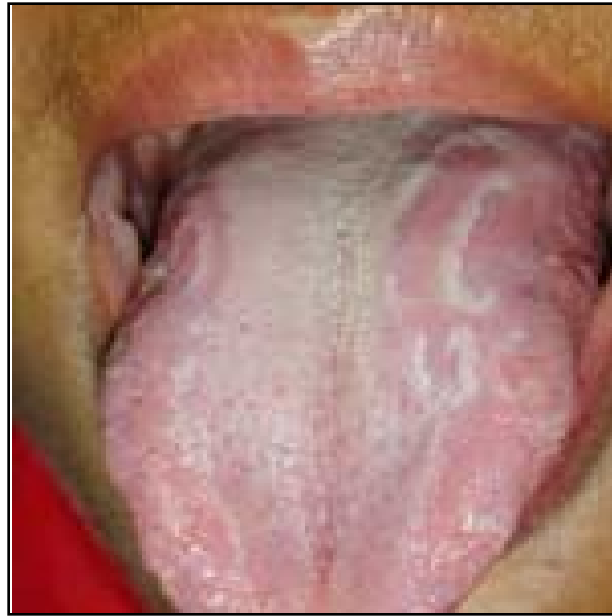
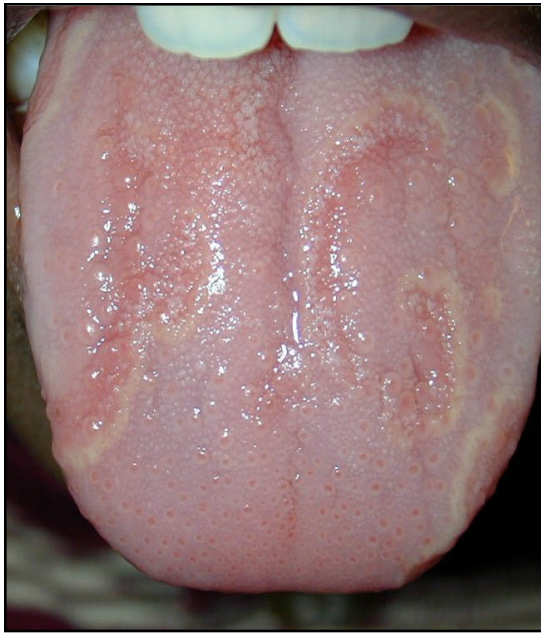
Lingua plicata (Down sy, Melkersson's syndrome)

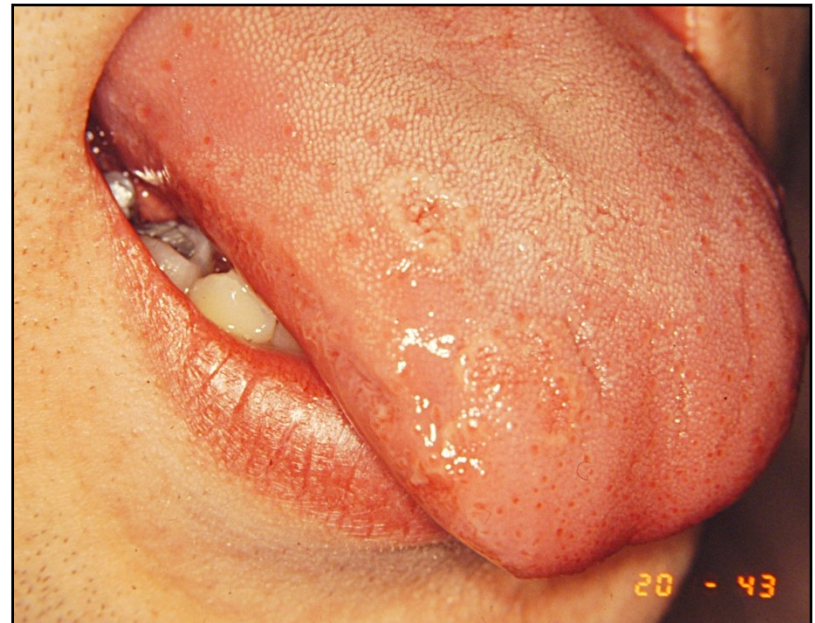
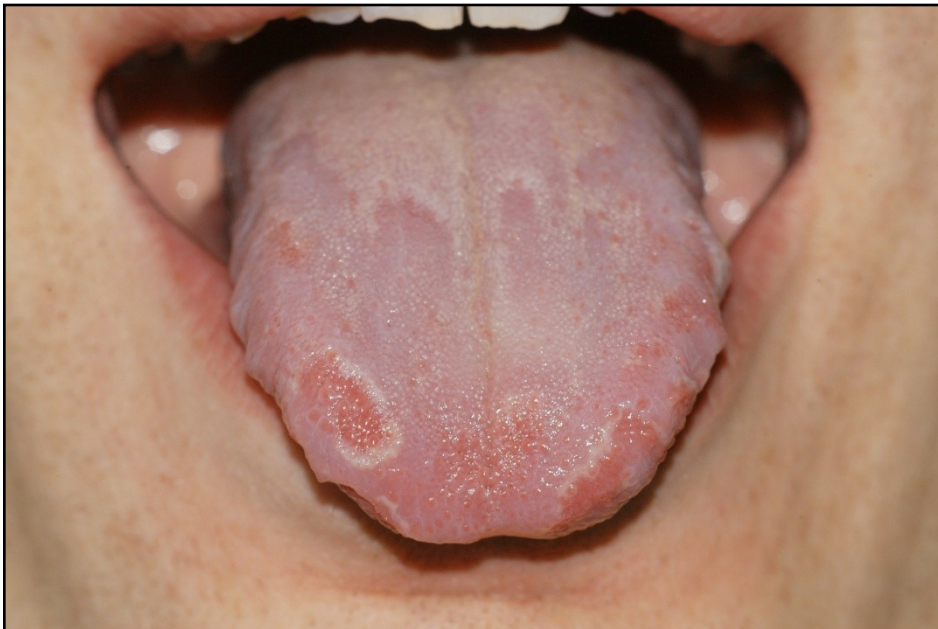
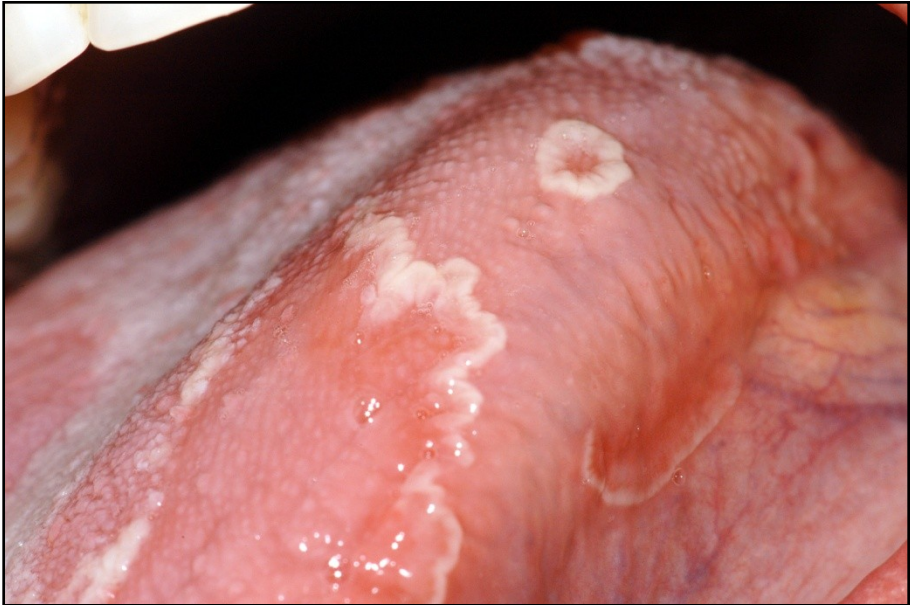
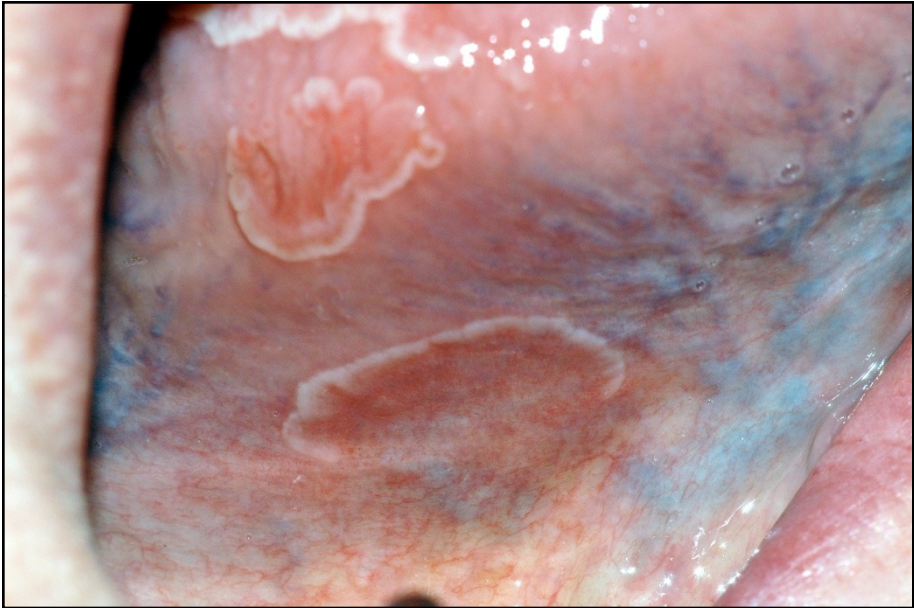


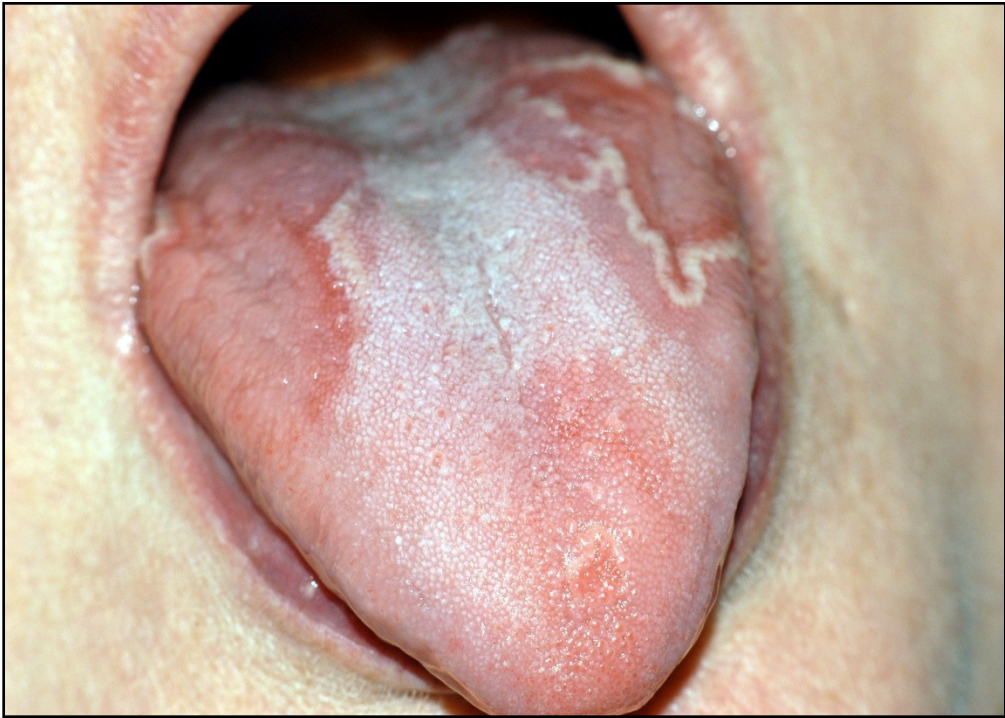


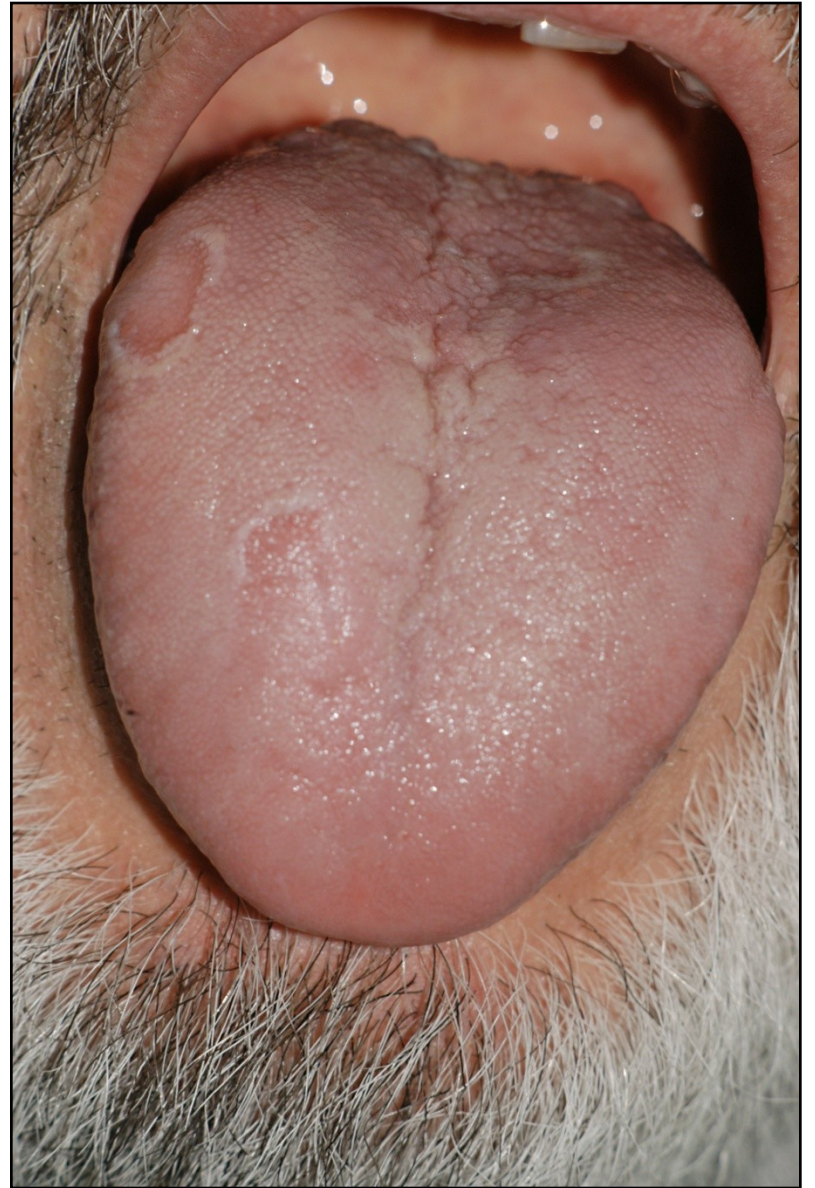
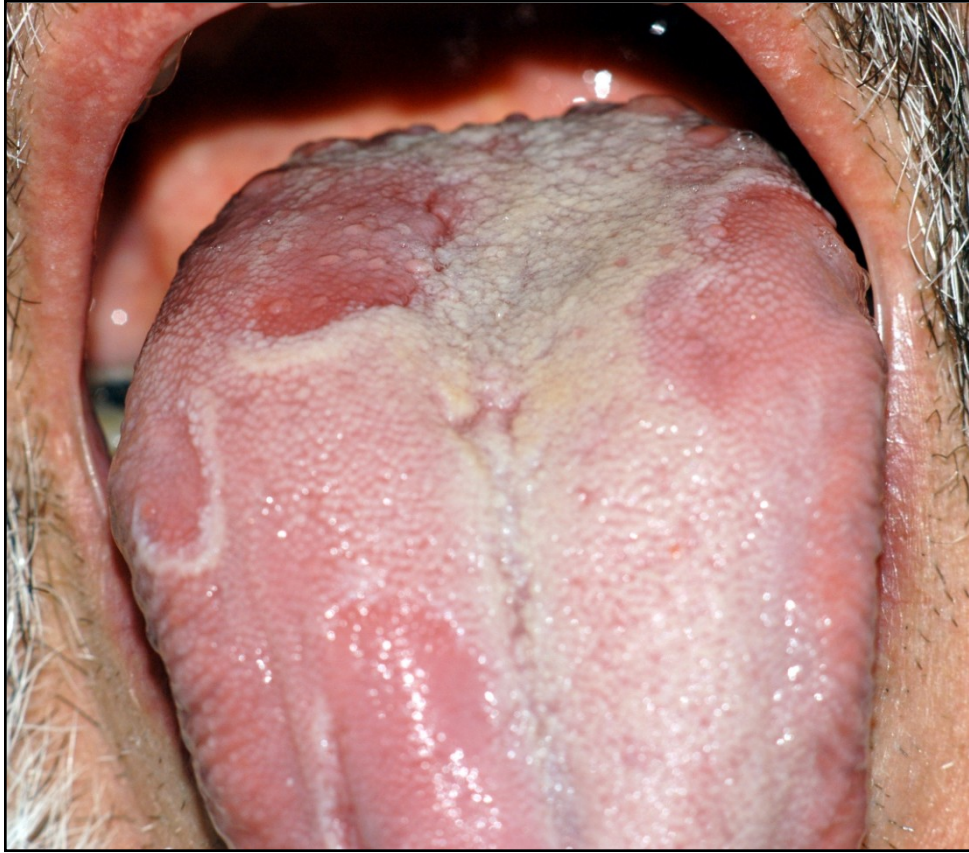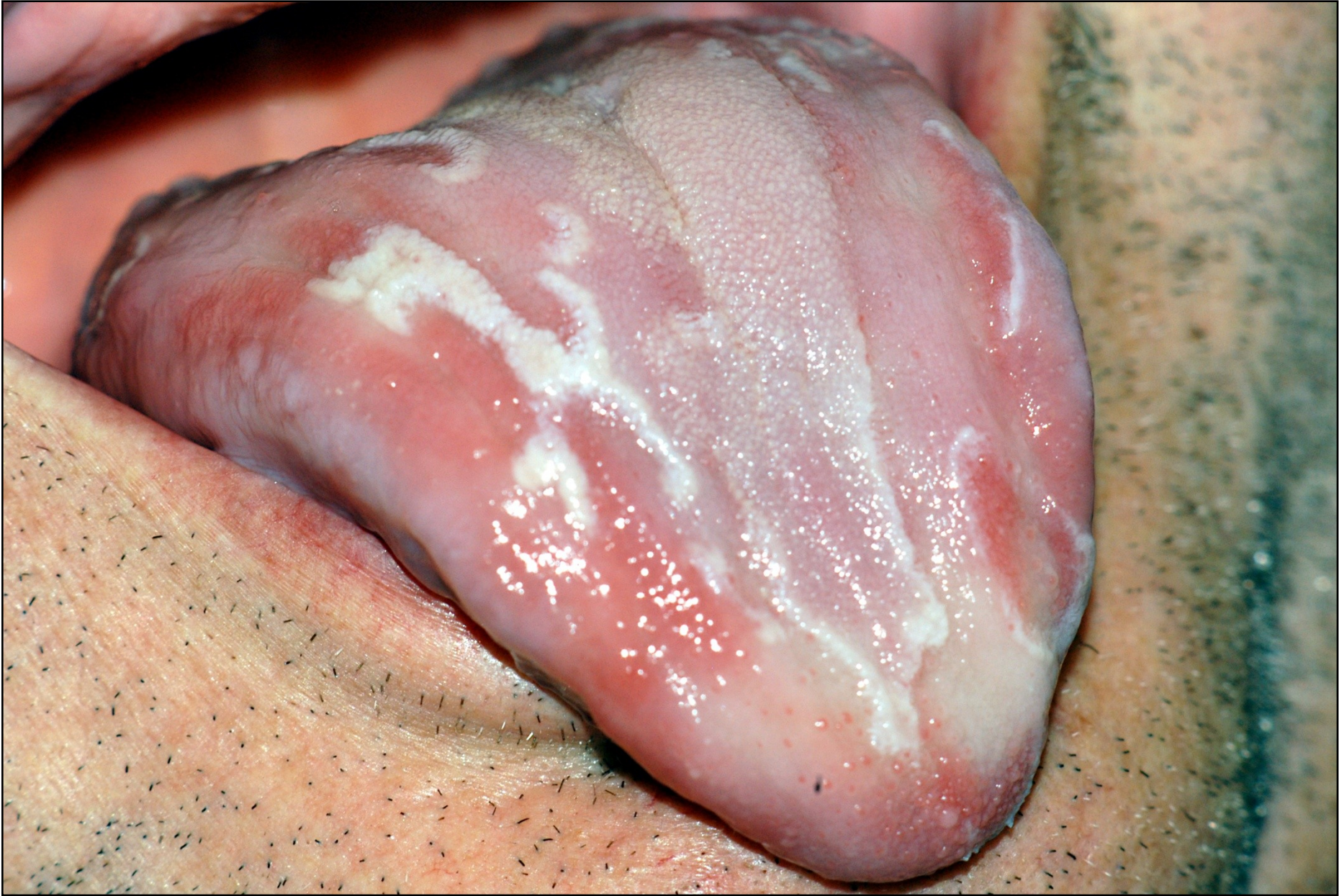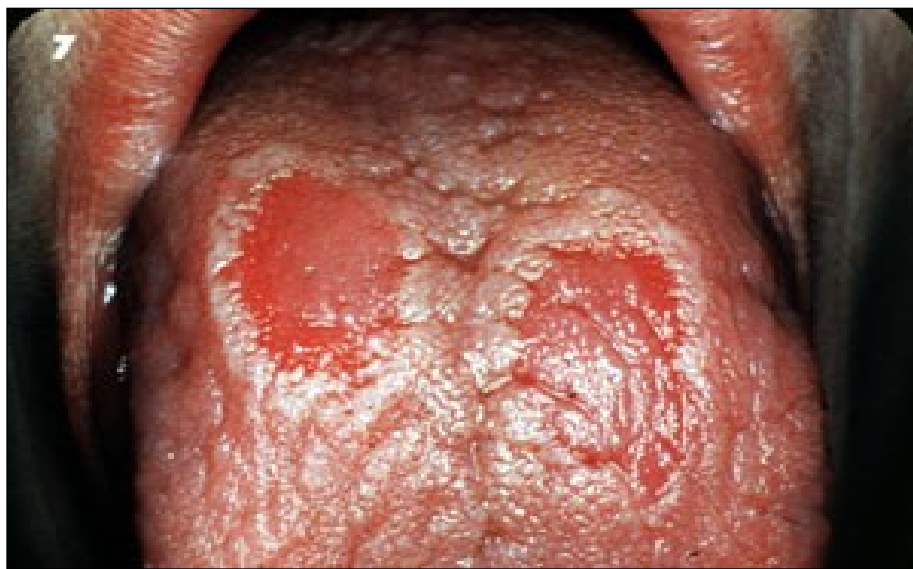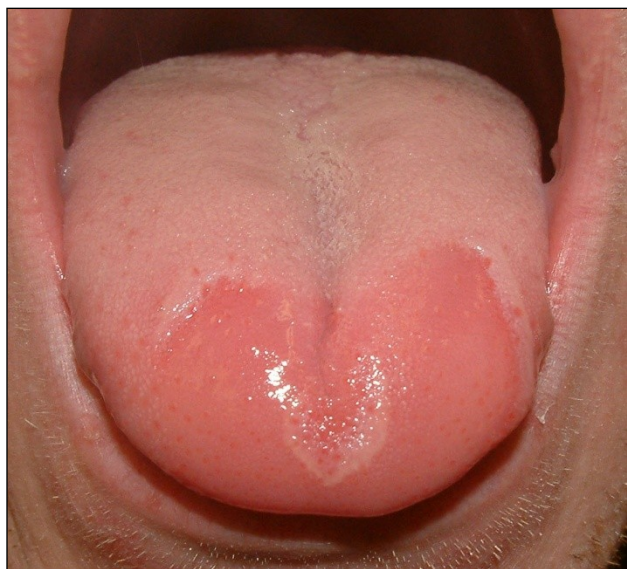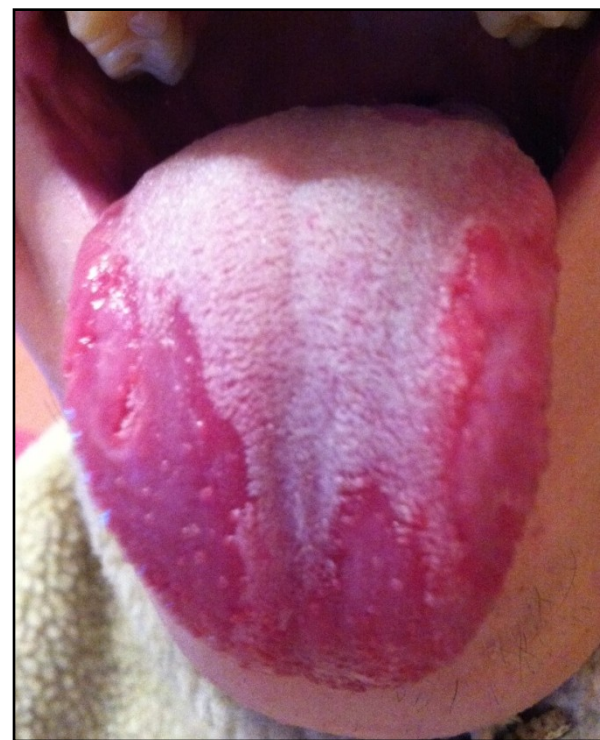
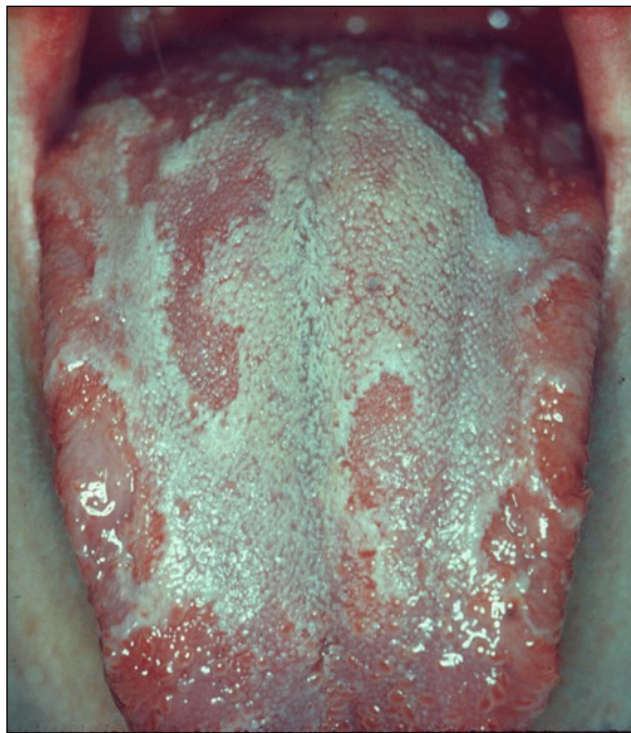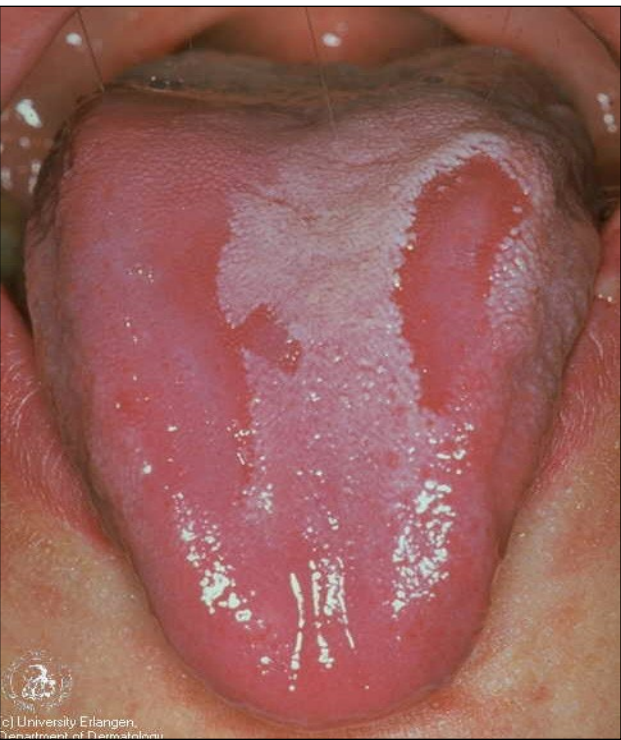Lingua
geografica

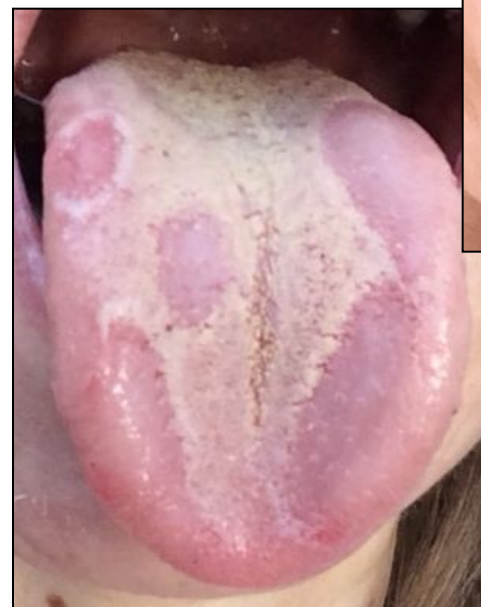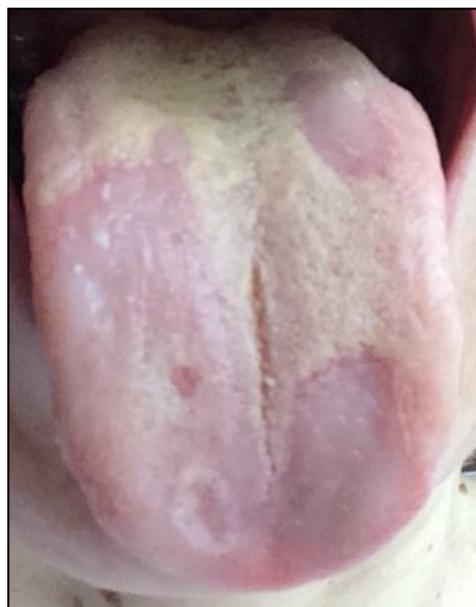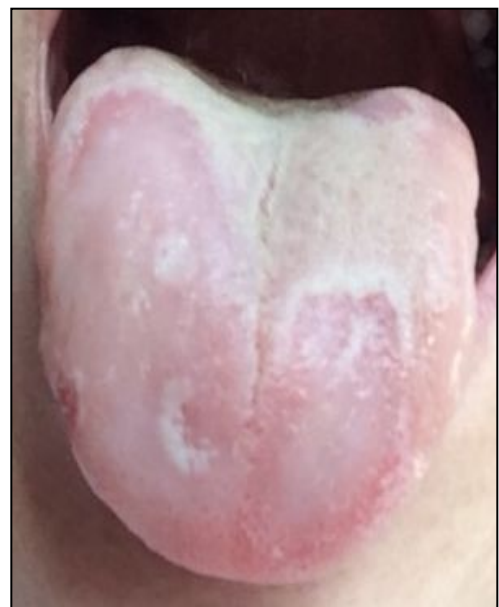
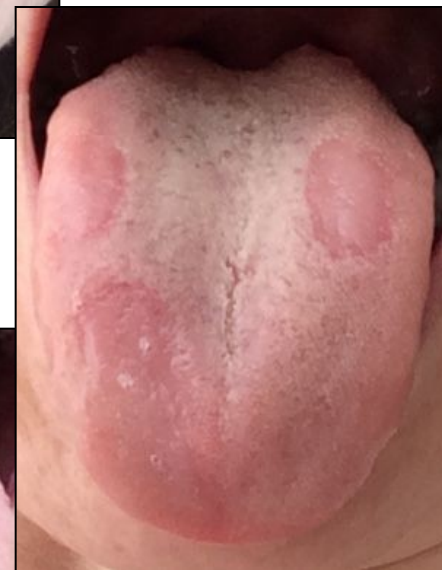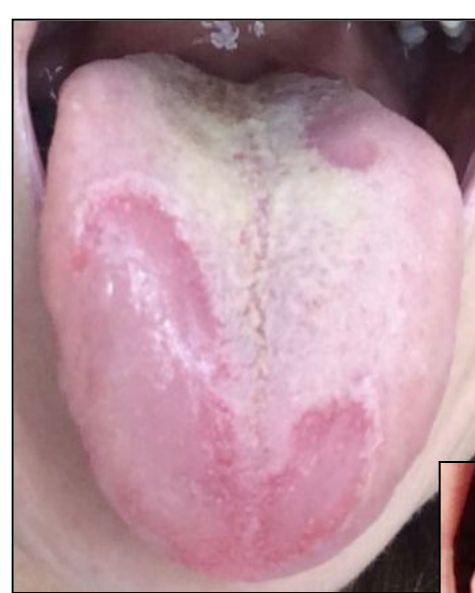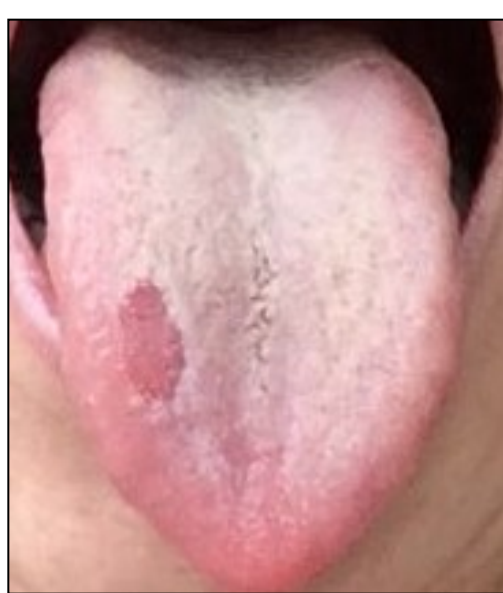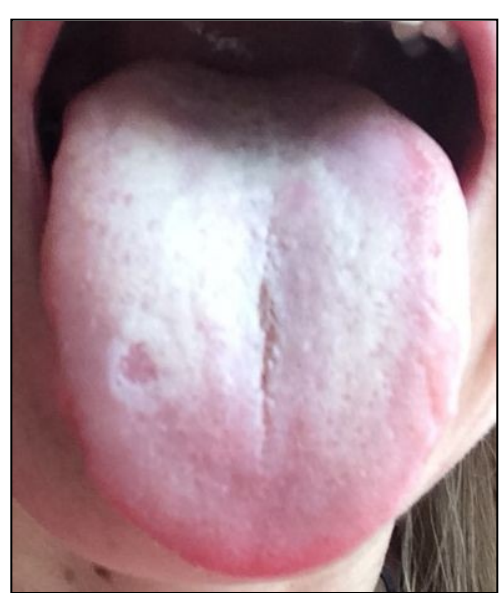


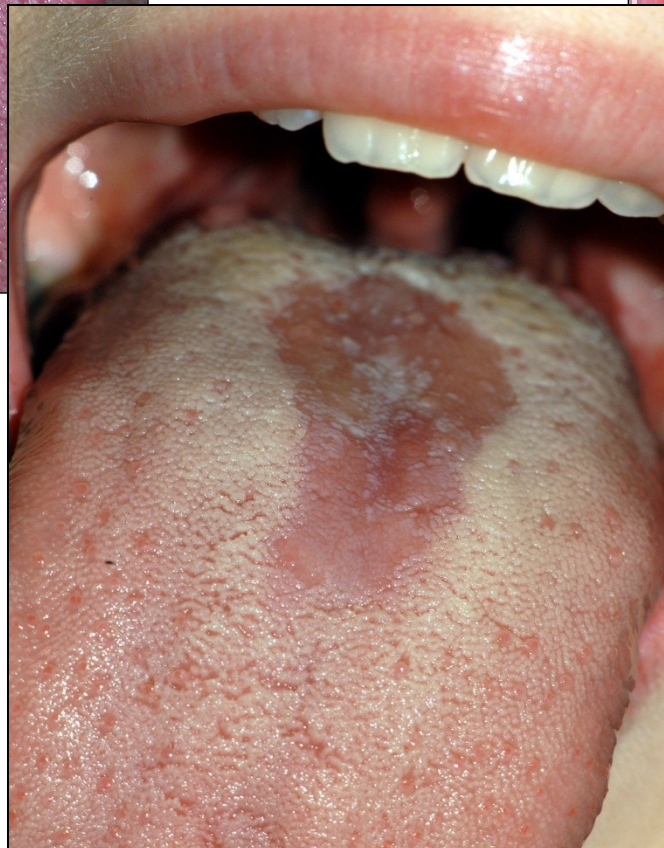




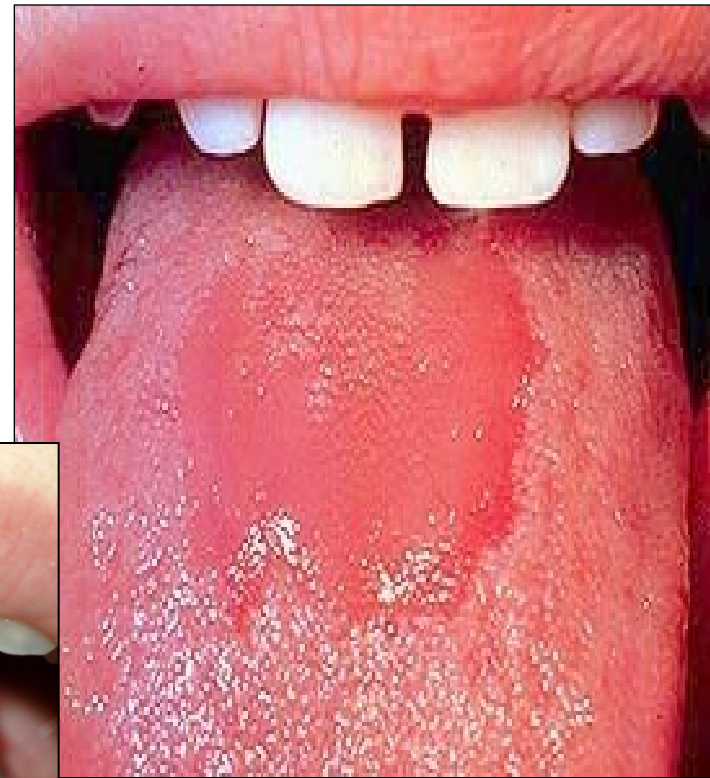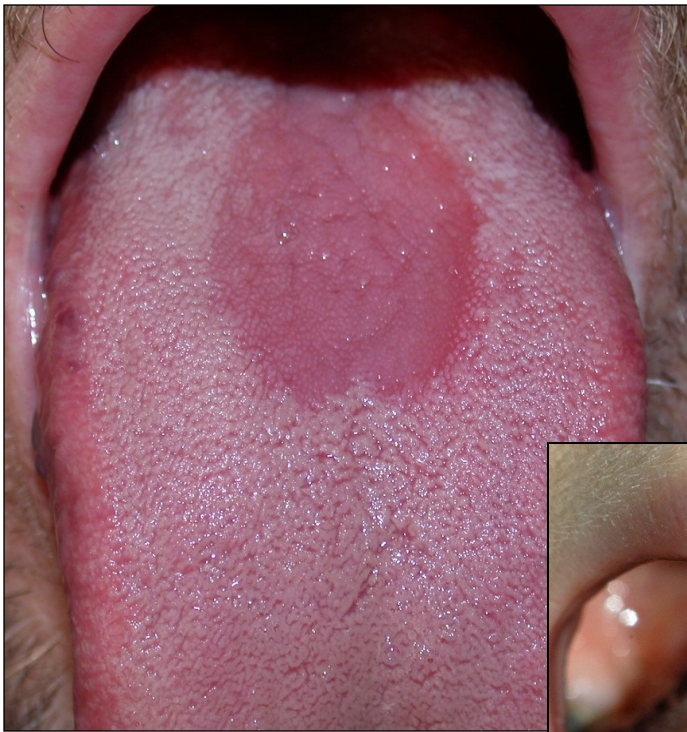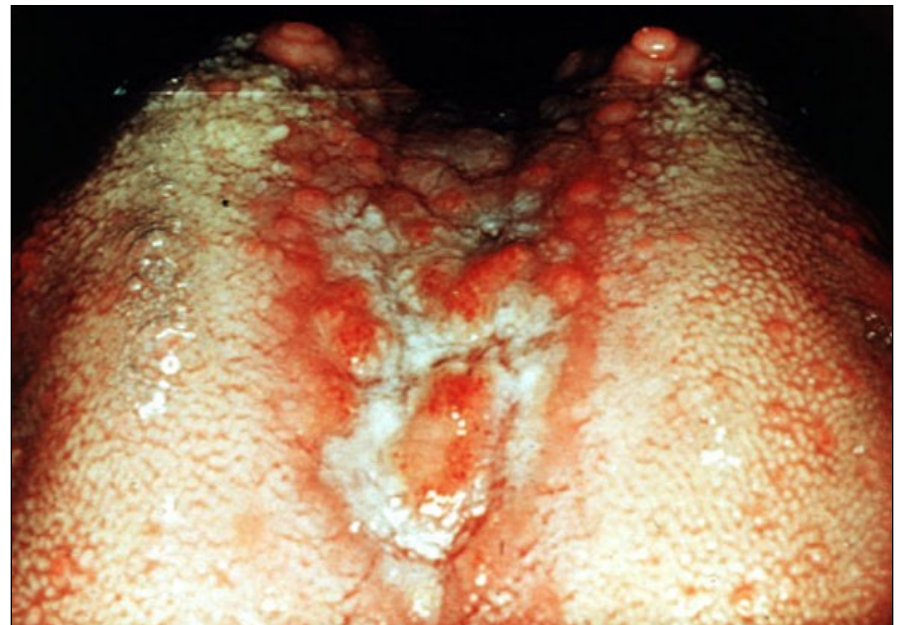







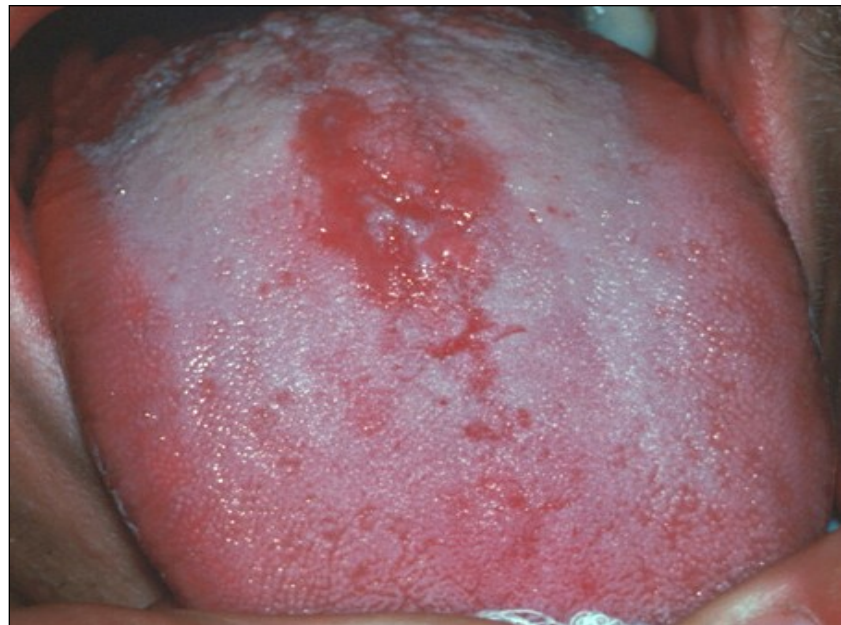
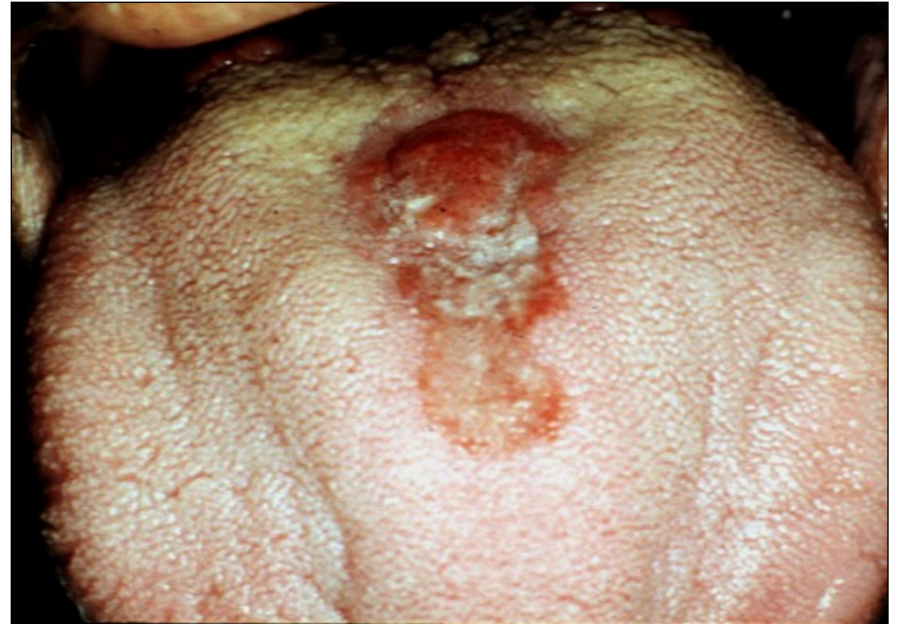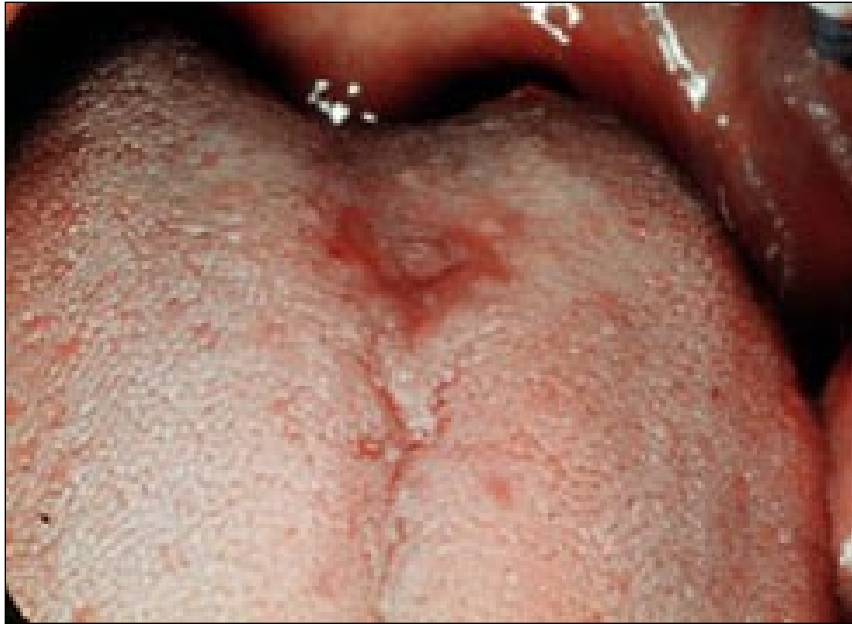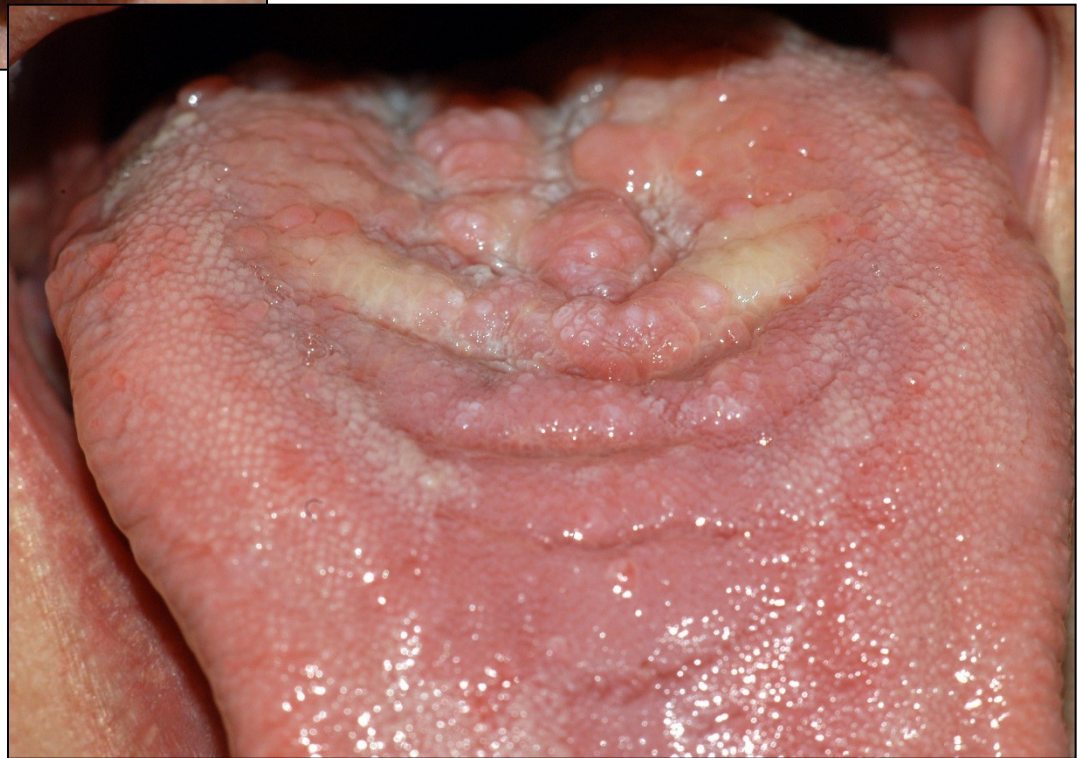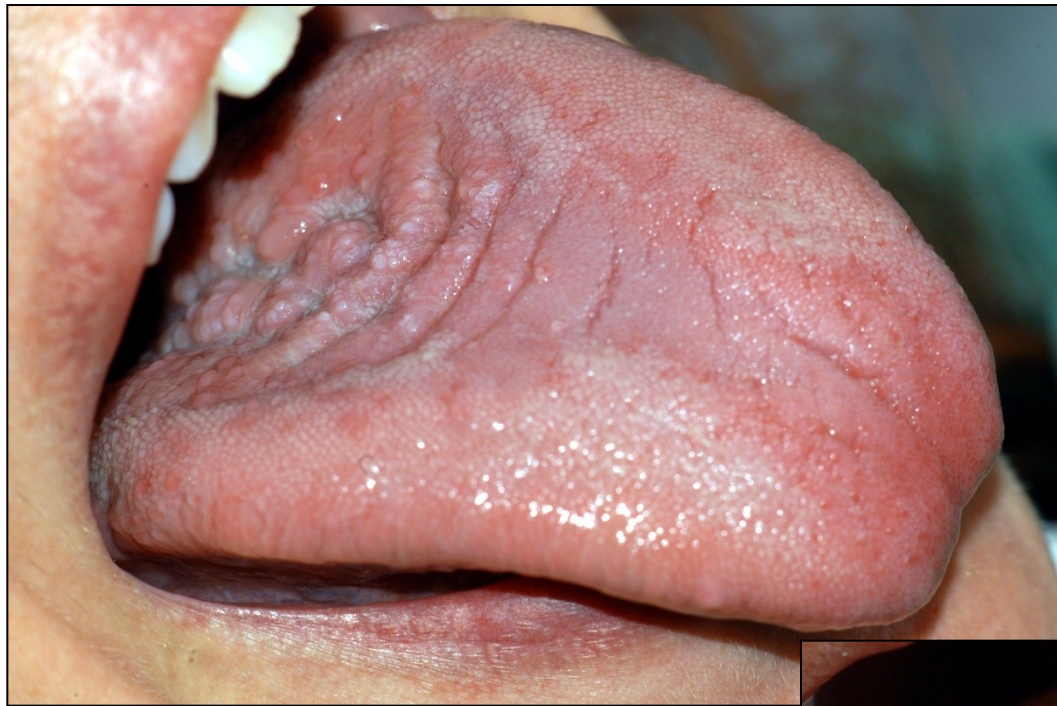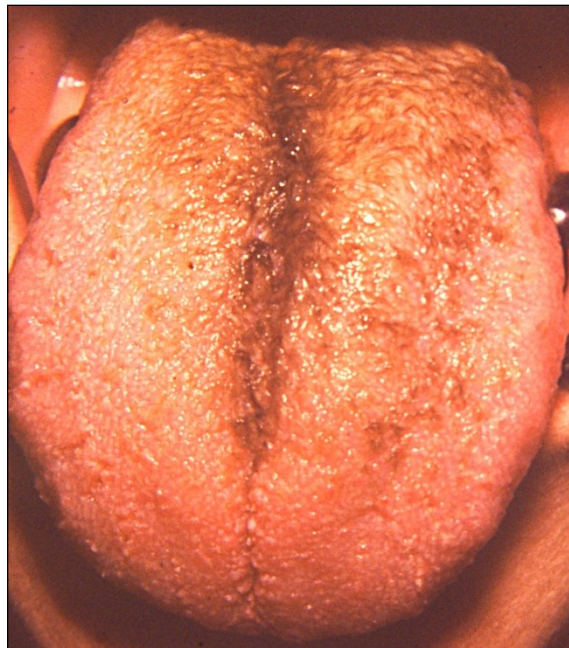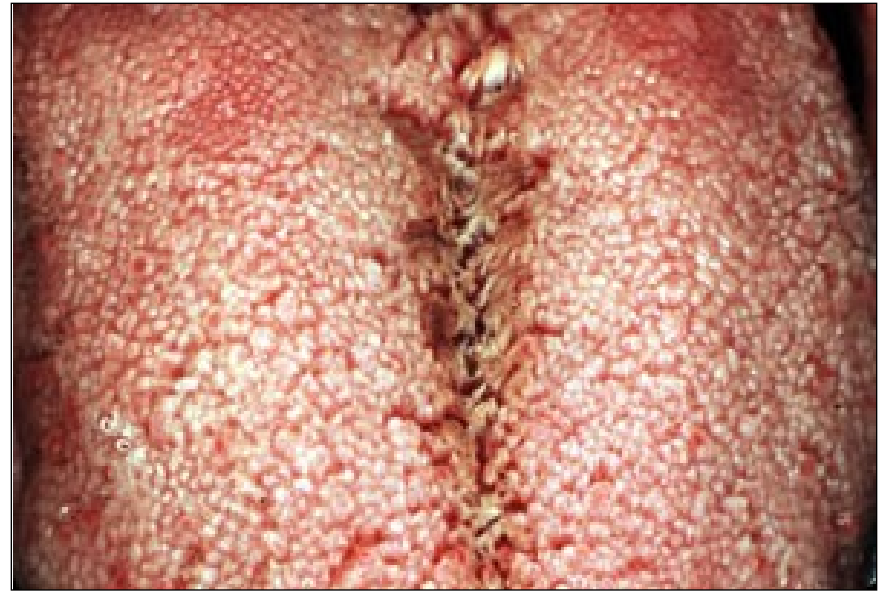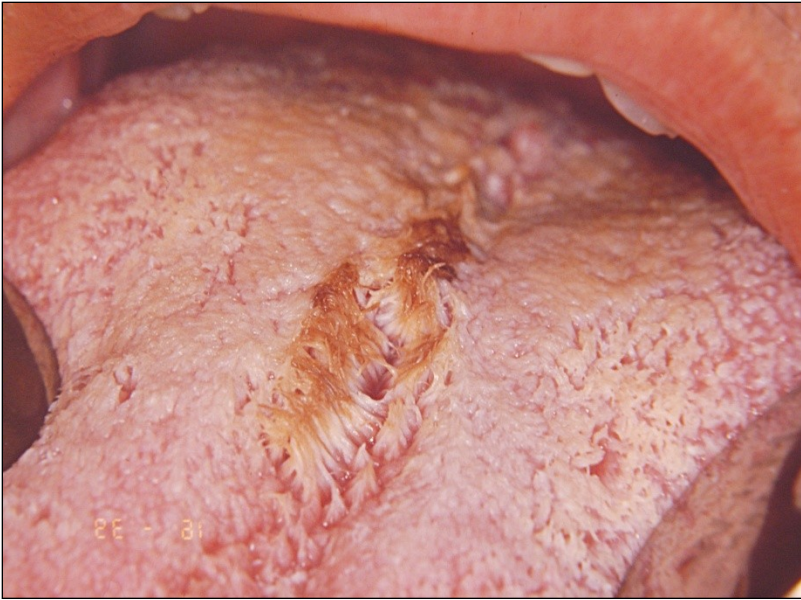Glossitis rhombica mediana – Rhomboid glossitis

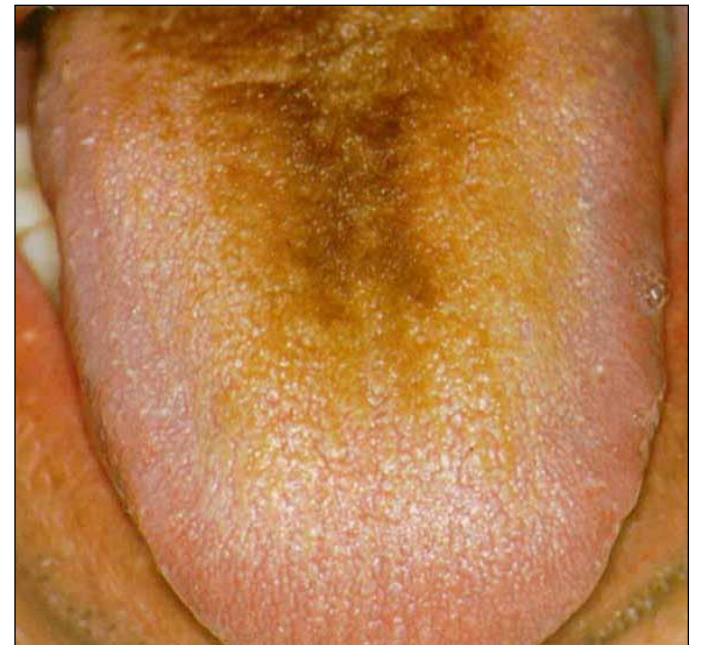


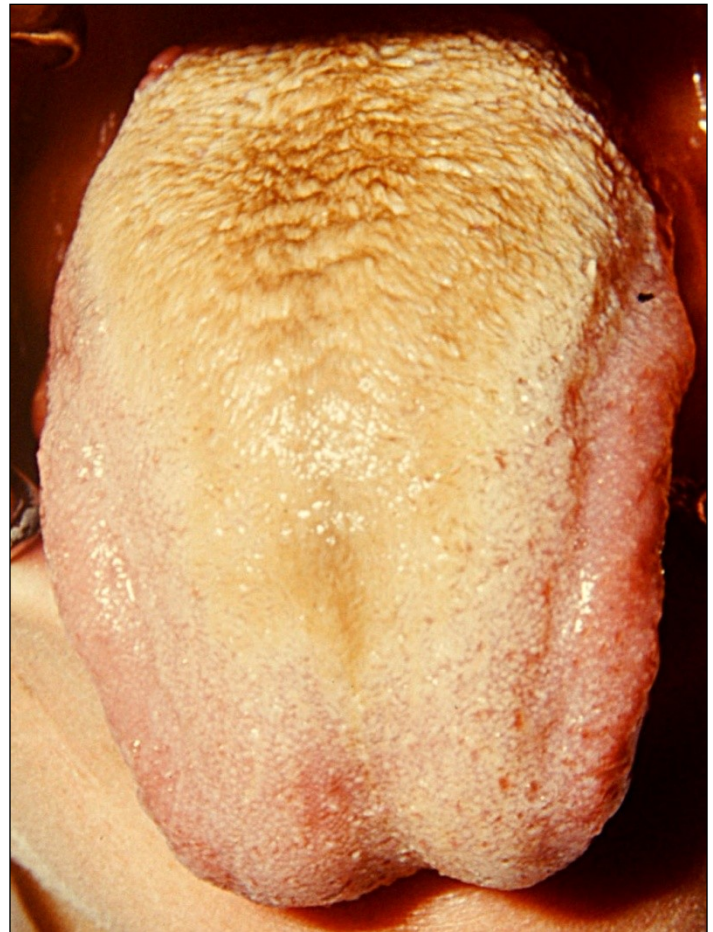
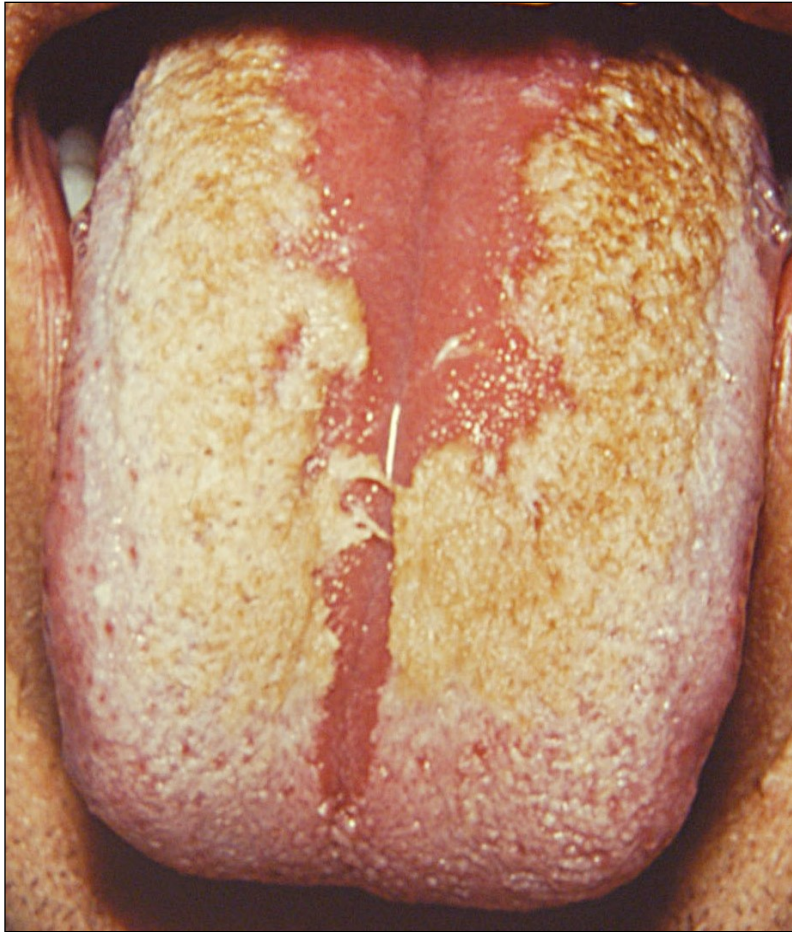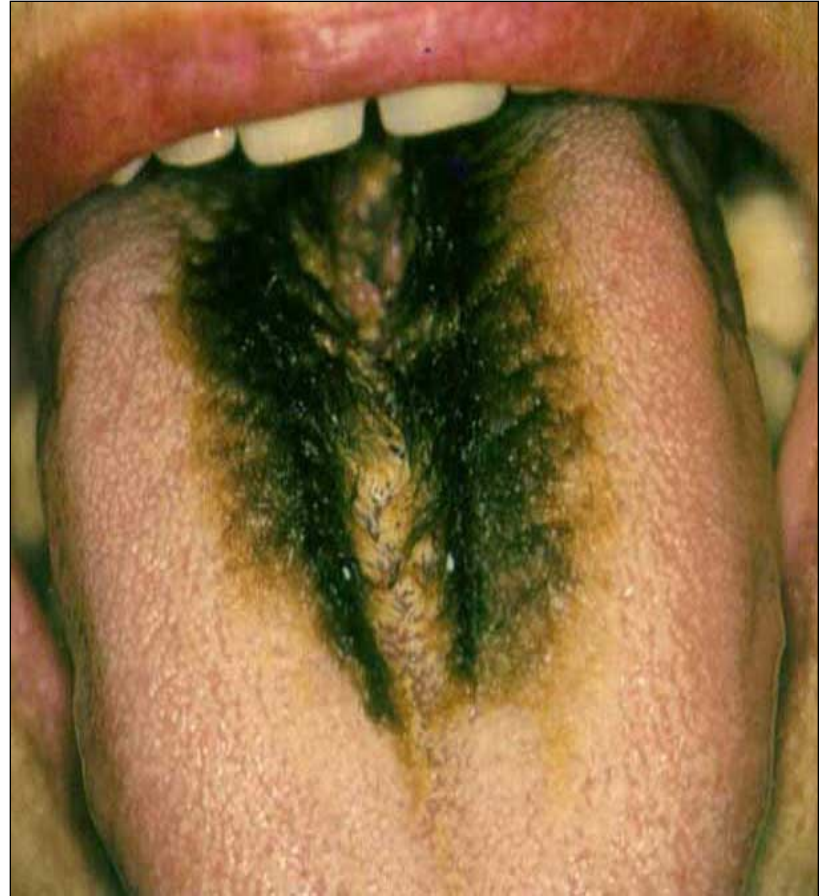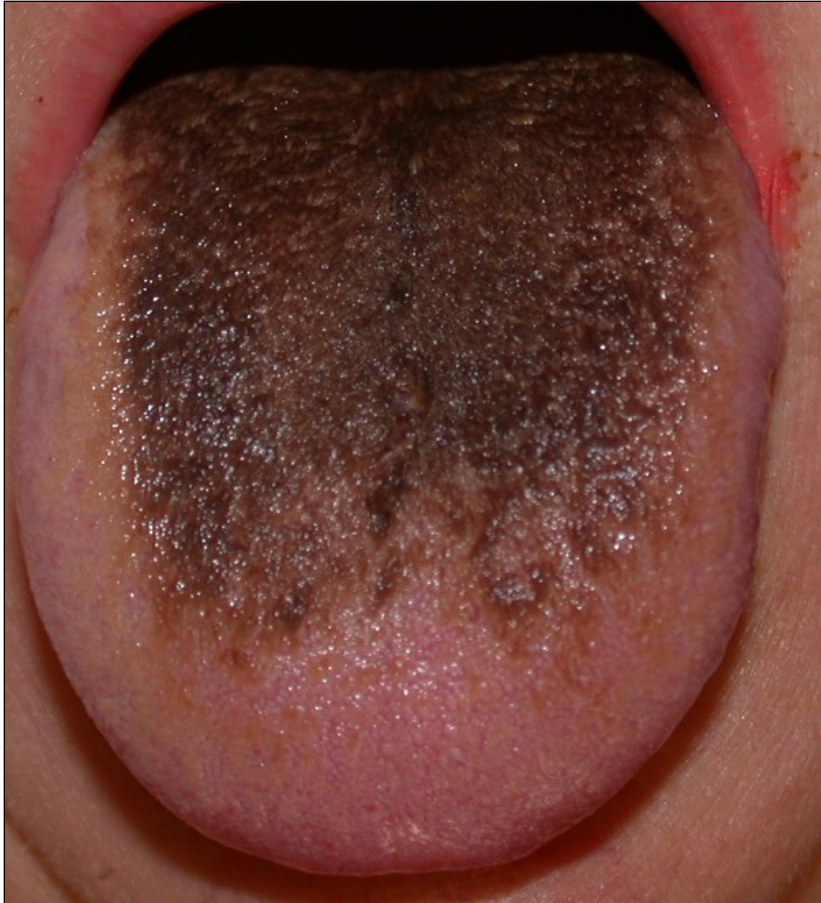P.Š. 1966

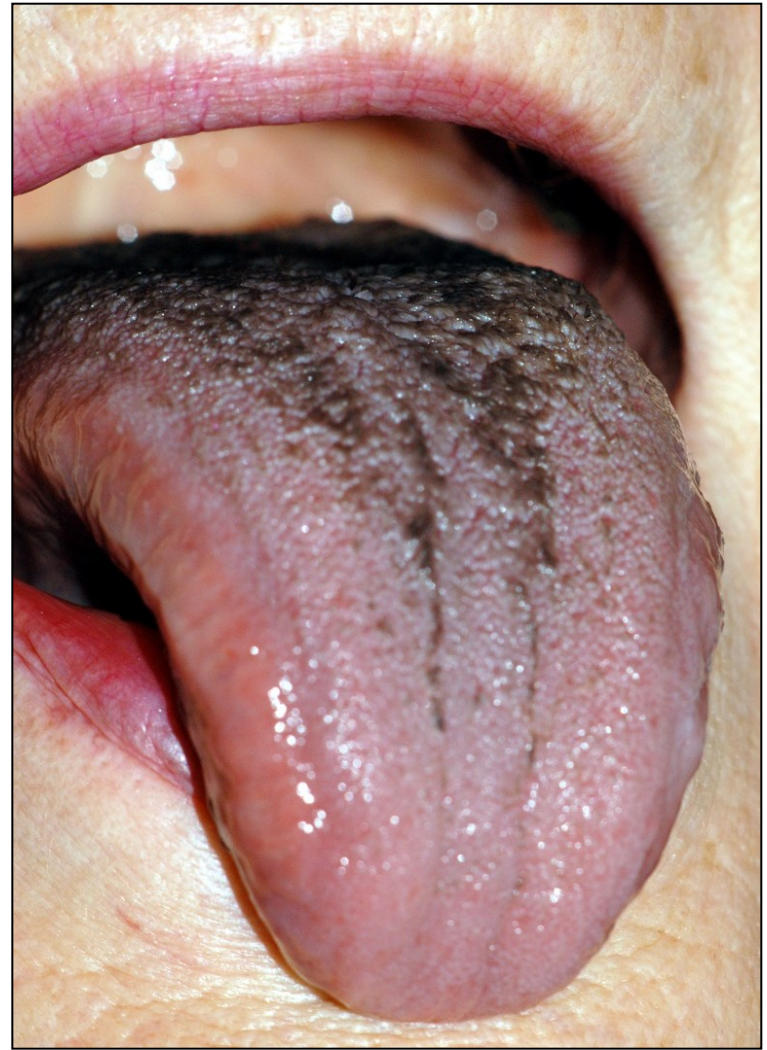
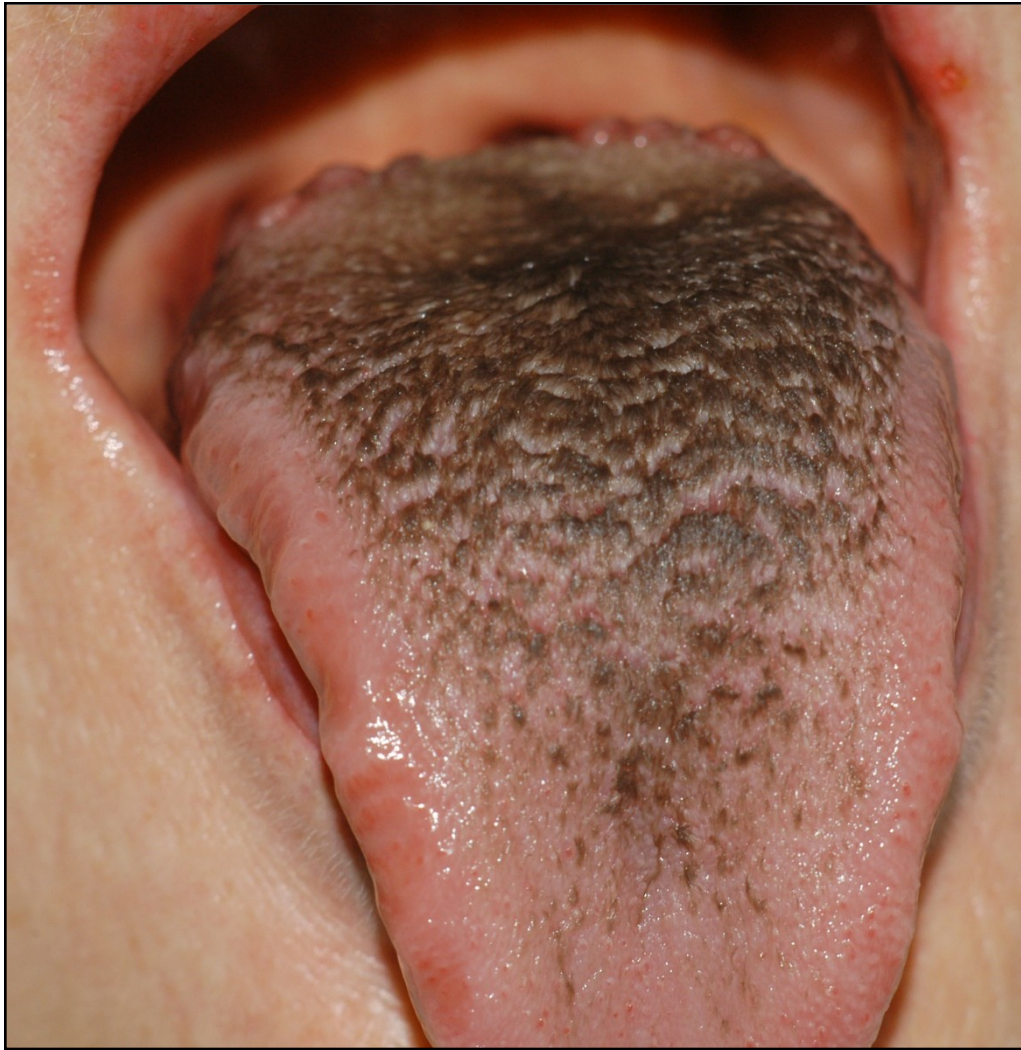
Lingua
villosa
nigra



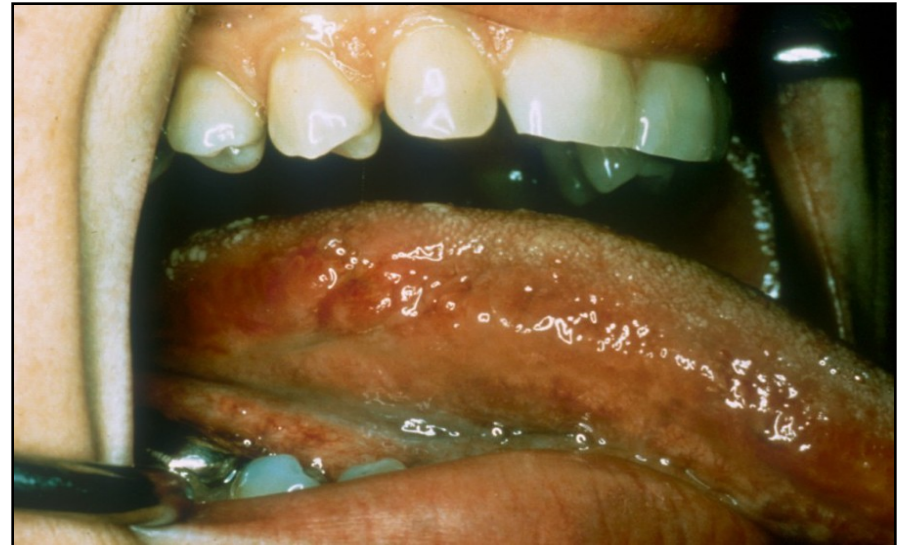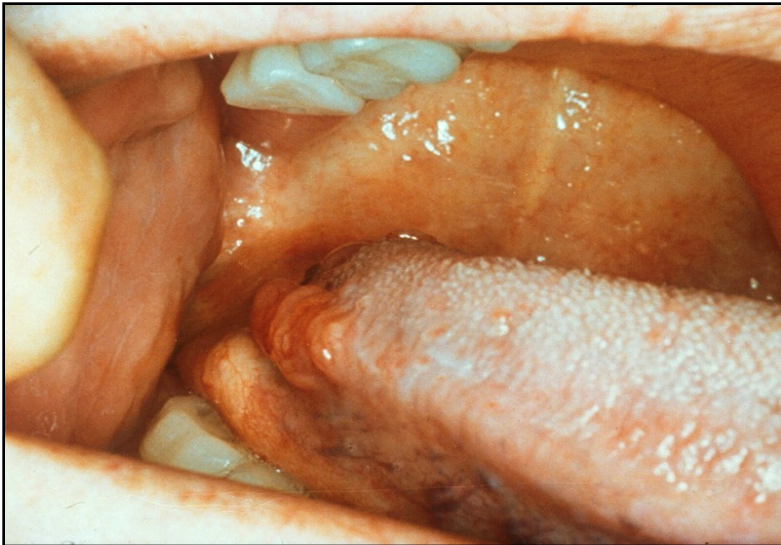






Local changes of the tongue

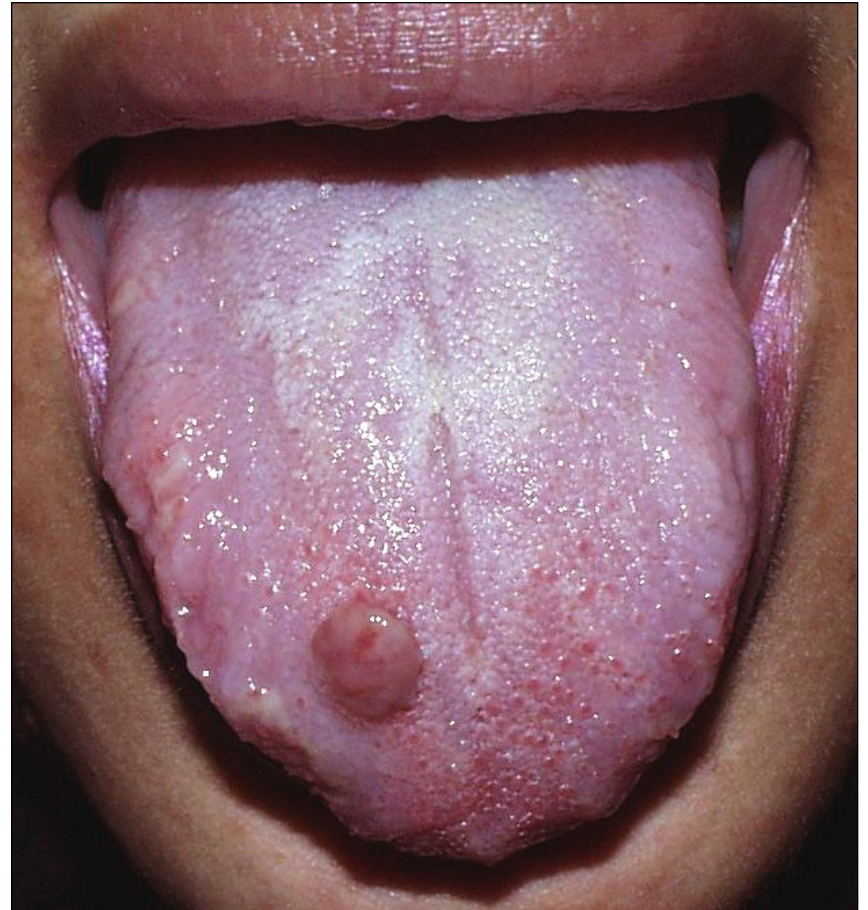
- **Tonsila lingualis**
- Lingual thyroid gland
- Cyst ductus thyreoglossus
- Dermoid and epidermoid cyst (floor of mouth and body of the tongue, macroglossy)

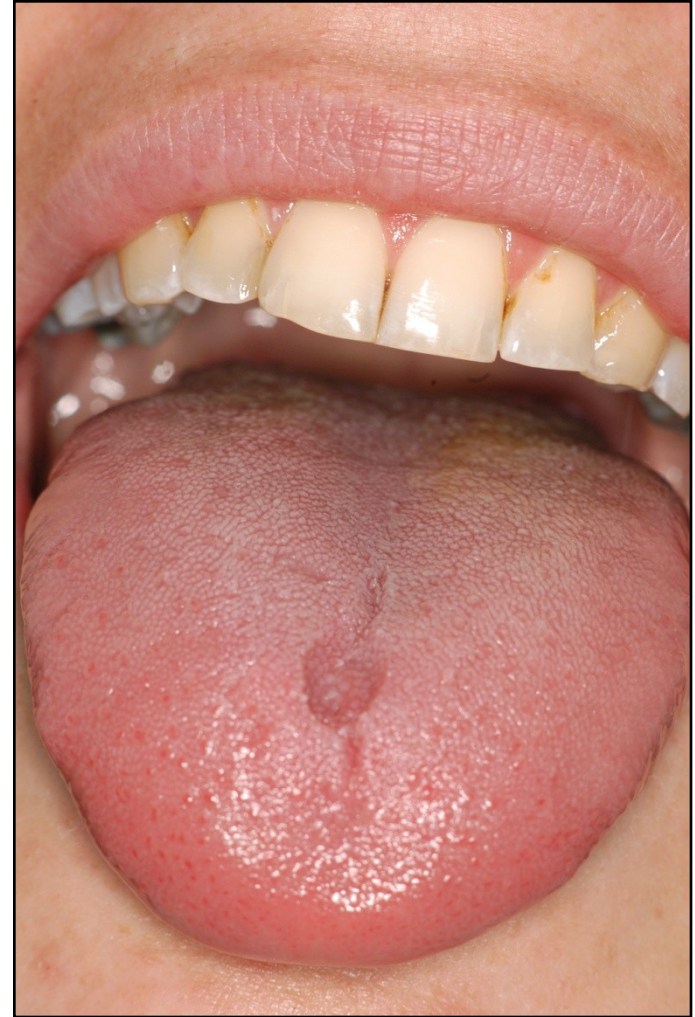
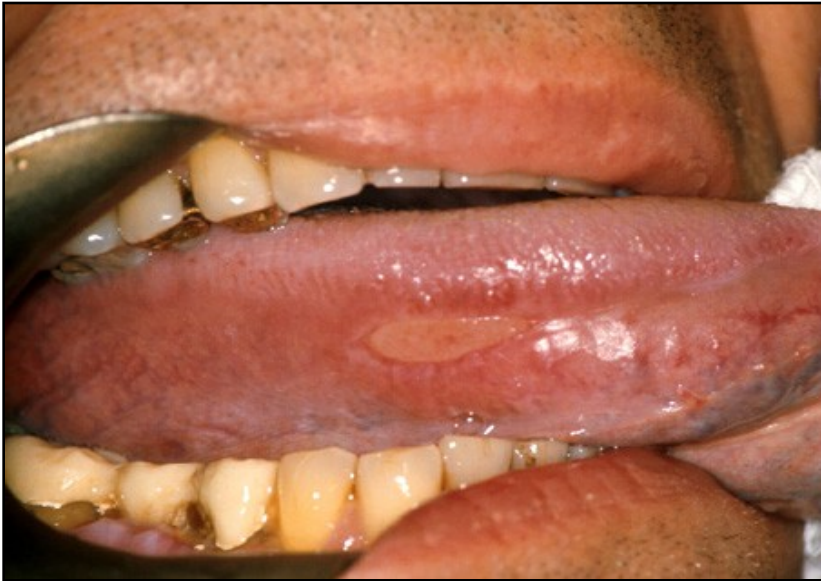
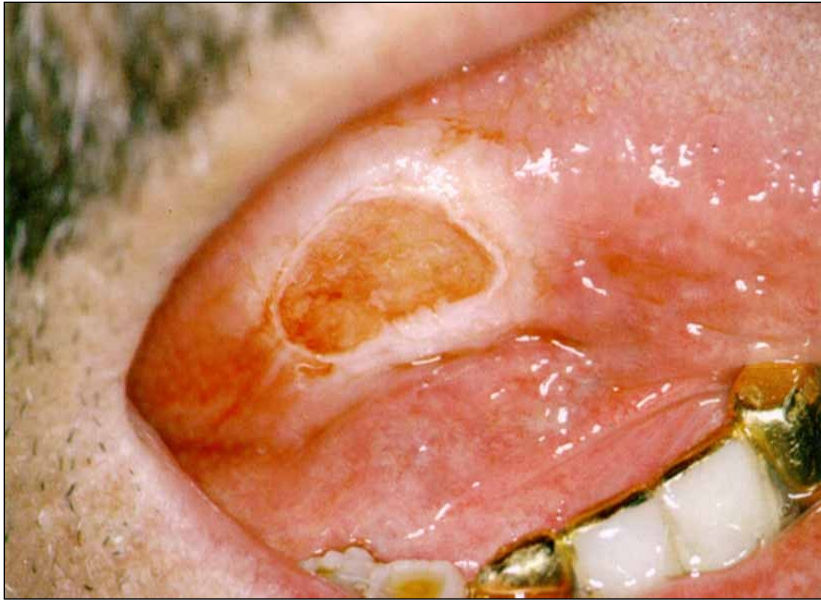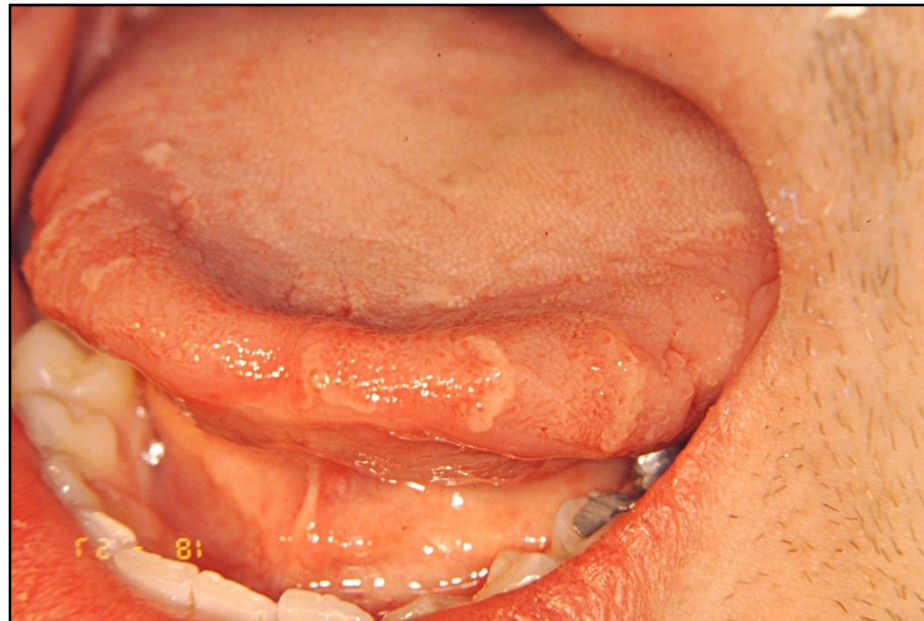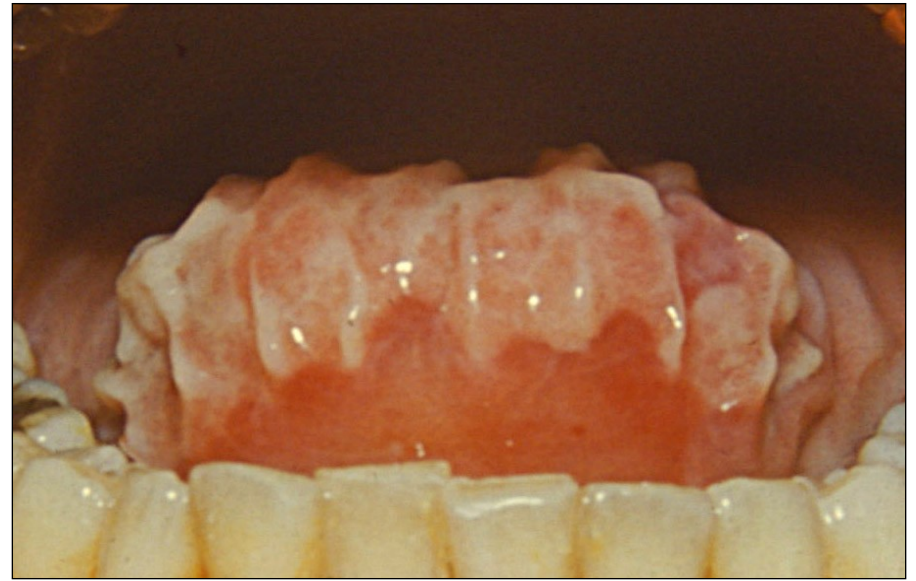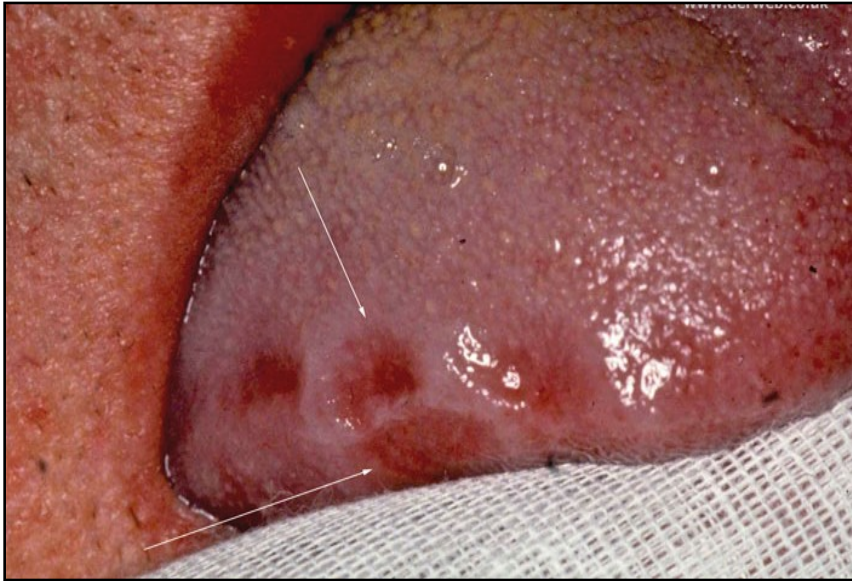Local changes of the tongue

Mechanical factors

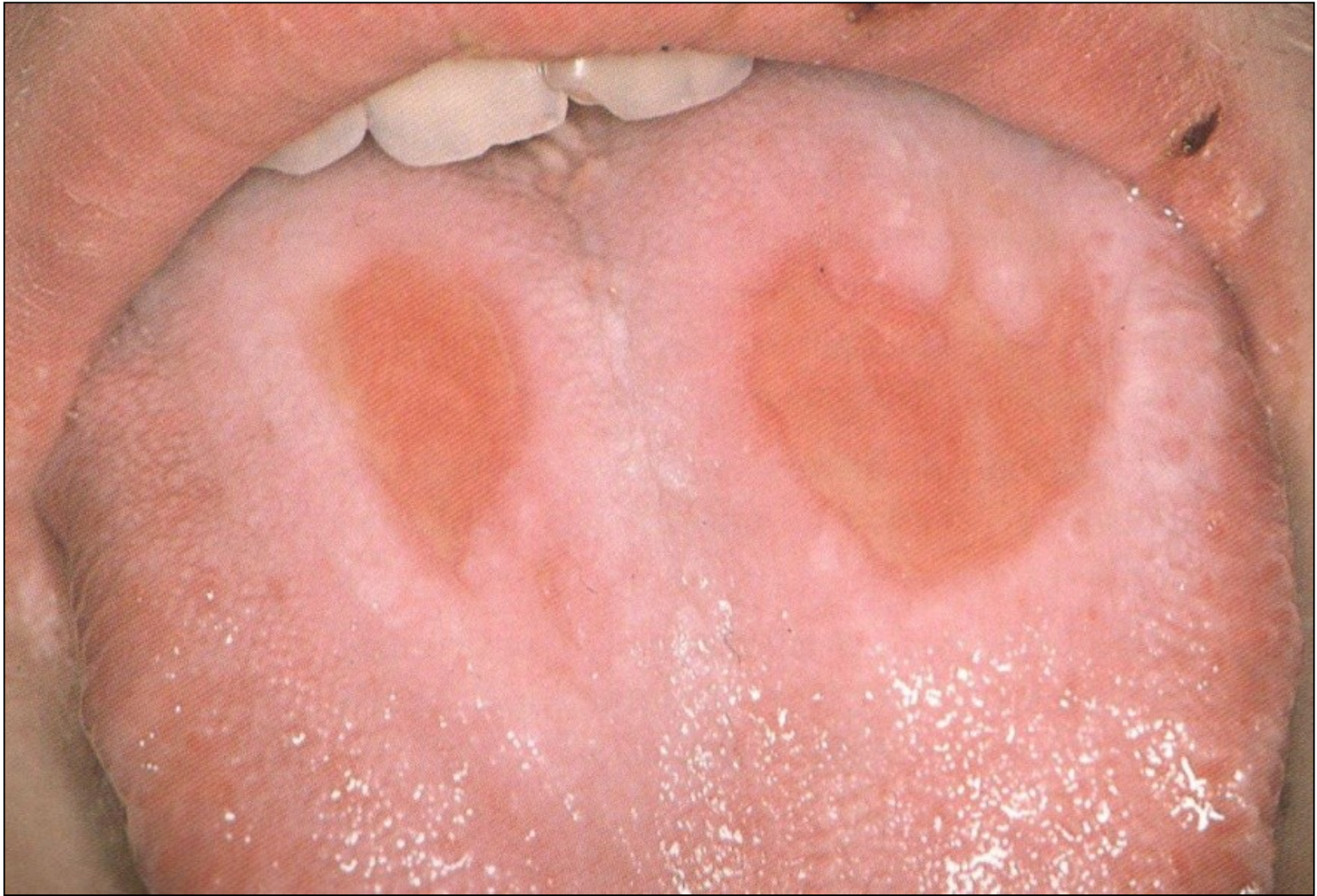- Traumatic ulcer
- Impressions
- Granuloma pyogenicum



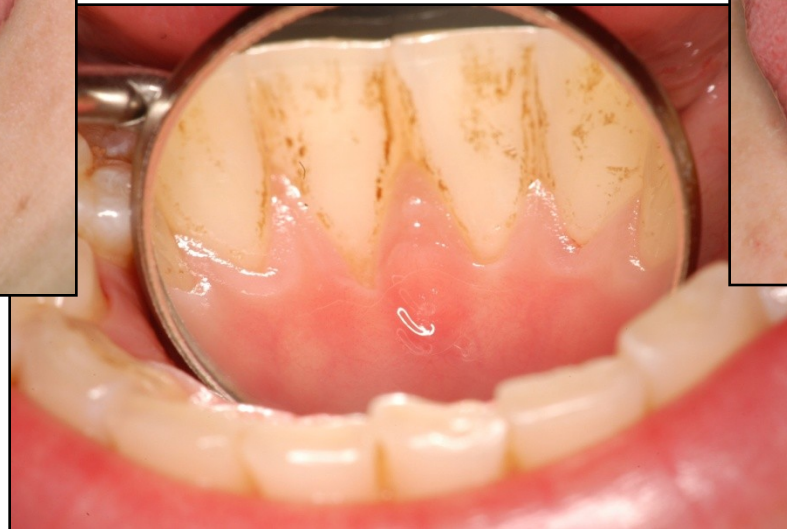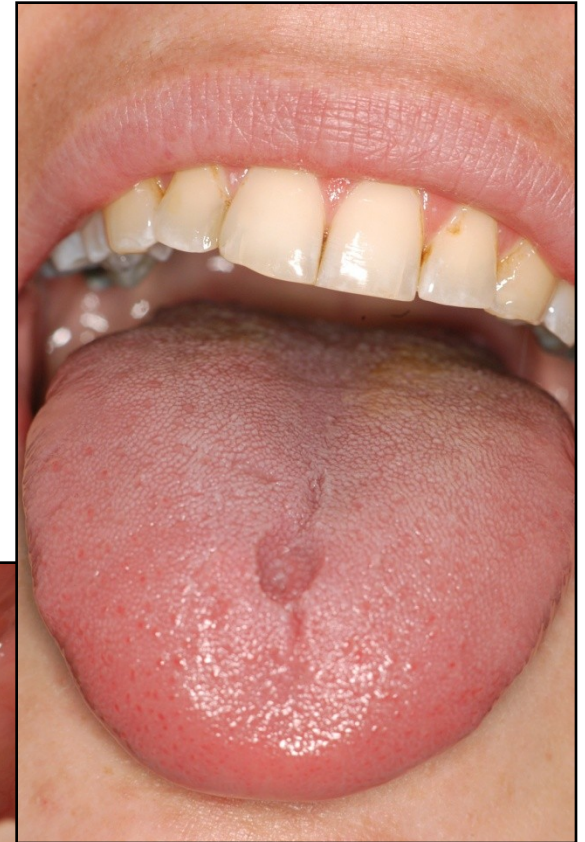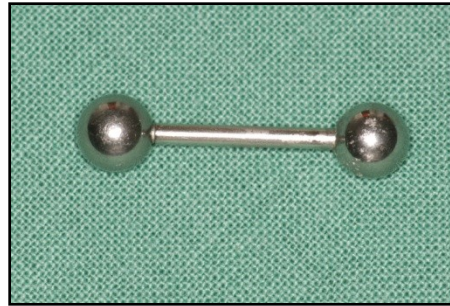


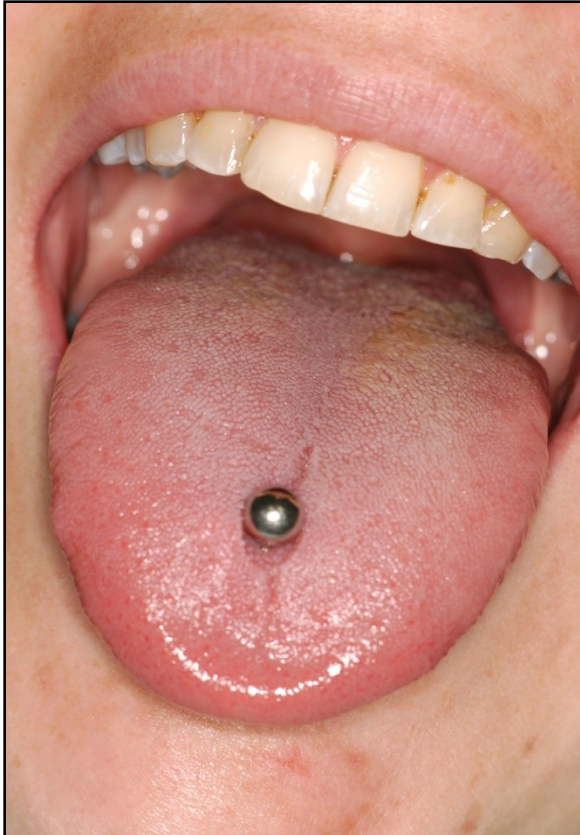

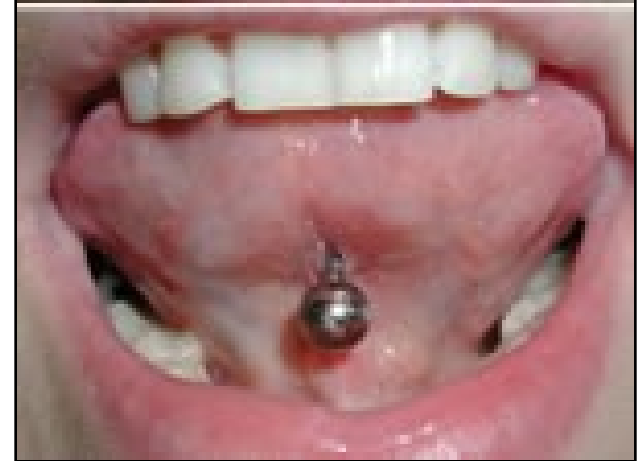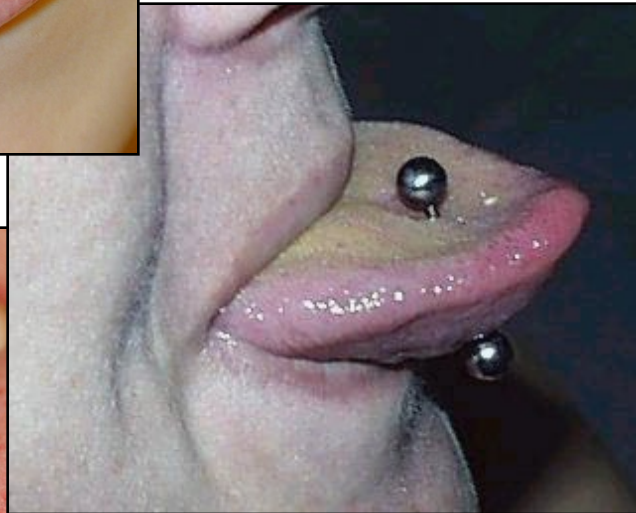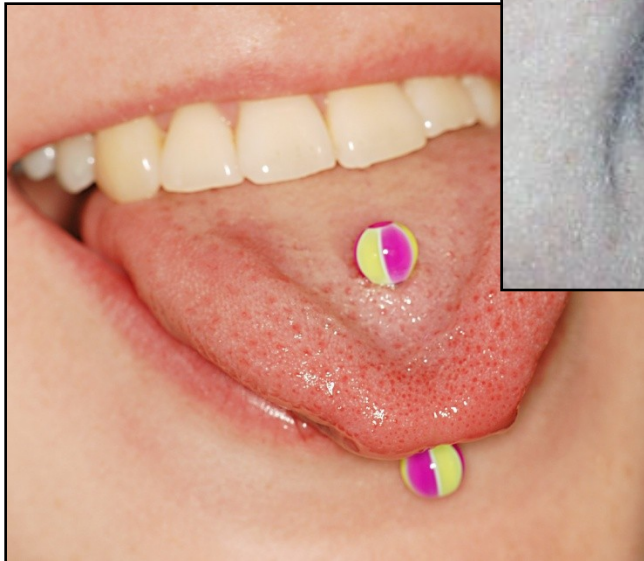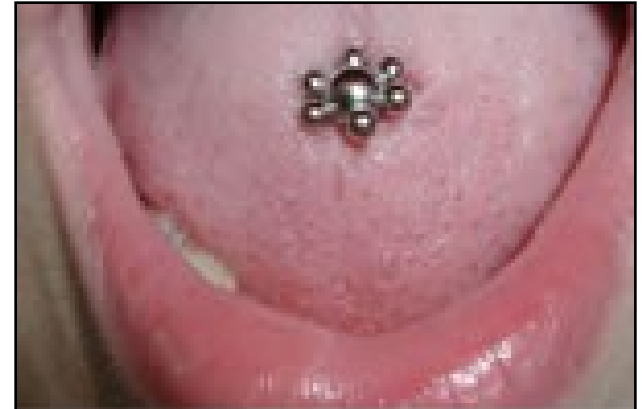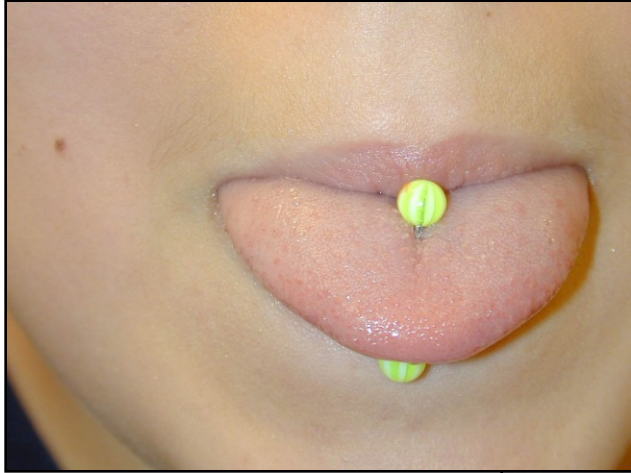
Burn of the tongue with hot food



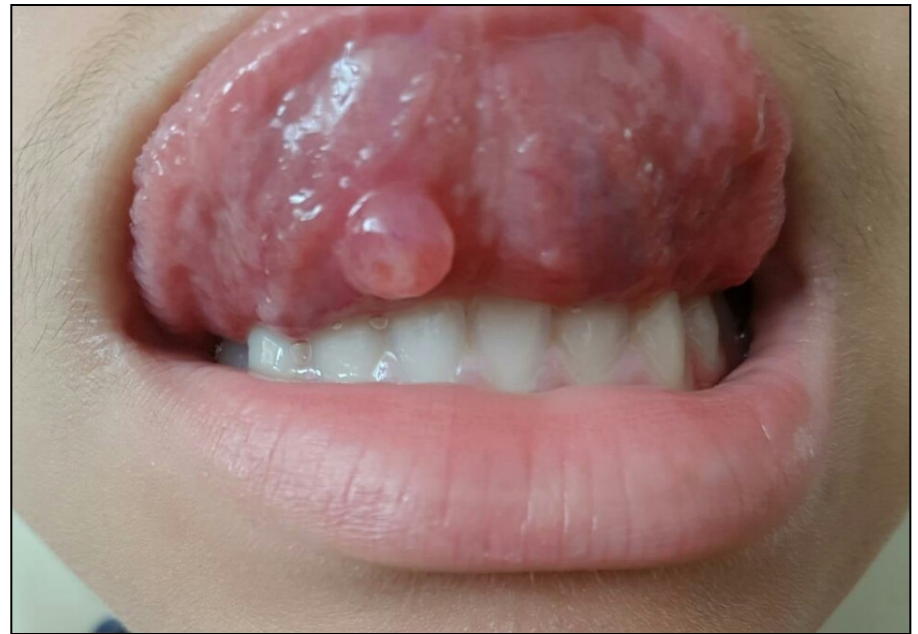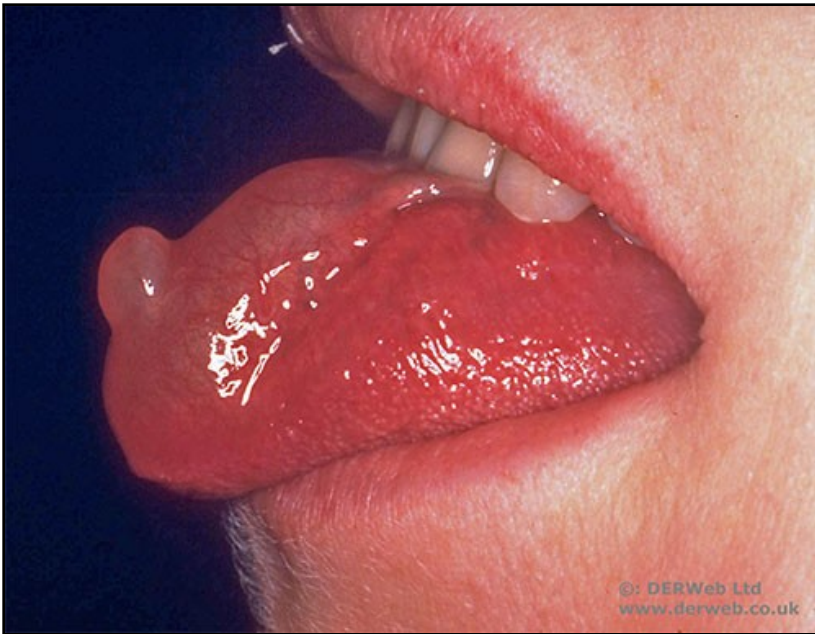Oral piercing



Oral piercing

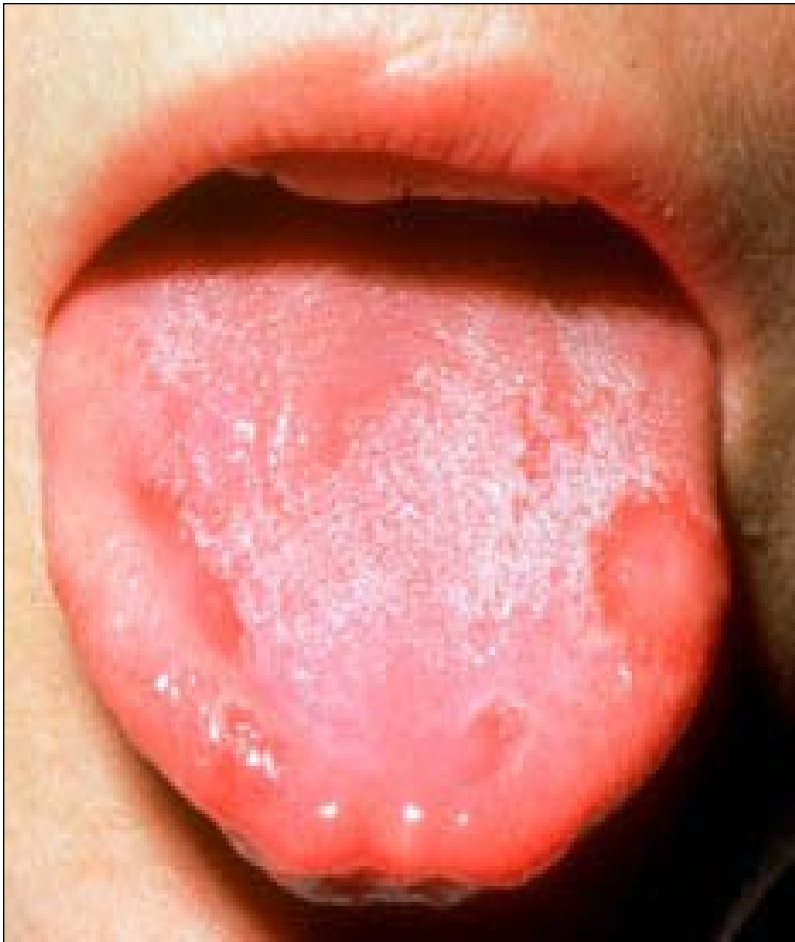

Local changes of the tongue



Retention cyst (mucocele) of minor salivary gland

Local changes of the tongue

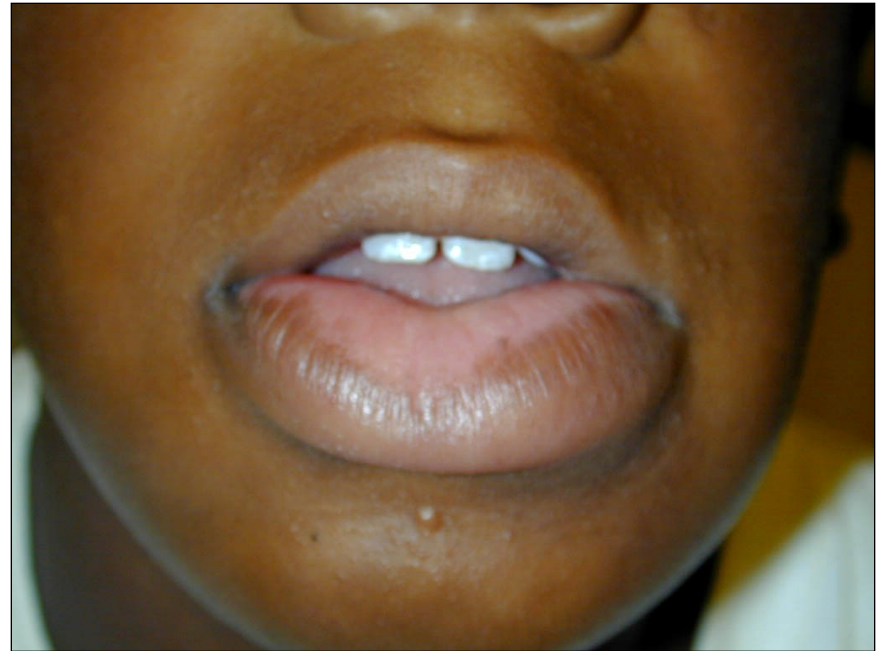
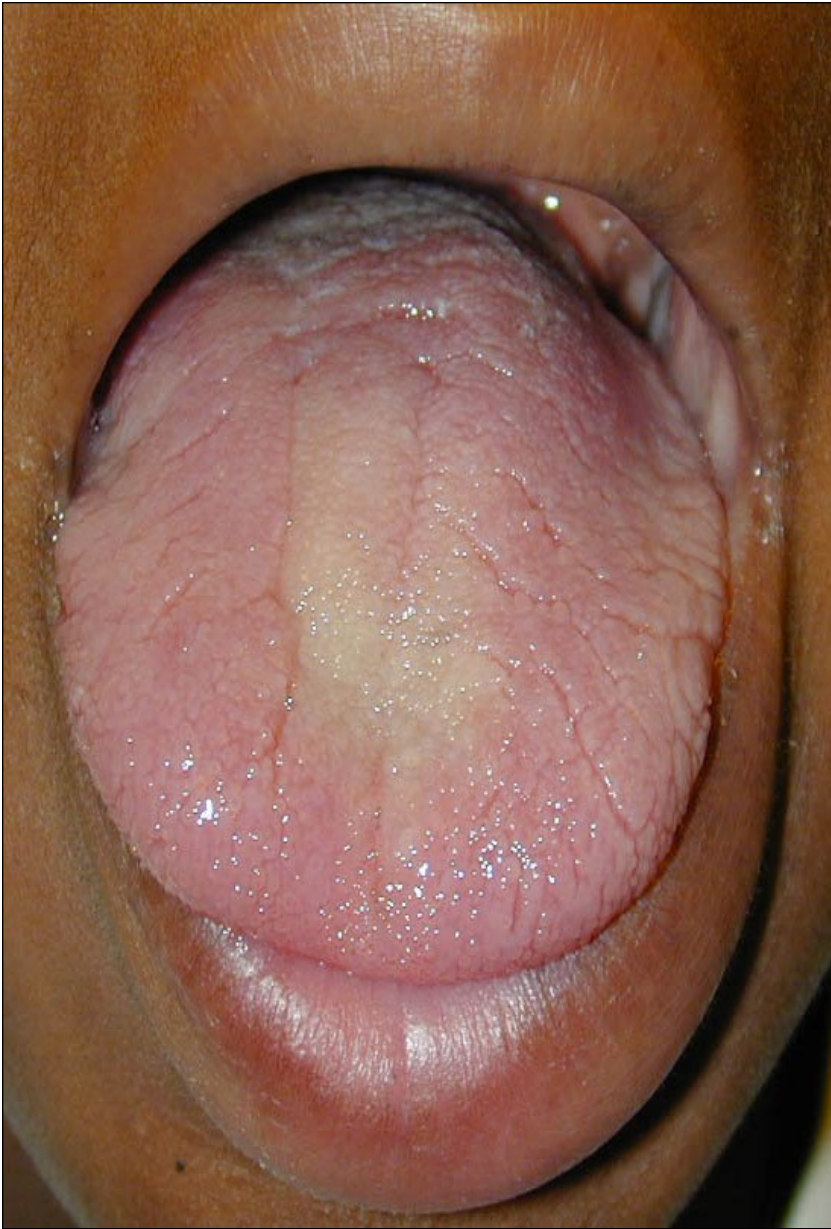
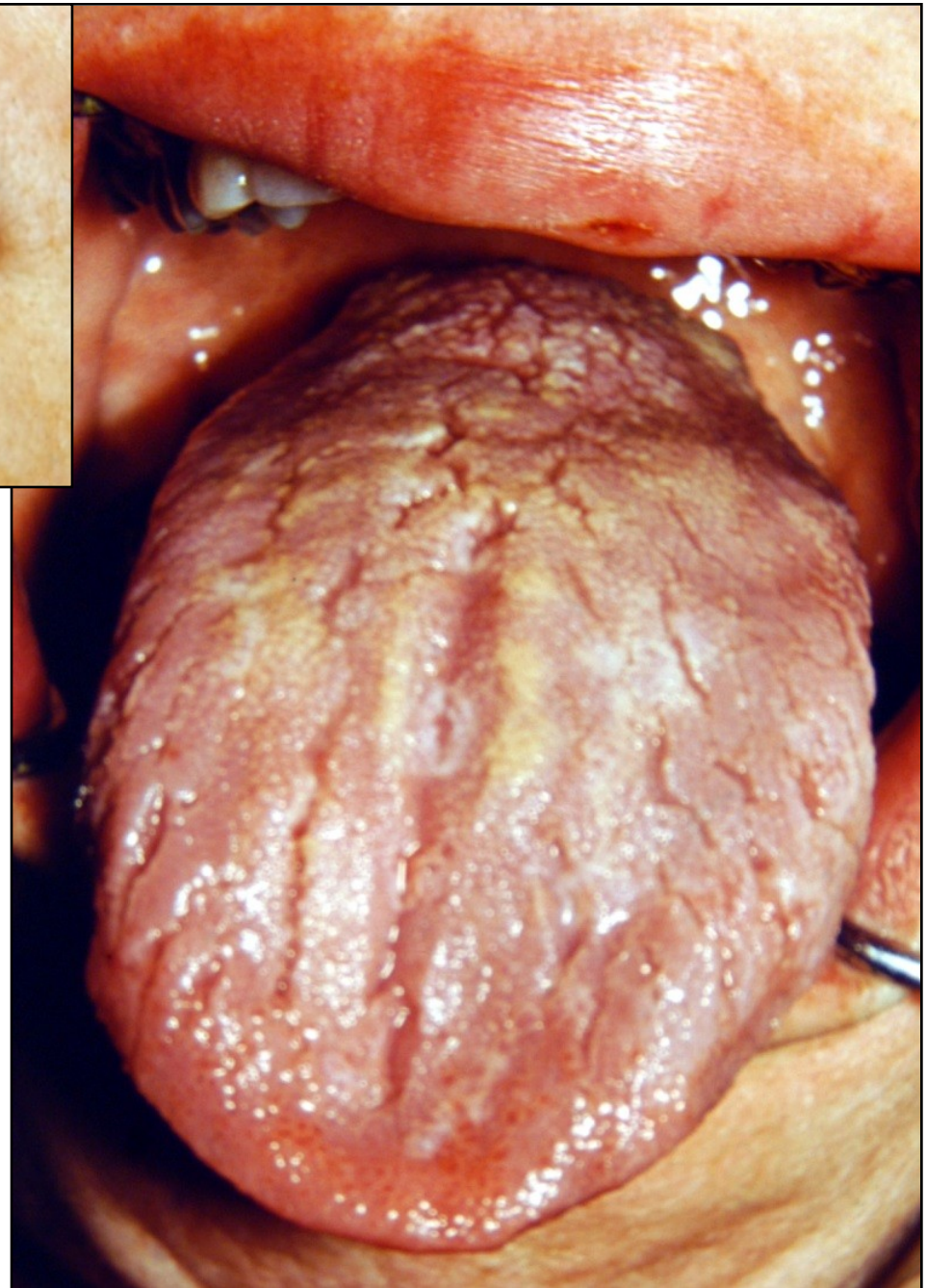
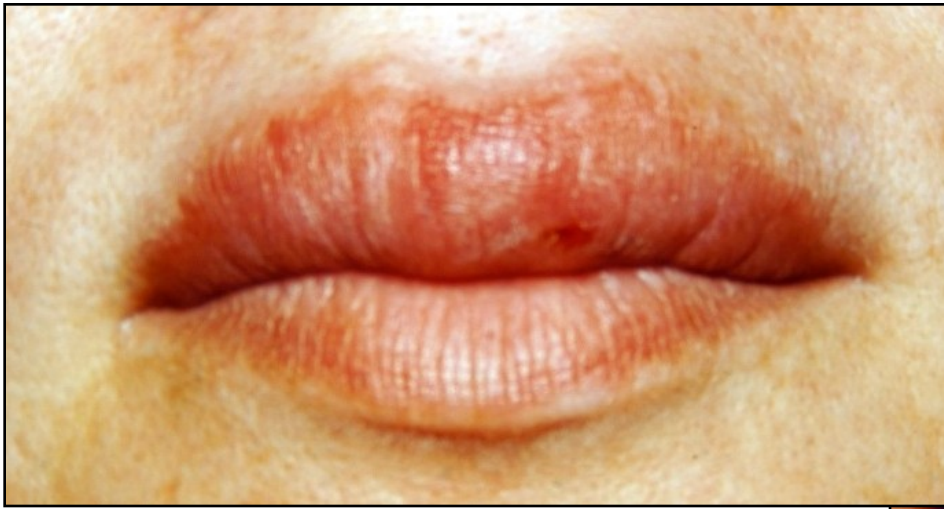Aphthous ulcers

- lateral, ventral side
- dorsum (major form)

Melkersson -Rosenthal syndrome

- recurrent lip (facial) edema
- fissured tongue
- facial paralysis





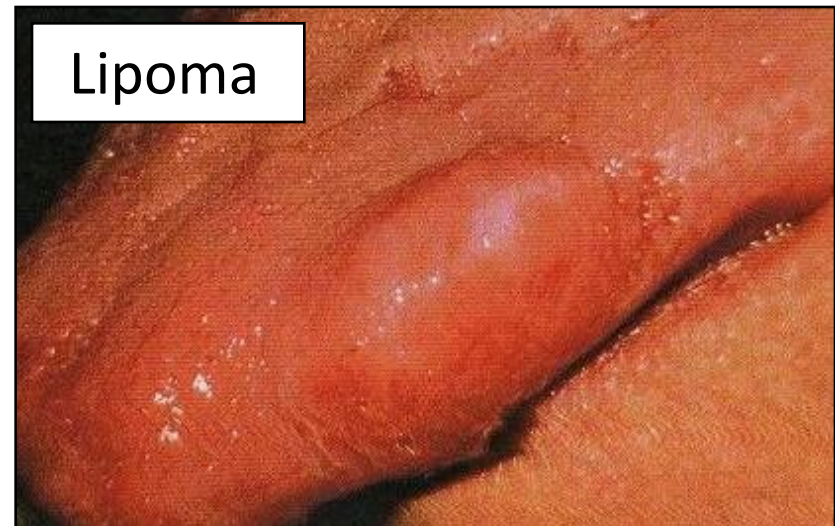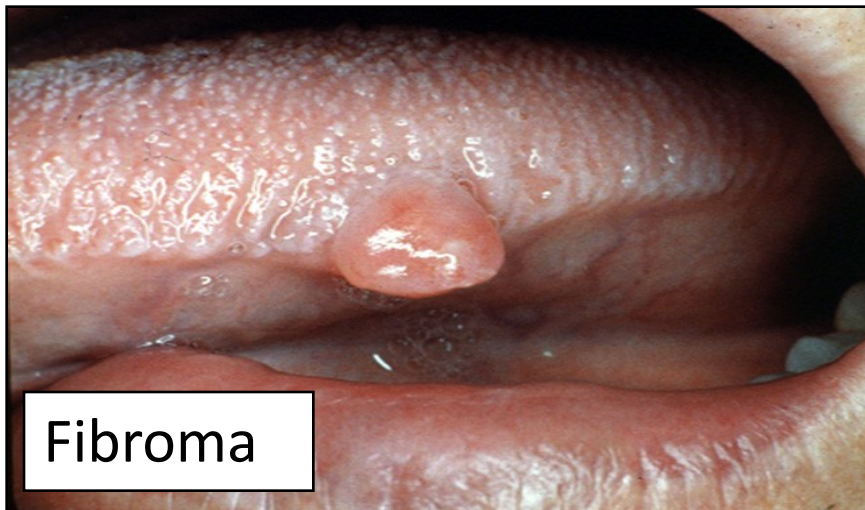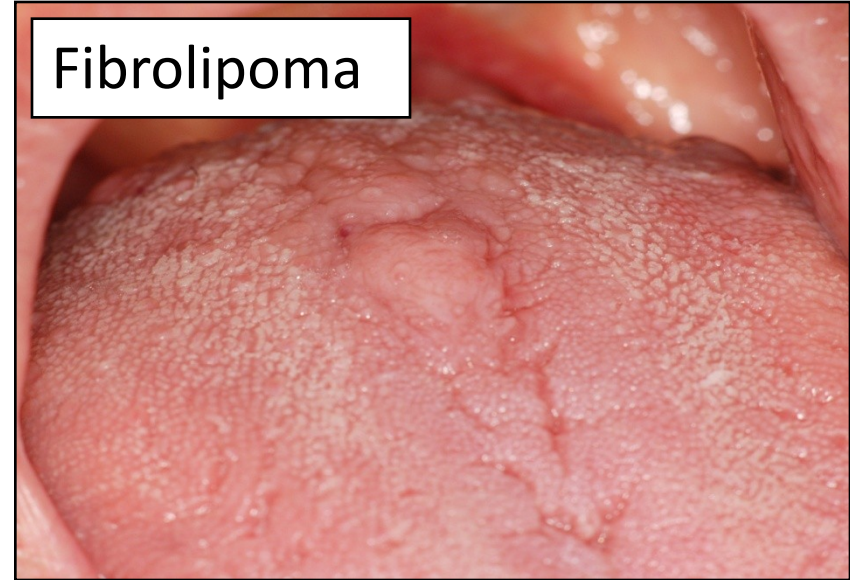
Melkersson's syndrome

- recurrent lip (facial) edema
- fissured tongue
- facial paralysis

Local changes of the tongue

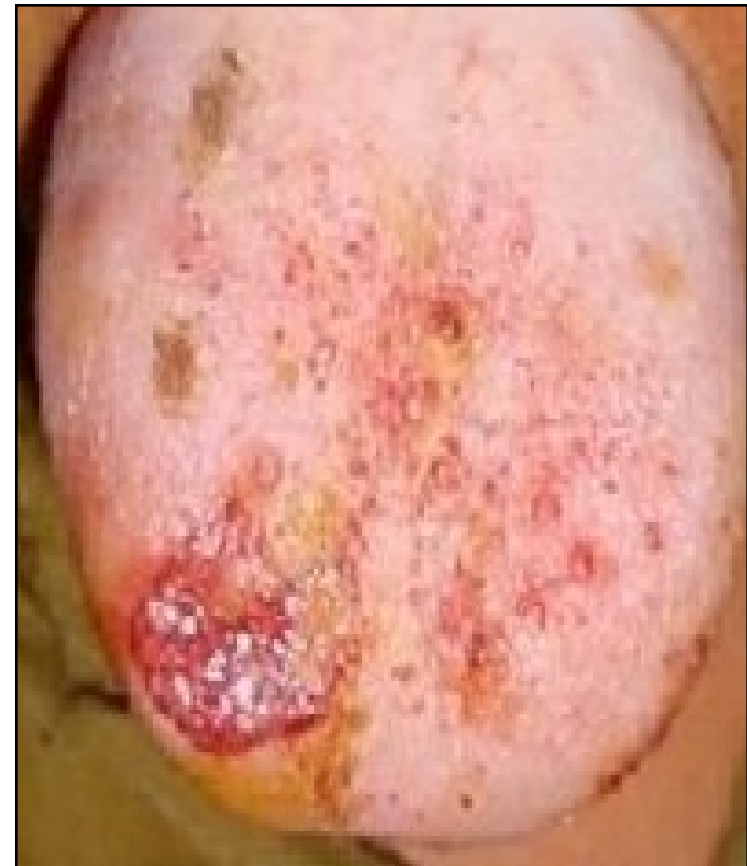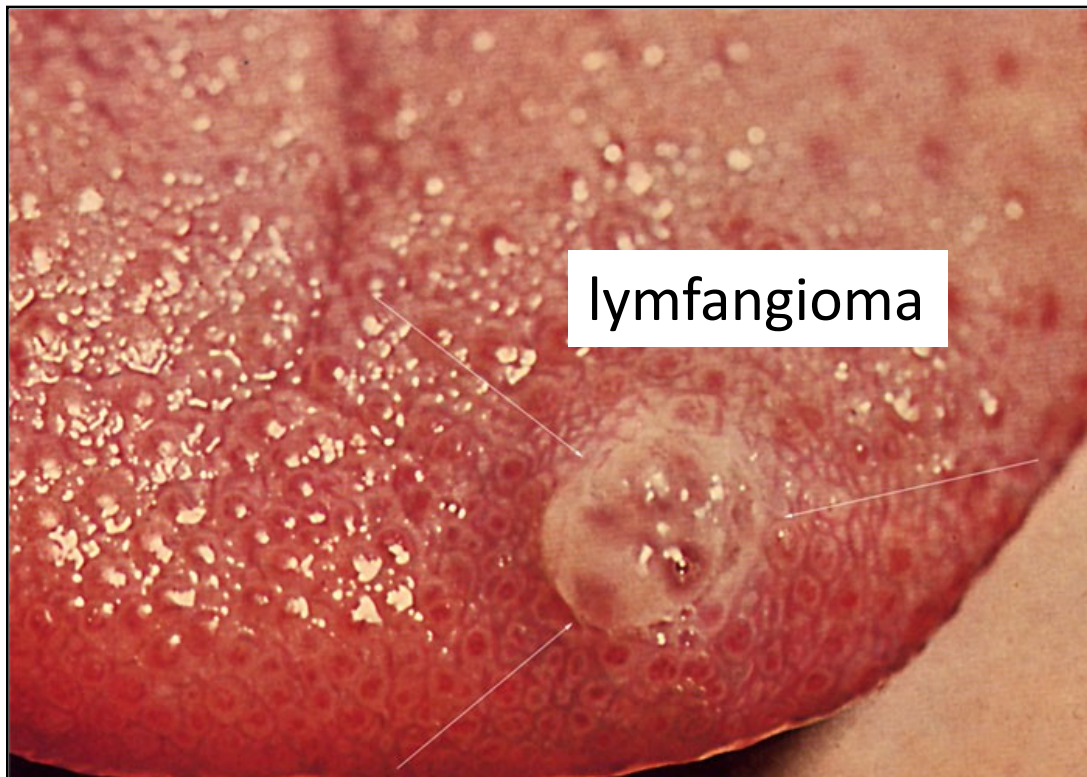Benign tumors

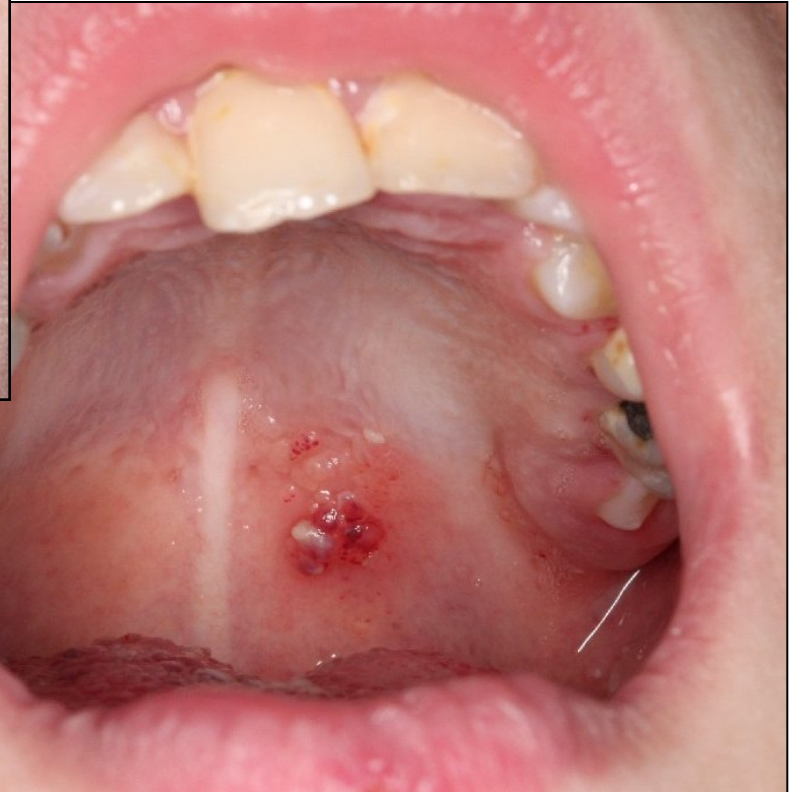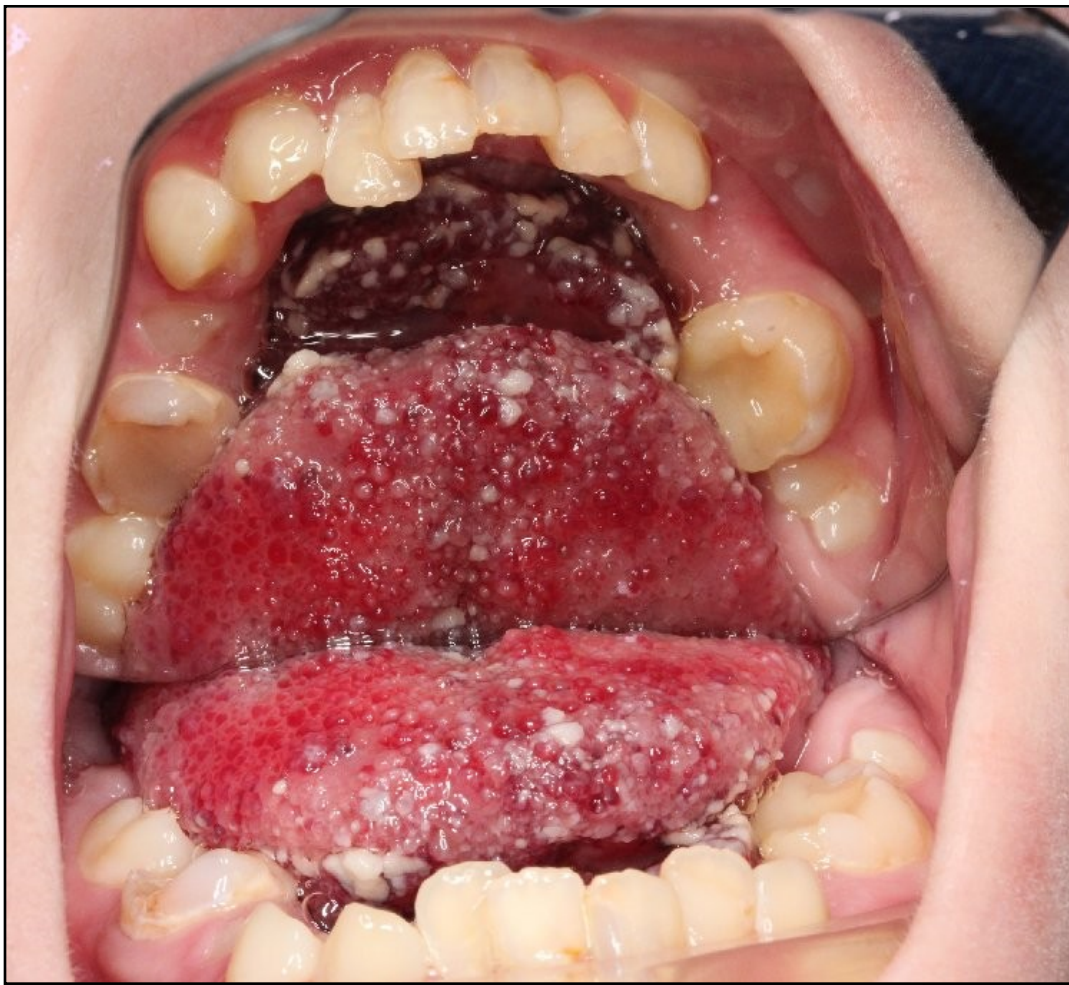- fibroma (lateral side)
- papiloma
- myoma (dorsum)
- lipoma (yellowish)
- neurofibroma



Local changes of the tongue

- Hemangioma
- Lymfangioma

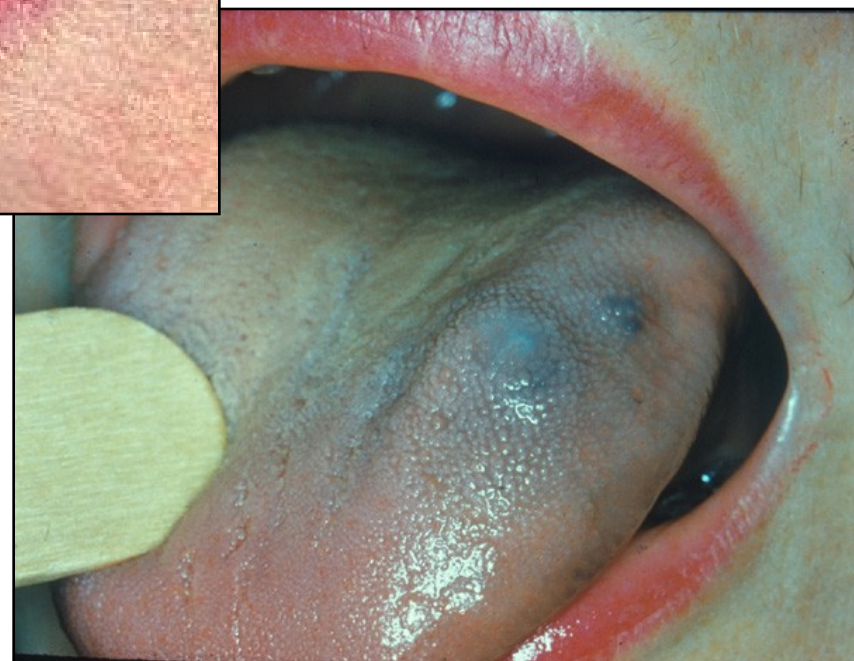
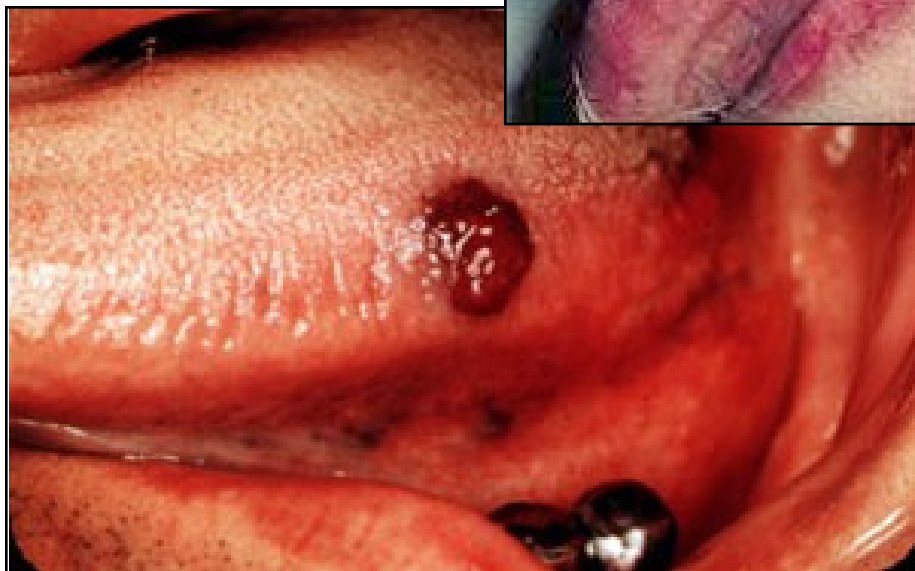
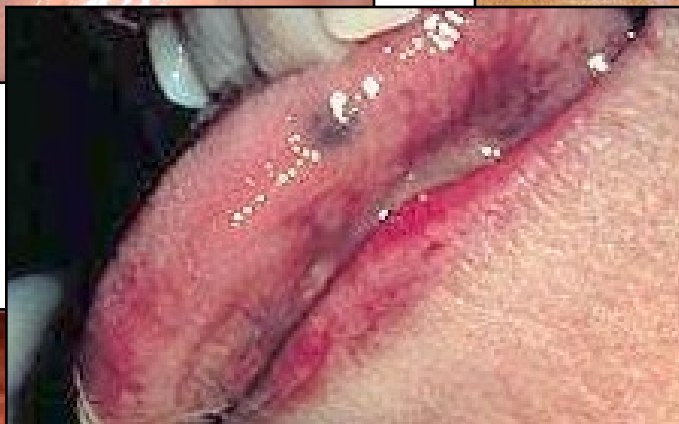
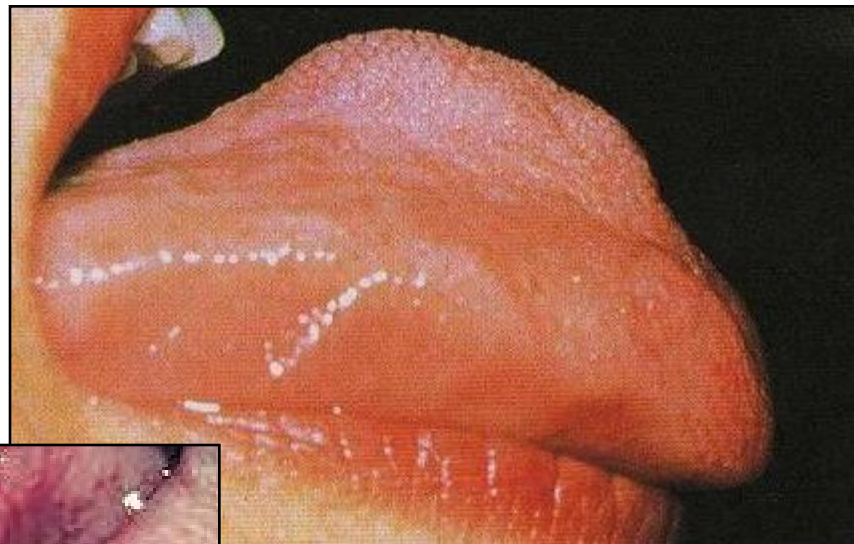
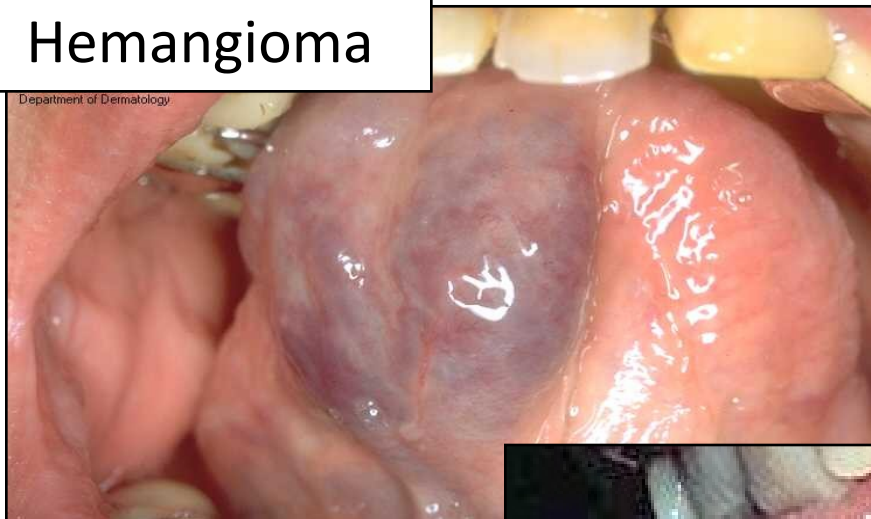Congenital
lymfangioma

Hemangioma

Department of Dermatology

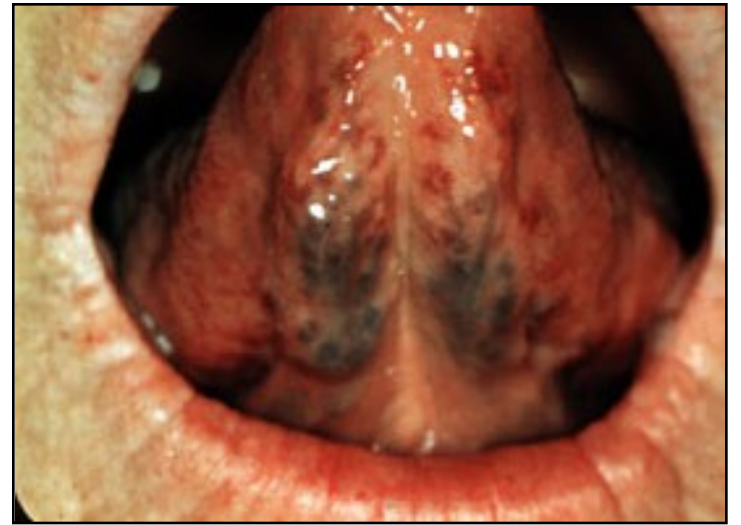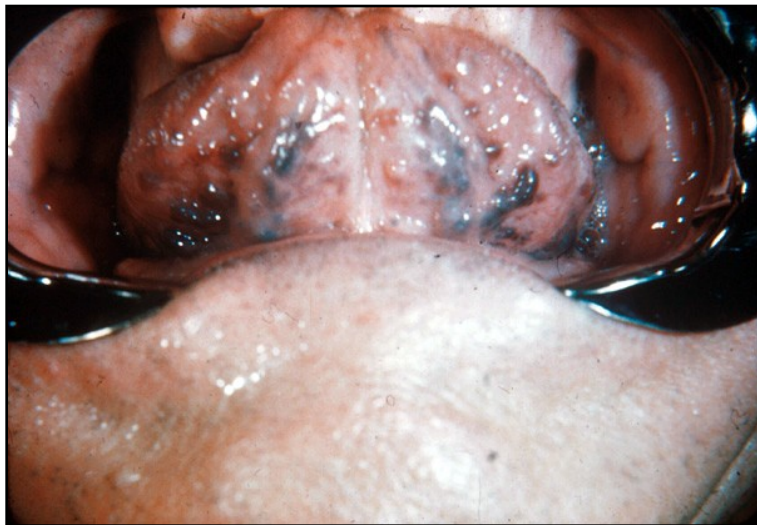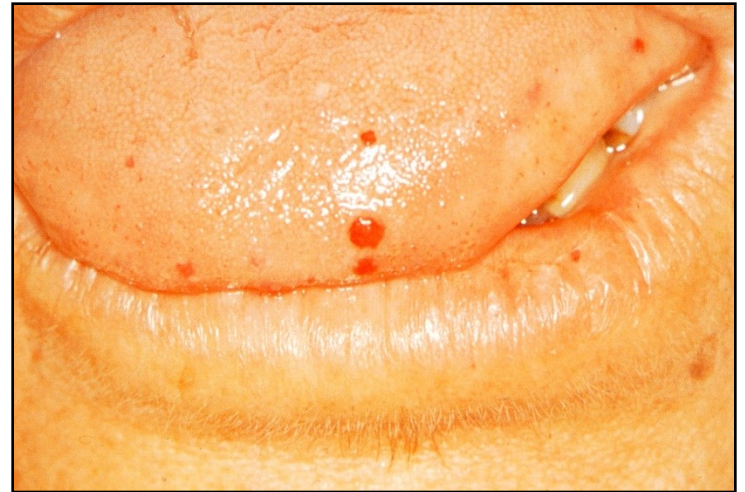


Local changes of the tongue

- Vascular changes

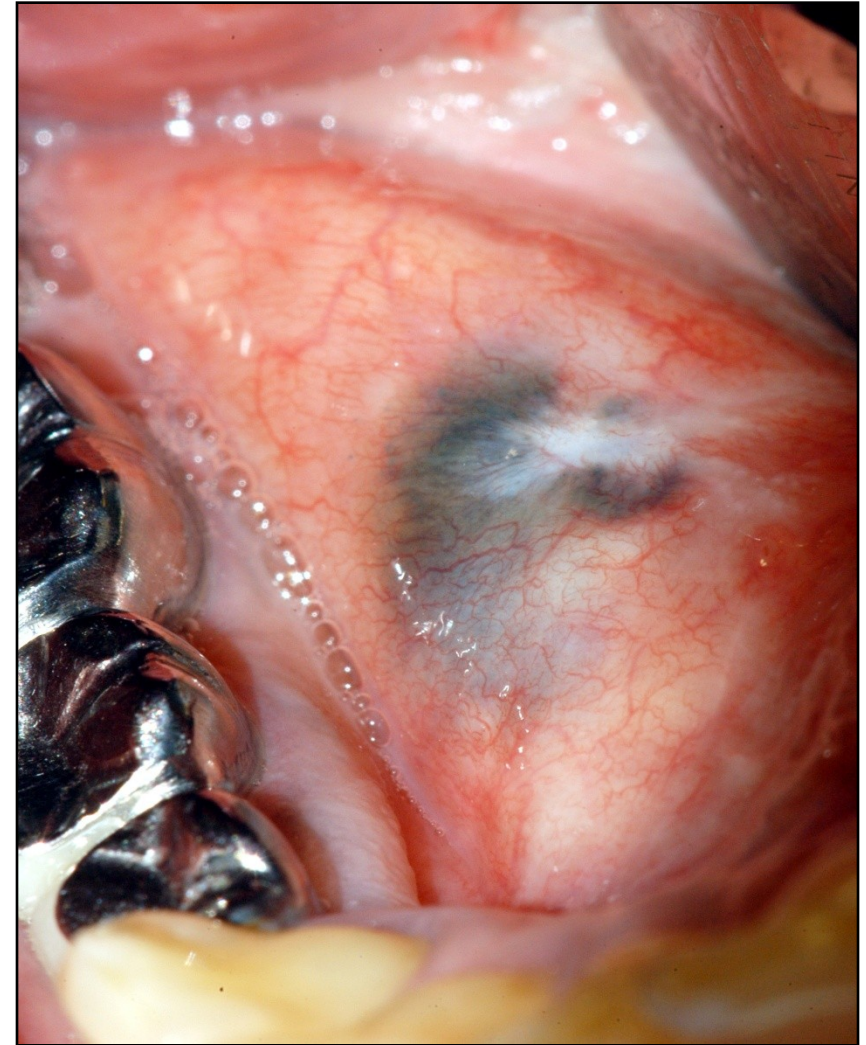
Teleangiectasias

Sublingual venectasias
(varices linguae)



Local changes of the tongue

- Metallic pigmentations
- Melanin pigmentations



artistic tattoo

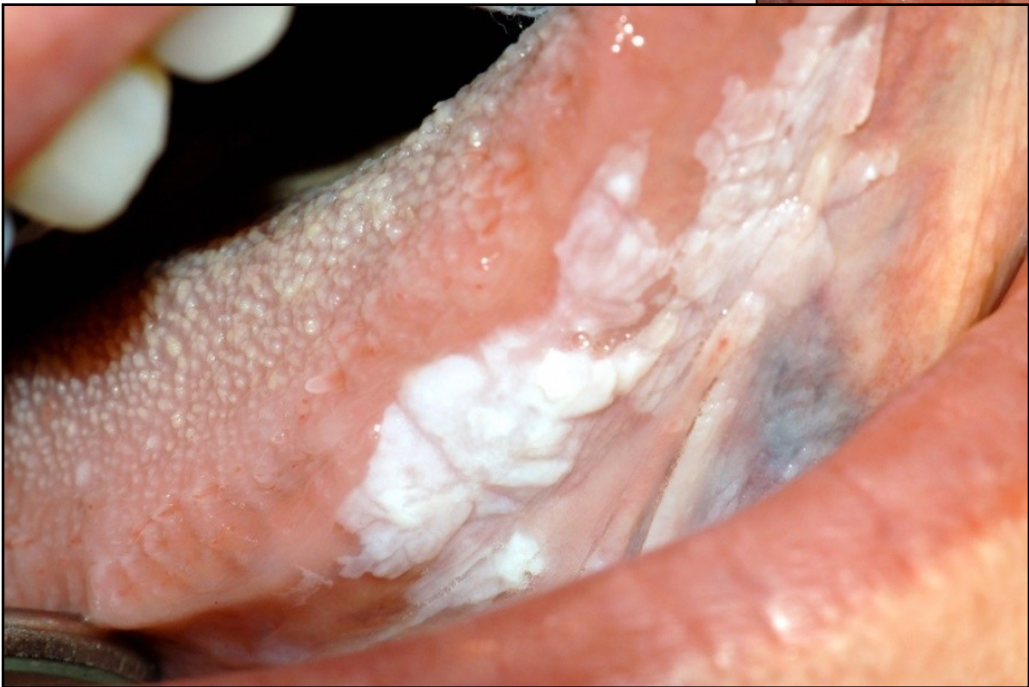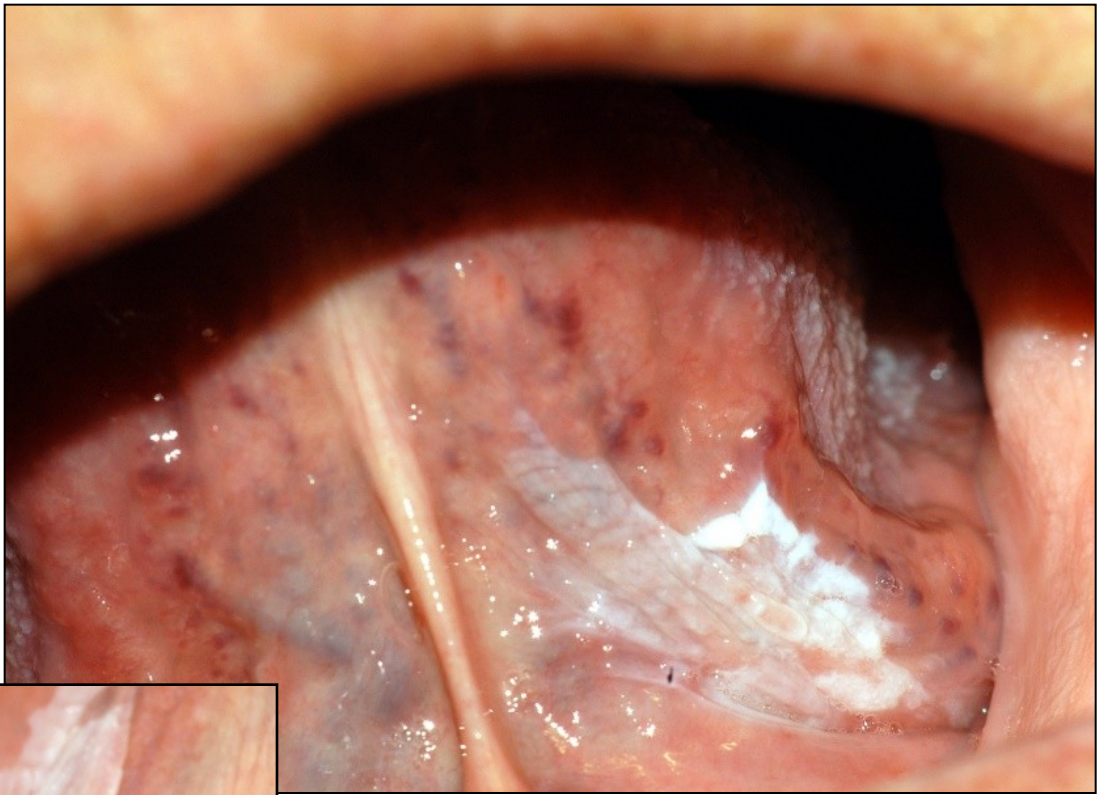


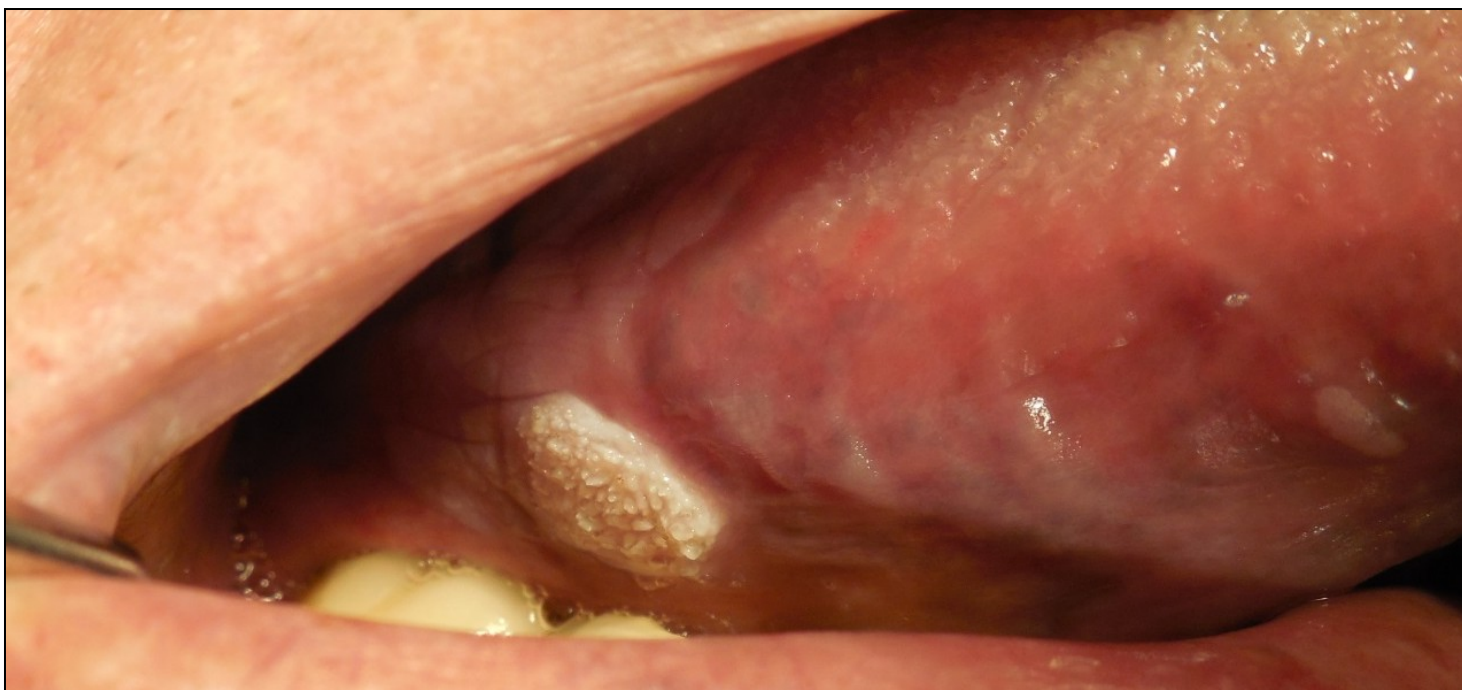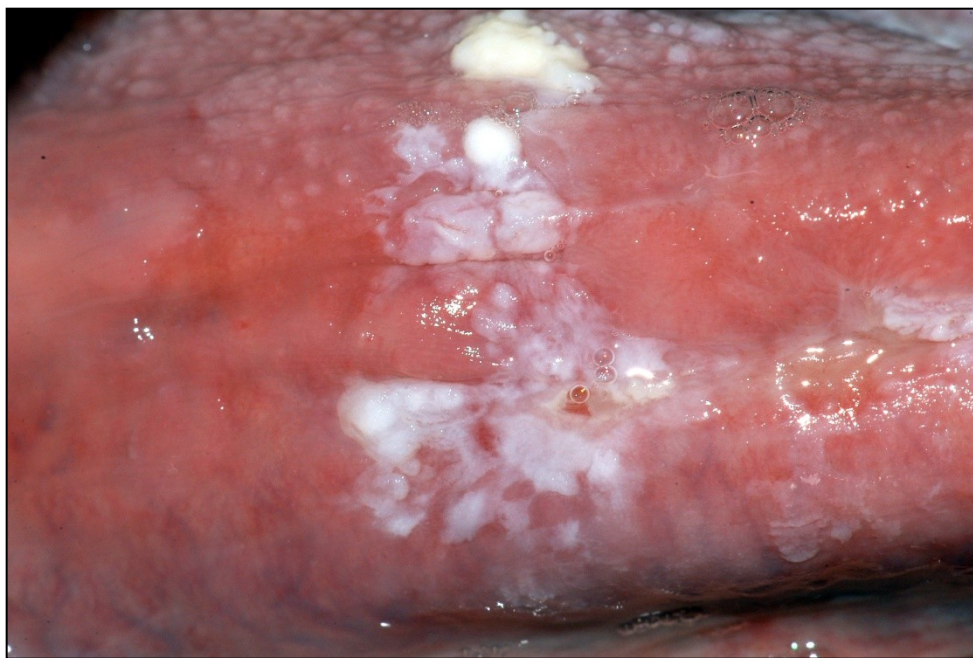
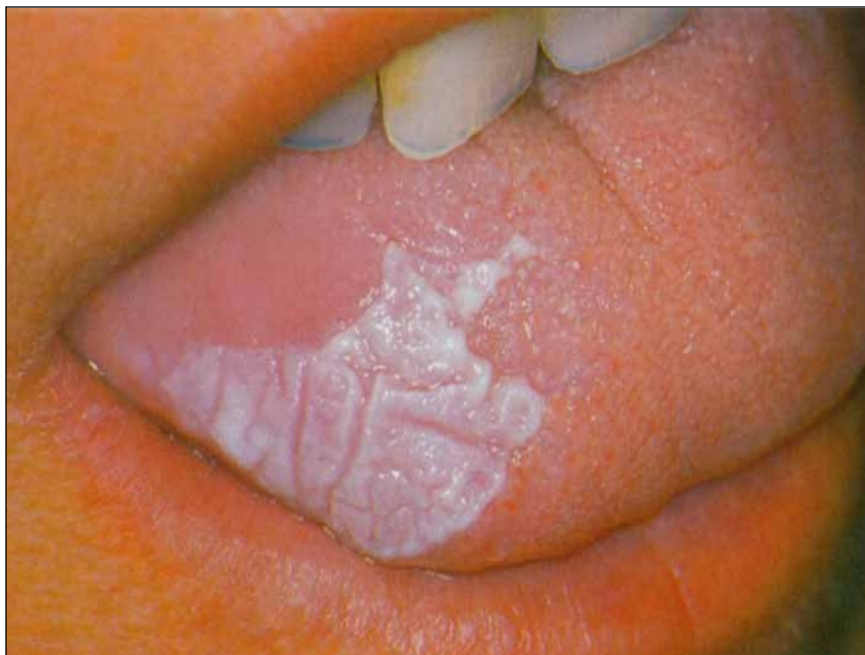Local changes of the tongue

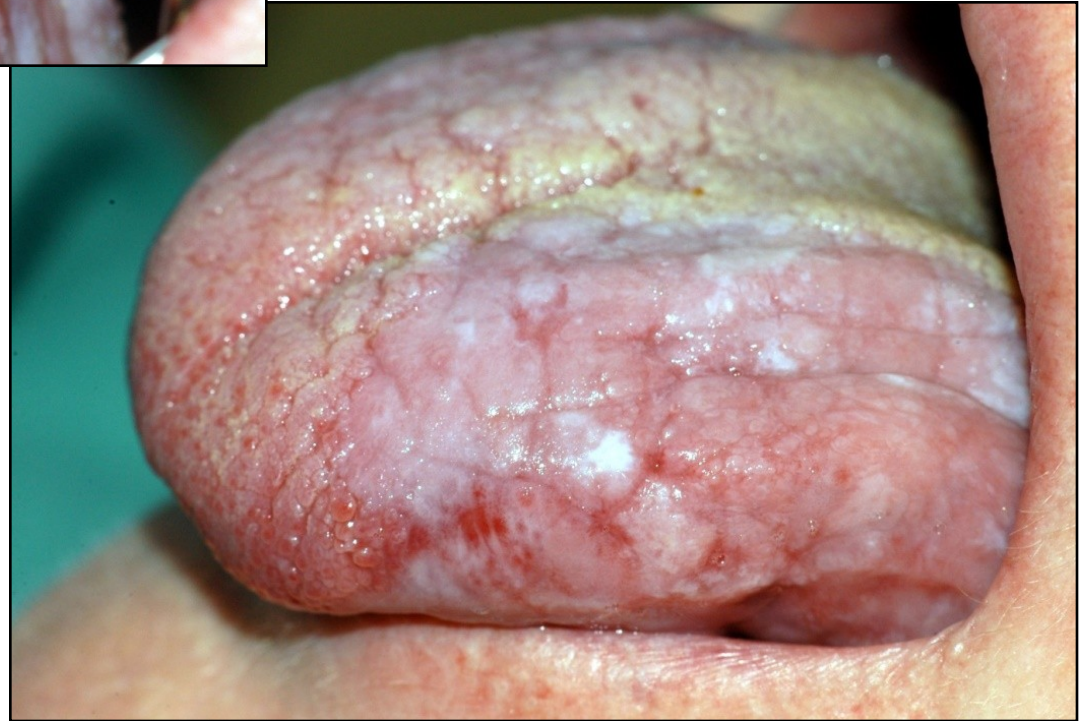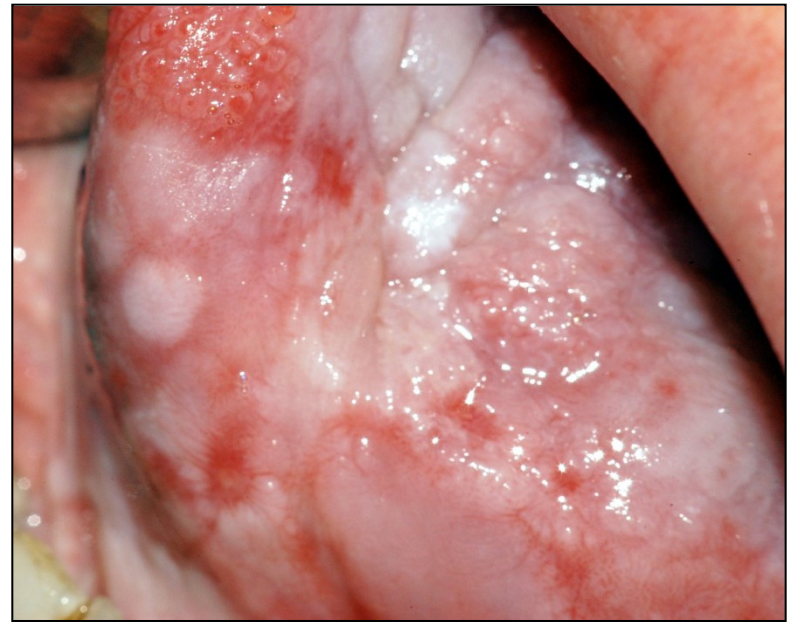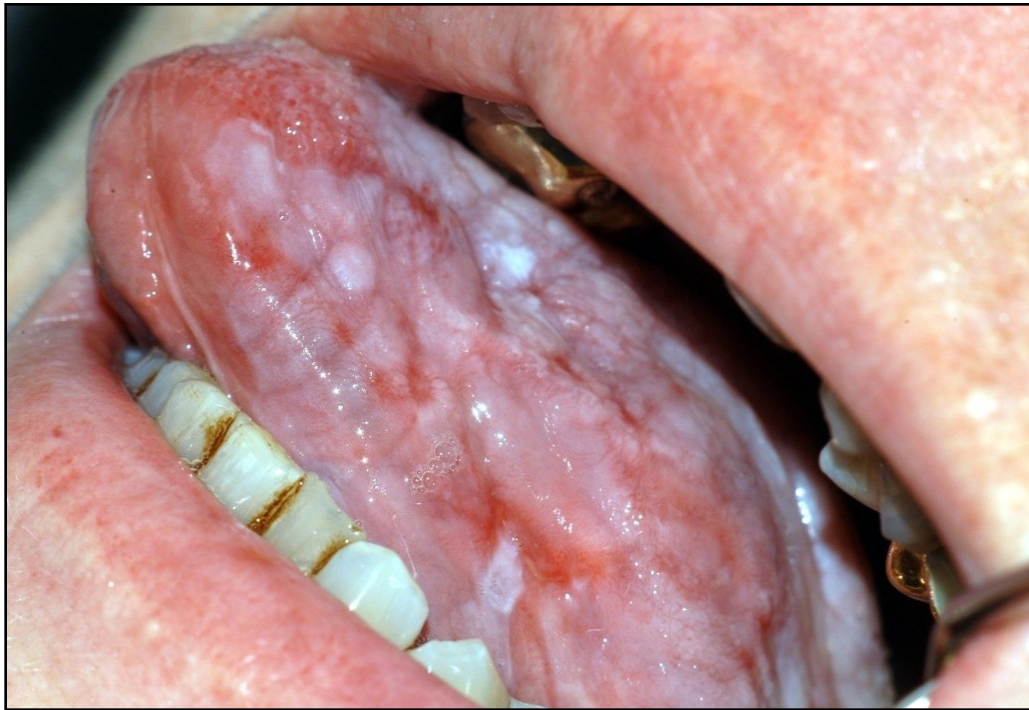- Precancerous lesions, leukoplakias and erythroplakias

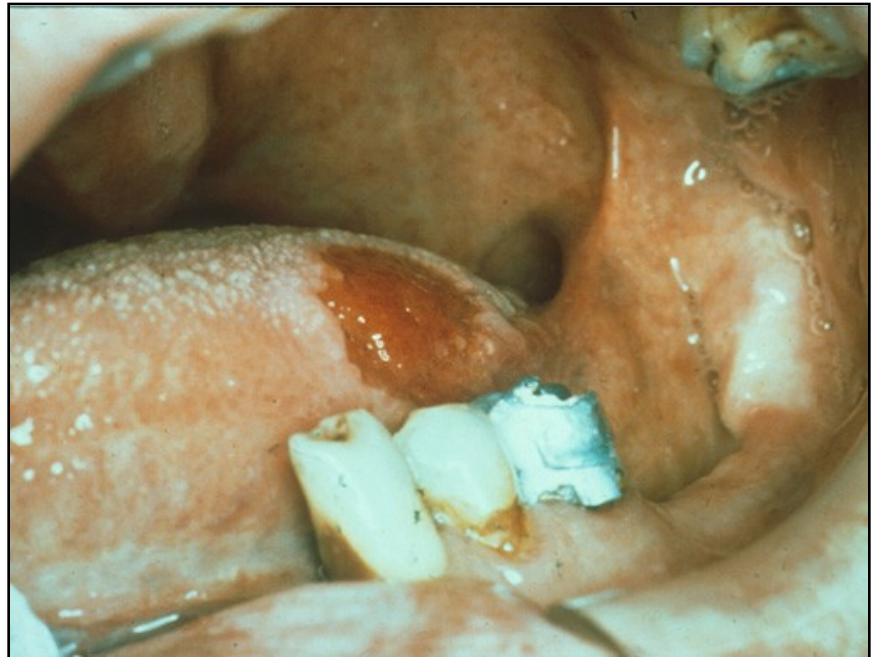
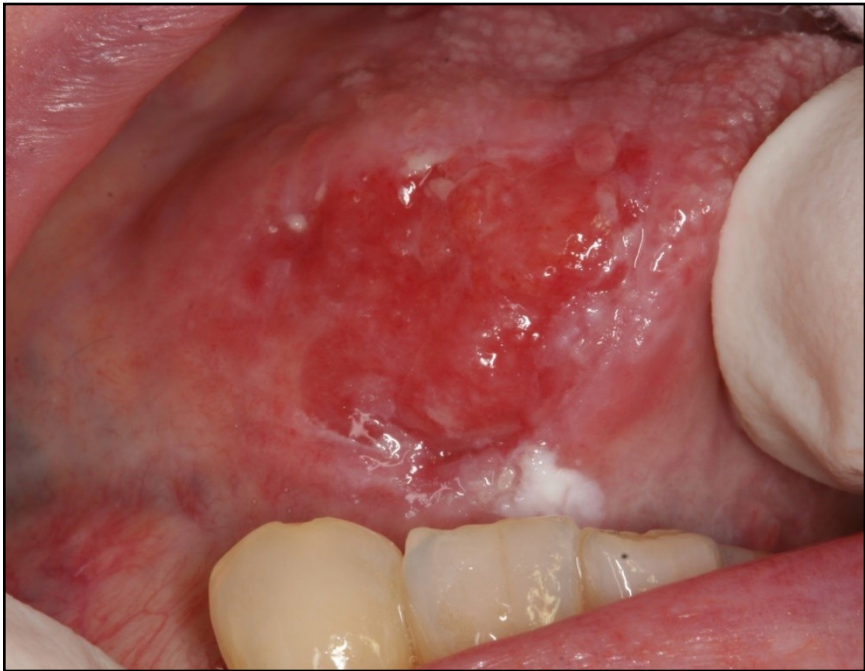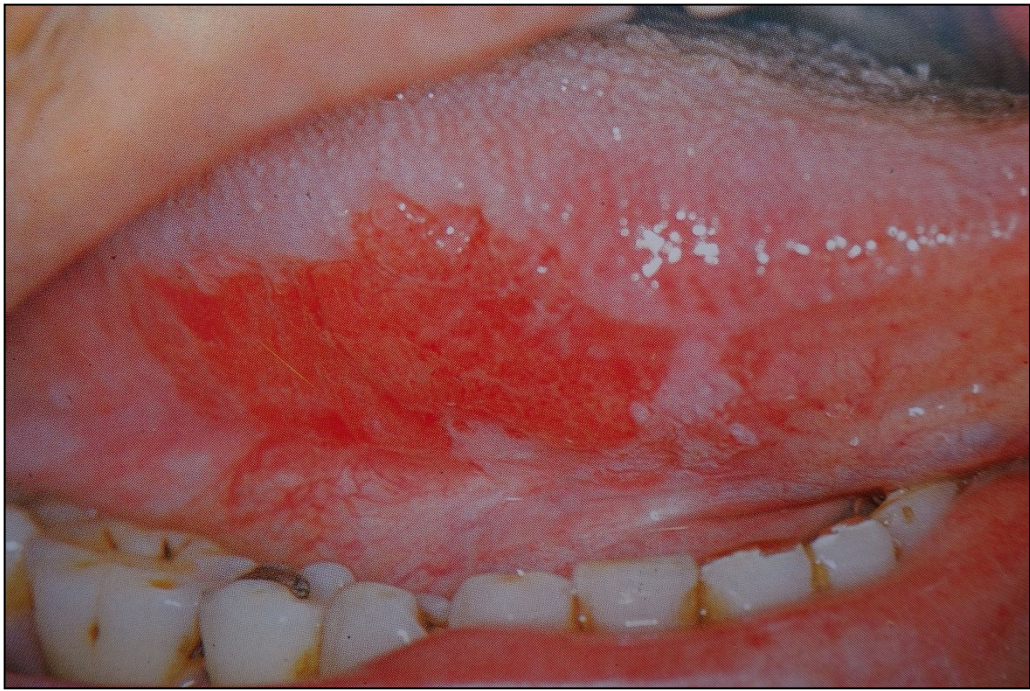10% -15% of leukoplakias occurs on the tongue

- Leukoplakias on the tongue - malignant transformation at 24 – 38 %
- Erythroplakie on the tongue - malignant transformation at 96 %





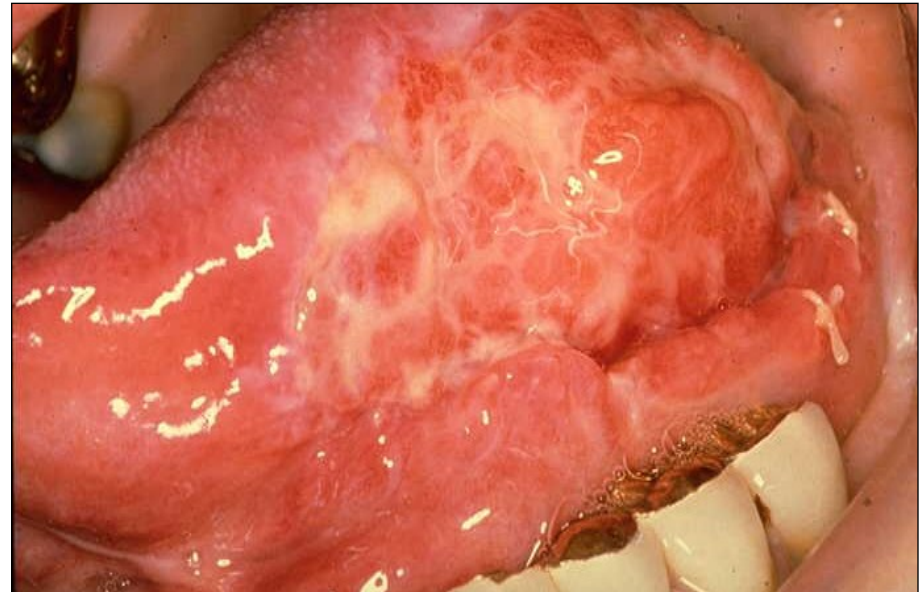
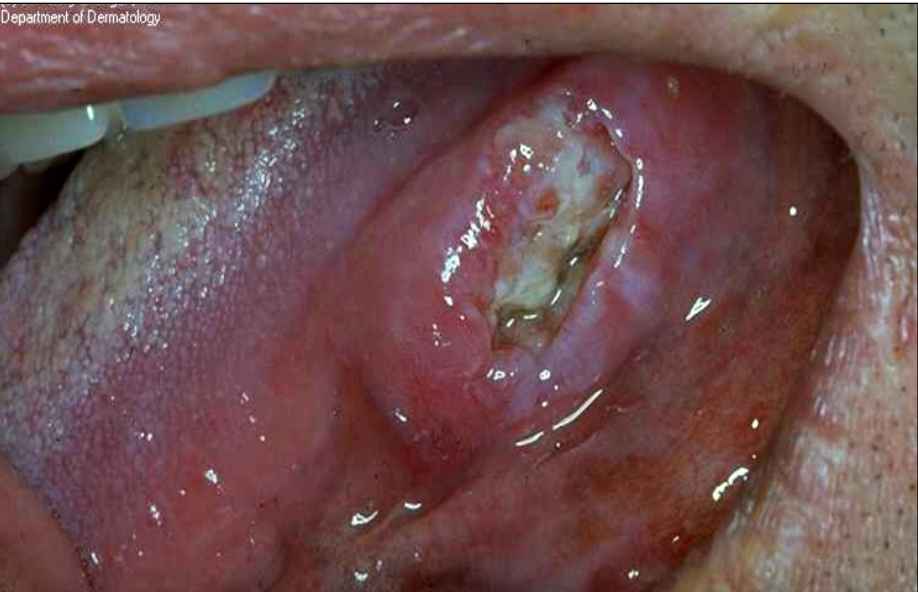
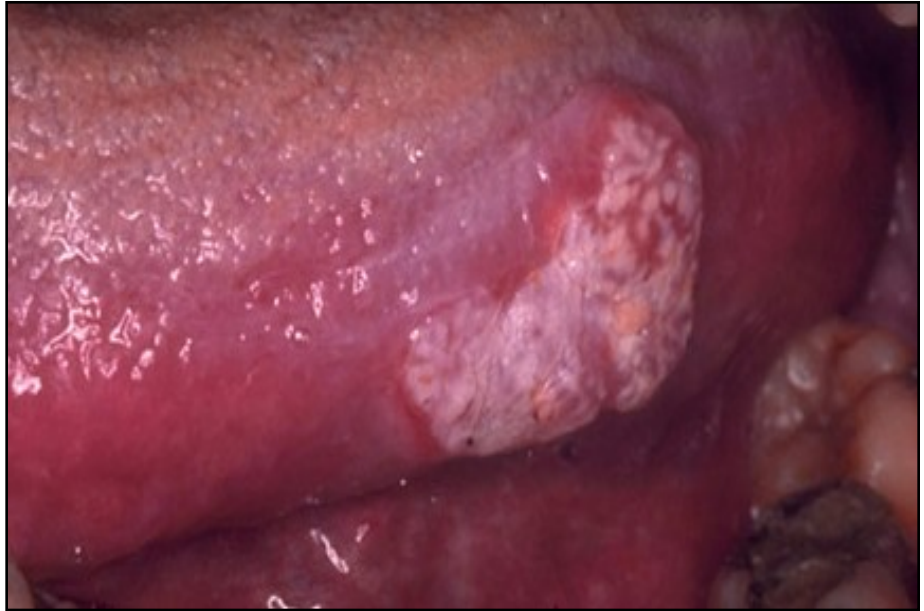
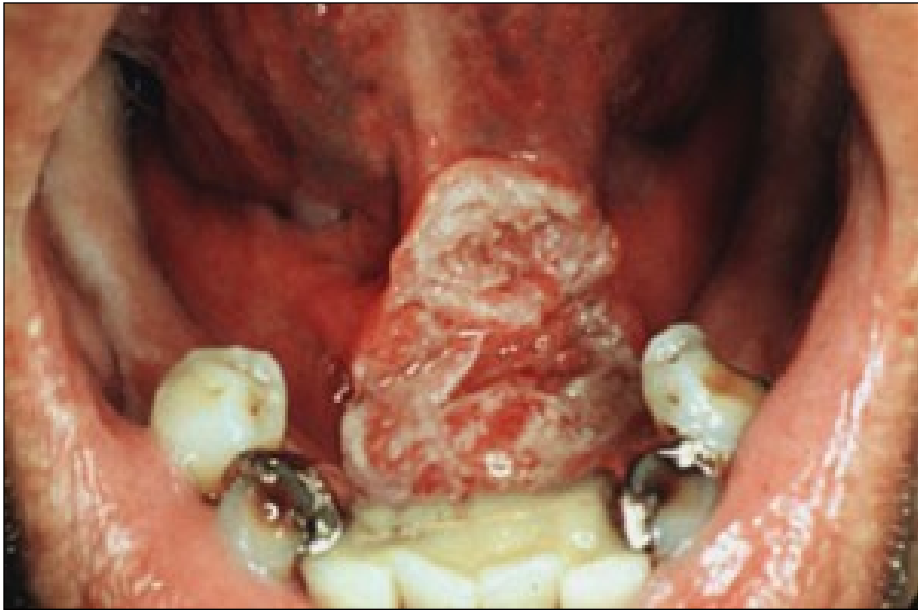
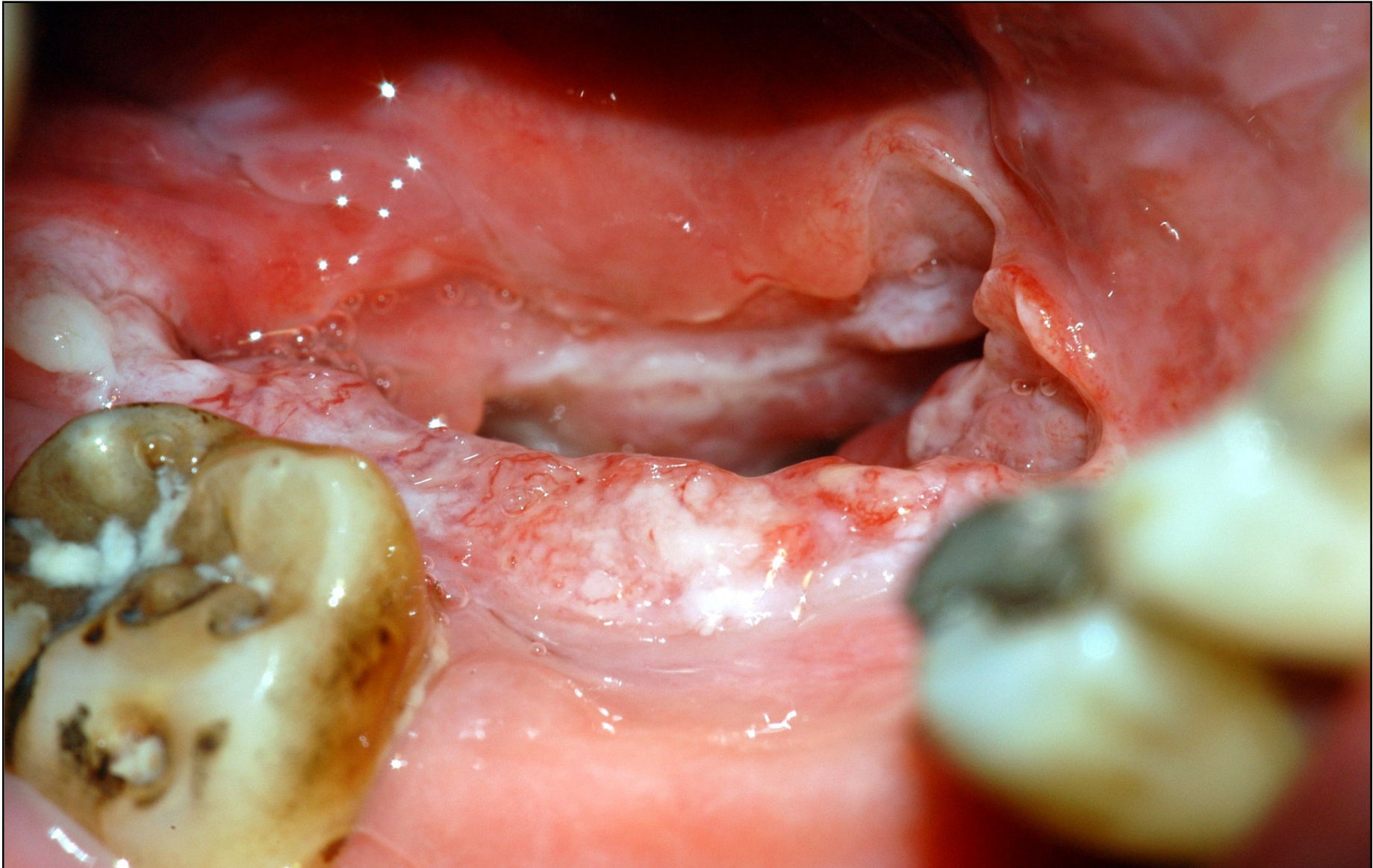
Malignant tumors

30 % of oral malignant lesions are located at the radix of the tongue

- **spinocellular Ca** (lateral side)
- malignant lymphomas (NHL)
- tumors of the salivary glands (ventral)
- sarkoma (rare, Kaposi sarkoma)
- metastatic tumors (radix)

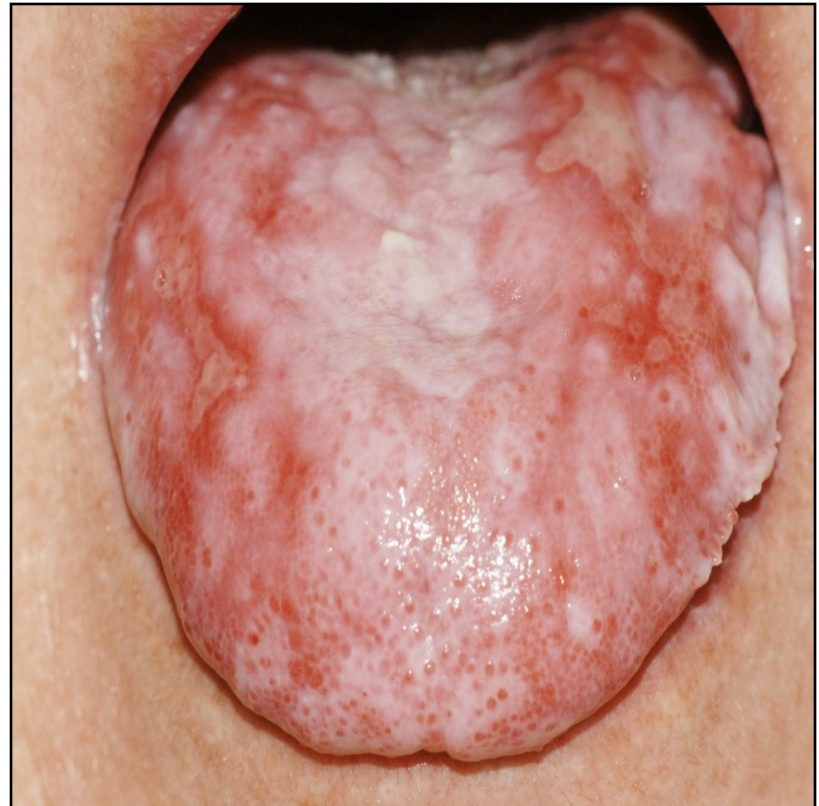

Man, 1960, felt defect under tongue (about a month),
15 cig / day, increased submandibular lymph nodes



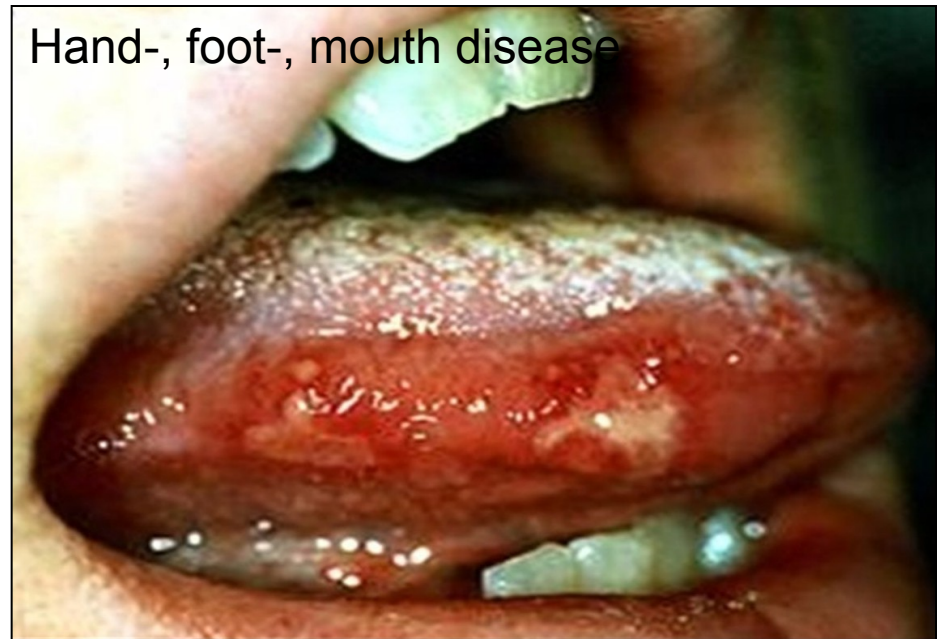2/ Manifestation of generalized diseases

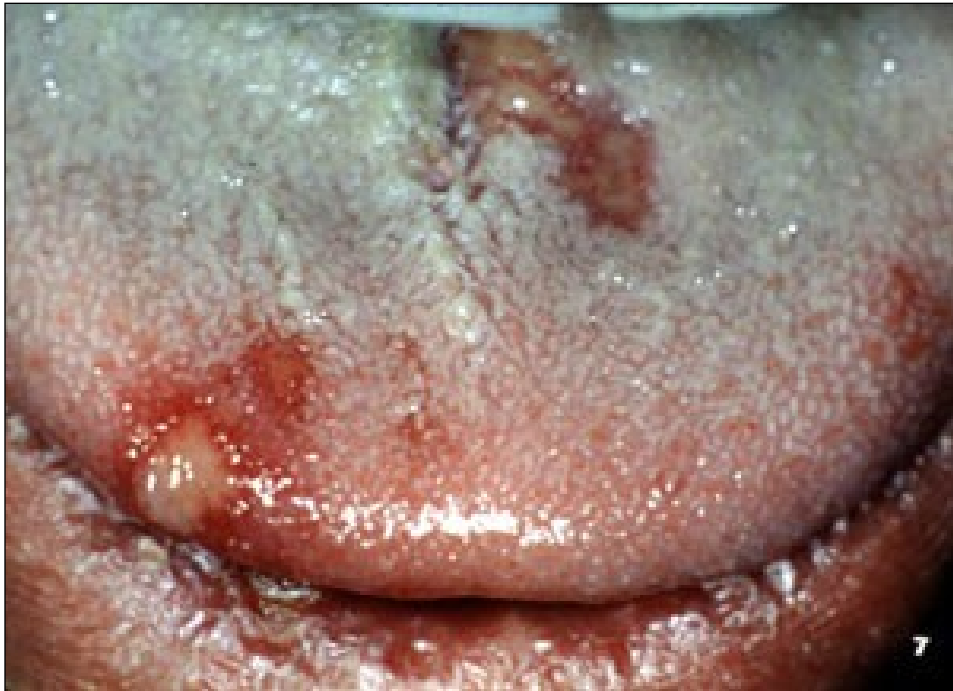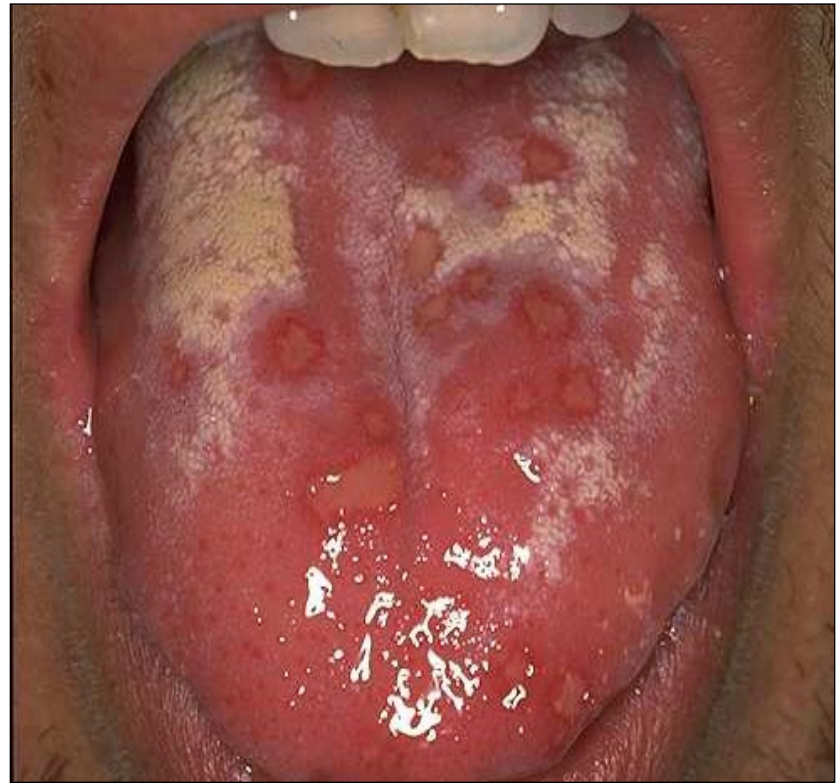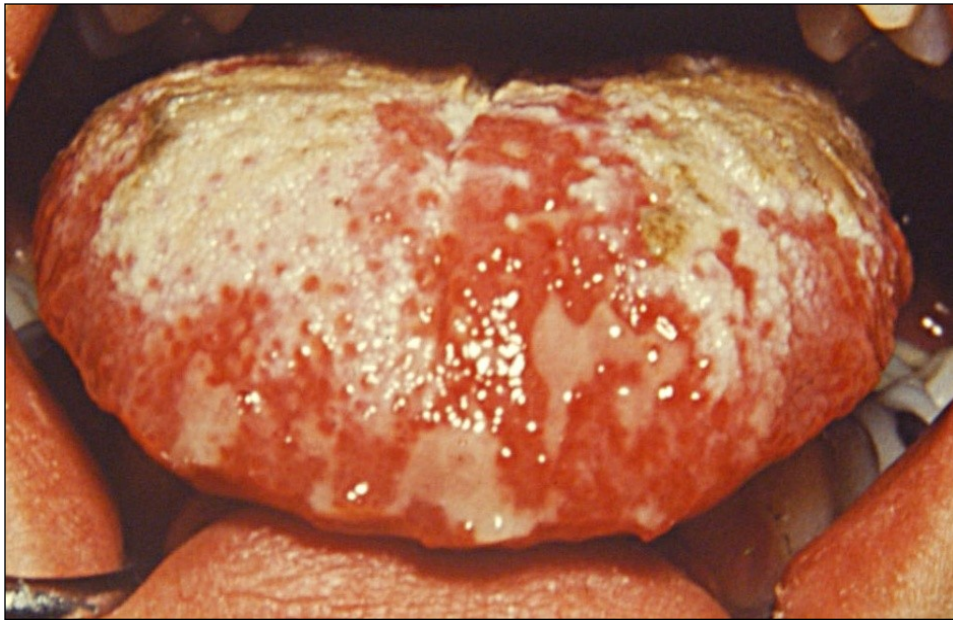
- Systemic infection
- Blood diseases
- Immunity disorders (autoimmune, allergic reaction)
- Metabolic disorders



2/ Manifestation of generalized disease

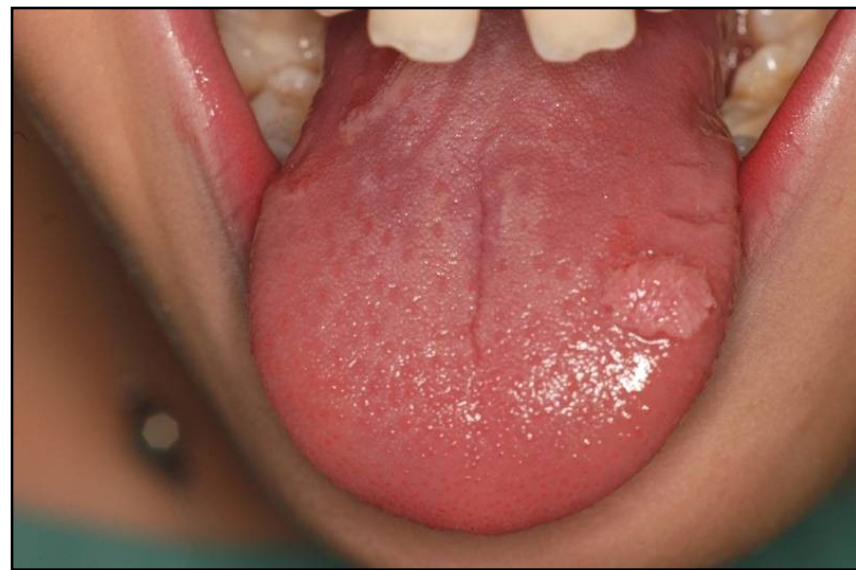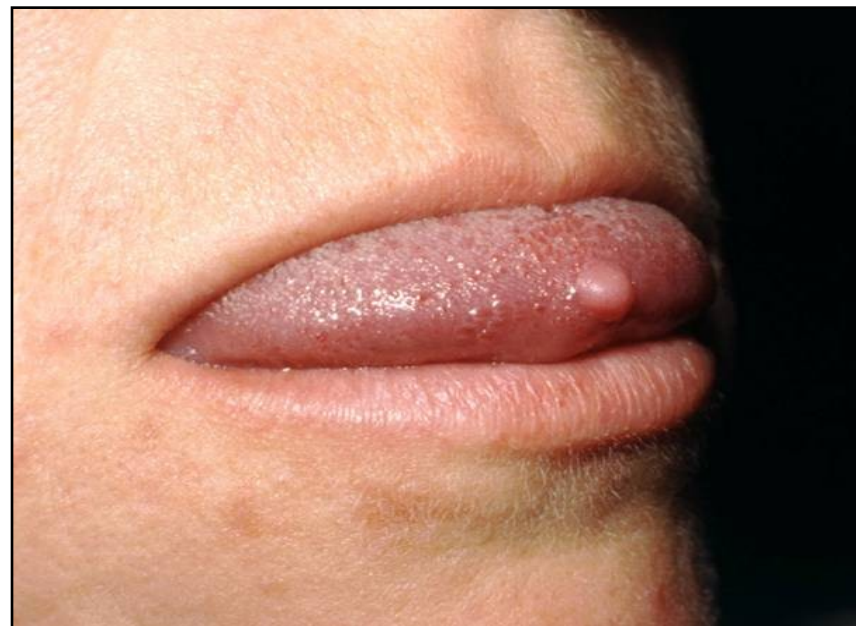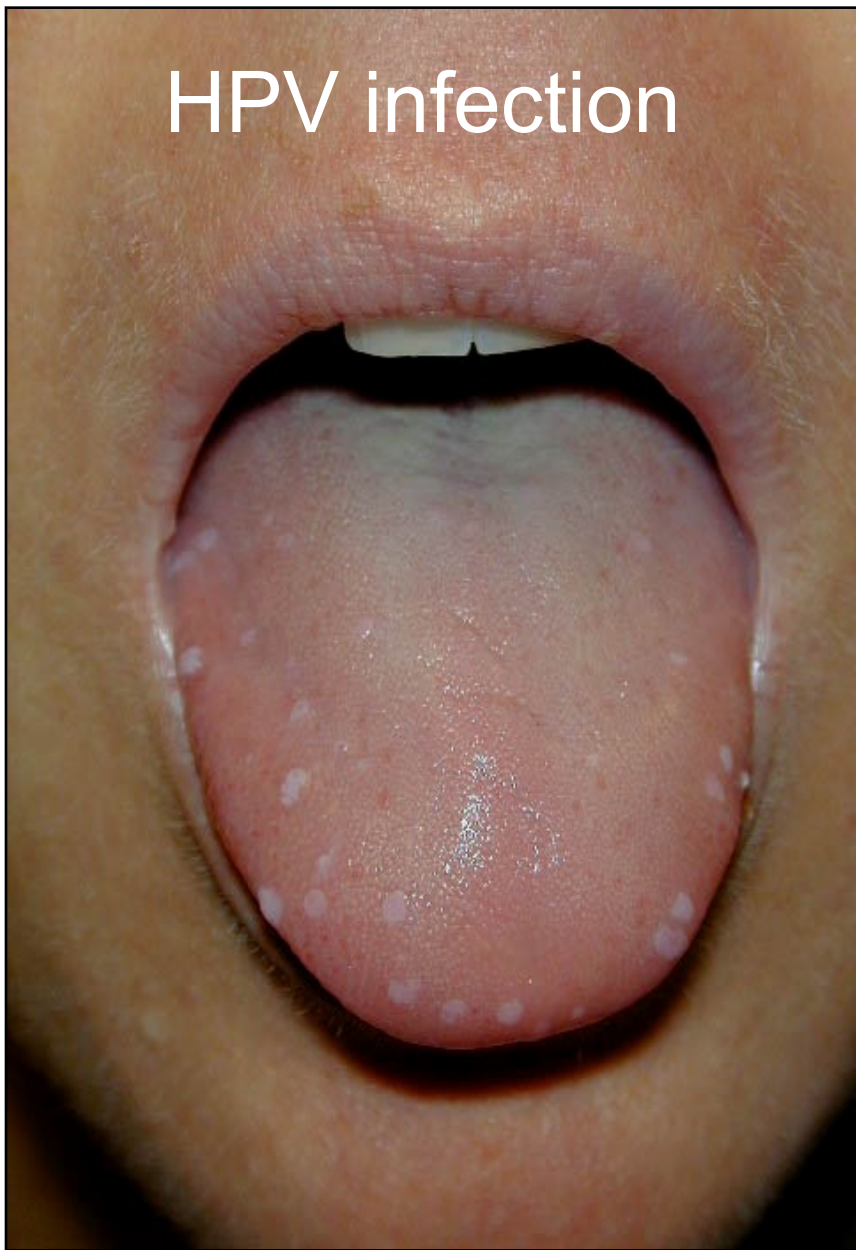- **Infection** (local or systemic problem)
 - Viral infection HSV (GSH, HS), VZV, Coxsackie, HPV
 - Oral candidiasis
 - Scarlet fever
 - syphilis - TBC
 - HIV

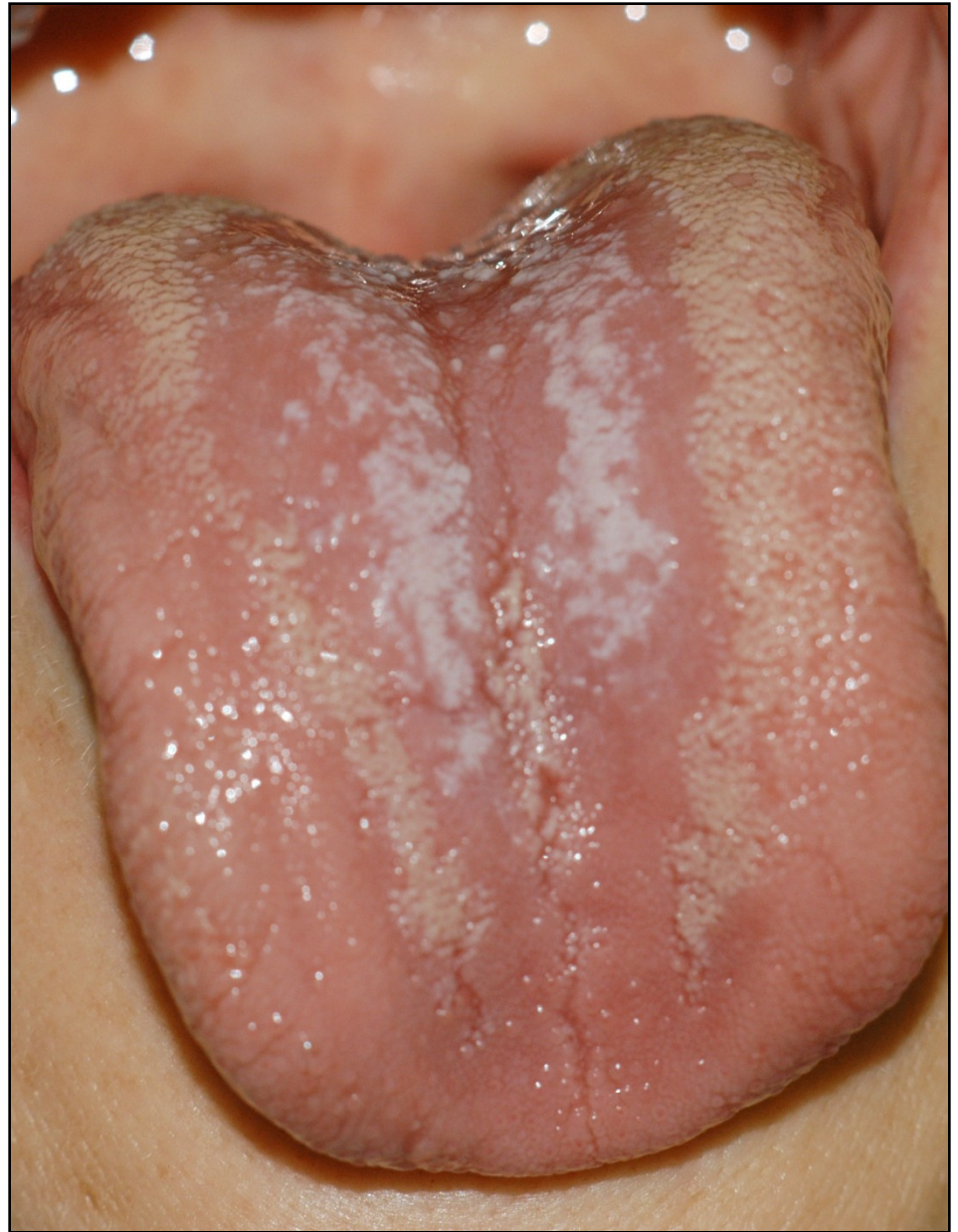
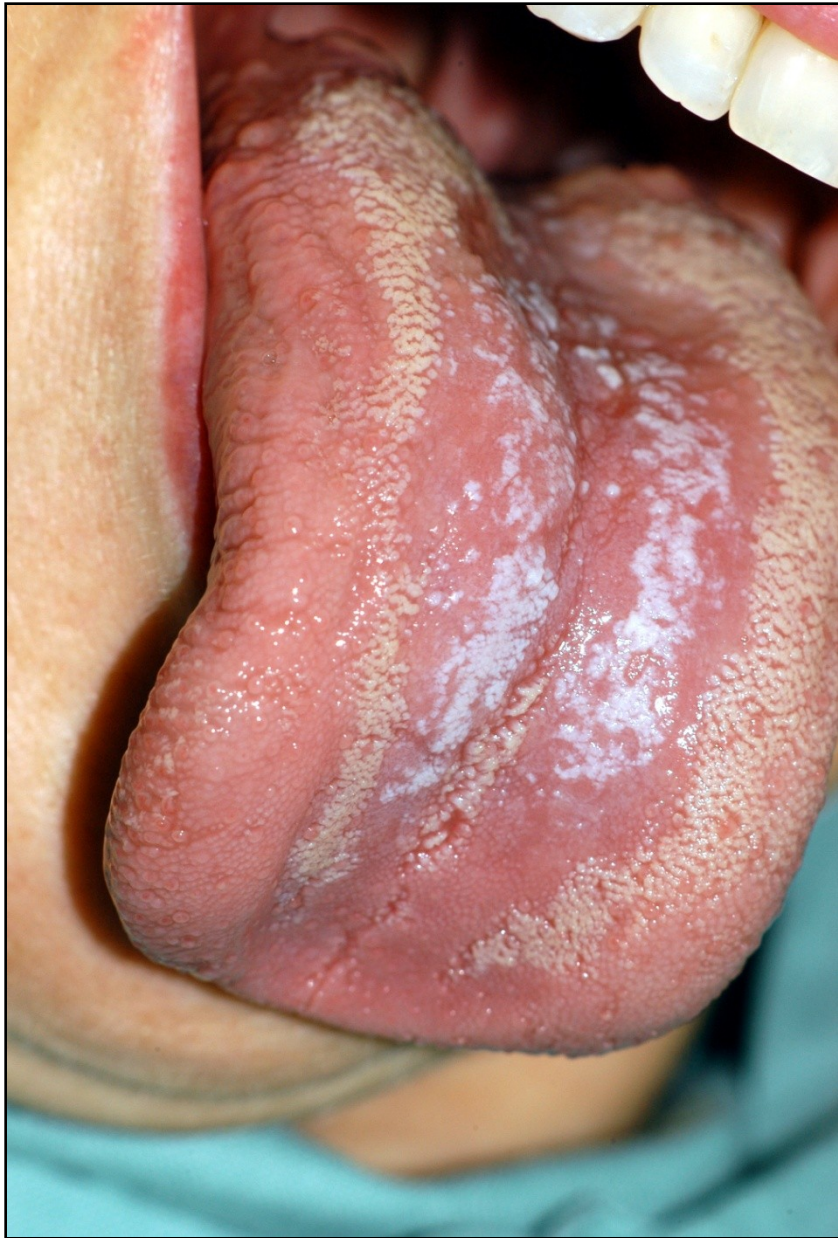


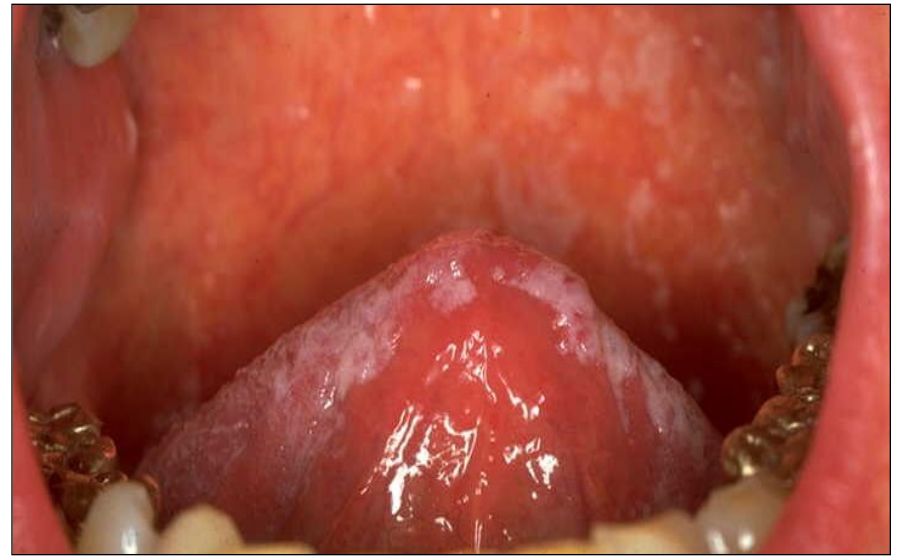
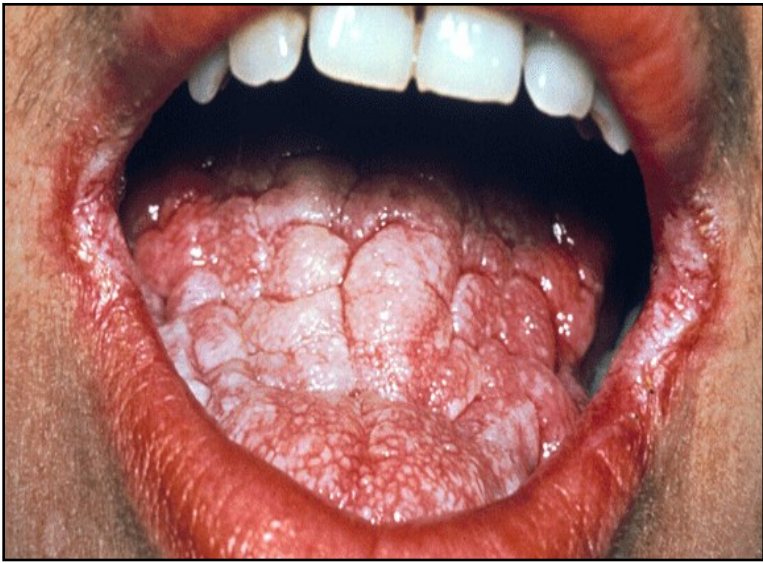Viral infection HSV

HPV infection

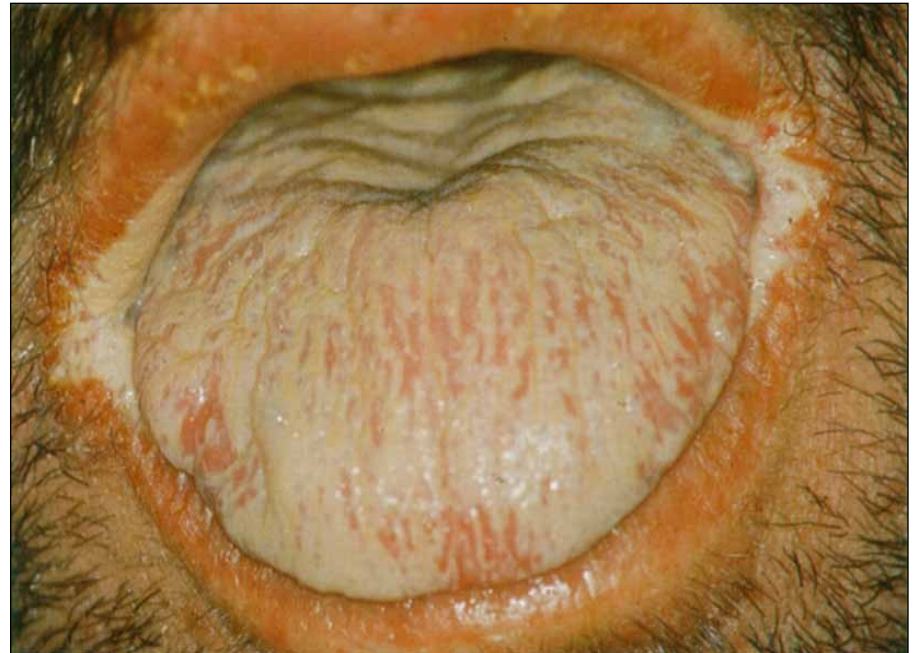
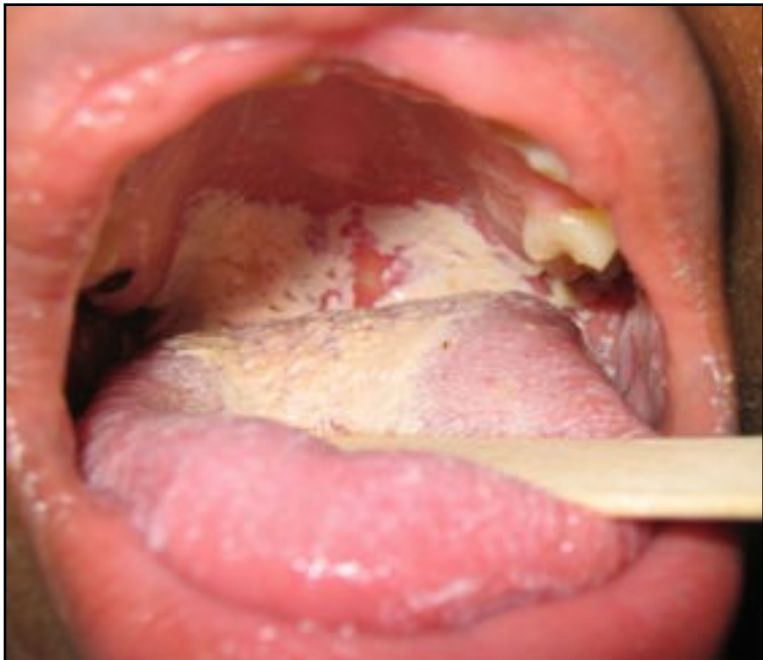



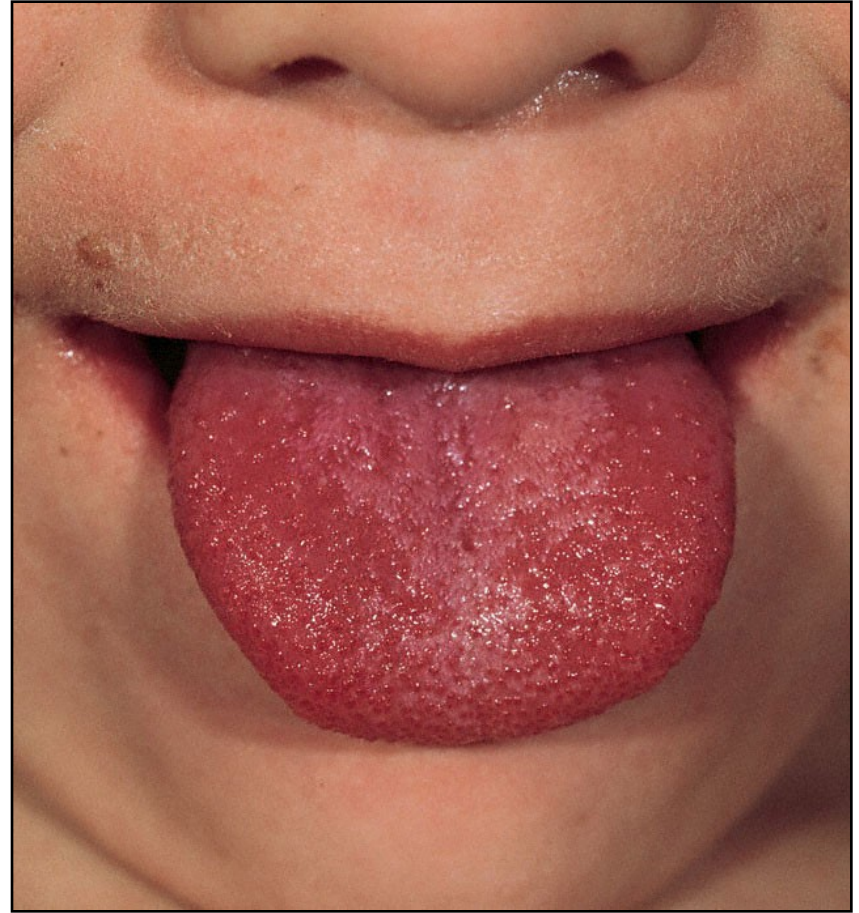
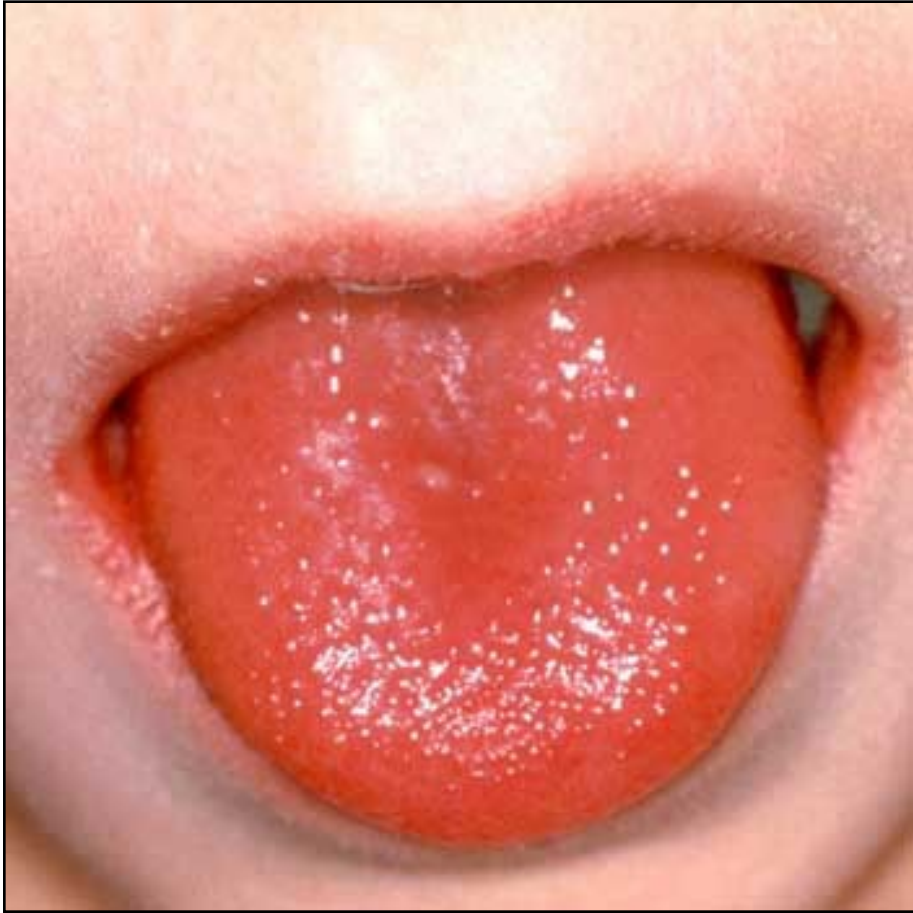Oral candidiasis



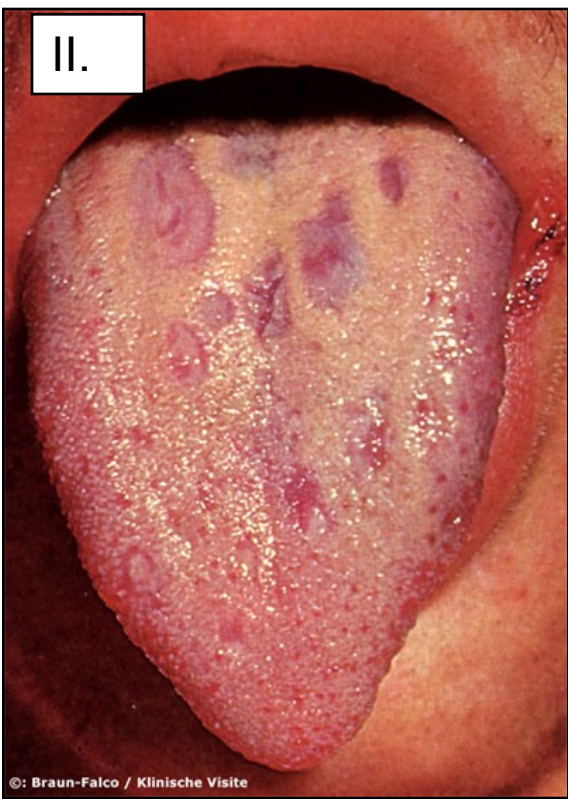Oral candidiasis



Scarlet fever

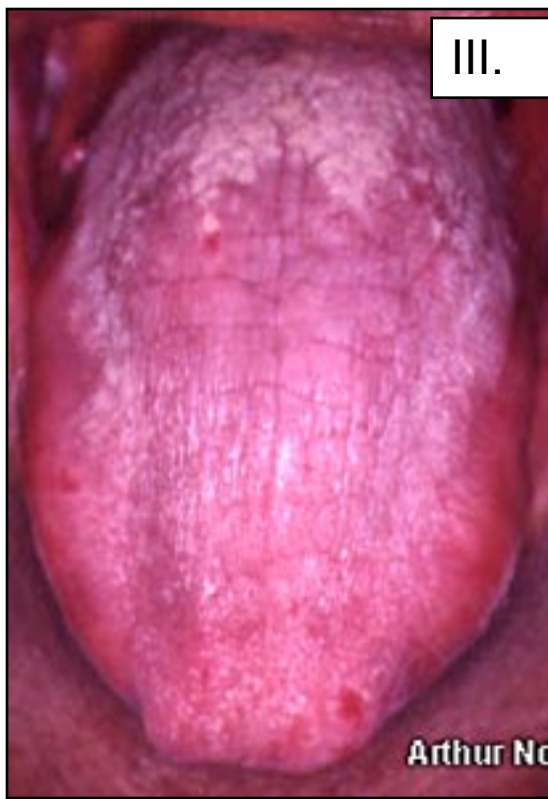


II.



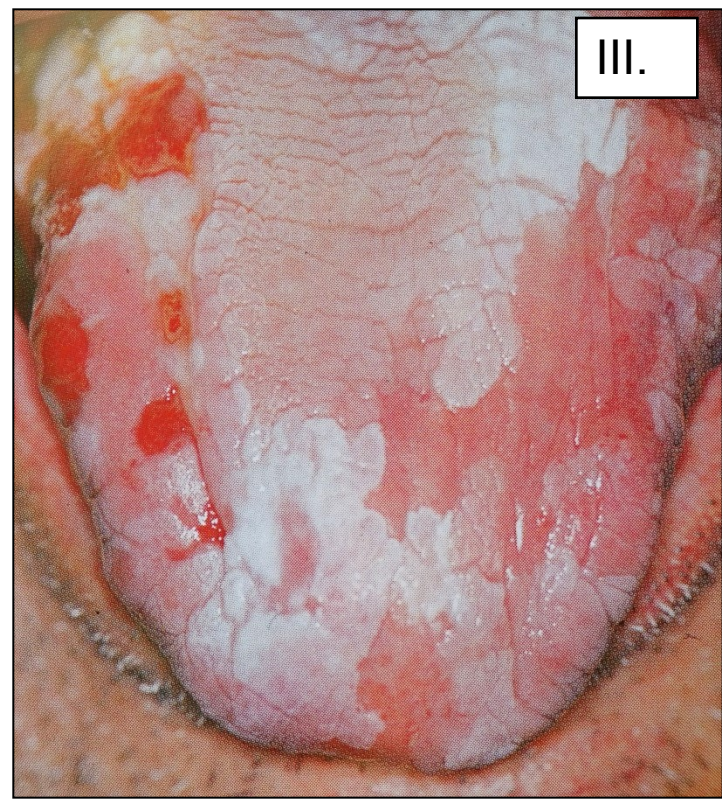
©: Braun-Falco / Klinische Visite

III.



Arthur No

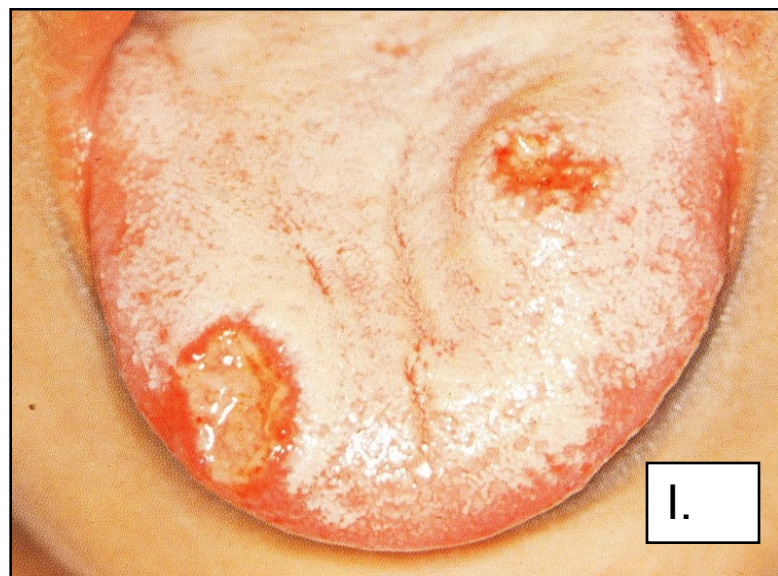III.



Syphilis

- all 3 stages

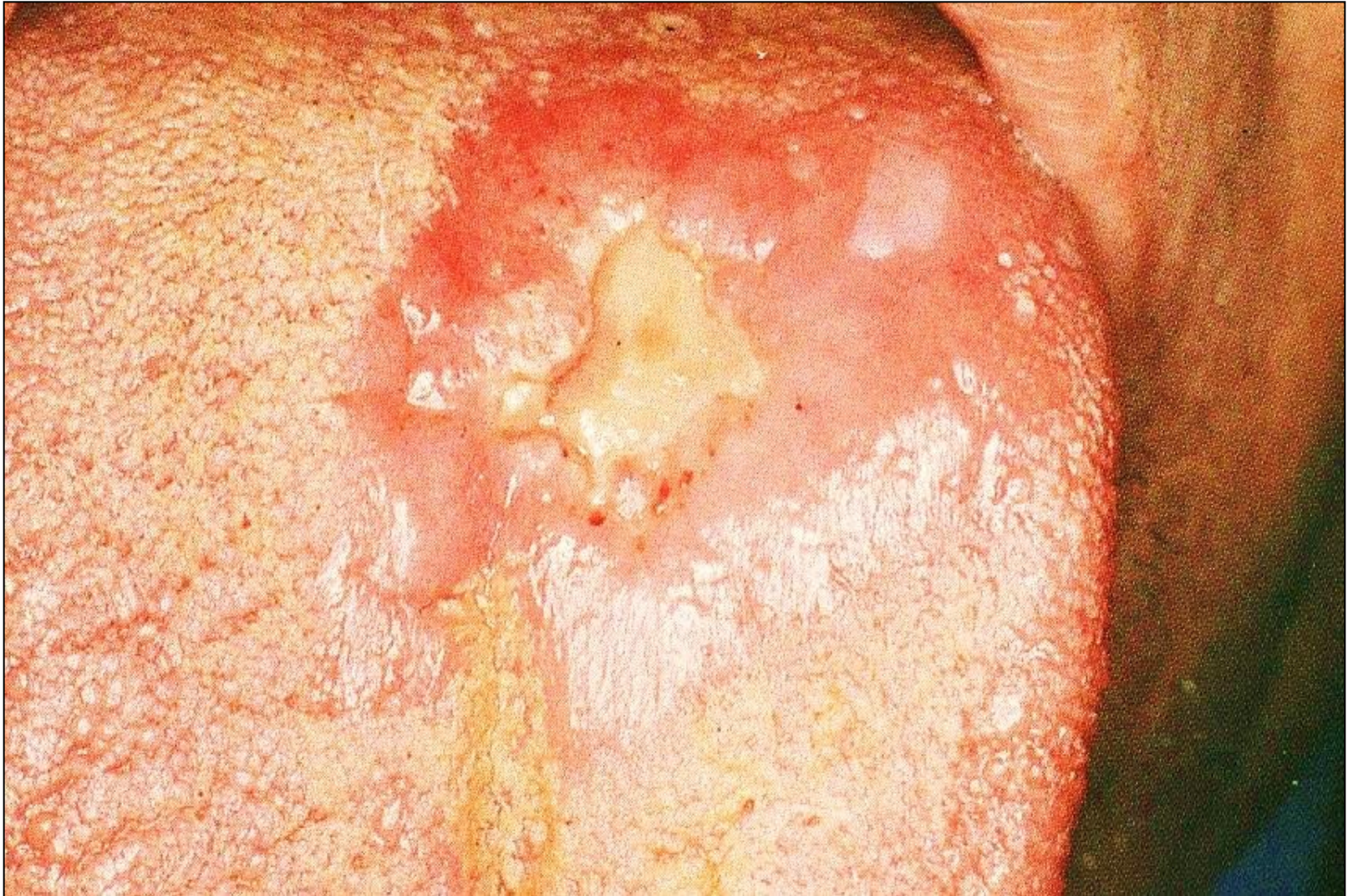I.



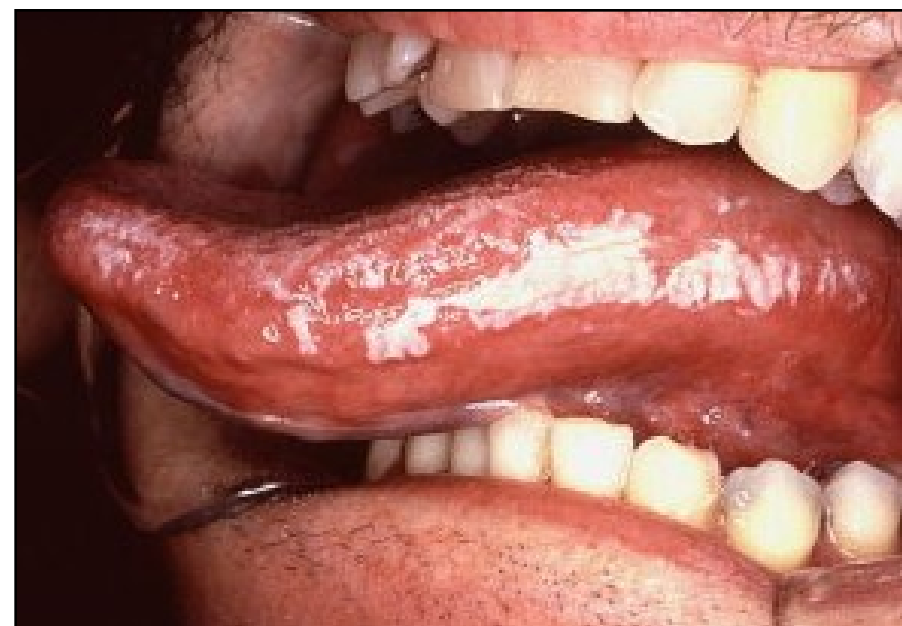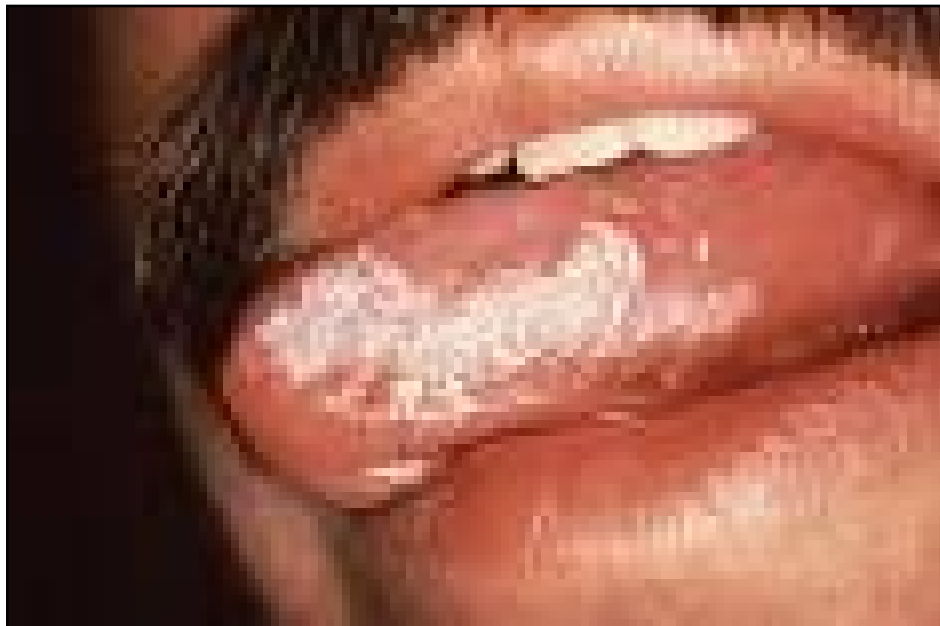
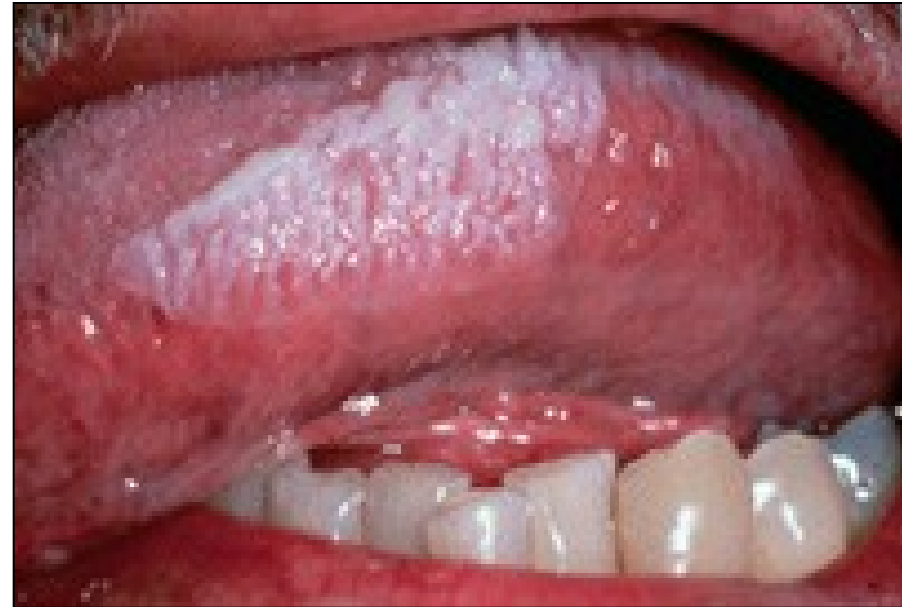- gumma
- glossitis luetica
- interstitialis
- superficialis
- et profunda
- lingua lobata

III.

TBC Tuberculous ulcer with bulging edges

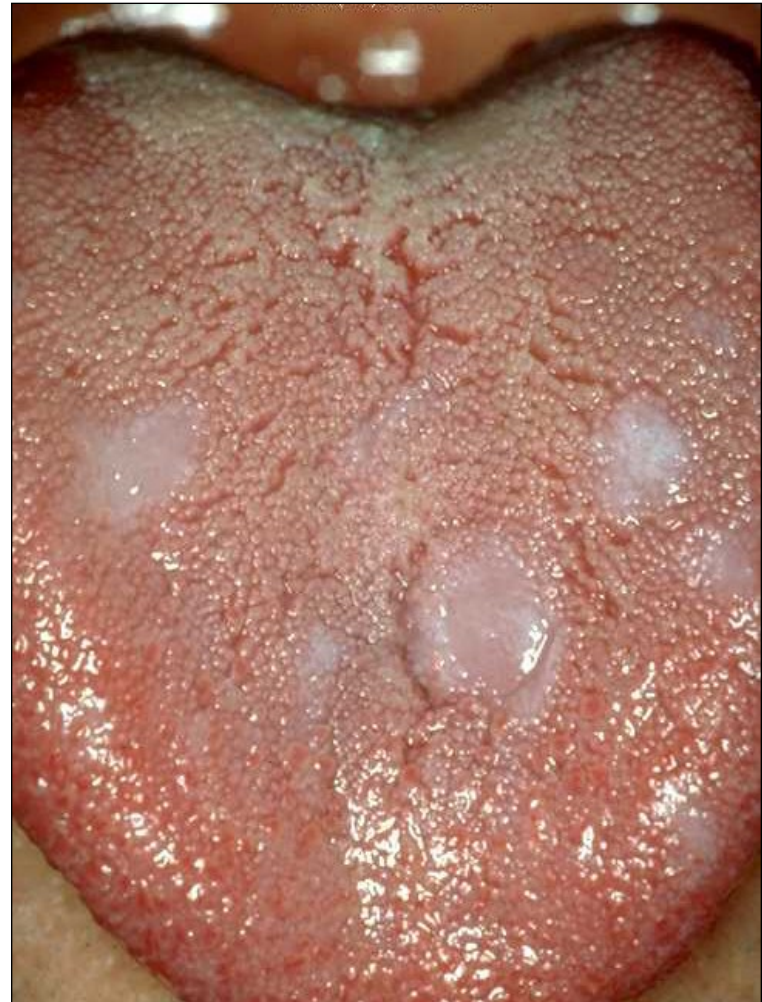


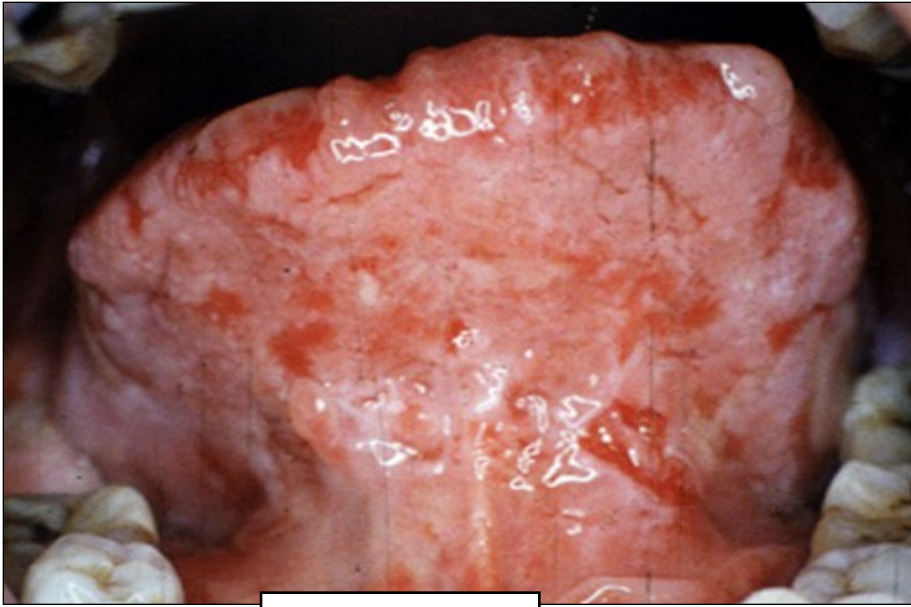
- HIV
- HSV, VZV
- hairy leukoplakia (HSV8)
- oral candidiasis
- aphthoid lesions
- Kaposi sarkoma



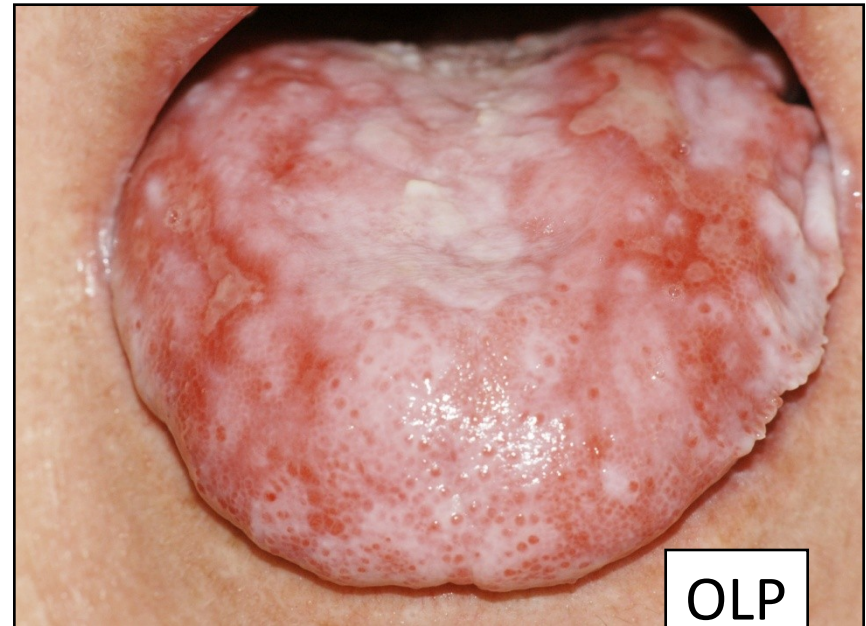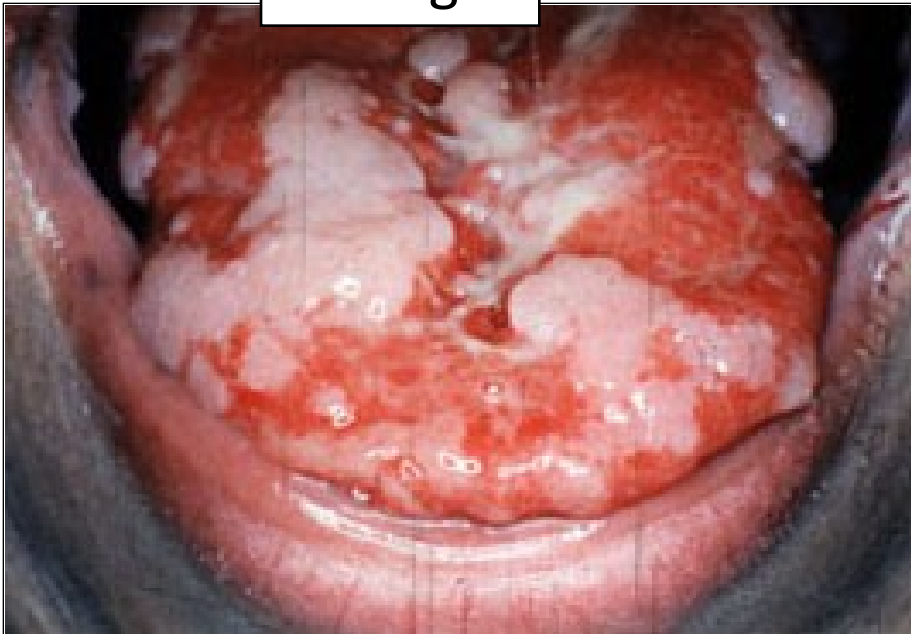
Manifestation of generalized disease

- Pemfigus
- Pemfigoid DLE
- Sclerodermia
- Sjögren's syndrome
- EEM
- OLP
- Psoriasis

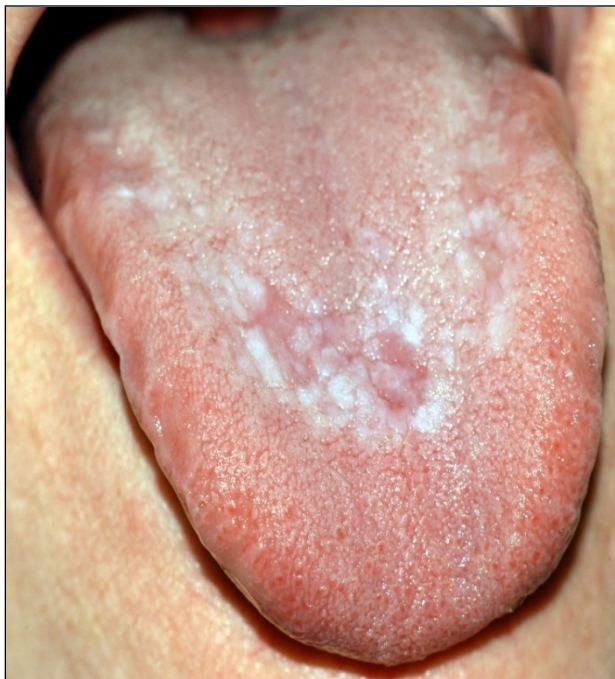
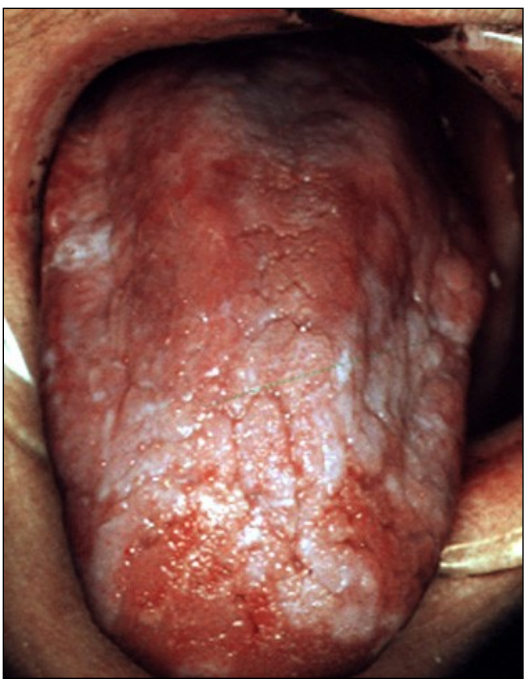
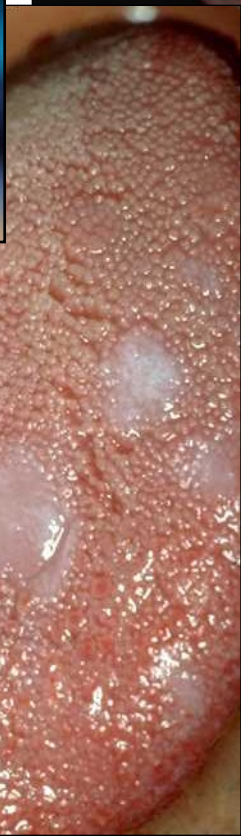
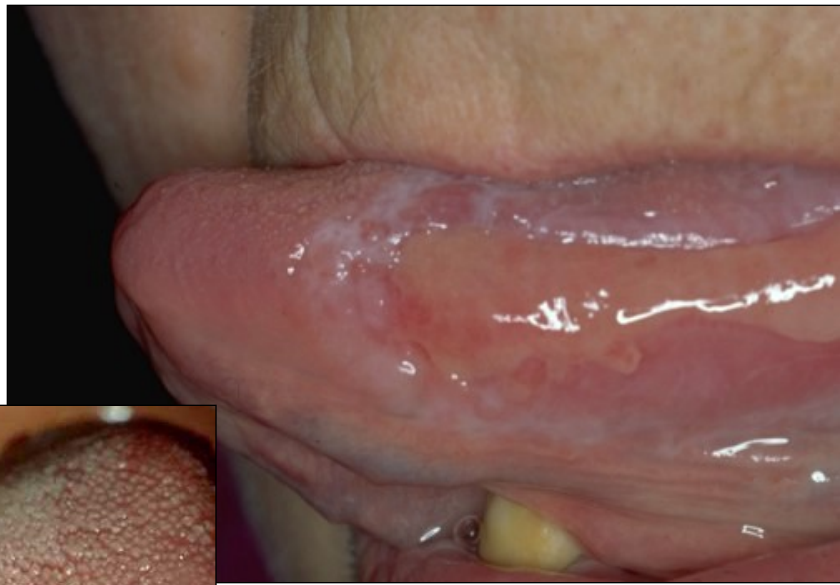
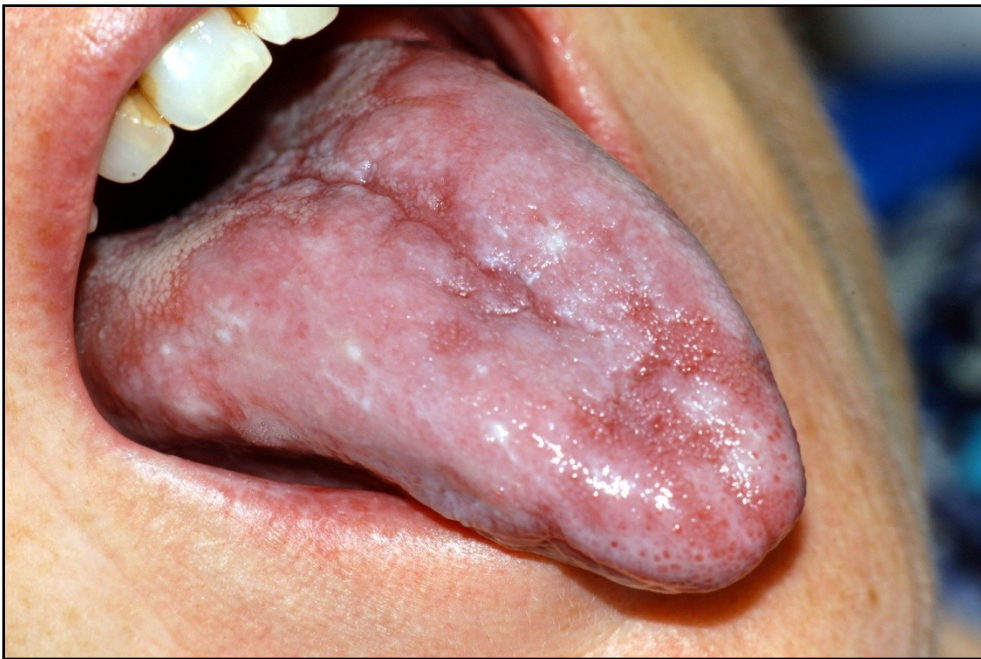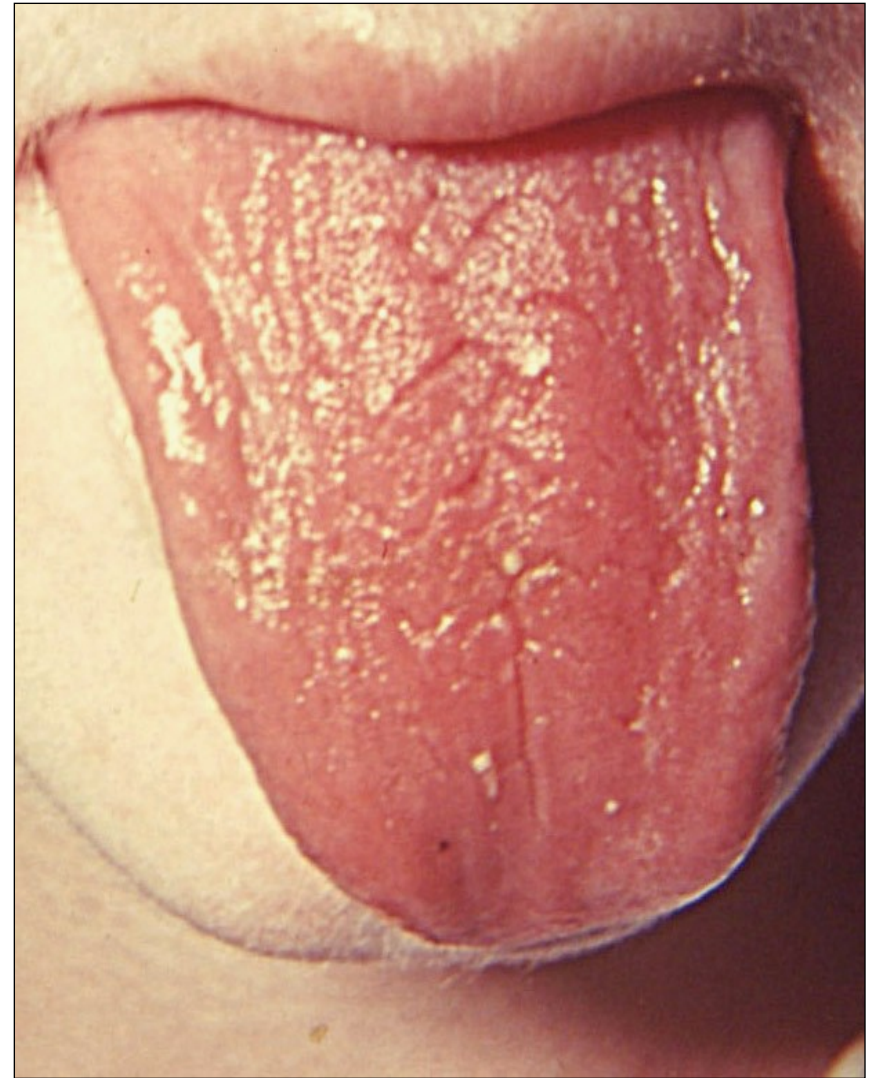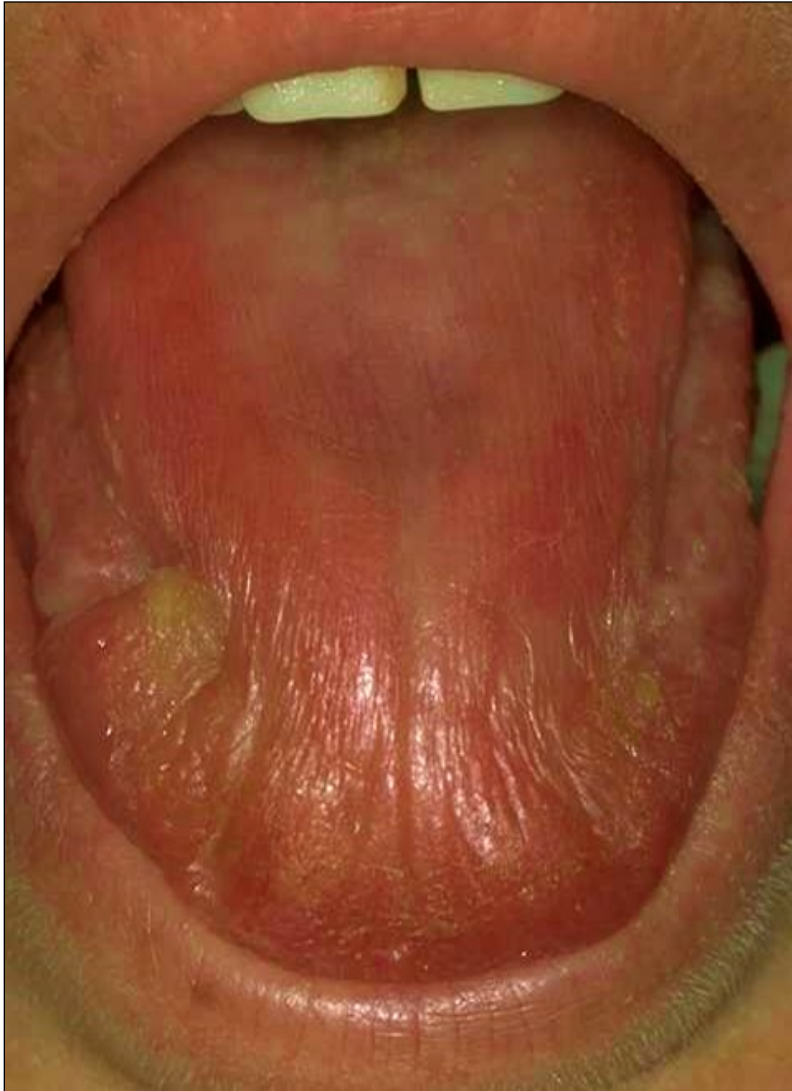Pemfigus



OLP



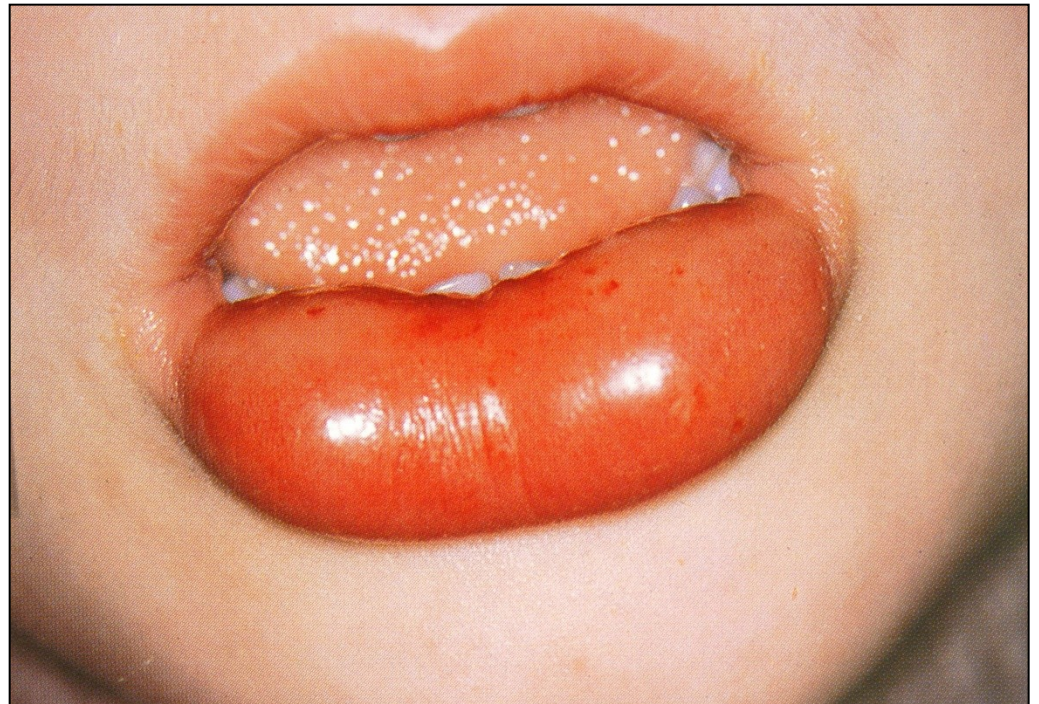OLP



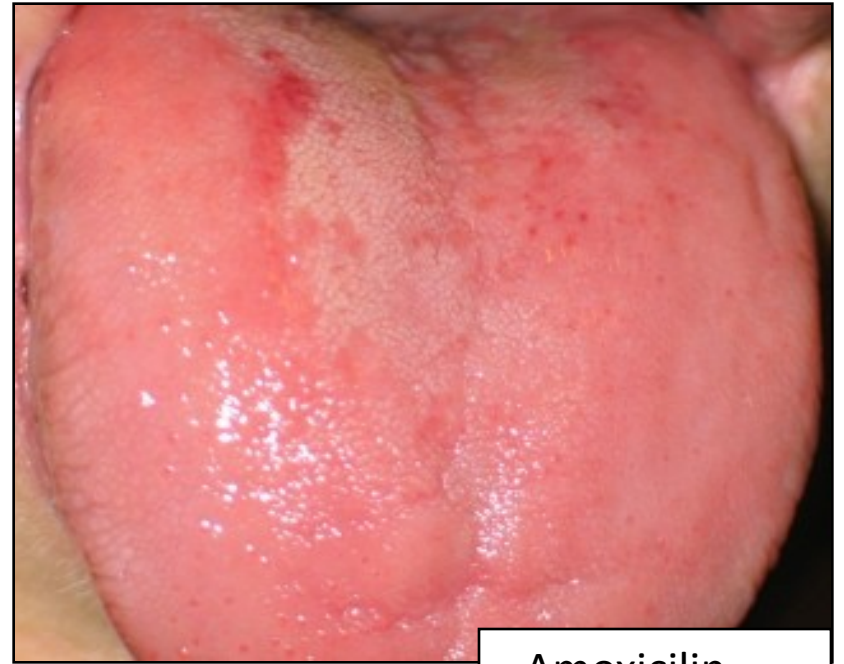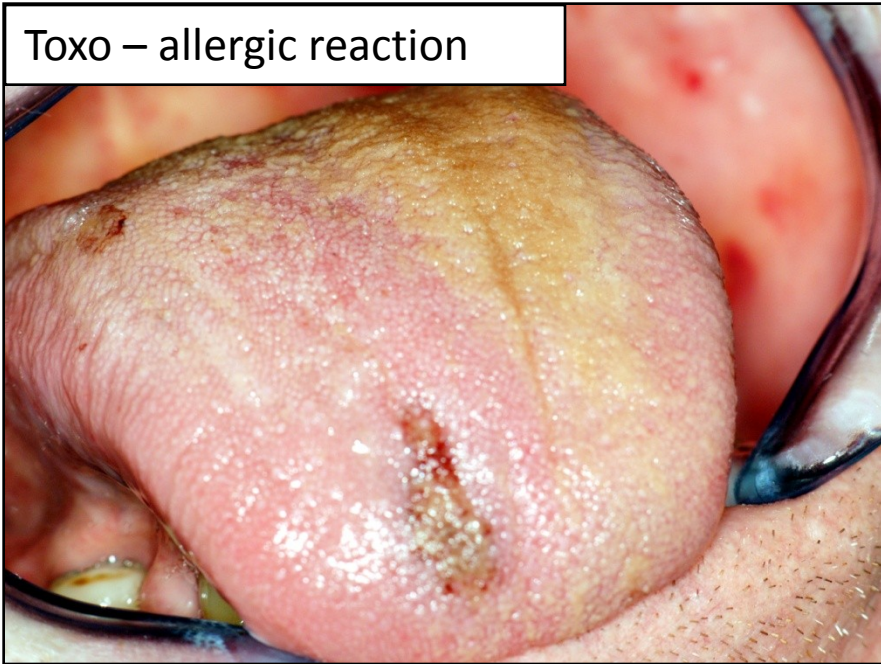
Sjögren's syndrome

Manifestation of generalized disease

- Allergic a toxo – allergic reactions
- Angioedema

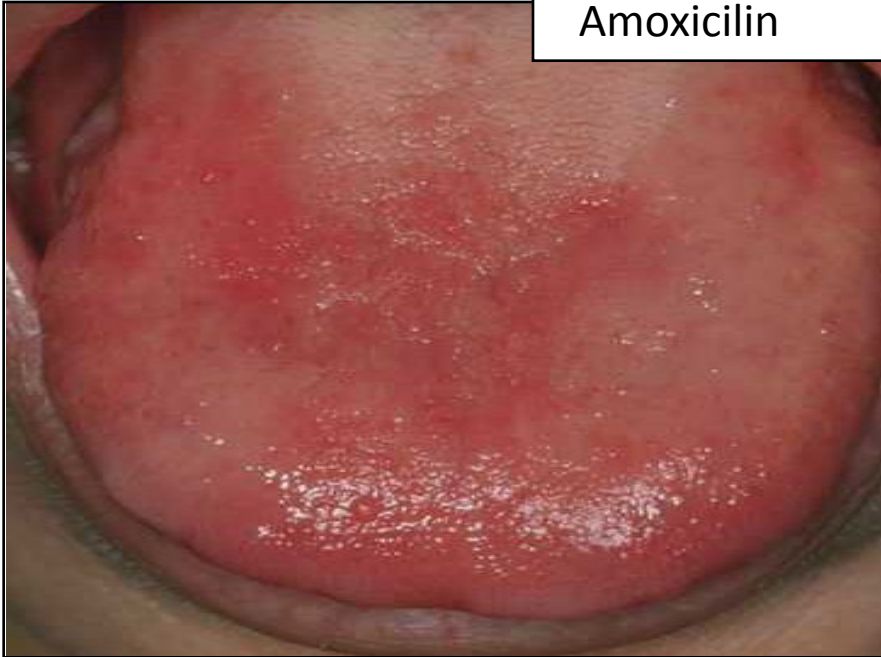

Toxo – allergic reaction

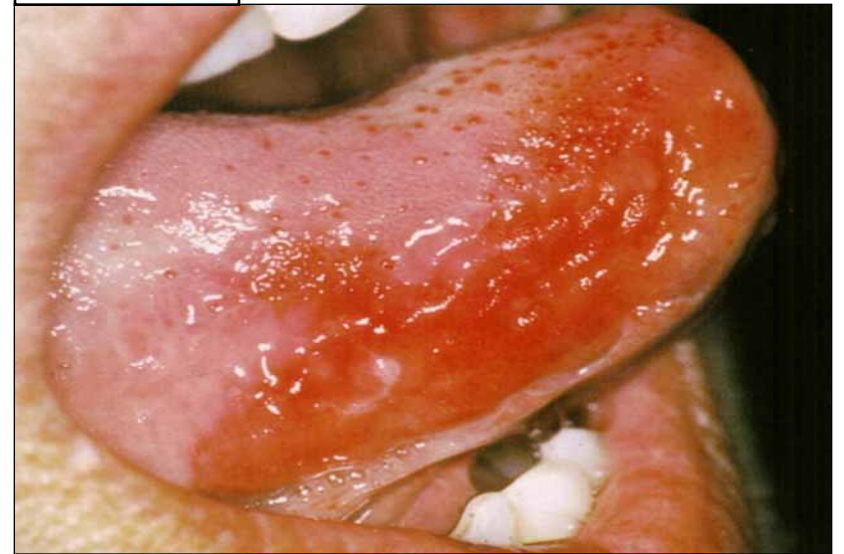

Amoxicilin

Amoxicilin

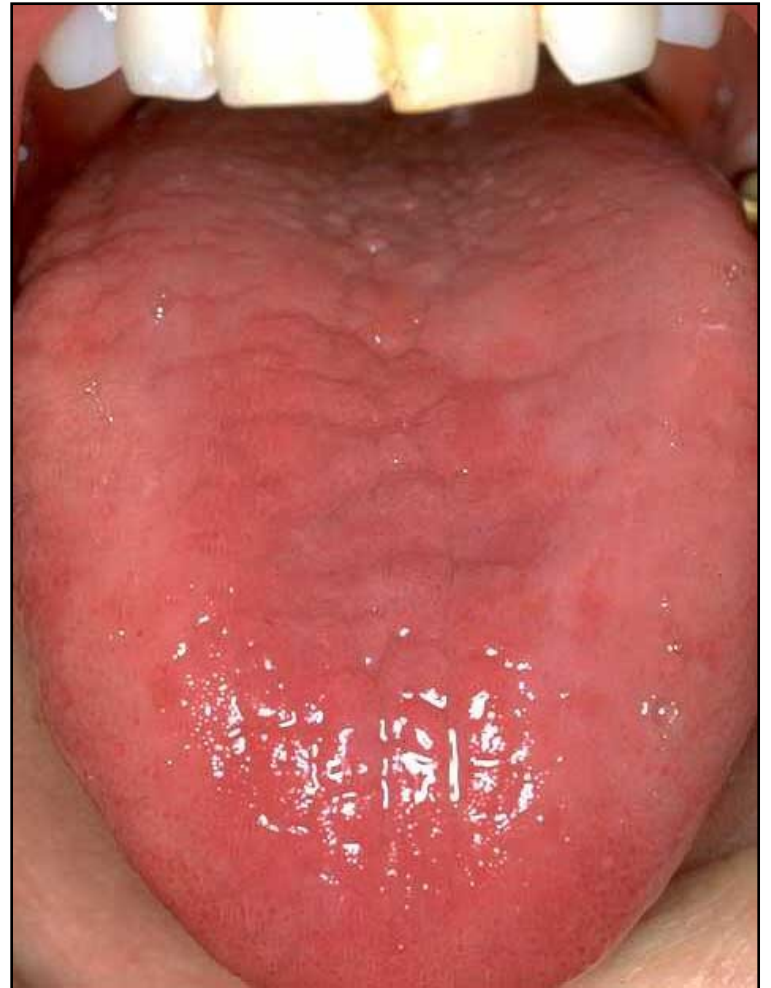

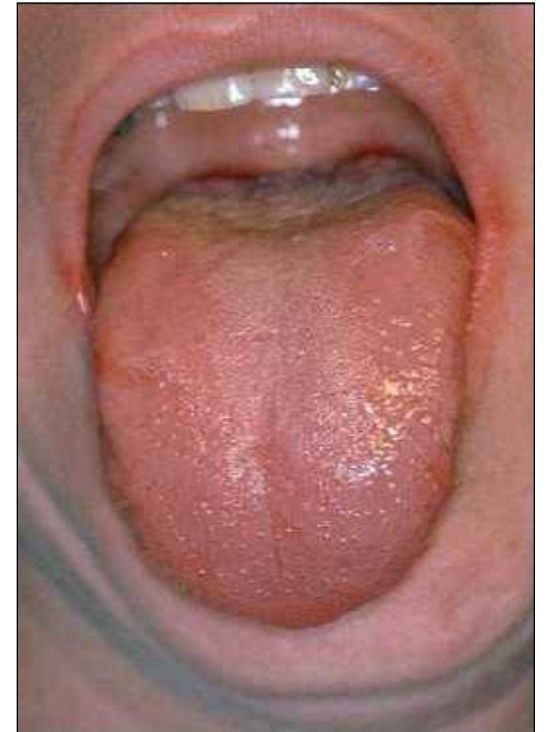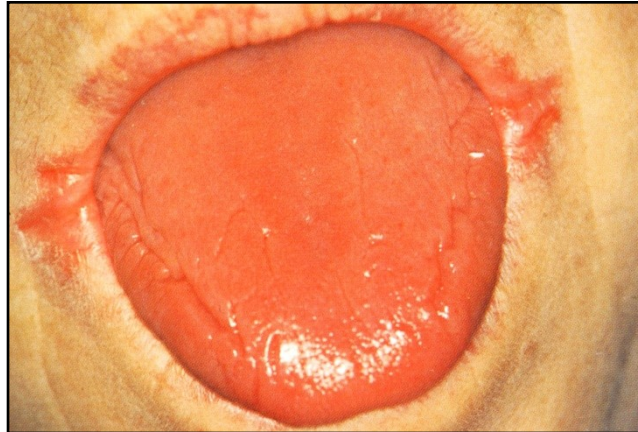
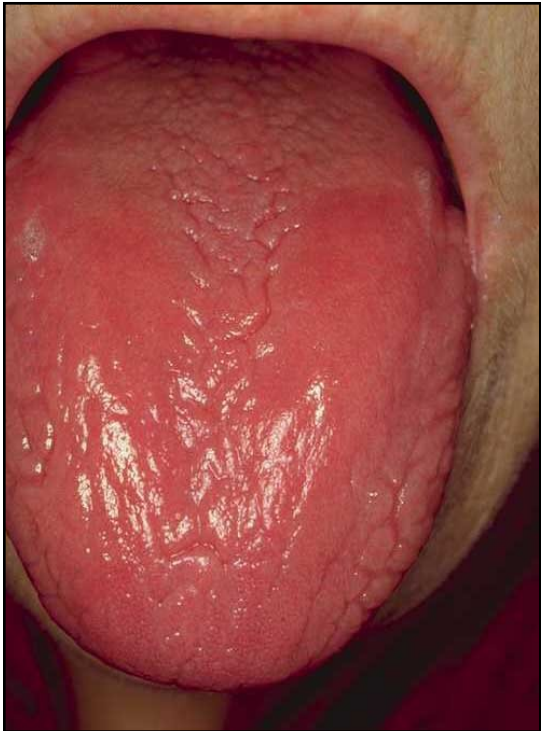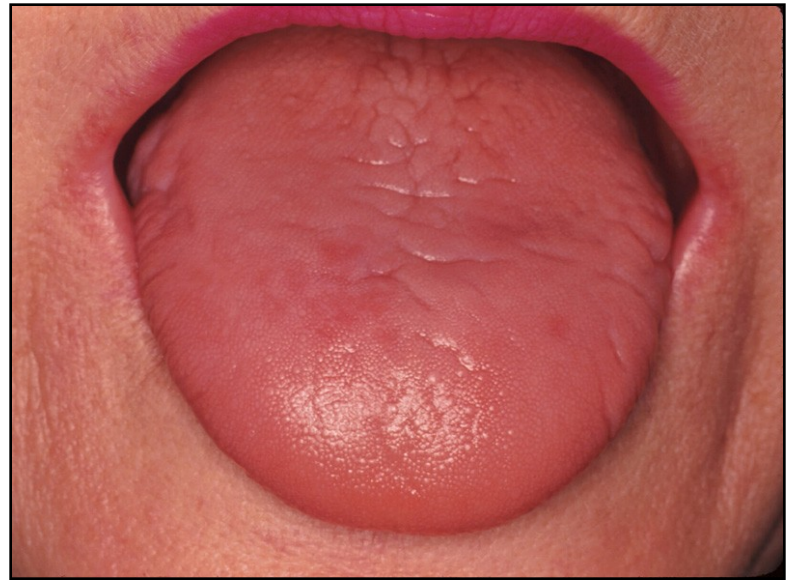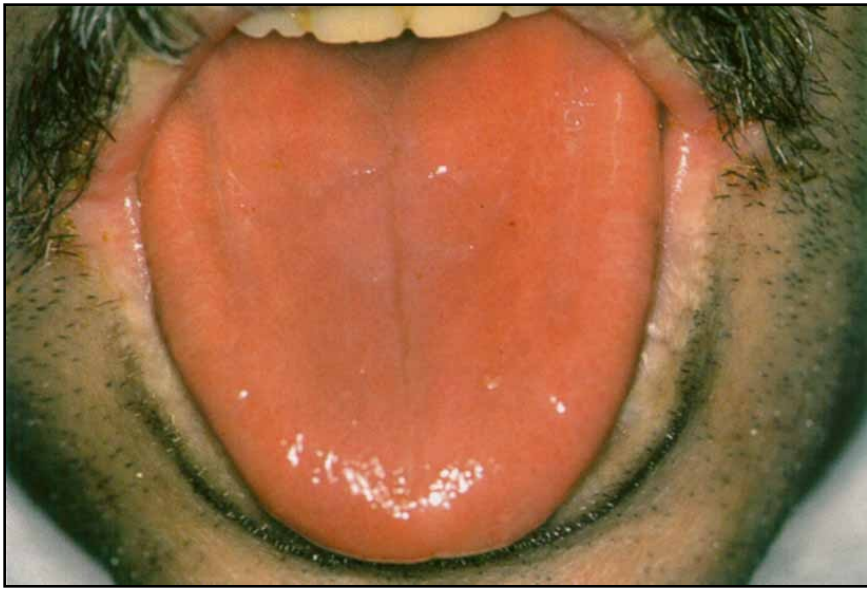
Eugenol

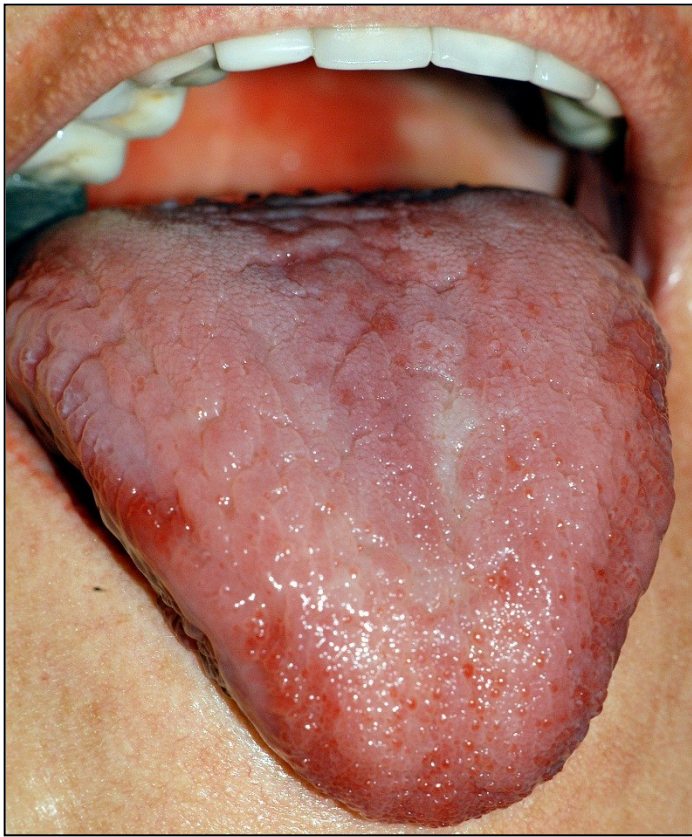

Manifestation of generalized disease

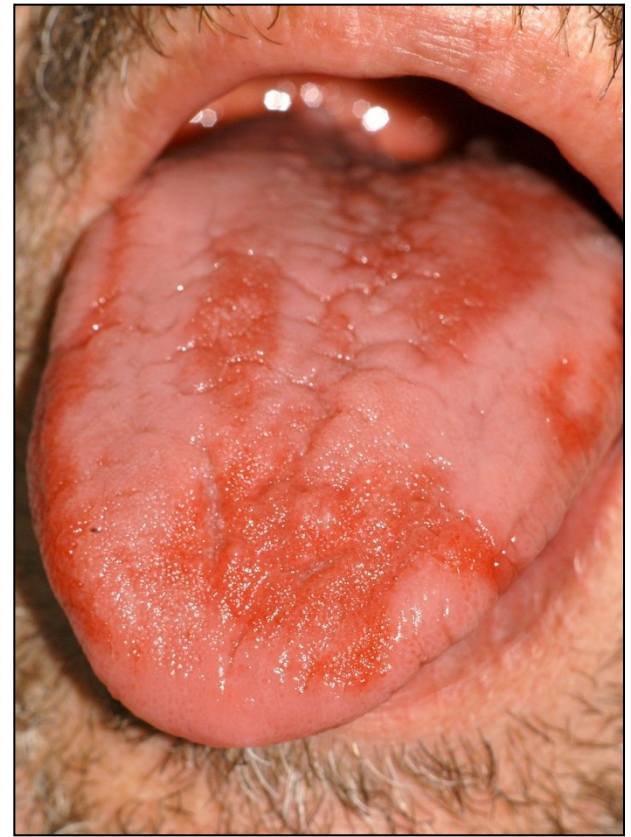- Blood disorders
 - Hemorrhagic diatheses
 - Anemias
 - Leukemias



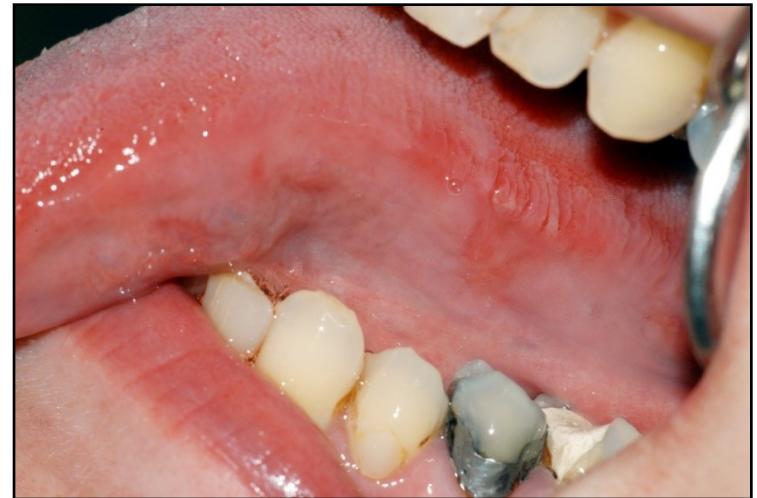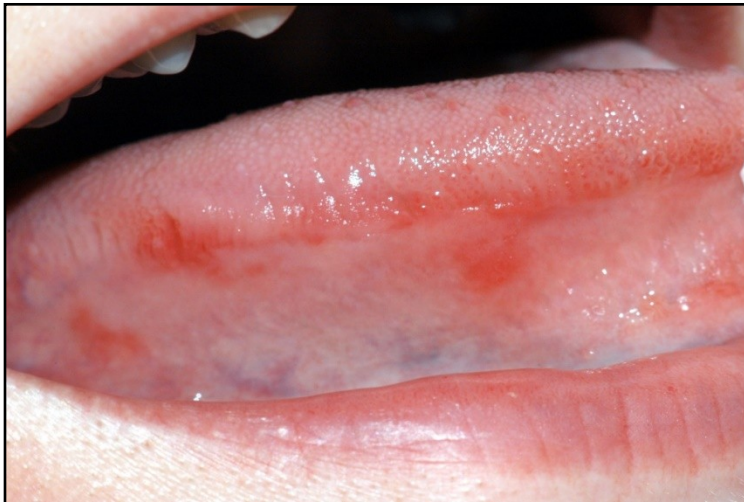




B12
deficiency

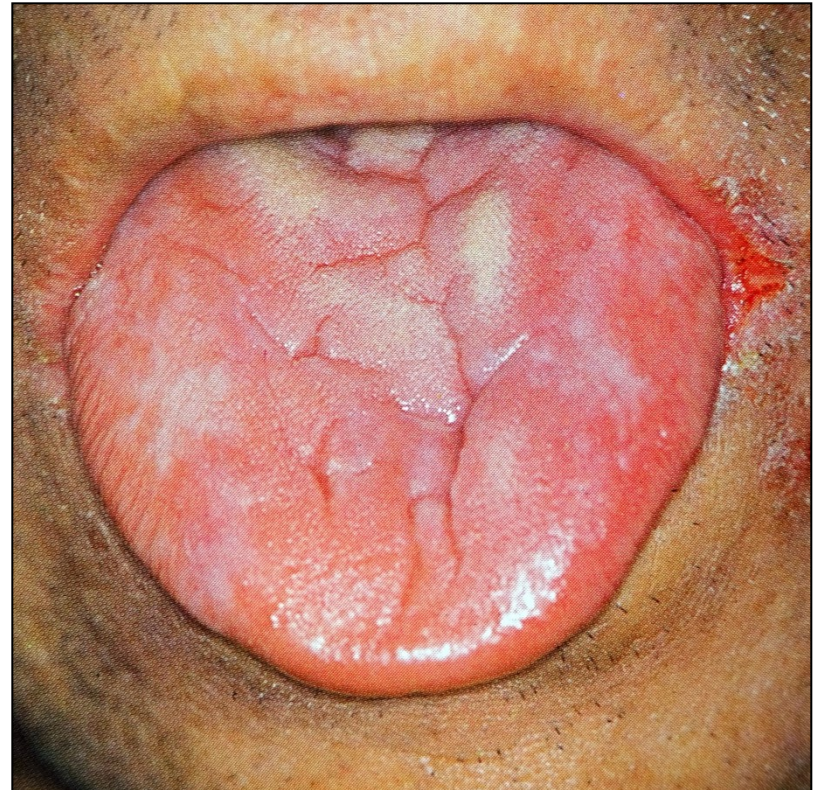

Folic acid
deficiency



Plummer - Vinson syndrome

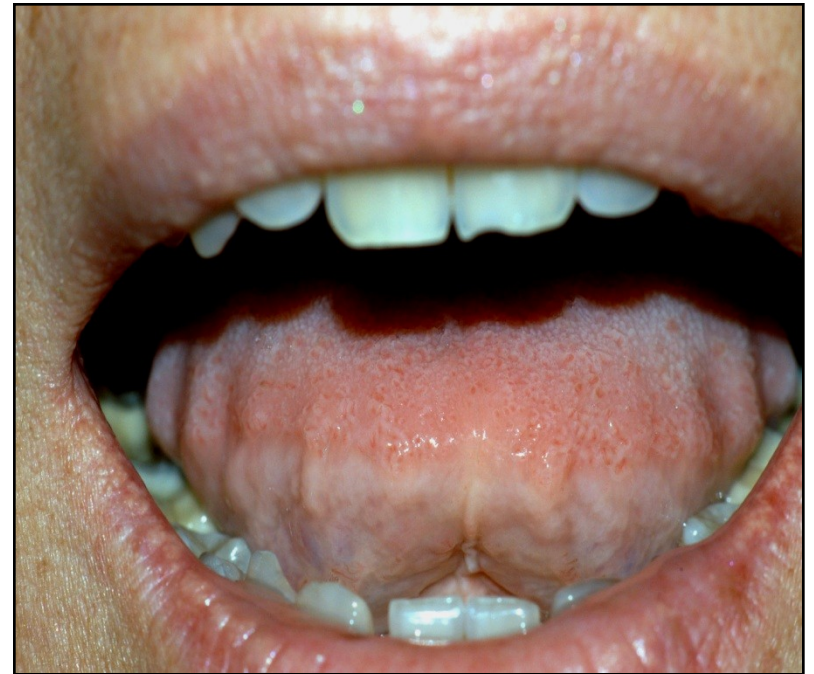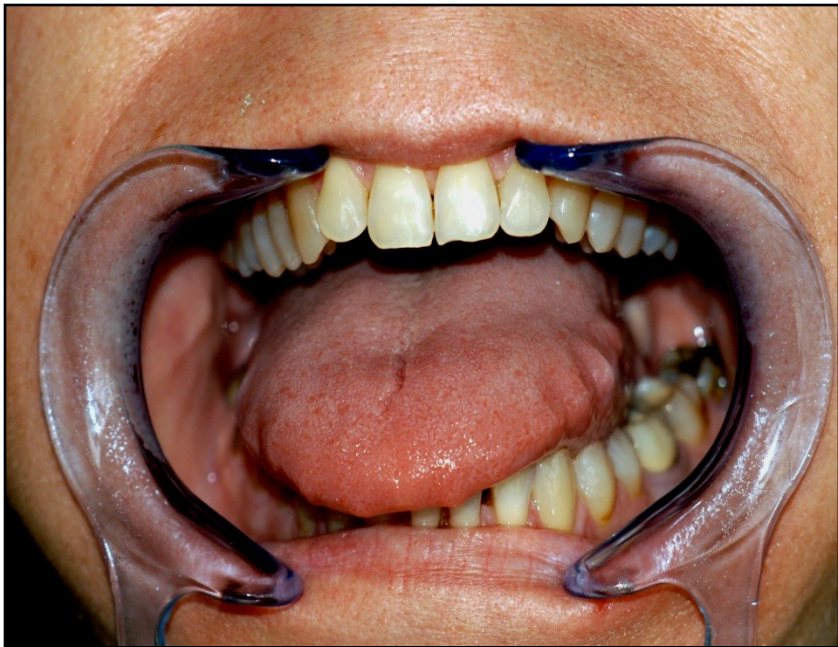- iron deficiency anemia
 - atrophic glossitis
 - dysphagia
 - koilonychia
- precancerous



Manifestation of generalized disease endocrinopathy

- Hypothyreosis

myxoedema → macroglossy; xerostomia



Manifestation of generalized disease

- **Diabetes mellitus**

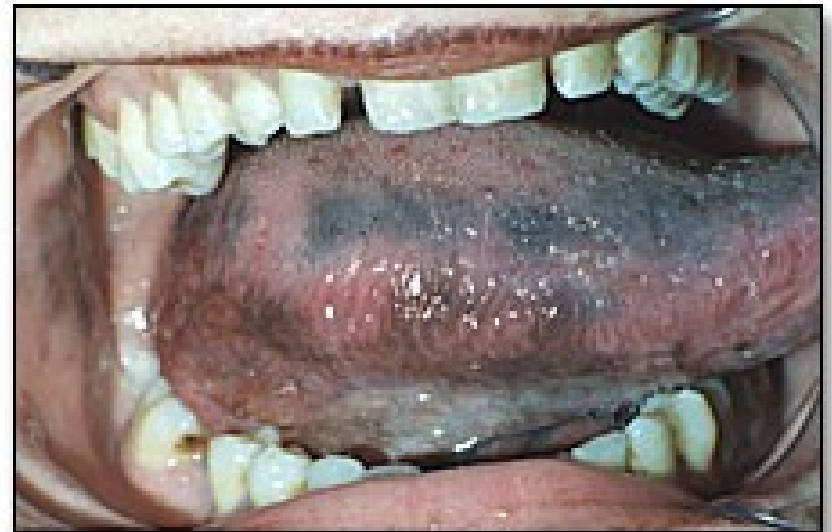
GRM, candidasis, glossodynia

- **Acromegaly** (overproduction of STH)

at 50 % macroglossy

- **M. Addison**

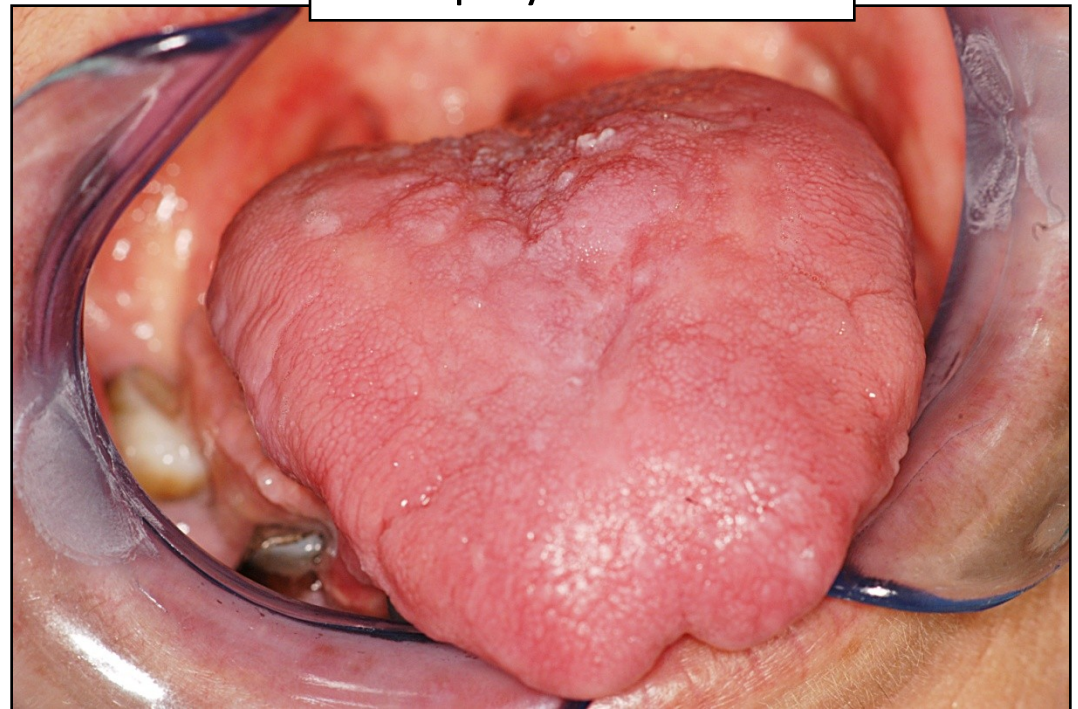
(adrenal cortex
insufficiency,
MSH - failure of
the feedback)



Manifestation of generalized disease

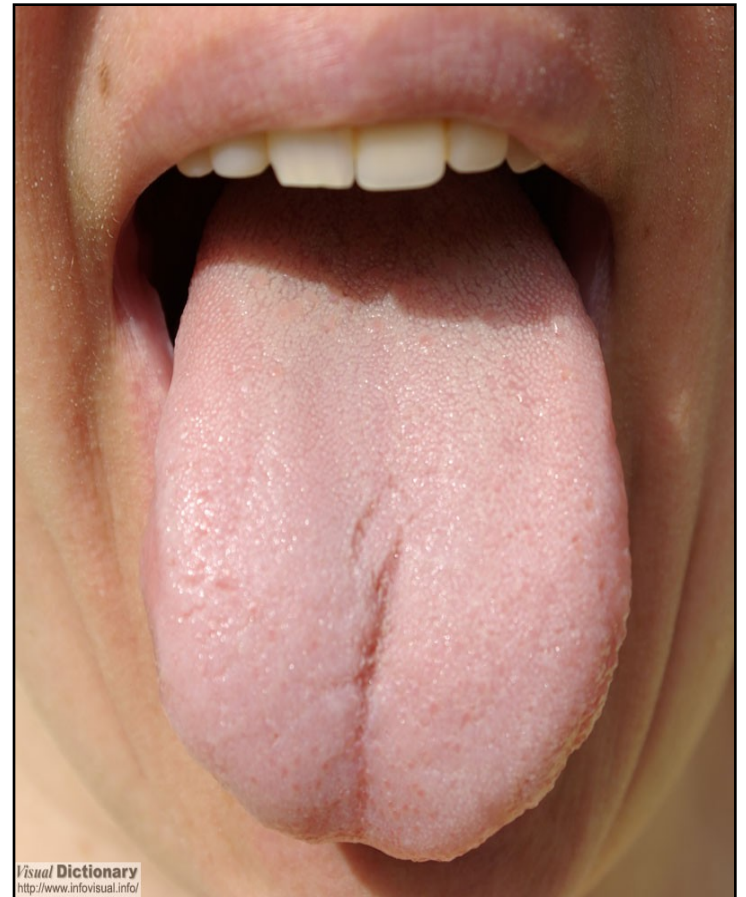
- Metabolic disorders of proteins, fat, carbohydrates
- Amyloidosis
- Mucopoly - saccharidosis

Mucopolysaccharidosis



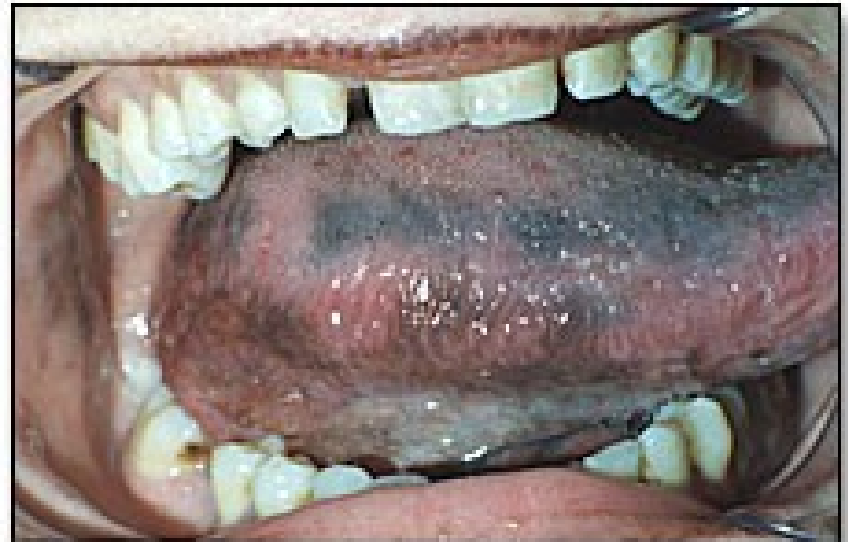Manifestation of generalized disease

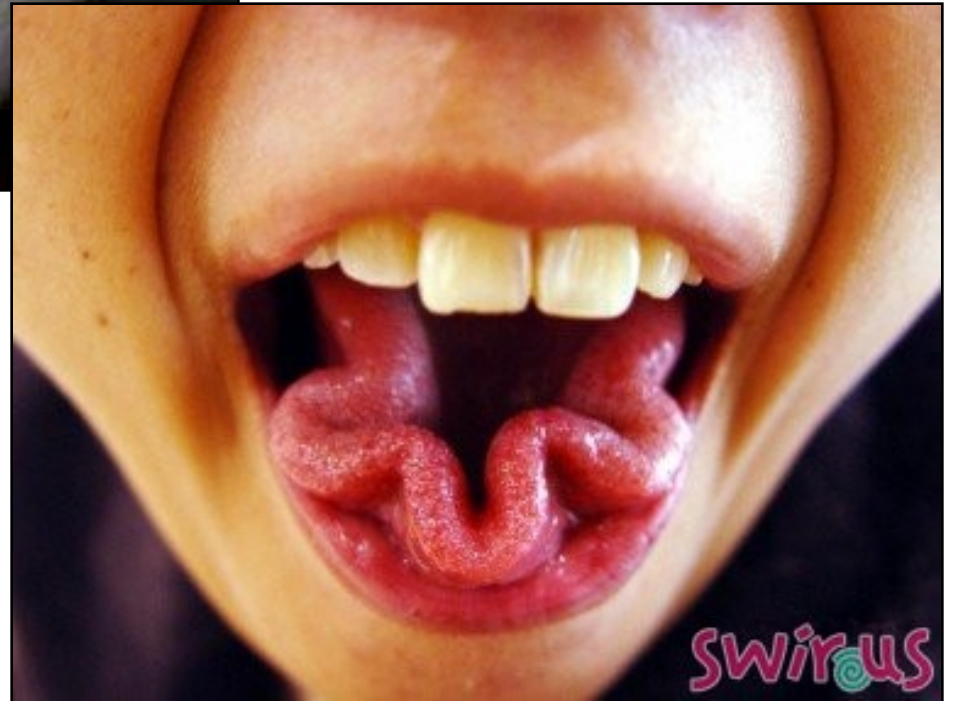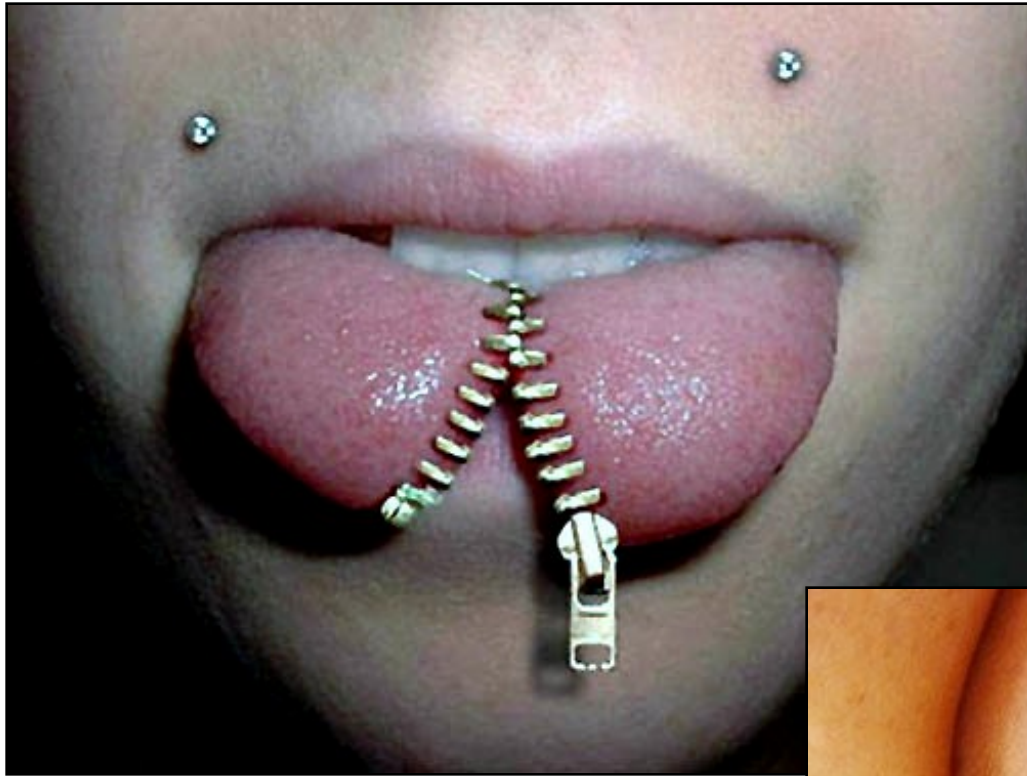- Neurologic diseases
- Neuralgia - III. branch n. V, n. IX
- Palsies, paralysis
- Glossodynia



Pigmentations

- Manifestation of generalized disease
 - Addison's disease
 - Peutz - Jeghers sy



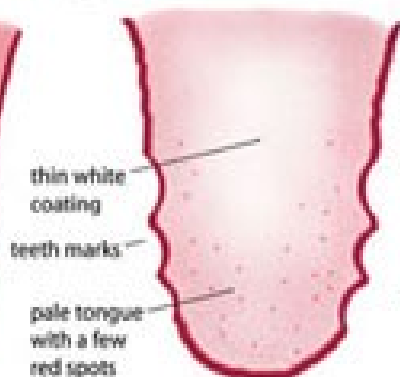


Which Tongue Are You?

Nine Common Syndromes & Possible Symptoms.
find out more at www.chinalifeweb.com

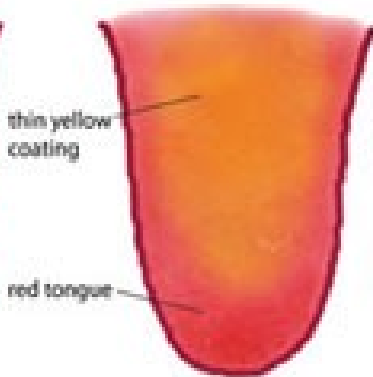


NORMAL



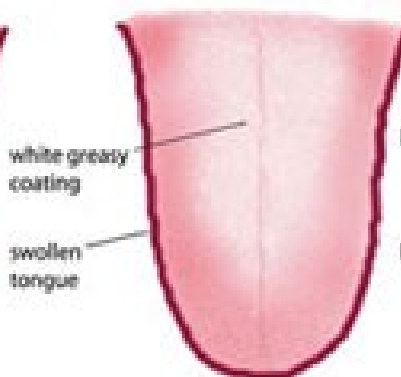
QI DEFICIENCY

Fatigue, Poor appetite,
 Spontaneous sweating,
 Shortness of breath,
 Over-thinking and
 worrying...



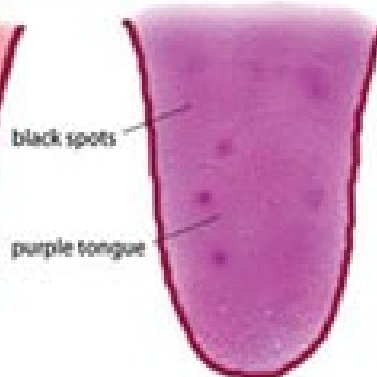
HEAT

Feel hot, Sweat easily,
 Thirsty, Constipated,
 Irritable and bad
 tempered, Skin
 problems...



DAMP RETENTION

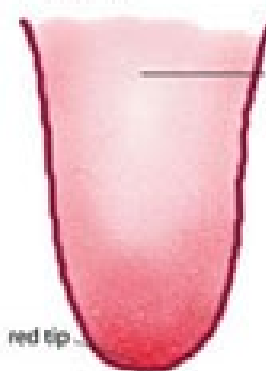
Bloated, Fullness in
 chest and abdomen,
 Feel heavy and
 lethargic...



BLOOD STASIS

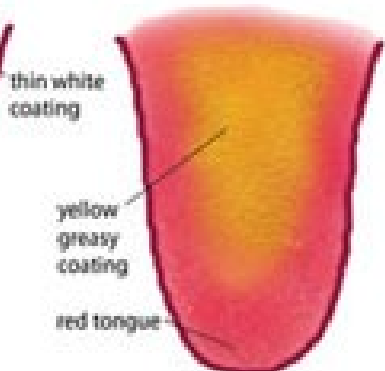
Cold limbs, Varicose
 veins, Painful legs,
 Headaches, Chest
 pain, Liver spots,
 Lack of skin lustre...

© AcuMedic Ltd 2008. All Rights Reserved. Unauthorised copying prohibited



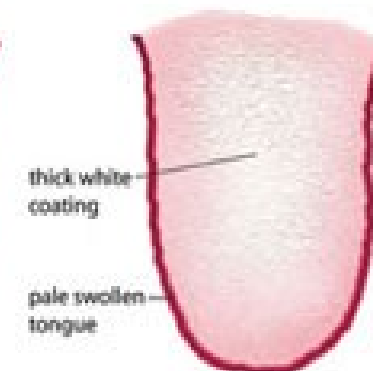
QI STAGNATION

Stressed, Tendency
 to be depressed and
 upset, Unstable
 emotional state,
 PMT....



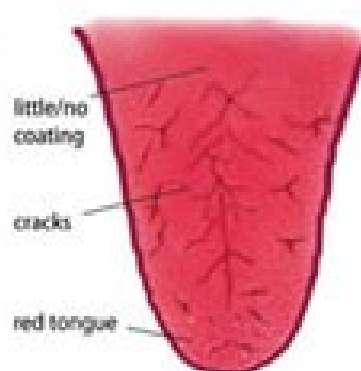
DAMP HEAT

Skin problems,
 Urinary infections,
 Clammy skin, Angry
 and uncomfortable...



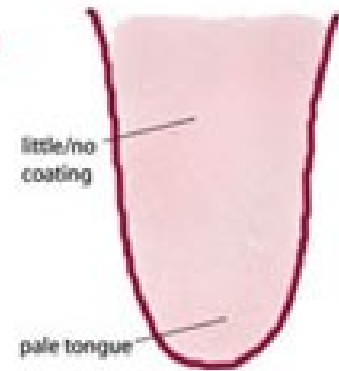
YANG DEFICIENCY

Feel cold easily, Pale
 complexion, Back pain,
 Tendency to panic,
 Emotionally low,
 Impotence, Infertility...



YIN DEFICIENCY

Hot Flushes, Sweat at
 night, Insomnia, Irritable,
 Ringing in the ears,
 Menopause...



BLOOD DEFICIENCY

Dizziness, Fatigue,
 Palpitations, Poor
 concentration and memory,
 Insomnia, Women's
 problems...