

ABNORMALITIES OF TEETH

V. Žampachová

Dental anomalies

- defects in tooth development
- environmental alterations of teeth

causes - hereditary, systemic, traumatic or local
factors (eg. drug)

Developmental alterations

Idiopathic or hereditary conditions

- Alterations in the number of teeth
- Alterations in the size of teeth
- Alterations in the shape of teeth
- Alterations in the structure of teeth

Environmental alterations

Influenced by environmental forces

- Developmental tooth defects
- Postdevelopmental structure loss
- Discoloration of teeth
- Localized disturbances in eruption

Environmental effects on tooth structure

- Turner's hypoplasia
- Hypoplasia due to antineoplastic therapy
- Dental fluorosis
- Syphilitic hypoplasia

Postdevelopmental loss of structure

- Tooth wear – attrition
 - abrasion
 - erosion
 - abfraction
- Internal and external resorption

Environmental discoloration

- Extrinsic stains
- Intrinsic stains

Localized disturbances in eruption

- Premature eruption
- Retarded eruption
- Premature loss
- Deciduous teeth persistence
- Primary impaction
- Ankylosis +/- reimposition

Histology of enamel

- Formed by ameloblasts
 - 95% mineralized anorganic material
 - 5% organic
 - 98% calcified
 - Consists of enamel rods or prisms
 - Yellow to grayish white
- Strong, but prone to splits and chips
- Hardest structure in body
- Non-reparative
- Subject to caries
- Subject to wear

Environmental effects on tooth structure

- Ameloblasts in the developing tooth germ highly sensitive to external forces → multiple possibilities of enamel abnormalities.
- No remodeling → permanent defects
- 3 stages: matrix formation
mineralization
maturation

Factors associated with enamel defects

Systemic

- Birth-related trauma (hypoxia, premature b., prolonged labor)
- Chemicals (chemotherapy, fluoride, Pb, TTC, thalidomide)
- Chromosomal abnormalities (trisomy 21)
- Infections (CMV, varicella, rubella, syphilis, ..)
- Inherited diseases (phenylketonuria, osseous dysplasia, ..)
- Malnutrition (generalized, vit. A, D def.)
- Metabolic diseases (celiac d., hypoparathyroidism, renal d.)
- Neurologic disorders (mental retardation,..)

Factors associated with enamel defects

Local

- Local acute mechanic trauma (falls, traffic accidents, gunshot, mechanical ventilation, ritual mutilation,..)
- Electric burn
- Irradiation
- Local infection (periapical etc.)

Cause period

- Prenatal
- Neonatal
- Postnatal

Prenatal

- Vertical transmission of infection, i.e. rubella, syphilis
- Maternal systemic disease

Neonatal

- haemolytic disease of the newborn
- hypocalcaemia
- premature birth/prolonged labour
(ischaemia)

Postnatal

- severe childhood infections, esp. viral exanthematic diseases
- chronic diseases in childhood, e.g. congenital heart disease, gastrointestinal and endocrine diseases
- nutritional deficiency, e.g. vitamin D
- cancer chemotherapy
- excess fluoride ions
- trauma

Enamel defects

- different causes may result in similar defects
- possible timing of cause in deciduous enamel
- rough estimate in permanent teeth
- very common ($\geq 50\%$)

Enamel defects patterns

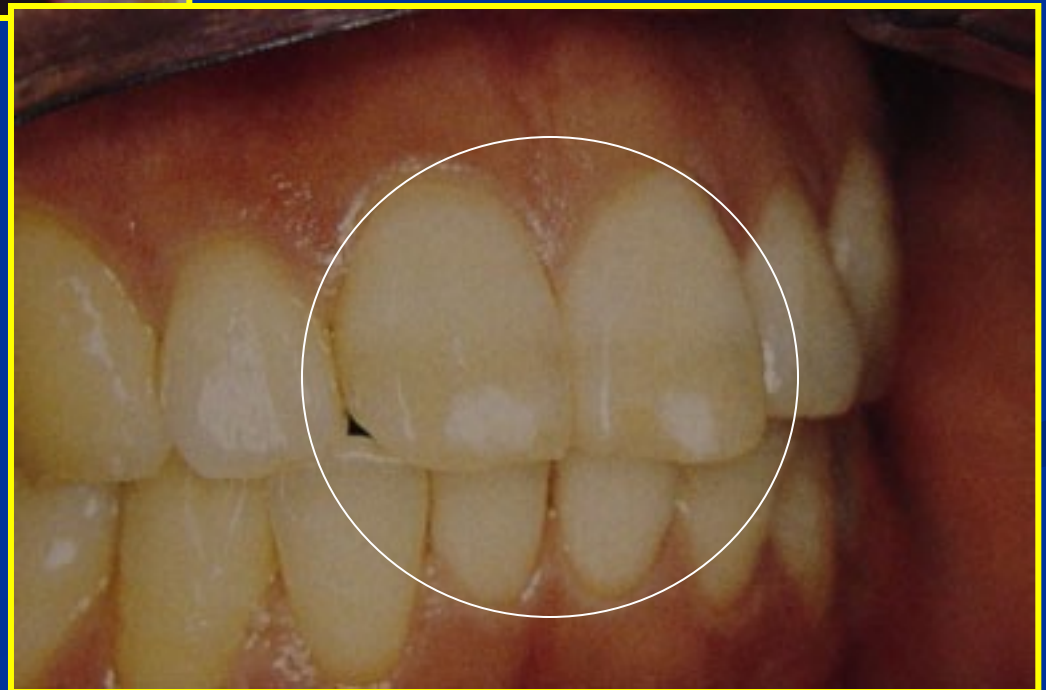
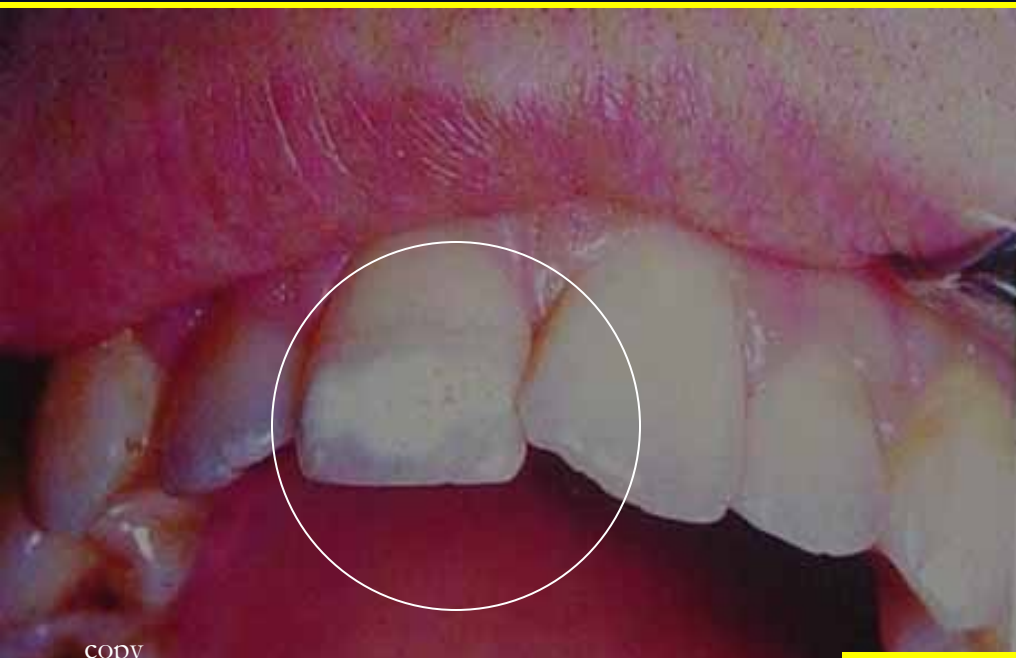Localized x multifocal (number of teeth affected)

Partial x global (amount of surface)

- **Hypoplasia** (pits, grooves, parts missing)
- **Diffuse opacities** (variations of translucence, white)
- **Demarcated opacities** (decreased translucence, sharp demarcation, white → brown)

mild type

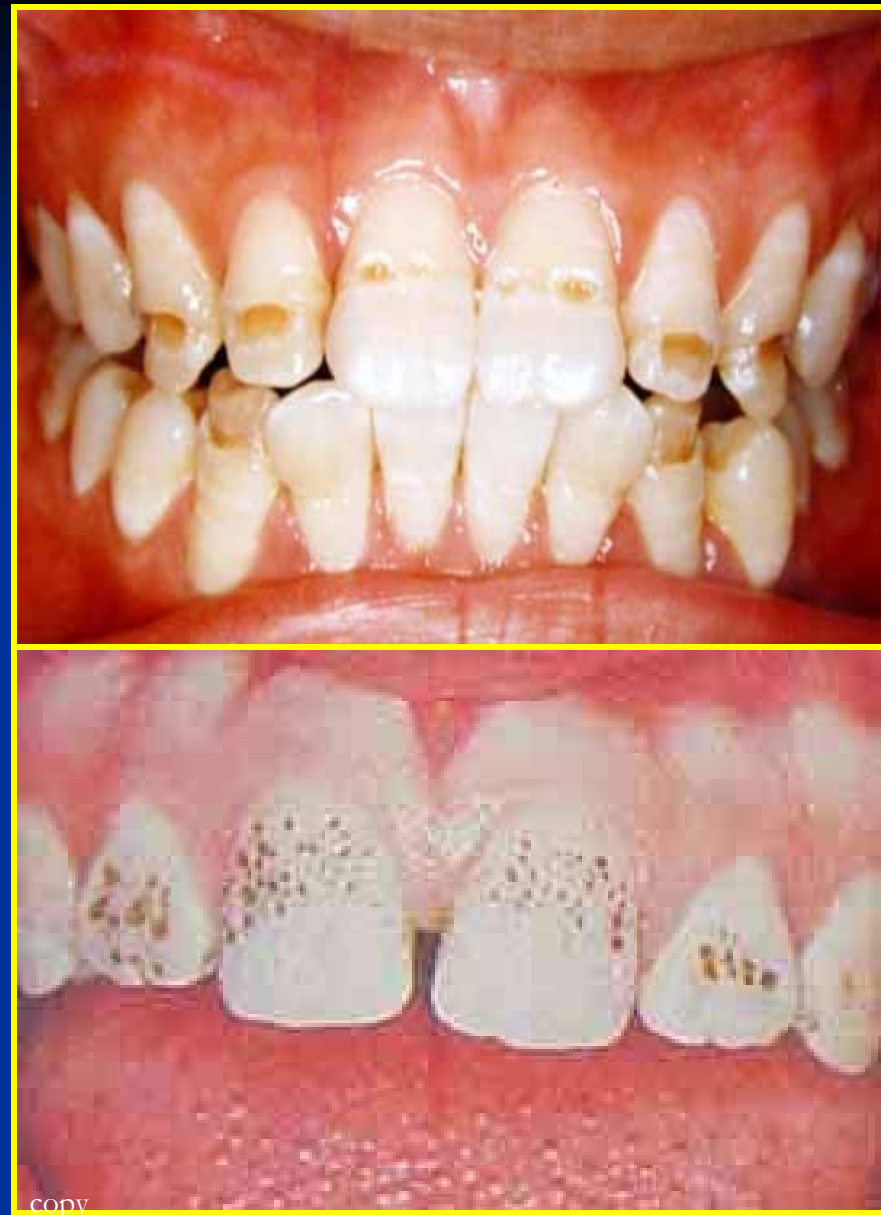smooth-surface enamel
white, opaque spots,
brown after eruption



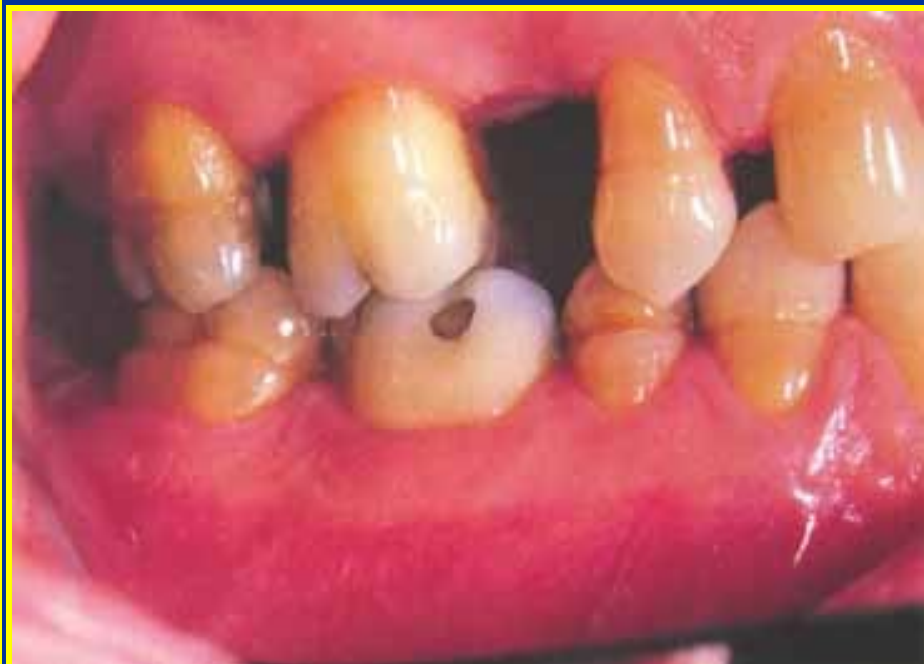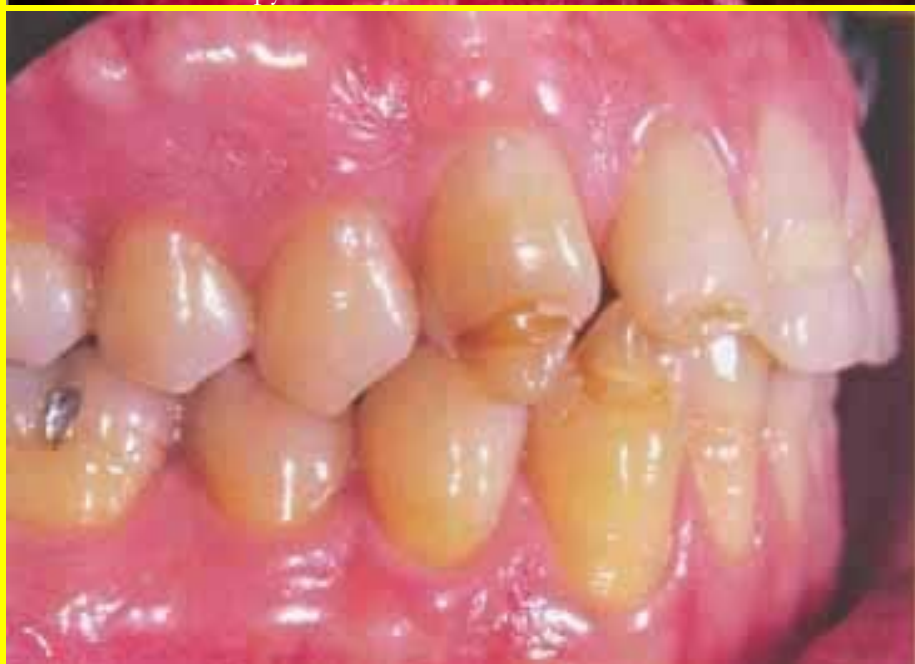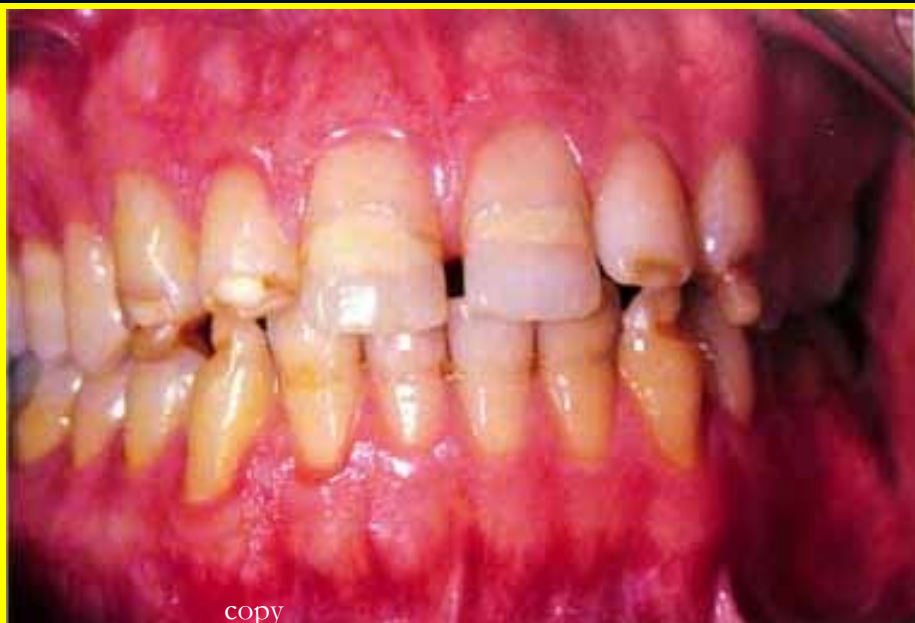copy

symmetrical

- horizontal grooves in the enamel surface
- pits in the enamel surface
- general reduction in the thickness of the whole enamel



symmetrical

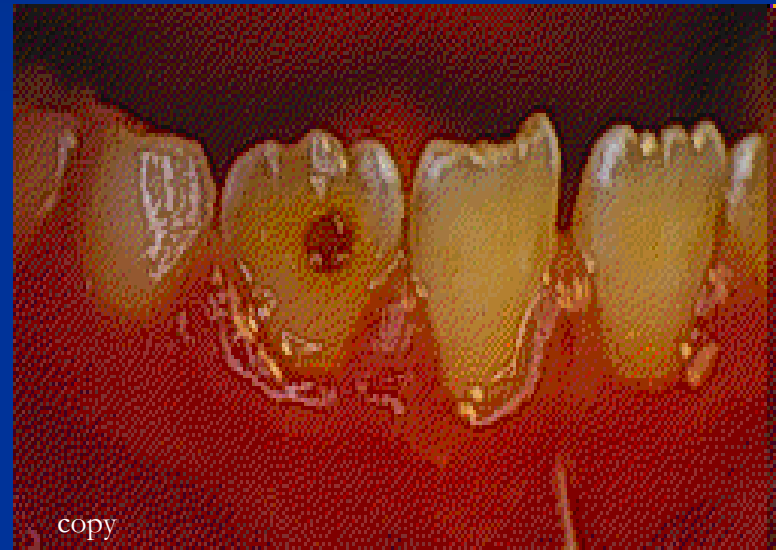

Turner's hypoplasia (Turner's tooth)

- *a local hypoplastic or hypomineralized defect in crown of a permanent tooth*
- extension of a periapical inflammatory disease (infection) or mechanical trauma from overlying deciduous tooth, disturbing the ameloblasts of the permanent tooth bud
- most common in lower premolars

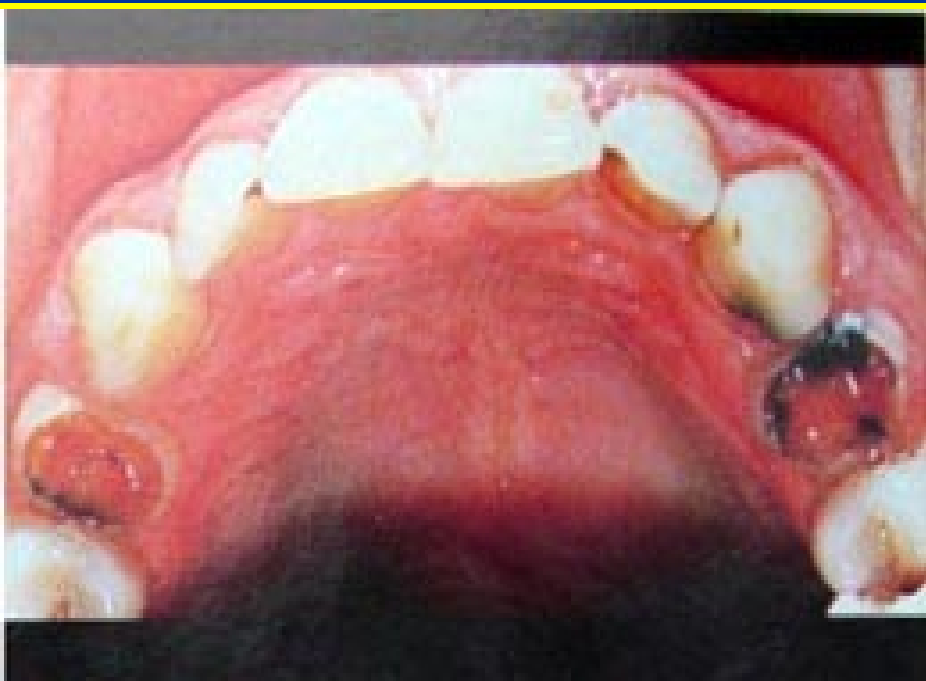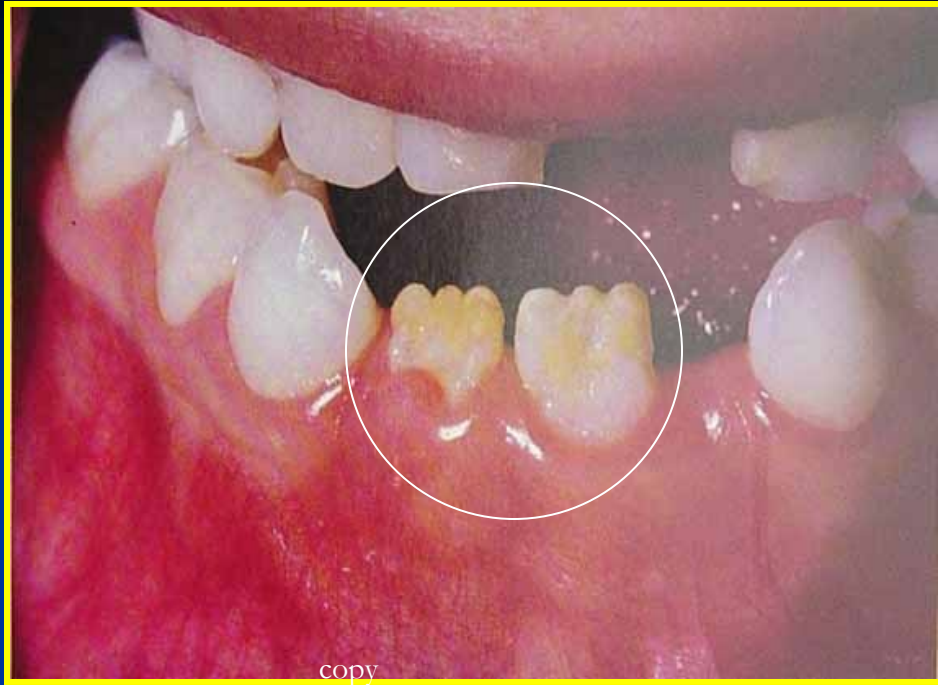
Localized enamel hypoplasia (Turner's teeth)

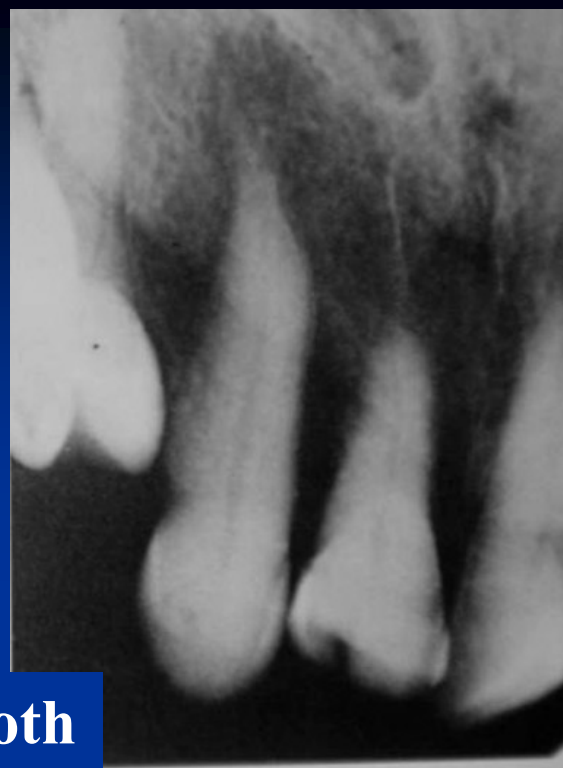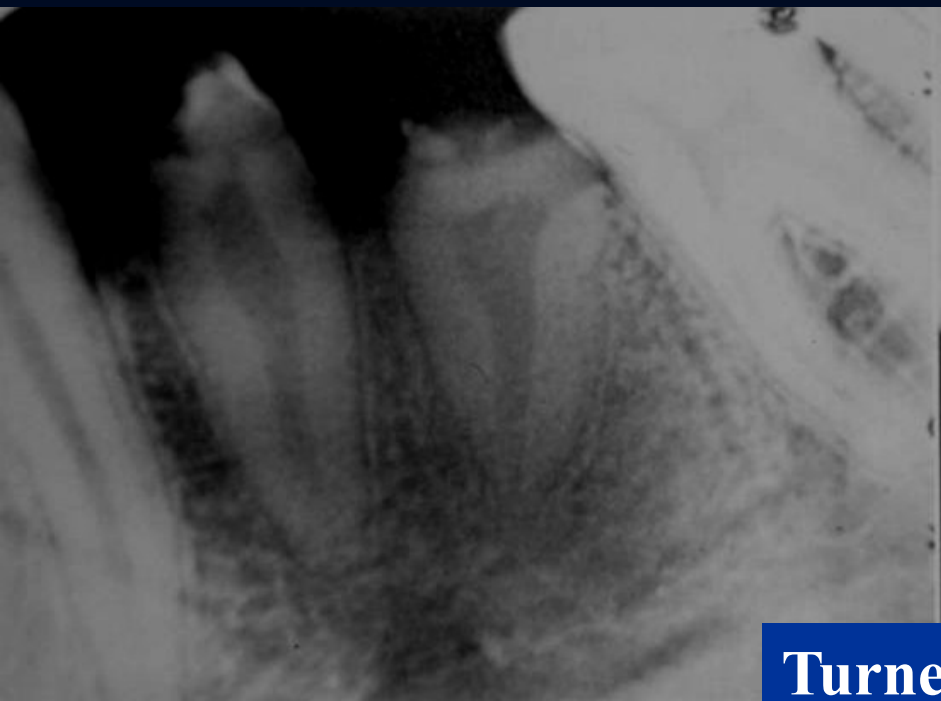- local or extensive



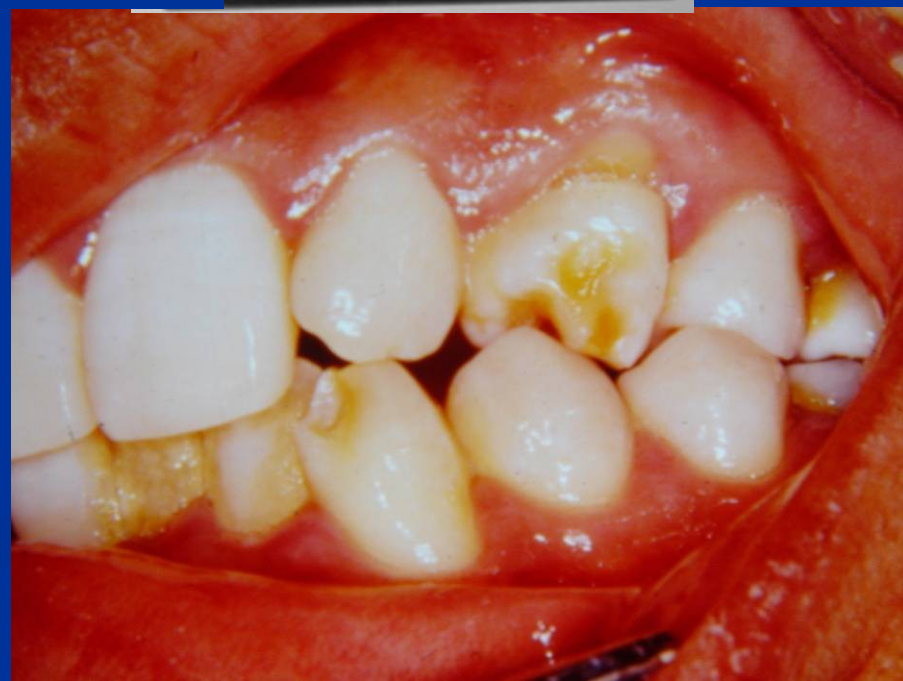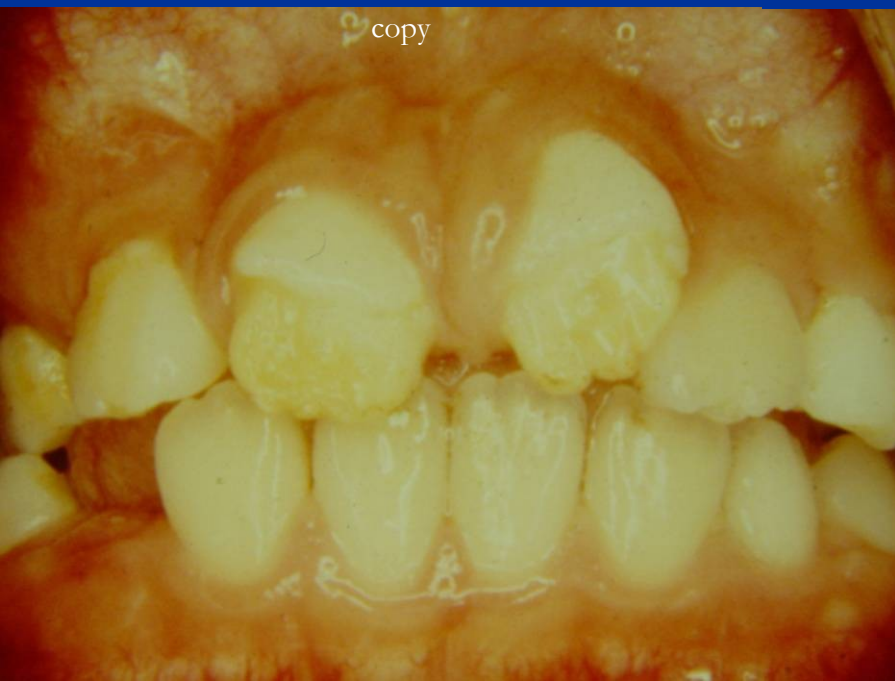Turner teeth

- yellowish or brownish pigmentation of the enamel
- pits and irregularity of the surface
- smaller crown than normal





Turner tooth



Hypoplasia due to antineoplastic therapy

- childhood cancer
- chemo and/or radiotherapy
- enamel and dentin defects
- hypodontia, microdontia, enamel hypoplasia, ...

Dental fluorosis

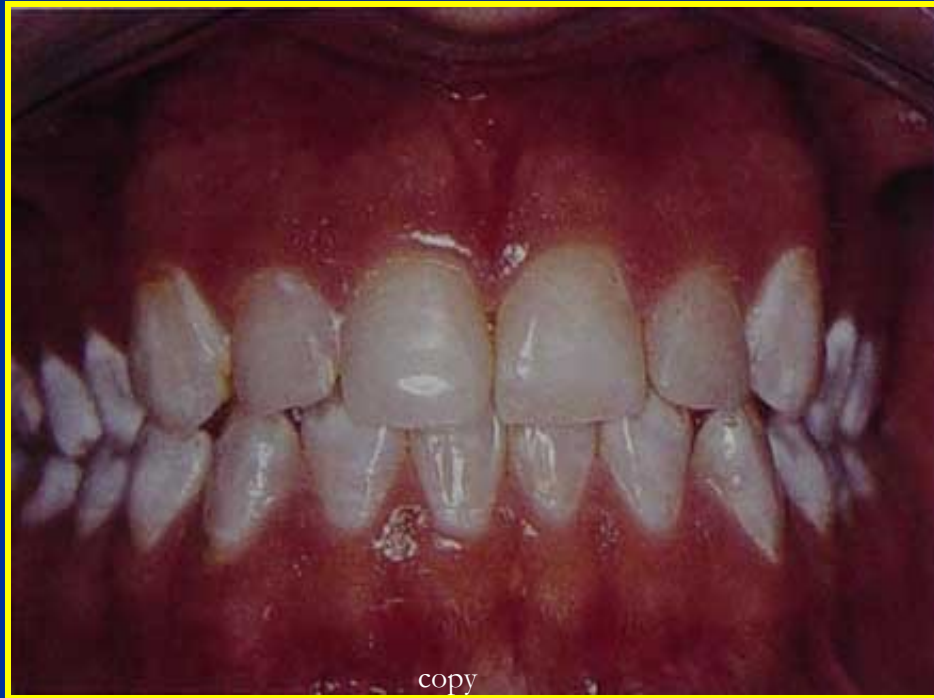■ Fluorosis (mottled enamel)

- fluoride in drinking water, toothpaste, supplements
- hypomineralization, event. enamel hypoplasia
- mostly discoloration, true hypoplasia uncommon
- paper-white patches brown
- permanent teeth (Placenta barrier normally resists fluoride, fluorosis seldom in deciduous dentition.)
- hydroxyapatite calcium fluorapatite
- matrix normal
- fluorosis x caries resistance

Dental fluorosis

- fluoride opacities symmetrically around the arch
- faint white flecking of the enamel, white patches or striations
- in severe cases may be associated with loss of the normal tooth form
- the deciduous teeth may be involved in severe cases and in areas of endemic fluorosis
- highly acid-resistant, rapid loss by abrasion and attrition

Fluorosis



Therapy

- bleaching
- composite resin

Congenital syphilis

- **Congenital syphilis - Hutchinson**
 - later fetal infection, now very rare
 - dental follicle infection by *T. pallidum*
 - permanent teeth
 - upper 1. I (*Hutchinson's incisors*) – barrel-shaped fissure on incisal edge
 - 1. M (*mulberry, Moon's molar*) – pitted + bumpy occlusal surface

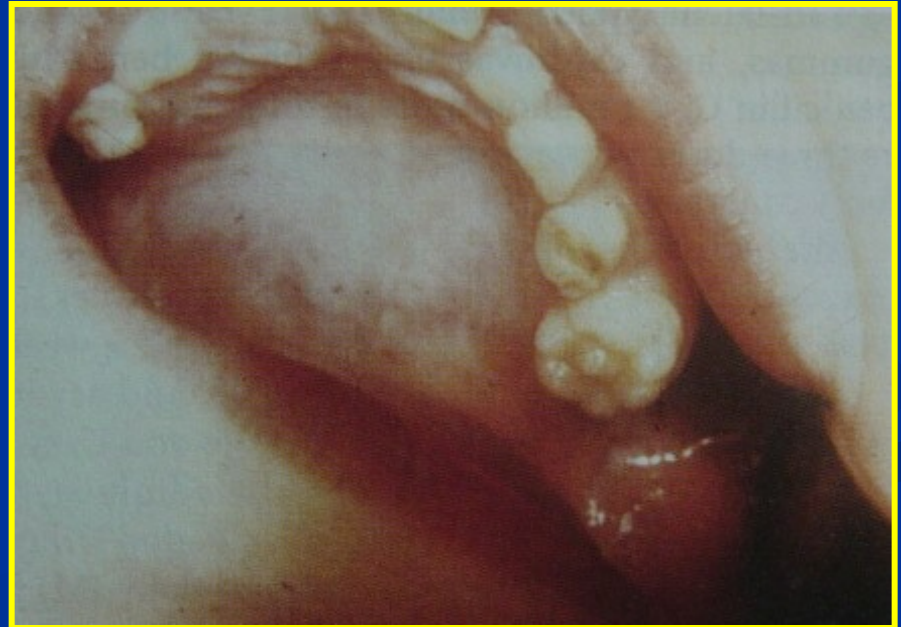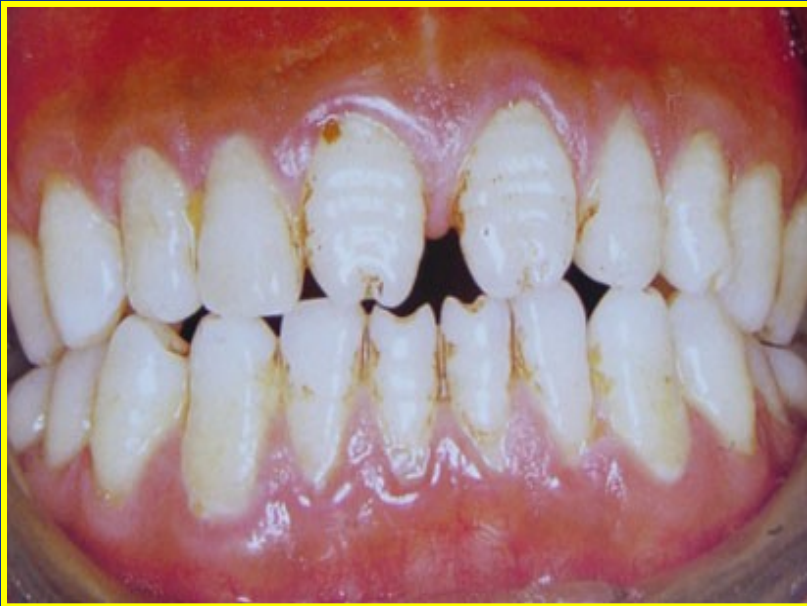Congenital syphilis

- 30 % of infected fetuses develop dental hypoplasia

Congenital syphilis

Hutchinson's incisors

mulberry molar



copy

Postdevelopmental loss of structure

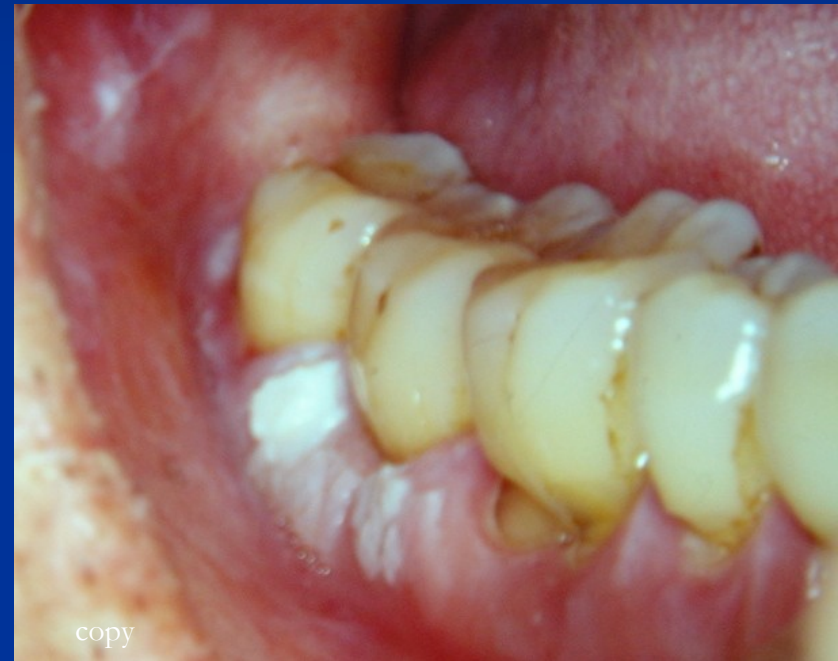- Non-bacterial (x caries)
- Non-traumatic (x fracture)
- Tooth wear (enamel) – attrition
 - abrasion
 - erosion
 - abfraction
- Internal and external resorption (dentin, cement)

Habitual disorders

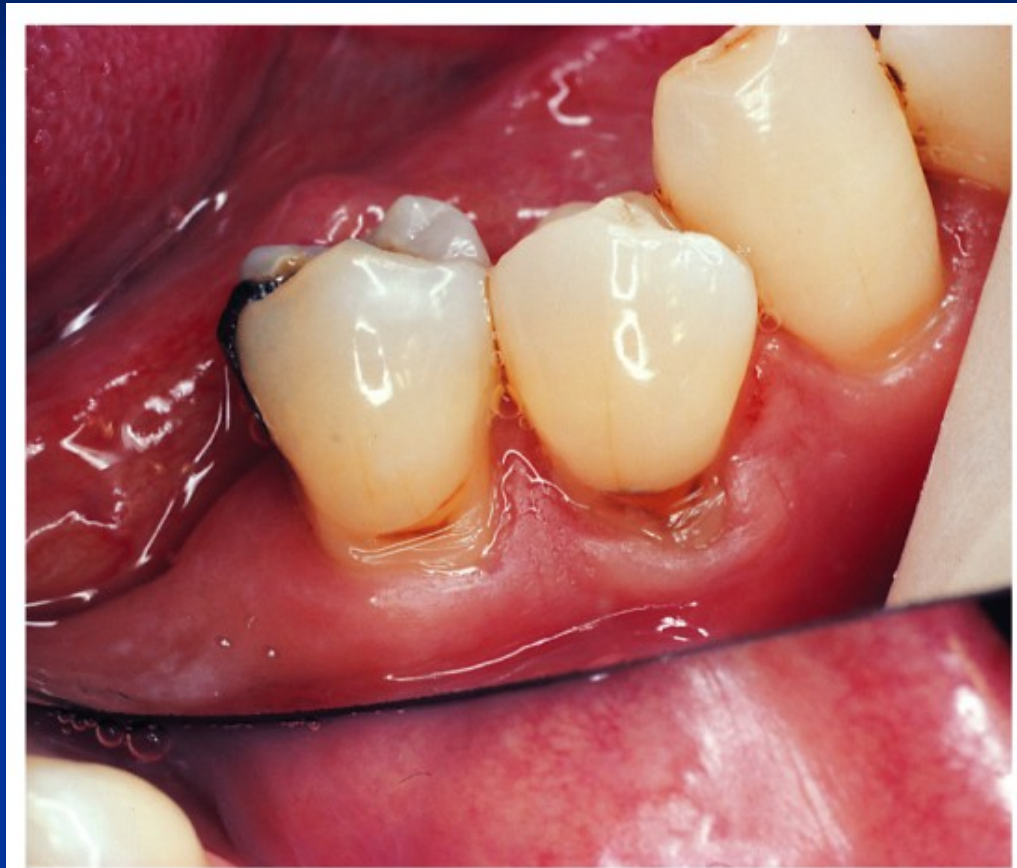- **Abrasion** is the abnormal wearing away of tooth structure caused by a repetitive mechanical habit.
- external cause (friction of a foreign body, abrasive material, pressure)
- improper toothbrushing – common, on exposed roots, maxillary > mandibular, anterior > molars, grooves + polished dentine
- gripping objects with teeth – habitual (pipe, pencils), occupational

Toothbrushing injury

- V-shaped groove in cervical area
- Sensitive
- Maxillary premolars > canines > incisors
- R-L (mostly) defect at cervical level, well-defined semilunar shapes



Toothbrushing abrasion

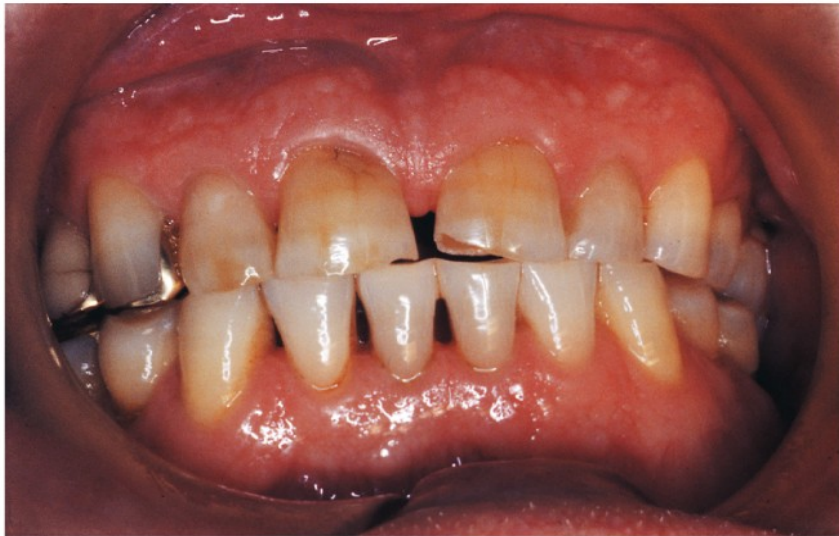

Copyright © 2003, Elsevier Science (USA). All rights reserved.

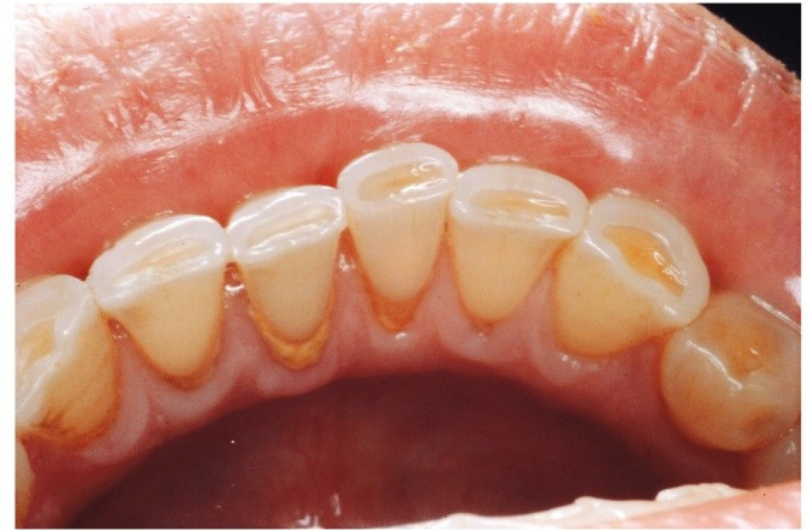Habitual disorders

- **Attrition:** wearing away of tooth structure during mastication (chewing) through tooth-to-tooth contact
- Incisal, occlusal and interproximal surfaces (contact points)
- Crown shortened, reduction of pulp chamber, canals
- Physiological (contact points and areas, abrasive foods, exposure of dentine → accelerated attrition)
- Dentin sensitivity rare due to slow loss + secondary dentin formation

Attrition



Copyright © 2003, Elsevier Science (USA). All rights reserved.



Copyright © 2003, Elsevier Science (USA). All rights reserved.

Habitual disorders

Pathological attrition

- abnormal occlusion (prolongated contact, developmental, acquired – extraction)
- bruxism; long-term use of intraoral abrasives (tobacco or betel chewing)
- abnormal tooth structure (poor quality or absent enamel – fluorosis, amelogenesis or dentinogenesis imperfecta)

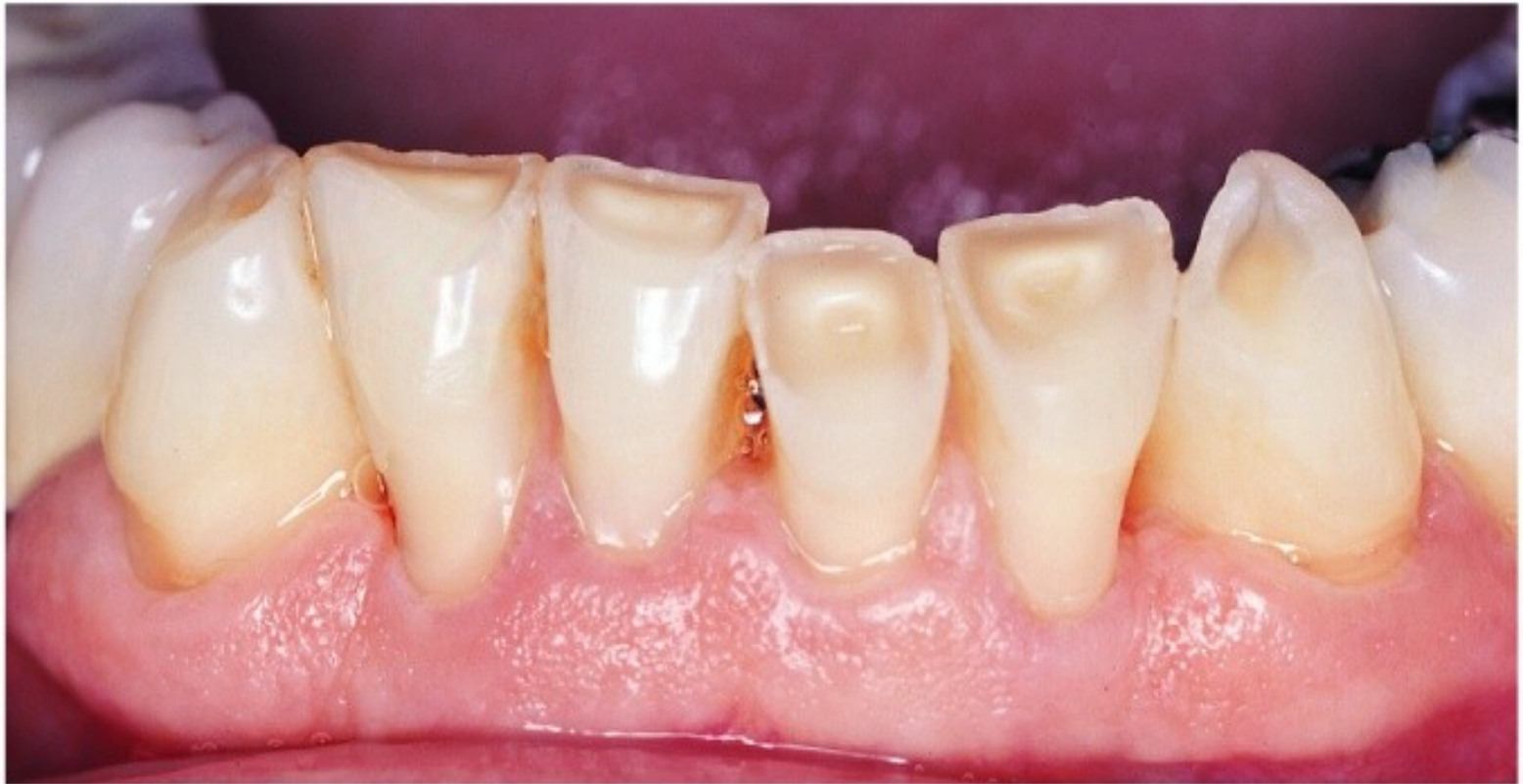Attrition

Toothbrushing injury

Habitual disorders

- **Bruxism:** an oral habit consisting of involuntary grinding and clenching of the teeth in movements other than chewing.
- Usually performed during sleep, commonly associated with stress or tension.

Bruxism



Copyright © 2003, Elsevier Science (USA). All rights reserved.

Habitual disorders

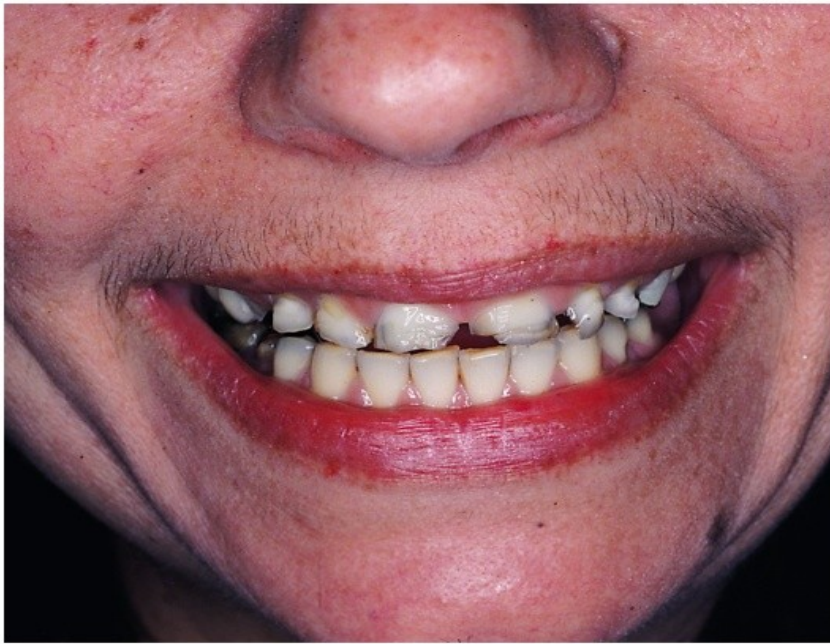Erosion – loss of tooth structure by a chemical process (acid) not associated with bacterial interaction. Possible combination (↑ attrition, abrasion).

- Dietary – carbonated soft drinks, fruit juices; shallow polished concavities
- Medication – aspirin, vit. C chewing
- Stomach regurgitation – involuntary (gastric reflux, pregnancy), voluntary (repeated vomiting)

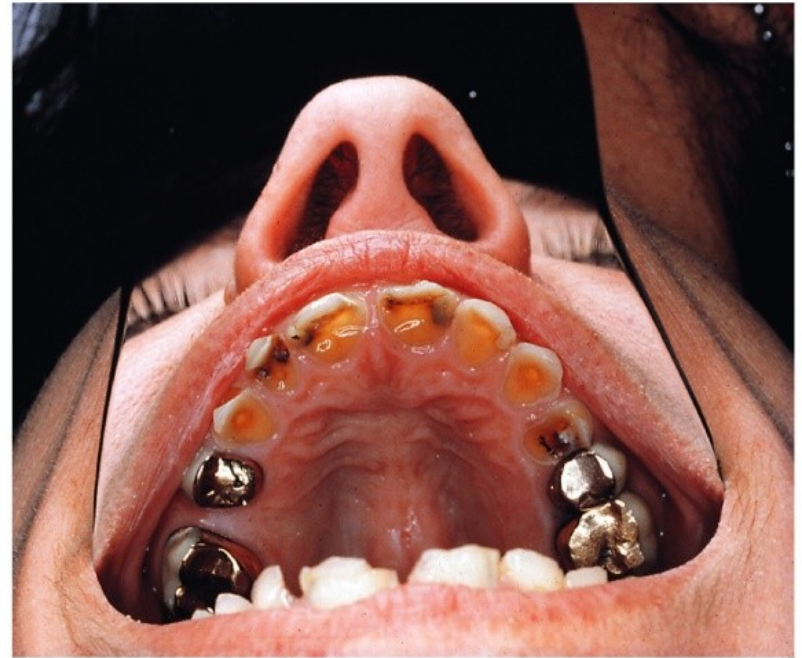
Habitual disorders

- Crown shortened, reduction of pulp chamber, canals
- dentin reactive changes, incl. tertiary reactionary dentine formation
- possible hypersensitive dentin if rapid course

Erosion caused by bulimia.



Copyright © 2003, Elsevier Science (USA). All rights reserved.



Copyright © 2003, Elsevier Science (USA). All rights reserved.

Habitual disorders

- **Abfraction** – due to the repeated tooth flexure (occlusion stress) → disruption of enamel crystals → cracked enamel → loss by erosion, abrasion
- wedge-shaped defect on cervical area of the teeth, facial surface
- single tooth often affected

Habitual disorders

- commonly multifactorial etiology + result
- functional, dental sensitivity, aesthetic problems

Histology of dentin

- Formed by odontoblasts
- 70% anorganic matter
- 30% organic matter
- Makes up bulk of tooth
- Dentinal tubules
- Not as hard as enamel
- Somewhat elastic
- Pale yellow
- Somewhat transparent
- More radiolucent than enamel
- Can repair itself

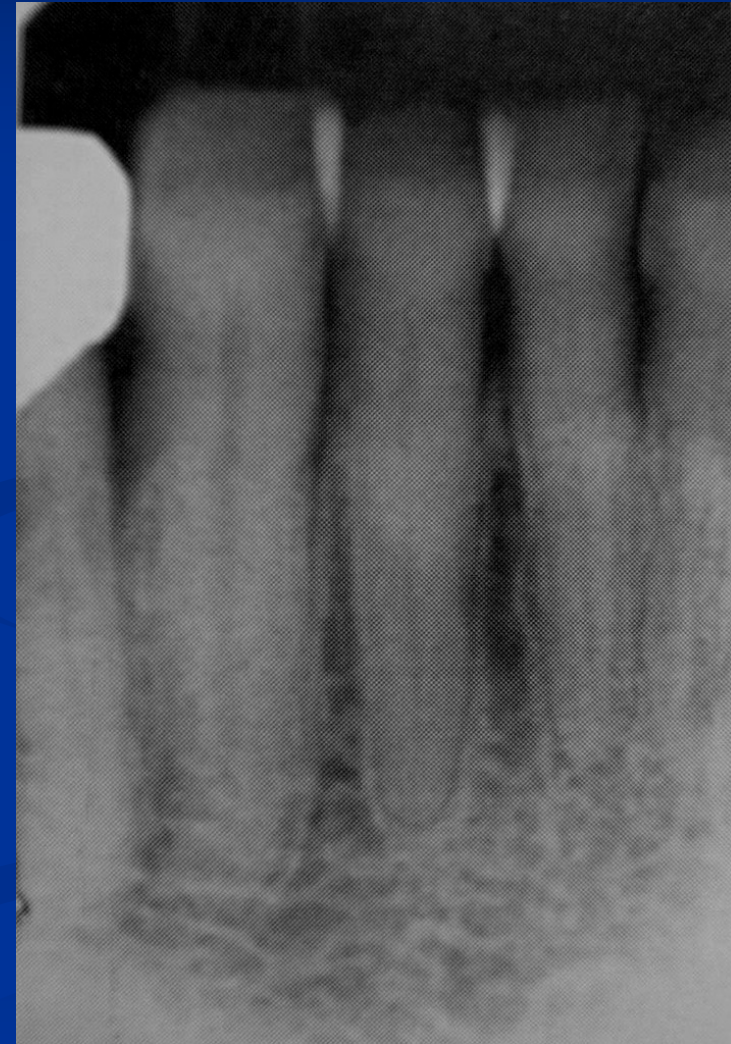
Histology of cementum

- Formed by cementoblasts
- Anchors tooth to socket via periodontal ligaments
- Covering of root
- 50% to 55% anorganic material
- 45% organic
- Primary cementum
- Secondary cementum

Secondary dentin

Dentin deposited in pulp chamber after primary dentin formed completely

- Normal aging process
- **tertiary dentin:** pathologic condition after chronic trauma
- Reduction in size of pulp chamber and canals
- Begins in the region adjacent to source of stimuli and alters normal shape of chamber



Internal and external resorption

resorption of dentin or cementum

- internal surface – cells in the pulp
- external surface – cells in the periodontal ligament

Internal and external resorption

- **Internal resorption** – macrophages (dentinoclasts) on pulpal surface, vital pulp necessary
- loss of odontoblasts
- associated with pulpitis, physical trauma
- rare idiopathic
- less common than external resorption
- pulp tissue visible through enamel – pink spot

Internal and external resorption

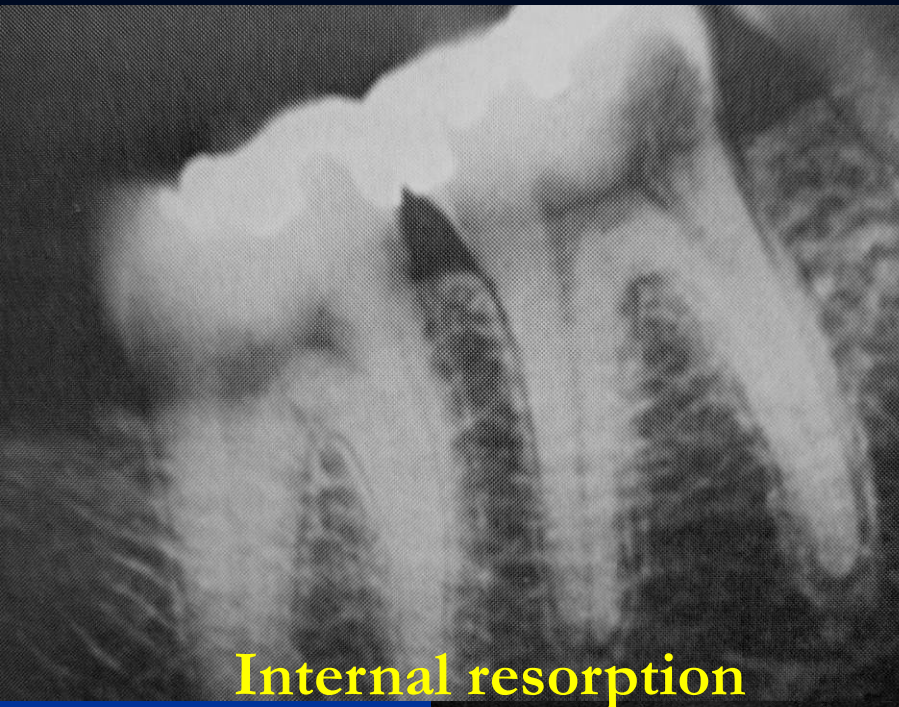
Internal resorption

2 main patterns:

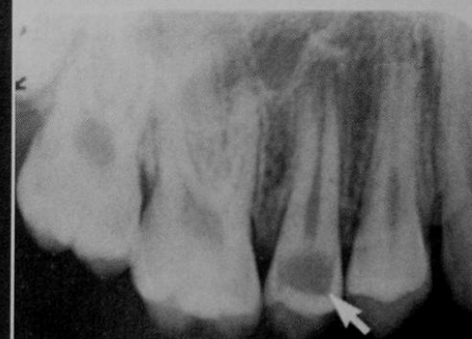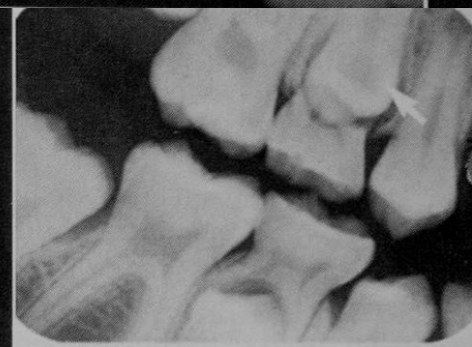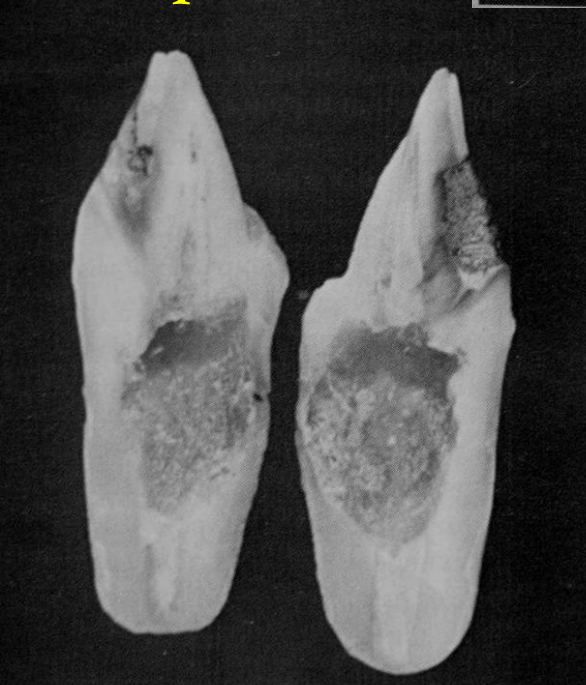
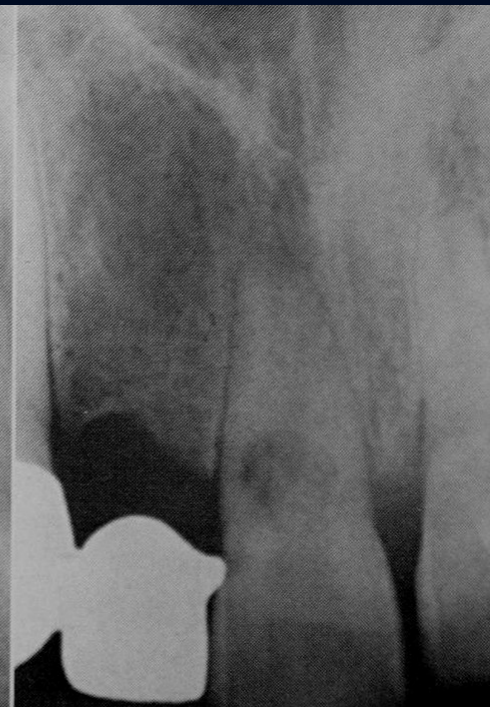
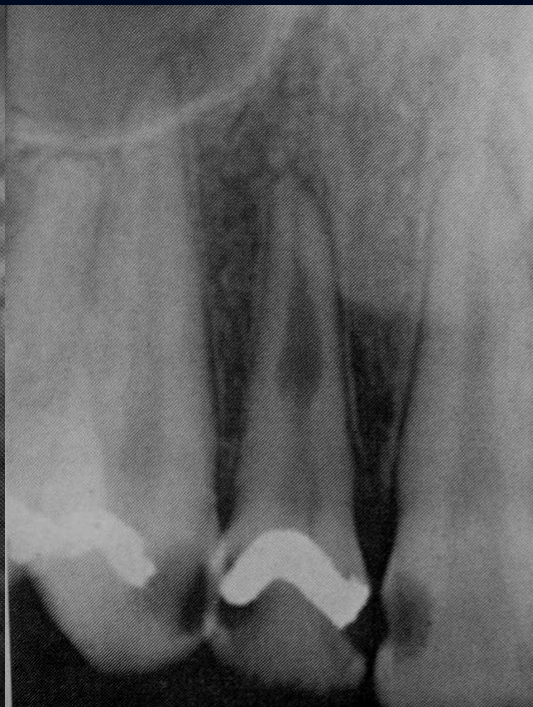
- inflammatory resorption: replacement of dentin by granulation tissue, in pulpitis
- metaplastic resorption: replacement by bone or cementum-like bone

Internal resorption

- Within the pulp chamber or canal, involves resorption of surrounding dentin, results in enlarged pulp space
- M>F, commonly begins during 3rd-5th decade
- Radiographs reveal symptomless early lesions of IR
- Radiolucent, round, oval, or elongated within root or crown and continuous with pulp chamber or canal
- Sharply defined and smooth or slightly scalloped → irregular widening of the pulp chamber or canal
- Metaplastic bone may lead to partial obliteration of the canal



Internal resorption



Internal and external resorption

External resorption

- from root surface
- variable individual susceptibility to external resorption – most important factor
- extremely common, in 10% serious
- variable radiolucency (moth-eaten)
- resorption by multinucleated dentinoclasts, inflammatory reaction + woven bone, may lead to ankylosis

Internal and external resorption

External resorption

- inflammatory res. – periapical inflammation, root res., layer of granulation tissue (later fibrotic), layer of woven bone
- pressure/mechanical res. - ? aseptic necrosis → repair
- idiopathic – burrowing from root surface into dentine → granulation tissue → bone (event. ankylosis); invasive cervical resorption

Internal and external resorption

Apical ER:

- blunting with normal bone and lamina dura
- root shortening, except due to periapical inflammatory lesions
- canal is visible and abnormal wide at apex

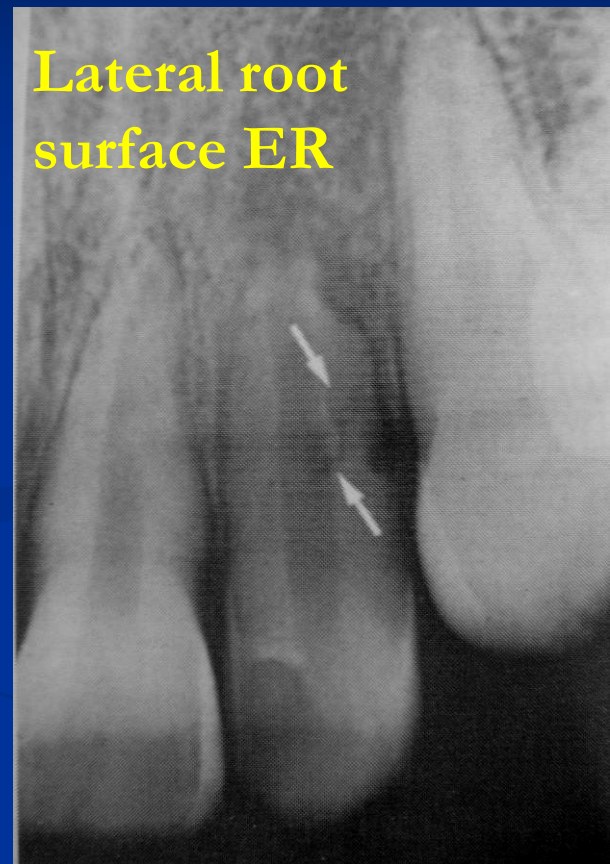
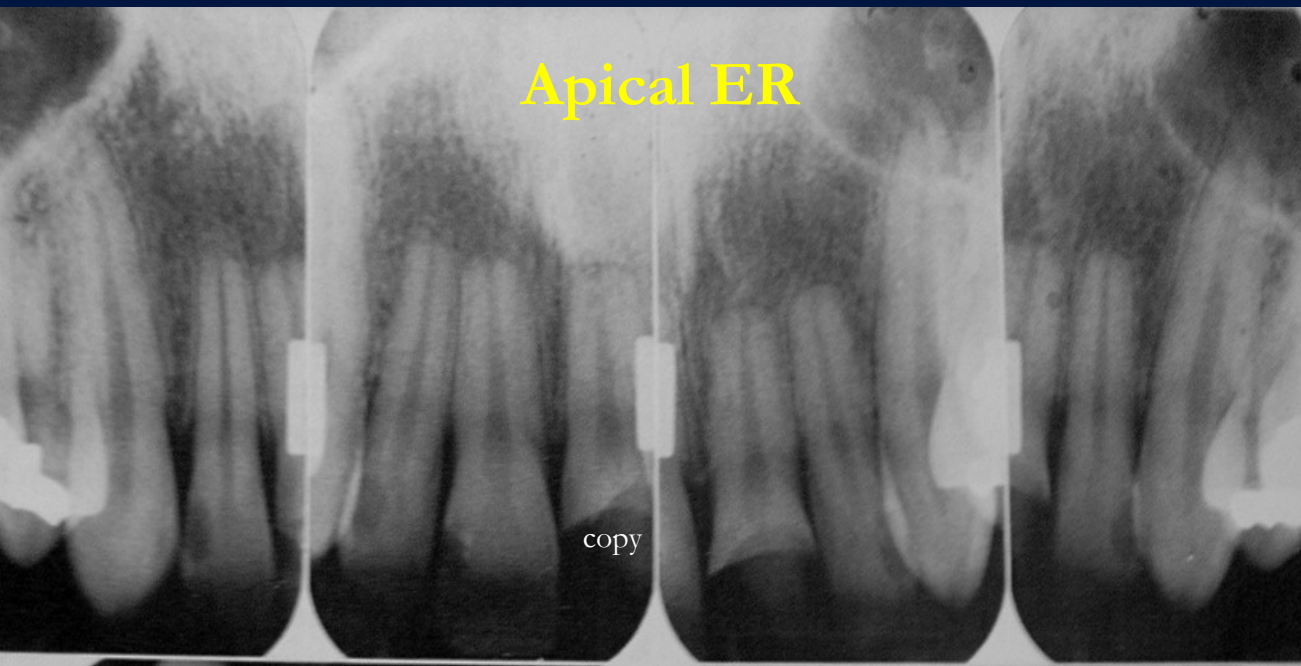Lateral root surface ER:

- presence of an unerupted adjacent tooth

Internal and external resorption

External resorption risk factors

- cysts
- dental trauma
- excessive external forces (mechanical, occlusal)
- therapy (orthodontic, bleaching, teeth reimplantation, ...)
- local diseases (periradicular inflammation, herpes zoster, Paget's bone disease, tumors...)
- generalized disorders (hormonal imbalances)
- idiopathic



Teeth discoloration

extrinsic – surface deposits

- bacterial stain
- iron, other metals
- tobacco, betel
- food + beverages
- gingival haemorrhage
- restorative materials
- medication

Teeth discoloration

Intrinsic:

- changes in the structure or thickness (amelo-, dentinogenesis imperfecta, developmental enamel hypoplasia, caries)
- diffusion of pigments after formation of tissues
 - ↑ in preexisting enamel or dentin changes (root filling material, pulp necrosis + haemorrhage)


Teeth discoloration

Intrinsic:

pigment incorporation during formation of enamel/dentin

- congenital hyperbilirubinemia (greenish)
- congenital porphyria (red-brown, UV red fluorescence)
- TTC pigmentation (yellow dentin bands, UV yellow, later brown)

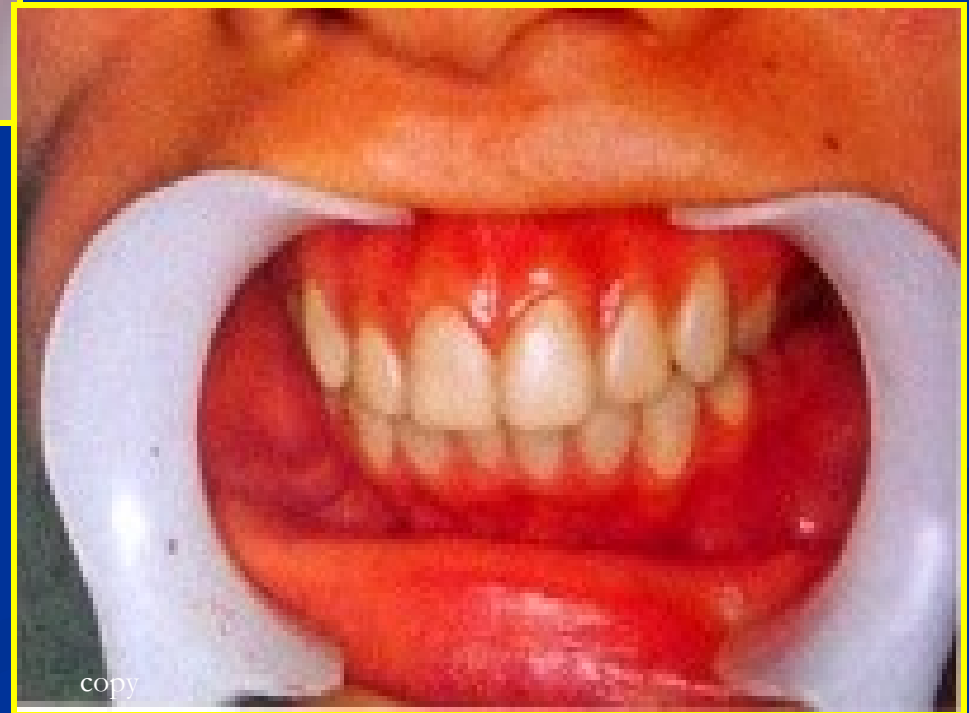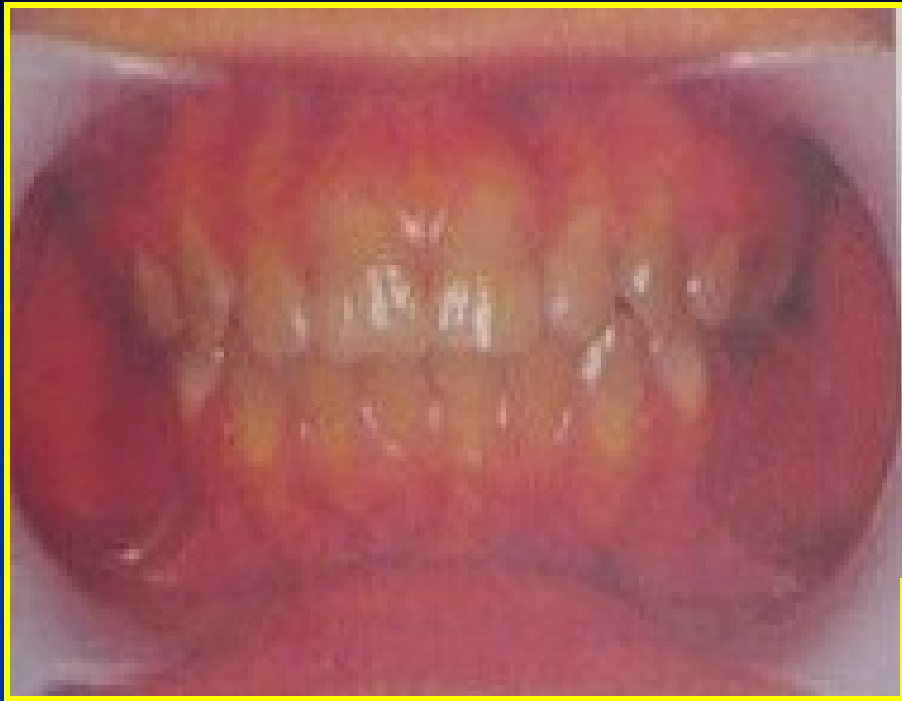TTC pigmentation



Pigment disorders therapy

- composite resin
- bleaching

Composite resin

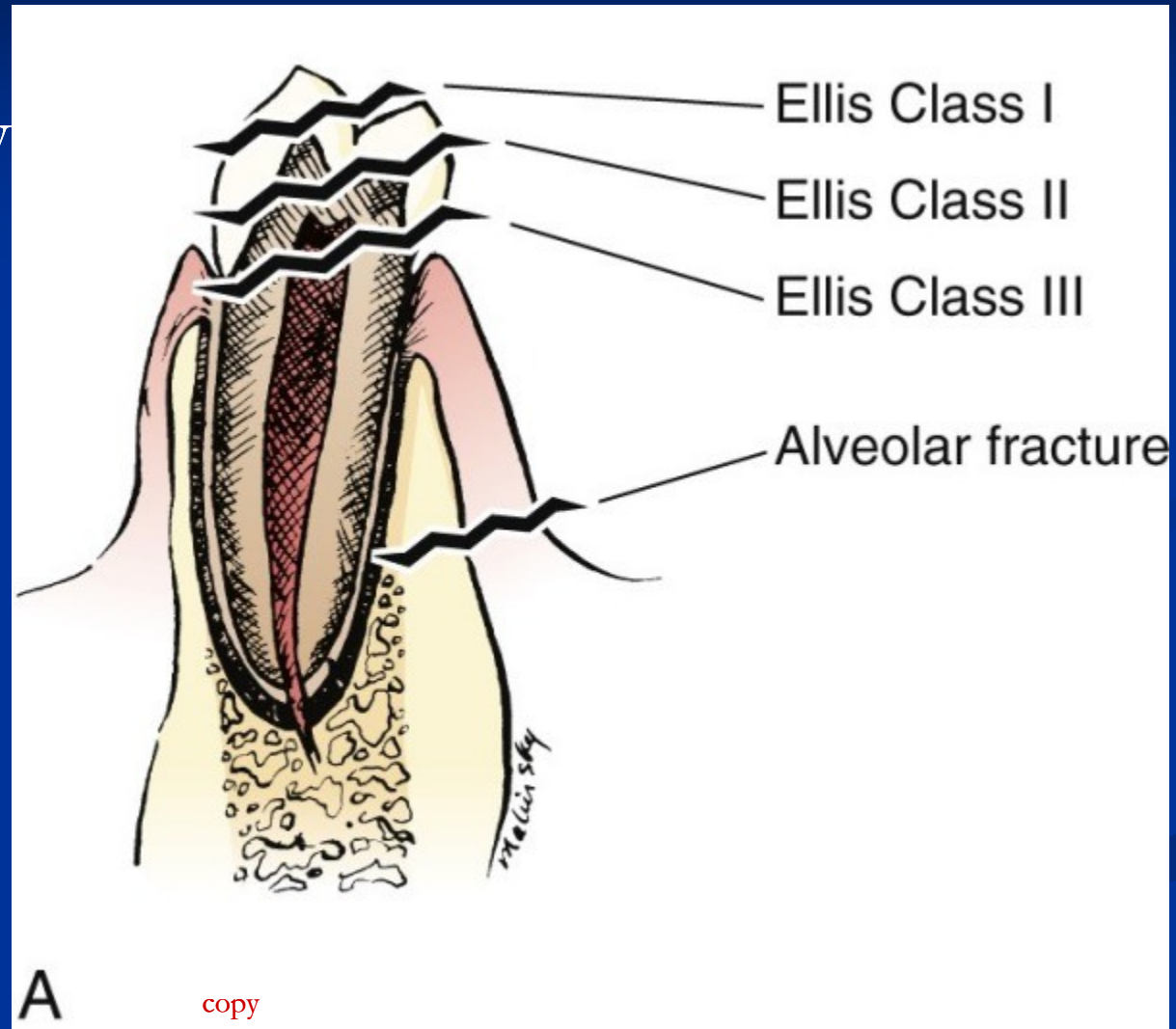


Tooth trauma

- Maxillary central incisors - 70-80% of all fractured teeth
- Complications: failure to complete eruption, color change of the tooth, abscess, loss of space in the dental arch, ankylosis, abnormal exfoliation, root resorption.

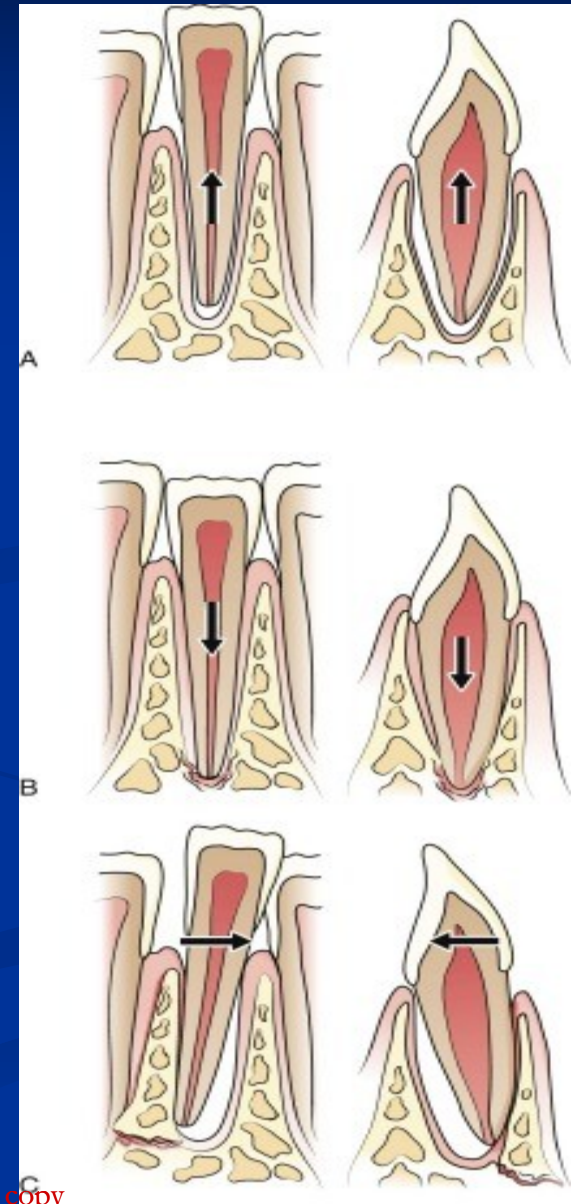
Tooth fracture

- I.- enamel, usually no complication
- II. – enamel+dentin: risk of pulp necrosis
- III. – into pulp, 10-30% necrosis



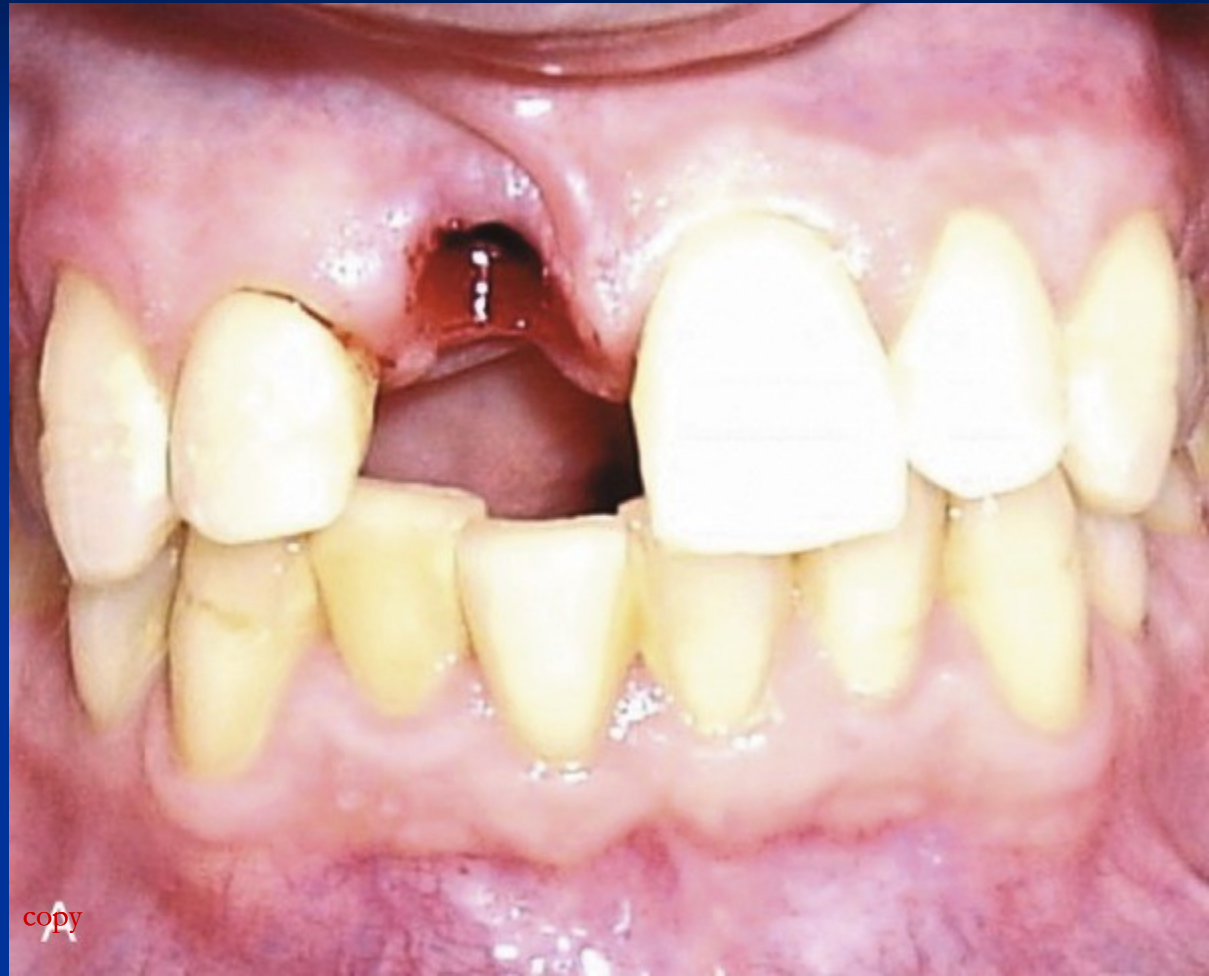Tooth luxation

- A. extrusive luxation – partially out of socket
- B. intrusive luxation – pulp compression, bone crush
- C. lateral luxation – commonly + alveolar bone fracture
- Complete luxation (complete avulsion) – entire tooth out of socket



Tooth trauma - intrusion

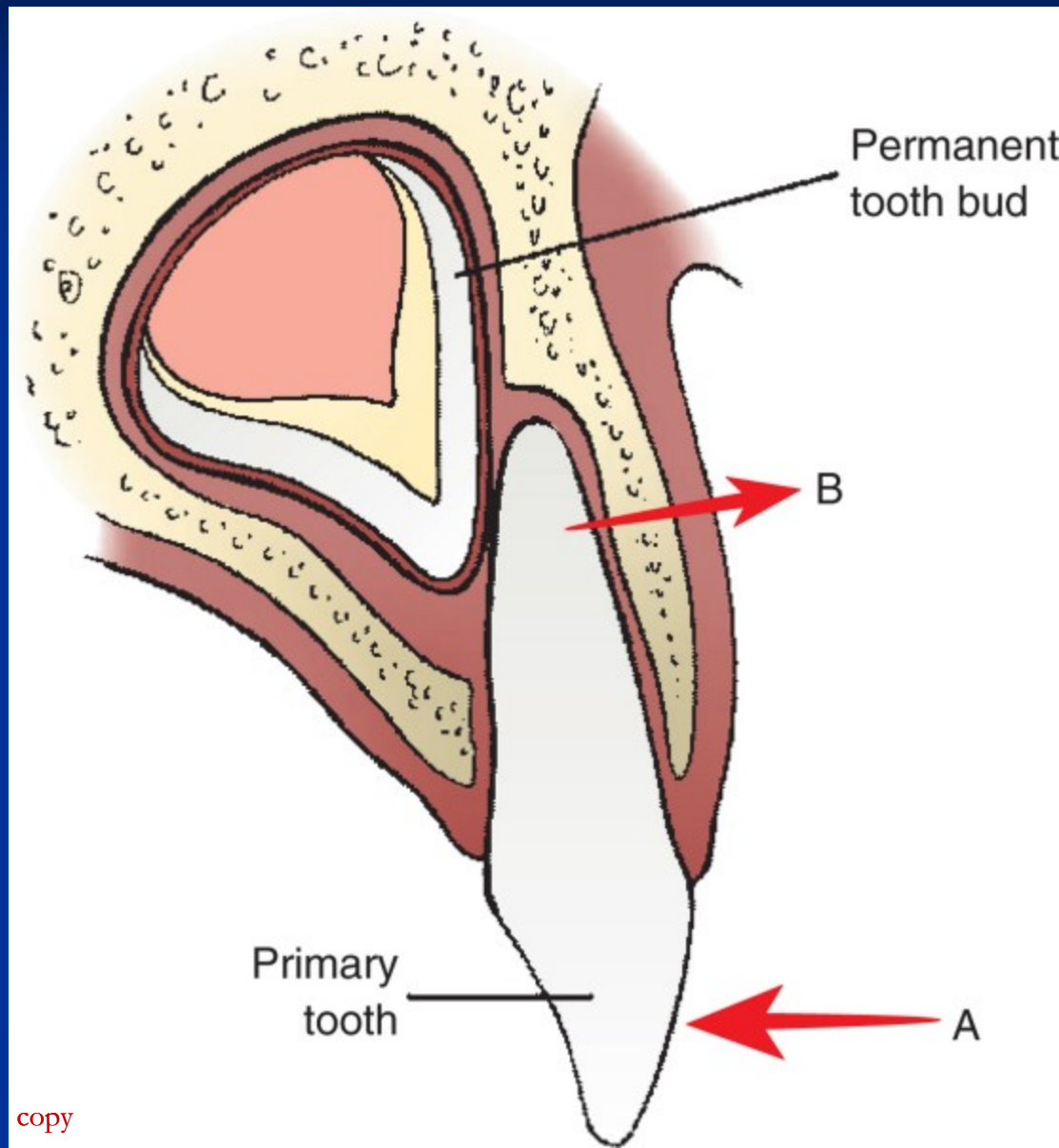
- The missing tooth could be lost, fully intruded, aspirated or swallowed.
- upper tooth into maxillary sinus → recurrent sinusitis
- into the nasal cavity → infection or bleeding
- aspiration into the airway



copy

Tooth trauma

- Deciduous tooth trauma: typical direction of force in a forward fall (A), the apex of the deciduous tooth levered away from the developing tooth bud (B).



Root fracture

- Multiple factors affecting healing: location, degree, fragment position and mobility
- **Sterile x infected**
- **Sterile:** similar to bone fracture healing - organisation of haematoma by granulation tissue → maturation + calcification.
- **Malposition:** fragments rounded, covered by cementum, more or less separated, gaps filled by fibrotic tissue
- **Infected:** abscess, gangrene