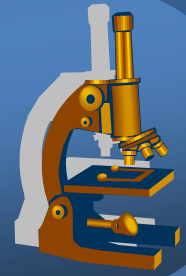


Systemic Pathology



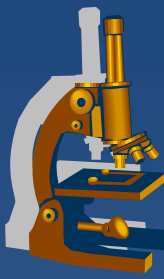
***CARDIOVASCULAR
system***

ATHEROSCLEROSIS



- disease of large and medium-sizes arteries with lipid deposition into intima
- active inflammatory process
- endogenous risk factors, mostly noninfluenceables :
 - *age, Mx^F (estrogen?), familiar factors (f. hypercholesterolemia), hereditary homocysteinemia*
- exogenous risk factors:
 - *hyperlipidemia (LDL) ←←← hypothyreosis, nephrotic sy;*
 - *hypertension, diabetes mellitus, life style smoking (nicotine, CO), sedentary life, food + obesity; ↑CRP*

Atherosclerosis - pathogenesis



1. Endothelial injury

- *mechanic* (\uparrow BP, turbulence)
- *endotoxins, immune complexes, exogenous toxins (cig. smoke), \uparrow cholesterol*

\uparrow expression of cell adhesion molecules, \uparrow permeability, \uparrow thrombogenicity

2. Lipoprotein insudation (LDL) – **oxidation** in intima

3. Inflammation

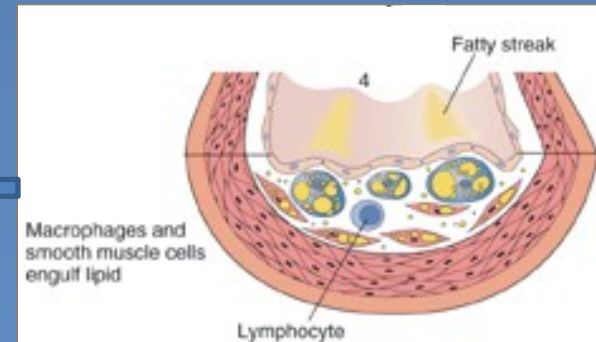
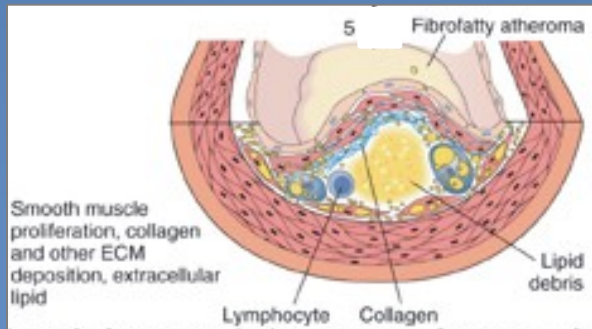
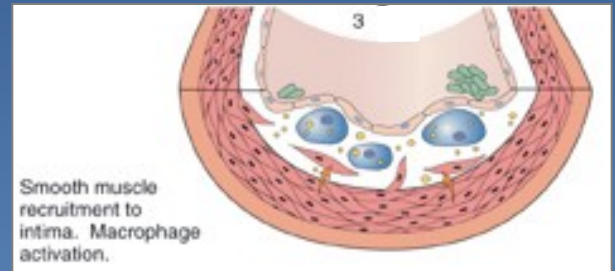
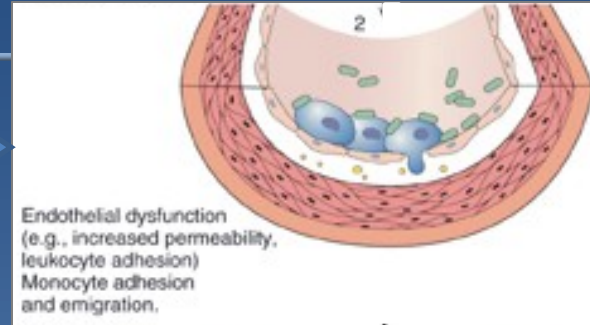
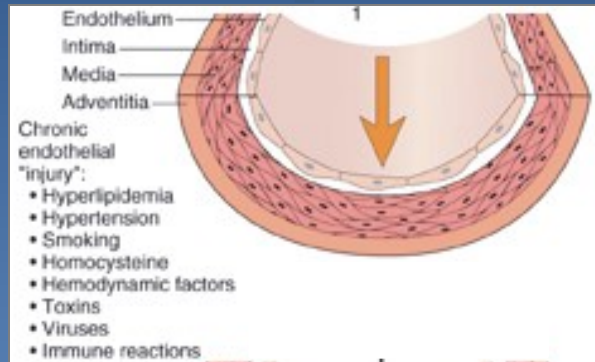
- *blood monocytes (\rightarrow foam cells), T-cells, platelets, smooth muscle cells*

4. Repair - proliferation of myointimal cells

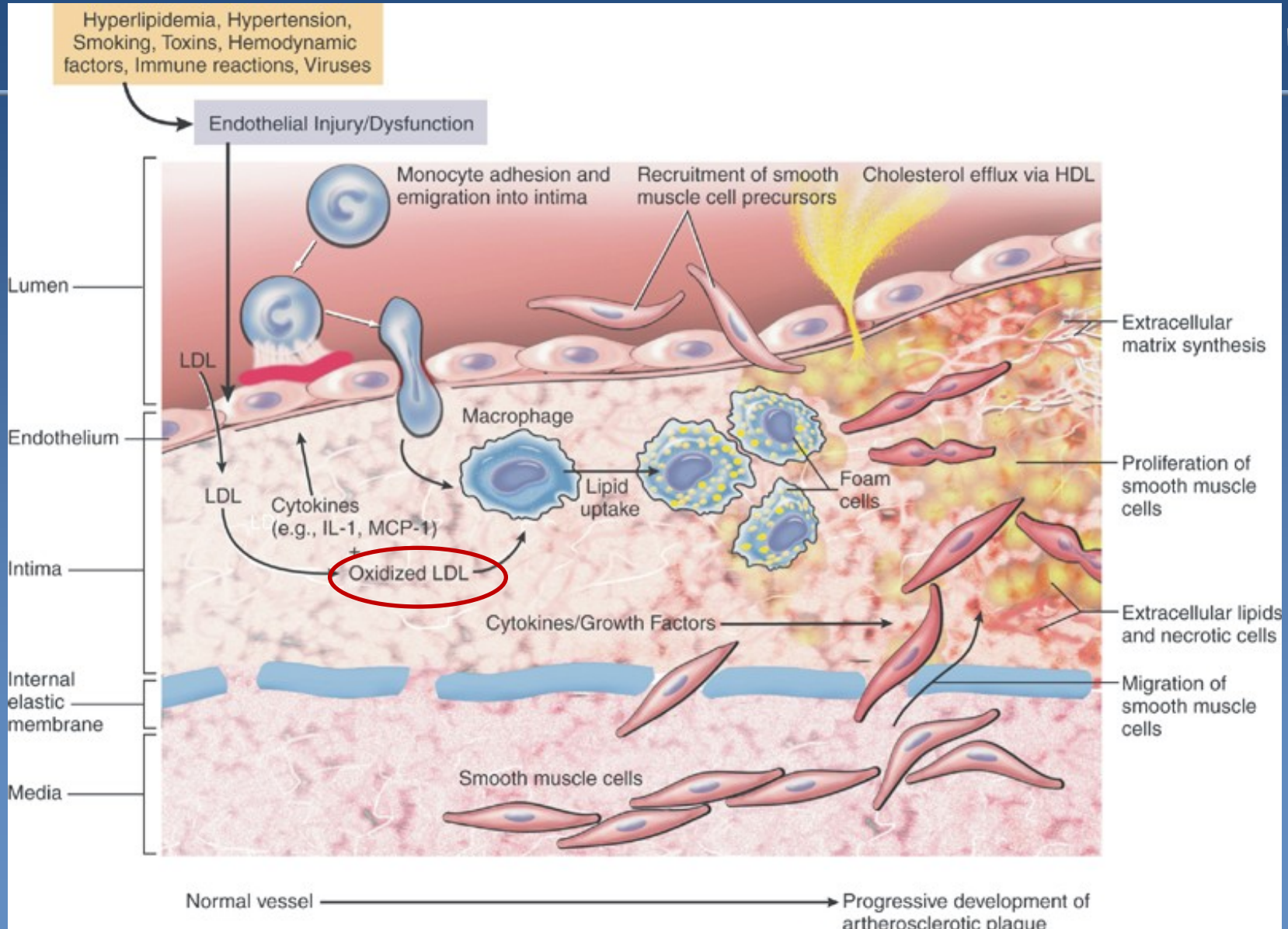
- *synthesis of collagen, elastin, proteoglycans \rightarrow **fibrotic plaque**, + lipid accumulation - **atheromatous plaque***

stable plaque under repeated inflammation turns into unstable plaque – fibrous cap + endothelium rupture - thrombus

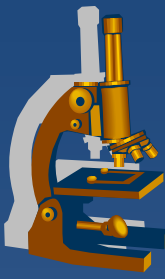Atherosclerosis - pathogenesis



atherosclerosis – cell interactions in an atheromatous plaque



Atherosclerosis



- ✘ fatty streak
- ✘ fibrotic plaque
- ✘ atheromatous plaque
- ✘ complicated atheromatous plaque
(ulceration, calcification, thrombosis)

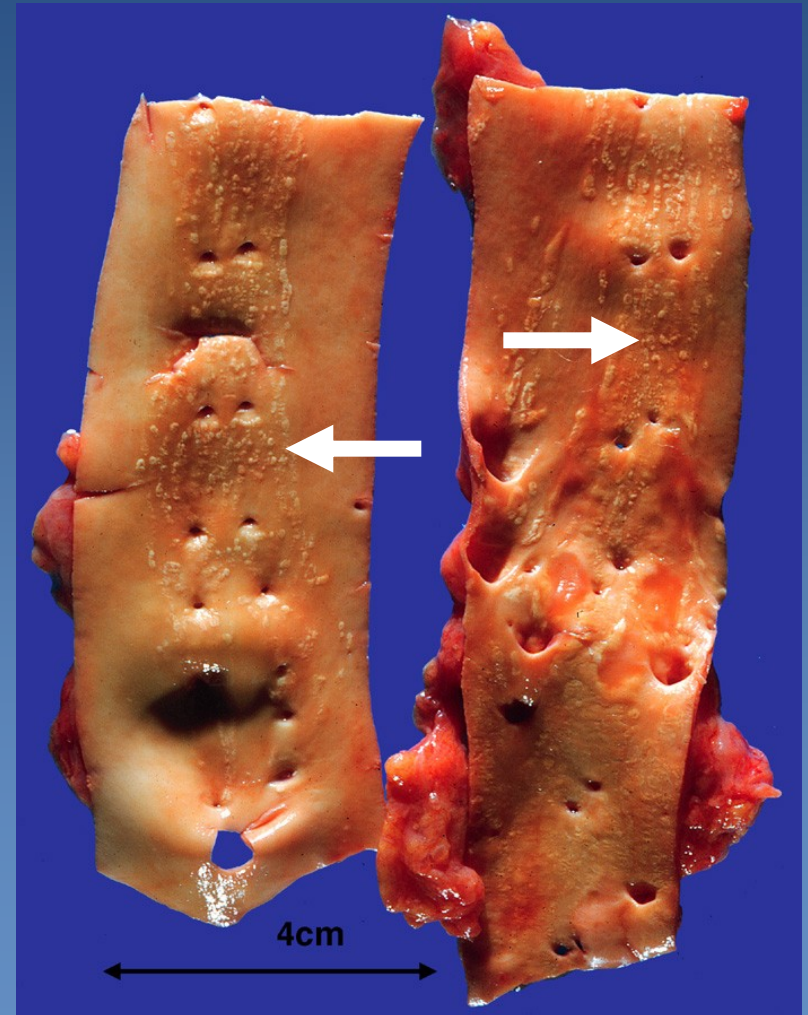
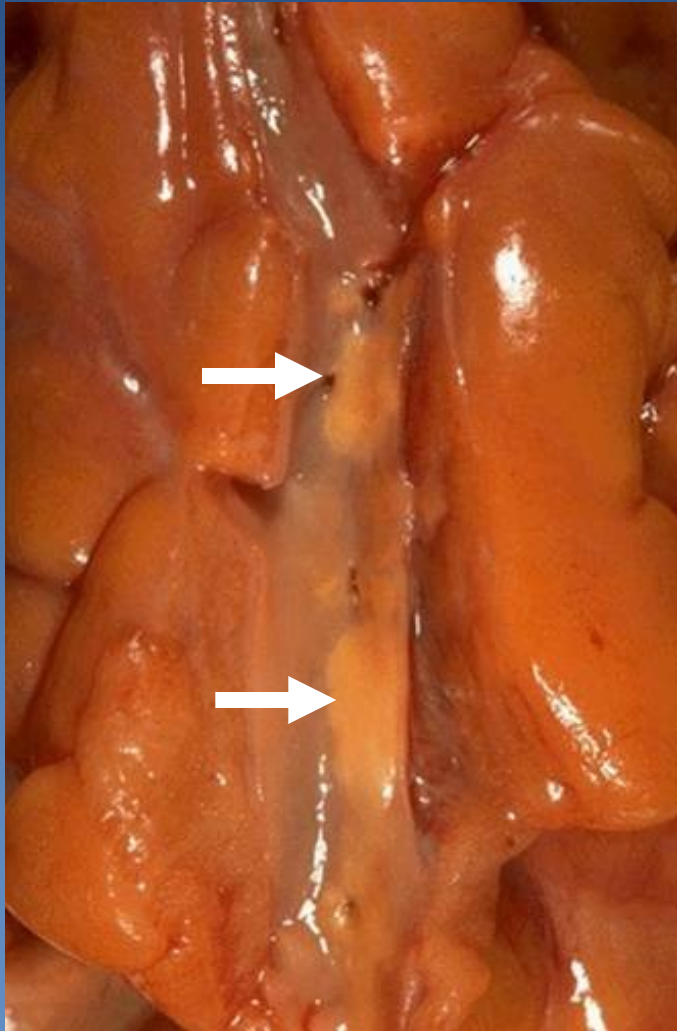
Atherosclerosis



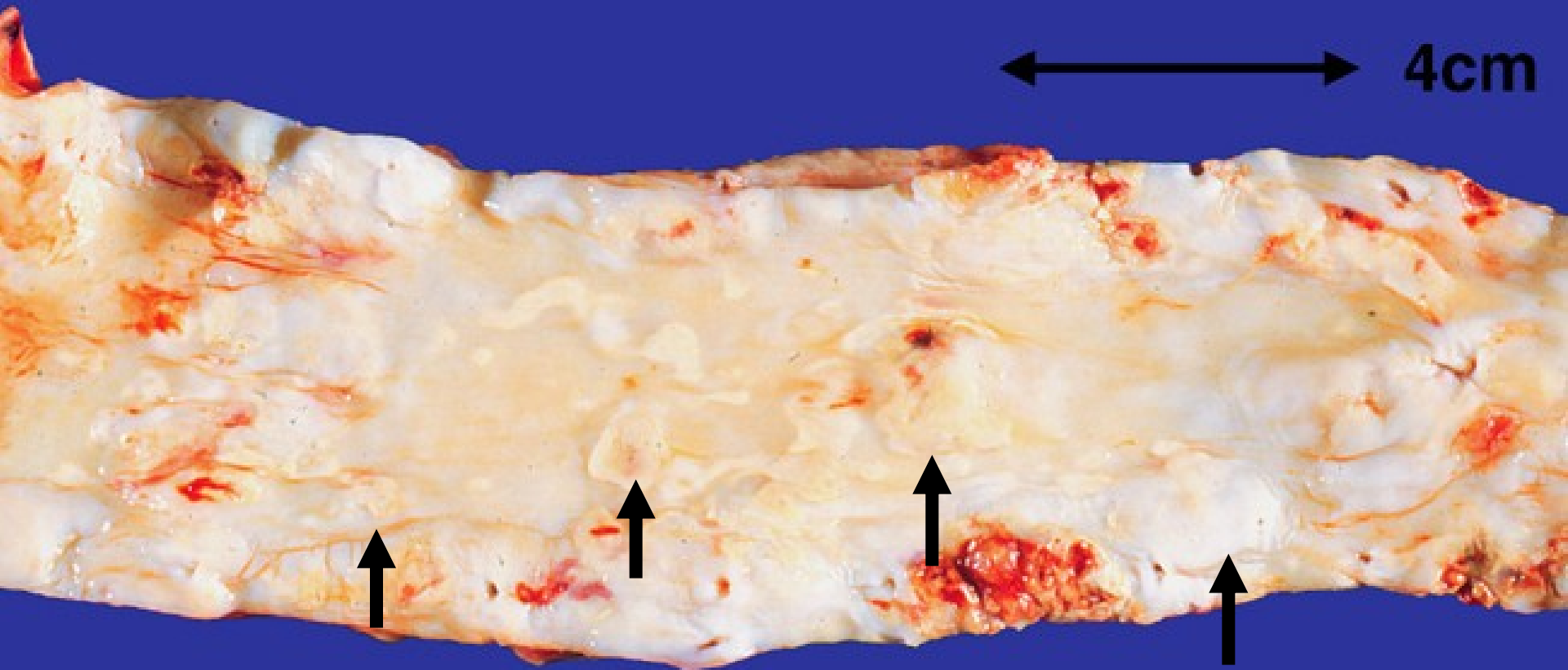
SEQUELS: arterial occlusion in situ

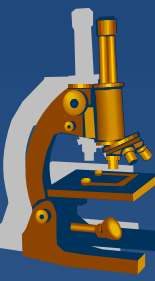
- ✗ chronic (→ hypoxia, atrophy)
- ✗ acute (→ ischemia, infarction, encephalomalatia)
- ✗ embolism (thrombus, plaque material)
- ✗ weakening of arterial wall (aneurysm), risk of rupture
- ✗ bleeding (from plaque, fissured wall)
- ✗ calcification (hypertensive factor)

Atherosclerosis- fatty streak

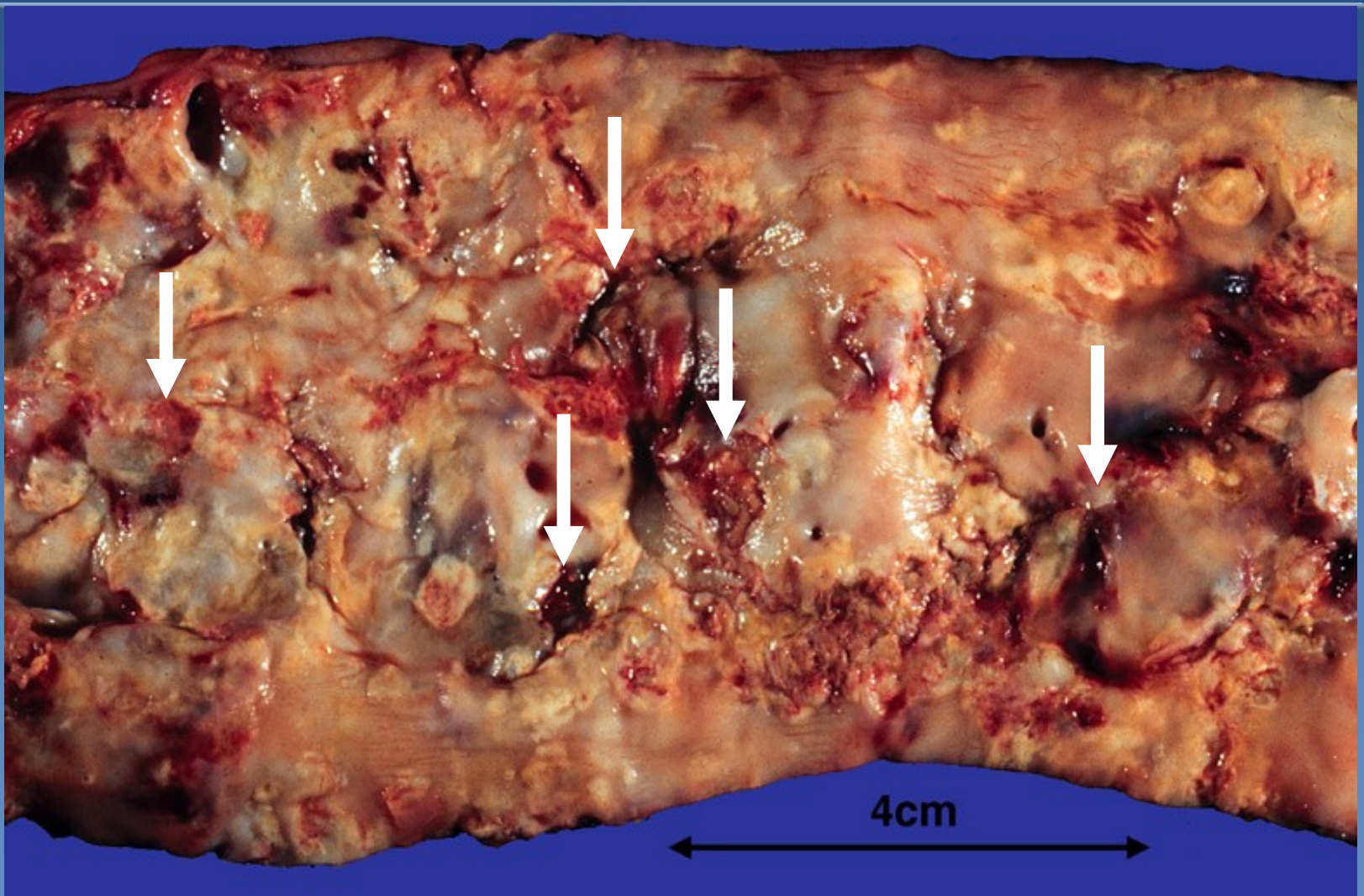


Atherosclerosis - fibrous and atheromatous plaques

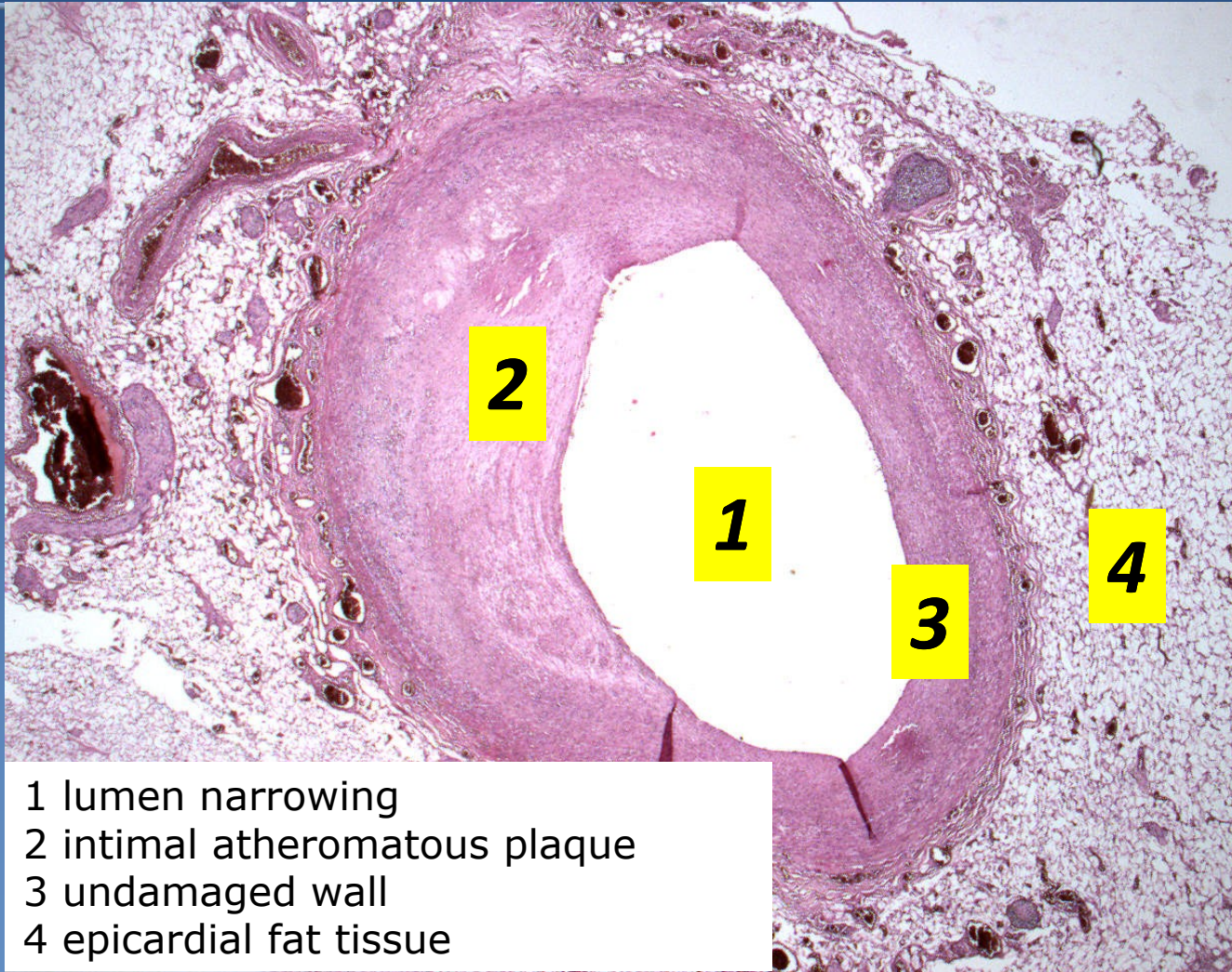




Atherosclerosis- plaque ulceration, mural thrombosis

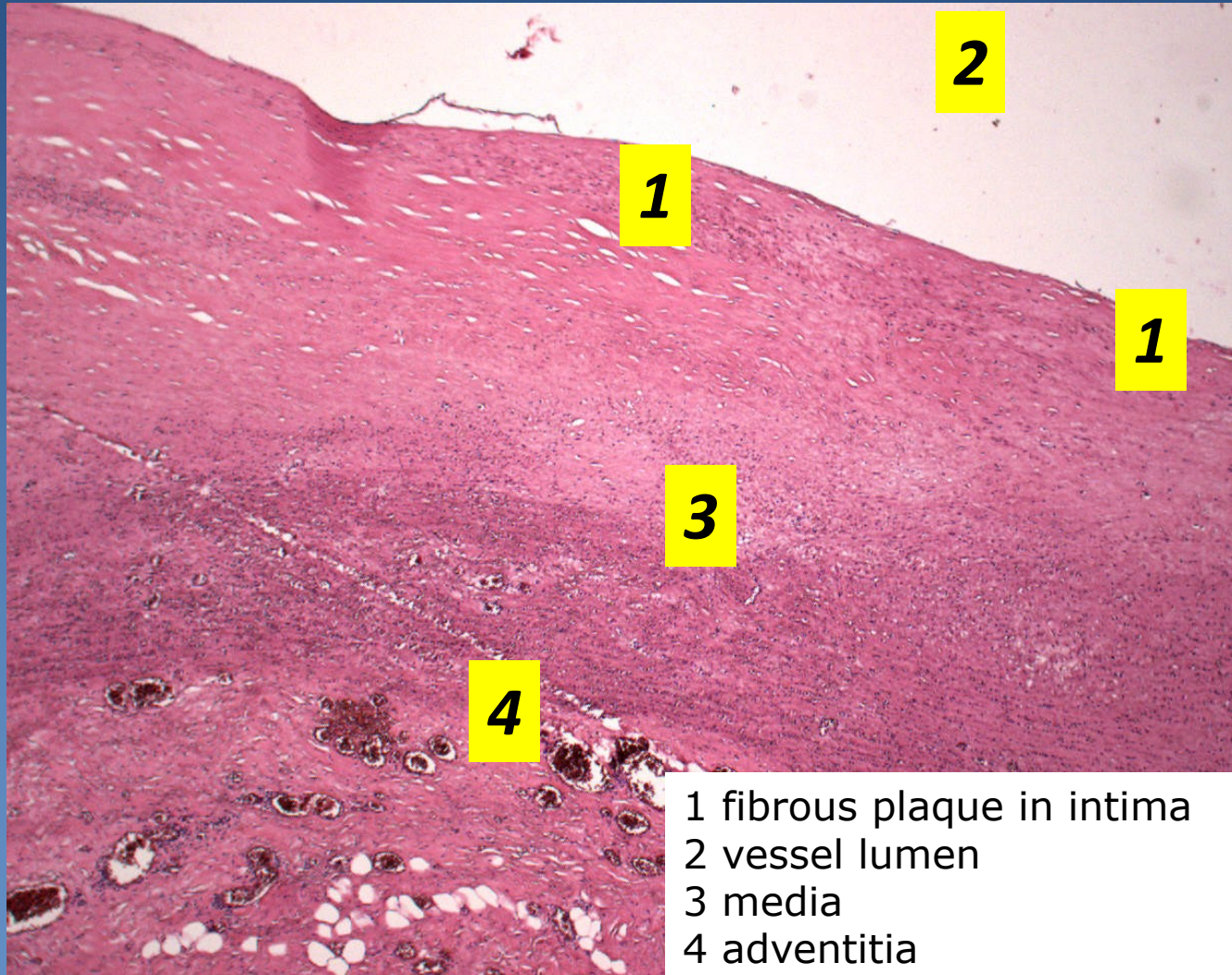


Atherosclerosis- coronary artery

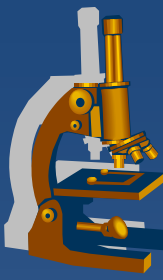


- 1 lumen narrowing
- 2 intimal atheromatous plaque
- 3 undamaged wall
- 4 epicardial fat tissue

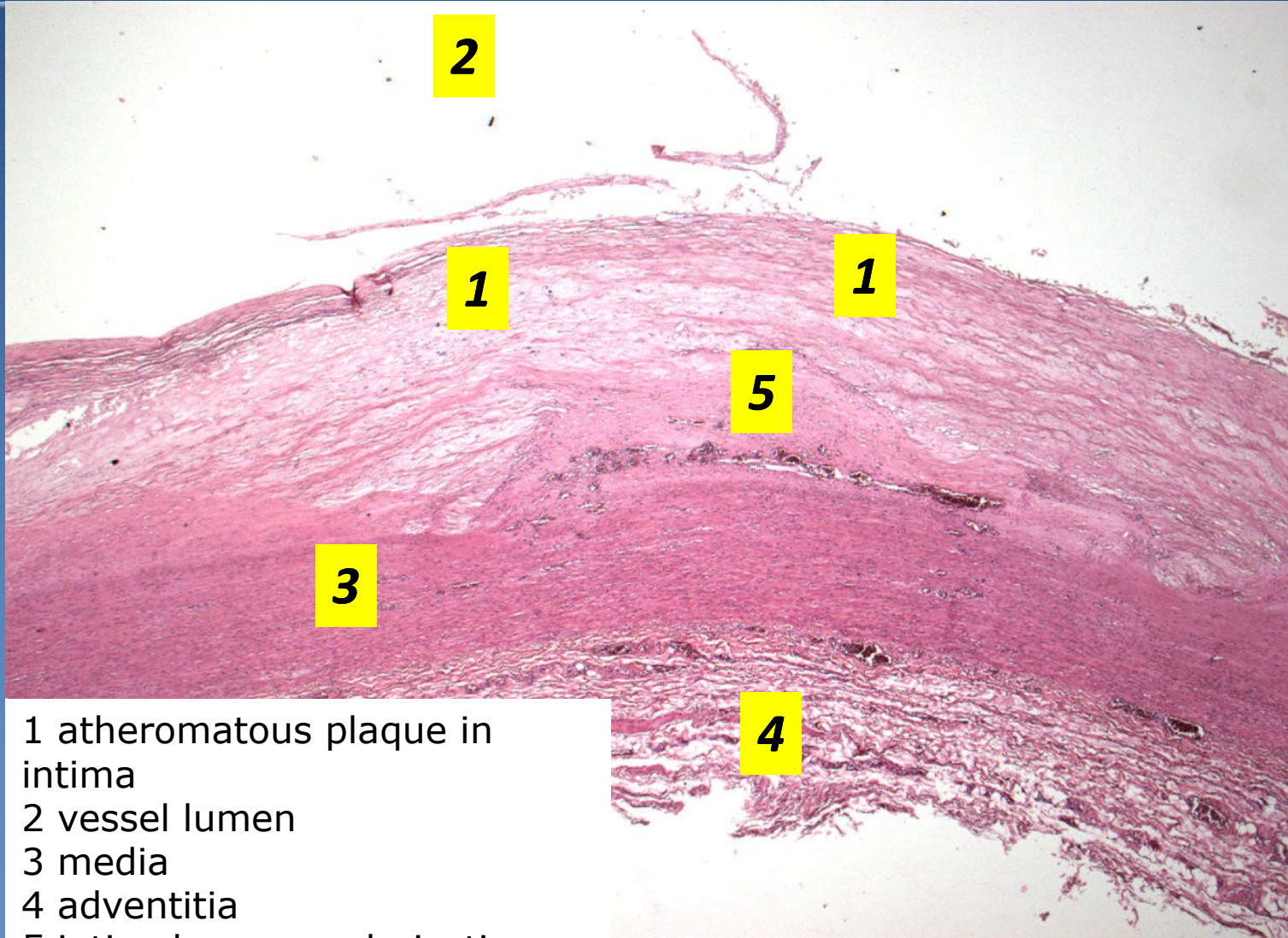
Atherosclerosis – fibrous plaque



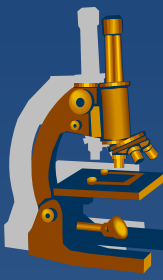
- 1 fibrous plaque in intima
- 2 vessel lumen
- 3 media
- 4 adventitia



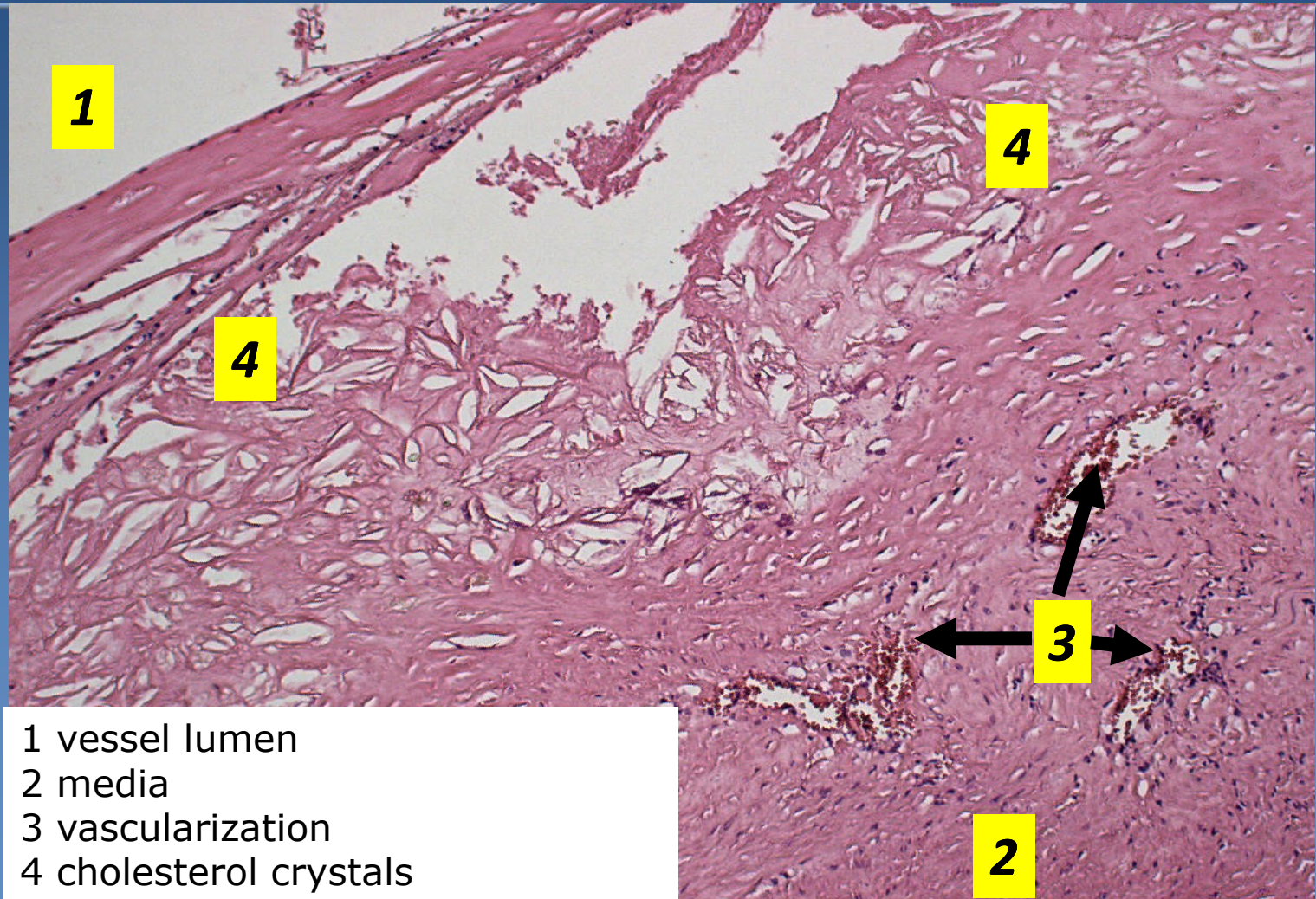
Atherosclerosis - atheromatous plaque



- 1 atheromatous plaque in intima
- 2 vessel lumen
- 3 media
- 4 adventitia
- 5 intimal neovascularization

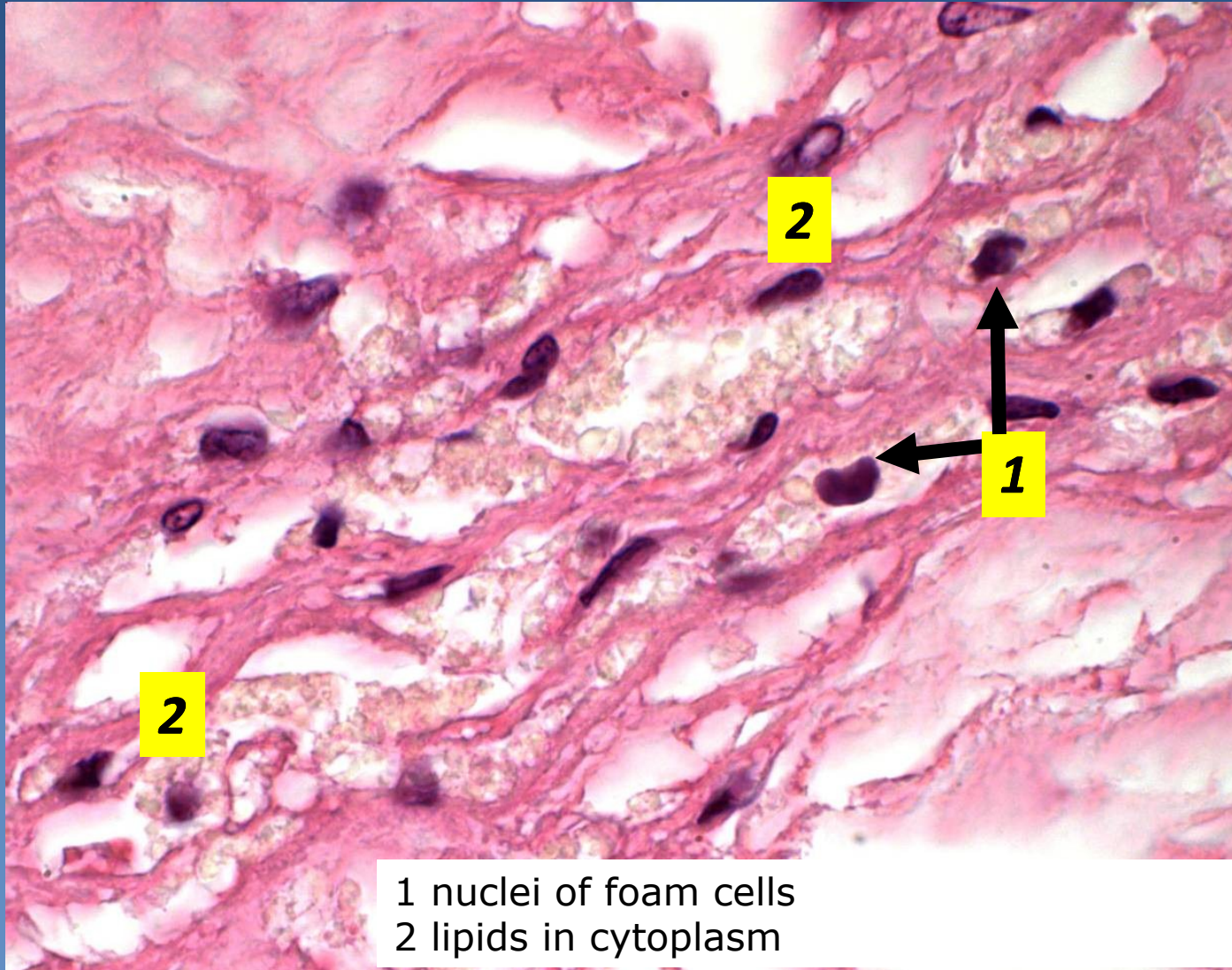


Atherosclerosis - atheromatous plaque, intimal neovascularization

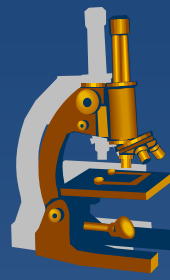


- 1 vessel lumen
- 2 media
- 3 vascularization
- 4 cholesterol crystals

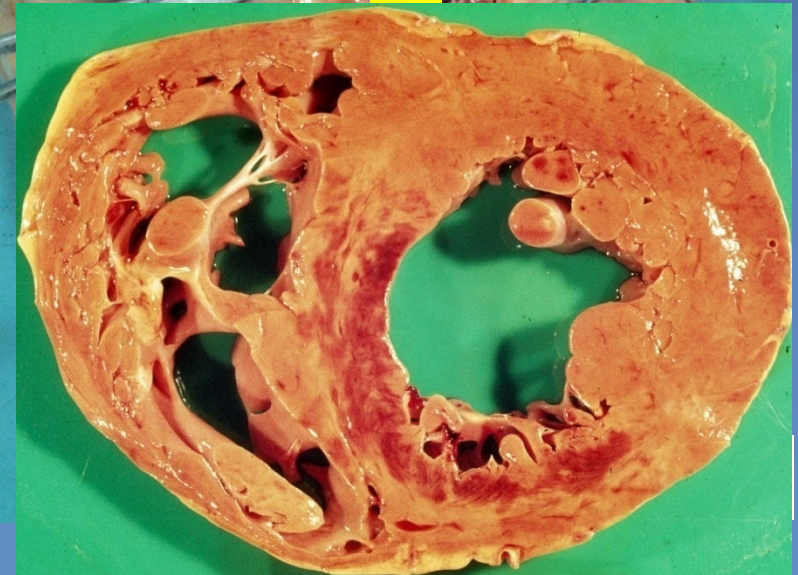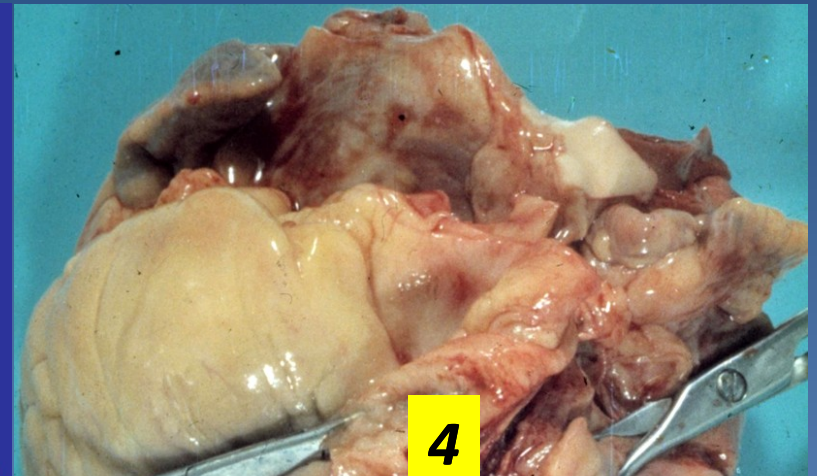
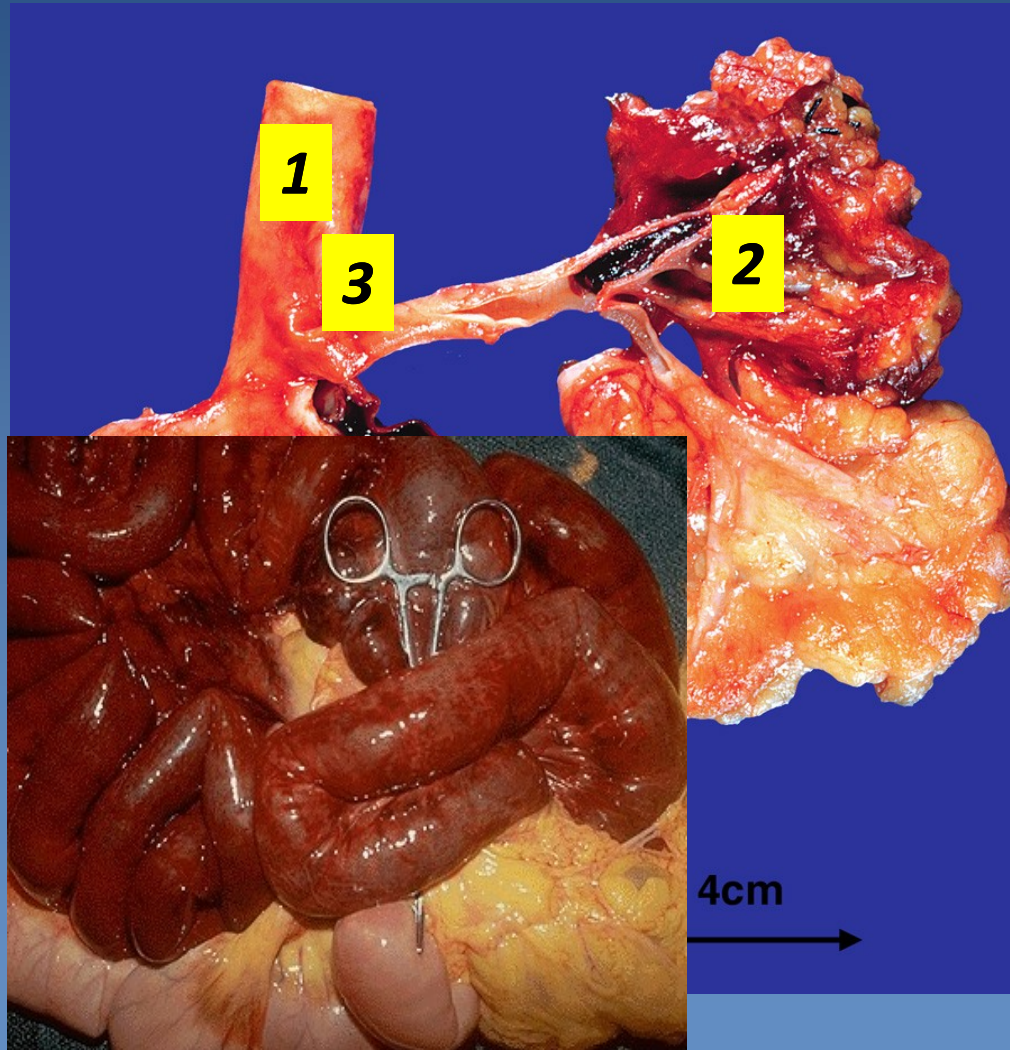
Atherosclerosis – foam cells in atheromatous plaque



1 nuclei of foam cells
2 lipids in cytoplasm



Atherosclerosis – complications thrombosis/thrombembolia

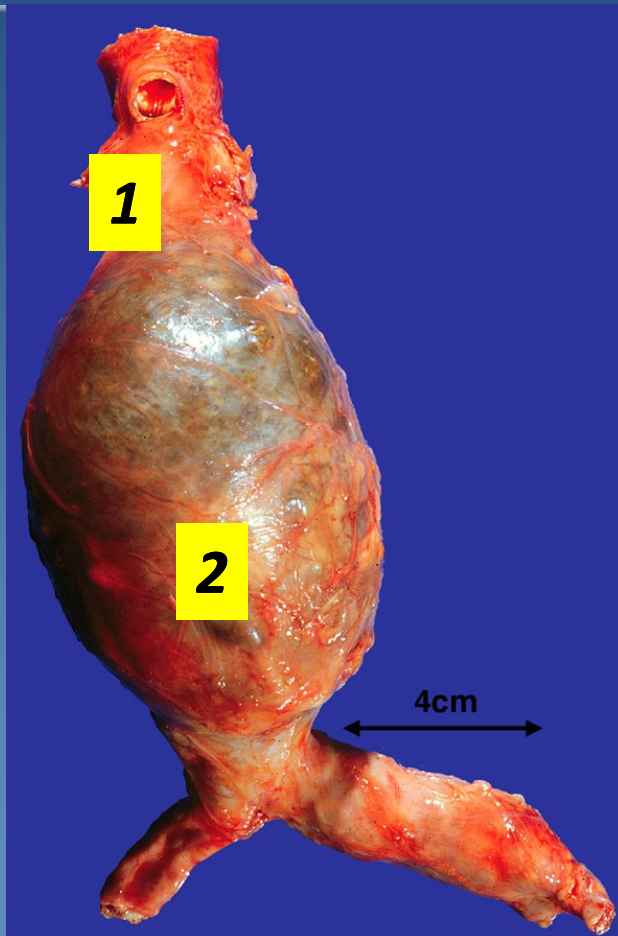


aneurysm

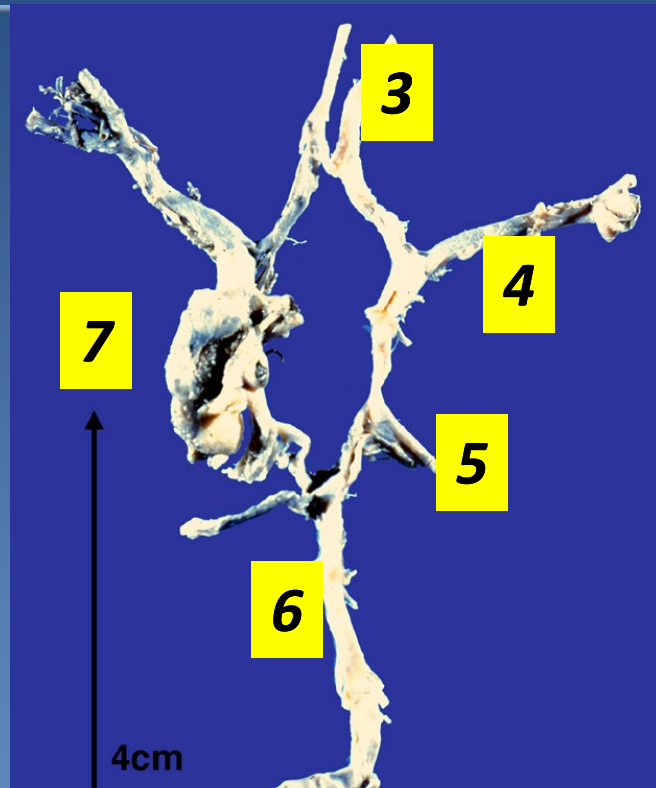


- ✗ localized, blood-filled balloon-like bulge in the wall of a blood vessel.
 - ⇒ *the circle of Willis in the brain, thoracic and abdominal aortic aneurysm*
- ✗ atherosclerotic aneurysm x syphilitic
- ✗ etiology:
 - ⇒ *hereditary defects in the structure, atherosclerosis, inflammation, disease process, accidents ...*
- ✗ false aneurysm
- ✗ serpentine aneurysm, arteriovenous aneurysm

Atherosclerosis - complications - aneurysm



1 abdominal aorta
2 aneurysm



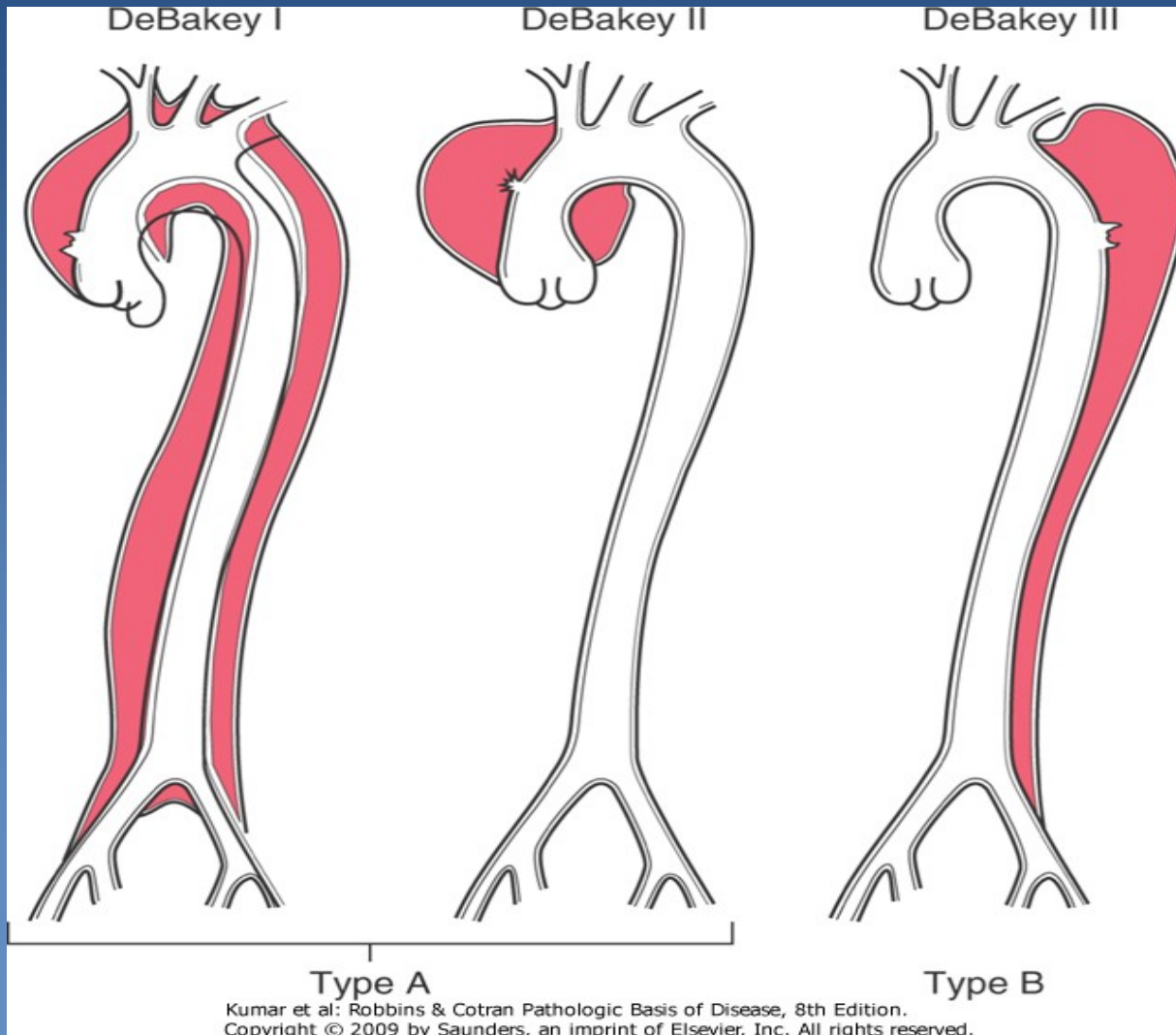
3 a. cerebri anterior
4 a. cerebri media
5 a. cerebri posterior
6 a. basilar
7 aneurysm

Aortic dissection

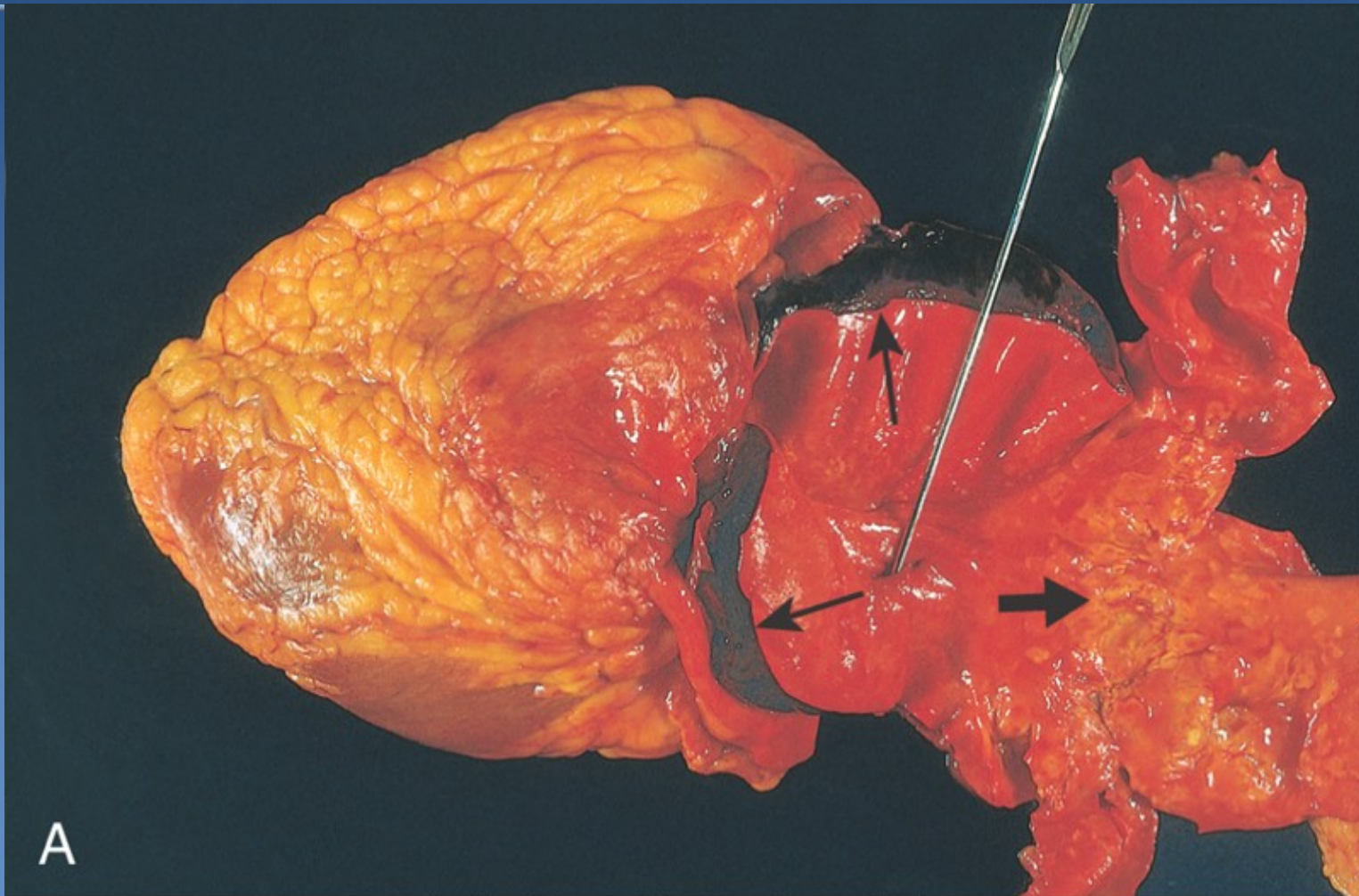


- ✗ tear in aortic intima - intramural bleeding through media, false lumen, possible „double-barreled“ aorta
- ✗ typical in ascending aort, 1–8 cm above aortic valve
- ✗ ante– and retrograde spread to the aortic root
- ✗ common thrombosis in false lumen
- ✗ risk of external rupture (→ **hemoperikardium**), progression at the aortic branches (→ **variable organ's ischemia**), **heart failure**
- ✗ predisposition – hypertension, Marfan sy, cystic medial necrosis, ...

Aortic dissection



Aortic dissection



Kumar et al: Robbins & Cotran Pathologic Basis of Disease, 8th Edition.
Copyright © 2009 by Saunders, an imprint of Elsevier, Inc. All rights reserved.

VASCULITIS



- ✗ Vessel wall inflammation
- ✗ Classification according cause: **infectious x non-infectious**
(commonly immune-mediated, ANCA+/ANCA-)
- ✗ Affected organs : all organs with vessels
- ✗ Type (size) of vessel involved: Large-vessel
Medium-vessel
Small-vessel

Vasculitis



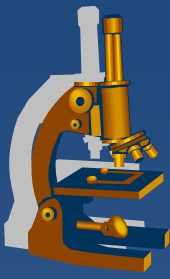
× **ANCA⁺ vasculitis** (dangerous, even fatal within a few years, if not recognised)

- ⇒ *Wegener granulomatosis*
- ⇒ *Churg-Strauss syndrome*
- ⇒ *microscopic polyangiitis*

× **ANCA⁻ vaskulitis:**

- ⇒ *polyarteritis nodosa*
- ⇒ *Kawasaki disease*
- ⇒ *giant-cell arteritis (Horton, temporal)*
- ⇒ *Takayasu arteritis*
- ⇒ *thrombangiitis obliterans (Bürger disease)*
- ⇒ *leukocytoclastic (alergic) vasculitis – cca 30%*

Etiology



× autoimmune process

× infection

⇒ *ie. streptococcus, ...*

⇒ *direct cause of infective v., or trigger factor of pathological immune processes*

Possible clinical signs of systemic vasculitis



ORL: - repeated respiratory tract inflammation

- exudate rich in plasma cells + eosinophils

Kidney: - glomerulonephritis

Lung: - variable presentation of lung diseases + hemoptysis

Skin: - ulceration, necrosis, petechiae-purpura

GIT: - ischemic ulcerations (sharply demarcated, without HP, minimal inflammation)

Chronic debilitating disease – clinical signs of tumor!!

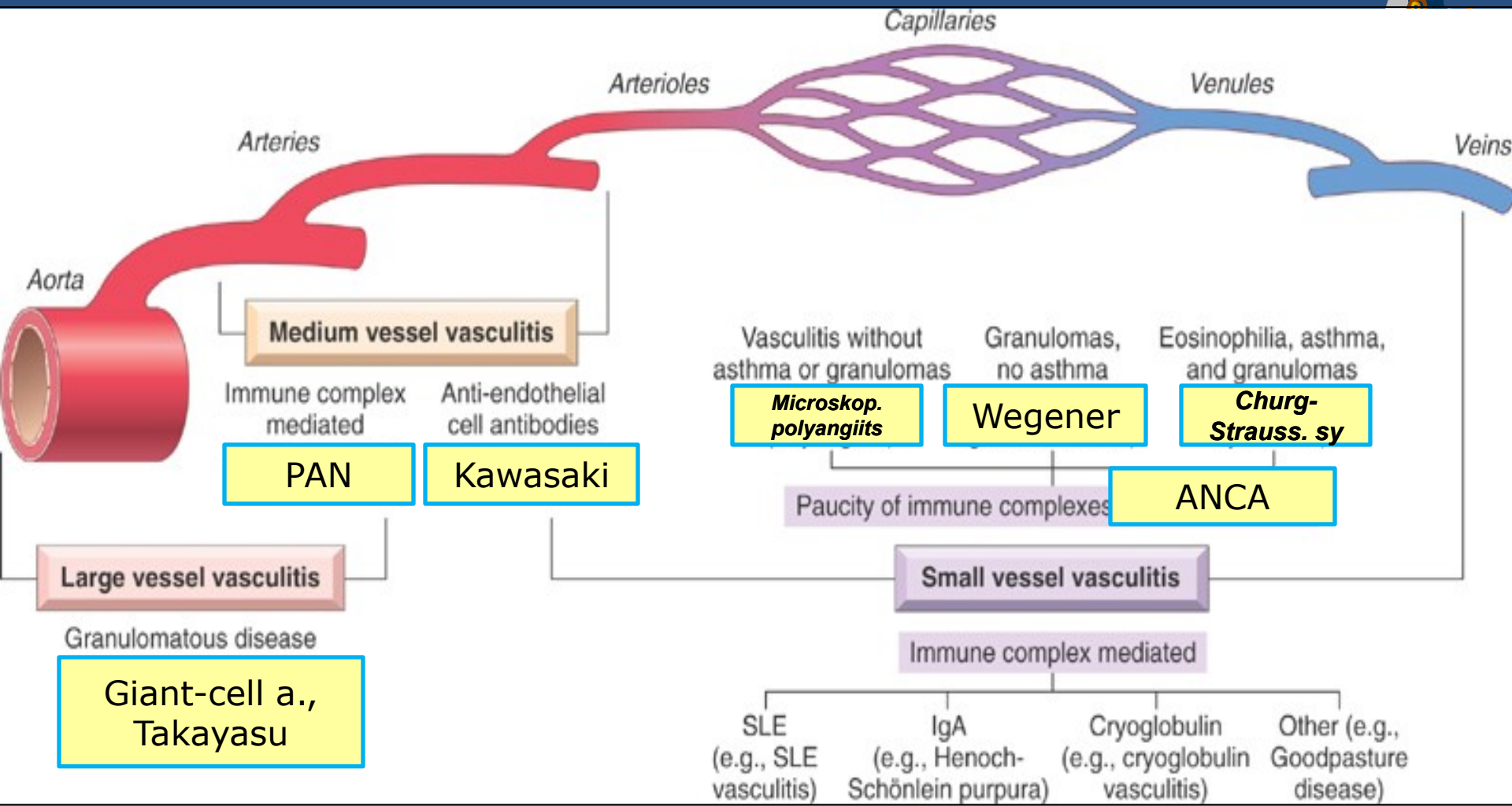
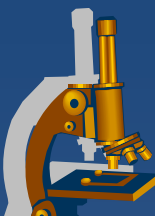
Patient presentation



- fever, nausea, myalgia, arthralgia
 - skin purpura
- signs of nephritis
- abdominal pain



general malaise (~ severe influenza, long duration, resistant to usual therapy)
sinusoid course (relapse --- remission --- relapse--)



ANCA+ vasculitis



× incidence ?????

⇒ $\leq 20/1\text{mil. inhabitants}$

⇒ **age 65+ - 53/1mil. inhabitants**

× prognosis:

⇒ *untreated ANCA⁺ vasculitis $\geq 80\%$ fatal in 2 yrs*

⇒ *treated ANCA⁺ vasculitis : $\geq 80\%$ survives 5 yrs*

⇒ *renal failure in elders >70 yrs - in 40% due to ANCA⁺ vasculitis*

granulomatosis with polyangiitis (Wegener granulomatosis)

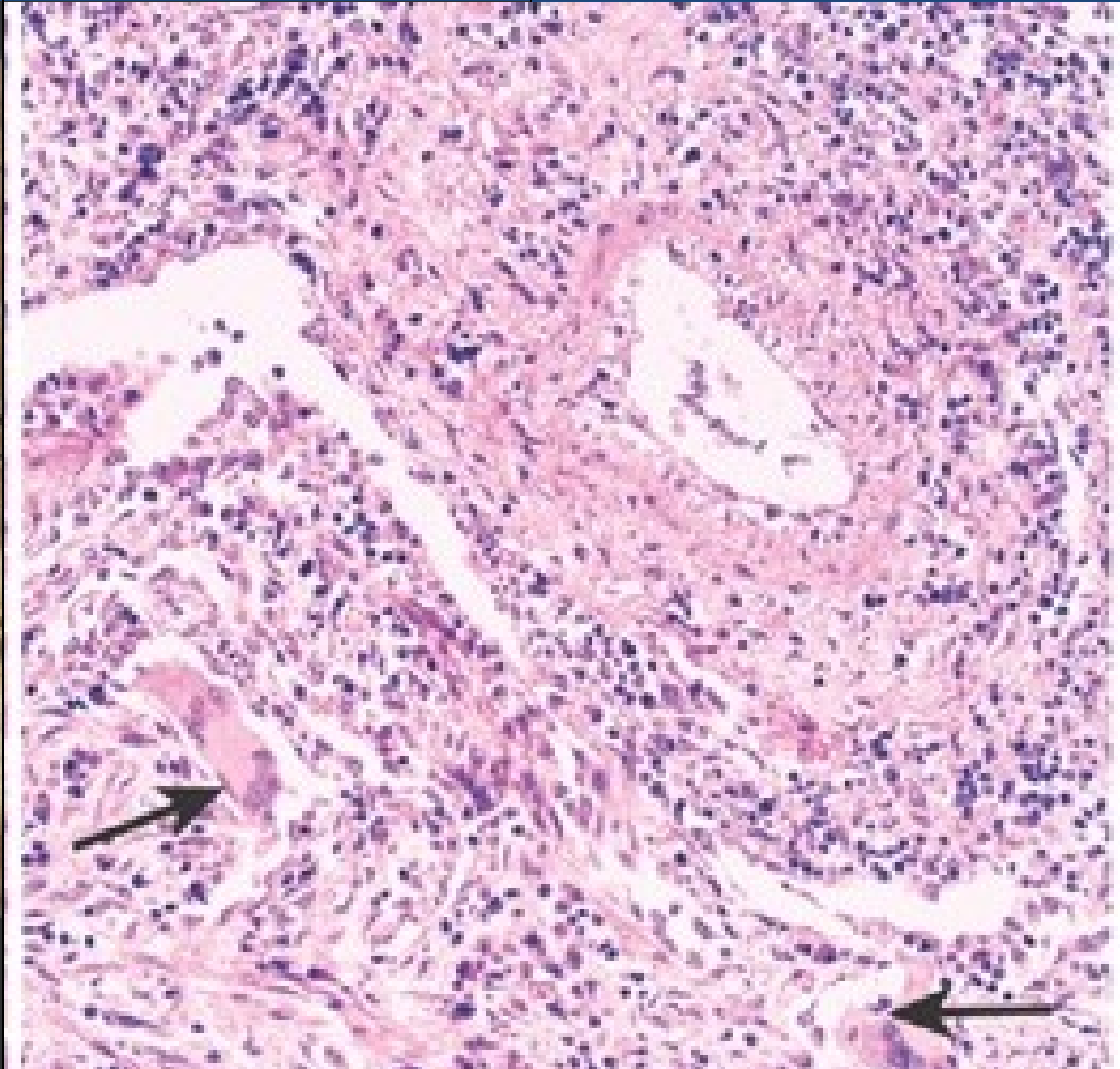


- ✗ clinically as **pneumonitis**, persistent X-ray with bilat. nodular infiltrates, **chronic sinusitis** with mucosal **ulcerations nasopharynx** (sometimes destructive axial structures), **ARI / CHRI** (focal necrosis, sickle cell GLN)

granulomatosis with polyangiitis (Wegener granulomatosis)



- ✘ persistent pneumonitis (95%) – nodular infiltrates
- ✘ chronic sinusitis (90%) – ulcerations, event. Destructive
- ✘ renal disease (80%) – glomerulonephritis
- ✘ other features: rashes, muscle pains, articular involvement, mono-/polyneuritis



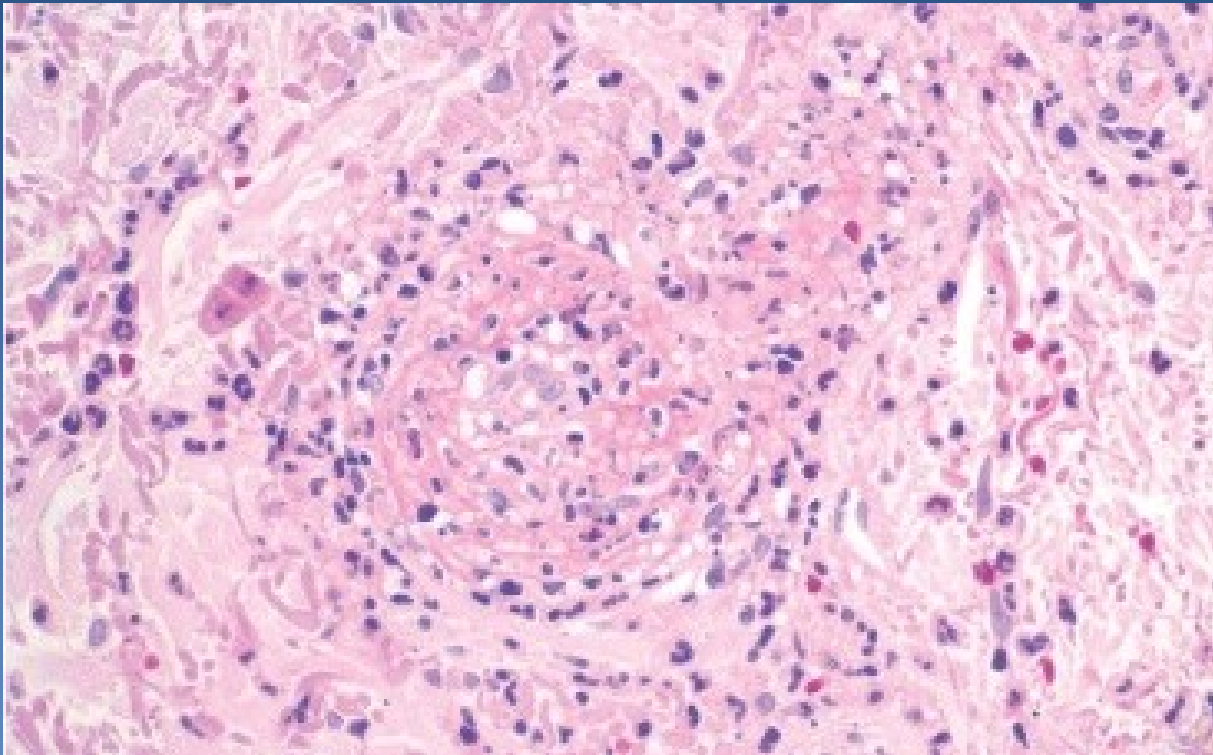
Small vessel vasculitis with giant-cell granulomatous reaction

ANCA+ VASCULITIS: microscopic polyangiitis



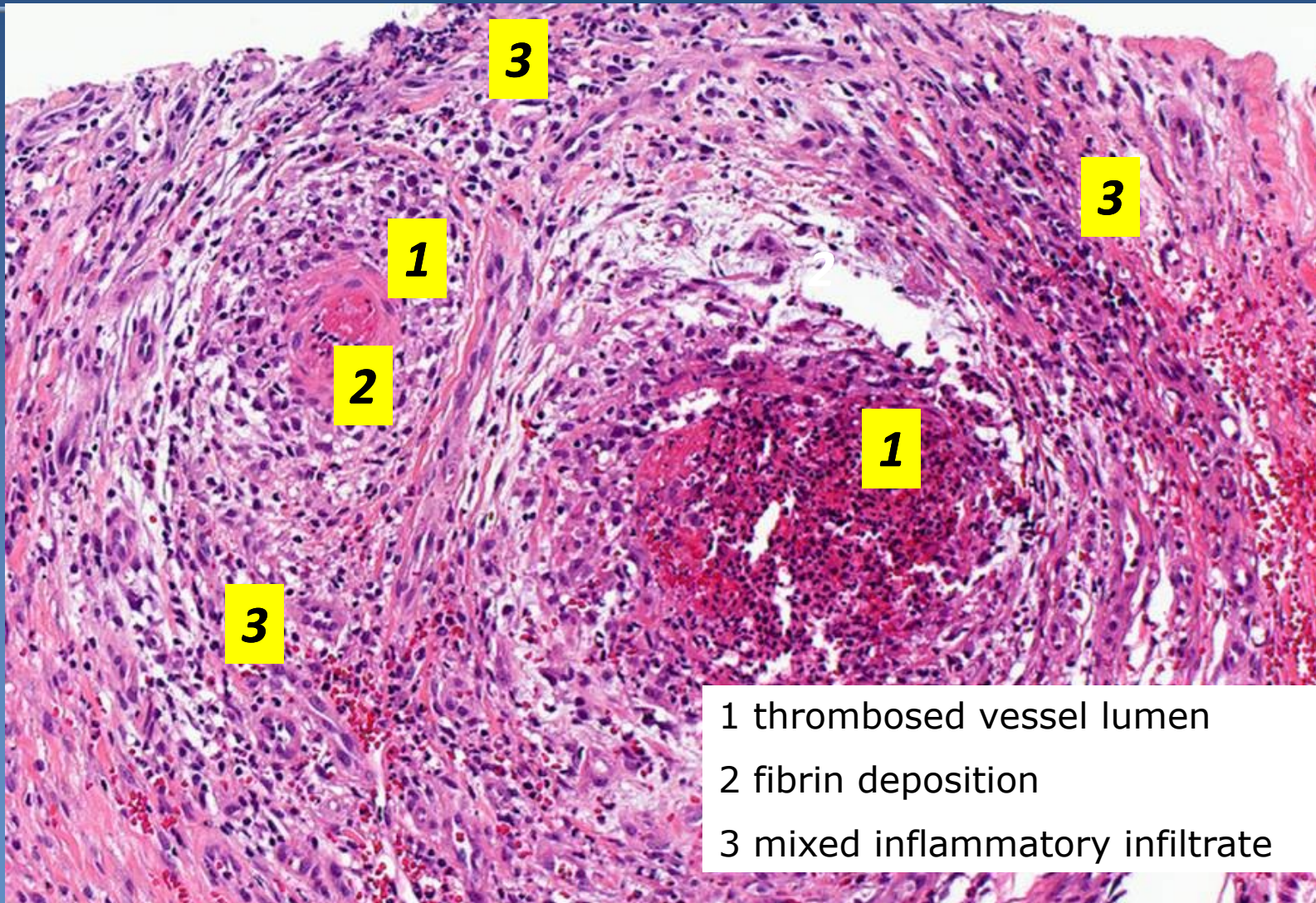
- ✗ ANCA in approx. 70% (remaining by immunecomplexes or antibodies)
- ✗ = **necrotizing vasculitis** arterioles, capillaries, venules (synonyms: leukocytoclastic v., hypersensitive v., allergic v.)
- ✗ : **SKIN**, kidney, lung, GIT, brain...
- ✗ highly variable etiopathogenesis (part of systemic connective tissue diseases; allergic response to exogenous antigens – bacteria, viruses, drugs)
- ✗ micro:
 - ⇒ *fibrinoid necrosis of vessel wall with neutrophils and chromatin fragments from neutrophil's nuclei - leukocytoclastic*
 - ⇒ *all lesions in the same stage of evolution* (X *polyarteritis nodosa*)

leukocytoclastic vasculitis



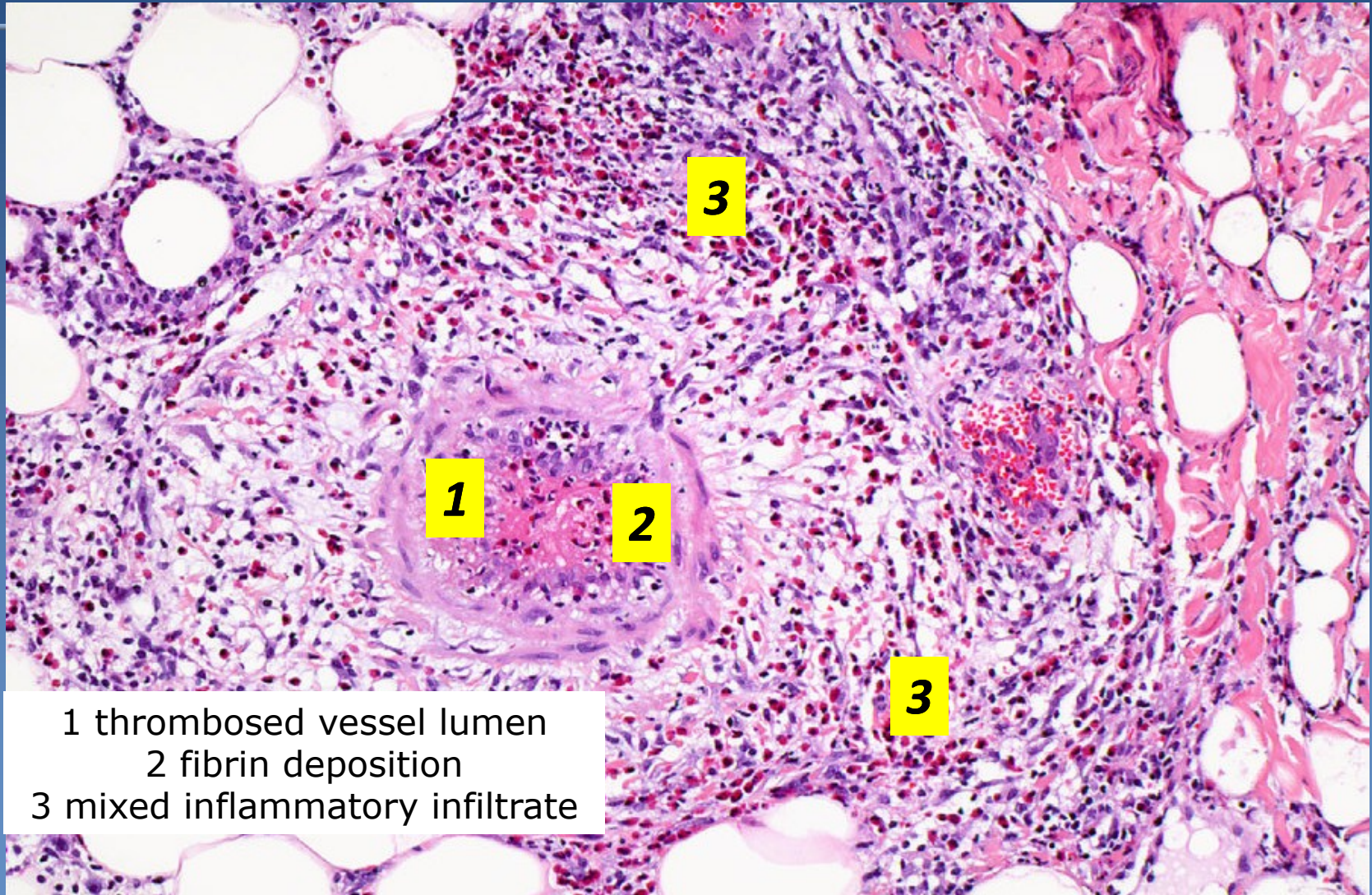
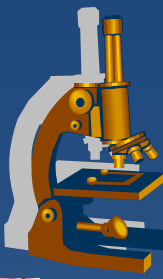
nuclear fragments from neutrophils in a small vessel wall

polyarteritis nodosa



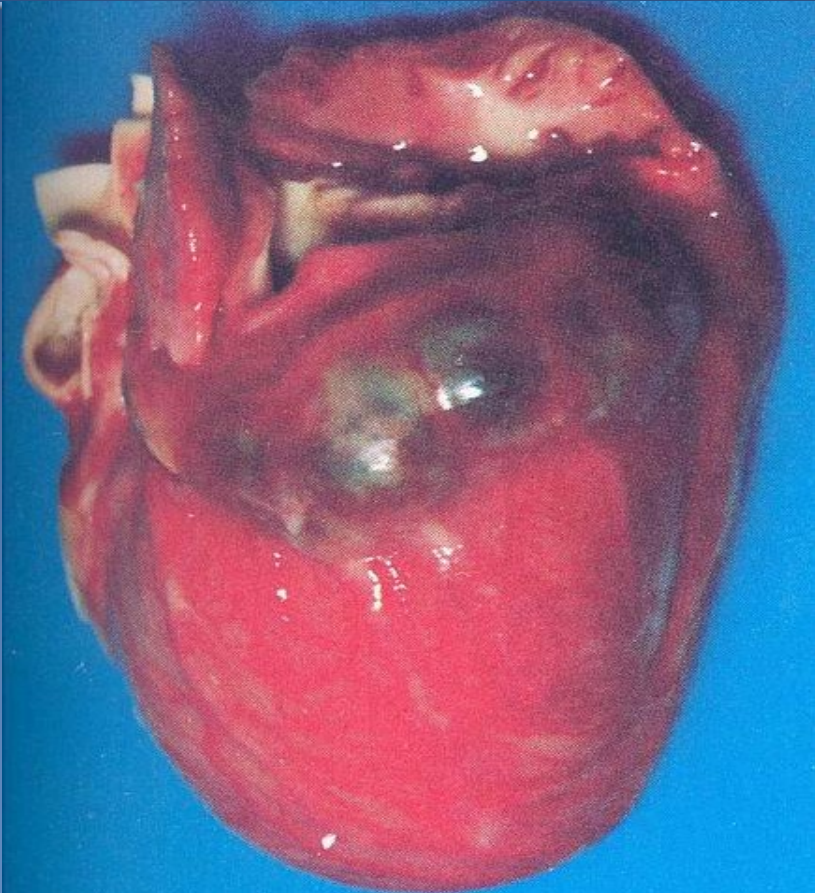
- 1 thrombosed vessel lumen
- 2 fibrin deposition
- 3 mixed inflammatory infiltrate

polyartereritis nodosa

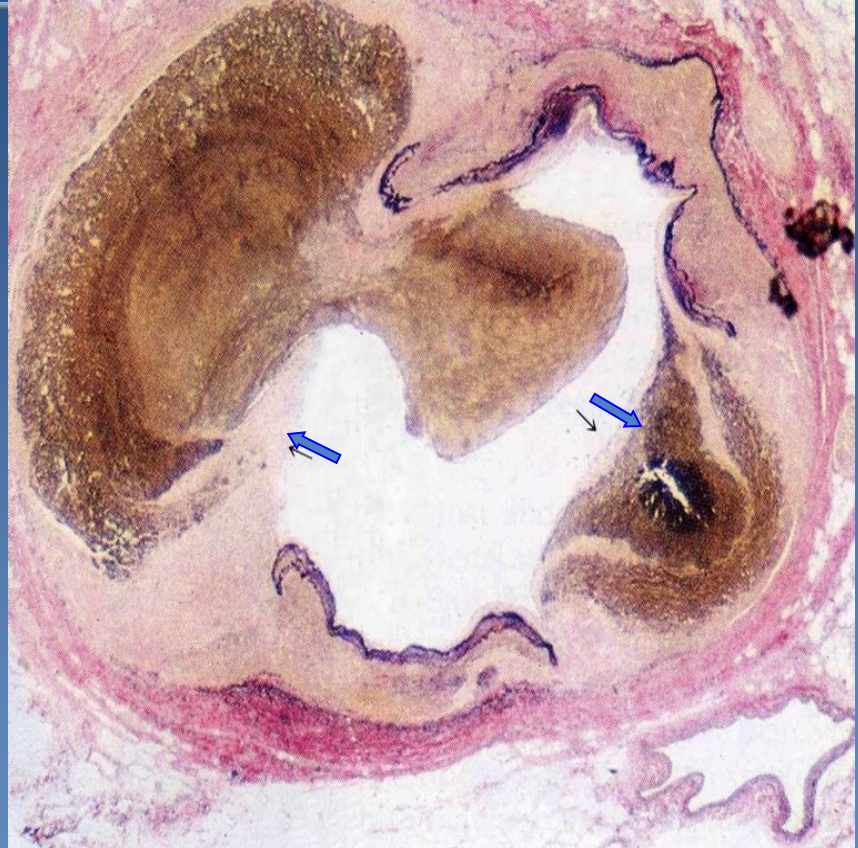


1 thrombosed vessel lumen
2 fibrin deposition
3 mixed inflammatory infiltrate

Kawasaki disease

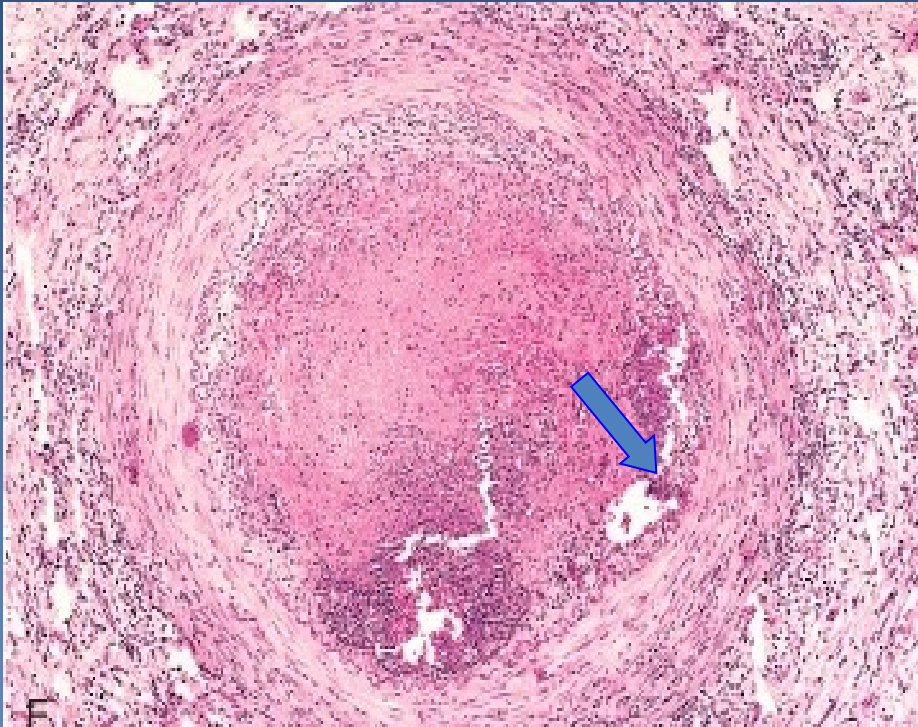


Coronary aneurysms in a child's heart

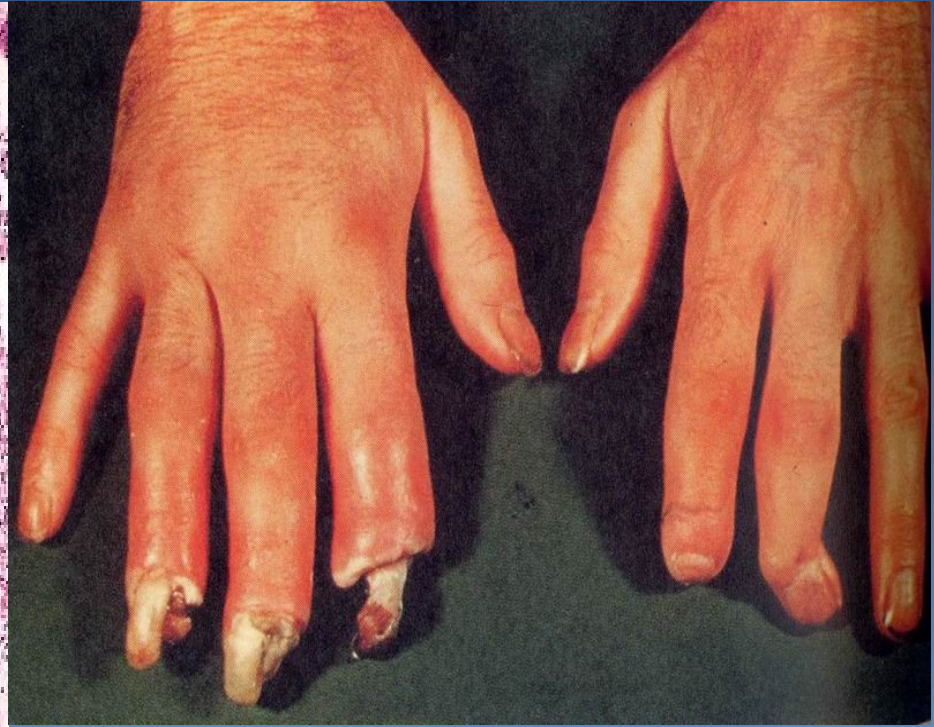

coronary artery with lamina elastica interna defects (arrows) and thrombotized aneurysms

Thrombangiitis obliterans (*Bürger disease*)



Obliterative thrombosis with granuloma with central microabscess (arrow)



acral necroses

infectious vasculitis



× rare

× arise:

- ⇒ *transfer of infection from surrounding tissues*
- ⇒ *infected emboli during pyemia*

× examples:

- ⇒ *aortitis luetica*
- ⇒ *bacillary angiomatosis = opportunistic infections (eg AIDS)??*

Infectious vasculitis



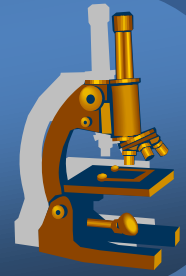
- × direct invasion of vascular wall by inf. pathogen

- × primary angioinvasive microorganism
Fungi: *Aspergillus*, *Mucor* - thrombosis → ischemic necrosis

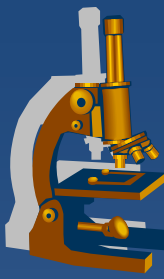
- × secondary vasculitis - **localized vasculitis** in focal infection
 - ⇒ purulent – meningitis
 - ⇒ pneumonia
 - ⇒ abscess, fasciitis – pyogenic bacteria
 - ⇒ granulomatous
 - obliterative endarteritis – TB tertiary syphilis, I
 - Lepra
 - ⇒ lymphocytic vasculitis – rickettsia (spotted fever, Q fever etc.)
 - ⇒ recurrent herpes, CMV
 - ⇒ necrotizing vasculitis – anthrax



Cardiac pathology

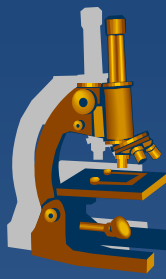


Morphology

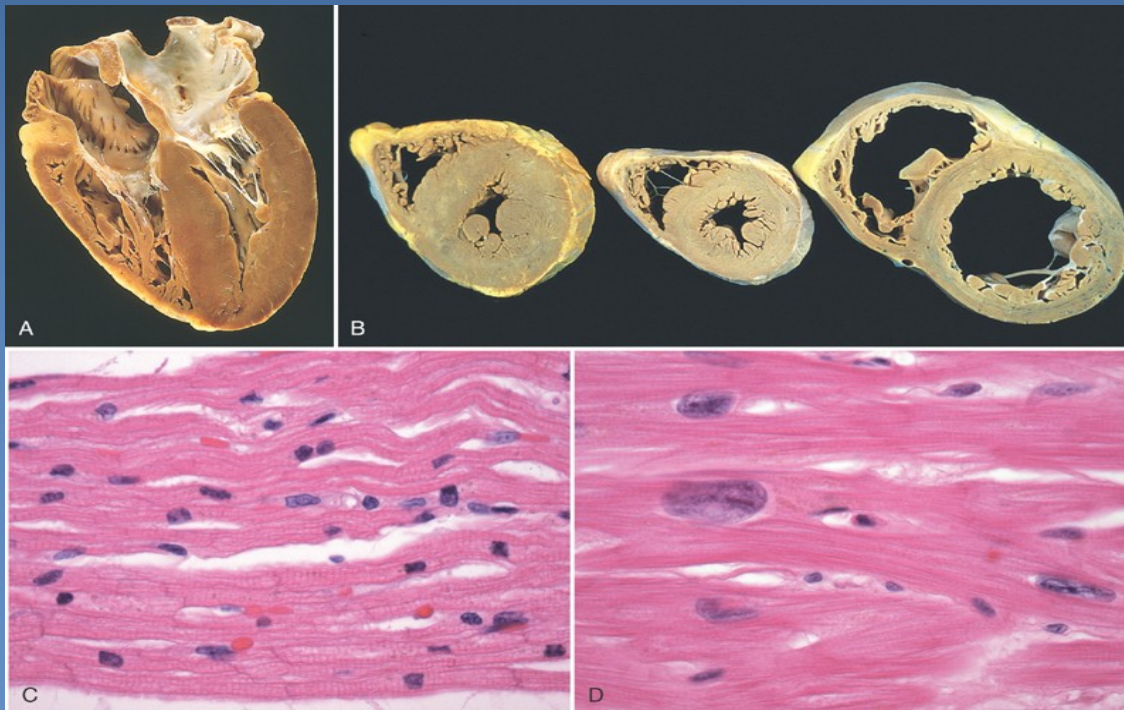


- ✗ pericardial sac – cca 30ml clear yellowish fluid
- ✗ **male = 300 – 350 g**,
 - *hypertrophy > 400g*
- ✗ **myocardium:**
 - RV 3 – 4 mm
 - LV 12 – 15 mm
- ✗ **foramen ovale**
 - *closed x opened → paradoxical embolia*

Systemic hypertension and heart



- × 90–95% essential , risk factor for AS
- × **work overload** → LV adaptation to ↑ peripheral resistance = **cor hypertonicum** (concentric LV hypertrophy) → limited compensatory mechanisms → **cor hypertonicum decompensatum** (dilatation of hypertrophic LV)
- × → heart insufficiency ← relative coronary incompetence



Heart failure



- ✘ heart unable to pump blood at a rate sufficient for metabolic demands of the tissues
- ✘ systolic dysfunction - ↓ myocardial contractile function (ischemic injury, pressure or volume overload – valvular disease, hypertension, cardiomyopathy)
- ✘ diastolic dysfunction - inability to dilatate sufficiently (massive LV hypertrophy, myofibrosis, amyloidosis)
- ✘ cardiac – extracardial pathologic changes

Heart failure



- ✘ failure of normal pumping action of the heart
- ✘ failure of forward and backward → to cardiogenic shock
- ✘ manifestations of the heart and heart out

Cardial changes



- × **disproportion between heart function and peripheral vascular resistance**
- × differ according rapidity of development:
 - **sudden** → acute dilatation
 - **chronic** → adaptation → → →
*myocardial hypertrophy (↑ nutritional demands) +/- ventricular dilatation
(enhanced contractility – Frank-Starling mechanism), + activation of
neurohumoral systems (norepinephrin, renin-angiotensin sy, atrial natriuretic peptide*

Extracardial changes

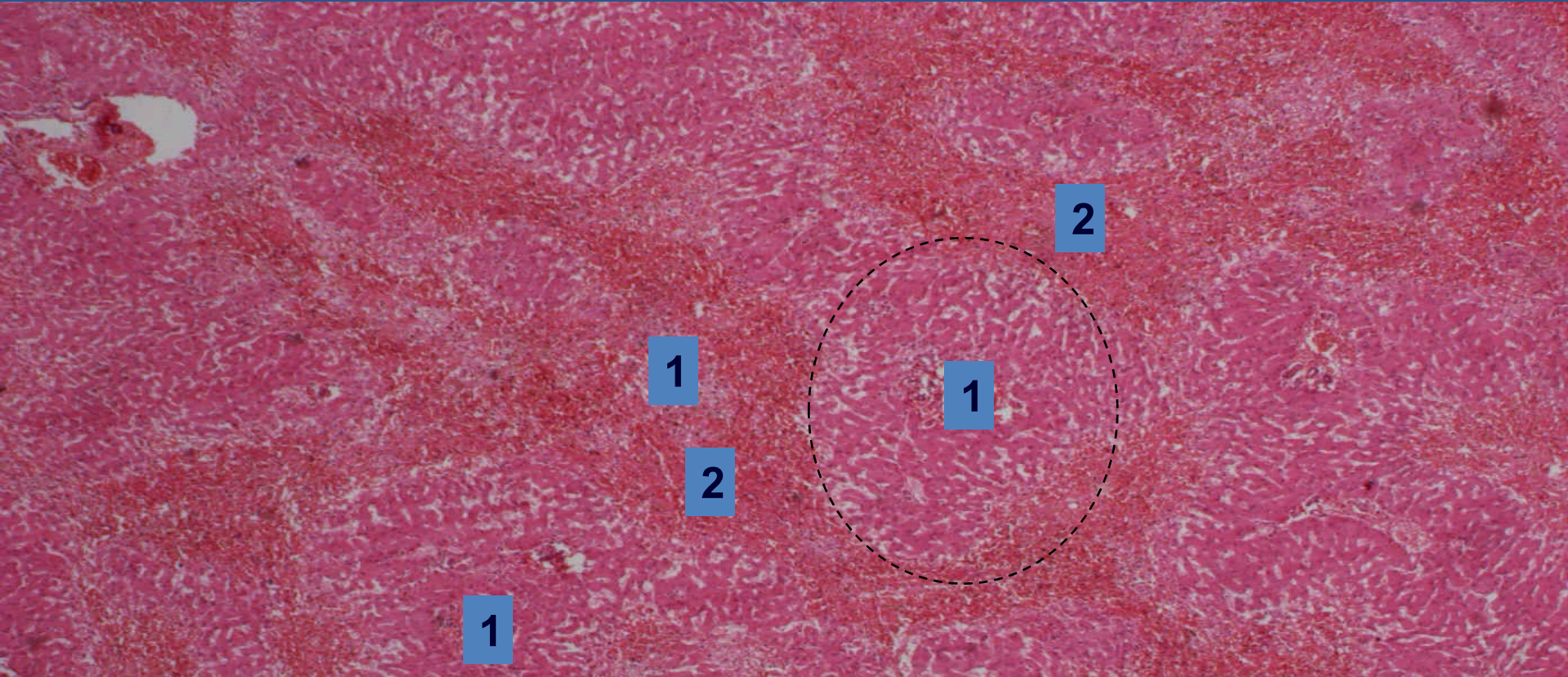
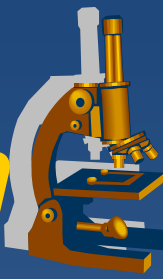


- × **venous congestion** – e.g. liver (-> *hepar moschatum*)
- × **induration** – fibroproduction (liver, spleen, kidney)
- × **oedema** –
- × **cyanosis** – visible on acral parts

***Chronic venous congestion
(nutmeg liver - hepar moschatum)***



Hepatic venous congestion

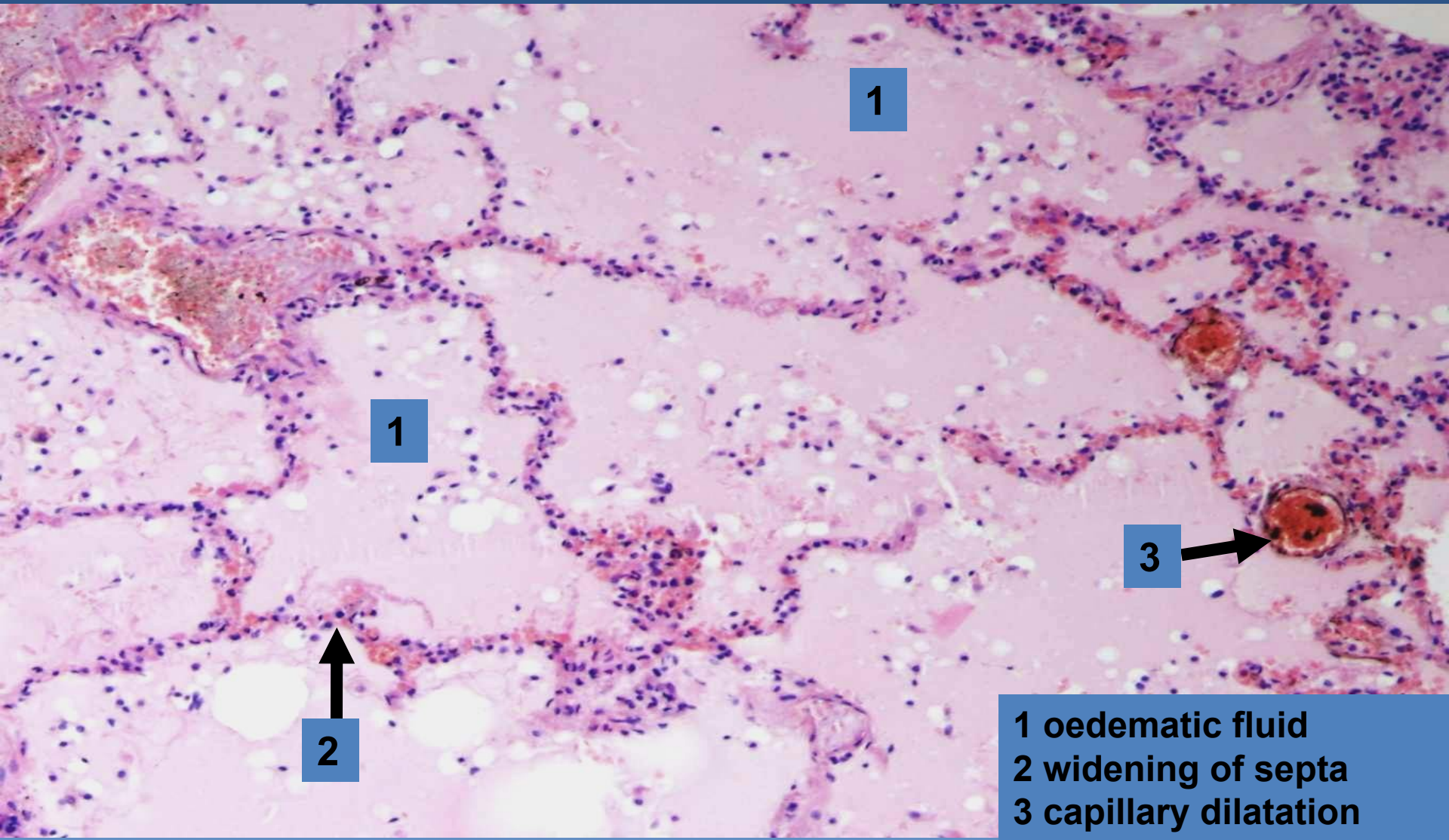


1 Portal spaces

2 Congestive lines (severe congestion with hepatocyte necrosis)

--- pseudolobule: confluent remnants of 3 lobules, centrally portal space

Pulmonary oedema



1

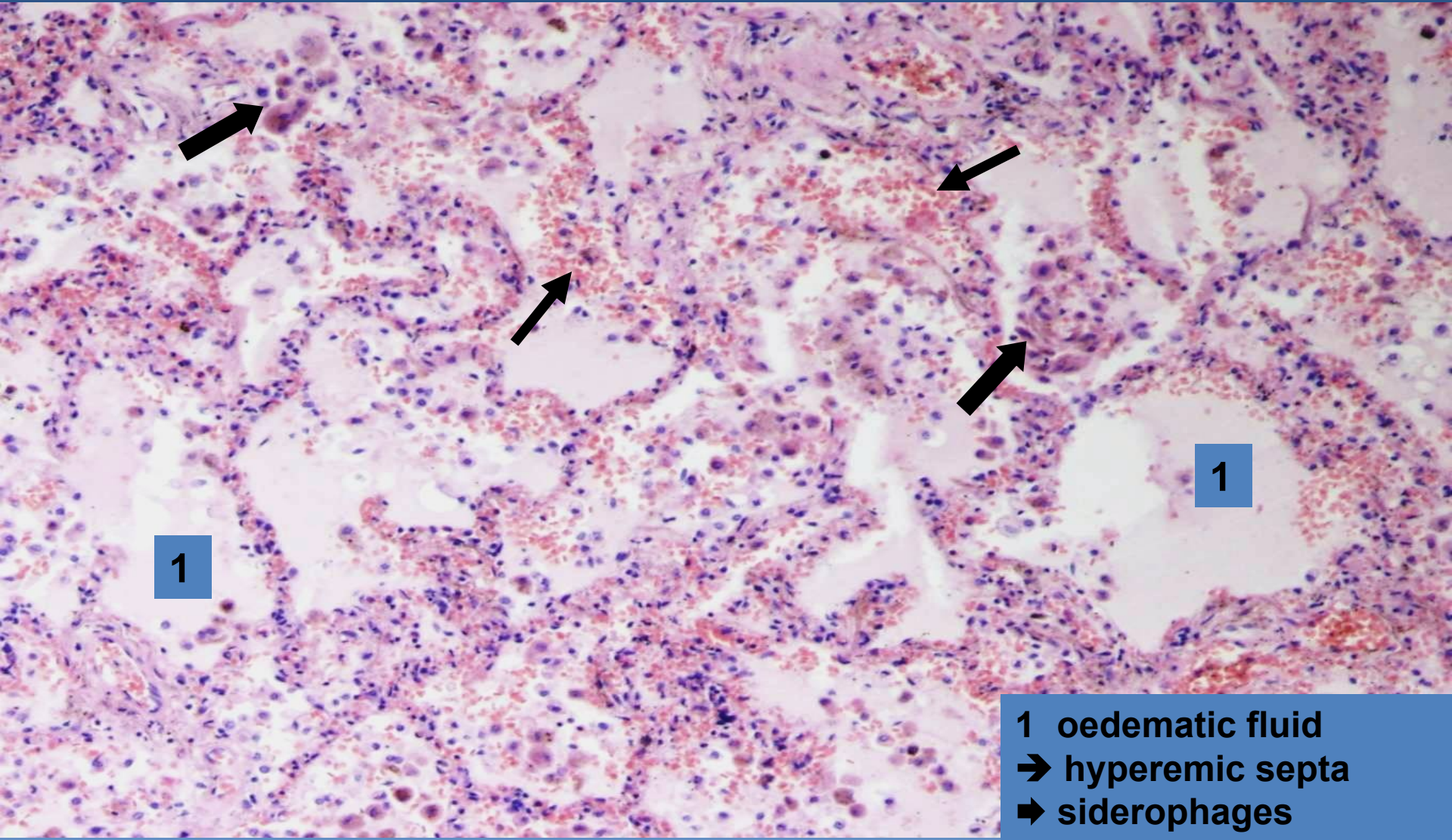
1

3

2

1 oedematous fluid
2 widening of septa
3 capillary dilatation

Chronic pulmonary venous congestion



- 1 oedemetic fluid
- hyperemic septa
- ➡ siderophages

Ischemic heart disease (IHD)



- ✘ group of pathophysiologically related syndromes resulting from **myocardial ischemia** (hypoxia or anoxia, ↓ nutrients, ↓ removal of metabolites)
- ✘ imbalance between the demand and supply by coronary arteries.
- ✘ important factor – coronary AS
- ✘ forms:
 - ⇒ *angina pectoris*
 - ⇒ *myocardial infarction (MI)*
 - ⇒ *chronic IHD with heart failure*
 - ⇒ *sudden cardiac death*

Pathogenesis of IHD



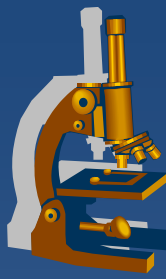
1) AS of coronary aa.

- commonly at a. branching
- fixed obstruction by plaque (fibrous, atheromatic)
- acute plaque change (rupture, erosion, haemorrhage, thrombosis)
- 75% stenosis – ischemia during \uparrow workload – stable angina pectoris
- 90% stenosis – ischemia even at rest – unstable angina - preinfarction

2) non-atherosclerotic

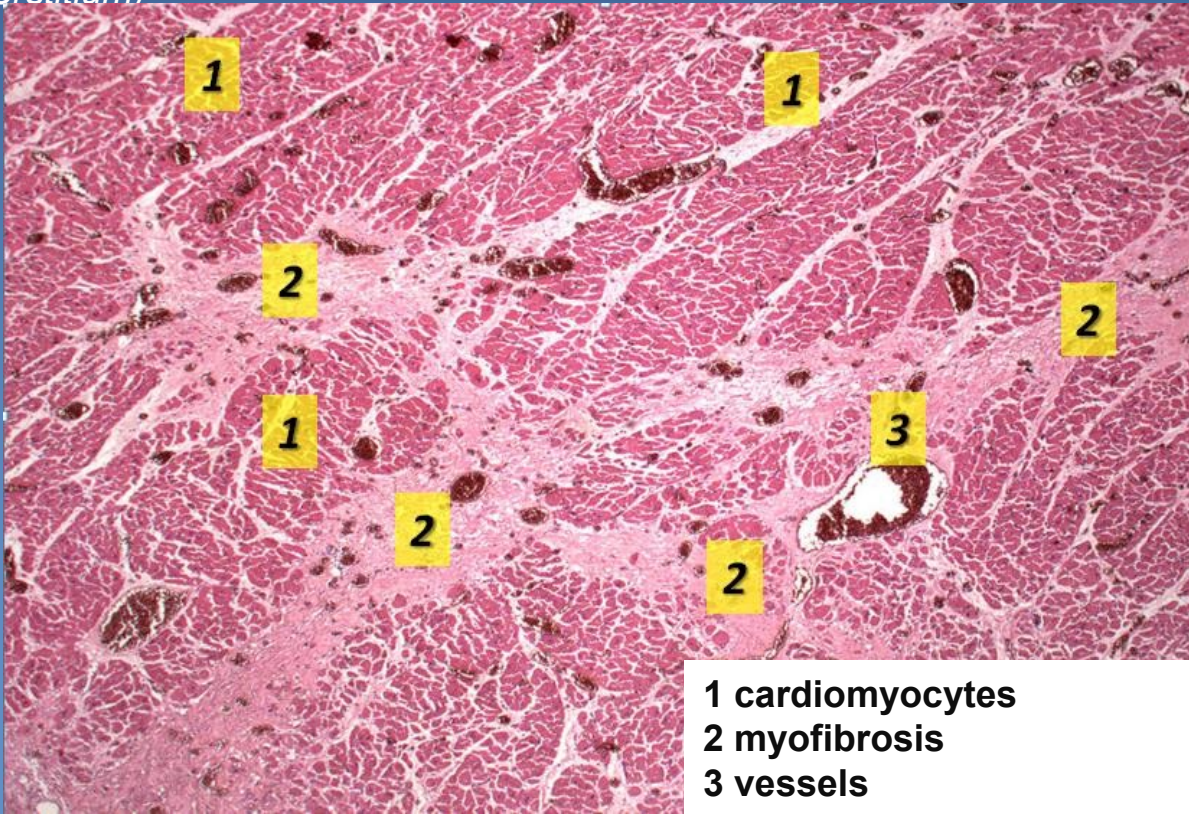
- coronary emboli – endocarditis, atrial fibrillation, mural thr., paradoxical e.
- coronary vasospasm
- aortic dissection
- coronary vasculitis
- congenital coronary aa. defects
 - hematologic disorders, amyloidosis, shock, etc.

ischemic heart disease (IHS)



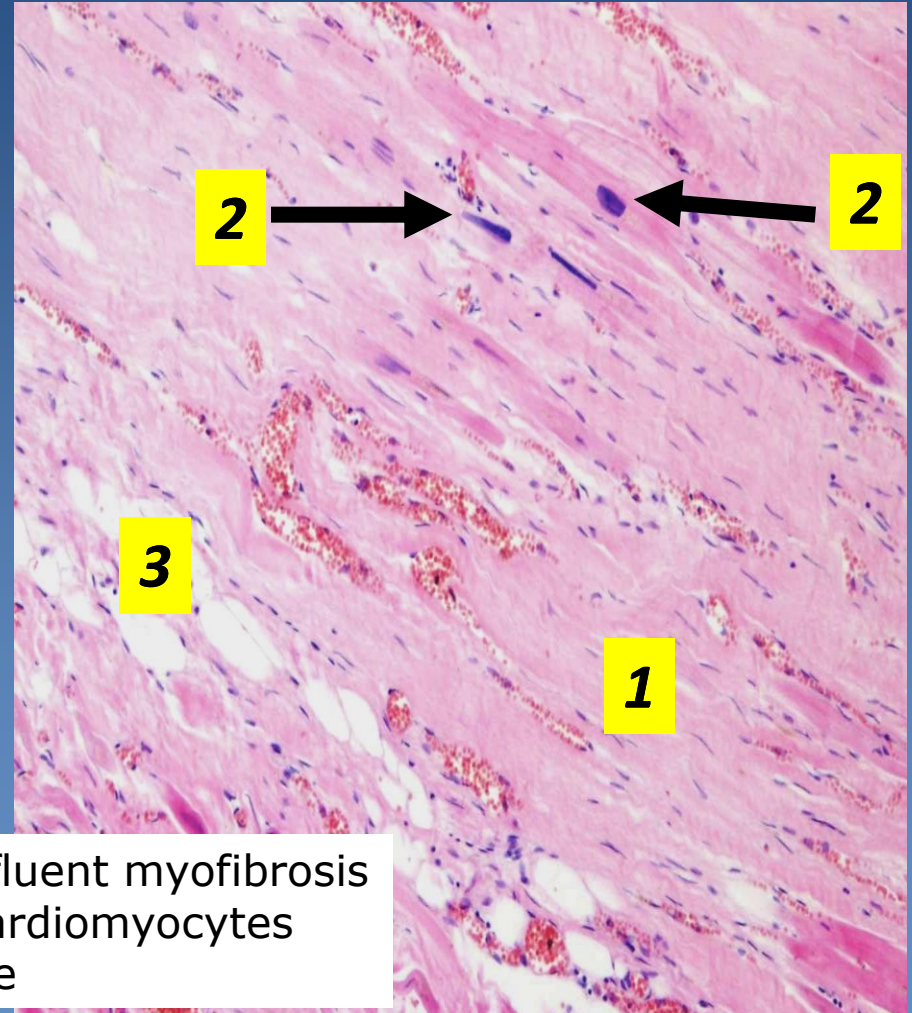
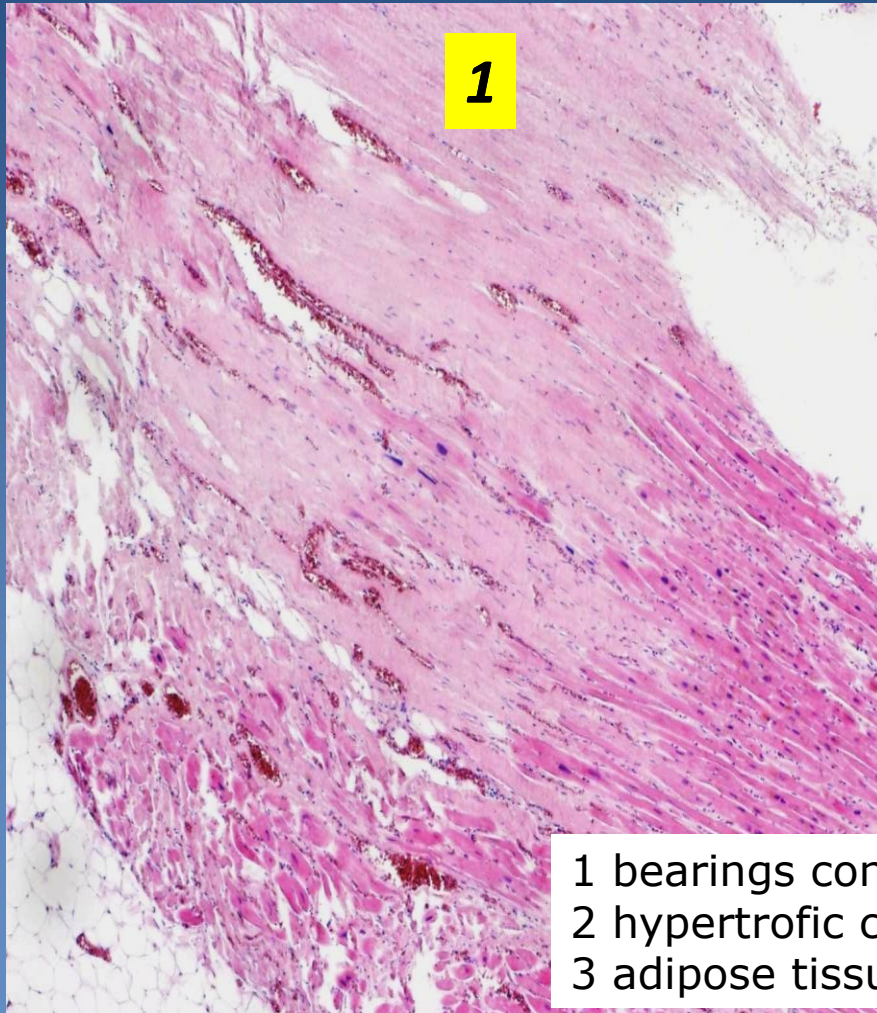
✘ Morphology of myocardial ischemia:

- ⇒ *steatosis myokardu*
- ⇒ *myomalatia* (= partial necrosis – cardiomyocytes only)
- ⇒ *dispersive /confluent myofibrosis*
- ⇒ *myocardial infarction: transmural/subendocardial* (complete coagulative necrosis incl. interstitium)

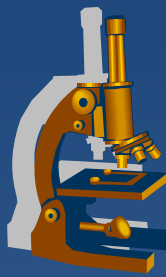


1 cardiomyocytes
2 myofibrosis
3 vessels

Confluent myofibrosis and myocard lipomatosis



1 bearings confluent myofibrosis
2 hypertrophic cardiomyocytes
3 adipose tissue



Angina pectoris (AP)

× **transient myocardial ischemia** → chest pain !!!

1. stable (typical)

- due to increased workload, duration ≤ 15 min, relieved by rest or nitroglycerin
- no myocardial necrosis
- subendocardial LV myocardium

2. unstable

- increasing frequency / duration of pain attack, even at rest
- plaque disruption + mural thrombosis, possible vasospasm
- preinfarction angina

3. variant (Prinzmetal) angina

- mostly unrelated to physical activity, coronary vasospasm - vasodilatative therapy

Myocardial infarction



× ischaemic coagulative necrosis

× causes:

- ⇒ *usually coronary thrombosis*
- ⇒ *complicated atheromatic plaque*
- ⇒ *event. embolism*
- ⇒ *spasm*
- ⇒ *inflammation*
- ⇒ *rarely systemic causes.*

× gross

- ⇒ **evolution**; *first signs (red, softer) after 12 hrs*
- ⇒ **2-3 days** *established infarction (yellowish, haemorrhagic rim)*
- ⇒ **weeks** – *formation of firm white fibrotic scar*

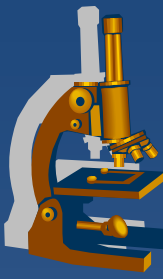
Myocardial infarction



× micro:

- ⇒ necrotic cells more red*
- ⇒ loss of nuclei and striation*
- ⇒ neutrophils*
- ⇒ later macrophages in stroma*
- ⇒ reparation by granulation tissue -> scar*

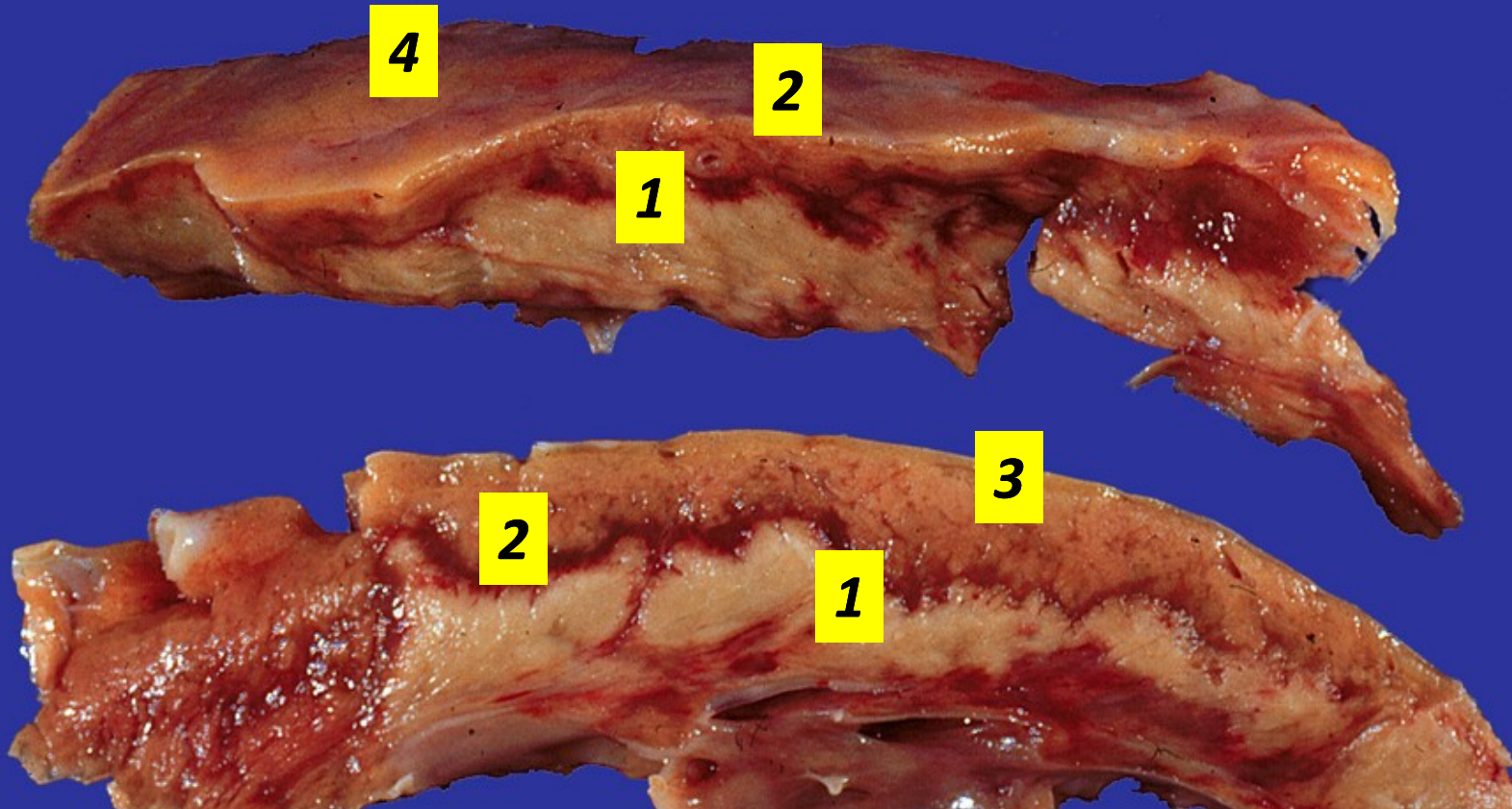
Myocardial infarction



micro:

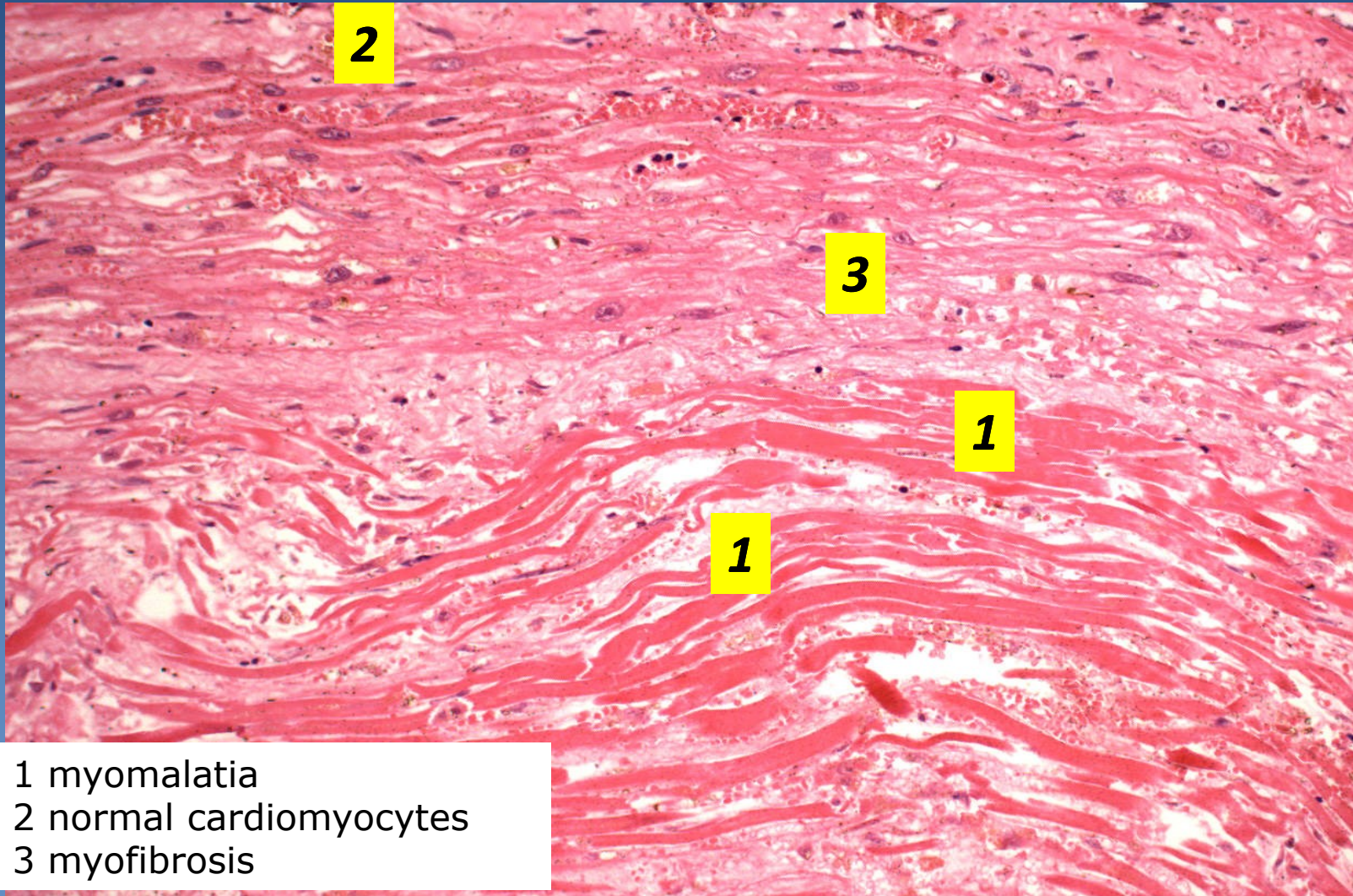- × **12-24 hr:** edema, hypereosinophilia of necrotic cells, pyknosis
- × **1-3 days:** neutrophils, loss of nuclei
- × **3-7 days:** macrophages at the border, desintegration of myofibers
- × **1-2 weeks:** repair by granulation tissue
- × **cca 2 months:** scar

Myocardial infarction



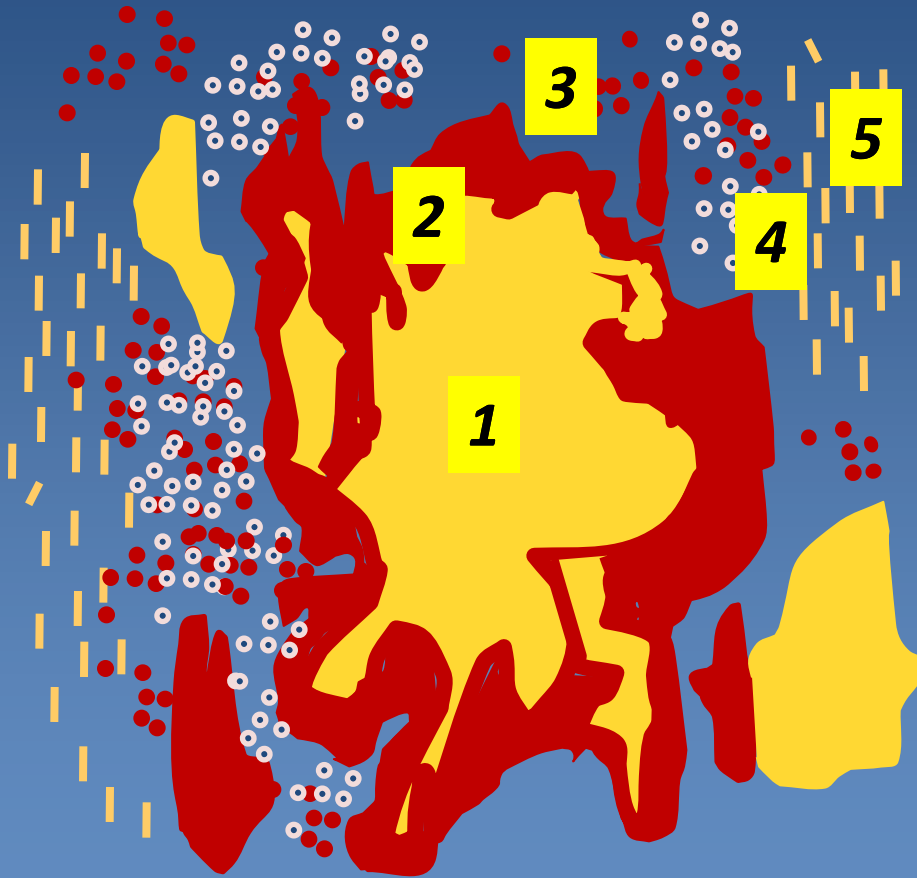
1 subendocardial coagulative necrosis 2 hyperemic rim 3 normal myocardium 4 epicardium






Myomalatia



- 1 myomalatia
- 2 normal cardiomyocytes
- 3 myofibrosis

Microscopic changes in developed MI



- 1 coagulative necrosis 
- 2 myomalatia 
- 3 hyperemic rim 
- 4 neutrophils 
- 5 regressive changes 

Myocardial infarction

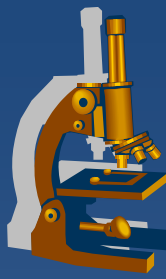


- × **transmural (QIM, STEMI) - + ST elevation on ECG**

- $\geq \frac{3}{4}$ of wall thickness, breadth >25 mm
- complete coronary artery obstruction
emergency angioplasty/stenting

- × **non-transmural (subendocardial, Non-STEMI)**

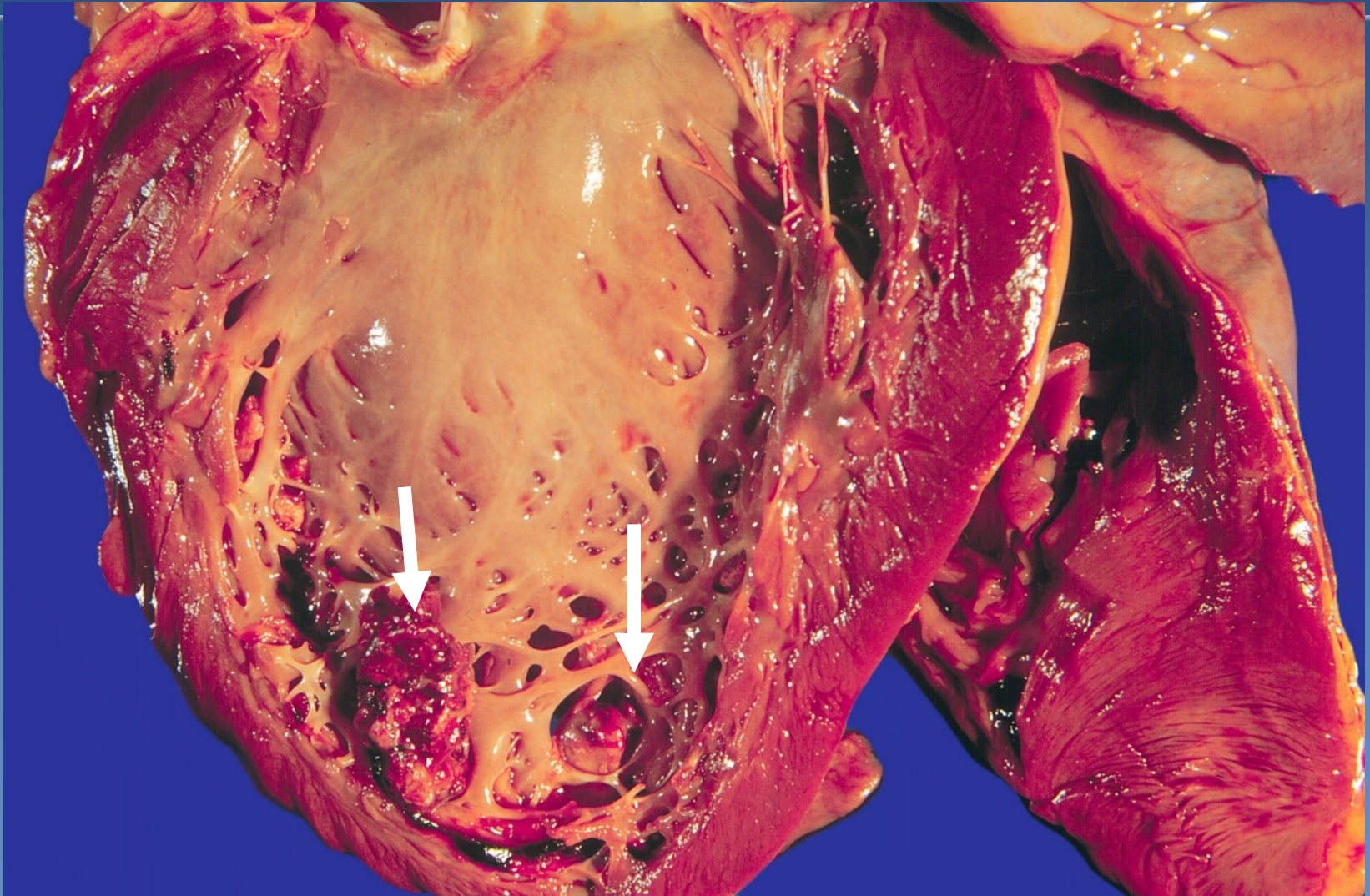
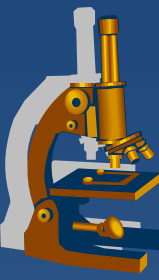
- internal $\frac{1}{4}$ až $\frac{1}{2}$ of LV wall
- collateral blood flow, incomplete obstruction, shorter ischemia



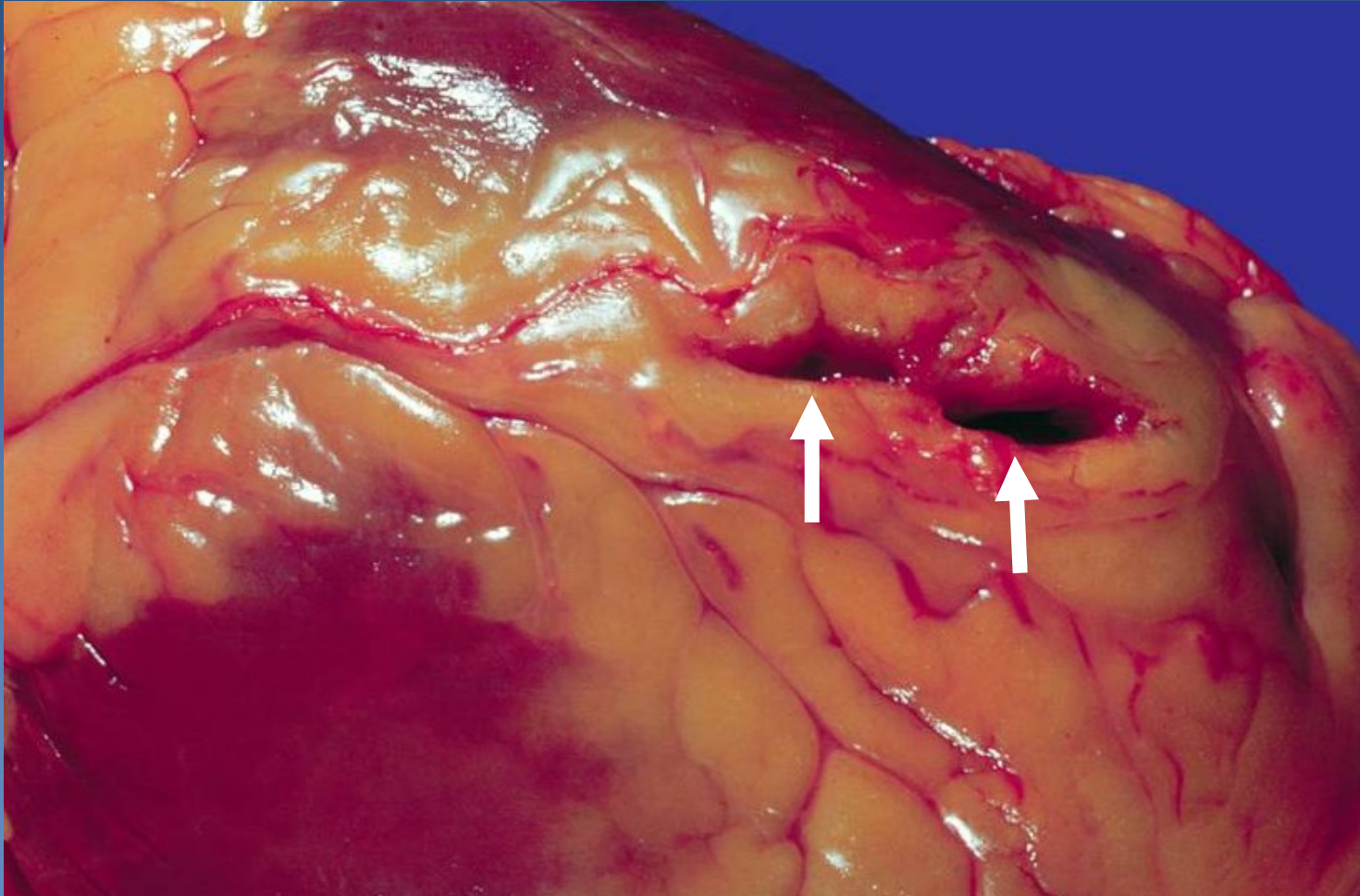
MI complications

- 1. sudden death (arrhythmia)**
- 2. cardiogenic shock (contractile dysfunction)**
- 3. pericarditis epistenocardiaca**
-> sero-fibrinous inflammation
- 4. mural thrombosis**
-> embolism into systemic circulation (-> brain, kidney, intestine, spleen infarction)
- 5. ventricular aneurysm**
-> acute – risk of rupture, thrombosis; chronic – LV insufficiency
- 6. cardiac rupture**
-> free wall, septum, : tamponade / acute heart failure
- 7. papillary muscle rupture**
-> valvular incompetence → acute heart failure

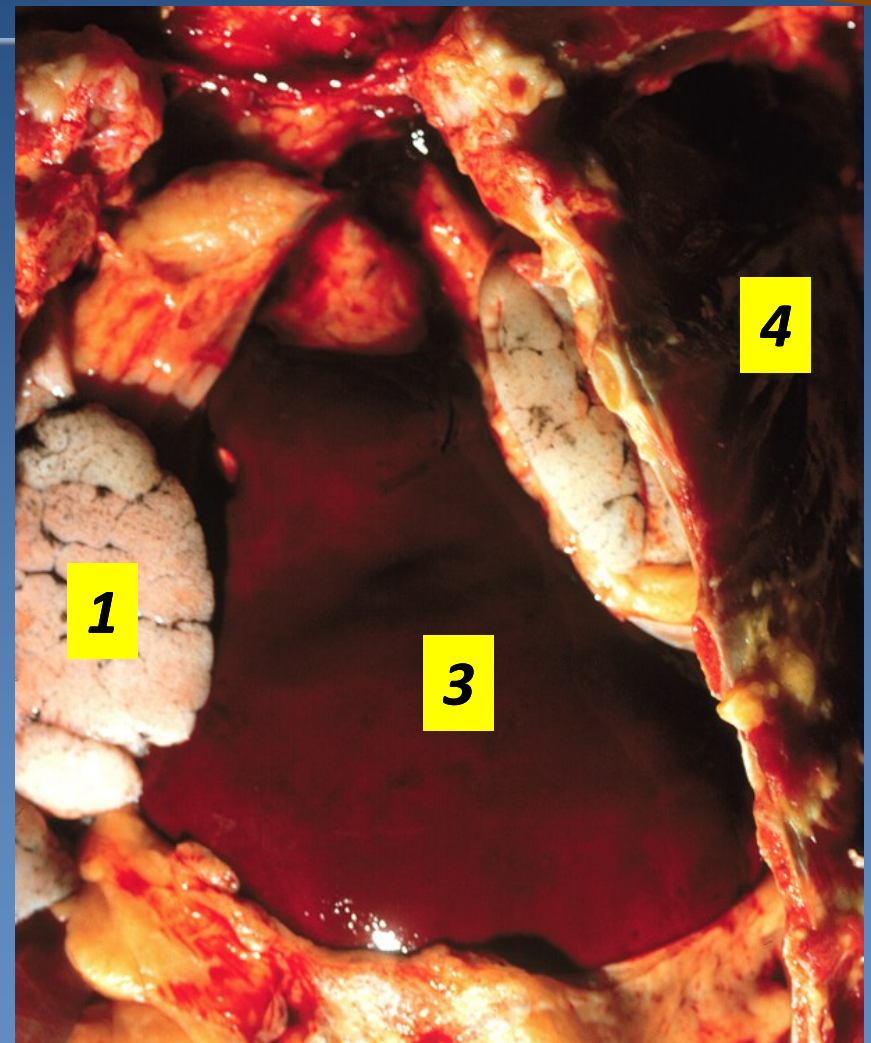
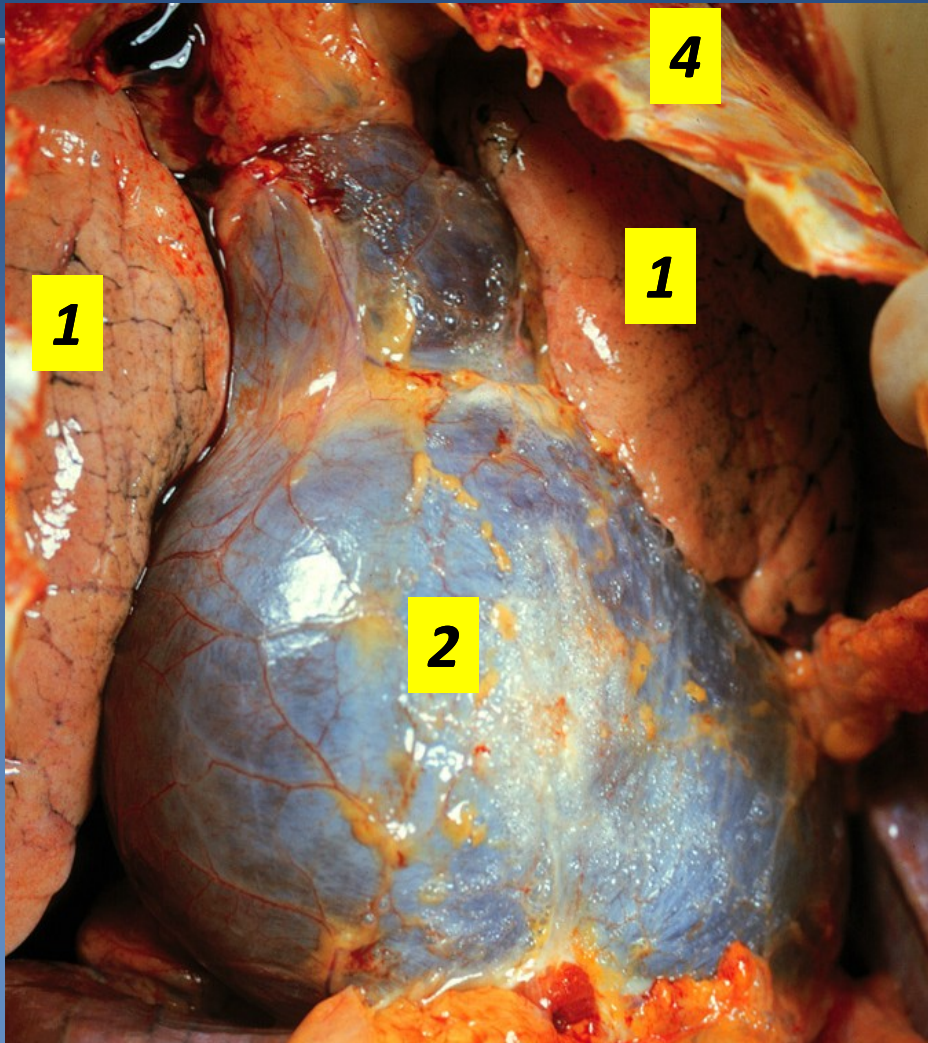
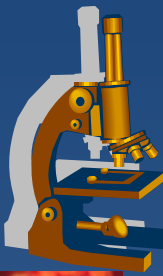
MI – mural thrombosis



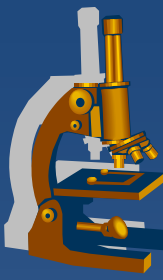
Mi - rupture



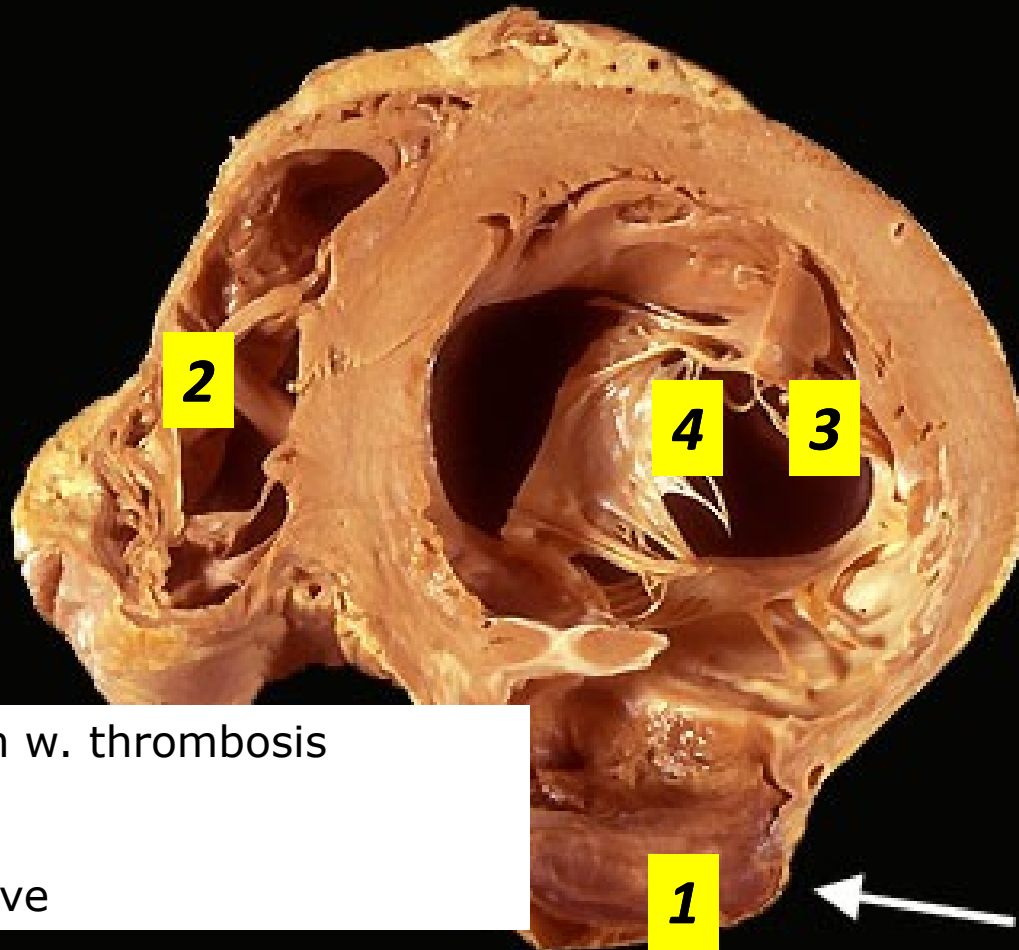
MI – rupture, tamponade



1 lung 2 pericardial sac 3 blood coagulum 4 thoracic wall



MI – LV aneurysm



- 1 aneurysm w. thrombosis
- 2 RV
- 3 LV
- 4 mitral valve

Chronic ischemic heart disease (IHD)



- ✘ angina pectoris or MI in anamnesis
- ✘ progressive heart failure due to ischemic myocardial damage → LV failure → congestive RV failure
- ✘ heart hypertrophy + dilatation, myofibrosis and/or post-MI scars
- ✘ multiple coronary arteries with significant AS stenosis
- ✘ imminent risk of MI, sudden cardiac death due to arrhythmia, heart failure

Sudden cardiac death



= unexpected death from cardiac causes, without preexisting symptoms or within 1 hr of the onset of symptoms

✗ most commonly due to lethal arrhythmia (ventricular fibrillation, asystole)

✗ sudden collapse without signs of acute MI

✗ other causes:

⇒ *dissecting/ruptured aortic aneurysm*

⇒ *pulmonary thromboembolism*

⇒ *massive intracerebral haemorrhage*

⇒ *heritable conditions incl. anatomic, electrical – channelopathies*

Endocardial / valvular diseases



- ✘ endocarditis

 - ⇒ *infectious or immune-mediated endocardial inflammation*

- ✘ degenerative diseases

 - ⇒ *calcific aortic (rarely mitral) stenosis, mitral valve prolapse, annular and marginal sclerosis*

- ✘ endocrine diseases

 - ⇒ *carcinoid syndrome*

- ✘ nonbacterial thrombotic endocarditis (in debilitated patients)

Infective endocarditis



- ✗ commonly by highly virulent microorganisms
 - ⇒ *Strep. pyogenes, Strep. pneumoniae, Staph. aureus, ... ev. fungi*
- ✗ subacute IE – less virulent microorganisms
 - ⇒ *viridans streptococci*
- ✗ predisposition:
 - ⇒ *deformed valve, bioprosthesis, postcatethrization, i.v. drug addicts*
- ✗ bacteremia - endocardial damage by bacteria - trombosis = infective vegetation

Infective endocarditis



✗ **gross:** friable red-brown mass 0,5-2 cm on leaflets or chordae tendinae, valvular damage incl. ulceration

✗ **micro:**

⇒ *fibrin + bacterial colonies + neutrophils (+ granulation tissue)*

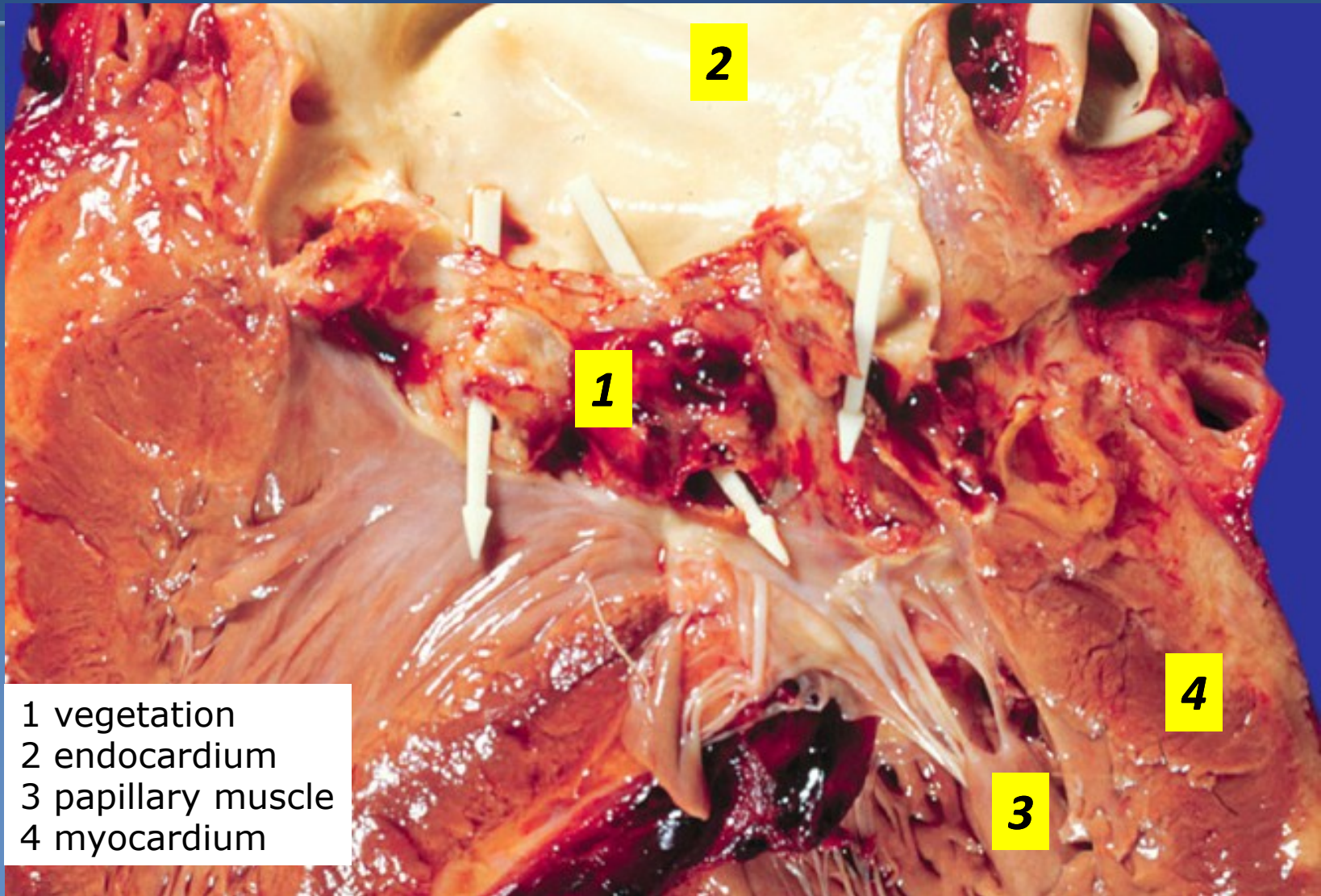
⇒ *Inflammation/ necrosis of the valve tissue*

✗ **complications:**

⇒ *acute: valvular damage, myocarditis + abscess, pyemia, thrombembolism*

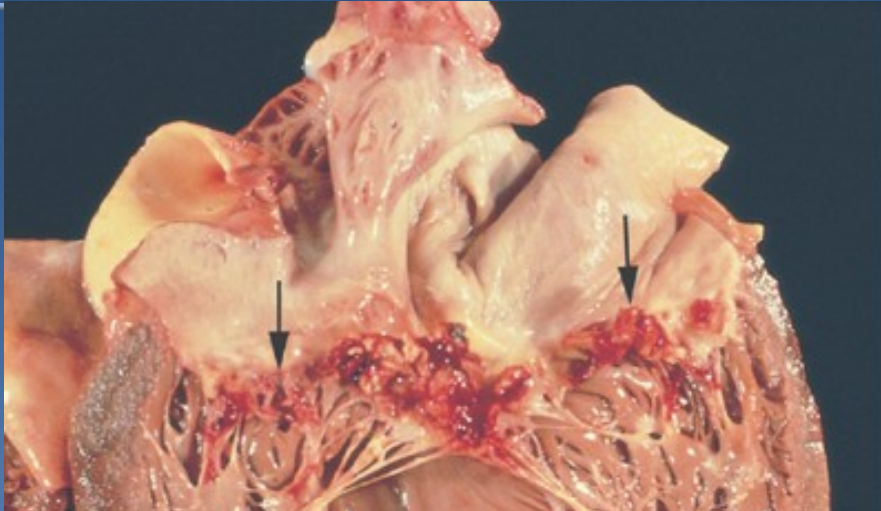
⇒ *chronic valvular disease*

Infective endocarditis- valve destruction

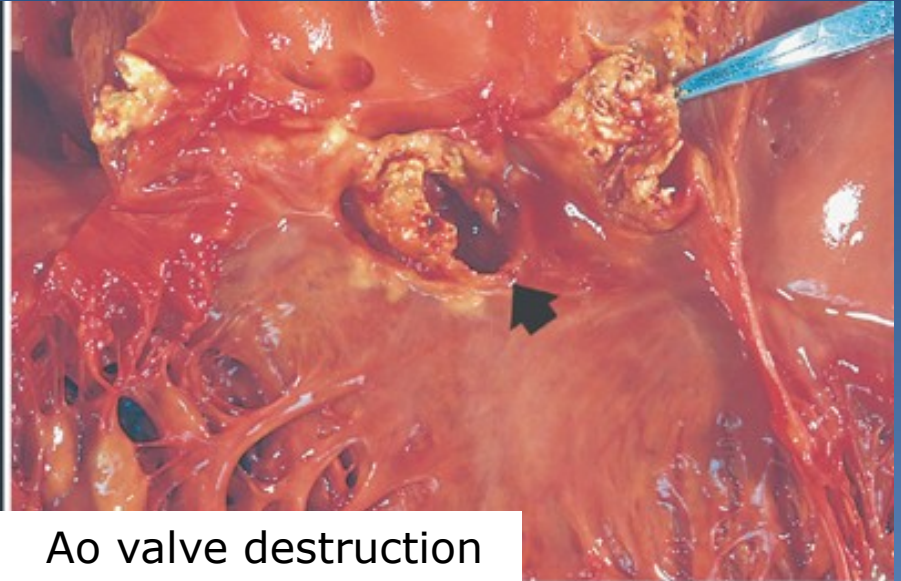


- 1 vegetation
- 2 endocardium
- 3 papillary muscle
- 4 myocardium

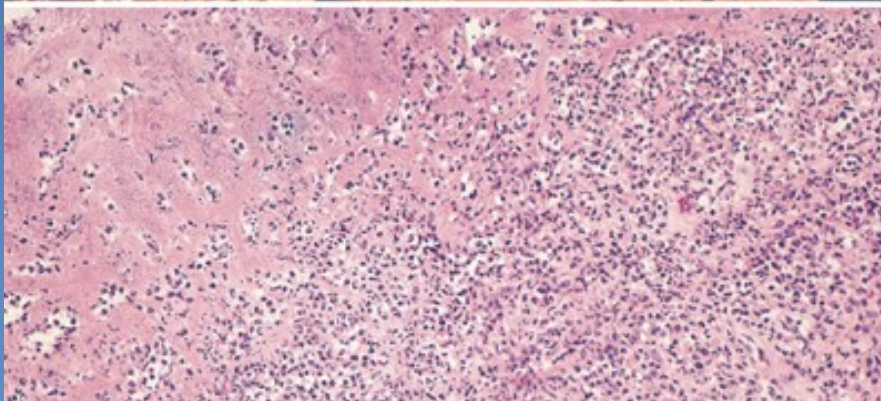
Infective endocarditis



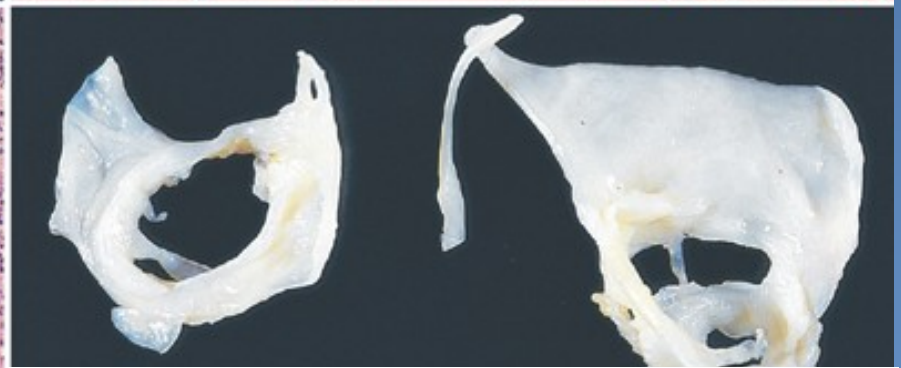
Mi vegetations



Ao valve destruction

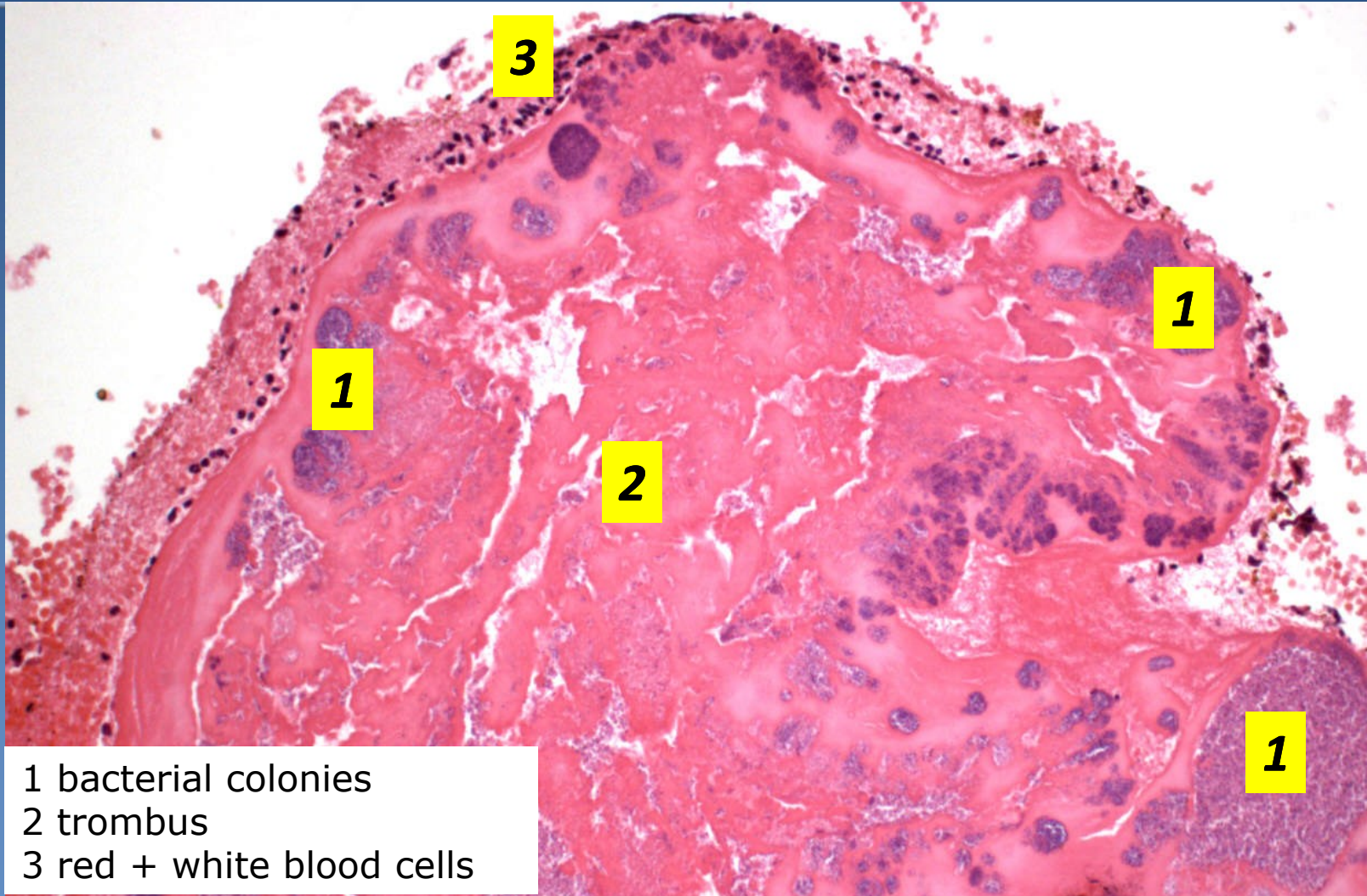


purulent inflammation



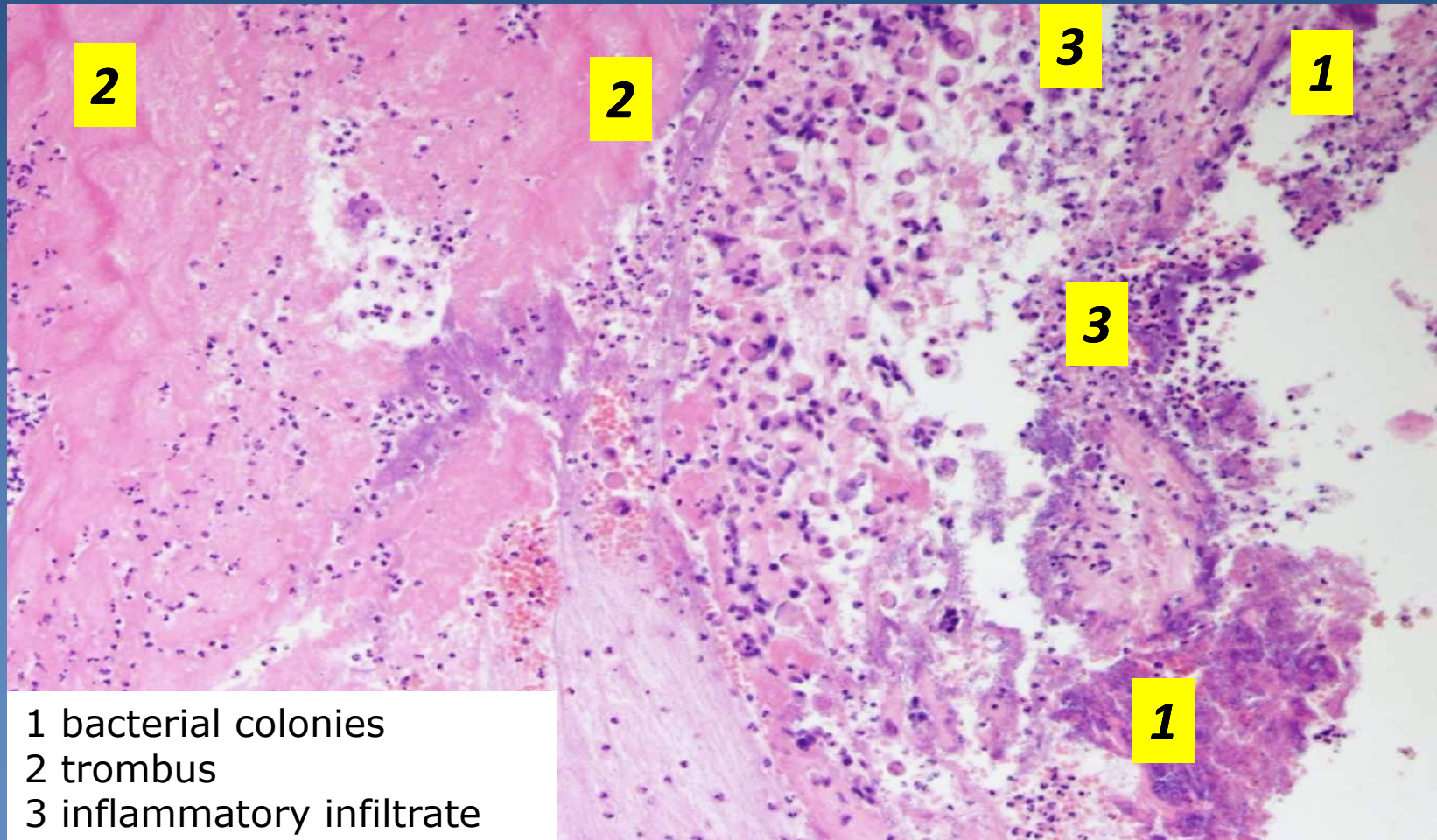
IE repair (Mi fenestration without vegetations)

Infective endocarditis - vegetations

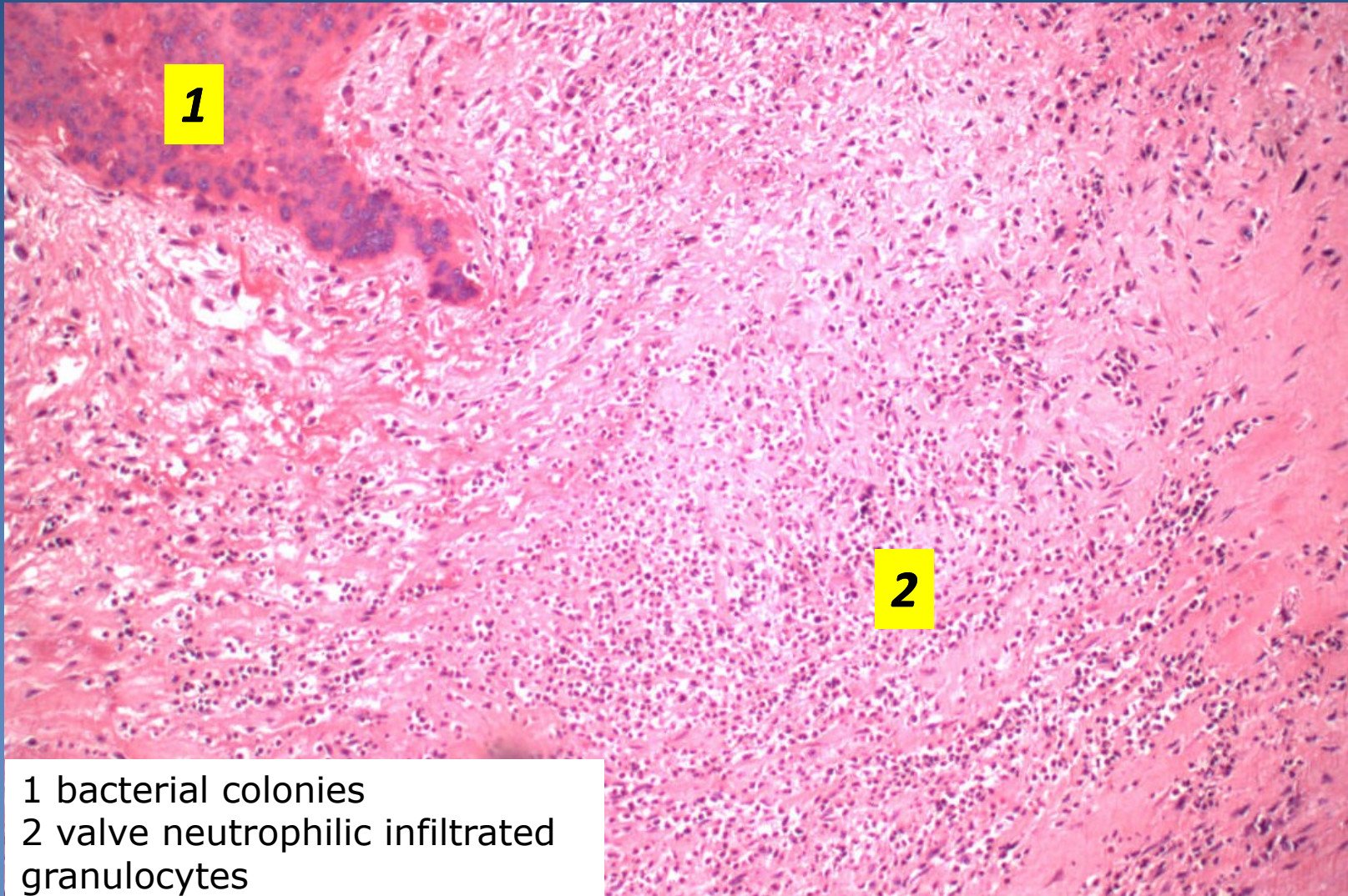
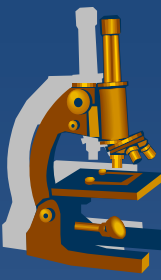


- 1 bacterial colonies
- 2 trombus
- 3 red + white blood cells

Infective endocarditis - vegetations



Infective endocarditis - vegetations

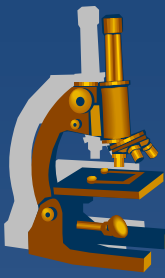


1

2

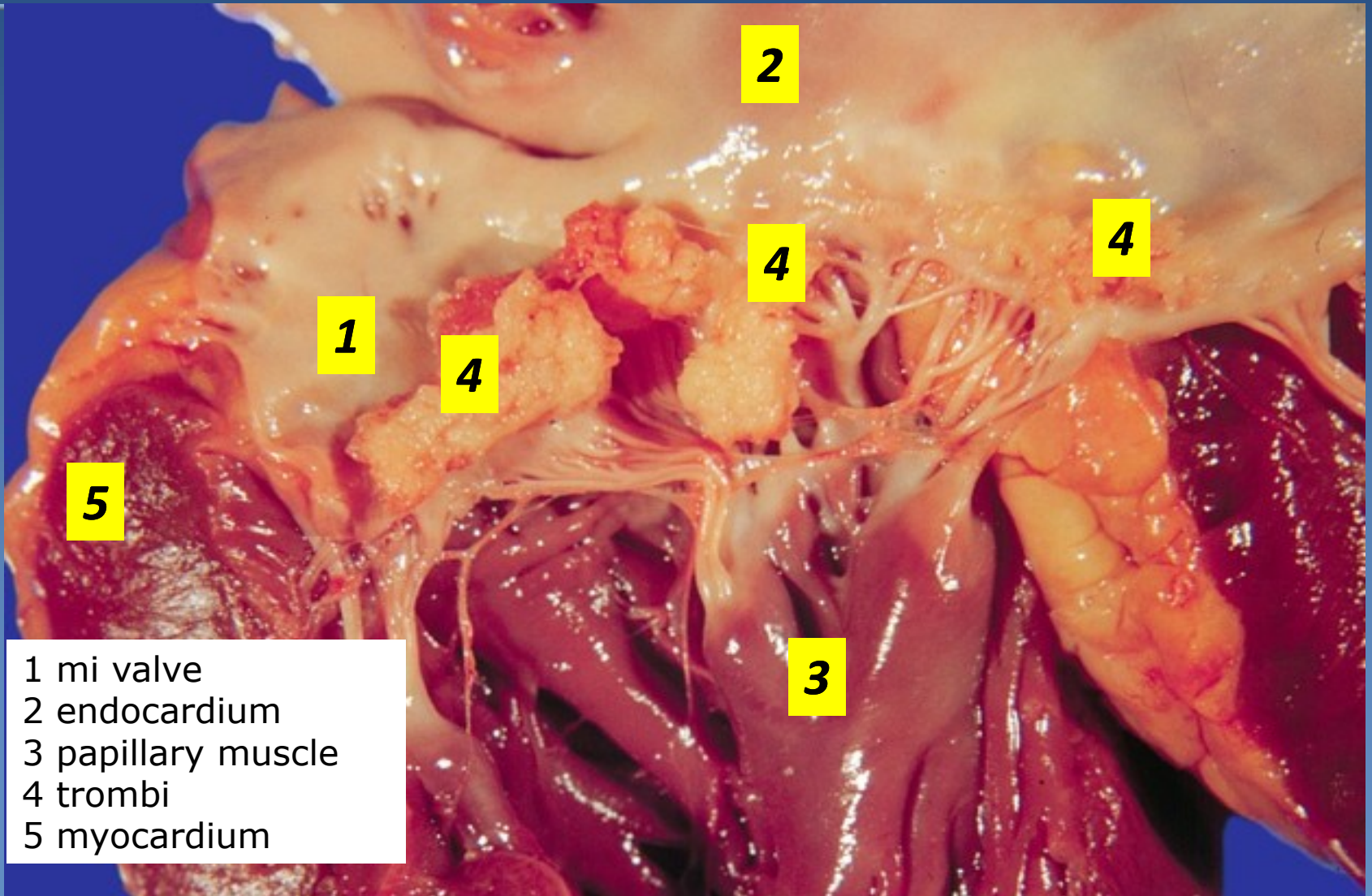
1 bacterial colonies
2 valve neutrophilic infiltrated
granulocytes

Non-bacterial thrombotic endocarditis



- ✗ **sterile** vegetations due to **hypercoagulative state** \Rightarrow concurrent venous thrombosis and lung embolization
- ✗ **in generalized malignancies**, chronic nephropathy with uremia, COPD etc.
- ✗ mostly on **mitral valve** (normal)
- ✗ micro: verrucous vegetations (single or multiple), 1-5 mm, bland thrombi
- ✗ possible source of **emboli**

Non-bacterial thrombotic endocarditis



- 1 mi valve
- 2 endocardium
- 3 papillary muscle
- 4 trombi
- 5 myocardium

Rheumatic fever, rheumatic heart disease



× acutenon-purulent, **imune-mediated** systemic poststreptococcal inflammation (cross-reactive antibodies)

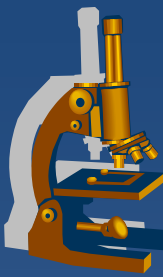
× acute stage: **PANCARDITIS**

⇒ *fibrinous pericarditis + myocarditis with Aschoff bodies (foci of **fibrinoid necrosis** + inflammatory reaction + verrucous endocarditis (small depositions of fibrin along the closure lines of Ao a Mi valves)*

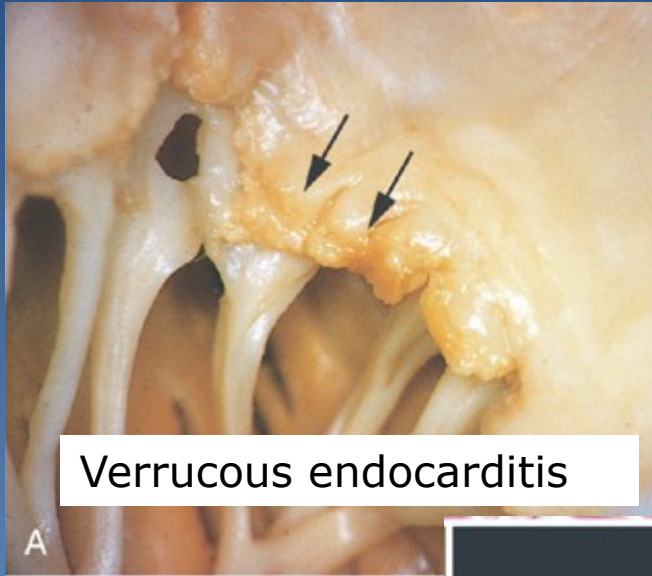
⇒ *acute endocarditis commonly recurrent*

× chronic stage:

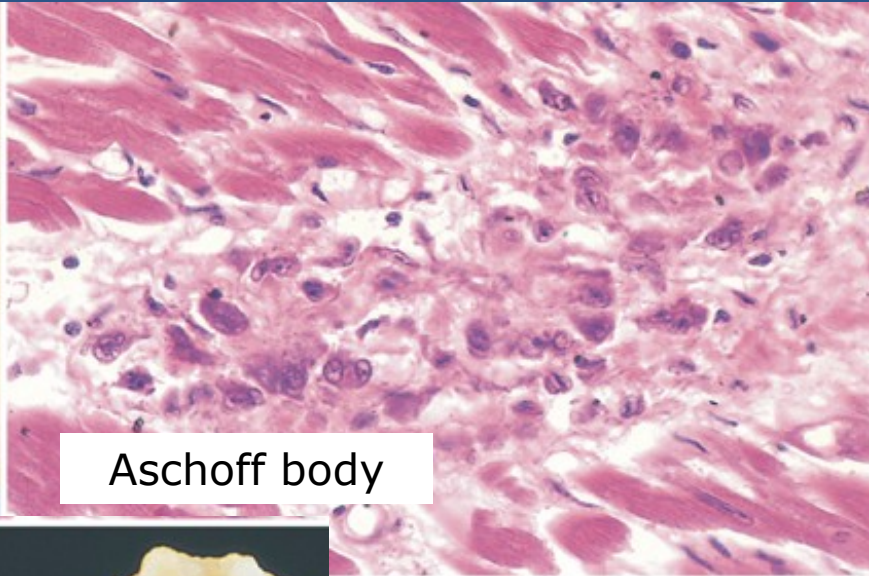
⇒ *diffuse fibrous thickening + distortion, commissural fusion → dystrophic calcification - stenosis + incompetence)*



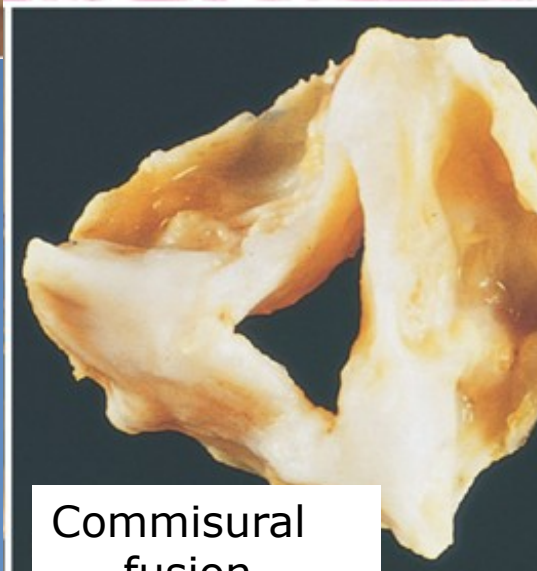
rheumatic heart disease



Verrucous endocarditis

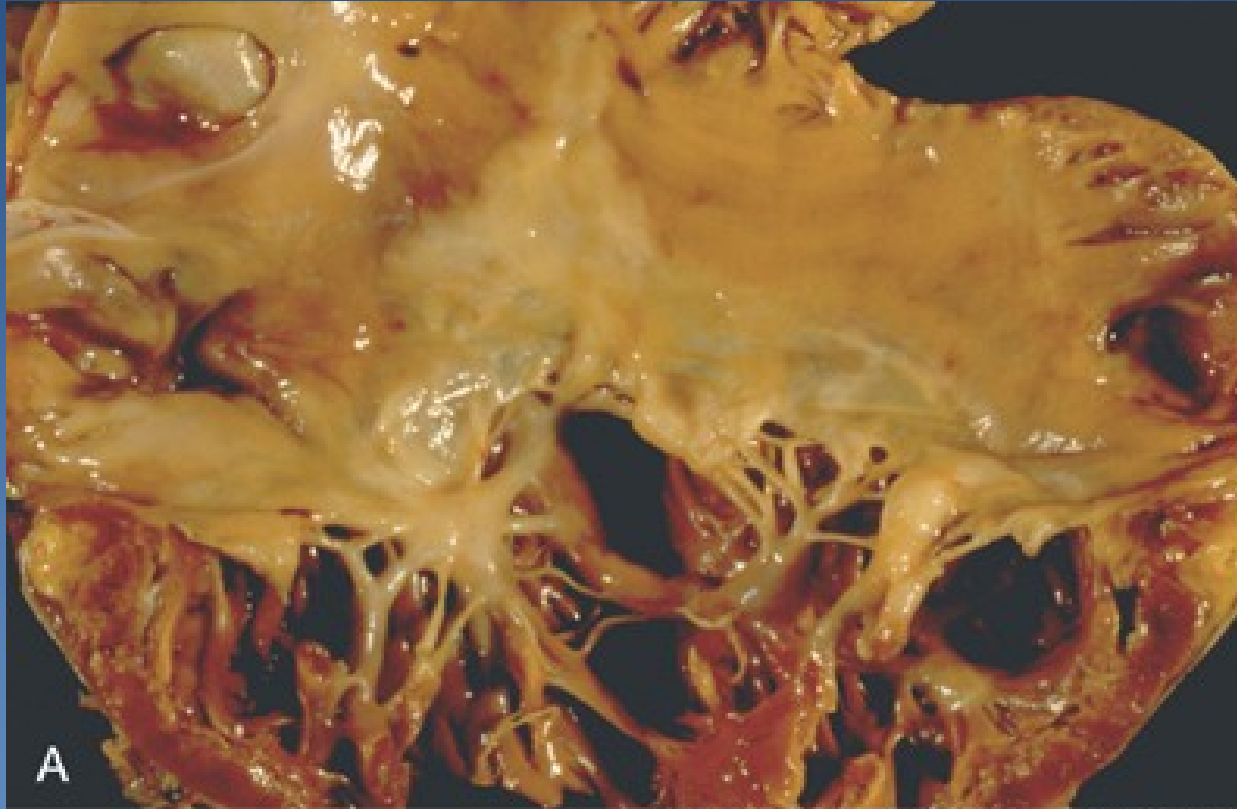


Aschoff body



Commissural fusion

Carcinoid syndrome



endocardial fibrous plaquelike thickenings – RA, RV

Myocarditis



- ✗ myokardial inflammatory damage without ischemia

- ✗ **gross:**
 - ⇒ *cardiac dilatation, flabby, mottled myocardium*

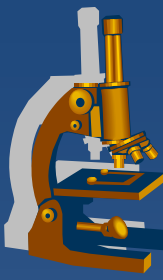
- ✗ **micro:**
 - ⇒ *inflammatory infiltrate (according etiology) + cardiomyocyte regressive changes incl. necrosis*

- ✗ **etiology:**
 - ⇒ viruses, rickettsia, chlamydia, bacteria (diphtheria, sepsis), fungi, protozoa (toxoplasmosis), helminths (trichinosis)
 - ⇒ immune-mediated (*drug hypersensitivity, postviral, rheumatic fever, rejection*)
 - ⇒ *ionising radiation*
 - ⇒ unknown (*giant-cell myocarditis*)

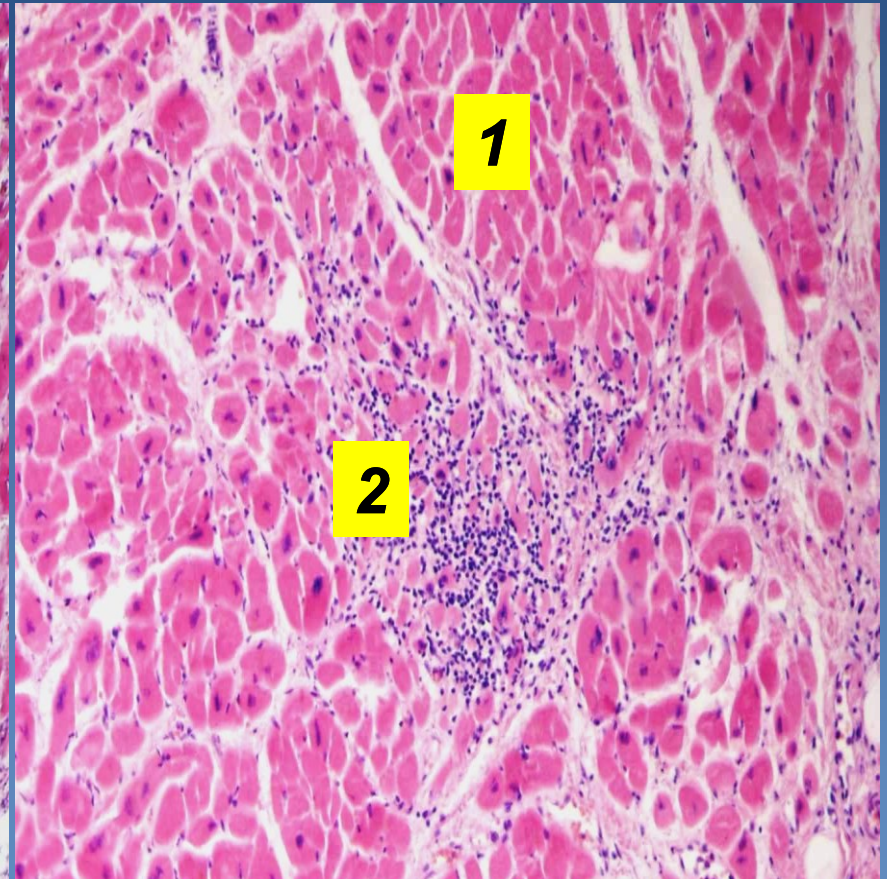
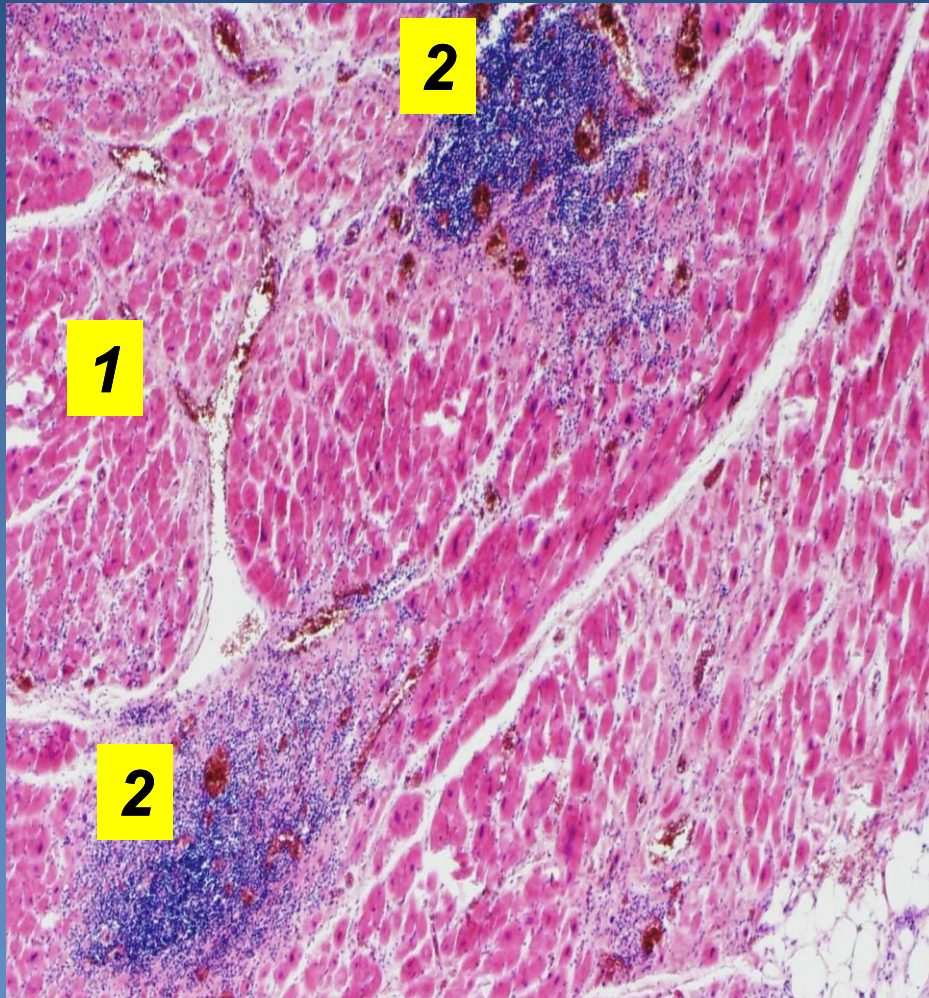
Viral myocarditis



- ✗ *Coxsackie, parvovirus B19, influenza, EBV, CMV, HIV*
- ✗ inflammatory infiltrate: T-cells mostly
- ✗ after acute attack commonly autoimmune-mediated cardiomyocytes destruction and fibrosis → dilated cardiomyopathy

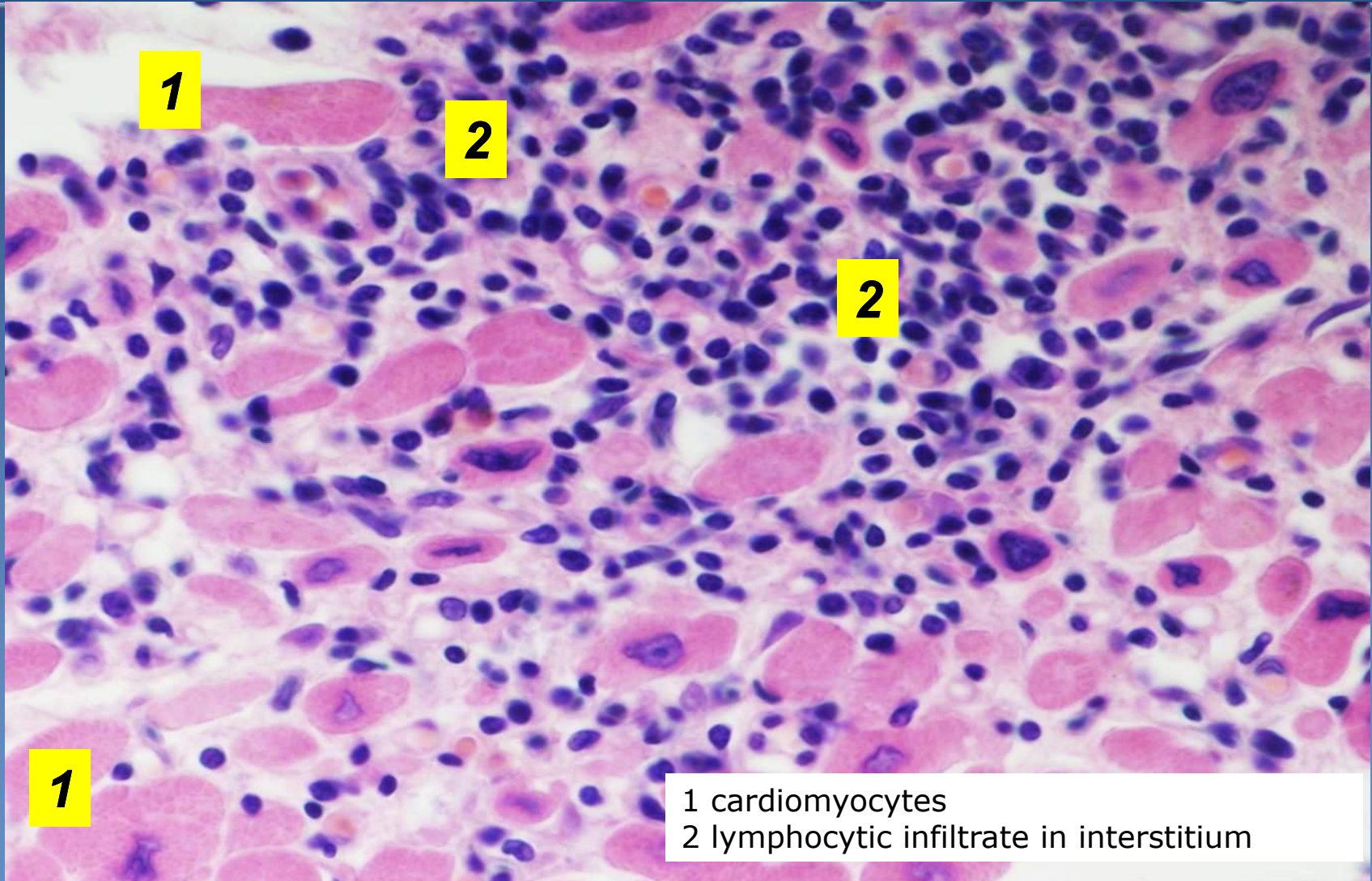
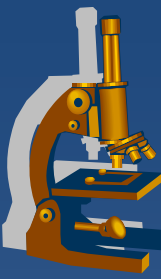


Viral myocarditis



1 cardiomyocytes
2 lymphocytic infiltrate in interstitium

Viral myocarditis



1

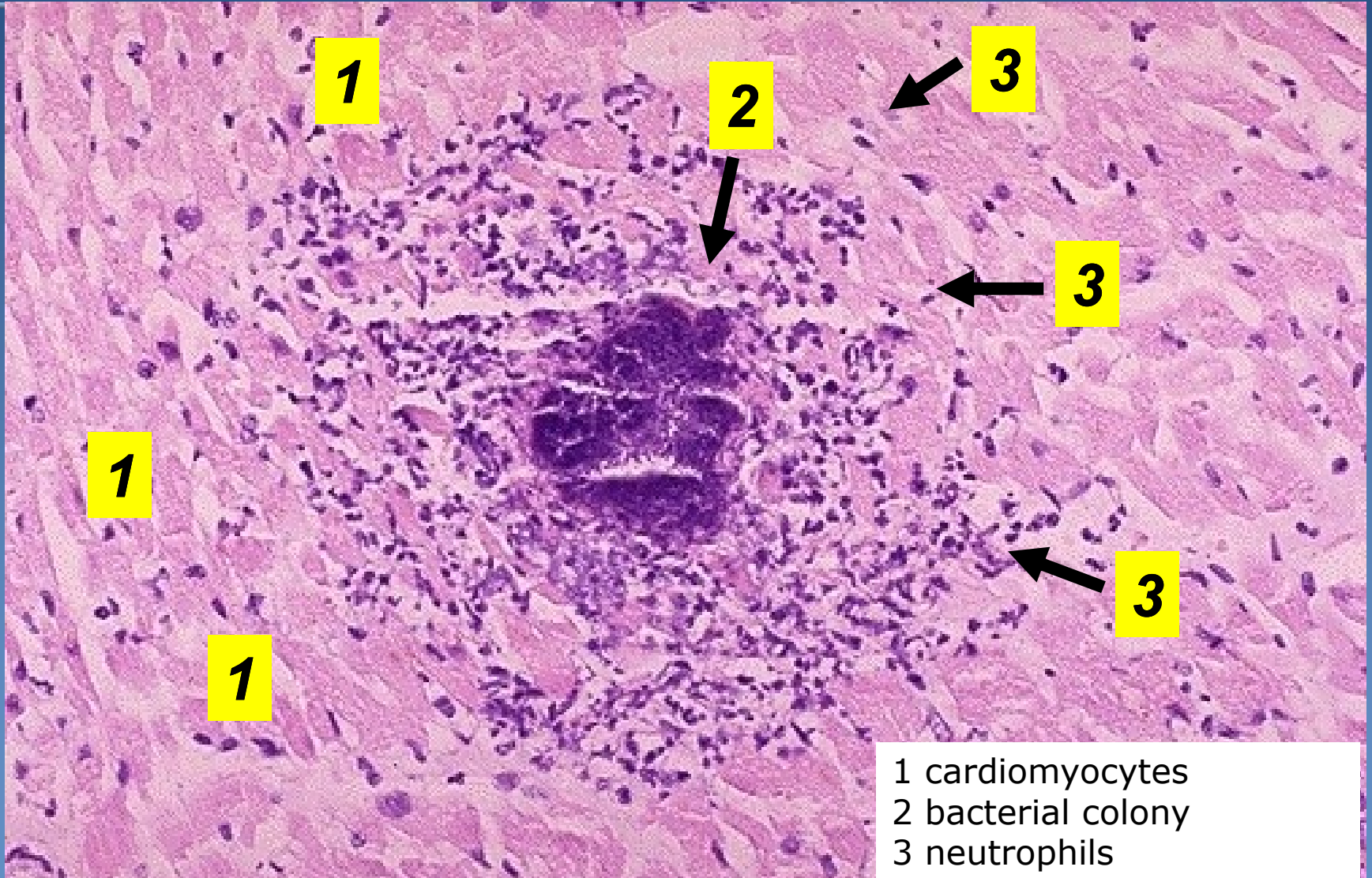
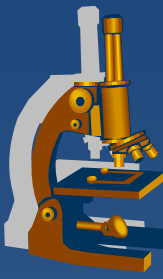
1

2

2

1 cardiomyocytes
2 lymphocytic infiltrate in interstitium

Septic myocarditis



Cardiomyopathies



= heart disease due to myocardial abnormality, with heart dysfunction
diagnosis after exclusion of IHD, valvular disease, congenital d. or hypertension

✗ heterogenous group of disorders:

⇒ dilated (DCM)

– dilatation + hypertrophy, ↓ LV contraction, possible mural thrombosis; 20–50% genetic (AD);
alcoholic, peripartum, myocarditis...

⇒ hypertrophic (HCM)

– massive LV hypertrophy, 100% genetic, diastolic dysfunction, histologic „disarray“

⇒ restrictive cardiomyopathy

– diastolic dysfunction, ↓ of compliance - ↓ filling, myocardial stiffness

⇒ specific CM

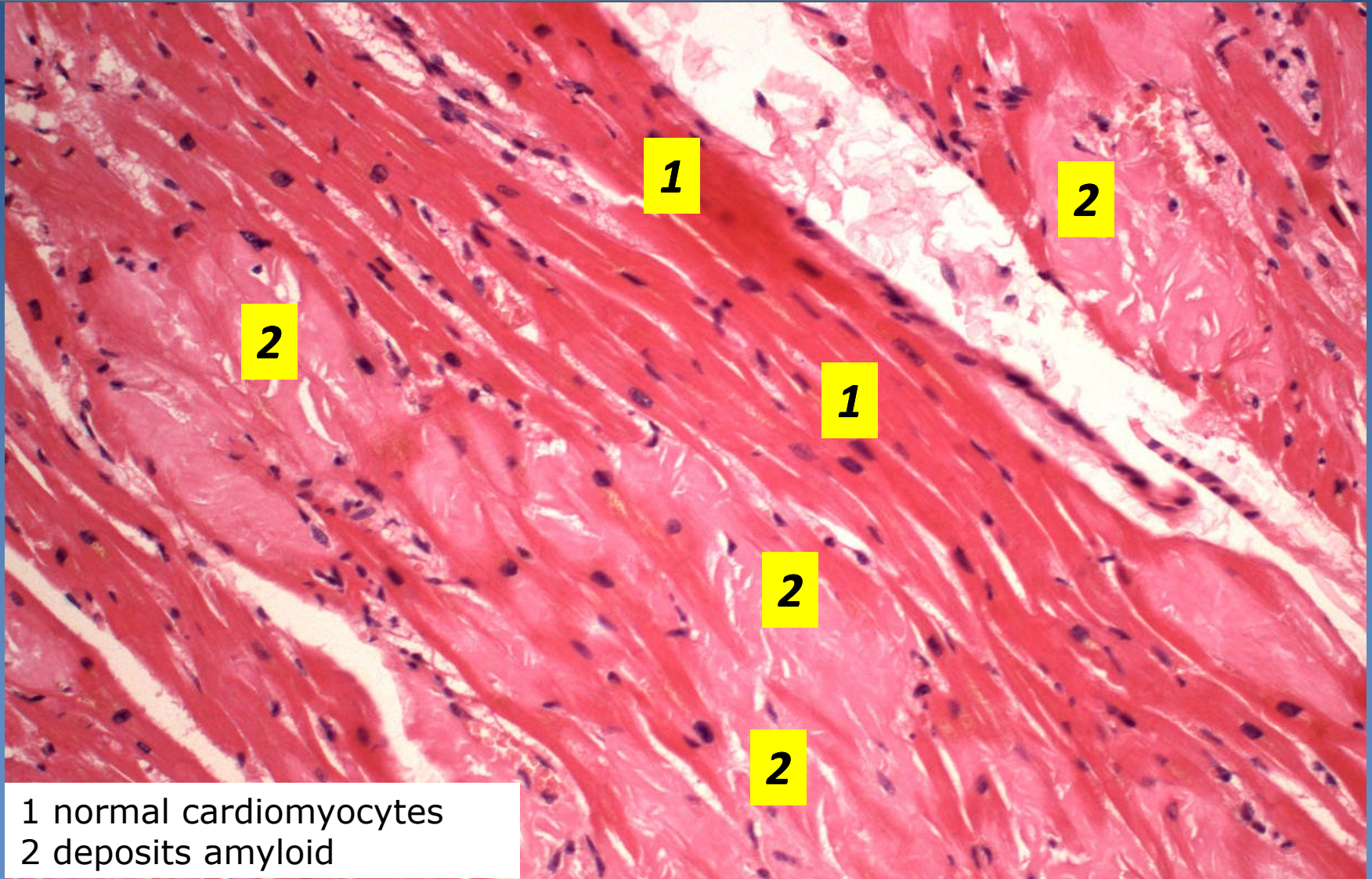
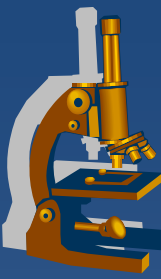
– Duchenne muscle dystrophy, toxic (drugs), endocrine d., metabolic d. (hemochromatosis, amyloidosis, glycogenosis, ...)

Myocardial amyloidosis



- ✗ local x systemic (mostly AL amyloidosis)
- ✗ senile amyloidosis
 - ⇒ *atrial + ventricles; amyloid protein = prealbumin (transthyretin)*
- ✗ *isolated atrial amyloidosis*
 - ⇒ *amyloid protein = atrial natriuretic peptide*
- ✗ **gross**: consistency normal - firm (rubbery)
- ✗ **micro**: variable amyloid deposits v interstitium and vessels, Congo red + polarization

Senile cardiac amyloidosis



1 normal cardiomyocytes
2 deposits amyloid

Pericardial pathology



1) Pericardial effusion

- transudate in congestive heart failure or hypoproteinemia, slow (up to 500ml – pericardial dilatation)

2) haemopericardium

– wall rupture in MI or aortic root dissection → **fatal cardiac tamponade**

diastolic filling restriction

Pericardial pathology



3) Inflammatory exudate in pericarditis:

a) *non-infectious*

– pericarditis epistenocardiaca, uremic, post-operative, SLE, Dressler sy (post-MI autoimmune)

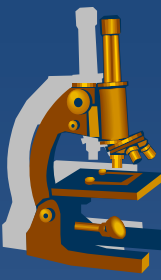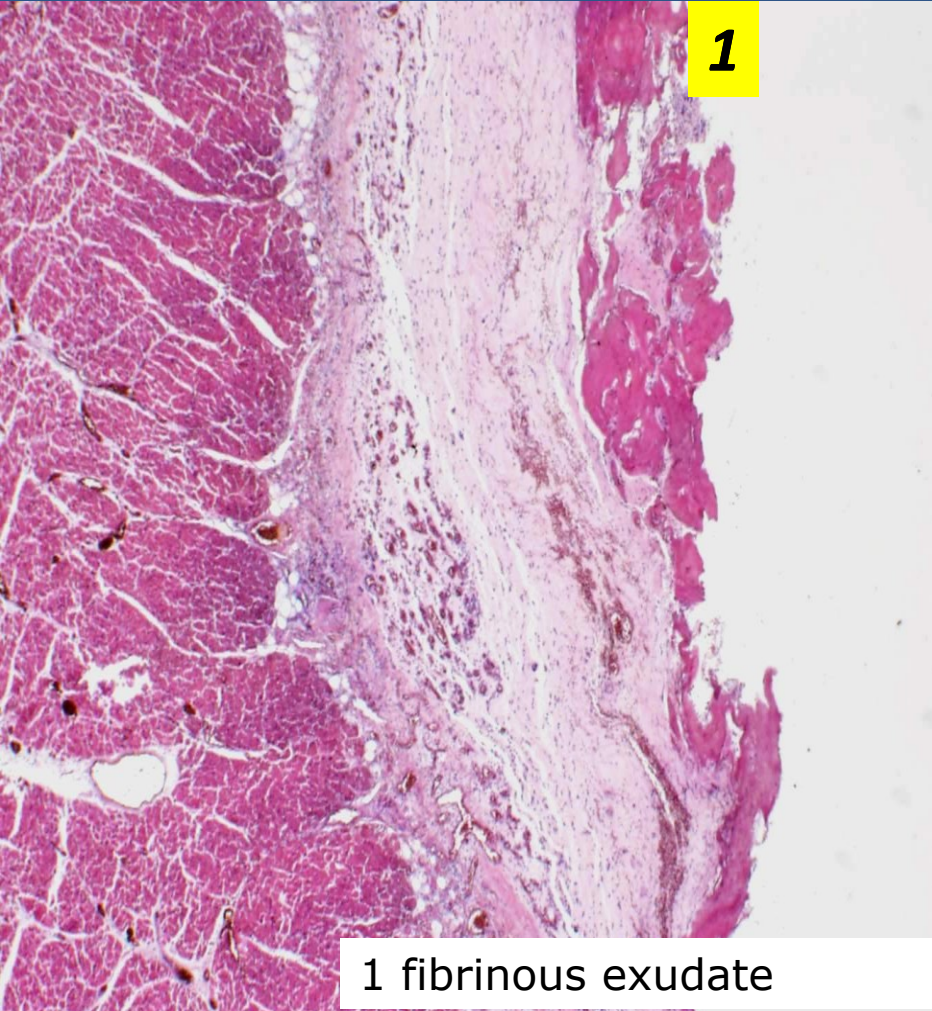
b) *infectious*

– *haematogenous, direct spread, lymphogenous; variable agents*

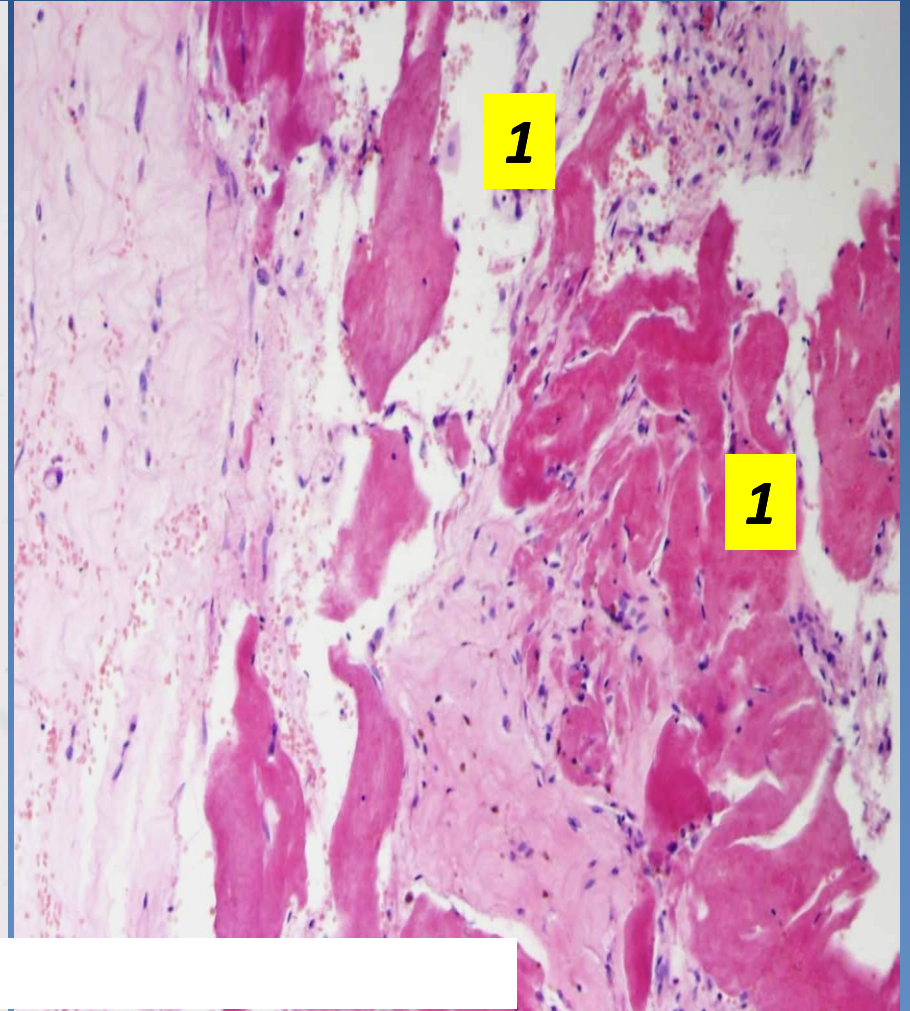
c) *idiopatická*

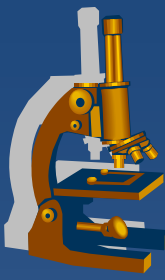
Pozn. hojení – serózní a část. i fibrinózní exsudát → vstřebávání x zbývající fibrin se organizuje → **perikardiální adheze /konstriktivní perikarditida** (pericarditis petrosa) → omezuje plnění komor

fibrinous pericarditis

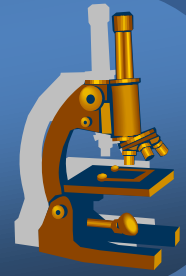


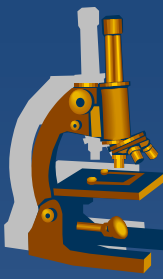
1 fibrinous exudate



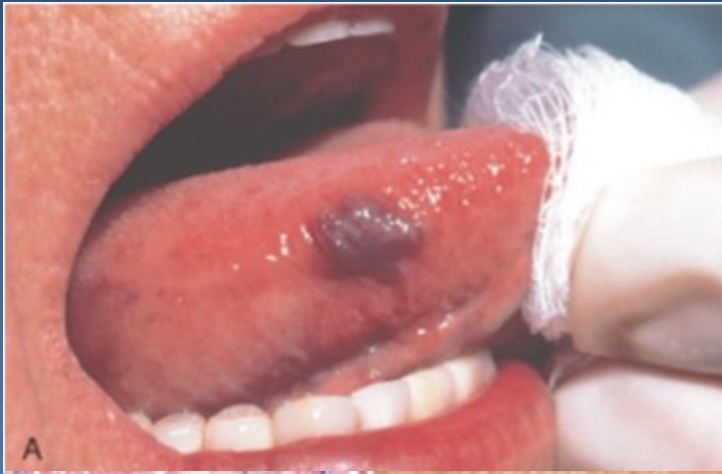

Cardiovascular tumors

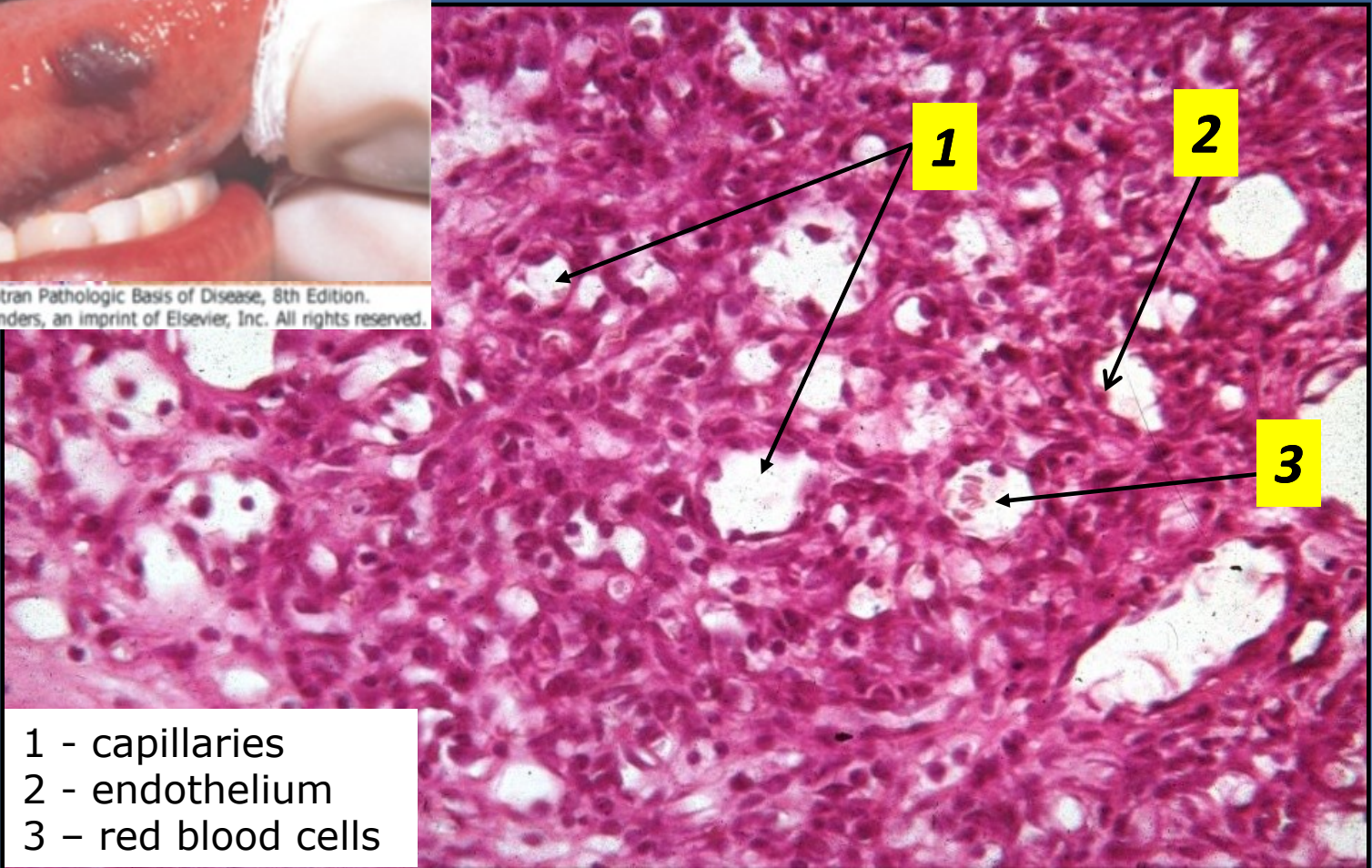




Capillary hemangioma



Kumar et al: Robbins & Cotran Pathologic Basis of Disease, 8th Edition.
Copyright © 2009 by Saunders, an imprint of Elsevier, Inc. All rights reserved.



- 1 - capillaries
- 2 - endothelium
- 3 - red blood cells

Cavernous hemangioma

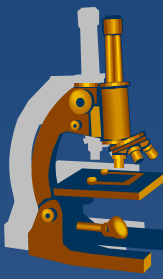


xgross:

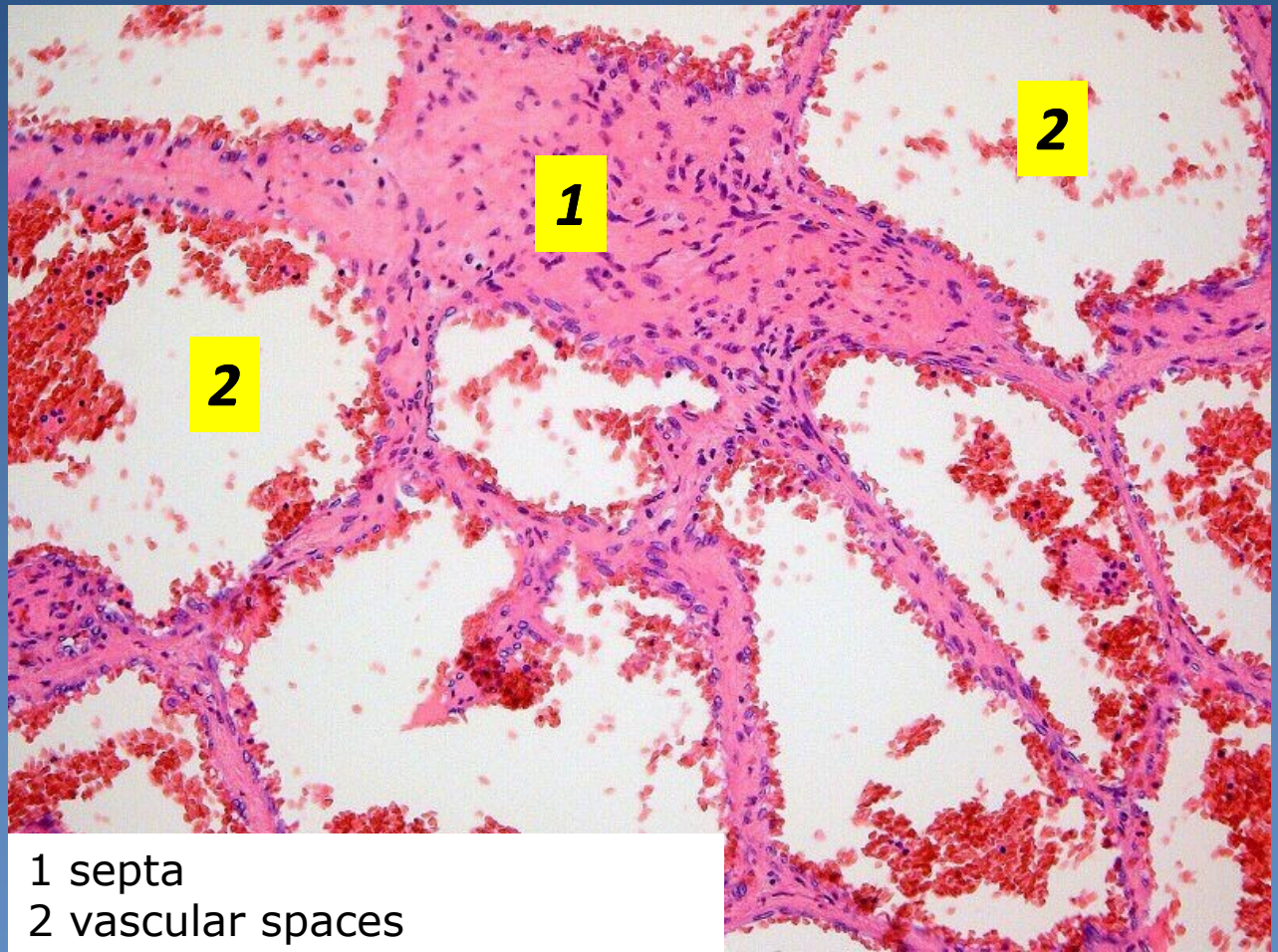
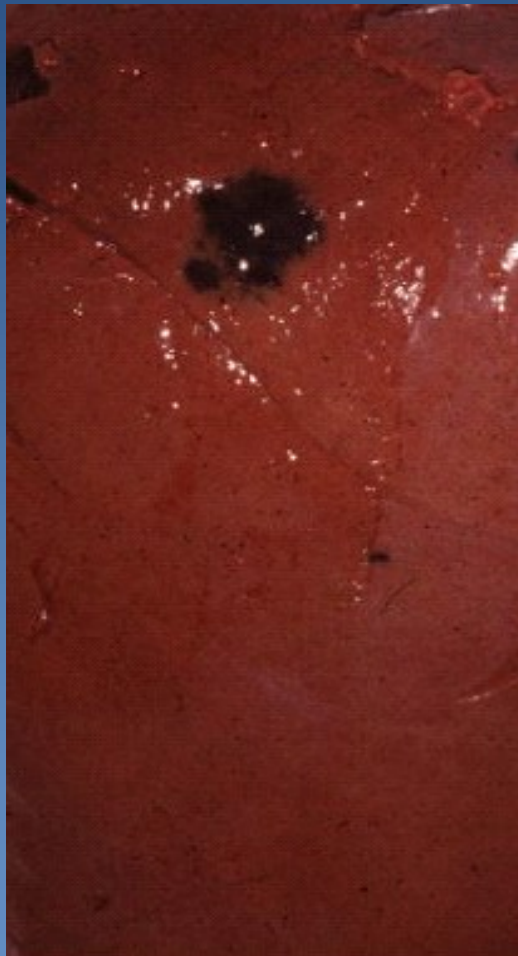
- ⇒ red -blue focus (nodular)
- ⇒ possible large size (-15 cm)
- ⇒ liver, spleen, skin; commonly multiple

xmicro:

- ⇒ large blood-filled vascular spaces divided by fibrous septa

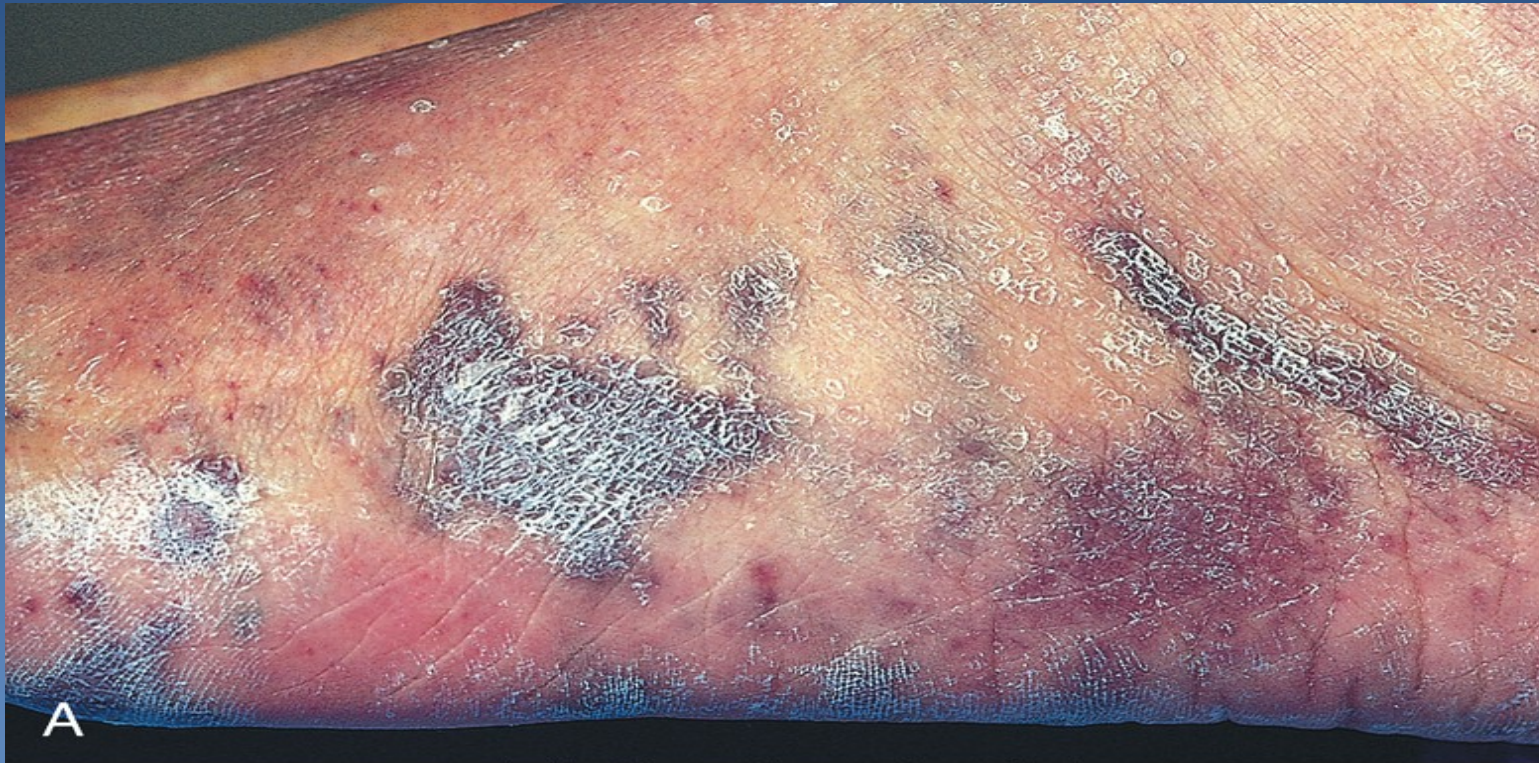

Cavernous hemangioma



1 septa
2 vascular spaces

Kaposi sarcoma



Kumar et al: Robbins & Cotran Pathologic Basis of Disease, 8th Edition.
Copyright © 2009 by Saunders, an imprint of Elsevier, Inc. All rights reserved.

Kaposi sarcoma



× classic form

- ⇒ *chronic*
- ⇒ *in mediterranean or jewish origin*
- ⇒ *usually (90%) confined to skin*

× endemic

- ⇒ *south-african children*
- ⇒ *lymphadenopathic*
- ⇒ *aggressive*

× immunosuppression (transplant) associated

- ⇒ *– internal organs in 50%*

× AIDS associated

Kaposi sarcoma

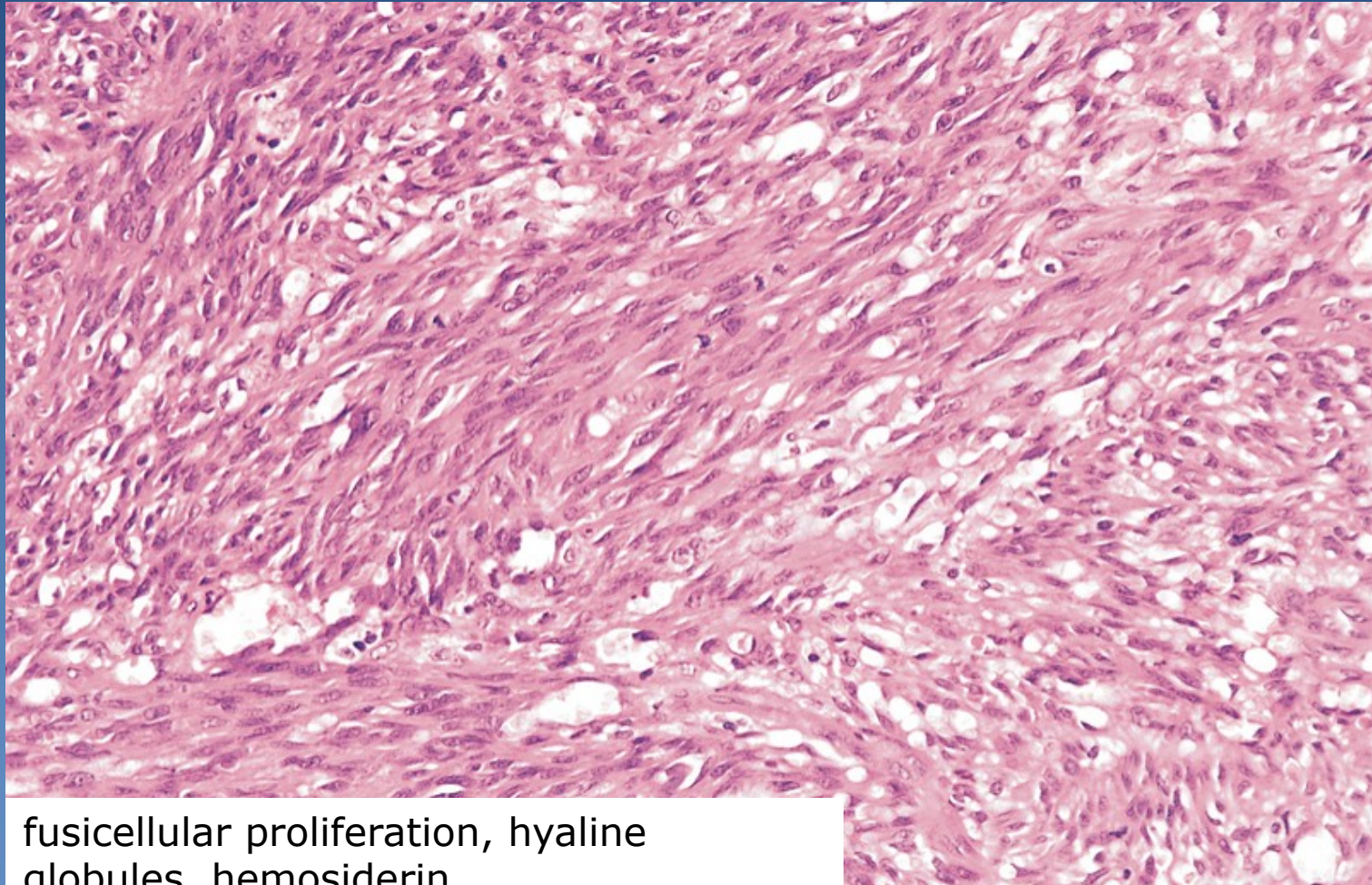


- × HHV-8
- × hyperproliferation of endothelial cells
- × prevention of apoptosis

- × **gross:**
 - ⇒ *red to purple patches*
 - ⇒ *raised plaques*
 - ⇒ *nodules*

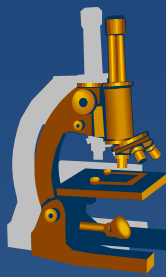
- × **micro:**
 - ⇒ *irregular blood spaces*
 - ⇒ *plump atypical endothelial cells*
 - ⇒ *perivascular aggregates of spindle cells*

Kaposi sarcoma



fusicellular proliferation, hyaline globules, hemosiderin

se, 8th Edition.
nc. All rights reserved.

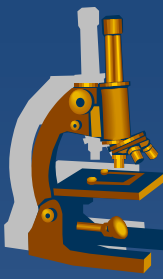


Heart tumors

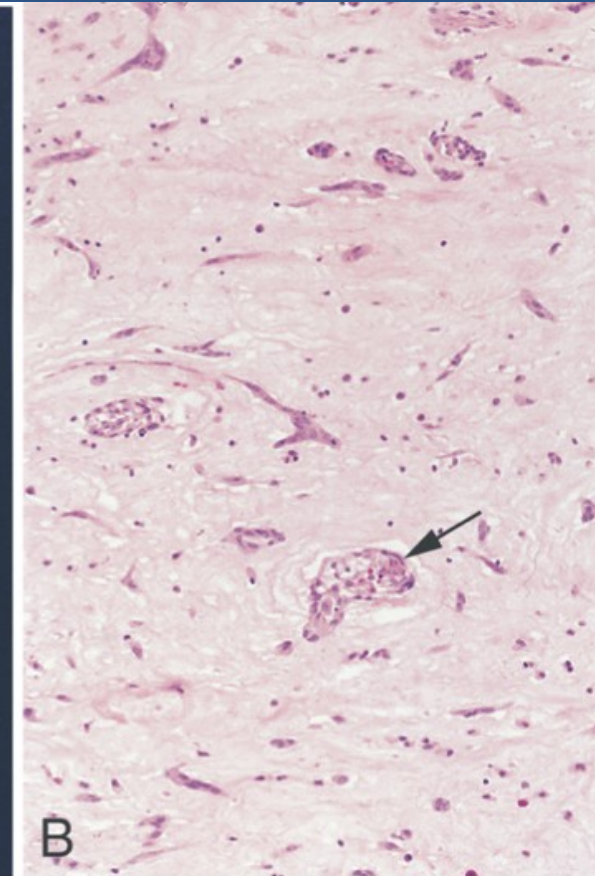
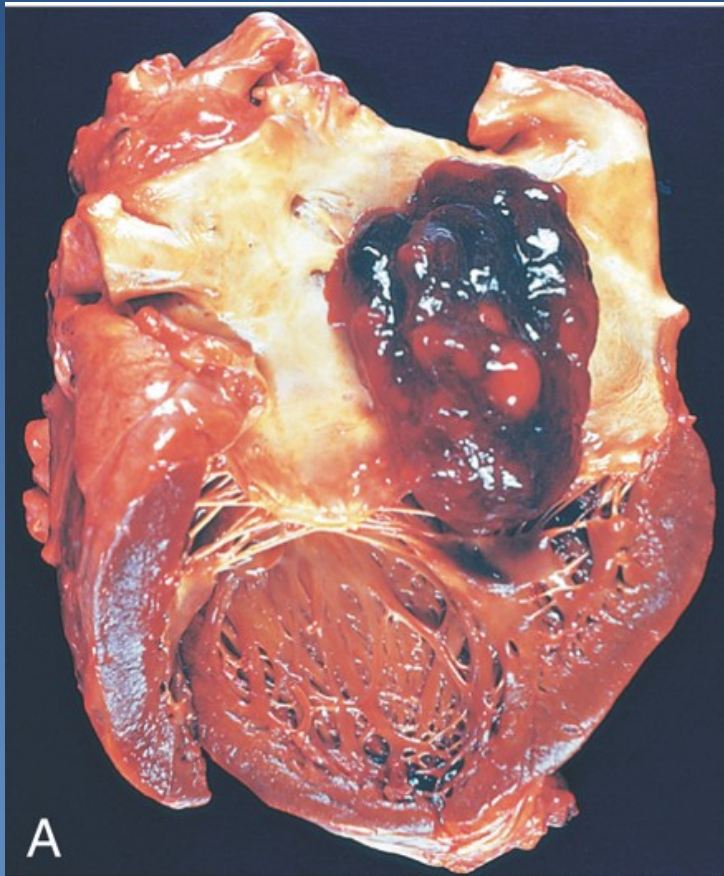
- ✘ primary tumors rare, mostly **benign myxomas**

- ✘ malignant mesenchymal (sarcomas)
 - ⇒ *leiomyo - , rhabdomyo - , hemangio - , fibrosarcoma*

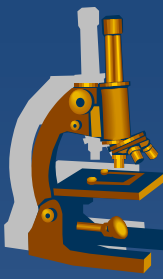
- ✘ secondary tumors
 - ⇒ *20-30 x more common than primary*
 - ⇒ *metastases + infiltrates : lung, breast carcinomas, malignant melanoma, malignant lymphomas and leukemias*
 - ⇒ *direct spread (lung ca, mesothelioma, renal ca)*
 - ⇒ *pericarditis carcinomatosa – hemorrhagic effusion*



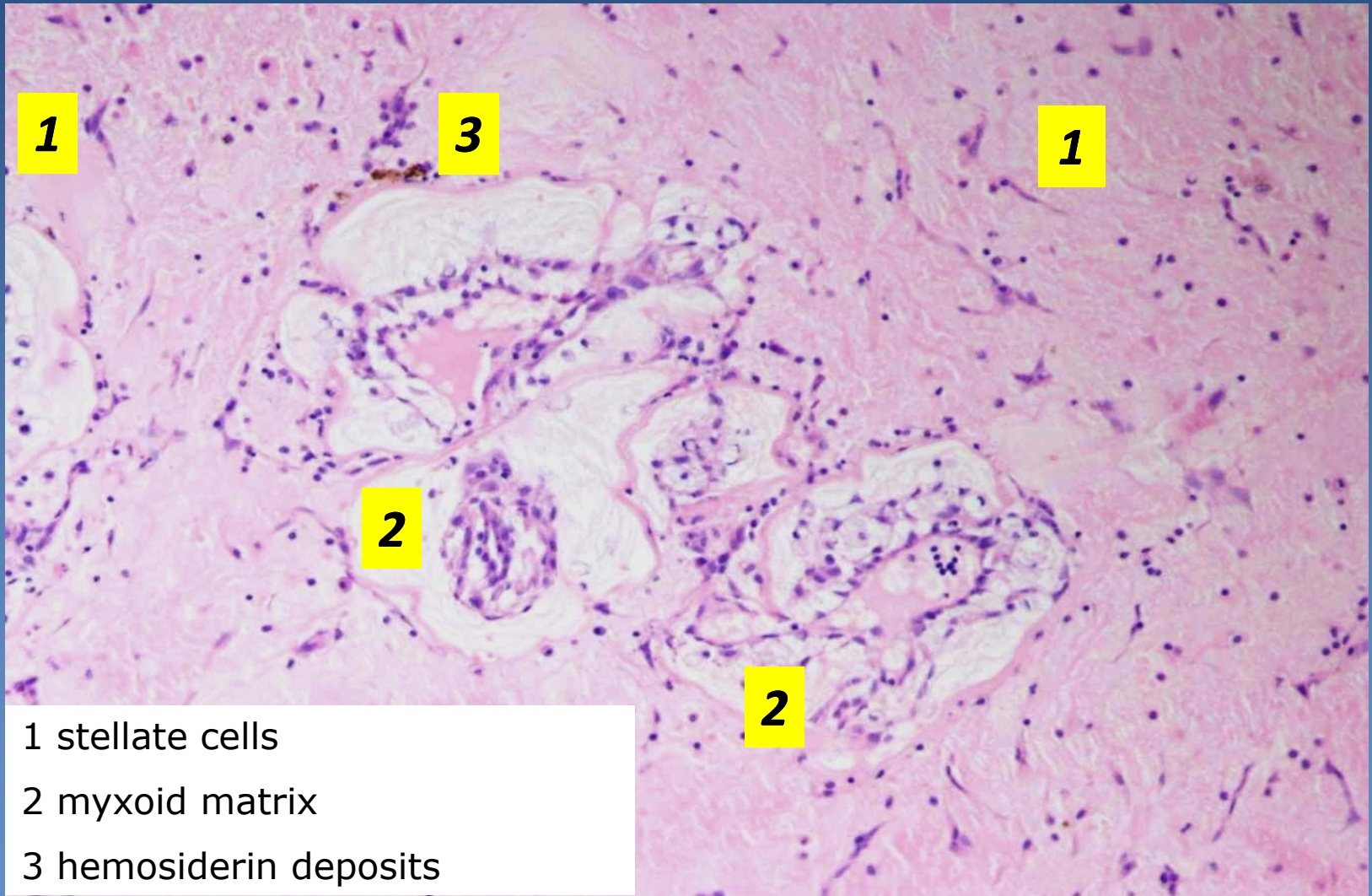
LV myxoma



Kumar et al: Robbins & Cotran Pathologic Basis of Disease, 8th Edition.
Copyright © 2009 by Saunders, an imprint of Elsevier, Inc. All rights reserved.



Myxoma (100x)



1

3

1

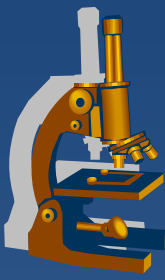
2

2

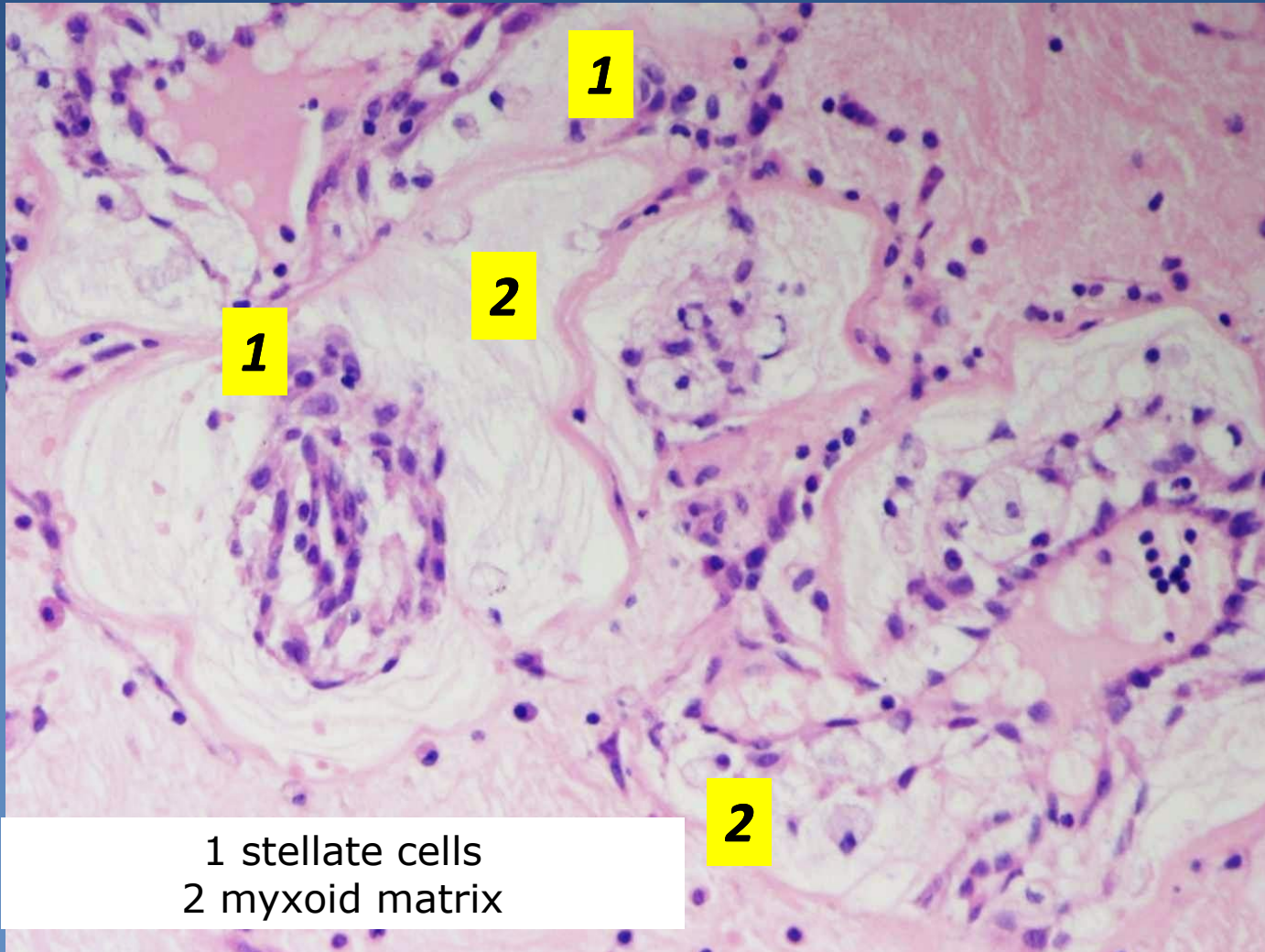
1 stellate cells

2 myxoid matrix

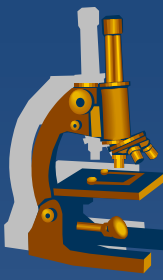
3 hemosiderin deposits



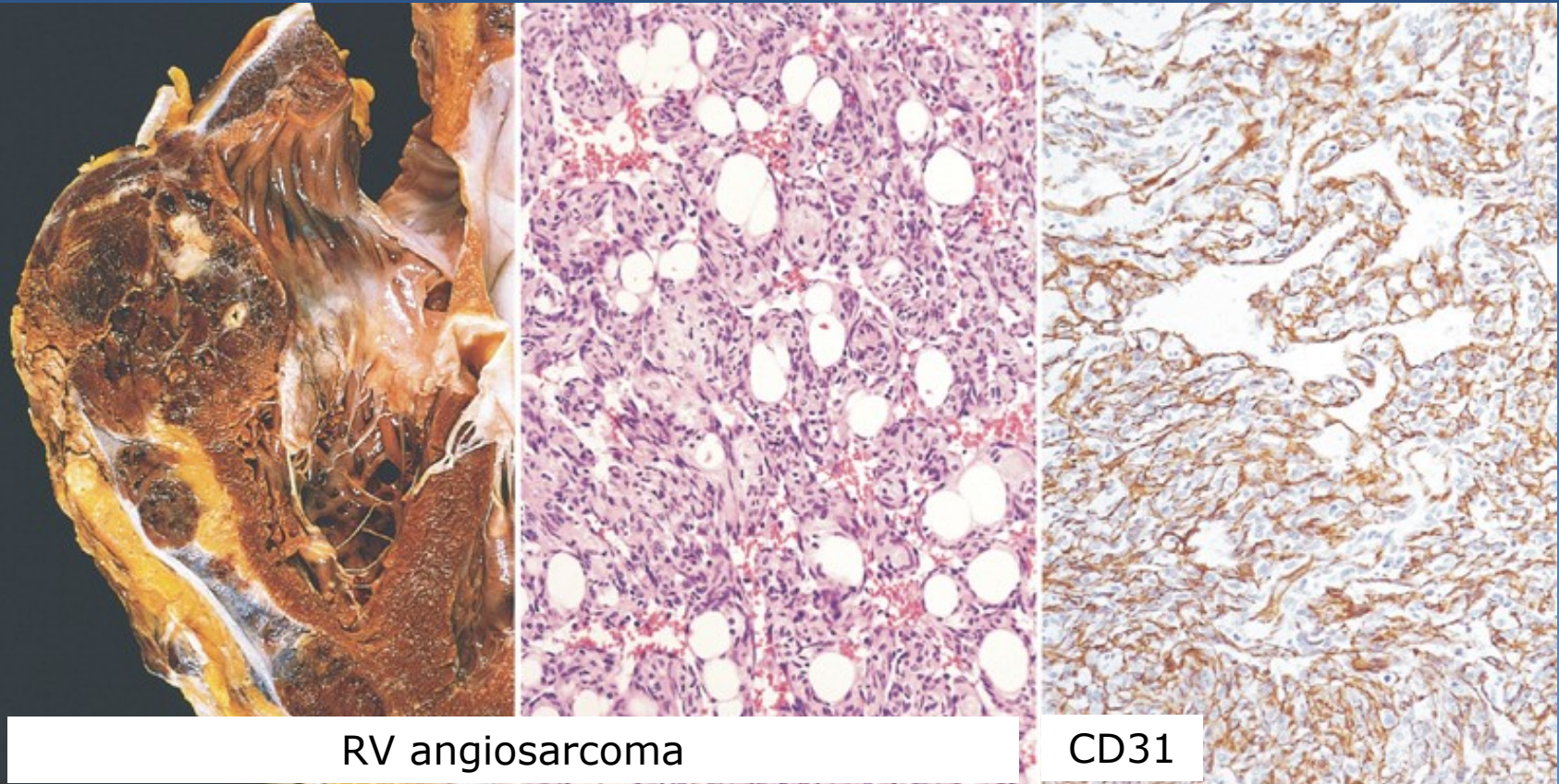
Myxoma (400x)



1 stellate cells
2 myxoid matrix



Angiosarcoma



RV angiosarcoma

CD31

Kumar et al: Robbins & Cotran Pathologic Basis of Disease, 8th Edition.
Copyright © 2009 by Saunders, an imprint of Elsevier, Inc. All rights reserved.

Angiosarcoma

