

CT, MRI AND SONOGRAPHY IN STOMATOLOGY

J.Stulík – Department of radiology and nuclear
medicine

Computed tomography (CT)

- a) Classic CT
- b) Dental Cone Beam CT




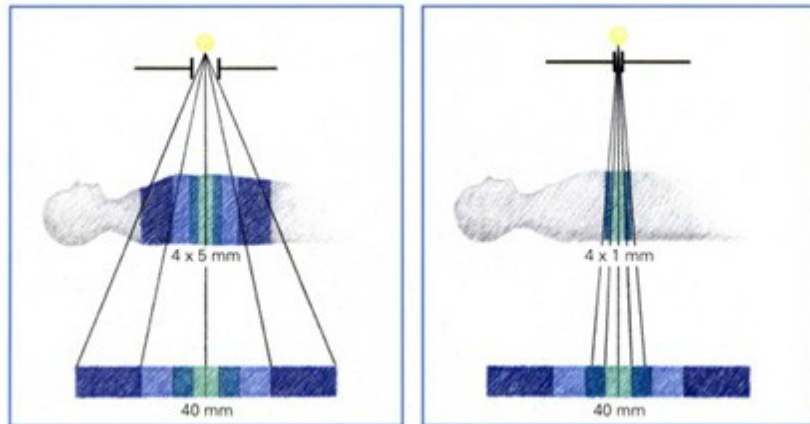
CLASSIC CT

- CT images are acquired while the x-ray tube is rotating 360deg. around the patient
- The x-ray beam is collimated in axial orientation and divergent to encompass the patient's width in the other orientation.
- The intensity of attenuated x-rays emerging from the patient is measured with an array of minute detectors



MULTISLICE CT

- Several rows of detectors each above another
- MS- detector array segmented in z axis, as a mosaic.
- –Allows for simultaneous acquisition of multiple images in scan plane with ONE rotation.

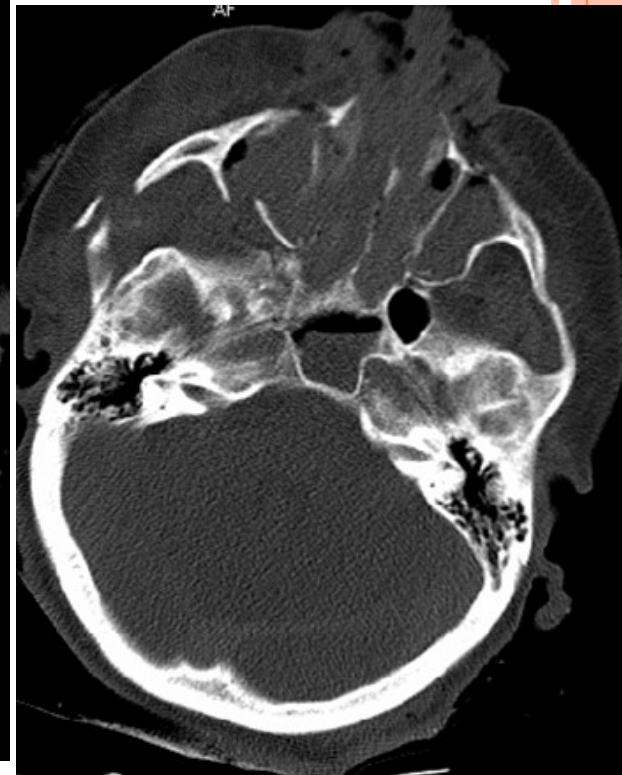
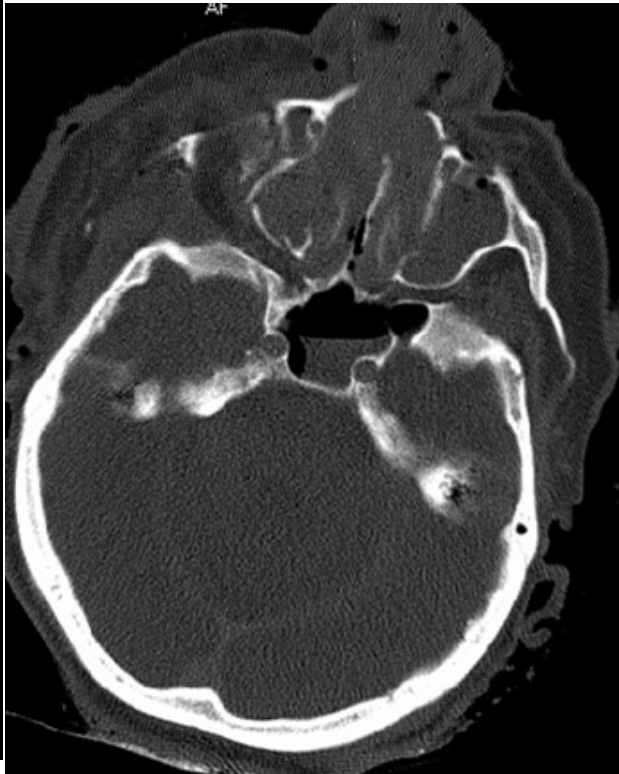
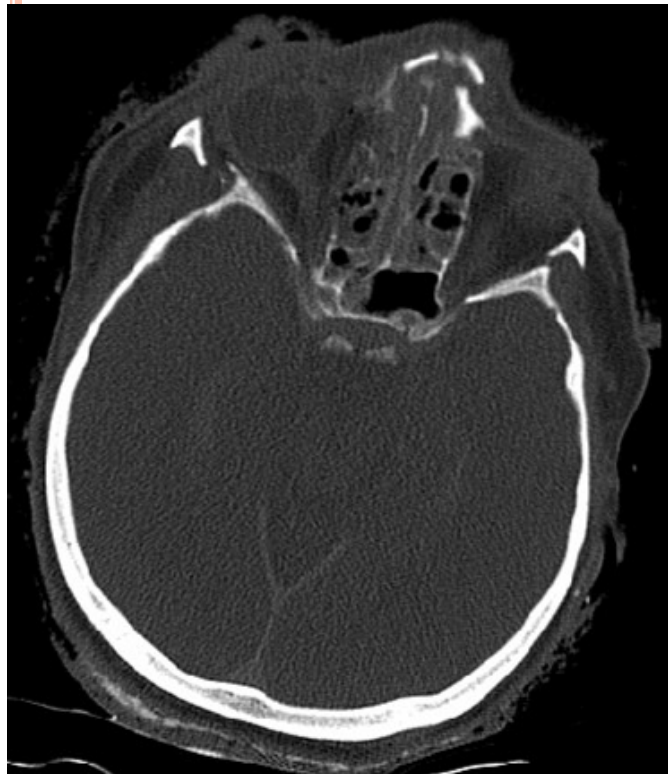CLASSIC CT INDICATION

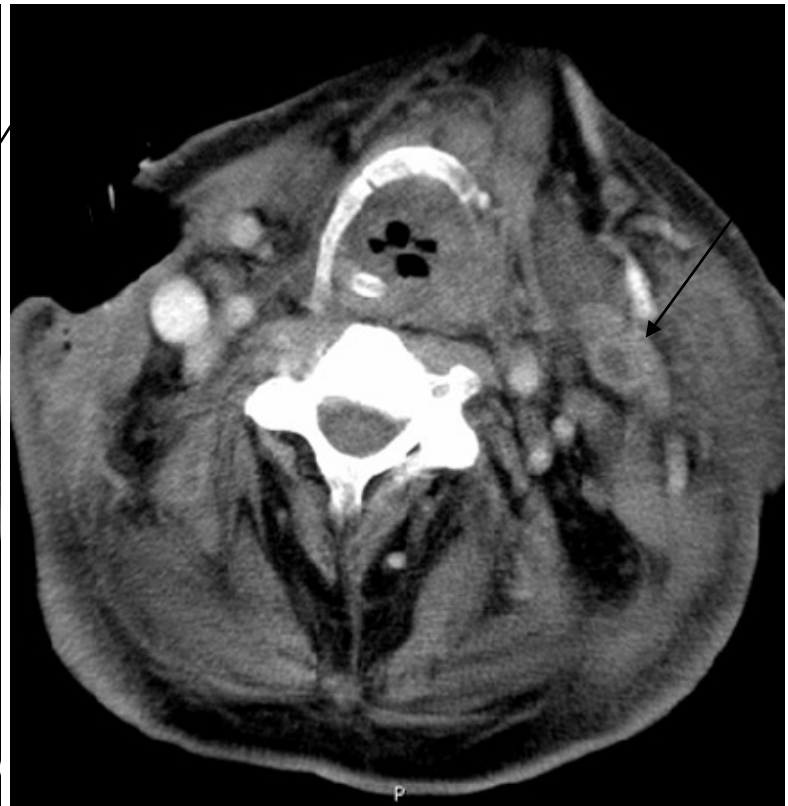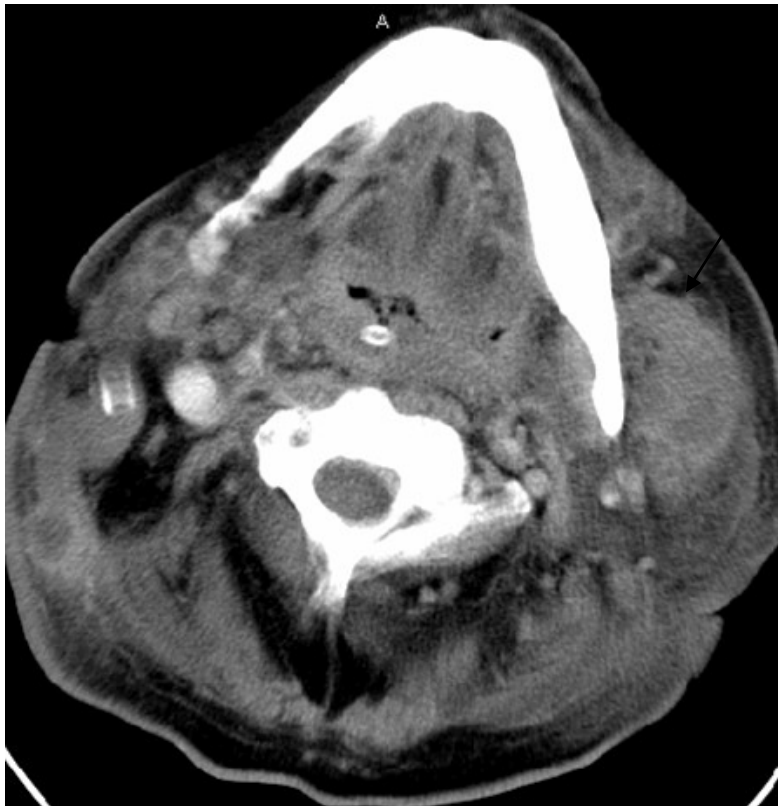- Examination of facial soft tissue
- parotid gland disease
- diagnosing and staging tumors
- diagnosis and assess the extent of osteomyelitis (inflammation of the jaw bone)
- temporomandibular joint disorders
- impacted teeth
- complex traumatic injuries of facial skeleton

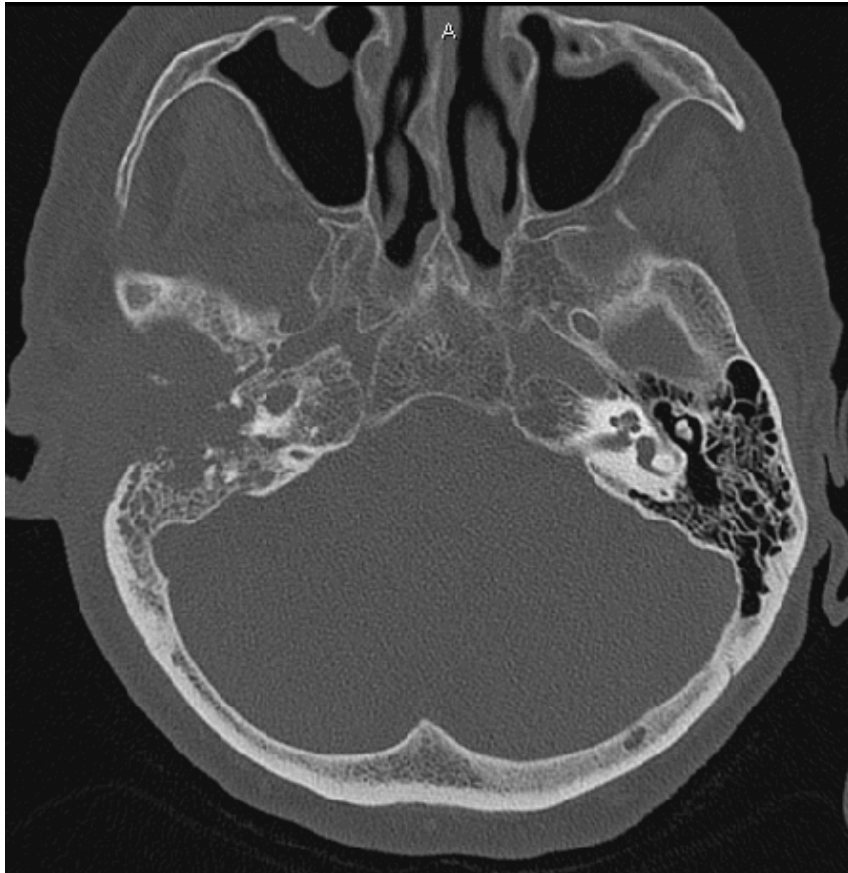

Complex fractures of facial skeleton

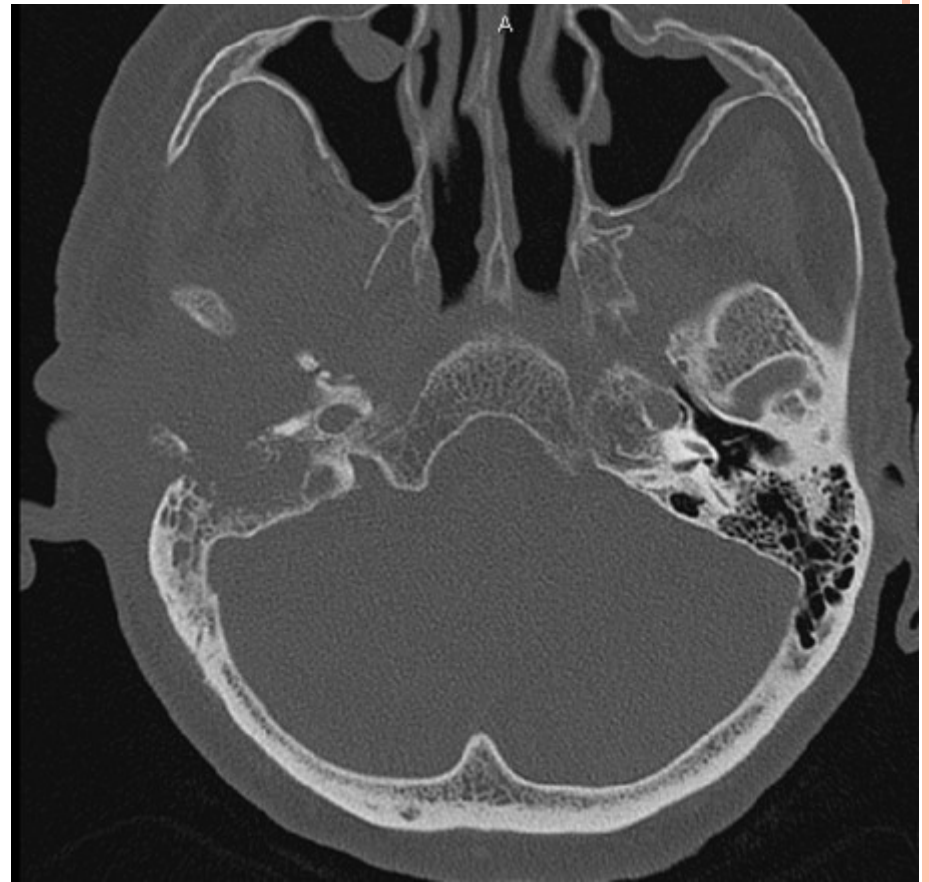


Absces



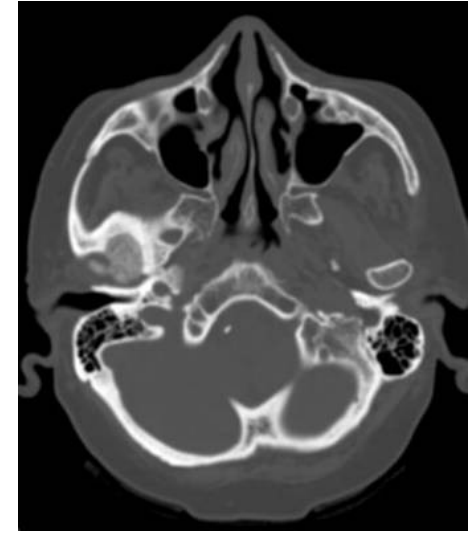
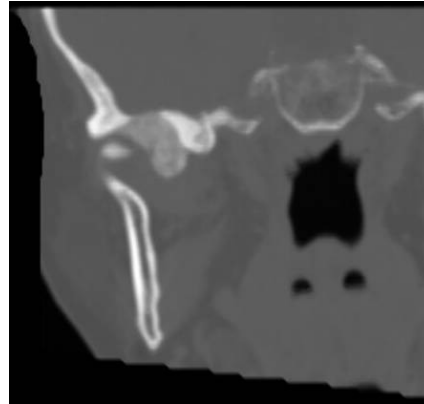
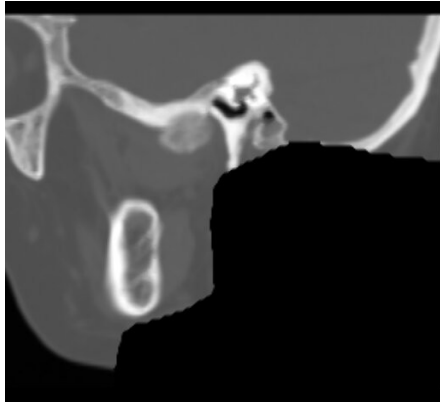


The extensive osteolysis of the temporal bone

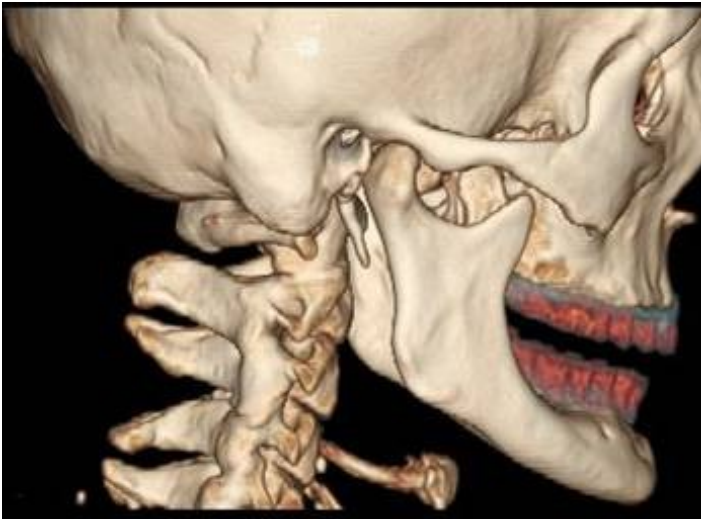

Postprocessing - reconstructions

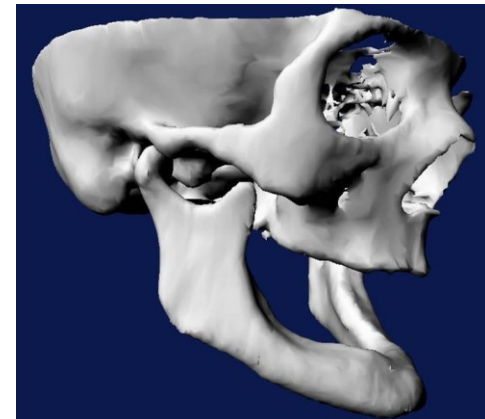
Multiplanar rec. - MPR



Volume rendering technique - VRT



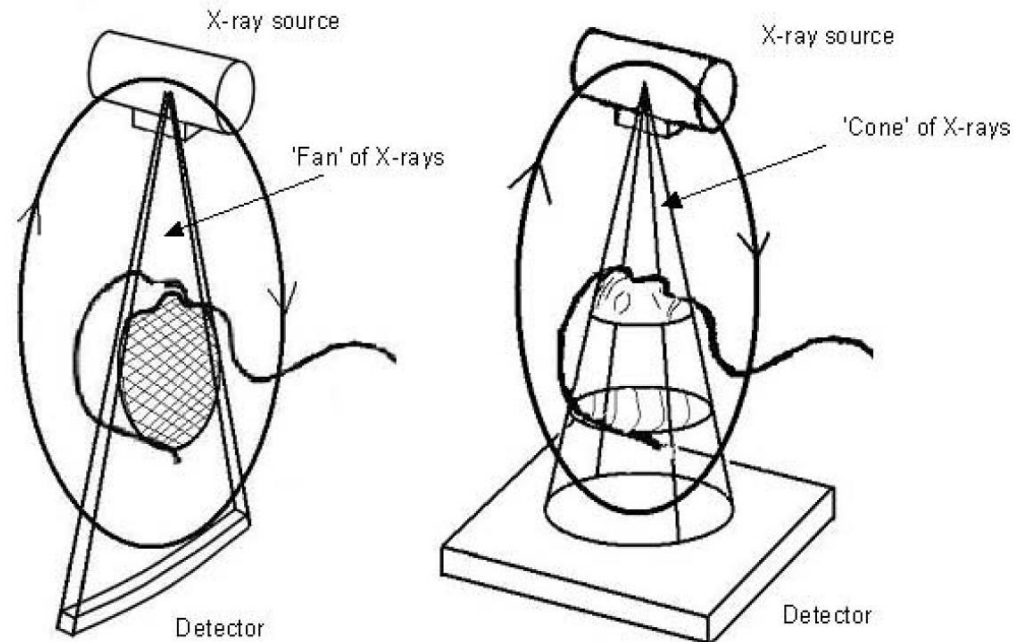
Shadow surface display - SSD



Dental Cone Beam CT

HOW CBCT WORKS

- Similar to current CT technology
- Uses cone shaped x-ray beam
- 2-D flat panel detector
- Gives volumetric data



ADVANTAGES IN DENTAL IMAGING

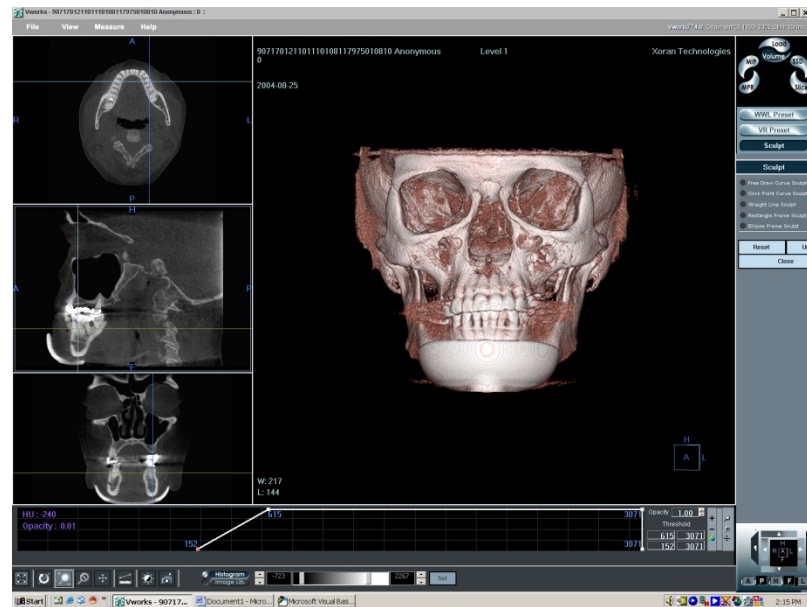- Lower dose than helical CT
- Compact design
- Superior images to Panoramic
- Low cost
- Low heat load

Dose:

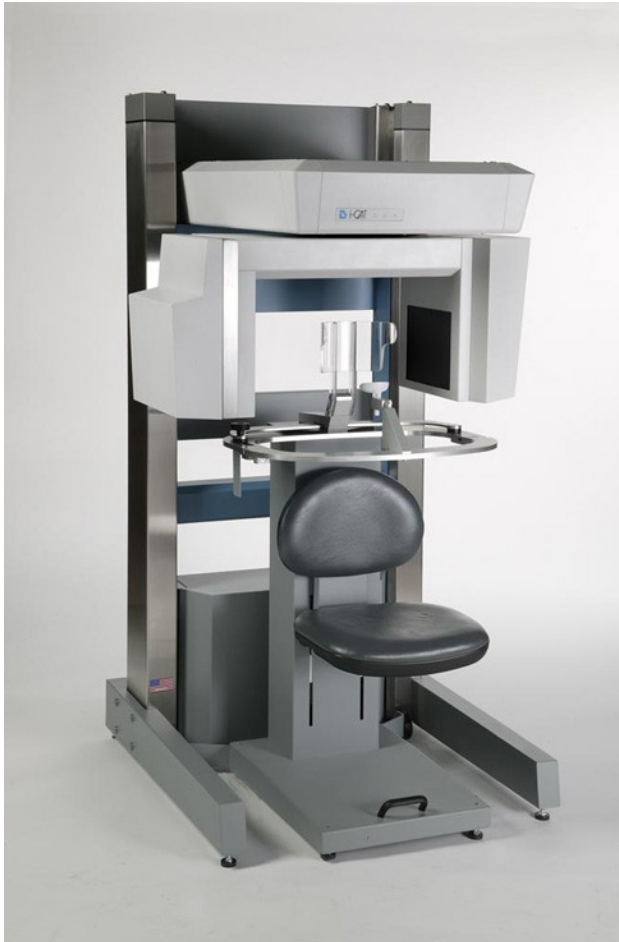Panoramic: 6-20 μSv

CBCT: 20-70 μSv

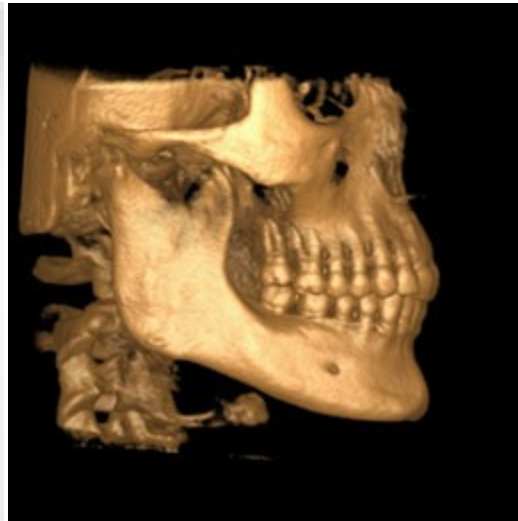
Conventional CT:
314 μSv



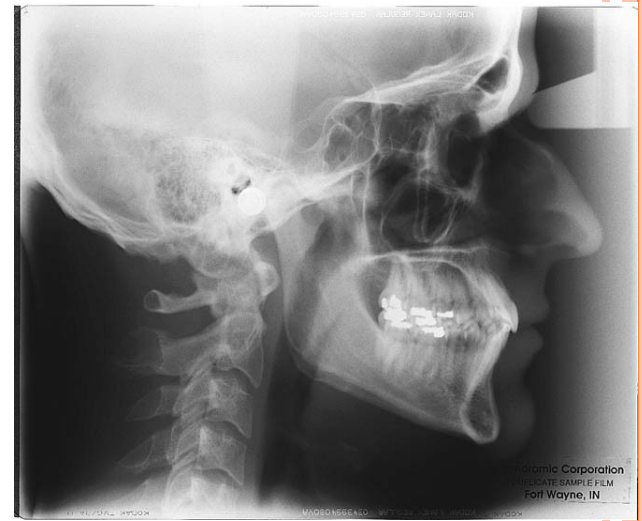CBCT



The i-Cat CBCT



Cephalometric
CBCT image

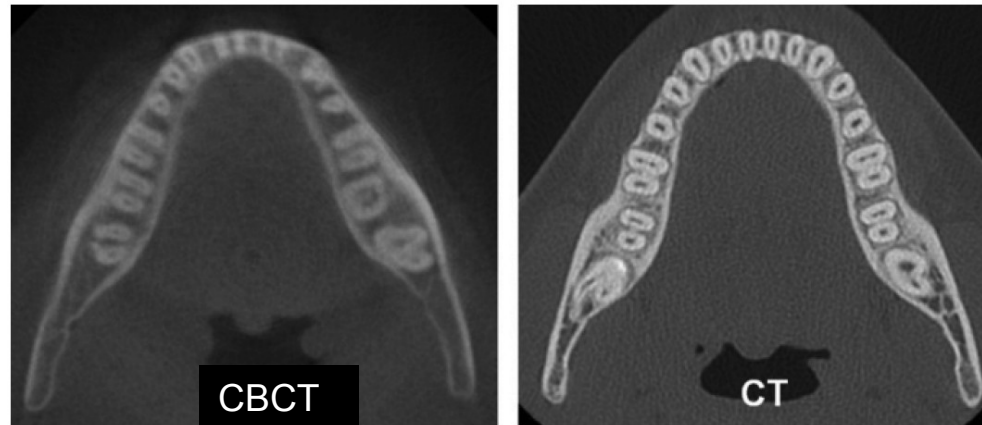


Cephalometric
Panoramic image



SHORTCOMINGS

- Worse resolution in low contrast tissues
- Long scan times = motion artifacts
- Slightly Inferior quality to conventional CT

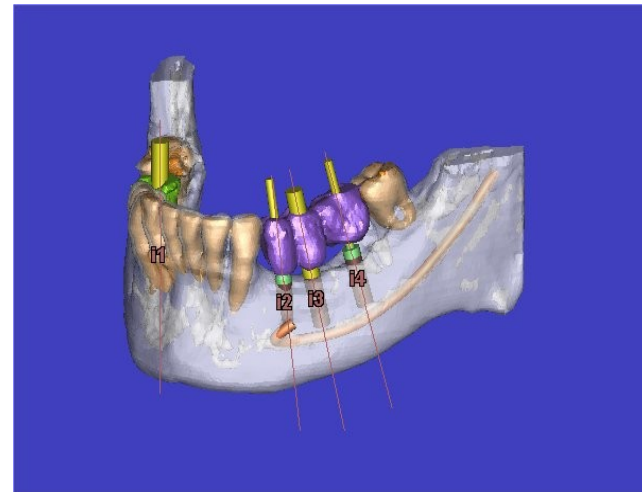
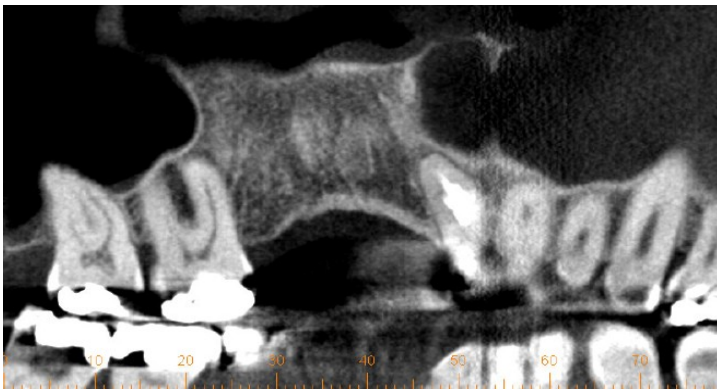


Periodontal ligament spaces easily recognizable in the dental CT but not satisfactory in the CBCT



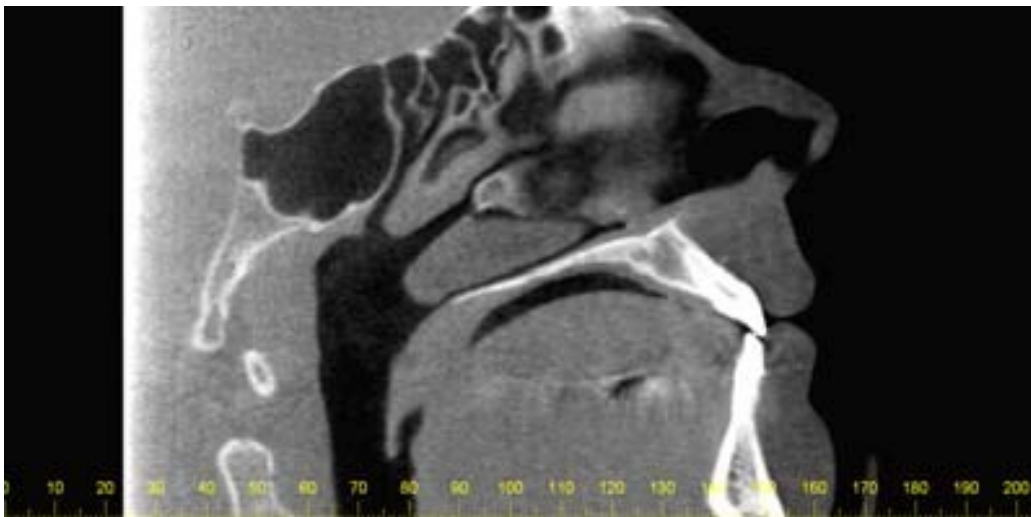
APPLICATIONS OF CBCT

- Great for pre-planning for implant surgery
- Virtual Surgery
- Conventional CT diagnosis at 1/5 the dose
- Tumor detection
- Airway visualization



CONCLUSIONS

- CBCT offers less dose than conventional CT
- CBCT offers superior images and diagnosis to panoramic
- More practical than a conventional CT



SONOGRAPHY



SOUND


- Mechanical waves (energy transfer).
- Sound use particles of enviroment for own transmision(so no sound in vacuum).

- Infrasound 0-16 Hz
- An audible sound 20 Hz-20 kHz
- **Ultrasound** **20 kHz-10 GHz**
- Hypersound 10 GHz - ?

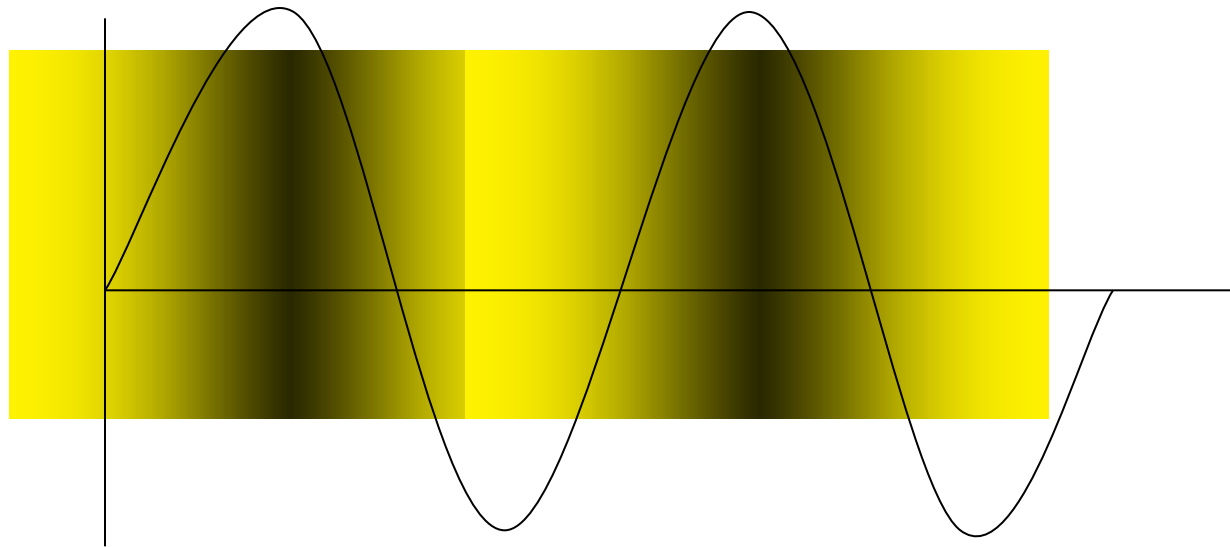


SOUND

- Wave propagation consists of cyclic compressions and decompressions of environmental particles



SOUND - GRAPHICALLY EXPRESSED



ZVUK

- Vyšší frekvence = vyšší rozlišení, horší penetrace
- Nižší frekvence = vyšší penetrace, horší rozlišení



SOUND - SPREAD RATE

Air 330 m/s

Water 1480 m/s

Liver 1550 m/s

Kidney 1560 m/s

Soft tissue 1540 m/s



SOUND

- The spread rate is determined only by the characteristics of the environment - in particular with density (stiffness)

 density (stiffness) =  **Speed**

- The average sound velocity in the human body for ultrasound purposes is about 1540 m / s

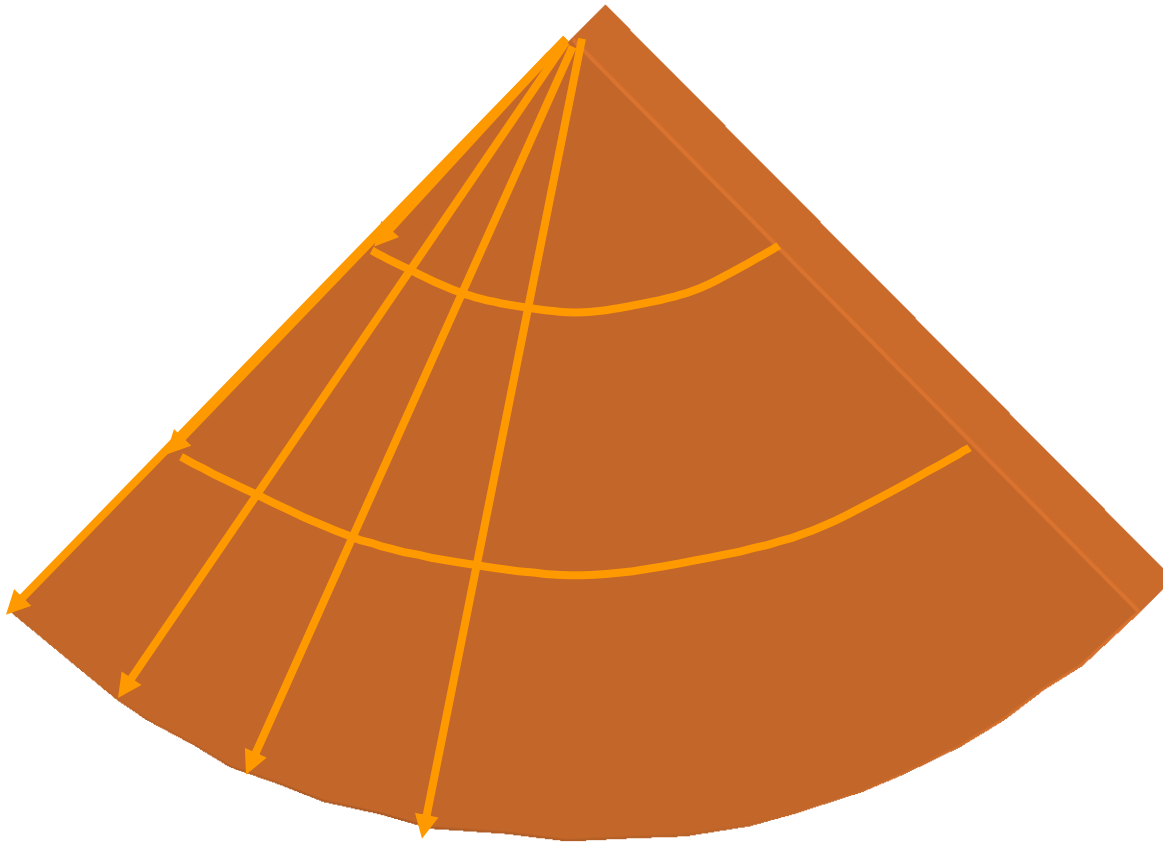


- Basic principle of ultrasound image creation - reflections of ultrasound waves on the interface of two different environments with different acoustic impedance.
- Reflections (echos) can be displayed in a 2D image, the reflected energy intensity is expressed on a gray scale (the strongest = lightest)

.



PULS ULTRASOUND



- The probe sends a wave and detects the amplitude of returning wave.
- According to the return time, it calculates from which depth the signal was reflected.
- Depending on the amplitude, it assigns the brightness to the point on the screen
- The same is repeated several times in the lateral direction and together all lines of points makes final picture



APPLICATION OF DIAGNOSTIC ULTRASOUND IN STOMATOLOGY

- Detection of cortical fracture lines in maxillo-facial fractures
- Position of mandibular condyls.
- Detection of diseases of the salivary glands (inflammation, tumors, sialolithiasis, dilation of the outlets)
- Detection of lymphadenopathy
- navigational interventions (biopsy, puncture) at palpably inaccessible departments, TMJ ozonotherapy
- Surface soft-tissue affection of the maxillo-facial region, differential diagnosis (significantly better resolution than CT)



THERAPEUTIC ULTRASOUND - PRINCIPLE

- The main mechanism of therapeutic effect is high-frequency micromassage of tissues together with heat inducing hyperaemia and physico-chemical changes in the environment.
- Its application enhances membrane permeability, accelerates diffusion in tissues, has a suppressive effect on the transmission of nerve impulses, changes the pH of the tissues.
- The result is an analgesic and spasmolytic effect, increased local blood circulation and consequently also metabolism



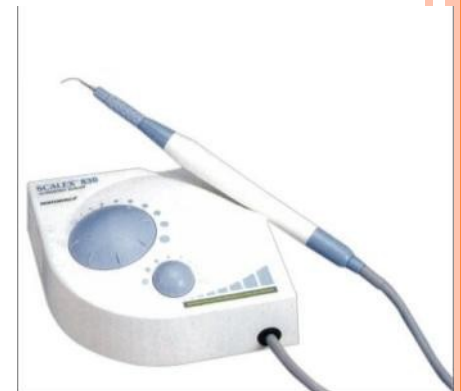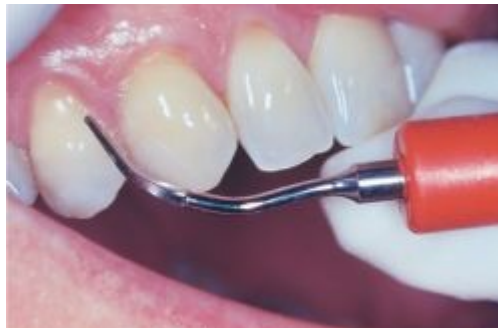THERAPEUTIC ULTRASOUND - INDICATION

- Myofacial pain dysfunction sy
- TMJ diseases
- Sialolitotripsy (extracorporeal shock wave - ESWL)
- Algic syndromes, bone healing
- It inhibits the release of inflammatory mediators from the cells
- Accelerates healing
- Increases the elasticity of collagen fibers
- Reduces joint stiffness
- Reduces muscle spasms, improves mobility



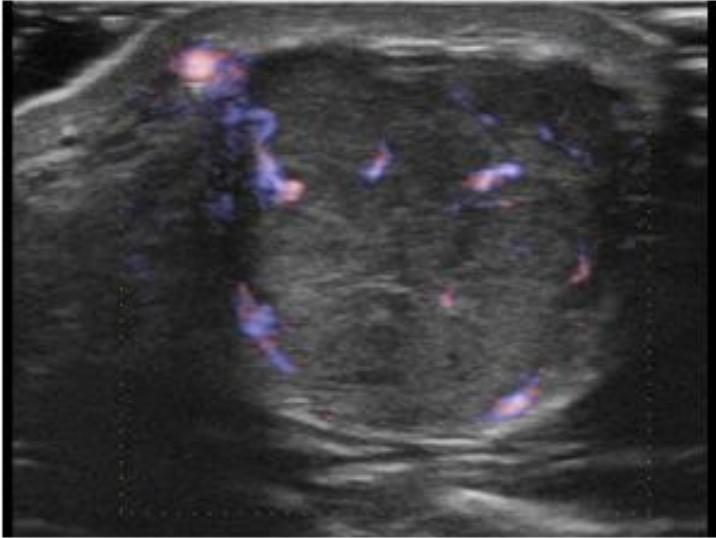
THERAPEUTIC ULTRASOUND - DENTAL DESCALER

- Ultrasound dental descaler - tartar removal.
- It is a device with a source of low-frequency ultrasonic waves (25-42 kHz), the end of which is equipped with a working extension. The tip of the extension vibrates and mechanically disturbs dental plaque.
- However, in addition to the direct mechanical effect of the oscillating tip, effect of ultrasonic cavitation is also involved.



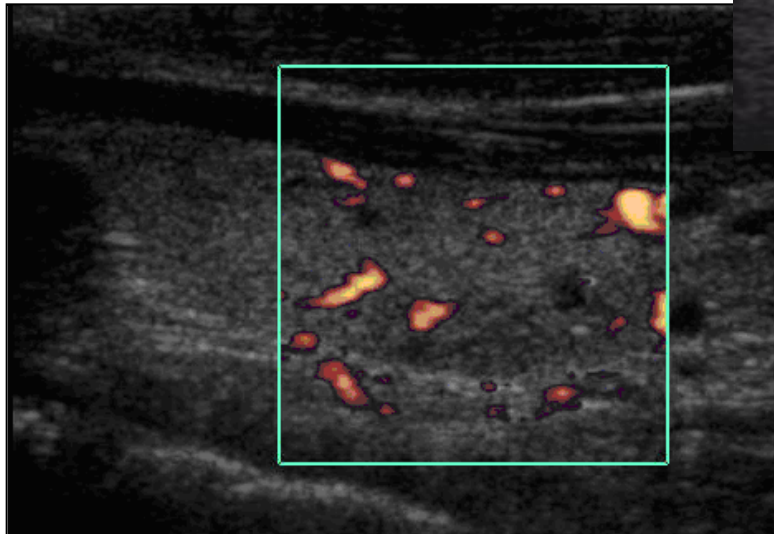
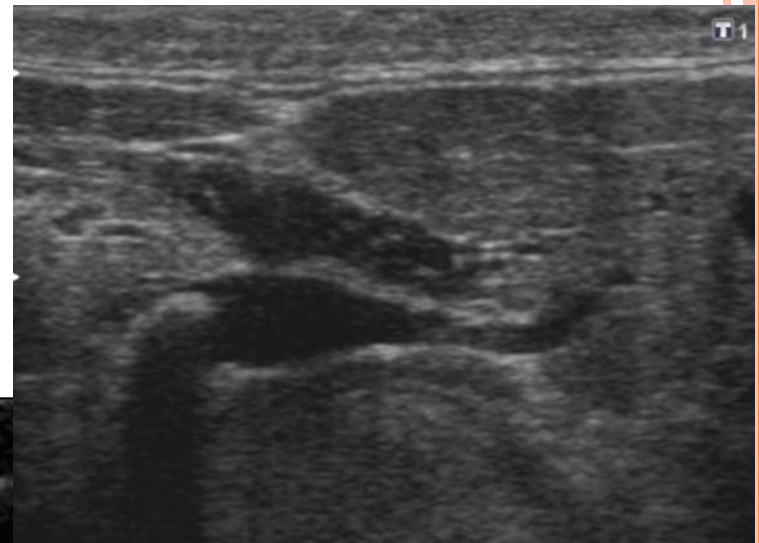
ULTRASOUND OF SALIVARY GLANDS

Pleomorf adenoma



Cysts

Sialolithiasis



ADVANTAGES OF ULTRASOUND EXAMINATIONS

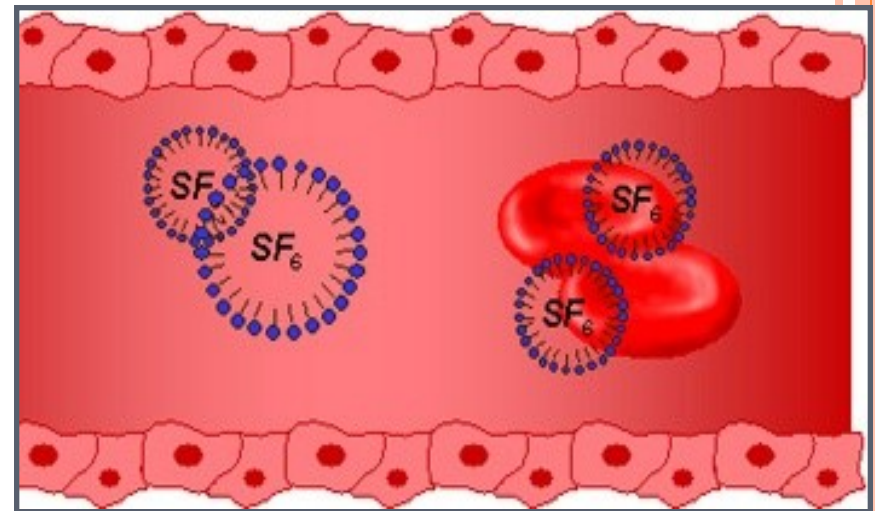
- safe, cheap and affordable method
- there are practically no contraindications
- accessibility at the patient's bed
- significant spatial resolution
- Doppler option, flow display, blood circulation



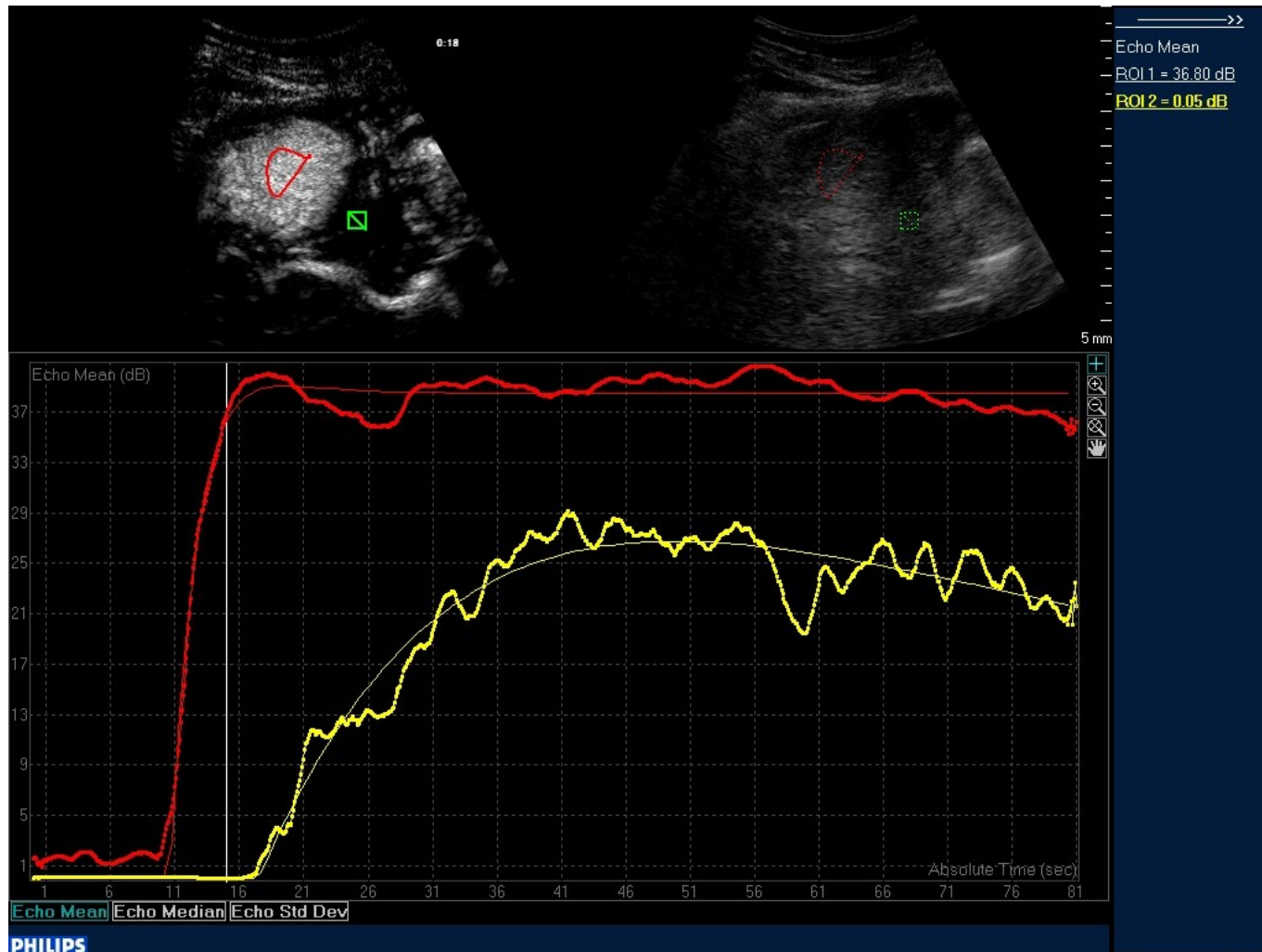
CEUS

- ultrasound examination with i.v. application of special contrast media
- microbubbles stabilized by phospholipid
- 100 million x higher soundwaves reflection of microbubbles than of blood.

- nontoxic
- no special patient preparation is required
- there are no allergic reactions
- is excreted after about 10 minutes with lungs
- only contraindication: AIM
- Pure intravascular contrast agent



POSSIBILITY OF QUANTIFICATION

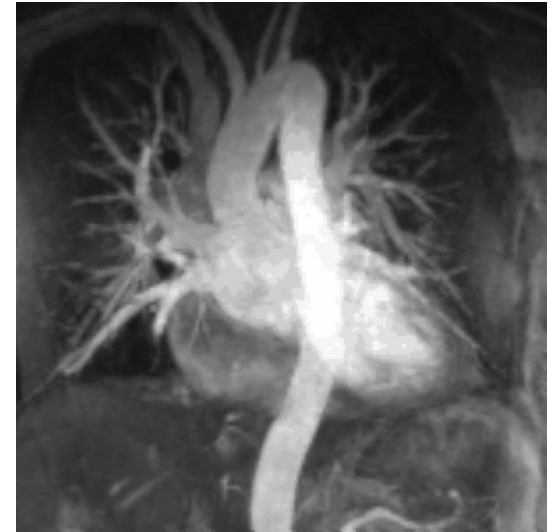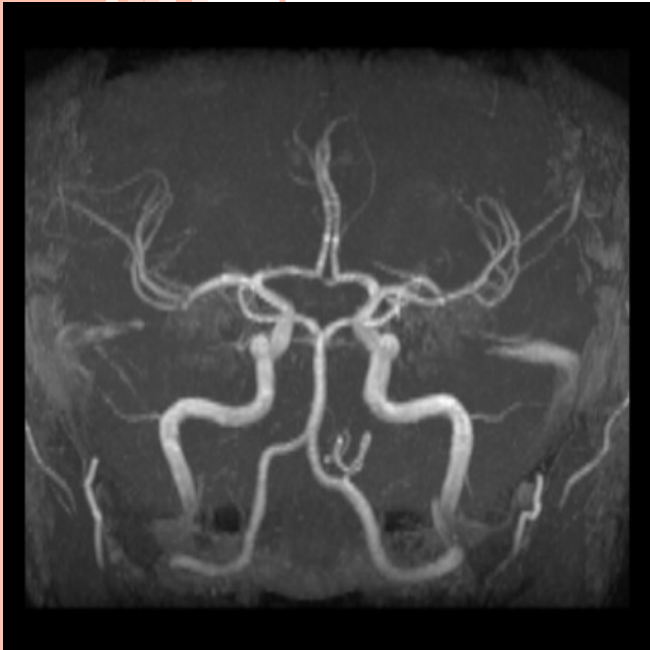


DISADVANTAGES, LIMITATIONS OF ULTRASOUND

- number of artifacts
- subjective examination
- limited investigability in non-cooperating patients



MAGNETIC RESONANCE



MAGNETIC RESONANCE

- Hydrogen nuclei (1H) have a magnetic behavior
- We use a strong magnetic field (0,2-2T)
- radiofrequency pulses - a **resonance** of frequencies
 - transfer of energy - 1H raising from lower to higher energy states
- signal from protons = from the patient body - induction of a current in a receiver coil - computer reconstruction - resulting image



DISADVANTAGES OF MRI

- Strong magnetic field! (*whole patient is placed in*)
- duration of examination - *untill 60 min.*
- limited examination space
- the price = availability
- limited examination field (*brain + Csp., C+Th, Th+L*)



BENEFITS OF MRI

- **Noninvasive technique**
- unprecedented soft **tissue contrast**
- arbitrary plane of cross-section
- MR angiography, ERCP, PMG (*without a contrast medium*)
- contrast media - Gd (*minimal risk of allergic reaction*)



CONTRAINDICATIONS OF MRI

ABSOLUTE

- presence of magnetic metallic implants in orbit or intracranially
- Magnetic implants in other locations shorter than 6 weeks after implantation
- pacemaker/ICD

RELATIVE

- claustrophobia
- non-cooperative patient
- I. trimester of pregnancy



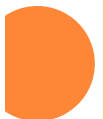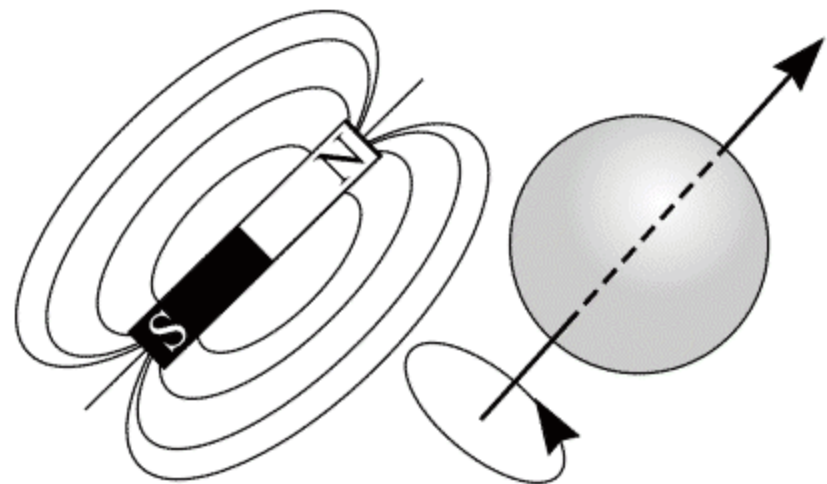
MR PRINCIPLES

- Nuclear magnetic resonance (NMR) is a non-invasive means of obtaining clinical images and of studying tissue metabolism in vivo. Bloch and Purcell independently discovered NMR in 1946. Six years later they were awarded the Nobel Prize for their achievements. Since then, the development of NMR spectrometers and NMR scanners has led to the opening up of whole new branches of physics, chemistry, biology and medicine.



- Nuclei with an odd number of protons and neutrons possess a property called spin. In quantum mechanics spin is represented by a magnetic spin quantum number. Spin can be visualised as a rotating motion of the nucleus about its own axis. As atomic nuclei are charged, the spinning motion causes a magnetic moment in the direction of the spin axis. This phenomenon is shown in figure. The strength of the magnetic moment is a property of the type of nucleus. Hydrogen nuclei (^1H), as well as possessing the strongest magnetic moment, are in high abundance in biological material. Consequently hydrogen imaging is the most widely used MRI procedure.

A charged, spinning nucleus creates a magnetic moment which acts like a bar magnet (dipole).



- The first step in creating a magnetic resonance image is placing the subject in a strong magnetic field.

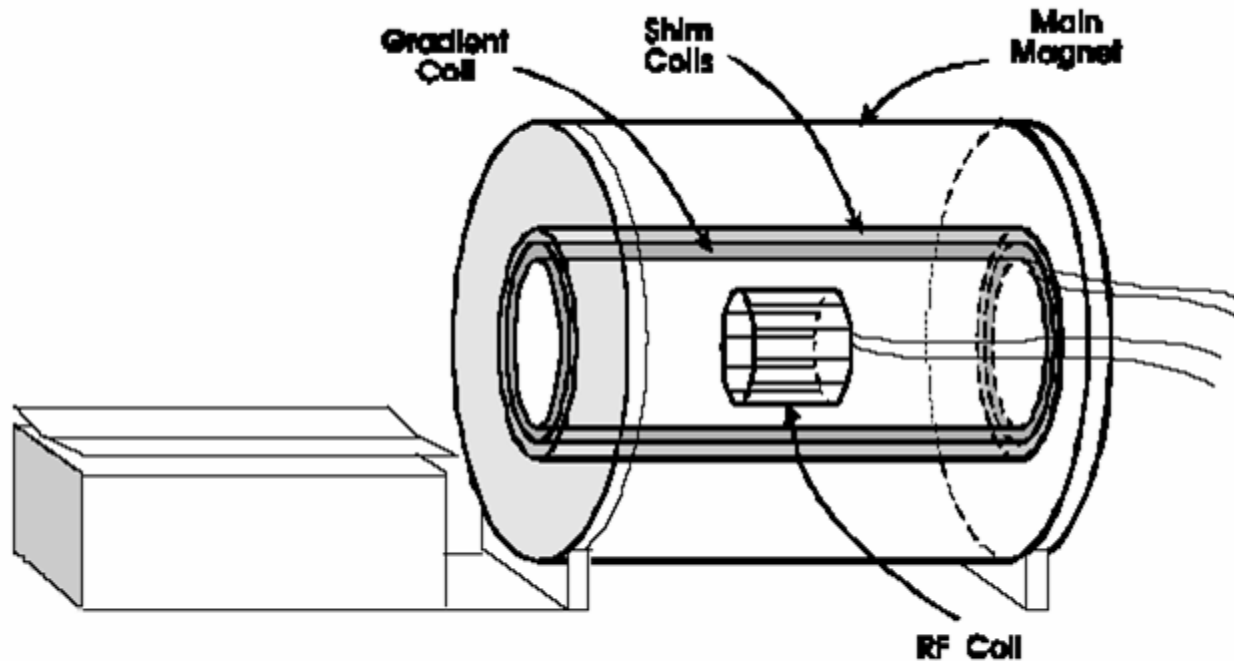
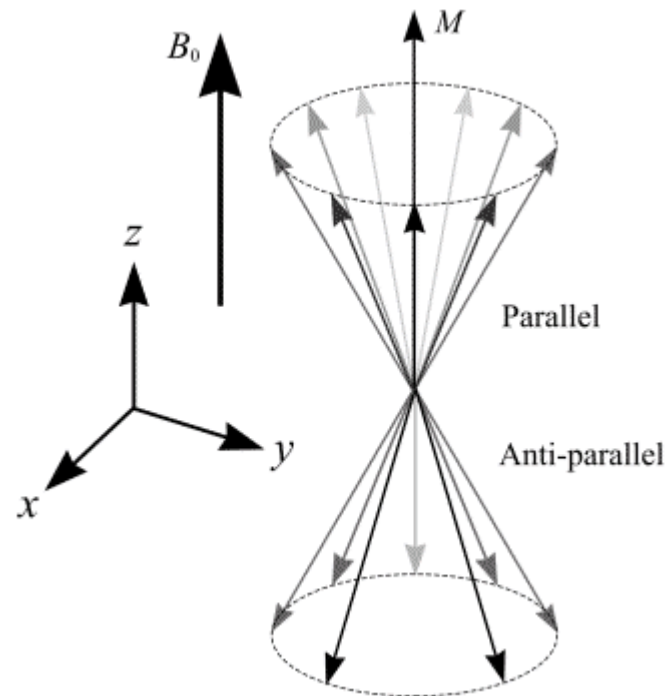


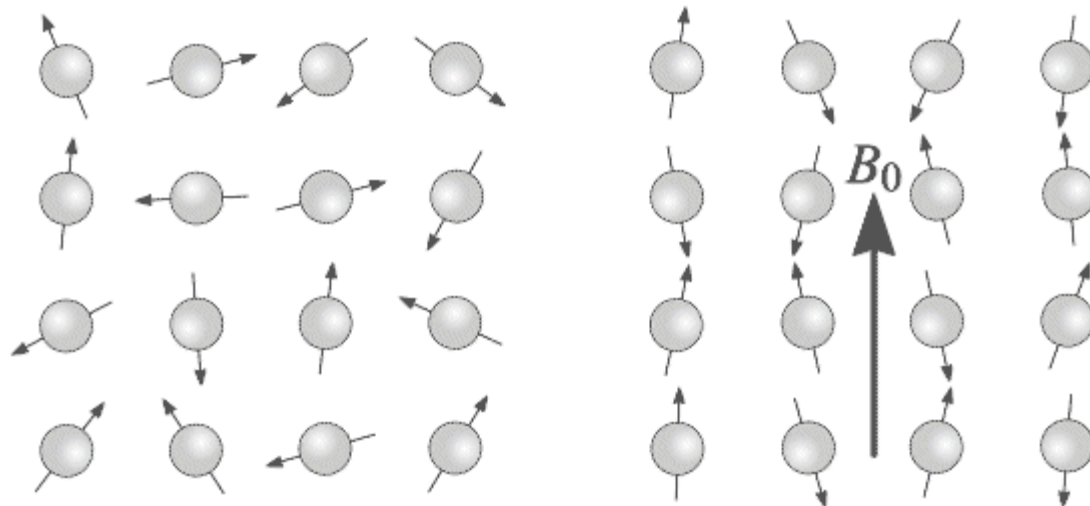
Figure 9.1: A schematic of a typical MR imaging system. The essential components include the magnet producing the main magnetic field, shim coils, a set of gradient coils, an RF coil, and amplifiers and computer systems (not shown) for control of the scanner



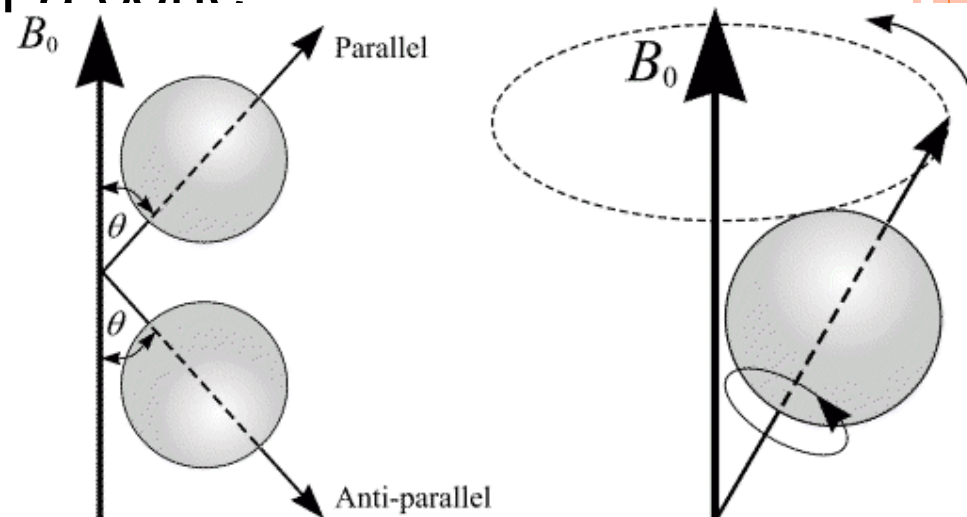
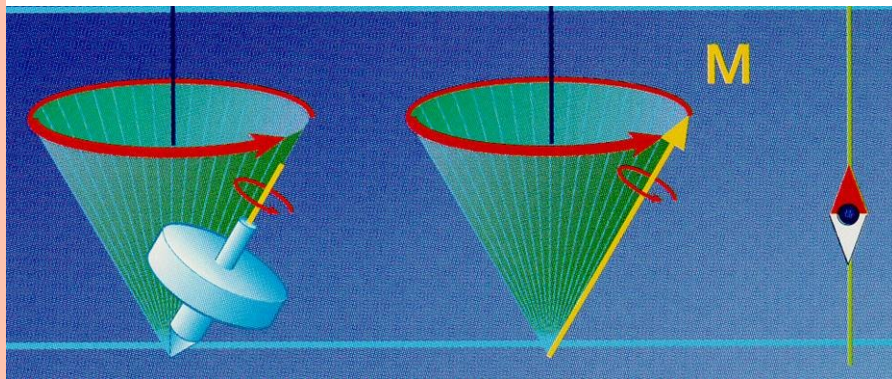
- Presence of a strong magnetic field causes the nuclear spins of certain atoms within the body, namely those atoms that have a nuclear spin dipole moment, to orient themselves with orientations either parallel or antiparallel to the main magnetic field (B_0).



- A collection of ^1H nuclei (spinning protons) in the absence of an externally applied magnetic field. The magnetic moments have random orientations. (b) An external magnetic field B_0 is applied which causes the nuclei to align themselves in one of two orientations with respect to B_0 (denoted parallel and anti-parallel).

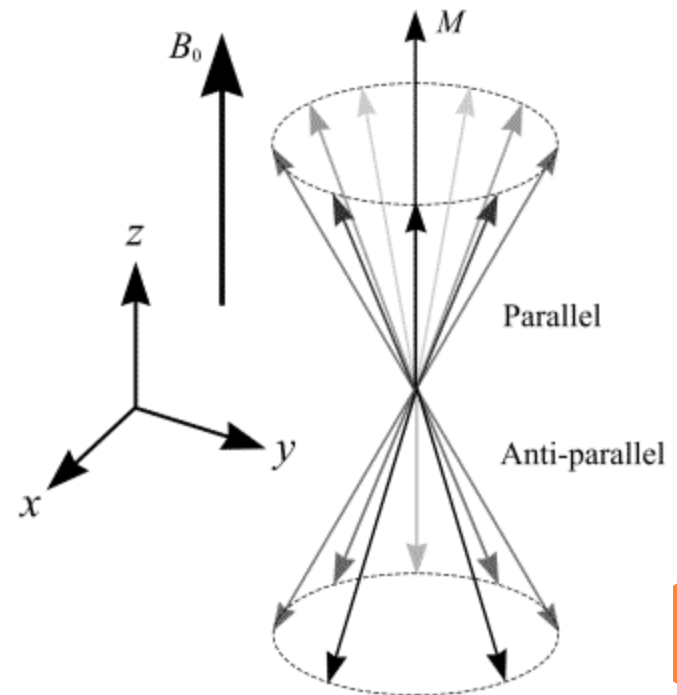


- The spin axes are not exactly aligned with B_0 , they **precess** around B_0 with a characteristic frequency
- (a) In the presence of an externally applied magnetic field, B_0 , nuclei are constrained to adopt one of two orientations with respect to B_0 . As the nuclei possess spin, these orientations are not exactly at 0 and 180 degrees to B_0 . (b) A magnetic moment precessing around B_0 . Its path describes the surface of a cone



- The nuclei precess about B_0 with a frequency called the resonance or a Larmor frequency.
- Because the parallel state is the state of lower energy, slightly more spins reside in the parallel configuration, creating a net magnetization represented by a vector M .

A collection of spins at any given instant in an external magnetic field, B_0 . A small net magnetisation, M , is detectable in the direction of B_0 .



- Magnetic resonance occurs when a radiofrequency pulse, applied at the Larmor frequency, excites the nuclear spins raising them from their lower to higher energy states. Classically this can be represented by a rotation of the net magnetization, away from its rest of equilibrium state.

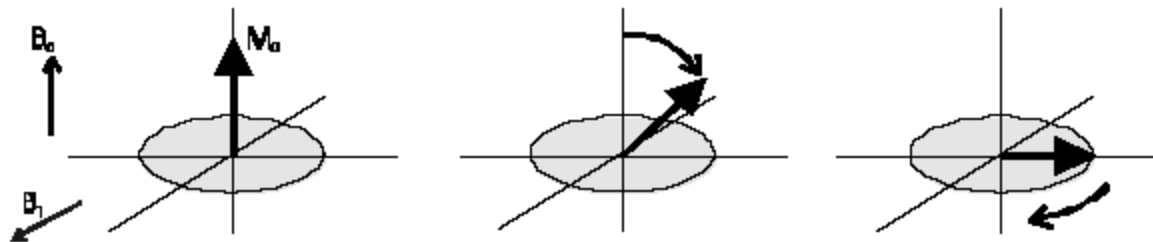
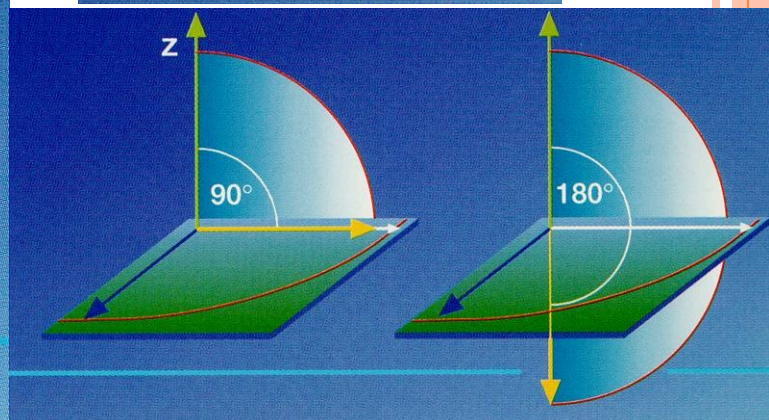

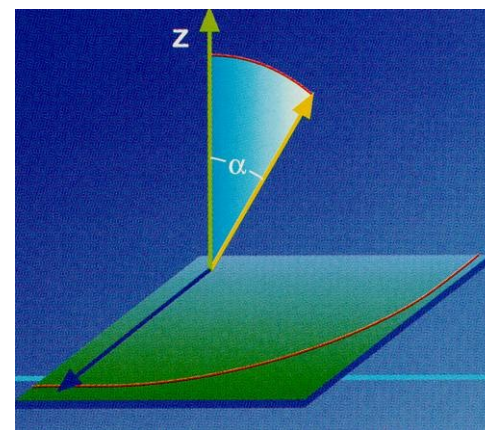

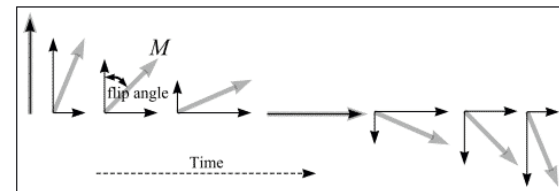
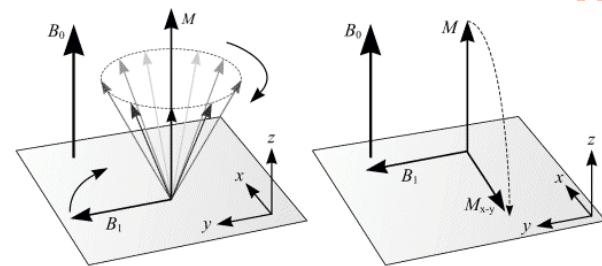


Figure 9.2: A series of vector diagrams illustrating the excitation of a collection of spins by applying an alternating magnetic field, in this case a 908 radio-frequency (RF) pulse (represented here as B_1). B_0 indicates the direction of the main magnetic field. The first 2 vector diagrams are in a frame of reference rotating with the radio-frequency pulse. As a result, the alternating magnetic field can be represented by a vector in a fixed direction. Application of the RF pulse flips the magnetization into the transverse plane, after which the magnetization continues to precess about the main magnetic field.

After a 90 degrees RF pulse, M lies in the x-y plane and rotates about the z-axis. The component of M in the x-y plane decays over time. An alternating current is induced in the receiver coil.



- Once the magnetization is deflected, the RF field is switched off and the magnetization once again freely precesses about the direction of B_0 .
- This time dependent precession will induce a current in a receiver coil.
- The resultant exponentially decaying voltage, referred to as the free induction decay (FID), constitutes the MR signal.

After a 90 degrees RF pulse, M lies in the x-y plane and rotates about the z-axis. The component of M in the x-y plane decays over time. An alternating current, shown in Figure (b), is induced in the receiver coil.

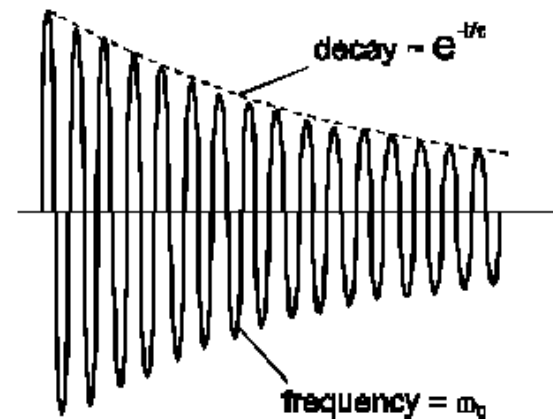
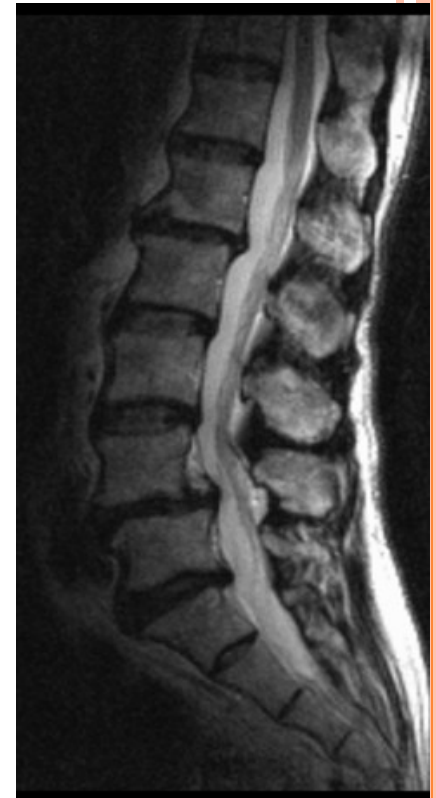
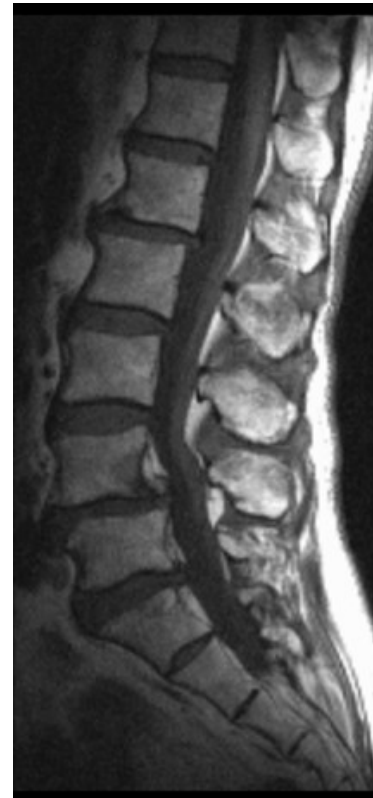
Figure 9.3: The signal acquired after excitation in the absence of applied magnetic field gradients is a decaying sinusoid, called the free induction decay (FID). This signal is characterized by two parameters – the amplitude and the frequency, which depend on the number and type of spins being studied and the magnetic environment that the spins are in.

- During the period of free precession the magnetization returns to its original equilibrium state by a process called ***relaxation*** which is characterized by two time constants, T1 and T2.

T1 and T2 depend on certain physical and chemical characteristics unique to tissue type, therefore contributing substantially to the capability of MRI to produce detailed images of the human body with unprecedented soft tissue contrast.



RECONSTRUCTION OF MR IMAGE

- How do we make the voxels (volume elements)?
- How do we know, from which part of the body comes the signal, how we make the final image?
- Complex and complicated process, we need a physical and mathematical device



Slice Selection

- The first step is the selection of a slice, which is achieved by applying a magnetic field gradient along the z-axis (G_z) during a 90° rf pulse of a specific frequency bandwidth (period 1 of Figure 9.7). When the slice select gradient, G_z , is applied along the z-axis, the resonance frequencies of the protons become linearly related to position along the z-axis. Individual resonance frequencies correspond to individual planes of nuclei.

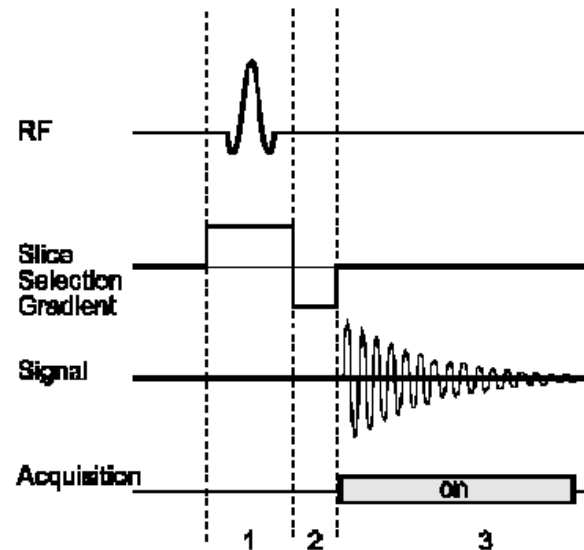
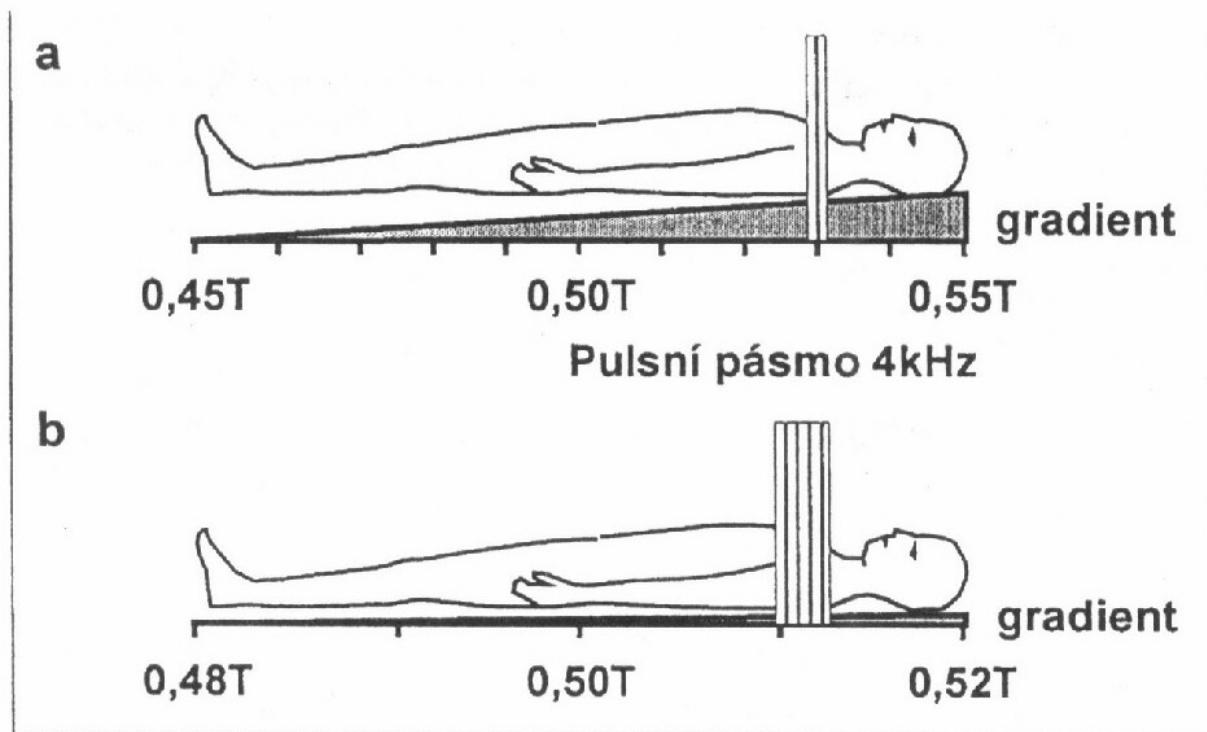
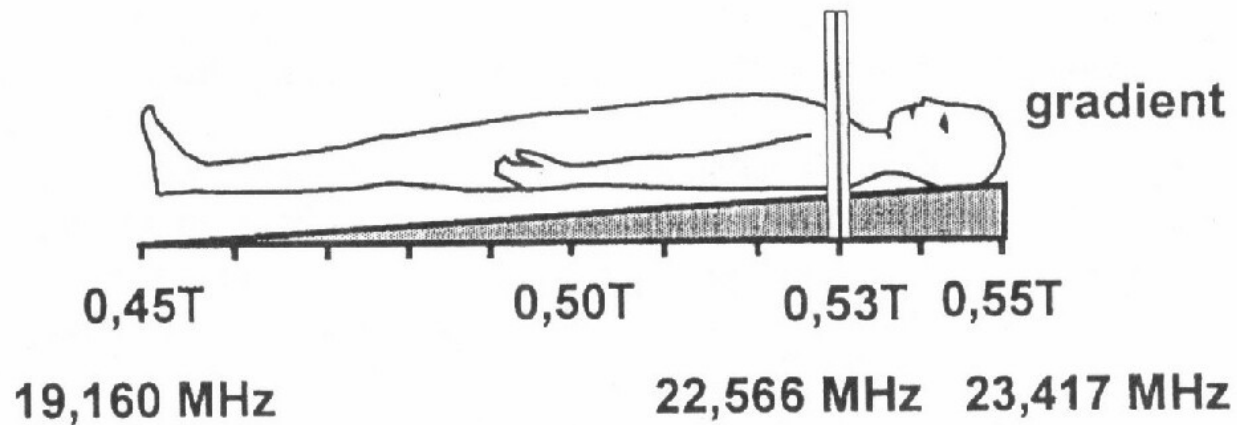


Figure 9.7: The sequence of RF power and gradient strength used for slice selection. To excite only one slice, a magnetic field gradient is applied during the excitation RF pulse.



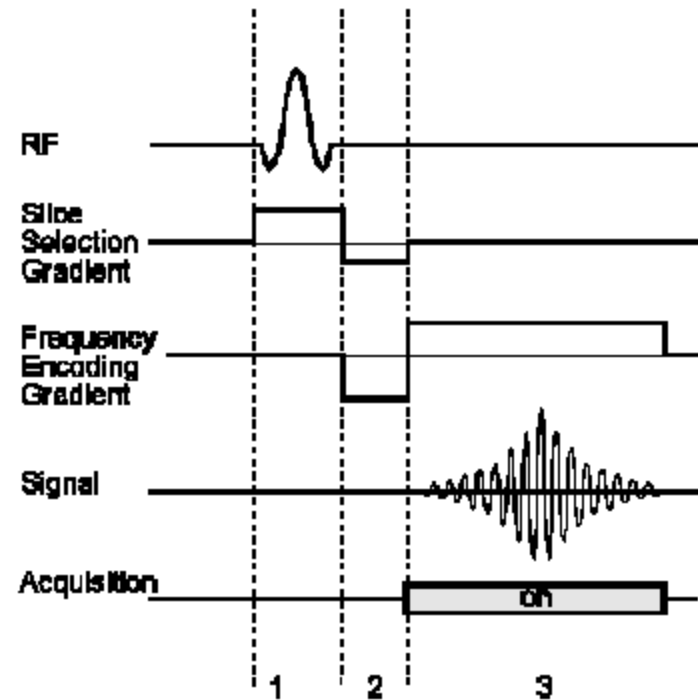
Dva možné postupy při volbě tloušťky tkáňového řezu



Frequency Encoding

- After slice selection, the next task is to distinguish signal from different spatial locations within this slice. This is accomplished in the x-direction by applying a gradient (G_x), the frequency-encoding gradient, during the acquisition of the signal. (time period 3 in Figure 9.11).

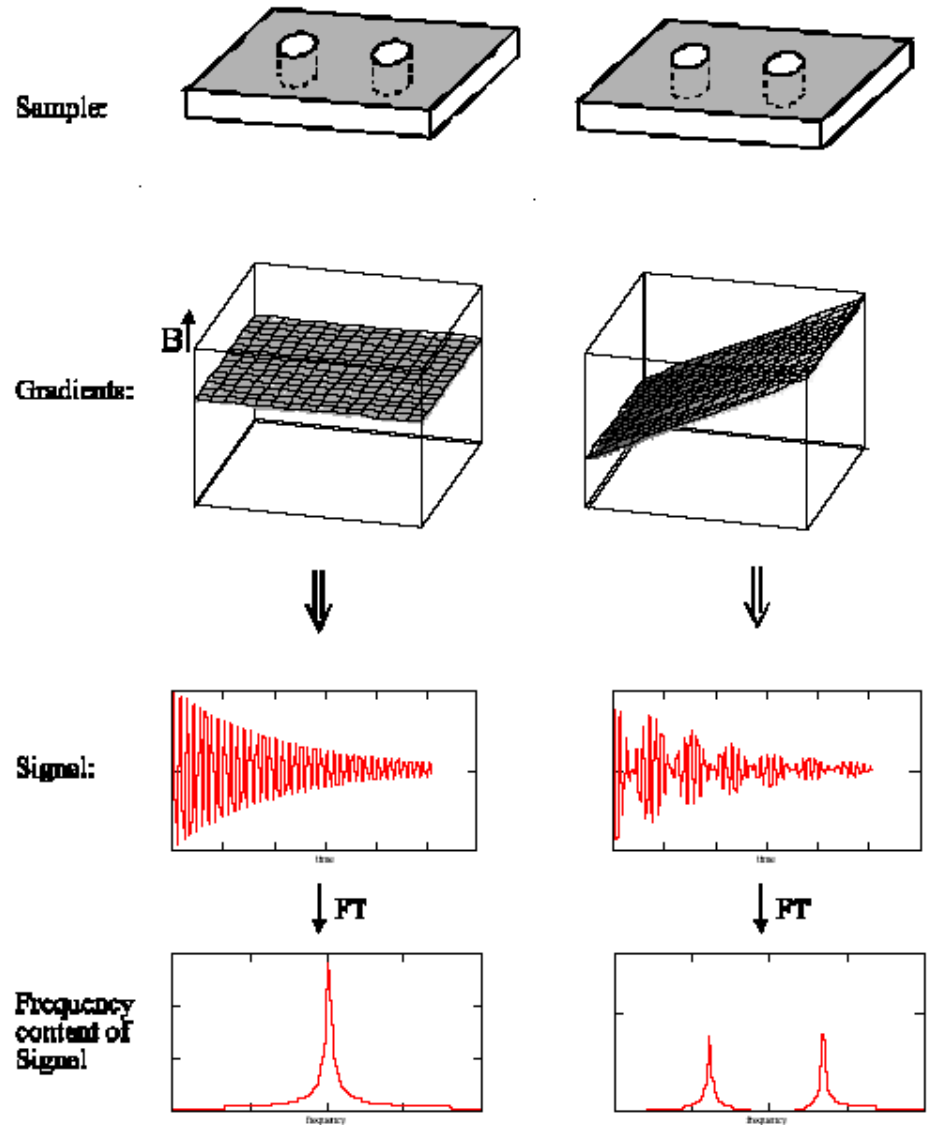
The sequence of RF power and gradient amplitudes used to excite one slice and encode the positions of the spins within that slice into the signal. In this “frequency encoding,” the positions of the spins encoded by applying a magnetic field gradient in one of the directions in the excited slice during the acquisition.



A series of steps illustrating the concept of frequency encoding to distinguish the signal coming from two point sources of magnetization, e.g. small vials of water, in an object. *(left)* When no gradient is applied, both sources of magnetization resonate at the same frequency and the signal is a simple decaying sinusoid. When this signal is Fourier transformed, the signal is shown to contain only one frequency. *(right)*

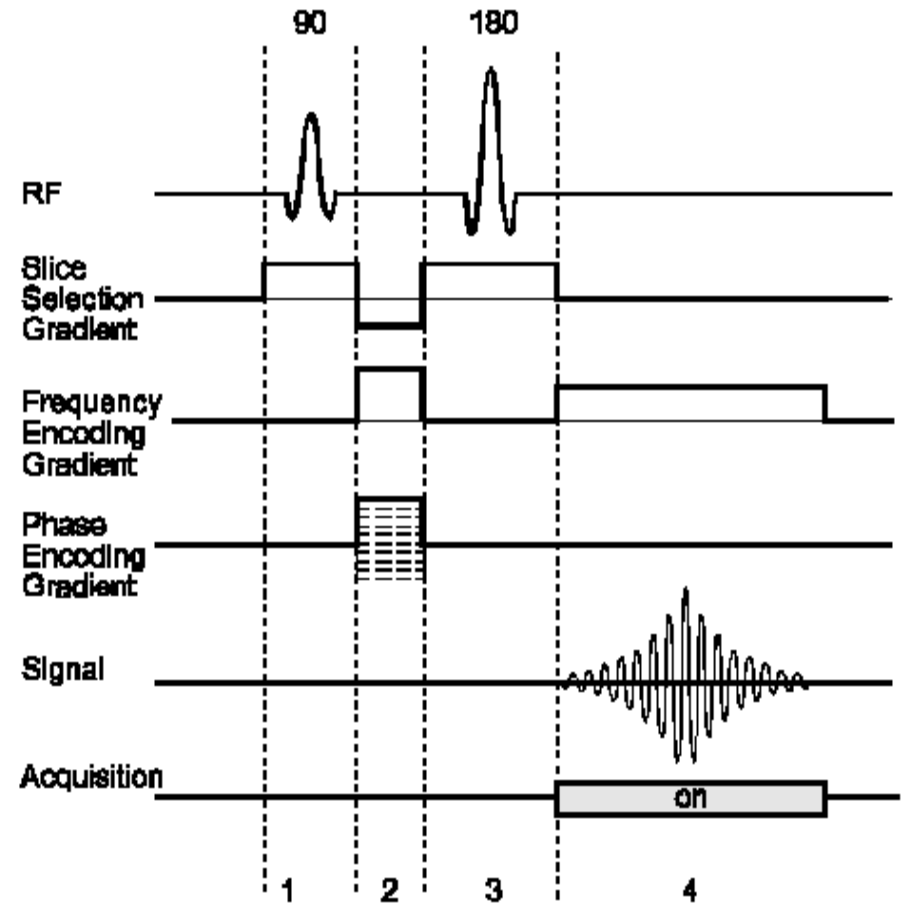
When a gradient is applied, one of the sources of magnetization precesses at a higher frequency than the other. The resulting signal is an interference pattern of the two frequencies and is shown to contain by Fourier transformation to contain two distinct frequencies. Notice that the Fourier transformed signal is the projection of the amount of magnetization along the axis along which the gradient was applied.

That is, in this one dimensional case, the frequency content of the signal *is* the image.



Spatial locations of the spins are encoded into the signal by applying three orthogonal gradients, techniques that are called slice selection, frequency encoding, and phase encoding. In period 1, a 90 degree pulse and a slice selection gradient excite one slice. In period 2, the initial frequency encoding gradient and the phase encoding gradient are applied. In period 3, a 180 degree pulse is applied, along with a slice selection pulse (such that only the spins in the same excited slice are “flipped,”) and in period 4 the frequency encoding gradient is applied and the signal is acquired. The sequence shown here is repeated numerous times (128, 256, 512, etc. depending on the desired resolution) each time with a different strength of the phase encoding gradient.

A complete pulse sequence diagram for the spin echo sequence.

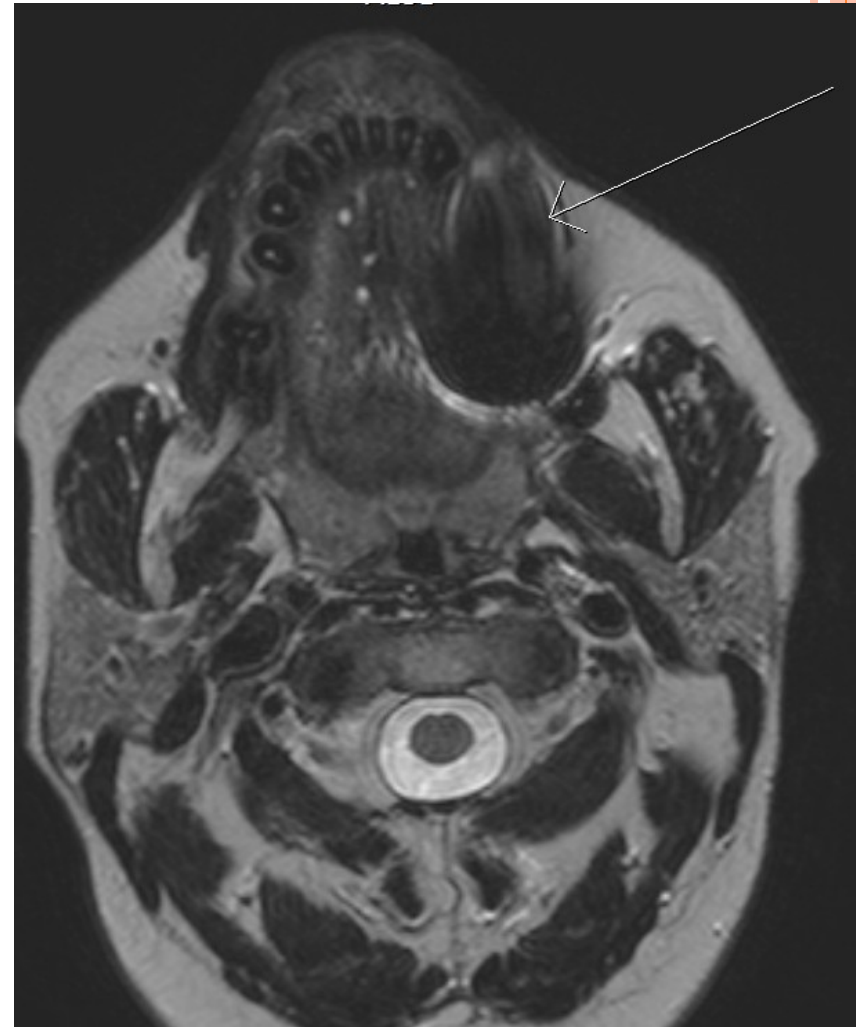


- Although the signal obtained from one acquisition (slice selection, phase encoding and frequency encoding) contains information from all voxels in the imaging slice, the information gathered from one iteration of this sequence is not sufficient to reconstruct an image. Consequently, the sequence has to be repeated with different settings of the phase-encoding gradient G_y .
- To construct a 256 x 256 pixels image a pulse sequence is repeated 256 times with only the phase encoding gradient changing.
- A Fourier transformation allows phase information to be extracted so that a pixel (x, y) in the slice can be assigned the intensity of signal which has the correct phase and frequency corresponding to the appropriate volume element. The signal intensity is then converted to a grey scale to form an image.



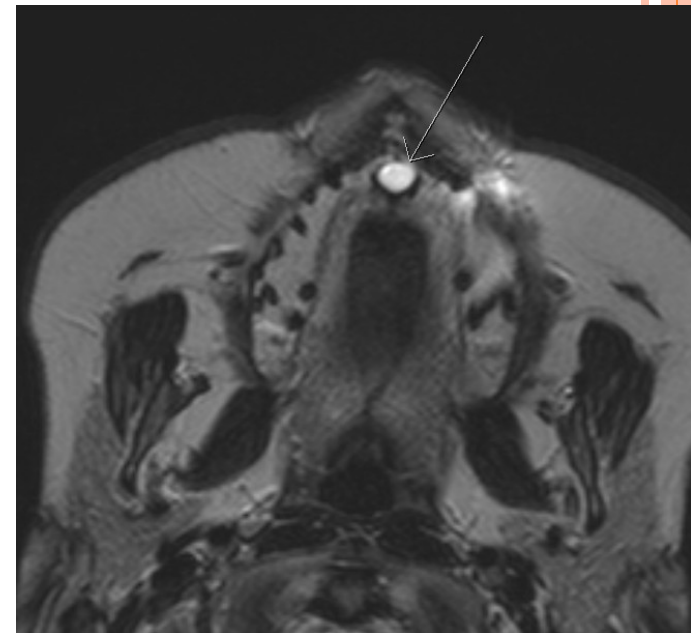
MR AND METALLIC DENTAL MATERIALS

- Different grade of artifacts according to the material used
- It depends mainly on material susceptibility (pronounced in amalgam, titanium, less nickel-chromium or cobalt-chromium)
- So if it can be removed, then take off before the examination



MR IN STOMATOLOGI

- The most common use is in temporomandibular joint diseases
 - Pseudodynamic sequences are used
- Ameloblastoma
- Osteomyelitis
- Dif.dg. Cystic lesions
- Range of hemangiomas, spread of tumors in general
- Localization of the neurovascular bundle before planning potential sites for implants



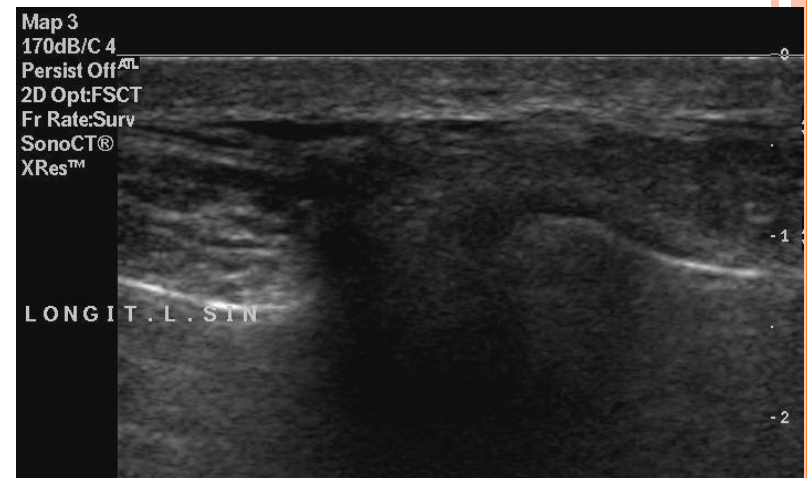
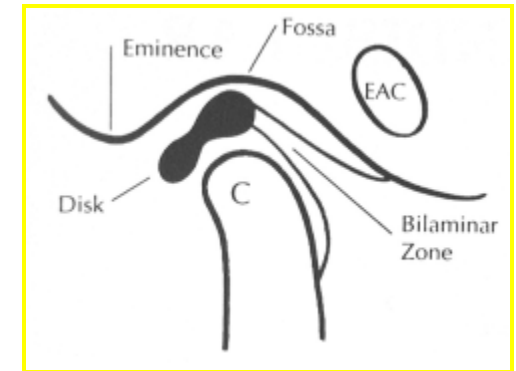
DISEASES OF THE TEMPOROMANDIBULAR JOINT

- dysfunctional syndrome
- inflammatory and degenerative changes
- iatrogenic lesions (repeated injections of steroids)
- M. Paget
- Gout
- Tumors
- osteochondritis dissecans (avaskular necrosis)
- Pigmented vilonodular synovitis
- Ankylosis of TMJ
- Hyperplasia of processus coronoideus



INTRACAPSULAR DISEASE = DISCOPATHY

- Discus articularis – an important part of the temporomandibular joint
- Disc – biconcav fibrocartilage structure dividing the joint into the upper and lower compartments
- The correct position prevents damage to the mandible
- The movement of the disc is limited by a strong rear ligament
- Dorsal part - neurovascular structures = retrodiscular tissue (bilaminar zone)



DISKOPATHY

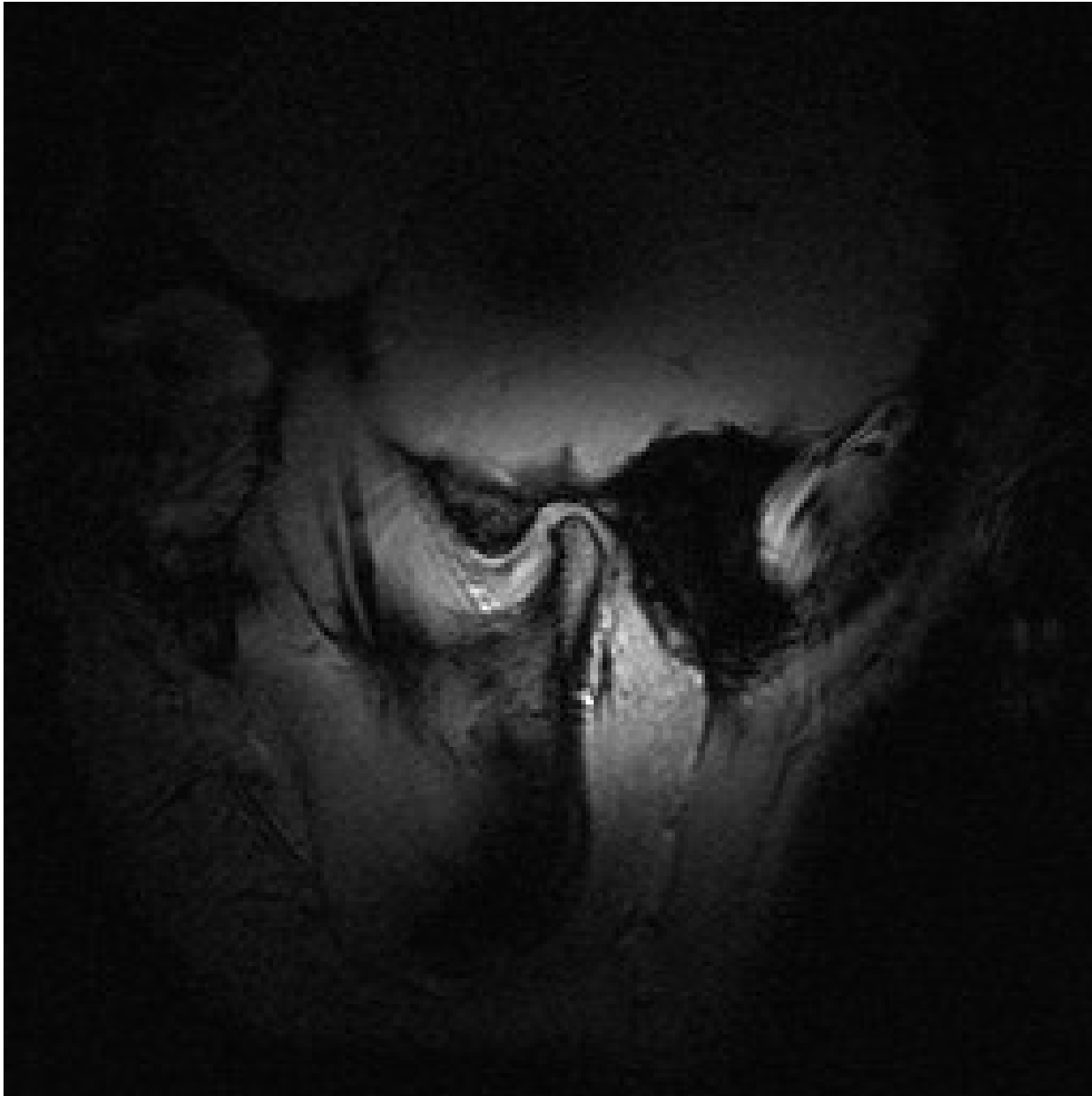
- due to the pathological location of the articular disk or the adhesion of the disc
- **disc dislocation with repositioning:** the disk is dislocated at rest (most often anterior to the joint head), in the movement is repositioned, asymmetric opening, sound phenomena (most often in the sense of clicking), eventually. with the presence of pain. There is no limitation of opening mouth
- **disc dislocation without repositioning:**
the disk is dislocated, but it does not reposition, the movement of the joint is so limited. In addition to limited opening, pain may be present, but no sound phenomena are present.

Adhesion of intraarticular disc:

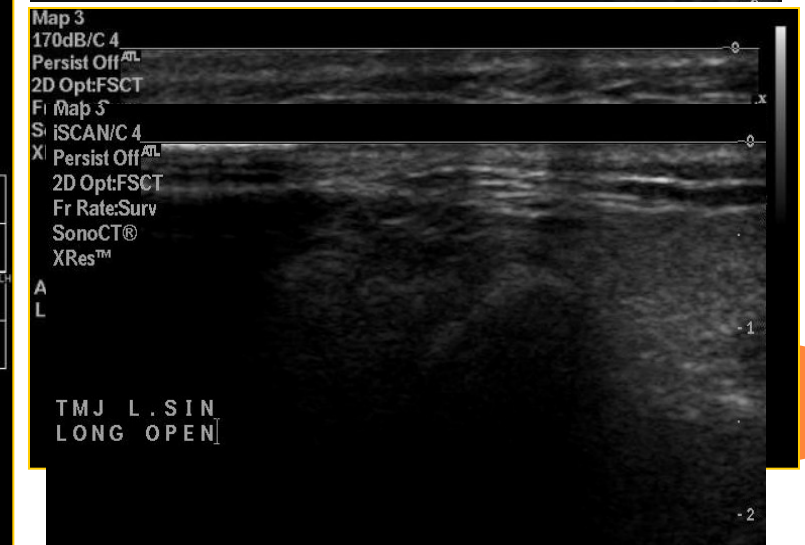
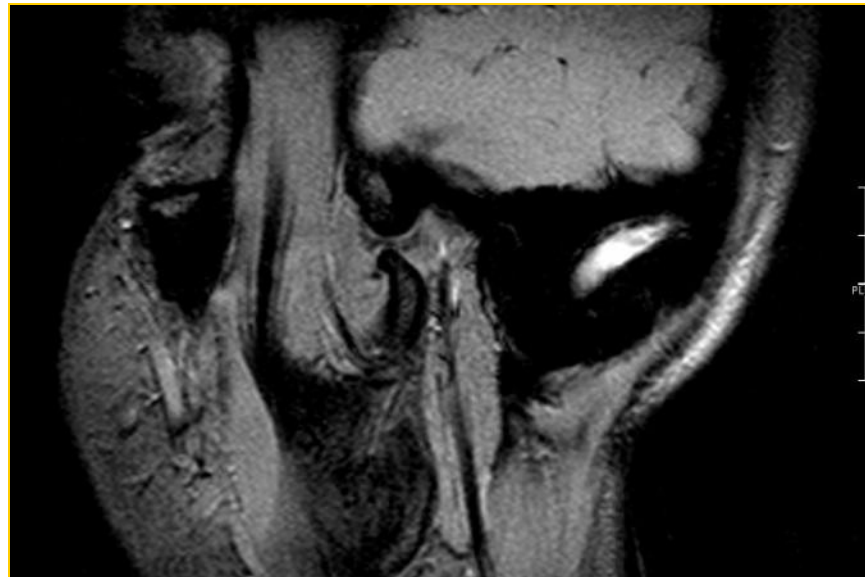
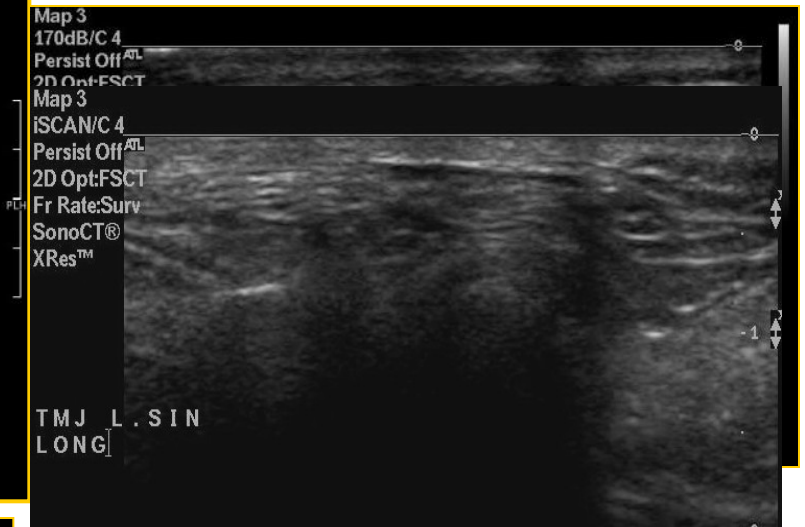
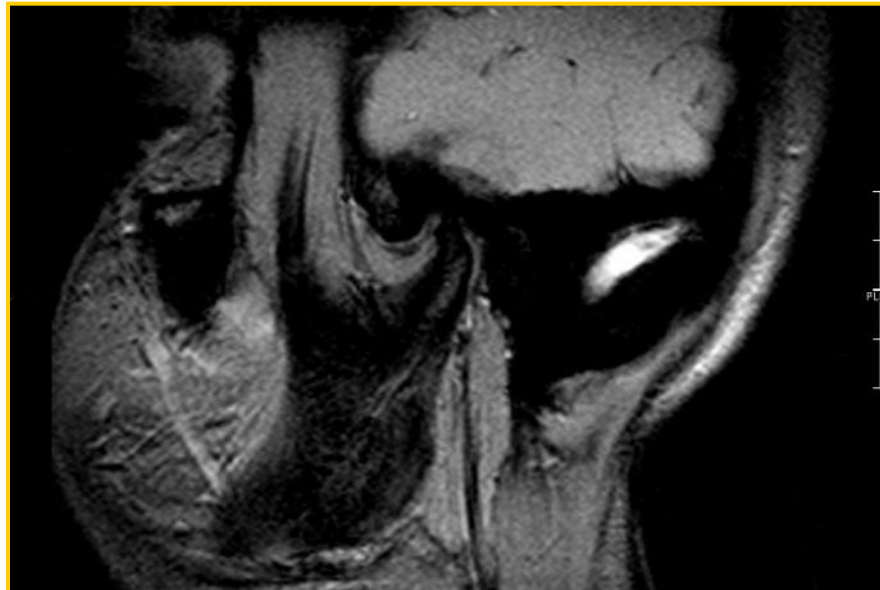
the disk is at rest in the correct, physiological, position, however its mobility is limited. The reduction of the opening of the mouth is characteristic.



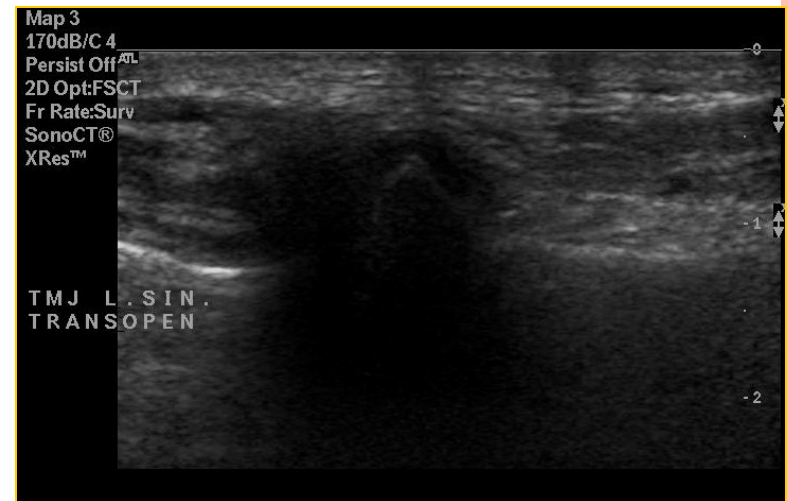
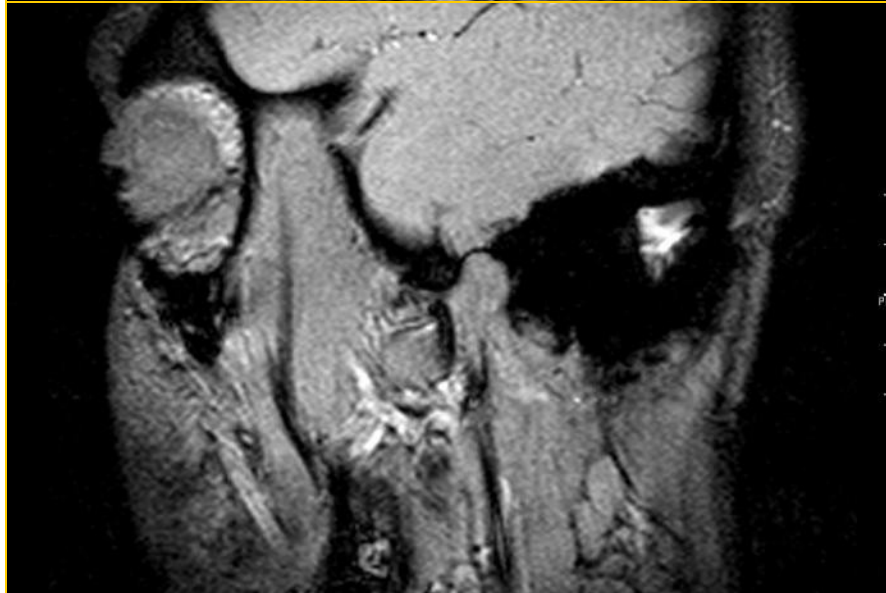
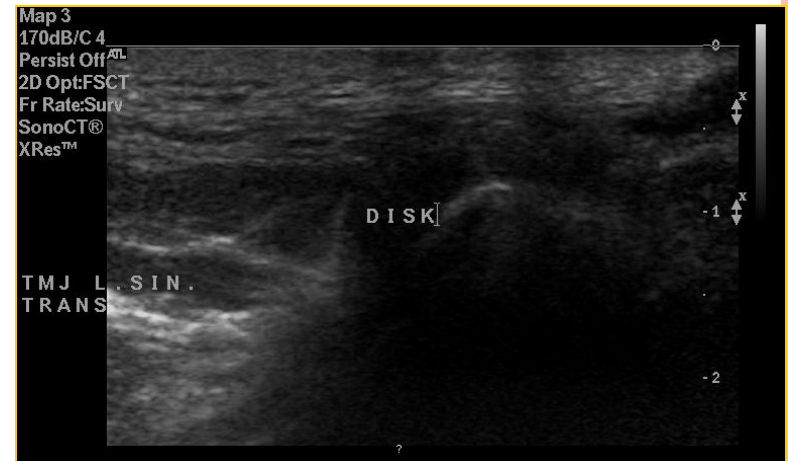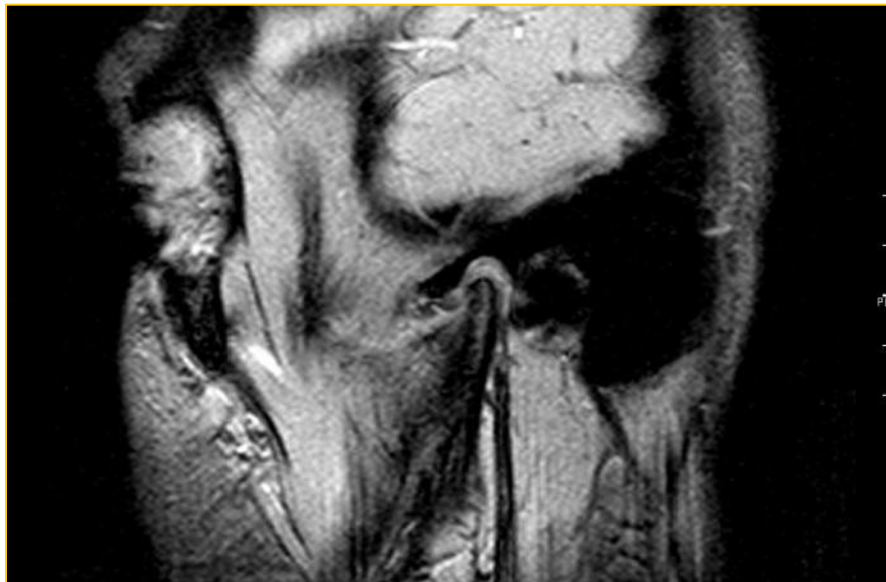
MRI PSEUDODYNAMICLY



18 YEAR OLD PATIENT WITH DD WITH REPOSITION



17 YEAR OLD PATIENT WITH DD WITHOUT REPOSITION

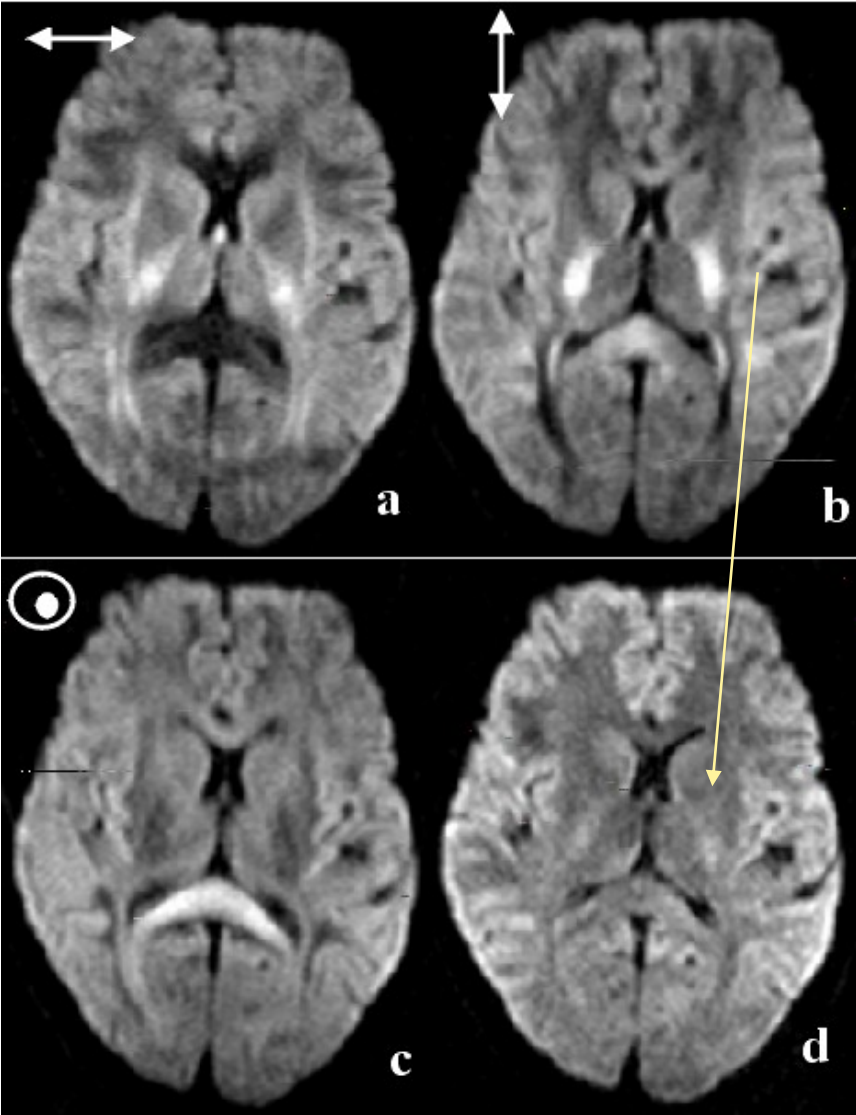


DWI – DIFFUSION-WEIGHTED IMAGING

- Diffusion - Random movement of water molecules in the tissue (Brown's motion)
- The degree of diffusion often differs between individual tissues or between healthy and pathological tissues
- The MR imaging of diffusion adds additional diagnostically valuable information.



Diffusion imaging in different directions

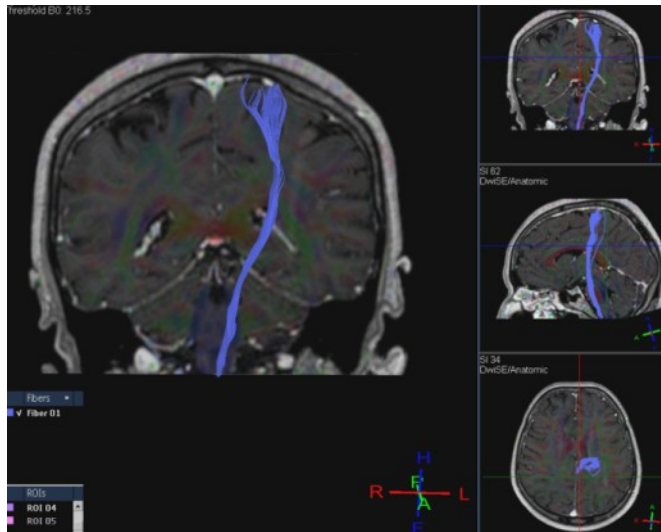


DTI –DIFFUSION TENSOR IMAGING

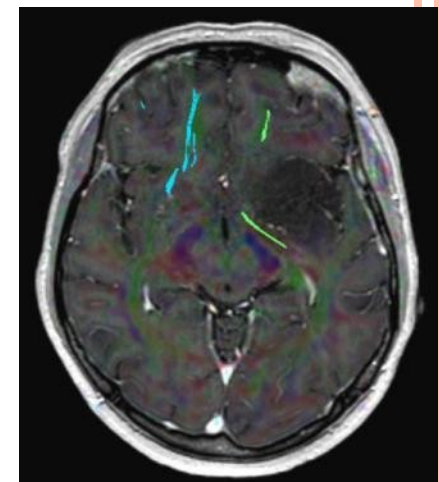
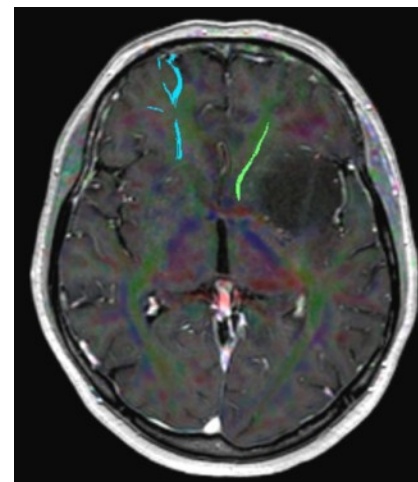
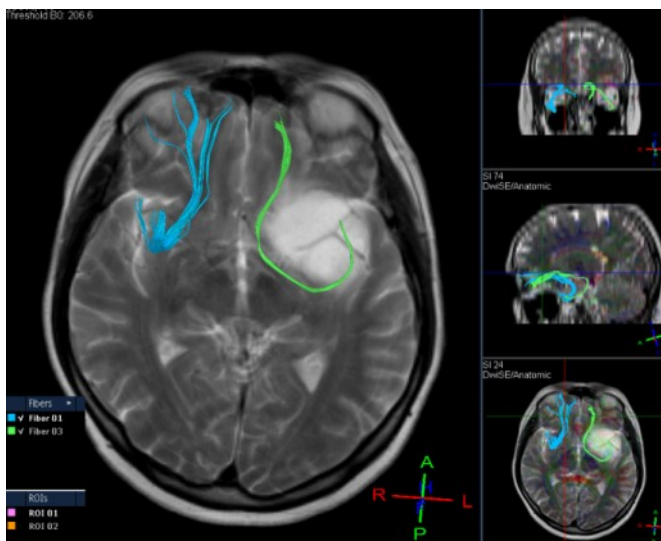
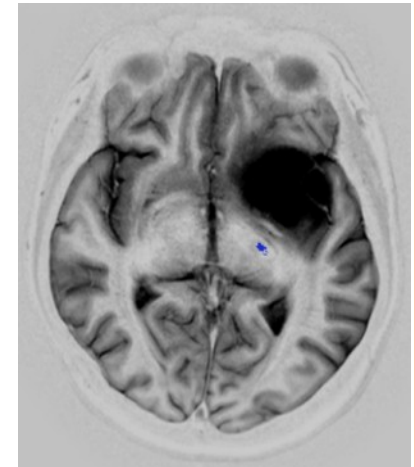
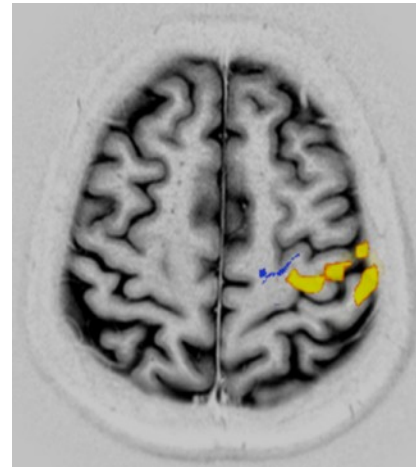
- Method based on DWI principles
- Anisotropy of diffusion in the white matter of the brain and spinal cord: the movement of water molecules proceeds more easily along the nerve fibers
- The intensity of the DWI image signal depends on the direction of the additional magnetic gradient used
- By repeated measurement with different diffusion directions we can detect the dominant direction of diffusion → the course of the nerve pathways



DTI FIBERTRACKING: GLIOMA GR. II

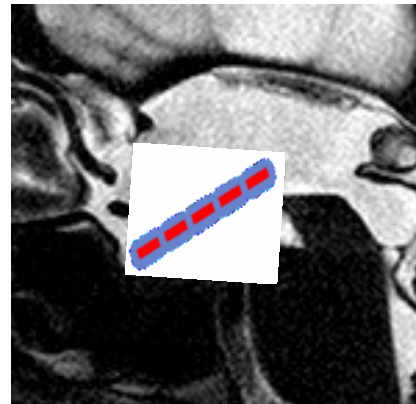
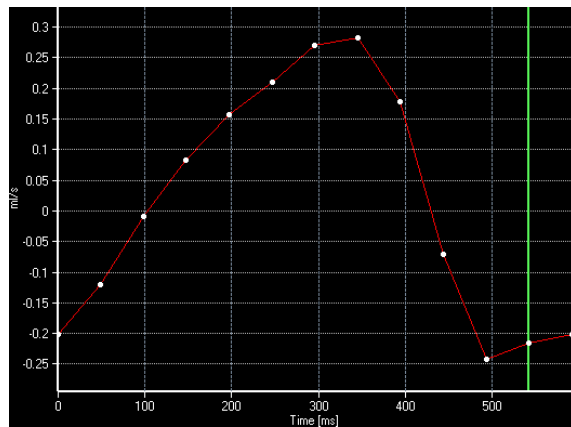
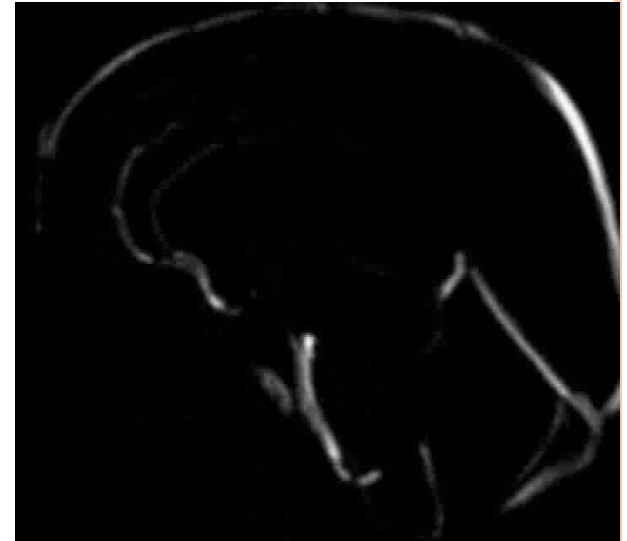
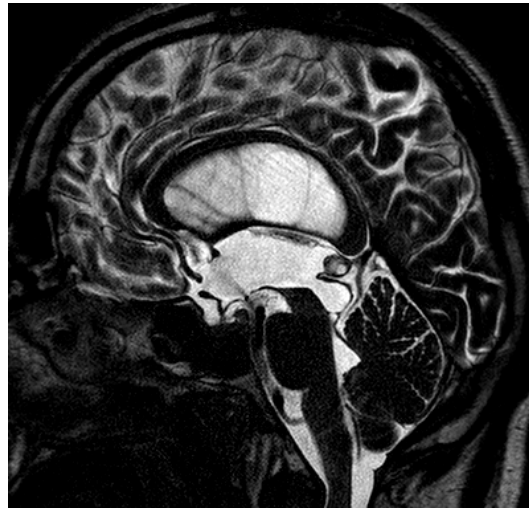
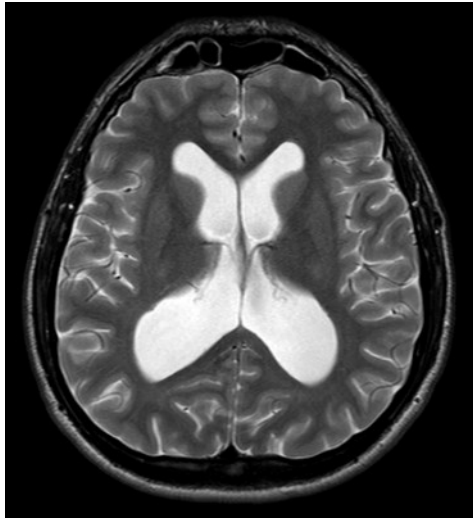


Tractus corticospinalis



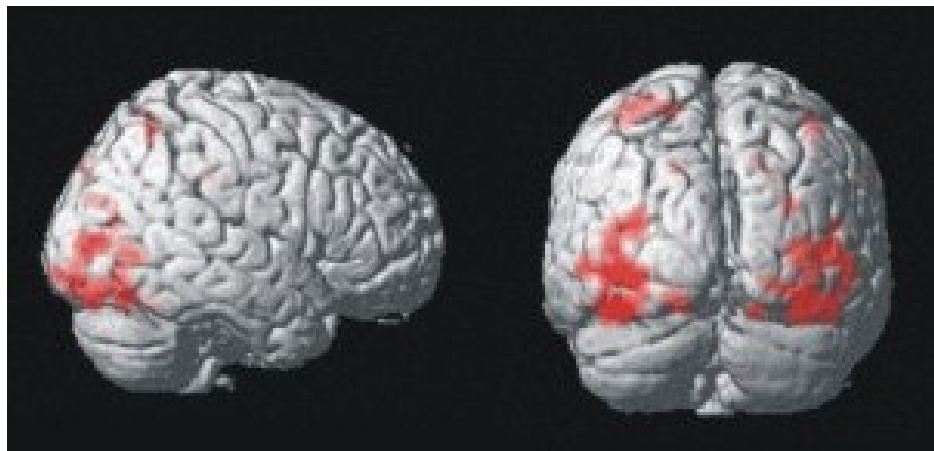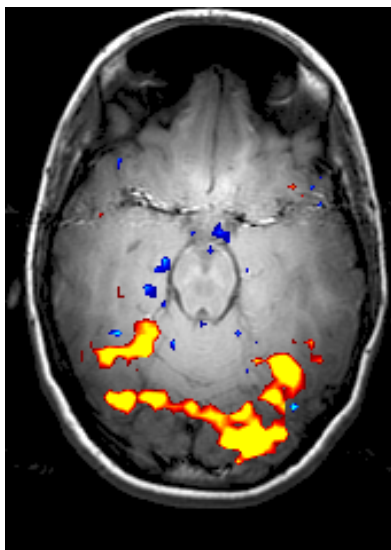
Fasciculus arcuatus

PCA: CSF CIRCULATION MEASUREMENT



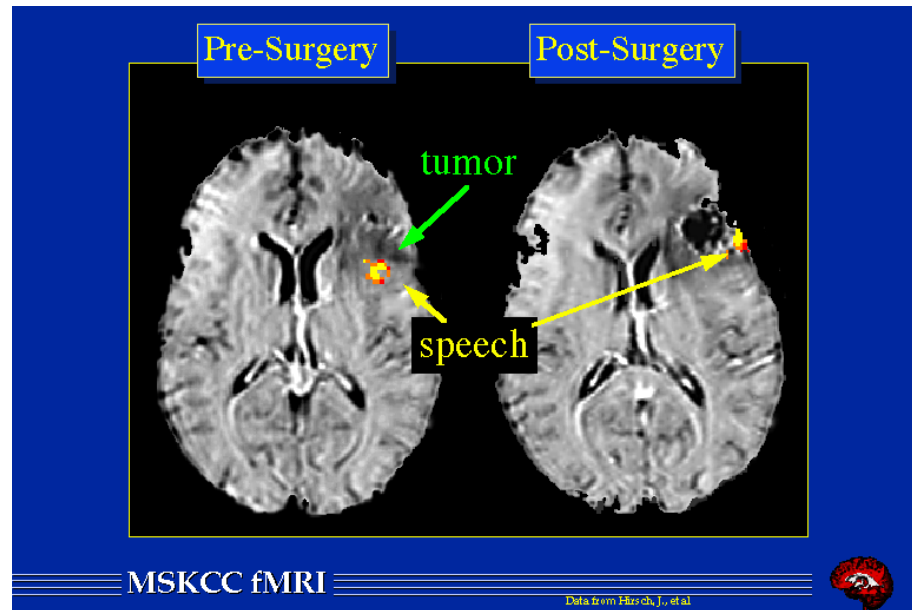
FUNKČNÍ MR

- It enables the resolution of active and inactive brain tissue regions by detecting changes in deoxyhemoglobin concentration occurring during activation
- Measurement is performed repeatedly at rest and during activation - the patient performs some specific action



POSSIBLE APPLICATIONS fMRI

Neurosurgery - Preoperative mapping of the location of important centers



1)The figure on the left shows the situation before the operation: The speech center activity during the verbal test is located in the immediate vicinity of the tumor mediodorsally

2)In the figure on the right, a postoperative state is visible: The activity area during the speech center remains intact near the bed after tumor resection. No verbal function deficit was found in the patient after surgery.

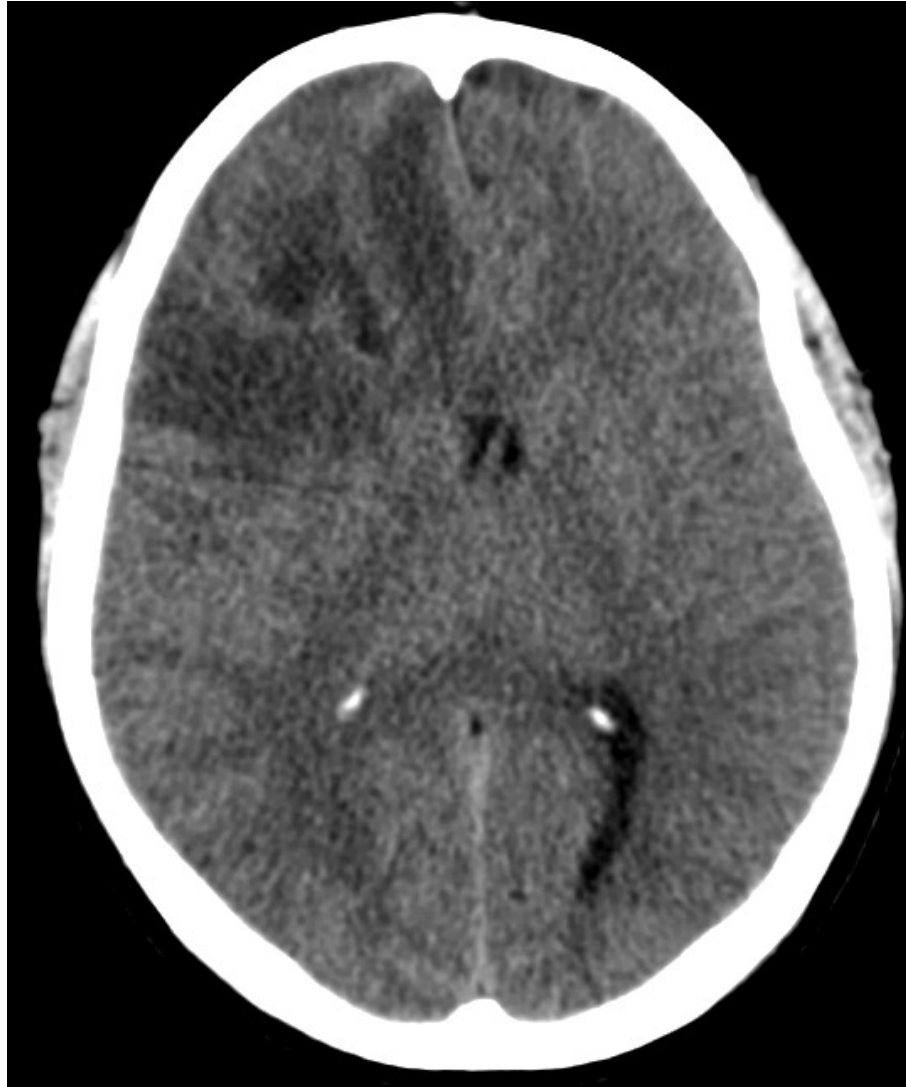


CASE – MEN *1979

- Personal anamnesis: hypertension, smoker
- Before two weeks purulent pouch in the oral cavity, self-emptying, since then but chills.
- now a few days of headache
- For headaches and prefrontal syndrome examined for CT

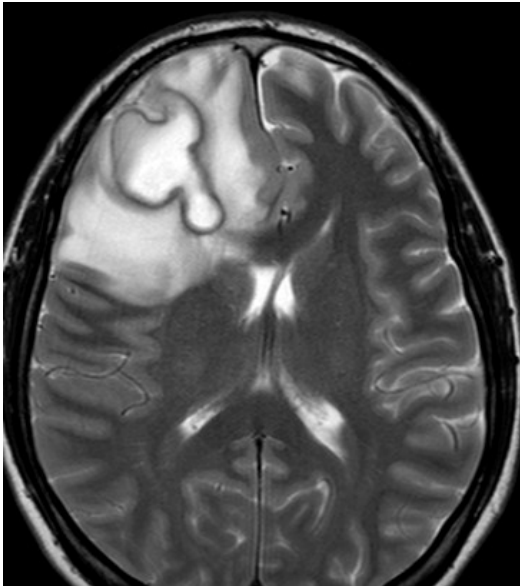


CT

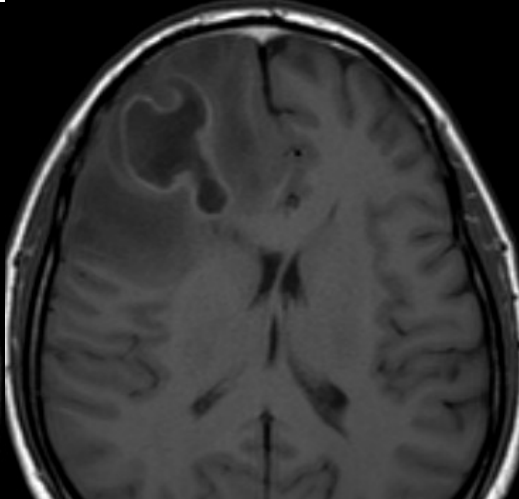


MR

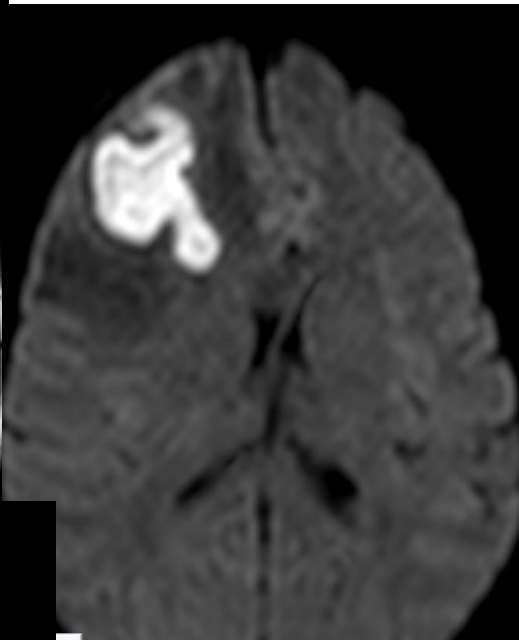
T2



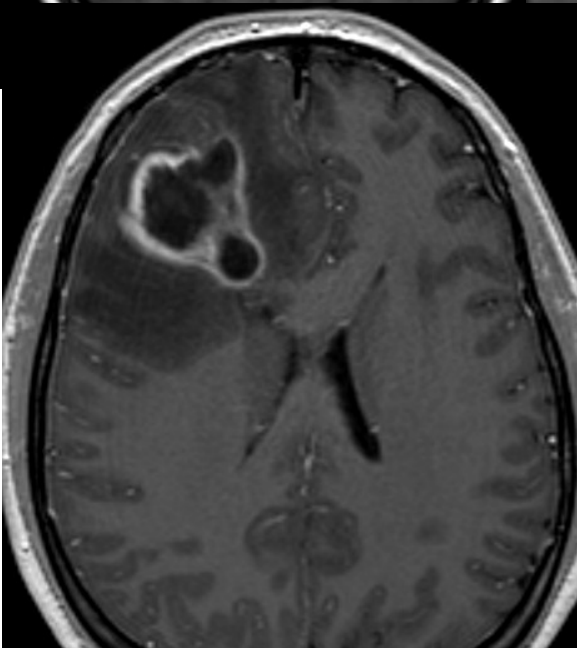
T1



DWI



T1 +
contrast



DG.

- Brain absces
- He underwent neurosurgical evacuation

Thanks for your
attention

