









## Nursing care of a newborn with epidermolysis bullosa: a case report

Cuidados de enfermagem a neonato com epidermólise bolhosa: relato de caso

Cuidados enfermeros al neonato con epidermólisis bullosa: relato de caso

### How to cite this article:

Secco IL, Costa T, Moraes ELL, Freire MHS, Danski MTR, Oliveira DAS. Nursing care of a newborn with epidermolysis bullosa: a case report. Rev Esc Enferm USP. 2019;53:e03501. DOI: <http://dx.doi.org/10.1590/S1980-220X2018023603501>

-  Izabela Linha Secco<sup>1</sup>
-  Taine Costa<sup>2</sup>
-  Etiene Letícia Leone de Moraes<sup>3</sup>
-  Márcia Helena de Souza Freire<sup>3</sup>
-  Mitzy Tannia Reichembach Danski<sup>3</sup>
-  Daniele Alaide de Siqueira Oliveira<sup>4</sup>

<sup>1</sup> Universidade Federal do Paraná, Programa de Pós-Graduação em Saúde da Criança e do Adolescente, Curitiba, PR, Brazil.

<sup>2</sup> Universidade de São Paulo, Escola de Enfermagem/Escola de Enfermagem de Ribeirão Preto, Programa Interunidades de Doutorado em Enfermagem, Ribeirão Preto, SP, Brazil.

<sup>3</sup> Universidade Federal do Paraná, Programa de Pós-Graduação em Enfermagem, Curitiba, PR, Brazil.

<sup>4</sup> Hospital Infantil Waldemar Monastier, Campo Largo, PR, Brazil.

### ABSTRACT

**Objective:** To describe a case of epidermolysis bullosa occurring in a children's hospital in the South of Brazil, evidencing the nursing care provided to this newborn diagnosed with this pathology. **Method:** A case study with data collection from medical records, approved by the Institution and by the Research Ethics Committee with Human Beings. **Results:** After the diagnostic confirmation, a specific care plan was established for the newborn, encompassing basic human needs to the clinical treatment of the disease. **Conclusion:** The neonate was discharged with shorter hospitalization time and with total epithelization of the lesions, despite the severity. The family actively participated in the care process, demonstrating the ability to perform the dressings at home.

### DESCRIPTORS

Infant, Newborn; Epidermolysis Bullosa; Critical Care Nursing; Neonatal Nursing; Bandages; Patient Care Planning.

### Corresponding author:

Izabela Linha Secco  
Rua XV de Novembro, 3701, Bom Jesus  
CEP 83601-030 – Campo Largo, PR, Brazil  
[izabelasecco\\_enf@hotmail.com](mailto:izabelasecco_enf@hotmail.com)

Received: 06/08/2018  
Approved: 02/21/2019

## INTRODUCTION

Epidermolysis bullosa (EB) is a group of phenotypically different, hereditary or acquired genodermatoses characterized by skin fragility and subsequent blistering in response to mechanical trauma, which can also affect the mucous membranes. Due to the severe forms of the disease and its high risk of infection, the neonatal mortality rate is high<sup>(1)</sup>.

EB can be classified into four main types based on the histopathological finding of the blisters: simple, junctional, dystrophic and Kindler. In the first three forms, the tissue separation occurs at the intraepidermal, lamina lucida and dense lamina level, respectively. Kindler's syndrome is a mixed type with multiple cleavage planes. The different degrees of vulnerability of the skin are caused by mutations in structural proteins involved in adhesion of the basal membrane zone<sup>(2)</sup>.

The management of EB lesions is a challenge within Medicine due to the complexity and variety of its manifestations. In addition, the dressing choice should be made according to the characteristics of the lesions, classified as dry or very exudative, colonized and infected, evaluating pruritus and pain, in addition to hypergranulated areas<sup>(3)</sup>.

The objective of this paper is to report a case of a newborn (NB) with EB which occurred in a children's hospital in the southern region of Brazil, evidencing the nursing care provided to a neonate diagnosed with this pathology.

## METHOD

### STUDY DESIGN

The methodology adopted for developing this study was a case report, considered as an important source of information which can provide fundamental subsidies for the best treatment of patients in certain situations. The communication of these reports is pertinent when the diagnosed entity is rare, the treatment is pioneering or has some innovation, or the result is unusual<sup>(4)</sup>.

### SCENARIO

The present study was carried out in a children's hospital in the metropolitan region of Curitiba, equipped to attend children between 0 and 18 years of age. This hospital has surgical and clinical hospitalization units, a Neonatal Intensive Care Unit (NICU), a Pediatric Intensive Care Unit (PICU), and Surgical Center (SC), laboratory, breast milk collection room, imaging center and outpatient clinic of medical specializations.

Hospitalization of the NB occurred in the NICU type III, which has 20 active beds, receives patients from the entire state of Paraná, and has a multidisciplinary team composed of nurses, nursing technicians, physicians, physiotherapists, speech therapists, social work and psychology to provide comprehensive care.

### SELECTION CRITERIA

The NB in question was chosen for the present study for having a medical diagnosis of EB and being hospitalized in the NICU in the year 2017.

## DATA COLLECTION

Data were collected from the patient's medical file between February and April 2018.

## DATA ANALYSIS AND TREATMENT

The data analysis occurred in a descriptive way through photos and information obtained from the patient's medical file.

## ETHICAL ASPECTS

This project was approved by the Ethics Committee of the Worker Hospital of Curitiba, under the opinion number 1.698.784/16, respecting the ethical precepts of Resolution 466 of 2012<sup>(5)</sup>. The research was approved by the Clinical Board and the Teaching and Research Center of the referred hospital and disclosure of the images was authorized by the parents through signing the Informed Consent Form (ICF).

## RESULTS

### CASE REPORT

Mother 28 years old, second pregnancy and second birth, seven prenatal consultations, O<sup>+</sup> blood type, non-reactive VDRL (Venereal Disease Research Laboratory) and HIV, immune to toxoplasmosis. No complications during pregnancy.

Patient NNBOH, born on April 1, 2017, at 15:27, male, Parkin 38 weeks, cesarean delivery, weighing 3.280 kg, Apgar 9/10, in good general condition, but skin blisters were observed at birth, some with bullous areas and others devoid of epidermis. The patient was diagnosed with EB, referred to joint accommodation, remained hospitalized until April 4, 2017, and on those three days he underwent umbilical venous catheterization for analgesia and hydro-electrolytic replacement, but he evolved with clinical worsening of the lesions, as they became more exudative with increased extension, depth and quantity. In addition, there was refusal of oral feeding due to lesions on the gums, palate and lip mucosa. Due to the difficulty of managing the newborn at the hospital of origin, a vacancy was requested by the Bed Central of Paraná to the NICU of the children's hospital, and the NB was admitted on April 4, 2017, at 4:30 p.m.

During the hospitalization period, the following medical diagnoses were presented: term newborn, suitable for gestational age, EB, and late sepsis by coagulase-negative staphylococci (CoNS).

Once admitted, he was put in a warm crib with electrolyte replacement by the umbilical venous catheter, as well as pain control by continuous Fentanyl. As there was worsening of bullous lesions and the initial appearance of areas with blisters, the care nurses opted for simple coverage with sterile vaseline (Rayon) gauze soaked in essential fatty acids (EFAs).

After 24 hours of hospitalization, the umbilical venous catheter had overflowed flush solution and continuous pump infusion, requiring a discussion regarding a new central venous catheter (CVC). As predicted in the literature, it was agreed to insert a CVC in the cephalic region, since it was the site with the most preserved epidermis. Therefore, a French caliber 1 peripherally inserted central catheter was inserted into the right temple, remaining until the end of the intravenous therapy (withdrawn on May 3<sup>rd</sup>). Peripheral blood cultures were collected on April 14 and 18 and CoNS was positive, considered late sepsis related to the use of CVC. However, this was maintained for the Vancomycin treatment for 12 days, since it was the only venous access available, and there were lesions around it, which could induce colonization and infection of the intravenous device.

Due to the involvement of the oral mucosa and esophagus pathology, the newborn had low oral acceptance of the diet, requiring nasogastric catheterization. The patient was followed up by a speech therapist daily, who replaced the silicone orthodontic nozzle with latex, aiming at malleability for suction and milk extraction.

The standardized Neonatal Infant Pain Scale (NIPS) was applied at the institution to the NB, and scores indicative of pain were measured between four and seven. Due to the large extent of the affected epidermis, the NB's crying was vigorous both at rest and in handling, and his facial expression was always contracted. His upper and lower limbs remained uninterruptedly contracted and always uncomfortable in a state of consciousness. The NB did not require ventilatory support during the hospitalization period because his breathing scored the least due to having minimal respiratory distress.

Due to the characterization of pain, analgesia needed to be optimized to offer comfort to the child. Paracetamol and Codeine were then associated with intermittent Fentanyl, even with intravenous Dipirone support, if necessary. Ketamine was also specifically administered for changing the NB's dressings at bedside. As days passed and according to the NB's drug tolerance, it was necessary to suspend Fentanyl and Paracetamol, to maintain Codeine and to associate it with Morphine. Oxcarbazepine was also associated according to the neurologist's guidance.

Under the guidance of a stomal therapist, care nurses replaced the lesion dressings with EFA by more technological dressings available at the Unified Health System. Such dressings are considered special because they are self-adhesive and decrease pain in the lesion as they are composed of soft silicone and stimulate healing by maintaining the ideal moisture environment, in addition to being atraumatic.

The dressings were performed at bedside in the first days every 48 hours, with previous sedation and analgesia, fulfilling the protocols of maximum sterility. However, it was observed that the procedure was intensely painful, and it was not possible to increase analgesia due to risk of cardiorespiratory arrest, since the newborn was in open

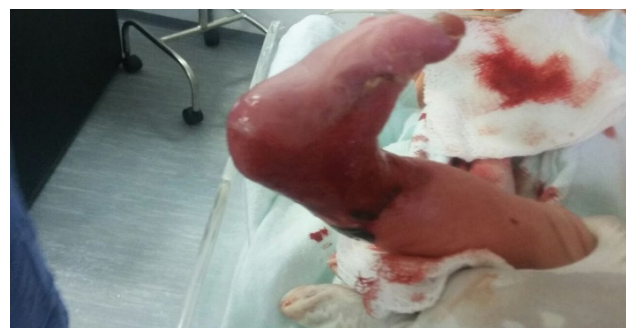air and any need for orotracheal intubation would cause serious damage to the mucous membranes by fixing the device to the skin and from the friction of the cannula on the gums, palate and oral mucosa. Also, the strict anti-sepsis standards were not being met because the child had extreme psychomotor agitation from pain, and the primary dressing was difficult to keep on the lesions. This situation referred to a minimum procedure time of 2 hours.

Therefore, after discussions with the multidisciplinary team, the dressings began to be performed in the SC under inhalation anesthesia starting on April 12<sup>th</sup>, offering the maximum comfort for the patient. The procedure time decreased to 30 minutes, and the dressings remained for more days, thus enabling weekly changes.

The lesions during the first dressing change in the SC were superficial on the face, neck, thorax and abdomen, presenting granulation tissue in 90% of the affected areas, and the remaining 10% had crusts, in addition to a medium level of serosanguineous exudate. In the facial region, a perforated polyurethane screen with a silicone layer was applied for aid and protection in fixing the medical devices such as the nasogastric catheter. The thoraco-abdominal region was covered with a thin polyurethane foam in order to stimulate healing and protect against local physical trauma. A tubular mesh was used as a secondary cover, which is composed of an elastic tissue which enables attaching the primary dressing to the lesions without causing traumas by adhesion, dispensing bandages and adhesive tapes.

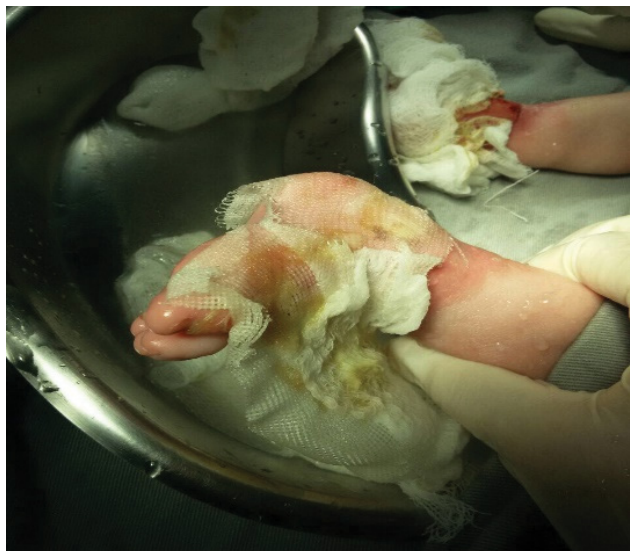However, lesions in the upper and lower limbs were more severe. Some were bullous with hemorrhagic content, others were already ruptured with deep dermal involvement, the presence of a moderate level of purulent exudate, areas with adhered crusts and abundant bleeding.

The initial action was rupturing the blisters with a 13 x 0.45 mm needle and draining its contents, cleaning the area with warmed 0.9% saline solution and applying exudate transfer foam with silicone. Care was also taken to separate the fingers and toes with the same dressing to avoid synechiae, a very common event in this pathology. This step was also completed using tubular mesh.



Source: The authors.

**Figure 1** – Coagulation necrosis in the right inner limb.



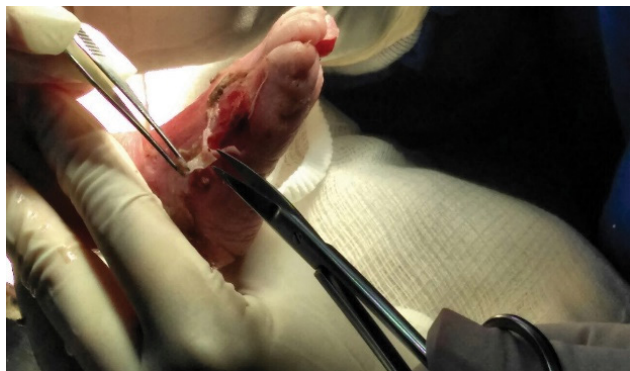Source: The authors.

**Figure 2** – Exudative lesions on lower limbs.

In continuing the topical use of these materials, debridement was indispensable in some lesions due to the involvement of coagulation necrosis and hyperkeratosis regions. Hydrogel was applied for the gradual withdrawal of the most adhered necrotic contents, and mechanical removal was performed for the lesions with partial or advanced detachment of the dead tissue.

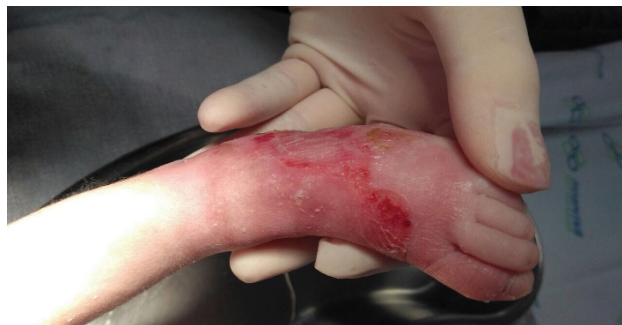A gradual improvement of the lesions was observed during the weekly changes, and the dressings were again performed at the bedside starting from April 27<sup>th</sup>. There were already epithelialized areas in the thorax and abdomen at this stage of treatment, and decreased depth in the upper and lower limb lesions, as well as epithelialized areas.

The last dressing change in the NICU occurred on May 3<sup>rd</sup>, with significant epithelialization in 90% of the lesions on the hands, 60% on the feet and absence of new hemorrhagic blisters. Thus, the infant was discharged to the clinical ward after 32 days of hospitalization in the NICU, with referrals to Baby Risk Offices, Dermatology, Orthopedics and Physiotherapy, and being administered Codeine and Oxcarbazepine. He is currently attending outpatient clinics once a month.



Source: The authors.

**Figure 3** – Surgical debridement in the lower left limb.



Source: The authors.

**Figure 4** – Complete epithelialization of the lesion in the lower left limb.

The NB's family was empowered and inserted in all care phases throughout the treatment, including during bedside dressings, with access to the lesion pictures and to the comparisons of weekly improvement. The mother was able to perform all the necessary care that EB demands upon hospital discharge, including changing the dressings with the help of the father. The stomal therapist who followed the case was present at the family home in the first two weeks of discharge, assisting and advising the parents to perform the dressings so that they would feel more secure to do so.



Source: The authors.

**Figure 5** – Performance of the dressing by the mother at home.

## NURSING DIAGNOSES AND PRESCRIPTIONS FOR EB

In view of the severity of the pathology and the risk of death, it was fundamental to build a systematized work process so that the NB was provided care for all its needs.

Thus, the Nursing Diagnoses according to the North American Nursing Diagnosis Association (NANDA)<sup>(6)</sup>, as well as the interventions prescribed to the NB and his family are presented below.

### DOMAIN 2 – NUTRITION

#### – **Diagnosis: Ineffective infant feeding pattern.**

Definition: an infant's impaired ability to suck or coordinate the sucking/swallowing response, resulting in inadequate oral nutrition for metabolic needs.

Defining characteristic: inability to maintain effective suction.

Related factor: Oral Hypersensitivity.

Nursing prescriptions: perform enteral catheterization; administer the diet according to medical prescription and monitor oral diet acceptance and tolerance to enteral volume progression.

#### – **Diagnosis: impaired deglutition.**

Definition: abnormal functioning of the swallowing mechanism associated with a deficit in oral, pharyngeal or esophageal structure or function.

Defining characteristics: ineffective sucking, difficulty swallowing.

Related factor: Oropharyngeal abnormalities.

Nursing prescriptions: administer an oral diet in proclivity and observe swallowing and mouth emptying.

#### – **Diagnosis: unstable glycemic risk.**

Definition: vulnerability to fluctuating glucose/blood sugar levels relative to normal variation, which may compromise health.

Risk factors: excessive stress, insufficient food intake.

Nursing prescriptions: monitor diet acceptance and avoid stressful situations to the NB.

#### – **Diagnosis: risk of electrolyte imbalance.**

Definition: vulnerability to changes in serum electrolyte levels which could compromise health.

Risk factor: insufficient liquid volume.

Nursing prescriptions: administering prescribed supplemental electrolytes; perform a rigorous water balance; monitor electrocardiogram tracings and report episodes of nausea, emesis and diarrhea.

#### – **Diagnosis: risk of unbalanced liquid volume.**

Definition: vulnerability to the decrease, increase or rapid change from one location to another of intravascular, interstitial and/or intracellular fluid, which may compromise health. It refers to the loss, gain, or both, of bodily fluids.

Risk factor: burn and sepsis.

Nursing prescriptions: monitor acceptance of diet; monitor weight, body temperature, volume and urine

concentration; perform rigorous water balance and consider additional losses associated with vomiting, diarrhea and hyperthermia.

#### – **Diagnosis: risk for constipation.**

Definition: vulnerability to a decrease in the normal frequency of evacuation, accompanied by difficulty to eliminate feces or incomplete feces elimination, which may compromise health.

Risk factors: electrolyte imbalance, pharmacological agents.

Nursing prescriptions: monitor intestinal eliminations: frequency, consistency, shape, volume and color; monitor signs of constipation and identify factors which may contribute to constipation.

### DOMAIN 4 – ACTIVITY/REST

#### – **Diagnosis: impaired sleep pattern.**

Definition: interruptions, limited by time, amount and quality of sleep, due to external factors.

Defining characteristics: change in sleep pattern and unintentional arousal.

Related factors: environmental barrier (noise, luminosity, temperature), non-restorative sleep pattern.

#### – **Diagnosis: sleep deprivation.**

Definition: prolonged periods without sleep (sustained natural and periodic suspension of relative consciousness).

Defining characteristics: agitation, irritability, increased sensitivity to pain.

Related factors: overly stimulating environment, prolonged discomfort.

#### – **Diagnosis: impaired comfort.**

Definition: perception of a lack of comfort, relief and/or transcendence in the physical, psychospiritual, environmental, cultural and/or social dimensions.

Defining characteristics: change in the sleep pattern, crying, restlessness, irritability.

Related factors: harmful environmental stimuli.

The nursing prescriptions for the three diagnoses above were: perform restricted and block handling; perform environmental control: reduce noise and lighting; record the sleep pattern of the newborn, the quality and quantity of sleeping hours and administer analgesia according to medical prescription and the pain scale.

#### – **Diagnosis: impaired mobility in the bed.**

Definition: movement limitation from one position to another in the bed.

Defining characteristics: Impaired ability to turn from side to side.

Related factors: pain, musculoskeletal impairment.

Nursing prescription: change in decubitus every 4 hours.

#### – **Diagnosis: ineffective respiratory pattern.**

Definition: inspiration and/or expiration that does not provide adequate ventilation.

Defining characteristics: nostrils flaring, abnormal respiratory pattern (frequency, rhythm and depth).

Related factors: pain.

Nursing prescription: avoiding painful stimuli and stressor factors.

## DOMAIN 7 – ROLES AND RELATIONSHIPS

### – **Diagnosis: impaired paternity or motherhood.**

Definition: inability of the primary caregiver to create, maintain or recover an environment that promotes optimal growth and development of the child.

Defining characteristics: inadequate skills for care, perceived incapacity to satisfy the needs of the child.

Related factor: poor knowledge about child health maintenance.

Nursing prescriptions: insert the parents into all phases of the care process; offer psychological counseling and encourage parents to cope with the disease.

### – **Diagnosis: caregiver role stress.**

Definition: difficulty to perform the role of family caregiver/significant persons.

Defining characteristics: anxiety as to the future ability to provide care, worry about the future health of the care recipient.

Related factors: increased need for care, chronic illness, unpredictability of illness course, recent hospital discharge, care responsibilities 24 hours a day.

Nursing prescriptions: enable caregivers to change dressings at home and schedule future follow-ups at the institution's outpatient clinics.

## DOMAIN 9 – COPING/STRESS TOLERANCE

### – **Diagnosis: disorganized behavior of the infant.**

Definition: fragmented physiological and neurobehavioral responses of an infant to environmental stimuli.

Defining characteristics: impaired reaction to sensory stimuli (difficulty to calm down), restlessness, exaggerated reactions of fright, irritability, irritable crying, active arousal.

Related factors: excessive environmental stimulation, pain, impaired motor function, invasive procedures.

Nursing prescriptions: perform non-pharmacological interventions to calm the newborn; perform care with gentle movements and decrease sensory stimulation.

## DOMAIN 11 – SAFETY/PROTECTION

### – **Diagnosis: risk for infection.**

Definition: vulnerability to invasion and multiplication of pathogenic organisms, which can compromise health.

Risk factors: invasive procedures, change in skin integrity.

Nursing prescriptions: keep headboard elevated by 30 degrees; monitor the validity of invasive devices; perform the exchange of valid invasive devices and handle the CVC with aseptic technique.

### – **Diagnosis: risk for aspiration.**

Definition: vulnerability to the entry of gastrointestinal, oropharyngeal, solid or liquid secretions in the tracheobronchial tract, which may compromise health.

Risk factors: enteral feeding, impaired swallowing ability, presence of oral/nasal catheter.

Nursing prescriptions: administer the diet with the head high; confirm enteral catheter placement before administering the diet and observe swallowing and mouth emptying.

### – **Diagnosis: risk for shock.**

Definition: vulnerability to inadequate blood flow to the tissues of the body which can lead to life-threatening cellular dysfunction, which may compromise health.

Risk factors: hypovolemia, infection, sepsis.

Nursing prescriptions: recognize clinical signs and symptoms of infection; monitor vital signs, level of consciousness and urinary elimination, and monitor water status.

### – **Diagnosis: impaired skin integrity.**

Definition: altered epidermis and/or dermis.

Defining characteristic: change in skin integrity.

Related factors: mechanical factor (shear forces, pressure, physical immobility), change in fluid volume, inadequate nutrition.

Nursing prescriptions: perform rotation of the oximetry sensor positioning sites; perform dressings on the injured areas with appropriate topical medication; observe signs and symptoms of infection; moisturize whole skin with specific emulsion; maintain special silicone-based dressings under the catheter attachment and observe new lesions.

### – **Diagnosis: impaired oral mucosa.**

Definition: lesions on the lips, soft tissues, oral cavity and/or oropharynx.

Defining characteristics: impaired ability to swallow, mucosal detachment, oral pain, oral lesion, bleeding.

Related factors: mechanical factor (gastric catheter), infection.

Nursing prescriptions: inspect the mouth for lesions, inflammation or excessive bleeding; observe vomiting episode; report oral diet refusal; monitor difficulty in swallowing and administer diet via nasogastric catheter.

## DOMAIN 12 – COMFORT

### – **Diagnosis: acute pain**

Definition: unpleasant sensory and emotional experience associated with actual or potential tissue injury or described in terms of such injury; sudden or slow onset of mild to severe intensity, with an anticipated or predicted end.

Defining characteristics: expressive behavior (agitation, crying, restlessness), evidence of pain using the standardized checklist of non-verbal pain indicators (NIPS).

Related factors: biological injury agent (infection), physical injury agent (burn).

Nursing prescriptions: apply pain scale every four hours; assess pain regarding location, frequency, intensity, duration

and quality; monitor non-verbal pain indicators and monitor the level of discomfort.

## DISCUSSION

Being considered a specific Nursing tool, the Systematization of Nursing Care (SNC) is a scientific and methodological tool which assures the quality and planning of care management, since it enables the intervention which the patient needs to be individualized, leading to the best implementation method<sup>(7-8)</sup>.

Despite being divided into phases, "SNC application involves more than a sequence of steps to be followed, requiring the professional to be more familiar with the nursing diagnoses and sensitivity to adapt the client's needs to the working conditions, making them less simple than the theory suggests"<sup>(9)</sup>. Benefits are observed from implementing the nursing process, given the enabling of comprehensive care, exchanges of experiences, and knowledge expansion, thus facilitating the work<sup>(10)</sup>.

This was observed in the case report herein, since the care management facilitated and provided individuality in the nursing care to the NB, contributing to a decrease in the length of stay and allowing the parents to continue the care at home. For the multidisciplinary team, providing care to this NB allowed a search for scientific knowledge so that

adequate care could be taken, a challenge could be overcome, and an experience gained for future cases to be admitted to the institution.

Implementing the nursing diagnosis steps and prescription require nurses to have deep knowledge of their patients, in addition to a vast domain on the pathophysiology of numerous clinical conditions. In this way, it is imperative that this professional is undergoing continuous improvement so that the care provided reaches a level of excellence.

The main limitation of this study was the lack of a theoretical reference involving good care practices in neonatal EB with regard to the specific treatment of the lesions.

This case report aims to help nursing professionals during the care stages of EB so that it is holistic, timely and evidence-based, considering that the scientific publications on the subject are limited.

## CONCLUSION

Because of its singularity, EB requires specific and qualified care from the entire interdisciplinary team, aiming at patient survival. On the other hand, managing the lesions becomes a difference maker in the treatment when the nurse is scientifically and technically able to intervene through practice, leading the technical staff to provide the best care and enabling the family members for the patient's discharge.

## RESUMO

**Objetivo:** Descrever um caso de epidermólise bolhosa ocorrido em um hospital infantil do Sul do Brasil, evidenciando o cuidado de enfermagem ao recém-nascido diagnosticado com essa patologia. **Método:** Estudo de caso com coleta de dados em prontuário, aprovado pela Instituição e pelo Comitê de Ética em Pesquisa com Seres Humanos. **Resultados:** Depois da confirmação diagnóstica, foi estabelecido um plano de cuidados específicos para o recém-nascido, que englobou desde as suas necessidades humanas básicas até o tratamento clínico da doença. **Conclusão:** O neonato recebeu alta hospitalar com tempo de internação menor que o esperado e com epitelização total das lesões, apesar da gravidade. A família participou ativamente do processo de cuidado, demonstrando aptidão para realizar os curativos em domicílio.

## DESCRIPTORIOS

Recém-Nascido; Epidermólise Bolhosa; Enfermagem de Cuidados Críticos; Enfermagem Neonatal; Bandagens; Plano de Assistência ao Paciente.

## RESUMEN

**Objetivo:** Describir un caso de epidermolísis bullosa ocurrido en un hospital infantil del Sur de Brasil, evidenciando el cuidado enfermero al recién nacido diagnosticado con dicha patología. **Método:** Estudio de caso con recolección de datos en ficha, aprobado por el Centro y el Comité de Ética en Investigación con Seres Humanos. **Resultados:** Después de la confirmación diagnóstica, fue establecido un plan de cuidados específicos para el recién nacido, el que abarcó desde sus necesidades humanas básicas hasta el tratamiento clínico de la enfermedad. **Conclusión:** El neonato recibió alta hospitalaria con tiempo de estancia menor que lo esperado y con epitelización total de las lesiones, pese a la severidad. La familia participó activamente en el proceso de cuidado, demostrando aptitud para realizar los apósitos en domicilio.

## DESCRIPTORES

Recién Nacido; Epidermolísis Ampollosa; Enfermería de Cuidados Críticos; Enfermería Neonatal; Vendajes; Planificación de Atención al Paciente.

## REFERENCES

1. Sousa MCS, Paula CDR, Tauil PL, Costa IMC. Correlation between nutritional, hematological and infectious characteristics and classification of the type of epidermolysis bullosa of patients assisted at the Dermatology Clinic of the Hospital Universitário de Brasília. *An Bras Dermatol* [Internet]. 2015 [cited 2018 June 06]; 90(6):922-4. Available from: [http://www.scielo.br/scielo.php?script=sci\\_arttext&pid=S0365-05962015000600922&lng=en](http://www.scielo.br/scielo.php?script=sci_arttext&pid=S0365-05962015000600922&lng=en)
2. Floriani MA, Bau AEK, Silva RP, Graziadio C, Dorfman LE, Zen TD, et al. Applications of electron microscopy in health: the example of epidermolysis bullosa. *J Bras Patol Med Lab* [Internet]. 2017 [cited 2018 June 6]; 53(1):65-7. Available from: [http://www.scielo.br/scielo.php?script=sci\\_arttext&pid=S1676-24442017000100065&lng=pt](http://www.scielo.br/scielo.php?script=sci_arttext&pid=S1676-24442017000100065&lng=pt)

3. Corrêa FB, Coltro PS, Junior JAF. General treatment and wound management in hereditary epidermolysis bullosa: indication and experience using silver hydrofiber dressing. *Rev Bras Cir Plast [Internet]*. 2016 [cited 2018 Feb 17];31(4):565-72. Available from: <http://www.dx.doi.org/10.5935/2177-1235.2016RBCP0082>
4. Yoshida WB. Redação do relato de caso [editorial] *J Vasc Bras [Internet]*. 2007 [citado 2018 jan. 31];6(2):112-3. Disponível em: <http://www.scielo.br/pdf/jvb/v6n2/v6n2a04.pdf>
5. Brasil. Ministério da Saúde; Conselho Nacional de Saúde. Resolução n. 466, de 12 de dezembro de 2012. Aprova as diretrizes e normas regulamentadoras de pesquisa envolvendo seres humanos [Internet]. Brasília; 2012 [citado 2018 fev. 20]. Disponível em: <http://www.conselho.saude.gov.br/resolucoes/2012/Reso466.pdf>.
6. NANDA International. Diagnósticos de enfermagem da NANDA: definições e classificação 2015-2017. Porto Alegre: Artmed; 2015.
7. Silva JP, Garanhani ML, Peres AM. Systematization of Nursing Care in undergraduate training: the perspective of Complex Thinking. *Rev Latino Am Enfermagem [Internet]*. 2015 [cited 2018 Feb 19];23(1):59-66. Available from: [http://www.scielo.br/pdf/rlae/v23n1/pt\\_0104-1169-rlae-23-01-00059.pdf](http://www.scielo.br/pdf/rlae/v23n1/pt_0104-1169-rlae-23-01-00059.pdf)
8. Oliveira CS, Borges MS. Social representations of systematization of nursing care in the perspective of nurses who take care of children. *Rev Gaúcha Enferm [Internet]*. 2017 [cited 2018 June 6]; 38(3):e66840. Available from: [http://www.scielo.br/scielo.php?script=sci\\_arttext&pid=S1983-14472017000300421&lng=en&nrm=iso&tlng=en](http://www.scielo.br/scielo.php?script=sci_arttext&pid=S1983-14472017000300421&lng=en&nrm=iso&tlng=en)
9. Silva EGC, Oliveira VC, Neves GBC, Guimarães TMR. Nurses' knowledge about Nursing Care Systematization: from theory to practice. *Rev Esc Enferm USP [Internet]*. 2011 [cited 2018 Feb 5];45(6):1380-6. Available from: [http://www.scielo.br/scielo.php?script=sci\\_arttext&pid=S0080-62342011000600015&lng=en&nrm=iso&tlng=en](http://www.scielo.br/scielo.php?script=sci_arttext&pid=S0080-62342011000600015&lng=en&nrm=iso&tlng=en)
10. Luiz FF, Mello SMM, Neves ET, Ribeiro AC, Tronco CS. A sistematização da assistência de enfermagem na perspectiva da equipe de um hospital de ensino. *Rev Eletr Enf [Internet]*. 2010 [citado 2018 set. 12];12(4):655-9. Disponível em: <https://www.fen.ufg.br/revista/v12/n4/v12n4a09.htm>



This is an open-access article distributed under the terms of the Creative Commons Attribution License.