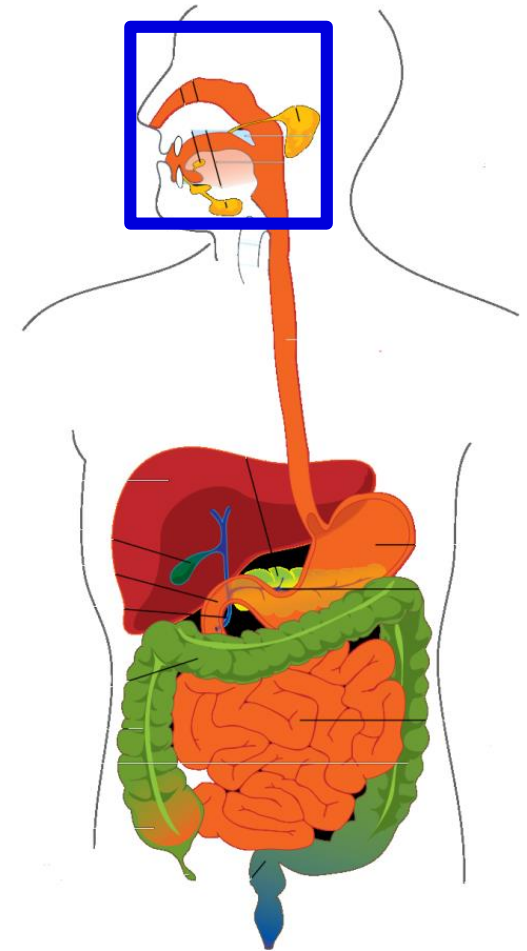


# GIT I

- Ústní dutina
- Vývoj obličeje
- Faryngový aparát



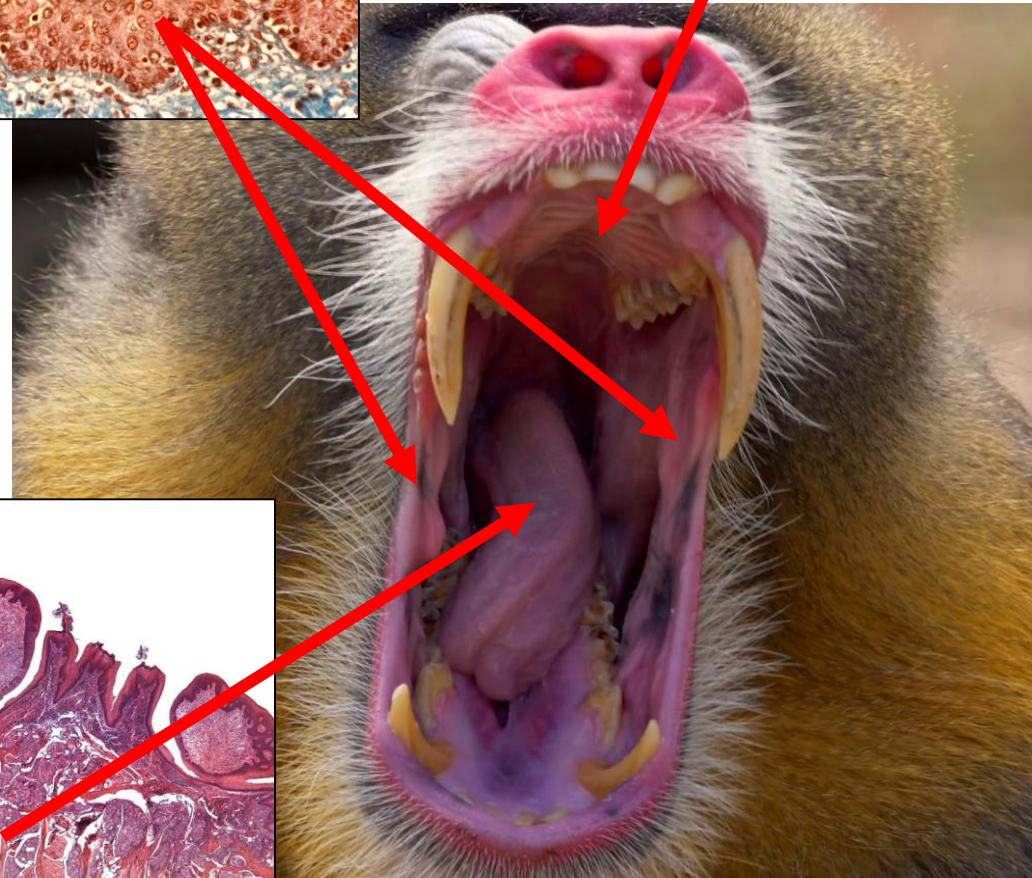
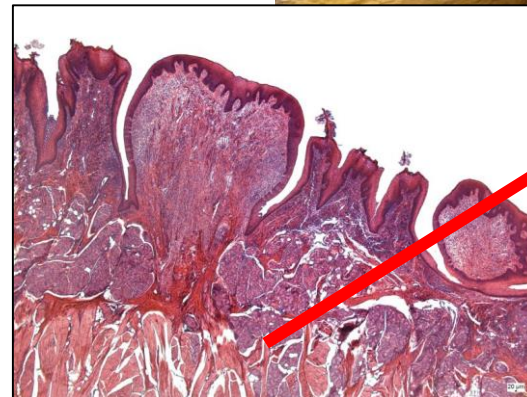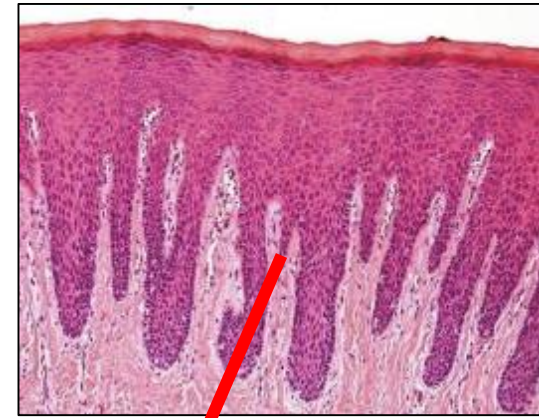
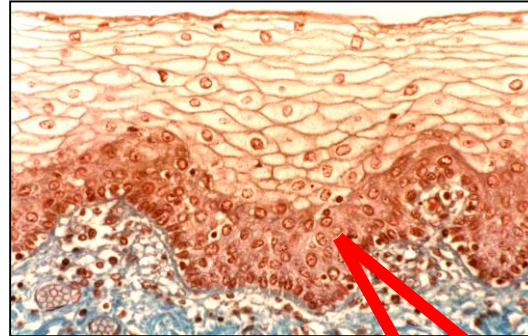


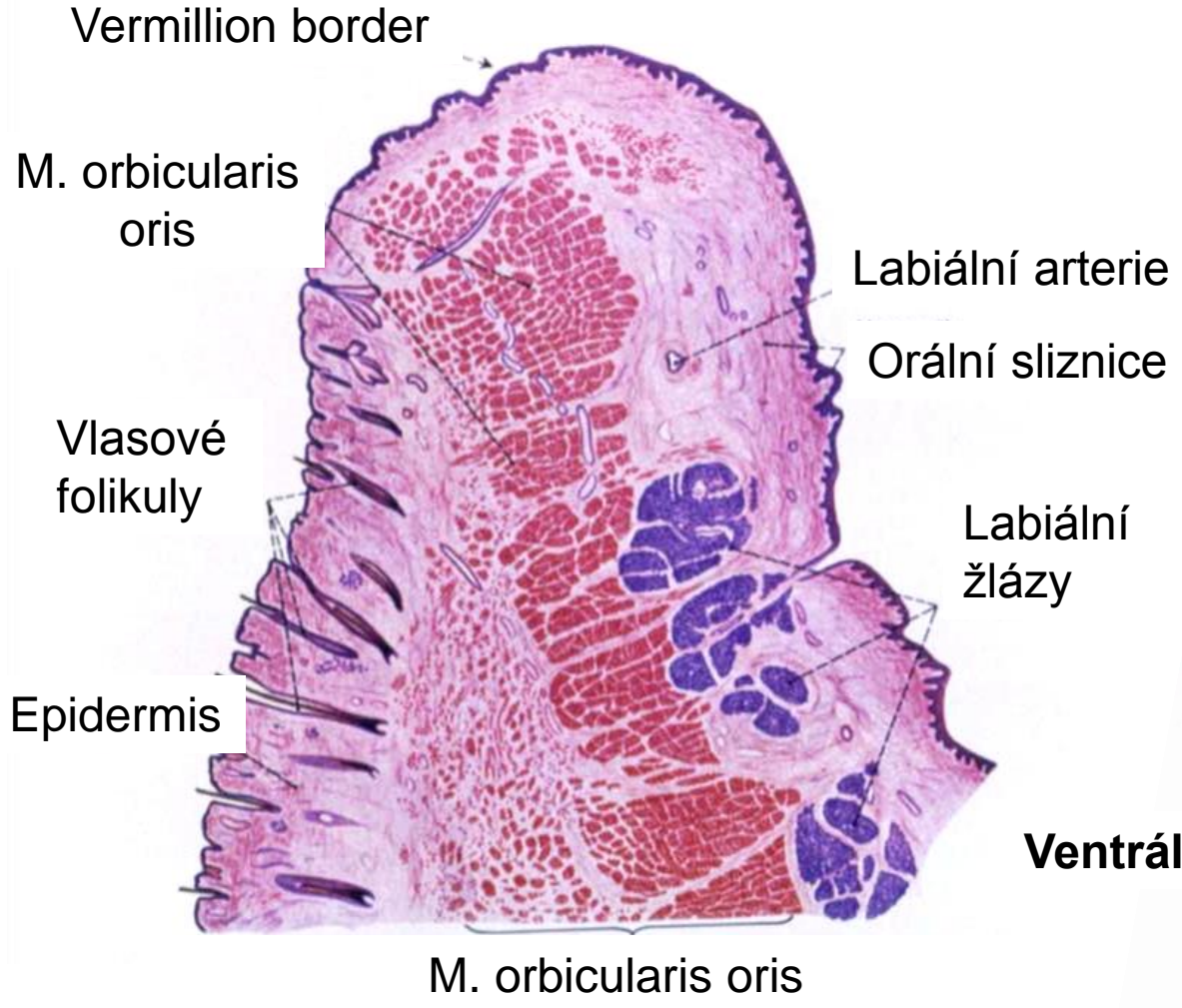
- Horní a dolní ret
- Vestibulum oris
- Tvrdé a měkké patro
- Zub
- Jazyk

# ORÁLNÍ SLIZNICE

## vrstevnatý dlaždicový epitel *lamina propria mucosae*

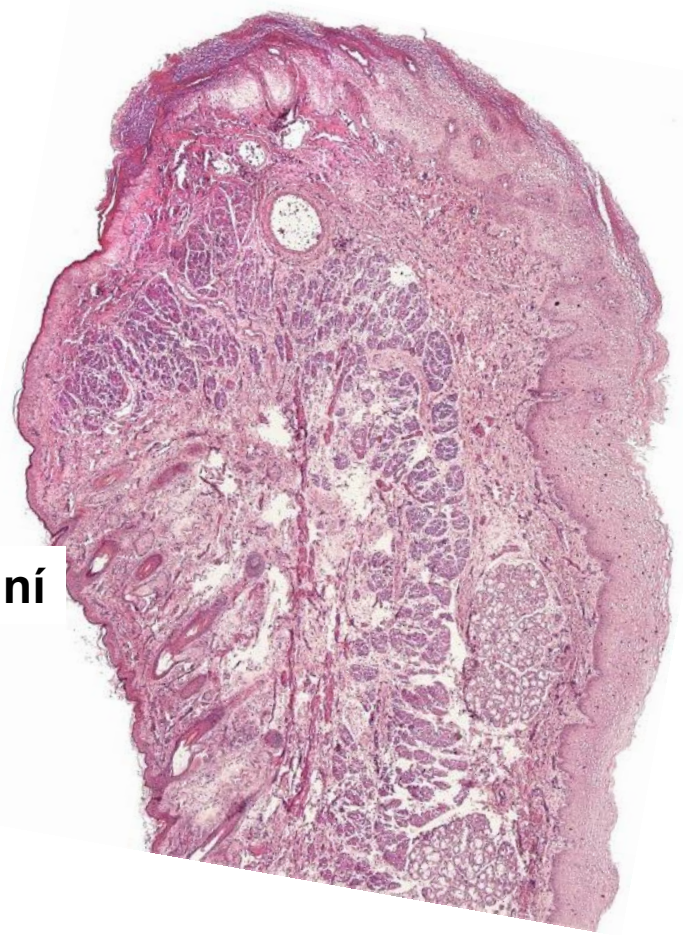
- **krycí** sliznice
  - slizniční vazivo (l. propria),  
posunlivé připojení sliznice
- **mastikační** sliznice
  - zrohovatělý epitel, lamina propria  
přechází v periost tvrdého patra  
(mukoperiost), dásně
- **specializovaná** sliznice
  - dorsum linguae





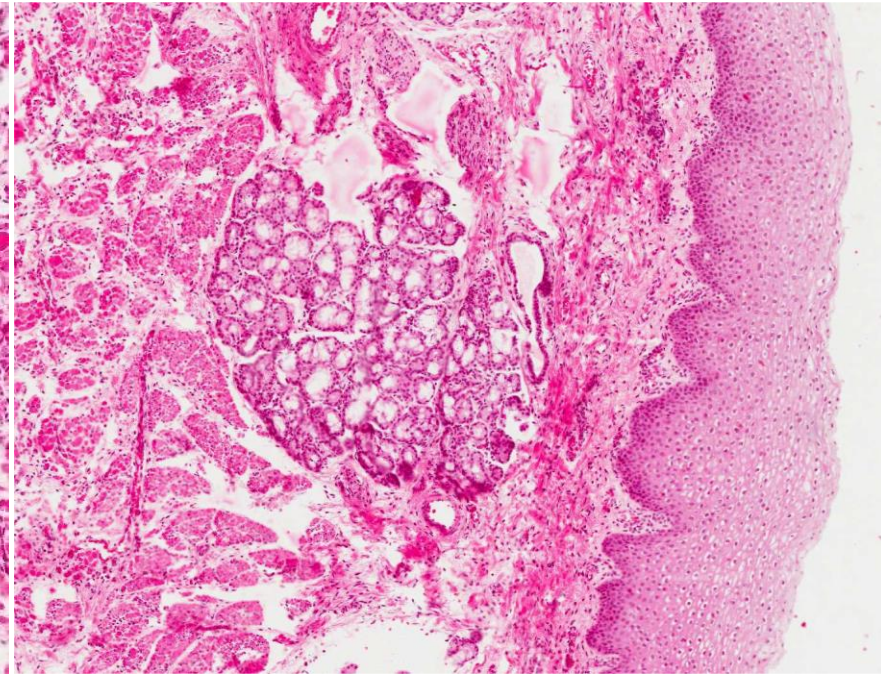
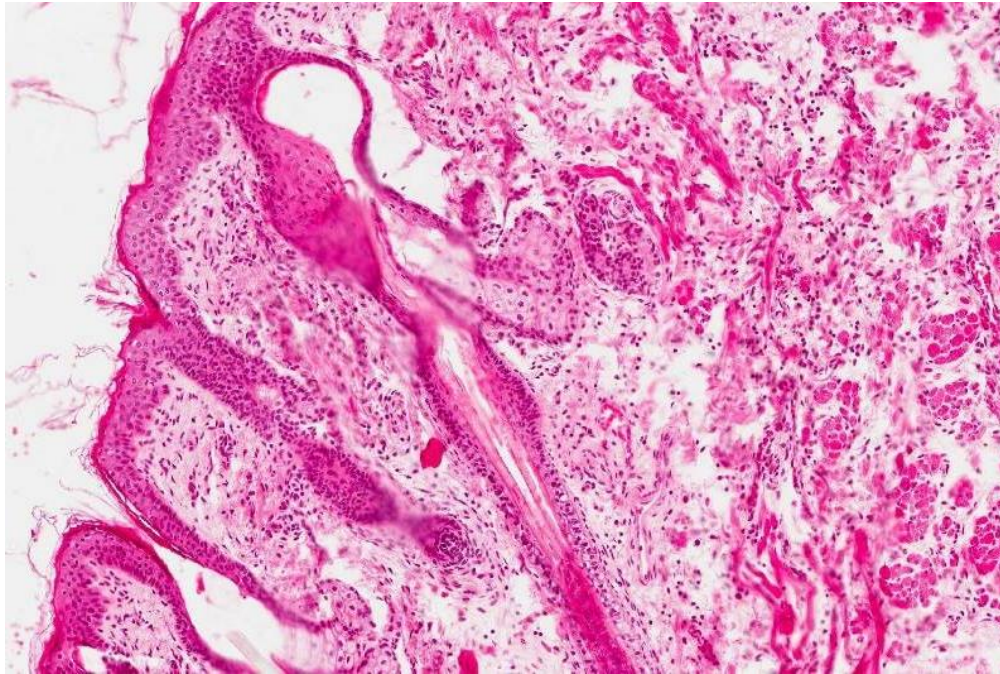
**Dorsální**

**Ventrální**



## Kožní aspekt (ventrálně)

## Orální aspekt (dorsálně)

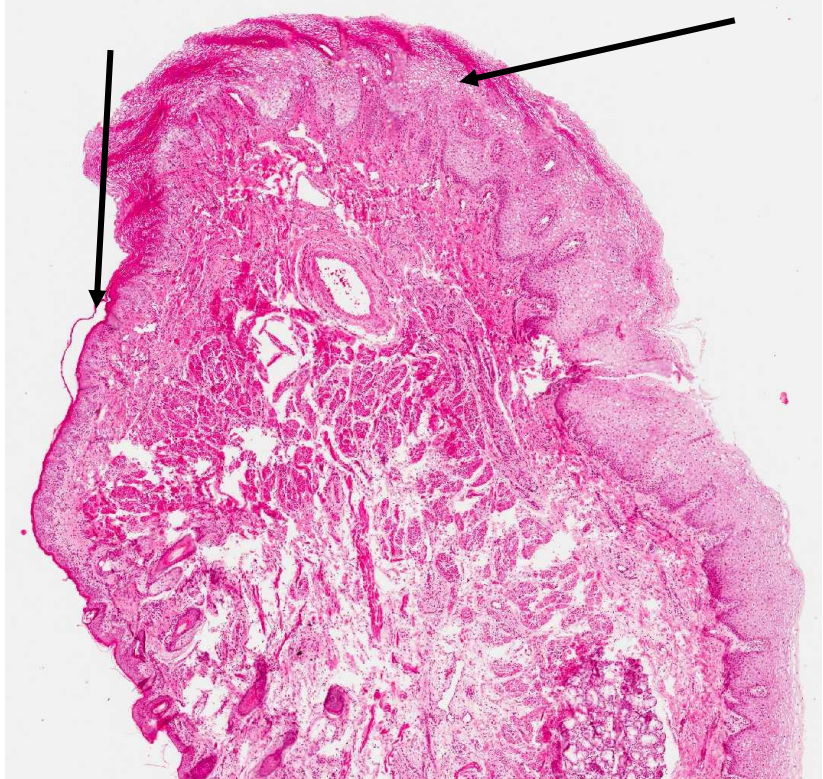

Epidermis  
Vlasové folikuly  
Mazové žlázy  
Potní žlázy

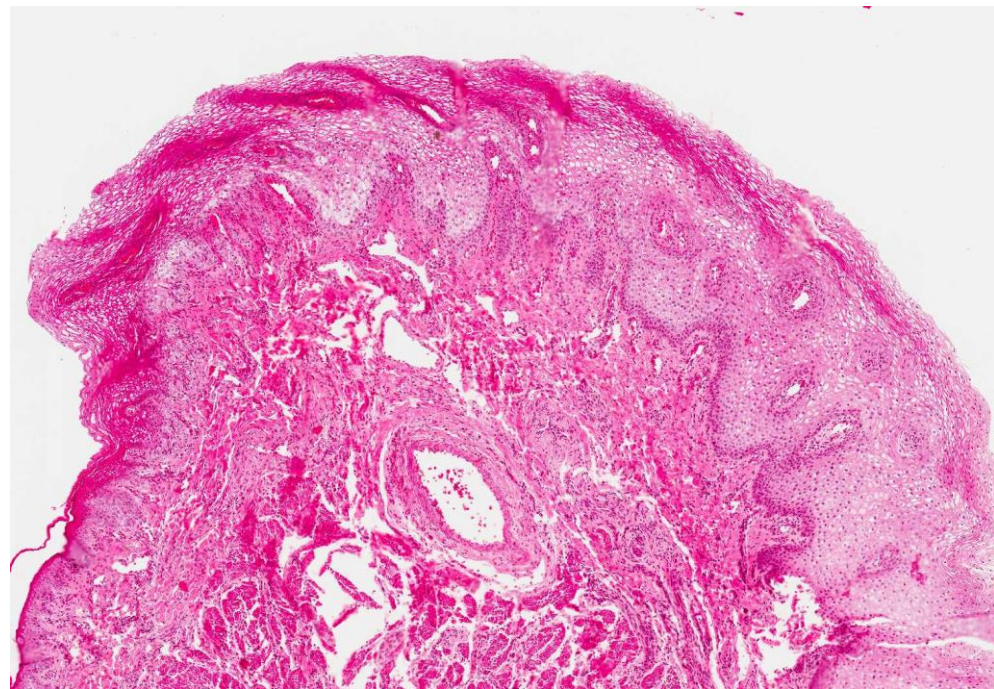
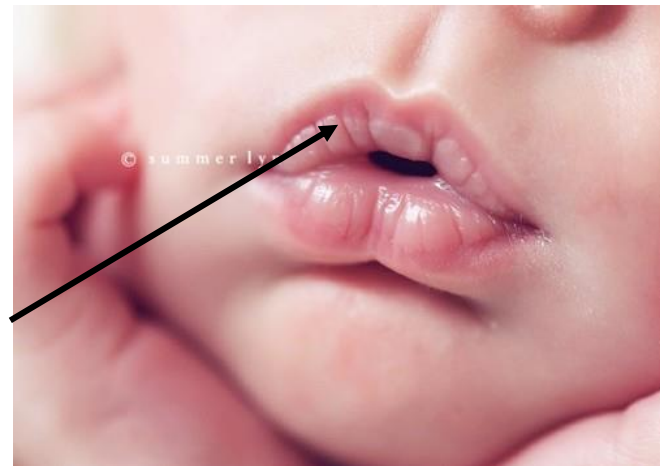Orální sliznice  
Malé smíšené slinné žlázy

pars glabra

pars villosa

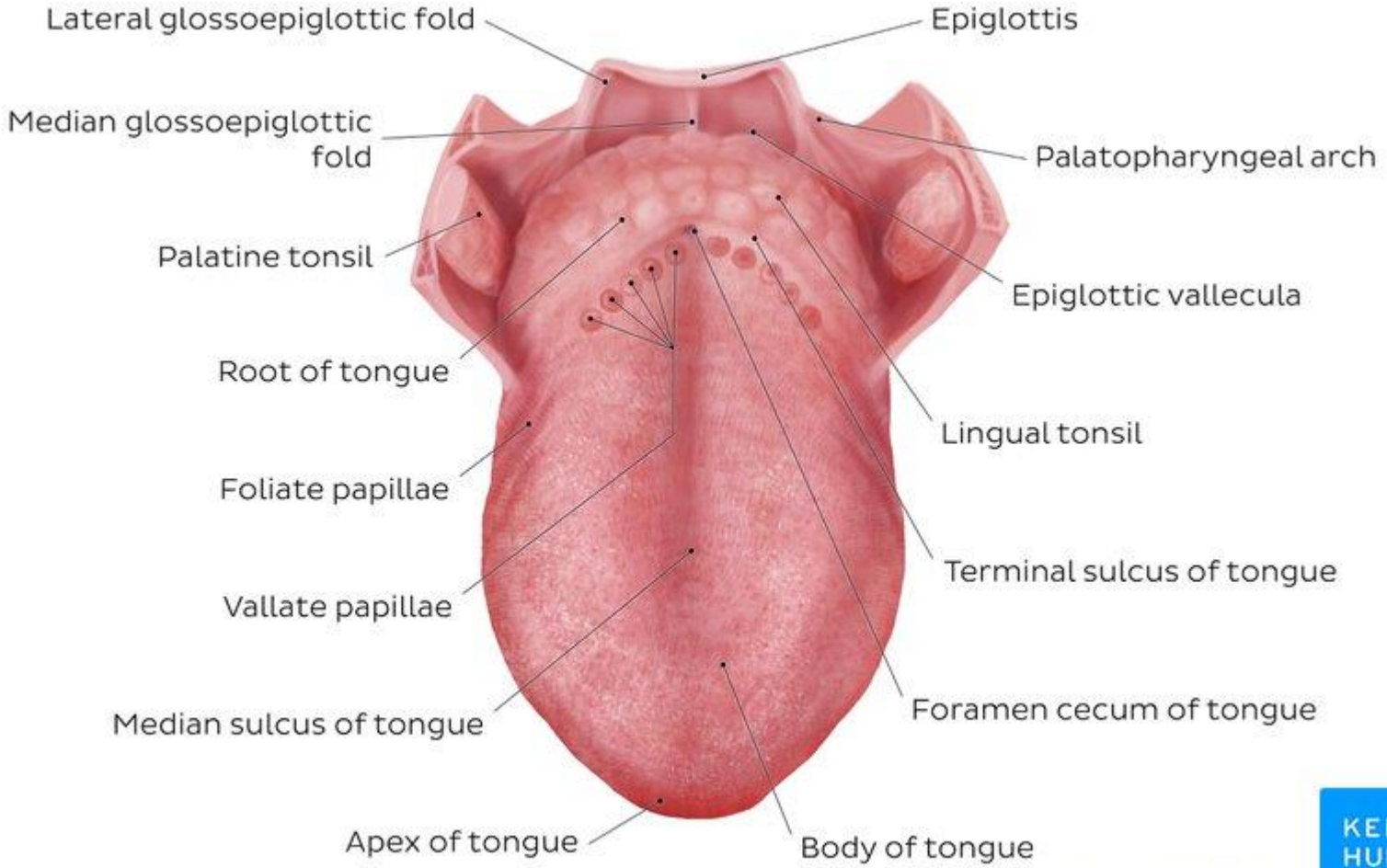


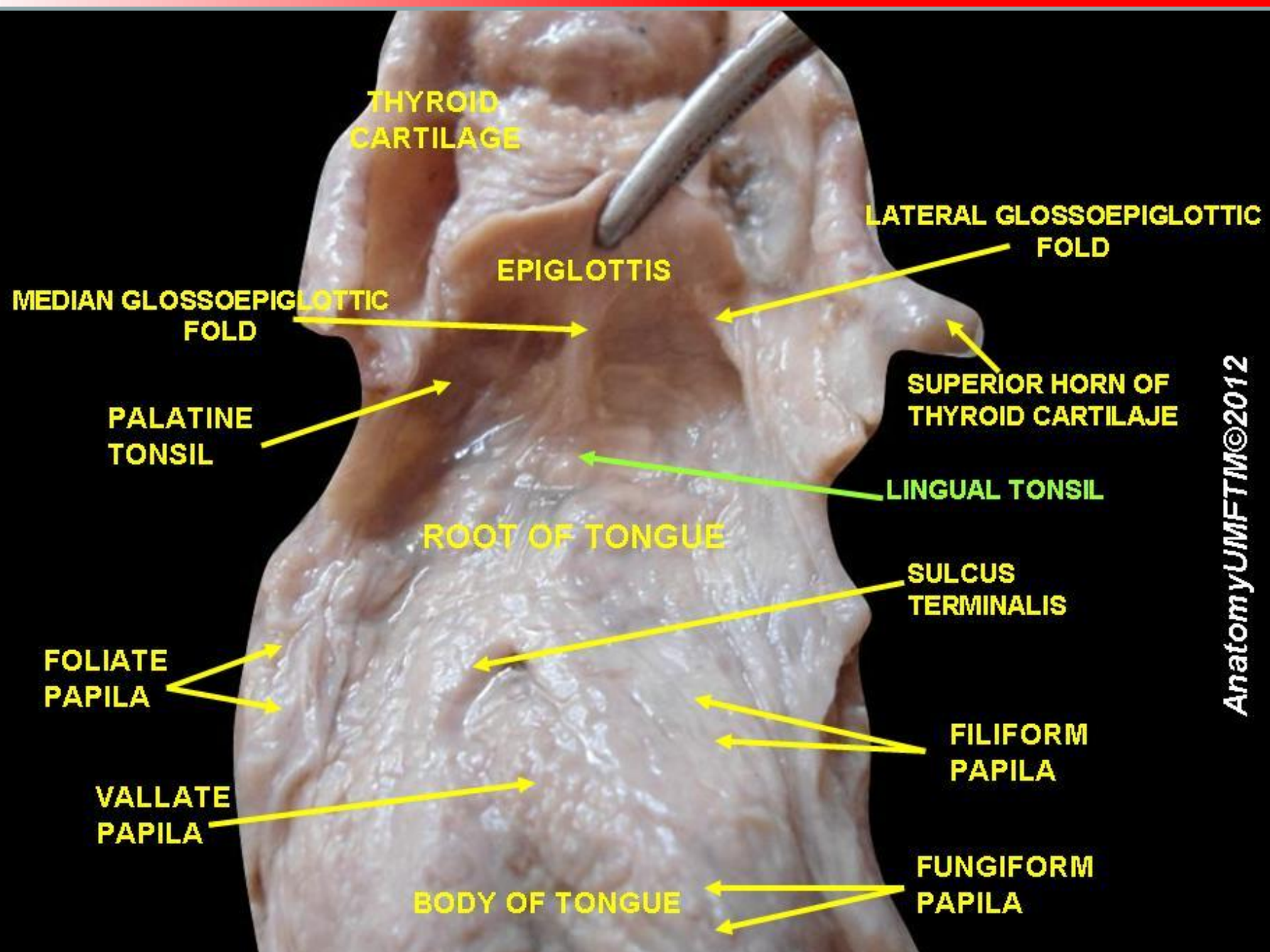
novorozenci  
torus labialis



## Vermillion border

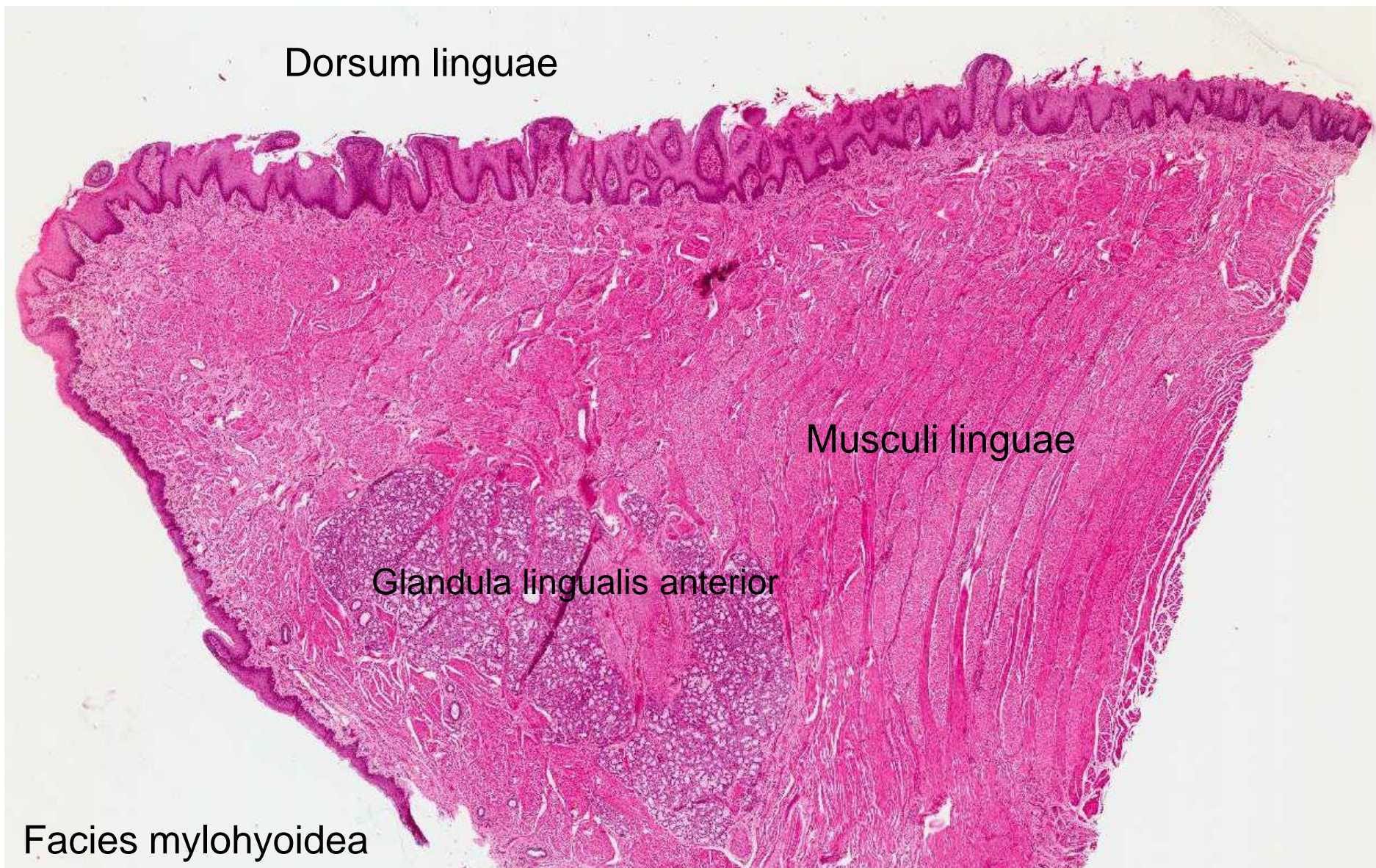
- Eleidin
- Absence slinných žláz, vlasových folikulů, potních žláz
- Vysoké vazivové papily, kapiláry
- Nervová zakončení, Meissnerova tělíska







# JAZYK – APEX LINGUAE



Dorsum linguae

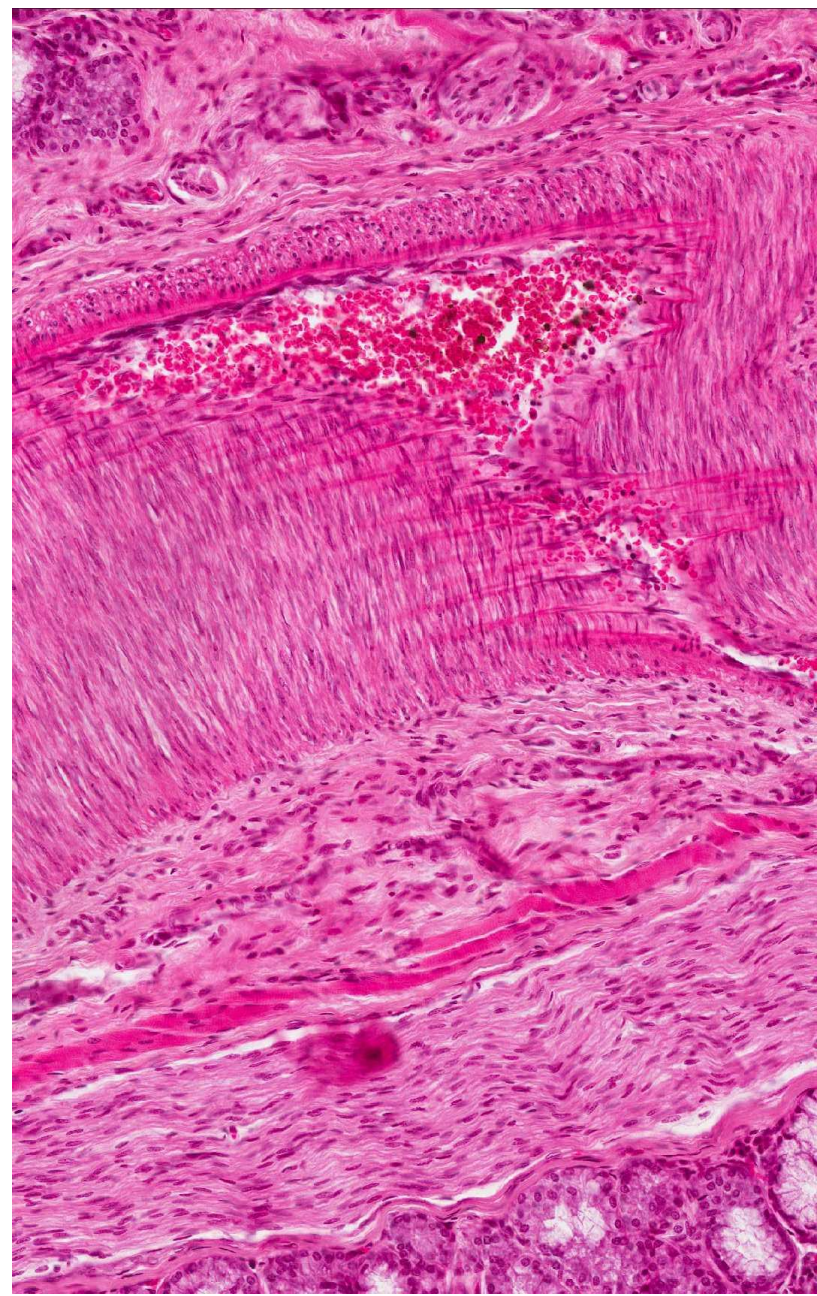
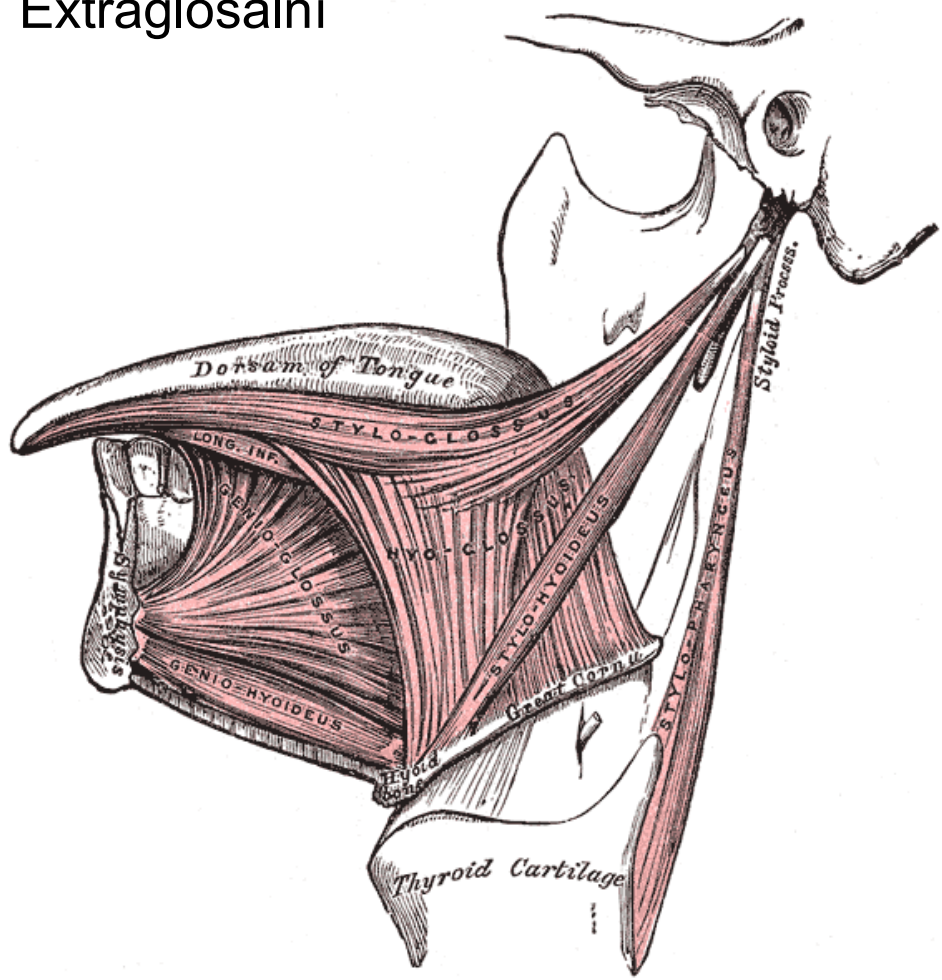
Musculi linguae

Glandula lingualis anterior

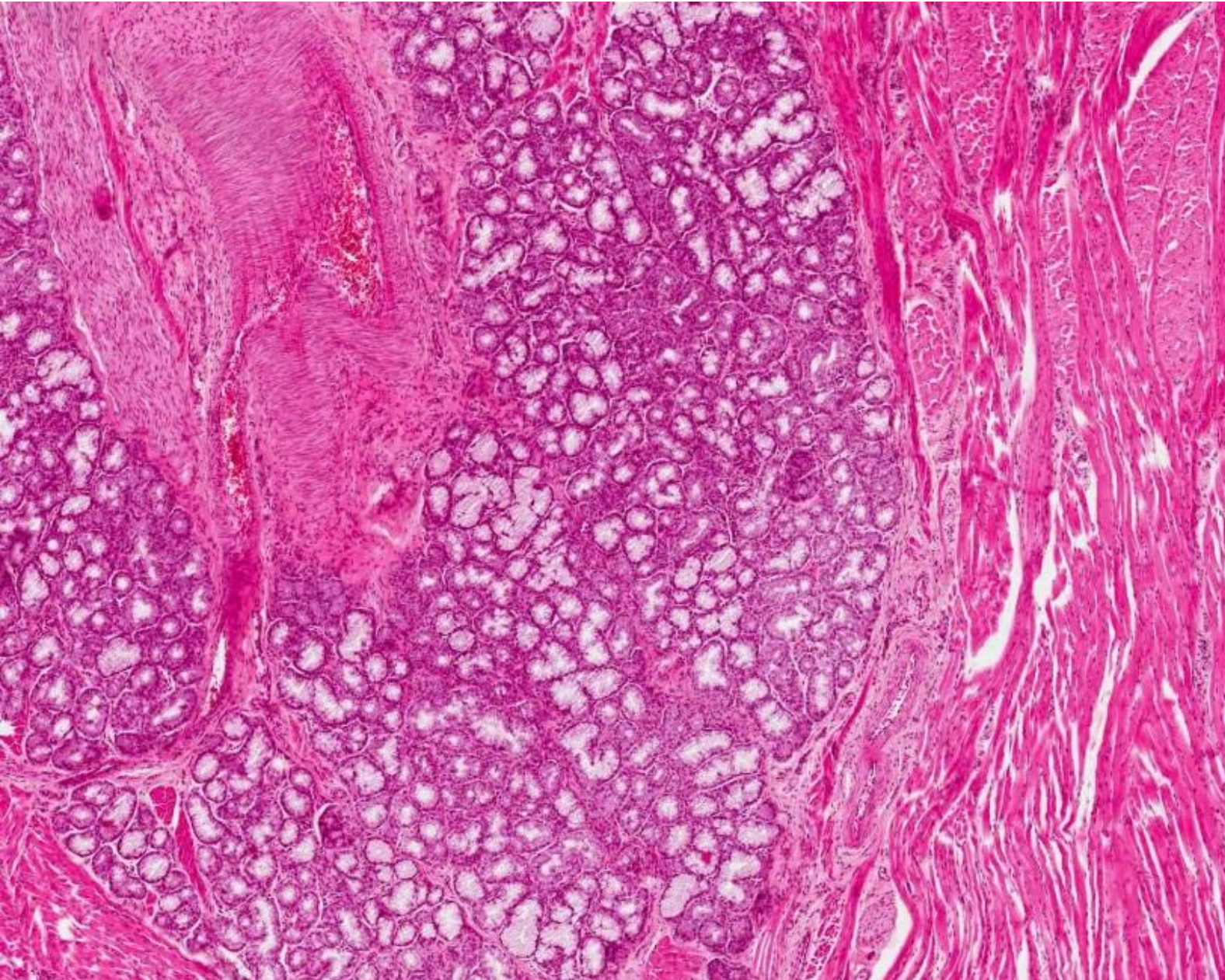
Facies mylohyoidea

# JAZYK - SVALY

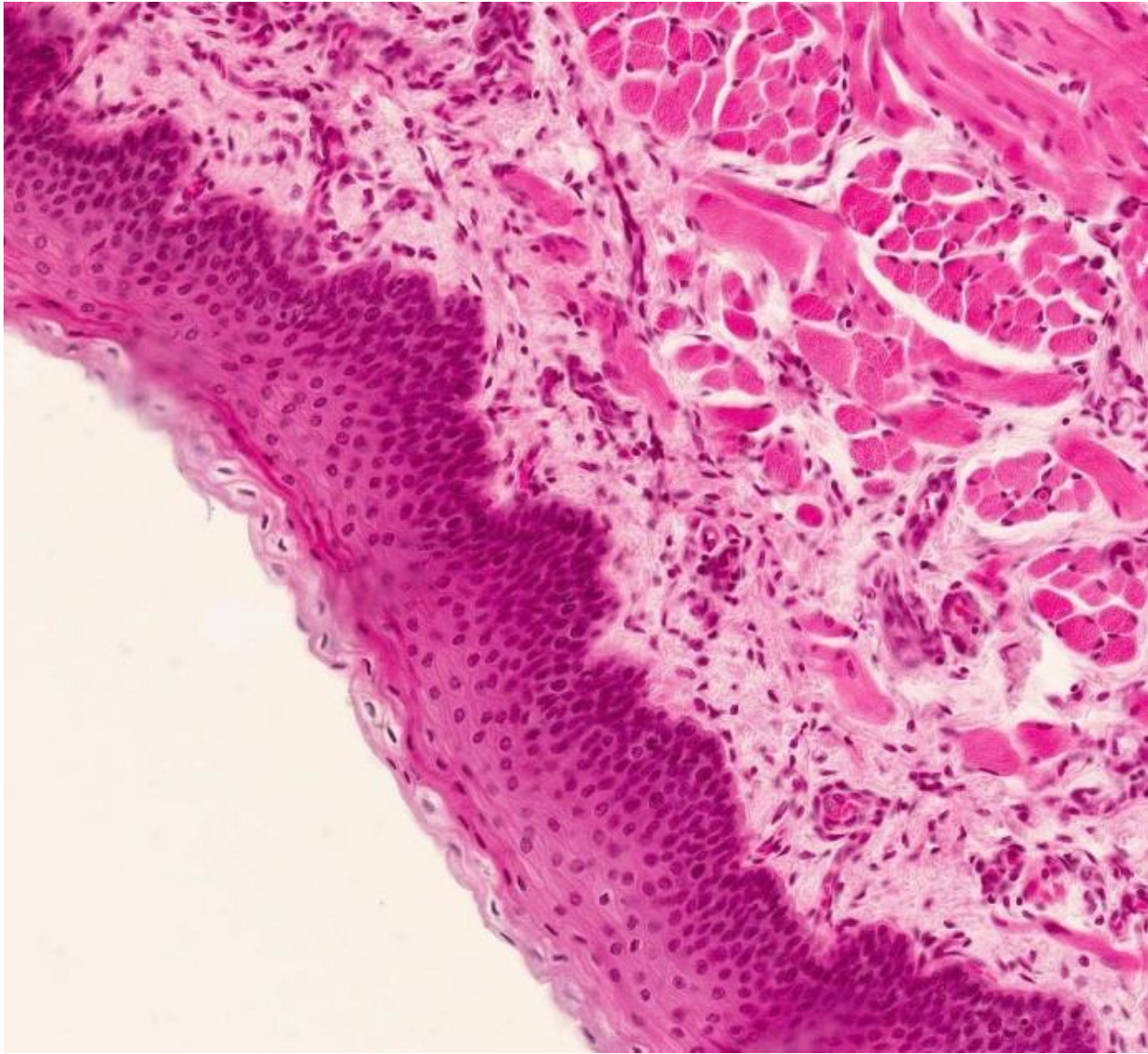
- Intraglosální
- Extraglosální



JAZYK - GLL. LINGUALES ANTERIORES (BLANDINI)

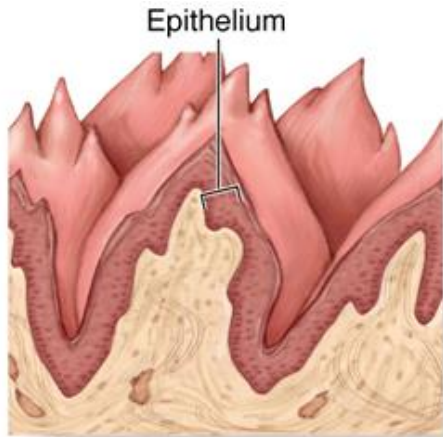


# JAZYK - FACIES MYLOHYOIDEA

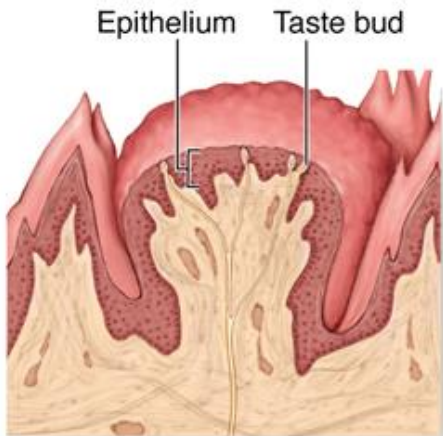


# JAZYK – DORSUM LINGUAE

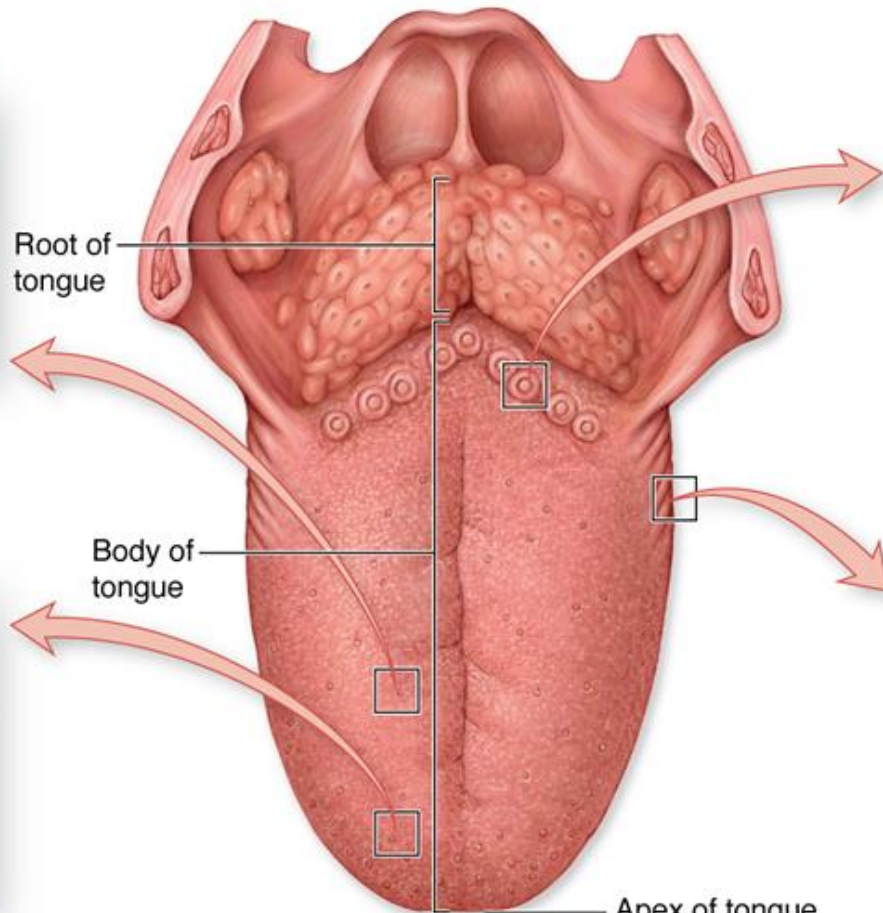
- specializované slizniční struktury - **papily**
- slizniční vazivo



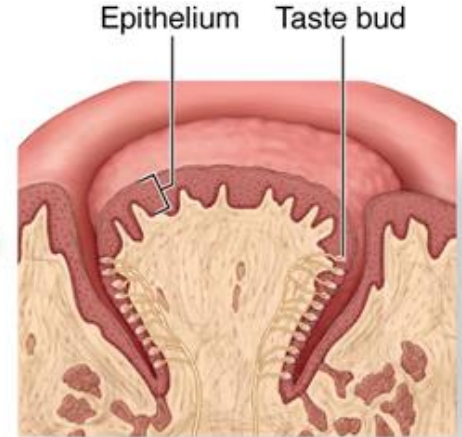
Filiform papilla



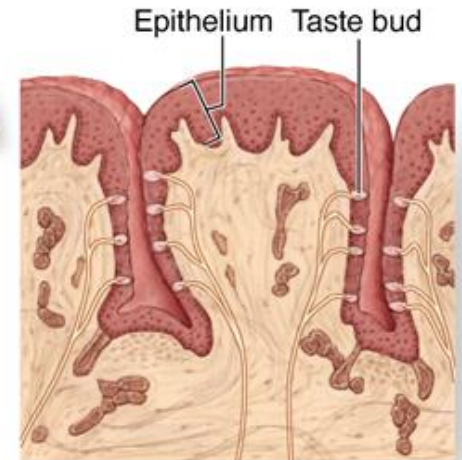
Fungiform papilla



Dorsal surface of tongue



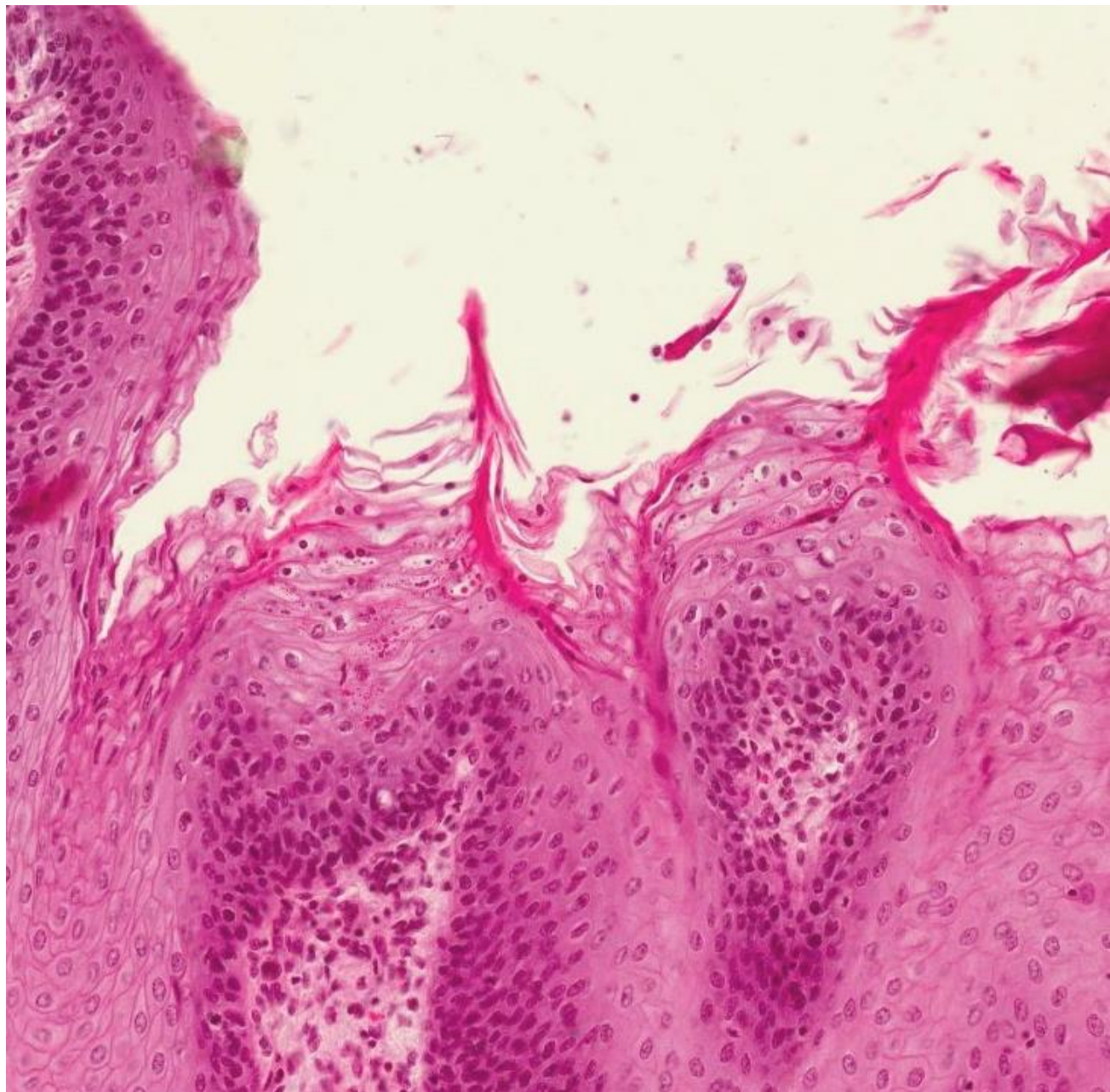
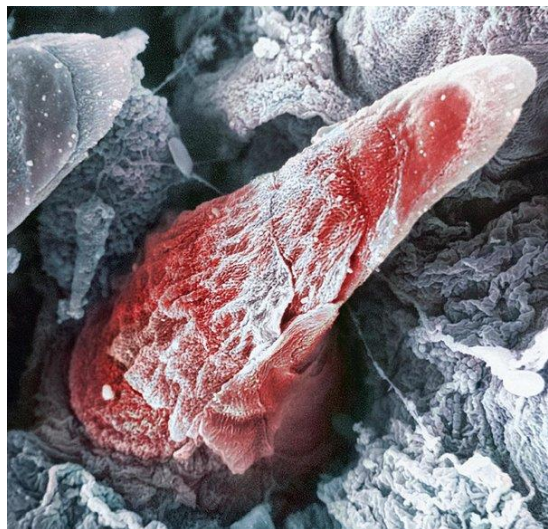
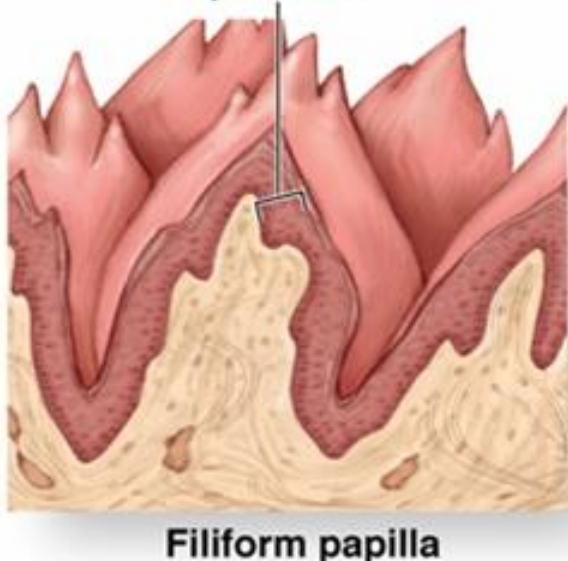
Vallate papilla



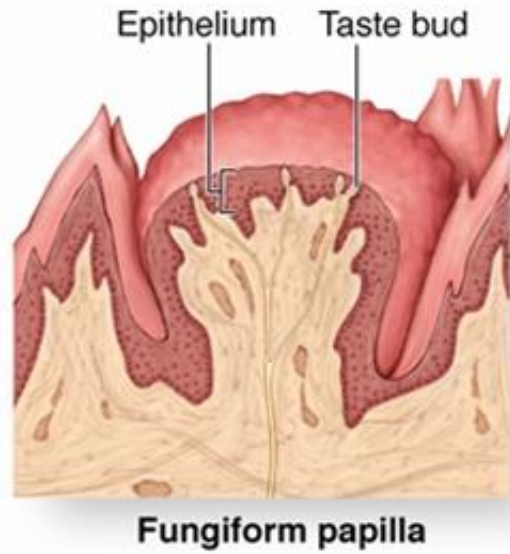
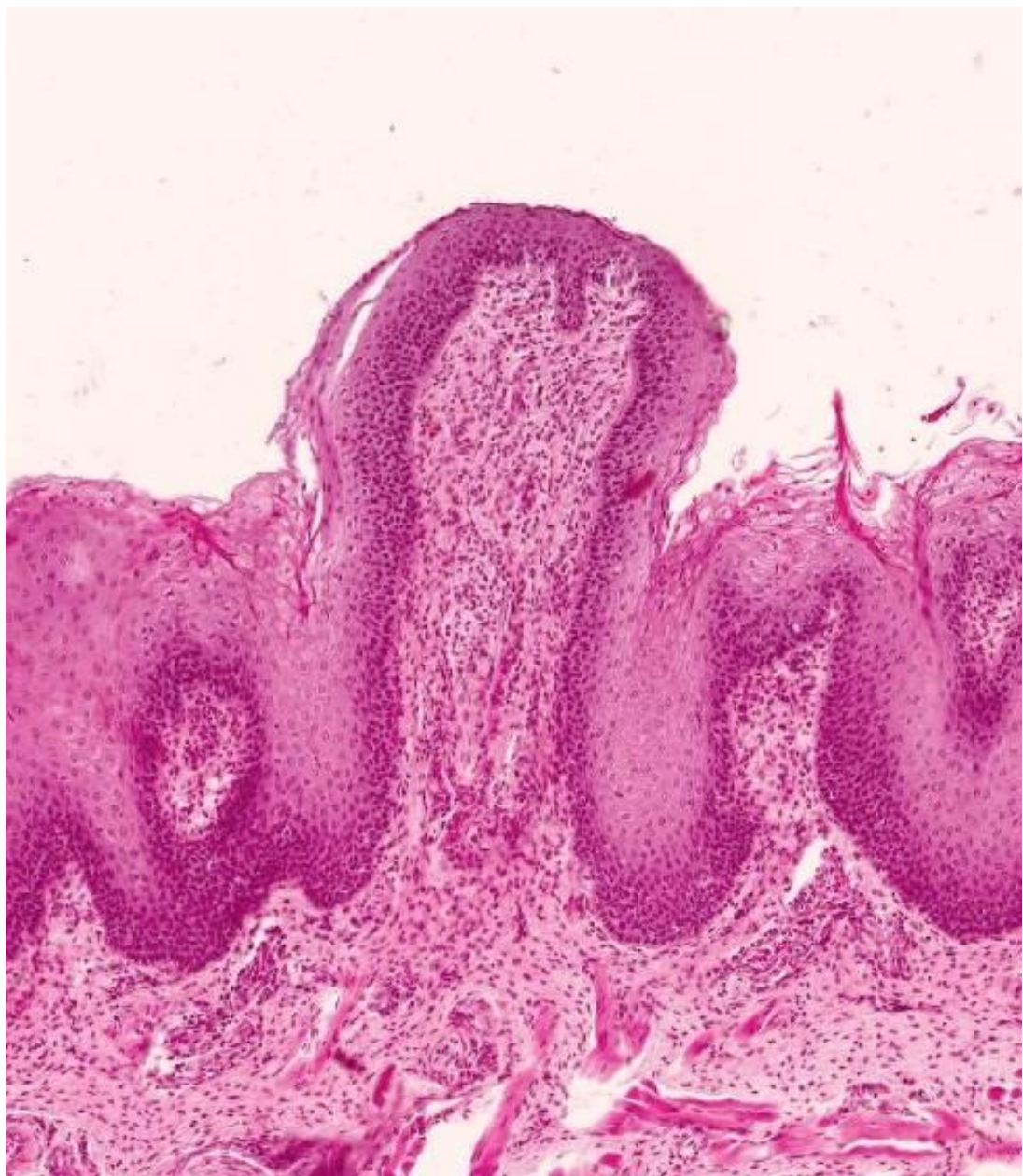
Foliate papilla

# JAZYK – FILIFORMNÍ (NITKOVITÉ) PAPILY

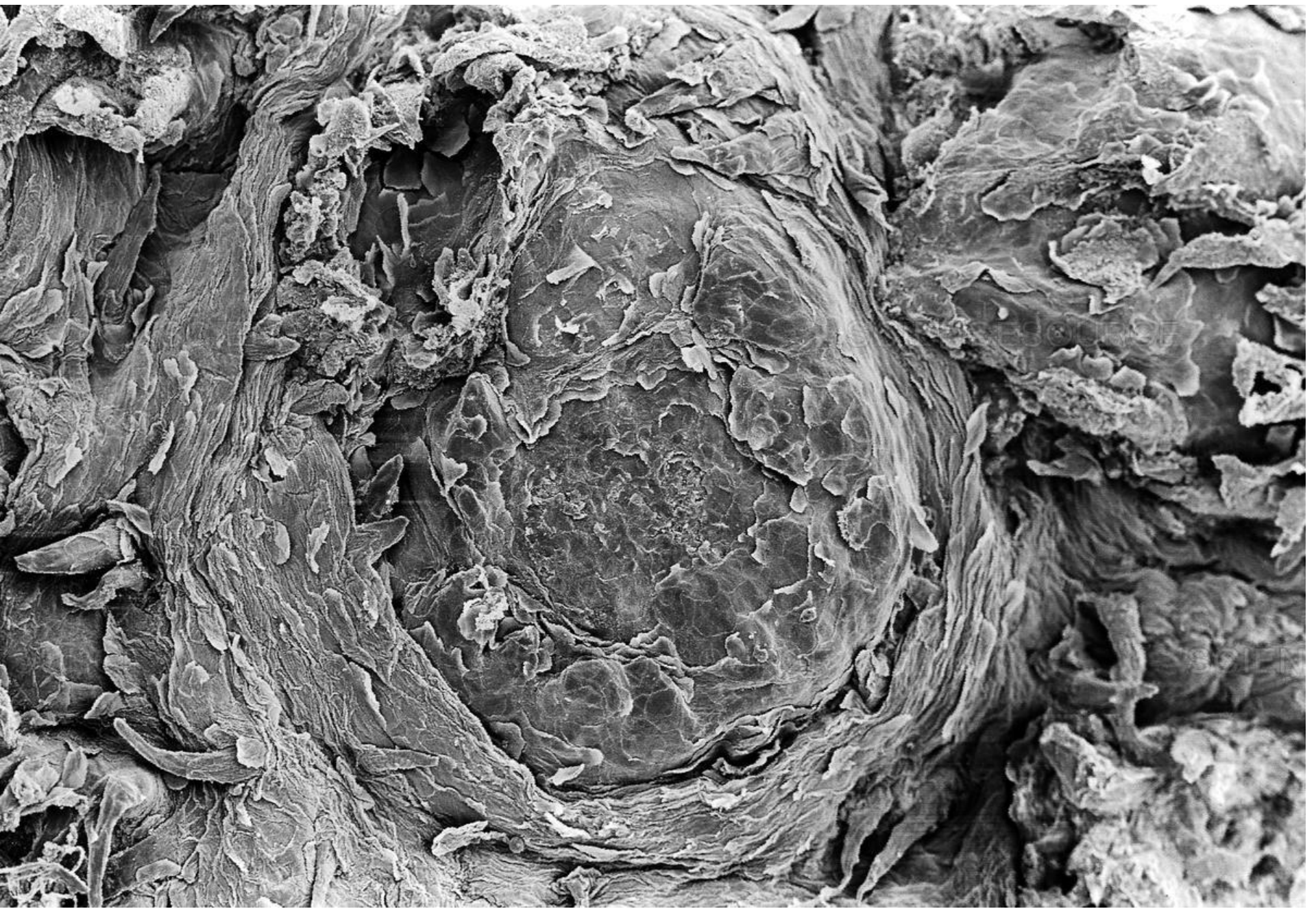
Epithelium



# JAZYK – FUNGIFORMNÍ (HOUBOVITÉ) PAPILY

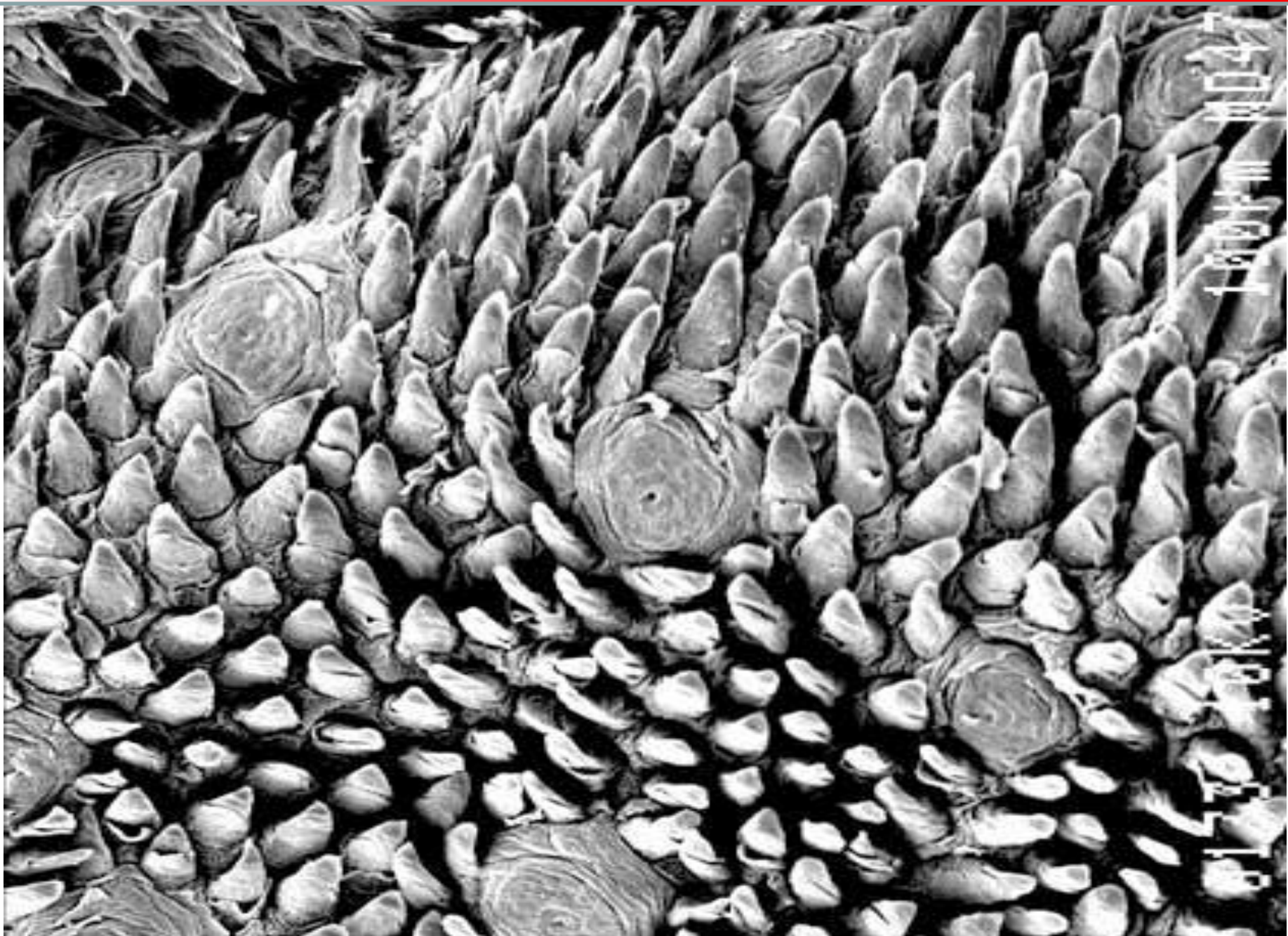


# JAZYK – FUNGIFORMNÍ PAPILY

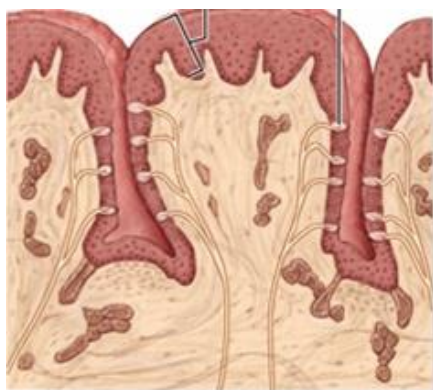




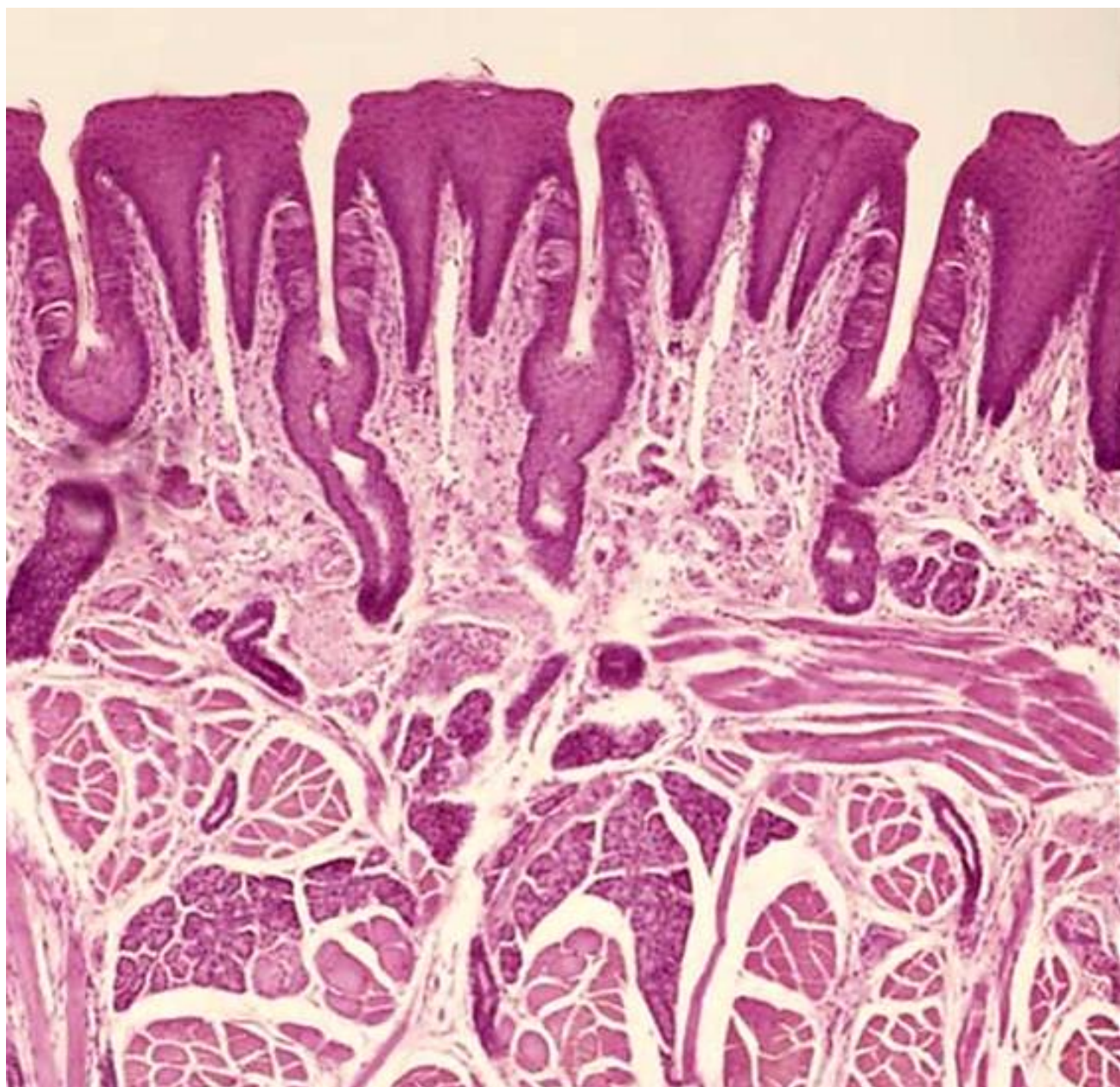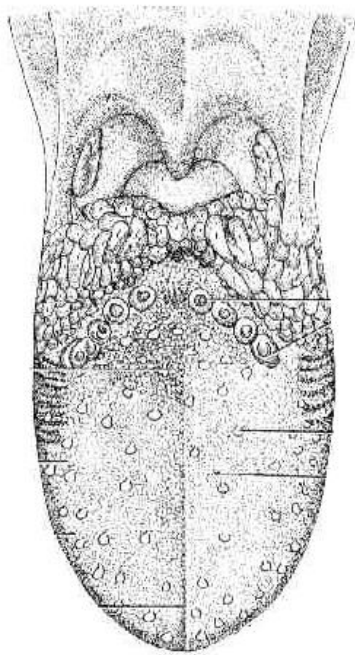
# JAZYK – FILIFORMNÍ A FUNGIFORMNÍ PAPILY



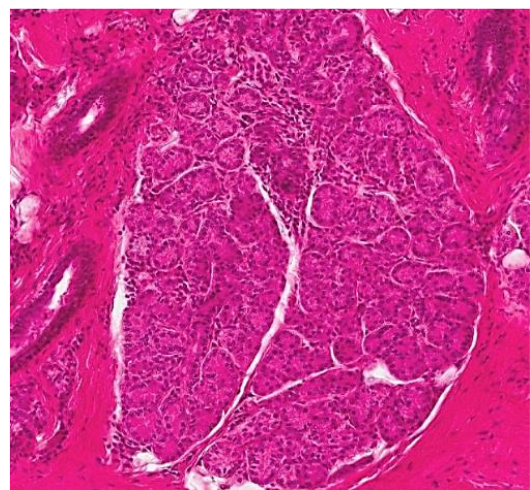
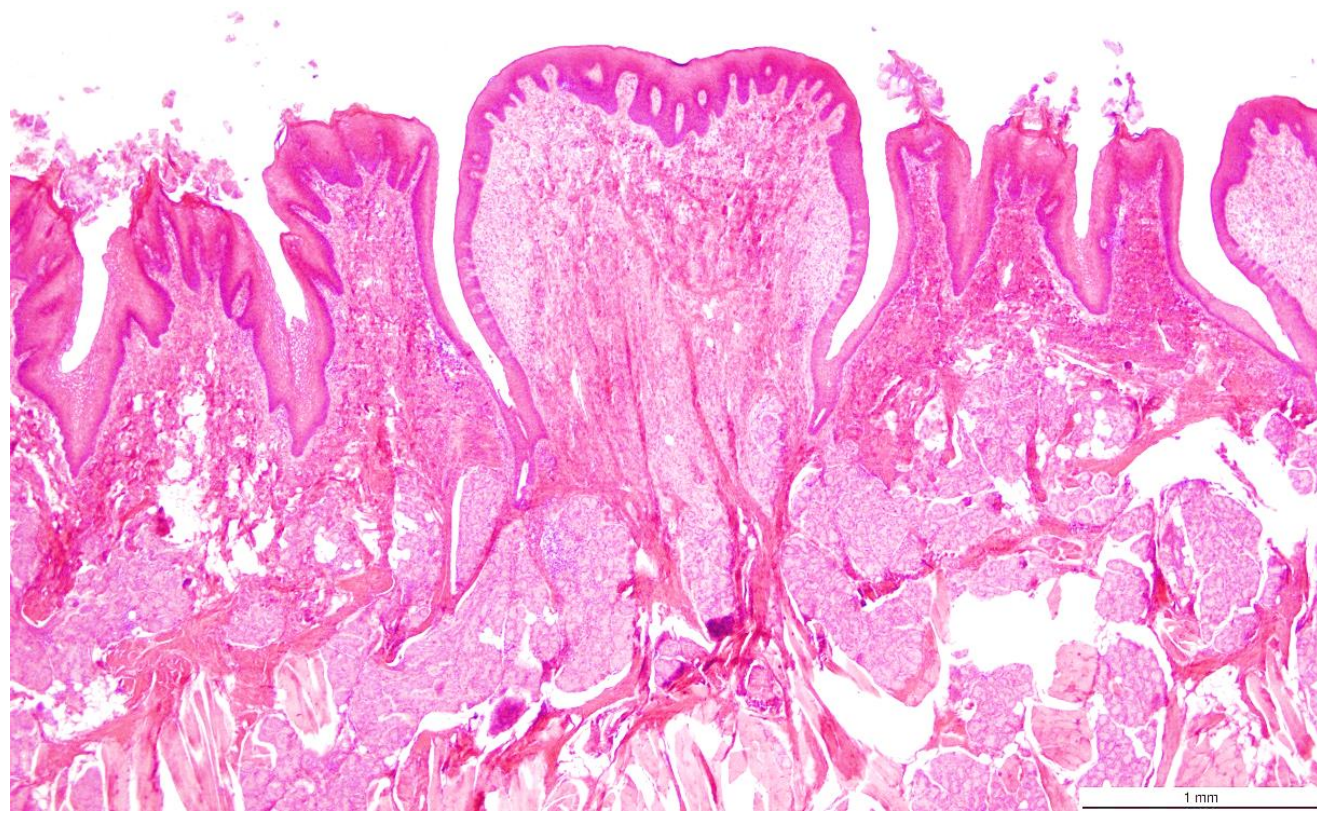
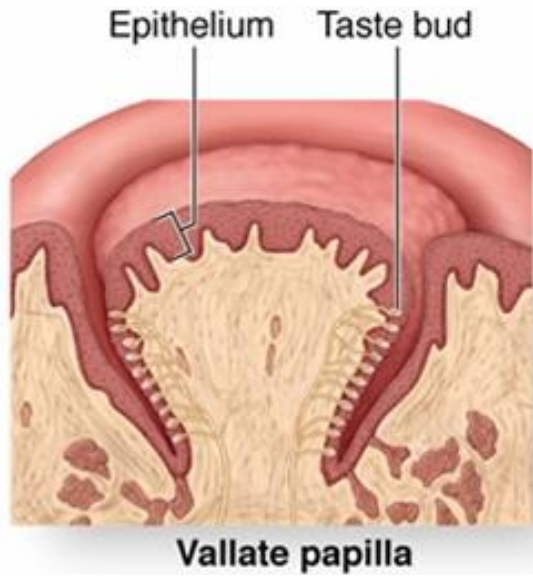
# JAZYK – FOLIÁTNÍ (LISTOVITÉ) PAPILY



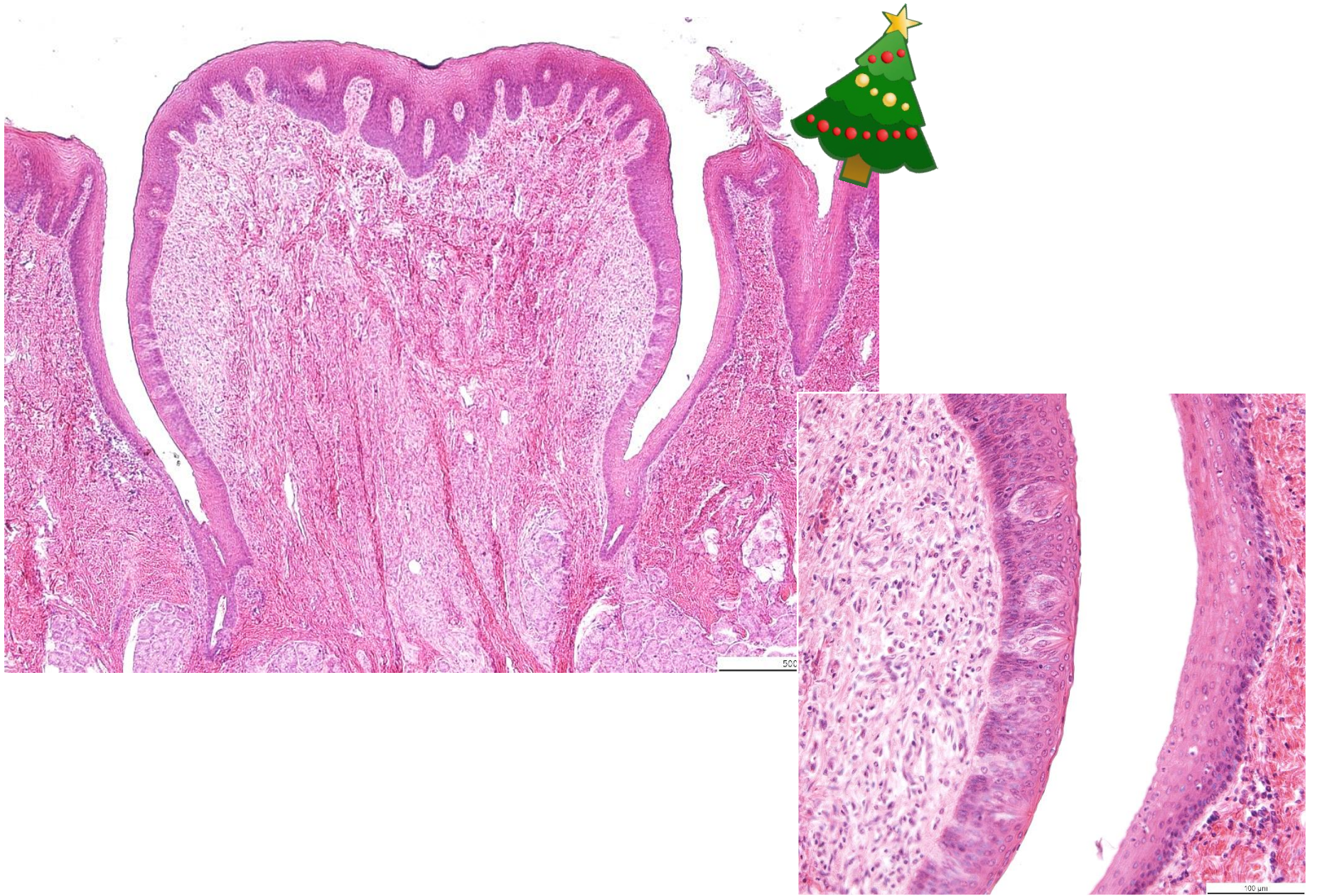
Foliate papilla



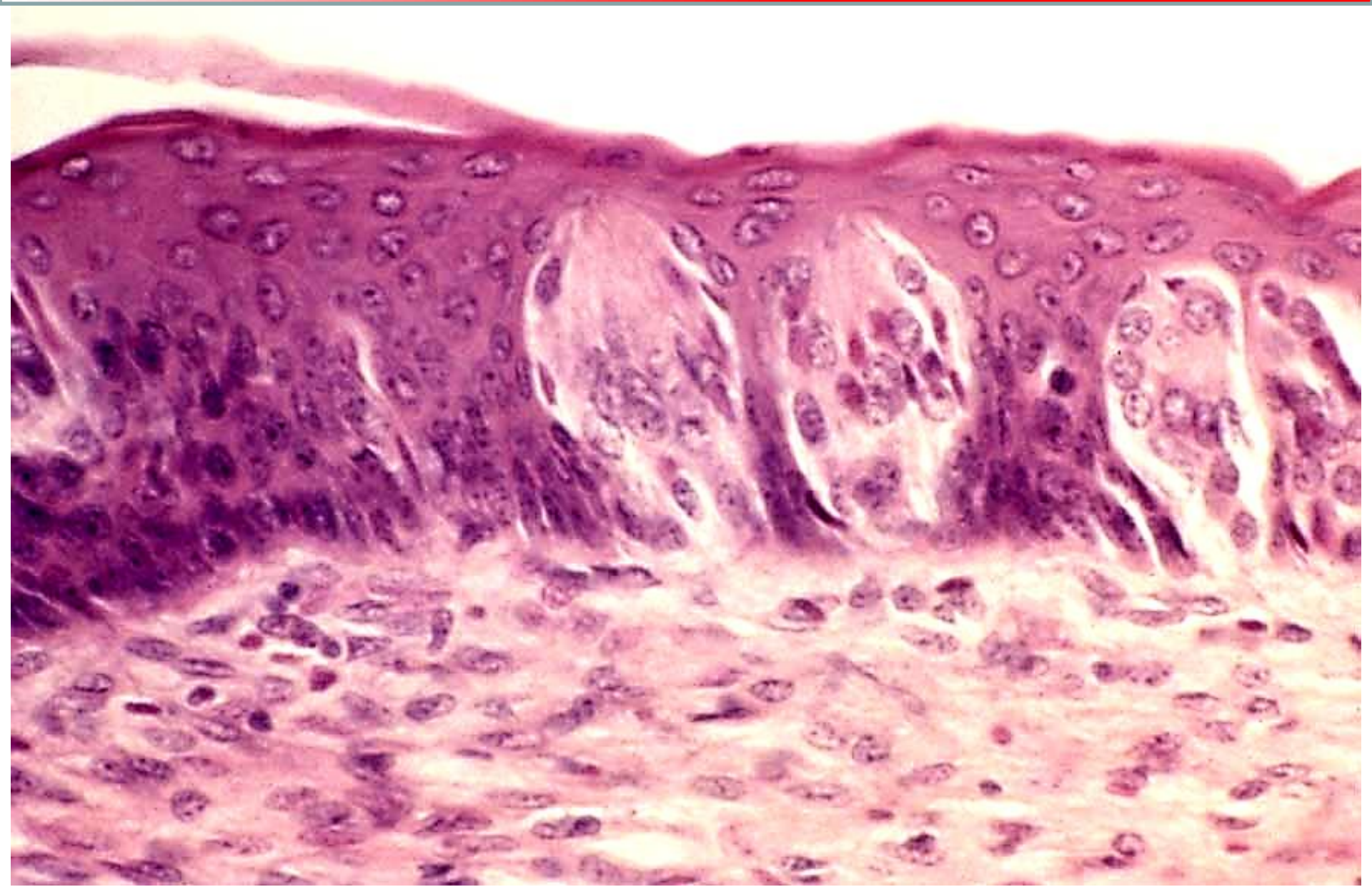
# JAZYK – VALÁTNÍ (HRAZENÉ) PAPILY



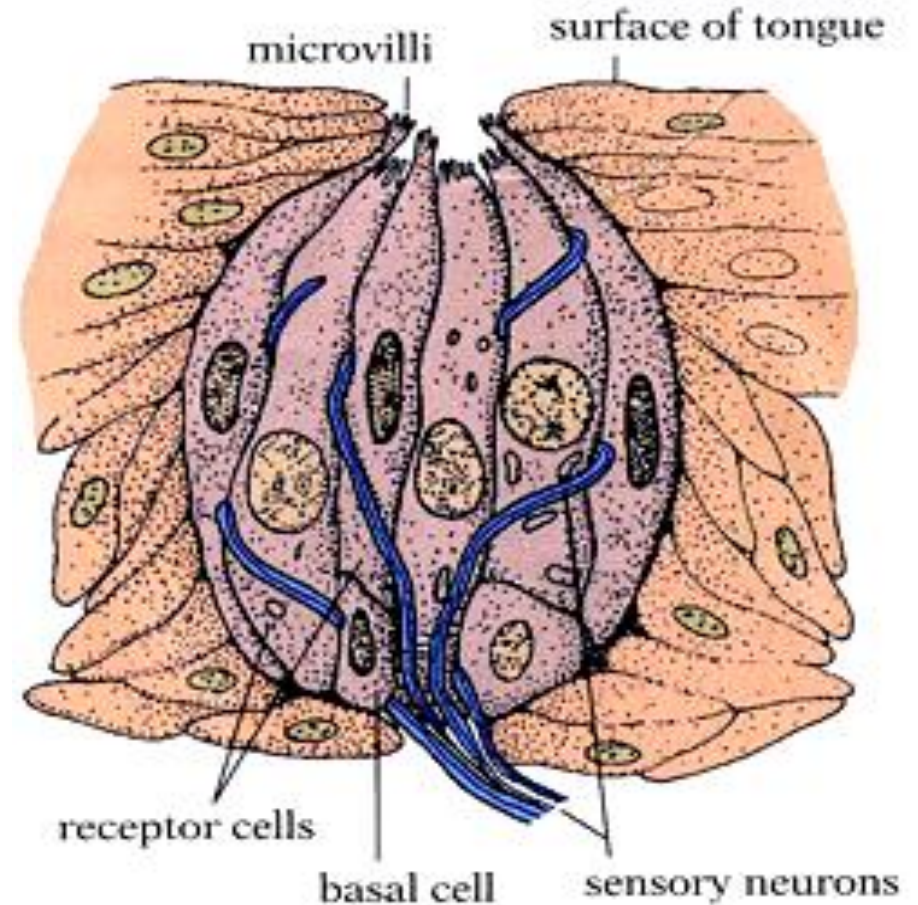
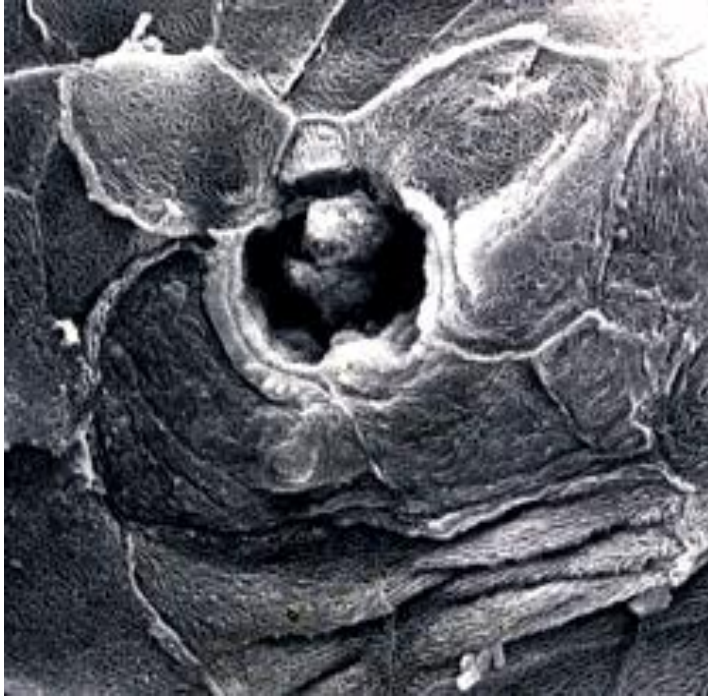# JAZYK – VALÁTNÍ (HRAZENÉ) PAPILY



# JAZYK – CHUŤOVÉ POHÁRKY

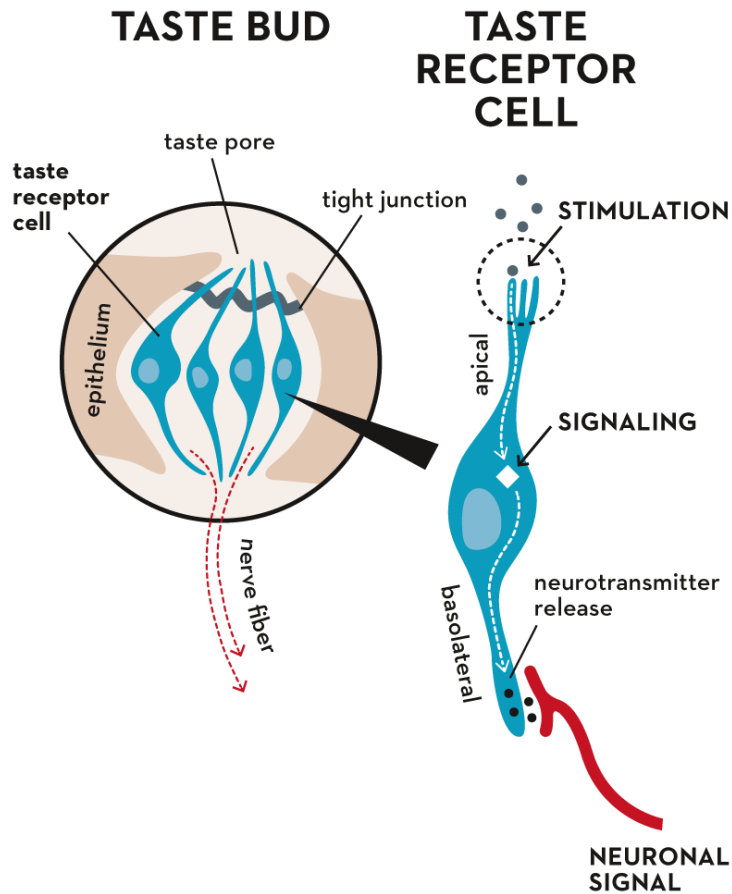


# JAZYK – CHUŤOVÝ POHÁREK



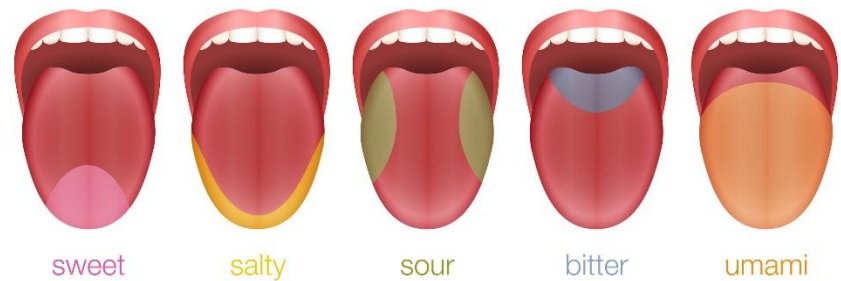
- intraepiteliální struktury
- porus gustatorius
- 2000-8000 v ústní dutině
- 60-80 buněk
- 70-80  $\mu\text{m}$   $\times$  30-40  $\mu\text{m}$
- mikrokly na smyslových buňkách
- nervová vlákna

# JAZYK – CHUŤOVÝ POHÁREK

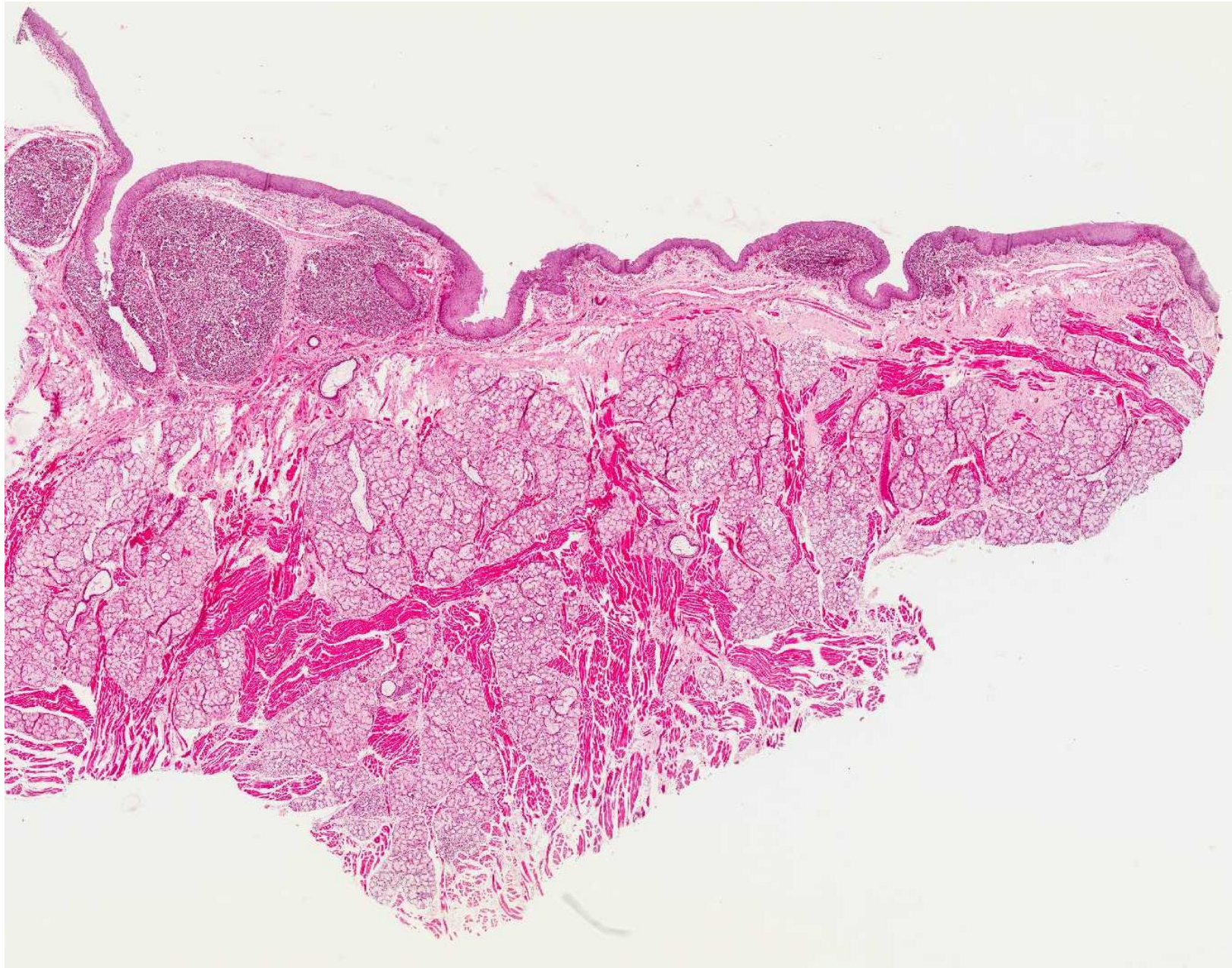

- hořké
- sladké
- umami (glutamát)
- G-proteiny asociované s receptory
- slané
- kyselé
- iontové kanály
- CD36
- fatty acid transporter

- na vnímání chuti se podílí i čichový epitel

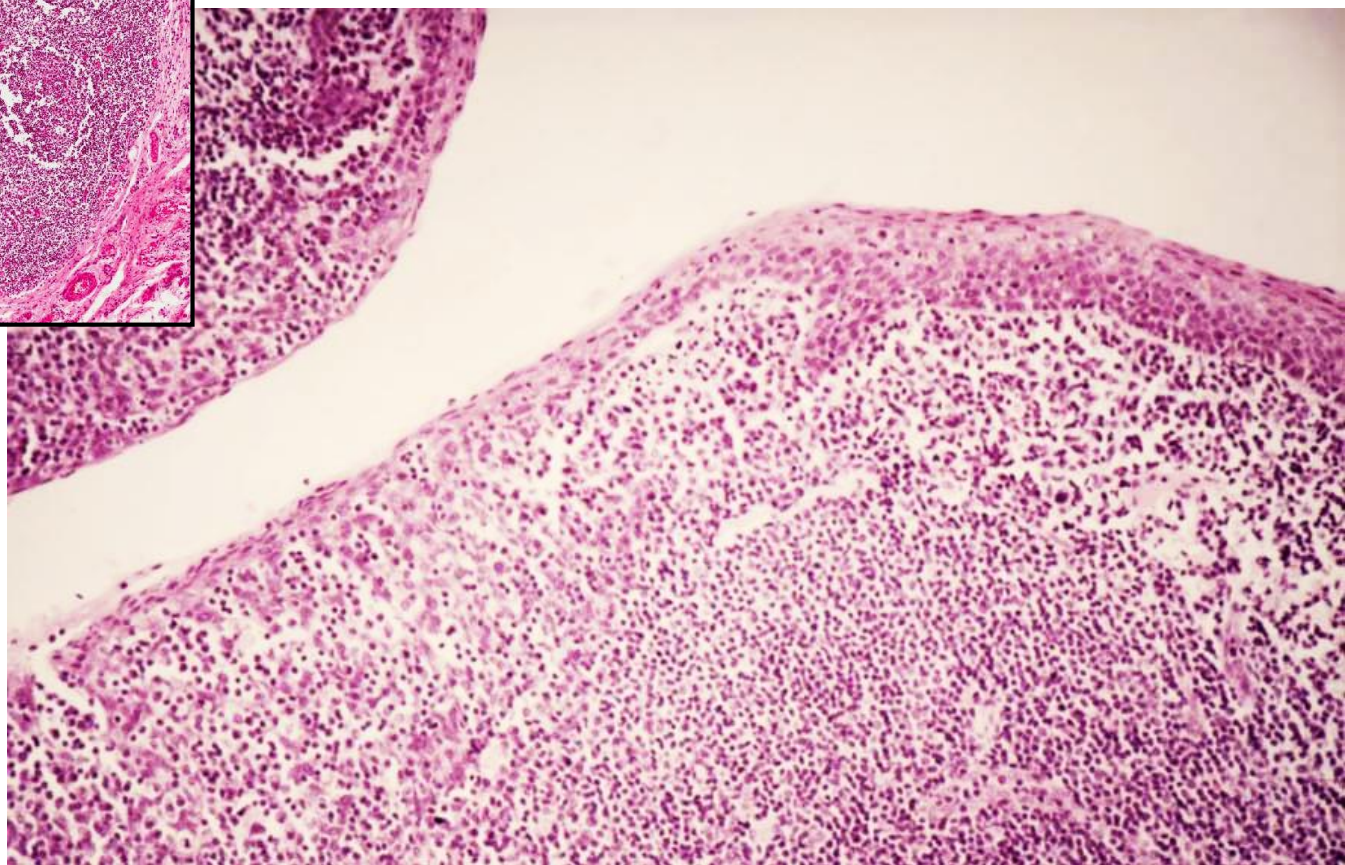
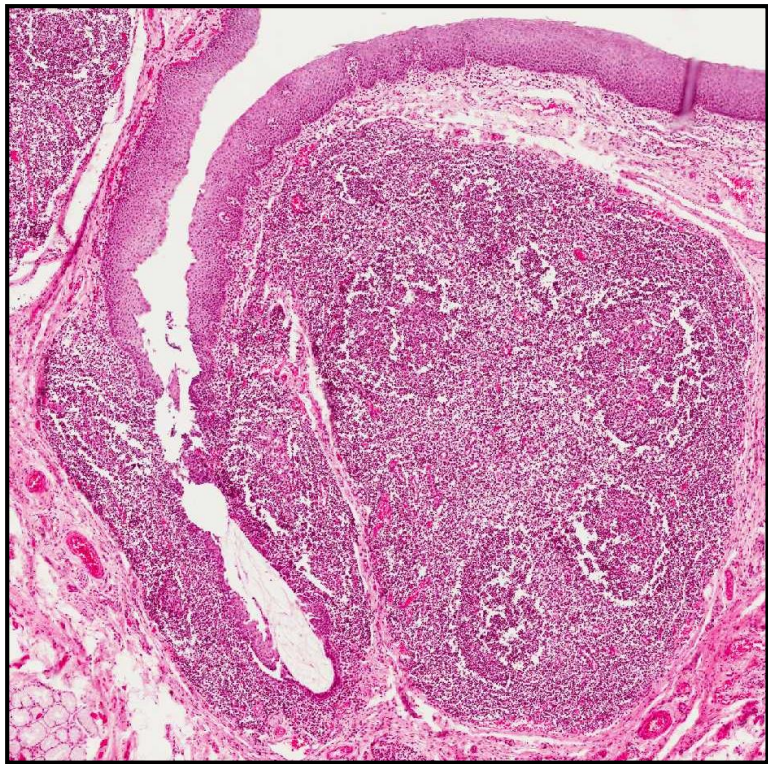


JAZYK – RADIX, TONSILLA LINGUALIS

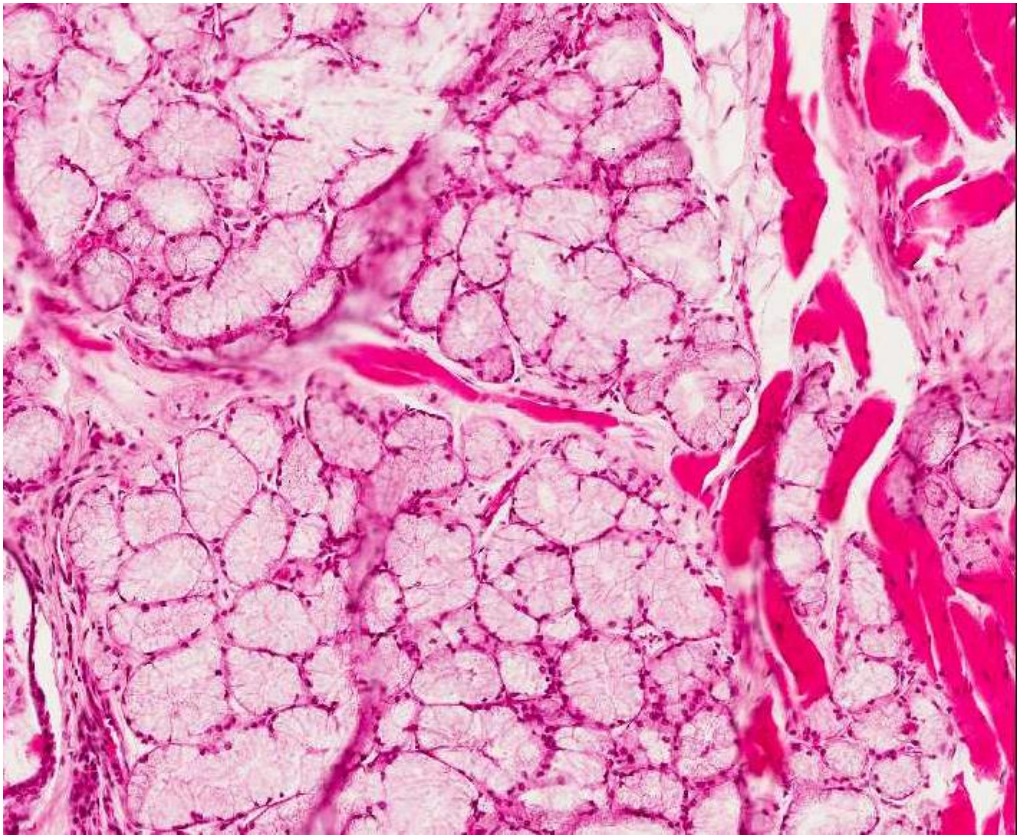
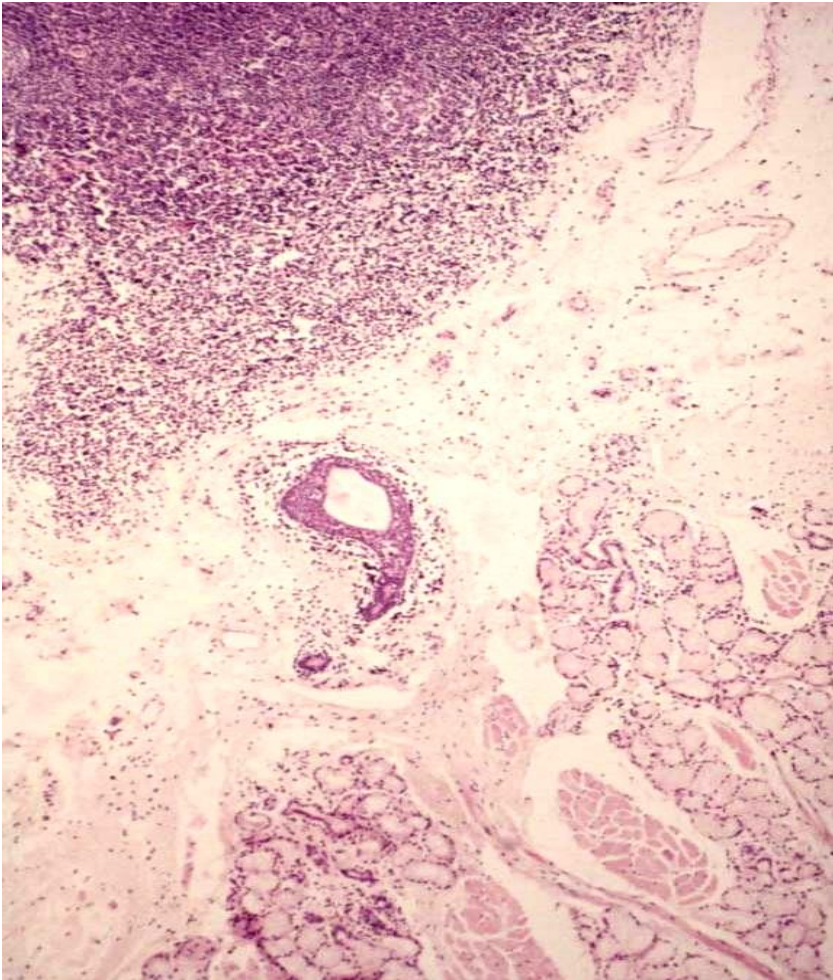




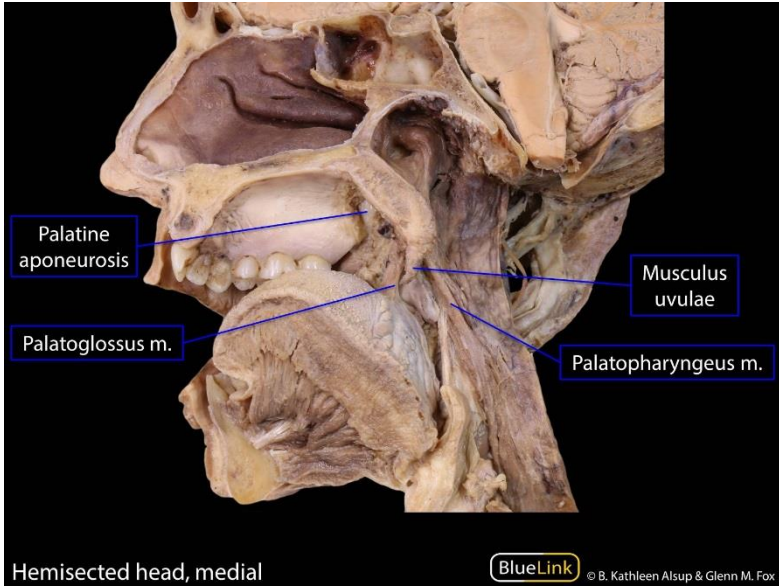
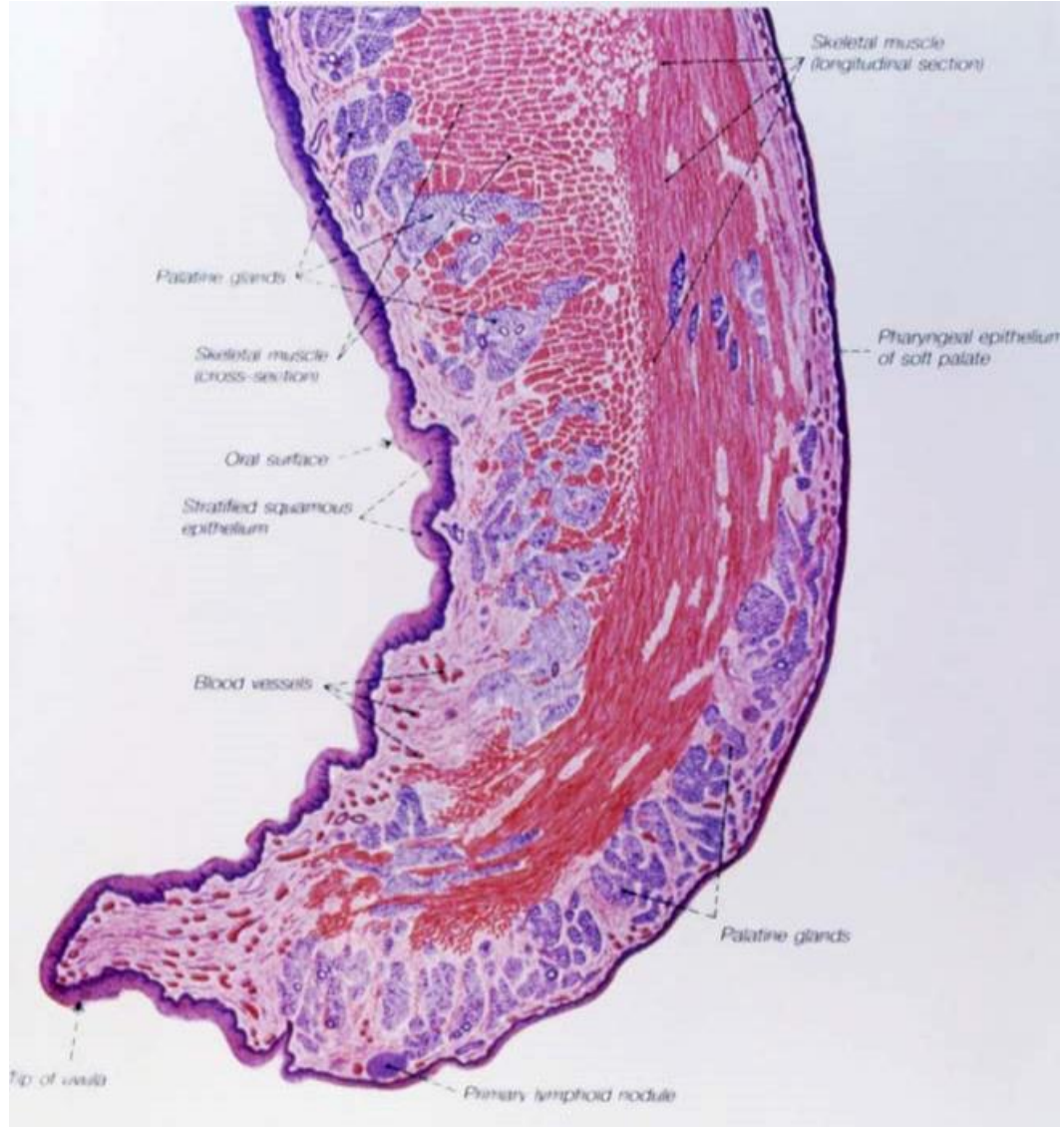
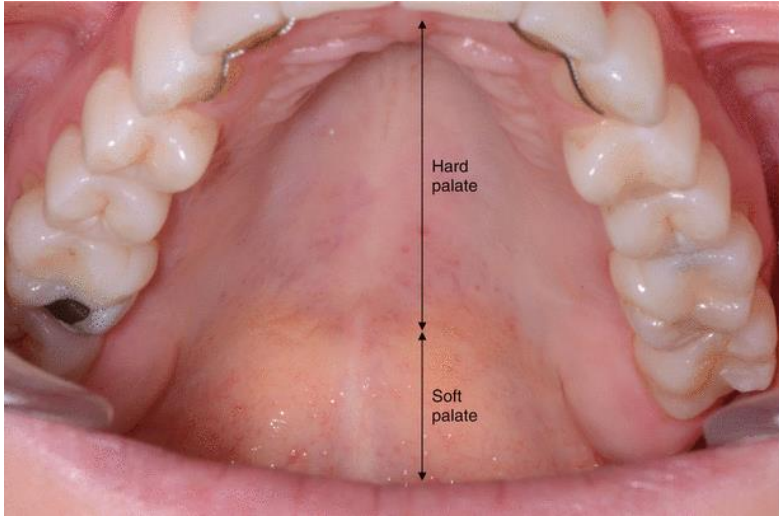
JAZYK – RADIX, TONSILLA LINGUALIS - KRYPTY



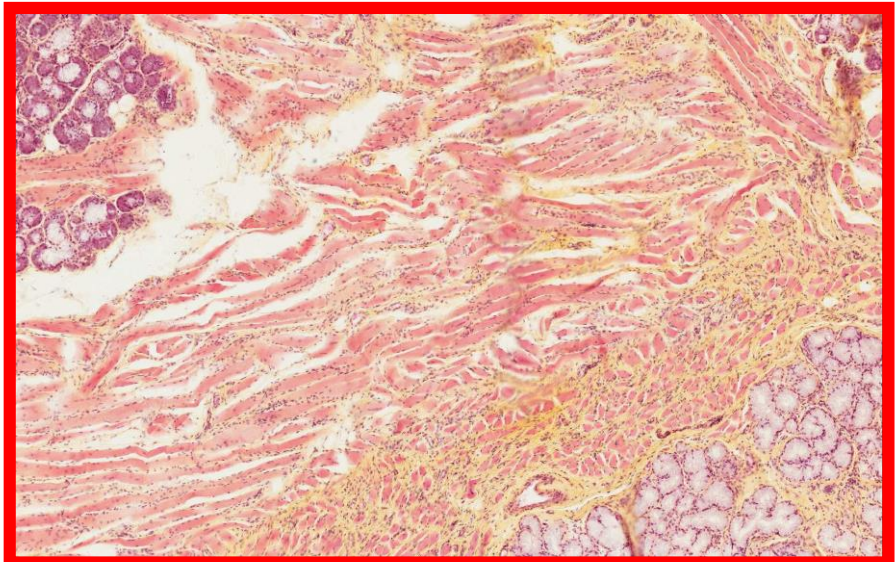
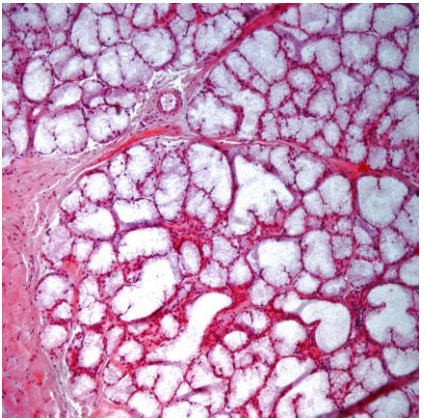
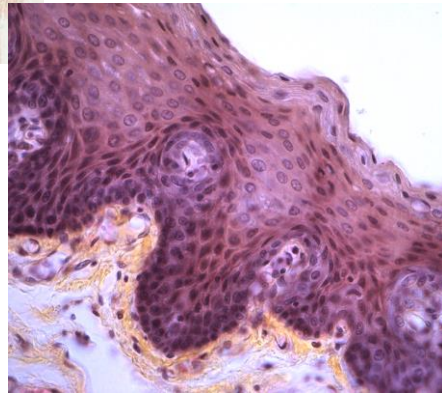
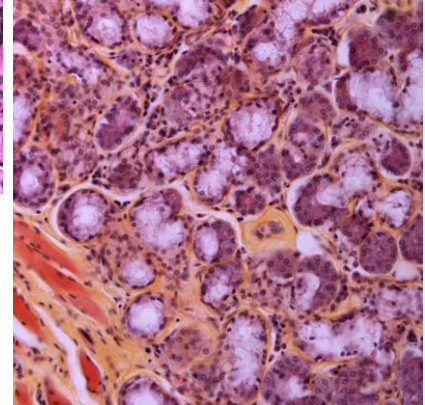
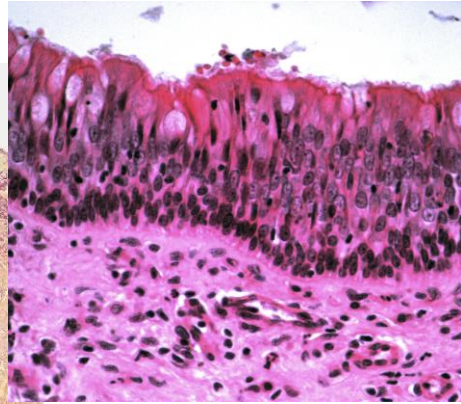
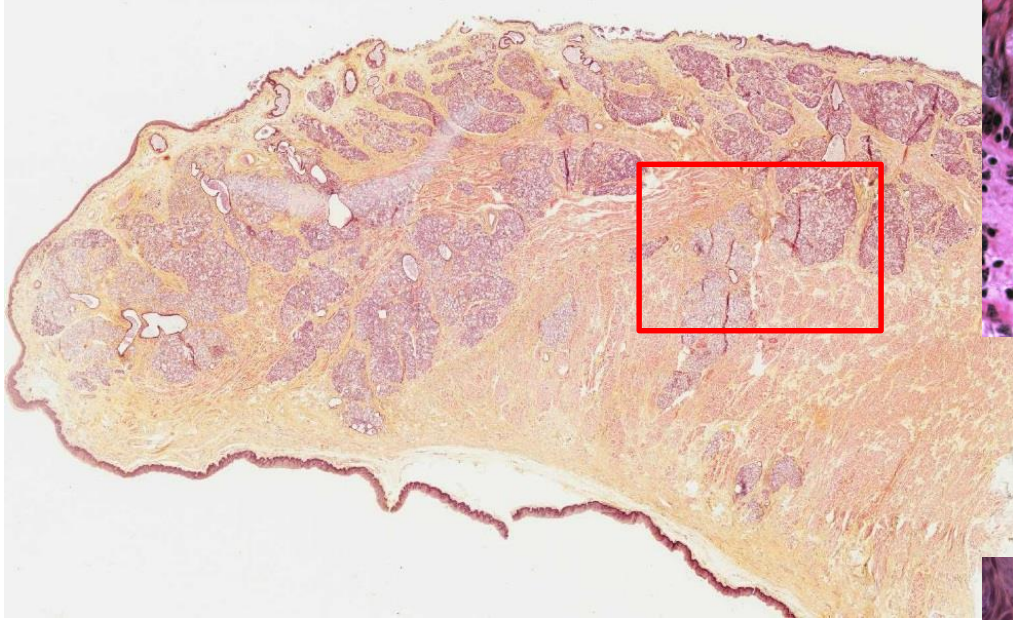
# JAZYK – RADIX, TONSILLA LINGUALIS A WEBEROVY ŽLÁZY



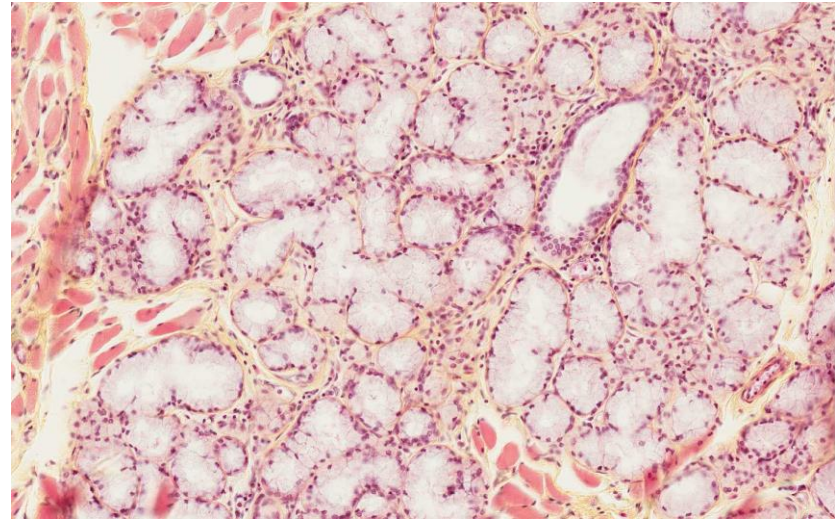
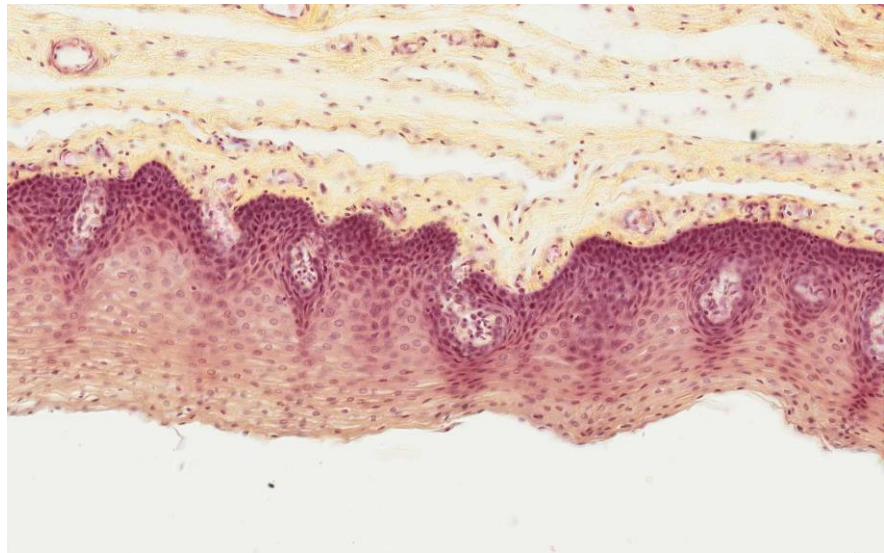
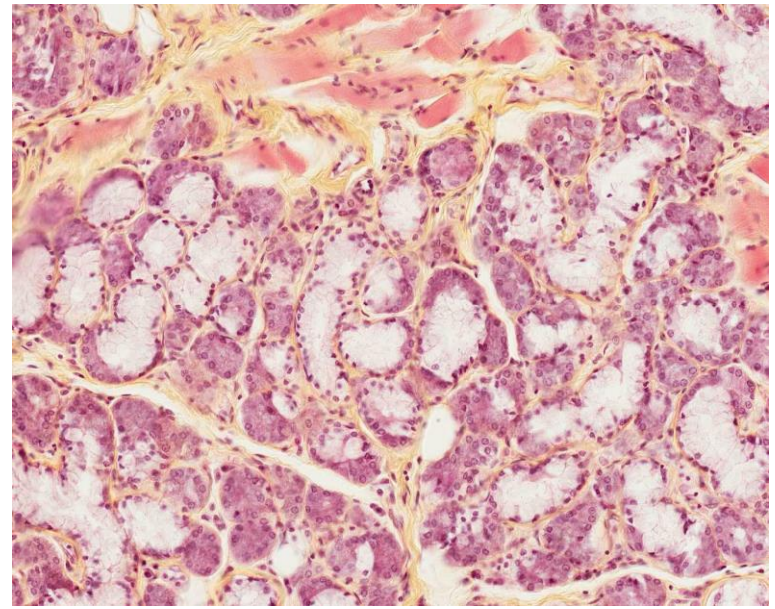
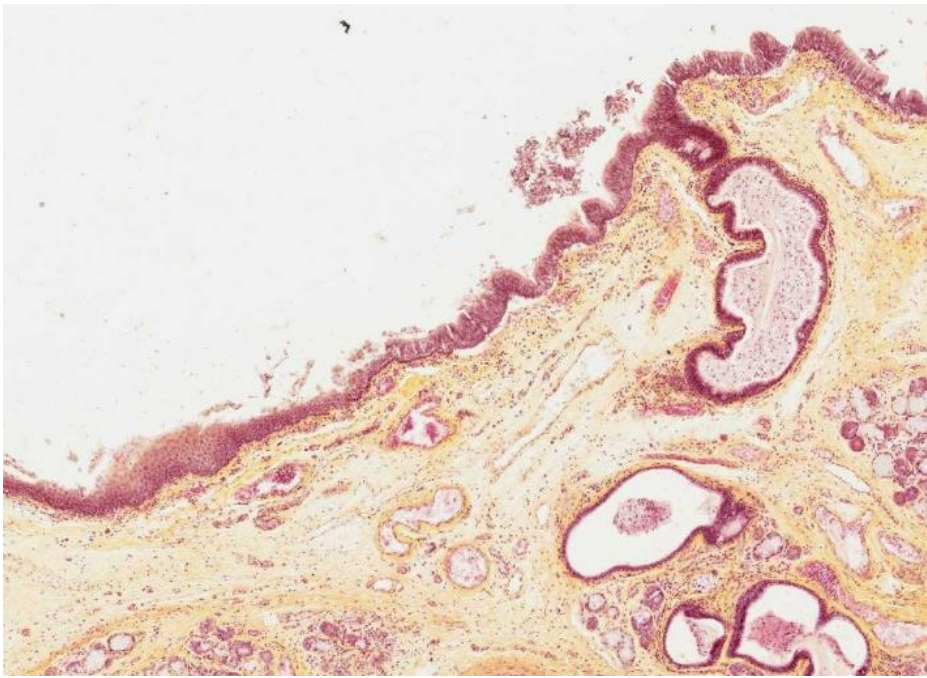
# PATRO



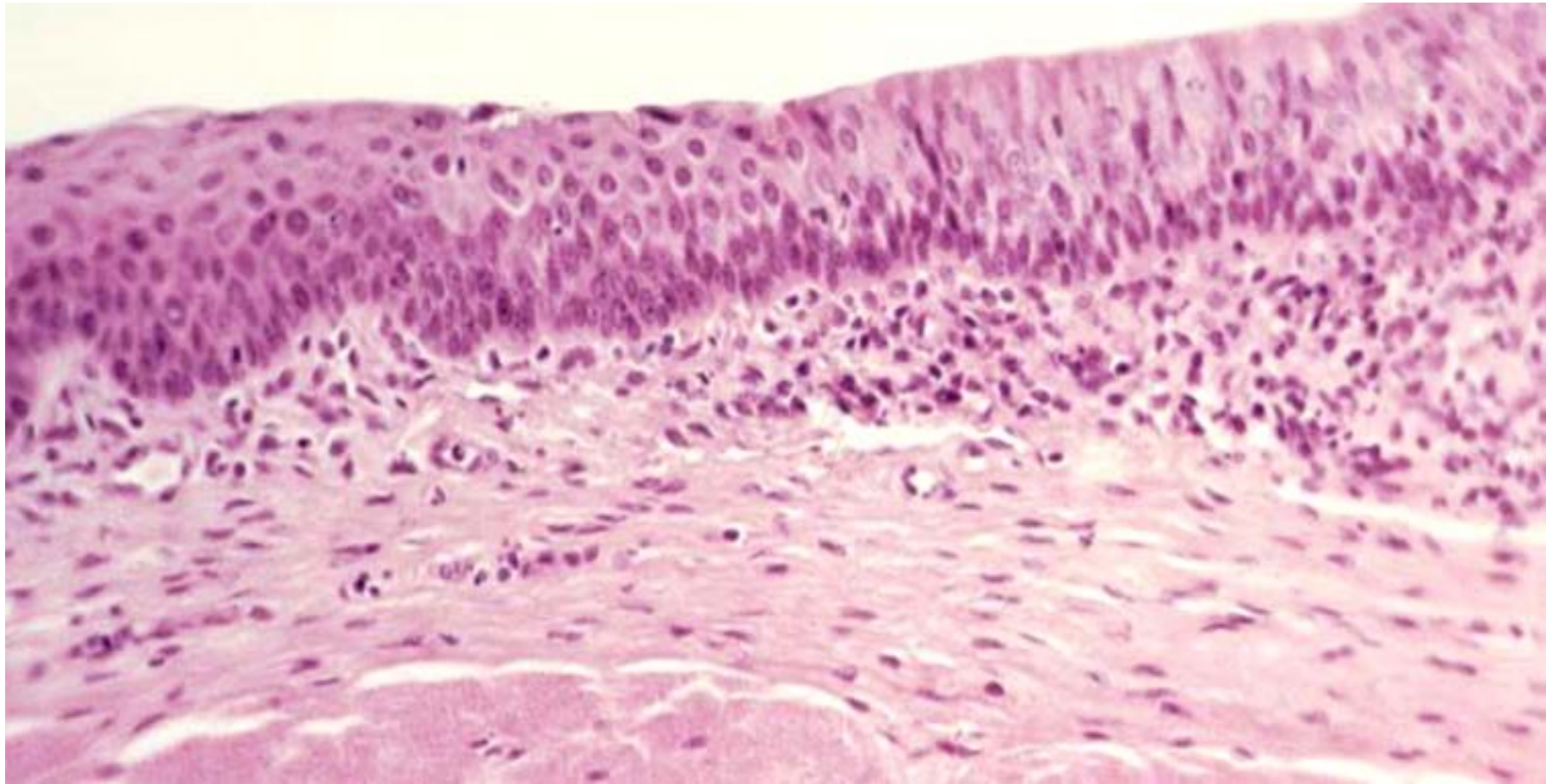
# MĚKKÉ PATRO



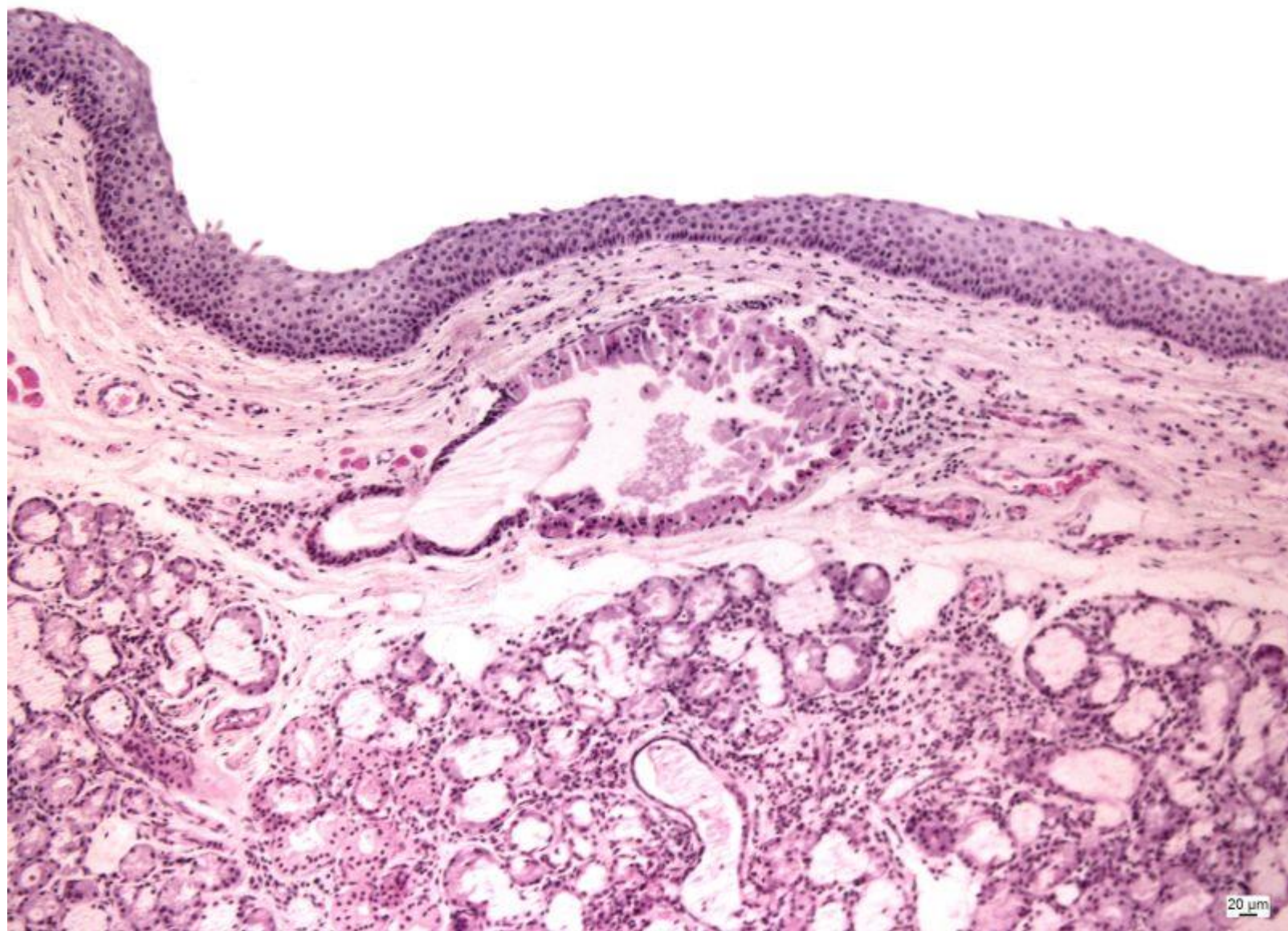
# MĚKKÉ PATRO



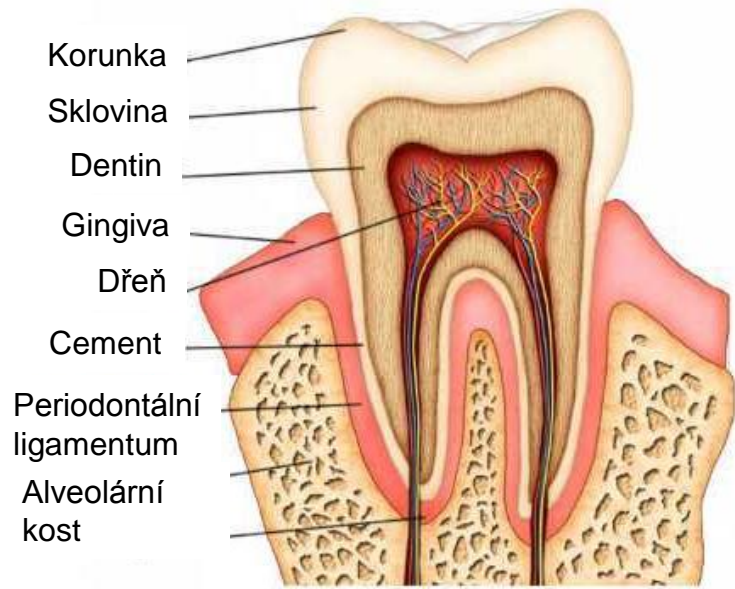
# MĚKKÉ PATRO - PŘECHOD EPITELŮ



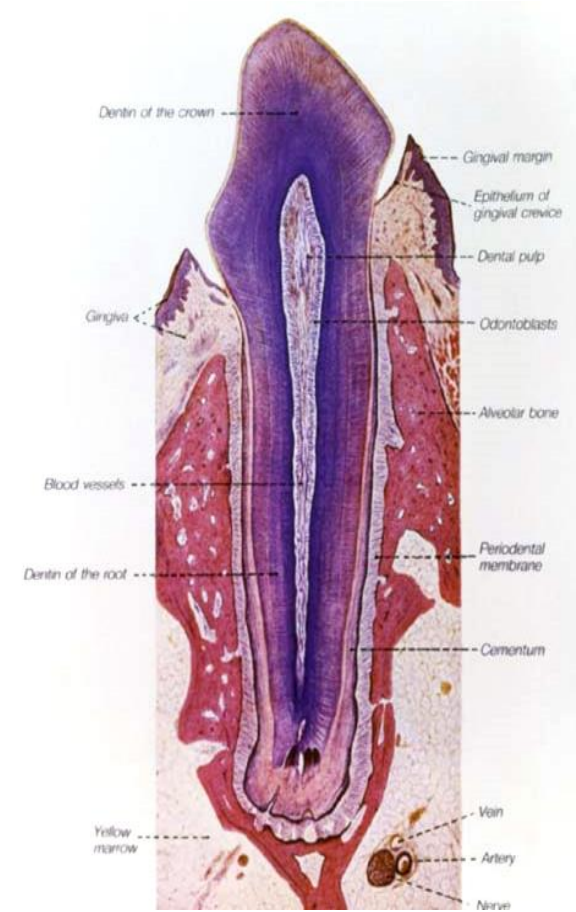
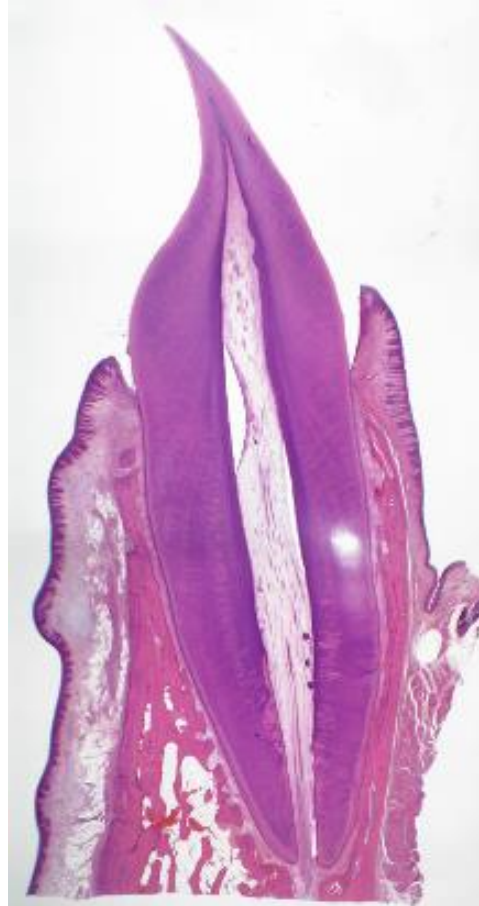# MĚKKÉ PATRO - METAPLASIE



# ZUB

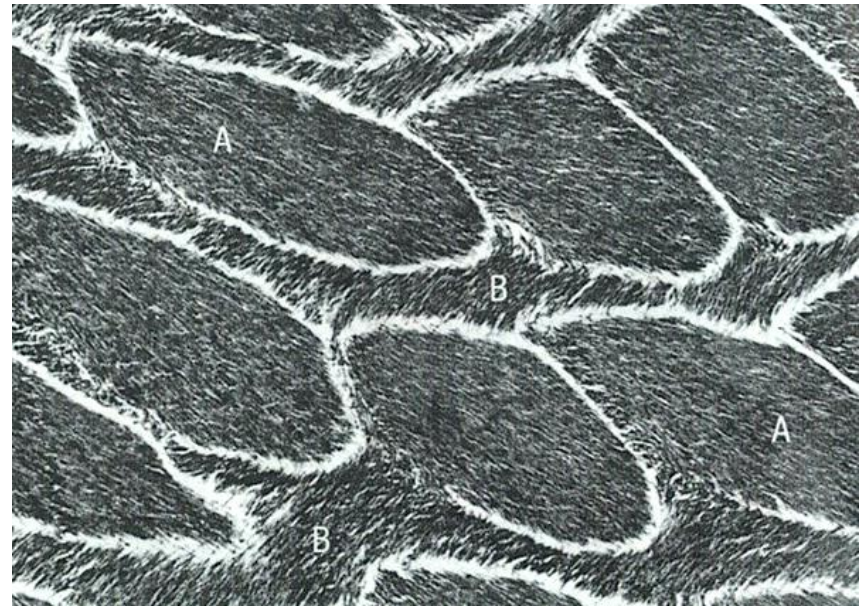
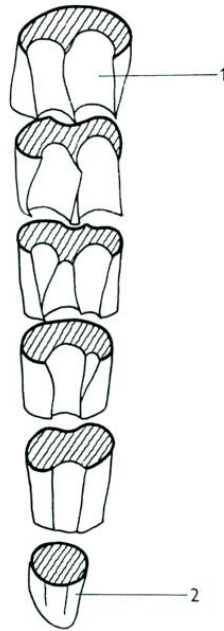
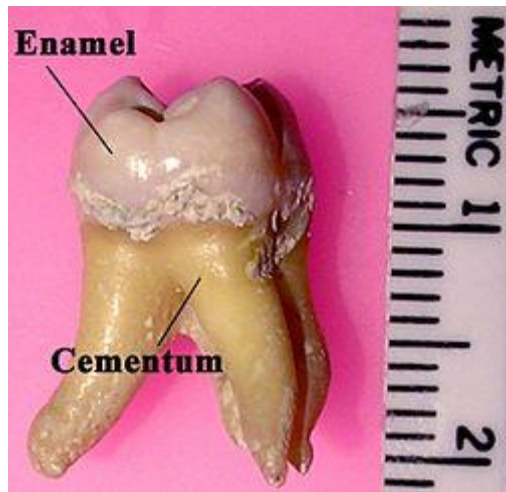

- Anatomická × klinická korunka
- Krček
- Kořen





# ZUB - ZUBNÍ SKLOVINA A CEMENT

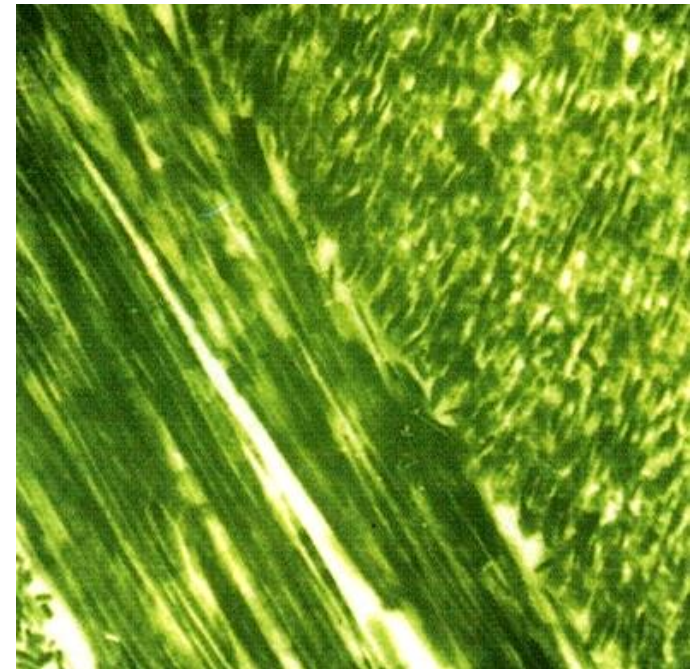


## Sklovina

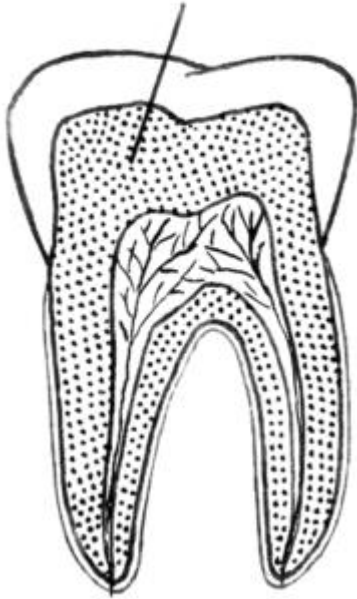
- **Ameloblasty**
- Neregeneruje
- 96% Ca-hydroxyapatit, prizmata
- Enameliny, amelogeniny, ameloblastiny

## Cement

- **Cementoblasty**
- Regeneruje
- 50% Ca-hydroxyapatit
- Kolagen I, III, XII, GAG, proteoglykany
- Sharpeyova vlákna - zubní alveolus

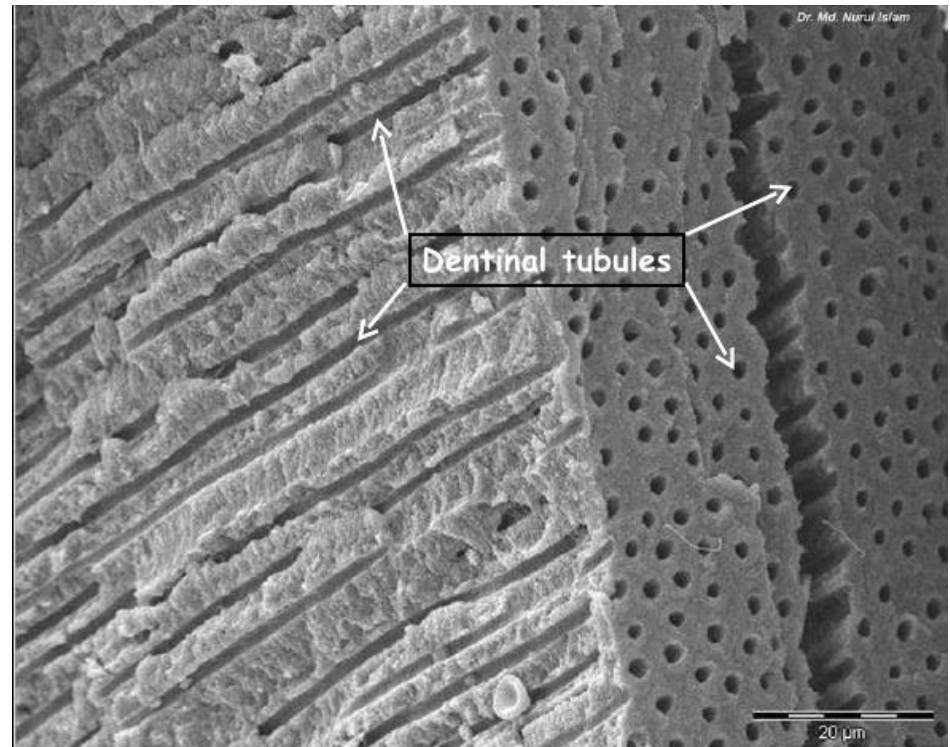
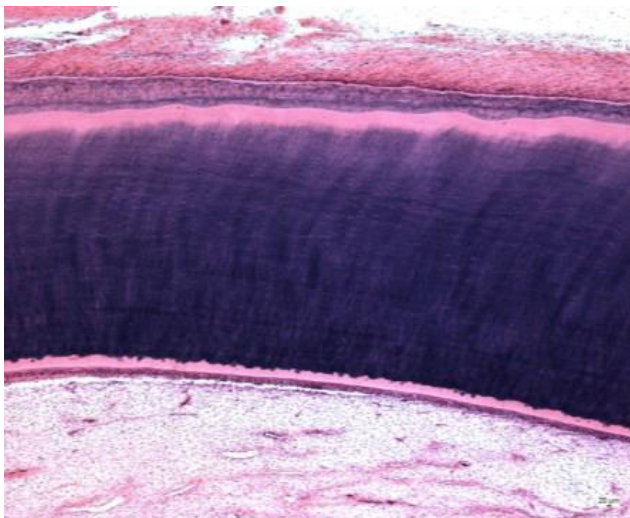


## DENTIN

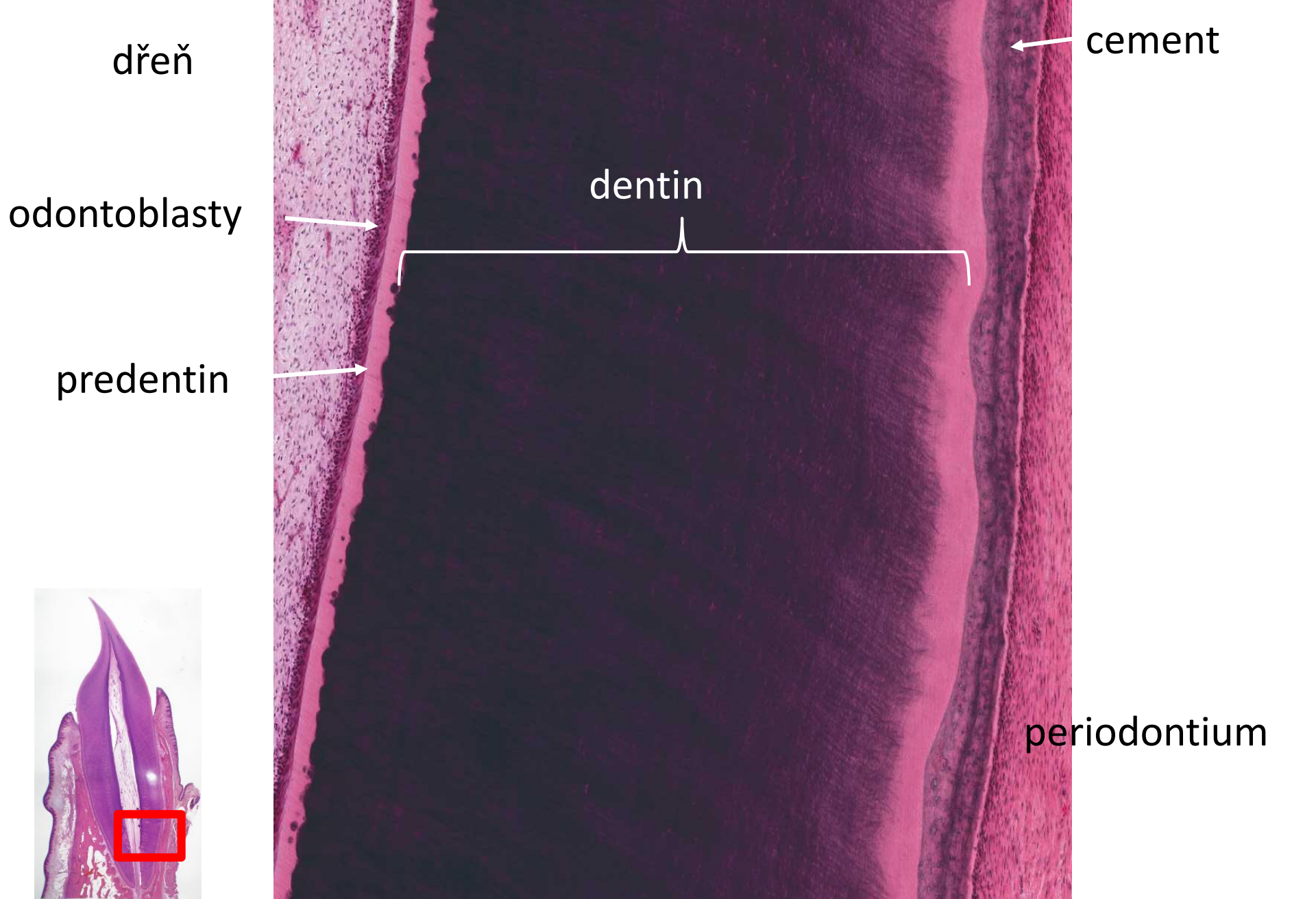


### Dentin

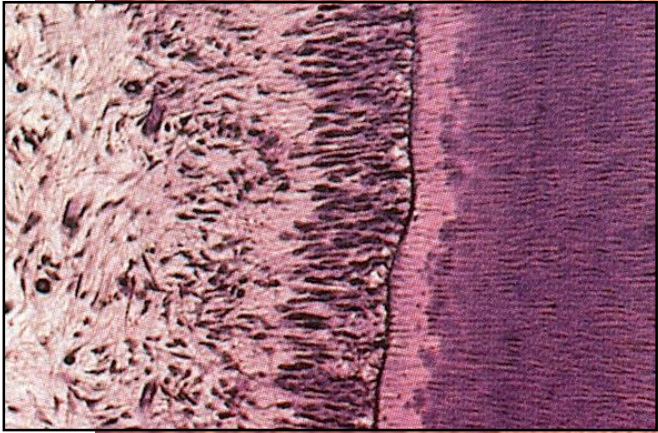
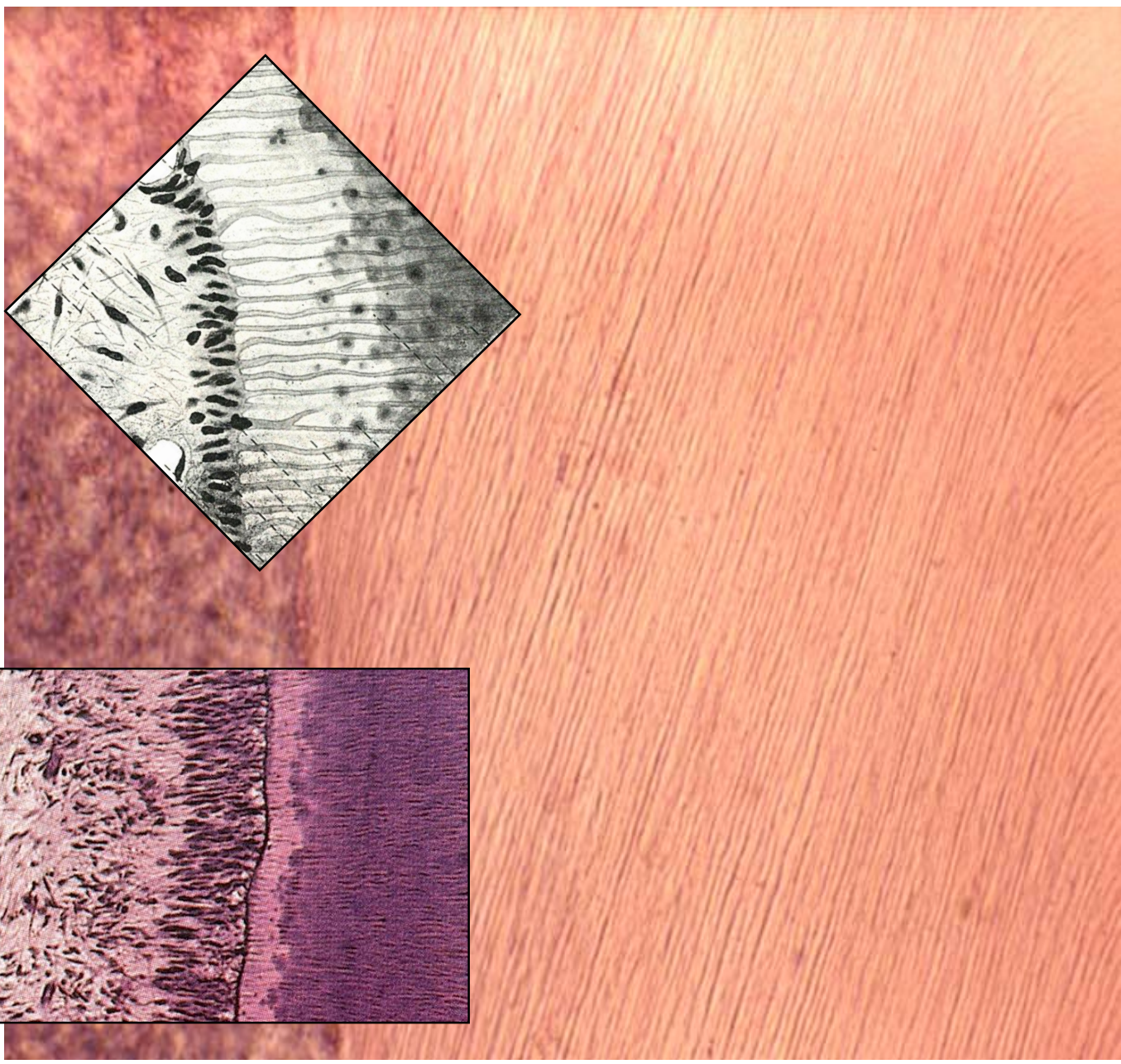
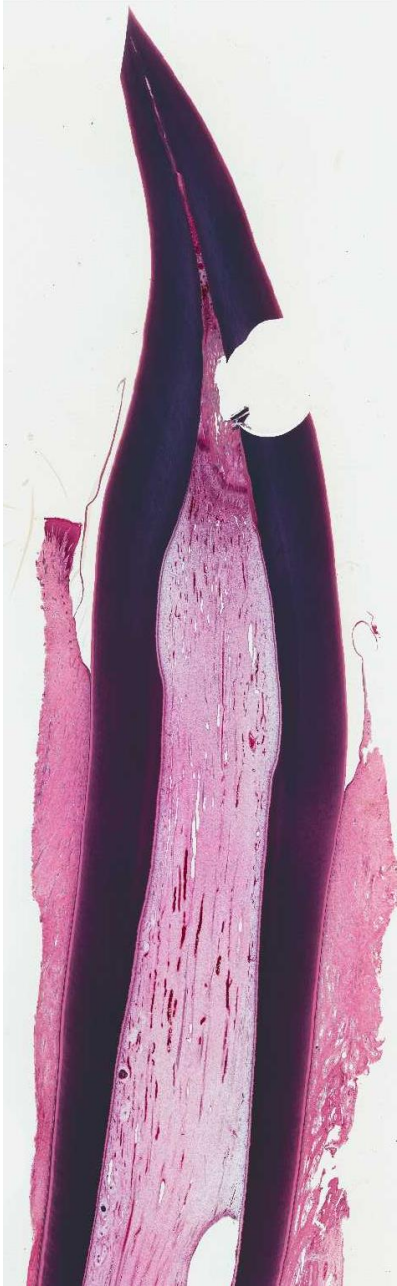
- **Odontoblasty**
- Regeneruje
- 70% Ca-hydroxyapatit
- Kolagen I, glykoproteiny, proteoglykany
- Výběžky odontoblastů - Tomesova vlákna
- Owenovy linie
- Nervová vlákna



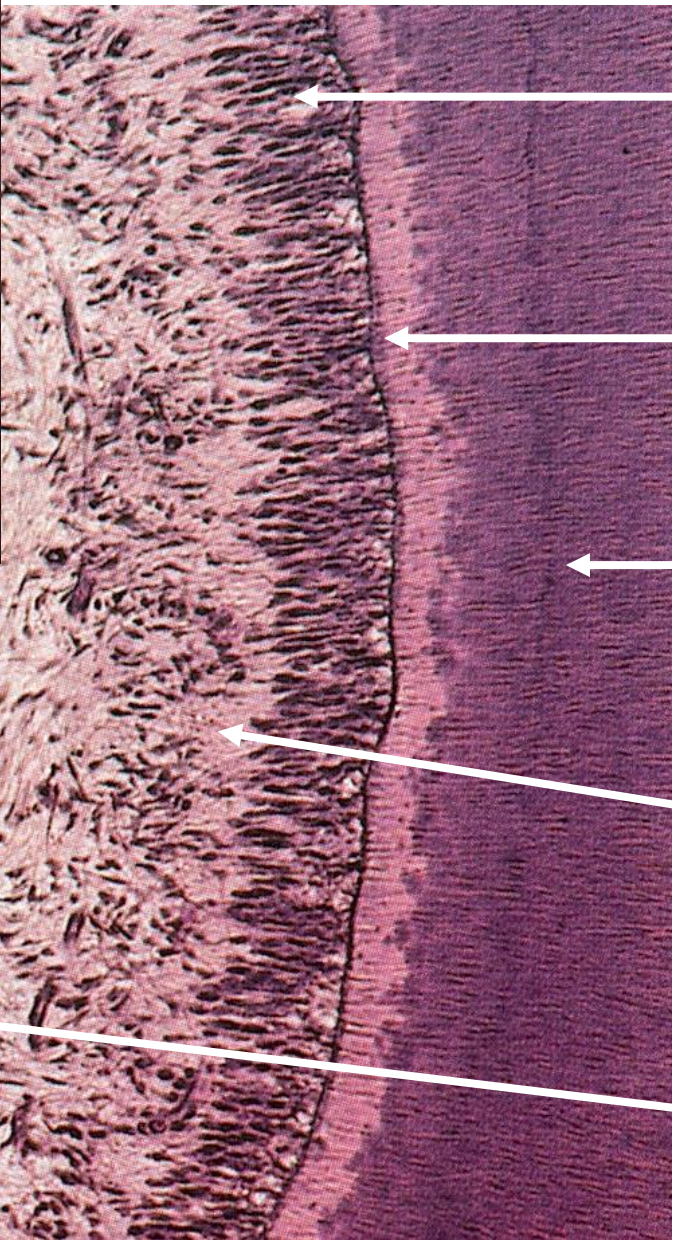

# ZUB - DENTIN



# ZUB - ODONTOBLASTY



# ZUB - ODONTOBLASTY



odontoblasts

predentin

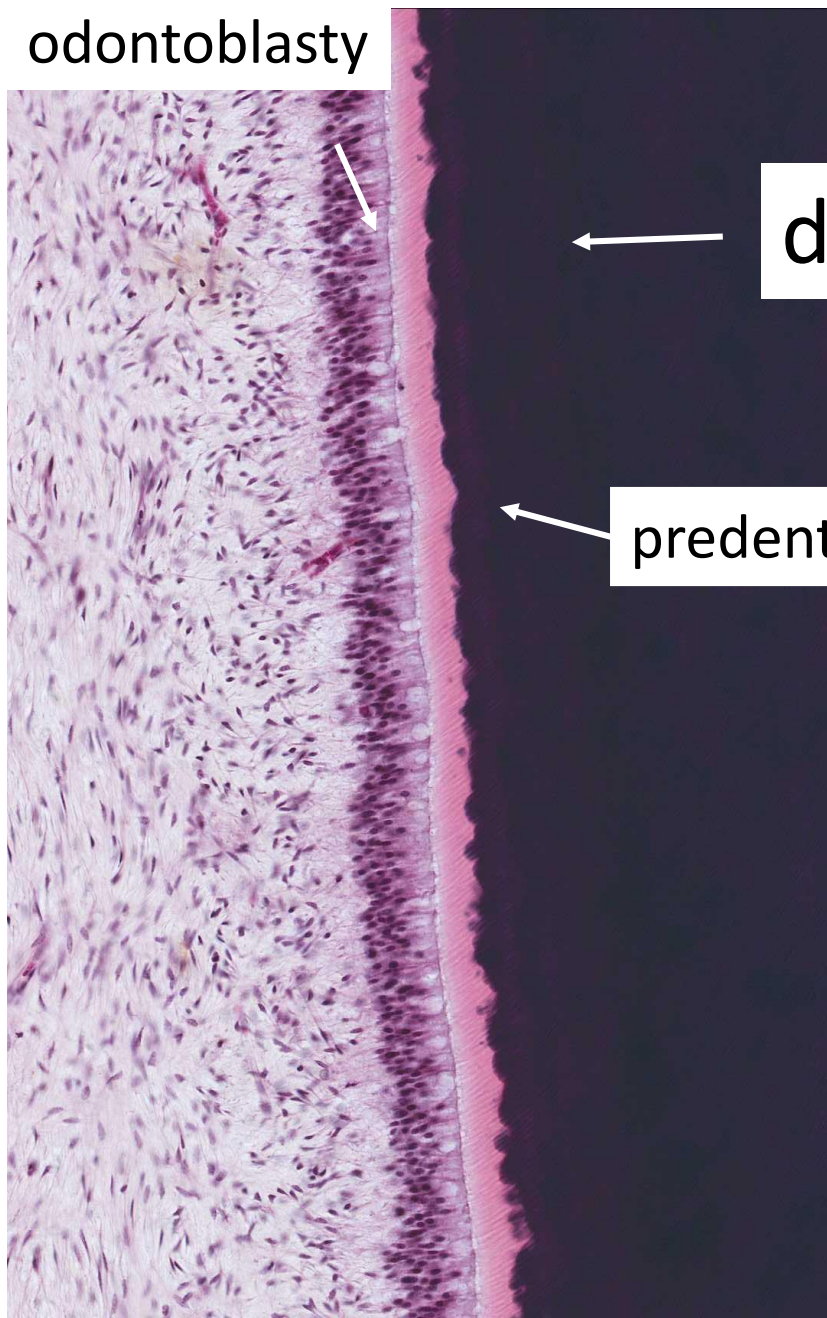
dentin

subodontoblastic zone

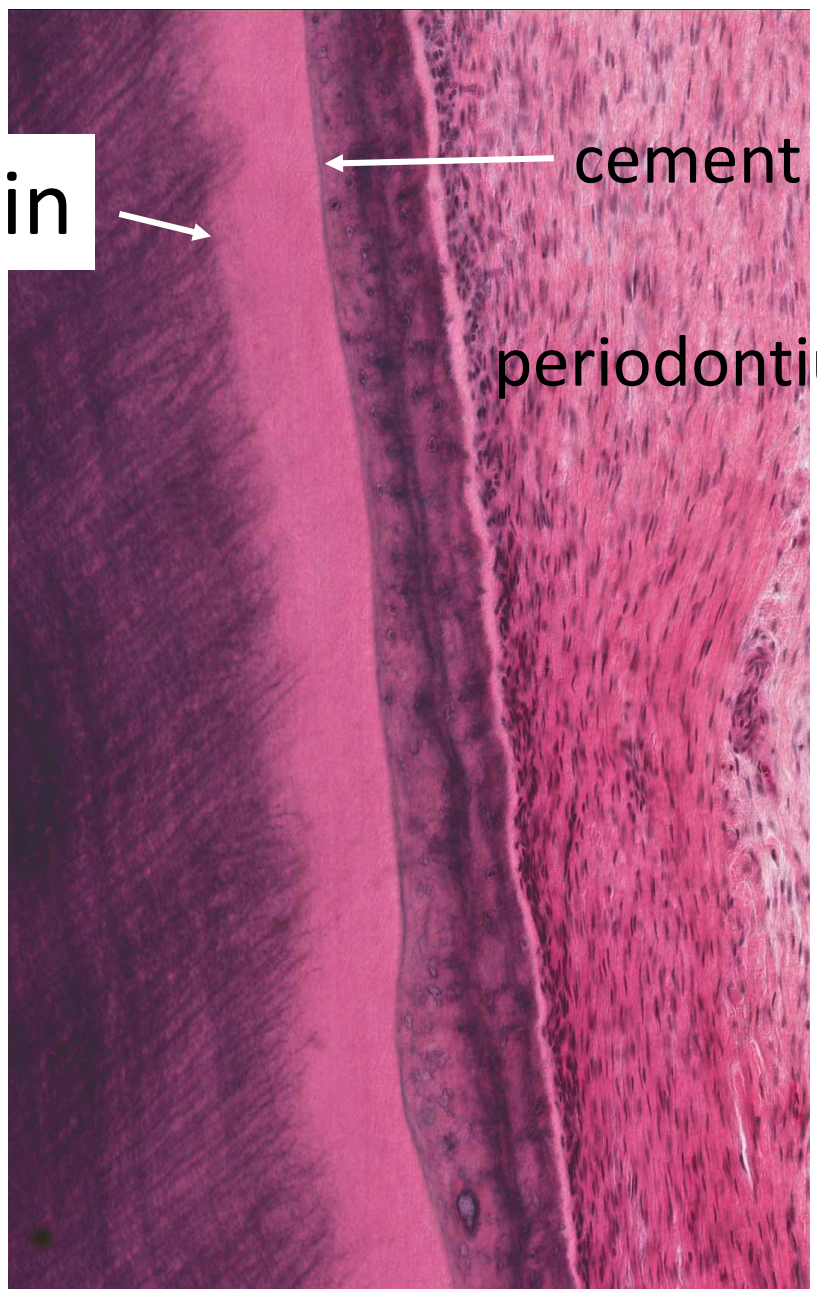
pulp

ZUB

odontoblasty



dentin

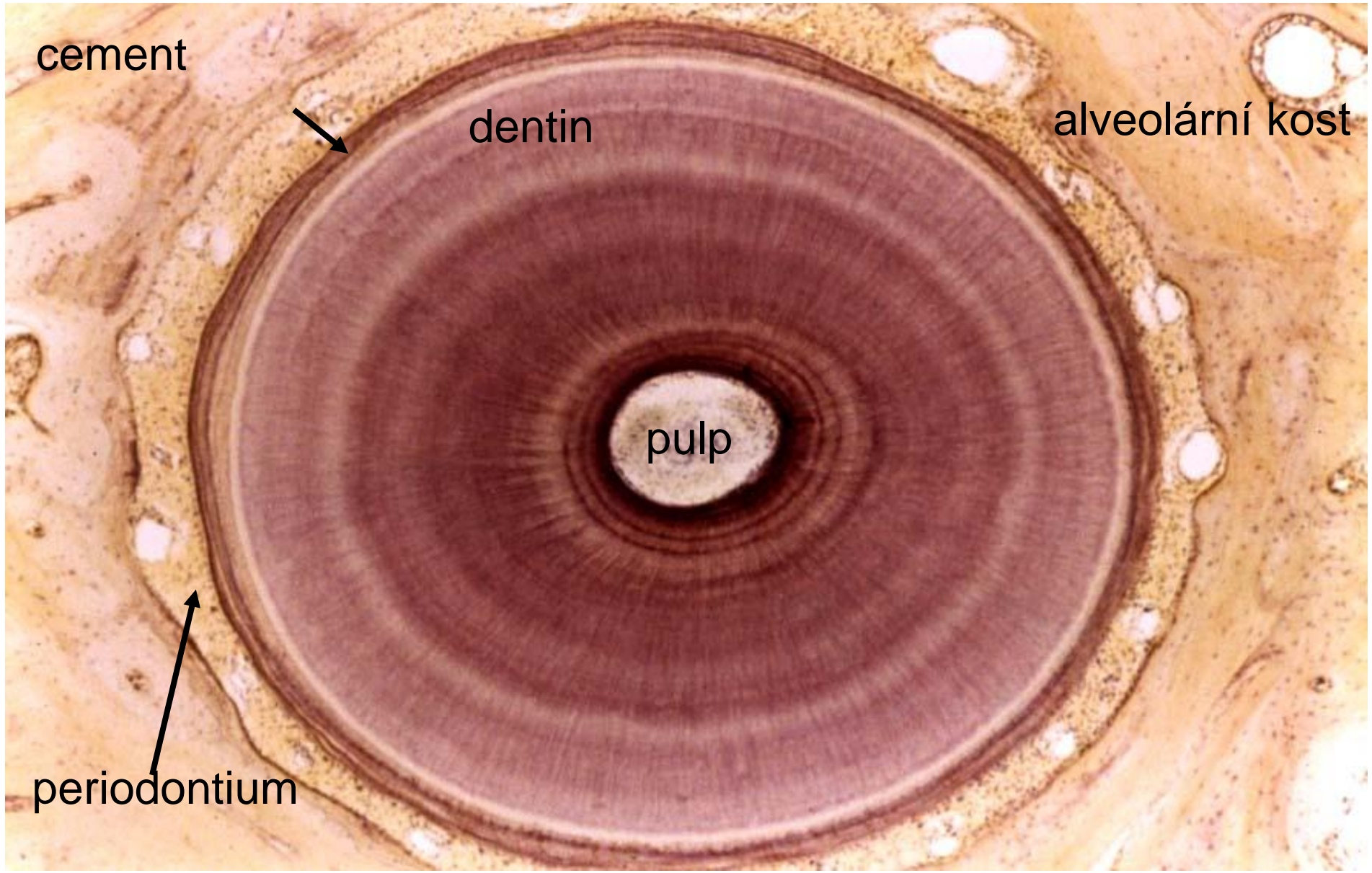


cement

periodontium

predentin

ZUB



cement

dentin

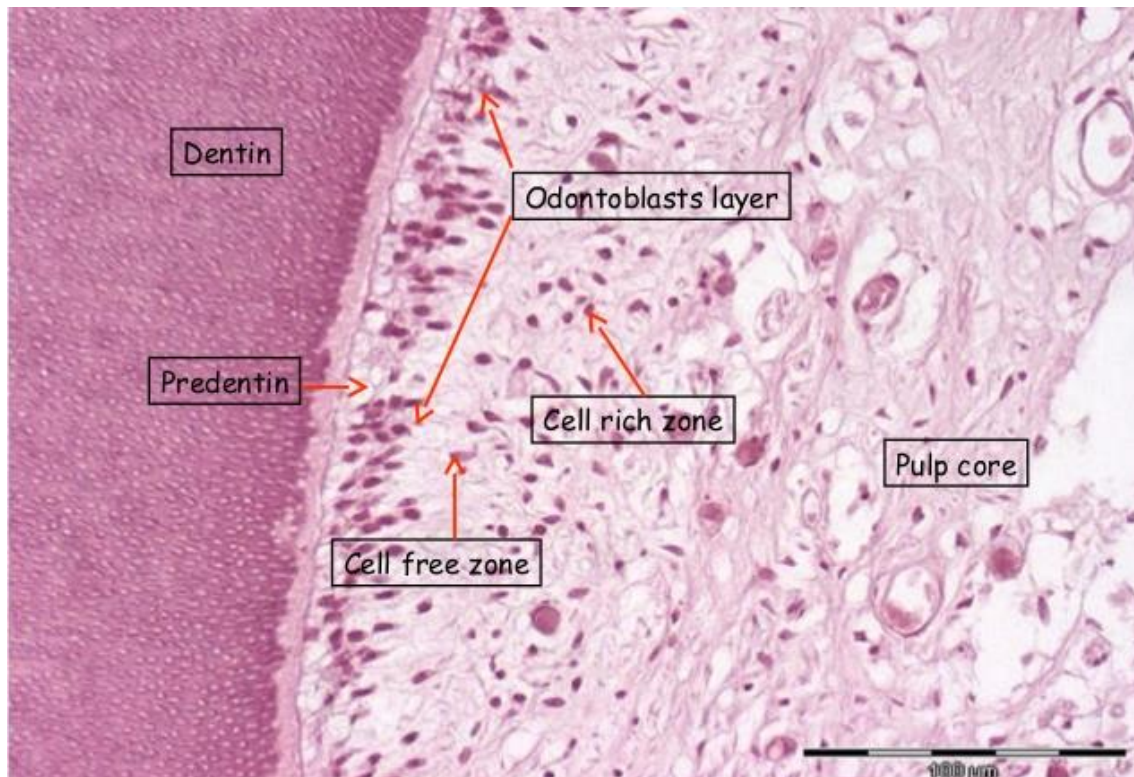
pulp

alveolární kost

periodontium

# ZUB - DŘEŇ (PULPA)

- rosolovité vazivo podobné embryonálnímu mesenchymu
- bohatá vaskularizace a inervace
- korunková dřeň a kořenový kanálek
- foramen apicale - periodontium
- odontoblasty
- nociceptivní nervová vlákna (plexus Raschkowi)

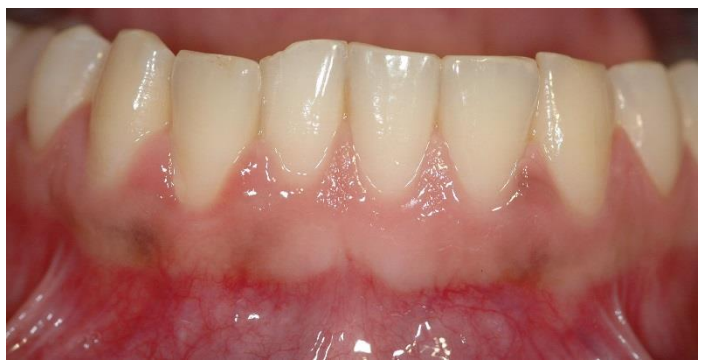

<https://www.slideshare.net/hesham63/pulp-15597098>

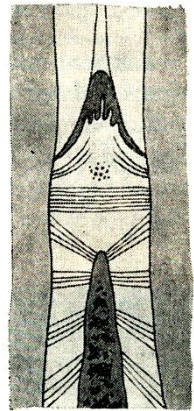
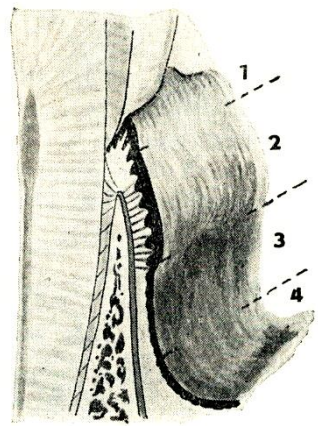


## Dáseň

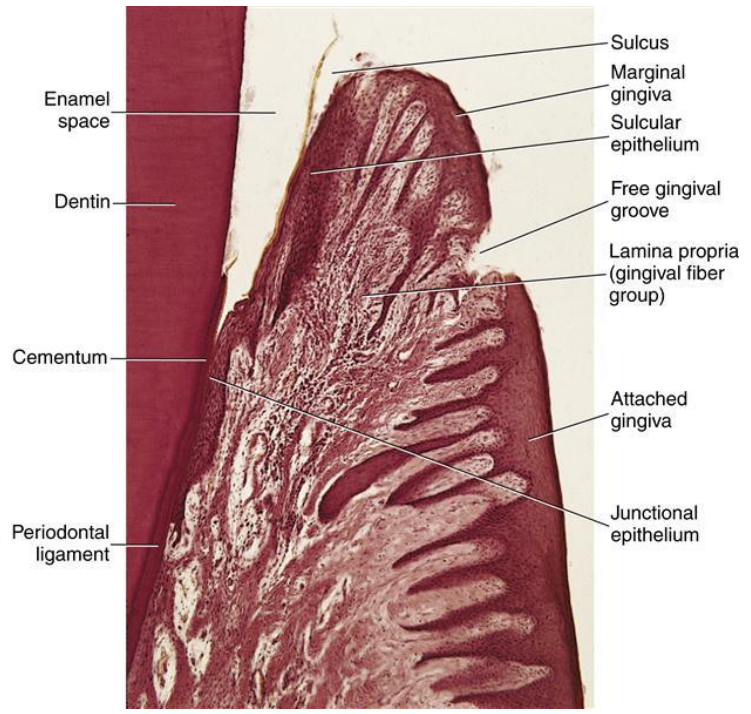
- volná (marginální, g. libera)
- připojená (g. affixa)
- paramarginální rýha (zevní gingivální žlábek)
- sulcus gingivalis
- gingivodentální uzávěr



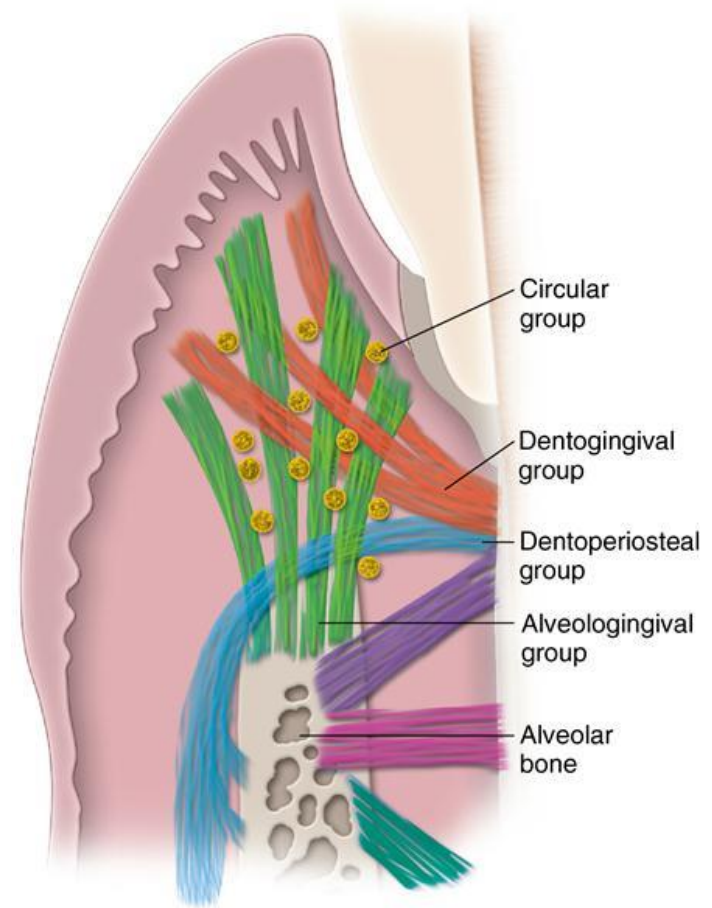
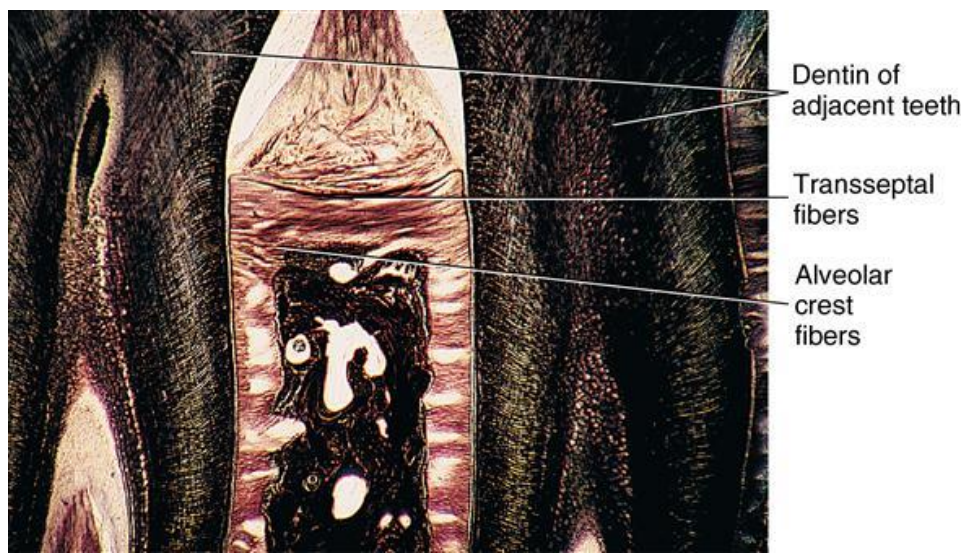
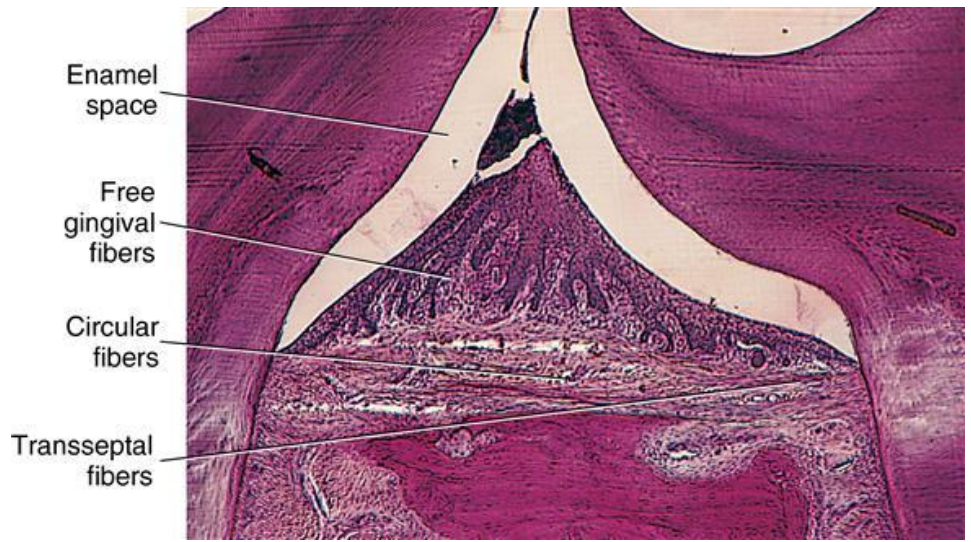
vrstevnatý dlaždicový epitel  
lamina propria mucosae – husté kolagenní vazivo



br. 8. Schéma gingivy. 1 — volná gingiva, 2 — připojená gingiva, 3 — alveolární sliznice, 4 — vestibulární sliznice

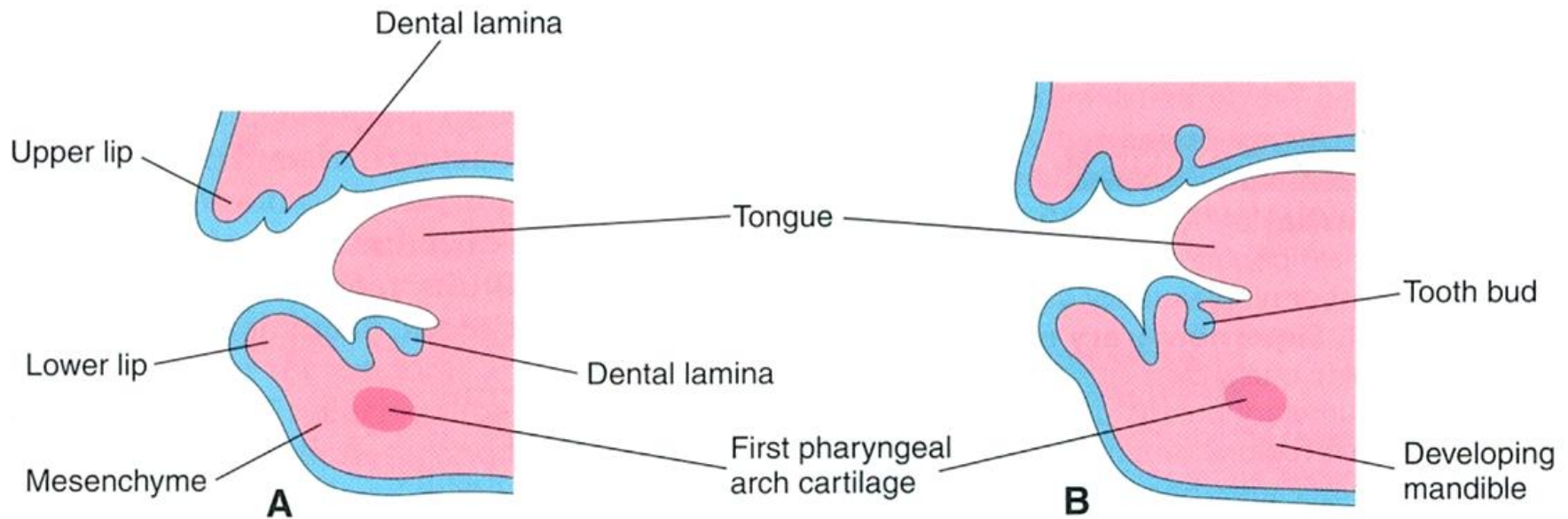


# ZUB – PERIODONTIUM A GINGIVA



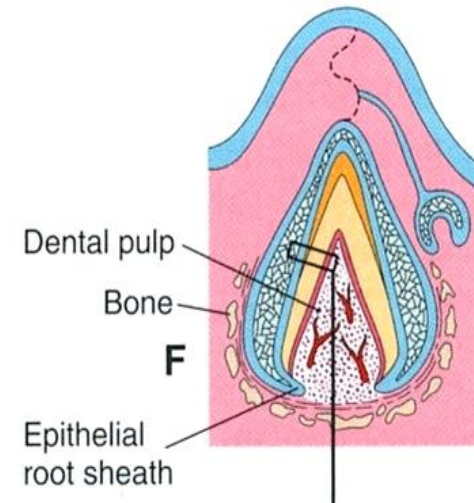
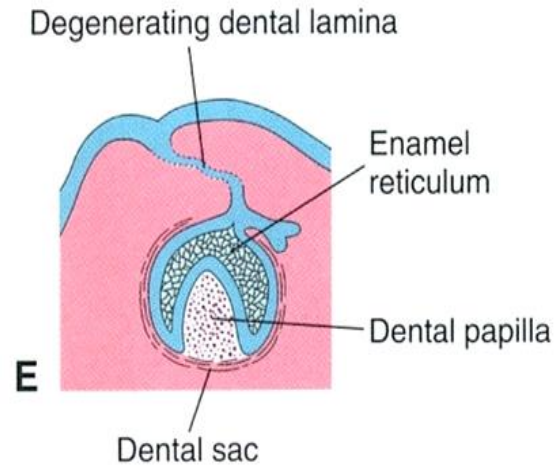
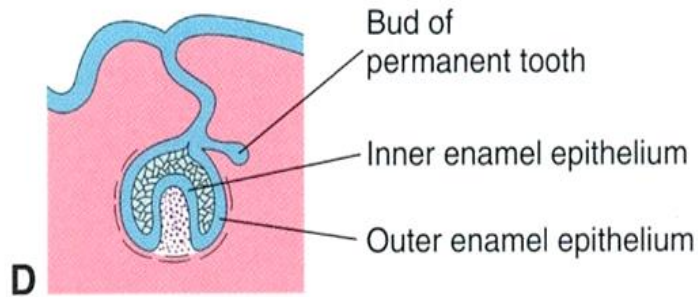
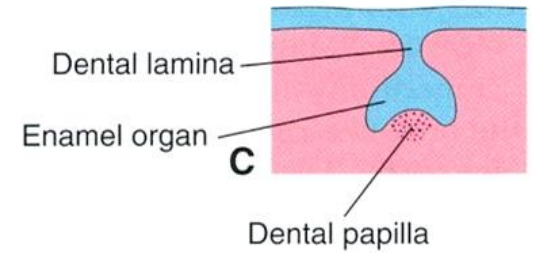
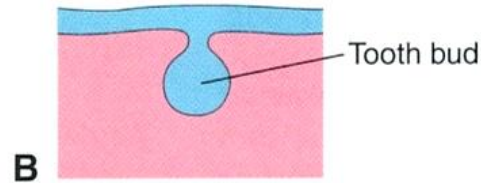
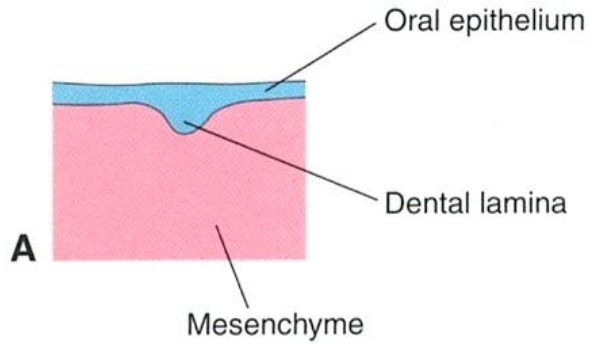
## Interakce ektodermu a mesenchymu

- primární dentální lamina – zubní primordia

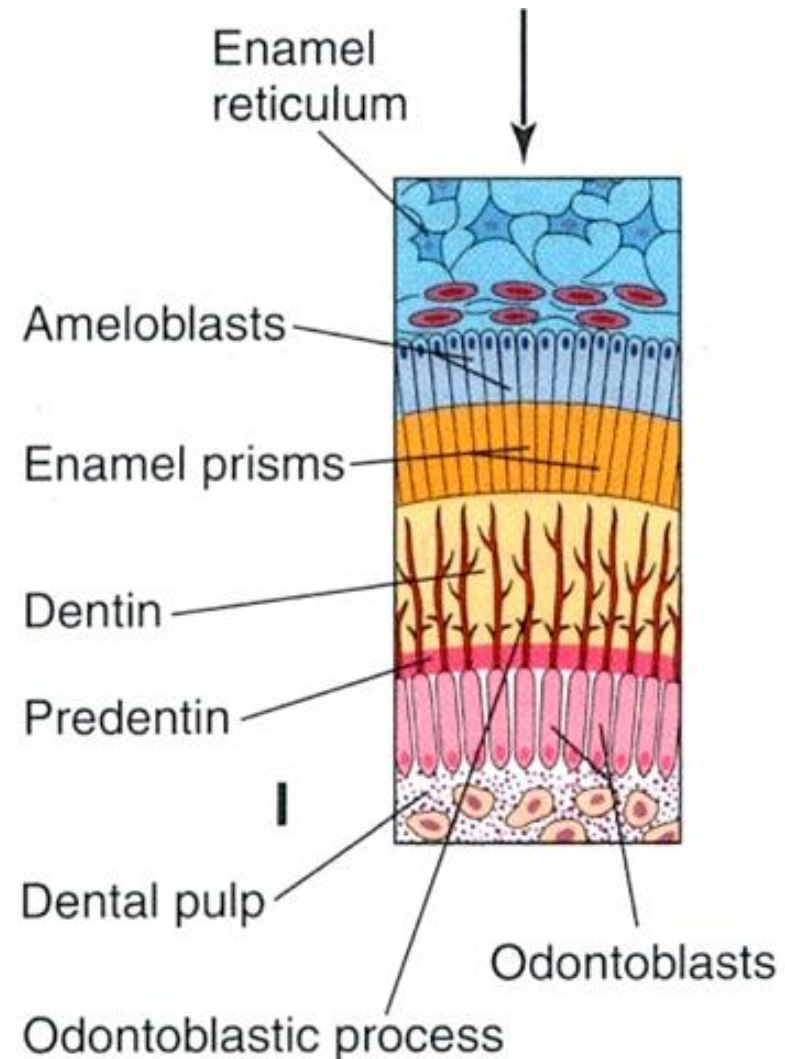
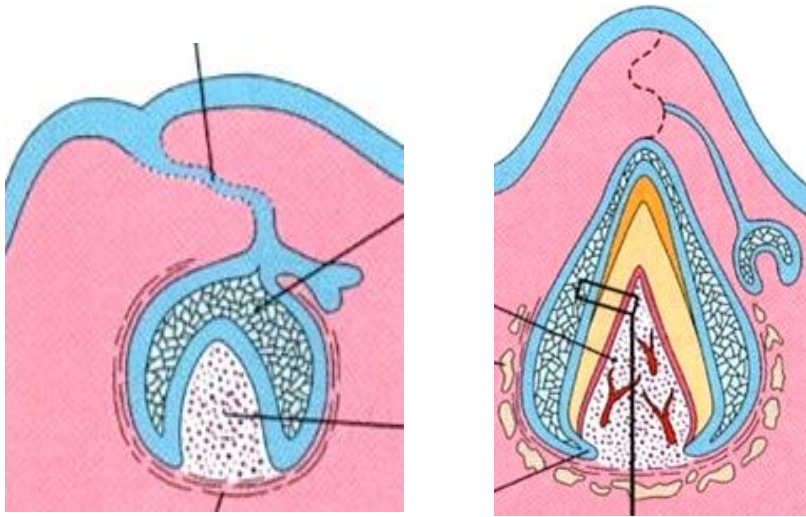


# VÝVOJ ZUBU

- Primordium
- Zubní váček (zubní papila)
- Zubní pohárek (orgán skloviny)



# VÝVOJ ZUBU

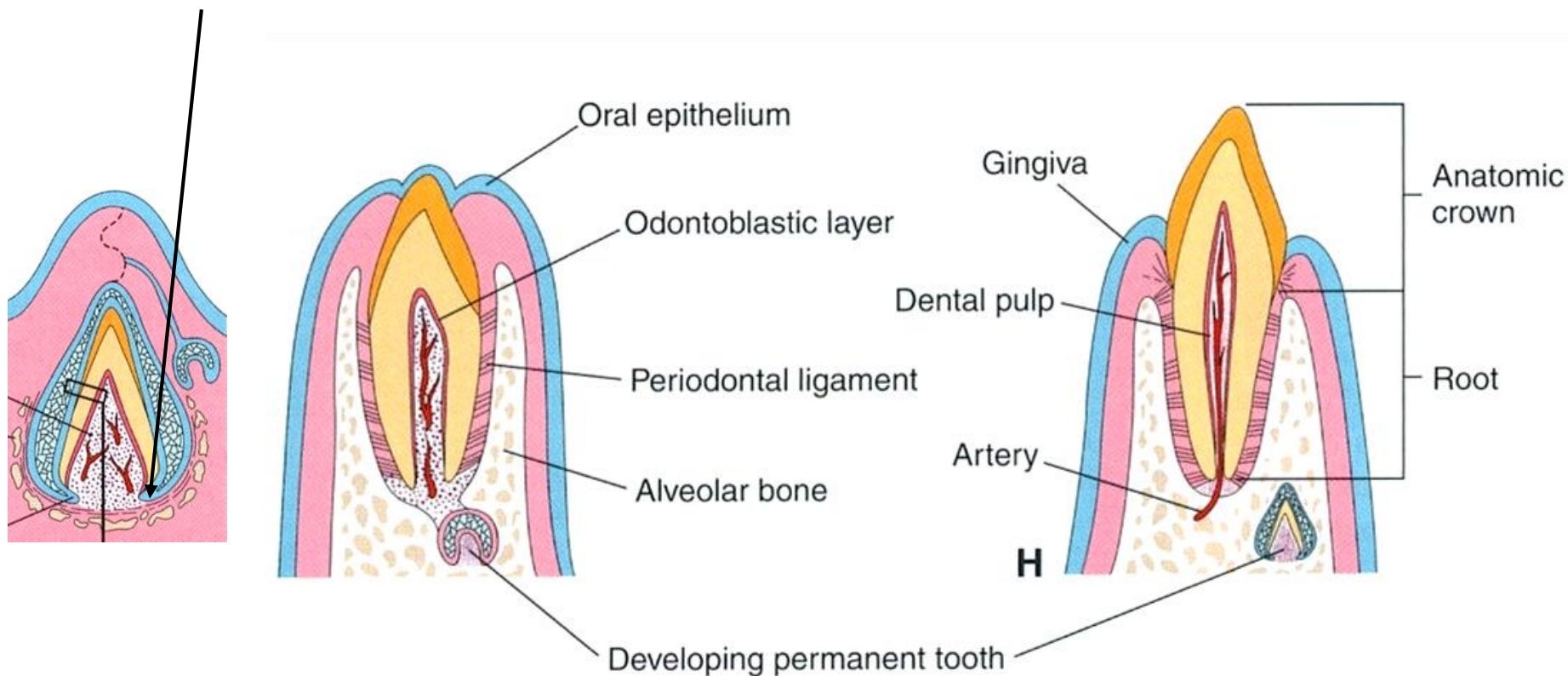


- orgán skloviny (zevní a vnitřní ameloblasty, pulpa skloviny – sklovinné retikulum) - produkce sklovinných prizmat
- diferenciacie odontoblastů - ukládání dentinové matrix
- výběžky odontoblastů: Tomesova vlákna

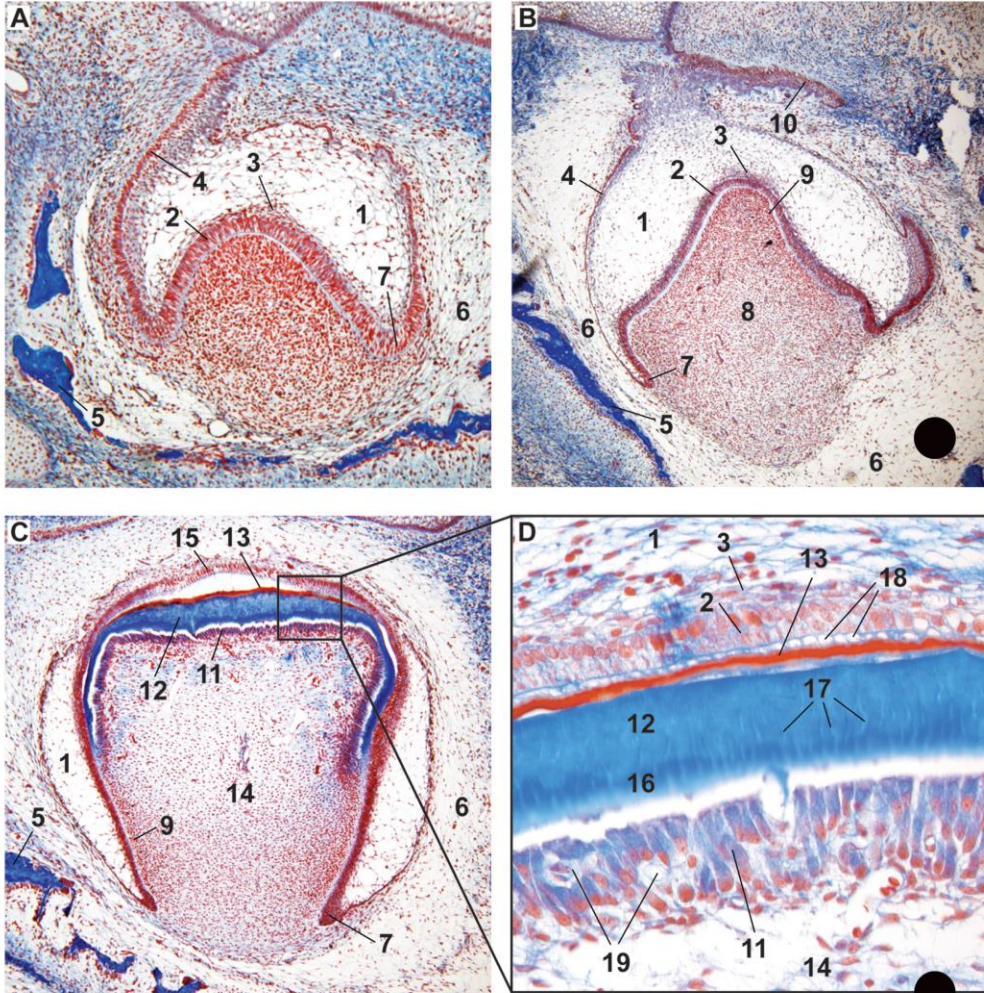
# VÝVOJ ZUBU

vývoj kořene – prořezání zubu

cervikální klička → Hertwigova kořenová pochva



# VÝVOJ ZUBU



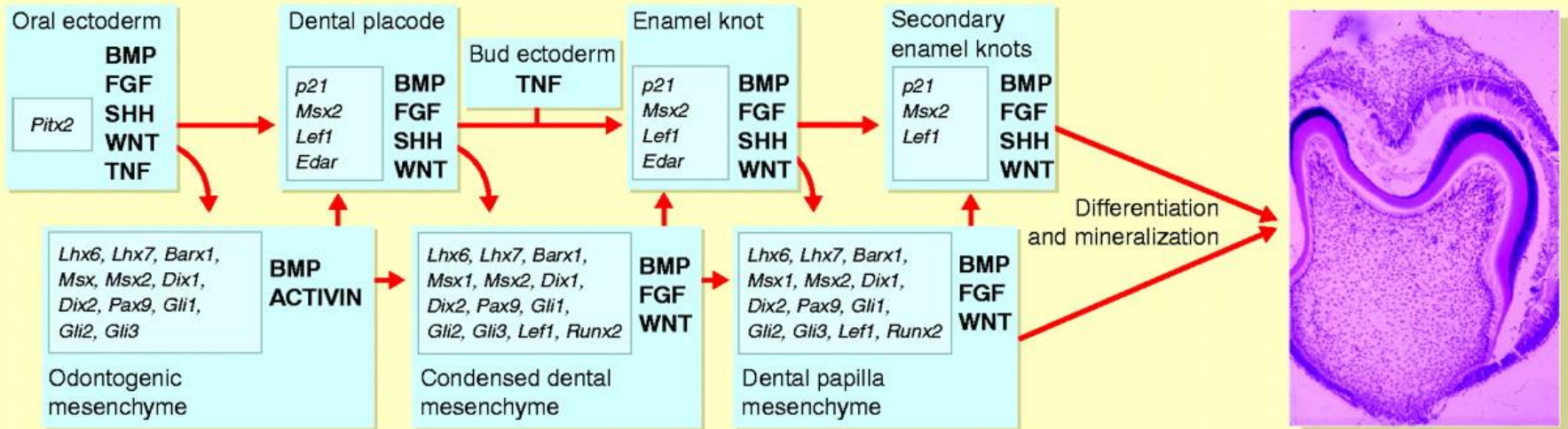
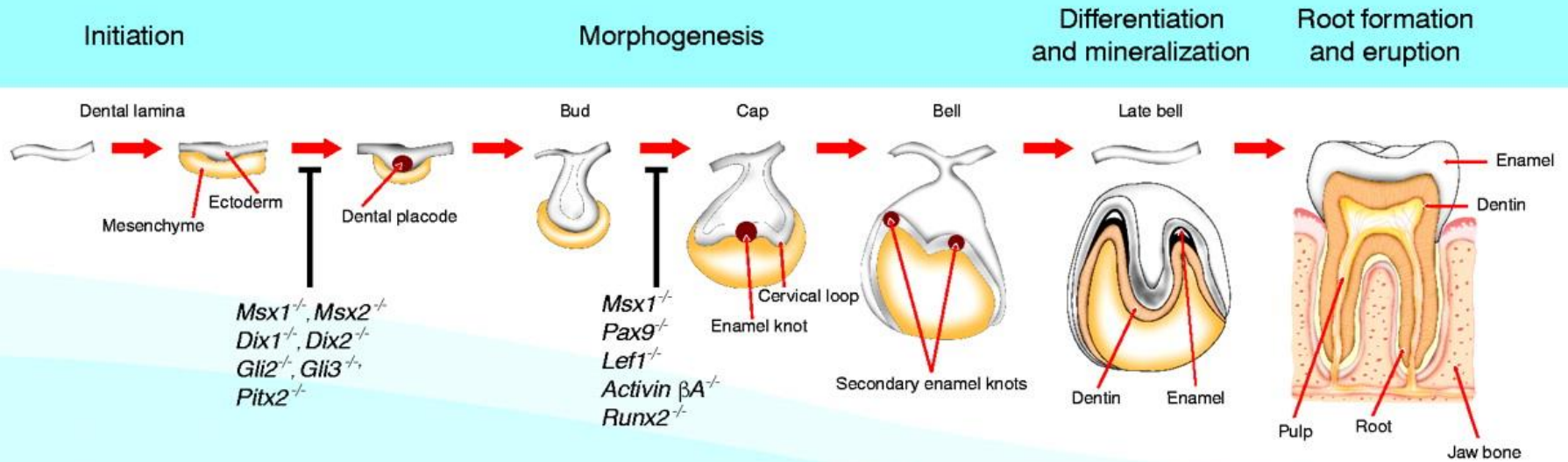
## Vývoj zubu – development of tooth (*maxilla, Sus scrofa*).

(A) Stádium pozdní čepičky – late cap stage, (B) stádium zvonku – bell stage, (C) stádium pozdního zvonku / stádium apozice – late bell stage / apposition stage, (D) detail místa apozice zuboviny a skloviny – detail of the site of dentin and enamel apposition.

(1) Hvězdčicovité retikulum – stellate reticulum, (2) preameloblasty (vnitřní sklovinný epitel) – preameloblasts (inner enamel epithelium), (3) *stratum intermedium*, (4) vnější sklovinný epitel – outer enamel epithelium, (5) vznikající kost budoucího zubní alveolu – developing bone of dental alveolus, (6) zubní folikul – dental follicle, (7) cervikální epitelová klička – cervical epithelial loop, (8) zubní papila – dental papilla, (9) preodontoblasty – preodontoblasts, (10) náhradní zubní lišta (základ pro zub trvalé dentice) – successional dental lamina (developmental origin of permanent teeth), (11) odontoblasty – odontoblasts, (12) zubovina – dentin, (13) sklovina – enamel, (14) zubní pulpa – dental pulp, (15) ameloblasty – ameloblasts, (16) predentin, (17) Tomesova vlákna (výběžky odontoblastů) – Tomes's fibers (processes of odontoblasts), (18) Tomesovy výběžky (výběžky ameloblastů) – Tomes's processes (processes of ameloblasts), (19) krevní cévy ve vrstvě odontoblastů – blood vessels in the layer of odontoblasts. Barvení – staining: Massonův trichrom – Masson's Trichrome.

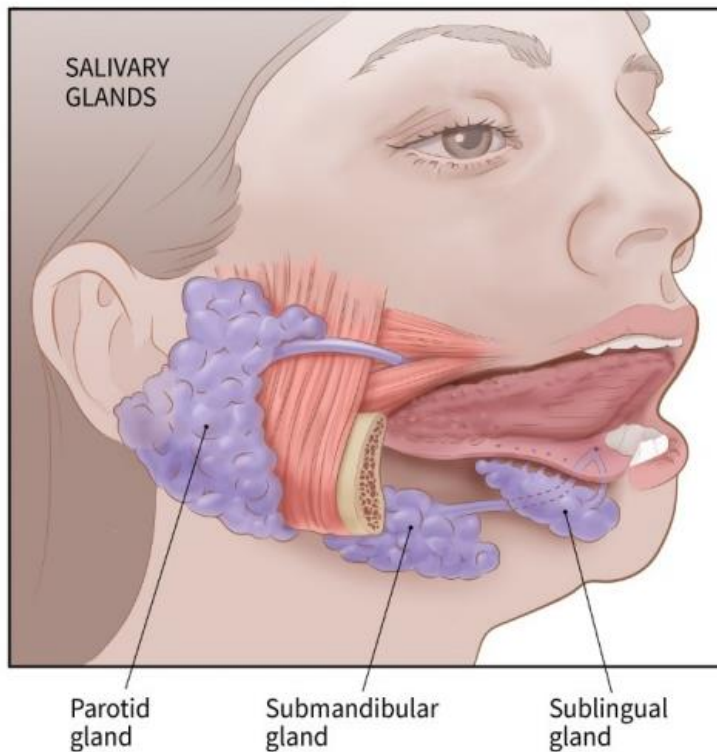
## Signalling In Tooth Development

Irma Thesleff



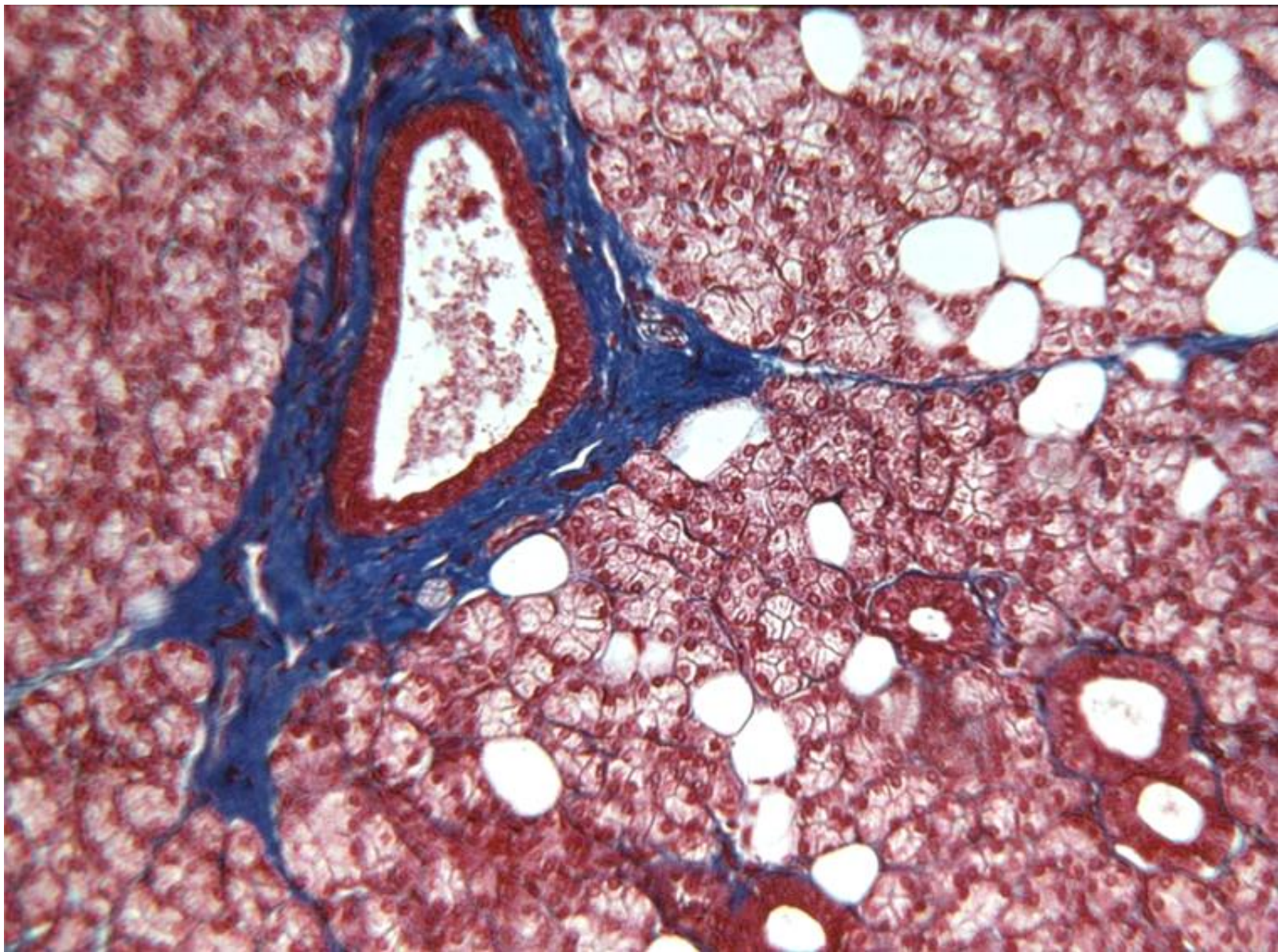


- malé (gll. labiales, buccales, retromolares, palatinae, gll. lingualis anterior - Blandini, gll. Ebneri, gll. Weberi)
- velké (gl. parotis, gl. submandibularis, gl. sublingualis)

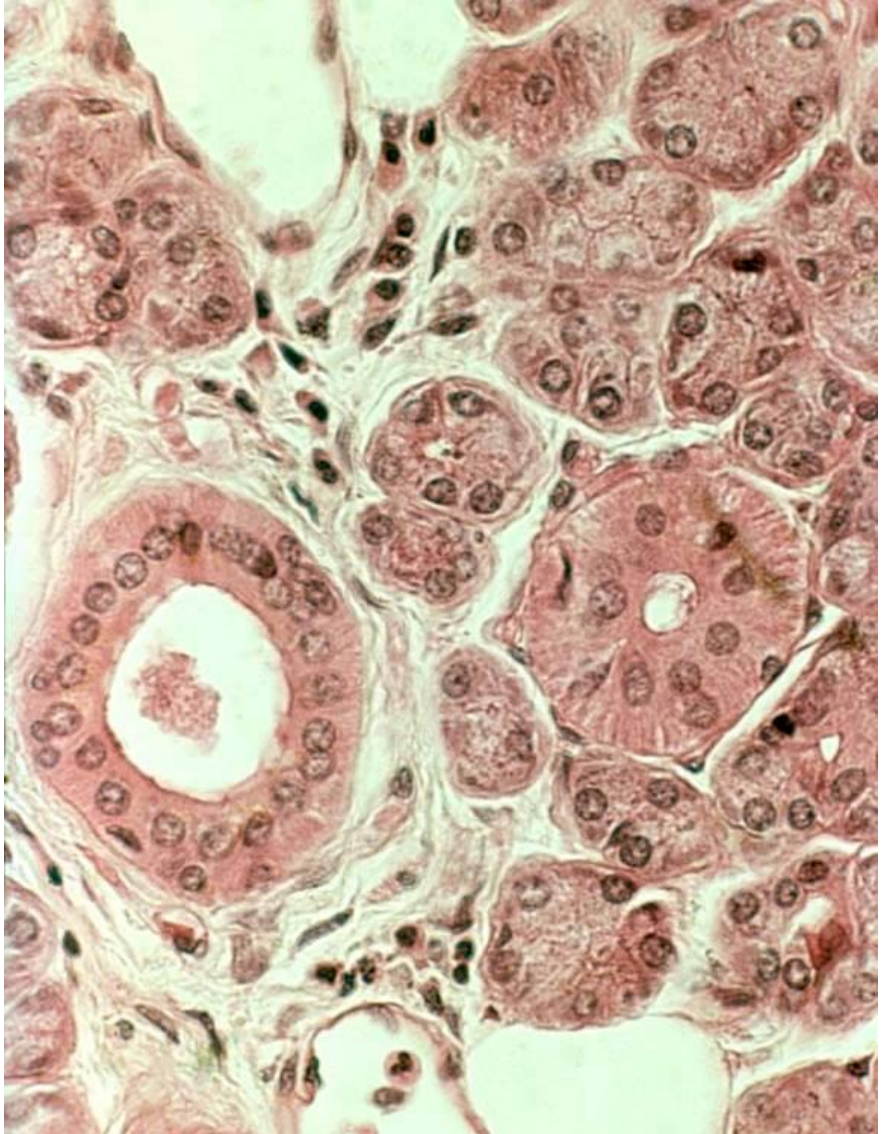
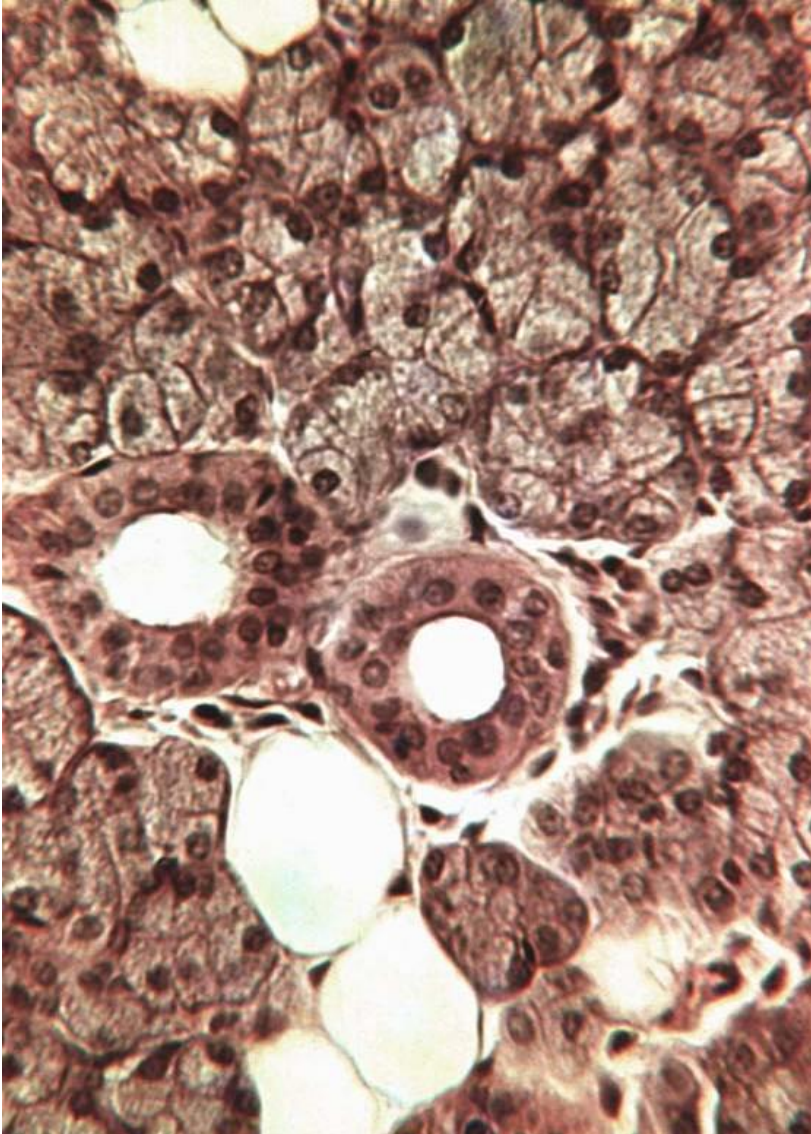


viz GIT 3

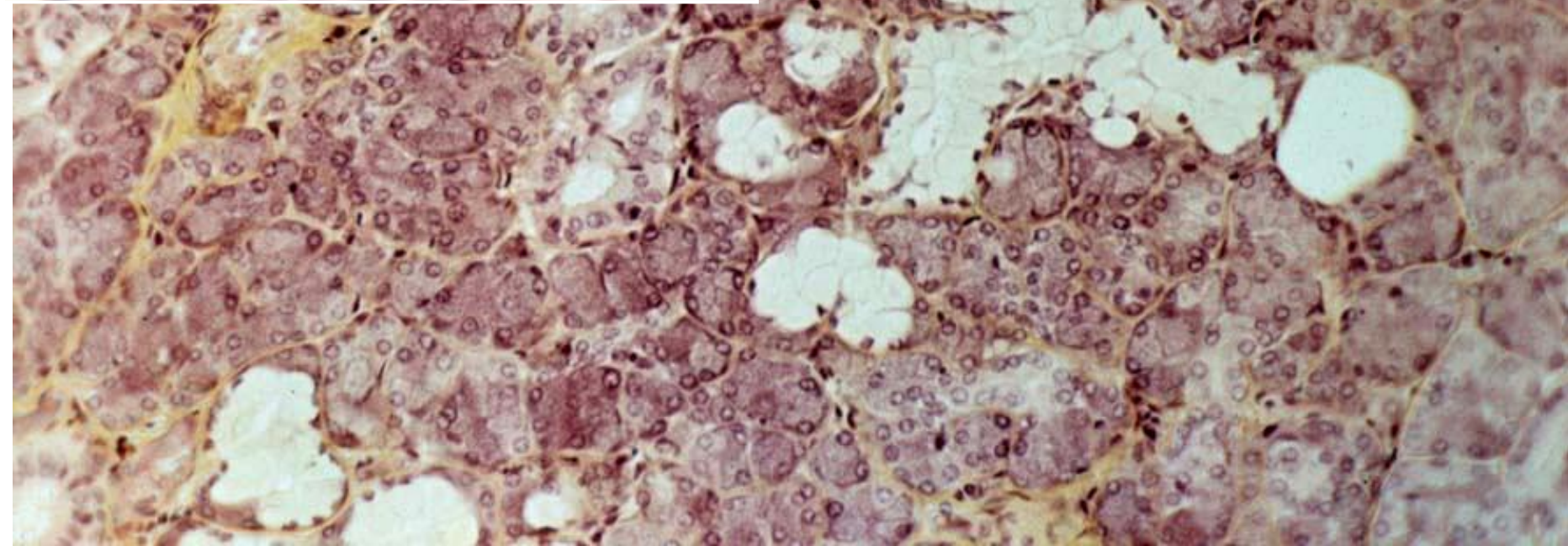
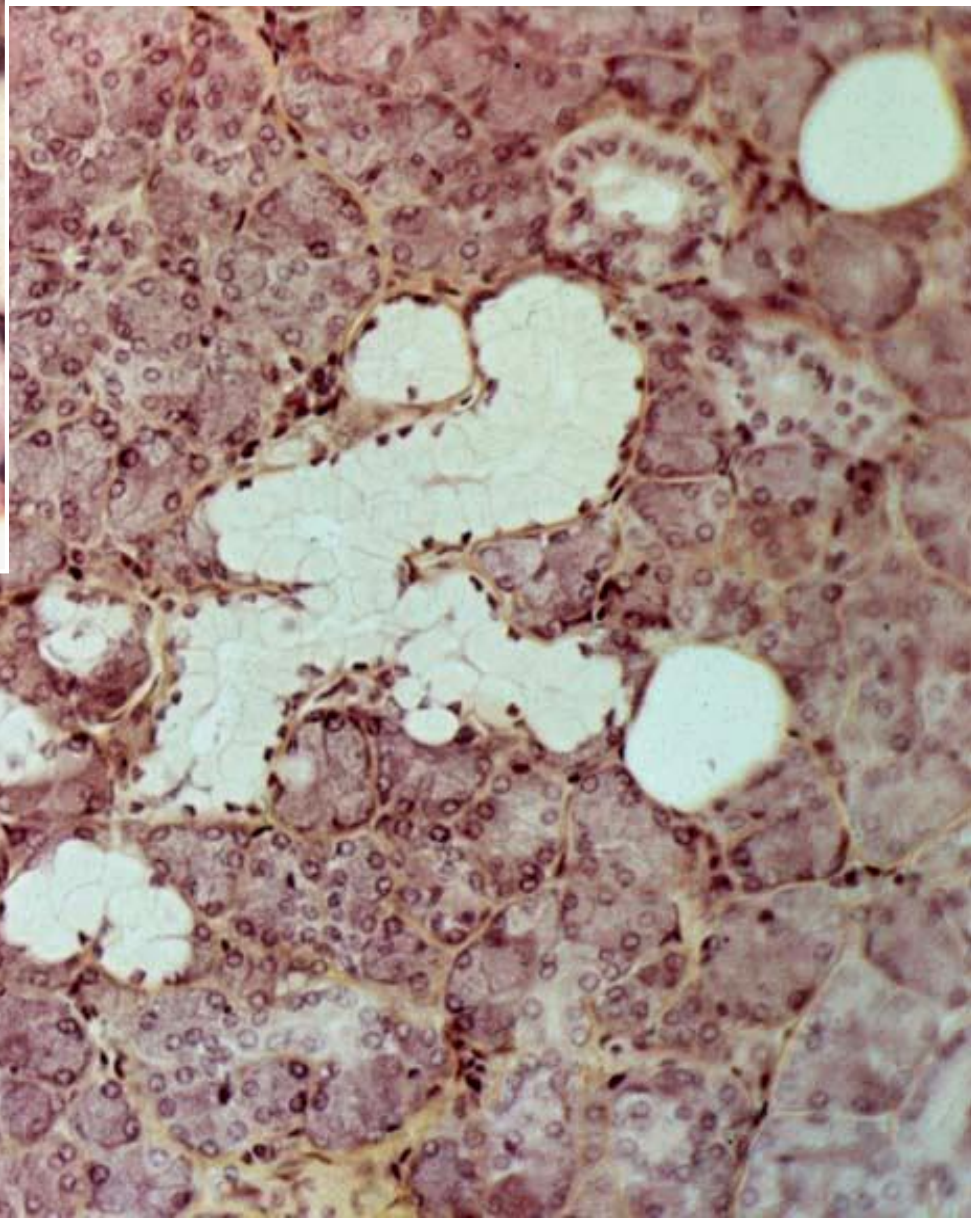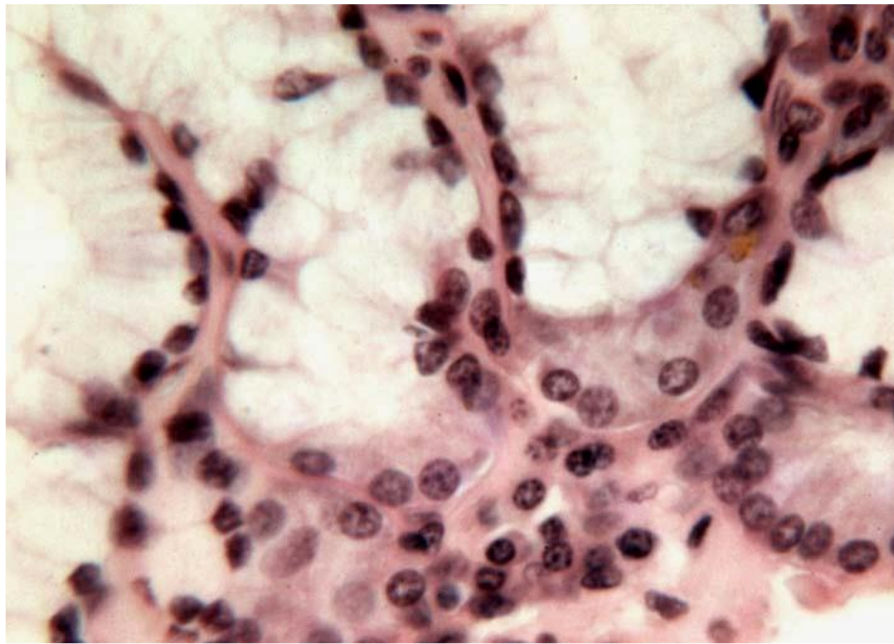
SLINNÉ ŽLÁZY – GL. PAROTIS



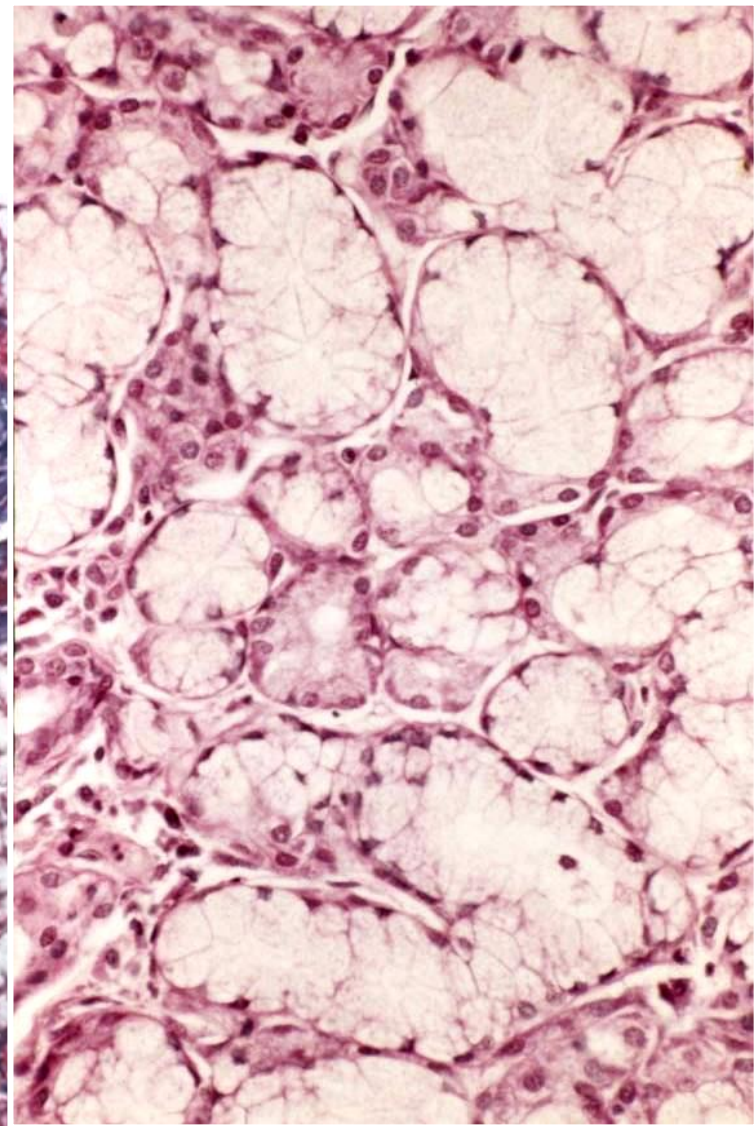
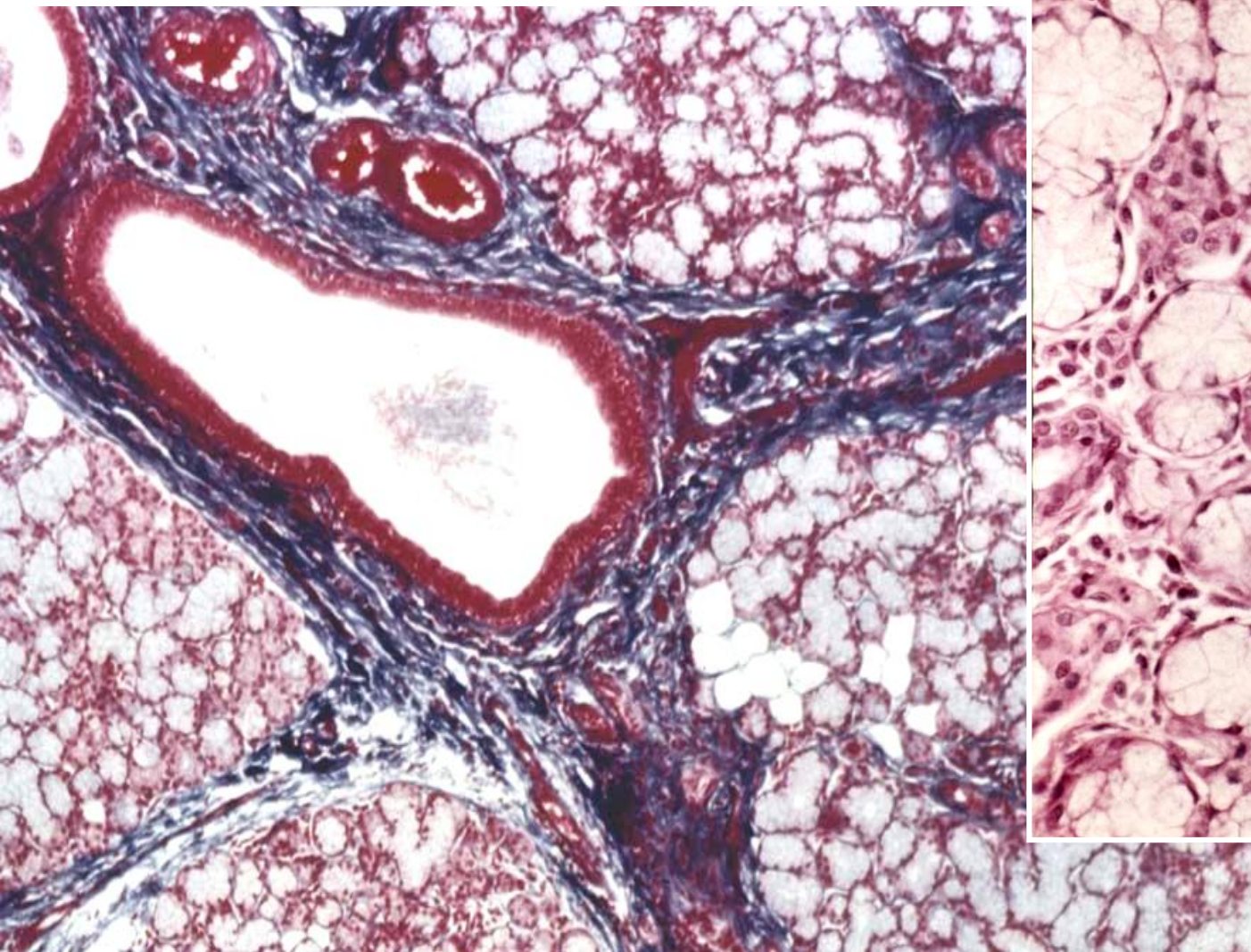
# SLINNÉ ŽLÁZY – GL. PAROTIS



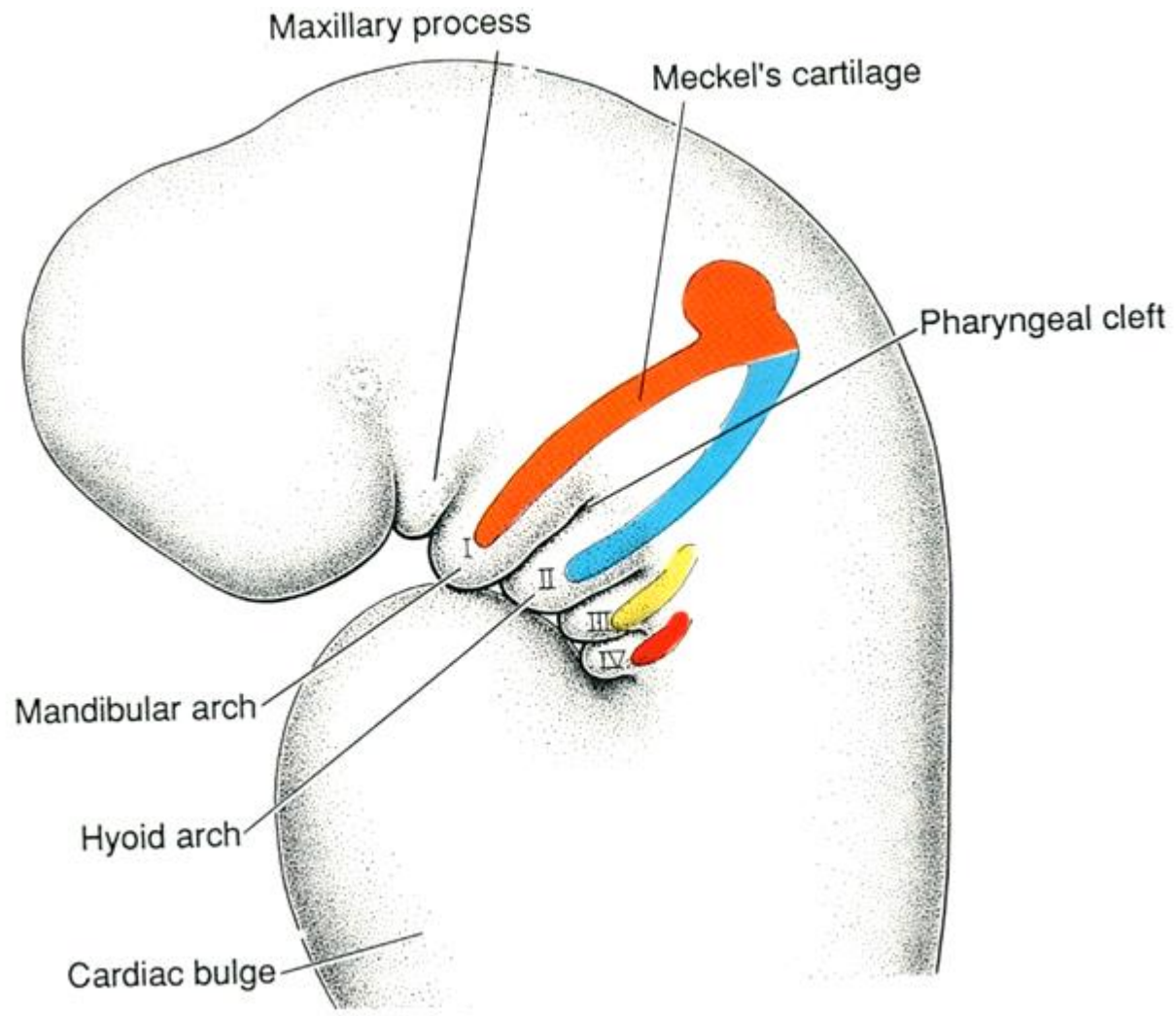
# SLINNÉ ŽLÁZY – GL. SUBMANDIBULARIS



# SLINNÉ ŽLÁZY – GL. SUBLINGUALIS



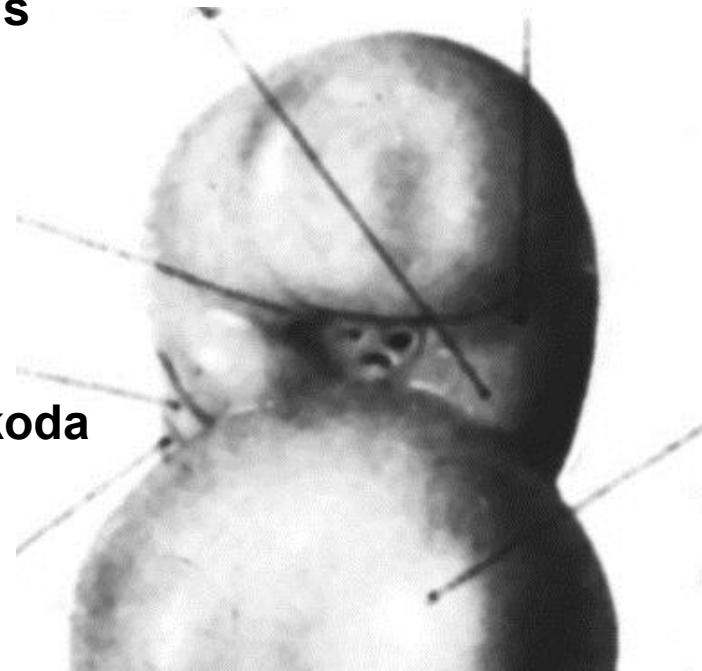
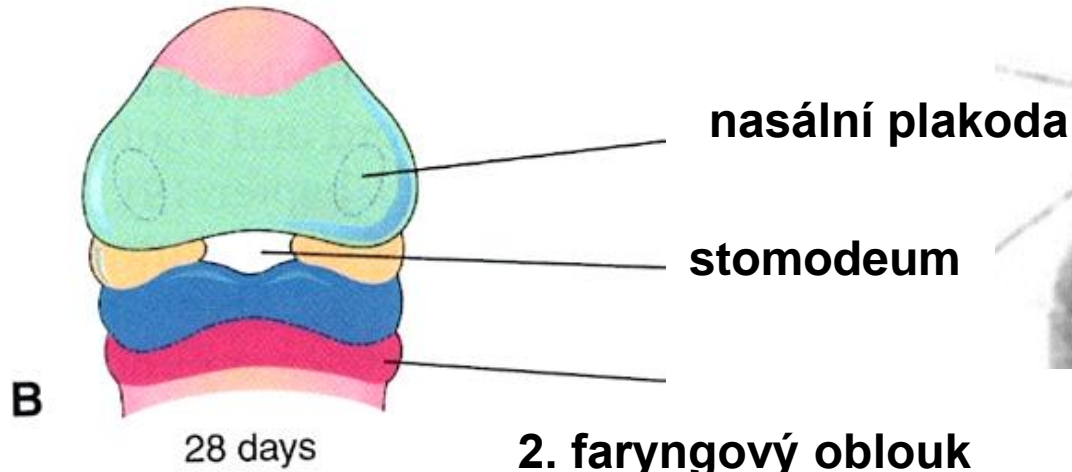
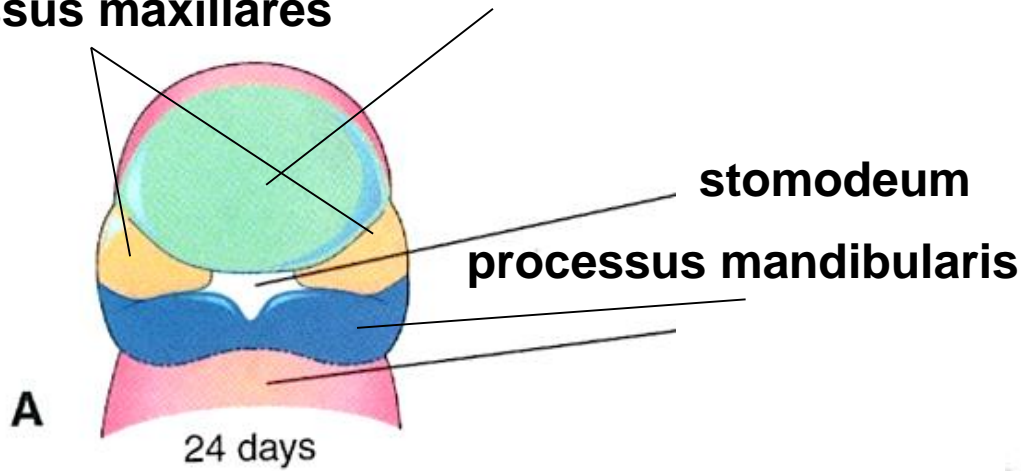
# VÝVOJ OBLIČEJE



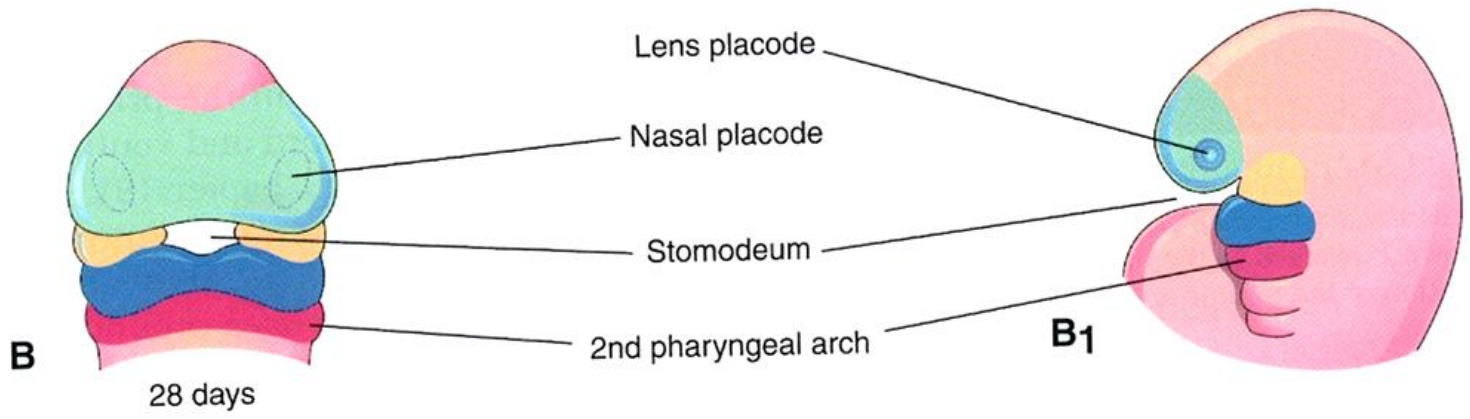
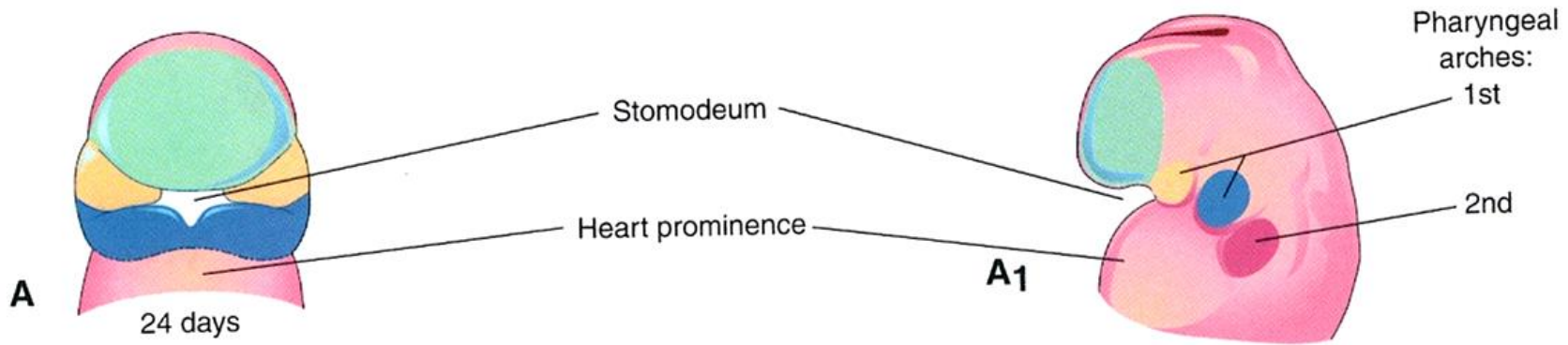
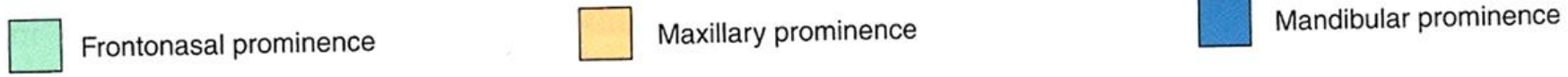
# VÝVOJ OBLIČEJE

processus frontonasalis

processus maxillares



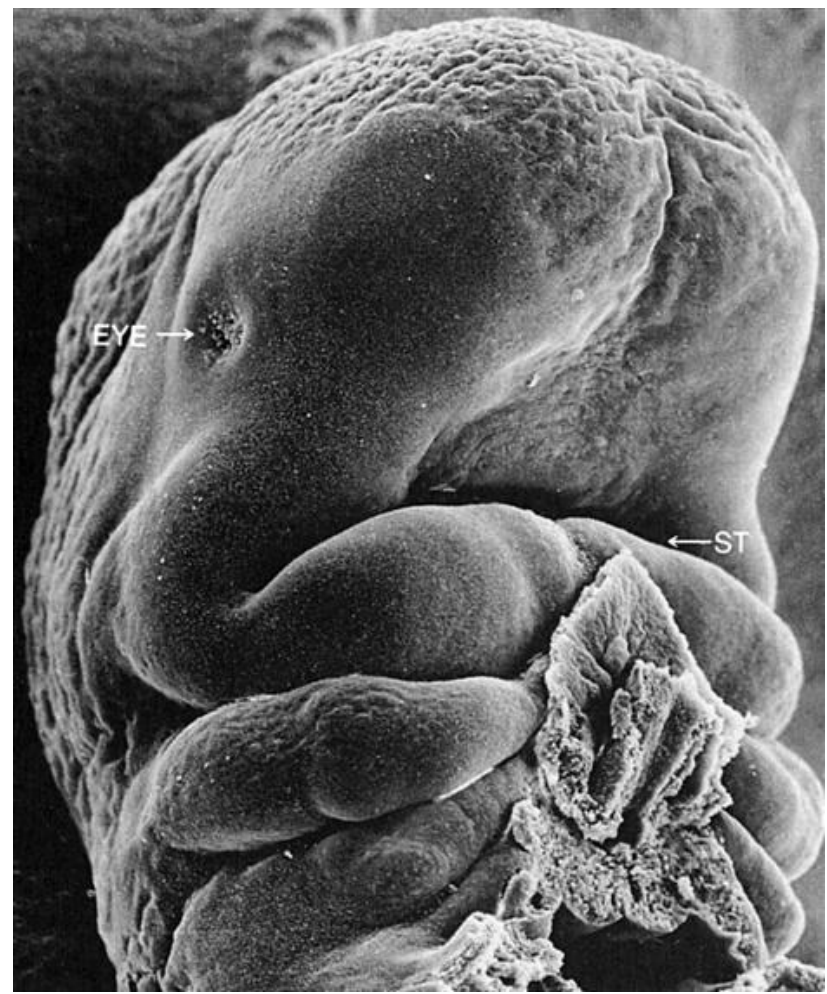
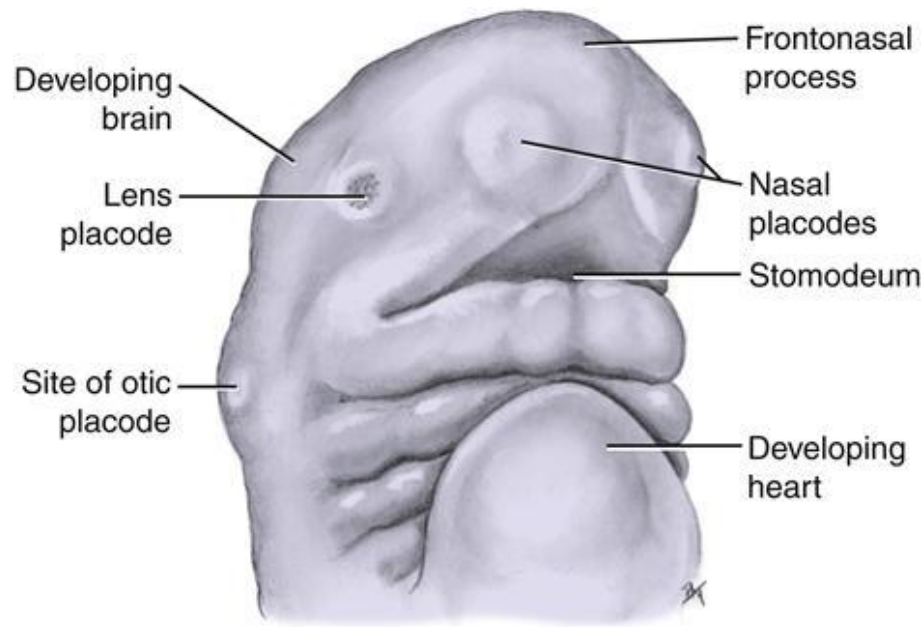
# VÝVOJ OBLIČEJE



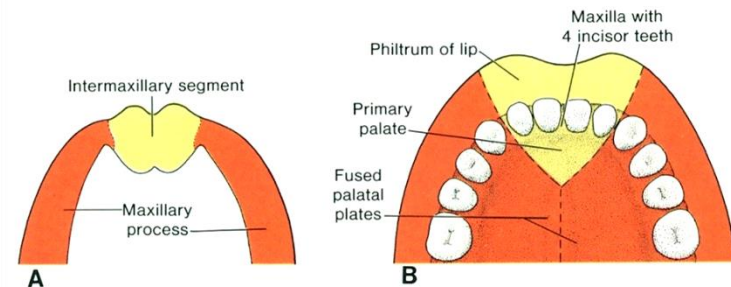
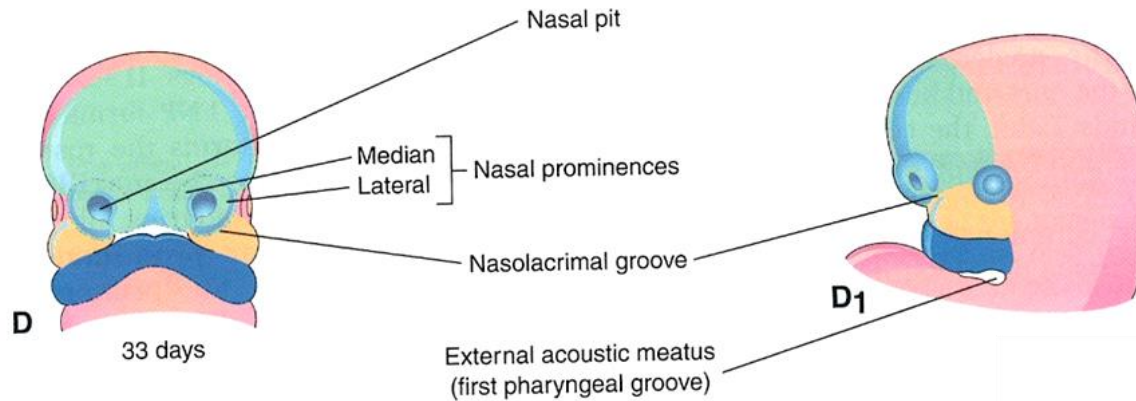
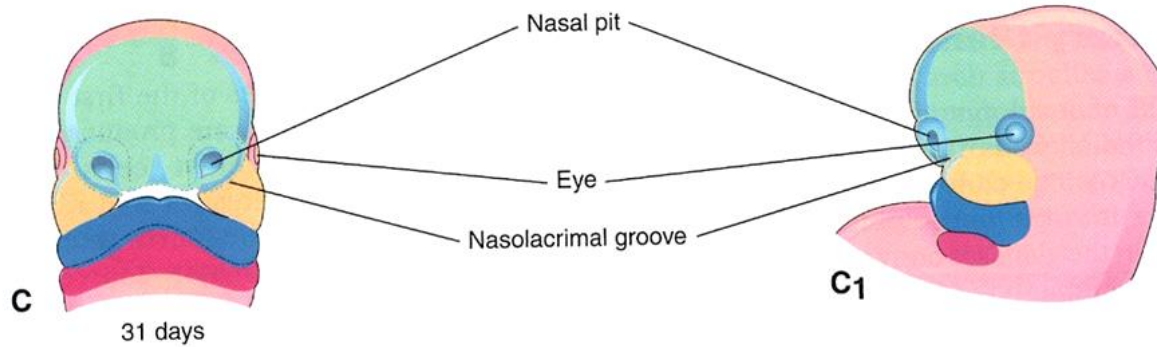


# VÝVOJ OBLIČEJE

4th week

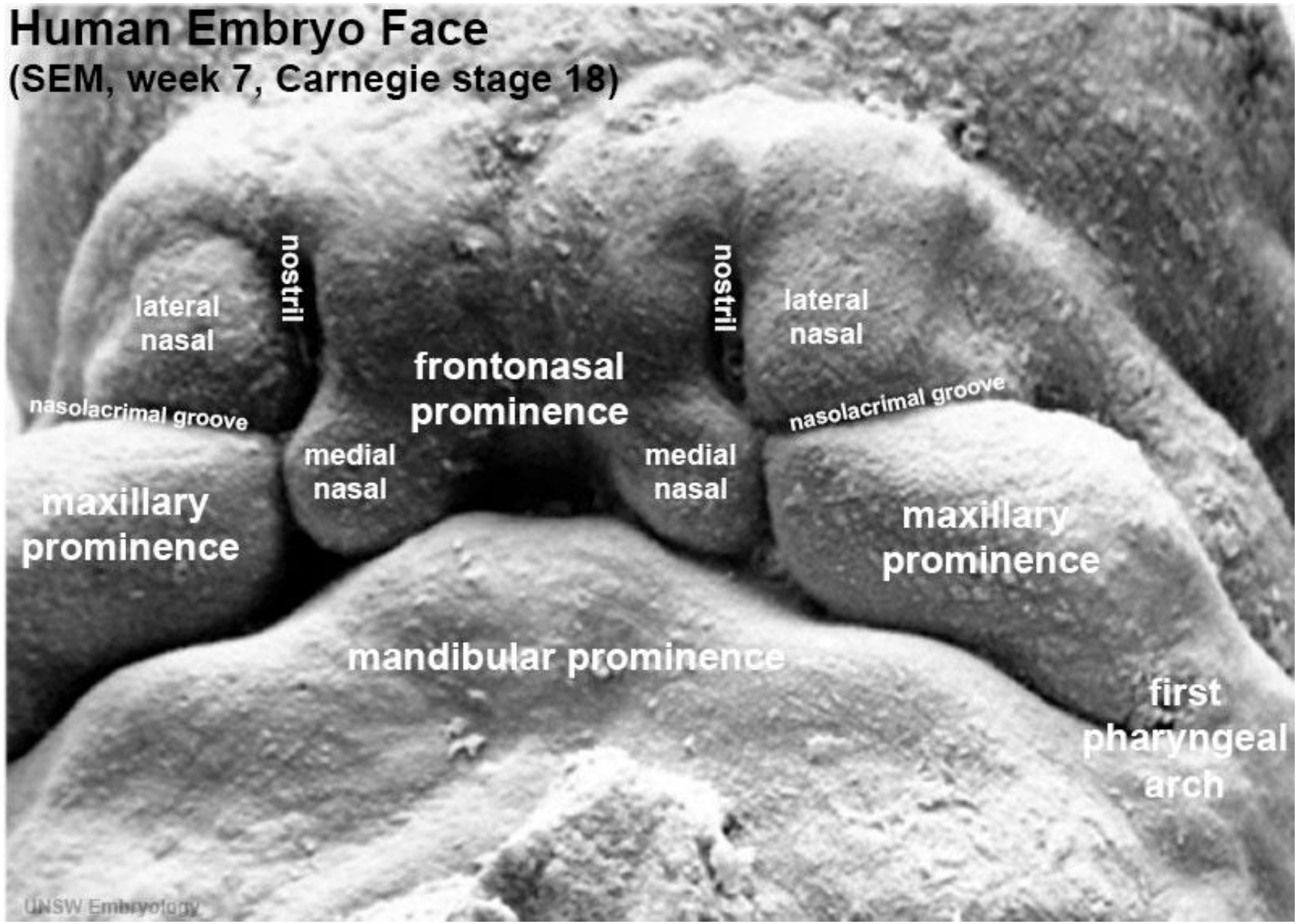


# VÝVOJ OBLIČEJE

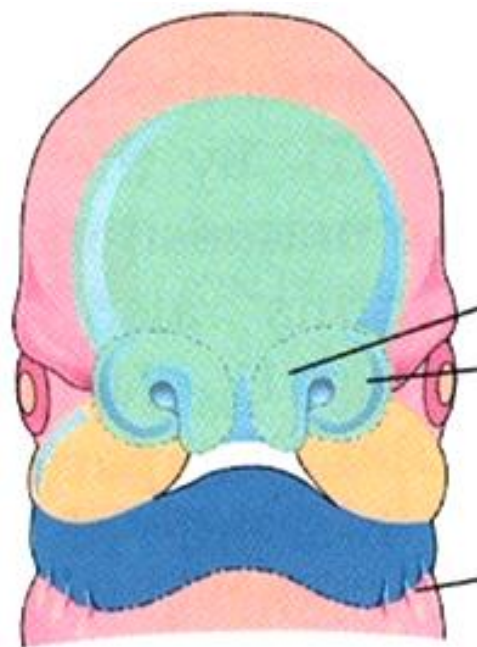


- čichové jamky jsou ohraničeny vally – **mediální a laterální nosní vally**
- zbytek čelního valu vytvoří **area triangularis** (základ pro hřbet a hrot nosu)
- mediální nosní vally spolu srostou a vsouvají se mezi maxilární výběžky jako **intermaxilární segment** (dávají vznik střední části horního rtu, části horní čelisti v oblasti řezáků a části patra – primární patro)

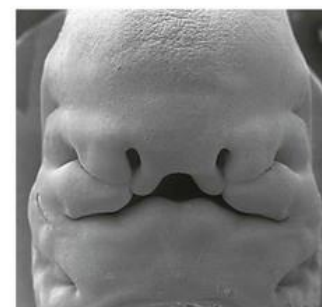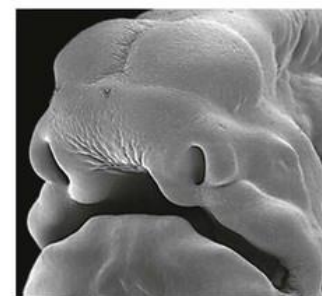
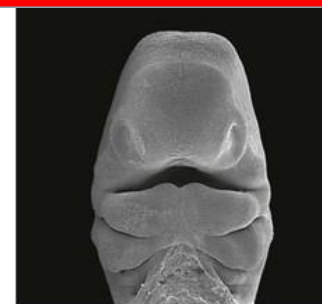
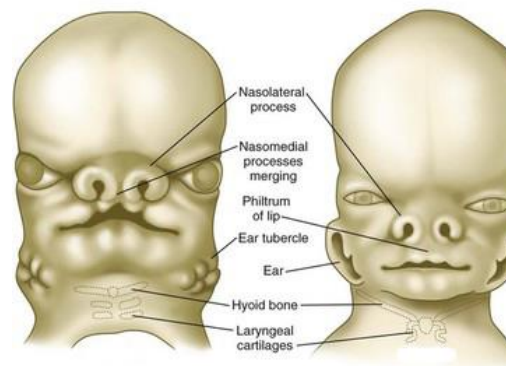
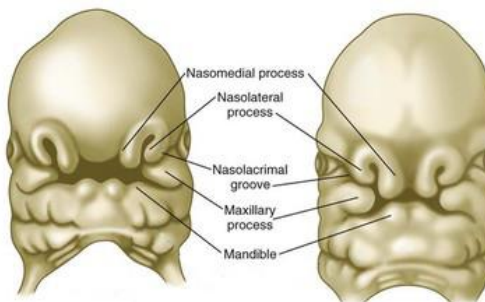
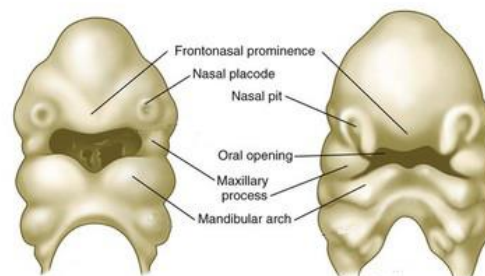
# Human Embryo Face (SEM, week 7, Carnegie stage 18)



# VÝVOJ OBLIČEJE



35 days

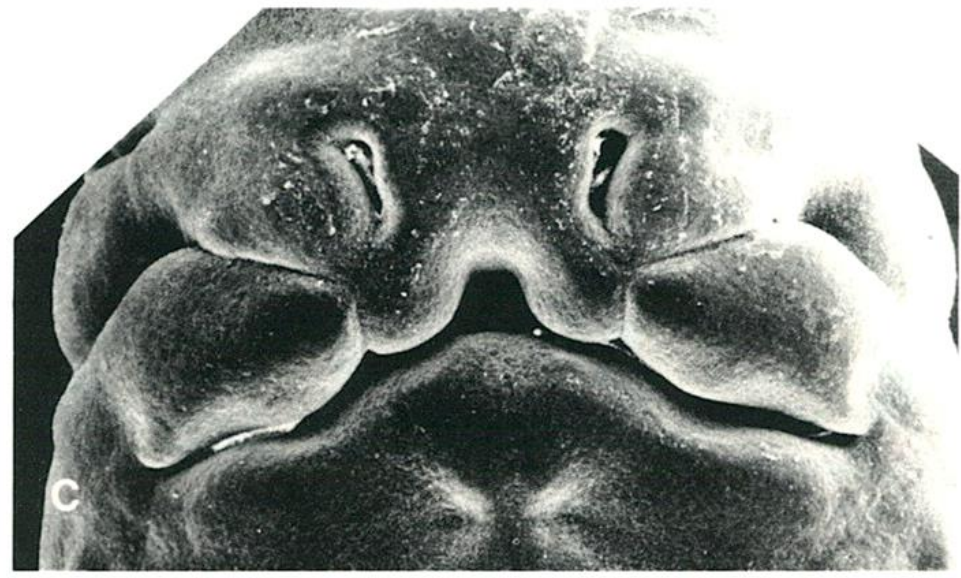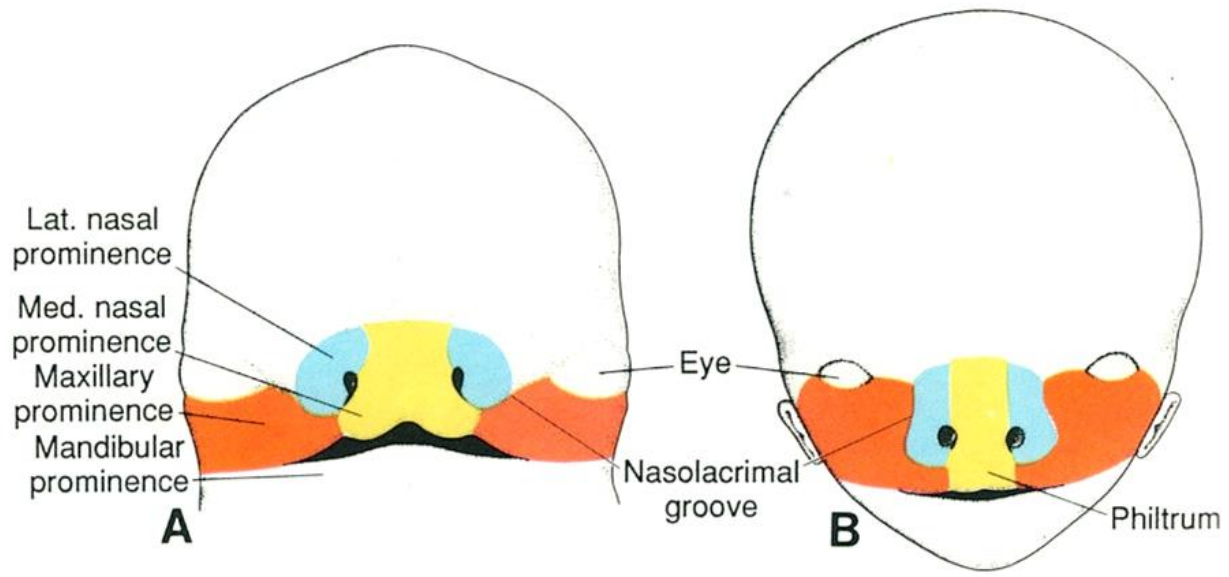


- **maxilární výběžky** srostou

1. s **intermaxilárním segmentem** (vytvoření horní čelisti a rtu)
2. s **laterálními nosními valy** – (zbytek horní čelisti a křídla nosu)

- laterální nosní valy jsou od maxilárních zpočátku odděleny rýhou – sulcus nasolacimalis, která se uzavře a vytvoří slzný kanálek

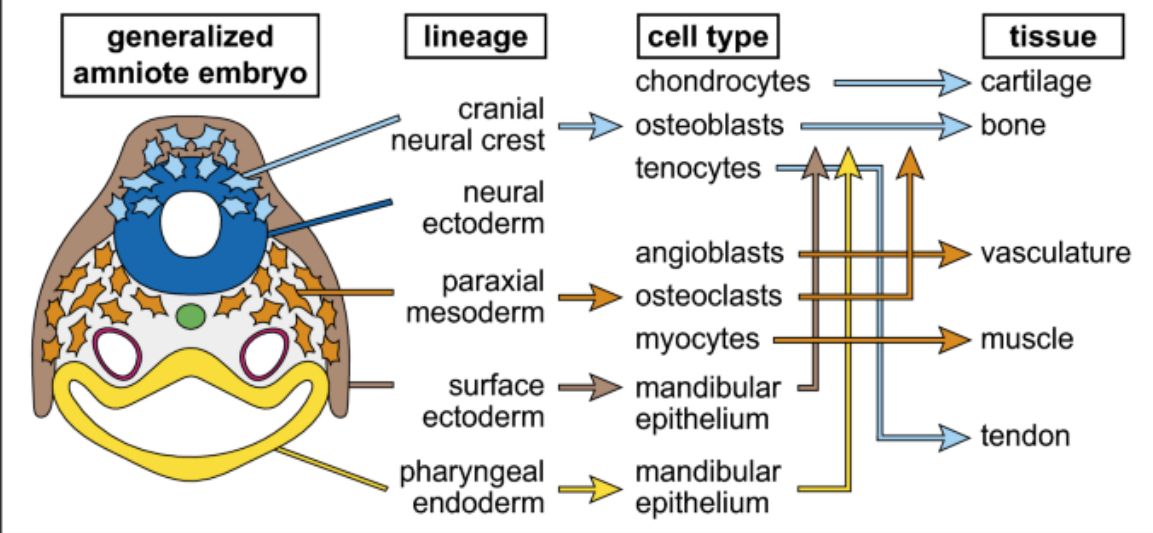
# VÝVOJ OBLIČEJE



7 týden

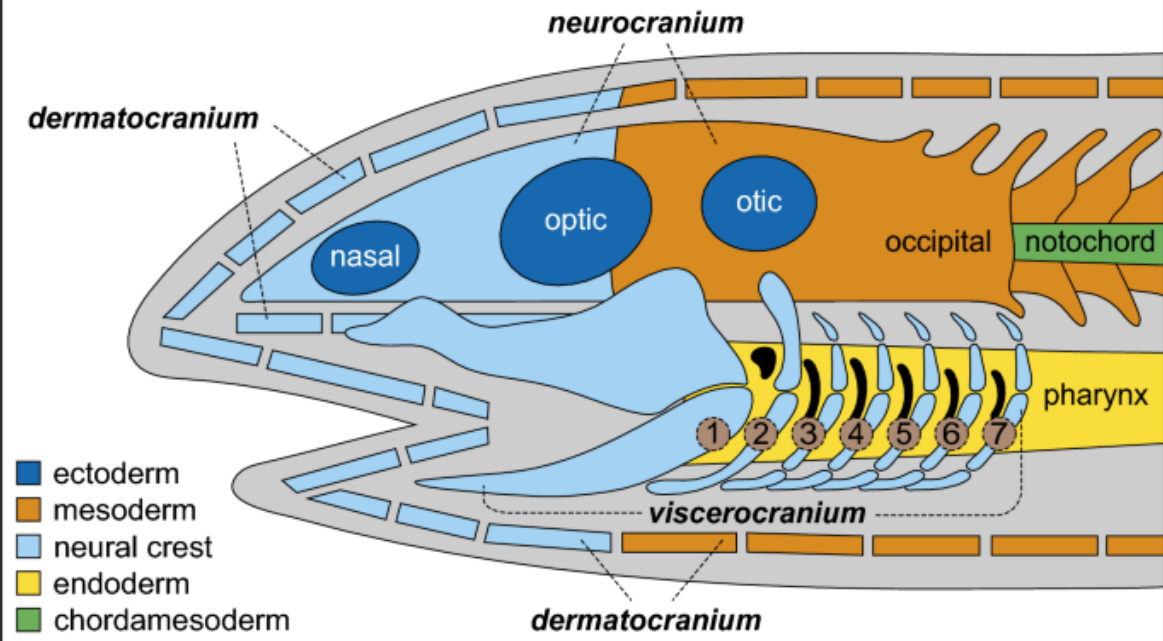
# VÝVOJ OBLIČEJE – LEKCE Z EVOLUČNÍ VÝVOJOVÉ BIOLOGIE

**a Embryonic origins of the cellular precursors of the jaw complex**

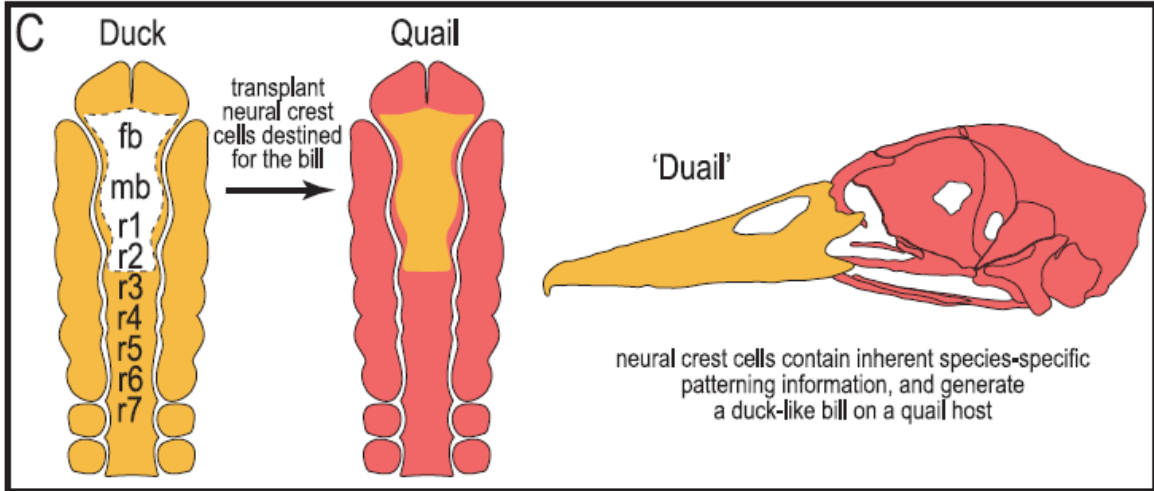
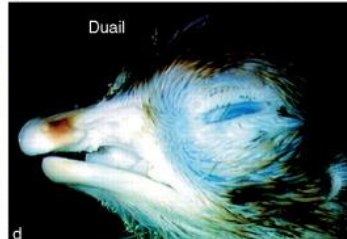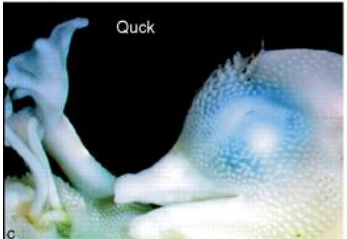
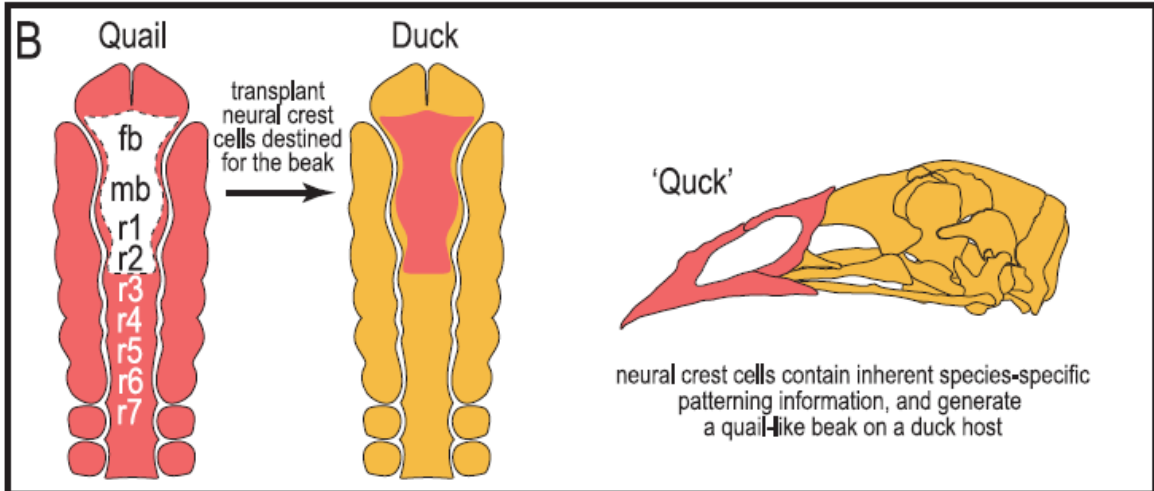
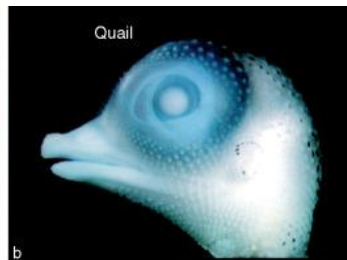
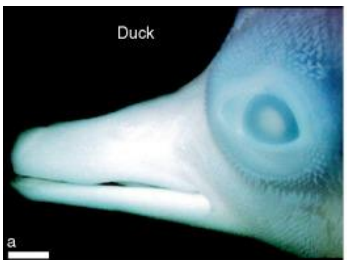
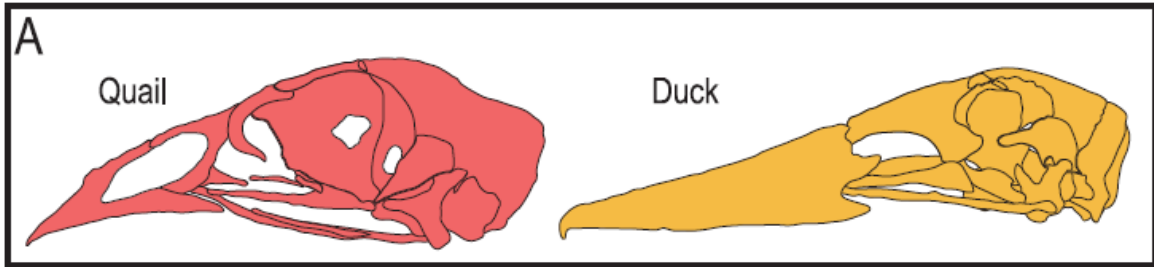


<https://evodevojournal.biomedcentral.com/articles/10.1186/s13227-019-0131-8>

**b Head and jaw skeleton of a generalized vertebrate embryo**



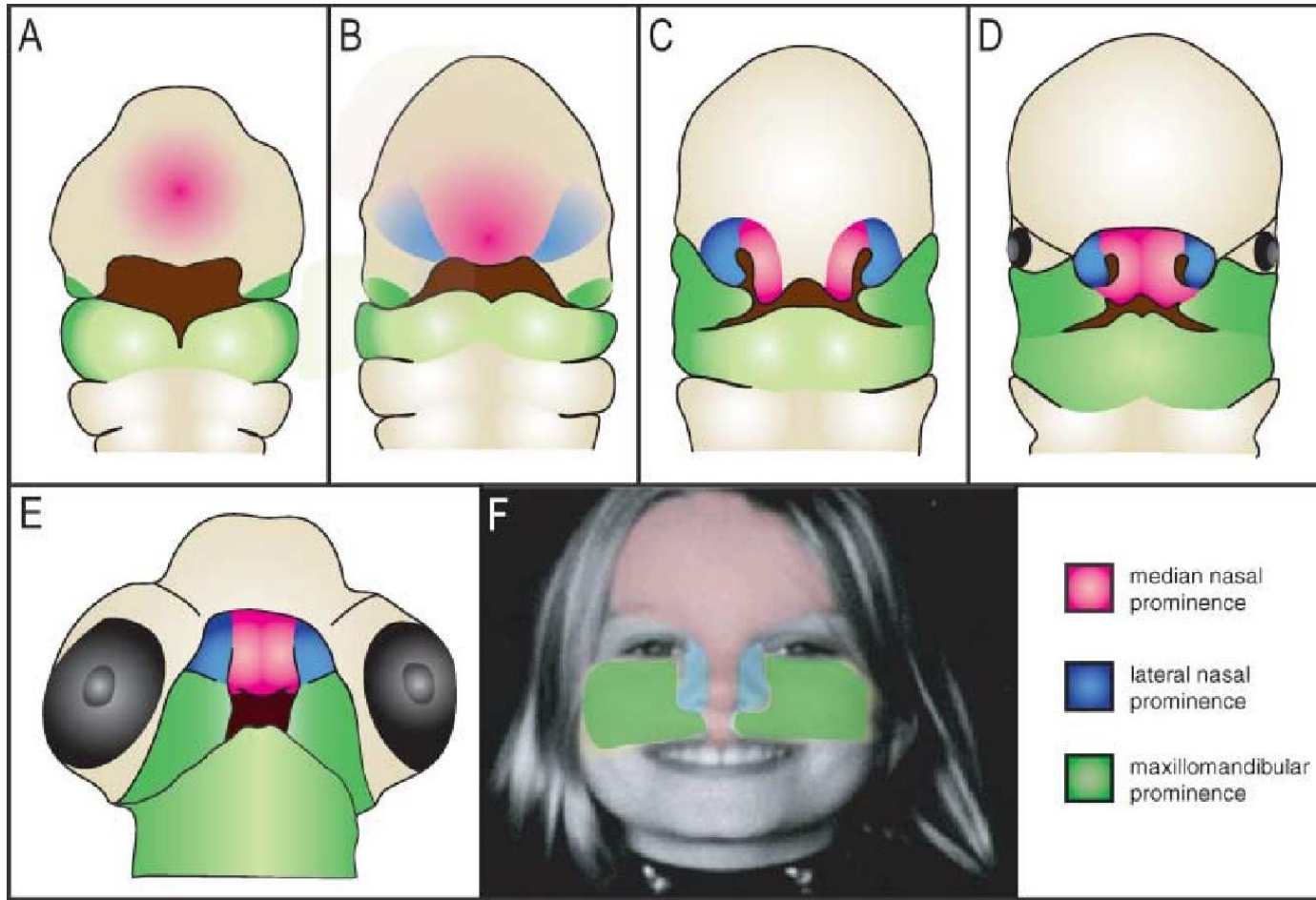
# VÝVOJ OBLIČEJE – GANGLIOVÁ LIŠTA



<https://evodevojournal.biomedcentral.com/articles/10.1186/s13227-019-0131-8>

<https://www.sciencedirect.com/science/article/pii/B9780080450469006732>

# VÝVOJ OBLIČEJE



Shh a FGF

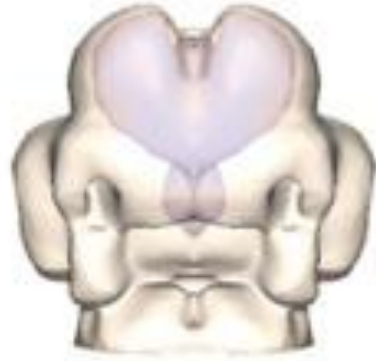
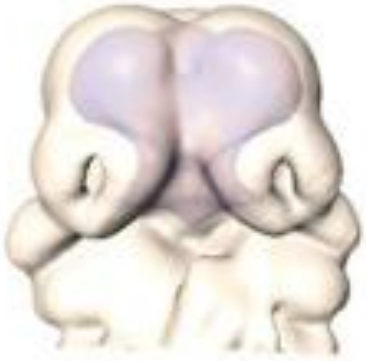
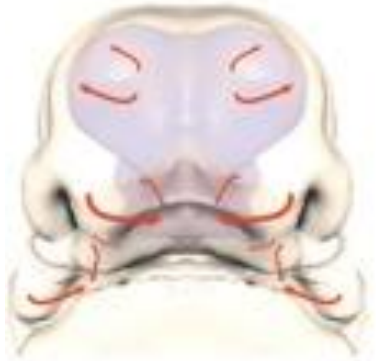# VÝVOJ OBLIČEJE - SHH

Human  
CS16

Mouse  
E10.5

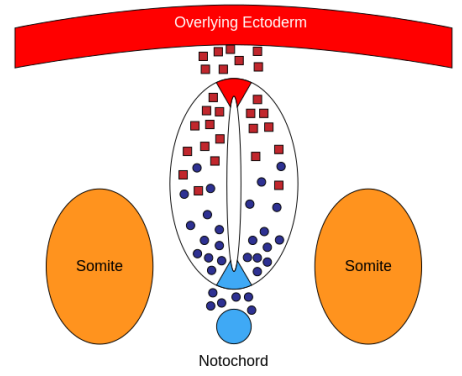
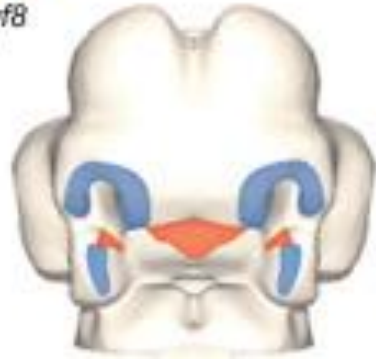
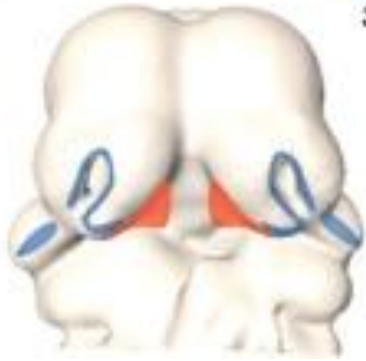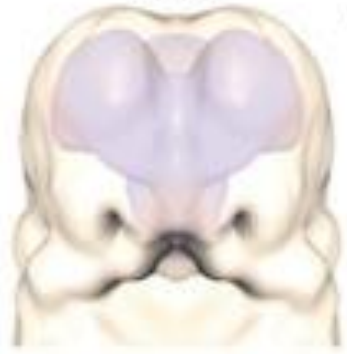Chick  
HH22



CS17

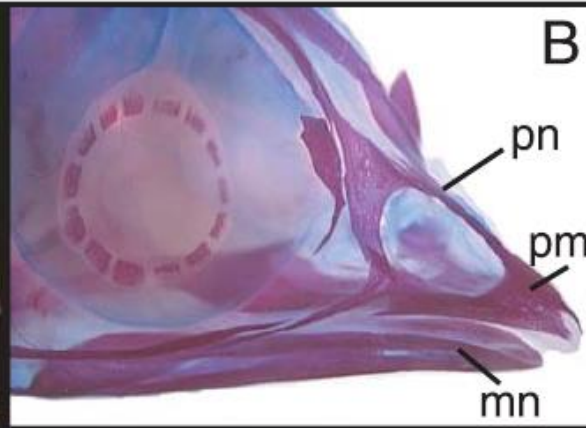
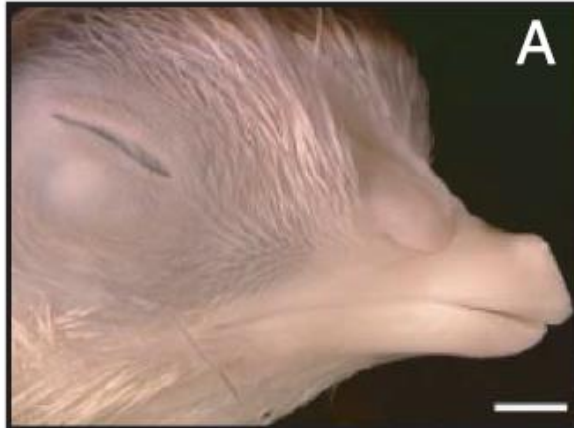Brain

Shh Fgf8

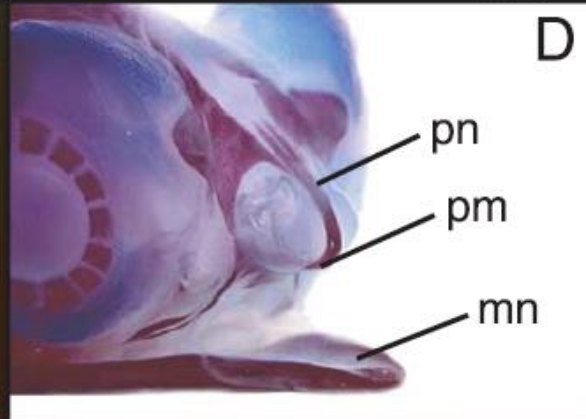


● Sonic hedgehog protein    ■ Sonic hedgehog producing cells  
 ■ BMP protein    ■ BMP producing cells

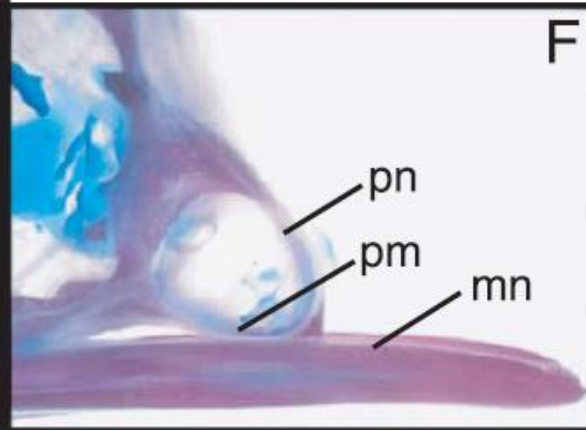
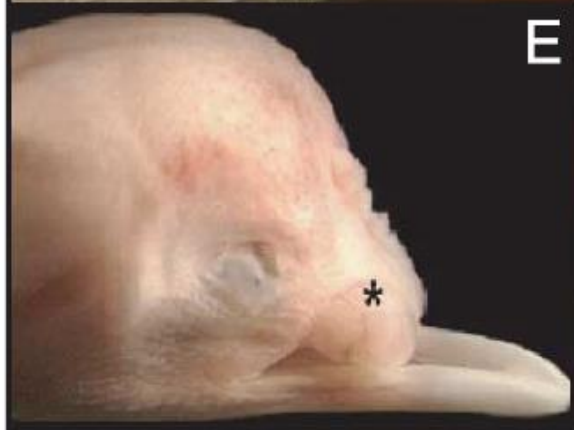
# VÝVOJ OBLIČEJE



Normální



Cyclopamine (teratogen)



anti-SHH Ab

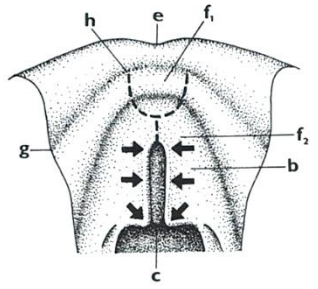
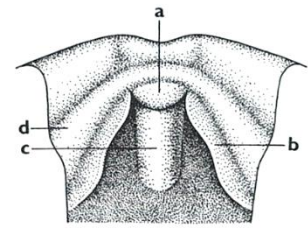
# VÝVOJ OBLIČEJE



<https://www.youtube.com/watch?v=FhhWG3XzARY>

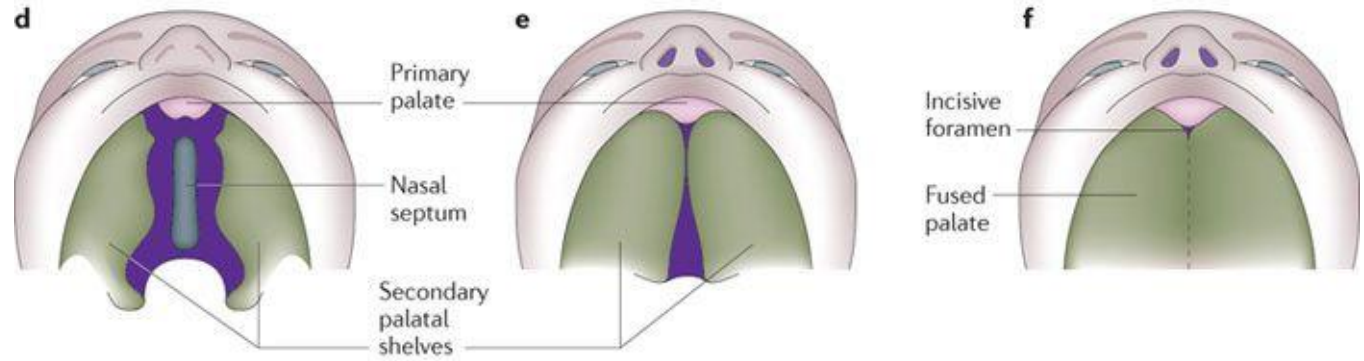
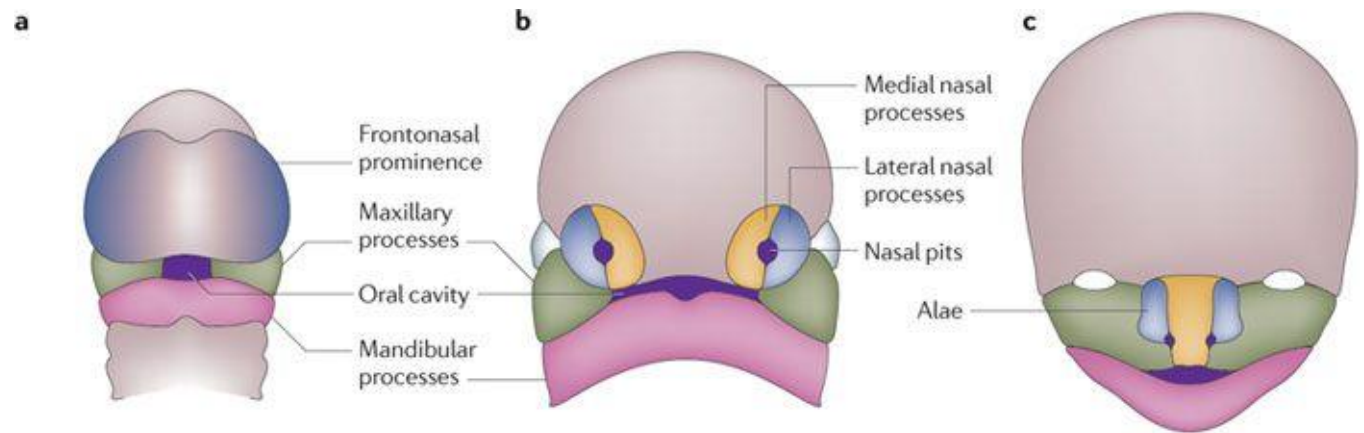
# VÝVOJ OBLIČEJE - PATRO

- **primární patro** (intermaxilární segment)
- **sekundární patro** (laterální patrové ploténky)

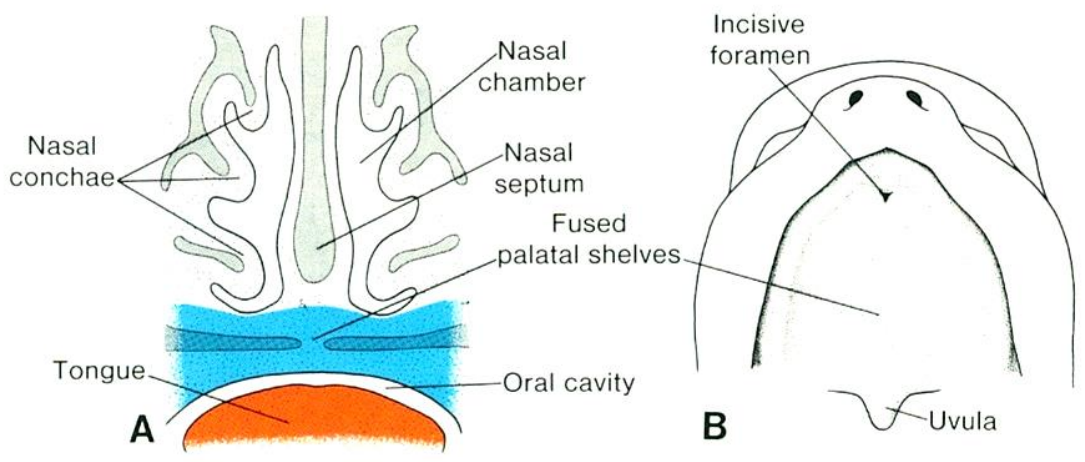
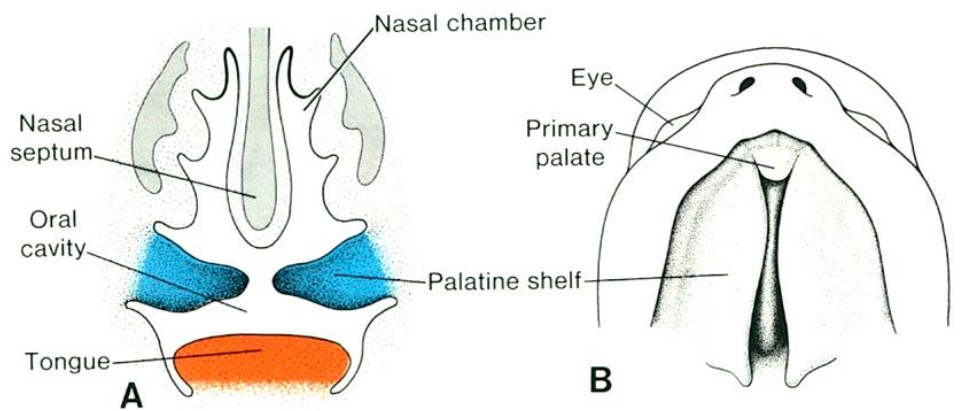
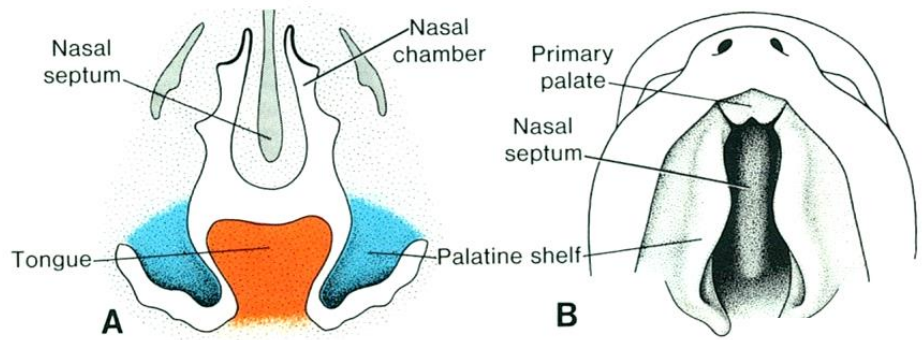


A

B

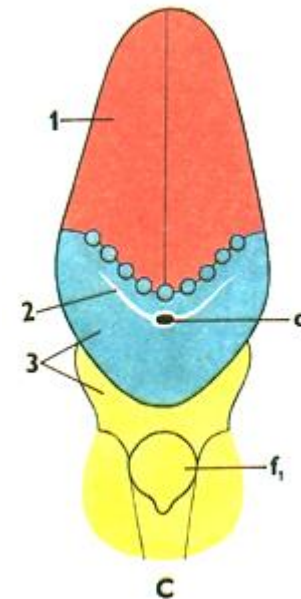
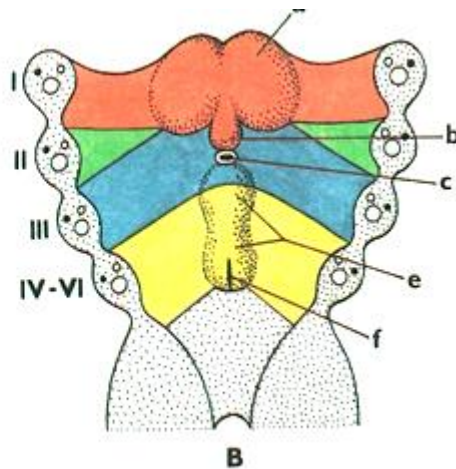
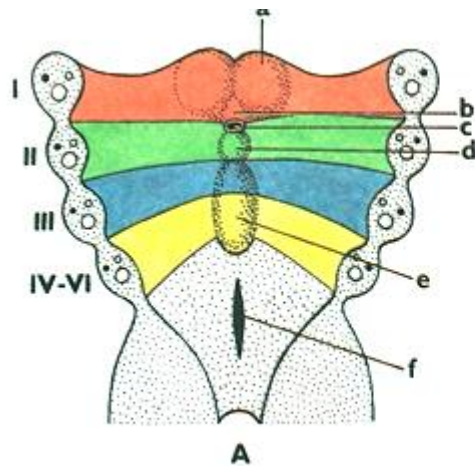


# VÝVOJ OBLIČEJE - PATRO



## Faryngové oblouky

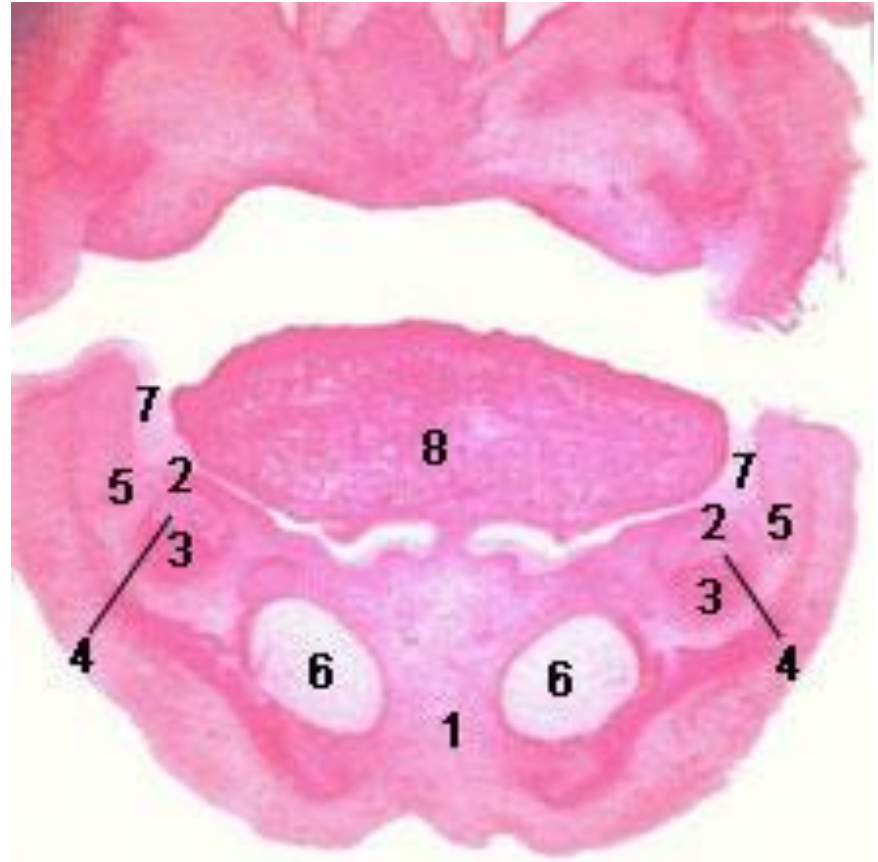
- I. **tuberculum linguale laterale** (dx. et sin.) + **tuberculum impar**  
(linguale mediale) → **apex a corpus**
- III-IV. **copula** + **eminentia hypobranchialis** → **radix**



## Vestibulární lišta

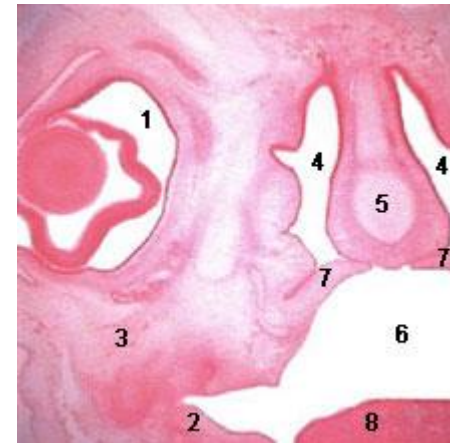
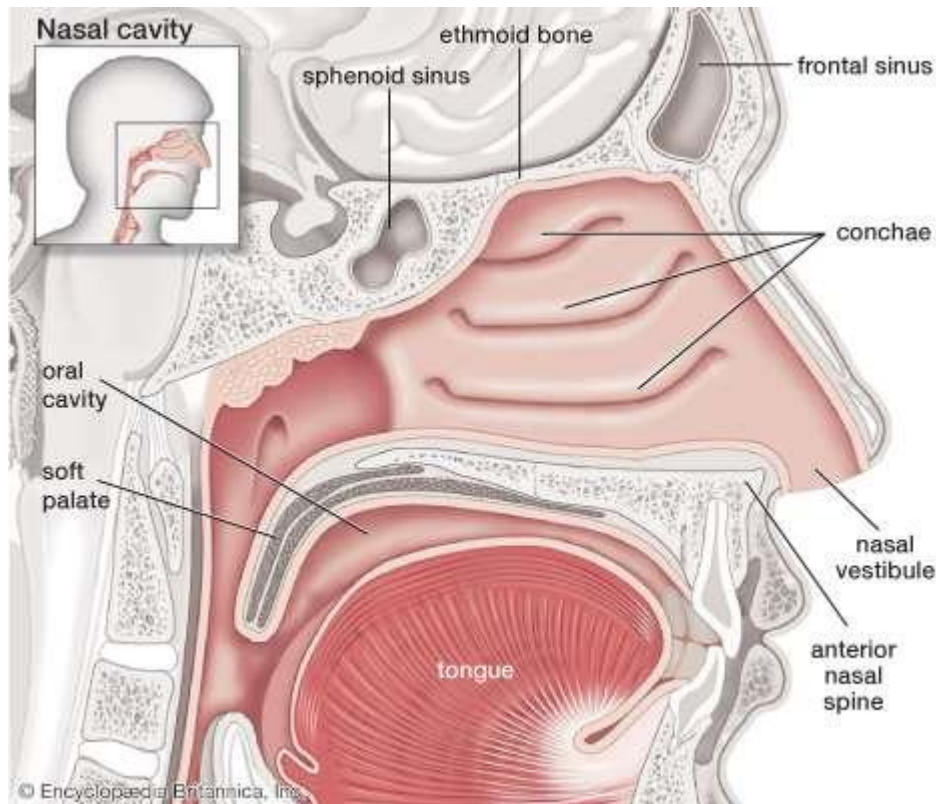
- **definitivní ret**
- **gingivální val**

1. Mandibula
2. Dentální lamina
3. Dentální papilla
4. Orgán skloviny
5. Labiogingivální lamina
6. Meckelova chrupavka
7. Orální epitel
8. Jazyk



# VÝVOJ VESTIBULUM NASI

- **Nazální kanálky** – primitivní choany
- **Nazální septum** z area triangularis – splývá se sekundárním patrem

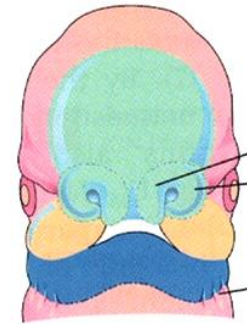


1. Oko
2. Mandibula
3. Maxila
4. Dutina nosní
5. Nosní septum
6. Dutina ústní
7. Patrové výběžky
8. Jazyk

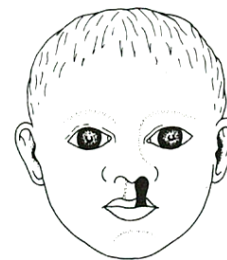


## Rozštěp měkké tkáně


- rozštěp horního rtu (*cheiloschisis*) – laterální (uni, bi), mediální
- rozštěp dolního rtu – mediálně, kombinovaný s dalšími vadami (čelist, jazyk) – *gnathoschisis et cheiloschisis inf.*
- šikmý rozštěp (*fissura orbitofacialis*)
- příčný rozštěp (*fissura transversa*)



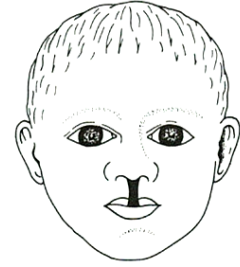
35 days



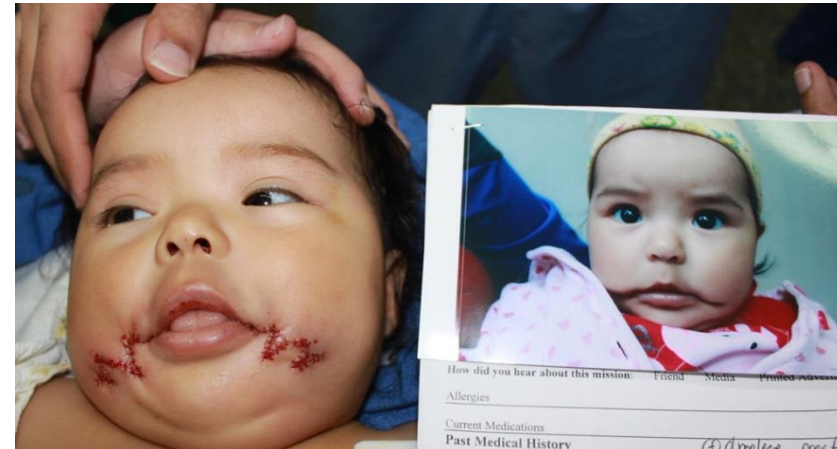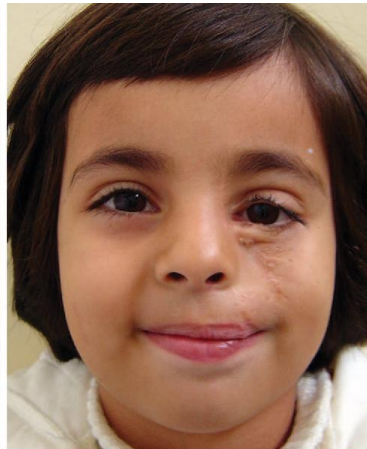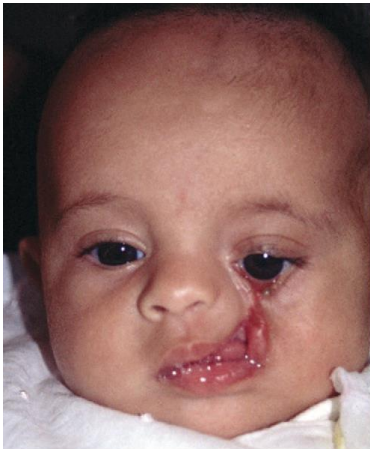A



B

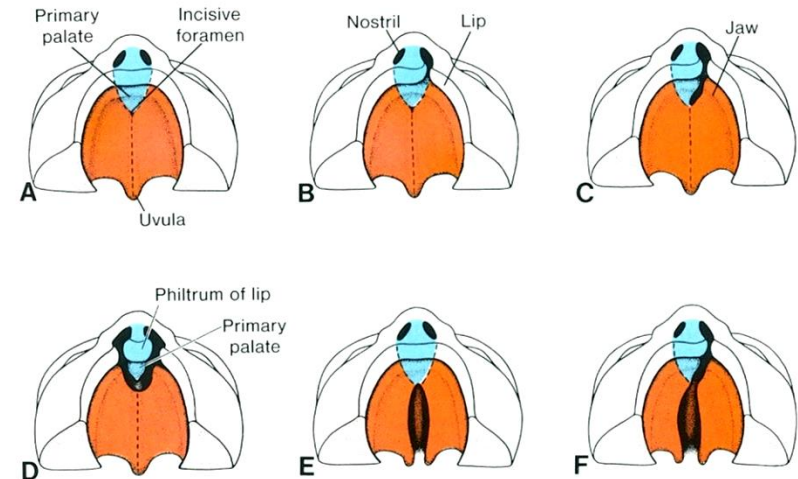
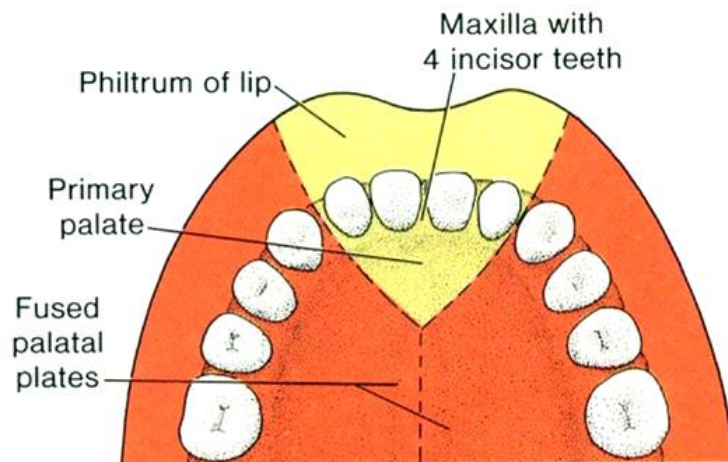
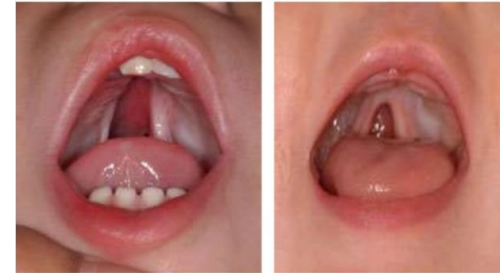
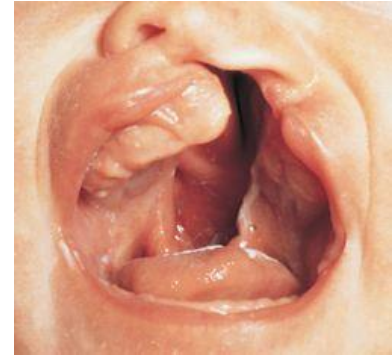
C

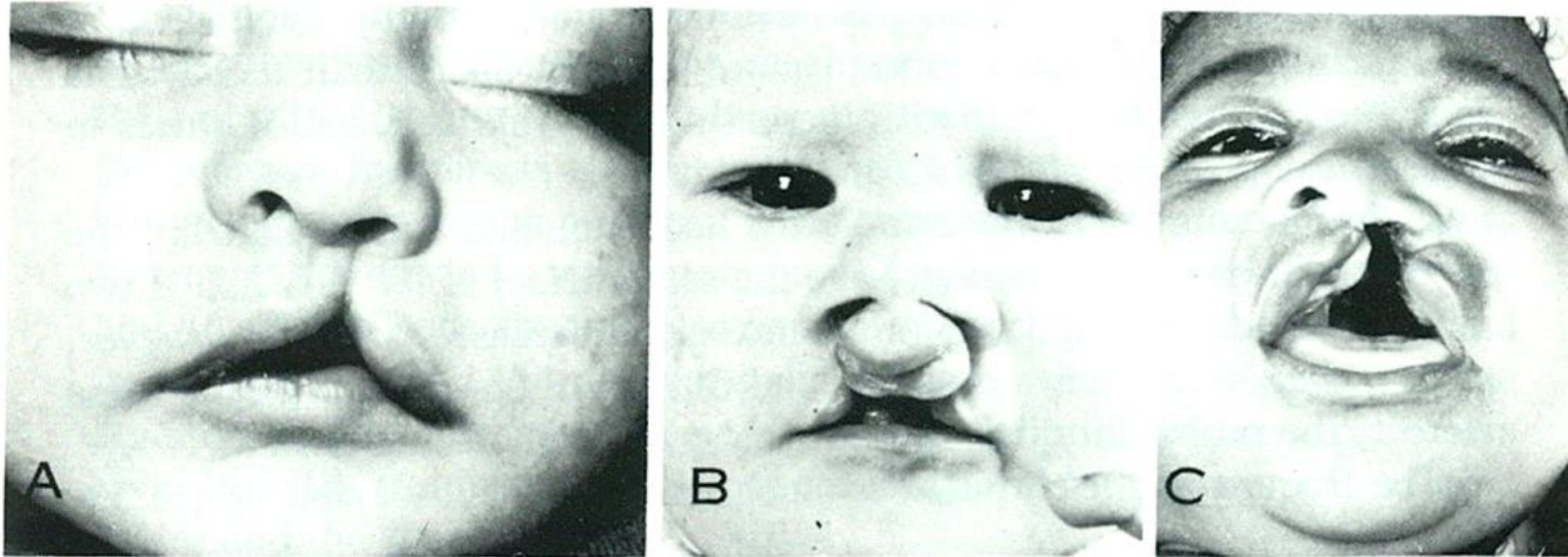


## Rozštěp tvrdé tkáně

- horní čelist
  - mezi špičkem a 2. řezákem
  - unilaterálně nebo bilaterálně
  - kombinována s rozštěpem patra (*cheilognathoschisis*)
- patro (*palatoschisis*)
  - primární (před foramen incisivum)
  - sekundární (za foramen incisivum)
- sdružené vady: *cheilognathopalatoschisis*

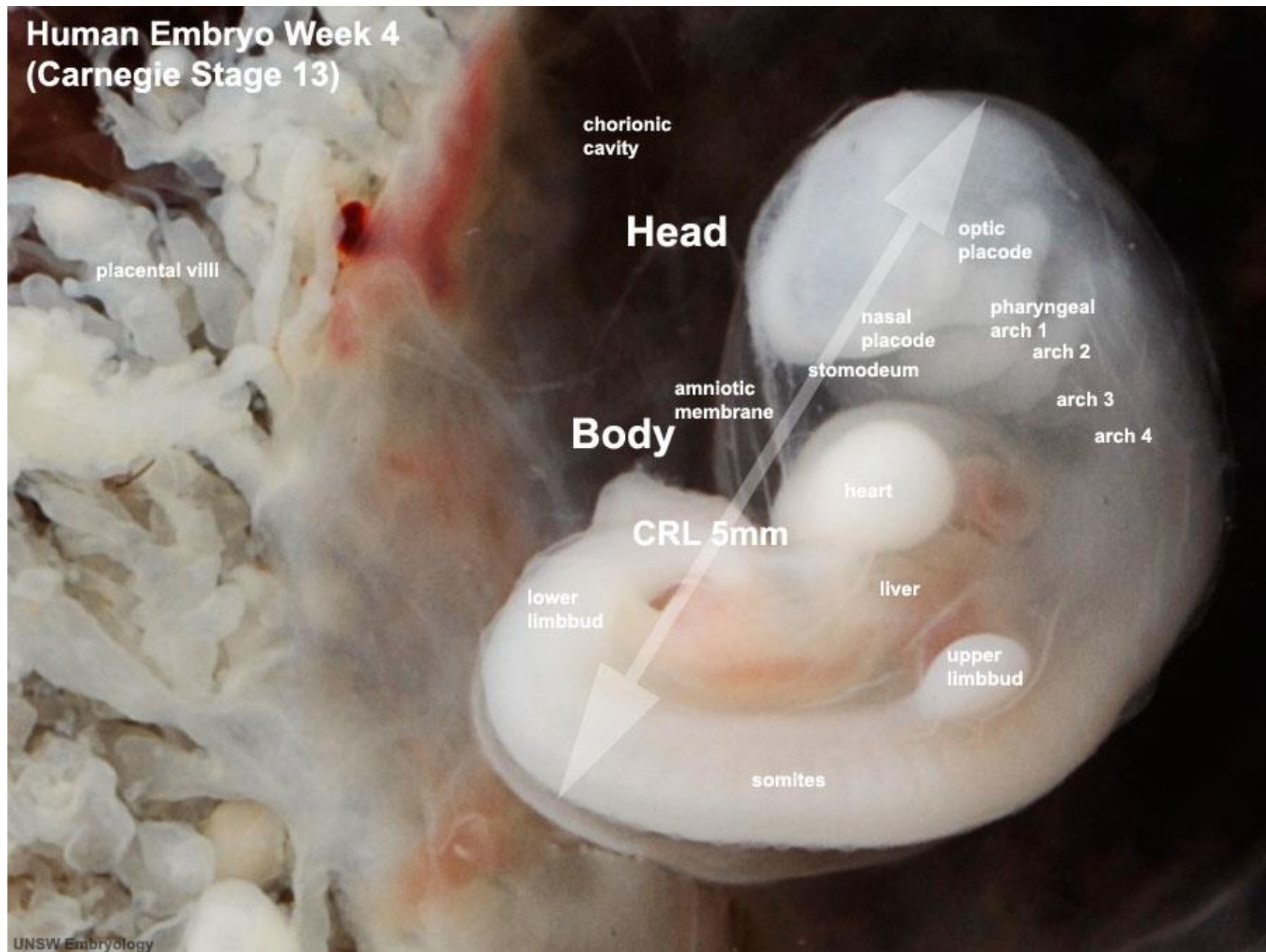


**Figure 16-25.** Ventral view of the palate, gum, lip, and nose. **A**, Normal. **B**, Unilateral cleft lip extending into the nose. **C**, Unilateral cleft involving lip and jaw, and extending to incisive foramen. **D**, Bilateral cleft involving lip and jaw. **E**, Isolated cleft palate. **F**, Cleft palate combined with unilateral anterior cleft.



**Figure 16-26.** Photographs of incomplete cleft lip (A), bilateral cleft lip (B), and cleft lip, cleft jaw, and cleft palate (C). (Courtesy Dr. M. Edgerton, Department of Plastic Surgery, University of Virginia.)

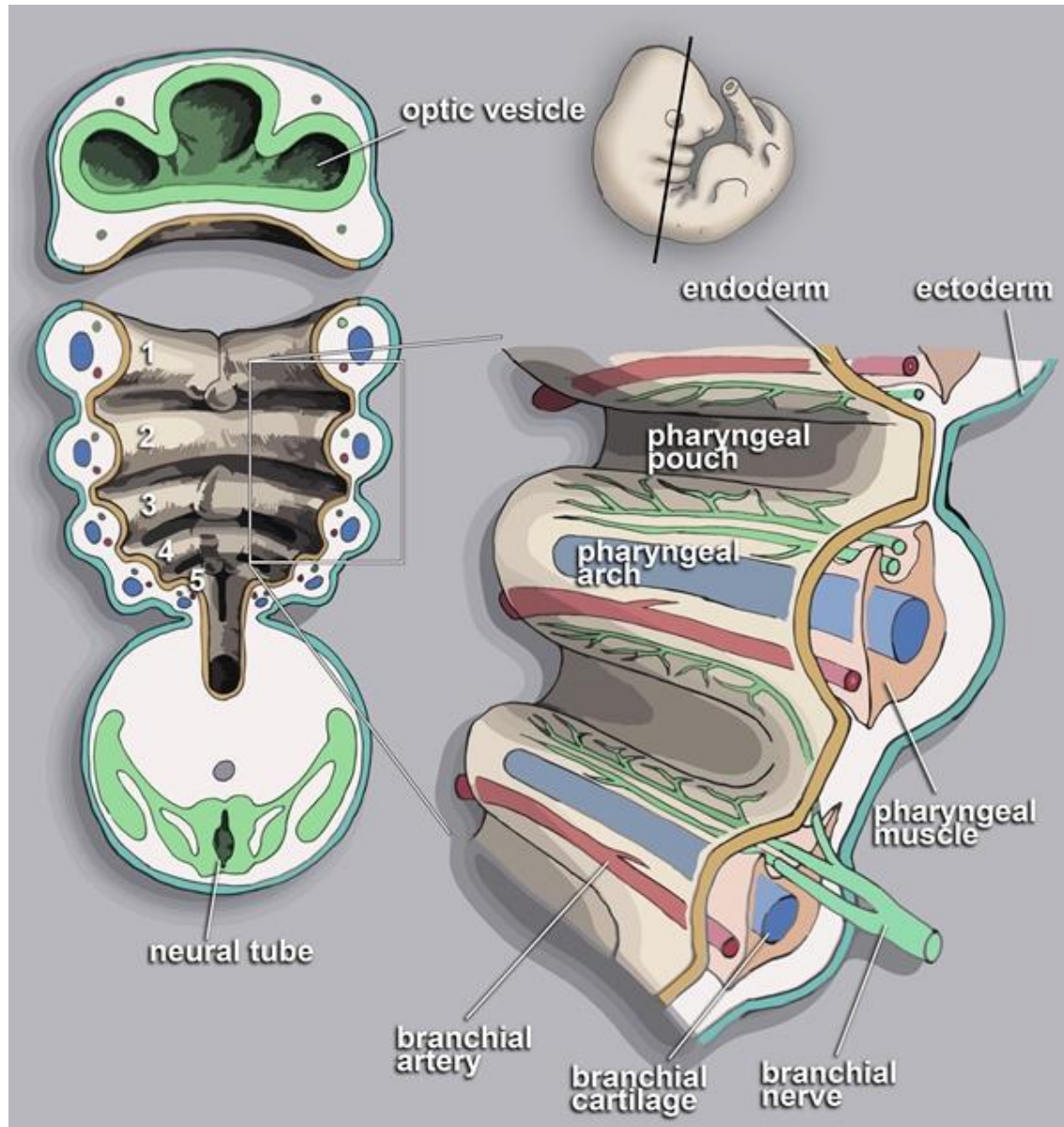
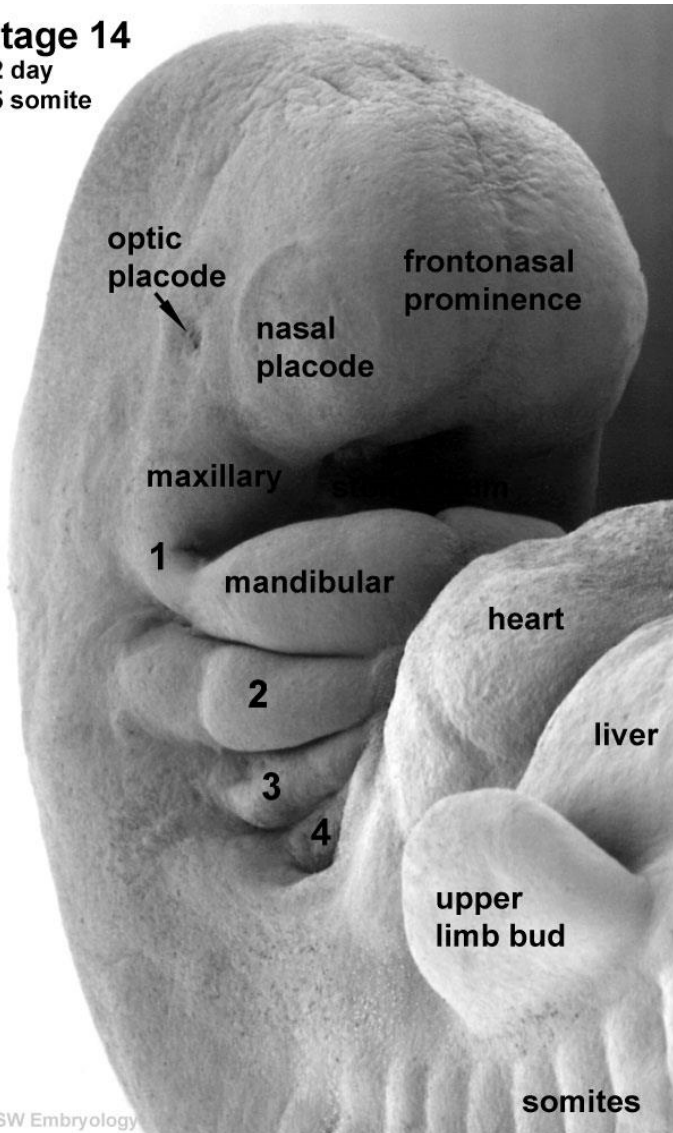
# FARYNGOVÝ APARÁT



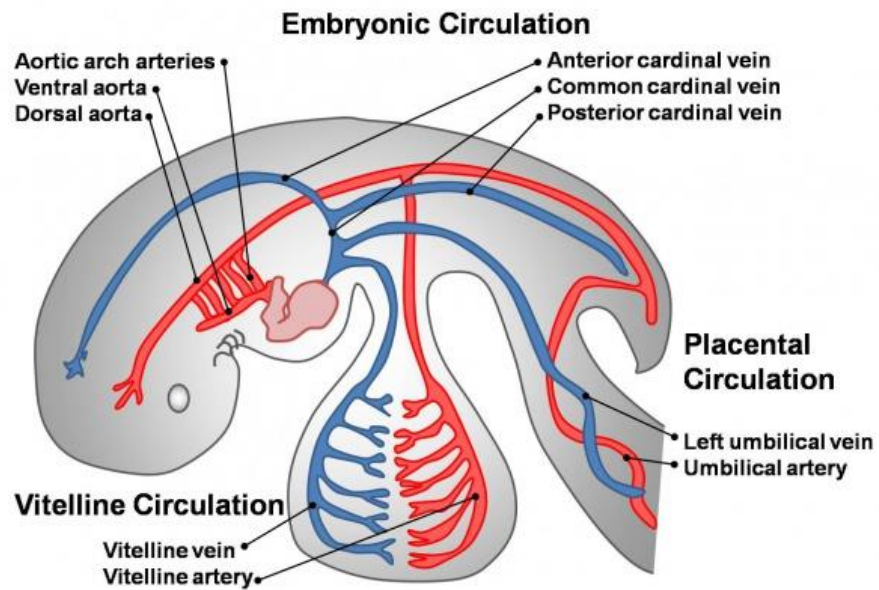
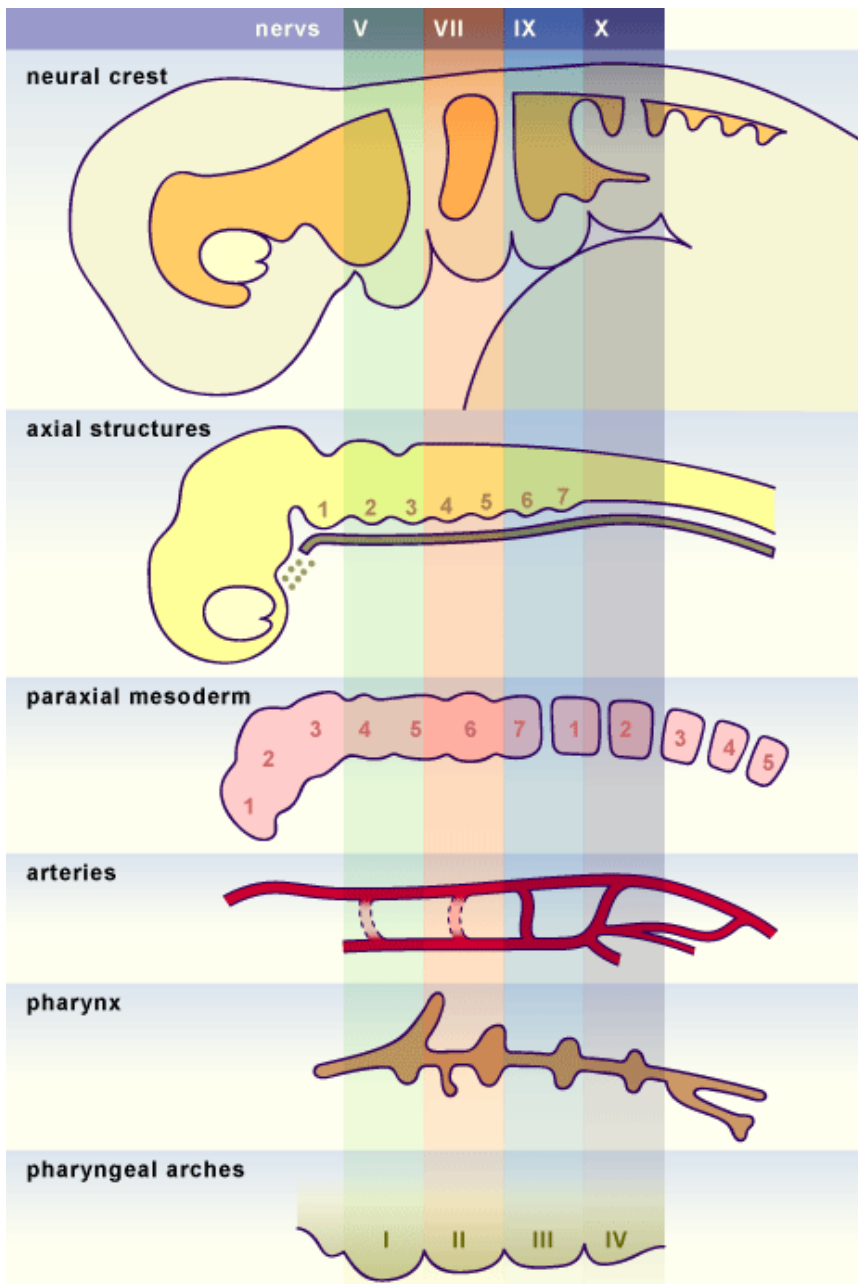
# FARYNGOVÝ APARÁT

## Stage 14

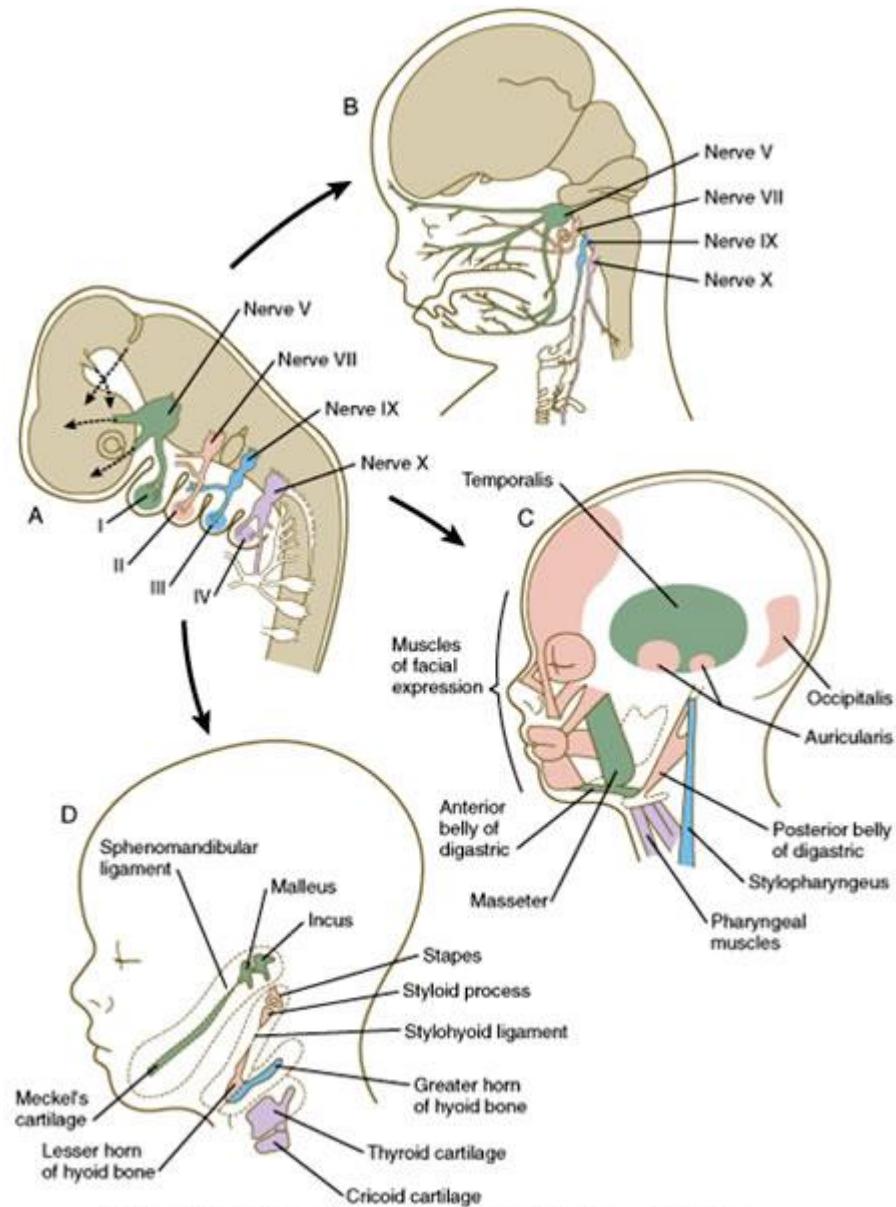
32 day  
35 somite



# FARYNGOVÝ APARÁT

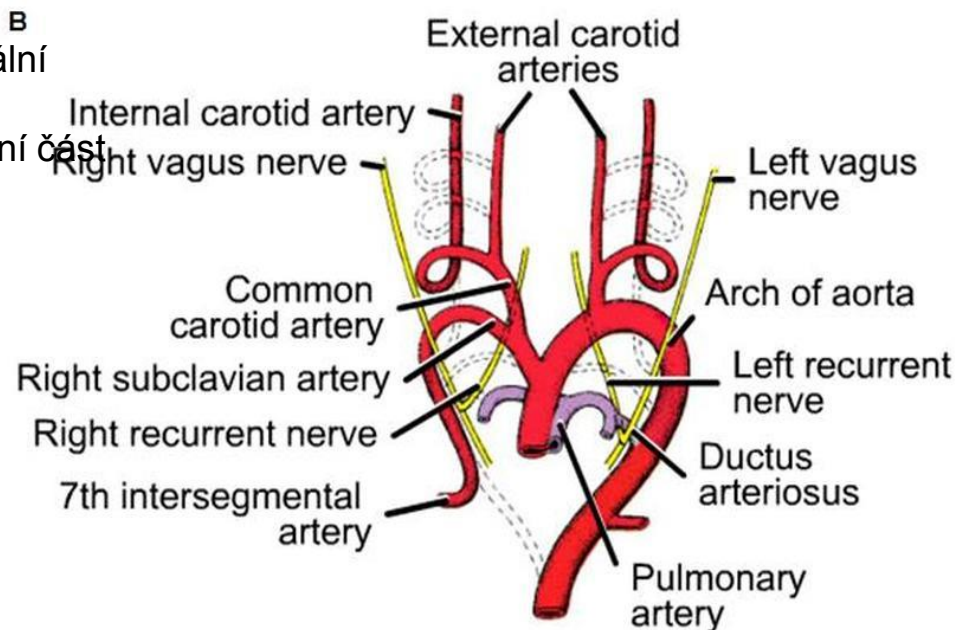
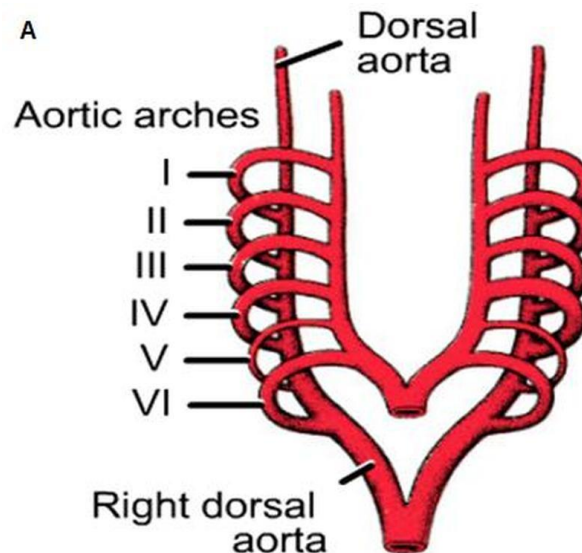


# FARYNGOVÝ APARÁT



## Aortální oblouky

- 1 zaniká, přispívá k a. maxillaris, a. carotis ext.
- 2 zaniká, přispívá k a. stapedia, a. hyoidea
- 3 a. carotis interna
- 4 pravý: t. brachiocephalicus + část a. subclavia dextra  
levý: arcus aortae
- 5 zaniká
- 6 pravý: proximální část: a. pulmonalis dextra, distální vymizí  
levý: proximální část a. pulmonalis sinistra, distální část ductus arteriosus





# FARYNGOVÝ APARÁT A JEHO DERIVÁTY - SHRNUÍ

Derivát ektodermové brázdy	Faryngový oblouk	Aortální oblouk	Kraniální nerv	Příklad branchiomerních svalů	Deriváty skeletu	Deriváty entodermové výchlípký
vnější zvukovod	1 mandibulární	zaniká, částečně a. maxillaris	V n.trigeminus	žvýkáci svaly m.mylohyoideus přední břiško m. digastricus	kladívko, kovadlinka lig. sphenomandib. Meckelova chrupavka	středoušní dutina, tuba auditiva
zanikají	2 hyoidní	zaniká, částečně a. stapedia a. hyoidea	VII n.facialis	mimické svaly zadní břiško m.- digastricus m.stapedius m. stylohyoideus	třmínek proc. styloideus, hyoidní chrupavka	fossa tonsillaris
	3	proximální úseky aa. carotides communes, distální aa. carotides internae	IX n.glossopharyngeus	m. stylopharyngeus	hyoidní chrupavka	thymus, příštítná tělíska (inf)
	4	pravý: proximální část a. subclavia dextra  levý: část arcus aortae	X n. vagus	m. cricothyroideus m levator veli palatini příčně pruhovaná svalovina hltanu a jíčnu svaly hrtanu	laryngeální chrupavky	příštítná tělíska (sup)
	5 nevyvíjí se	pokud je založen, rychle zaniká				
	6	vpravo: z proximální části vzniká a. pulmonalis dextra, distální část zaniká; vlevo: z proximální části vzniká a. pulmonalis sinistra, z distální části vzniká ductus arteriosus.			svaly faryngu a laryngu	laryngeální chrupavky

# DĚKUJI ZA POZORNOST

pvanhara@med.muni.cz

<http://www.med.muni.cz/histology/education/>