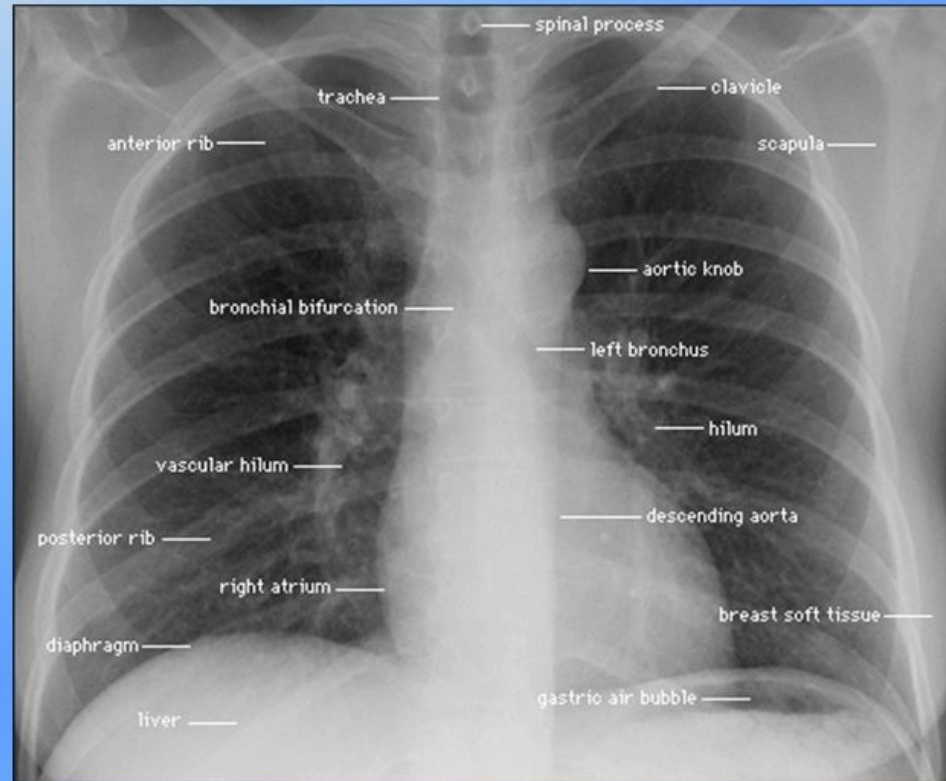


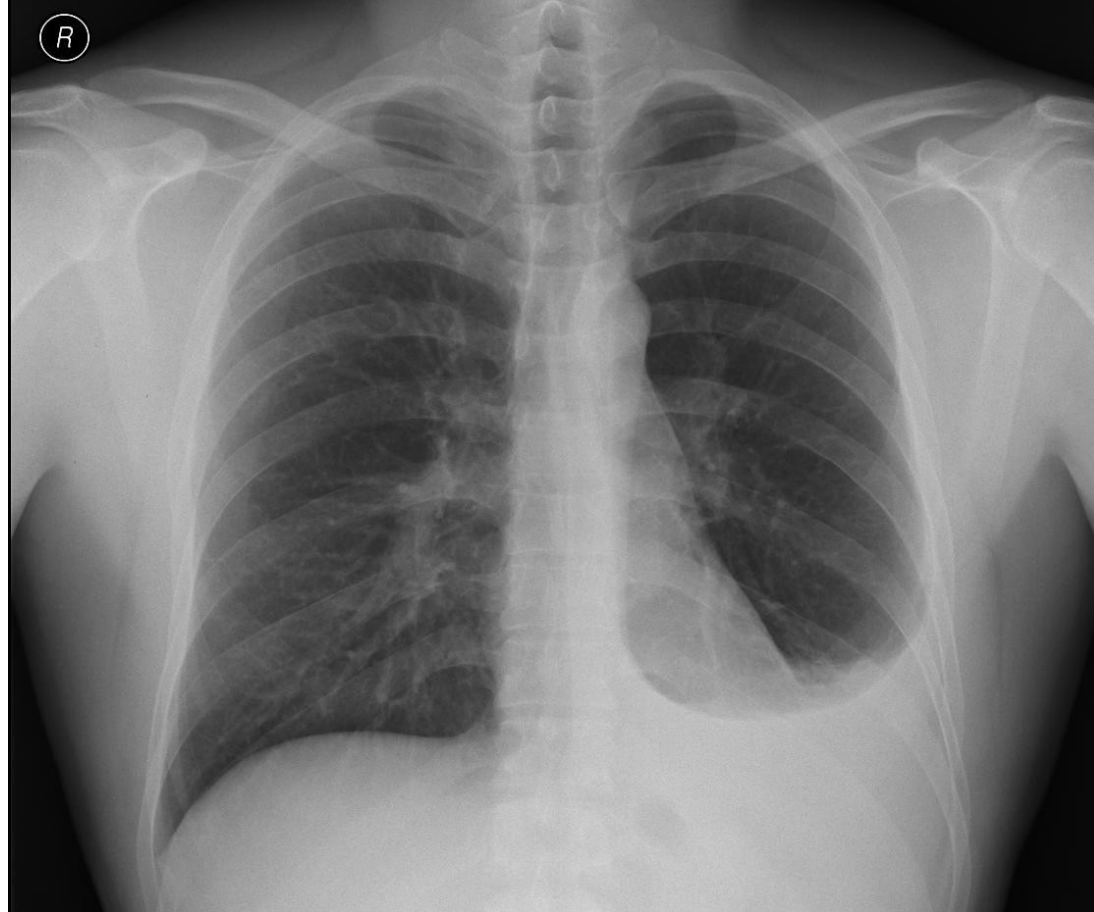
Rtg snímky

Normální rtg S a P

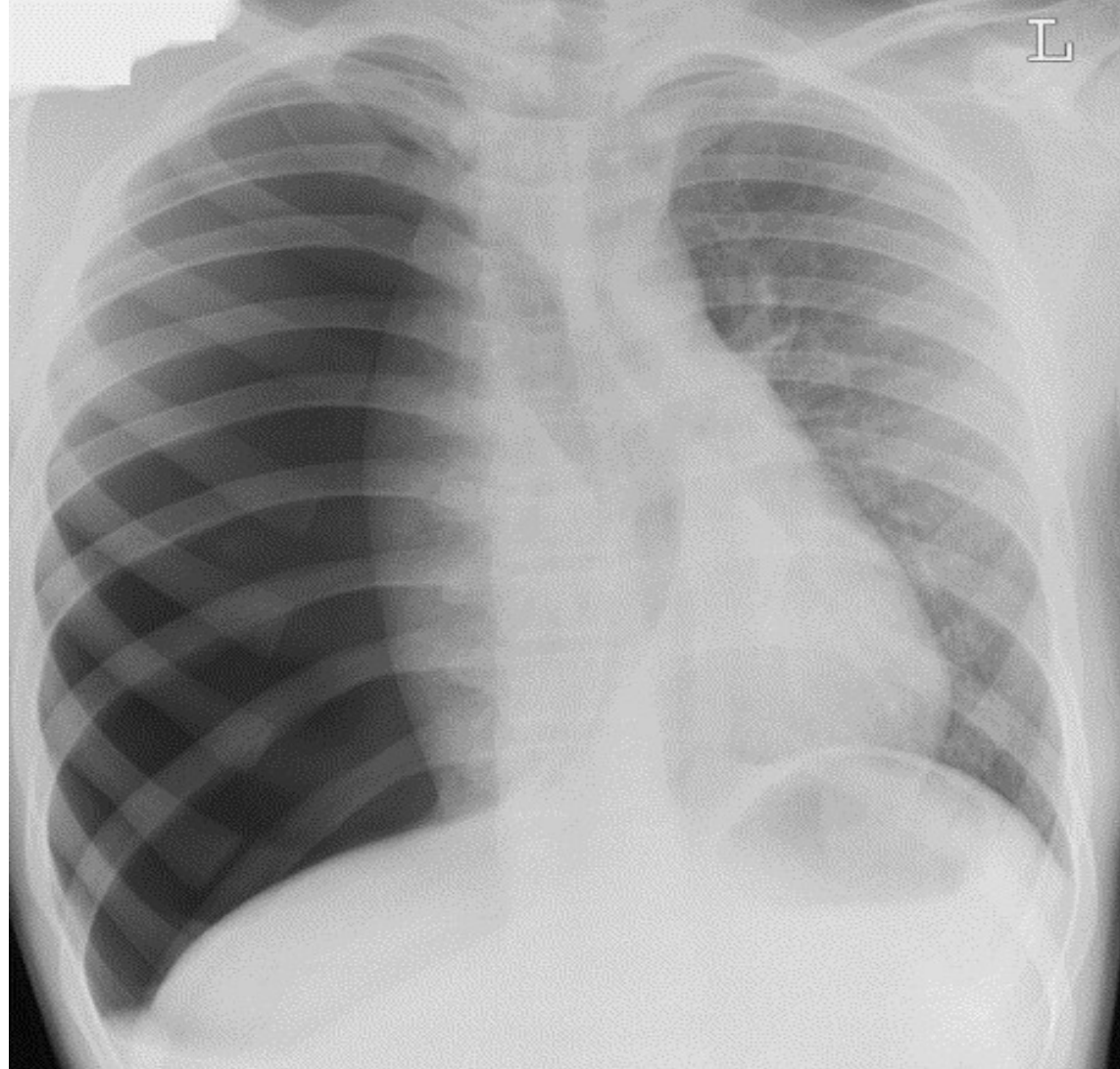
Normální RTG hrudníku



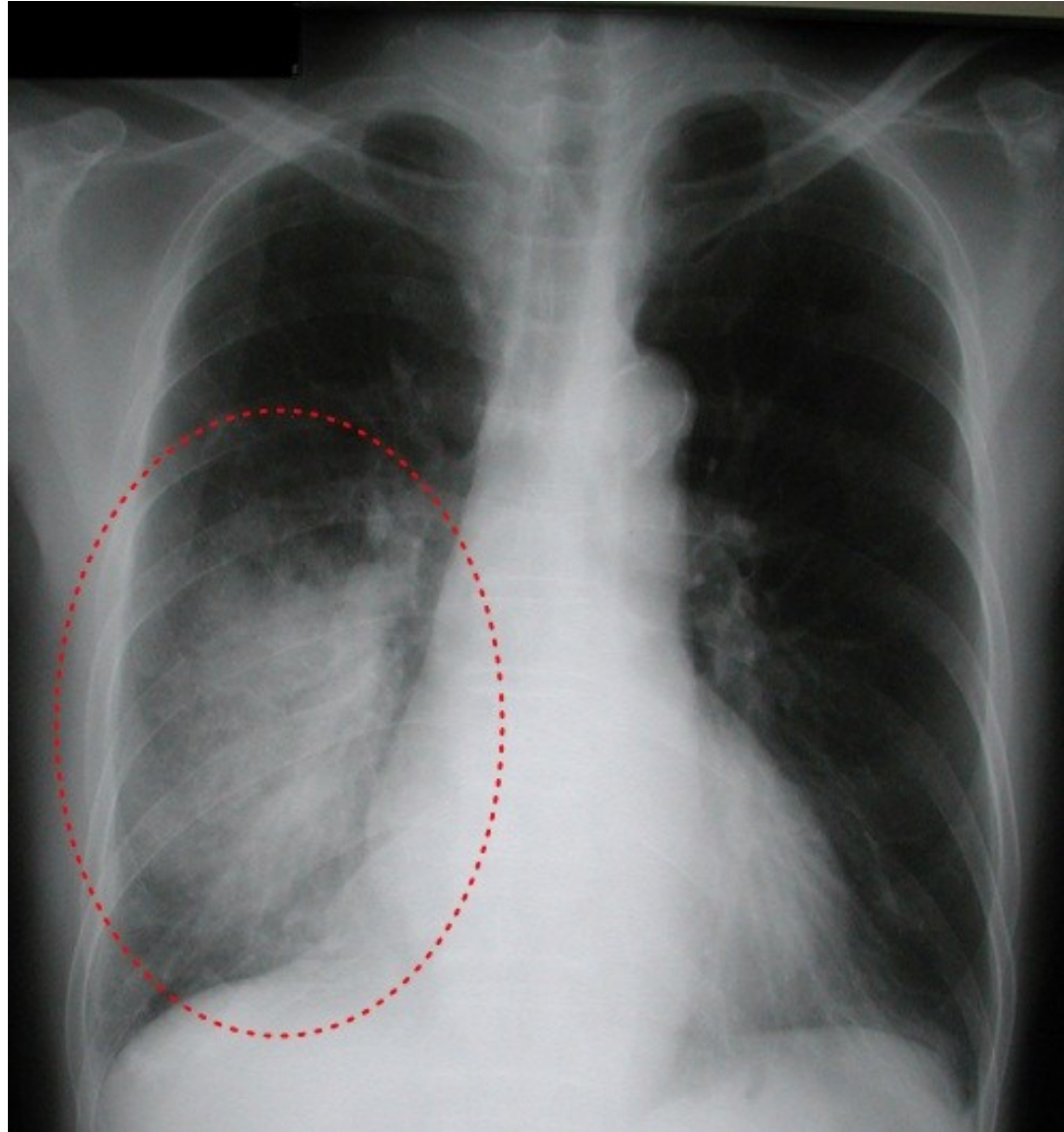
Fluidothorax



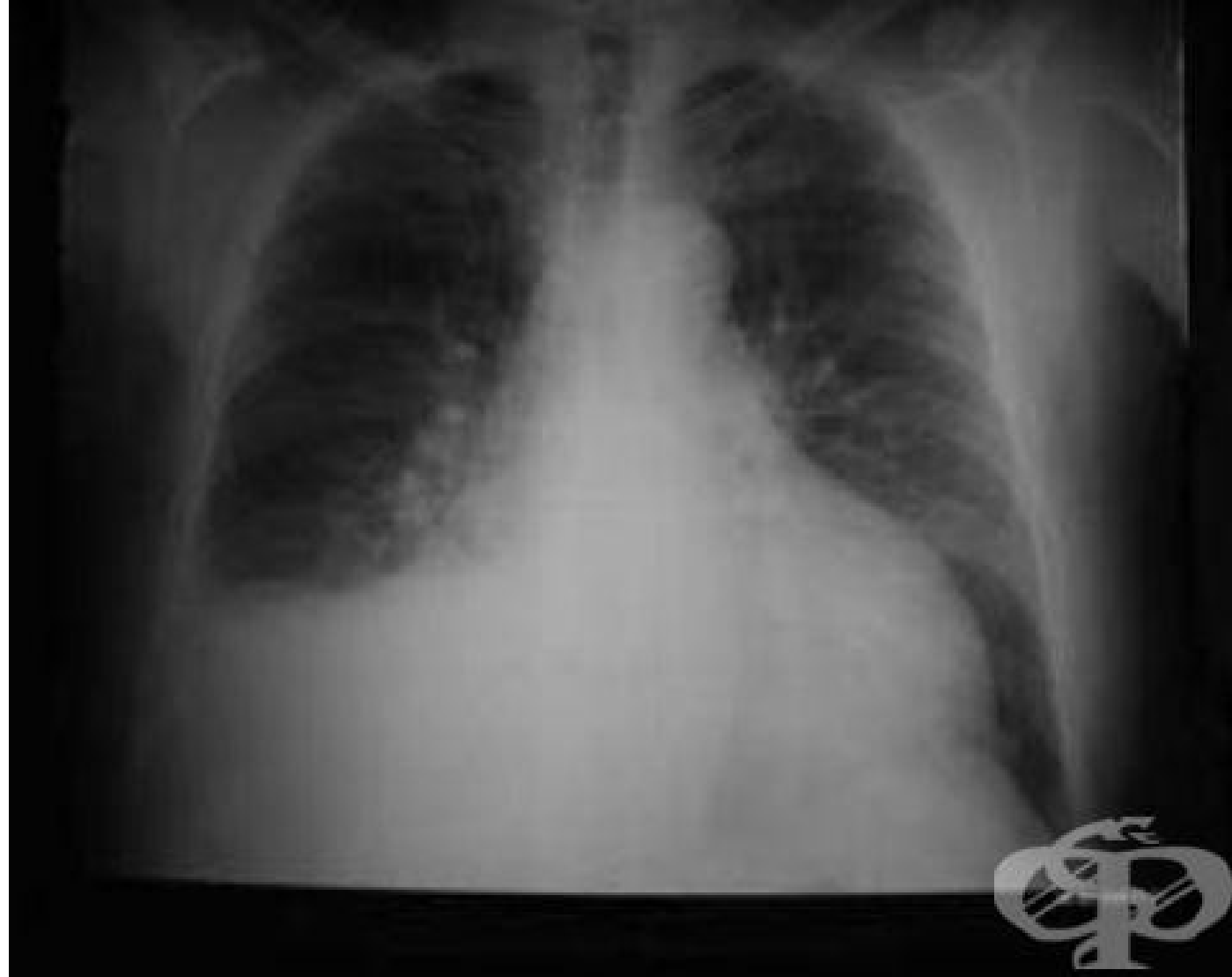Pneumothorax



Pneumonie



Exudativní perikarditida (+ exudativní pleuritida)



Meta ad pulm.

Plicní uzly

- metastázy karcinomu varlete

