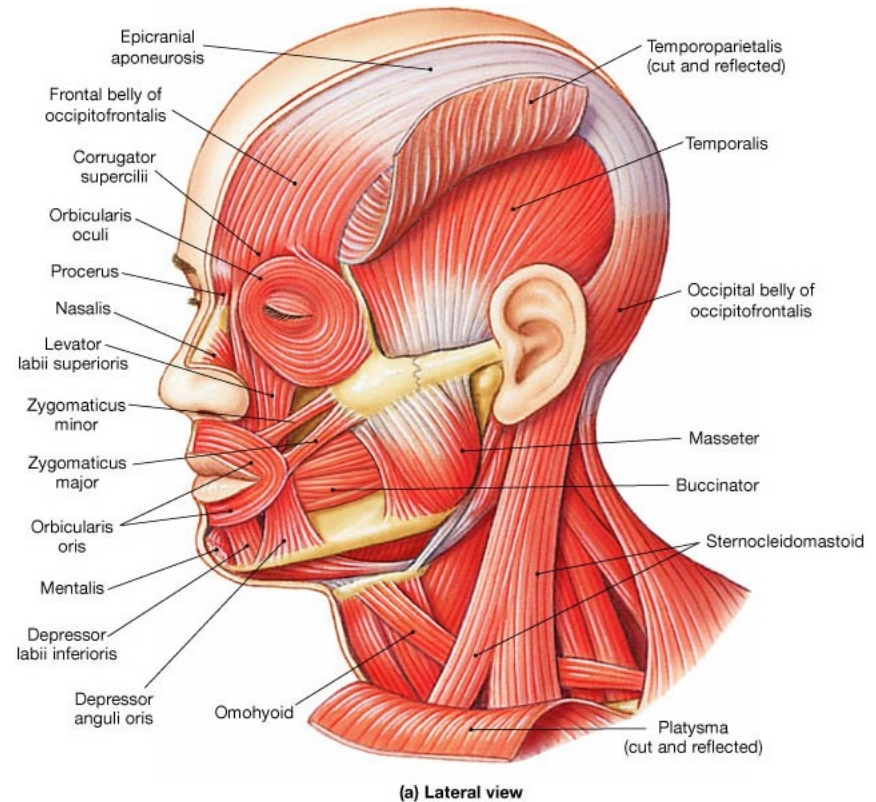


Manual muscle testing (2)

Facial muscles



Introduction

- Facial muscles
- MMT, grading
- Facial nerve
- Facial paralysis

Muscles of the Face (Facial Muscles)

Occipitofrontalis

Levator labii superioris

Zygomaticus minor

Zygomaticus major

Buccinator

Levator anguli oris

Depressor labii inferioris

Temporalis

Procerus

Orbicularis oculi

Levator labii superioris alaeque nasi

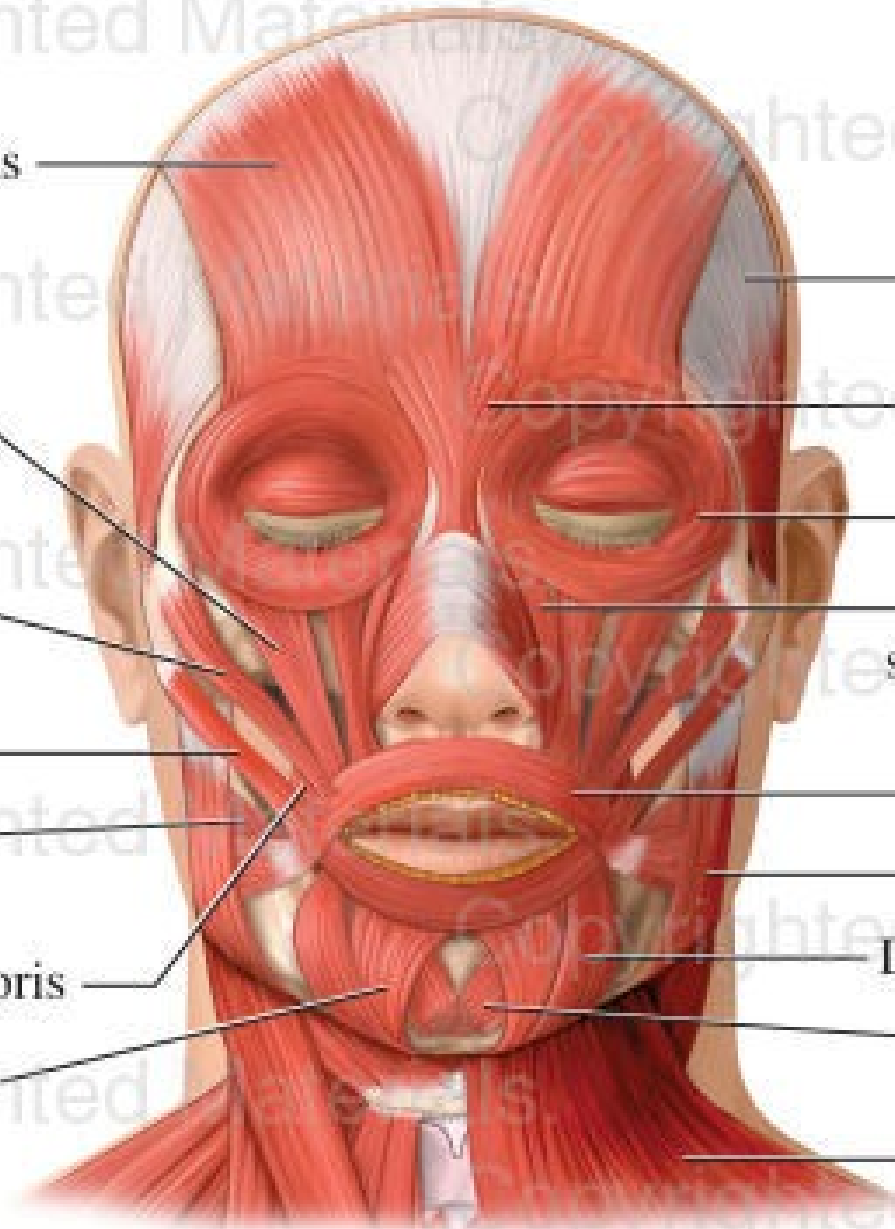
Orbicularis oris

Masseter

Depressor anguli oris

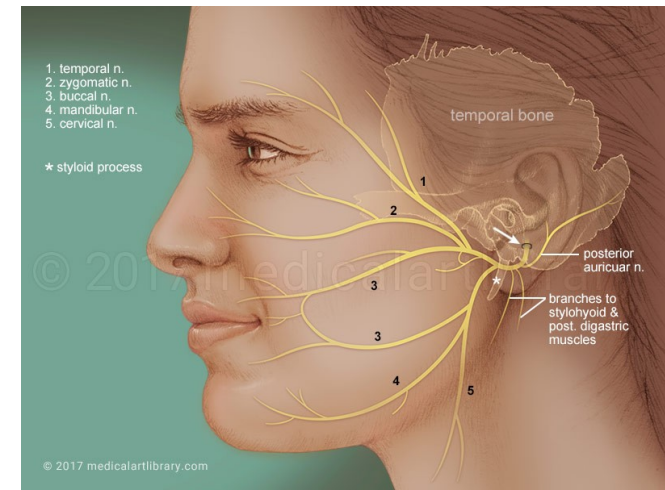
Mentalis

Platysma



Facial Nerve

- Most of the facial nerve is comprised of **motor innervation of the muscles of facial expression**



In addition, it subserves several other functions including:

- **taste perception** from the anterior two-thirds of the tongue
- **perception of cutaneous stimuli** in the external auditory canal and over part of the pinna and mastoid region
- innervation of **the stapedius muscle** in the middle ear
- innervation of **the lacrimal gland** and two of **the salivary glands** (the submaxillary and submandibular)

Facial expression

- The most prominent deficit noted by patients with facial nerve damage is **weakness of muscles of facial expression**
- Careful **observation** of the patient's face during conversation and at rest almost always reveals facial weakness
- Additionally, the face may "**droop**" on the side of damage due to the effects of gravity

Facial nerve: test

The nerve can be further tested by **functional activities:**

- having the patient **close their eyes and lips** tightly
- having the patient **grimace** (show their teeth)
- having the patient **look up** (elevating the eyebrows and creasing the forehead)
- having the patient **fill their cheeks with air** with their lips tightly pursed. If one or both sides of the face are weak, s/he will have difficulty holding the air in

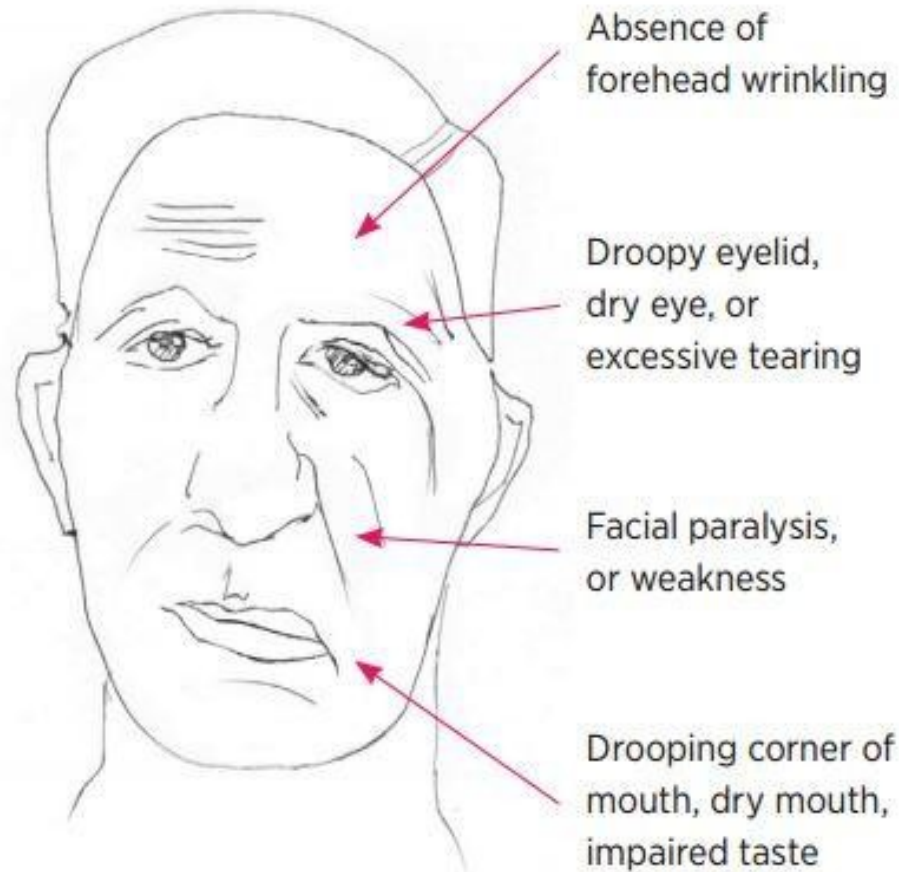
Bell's palsy

- The most common cause of facial weakness, an idiopathic condition that may result from **viral infection-induced inflammatory swelling** of the facial nerve in its canal
- Since the canal is very long and tight, swelling can put **pressure on the nerve**, resulting in damage either by direct effects or by impairing blood flow in the nerve
- In some cases, facial palsy is produced by a very clear viral infection with **Herpes Zoster**, often associated with ear pain and vesicles on the tympanic membrane
- **Lyme disease** also has a predisposition to produce facial palsy, sometimes bilateral

Bell's palsy

- The characteristic of peripheral facial palsy is that it **involves the entire side of the face**, including weakness of the forehead muscles as well as those around the eye and mouth
- This is because fibers to all of these regions of the face are packed together in the facial canal
- Most cases of uncomplicated Bell's palsy recover quite well
- In its most severe form, infarction of the nerve may occur with a prolonged and not infrequently incomplete process of regeneration
- This is more common when a longer course of the nerve is affected, accompanied by ageusia (loss of taste) and hyperacusis

Bell's palsy



Central paralysis

- Corticobulbar (pyramidal) projections from the motor cortex (precentral gyrus) through the genu of the internal capsule are the major pathway for voluntary facial movement
- The cerebral cortical projections to the facial motor neurons innervating the upper face are essentially bilateral (i.e., each cortical hemisphere provides innervation to both sides)
- Therefore, unilateral lesions (such as a stroke affecting one hemisphere or the internal capsule) will not produce weakness of the upper face muscles

Central paralysis

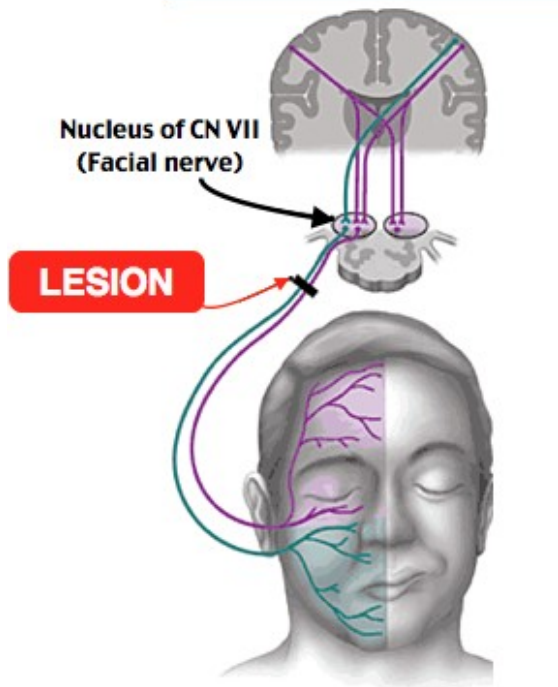
- On the other hand, facial motor neurons that innervate the muscles of the lower face receive input largely from the contralateral hemisphere (i.e., the right hemisphere activates motor neurons of the left facial nucleus, and vice-versa)
- Therefore, a lesion involving the right motor cortex (e.g., carotid-middle cerebral arterial system occlusion and hemispheric infarction) causes a weakness of voluntary left lower facial movement that is especially noticeable while the patient is talking, grimacing (usually elicited by asking the patient to bare their teeth or gums), or resting

Central paralysis

- The corner of the mouth droops and there may be some widening of the palpebral fissure (eye)
- On the other hand, the forehead is normally creased when a person raises their eyebrows or looks toward the ceiling
- This distinguishes the "supranuclear" weakness of the face from the weakness of the whole side of the face due to damage of the peripheral facial nerve, as seen with Bell's palsy.

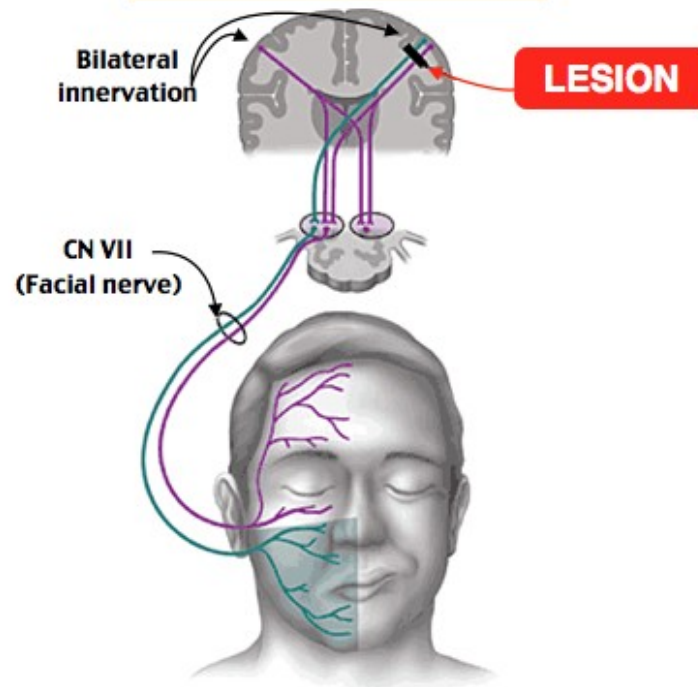
Peripheral vs. central lesion

Peripheral lesion (Bell's palsy (CNVII))



NO forehead sparing
Forehead and lip droop

Central lesion (Stroke)

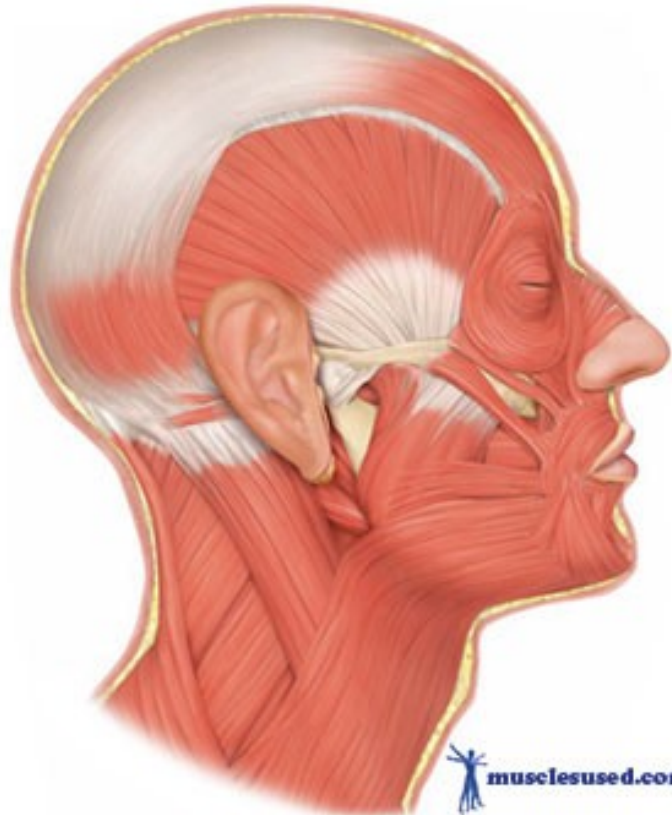
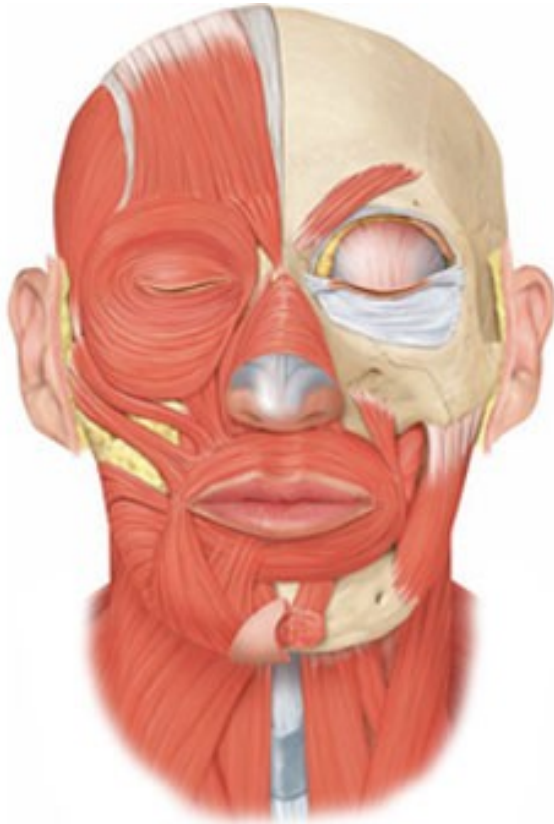

Forehead sparing
Lip droop

Manual muscle test - grading

- 5 Normal contraction of the muscle, no asymmetry compared to healthy side
- 4 Nearly normal contraction, little asymmetry compared to healthy side
- 3 Contraction of the muscle in one half compared to healthy side
- 2 Contraction of the muscle in one quarter compared to healthy side
- 1 Trace of muscle contraction can be seen/palpated
- 0 The muscle demonstrates no palpable muscle contraction

Muscles of facial expression


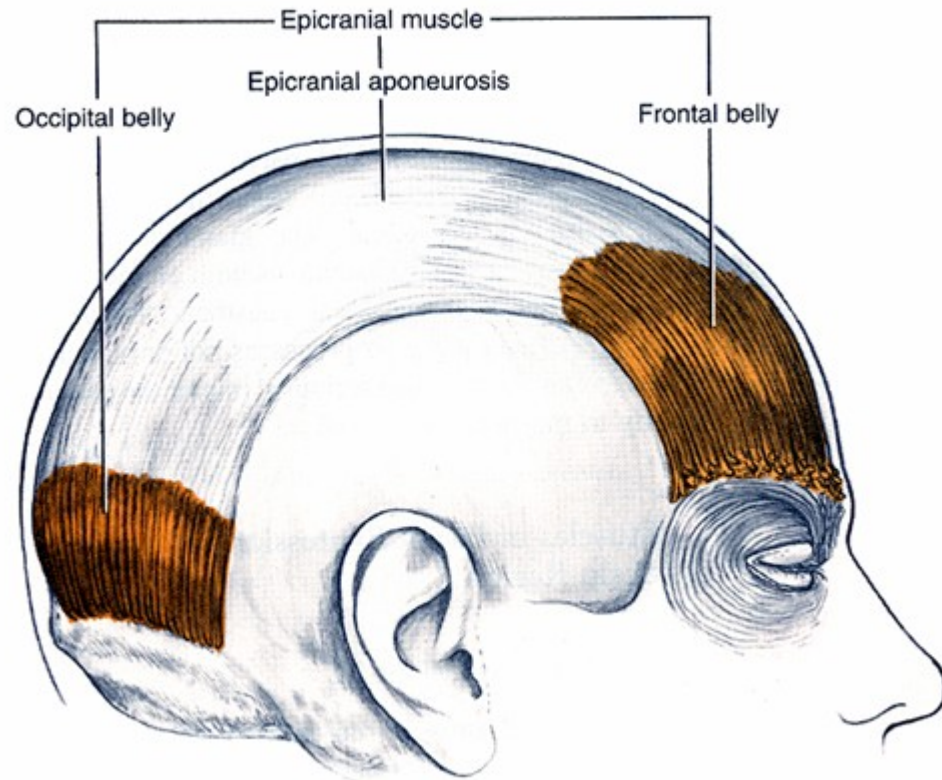


Occipitofrontalis group

- The occipitofrontalis, or scalp, group consists of the frontalis and occipitalis
- These muscles provide **movement of the eyebrows, forehead, and scalp**

M. occipitofrontalis

Raises forehead, pulls scalp backward



Occipitofrontalis

Orbital group


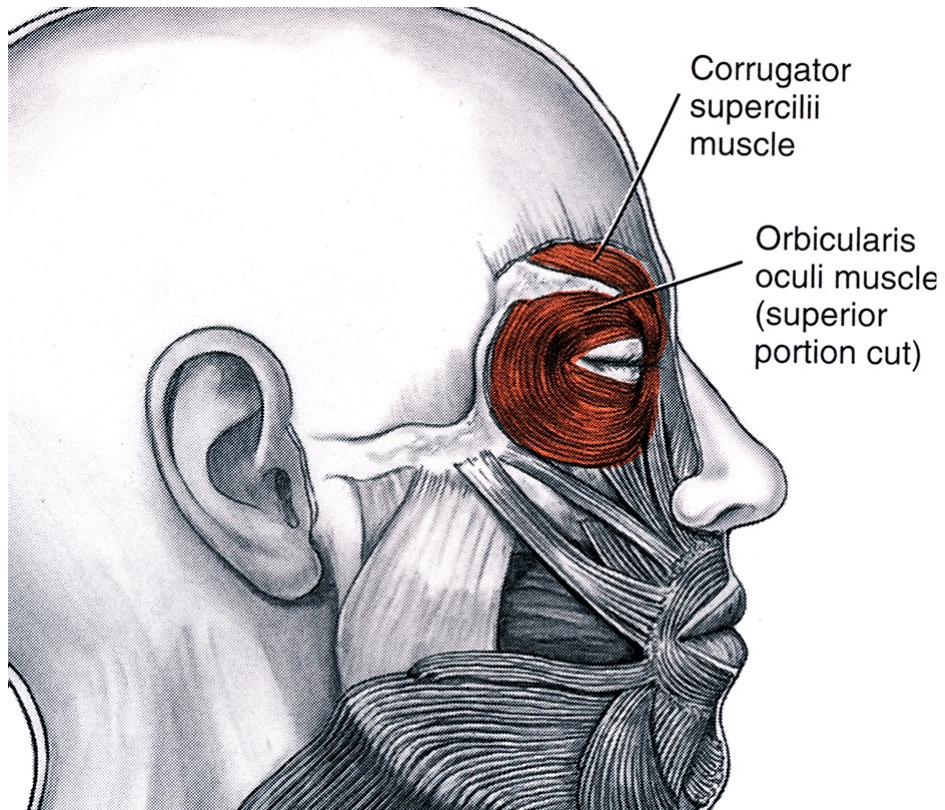
The orbital group consists of:

- orbicularis oculi
- corrugator supercilii

These muscles provide **movement of the eyelid and periorbital skin**

M. corrugator supercilii

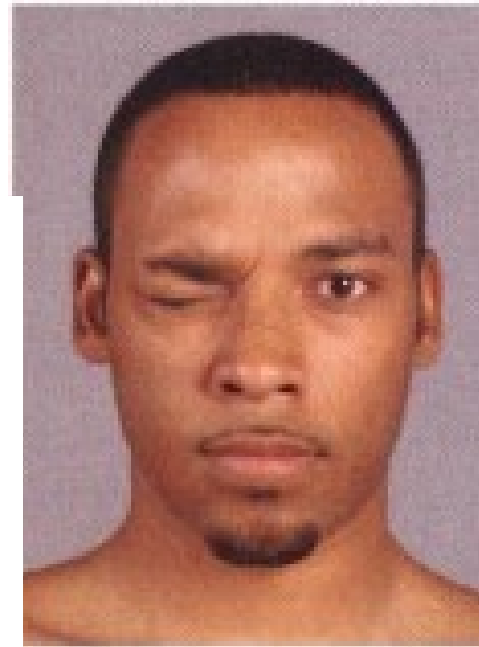
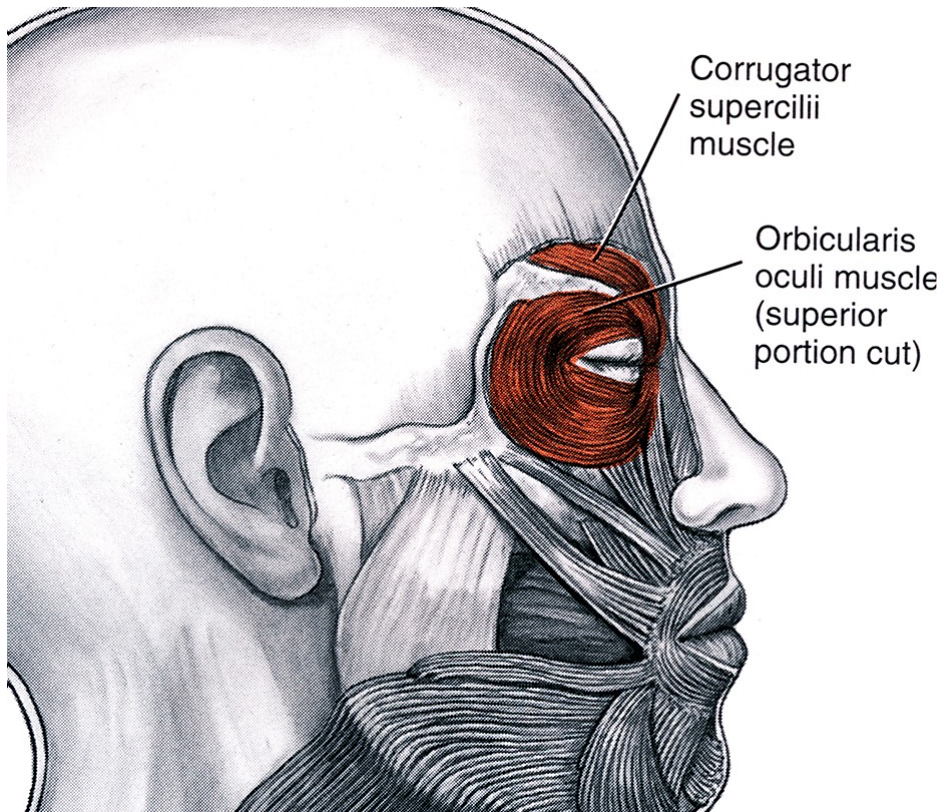
Draws eyebrow medially



Corrugator supercilii

M. orbicularis oculi

Closes eyelid



Nasal group

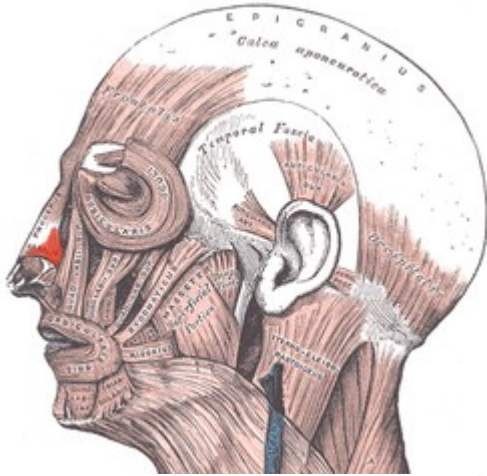
The nasal group consists of:

- Procerus
- Nasalis

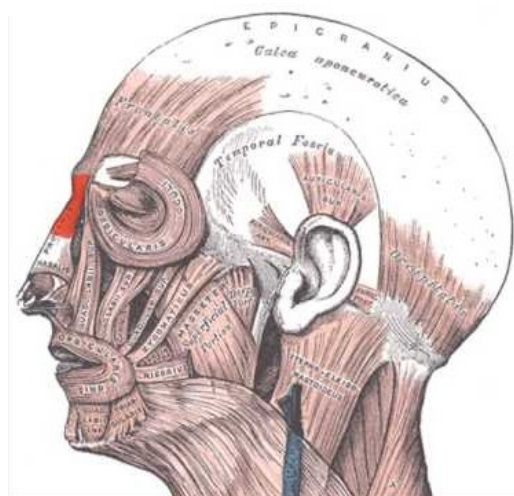
These muscles provide **movement of the nose and perinasal skin**

M. procerus


M. nasalis



M. nasalis



M. procerus



Procerus + transverse
part of nasalis

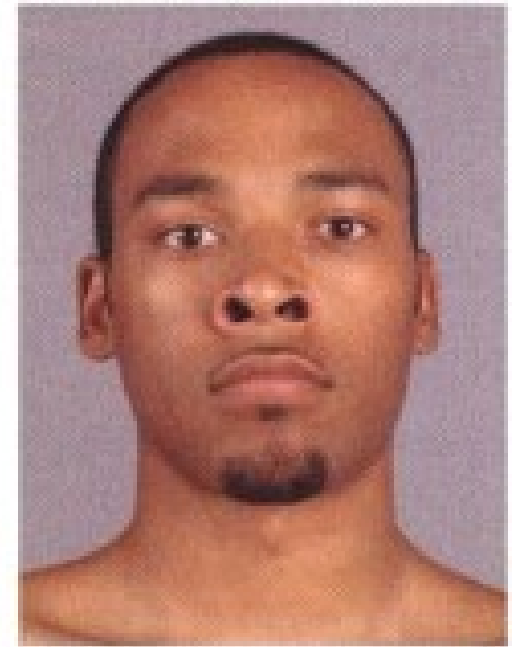
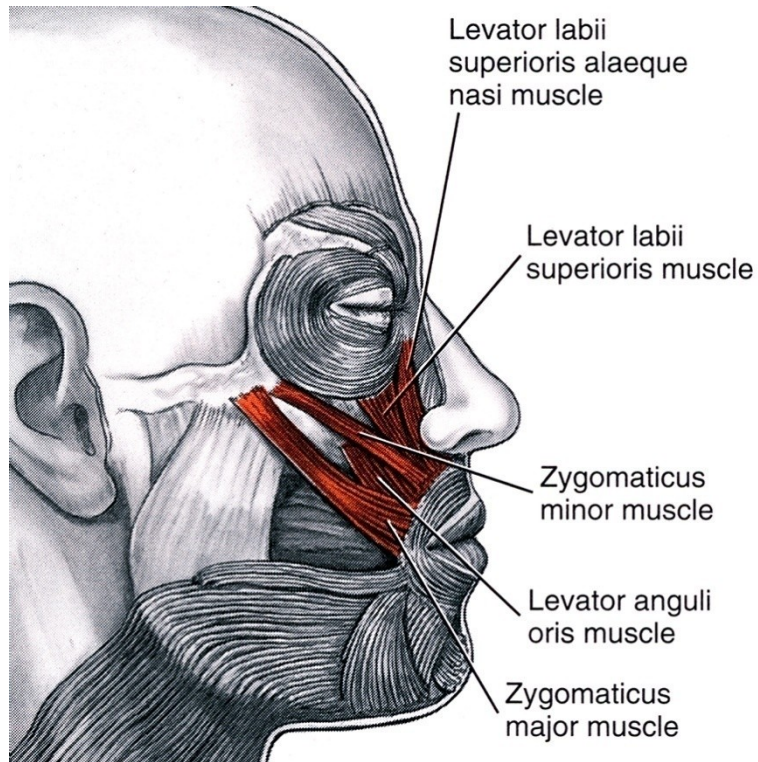
Oral Group

The oral group consists of:

- obicularis oris
- depressor anguli oris, levator anguli oris
- zygomaticus major et minor
- levator labii sup., levator labii sup. alaeque nasi
- risorius
- depressor labii inferioris
- mentalis
- buccinator

These muscles provide **movement of the lips**

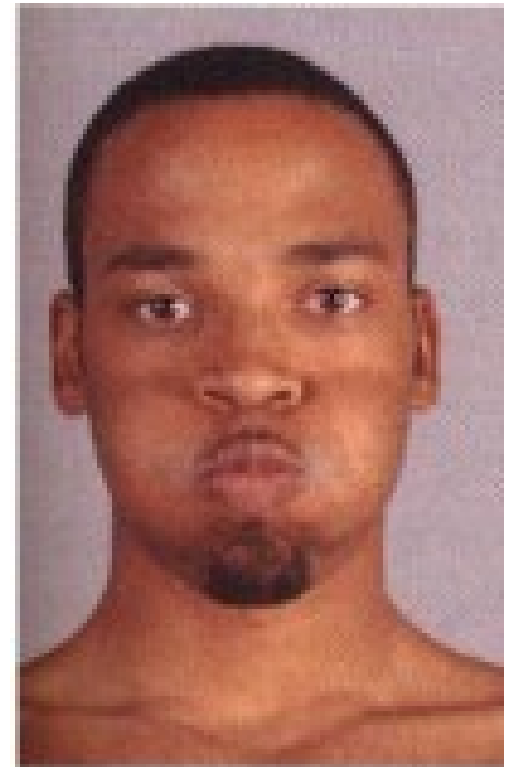
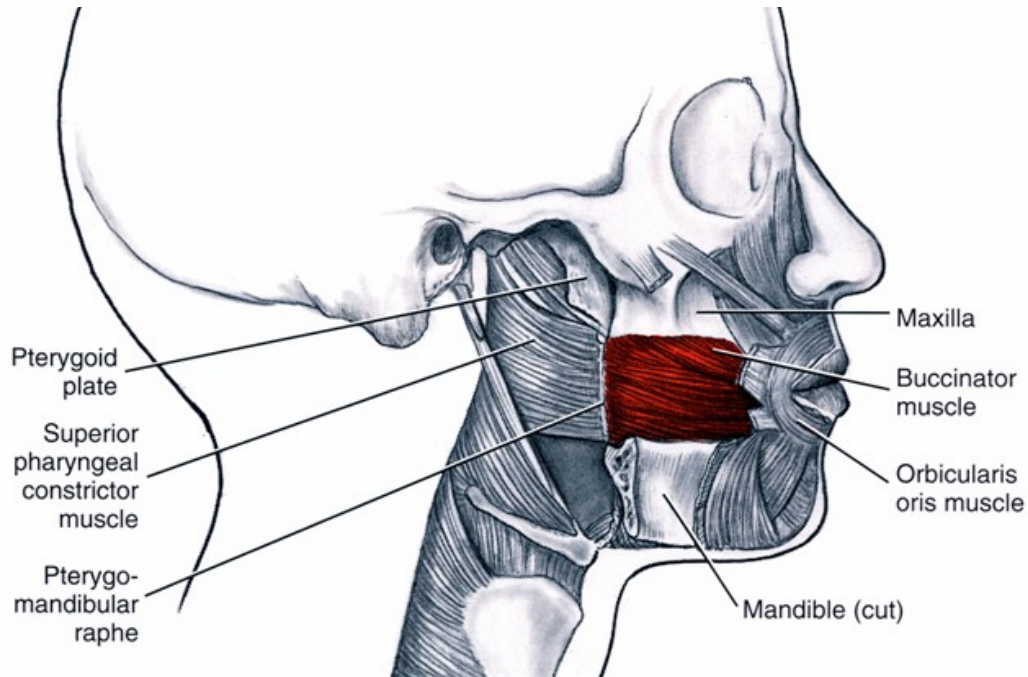
M. levator labii superioris alaeque nasi



Lev. labii sup. alaeque nasi +
alar part of nasalis

Raises upper lip
and widens nostril

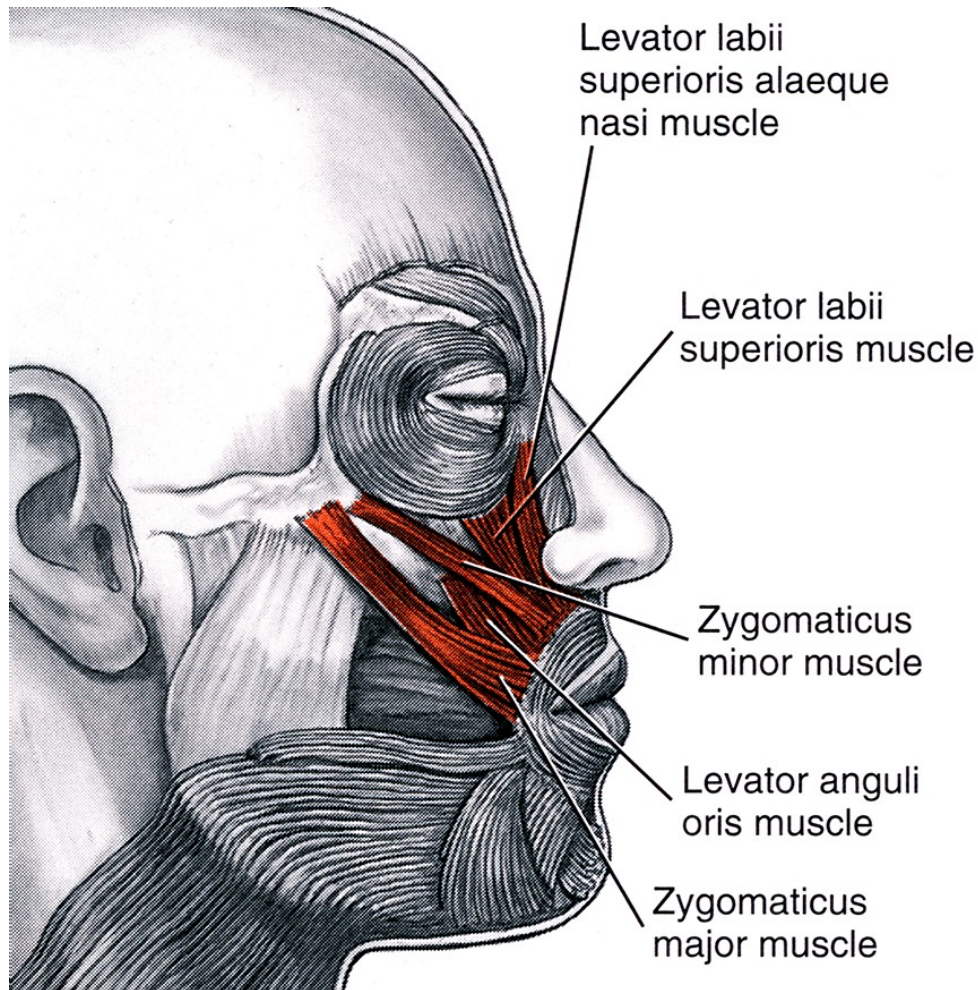
M. buccinator




Buccinator + orbicularis oris

Moves "bolus" of food

M. zygomaticus major et minor


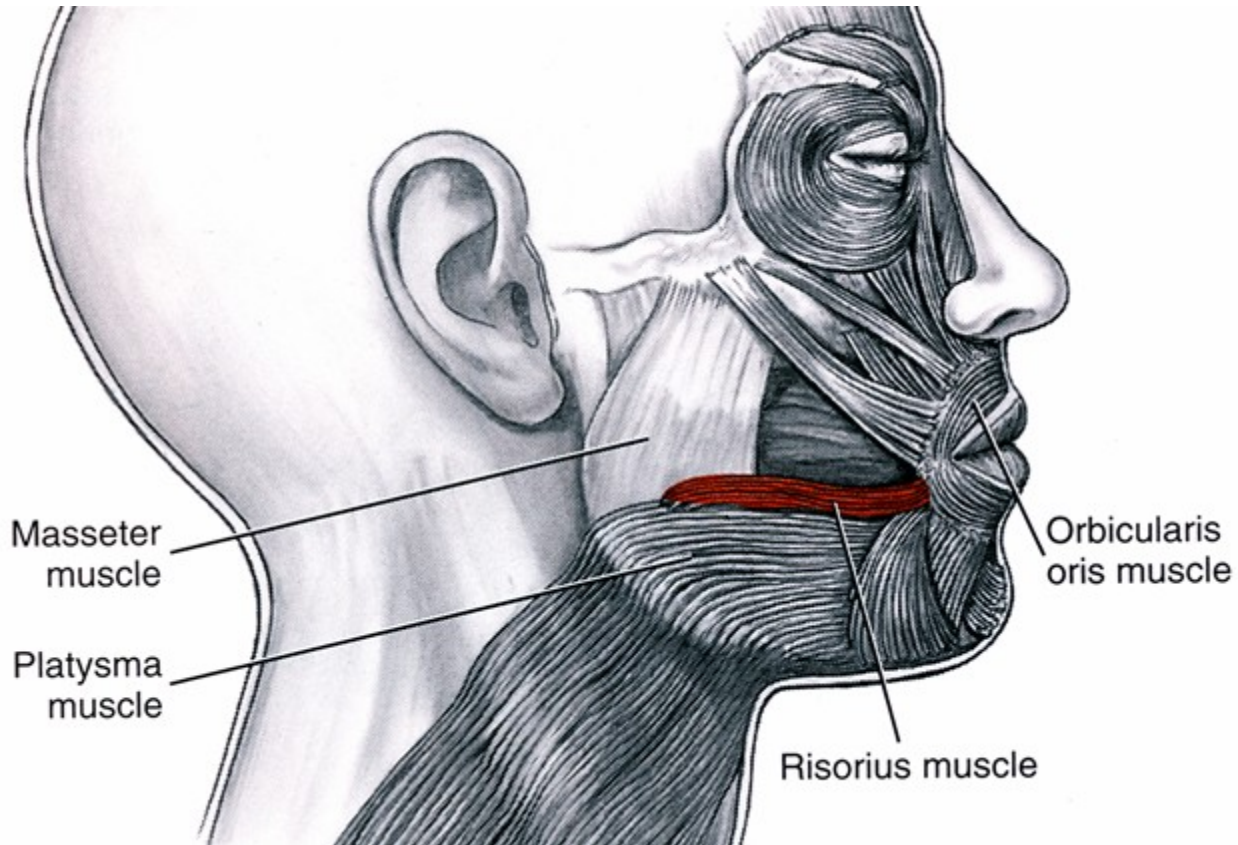


Raises angle of mouth



Zygomaticus major + minor


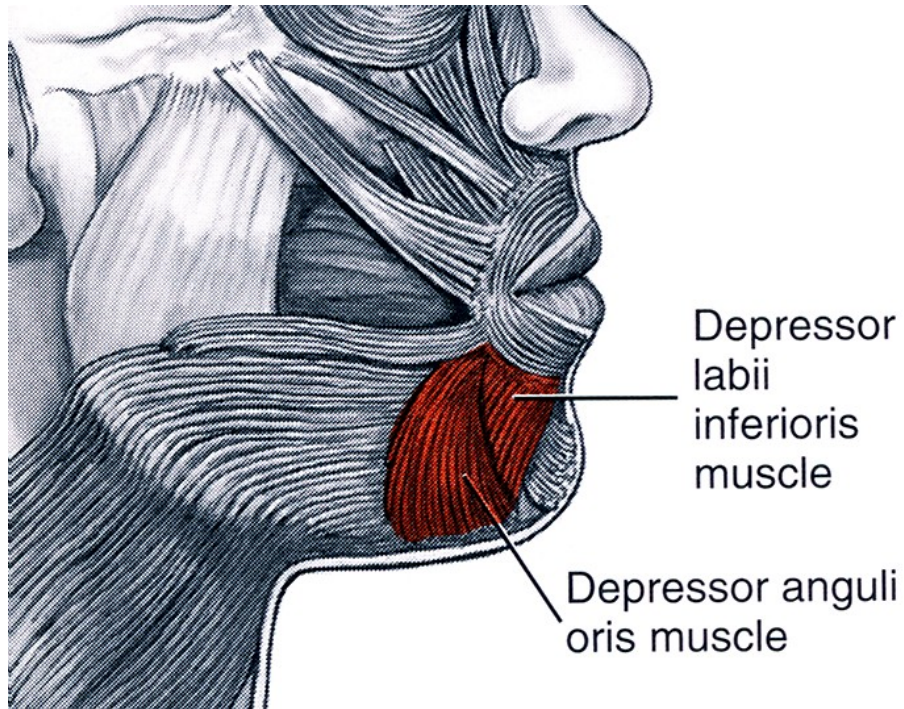
M. risorius



Risorius

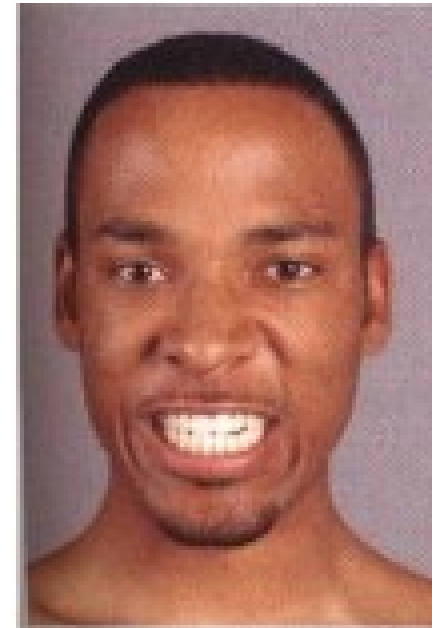
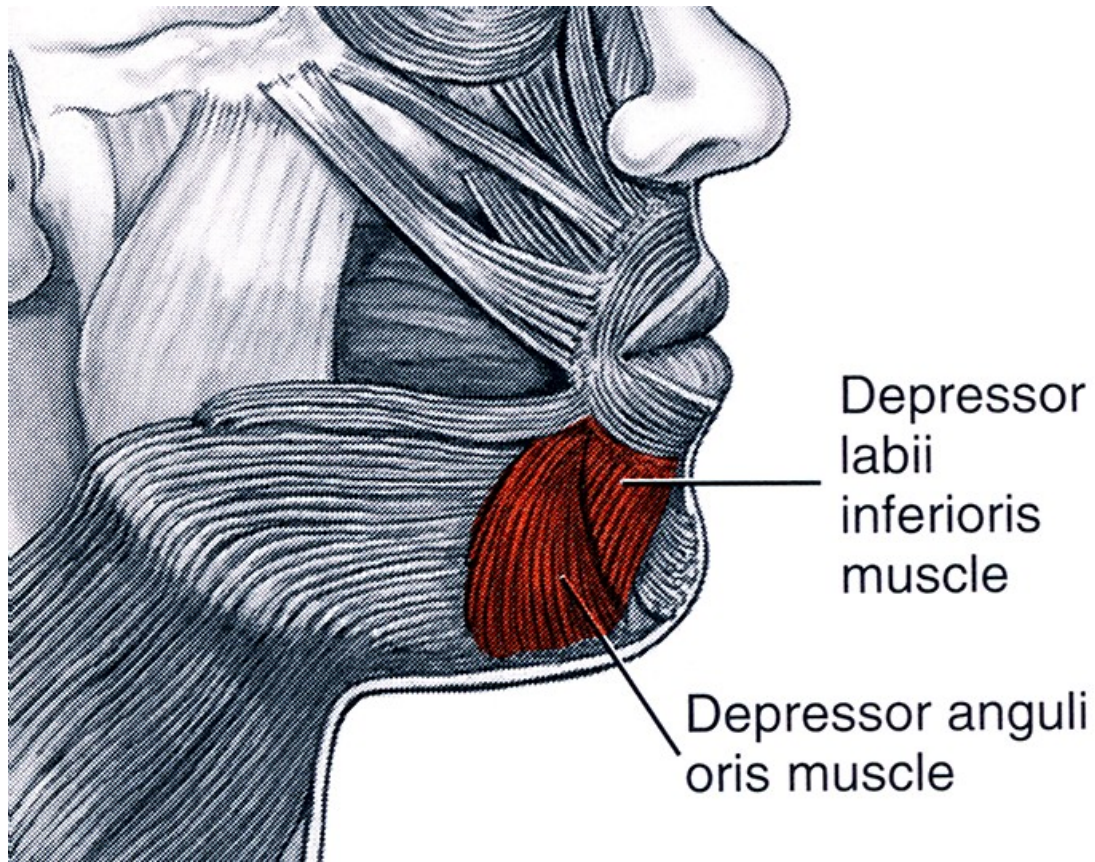
Smile widely

M. risorius, m. depressor labii inferioris



M. levator labii superioris

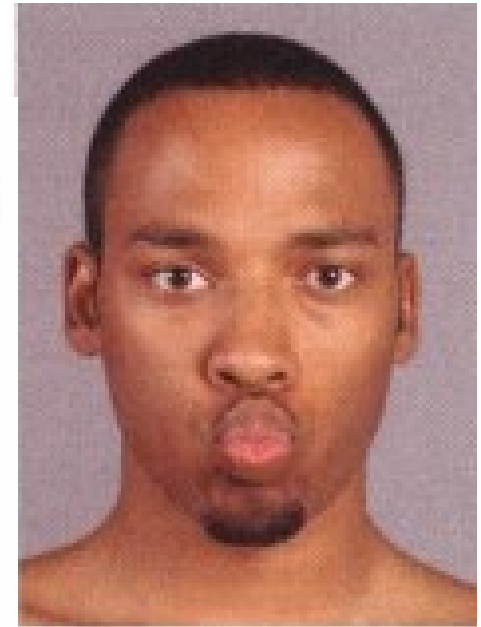
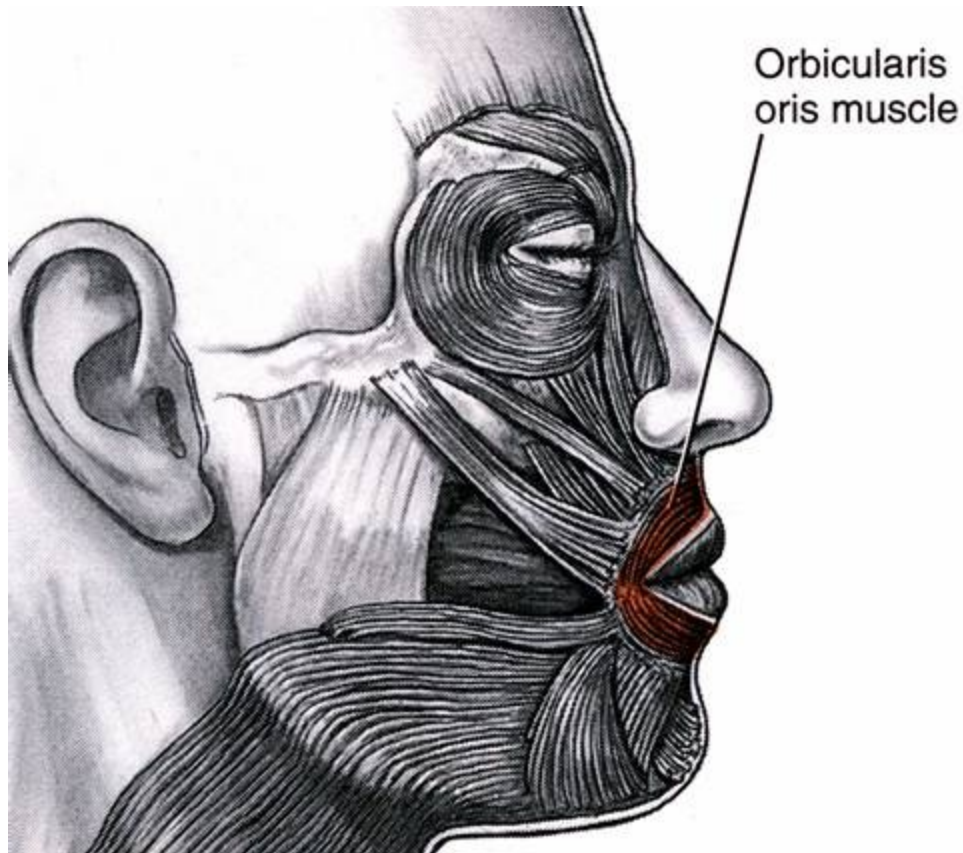
M. depressor labii inferioris



Lowers lower lip

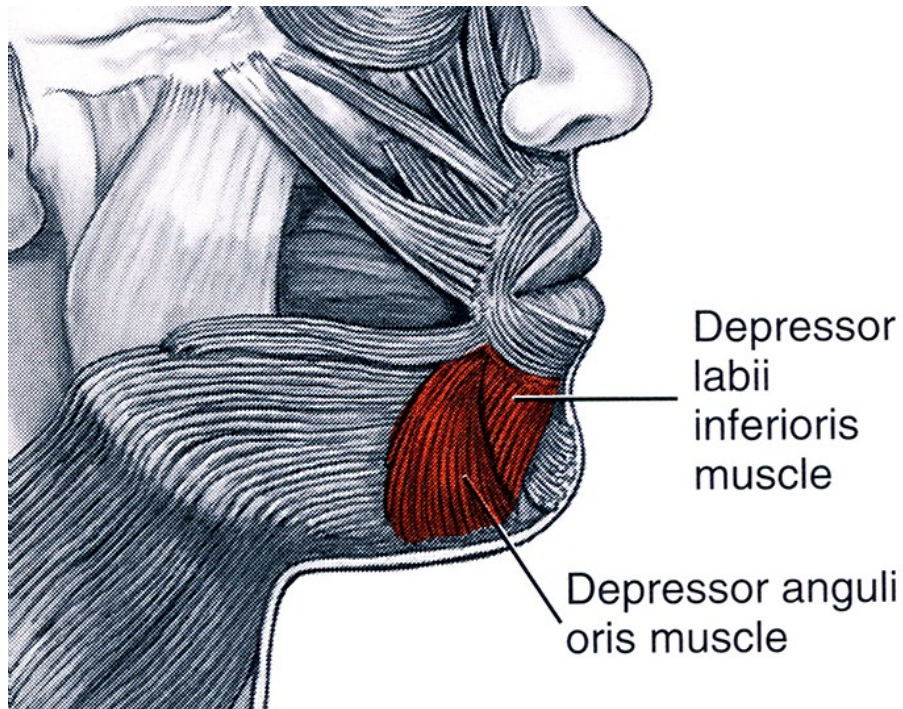
M. orbicularis oris

Closes or purses lips



Orbicularis oris

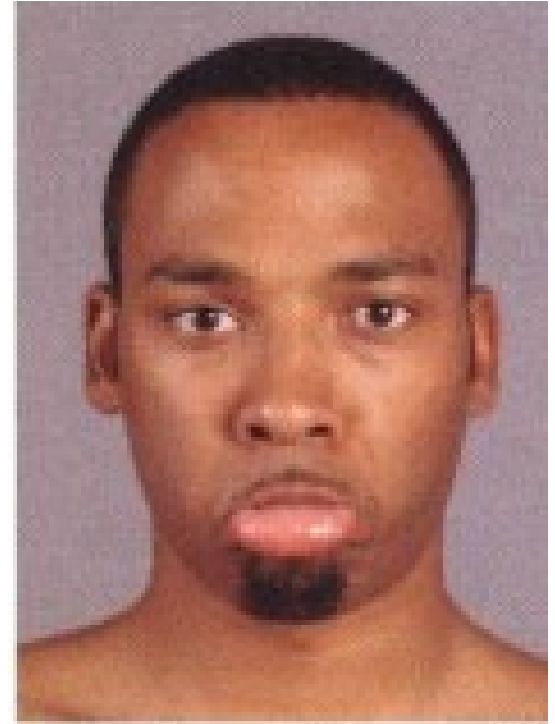
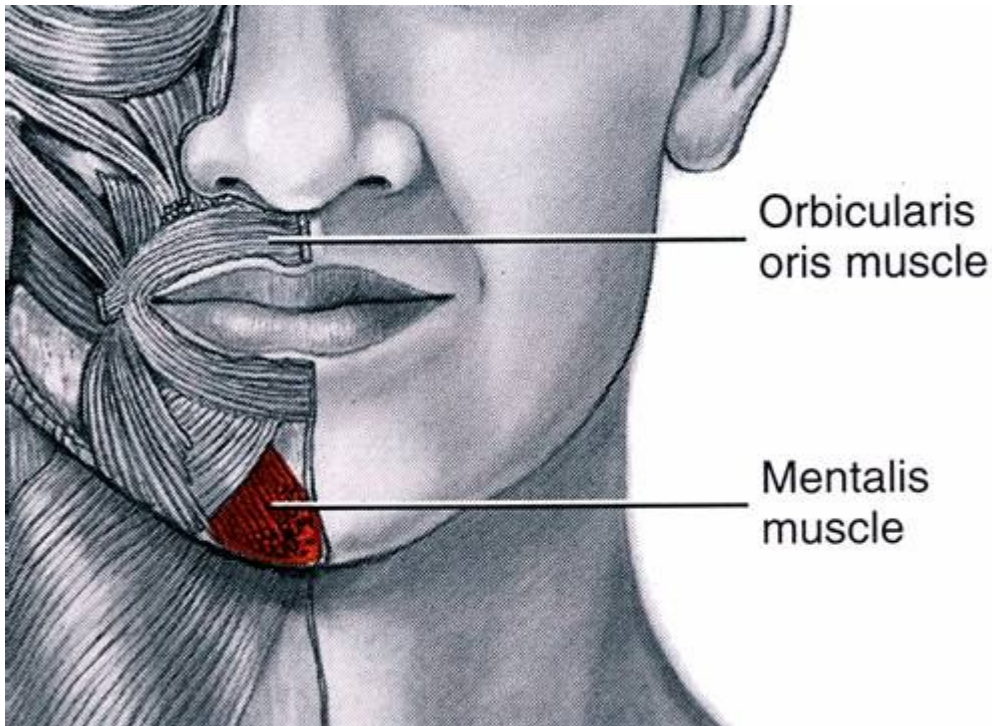
M. depressor anguli oris



Depressor anguli oris

M. mentalis

Raises chin, protrudes lower lip, and decreases depth of lower vestibule

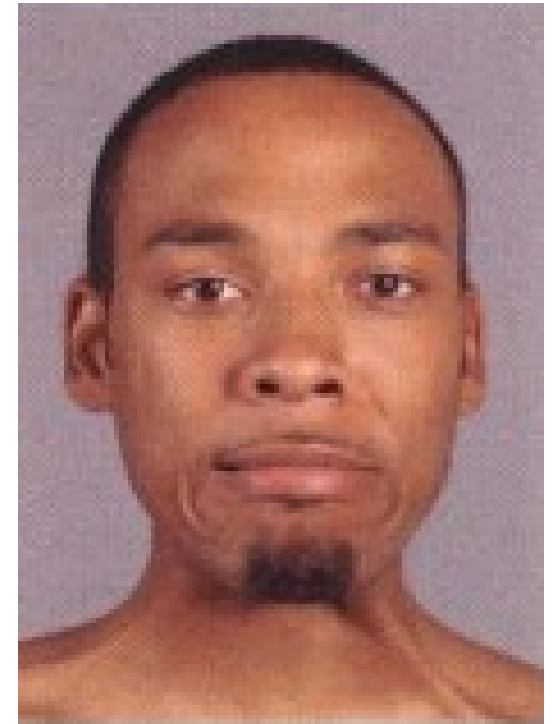
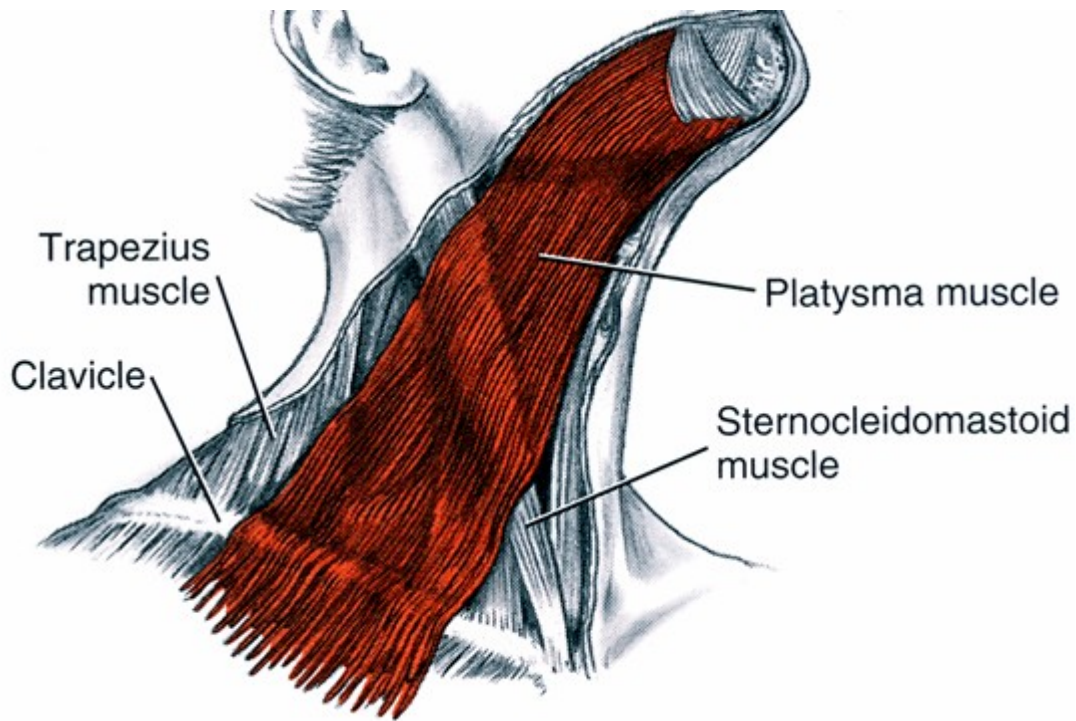


Mentalis

Neck group

- The neck group consists of the platysma
- It provides **movement of the skin of the neck**

M. platysma



Platysma

Raises skin of neck and lowers corner of mouth

Thank you for attention 😊

Surprise



Fear



Happy



Sadness



Anger



Contempt



Disgust

The Seven Universal Facial Expressions of Emotion