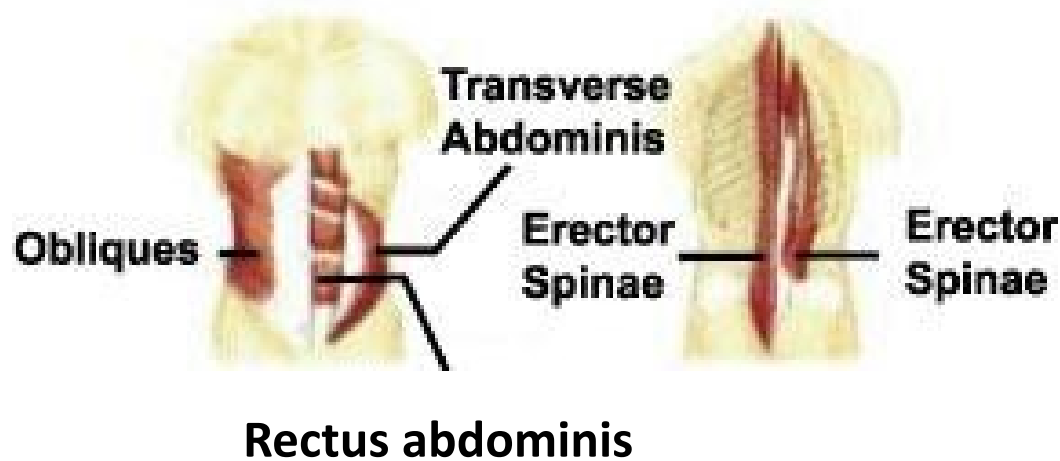


Manual muscle test: Neck, Trunk, Pelvis



Content

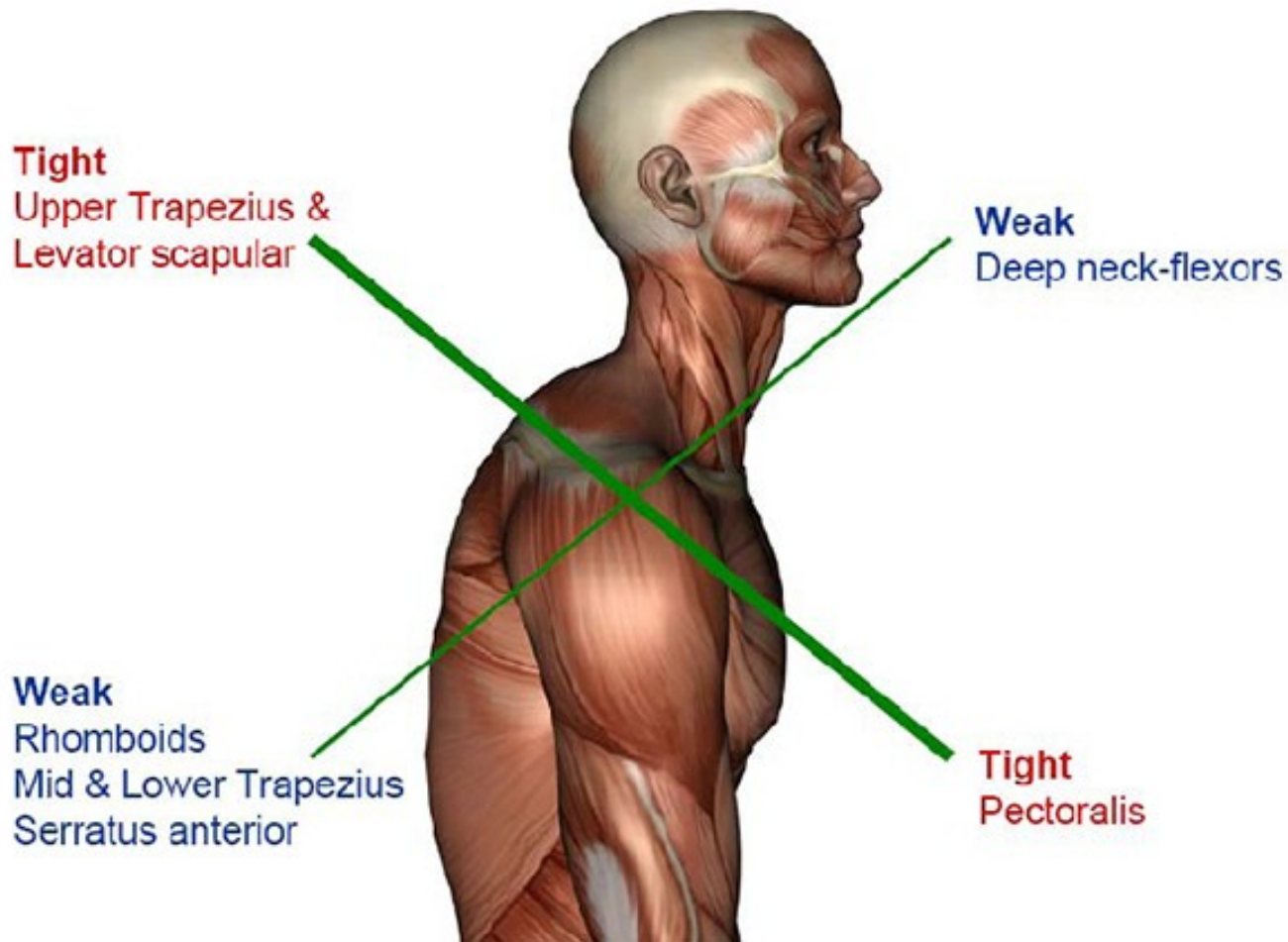
- Neck
- Back
- Abdomen
- Pelvis

Neck muscles

Possible causes of neck muscles weakness:

- Muscular imbalances (upper crossed syndrome)
- Neurological conditions (cervical dystonia, Guillain-Barré syndrome, multiple sclerosis etc.)
- Spine injuries (whiplash syndrome)
- Muscular diseases (dropped head syndrome, fibromyalgia, myasthenia gravis)
- etc.

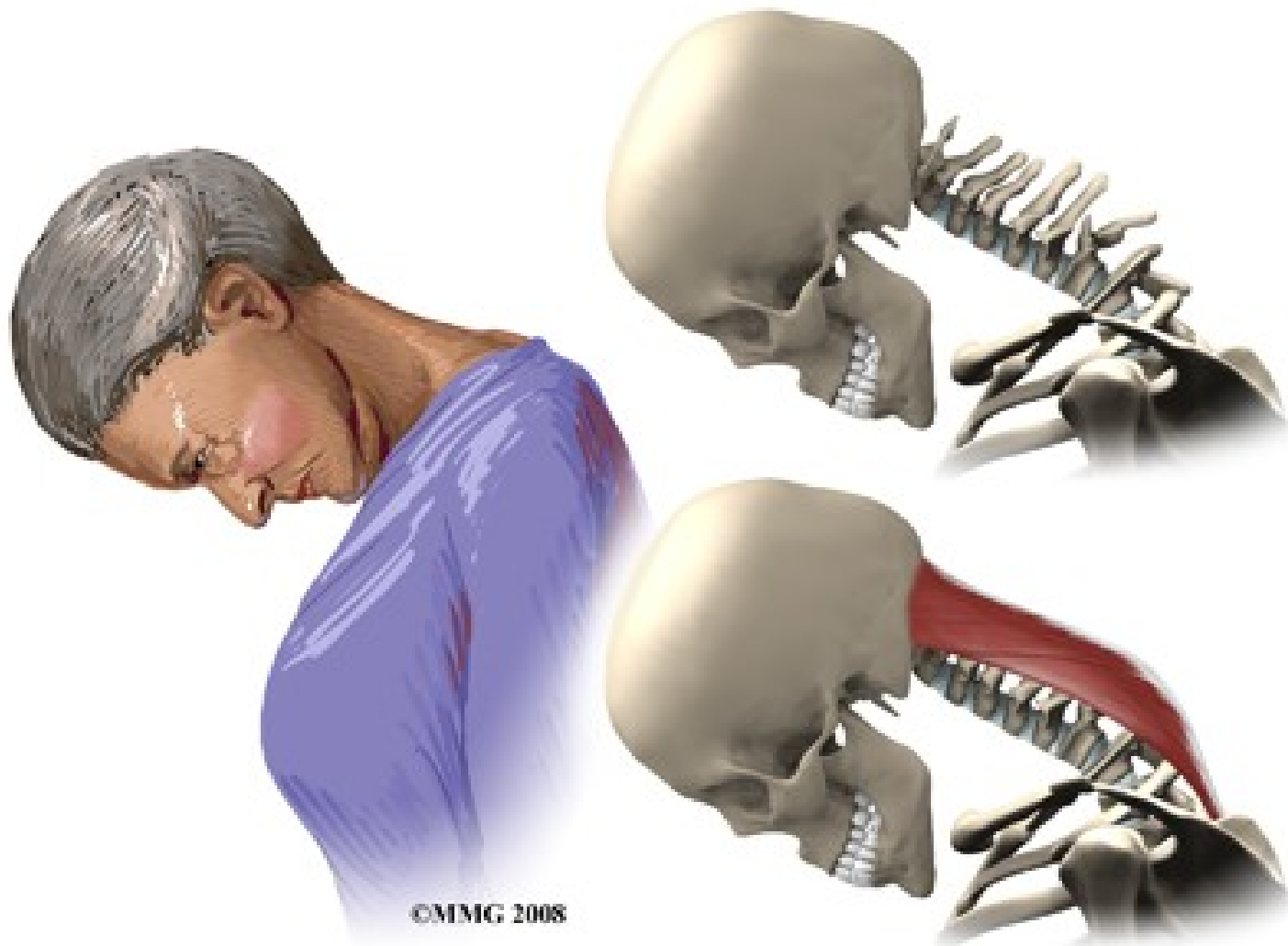
Upper crossed syndrome



Upper crossed syndrome

- impairment in the deep cervical muscles, which are considered to be functionally important for joint support and control
- deficits in muscle coordination which could result in poor support and potential overload on cervical structures
- insufficiency in the pre-programmed activation of cervical muscles
- inefficient neuromuscular activation
- greater fatigability of superficial cervical muscles

Dropped Head Syndrome

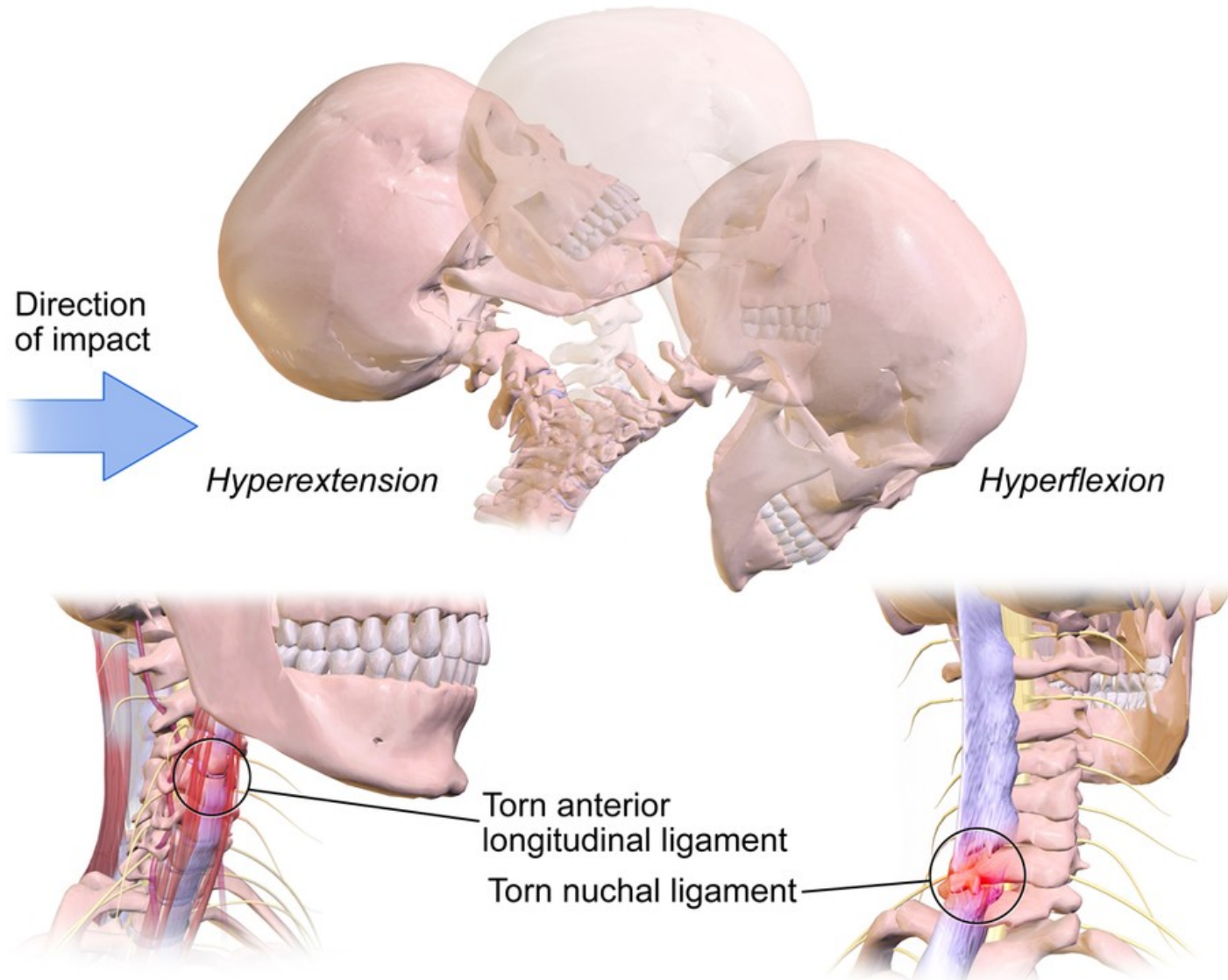


Dropped Head Syndrome

(Floppy Head Syndrome or Head Ptosis)

- is characterized by severe weakness of the muscles of the back of the neck
- this causes the chin to rest on the chest in standing or sitting
- most of the time it is caused by a specific generalized neuromuscular diagnosis
- when the cause is not known, it is called *isolated neck extensor myopathy*, or INEM

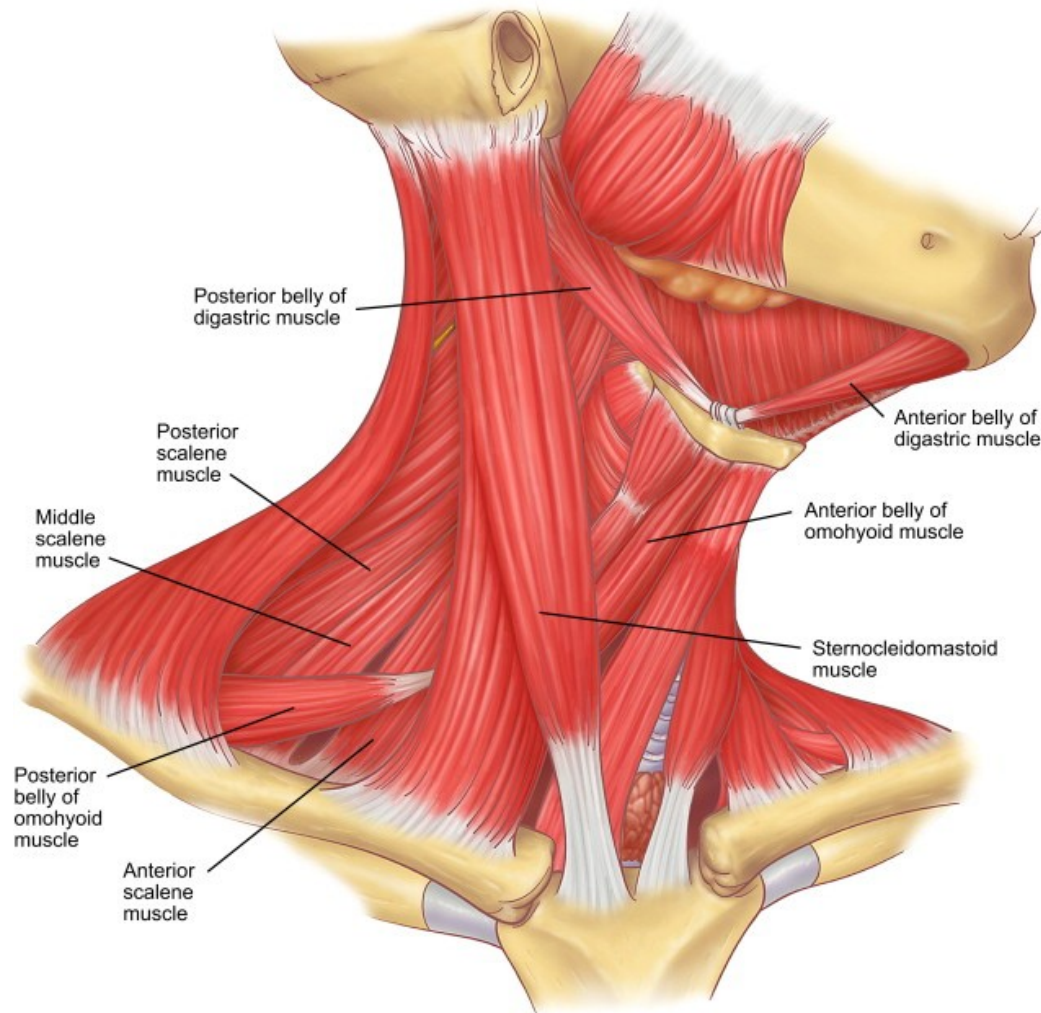
Whiplash injury



Whiplash injury

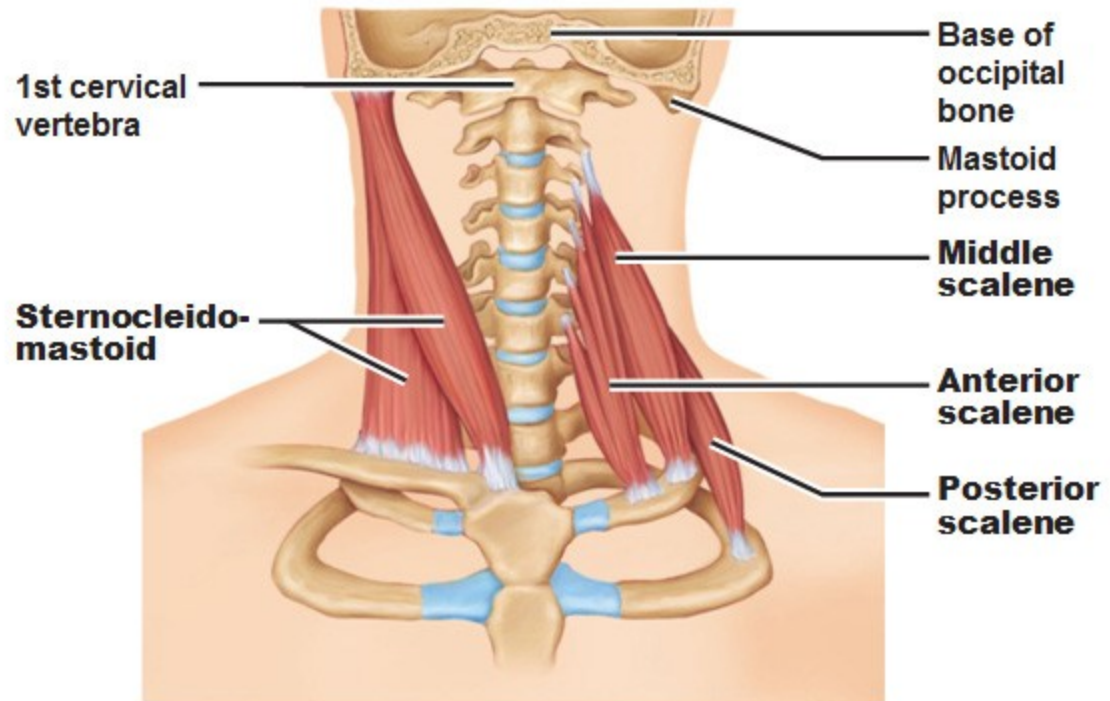
- a relatively common **injury** that occurs to a person's **neck** following a sudden acceleration-deceleration force that causes unrestrained, rapid forward and backward movement of the head and **neck**, most commonly from motor vehicle accidents
- it describes damage to both the bone structures and soft tissues

Muscles of the neck



Neck flexion (bow)

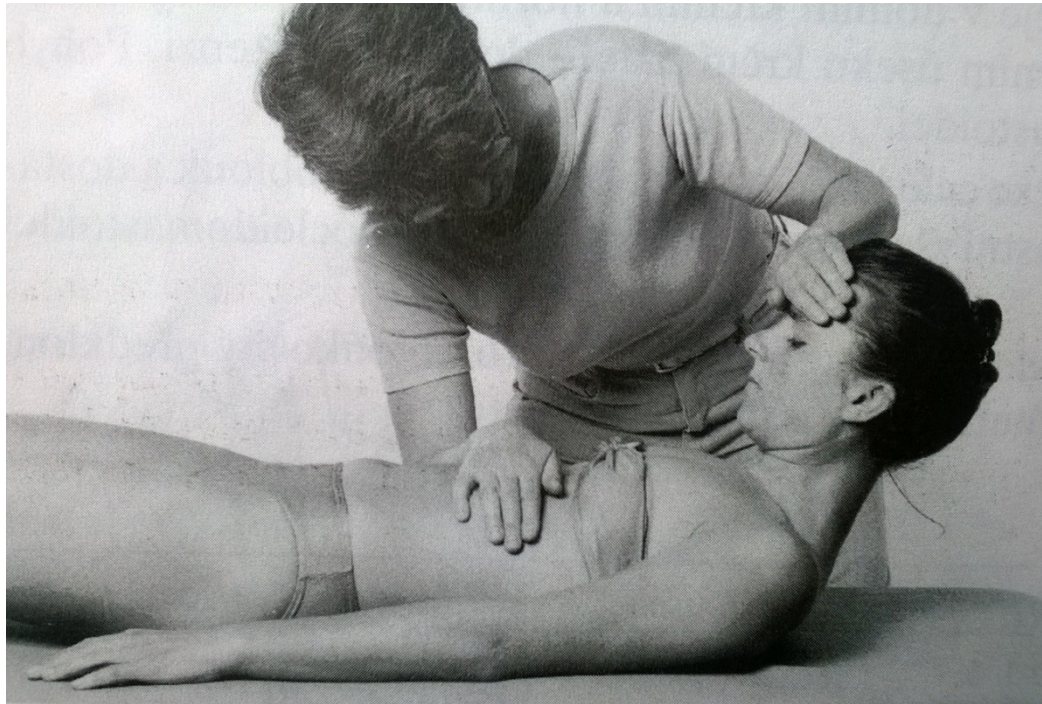- Scaleni muscles (ant., med., post.)
- Sternocleidomastoid
- M. longus colli, m. longus capitis



(a) Anterior

Neck flexion (bow)

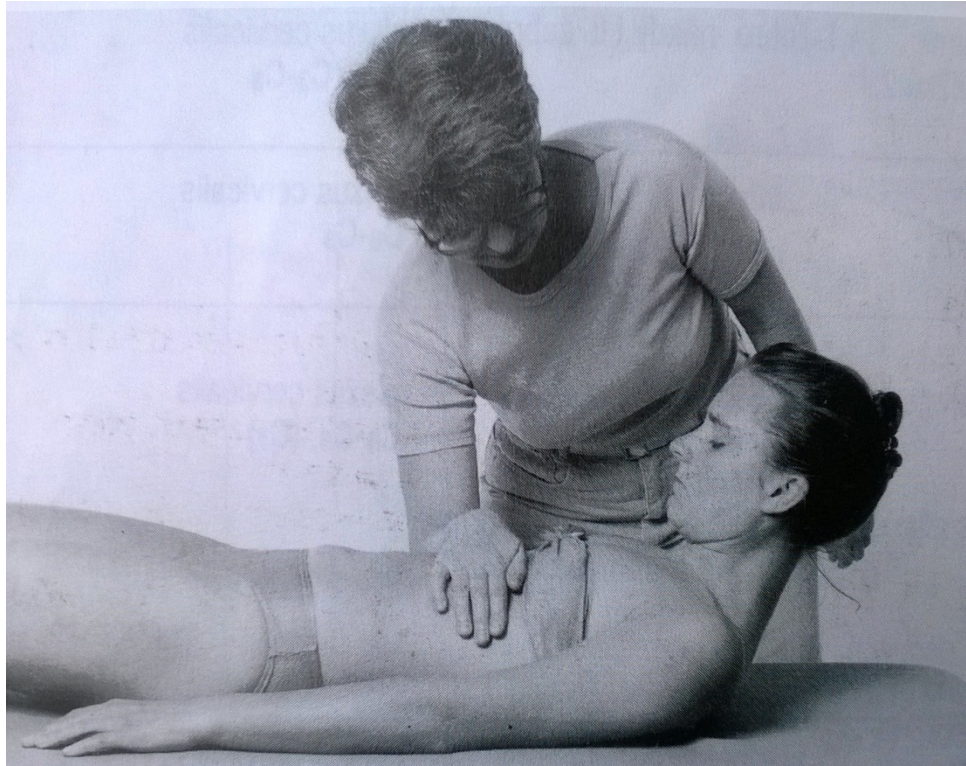
Grade 5,4



- Position: supine position, lower limbs slightly bended, upper limbs relaxed, lying along the body side
- Fixation: PT fix the patients lower part of the chest with one hand
- Movement: fluent flexion of the neck spine (bow)
- Resistance: PT put resistance using one hand on the patients' forehead (arched) against the movement

Neck flexion (bow)

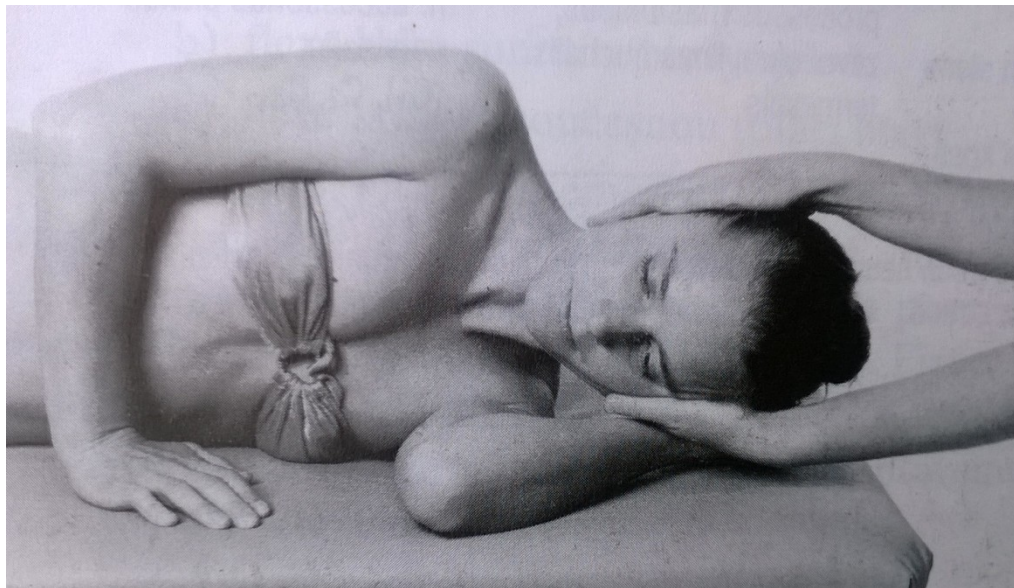
Grade 3



- Position: supine position, lower limbs slightly bended, upper limbs relaxed, lying along the body side
- Fixation: PT fix the patients lower part of the chest with one hand
- Movement: fluent flexion of the neck spine (bow)

Neck flexion (bow)

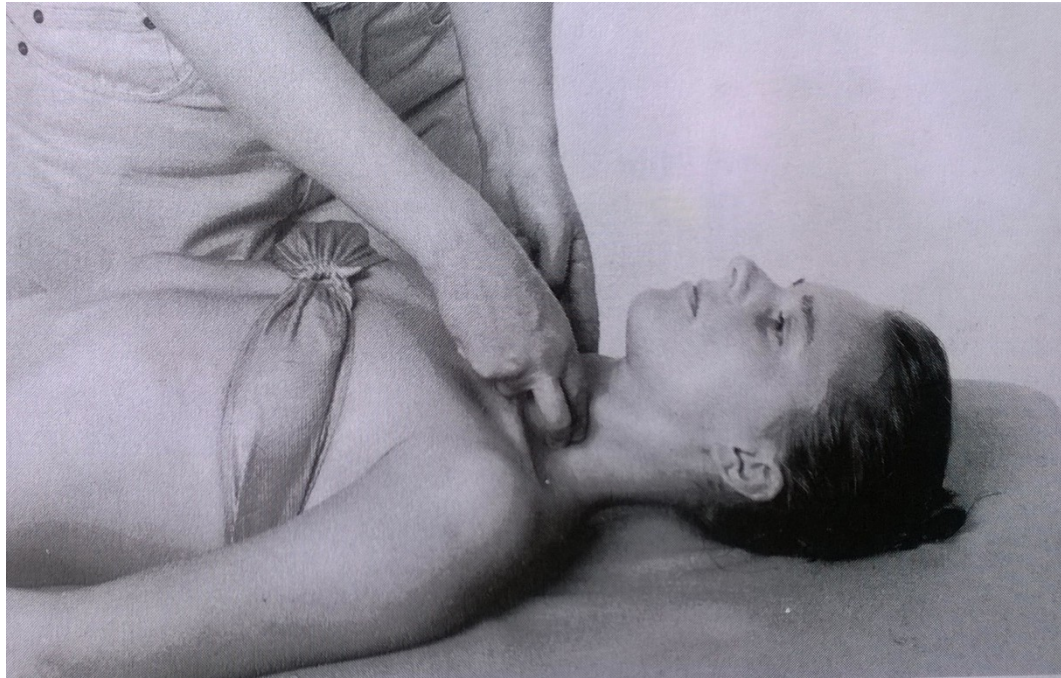
Grade 2



- Position: lying on the side, patient hold with his/her upper hand the table, the lower hand is relaxed, lying in flexed position below the patients' head
- Fixation: PT supports patients head, in central position
- Movement: patient flexes the neck spine in full range of motion, with constant support of PT

Neck flexion (bow)

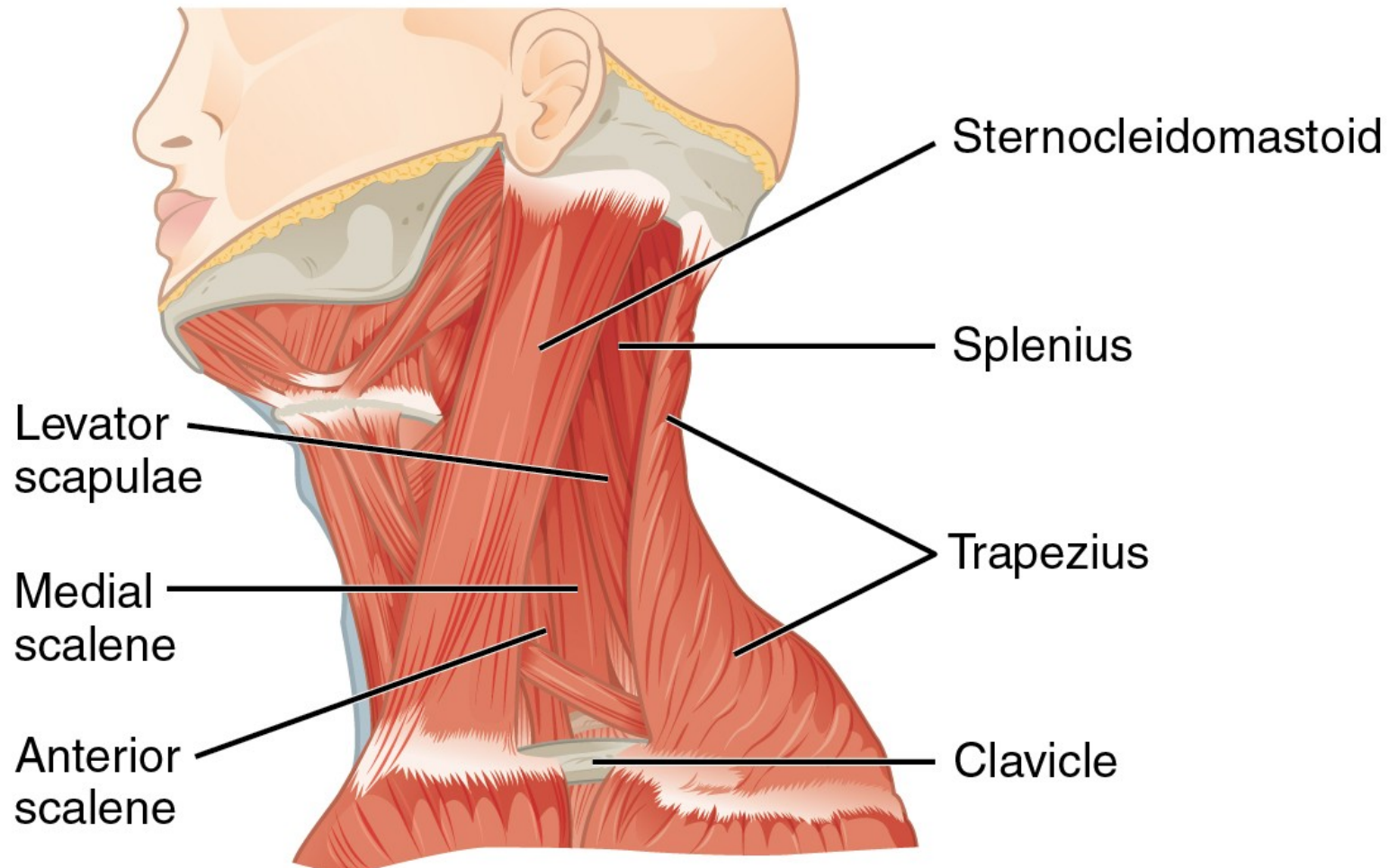
Grade 1,0



- Position: supine position, lower limbs slightly bended, upper limbs relaxed, lying along the body side
- Attempt to move: patient tries to elevate the head, PT palpates the trace of contraction of the neck flexors

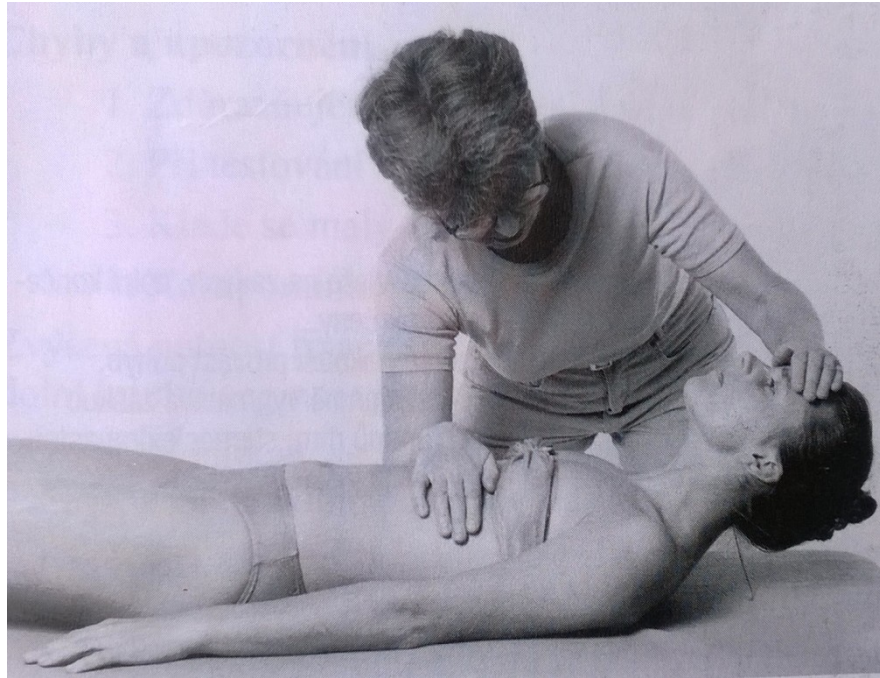
Neck flexion (move forward)

Sternocleidomastoid muscle



Neck flexion (move forward)

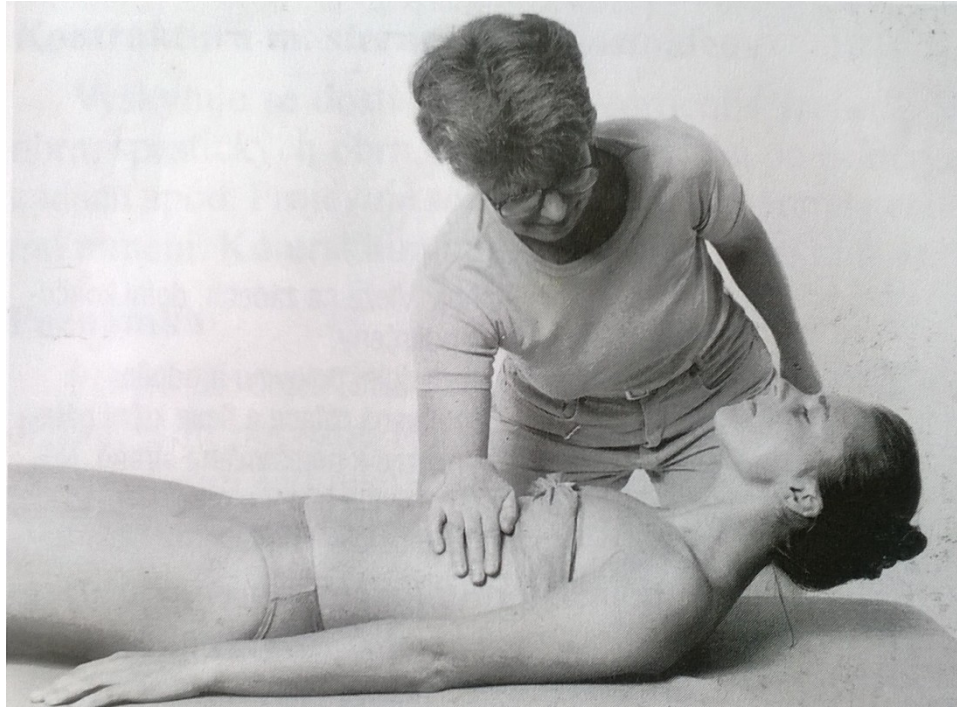
Grade 5,4



- Position: supine position, lower limbs slightly bended, upper limbs relaxed, lying along the body side
- Fixation: PT fix the patients lower part of the chest with one hand
- Movement: flexion of the neck spine – moving the head forward
- Resistance: PT put resistance using one hand on the patients' forehead against the movement

Neck flexion (move forward)

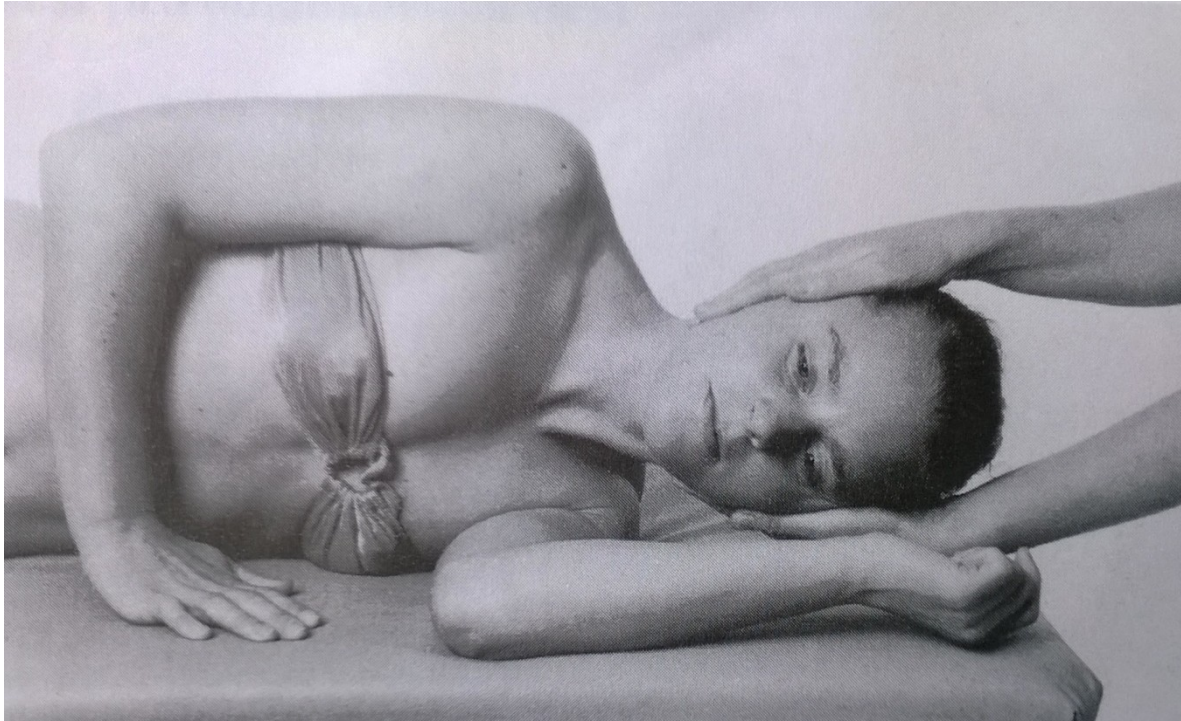
Grade 3



- Position: supine position, lower limbs slightly bended, upper limbs relaxed, lying along the body side
- Fixation: PT fix the patients lower part of the chest with one hand
- Movement: flexion of the neck spine – moving the head forward

Neck flexion (move forward)

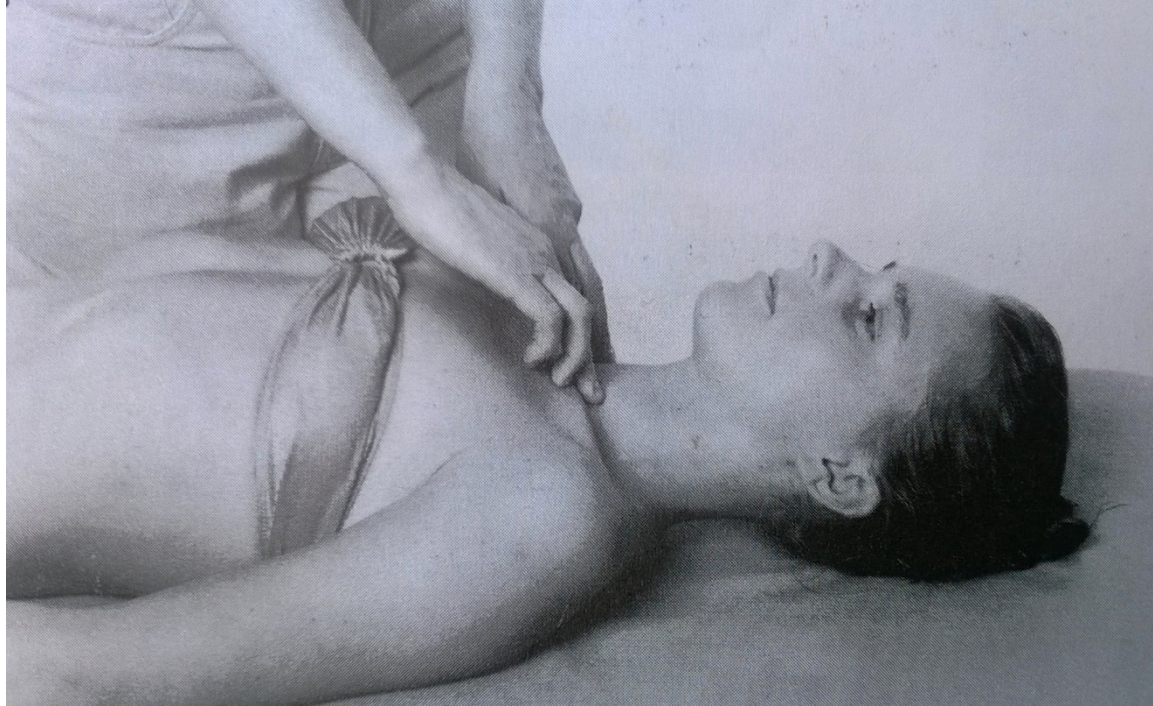Grade 2



- Position: lying on the side, patient hold with his/her upper hand the table, the lower hand is relaxed, lying in flexed position below the patients' head
- Fixation: PT supports patients head, in central position
- Movement: patient flexes the neck spine in full range of motion, moving the head forward, with constant support of PT

Neck flexion (move forward)

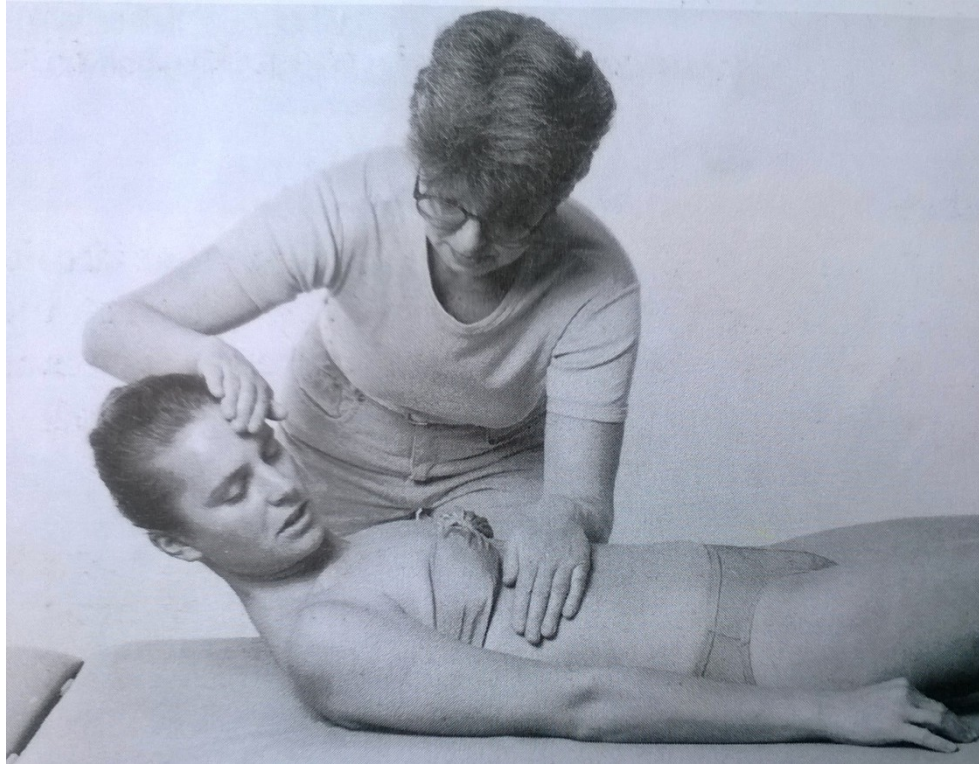Grade 1,0



- Position: supine position, lower limbs slightly bended, upper limbs relaxed, lying along the body side
- Attempt to move: patient tries to elevate the head, PT palpates the trace of contraction of the sternocleidomastoideid

Neck flexion – unilateral test

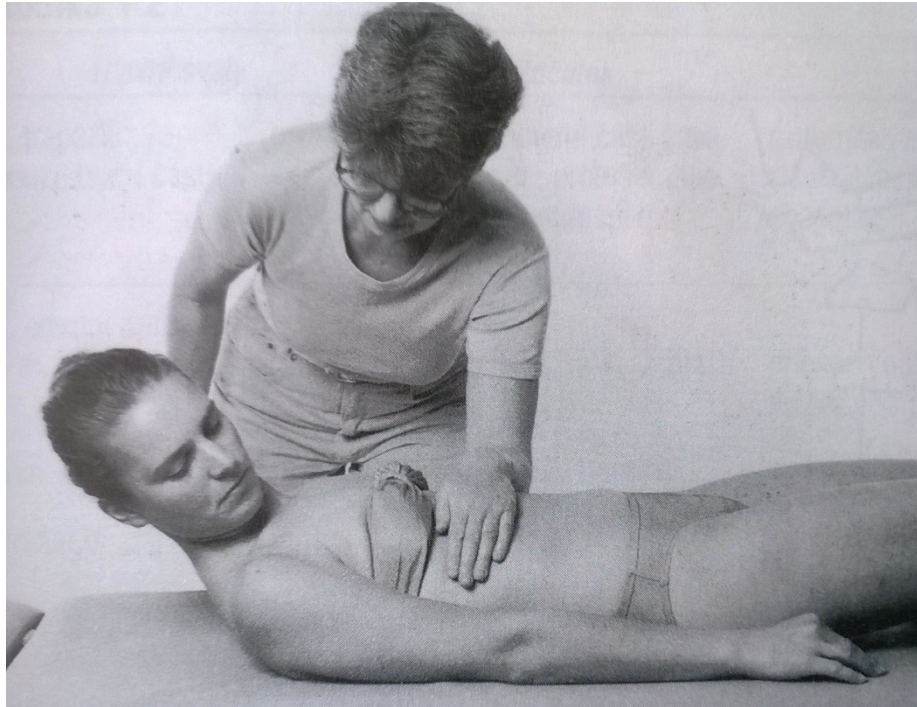Grade 5,4



- Position: supine position, lower limbs slightly bended, upper limbs relaxed, lying along the body side
- Fixation: PT fix the patients lower part of the chest with one hand
- Movement: flexion of the neck spine combined with rotation to the untested side
- Resistance: PT put resistance using one hand on the patients' lateral part of the forehead (on the tested side)

Neck flexion – unilateral test

Grade 3



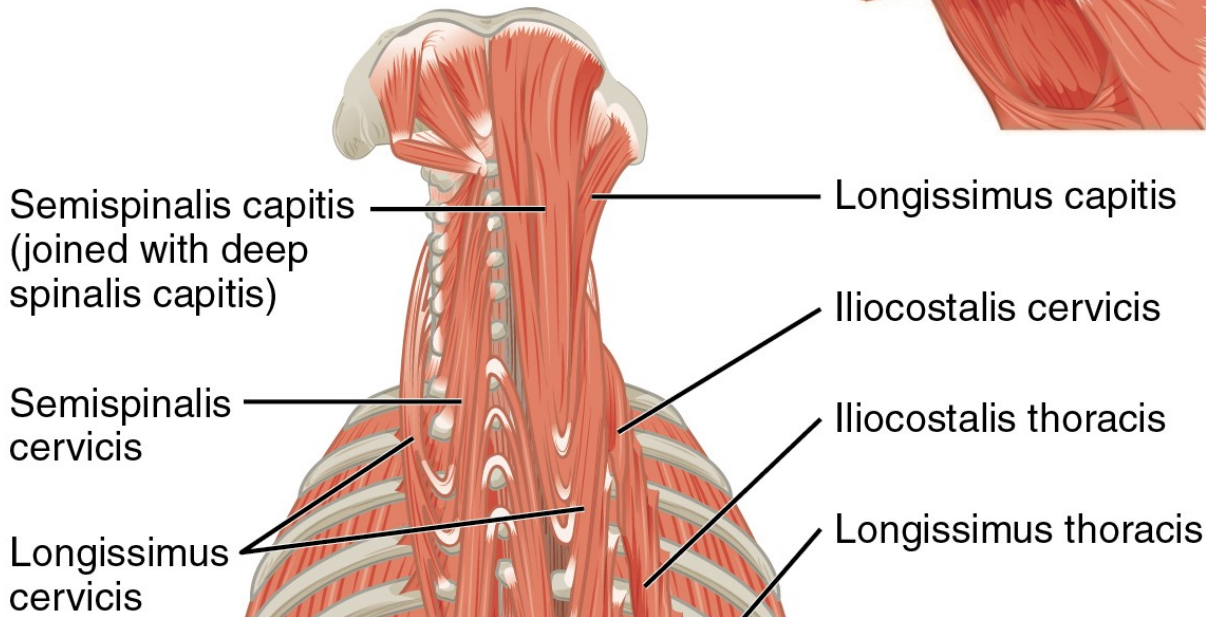
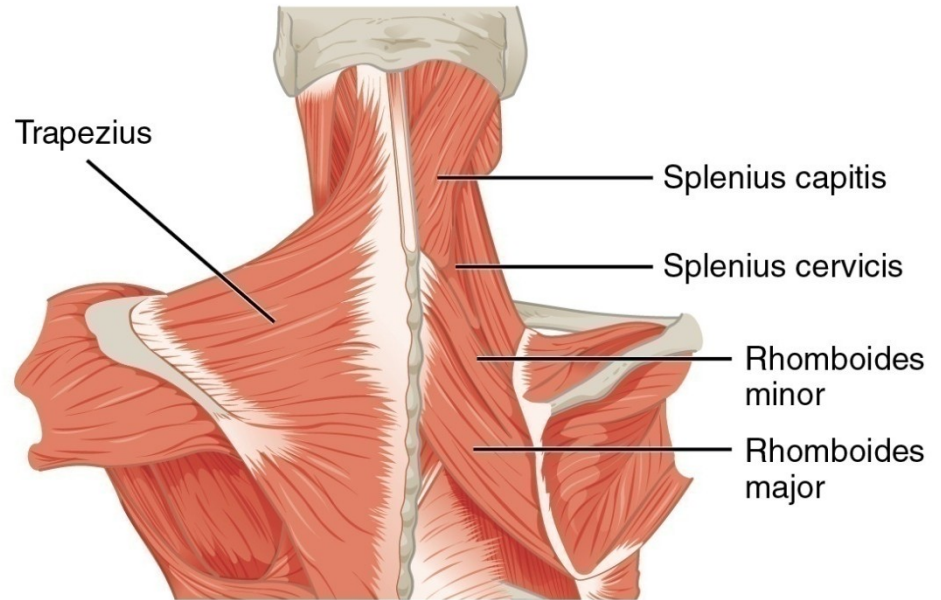
- Position: supine position, lower limbs slightly bended, upper limbs relaxed, lying along the body side
- Fixation: PT fix the patients lower part of the chest with one hand
- Movement: flexion of the neck spine combined with rotation to the untested side
- Note: grade 2, 1, 0 is not tested

Neck flexion – notes:

- The movement should be done fluently, no rotation to the side, no assistance of the arms of patient
- During one-side testing – do the movement in combination of flexion and rotation
- The fixation of the trunk, especially when the neck flexors are weak, is necessary
- Contracture, usually of the SCM, is relatively common – rotation and inclination of the head is typical
- Spasm of the scaleni muscles can be sometimes found

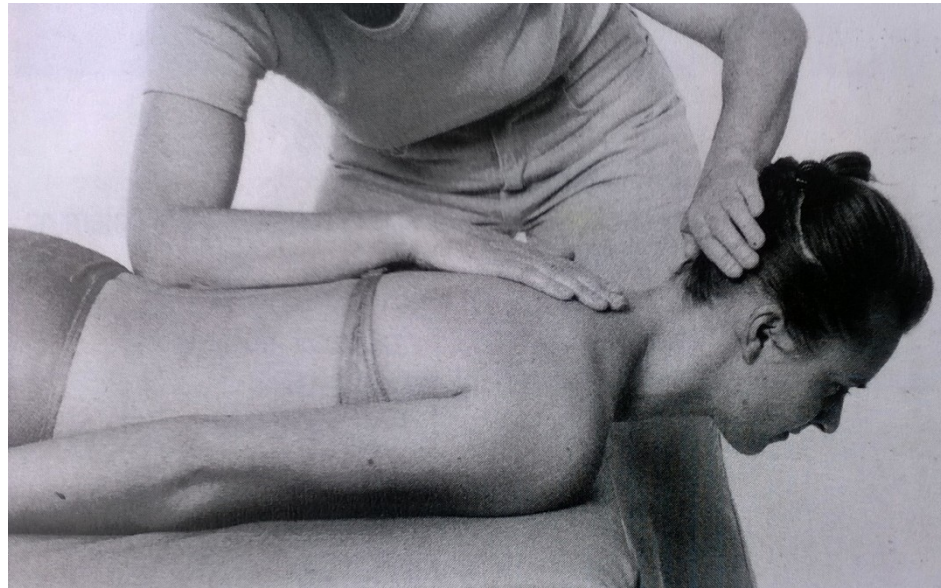Neck extension

- Trapezius
- Iliocostalis cervicis
- Longissimus capitis et cervicis
- Spinalis capitis et cervicis



Neck extension

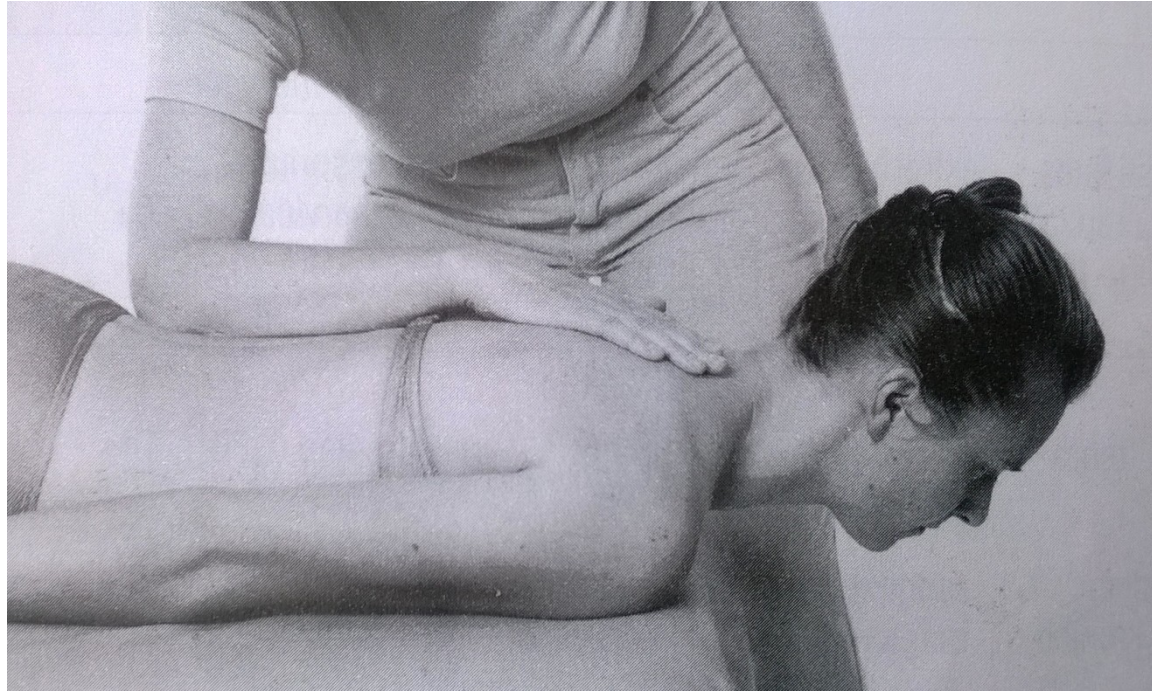Grade 5,4



- Position: prone position, upper limbs lying relaxed along the body side, the head away from the table, neck spine fully flexed
- Fixation: PT uses the whole forearm and palm to fix the thoracal part of the spine
- Movement: fluent extension of the neck in full range of motion
- Resistance: PT put resistance with the palm at the back of the patients' head

Neck extension

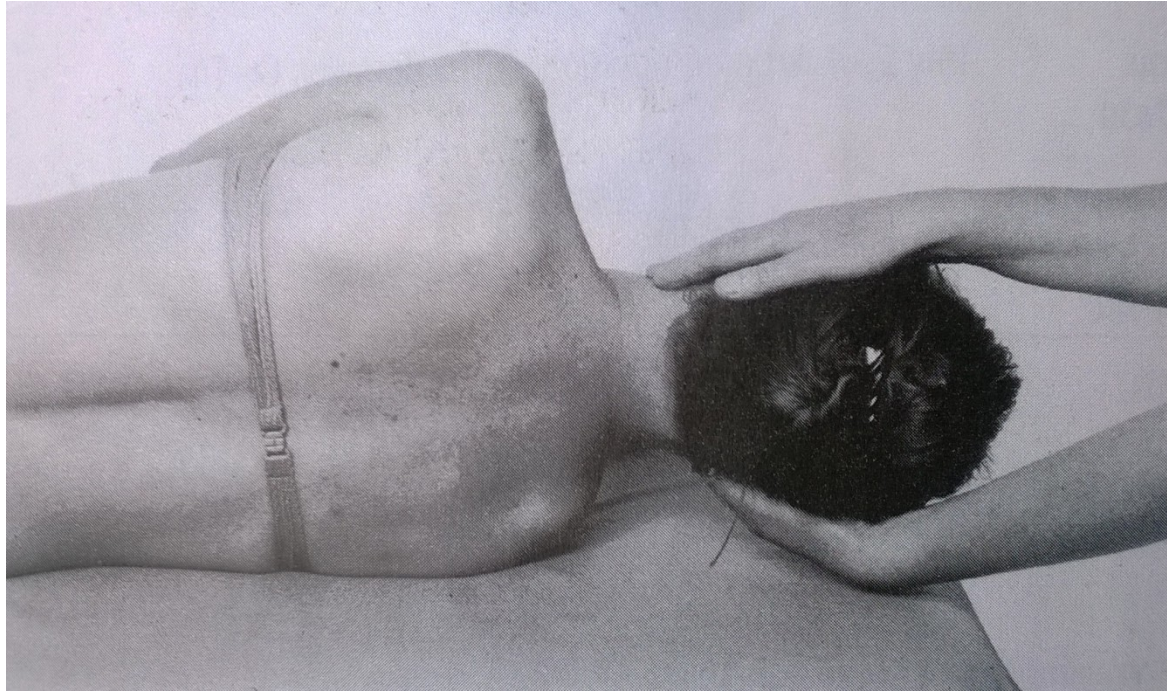
Grade 3



- Position: prone position, upper limbs lying relaxed along the body side, the head away from the table, neck spine fully flexed
- Fixation: PT uses the whole forearm and palm to fix the thoracical part of the spine
- Movement: fluent extension of the neck in full range of motion

Neck extension

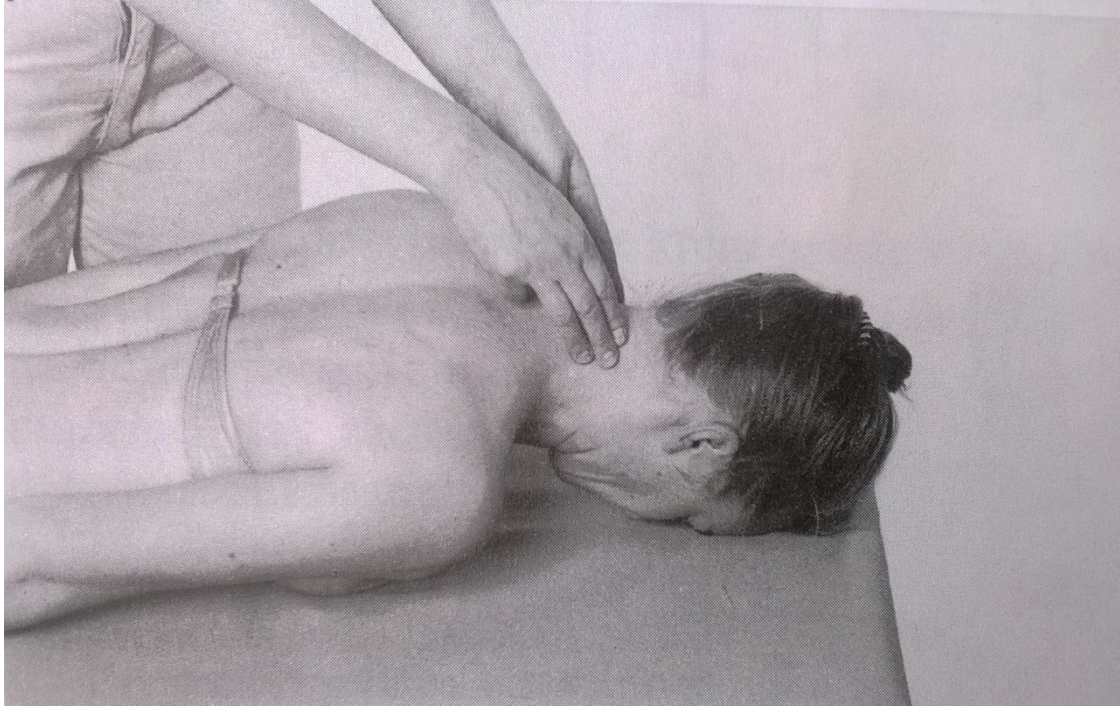Grade 2



- Position: lying on the side, patient hold with his/her upper hand the edge of the table, the lower hand is relaxed, lying in flexed position, neck spine in full flexion
- Fixation: PT supports patients head, in central position
- Movement: patient extends the neck spine in full range of motion, with constant support of PT

Neck extension

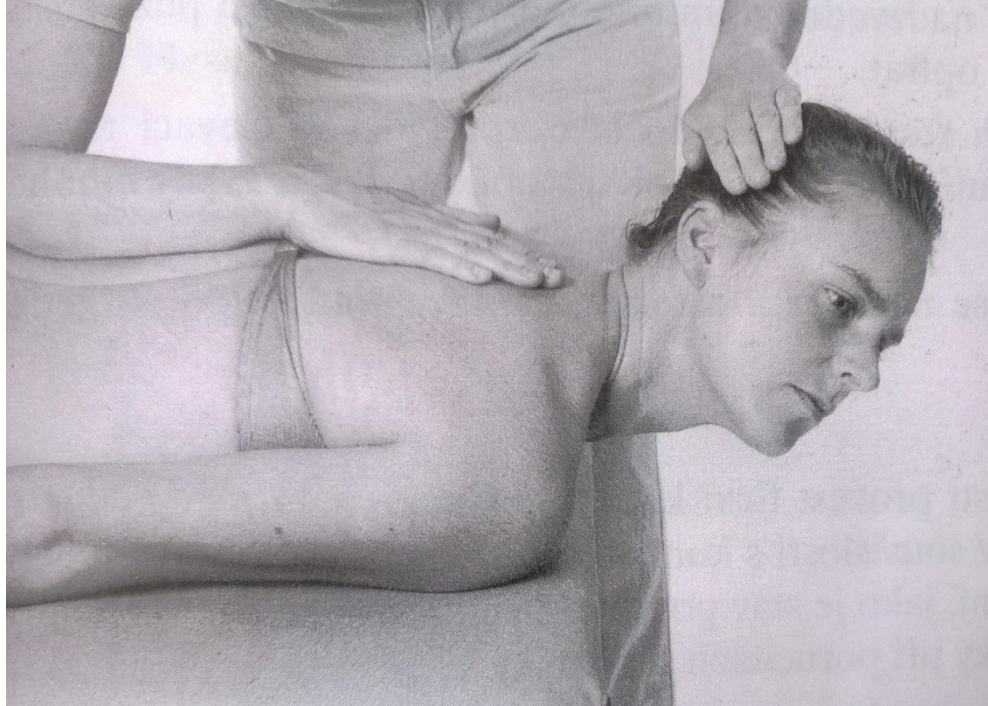
Grade 1,0



- Position: prone lying, head on the table, upper limbs extended, lying relaxed along the body side
- Attempt to move: patient tries to elevate the head, PT palpates the trace of contraction of the extensors

Neck extension – unilateral test

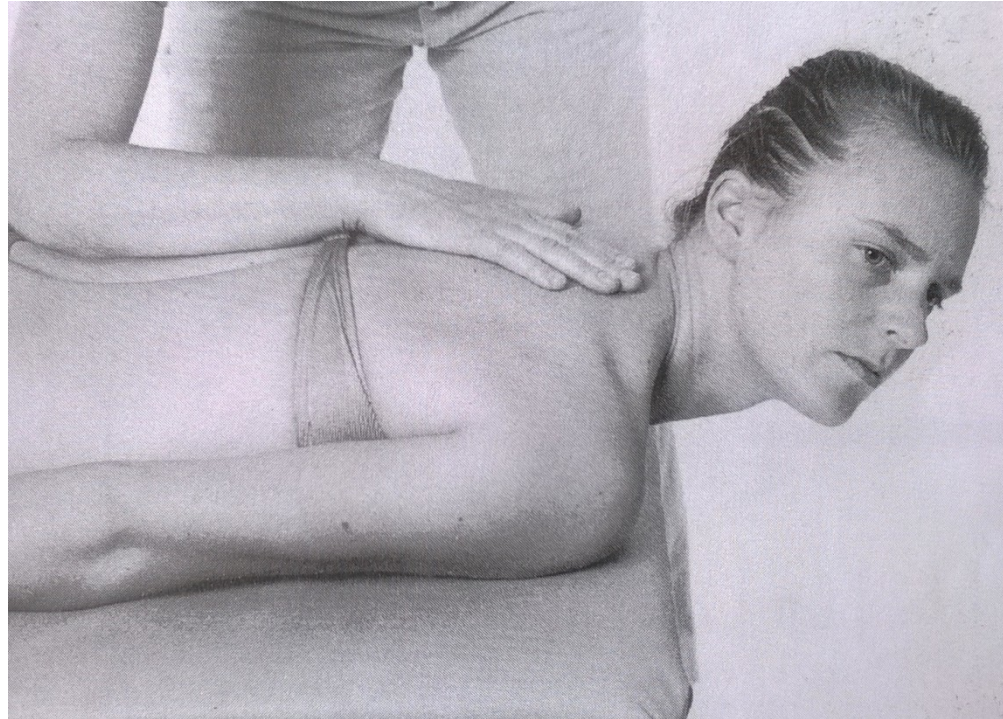
Grade 5,4



- Position: prone position, upper limbs lying relaxed along the body side, the head away from the table, neck spine fully flexed, and rotated to the side
- Fixation: PT uses the whole forearm and palm to fix the thoracical part of the spine
- Movement: fluent extension of the neck in full range of motion, when the neck spine is rotated to the tested side
- Resistance: PT put resistance with the palm at the lateral side of the patients' head

Neck extension – unilateral test

Grade 3

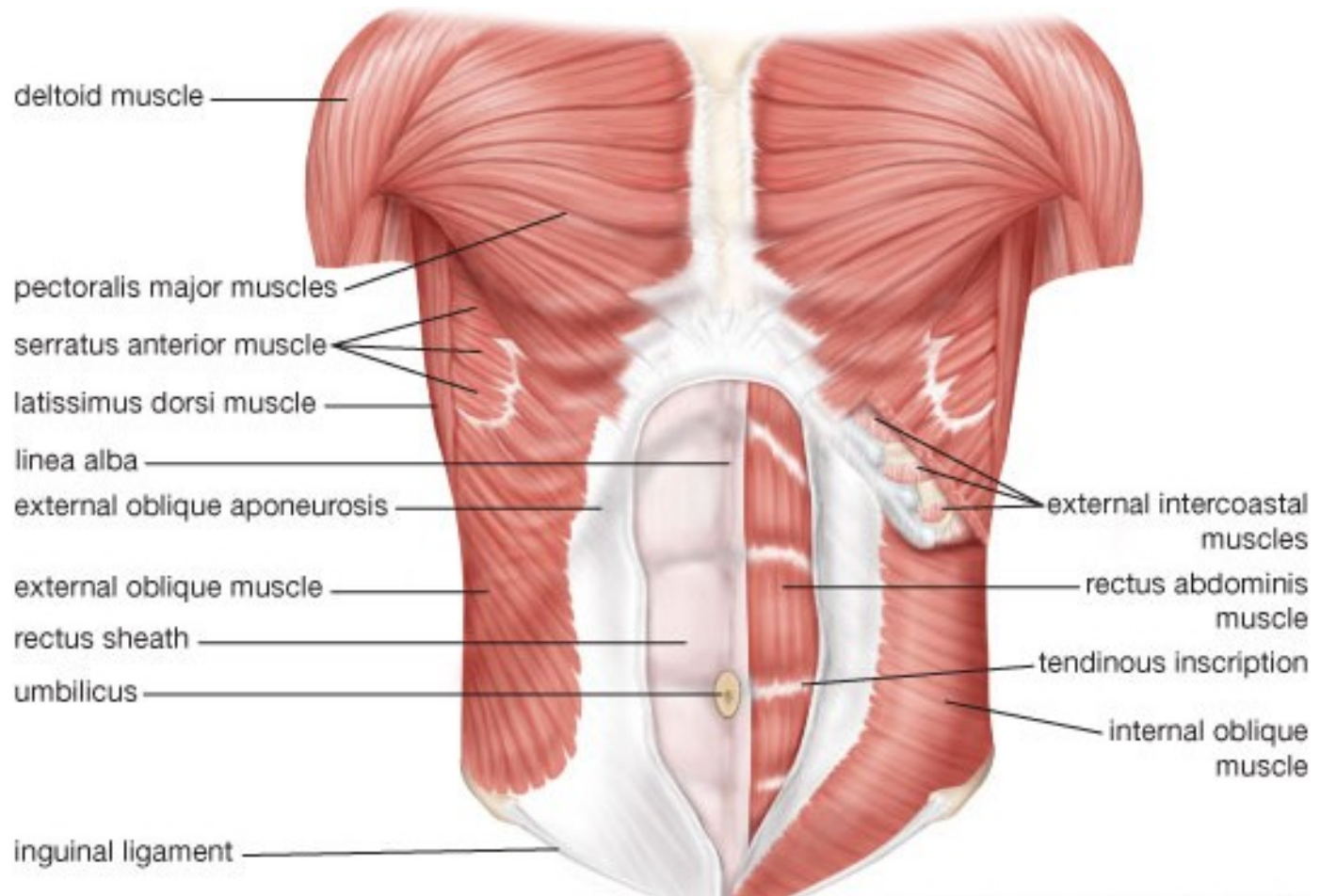


- Position: prone position, upper limbs lying relaxed along the body side, the head away from the table, neck spine fully flexed, and rotated to the side
- Fixation: PT uses the whole forearm and palm to fix the thoracal part of the spine
- Movement: fluent extension of the neck in full range of motion, when the neck spine is rotated to the tested side

Neck extension – notes:

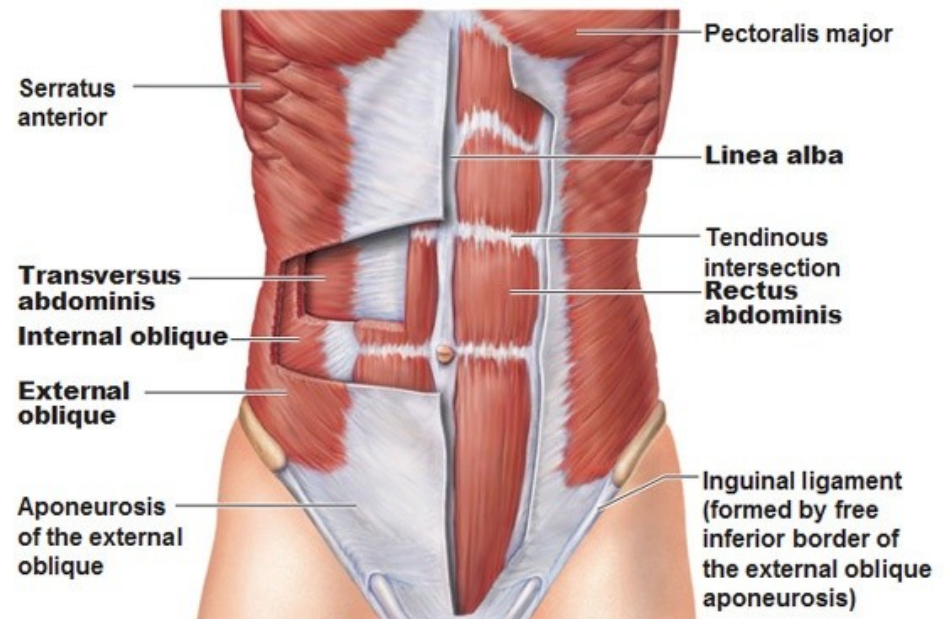
- A lot of substitutions can occur during neck extension: don't allow the patient to use the muscles of the scapula and the arm (abduction of scapula, elevation of shoulders)
- If the contracture of neck extensors is present, patient is not able to do flexion of the neck in full range of motion

Muscles of the abdominal wall



Abdominal muscles

- any of the muscles of the anterolateral wall of the [abdominal cavity](#)
- composed of 3 flat muscular sheets, from without inward:
 - external oblique
 - internal oblique
 - transverse abdominis
 - rectus abdominis



Abdominal muscles

- The first 3 muscle layers extend between the vertebral column behind, the lower ribs above, and the iliac crest and pubis of the hip bone below
- Their fibres all merge toward the midline, where they surround the rectus abdominis in a sheath before they meet the fibres from the opposite side at the linea alba
- Strength is developed in these rather thin walls by the crisscrossing of fibres
- Thus, the fibres of the external oblique are directed downward and forward, those of the internal oblique upward and forward, and those of the transverse horizontally forward

Abdominal muscles – function:

The muscles of the abdominal wall perform a variety of **functions**:

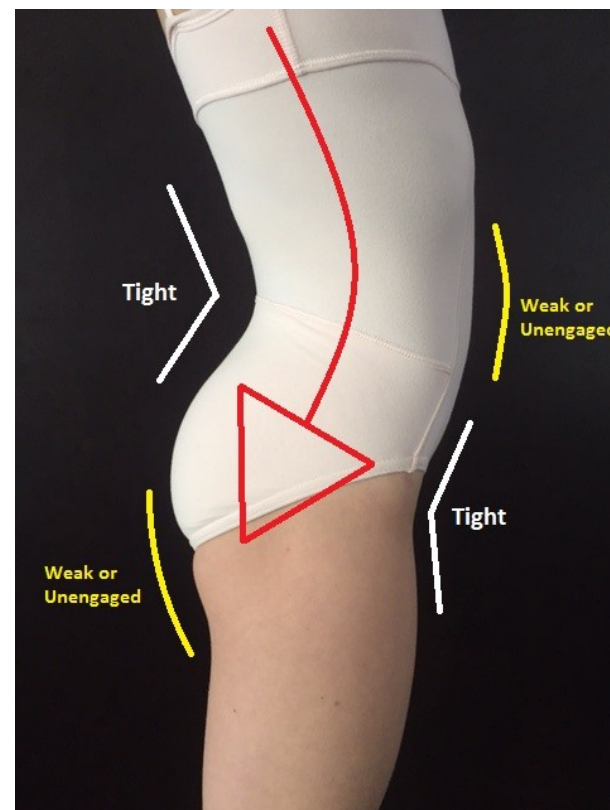
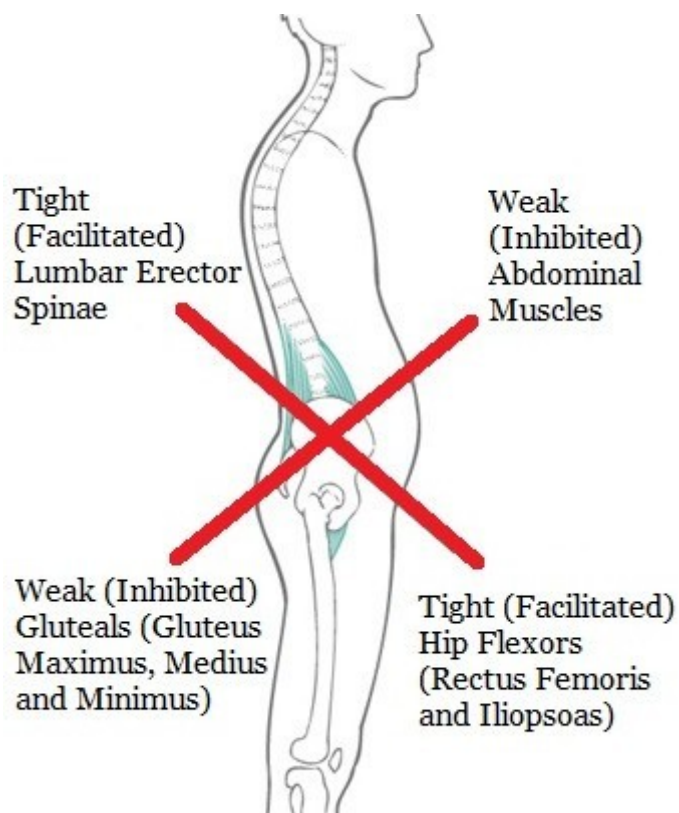
- (1) provide a tonic, elastic **muscular support for the viscera** and, by their recoil, **pull down the rib cage in expiration**
- (2) They contract against blows to form a rigid protective wall for the viscera
- (3) When the glottis is closed and the thorax and pelvis are fixed, these muscles **take part in the expulsive efforts** of urination, defecation, childbirth, vomiting, and of singing and coughing
- (4) When the pelvis is fixed, they initiate the movement of **bending the trunk forward**. Thereafter, gravity comes into play, the abdominal muscles relax, and the muscles of the back then take on the strain
- (5) Conversely, the abdominal muscles come into play in **preventing hyperextension**
- (6) When the thorax is fixed, the abdominals can **pull up the pelvis** and lower limbs
- (7) The muscles of one side can **bend the vertebral column sideways and assist in its rotation**.

Abdominal muscles weakness

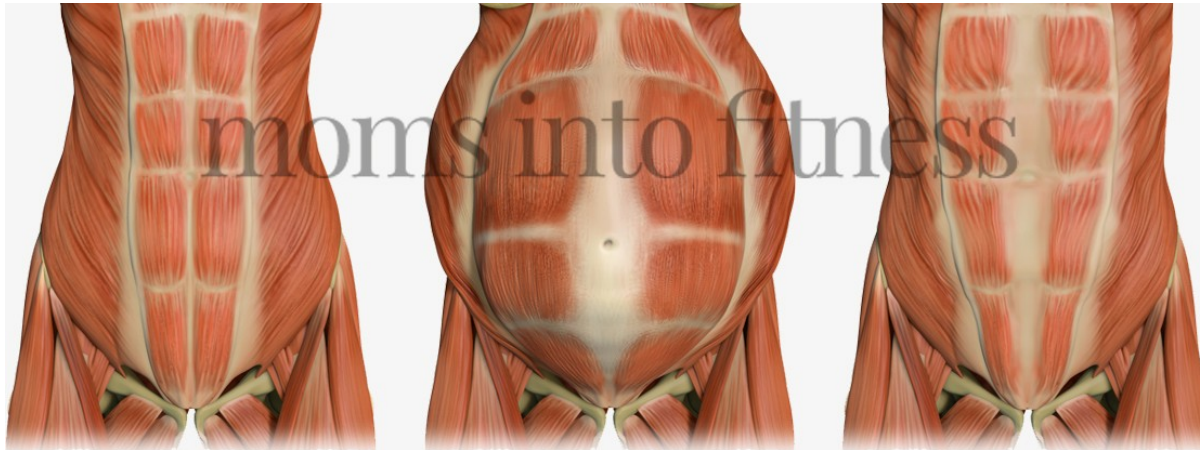
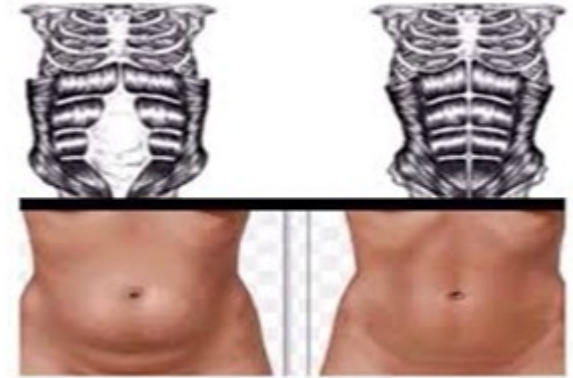
- Muscular imbalances (lower crossed syndrome, abdominal diastasis)
- Neurological conditions (abdominal wall paralysis, multiple sclerosis)
- Spine injuries
- Muscular diseases

Weak abdominal wall

- Muscular imbalances (lower crossed syndrome)



Abdominal diastasis

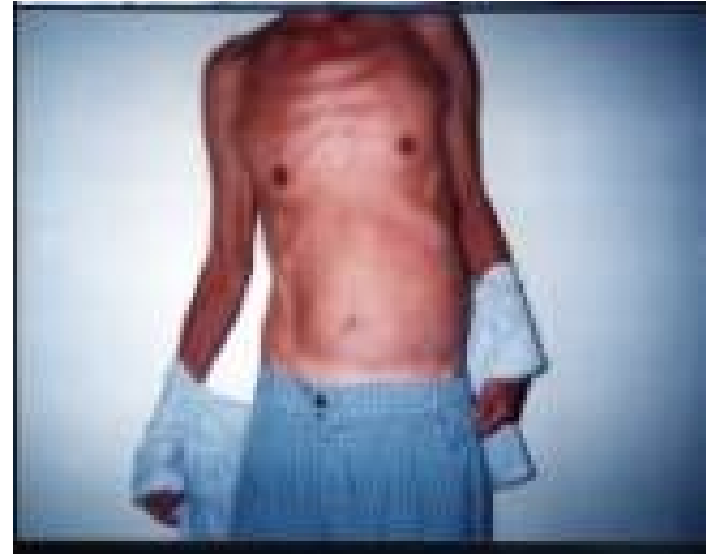
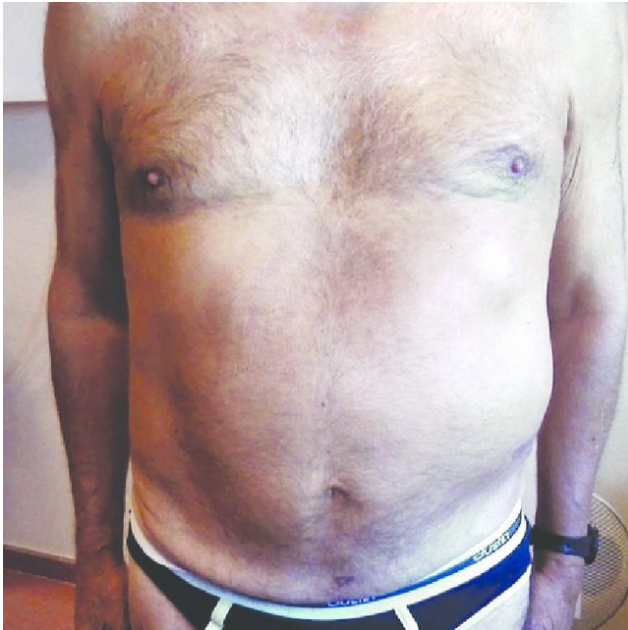
No Diastasis Recti

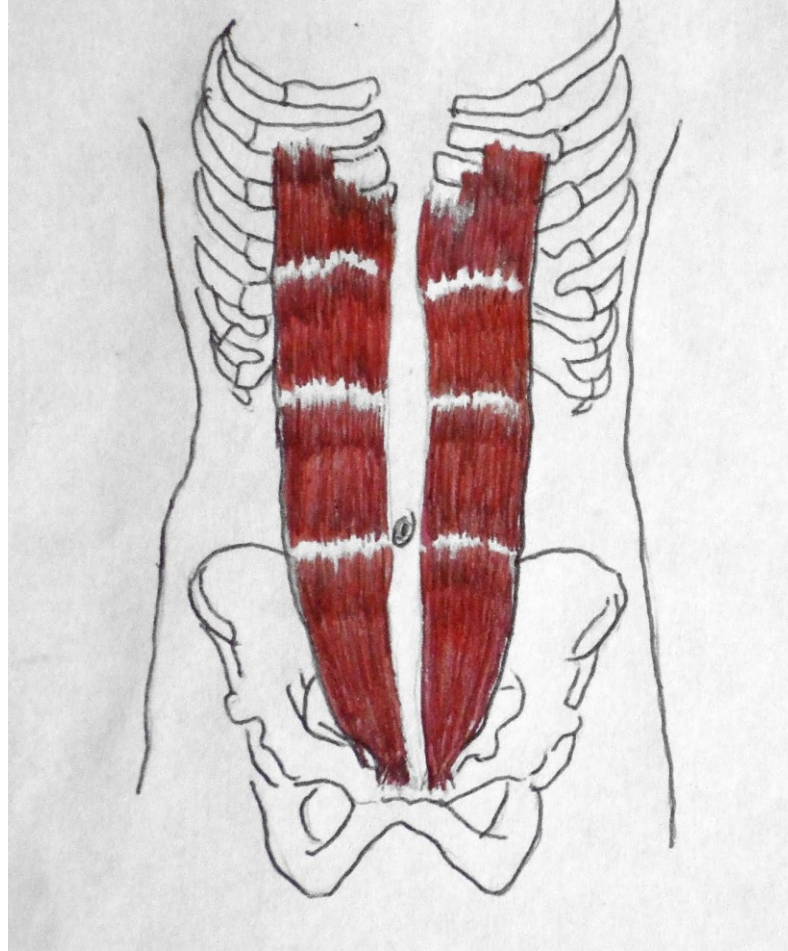
Diastasis Recti
during Pregnancy

Diastasis Recti
after Pregnancy

Abdominal muscles paralysis




Trunk flexion



Rectus abdominis muscle

Trunk flexion Grade 5




Note: before the test,
do the mark on the
spine at the level of
lower part of scapula

- Position: supine position, lower limbs relaxed in knee semiflexion position, upper limbs bended and placed below the head, elbows forward
- Fixation: not necessary
- Movement: fluent flexion of the trunk (bow), without moving of the pelvis in such an extend, that the distance between the table and the mark is at least 5cm
- Resistance: no resistance

Trunk flexion


Grade 4



- Position: supine position, lower limbs relaxed in knee semiflexion position, upper limbs bended and placed crossed at the chest
- Fixation: not necessary
- Movement: fluent flexion of the trunk (bow), without moving of the pelvis in such an extend, that the distance between the table and the mark is at least 5cm
- Resistance: no resistance

Trunk flexion


Grade 3



- Position: supine position, lower limbs relaxed in knee semiflexion position, upper limbs bended and placed crossed at the chest
- Fixation: not necessary
- Movement: fluent flexion of the trunk (bow), without moving of the pelvis in such an extend, that the mark can at least be seen
- Resistance: no resistance

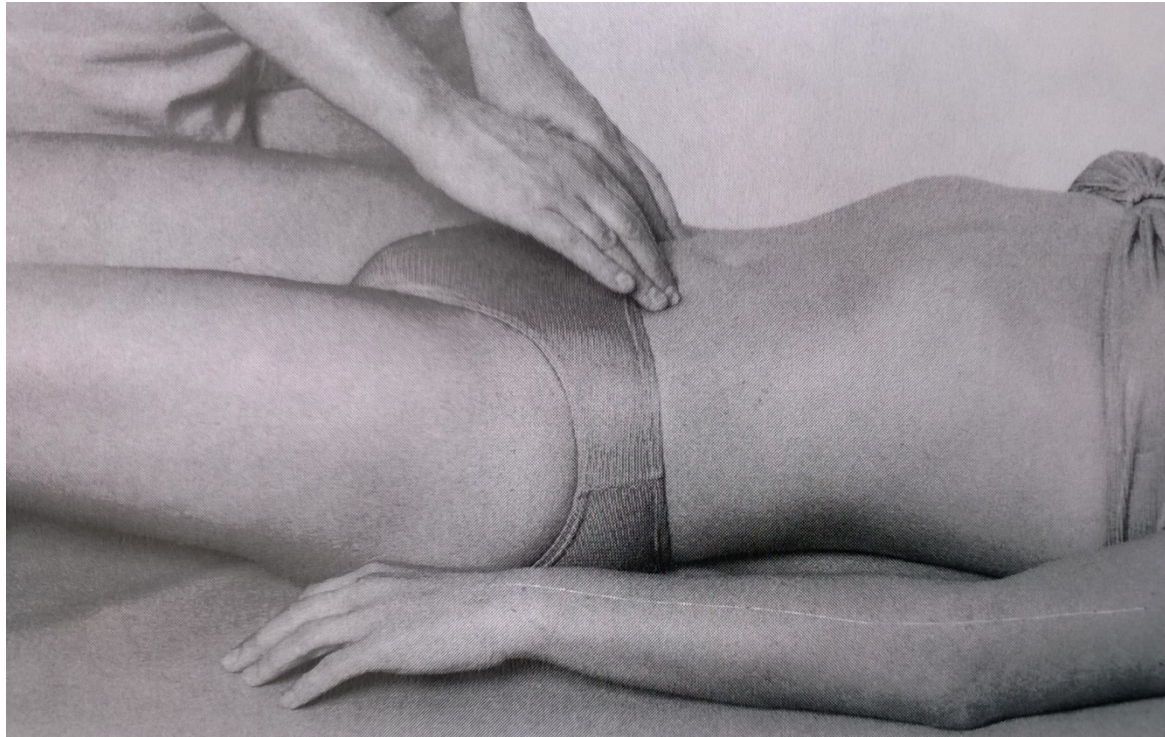Trunk flexion

Grade 2



- Position: supine position, lower limbs relaxed in knee semiflexion position, upper limbs bended and placed crossed at the chest
- Fixation: not necessary
- Movement: fluent flexion of the neck (bow) in full range of motion, elevation of the upper part of scapulas (the chest depression, lumbar applanation)
- Resistance: no resistance

Trunk flexion Grade 1,0

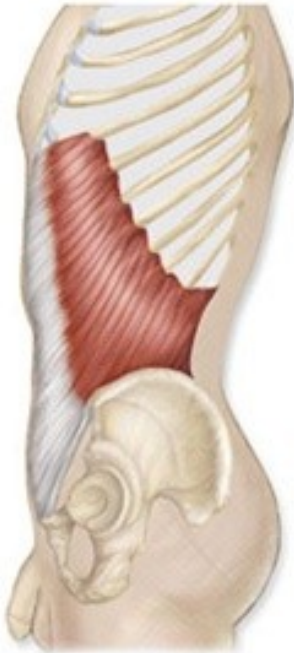

- Position: supine position, lower limbs relaxed in knee semiflexion position, upper limbs extended, lying relaxed along the body side
- Attempt to move: patient tries to cough or deeply breath out, PT palpates the trace of abdominal muscles contraction

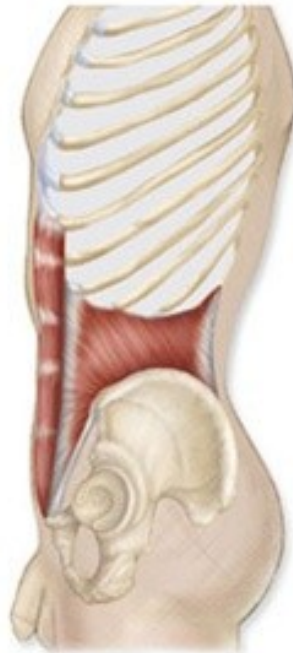Trunk flexion – note:

- The tested movement should be fluent, no swing at the start should be allowed
- The movement should be done symmetrically (without rotation to the side)
- Lower limbs have to be flexed and relaxed (to avoid iliopsoas muscles to take over the function)
- Finish the movement to flexion of the trunk when the pelvis starts to move (anteflexion)
- Shortening of the abdominal muscles is not common, but TrPs or spasms can occur

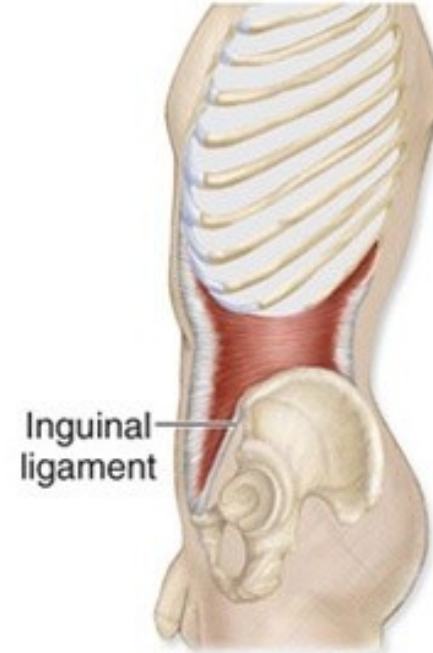
Trunk flexion with rotation



External oblique



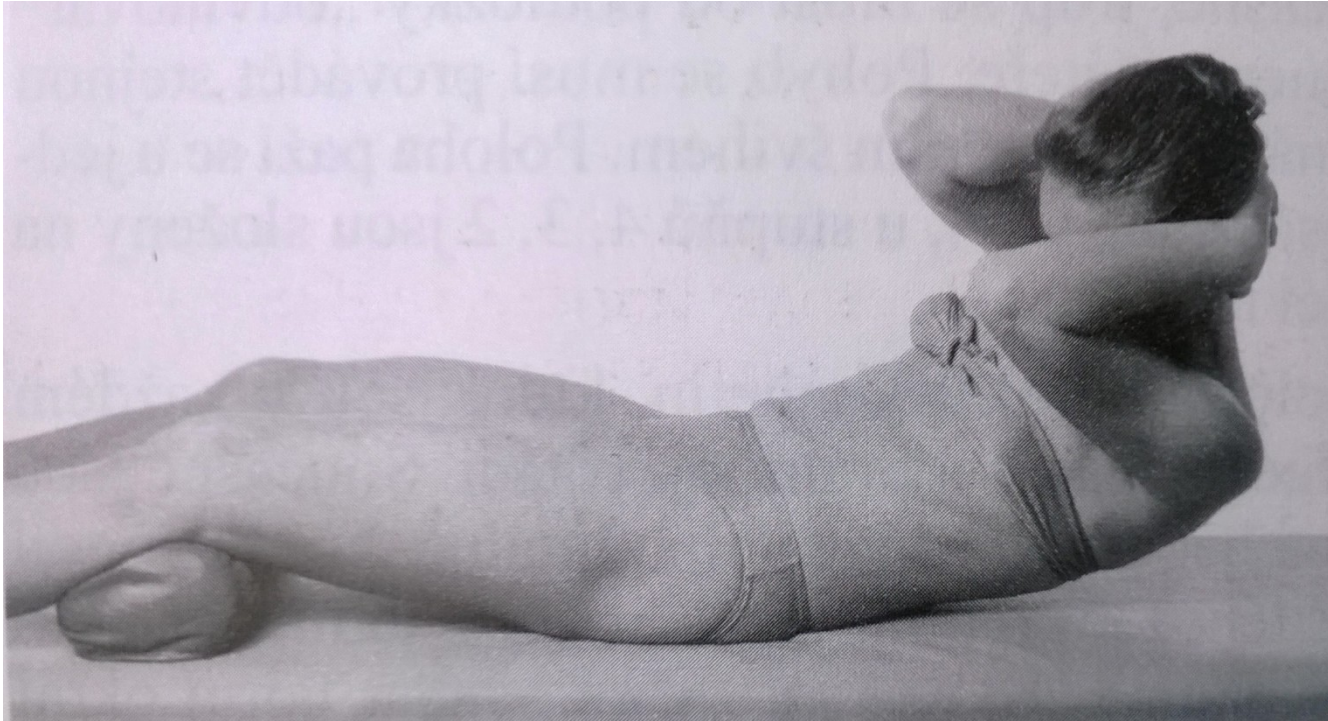
Internal oblique
and
rectus abdominis



Transversus
abdominis

Trunk flexion with rotation

Grade 5

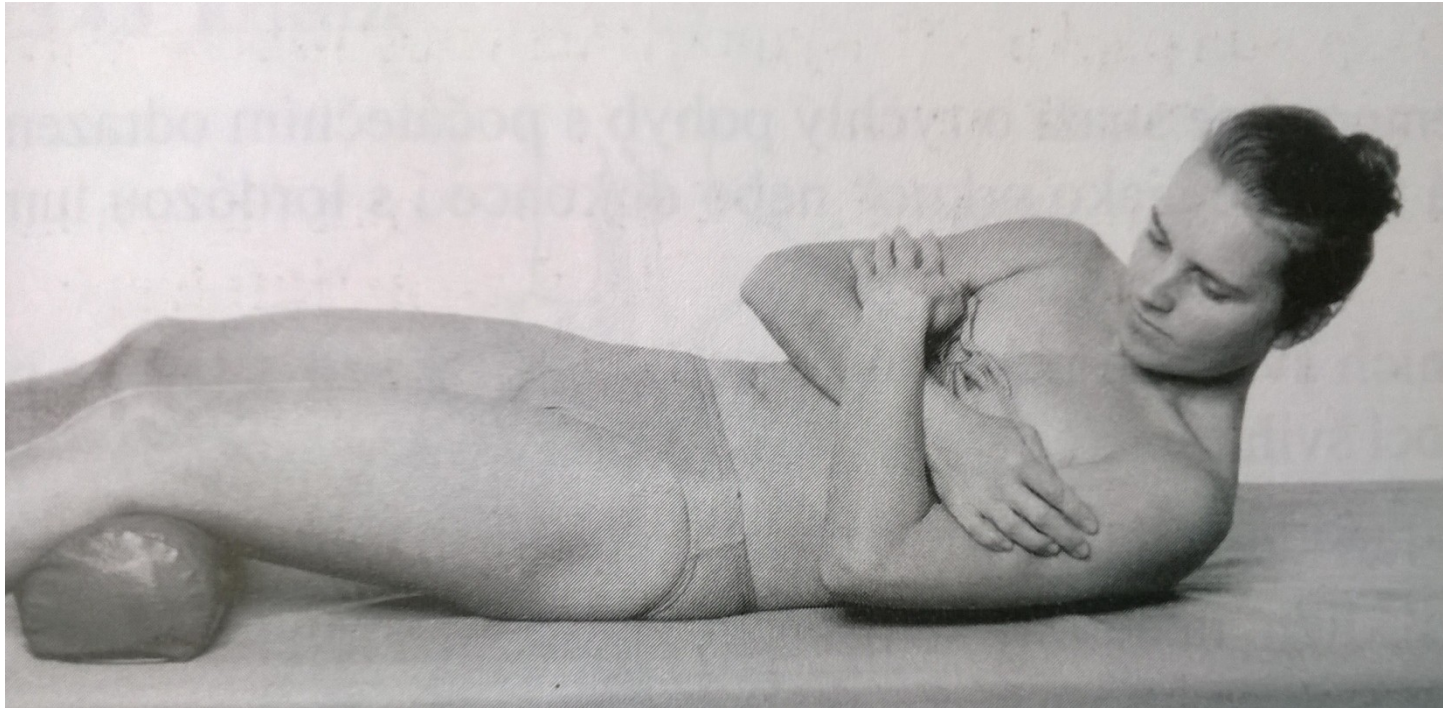


Note: before the test, do the mark on the spine at the level of lower part of scapula

- Position: supine position, lower limbs relaxed in knee semiflexion position, 25° hip abduction, upper limbs bended and placed below the head, elbows forward
- Fixation: not necessary
- Movement: fluent combined flexion and rotation of the trunk (bow), without moving of the pelvis in such an extend, that the distance between the table and the mark is at least 5cm
- Resistance: no resistance

Trunk flexion with rotation

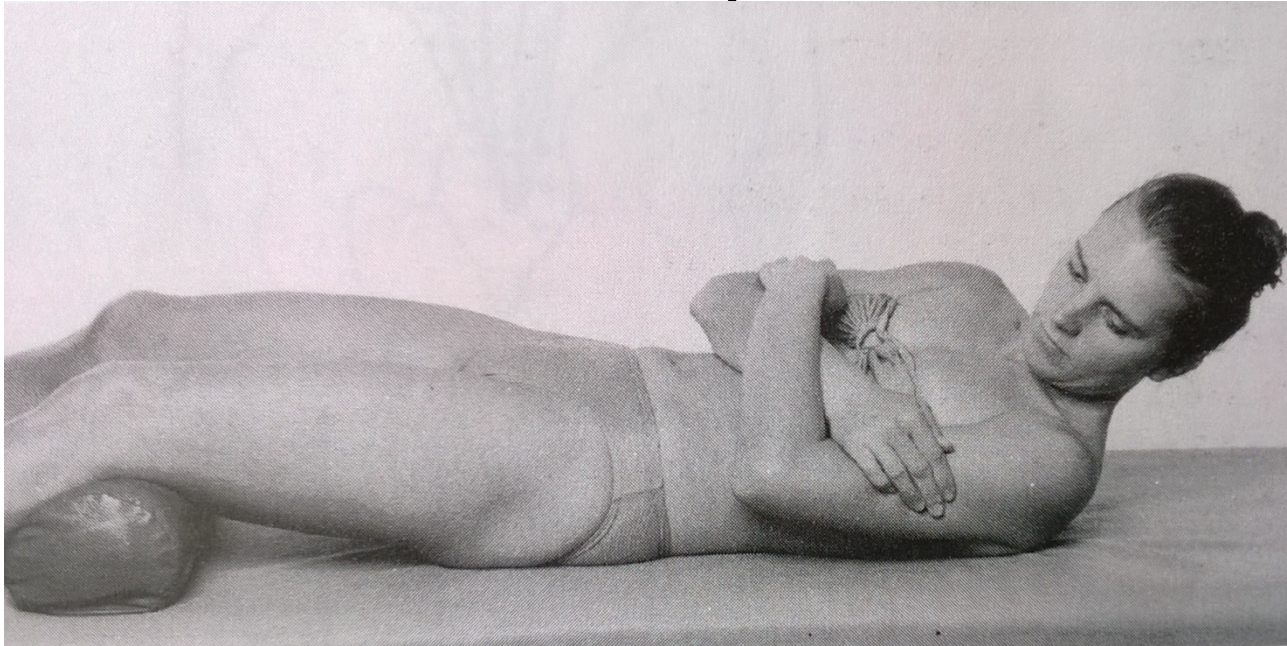
Grade 4



- Position: supine position, lower limbs relaxed in knee semiflexion position, 25° hip abduction, upper limbs bended and placed crossed at the chest
- Fixation: not necessary
- Movement: fluent combined flexion and rotation of the trunk (bow), without moving of the pelvis in such an extend, that the distance between the table and the mark is at least 5cm
- Resistance: no resistance

Trunk flexion with rotation

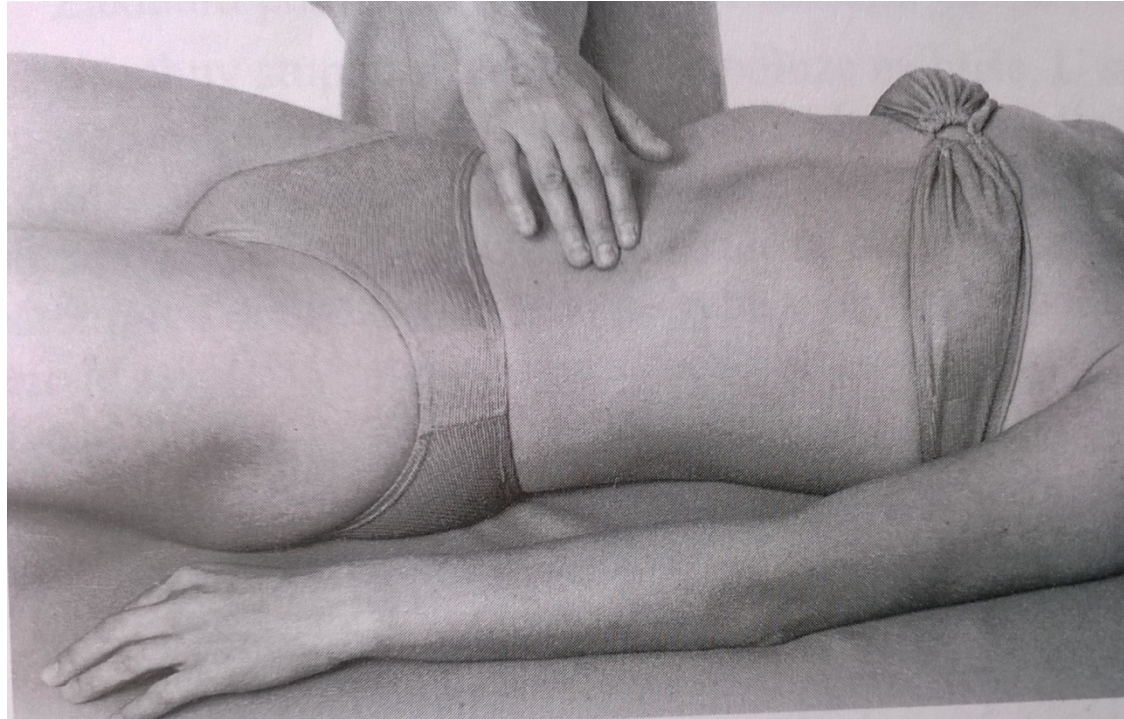Grade 3, 2



- Position: supine position, lower limbs relaxed in knee semiflexion position, 25° hip abduction, upper limbs bended and placed crossed at the chest
- Fixation: not necessary
- Movement: fluent combined flexion and rotation of the trunk (bow), without moving of the pelvis in such an extend, that the mark can be at least seen
- Resistance: no resistance
- Grade 2: the same as grade 3, the patient should at least elevate the head, shoulder and the upper thorax

Trunk flexion with rotation

Grade 1,0

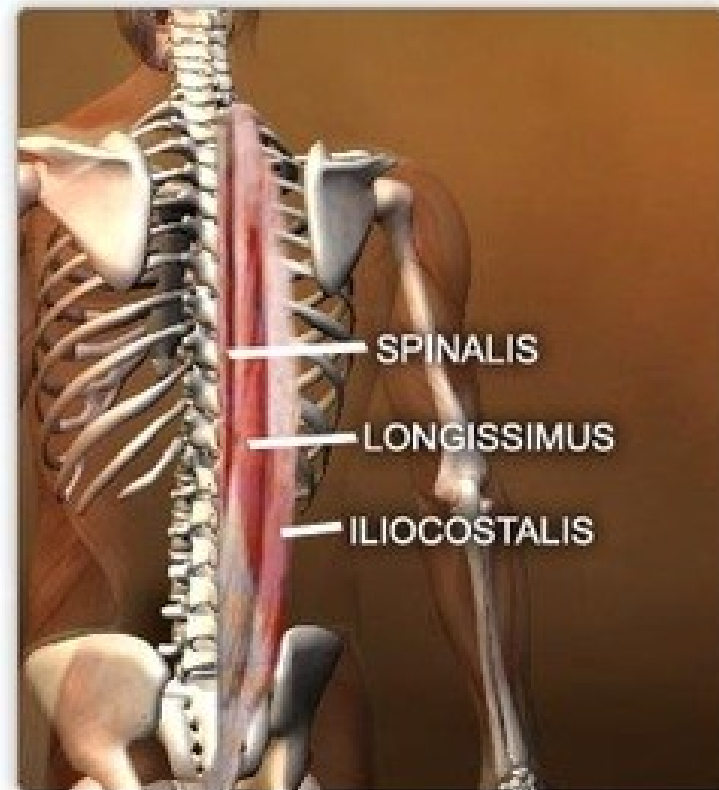
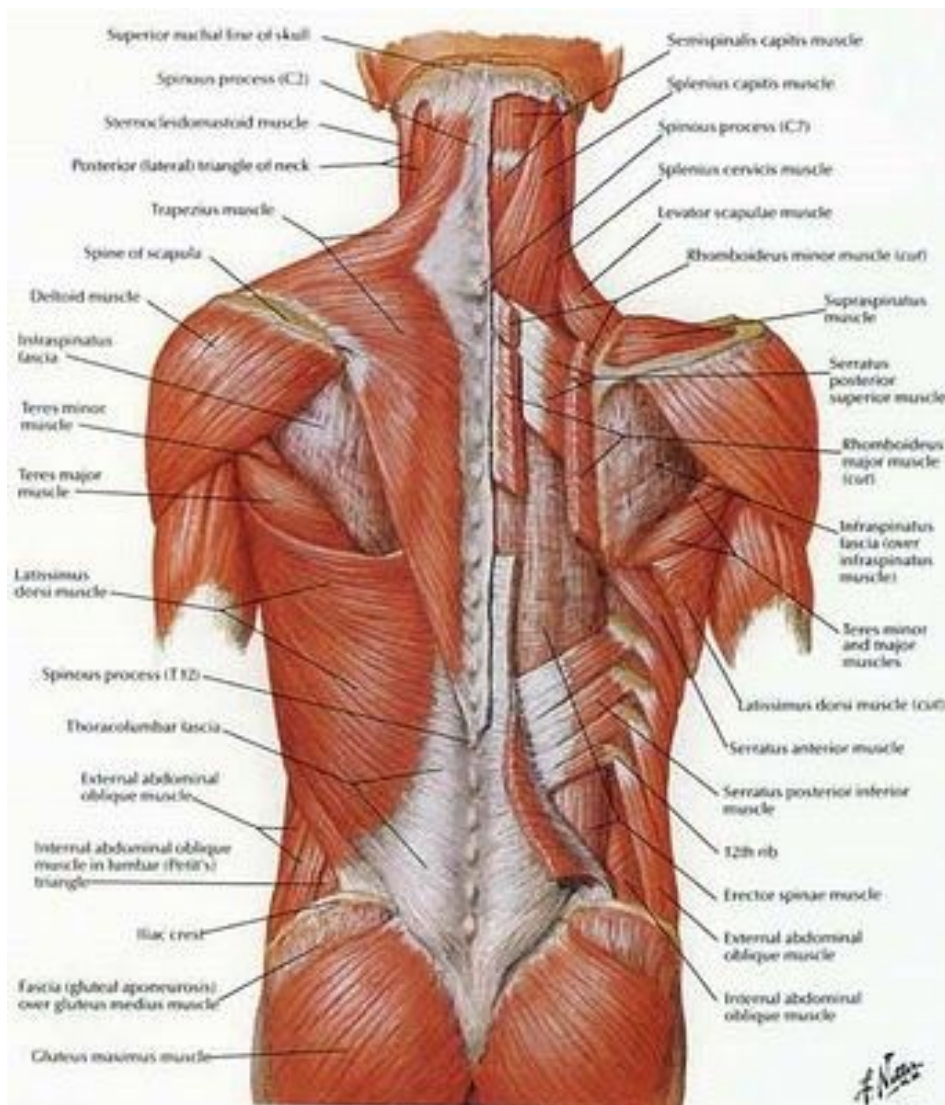


- Position: supine position, lower limbs relaxed in knee semiflexion position, 25° hip abduction, upper limbs extended, lying relaxed along the body side
- Attempt to move: patient tries to do rotation with flexion of the trunk, PT palpates the trace of contraction of abdominal muscles

Trunk flexion with rotation – notes:

- The movement should be fluent – combination of flexion and rotation, try to avoid lumbar hyperextension or lumbar lateroflexion
- The lower limbs has to be flexed, abduct and relaxed
- Contracture of abdominal muscles is not common, sometimes hypertonus occur at deep stabilization muscles insufficiention

Muscles of the back



The erector spinae

- a muscle group of the back, which extends the vertebral column (a more modern term is extensor spinae)
- it is not just one muscle, but a bundle of [muscles](#) and [tendons](#)
- it is paired and runs more or less vertically
- it extends throughout the lumbar, thoracic and cervical regions, and lies in the groove to the side of the [vertebral column](#)
- it is covered in the lumbar and thoracic regions by the [thoracolumbar fascia](#), and in the cervical region by the [nuchal ligament](#)

Iliocostalis

- originates from the [sacrum](#), [erector spinae aponeurosis](#) and [iliac crest](#)
- has three different insertions according to the parts:
 - [iliocostalis lumborum](#) has the lumbar part (where its insertion is in the 12th to 7th ribs)
 - [iliocostalis thoracis](#) where its insertion runs from the last 6 ribs to the first 6 ribs.
 - [iliocostalis cervicis](#) which runs from the first 6 ribs to the posterior tubercle of the transverse process of C6-C4.

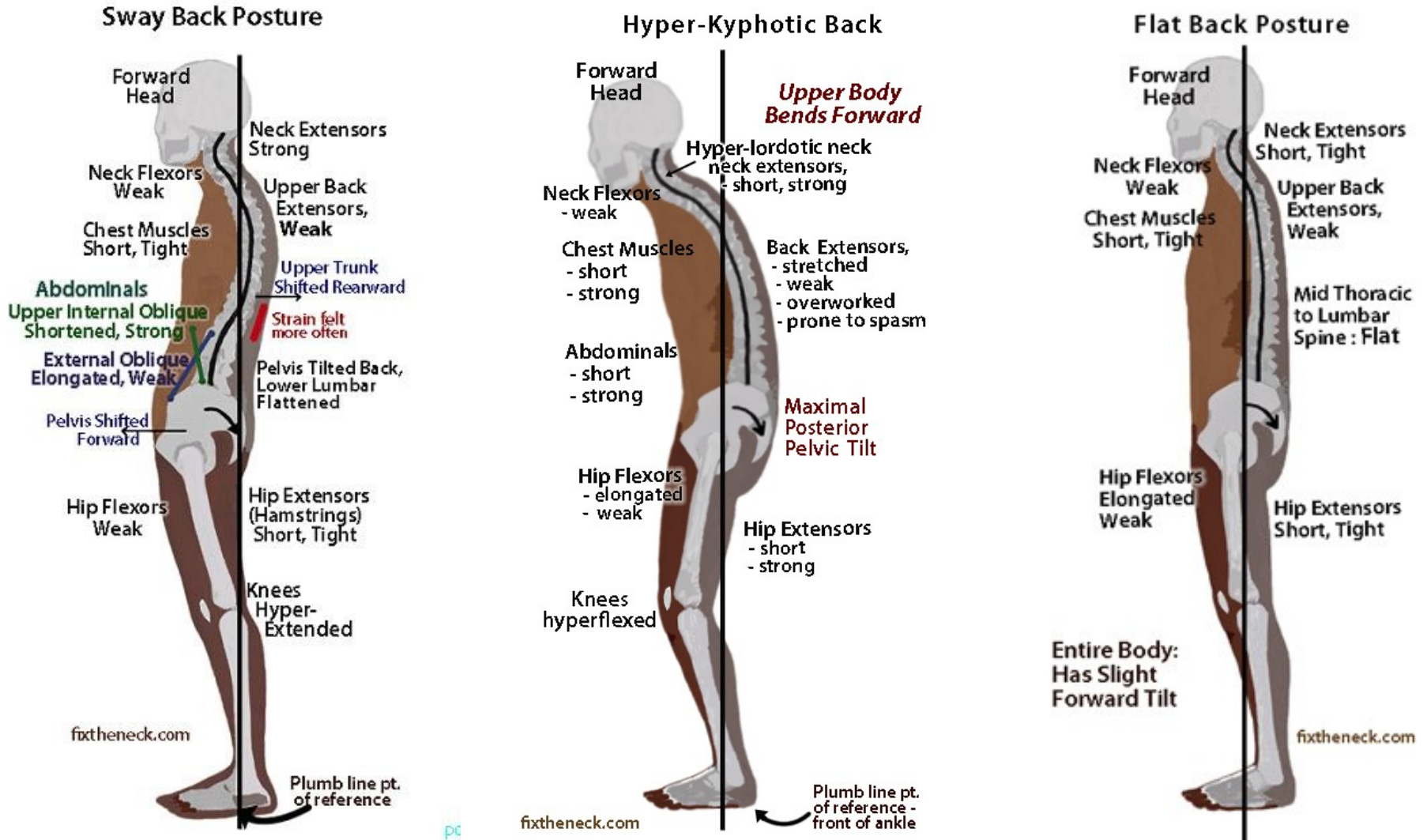
Longissimus

- is the intermediate and the largest of the three columns
- it has three parts with different origin and insertion:
 - [longissimus thoracis](#) originates from the sacrum, spinous processes of the lumbar vertebrae and transverse process of the last thoracic vertebra and inserts in the transverse processes of the lumbar vertebrae, erector spinae aponeurosis, ribs and costal processes of the thoracic vertebrae.
 - [longissimus cervicis](#) originates from the transverse processes of T6-T1 and inserts in the transverse processes of C7-C2.
 - [longissimus capitis](#) originates from the transverse processes of T3-T1 runs through C7-C3 and inserts in the mastoid process of the temporal bone.

Spinalis

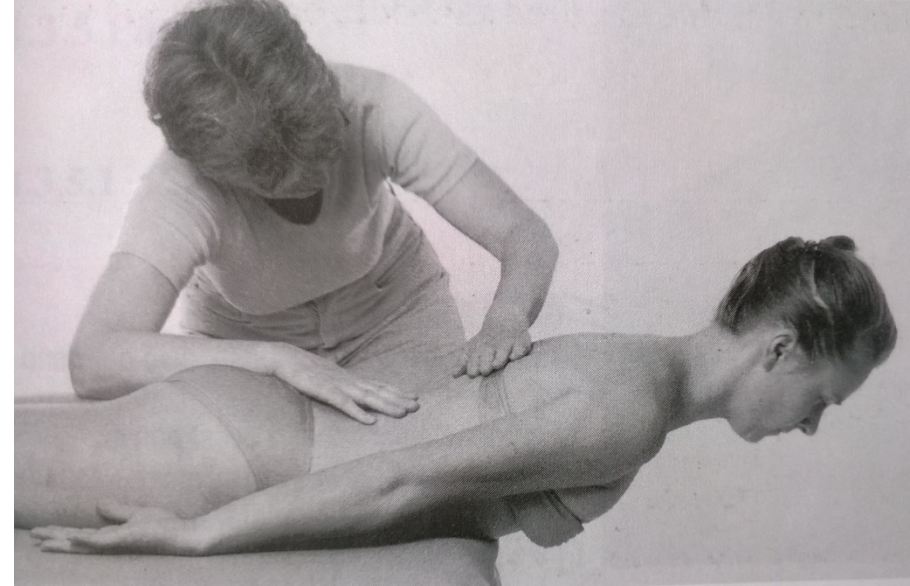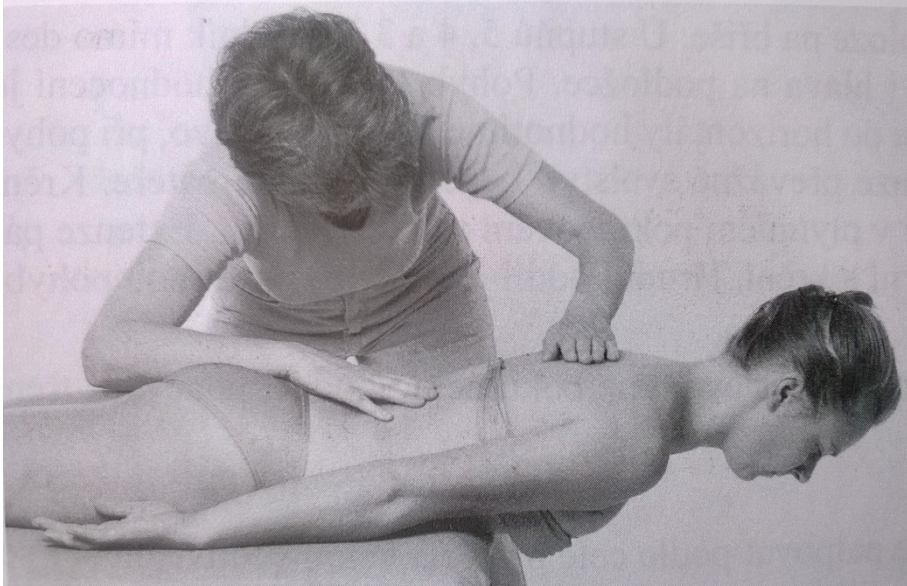
- it is the most medial and the smallest column
- it has three parts:
 - [spinalis thoracis](#) which originates from the spinous process of L3-T10 and inserts in the spinous process of T8-T2.
 - [spinalis cervicis](#) originates from the spinous process of T2-C6 and inserts in the spinous process of C4-C2.
 - [spinalis capitis](#) is an inconstant muscles fibres that runs from the cervical and upper thoracic that then inserts in the external occipital protuberance.

Weak back extensors



Trunk extension

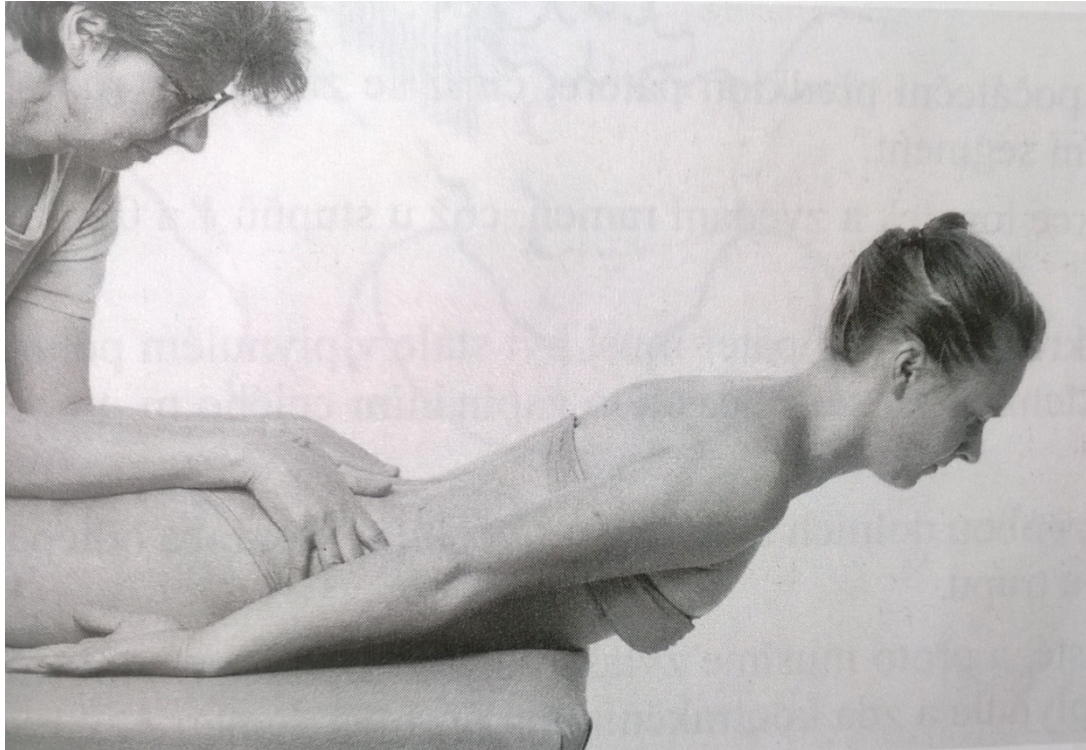
Grade 5,4



- Position: prone position, the chest away from the table, trunk in flexion (30°), arm along body side, palms up
- Fixation: to fix the buttocks, pelvis and lumbar part of the spine
- Movement: from forward bending position the patient extends the spine fully (thoracal and lumbal spine)
- Resistance: put up resistance between scapula using a palm (first phase), to the lower ribs (second phase)

Trunk extension

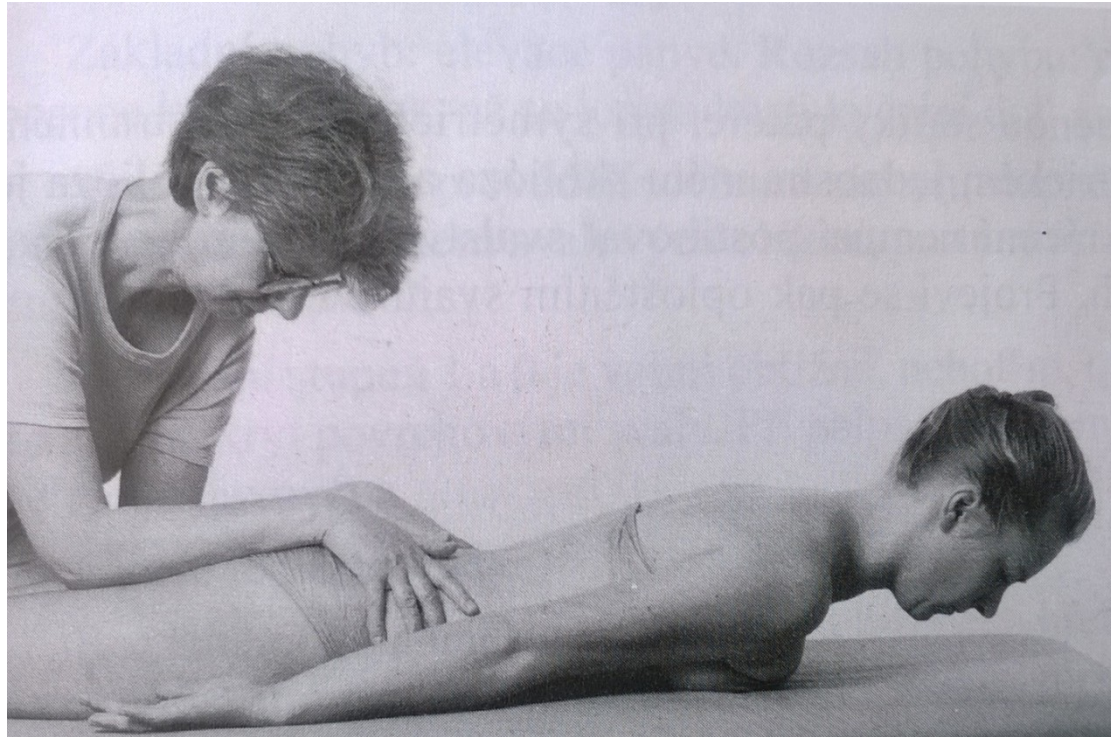
Grade 3



- Position: prone position, the chest away from the table, trunk in flexion (30°), arm along body side, palms up
- Fixation: to fix the buttocks and pelvis, firmly, using both hands
- Movement: from forward bending position the patient extends the spine fully

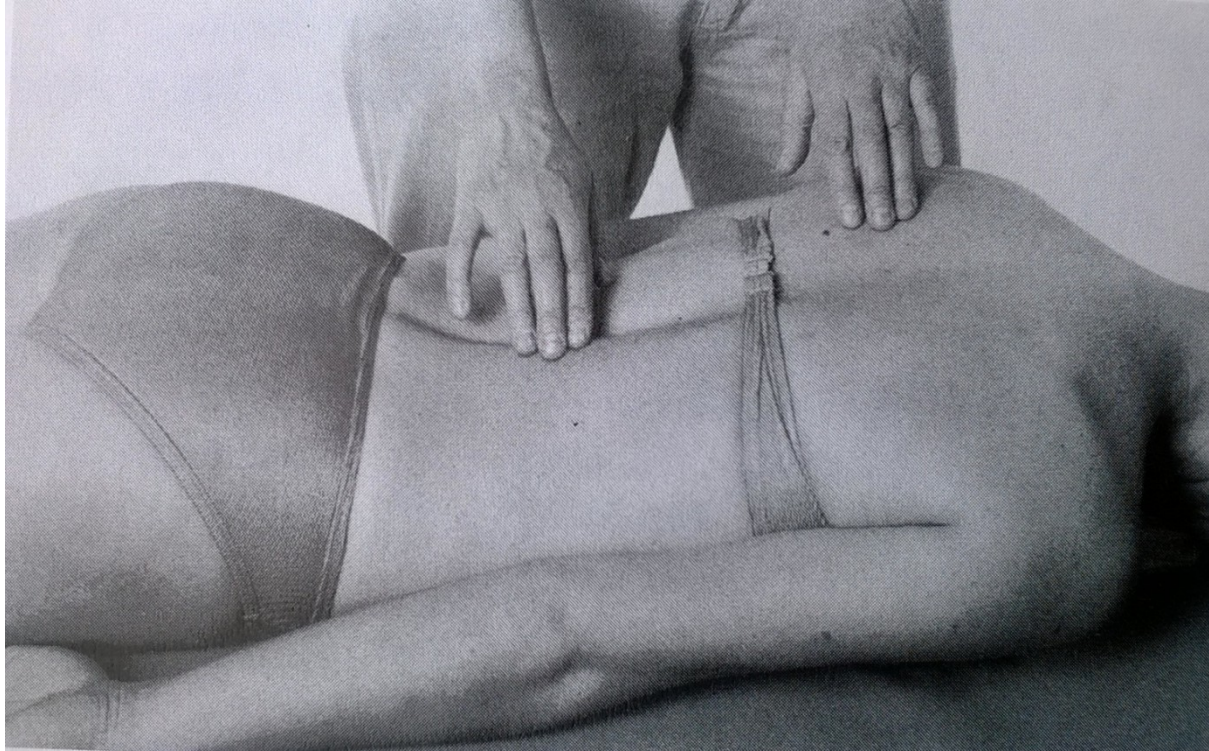Trunk extension

Grade 2



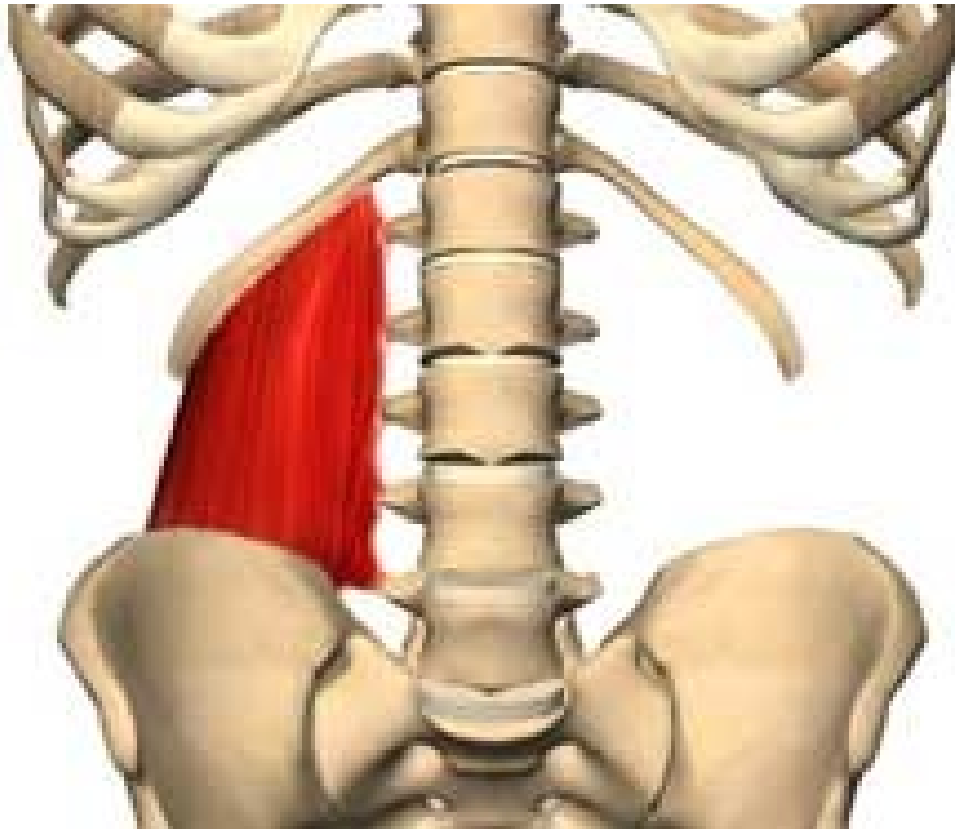
- Position: prone position, arm along body side, palms up, head laying down on the forehead
- Fixation: to fix the buttocks and pelvis, using both hands
- Movement: the patient extends the spine to elevate the head and shoulders

Trunk extension Grade 1,0

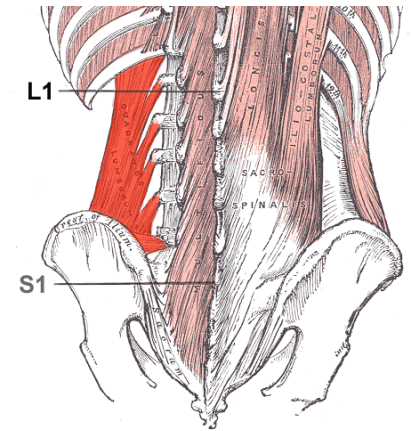


- Position: prone position, arm along body side, palms up, head laying down on the forehead
- Attempt to move: the patient tries to extend the spine, at least to elevate the head.
- PT tries to palpate the trace of contraction of the extensors along the whole spine

Quadratus lumborum



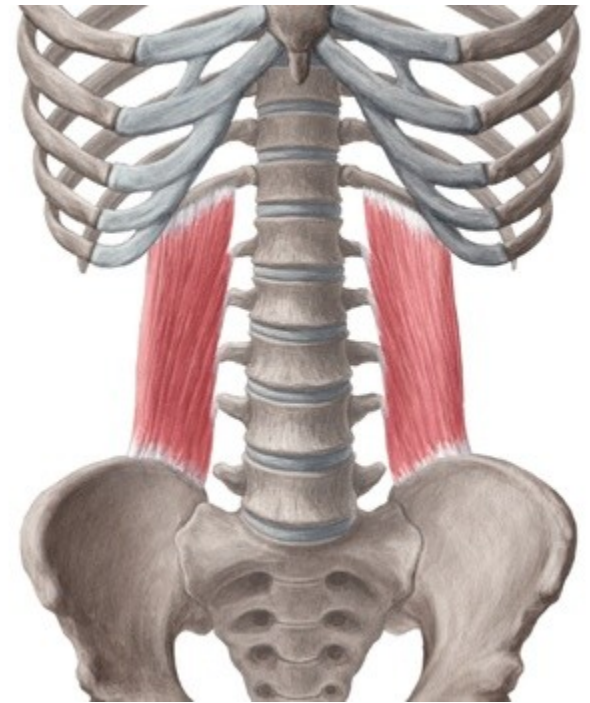
Quadratus lumborum



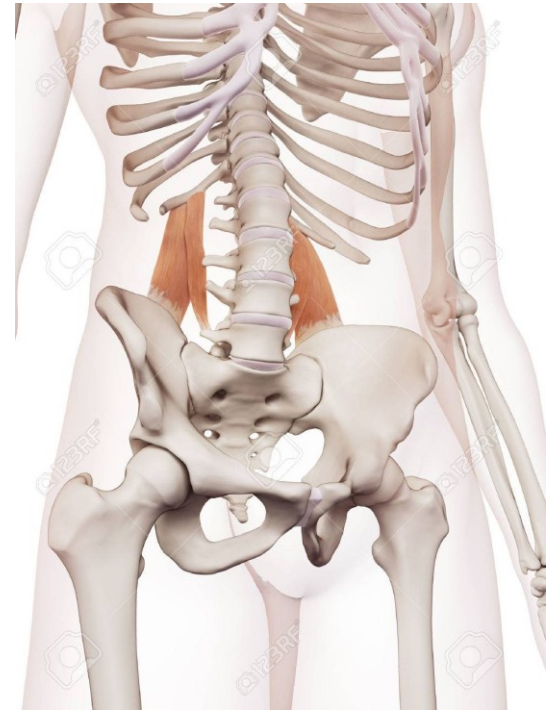
- a [muscle](#) in the lower [back](#)
- irregular and quadrilateral in shape, and broader below than above
- originates via [aponeurotic](#) fibers into the [iliolumbar ligament](#) and the internal lip of the [iliac crest](#) for about 5 cm
- inserts from the lower border of the last [rib](#) for about half its length, and by four small tendons from the apices of the [transverse processes](#) of the upper four [lumbar vertebrae](#)
- Occasionally a second portion of this muscle is found in front of the preceding. It arises from the upper borders of the transverse processes of the lower three or four [lumbar vertebrae](#), and is inserted into the lower margin of the last rib

Quadratus lumborum - function

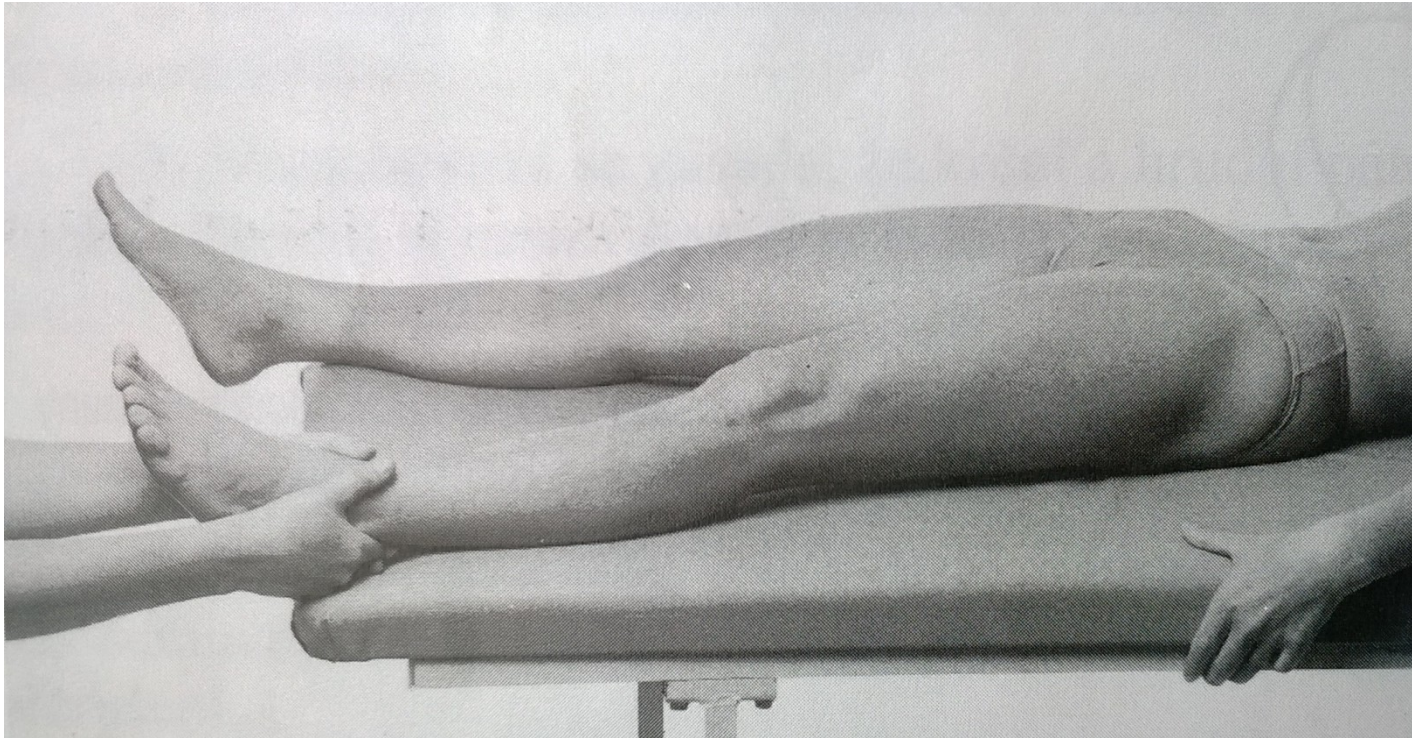
- Lateral flexion of vertebral column, with [ipsilateral contraction](#)
- Extension of lumbar vertebral column, with bilateral contraction
- Fixes the 12th rib during forced expiration
- Elevates the [Ilium \(bone\)](#), with [ipsilateral contraction](#)



Quadratus lumborum weakness

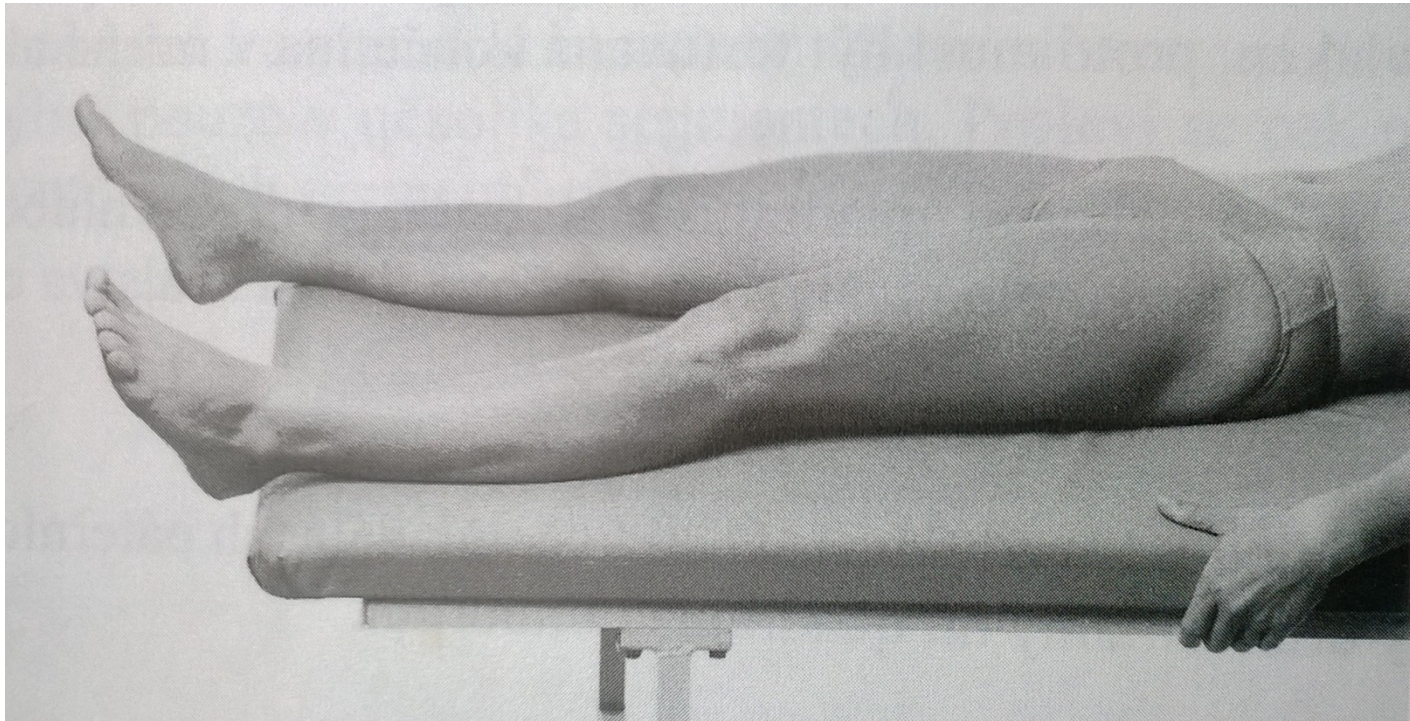


Pelvis elevation Grade 5,4,3



- Position: supine position, lower limb extended, 25° hip abduction
- Fixation: patient holds the edge of the table both hands
- Movement: to elevate one side of the pelvis to the chest
- Resistance: PT holds the tested lower limb around the ankle and pull it distally (the grades differentiate according to the resistance PT uses)

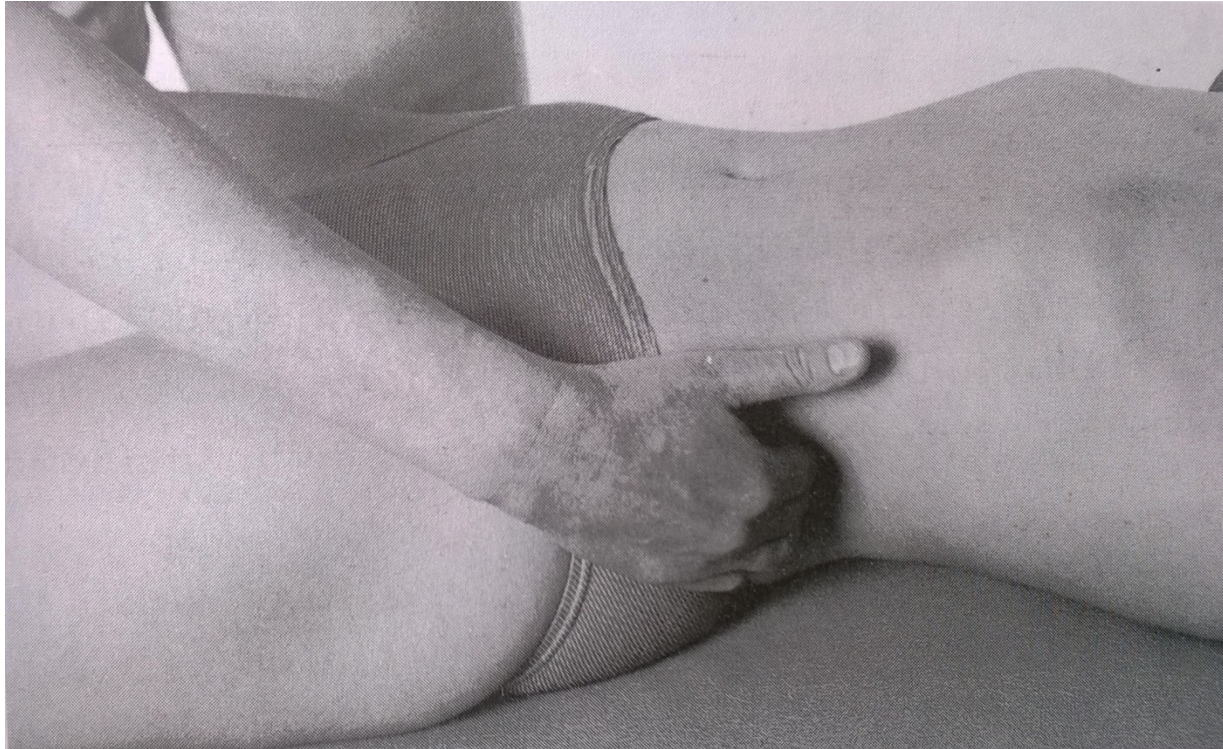
Pelvis elevation Grade 2



- Position: supine position, lower limb extended, 25° hip abduction
- Fixation: patient holds the edge of the table both hands
- Movement: to elevate one side of the pelvis to the chest in full range of motion

Pelvis elevation

Grade 1,0



- Position: supine position, lower limb extended, hip in slight abduction
- Fixation: PT supports the thigh slightly
- Attempt to move: patient tries to move one side of the pelvis to the chest, PT palpates the trace of contraction at the lateral side of the trunk

Pelvis elevation – note:

- Position: don't forget an abduction of the lower limbs
- Movement: don't allow the patient to do a trunk lateroflexion during testing
- Quadratus lumborum shortening: elevation of pelvis, scoliosis, lumbar spine doesn't expand to lateral flexion to the other side

Literature, e-sources

- <http://www.britannica.com/science/abdominal-muscle>
- https://en.wikipedia.org/wiki/Quadratus_lumborum_muscle
- <http://www.britannica.com/science/erector-spinae>

Thank you for your attention 😊

