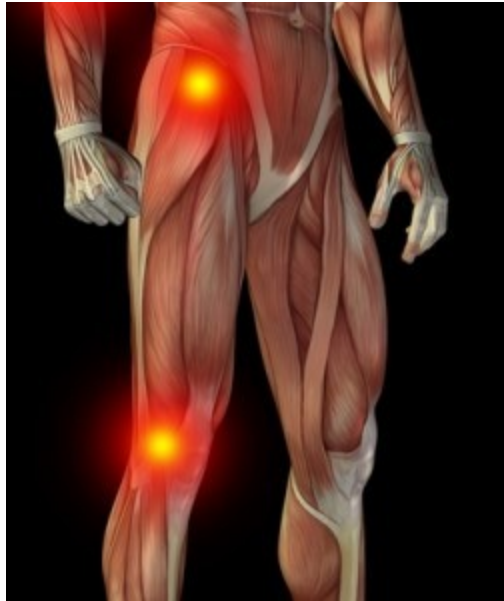


Examination Methods in Rehabilitation (18.10.2021)

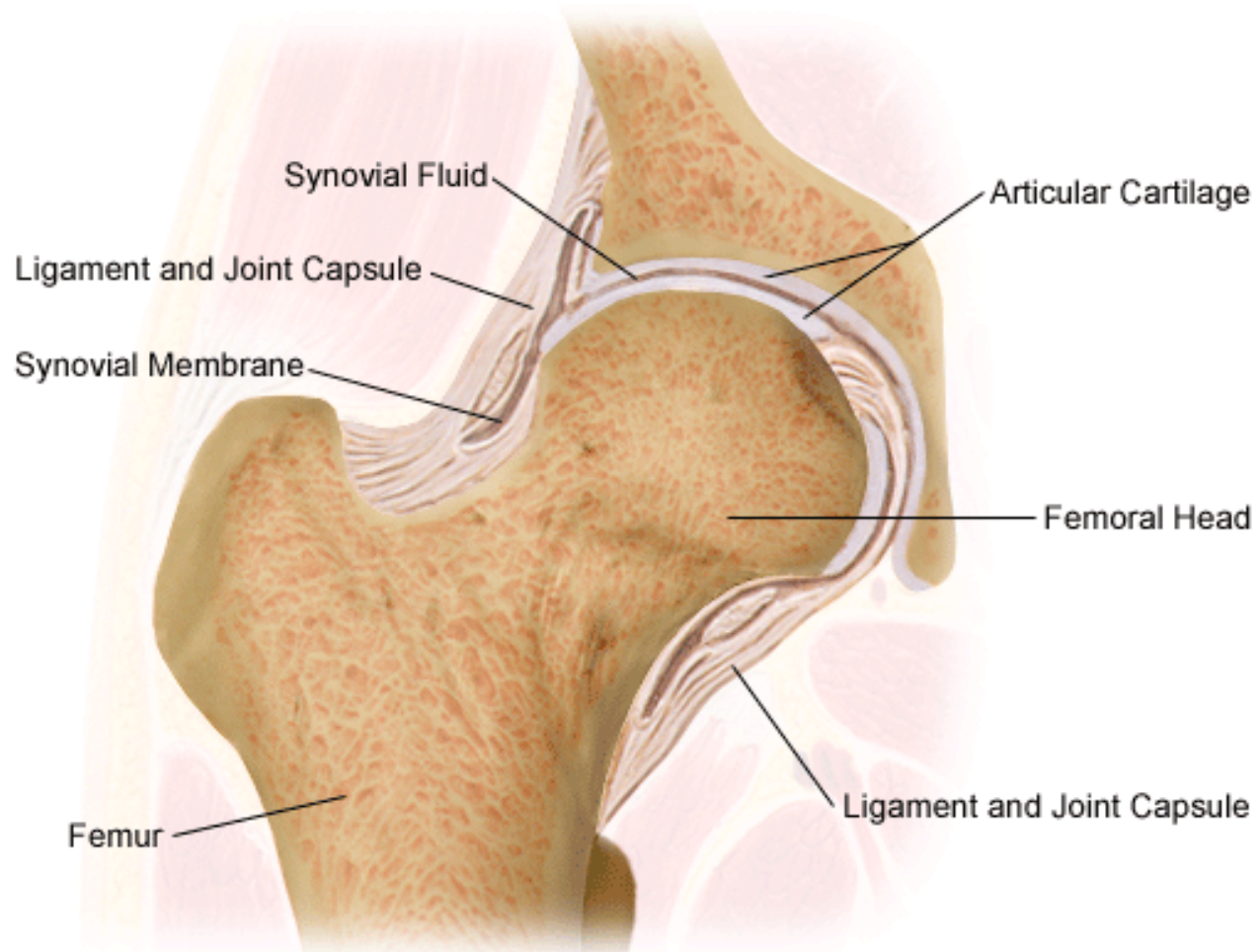
Manual muscle test

Hip and knee

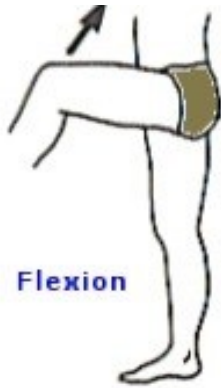

Mgr. Veronika Mrkvicová, Ph.D. (physiotherapist)

Hip joint

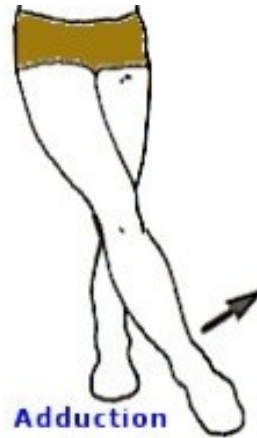

Hip joint movements



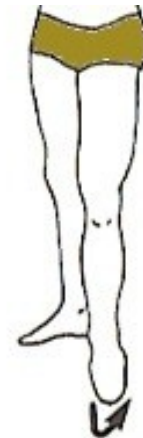
Flexion

Flex-Extension: 120-140 deg

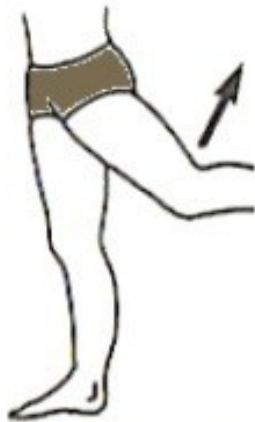

Adduction

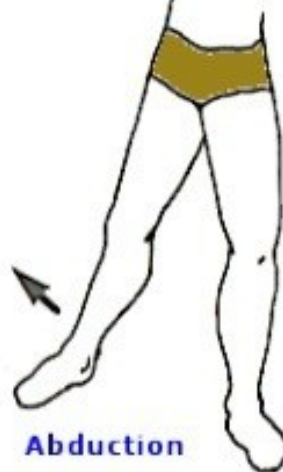
Abd-Adduction: 60-80 deg



Lateral Rotation



Extension



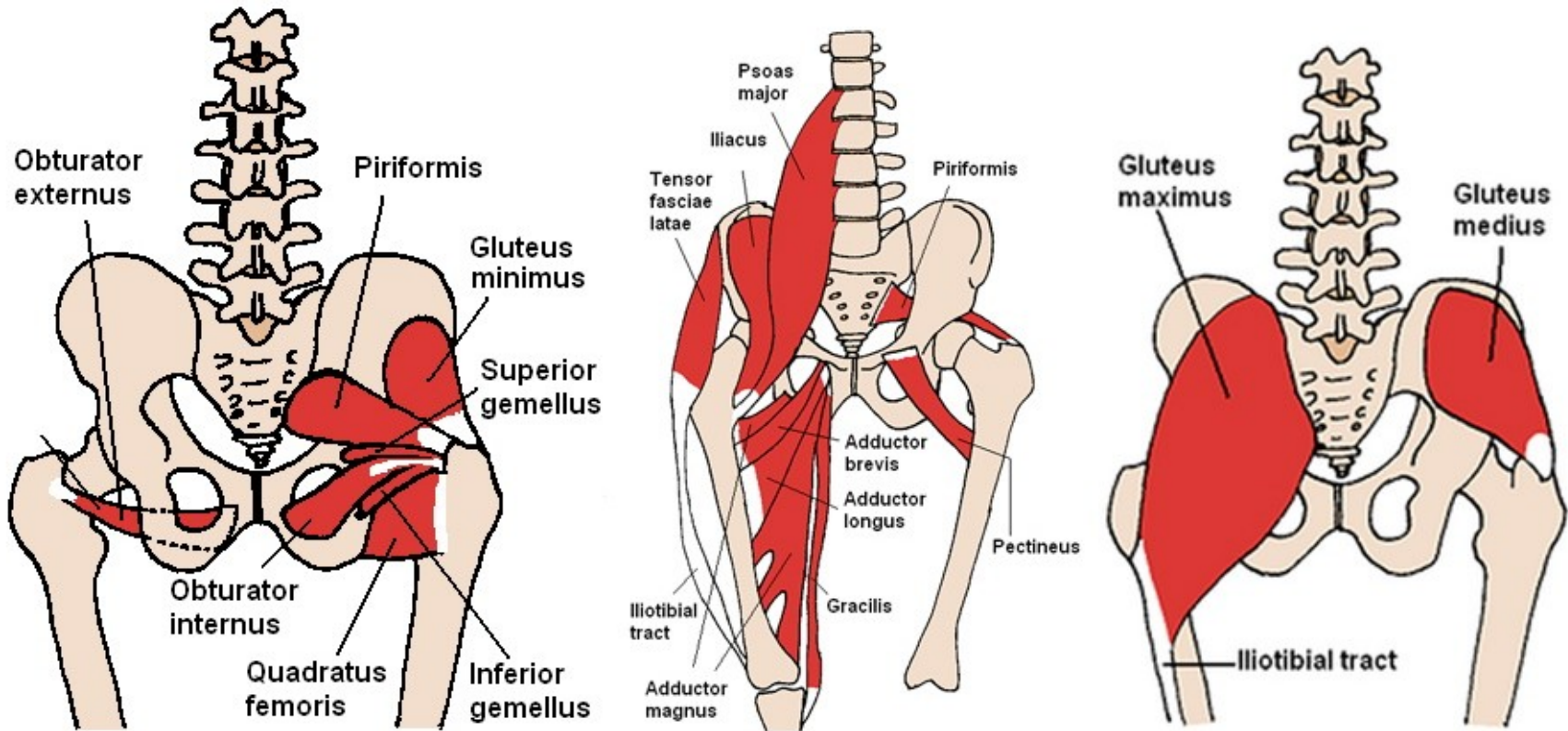
Abduction



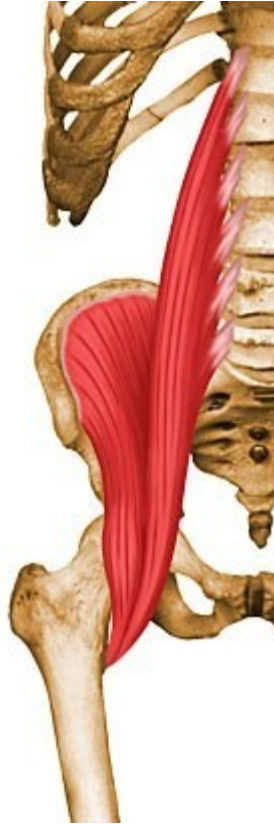Medial Rotation

Int-External rotation:
60-90 deg

Hip joint muscles



Hip flexion



Iliopsoas

M. iliopsoas

Origin

- Upper 2/3 of iliac fossa of ilium, internal lip of iliac crest, lateral aspect of sacrum, ventral sacroiliac ligament, and lower portion of iliolumbar ligament

Insertion

- Lesser trochanter

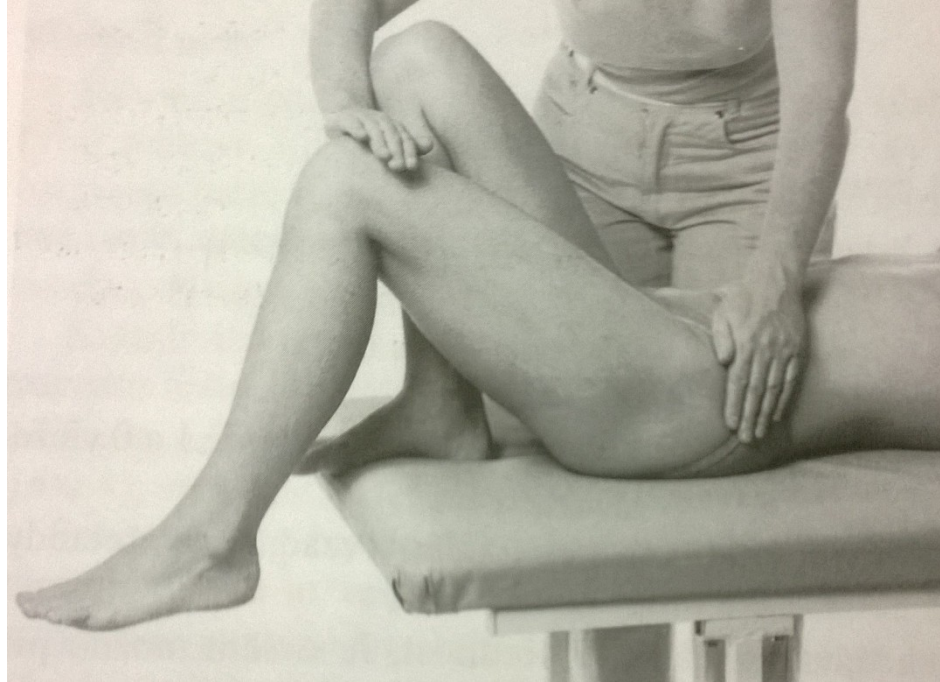Action

- Flex the torso and thigh with respect to each other

Innervation

- Muscular branch of femoral nerve (L1, L2, L3)

Hip flexion – grade 5,4



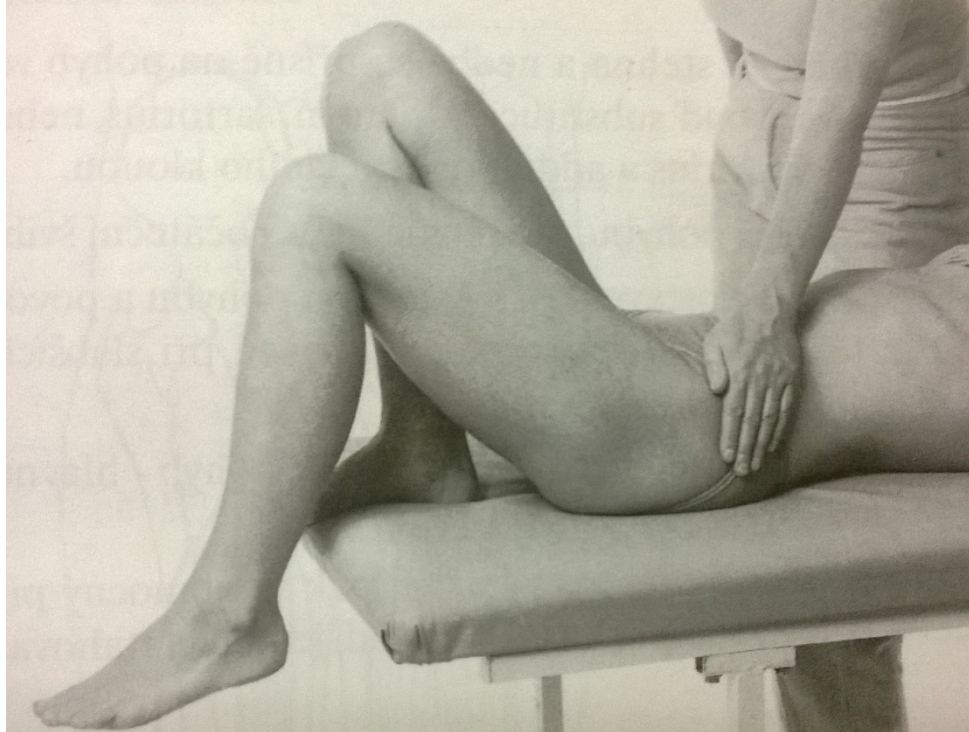
Position: lying supine, arms along body side, uninvolved lower limb flexed in hip and knee, foot on the table, tested lower limb in 90° flexion in knee joint, foot free, hanging from the table

Fixation: pelvis on the tested side

Movement: hip flexion in full range of motion

Resistance: at the lower part of thigh (arched)

Hip flexion – grade 3

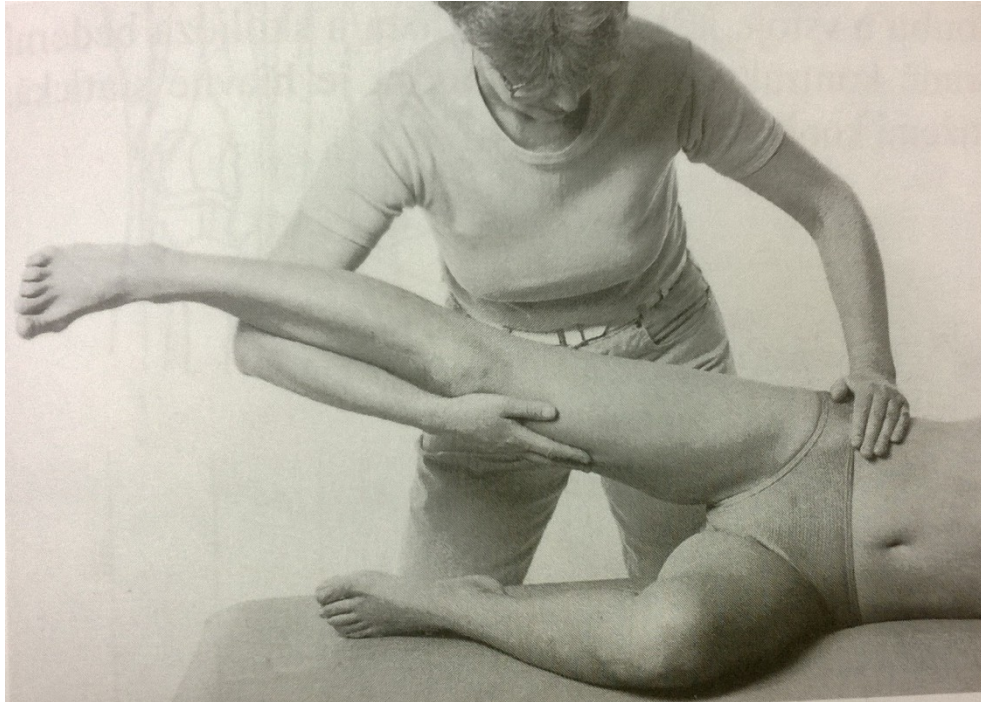


Position: lying supine, arms along body side, uninvolved lower limb flexed in hip and knee, foot on the table, tested lower limb in 90° flexion in knee joint, foot free, hanging from the table

Fixation: pelvis on the tested side

Movement: hip flexion in full range of motion

Hip flexion – grade 2

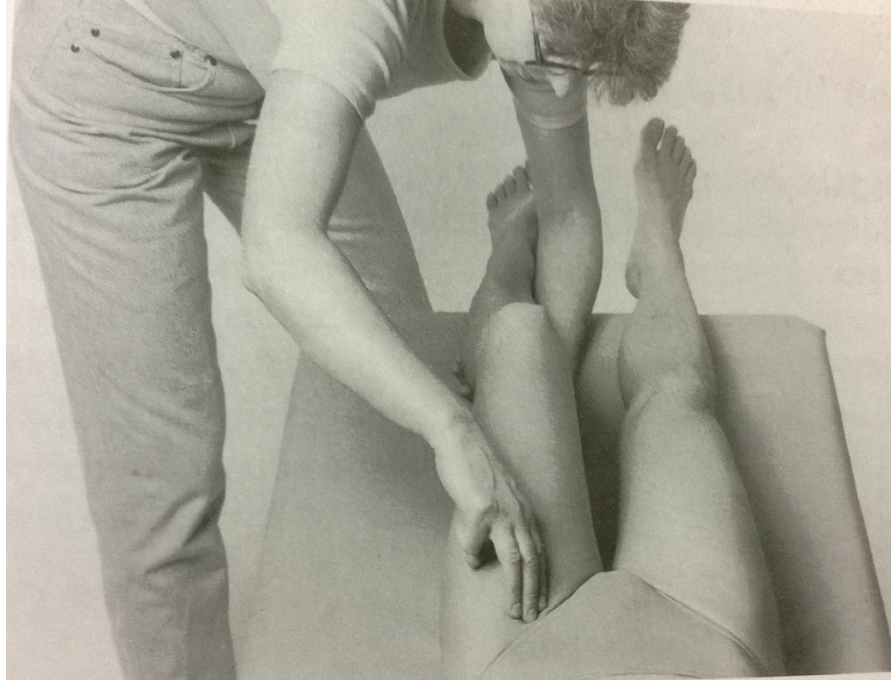


Position: lying on the tested side, tested lower limb in central position of the hip, 90° flexion in the knee joint

Fixation: PT supports with one hand the uninvolved lower limb, which is extended in the knee and central position in the hip joint, PTs' other hand fix the pelvis on the untested side

Movement: flexion of the tested lower limb by pushing on the table in full range of motion

Hip flexion – grade 1,0



Position: patient lying supine

Fixation: PT supports patients tested lower limb in semiflexion in the knee and semiflexion and a slight external rotation in hip joint

Attempt to move: PT palpates a trace of contraction during the patients' attempt to flex the hip – in the inguinal area (groin)

Hip flexion – notes:

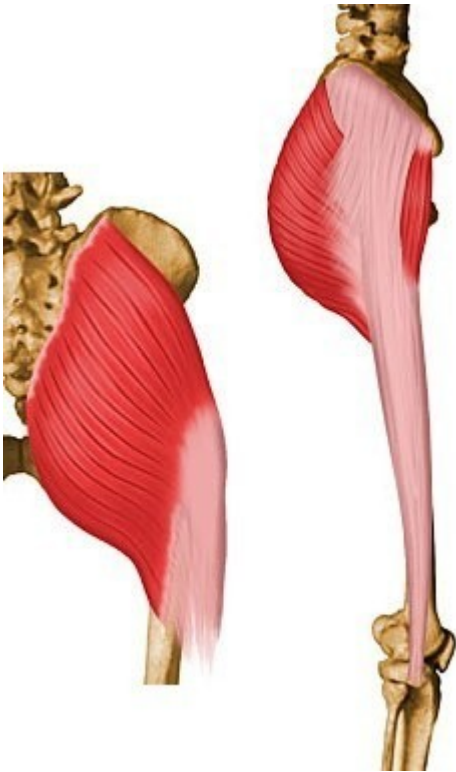
The movement should be done in exact sagittal plane (no rotation of the hip joint)

No swing during the movement

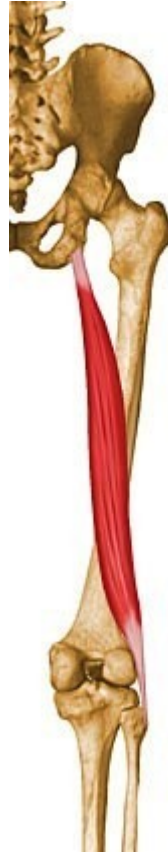No extension of the knee joint or lumbar hyperlordosis (substitution of rectus femoris muscle)

No elevation of the pelvis (substitution of quadratus lumborum)

Hip extension



Gluteus
maximus



Biceps femoris
(long head)



Semitendinosus
Semimembranosus



Gluteus maximus

Origin

- Posterior aspect of dorsal ilium posterior to posterior gluteal line, posterior superior iliac crest, posterior inferior aspect of sacrum and coccyx, and sacrotuberous ligament

Insertion

- Primarily in fascia lata at the iliotibial band
- also into the gluteal tuberosity on posterior femoral surface

Action

- Major extensor of hip joint, assists in laterally rotating the thigh
- upper and middle third section of the muscle are abductors

Innervation

- Inferior gluteal nerve (L5, S1, S2) (L5, S1, S2)

Biceps femoris (long head)

Origin

- Common tendon with semitendinosus from superior medial quadrant of the posterior portion of the ischial tuberosity

Insertion

- Primarily on fibular head
- also on lateral collateral ligament and lateral tibial condyle

Action

- Flexes the knee, and also rotates the tibia laterally
- long head also extends the hip joint

Innervation

- Tibial nerve (L5, S1, S2)

Semitendinosus

Origin

- From common tendon with long head of biceps femoris from superior medial quadrant of the posterior portion of the ischial tuberosity

Insertion

- Superior aspect of medial portion of tibial shaft

Action

- Extends the thigh and flexes the knee
- rotates the tibia medially, especially when the knee is flexed

Innervation

- Tibial nerve (L5, S1, S2)

Semimembranosus

Origin

- Superior lateral quadrant of the ischial tuberosity

Insertion

- Posterior surface of the medial tibial condyle

Action

- Extends the thigh, flexes the knee
- rotates the tibia medially, especially when the knee is flexed

Innervation

- Tibial nerve (L5, S1, S2)

Hip extension – grade 5,4



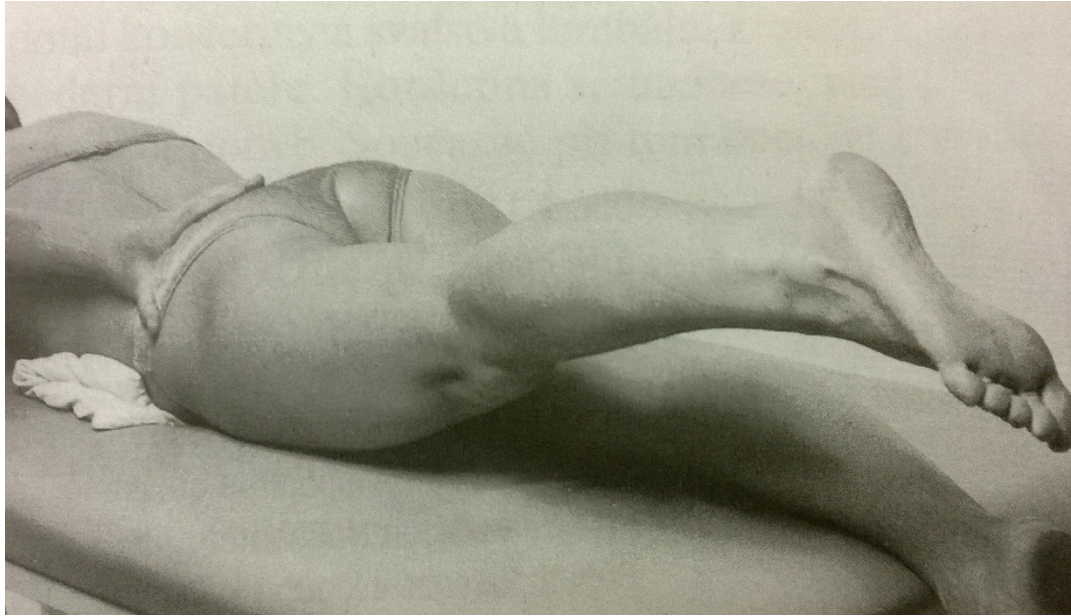
Position: patient lying prone, arms along body side, head lying on the forehead, lower limbs extended, foot away from the table (the abdomen underlaid with the pillow to ensure lumbar aplanation)

Fixation: the pelvis on the tested side

Movement: hip extension (in 10° range of motion)

Resistance: on the lower part of the thigh (arched)

Hip extension – grade 3

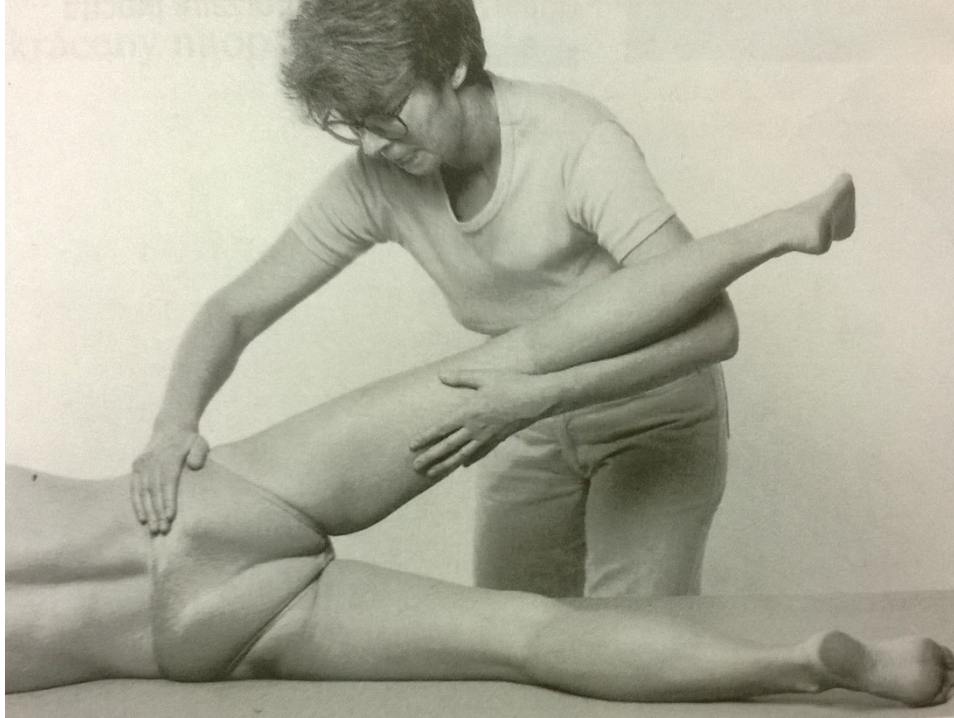


Position: patient lying prone, arms along body side, head lying on the forehead, lower limbs extended, foot away from the table (the abdomen underlaid with the pillow to ensure lumbar aplanation)

Fixation: the pelvis on the tested side

Movement: hip extension (in 10° range of motion)

Hip extension – grade 2

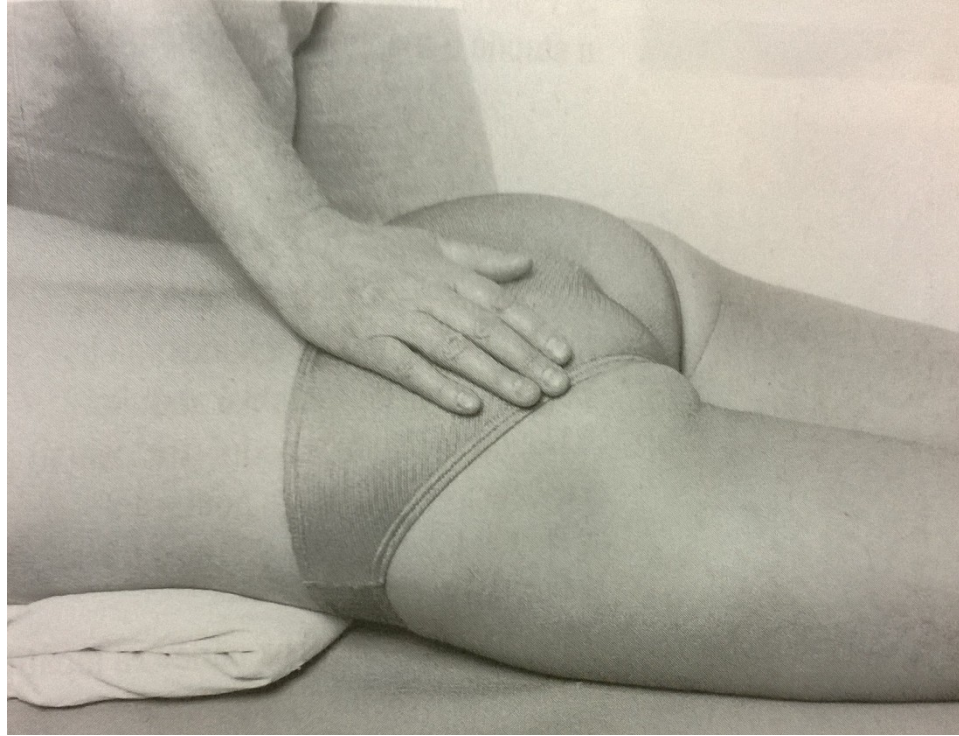


Position: lying on the tested side, the uninvolved lower limb is supported by PT in slightly flexion and abduction in the hip and slightly flexed in the knee joint, the tested lower limb extended in the knee joint, central position of the hip

Fixation: the pelvis on the untested side

Movement: hip extension (in 10° range of motion)

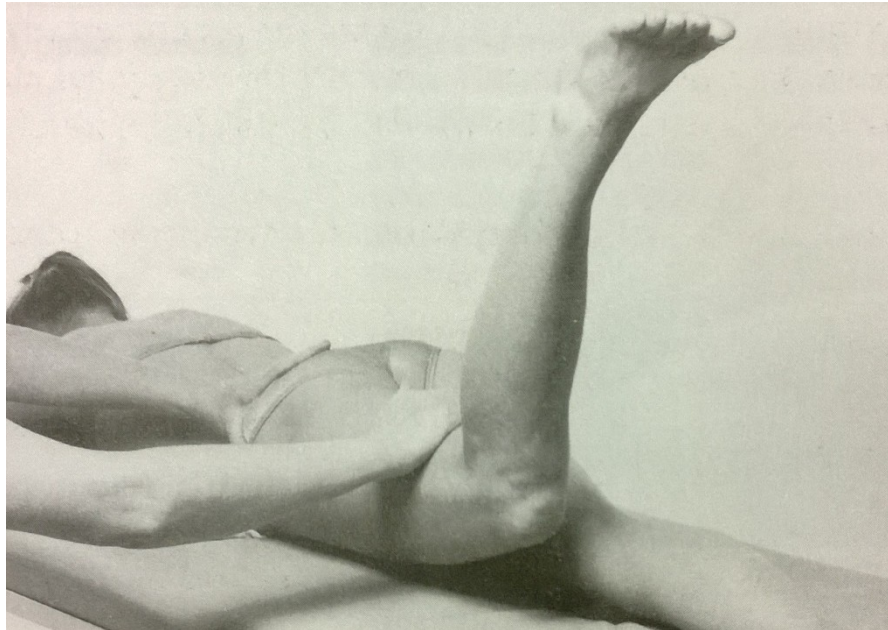
Hip extension – grade 1,0



Position: patient lying prone, arms along body side, head lying on the forehead, lower limbs extended, foot away from the table (the abdomen underlaid with the pillow to ensure lumbar aplanation)

Attempt to move: PT palpates a trace of contraction during patients attempt to extend the hip joint

Hip extension (gluteus max.) – grade 5,4



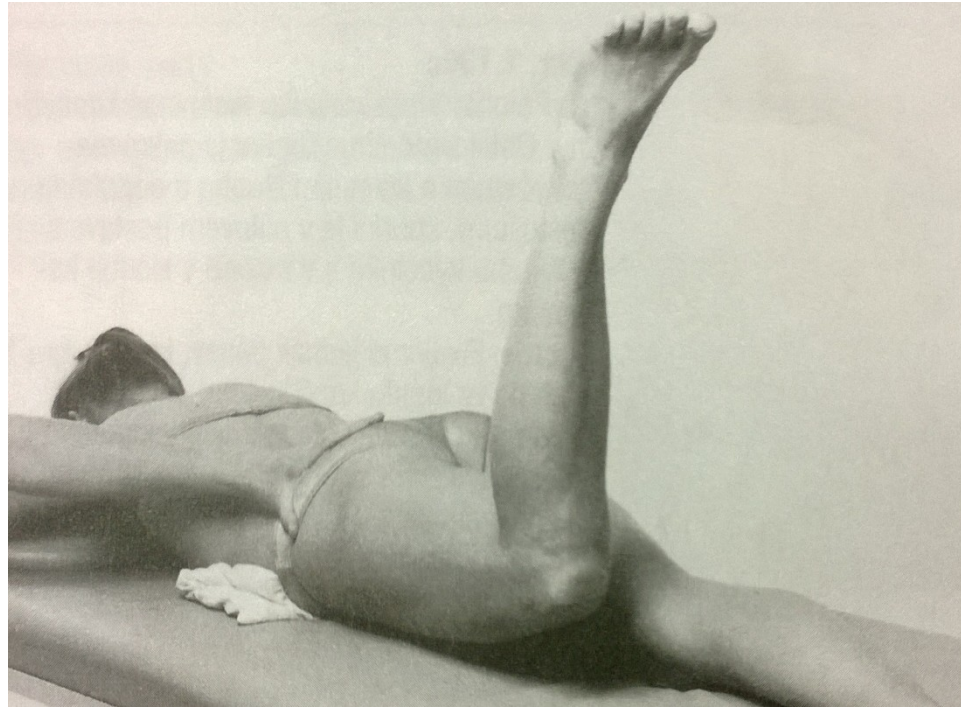
Position: patient lying prone, arms along body side, head lying on the forehead, lower limbs extended (except 90° flexion in the knee of the tested side), foot away from the table (the abdomen underlaid with the pillow to ensure lumbar aplanation)

Fixation: the pelvis on the tested side

Movement: hip extension (in 10° range of motion)

Resistance: on the lower part of the thigh (arched)

Hip extension (gluteus max.) – grade 3

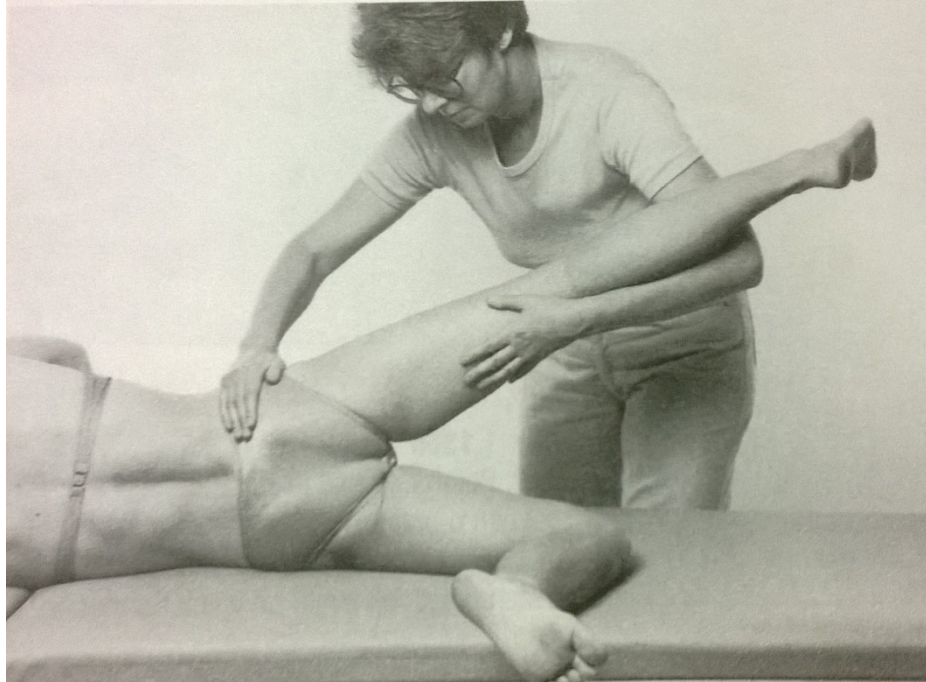

Position: the same as grade 5,4

Fixation: the pelvis on the tested side

Movement: hip extension (in 10° range of motion)

Hip extension (gluteus max.) – grade 2



Position: lying on the tested side, the uninvolved lower limb is supported by PT in slightly flexion and abduction in the hip and slightly flexed in the knee joint, the tested lower limb flexed in the knee joint, central position of the hip

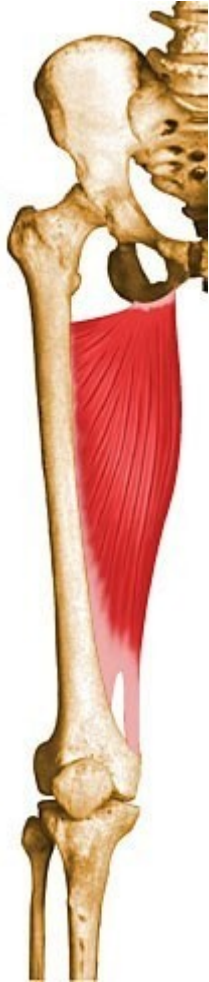Fixation: the pelvis on the untested side

Movement: hip extension (in 10° range of motion)

Hip extension – notes:

- The pelvis has to be fixed by PT (no extension of the lumbar spine as a substitution of hip extension)
- No external rotation or adduction or abduction of the hip joint
- Foot should be away from table

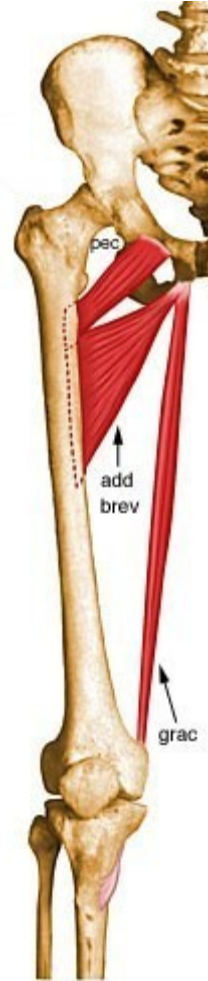
Hip adduction



Adductor
magnus



Adductor
longus



Gracilis
Pectineus

Adductor magnus

Origin

- Inferior pubic ramus, ischial ramus, and inferolateral area of ischial tuberosity

Insertion

- Gluteal tuberosity of femur, medial lip of linea aspera, medial supracondylar ridge, and adductor tubercle

Action

- Powerful thigh adductor
- superior horizontal fibers also help flex the thigh
- vertical fibers help extend the thigh

Innervation

- Posterior division of obturator nerve innervates most of the adductor magnus; vertical or hamstring portion innervated by tibial nerve (L2, L3, L4)

Adductor longus

Origin

- Anterior surface of body of pubis, just lateral to pubic symphysis

Insertion

- Middle third of linea aspera, between the more medial adductor magnus and brevis insertions and the more lateral origin of the vastus medialis

Action

- Adducts and flexes the thigh
- helps to laterally rotate the hip joint

Innervation

- Anterior division of obturator nerve (L2, L3, L4)

Adductor brevis

Origin

- Anterior surface of inferior pubic ramus, inferior to origin of adductor longus

Insertion

- Pectineal line and superior part of medial lip of linea aspera

Action

- Adducts and flexes the thigh
- helps to laterally rotate the thigh

Innervation

- Anterior or posterior division of obturator nerve (L4, L2, L3)

Gracilis

Origin

- Inferior margin of pubic symphysis, inferior ramus of pubis, and adjacent ramus of ischium

Insertion

- Medial surface of tibial shaft, just posterior to sartorius

Action

- Flexes the knee, adducts the thigh
- helps to medially rotate the tibia on the femur

Innervation

- Anterior division of obturator nerve (L2, L3)

Pectineus

Origin

- Pecten pubis and pectineal surface of the pubis

Insertion

- Pectineal line of femur

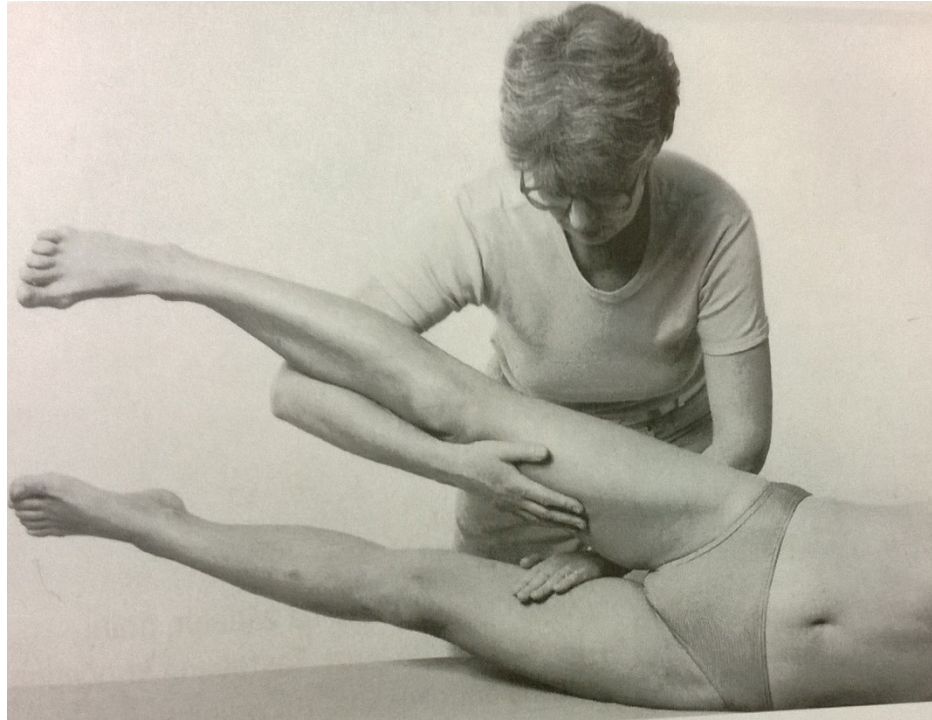Action

- Adducts the thigh and flexes the hip joint

Innervation

- Femoral nerve usually, although it may sometimes receive additional innervation from the obturator nerve as well (L2, L3, L4)

Hip adduction – grade 5,4



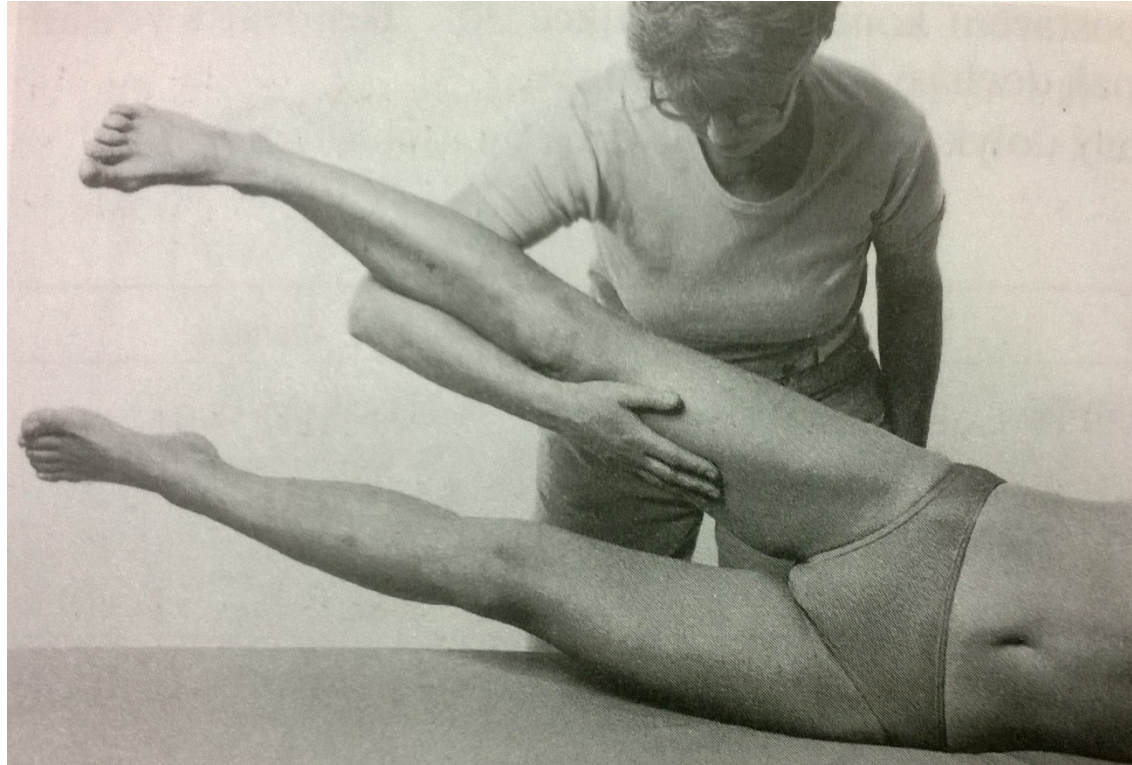
Position: patient lying on the tested side, lower limbs extended, the uninvolved one supported by PT in 30° abduction

Fixation: the uninvolved lower limb in abduction

Movement: adduction of the tested hip joint (by moving the tested lower limb closer to the untested)

Resistance: on the lower part of the thigh

Hip adduction – grade 3

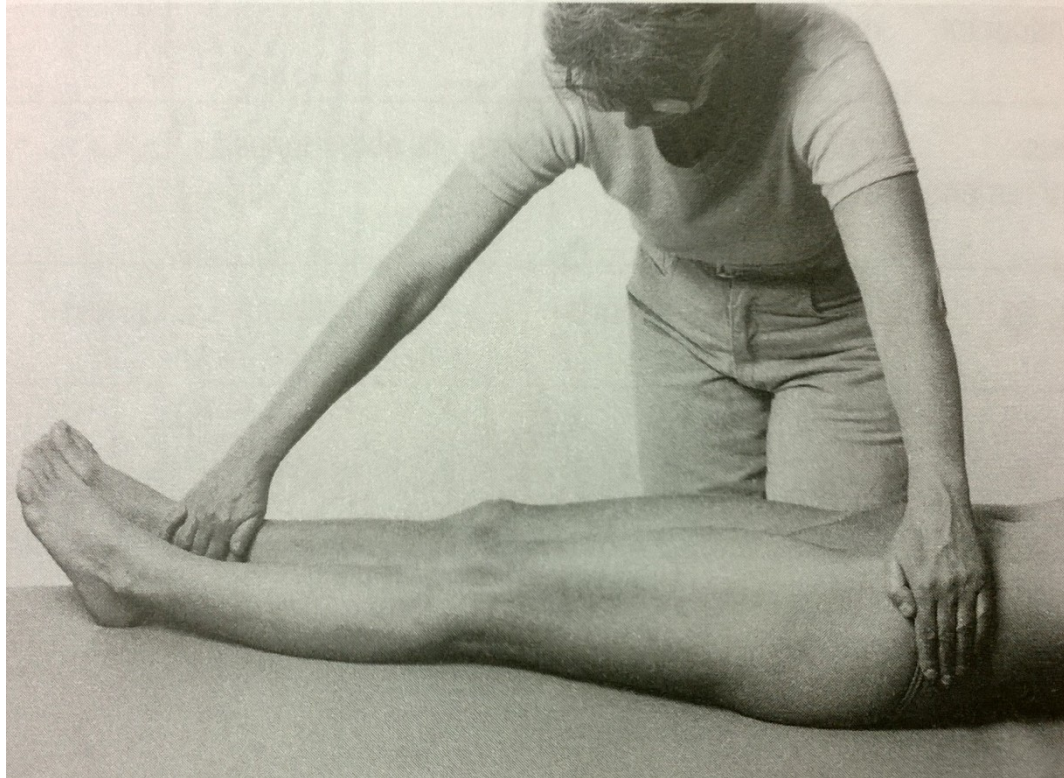


Position: patient lying on the tested side, lower limbs extended, the uninvolved one supported by PT in 30° abduction

Fixation: the uninvolved lower limb in abduction

Movement: adduction of the tested hip joint (by moving the tested lower limb closer to the untested)

Hip adduction – grade 2

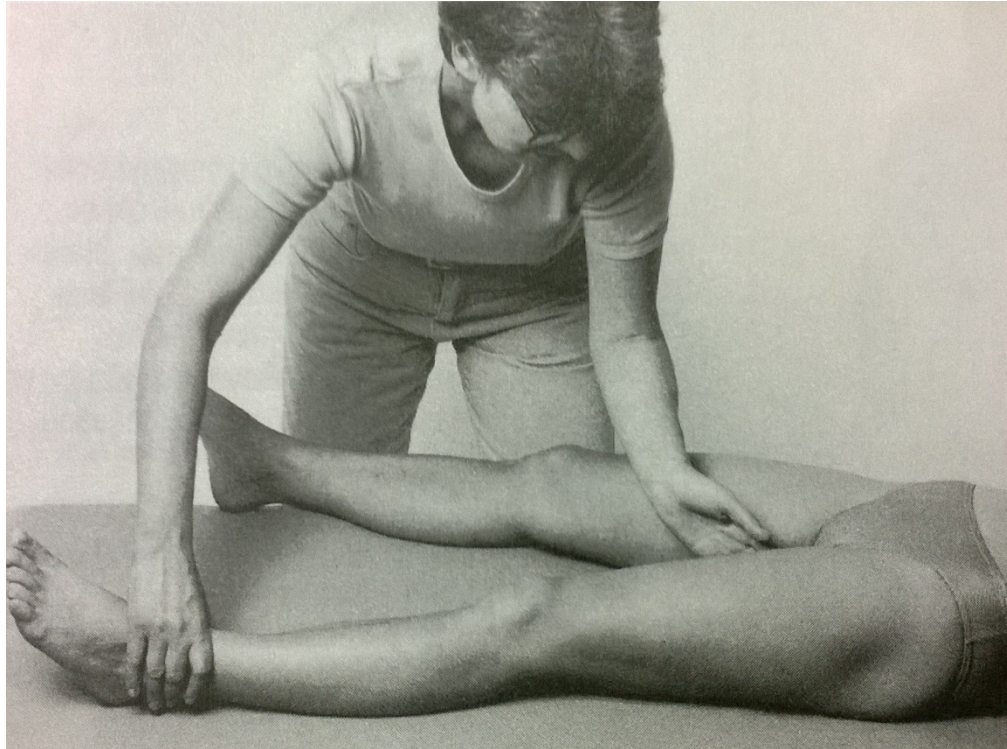


Position: patient lying supine, lower limbs extended and in 30° abduction in hip joint

Fixation: the pelvis on the tested side

Movement: adduction of the tested hip joint – 10-15° (by moving the tested lower limb closer to the untested)

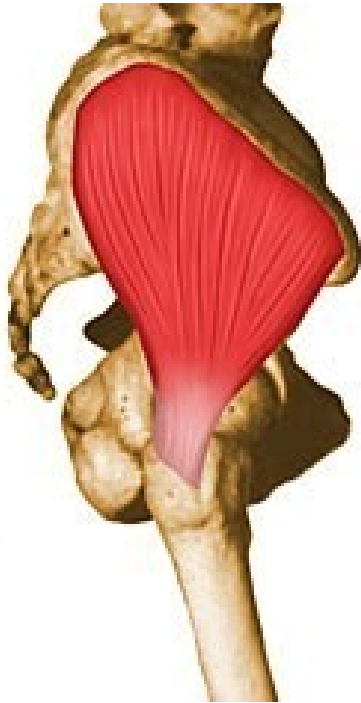
Hip adduction – grade 1,0



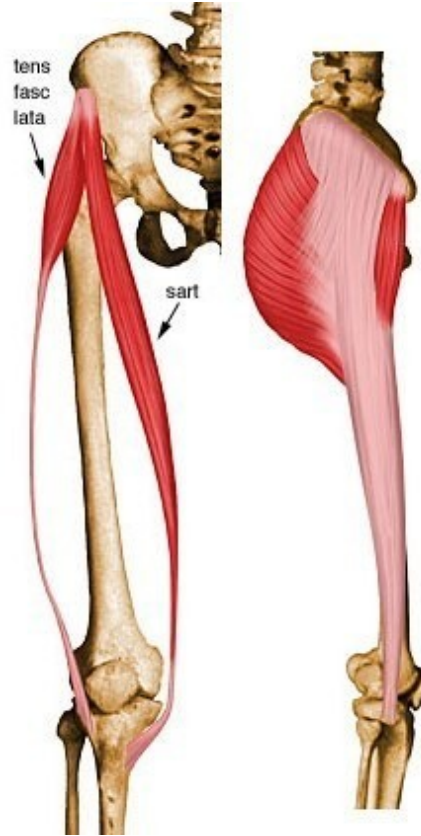
Position: patient lying supine, lower limbs extended and in 30° abduction in hip joint

Attempt to move: PT palpates the trace of contraction during patients attempt to adduct the hip (at the inner side of thigh)

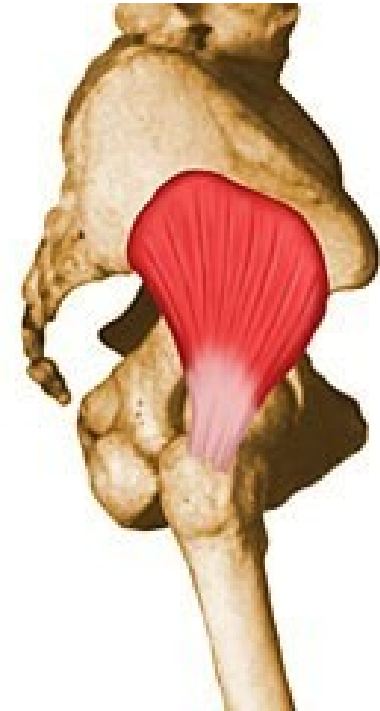Hip abduction



Gluteus
medius



Tensor
fasciae latae



Gluteus
minimus

Gluteus medius

Origin

- Dorsal ilium inferior to iliac crest

Insertion

- Lateral and superior surfaces of greater trochanter

Action

- Major abductor of thigh
- anterior fibers help to rotate hip medially
- posterior fibers help to rotate hip laterally

Innervation

- Superior gluteal nerve (L4, L5, S1) (L4, L5, S1)

Tensor fasciae latae

Origin

- Anterior superior iliac spine, outer lip of anterior iliac crest and fascia lata

Insertion

- Iliotibial band

Action

- Helps stabilize and steady the hip and knee joints by putting tension on the iliotibial band of fascia

Innervation

- Superior gluteal nerve (L4, L5, S1) (L4, L5, S1)

Gluteus minimus

Origin

- Dorsal ilium between inferior and anterior gluteal lines; also from edge of greater sciatic notch

Insertion

- Anterior surface of greater trochanter

Action

- Abducts and medially rotates the hip joint

Innervation

- Superior gluteal nerve (L4, L5, S1) (L4, L5, S1)

Hip abduction – grade 5,4



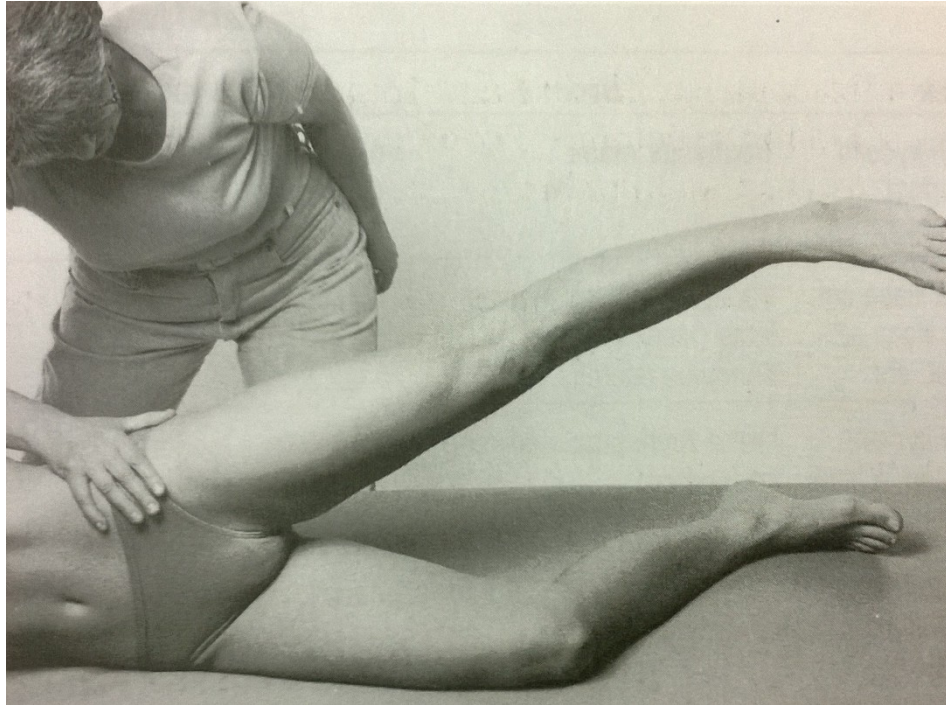Position: patient lying on the untested side, the untested lower limb slightly flexed in knee and hip joint, the tested lower limb extended

Fixation: pelvis on the tested side

Movement: hip abduction in full range of motion

Resistance: on the lower part of the thigh

Hip abduction – grade 3

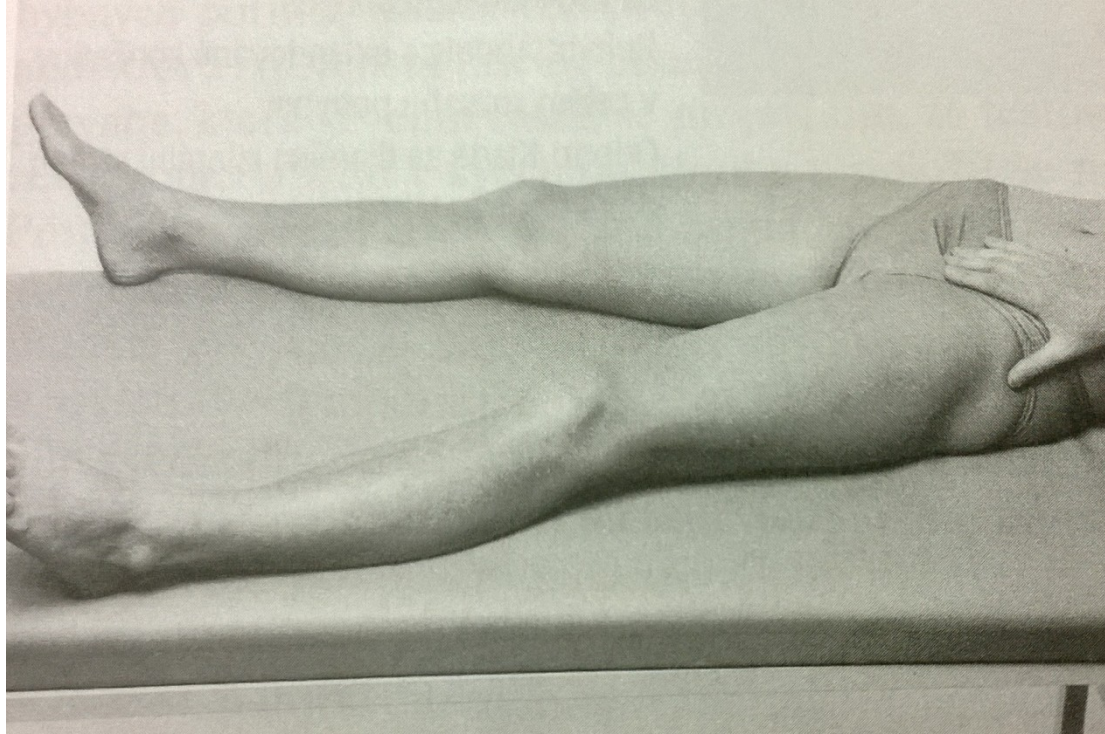


Position: patient lying on the untested side, the untested lower limb slightly flexed in knee and hip joint, the tested lower limb extended

Fixation: pelvis on the tested side

Movement: hip abduction in full range of motion

Hip abduction – grade 2

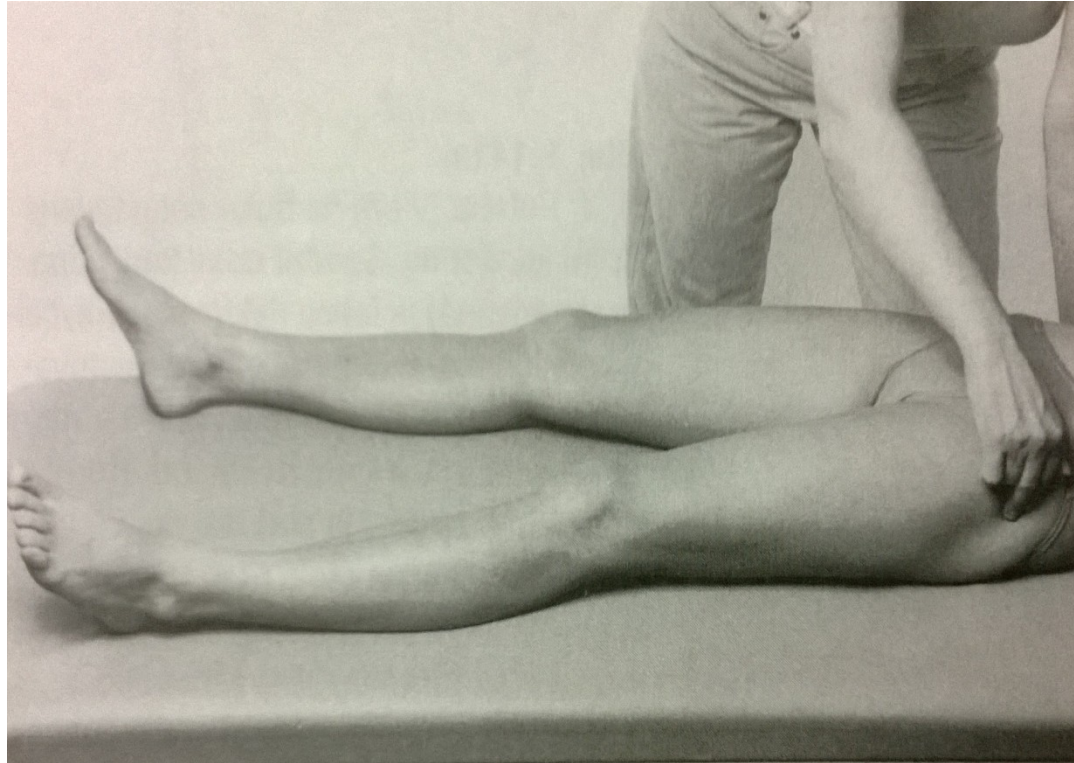


Position: patient lying supine, lower limb extended (the untested one slightly abducted)

Fixation: pelvis on the tested side

Movement: hip abduction in full range of motion

Hip abduction – grade 1,0



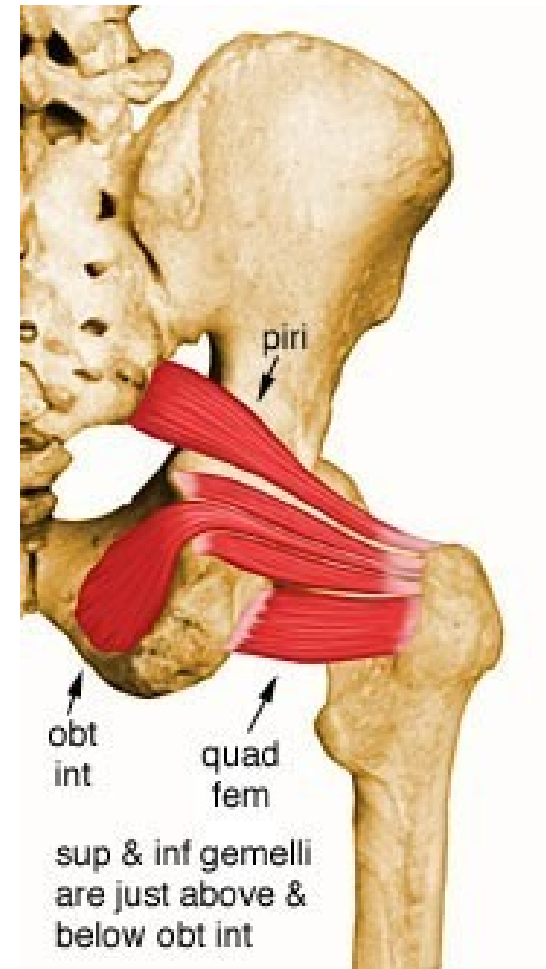
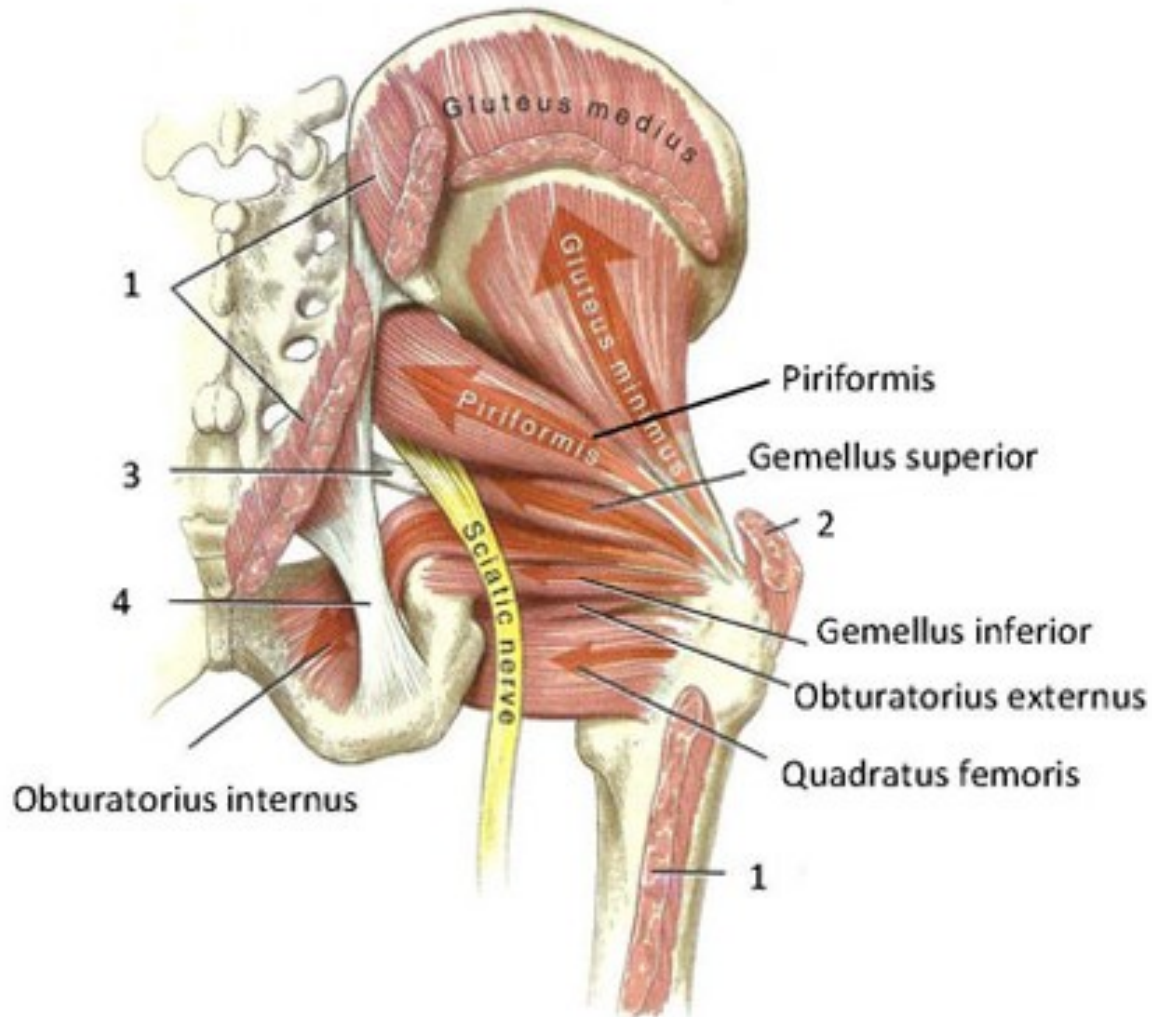
Position: patient lying supine, lower limb extended

Attempt to move: PT palpates a trace of contraction during patients attempt to abduct a hip (over the trochanter major)

Hip abduction – notes:

- The fixation of the pelvis is necessary (no elevation of the pelvis should be allowed)
- No external rotation or flexion in the hip joint (substitution of iliopsoas and tensor fasciae latae)
- Proper range of motion and proper direction of movement should be kept
- No anteversion of the pelvis or hyperlordosis of the lumbar spine

Hip external rotation



Quadratus femoris

Origin

- Lateral margin of obturator ring above ischial tuberosity

Insertion

- Quadrate tubercle and adjacent bone of intertrochanteric crest of proximal posterior femur

Action

- Rotates the hip laterally; also helps adduct the hip

Innervation

- Quadratus femoris branch of nerve to the quadratus femoris and inferior gemellus (L5, S1) (L5, S1)

Piriformis

Origin

- Anterior surface of lateral process of sacrum and gluteal surface of ilium at the margin of the greater sciatic notch

Insertion

- Superior border of greater trochanter

Action

- Lateral rotator of the hip joint
- helps abduct the hip if it is flexed

Innervation

- Piriformis nerve (L5, S1, S2) (L5, S1, S2)

Gemellus superior

Origin

- Ischial spine

Insertion

- Medial surface of greater trochanter of femur, in common with obturator internus

Action

- Rotates the thigh laterally
- helps abduct the flexed thigh

Innervation

- Nerve to the obturator internus and superior gemellus -- a branch of the sacral plexus (L5, S1) (L5, S1)

Gemellus inferior

Origin

- Posterior portions of ischial tuberosity and lateral obturator ring

Insertion

- Medial surface of greater trochanter of femur, in common with obturator internus

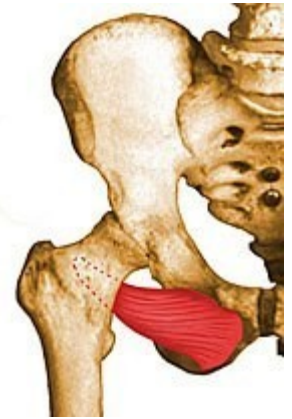Action

- Rotates the thigh laterally
- helps abduct the flexed thigh

Innervation

- Nerve to the obturator internus and inferior gemellus -- a branch of the sacral plexus (L5, S1) (L5, S1)

Obturatorius externus



Origin

- External surface of obturator membrane and anterior bony margins of obturator foramen

Insertion

- Posteromedial surface of greater trochanter of femur

Action

- Rotates the thigh laterally; also helps adduct thigh

Innervation

- Posterior division of obturator nerve innervates most of the adductor magnus; vertical or hamstring portion innervated by tibial nerve (L3, L4)

Obturatorius internus

Origin

- Internal surface of obturator membrane
- posterior bony margins of obturator foramen

Insertion

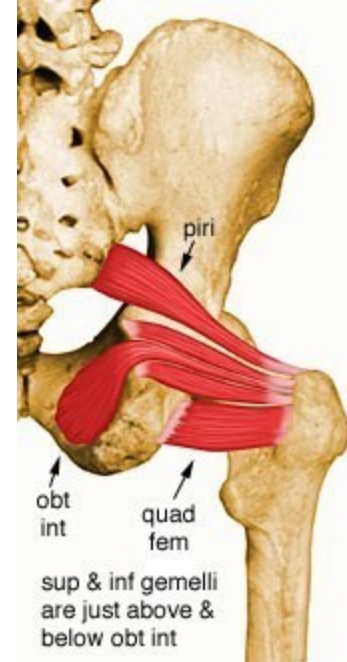
- Medial surface of greater trochanter of femur, in common with superior and inferior gemelli

Action

- Rotates the thigh laterally
- helps abduct the thigh when it is flexed

Innervation

- Nerve to the obturator internus and superior gemellus -- a branch of the sacral plexus (L5, S1) (L5, S1)



Gluteus maximus

Origin

- Posterior aspect of dorsal ilium posterior to posterior gluteal line, posterior superior iliac crest, posterior inferior aspect of sacrum and coccyx, and sacrotuberous ligament

Insertion

- Primarily in fascia lata at the iliotibial band
- also into the gluteal tuberosity on posterior femoral surface

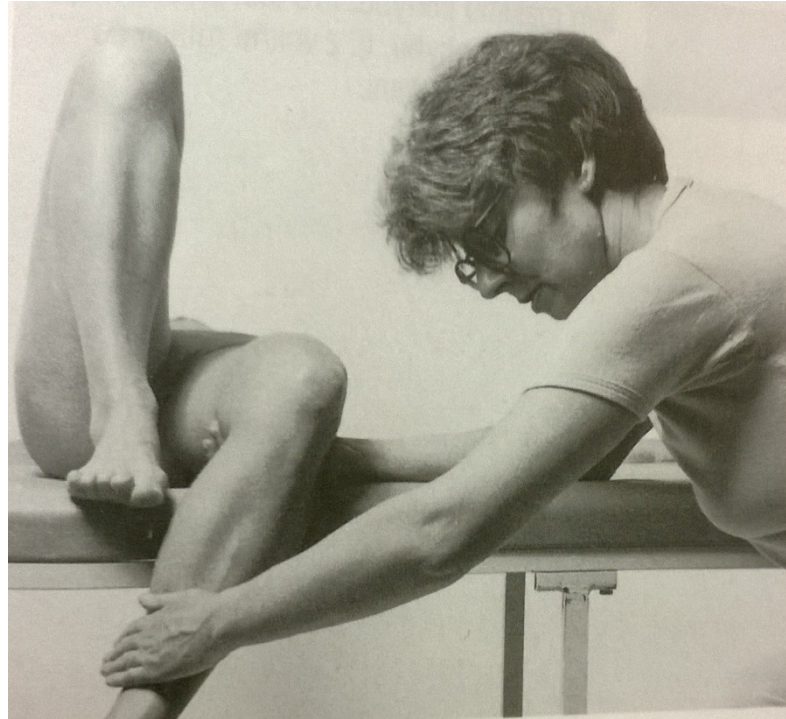Action

- Major extensor of hip joint, assists in laterally rotating the thigh
- upper and middle third section of the muscle are abductors

Innervation

- Inferior gluteal nerve (L5, S1, S2) (L5, S1, S2)

Hip external rotation – grade 5,4



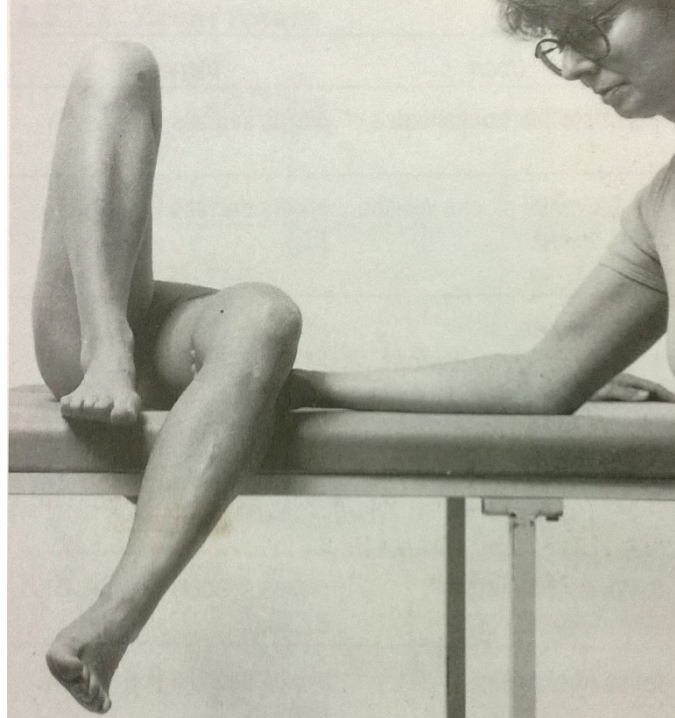
Position: patient lying supine, the shank of the tested lower limb hanging from the table, the untested lower limb flexed in hip and knee joint, foot on the table

Fixation: dorsal side of the lower part of the thigh

Movement: hip external rotation in full range of motion (40-50°)

Resistance: at the inner side of the lower shank

Hip external rotation – grade 3

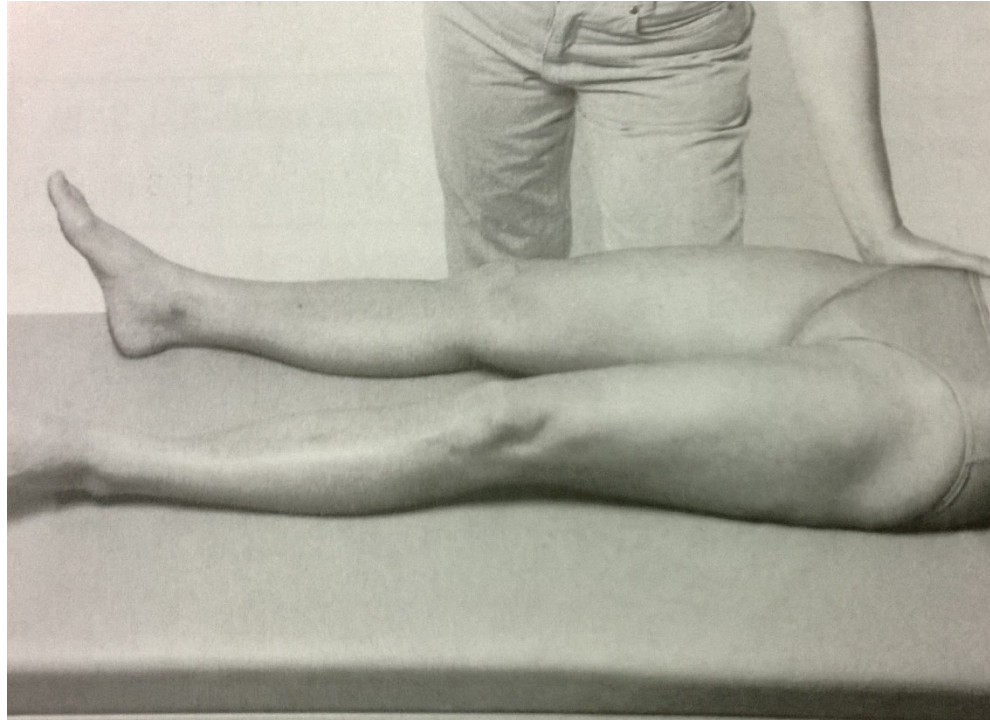


Position: patient lying supine, the shank of the tested lower limb hanging from the table, the untested lower limb flexed in hip and knee joint, foot on the table

Fixation: dorsal side of the lower part of the thigh

Movement: hip external rotation in full range of motion (40-50°)

Hip external rotation – grade 2

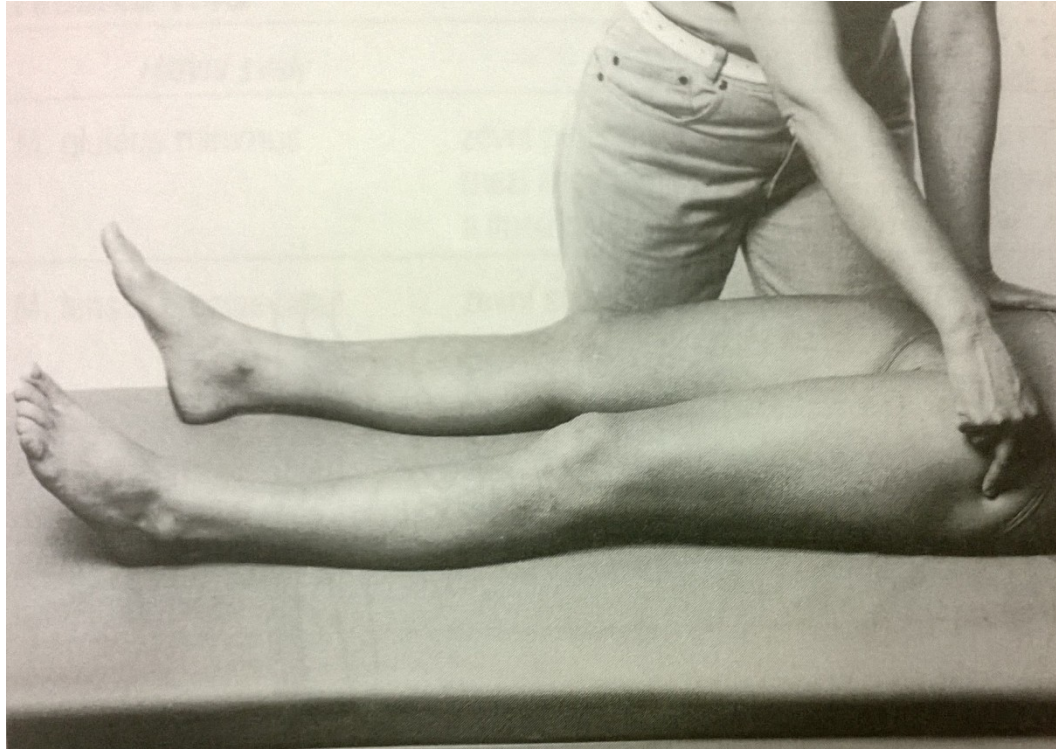


Position: patient lying supine, lower limbs extended and slightly abducted, the tested one inner rotated

Fixation: pelvis on the untested side

Movement: hip external rotation in full range of motion (40-50°)

Hip external rotation – grade 1,0



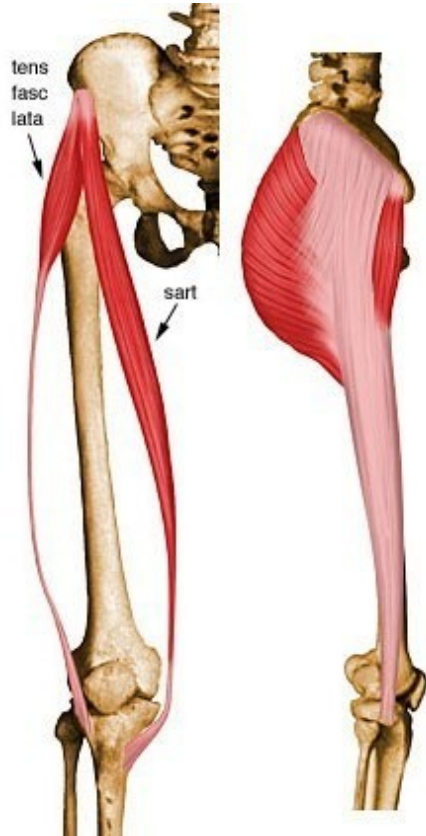
Position: patient lying supine, lower limbs extended

Attempt to move: PT palpates a trace of contraction during patients attempt of hip external rotation (at the area of trochanter major) and observes the attempt to move the leg outward

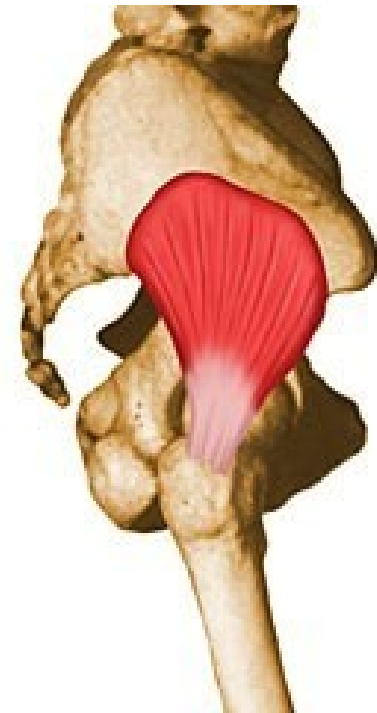Hip external rotation – notes:

- No adduction and flexion of the hip joint
- No supination of the foot

Hip internal rotation




Tensor fasciae latae



Gluteus minimus

Hip internal rotation – grade 5,4




Position: patient lying supine, the shank of the tested lower limb hanging from the table, the untested lower limb flexed in hip and knee joint, foot on the table

Fixation: dorsal side of the lower part of the thigh

Movement: hip internal rotation in full range of motion (approximately 30°)

Resistance: at the outer side of the lower shank

Hip internal rotation – grade 3

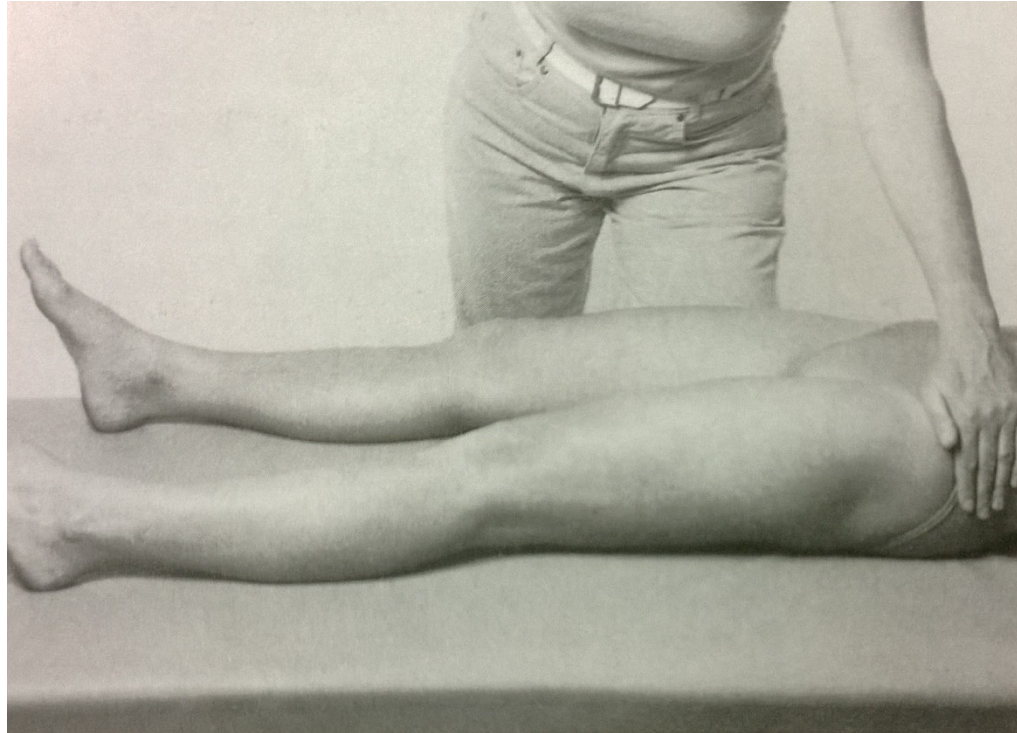


Position: patient lying supine, the shank of the tested lower limb hanging from the table, the untested lower limb flexed in hip and knee joint, foot on the table

Fixation: dorsal side of the lower part of the thigh

Movement: hip internal rotation in full range of motion (30°)

Hip internal rotation – grade 2

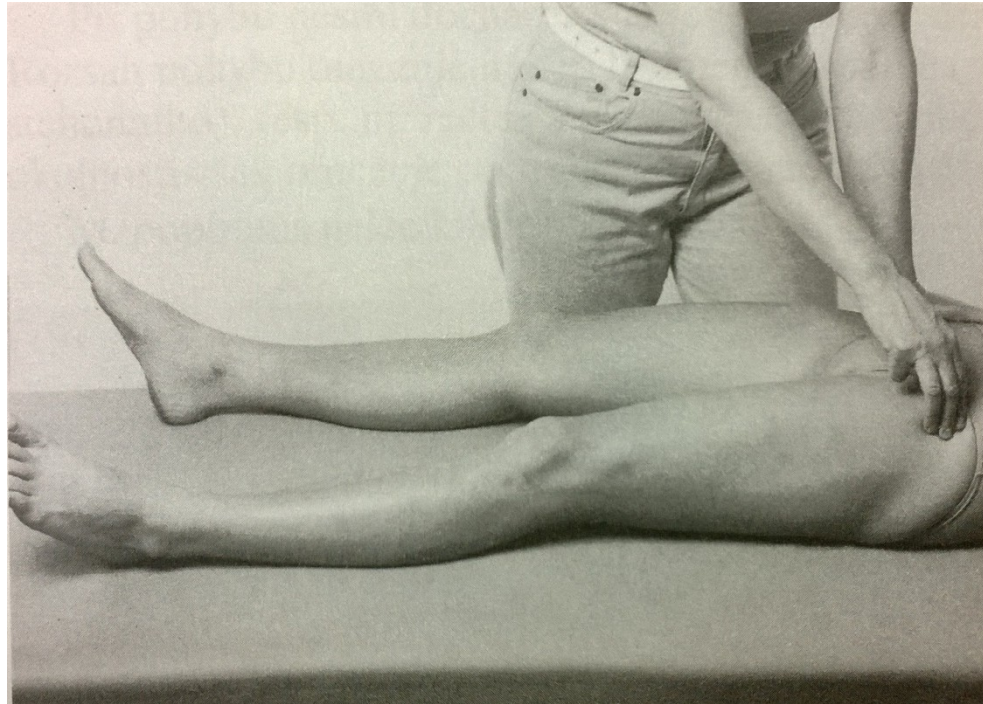


Position: patient lying supine, lower limbs extended and slightly abducted, the tested one outer rotated

Fixation: pelvis on the tested side

Movement: hip internal rotation in full range of motion

Hip internal rotation – grade 1,0



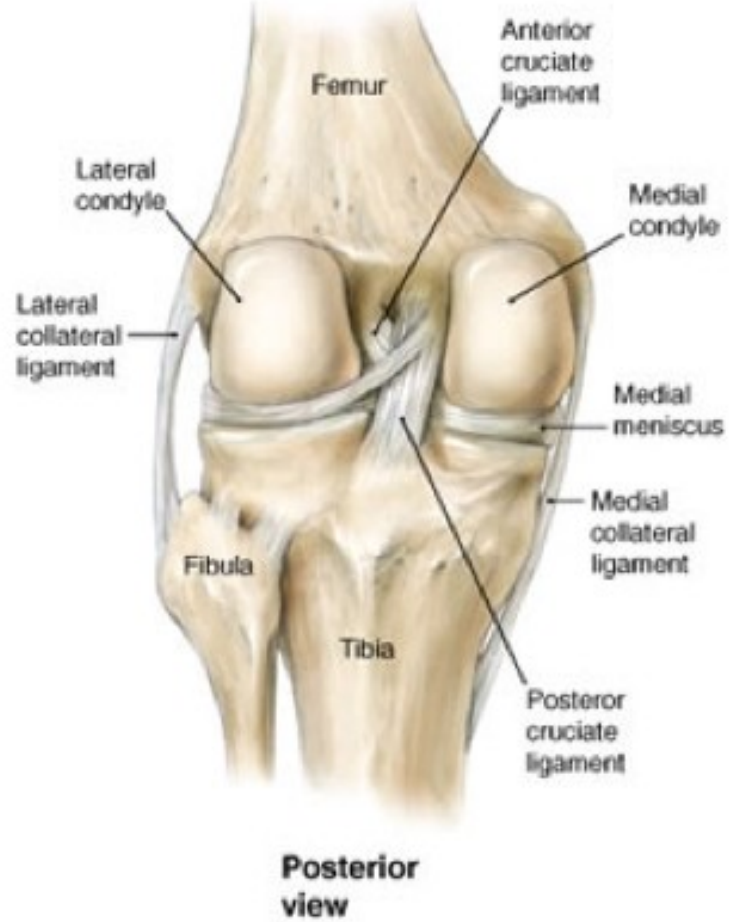
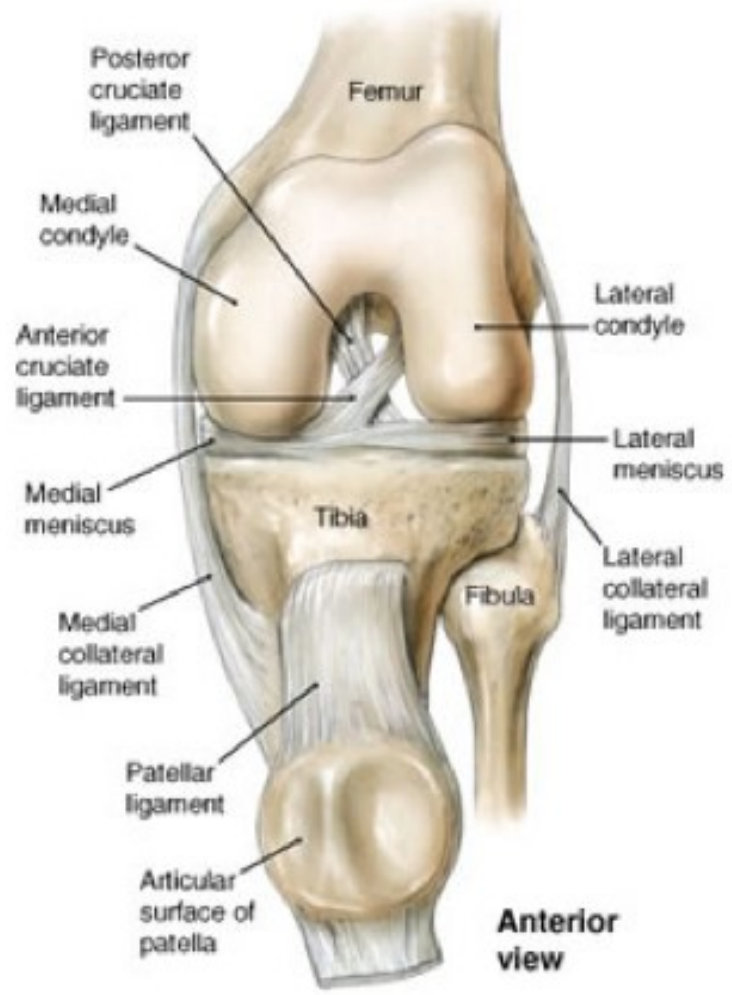
Position: patient lying supine, lower limbs extended

Attempt to move: PT palpates a trace of contraction during patients attempt of hip internal rotation (at the area of trochanter major) and observes the attempt to move the leg inward

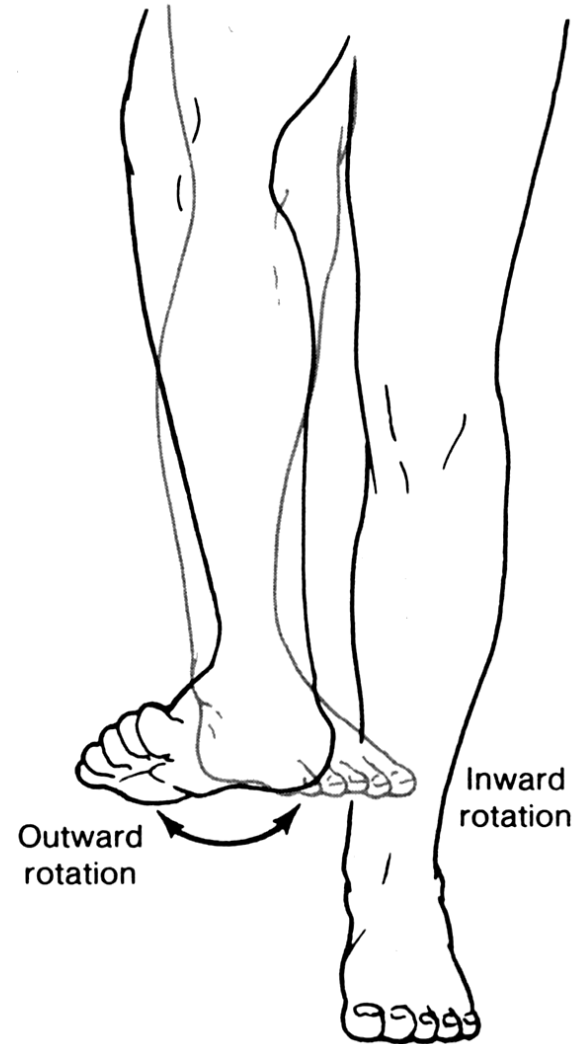
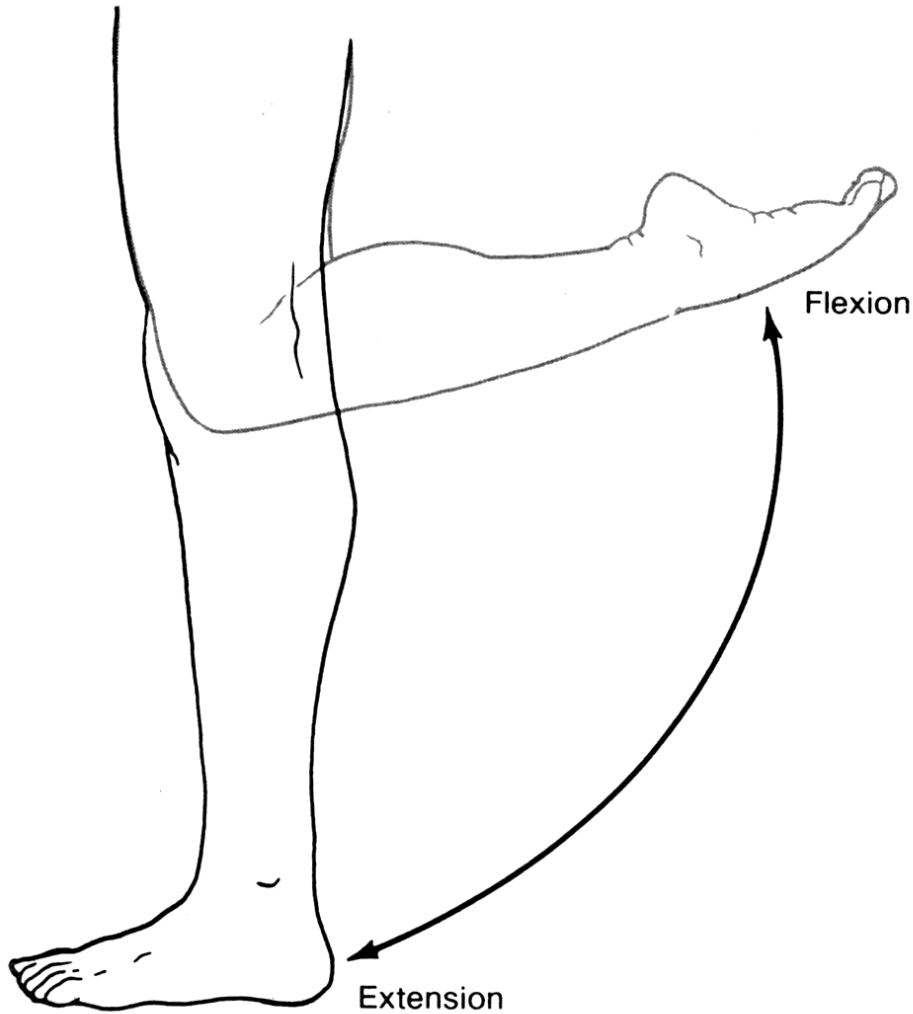
Hip internal rotation

- Fixation of the pelvis is necessary, proper position of the lower extremity
- No adduction or supination of the foot

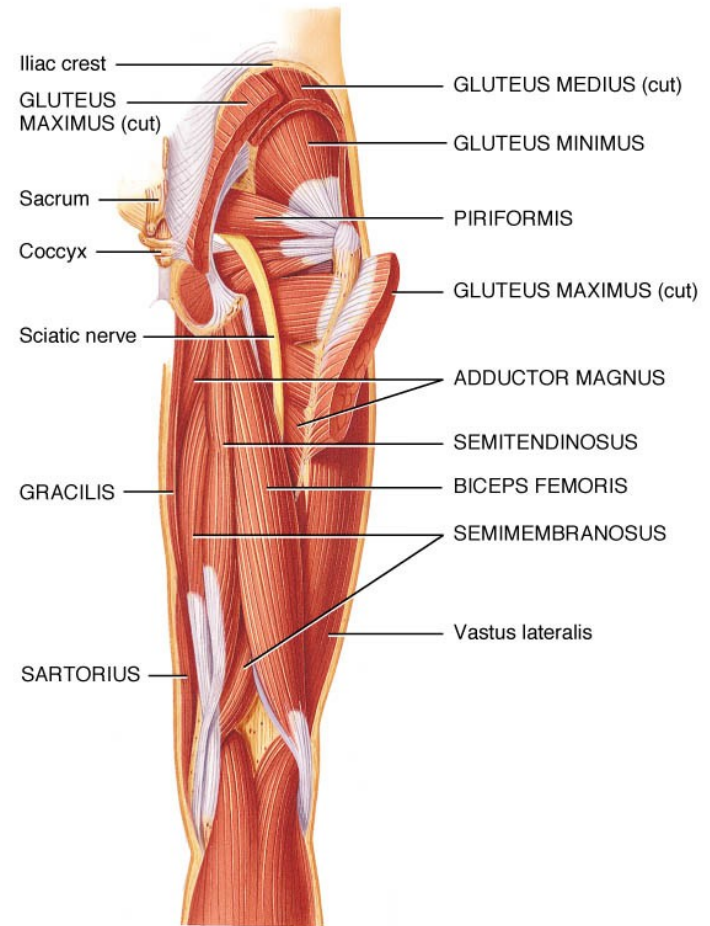
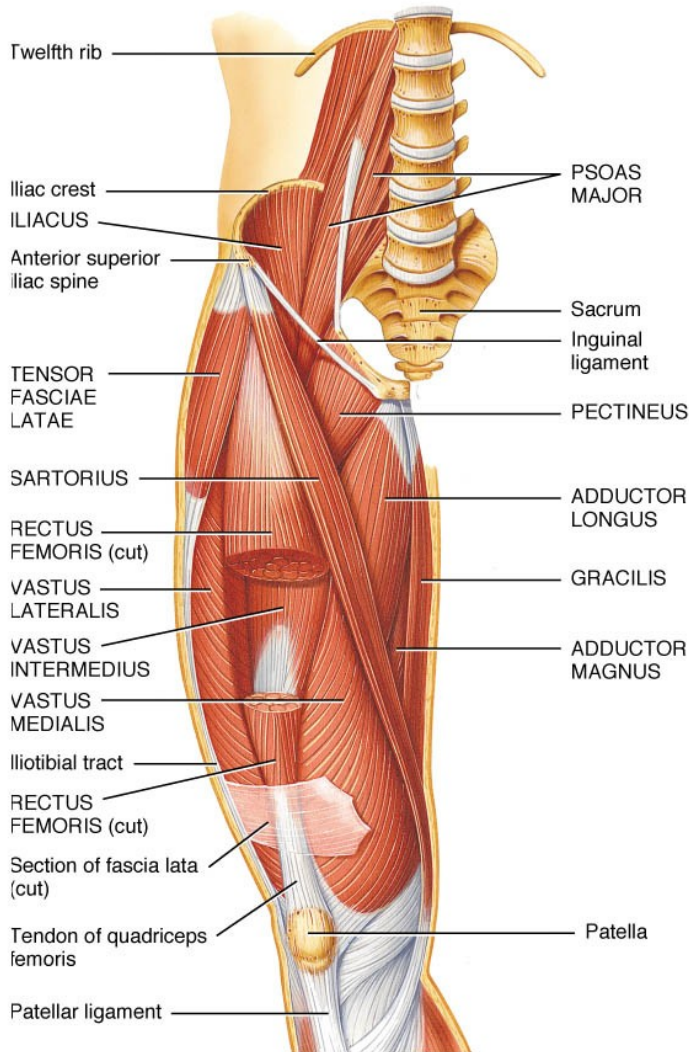
Knee joint



Knee joint movements



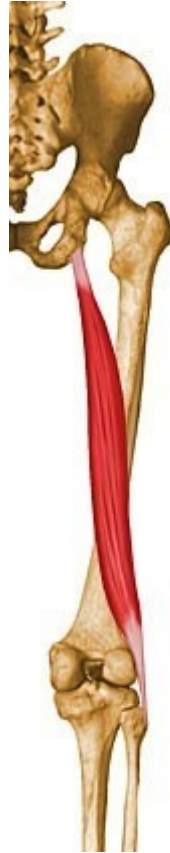Knee joint muscles



Knee flexion



Biceps femoris
(short head)



Biceps femoris
(long head)



Semitendinosus
Semimembranosus



Biceps femoris - long head

Origin

- Common tendon with semitendinosus from superior medial quadrant of the posterior portion of the ischial tuberosity

Insertion

- Primarily on fibular head
- also on lateral collateral ligament and lateral tibial condyle

Action

- Flexes the knee, and also rotates the tibia laterally
- long head also extends the hip joint

Innervation

- Tibial nerve (L5, S1, S2)

Biceps femoris – short head

Origin

- Lateral lip of linea aspera, lateral supracondylar ridge of femur, and lateral intermuscular septum of thigh

Insertion

- Primarily on fibular head; also on lateral collateral ligament and lateral tibial condyle

Action

- Flexes the knee, and also rotates the tibia laterally
- long head also extends the hip joint

Innervation

- Common peroneal nerve (L5, S1, S2)

Semitendinosus

Origin

- From common tendon with long head of biceps femoris from superior medial quadrant of the posterior portion of the ischial tuberosity

Insertion

- Superior aspect of medial portion of tibial shaft

Action

- Extends the thigh and flexes the knee
- rotates the tibia medially, especially when the knee is flexed

Innervation

- Tibial nerve (L5, S1, S2)

Semimembranosus

Origin

- Superior lateral quadrant of the ischial tuberosity

Insertion

- Posterior surface of the medial tibial condyle

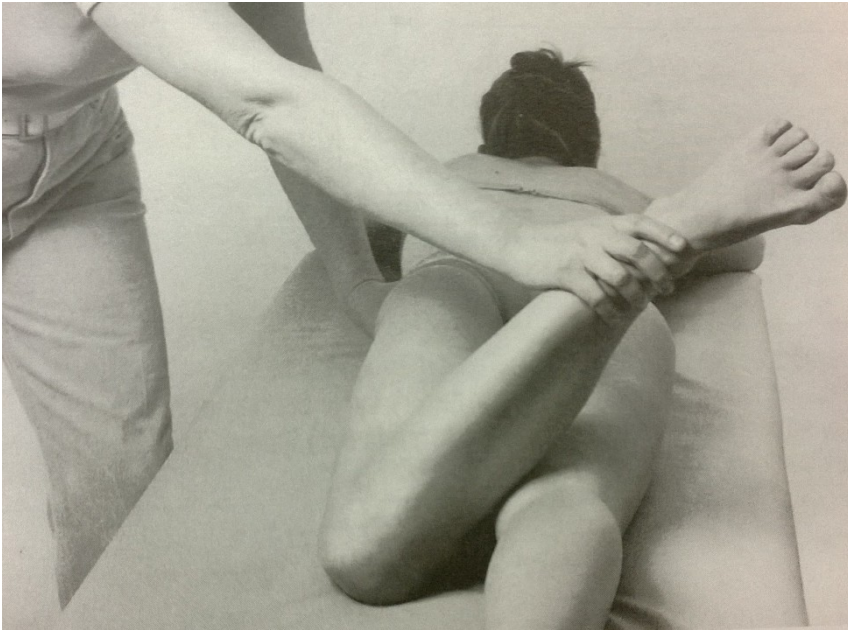
Action

- Extends the thigh, flexes the knee
- rotates the tibia medially, especially when the knee is flexed

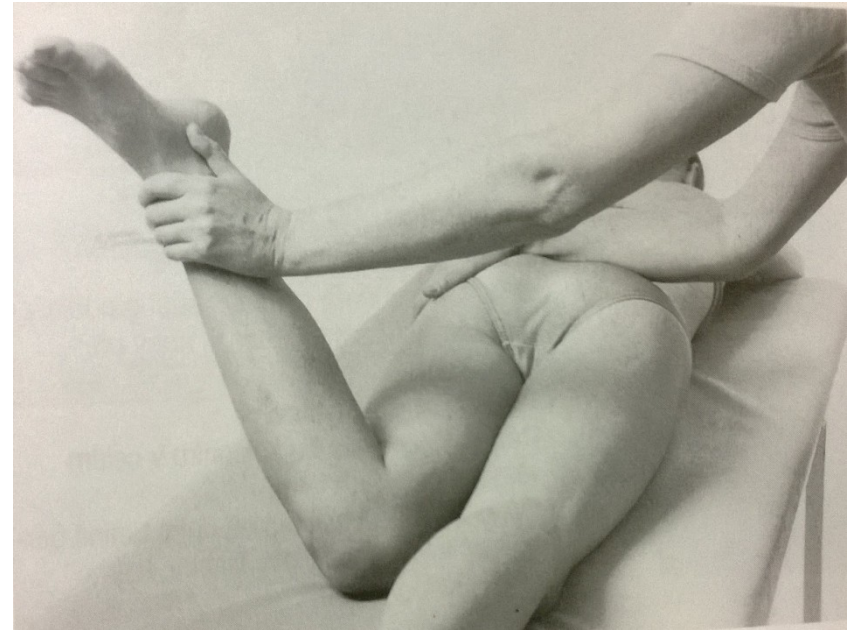Innervation

- Tibial nerve (L5, S1, S2)

Knee flexion

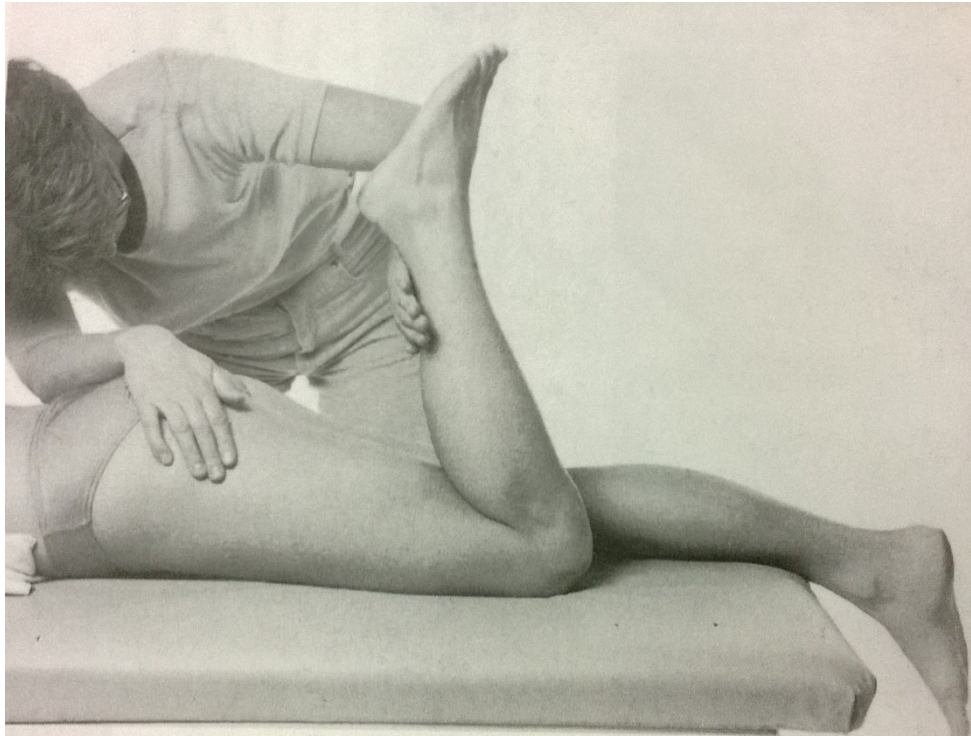

Knee flexion with external rotation
(biceps femoris)



Knee flexion with internal rotation
(semitendinosus, semimembranosus)

Knee flexion – grade 5,4



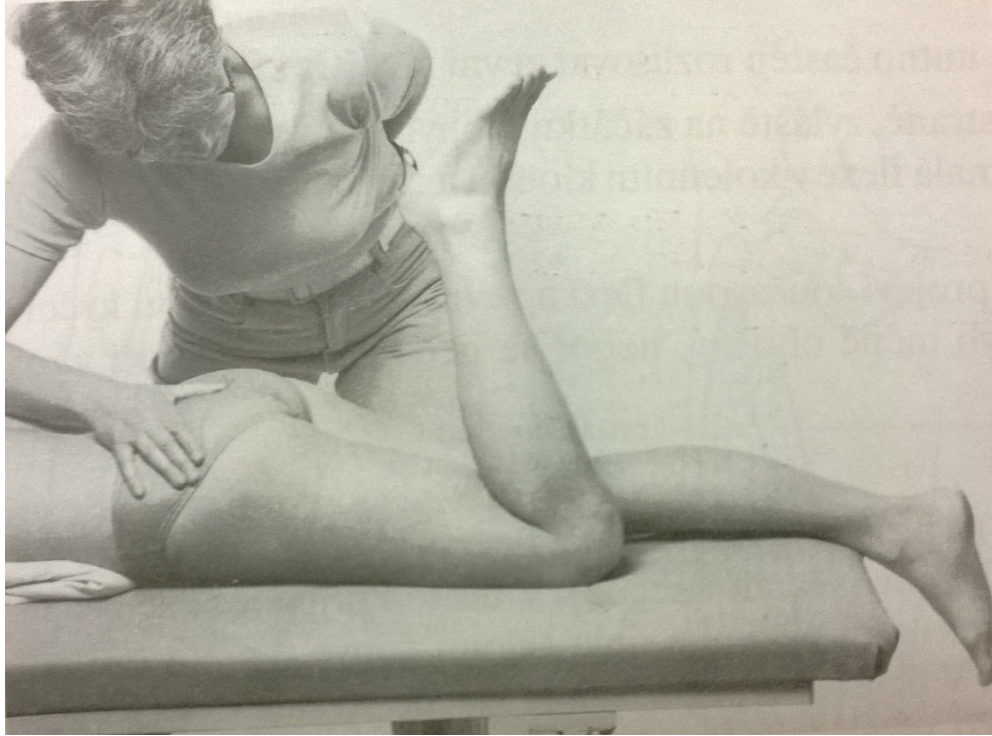
Position: patient lying supine, abdomen underlaid with pillow, lower limb extended, feet away from the table

Fixation: the pelvis

Movement: knee flexion in full range of motion

Resistance: at the lower part of the shank (arched)

Knee flexion – grade 3



Position: patient lying supine, abdomen underlaid with pillow, lower limb extended, feet away from the table

Fixation: the pelvis

Movement: knee flexion in full range of motion

Knee flexion – grade 2

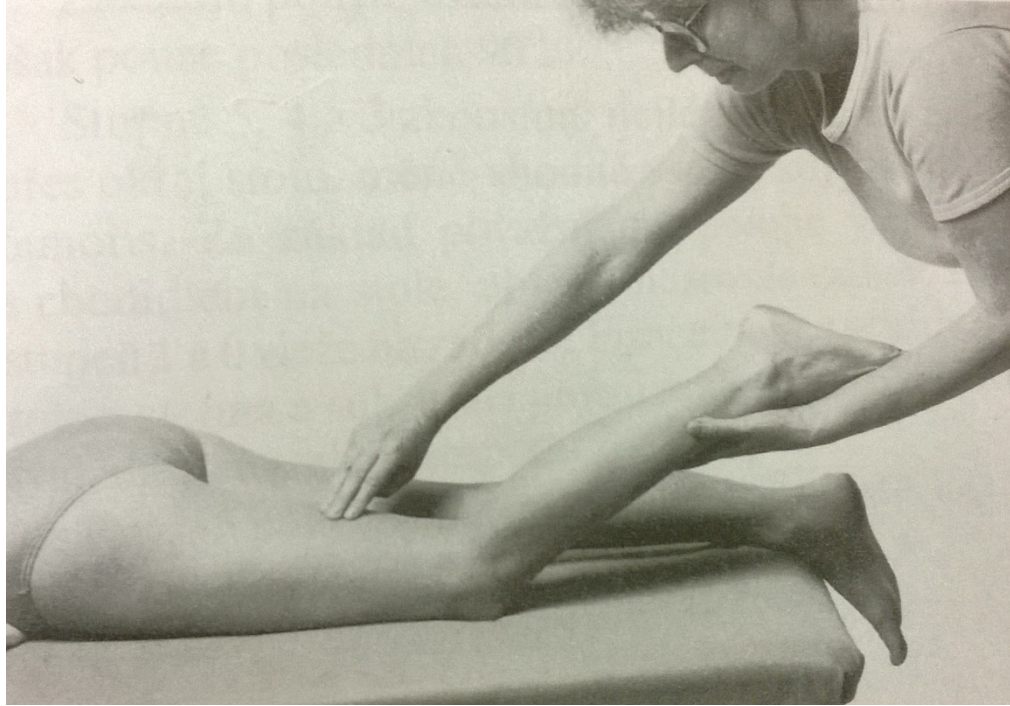


Position: patient lying on the tested side, untested lower limb extended and slightly abducted in the hip, extended in the knee

Fixation: PT supports the untested lower limb, fix the the pelvis on the untested side

Movement: knee flexion in full range of motion

Knee flexion – grade 1,0



Position: patient lying supine, abdomen underlaid with pillow, untested lower limb extended with foot away from the table, tested lower limb supported in slightly knee flexion

Attempt to move: PT palpates a trace of contraction during patient's attempt to flex the knee joint (at the dorsal part of the thigh)

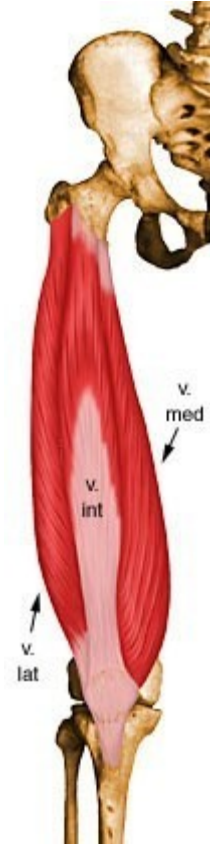
Knee flexion – notes:

- Distinguish knee flexion with external and internal rotation if necessary
- No movement of the pelvis (anteversion)
- No movement of the hip joint (no rotation)

Knee extension – quadriceps femoris



Rectus
femoris



Vastus
medialis

Vastus
lateralis

Vastus
intermedius

Rectus femoris

Origin

- Straight head from anterior inferior iliac spine; reflected head from groove just above acetabulum

Insertion

- Base of patella to form the more central portion of the quadriceps femoris tendon

Action

- Extends the knee

Innervation

- Muscular branches of femoral nerve (L2, L3, L4)

Vastus medialis

Origin

- Inferior portion of intertrochanteric line, spiral line, medial lip of linea aspera, superior part of medial supracondylar ridge of femur, and medial intermuscular septum

Insertion

- Medial base and border of patella; also forms the medial patellar retinaculum and medial side of quadriceps femoris tendon

Action

- Extends the knee

Innervation

- Muscular branches of femoral nerve (L2, L3, L4)

Vastus lateralis

Origin

- Superior portion of intertrochanteric line, anterior and inferior borders of greater trochanter, superior portion of lateral lip of linea aspera, and lateral portion of gluteal tuberosity of femur

Insertion

- Lateral base and border of patella; also forms the lateral patellar retinaculum and lateral side of quadriceps femoris tendon

Action

- Extends the knee

Innervation

- Muscular branches of femoral nerve (L2, L3, L4)

Vastus intermedius

Origin

- Superior 2/3 of anterior and lateral surfaces of femur; also from lateral intermuscular septum of thigh

Insertion

- Lateral border of patella; also forms the deep portion of the quadriceps tendon

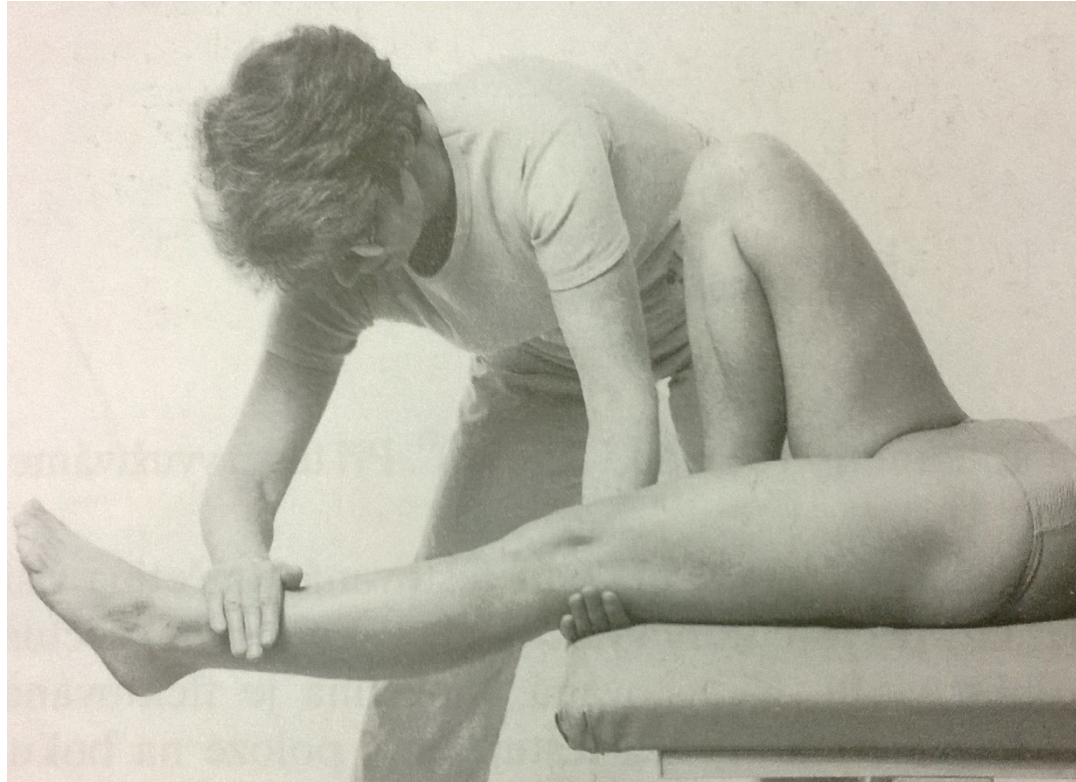
Action

- Extends the knee

Innervation

- Muscular branches of femoral nerve (L2, L3, L4)

Knee extension – grade 5,4



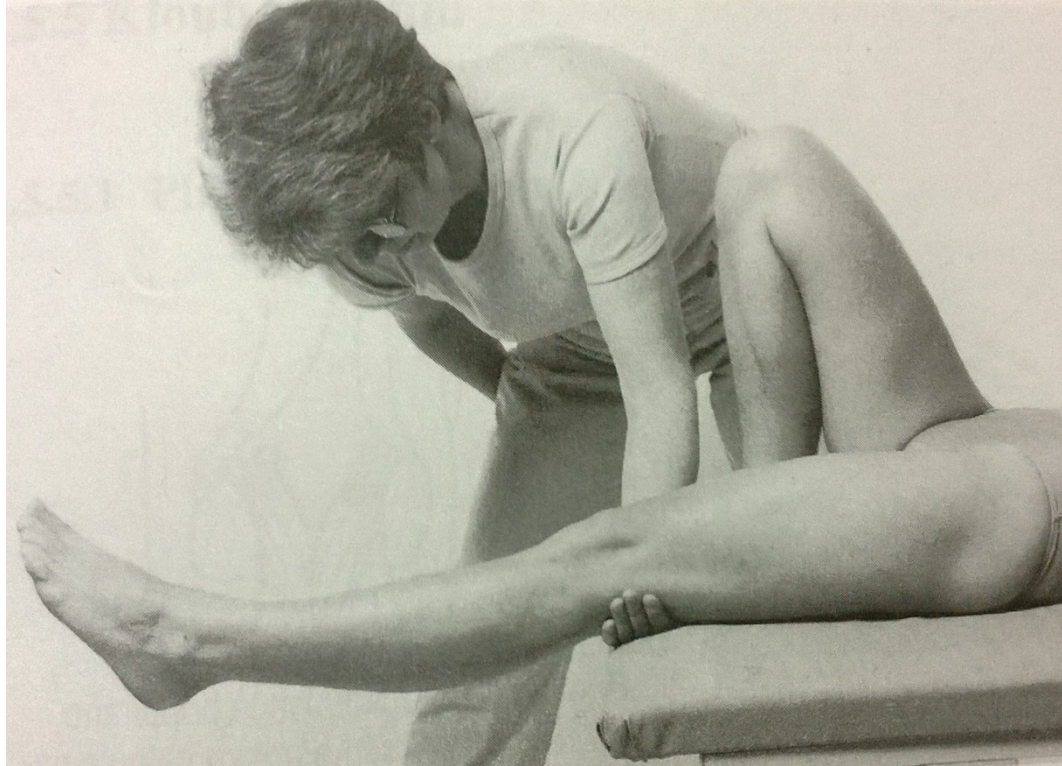Position: patient lying supine, shank of the tested lower limb hanging from the table, untested lower limb flexed in knee and hip joint, foot on the table

Fixation: the lower part of the dorsal side of thigh

Movement: knee extension from 90° flexion to full extension

Resistance: at the frontal part of the distal shank

Knee extension – grade 3




Position: patient lying supine, shank of the tested lower limb hanging from the table, untested lower limb flexed in knee and hip joint, foot on the table

Fixation: the lower part of the dorsal side of thigh

Movement: knee extension from 90° flexion to full extension

Knee extension – grade 2

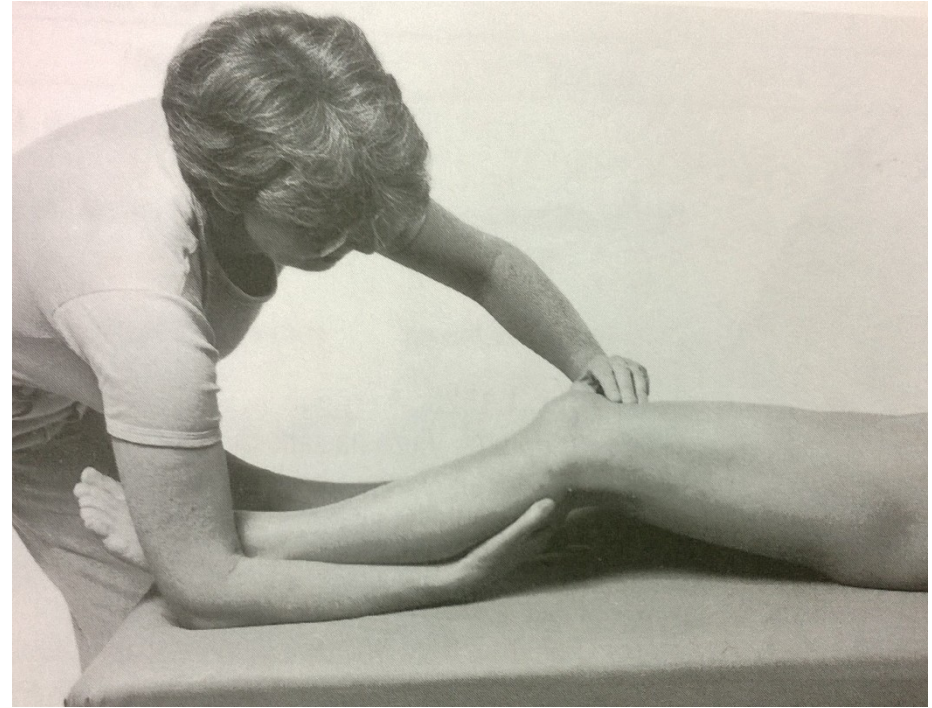
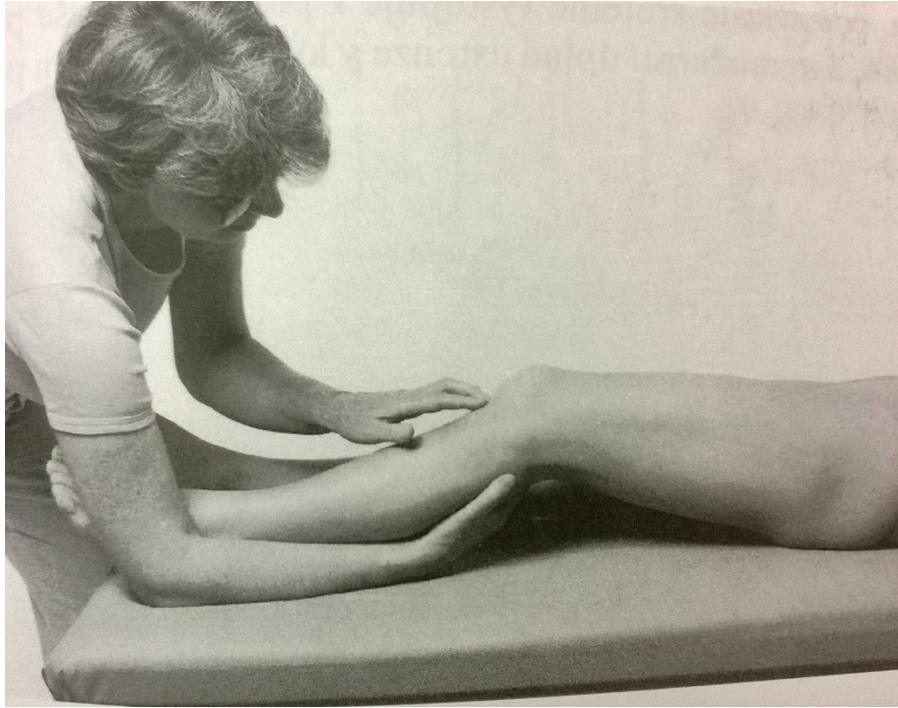


Position: patient lying on the tested side, untested lower limb in knee extension, hip slightly abducted – PT supports the position, tested lower limb in 90° knee flexion, hip extension

Fixation: pelvis on the untested side

Movement: from 90° flexion to full extension of the knee joint

Knee extension – grade 1,0



Position: patient lying supine, untested lower limb in extension, tested lower limb slightly flexed in knee and hip joint (supported by PT)

Attempt to move: PT palpates a trace of contraction during patients attempt of knee extension (at the ligament patellae or quadriceps muscle area)

Knee extension – notes:

- No swing at the start of the movement
- No rotation of the hip joint
- No retroversion of the pelvis
- Do the movement to full extension
- Don't fix the thigh from above (don't touch quadriceps muscle)

Thank you for your attention 😊

