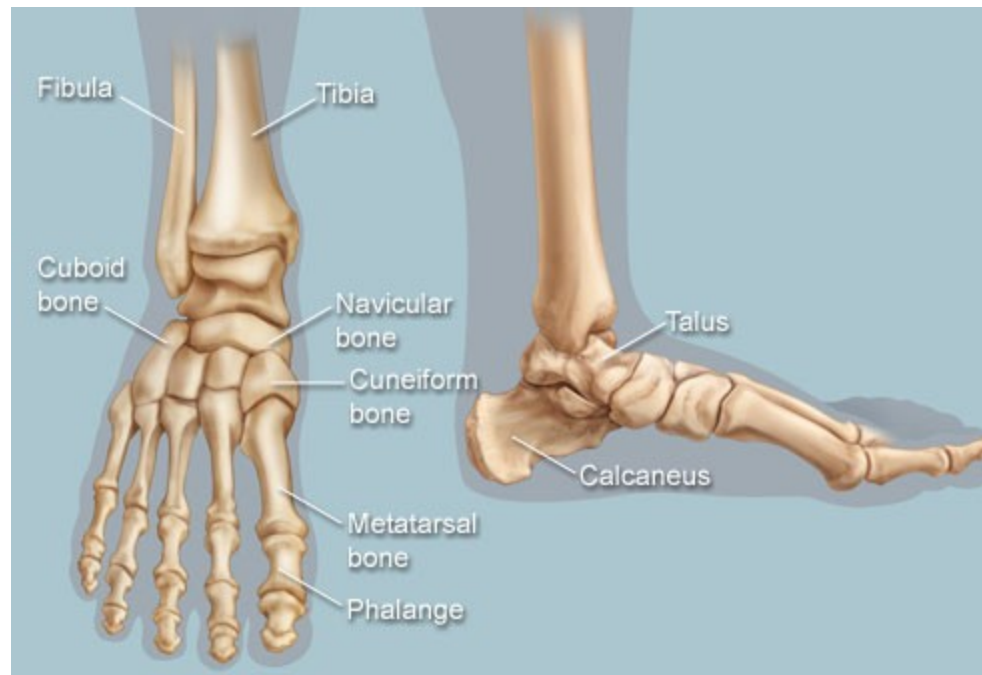
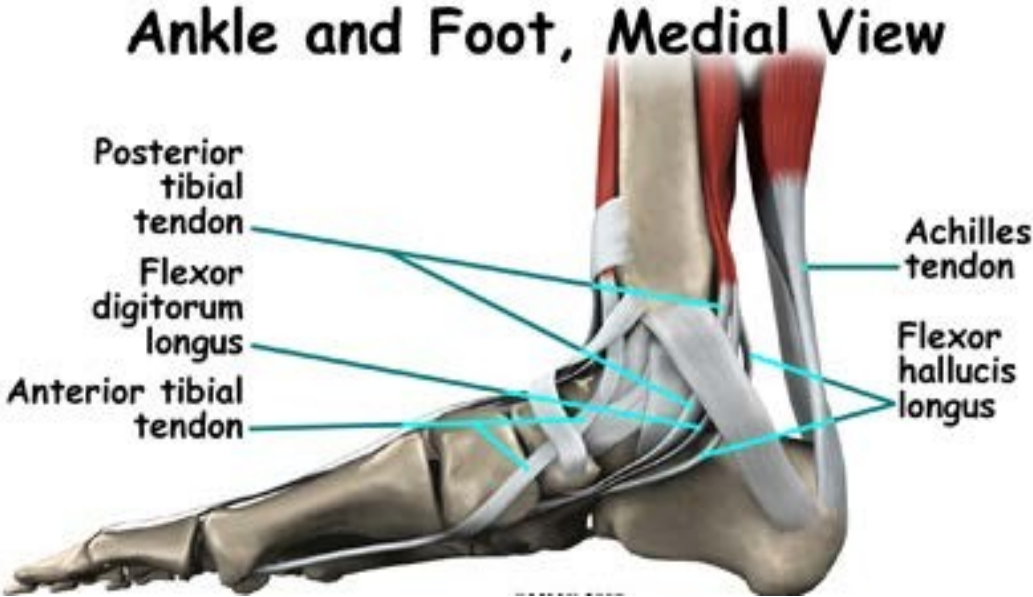
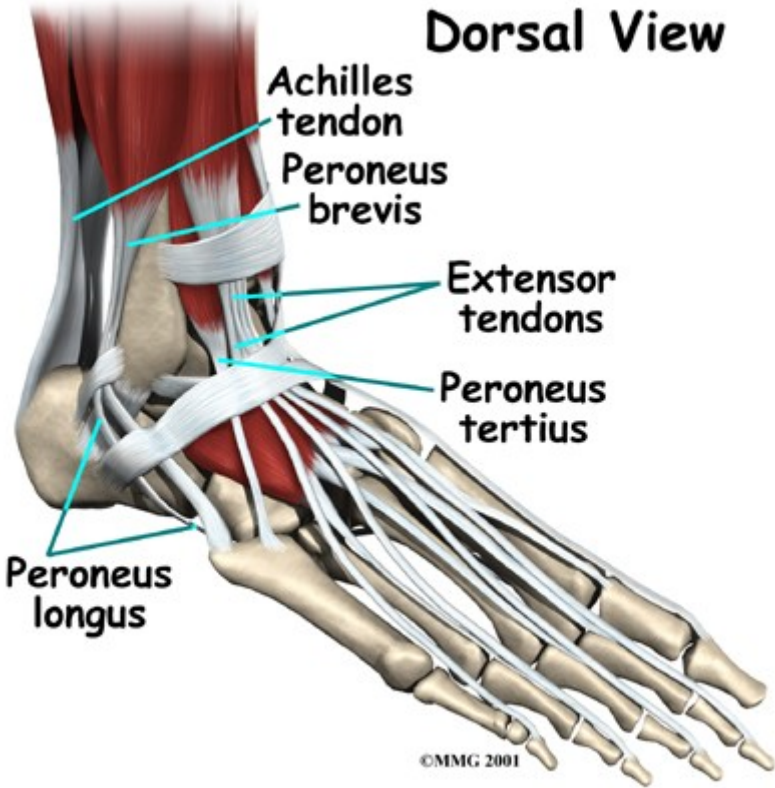


Manual muscle test

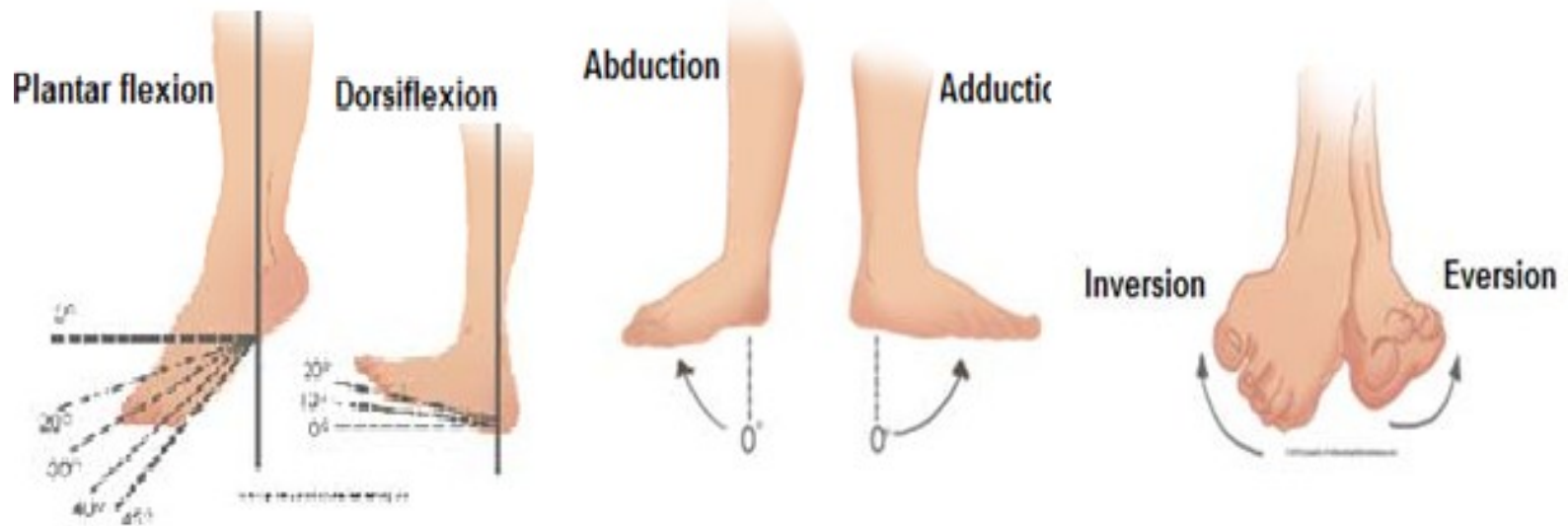
The ankle joint, the fingers



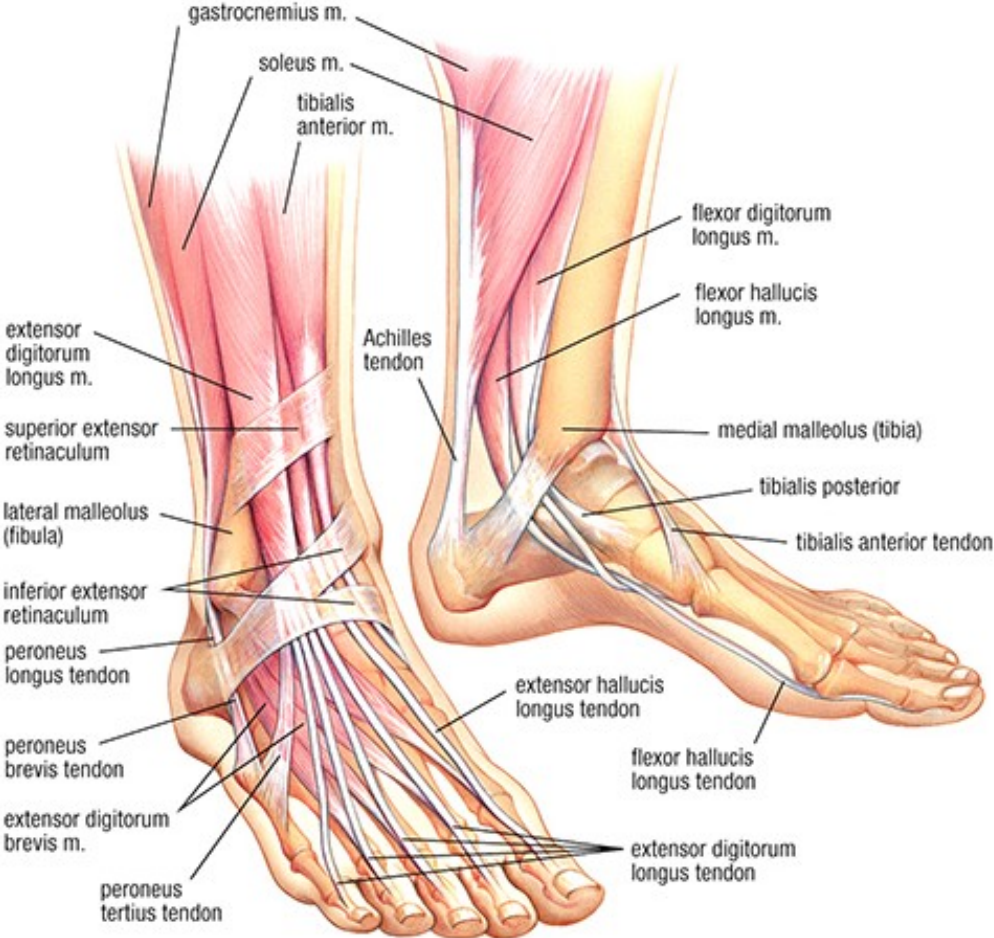
The ankle joint



Ankle joint movements



The muscles of the ankle joint



Ankle plantar flexion



Gastrocnemius



Soleus

Ankle plantar flexion - gastrocnemius

Origin

- Medial head from posterior nonarticular surface of medial femoral condyle
- Lateral head from lateral surface of femoral lateral condyle

Insertion

- The two heads unite into a broad aponeurosis which eventually unites with the deep tendon of the soleus to form the Achilles tendon, inserting on the middle 1/3 of the posterior calcaneal surface

Action

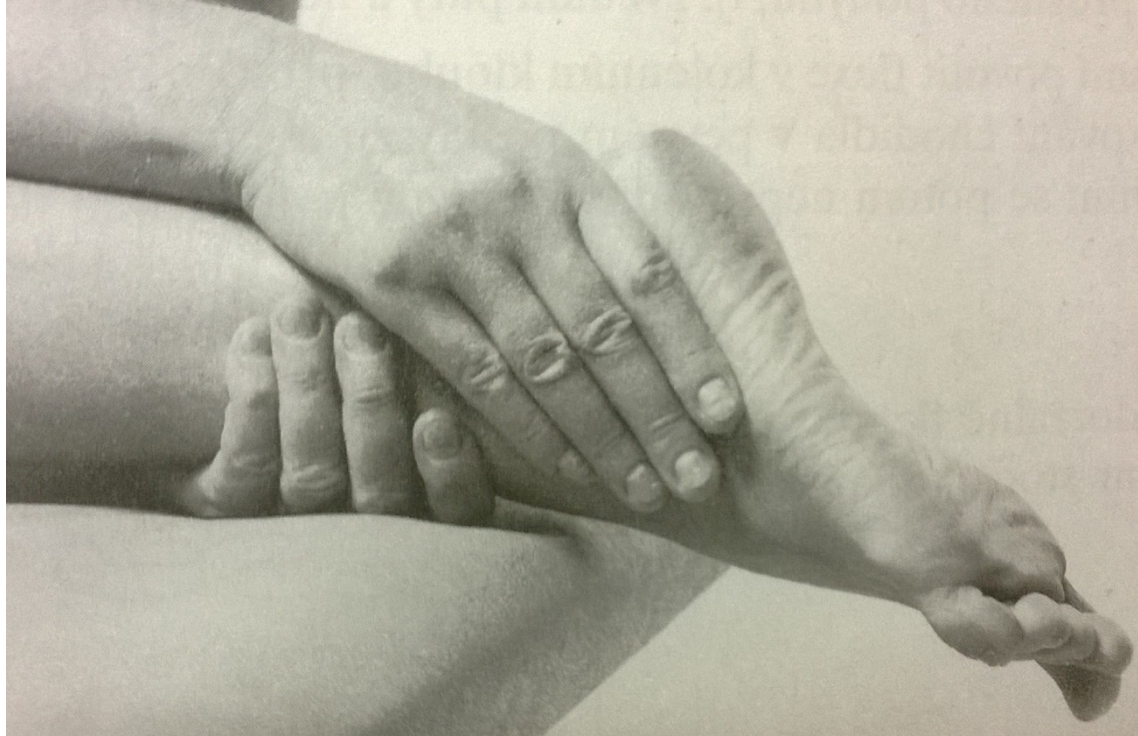
- Powerful plantar flexor of ankle

Innervation

- Tibial nerve (S1, S2) (S1, S2)



Ankle plantar flexion – grade 5, 4, 3



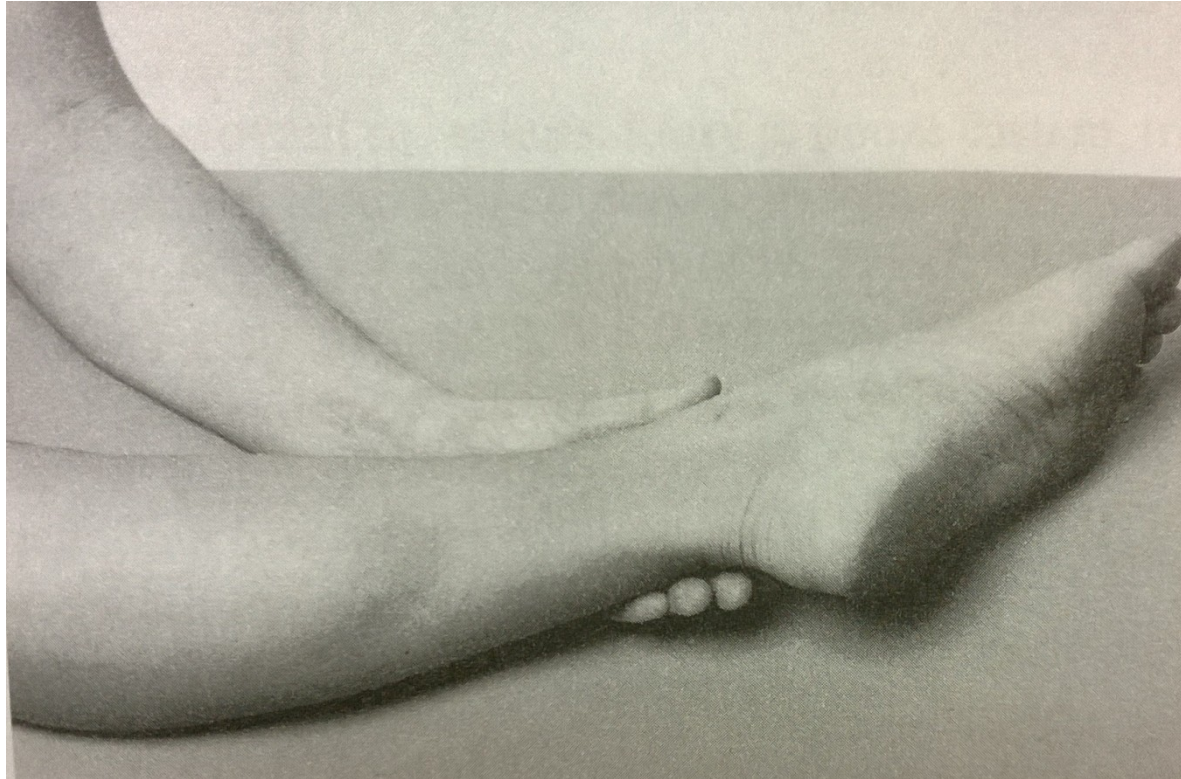
Position: patient lying prone, lower limbs extended, feet out of the table

Fixation: lower part of the shank (front side)

Movement: ankle plantar flexion in full range of motion

Resistance: PT puts resistance against the heel movement, differentiates the grades according to the amount of resistance, fingers are relaxed

Ankle plantar flexion – grade 2

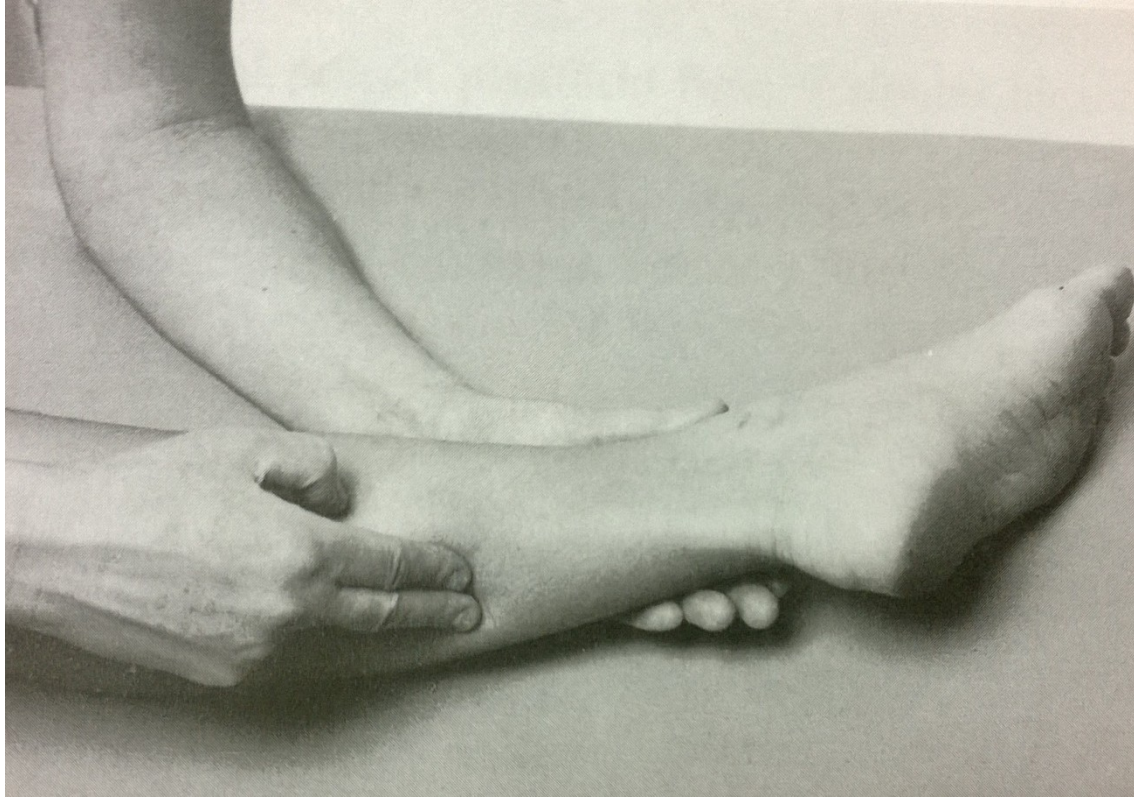


Position: patient lying on the tested side, tested lower limb extended in knee and hip joint, untested lower limb flexed in knee and hip joint, lying on the table

Fixation: lower part of the shank (front side)

Movement: ankle plantar flexion in full range of motion, pushing on the table

Ankle plantar flexion – grade 1,0



Position: lying on the tested side, tested lower limb extended in the knee and hip joint

Attempt to move: PT palpates a trace of contraction during patients attempt to flex the ankle

Ankle plantar flexion – notes:

- It is necessary to move the heel up, not just the foot down

Ankle plantar flexion - soleus

Origin

- Posterior aspect of fibular head, upper 1/4 - 1/3 of posterior surface of fibula, middle 1/3 of medial border of tibial shaft, and from posterior surface of a tendinous arch spanning the two sites of bone origin

Insertion

- Eventually unites with the gastrocnemius aponeurosis to form the Achilles tendon, inserting on the middle 1/3 of the posterior calcaneal surface

Action

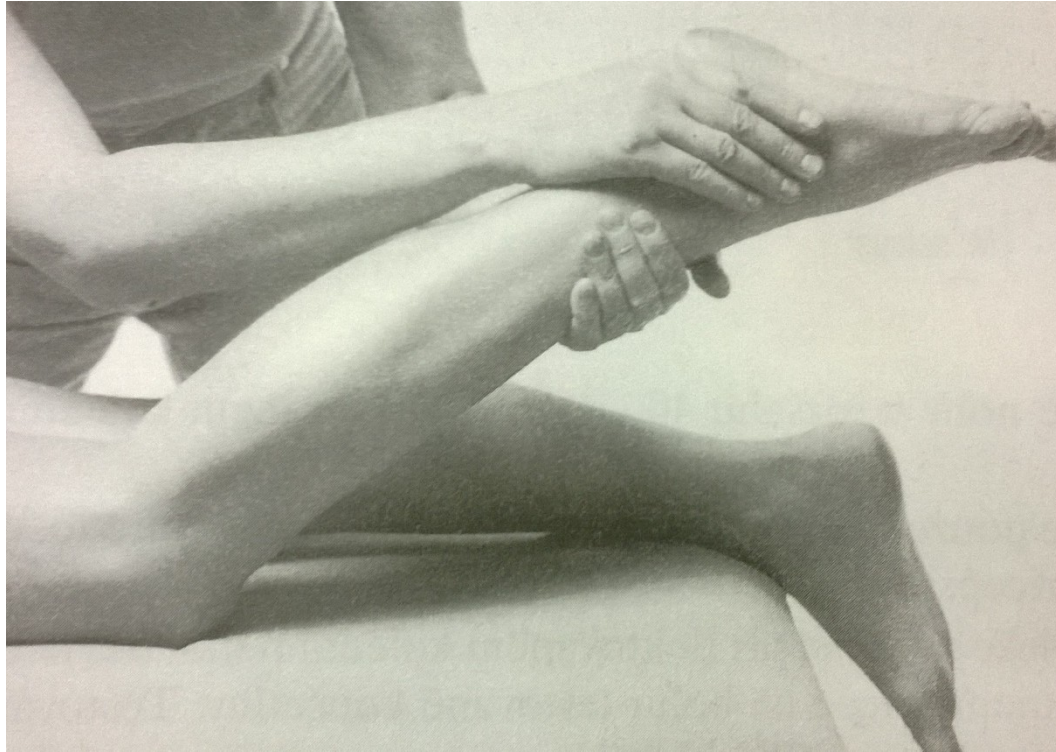
- Powerful plantar flexor of ankle

Innervation

- Tibial nerve (S1, S2) (S1, S2)



Ankle plantar flexion – grade 5,4,3 (a.)



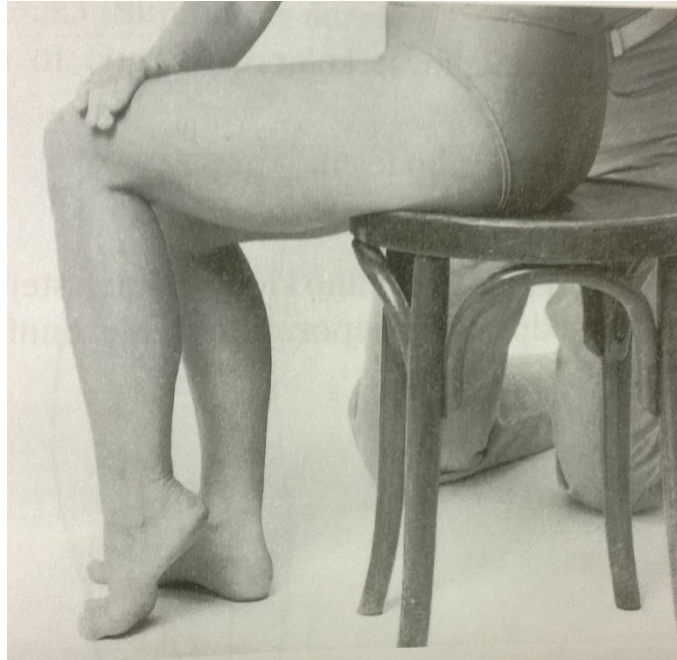Position: patient lying prone, untested lower limb extended, feet out of the table, tested lower limb flexed in the knee joint

Fixation: lower part of the shank (front side)

Movement: ankle plantar flexion in full range of motion

Resistance: PT puts resistance against the heel movement, differentiates the grades according the amount of resistance, fingers are relaxed

Ankle plantar flexion – grade 5,4,3 (b.)



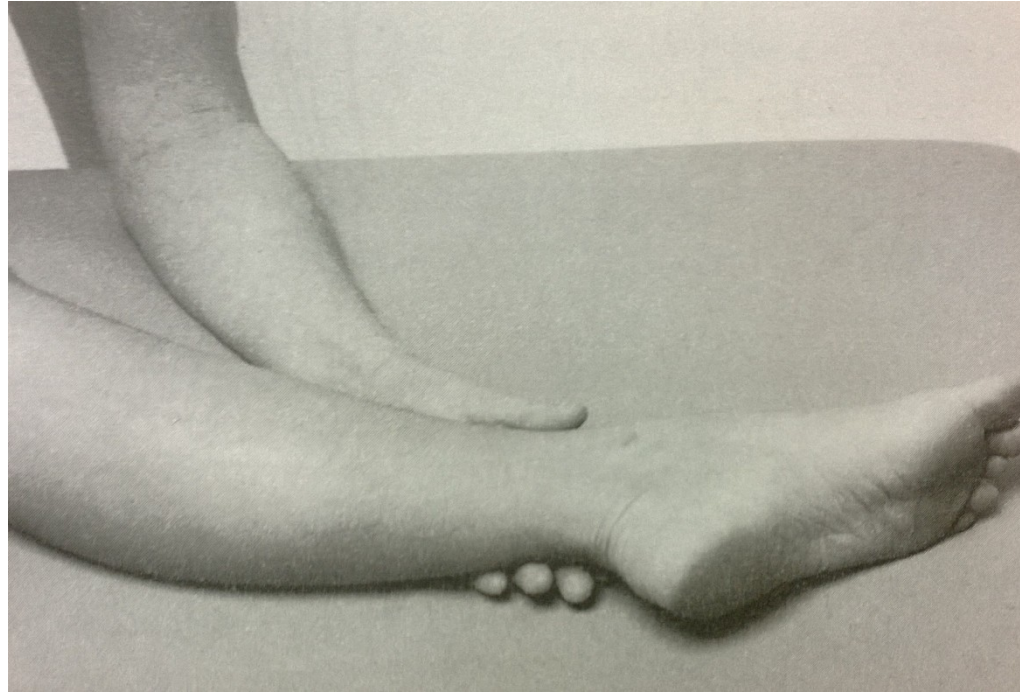
Position: patient sits on the chair, feet on the floor

Fixation: not necessary

Movement: ankle plantar flexion in full range of motion, heel up, fingers stays on the floor

Resistance: PT puts resistance at the knee , against its the movement up, differentiates the grades according the amount of resistance

Ankle plantar flexion – grade 2

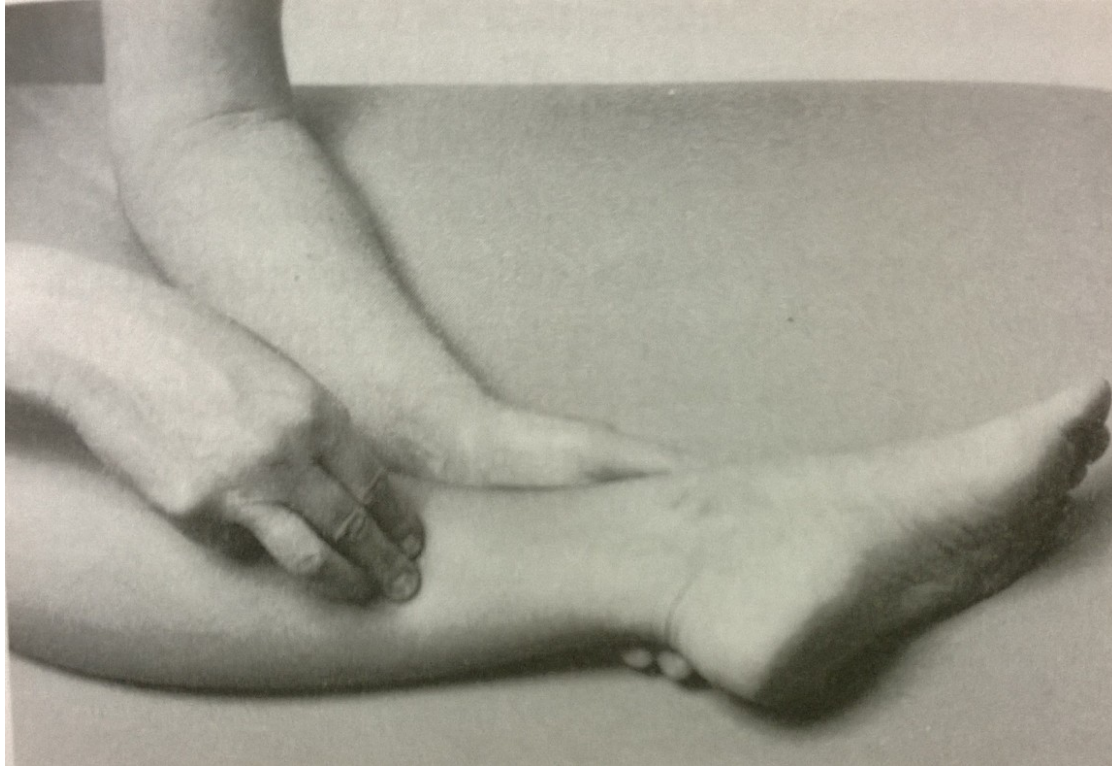

Position: patient lying on the tested side, tested lower limb flexed in knee joint, untested lower limb flexed in knee and hip joint, lying on the table

Fixation: lower part of the shank (front side)

Movement: ankle plantar flexion in full range of motion, pushing on the table

Ankle plantar flexion – grade 1,0



Position: lying on the tested side, tested lower limb flexed in the knee joint
Attempt to move: PT palpates a trace of contraction during patients attempt to flex the ankle

Ankle extension with supination

Tibialis anterior

Origin

- Lateral condyle of tibia, proximal 1/2 - 2/3 or lateral surface of tibial shaft, interosseous membrane, and the deep surface of the fascia cruris

Insertion

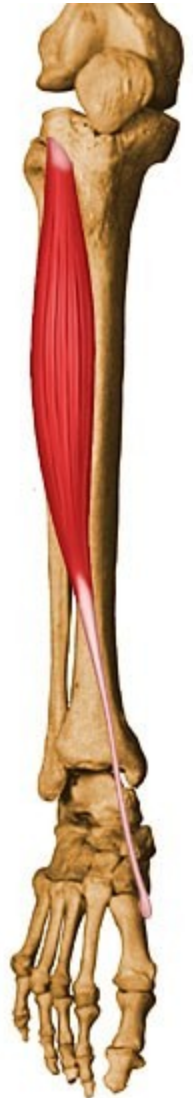- Medial and plantar surfaces of 1st cuneiform and on base of first metatarsal

Action

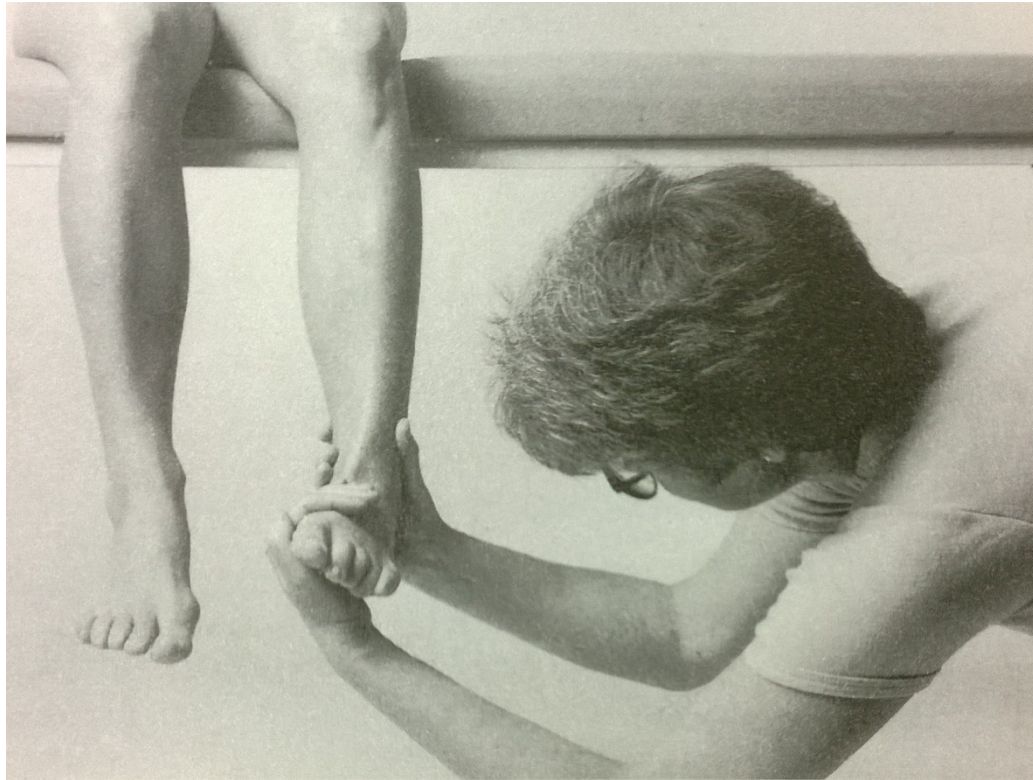
- Dorsiflexor of ankle and invertor of foot

Innervation

- Deep peroneal nerve (L4, L5, S1) (L4, L5, S1)



Ankle extension with supination – grade 5,4



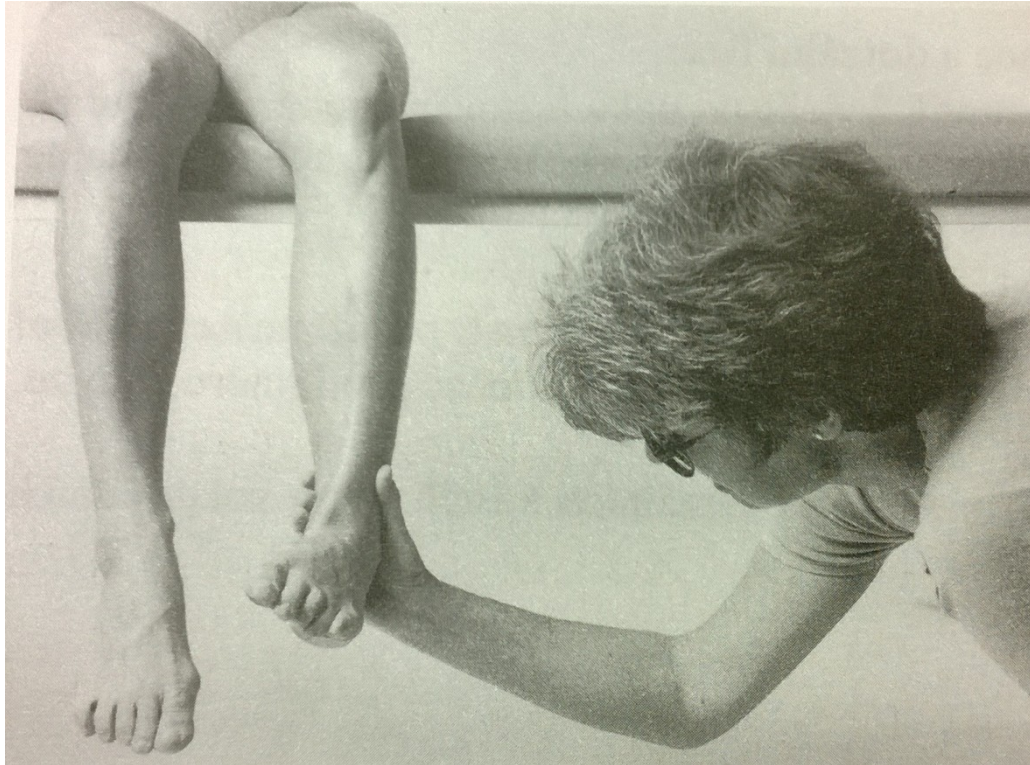
Position: patient sits, shins away from the table, knee 90° flexed, central position of the foot, no contact with the ground

Fixation: lower part of the shin (from behind)

Movement: ankle extension with supination (fingers free)

Resistance: PT puts resistance at the medial part of the foot against the movement

Ankle extension with supination – grade 3

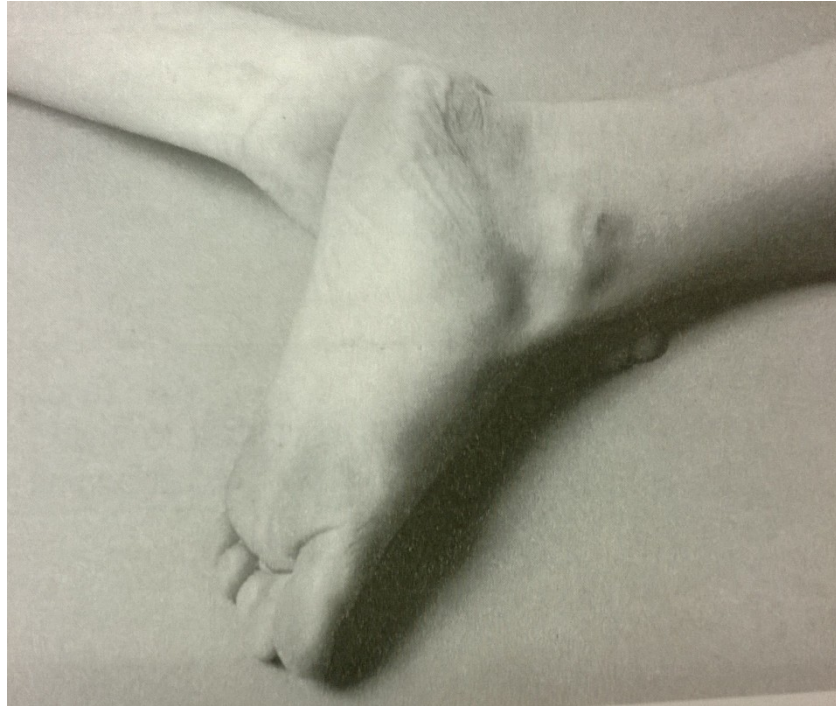

Position: patient sits, shins away from the table, knee 90° flexed, central position of the foot, no contact with the ground

Fixation: lower part of the shin (from behind)

Movement: ankle extension with supination (fingers free)

Ankle extension with supination – grade 2

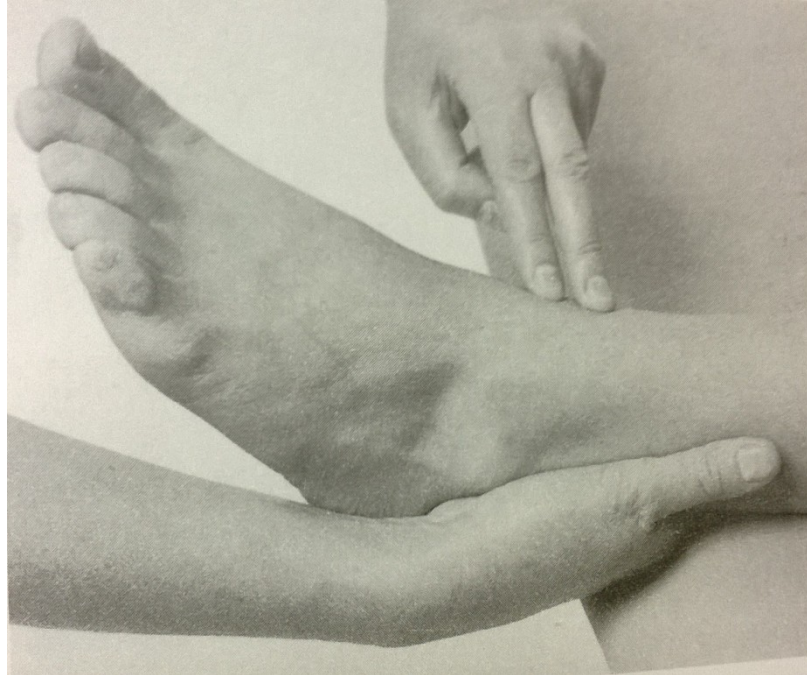

Position: patient lies on the tested side, knee and hip slightly flexed, lateral part of the foot on the table

Fixation: lower part of the shin, no contact of the heel on the table

Movement: ankle extension with supination by pushing the foot on the table

Ankle extension with supination – grade 1,0



Position: patient lies supine, foot in central position, away from the table

Fixation: distal part of the calf

Attempt to move: PT palpates a trace of contraction at the level of talocrural joint

Ankle extension with supination - notes

- Fixation of the leg is necessary
- A proper direction of the resistance
- Knee has to be flexed
- Muscles of the fingers has to be relaxed

Supination in plantar flexion

Tibialis posterior

Origin

- Posterior aspect of interosseous membrane, superior 2/3 of medial posterior surface of fibula, superior aspect of posterior surface of tibia, and from intermuscular septum between muscles of posterior compartment and deep transverse septum

Insertion

- Splits into two slips after passing inferior to plantar calcaneonavicular ligament; superficial slip inserts on the tuberosity of the navicular bone and sometimes medial cuneiform; deeper slip divides again into slips inserting on plantar surfaces of metatarsals 2 - 4 and second cuneiform

Action

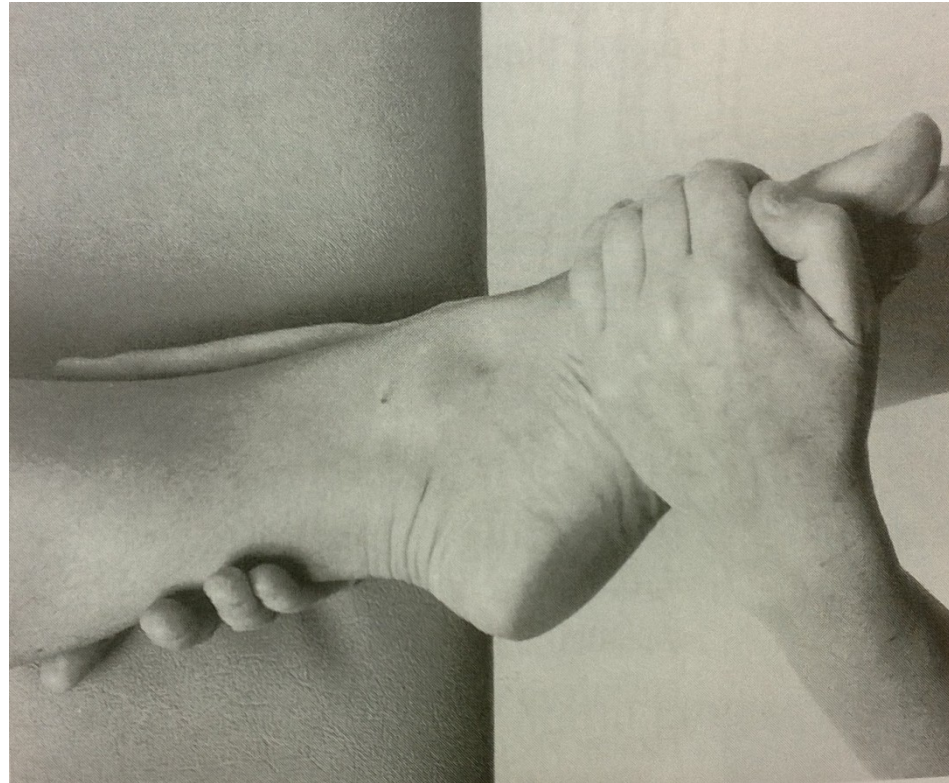
- Principal invertor of foot; also adducts foot, plantar flexes ankle, and helps to supinate the foot

Innervation

- Tibial nerve (L4, L5) (L4, L5)



Supination in plantar flexion – grade 5,4



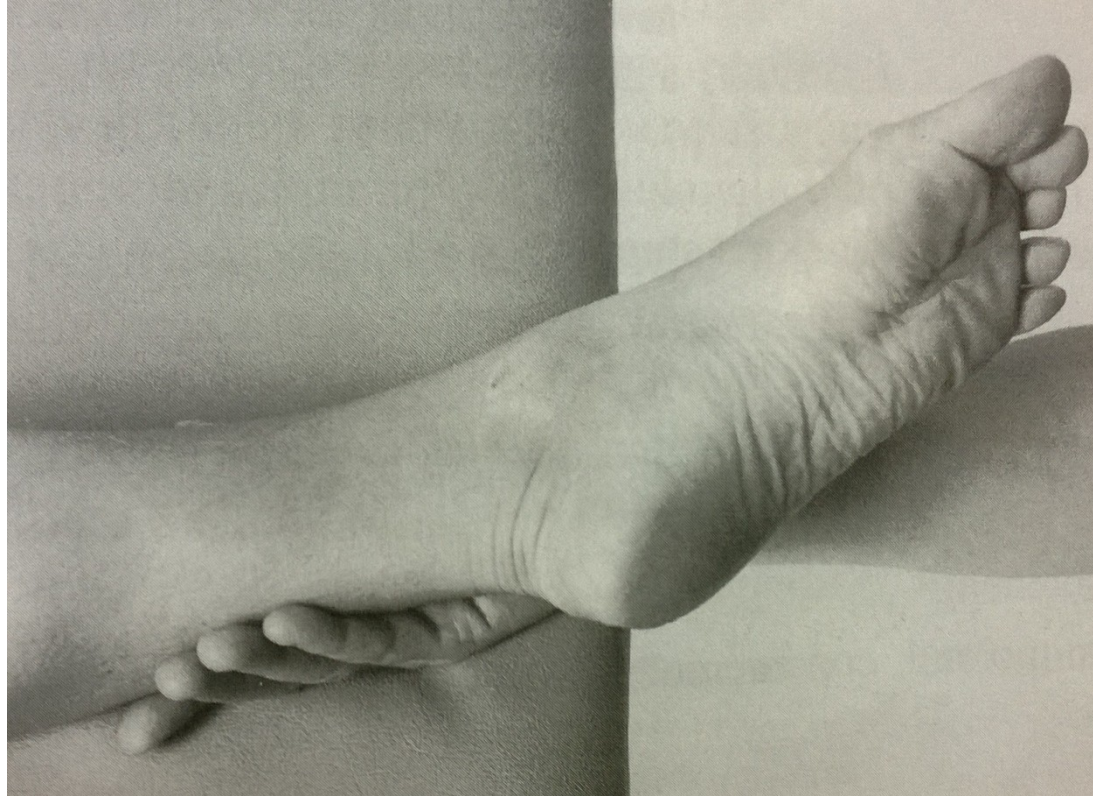Position: patient lies on the tested side, knee slightly flexed, foot away from the table

Fixation: lower part of the shin

Movement: foot supination in plantar flexion in full range of motion, fingers flexed

Resistance: PT puts resistance on medial part of the foot against the movement

Supination in plantar flexion – grade 3

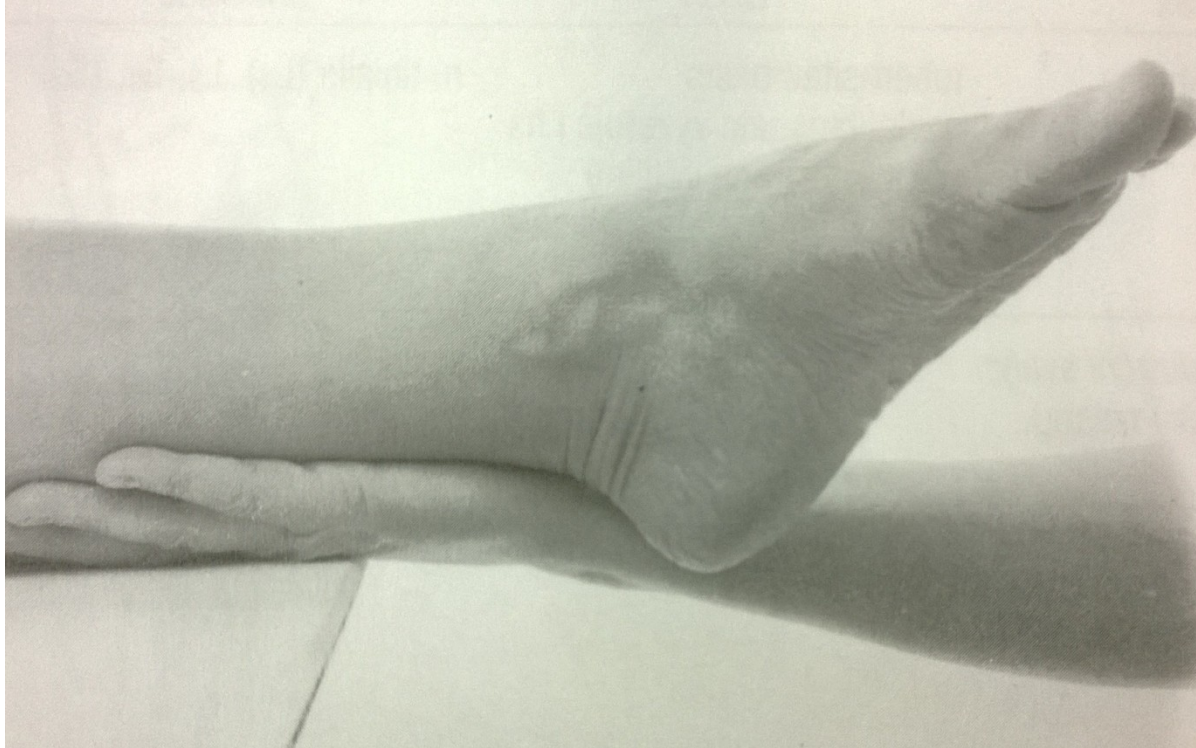


Position: patient lies on the tested side, knee slightly flexed, foot away from the table

Fixation: lower part of the shin

Movement: foot supination in plantar flexion in full range of motion, fingers flexed

Supination in plantar flexion – grade 2

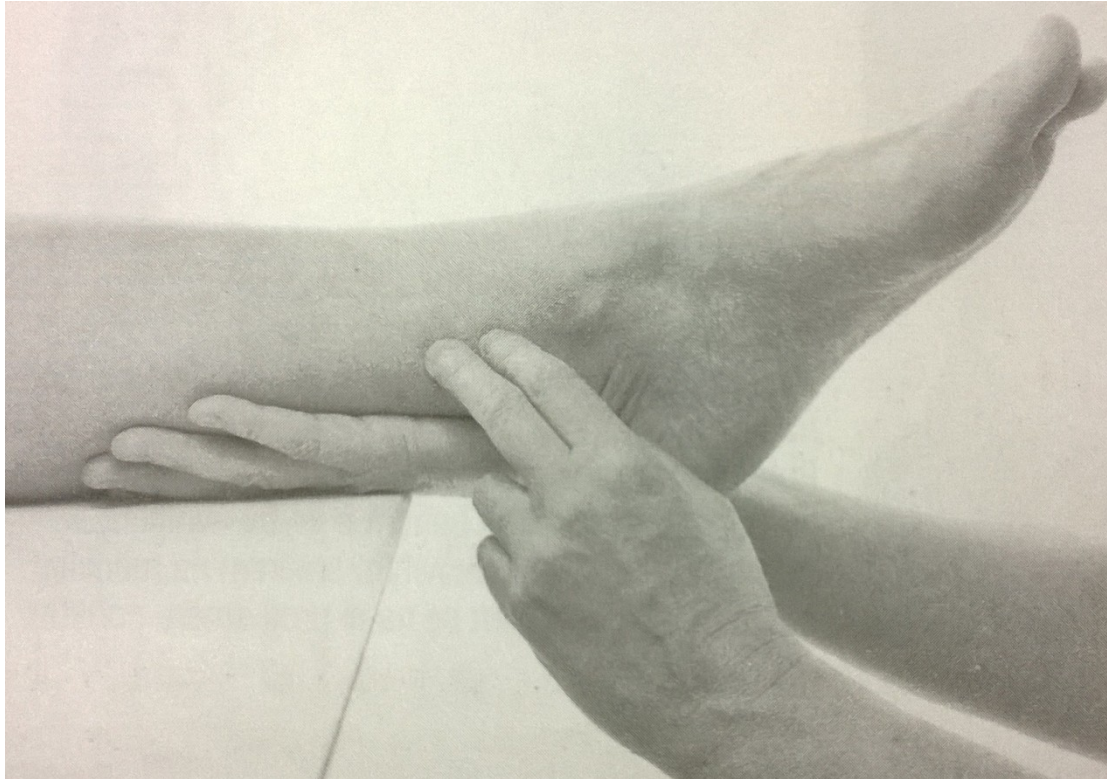


Position: patient lies supine, ankle flexion, foot away from the table, knee slightly flexed

Fixation: lower part of the calf

Movement: supination in plantar flexion

Supination in plantar flexion – grade 1,0



Position: patient lies supine, ankle flexion, foot away from the table, knee slightly flexed

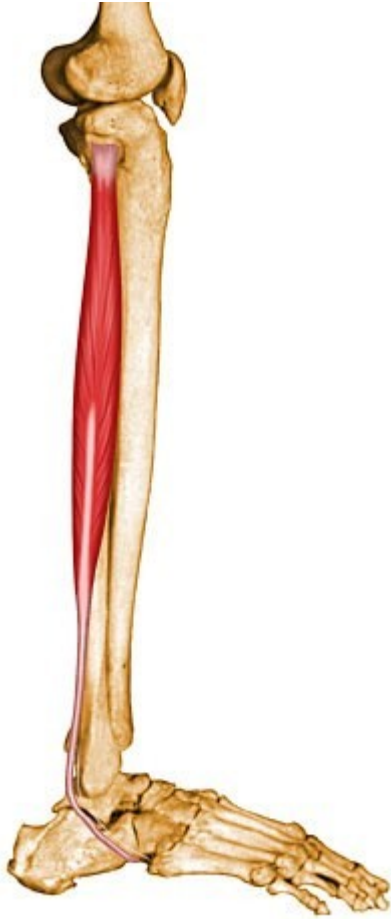Fixation: lower part of the calf

Attempt to move: PT palpates a trace of contraction during patients attempt to move, over the medial knuckle

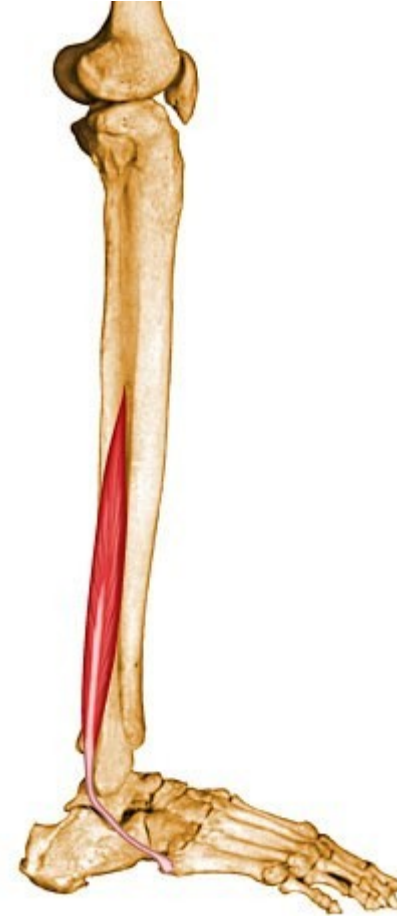Supination in plantar flexion - notes

- Foot has to be away from the table
- Ankle and knee has to be in flexion
- Proper fixation is necessary
- Correct direction of the resistance is important

Plantar pronation



Peroneus longus



Peroneus brevis

Peroneus longus

Origin

- Head of fibula, upper 1/2 - 2/3 of lateral fibular shaft surface
- also anterior and posterior intermuscular septa of leg

Insertion

- Plantar posterolateral aspect of medial cuneiform
- lateral side of 1st metatarsal base

Action

- Everts foot and plantar flexes ankle
- also helps to support the transverse arch of the foot

Innervation

- Superficial peroneal nerve (L5, S1, S2)
- may also receive additional innervation from common or deep peroneal nerves (L5, S1, S2)

Peroneus brevis

Origin

- Inferior 2/3 of lateral fibular surface
- anterior and posterior intermuscular septa of leg

Insertion

- Lateral surface of styloid process of 5th metatarsal base

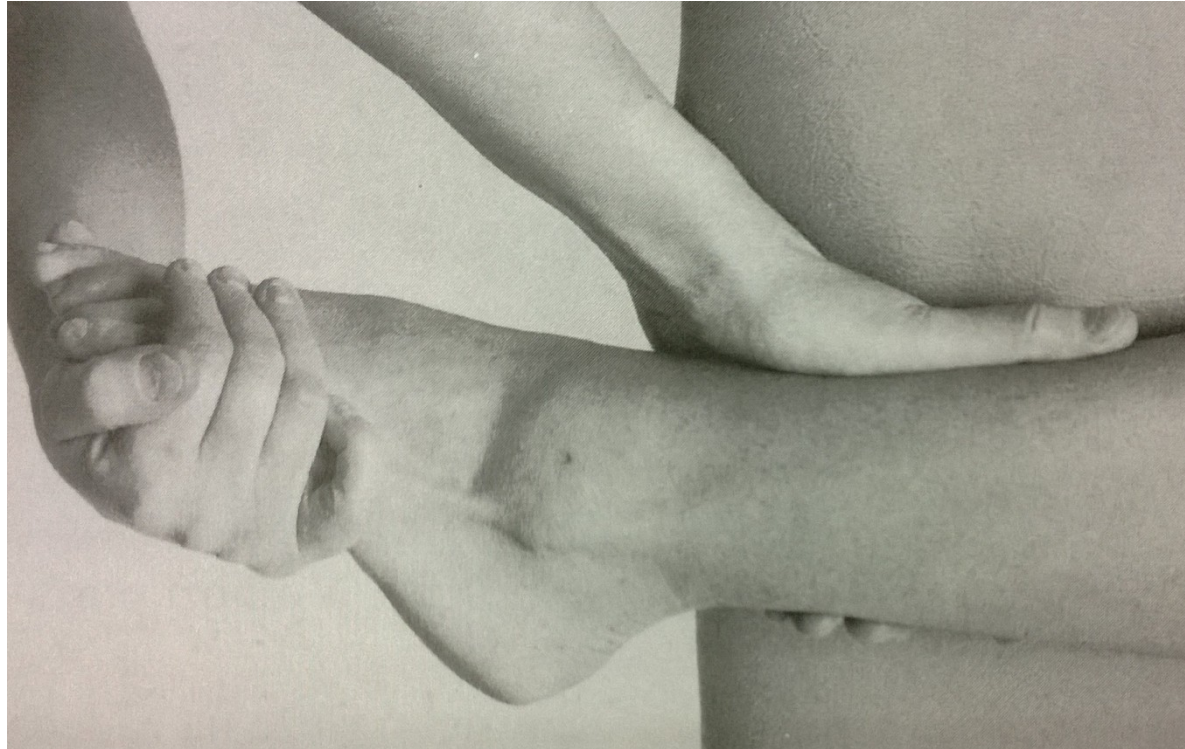Action

- Everts foot and plantar flexes ankle

Innervation

- Superficial peroneal nerve (L5, S1, S2) (L5, S1, S2)

Plantar pronation – grade 5,4



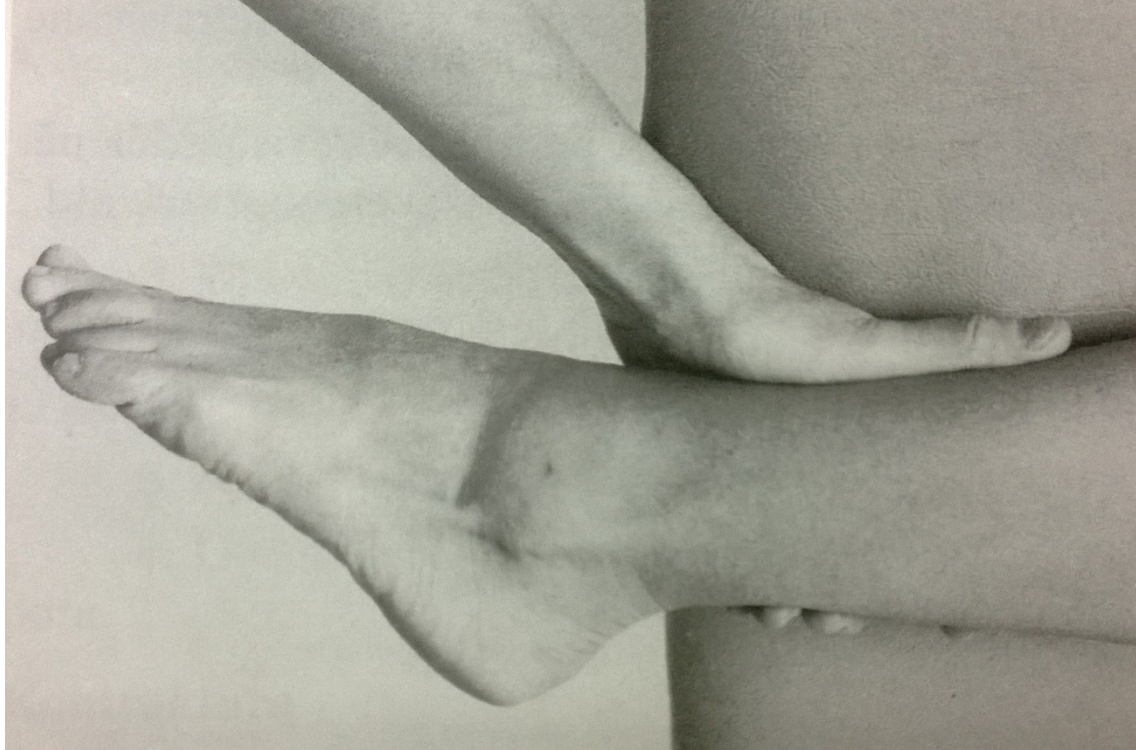Position: patient lies on the untested side, untested lower limb flexed, tested lower limb in knee and ankle flexion, foot away from the table, fingers relaxed

Fixation: lower part of the shin

Movement: pronation in plantar flexion in full range of motion

Resistance: PT puts resistance at lateral part of the foot against the movement

Plantar pronation – grade 3

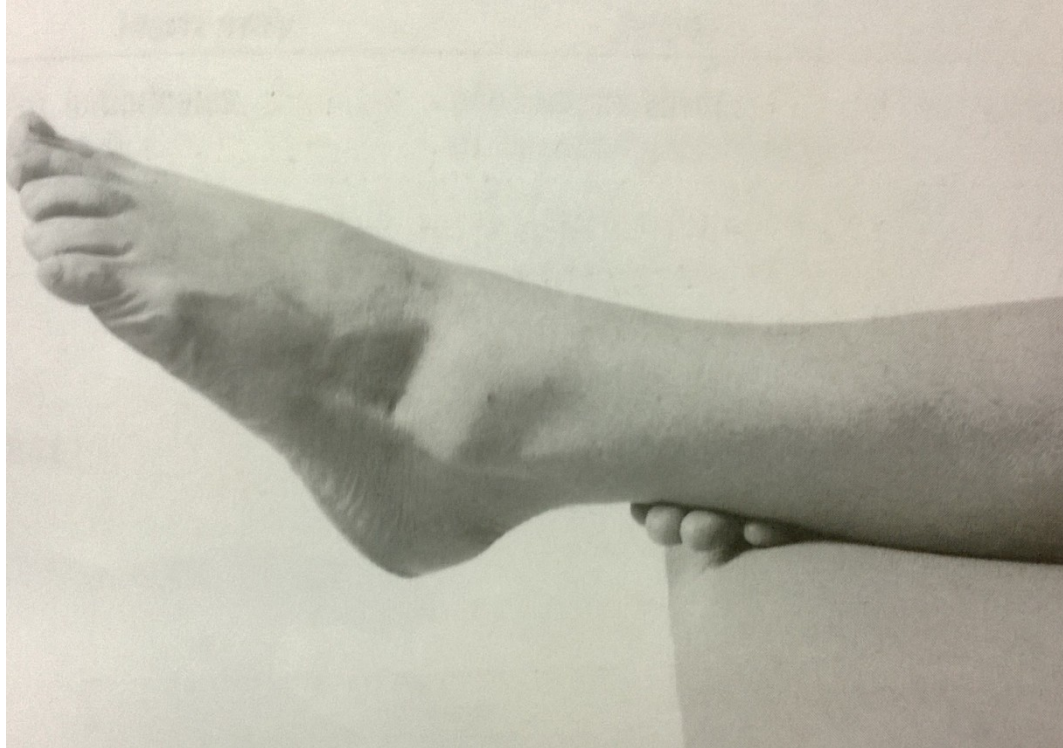


Position: patient lies on the untested side, untested lower limb flexed, tested lower limb in knee and ankle flexion, foot away from the table, fingers relaxed

Fixation: lower part of the shin

Movement: pronation in plantar flexion in full range of motion

Plantar pronation – grade 2

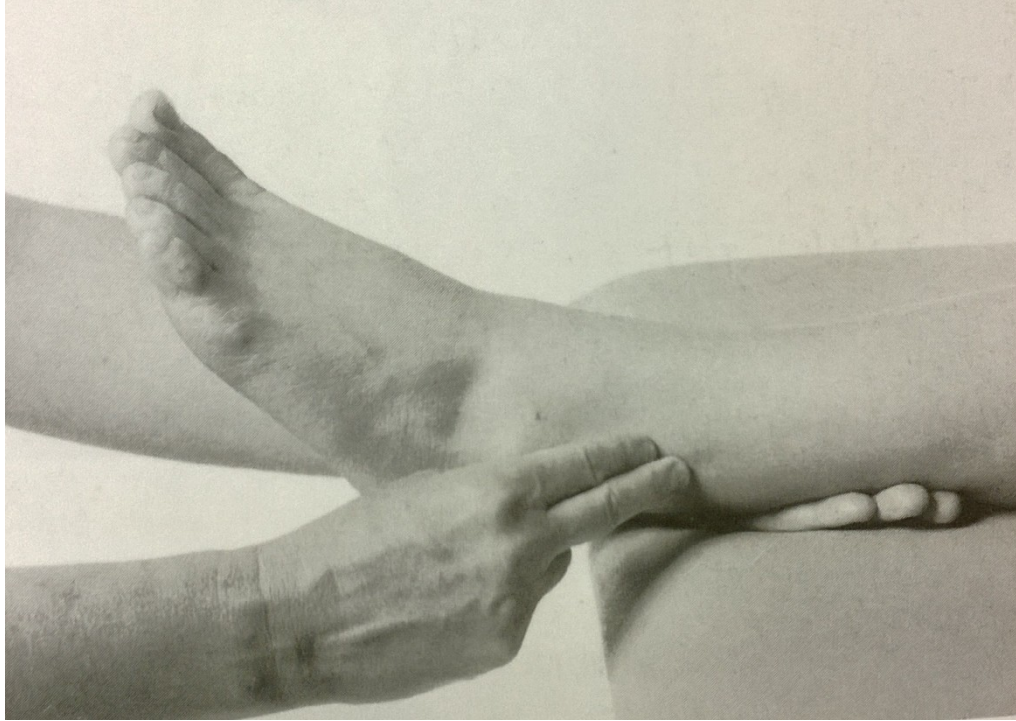


Position: patient lies supine, ankle flexion, foot away from the table, knee slightly flexed

Fixation: lower part of the calf

Movement: pronation in plantar flexion in full range of motion

Plantar pronation – grade 1,0



Position: patient lies supine, ankle flexion, foot away from the table, knee slightly flexed

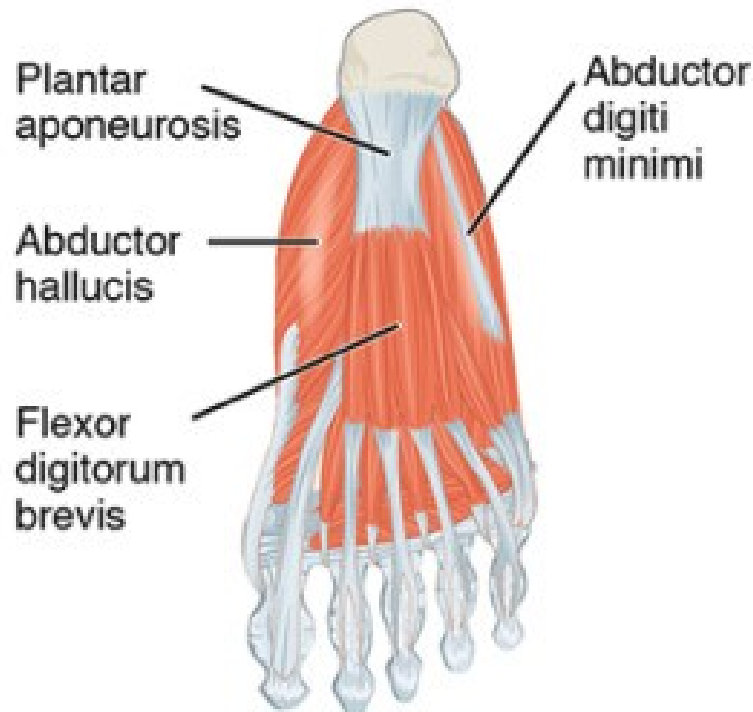
Fixation: lower part of the calf

Attempt to move: PT palpates the tendon at the area of lateral knuckle

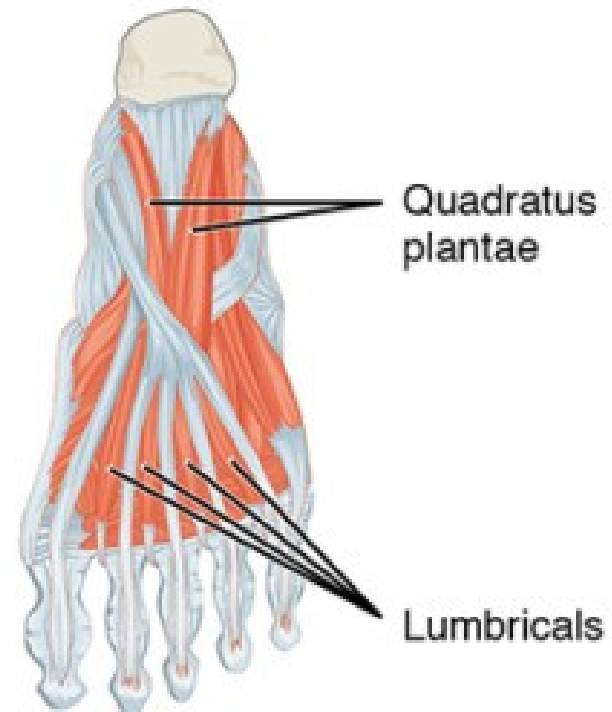
Plantar pronation - notes

- Fixation of the shin is necessary
- Ankle has to be in flexion
- Fingers has to be relaxed

The muscles of the foot



Superficial muscles of the left sole (plantar view)

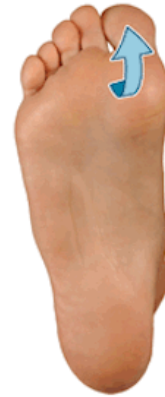

Intermediate muscles of the left sole (plantar view)

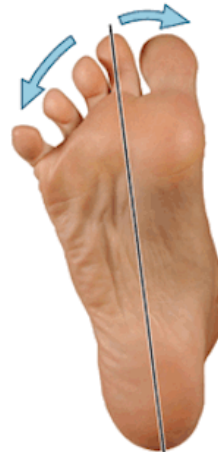Fingers movements



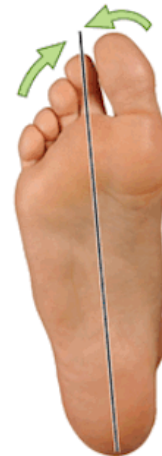(A) Flexion



(B) Extension

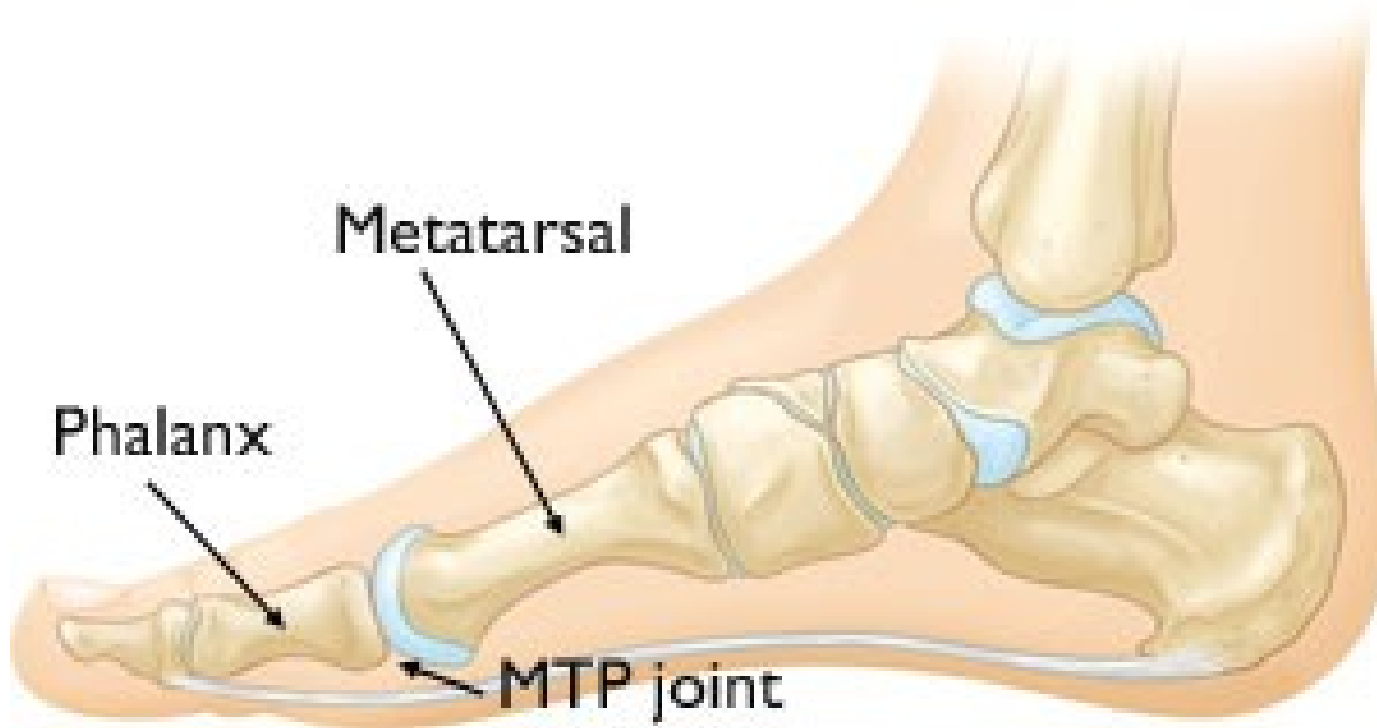


(C) Abduction

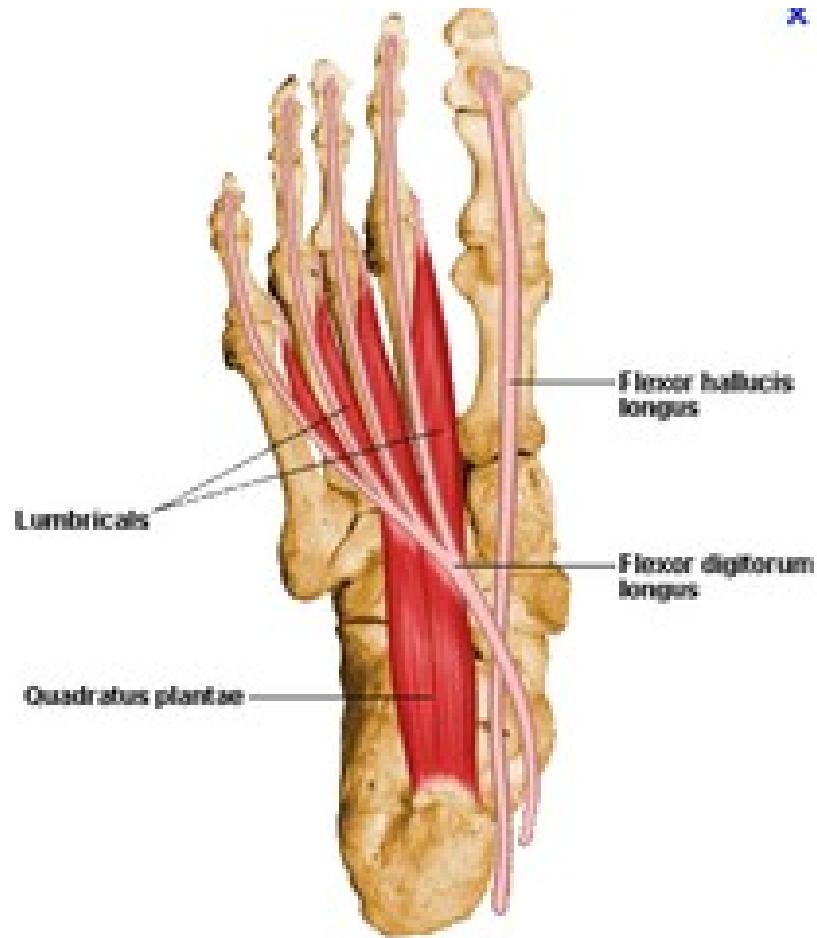

(D) Adducted
(relaxed position)

Metatarsophalangeal (MP) joints of the fingers



MP joints flexion



Lumbricals

Lumbricals

Origin:

- 1st: Med. side of 1st tendon of FDL
- 2nd: Adjacent sides of 1st-2nd tendons of FD
- 3rd: Adjacent sides of 2nd-3rd tendons of FD
- 4th: Adjacent sides of 3rd-4th tendons of FDL

Insertion:

- Extensor Wing and Extensor Trifurcation of 1st-4th tendons of EDL (1st Lumbrical - 1st tendon of EDL, etc.)

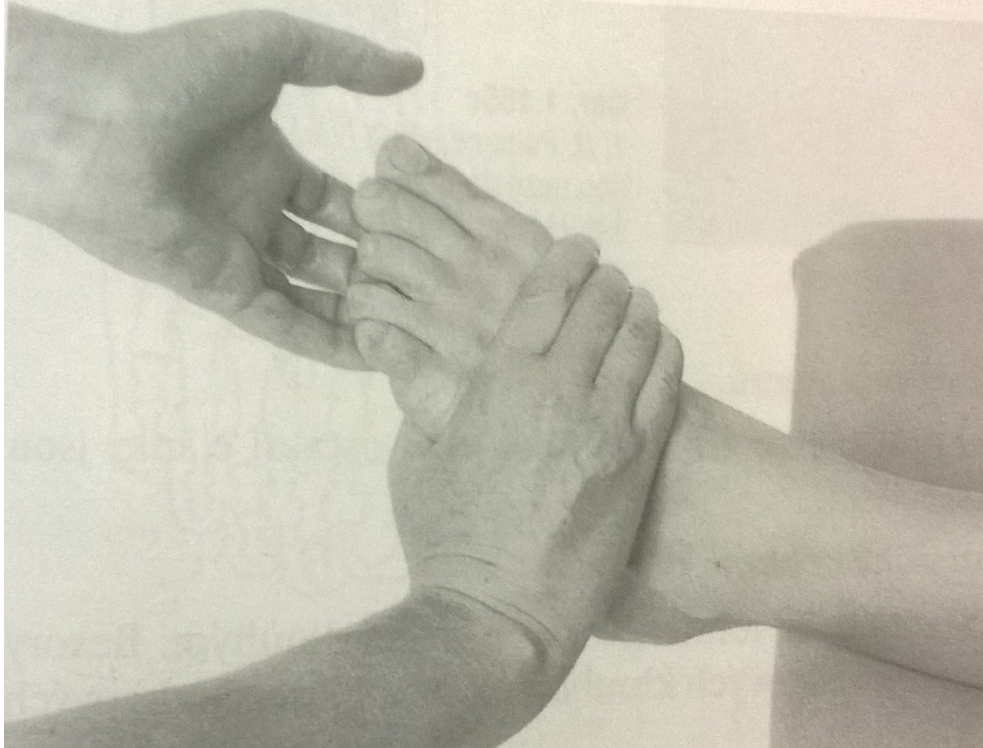
Action:

- Plantarflex PP, Extend MP, Extend DP of lesser digits
- Tighten wings & slacken sling of Extensor Hood

Innervation:

- 1st: 1st Plantar Common Digital branch of Medial Plantar Nerve
- 2nd-4th: Deep branch of Lateral Plantar Nerve

MP joints flexion – grade 5,4



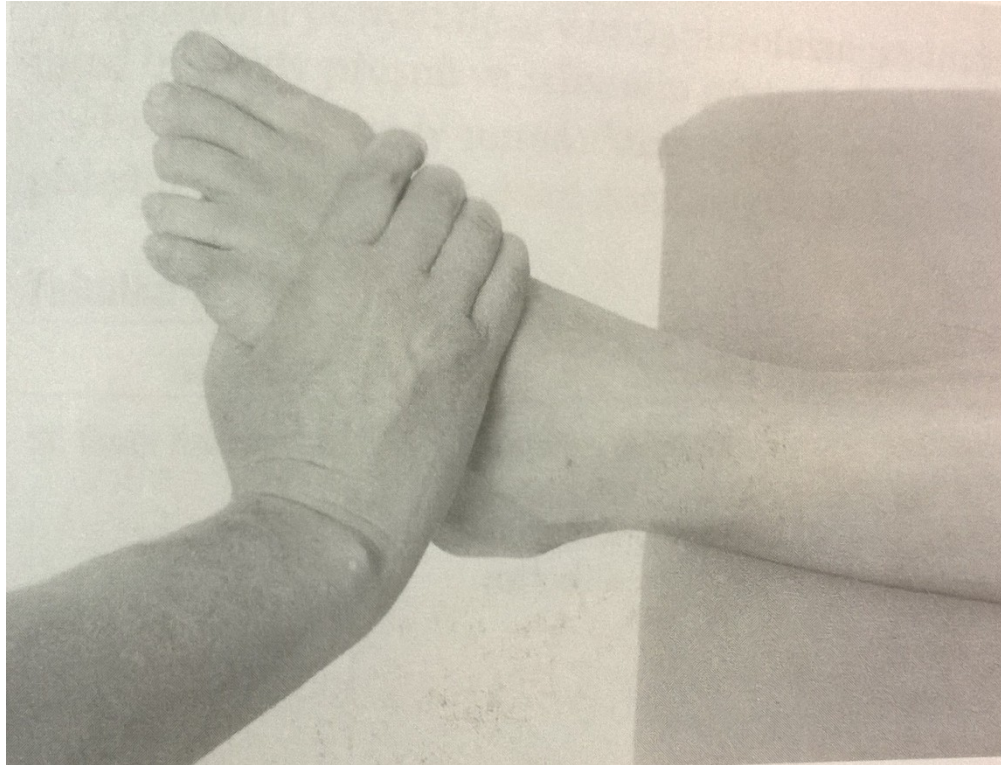Position: patient lies supine (or sits), knee slightly flexed, foot in central position

Fixation: metatarses

Movement: II.-V. MP joints flexion in full range of motion

Resistance: PT puts resistance at the plantar side of proximal phalanges against the movement

MP joints flexion – grade 3,2

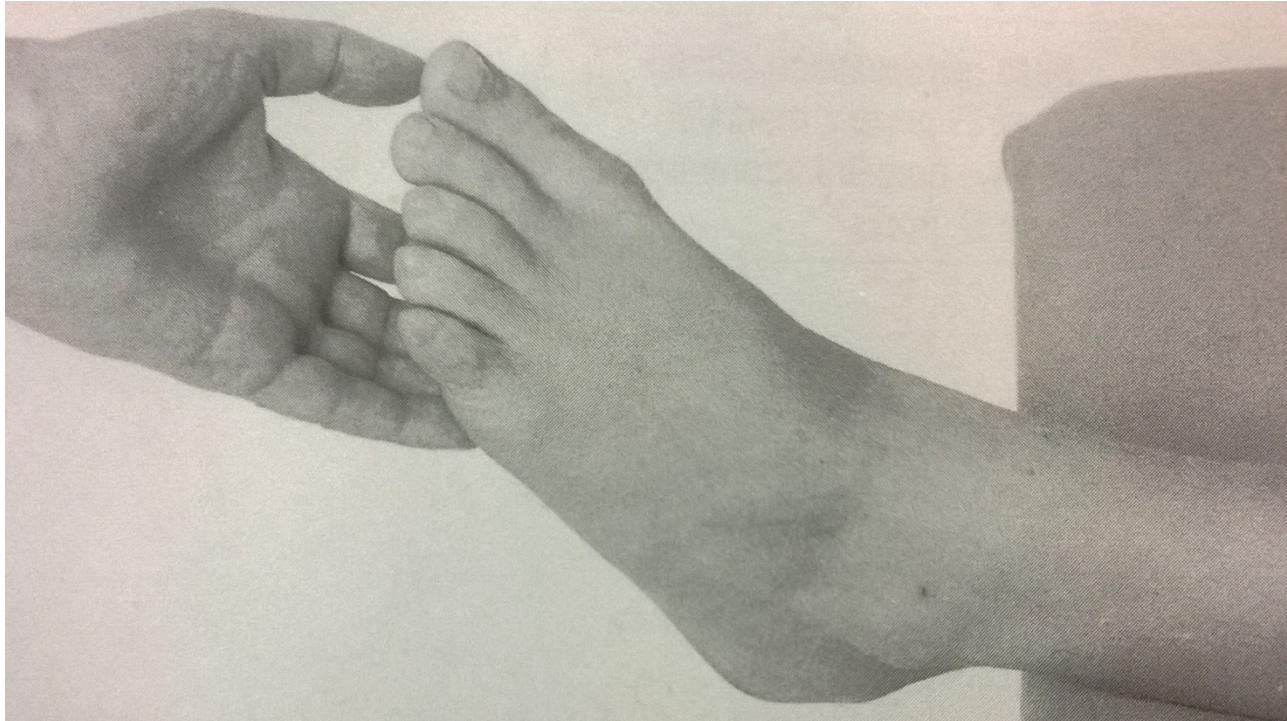


Position: patient lies supine (or sits), knee slightly flexed, foot in central position

Fixation: metatarses

Movement: II.-V. MP joints flexion in full range of motion

MP joints flexion – grade 1,0



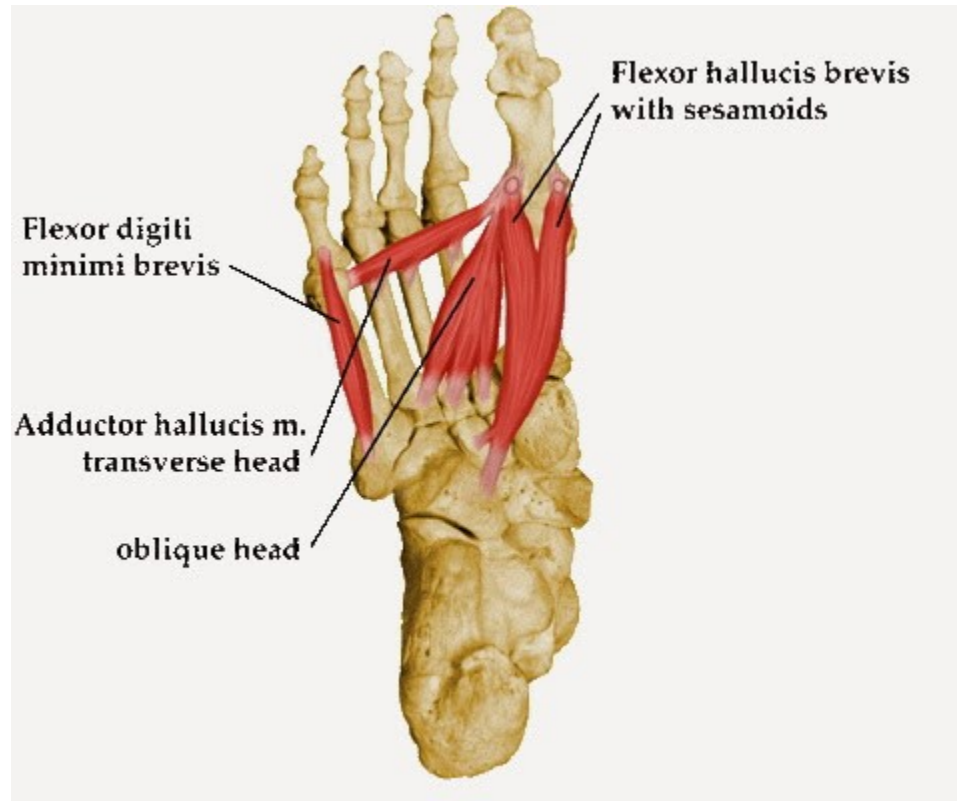
Position: patient lies supine (or sits), knee slightly flexed, foot in central position

Attempt to move: palpation of tendons is difficult, observe the tremble of the fingers during patients attempt to move

MP joints flexion - notes

- Fixation of metatarses is necessary
- No movement of IP joints
- Correct position of the foot

I. MP joint flexion



Flexor hallucis brevis

Flexor hallucis brevis

Origin:

- Y-shaped tendon
- Lateral arm: Plantar surface of Cuboid and 3rd Cuneiform
- Medial arm: Plantar component of tendon of Tibialis Posterior

Insertion:

- Lateral tendon: Lat. Sesamoid, Plantar Plate, Conjoined tendon of AdH, contribute to Extensor Hood
- Medial tendon: Med. Sesamoid, Plantar Plate, tendon of AbH, contribute to Extensor Hood
- United tendon: Plantar surface of Base of PP of Hallux

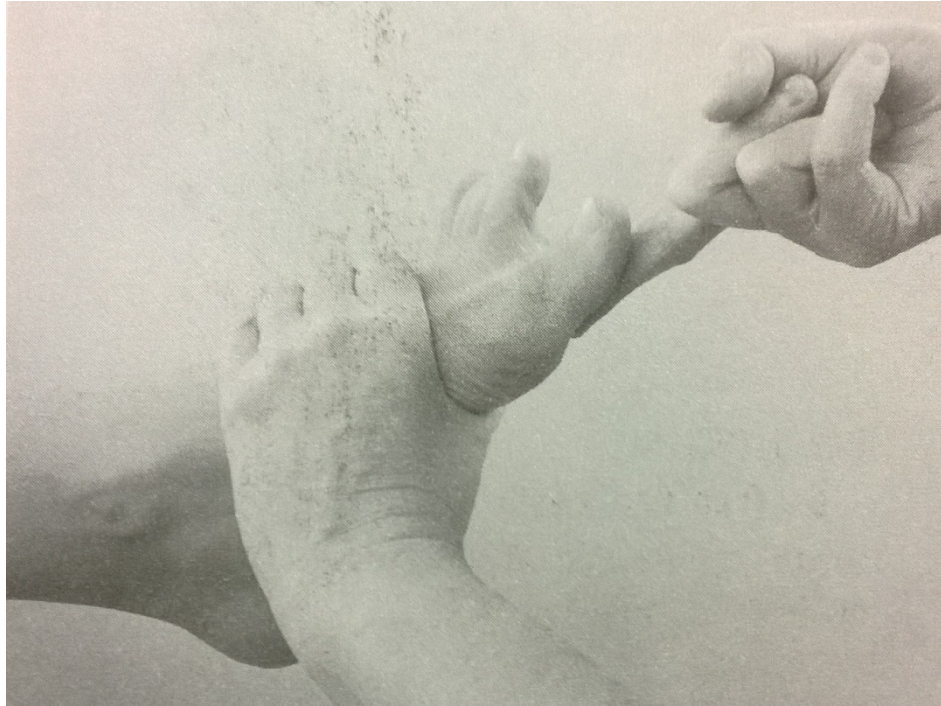
Action:

- Plantarflex PP of Hallux

Innervation:

- Plantar Digital branch of Medial Plantar Nerve

I. MP joint flexion – grade 5,4



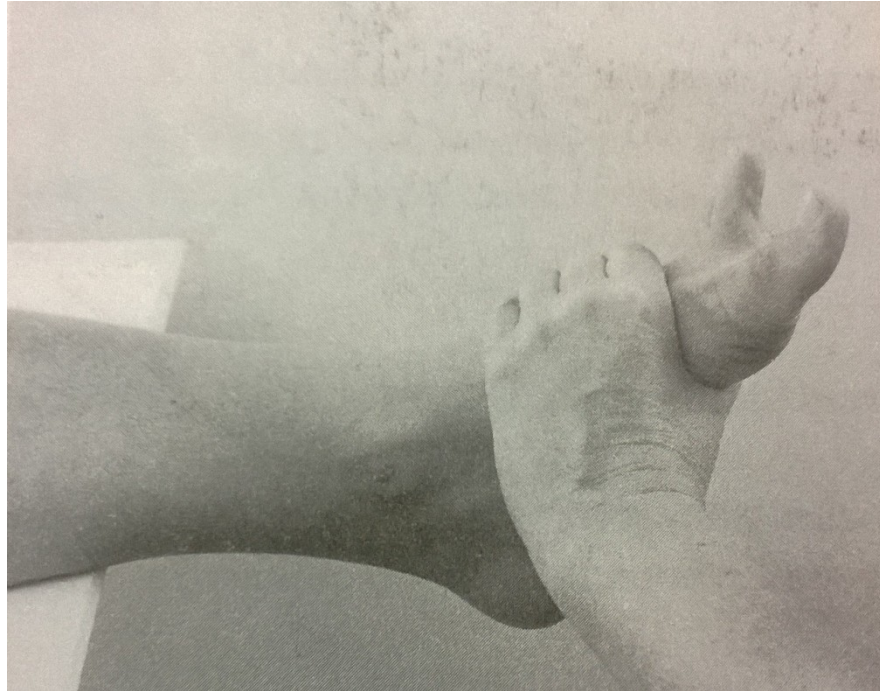Position: patient lies supine (or sits), knee and hip slightly flexed, foot in central position

Fixation: I. metatars (from the sides)

Movement: I. MP joint flexion in full range of motion

Resistance: PT puts resistance at the plantar side of proximal phalanx of the thumb against the movement

I. MP joint flexion – grade 3,2

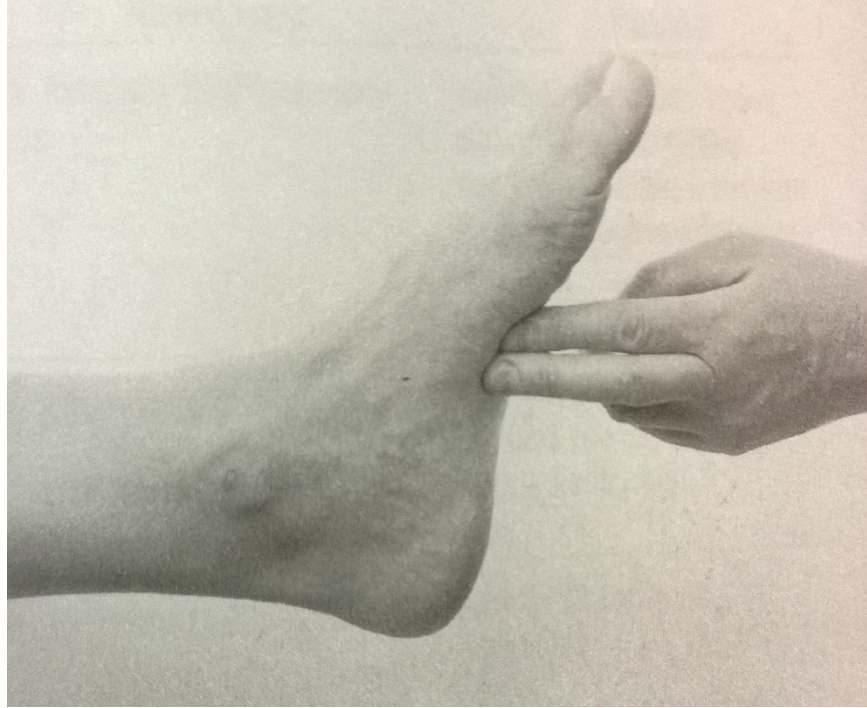


Position: patient lies supine (or sits), knee and hip slightly flexed, foot in central position

Fixation: I. metatars (from the sides)

Movement: I. MP joint flexion in full range of motion

I. MP joint flexion – grade 1,0



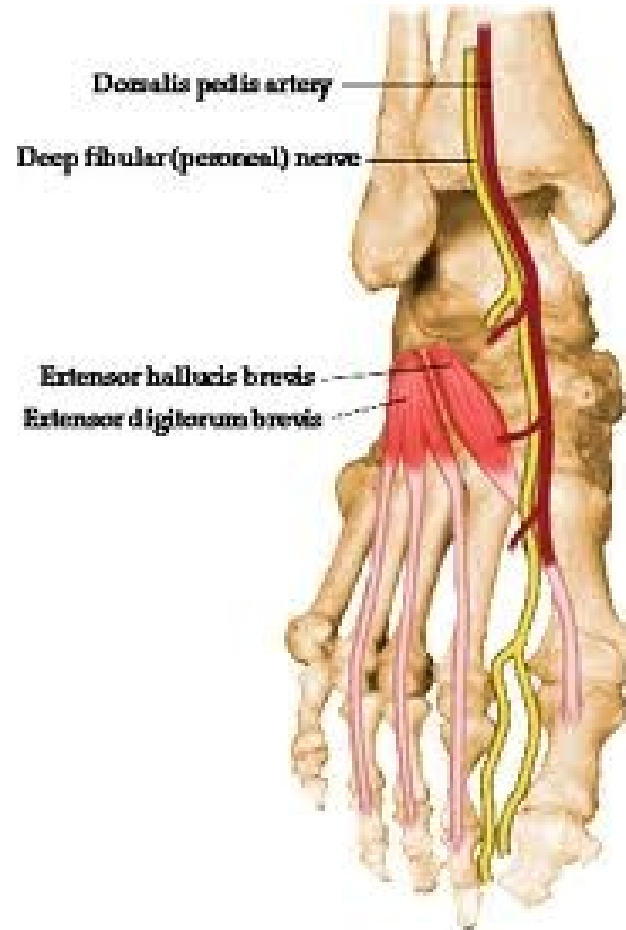
Position: patient lies supine (or sits), knee slightly flexed, foot in central position

Attempt to move: palpation of tendons is difficult, observe the tremble of the thumb during patients attempt to move

MP joints extension



Extensor digitorum longus



Extensor digitorum brevis

Extensor hallucis brevis

Extensor digitorum longus

Origin

- Lateral condyle of fibula, upper 2/3 - 3/4 of medial fibular shaft surface, upper part of interosseous membrane, fascia cruris, and anterior intermuscular septum

Insertion

- Splits into 4 tendon slips after inferior extensor retinaculum, each of which insert on dorsum of middle and distal phalanges as part of extensor expansion complex

Action

- Extend toes 2 - 5 and dorsiflexes ankle

Innervation

- Deep peroneal nerve (L4, L5, S1) (L4, L5, S1)



Extensor digitorum brevis

Origin:

- Sinus Tarsi of the Calcaneus
- Interosseous Talocalcaneal Ligament
- Inferior Extensor Retinaculum

Insertion:

- Lateral side of EDL tendons at Base of PP of Toes 2-4
- Contribute to Extensor Hood

Action:

- Dorsiflex Phalanges of Toes 2-4

Innervation:

- Lateral Terminal Branch of Deep Fibular Nerve

Extensor hallucis brevis

Origin:

- Sinus Tarsi of the Calcaneus
- Interosseous Talocalcaneal Ligament
- Inferior Extensor Retinaculum

Insertion:

- Dorsum of the Base of the Proximal Phalanx of the Hallux

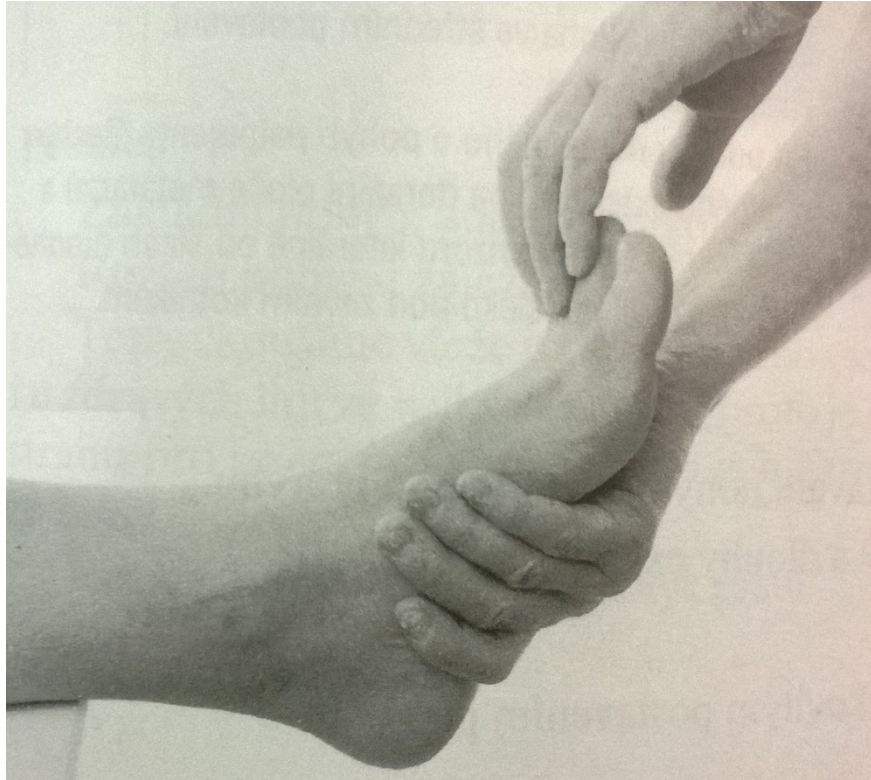
Action:

- Dorsiflex Proximal Phalanx of Hallux

Innervation:

- Lateral Terminal Branch of Deep Fibular Nerve

MP joints extension – grade 5,4



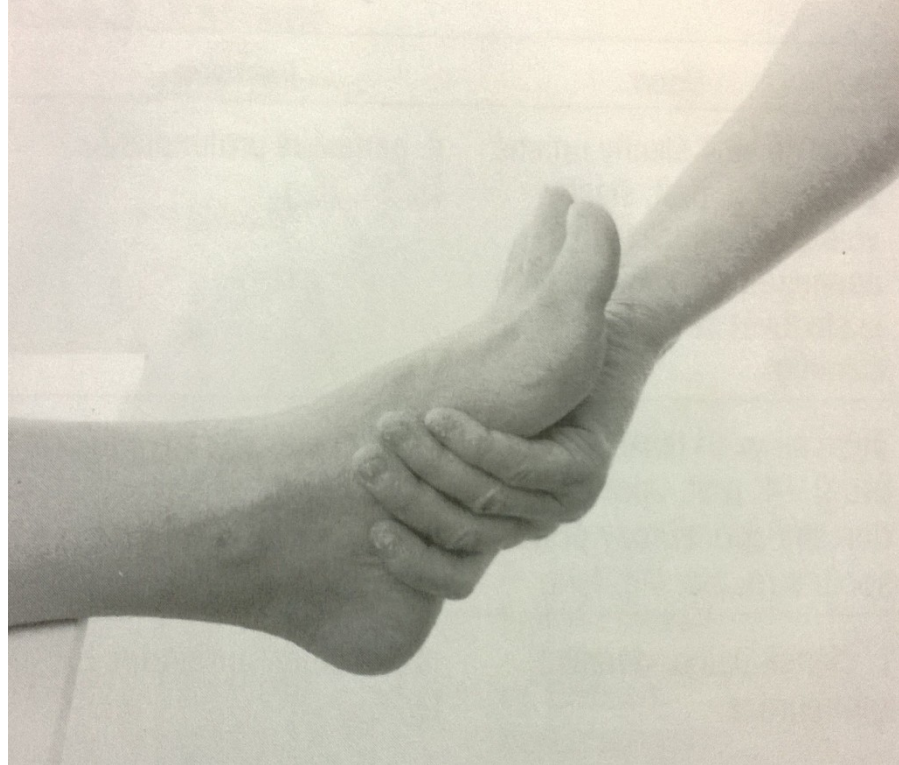
Position: patient lies supine (or sits), knee slightly flexed, foot in central position

Fixation: metatarses (from plantar side)

Movement: MP joints extension in full range of motion

Resistance: PT puts resistance at the dorsal side of proximal phalanges against the movement

MP joints extension – grade 3,2

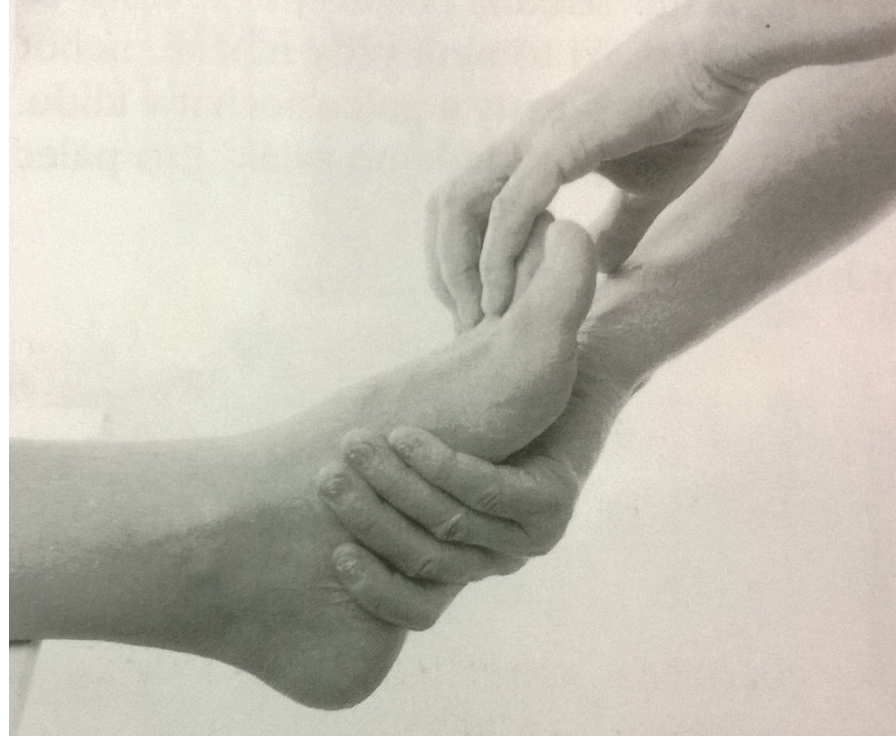


Position: patient lies supine (or sits), knee slightly flexed, foot in central position

Fixation: metatarses (from plantar side)

Movement: MP joints extension in full range of motion

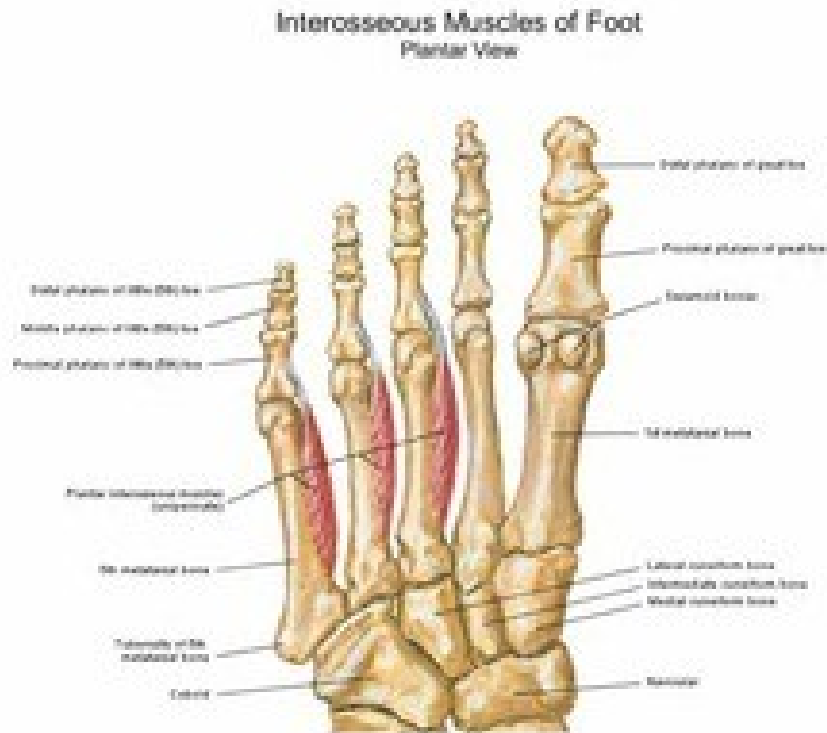
MP joints extension – grade 1,0



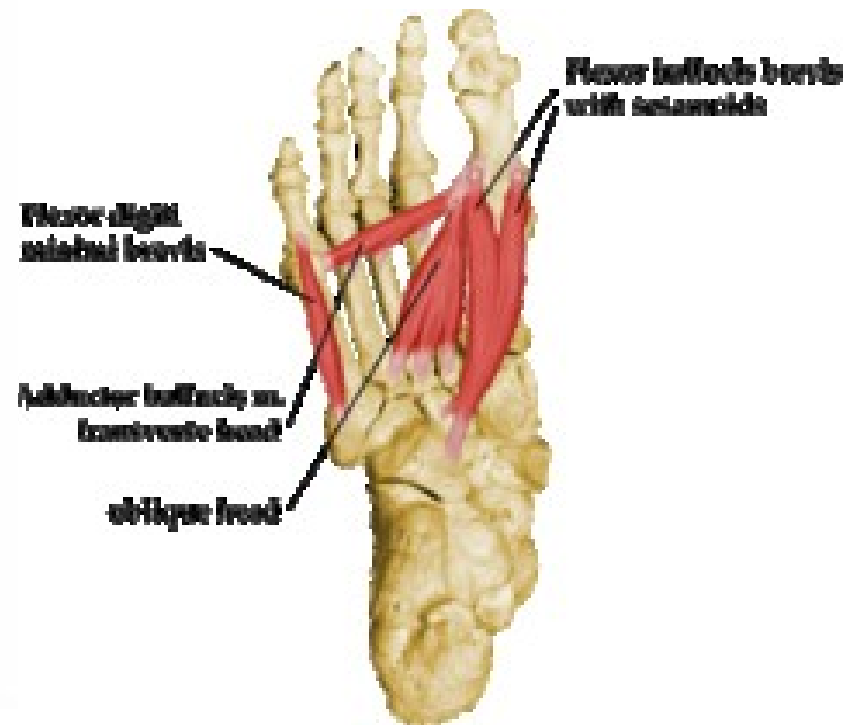
Position: patient lies supine (or sits), knee slightly flexed, foot in central position

Attempt to move: palpation of tendons at dorsal side of foot (at the area of metatars)

MP joints adduction



Plantar interossei



Adductor hallucis

Plantar interossei

Origin:

Inf. surface of Base & Med. surface of Shaft of 3rd, 4th, 5th MT (1st PI -> 3rd MT, etc.)

Insertion:

Med. side of Base of PP of 3rd, 4th, 5th Toe (1st PI -> PP of 3rd Toe, etc.)
Extensor Hood of Toes (3rd, 4th, 5th)

Action:

Adduct 3rd, 4th, 5th Toe (P-Ad vs D-Ab)

Innervation:

1st-2nd: Deep branch of Lateral Plantar Nerve

3rd: Plantar Digital branch of Superficial branch of Lateral Plantar Nerve

Adductor hallucis

Origin:

Oblique head: Plantar surface of Base of 2-4 MT, tendon sheath of FL
Transverse head: Plantar plate of 3-5 MTP, Deep Transverse MT Lig.

Insertion:

Heads conjoin at 1st interspace prox. to MTP & course through split in Deep Transverse MT Lig
Fibers blend with lateral tendon of FHB, Lat. Sesamoid, Plantar Plate, contribute to Extensor Hood
Insert on Lat.Plant. aspect of Base of PP of Hallux

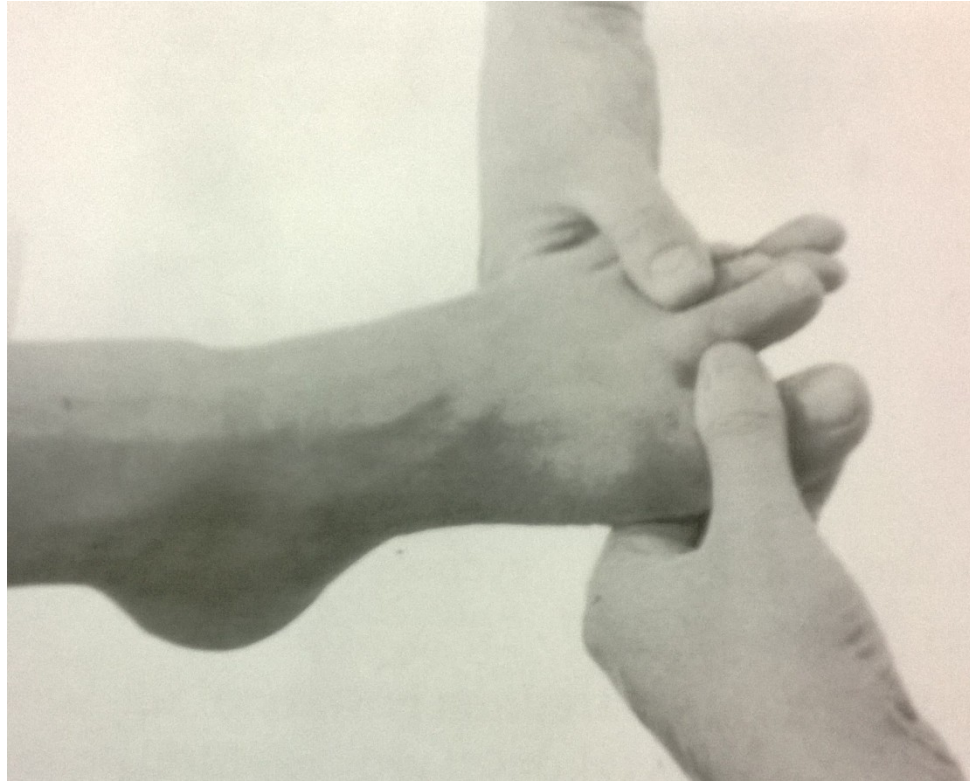Action:

Adducts Hallux
Aid in Plantarflexion of Hallux
Assist in pulling MT heads together

Innervation:

Deep branch of Lateral Plantar Nerve

MP joints adduction – grade 5,4



Position: patient lies supine (or sits), knee extended, foot in central position

Fixation: fingers in abduction

Movement: MP joints adduction

Resistance: PT puts resistance at the phalanges against the movement (the movement is adduction to the second finger)

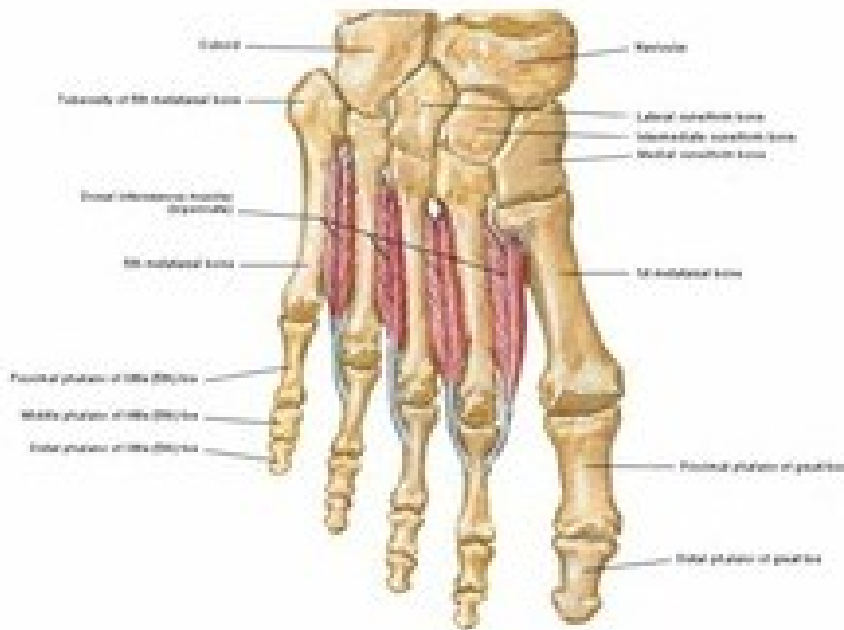
MP joints adduction – grade 3,2,1,0



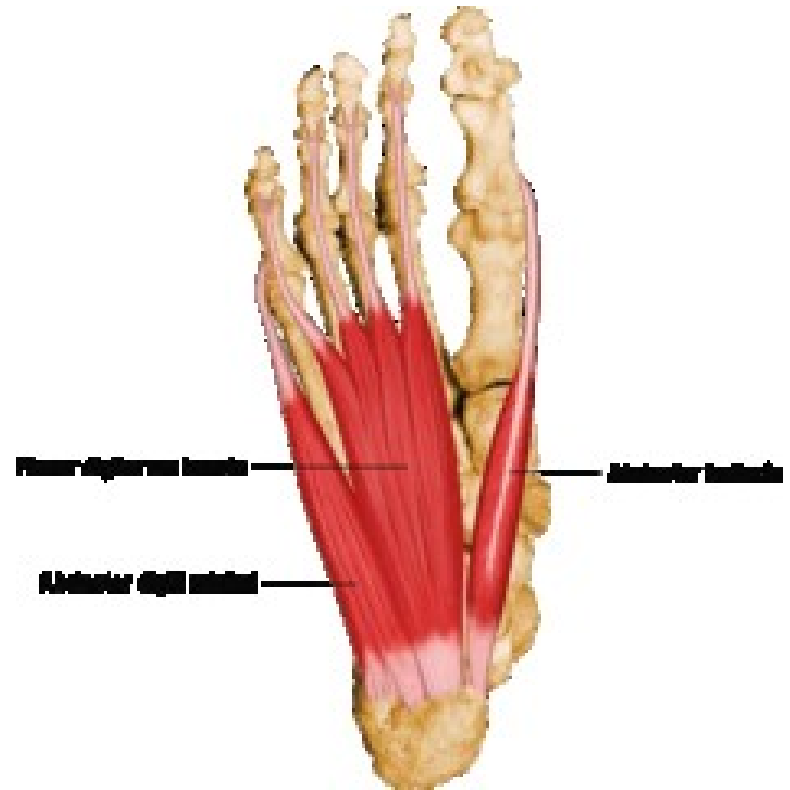
- For grade 3,2,1,0 we just want to see the ability of the patient to make an adduction (notice that adduction of the fingers can be passive action)

MP joints abduction

Interosseous Muscles of Foot
Dorsal View



Dorsal interosseals



Abductor hallucis

Abductor digiti minimi

Dorsal interosseals

Origin:

1st: Adjacent sides of 1st-2nd MT

2nd: Adjacent sides of 2nd-3rd MT

3rd: Adjacent sides of 3rd-4th MT

4th: Adjacent sides of 4th-5th MT

Insertion:

1st: Med. side of Base of PP of 2nd Toe

2nd: Lat side of Base of PP of 2nd Toe

3rd: Lat side of Base of PP of 3rd Toe

4th: Lat side of Base of PP of 4th Toe

Extensor Hood of Toes (2nd, 2nd, 3rd, 4th)

Action:

Abduct 2nd, 3rd, 4th Toes (P-Ad vs D-Ab)

Innervation:

1st-3rd: Deep branch of Lateral Plantar Nerve

4th: Plantar Digital branch of Superficial branch of Lateral Plantar Nerve

Abductor hallucis

Origin:

- Med. Process of Calcaneal Tuberosity
- Flexor Retinaculum
- Deep Surface of Plantar Aponeurosis
- Tuberosity of Navicular

Insertion:

- Fibers blend with med. tendon of FHB, med. Sesamoid, Plantar Plate, Extensor Hood
- Insert on Med.Plant. aspect of Base of PP of Hallux

Action:

- Abduct Hallux
- Aid in Plantarflexion of Hallux

Innervation:

- Medial Plantar Nerve

Abductor digiti minimi

Origin:

Lat. margin of Med. Process of Calcaneal Tuberosity

Lat. Process of Calcaneal Tuberosity

Deep Surface of Plantar Aponeurosis

Tuberosity of Base of 5th MT

Insertion:

Lateral aspect of Base of PP of 5th Toe

Action:

Abduct 5th Toes

Innervation:

Lateral Plantar Nerve (before Sup. & Deep divisions)

MP joints abduction – grade 5,4



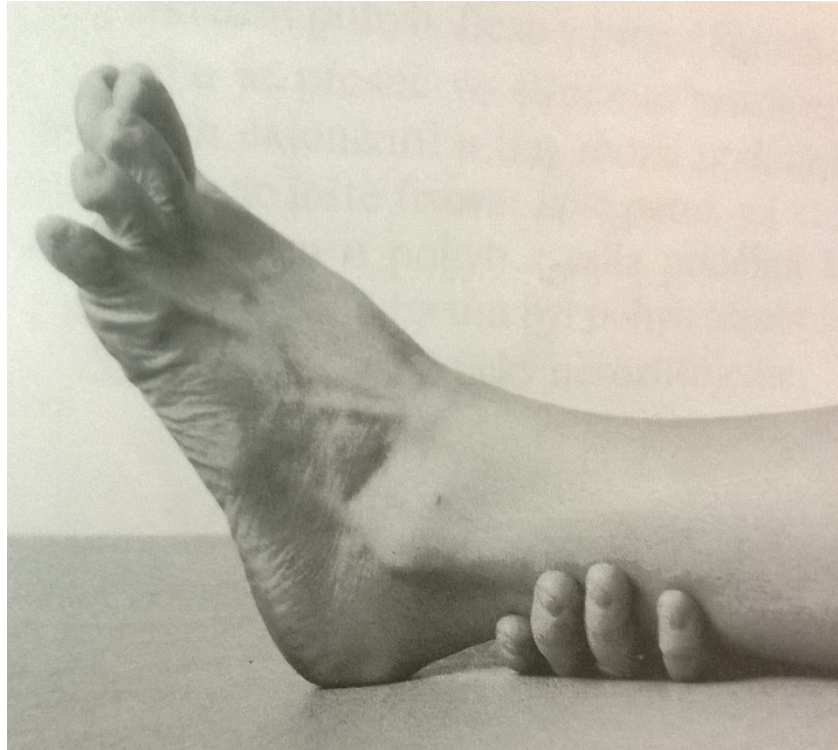
Position: patient lies supine (or sits), knee extended, foot in central position

Fixation: not necessary

Movement: MP joints abduction

Resistance: PT puts resistance at the phalanges against the movement

MP joints abduction – grade 3,2



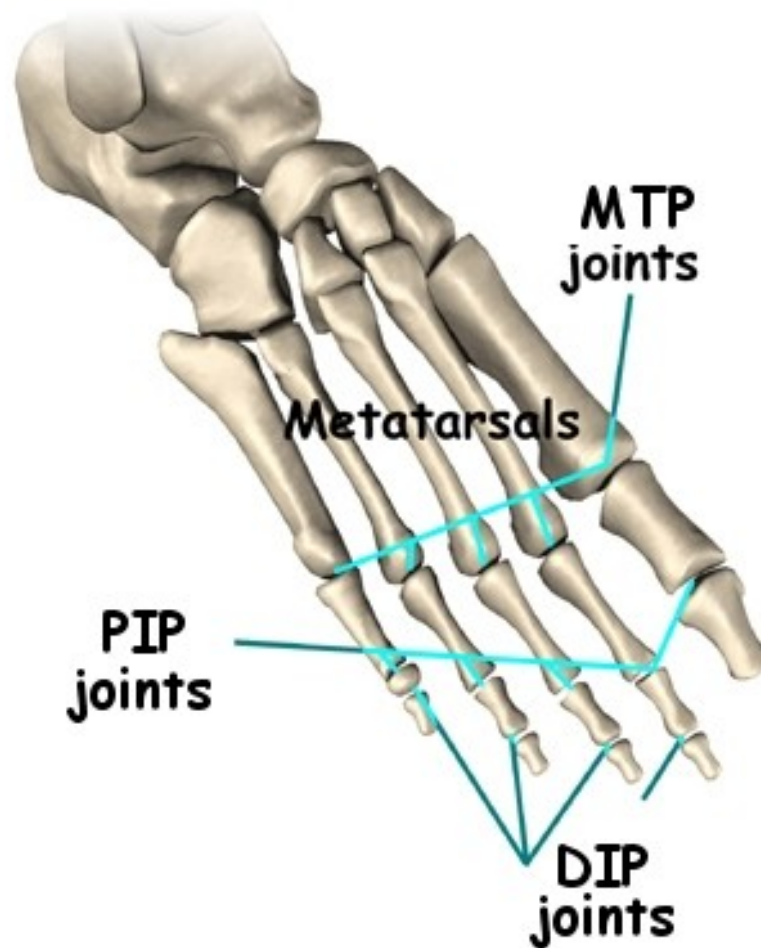
Position: patient lies supine (or sits), knee extended, foot in central position
Fixation: calf from the dorsal side (the ankle in central position)
Movement: MP joints abduction

MP joints abduction – grade 1,0

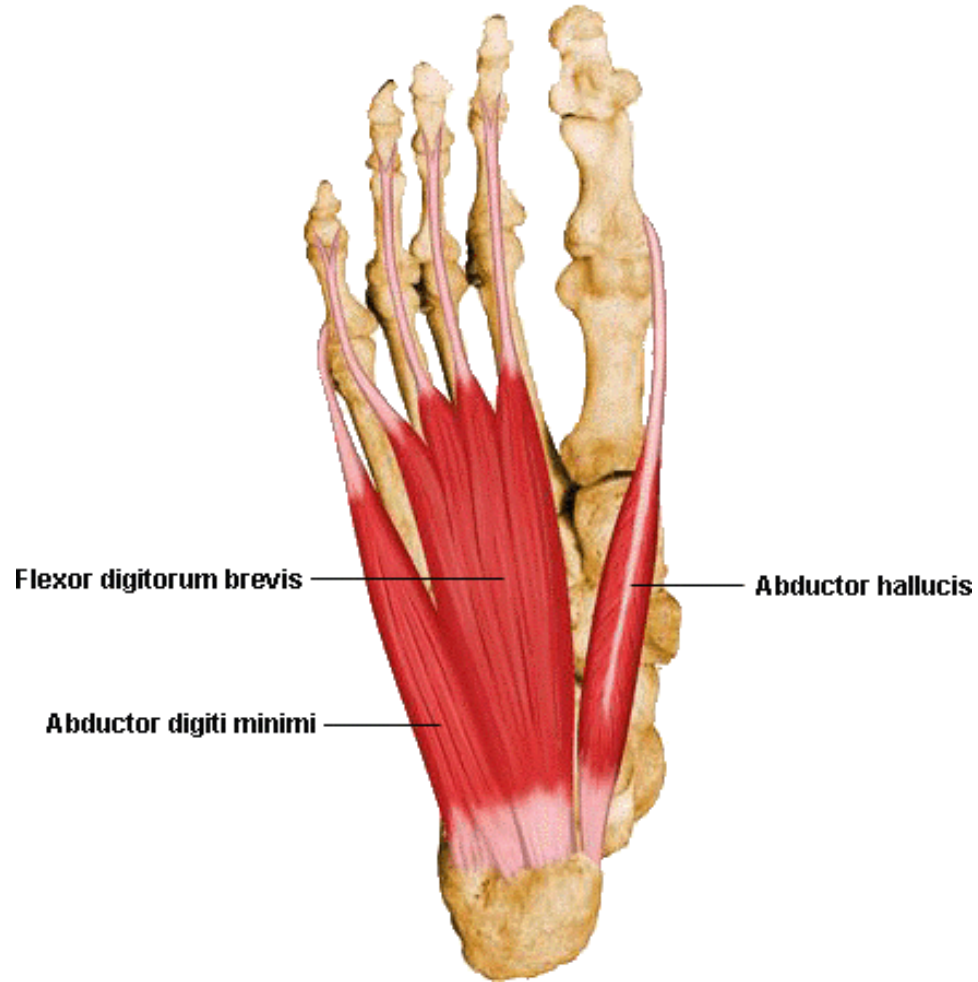


Position: patient lies supine (or sits), knee slightly flexed, foot in central position
Attempt to move: palpation of abductor hallucis and abductor digiti minimi, observe the tremble of the fingers during patient's attempt to move

Interphalangeal joints (IP) of the fingers



Proximal interphalangeal joints (PIP) flexion



Flexor digitorum brevis

Flexor digitorum brevis

Origin

Medial process of calcaneal tuberosity

Insertion

Middle phalanx of 2nd through 5th toes

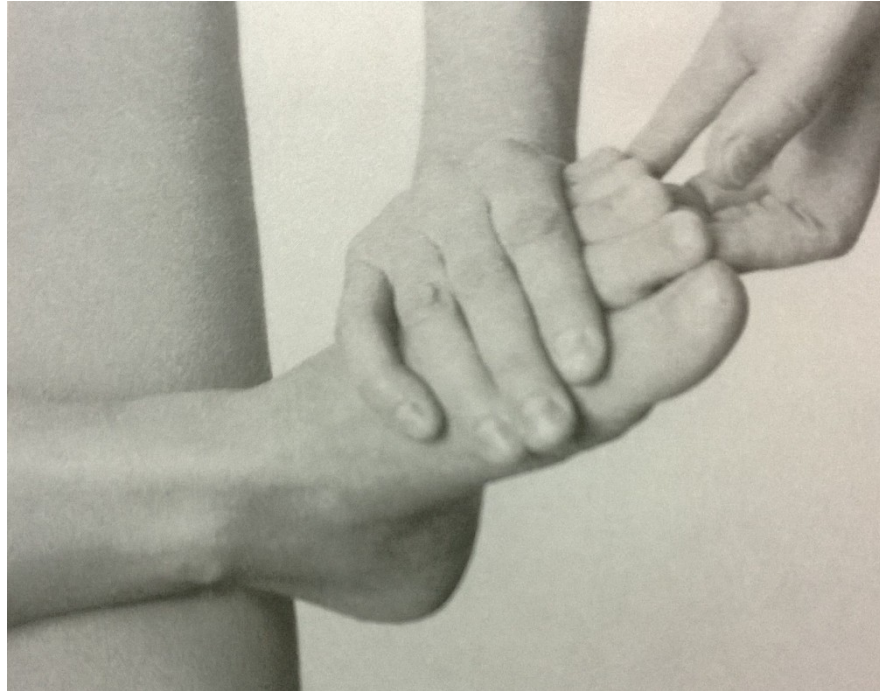Action

Flexes the MP joint of the 2nd through 5th digit

Innervation

Tibial nerve

Fingers PIP flexion – grade 5,4



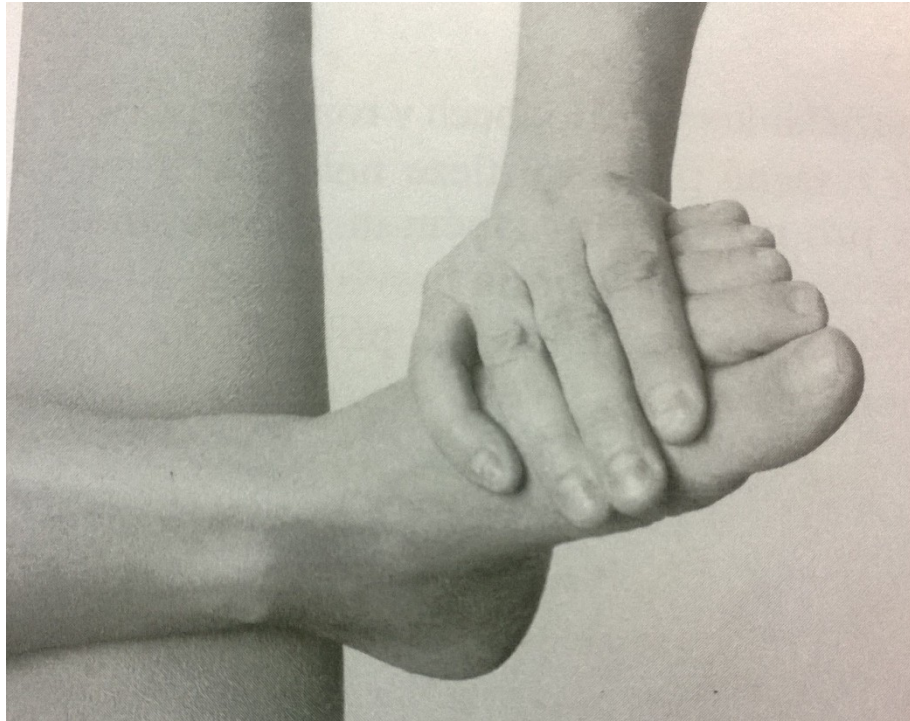
Position: patient lies supine (or sits), foot in central position

Fixation: PT fix metatarses (with the fingers on dorsal side of the foot) and proximal phalanges (with the thumb on plantar side of the foot)

Movement: II.-V. PIP joint flexion in full range of motion

Resistance: PT puts resistance at the plantar side of middle phalanges (II.-V.) against the movement

Fingers PIP flexion – grade 3,2 (1,0)



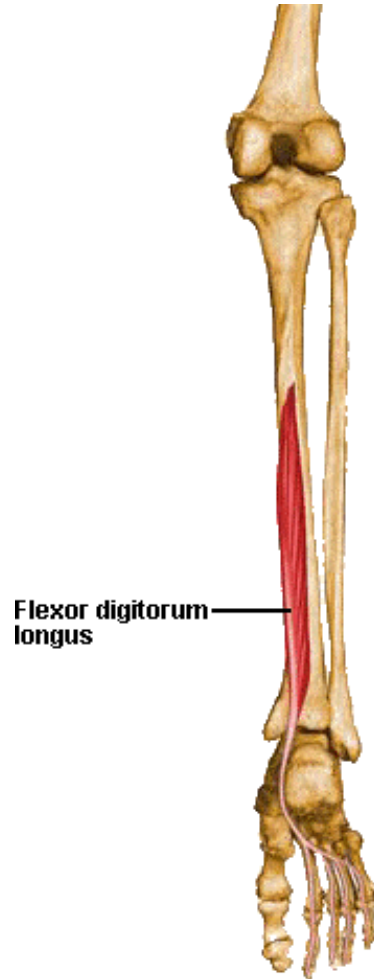
Position: patient lies supine (or sits), foot in central position

Fixation: PT fix metatarses (with the fingers on dorsal side of the foot) and proximal phalangs (with the thumb on plantar side of the foot)

Movement: II.-V. PIP joint flexion in full range of motion

Grade 1,0: observe the tremble of the fingers during patients attempt to move

Distal interphalangeal joints (DIP) flexion



Flexor digitorum longus

Flexor digitorum longus

Origin

- Posterior surface of tibia distal to popliteal line

Insertion

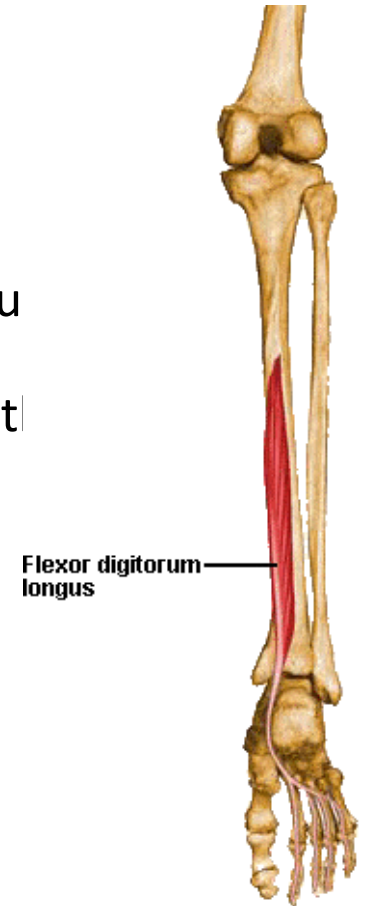
- Splits into four slips after passing through medial intermuscular septum of plantar surface of foot
- these slips then insert on plantar surface of bases of 2nd - 5th distal phalanges

Action


- Flexes toes 2 - 5; also helps in plantar flexion of ankle

Innervation

- Tibial nerve (S2, S3)



Fingers DIP flexion – grade 5,4



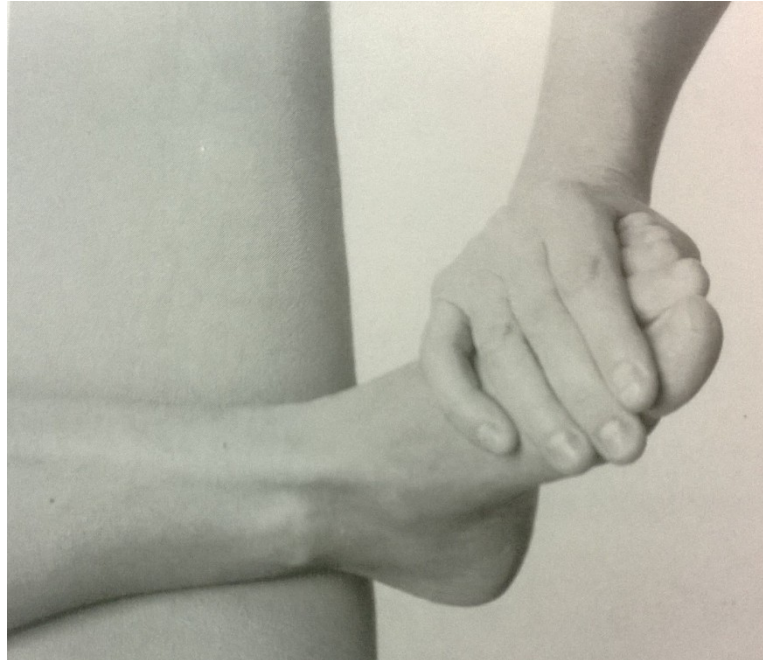Position: patient lies supine (or sits), foot in central position

Fixation: PT fix metatarses (with the fingers on dorsal side of the foot) and middle phalangs (with the thumb on plantar side of the foot)

Movement: II.-V. DIP joint flexion in full range of motion

Resistance: PT puts resistance at the plantar side of distal phalanges (II.-V.) against the movement

Fingers DIP flexion – grade 3,2 (1,0)



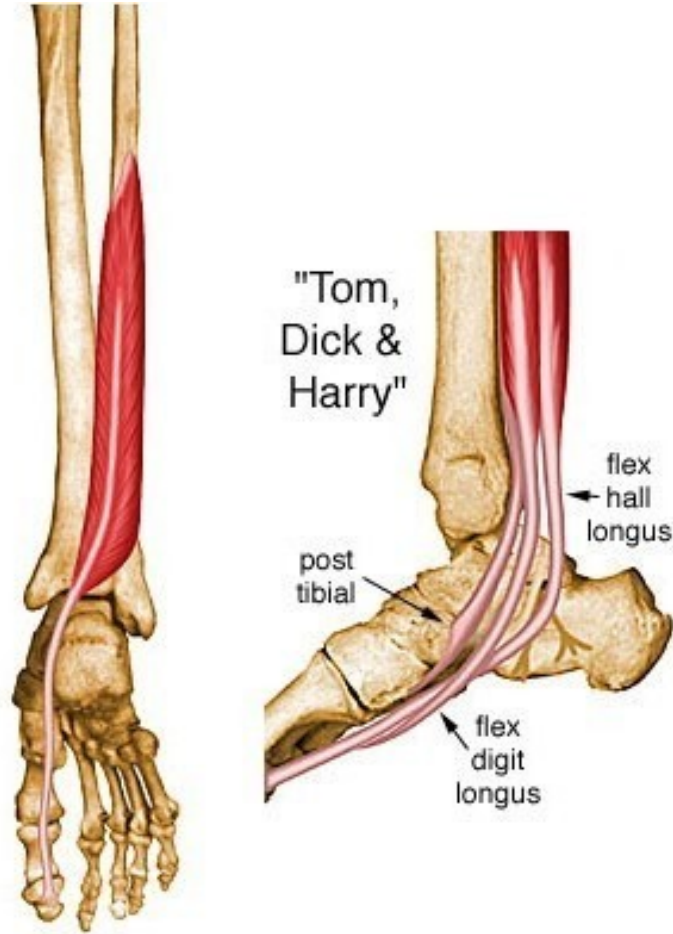Position: patient lies supine (or sits), foot in central position

Fixation: PT fix metatarses (with the fingers on dorsal side of the foot) and middle phalangs (with the thumb on plantar side of the foot)

Movement: II.-V. DIP joint flexion in full range of motion

Grade 1,0: observe the tremble of the fingers during patients attempt to move

Toe interphalangeal joint (IP) flexion



Flexor hallucis longus

Flexor hallucis longus

Origin

- Inferior 2/3 of posterior surface of fibula, lower part of interosseous membrane

Insertion

- Plantar surface of base of distal phalanx of great toe

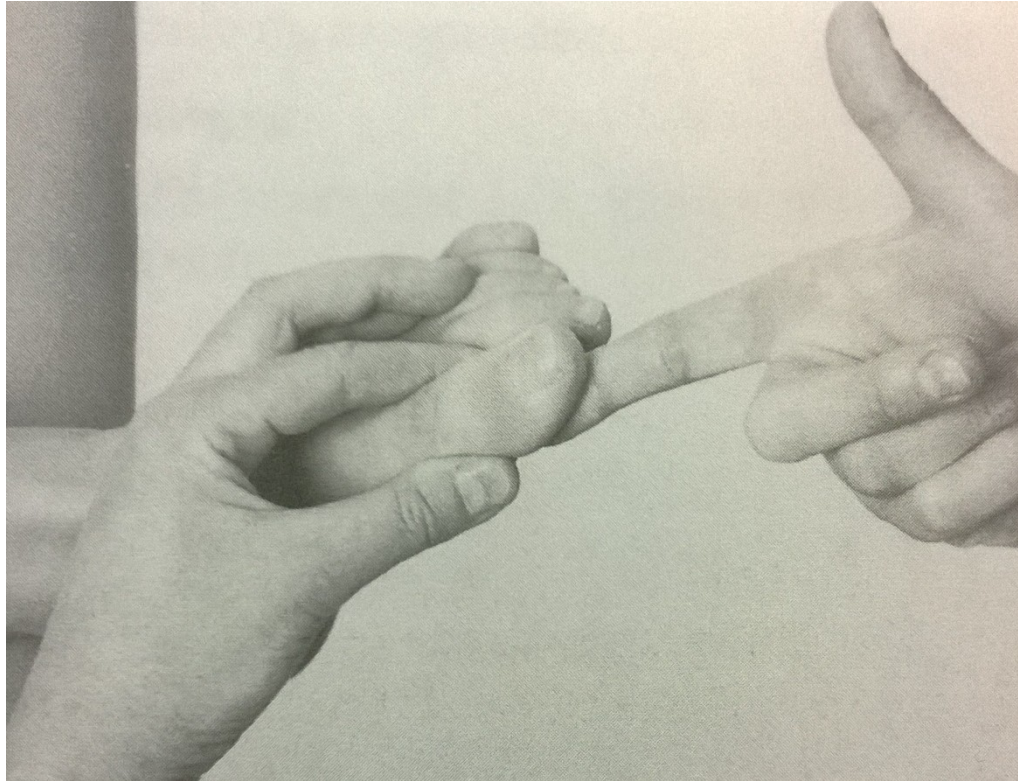
Action

- Flexes great toe, helps to supinate ankle, and is a very weak plantar flexor of ankle

Innervation

- Tibial nerve (S2, S3) (S2, S3)

Toe IP flexion – grade 5,4



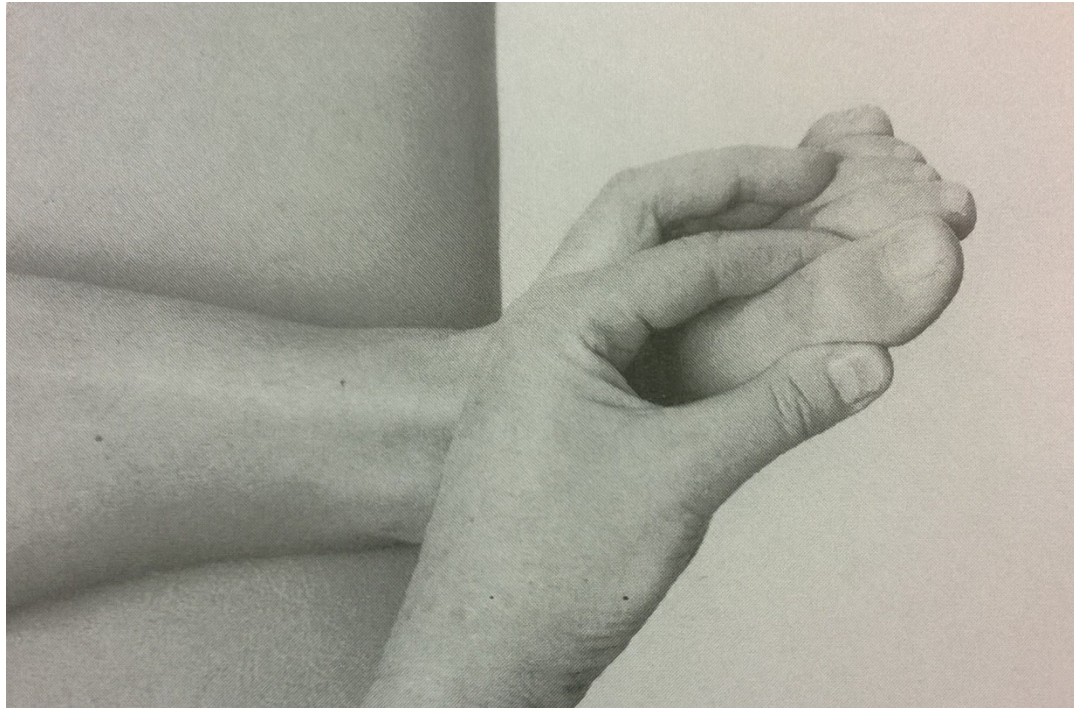
Position: patient lies supine (or sits), foot in central position

Fixation: PT fix proximal phalange of the toe from the sides, MP joint slightly hyperextended

Movement: toe IP joint flexion

Resistance: PT puts resistance at the plantar side of distal phalange against the movement

Toe IP flexion – grade 3,2

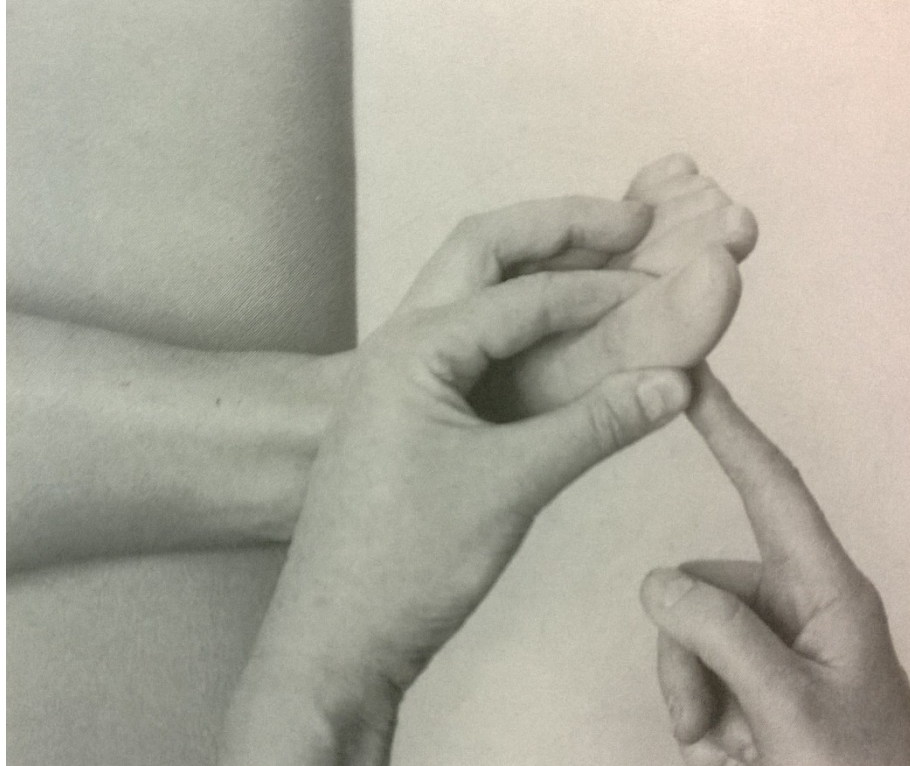

Position: patient lies supine (or sits), foot in central position

Fixation: PT fix proximal phalanx of the toe from the sides, MP joint slightly hyperextended

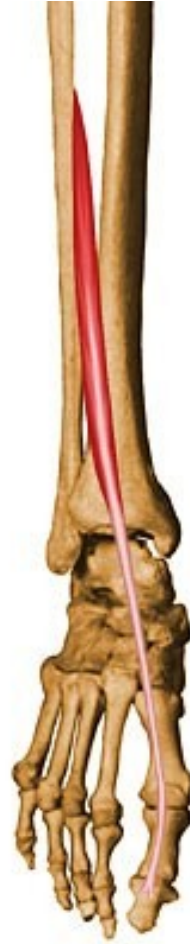Movement: toe IP joint flexion

Toe IP flexion – grade 1,0



Observe the tremble of the toe during patients attempt to move, or palpate the trace of contraction on the plantar side of proximal phalang

Toe interphalangeal joint (IP) extension



Extensor hallucis longus

Extensor hallucis longus

Origin

- Anterior surface of the fibula and the adjacent interosseous membrane

Insertion

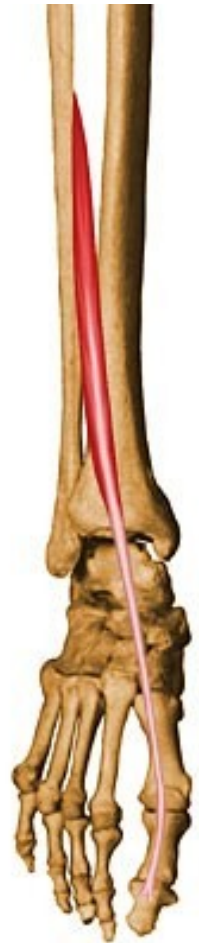- Base and dorsal center of distal phalanx of great toe

Action

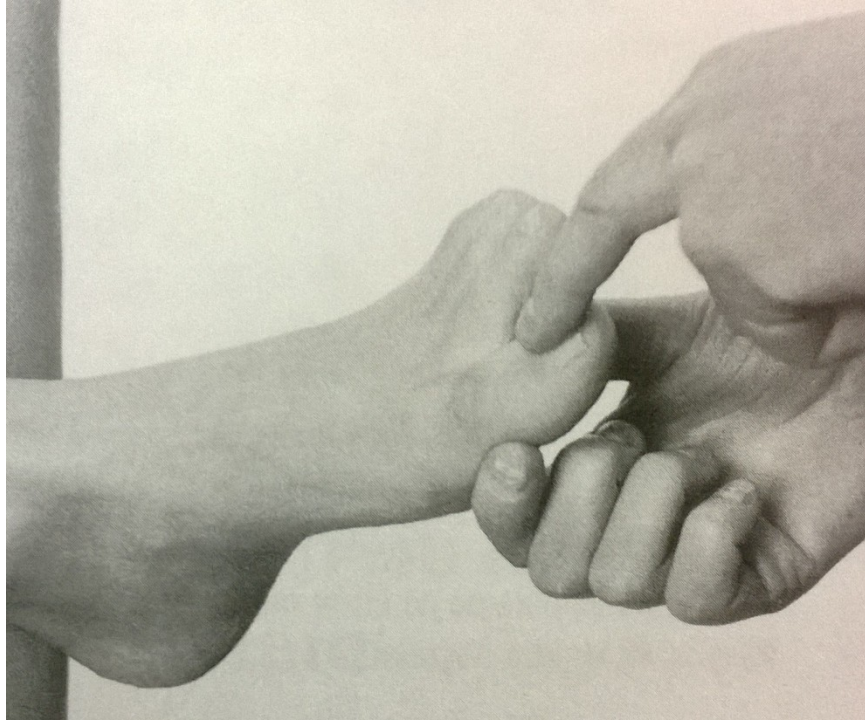
- Extends great toe and dorsiflexes ankle

Innervation

- Deep peroneal nerve (L4, L5, S1) (L4, L5, S1)



Toe IP extension – grade 5,4



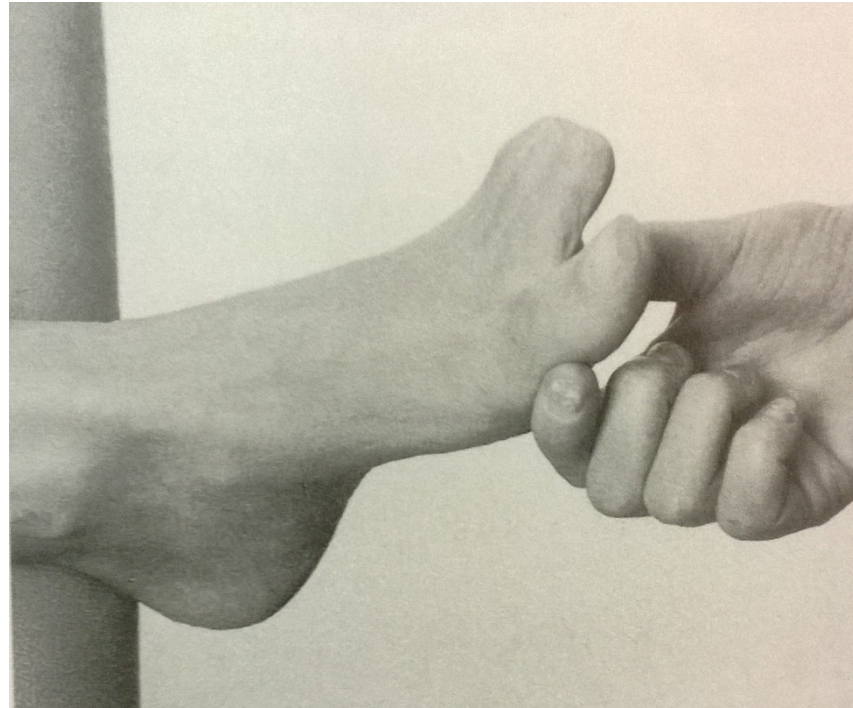Position: patient lies supine (or sits), foot in central position

Fixation: PT fix proximal phalang of the toe from the sides

Movement: toe IP joint extension

Resistance: PT puts resistance at the dorsal side of distal phalang against the movement

Toe IP extension – grade 3,2

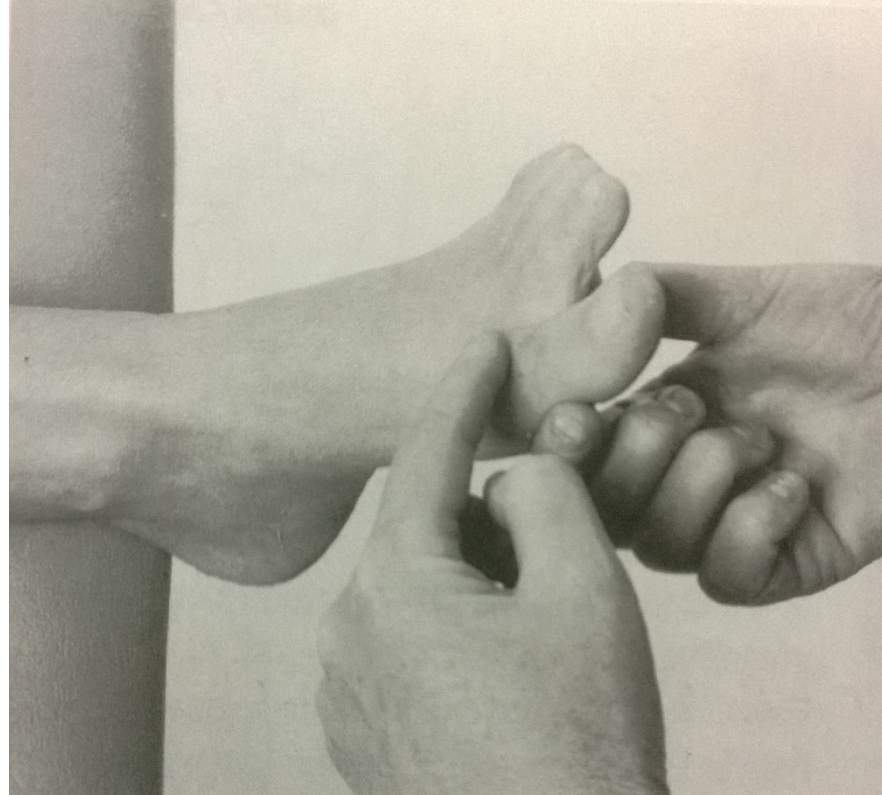


Position: patient lies supine (or sits), foot in central position

Fixation: PT fix proximal phalange of the toe from the sides

Movement: toe IP joint extension

Toe IP extension – grade 1,0



PT palpates the trace of contraction on the level of MP joint of the toe (dorsal side)

Movement of the fingers and toe – notes:

- Foot has to be in a central position
- It is necessary to fix properly

Thank you for your attention 😊

