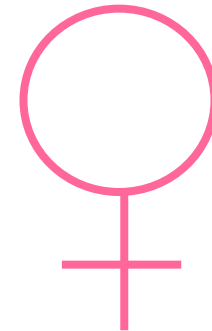


# The female reproductive system

Aleš Hampl

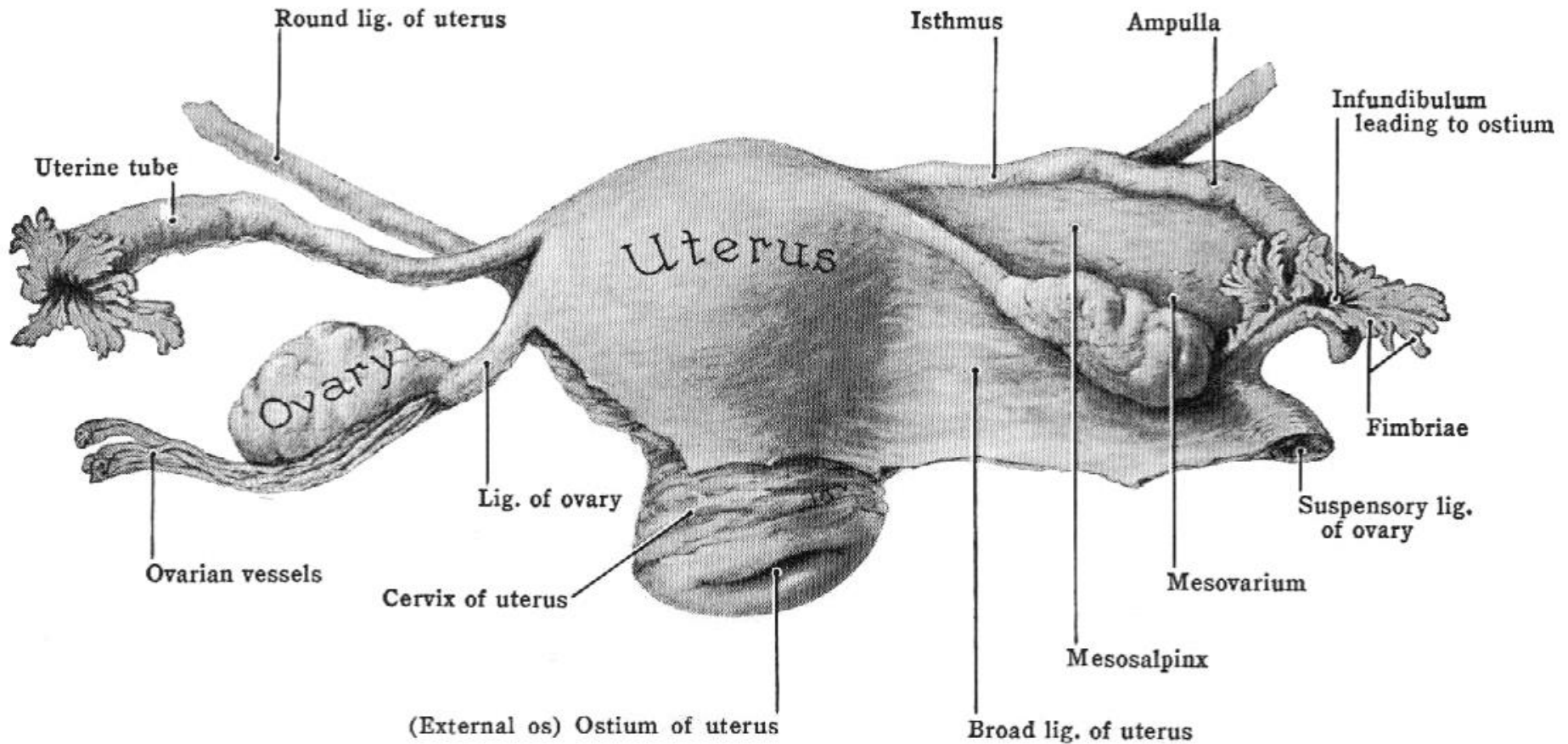
November 2021



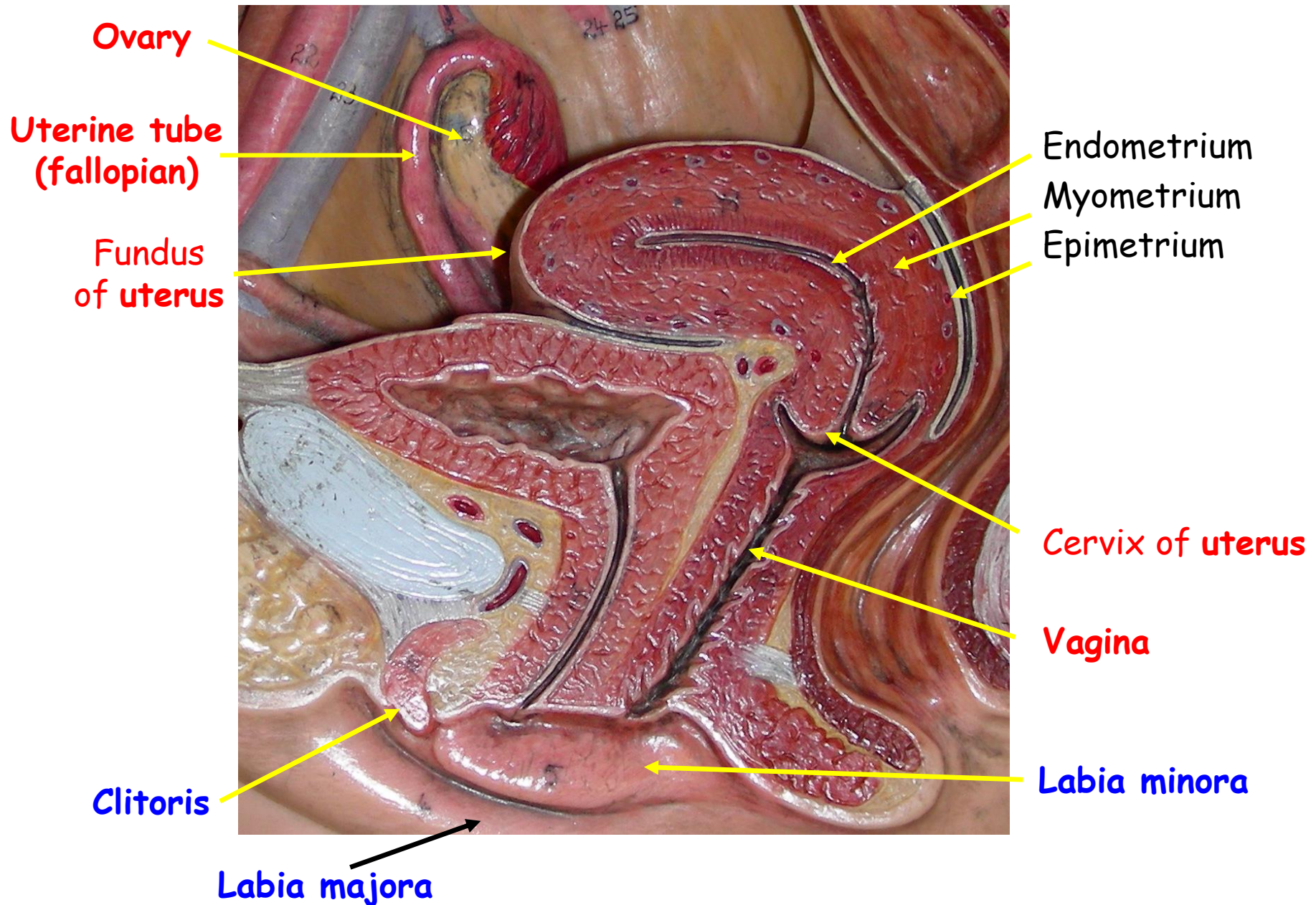
# Functions of the female reproductive system

1. **Oogenesis**
2. **Copulation** - receives sperm from male
3. **Hormone production**
4. Provides sites for egg **fertilization, implantation, and development**
5. Acts as **birth canal**

# Female genital organs - Gross anatomy 1

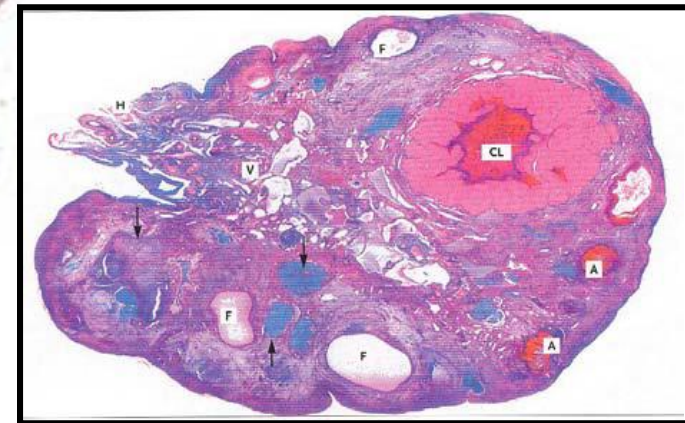
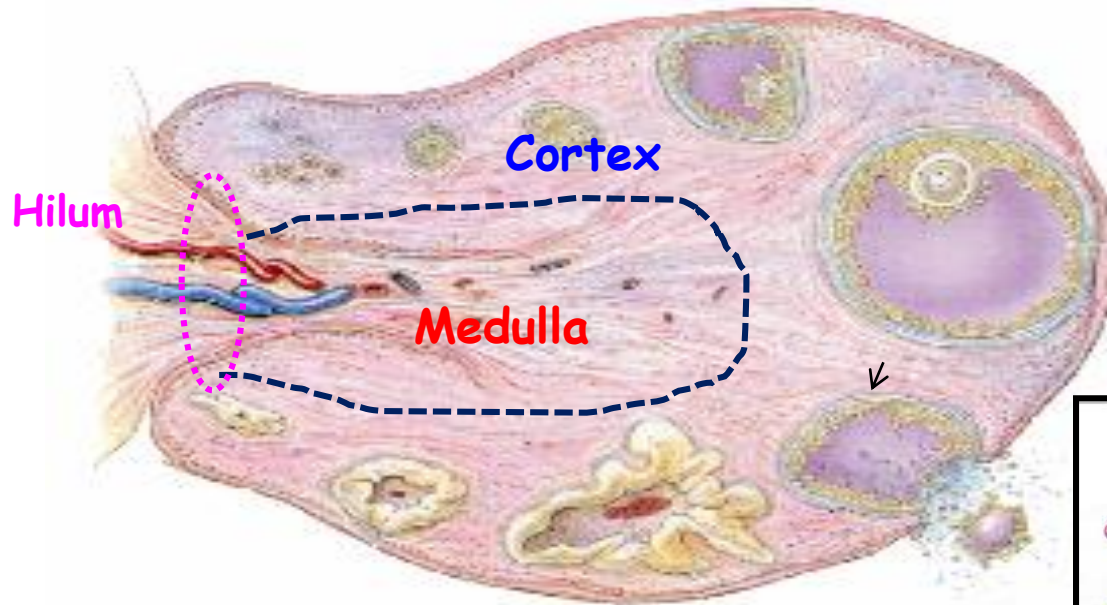


# Female genital organs - Gross anatomy 2



Length - 3 cm  
Width - 1.5 cm  
Thickness - 1 cm

# Ovary - Overall structure



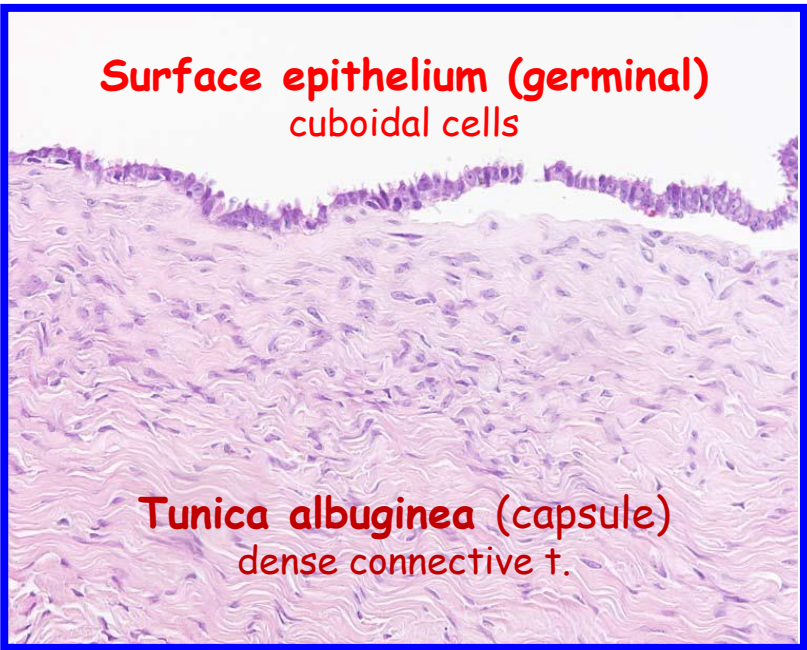
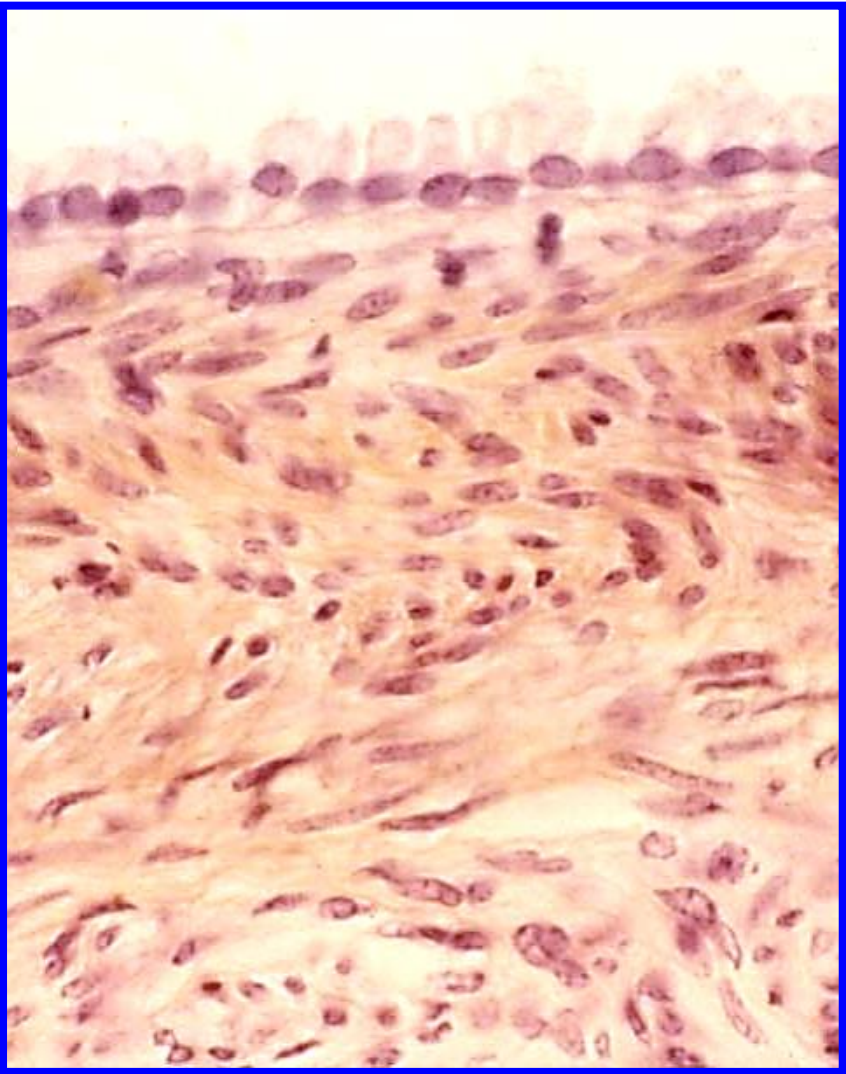
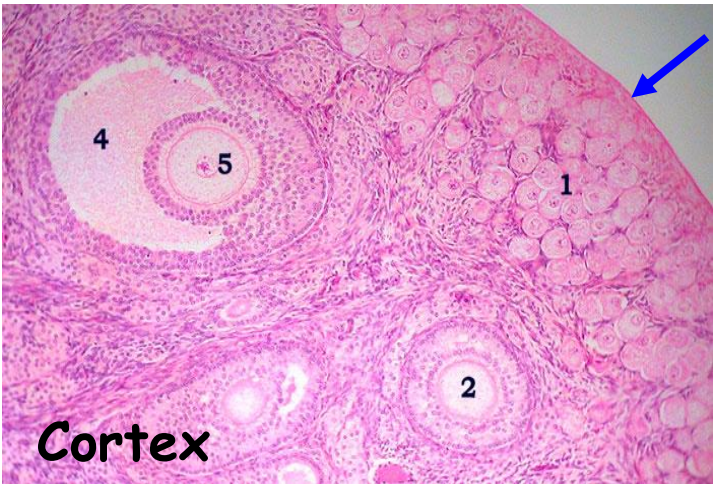
## Cortex

- Follicles
- Highly vascularized stroma

## Medulla

- Vessels
- Loose connective tissue

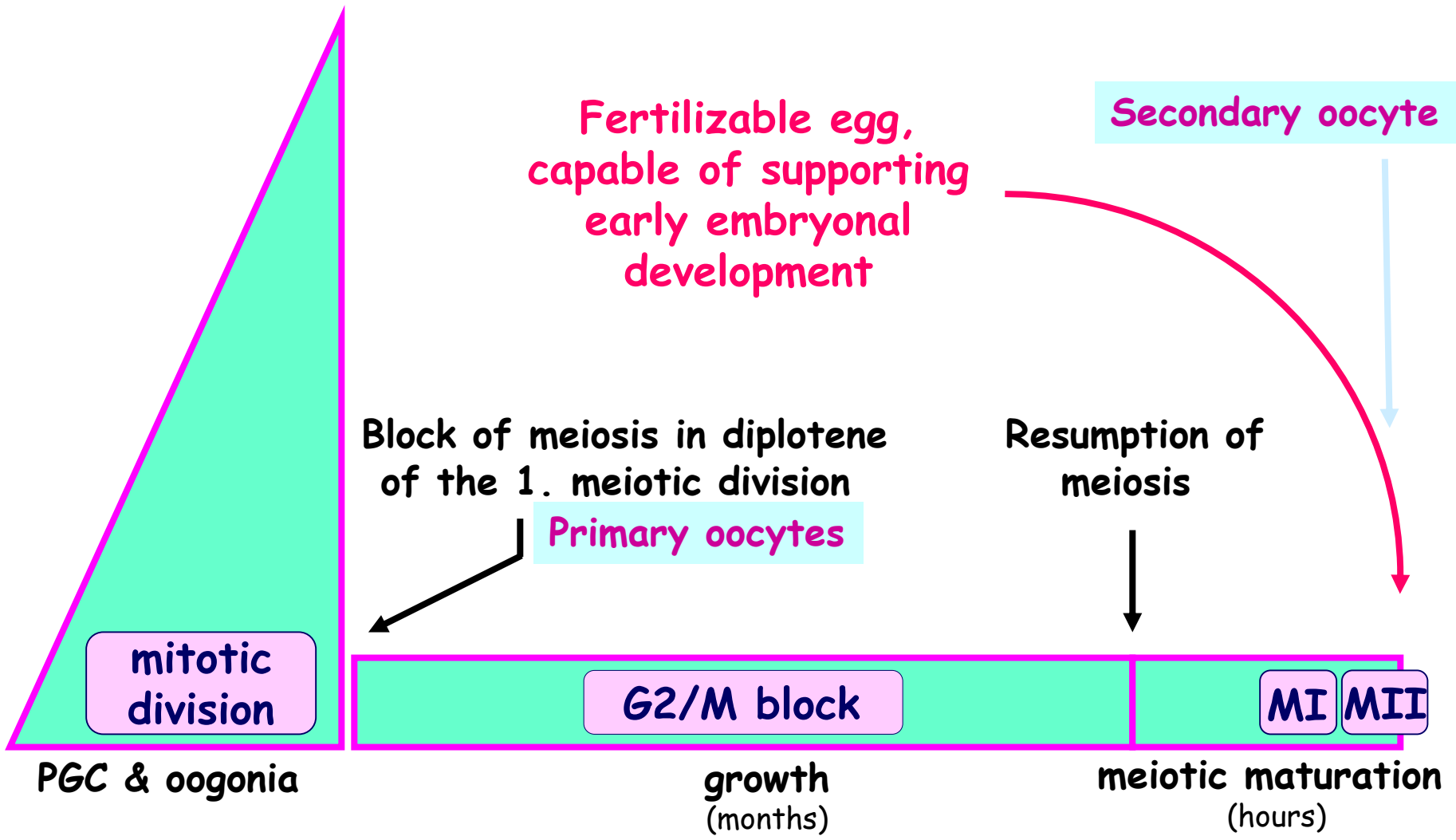
# Ovary - Surface

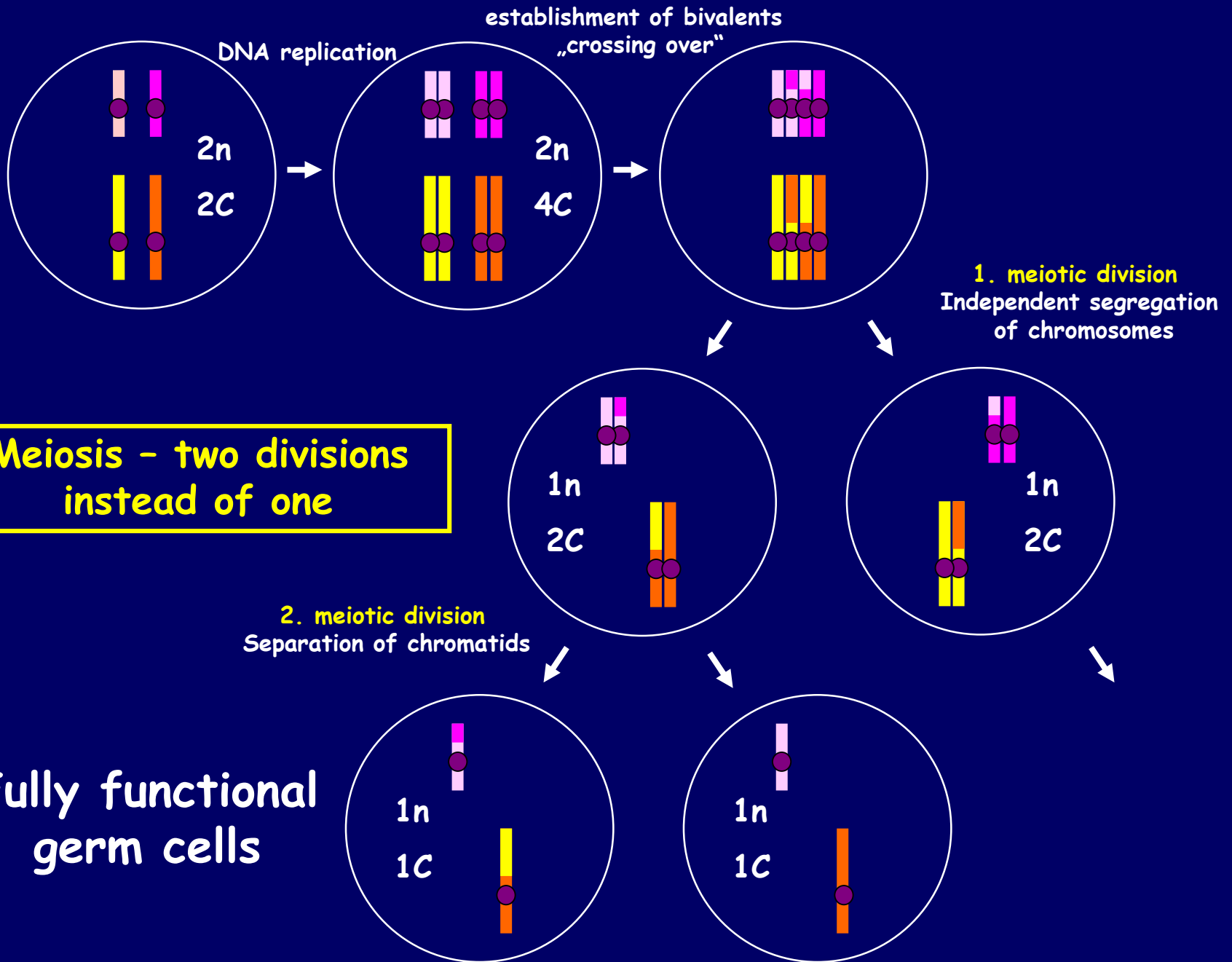


**Surface epithelium (germinal)**  
cuboidal cells

**Tunica albuginea (capsule)**  
dense connective t.

# Oogenesis - Key periods







# Oogenesis - Lifetime summary

At the end of 6 month of fetal development  
~ 6 - 7 millions of primary oocytes



Atresia

At the time of birth  
~ 500 thousands of primary oocytes

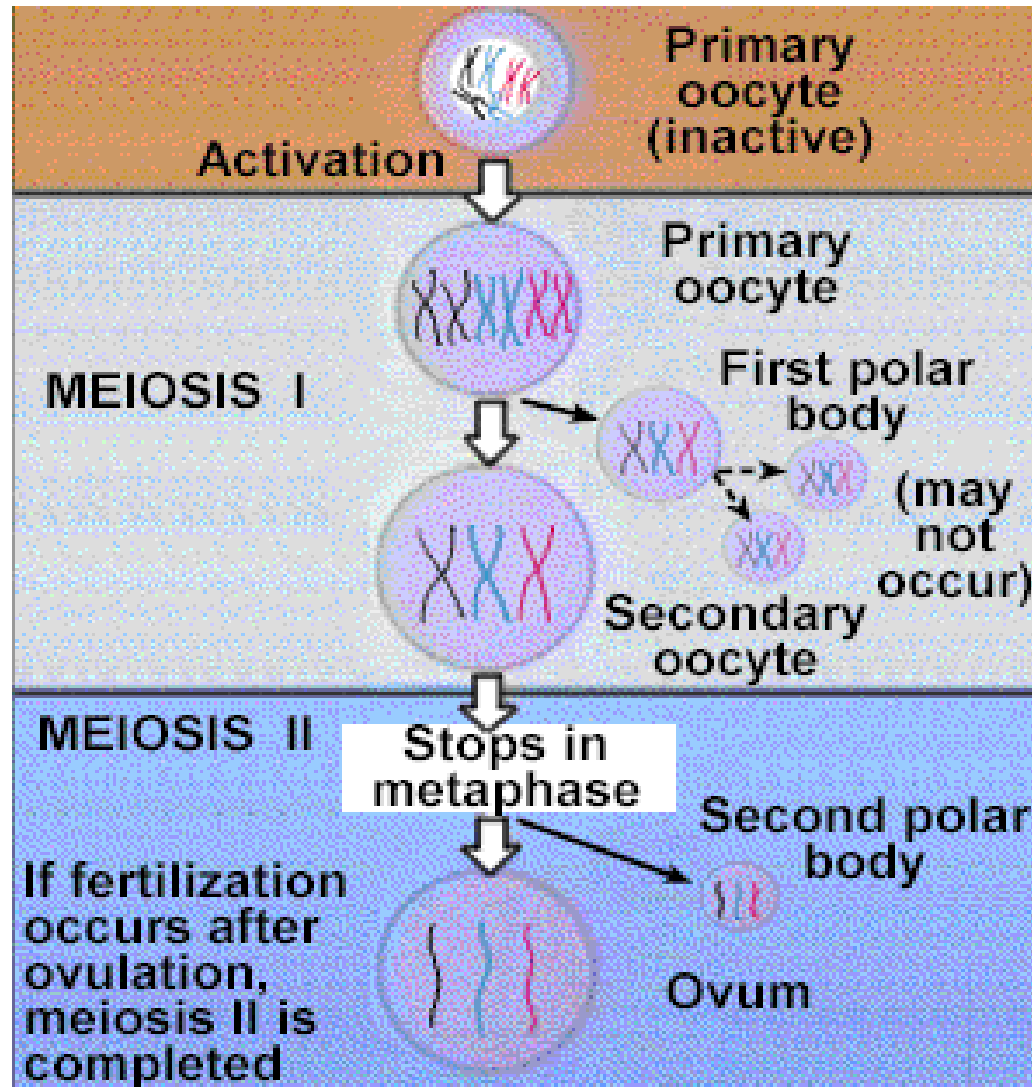


Atresia

Ovulation (~ 500 oocytes)

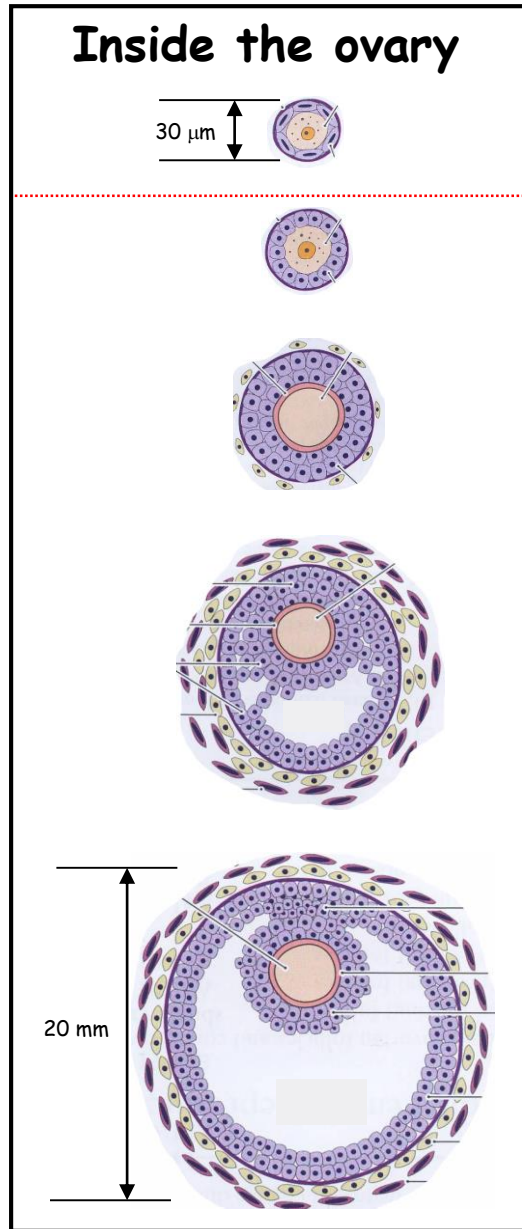
At the time of menopause  
max. 100 - 1000 remaining oocytes

# Oogenesis - Polar body production



# Oogenesis - stages of the oocyte development

Diplotene of the Meiosis I



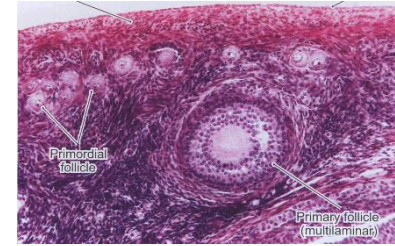**Primordial follicle**

**Recruited follicle (unilaminar)**

**Preantral follicle (multilaminar)**

**Secondary (antral) follicle (medium size)**

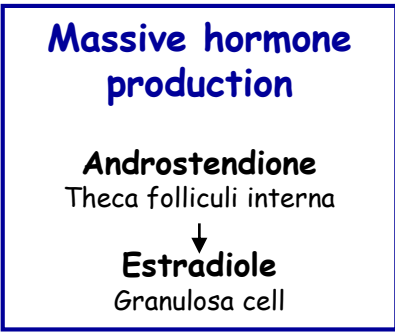**Tertiary (Graafian) follicle**



**Growth**

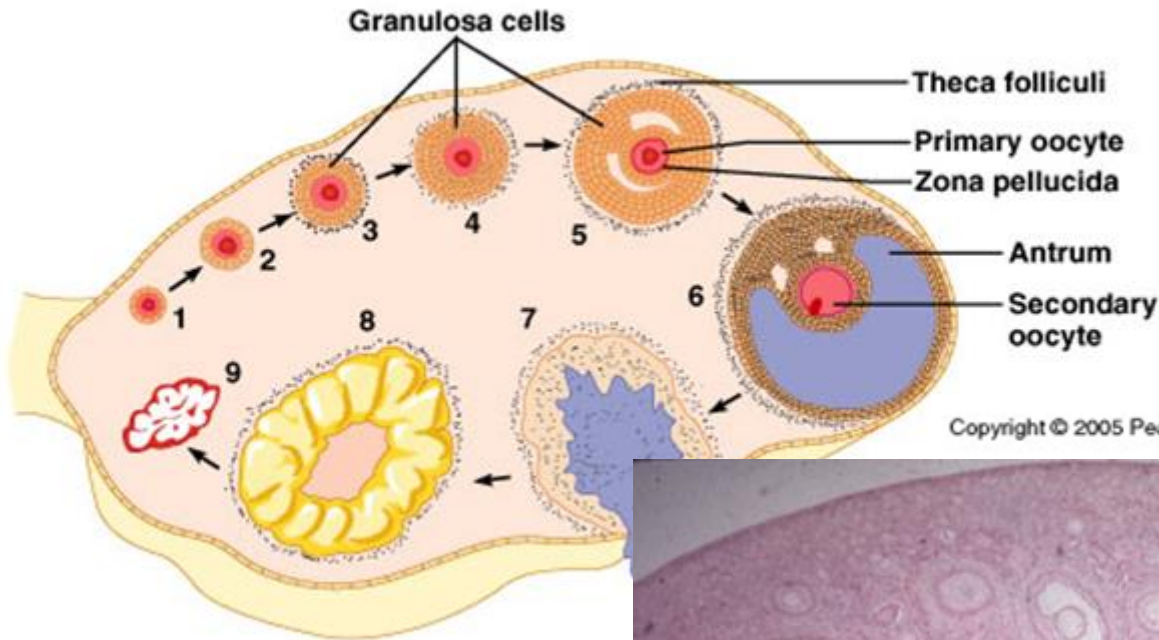
**Primary follicles**

**Selection of the Dominant follicle**  
(the one most sensitive to FSH)

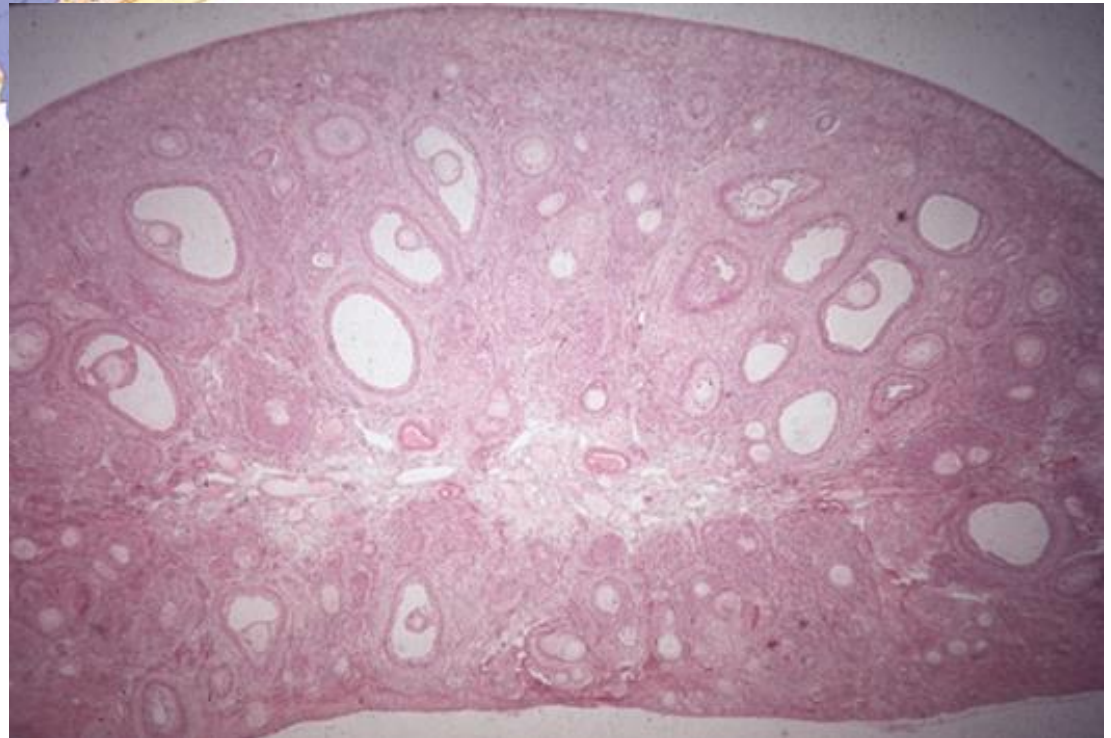


~14 days

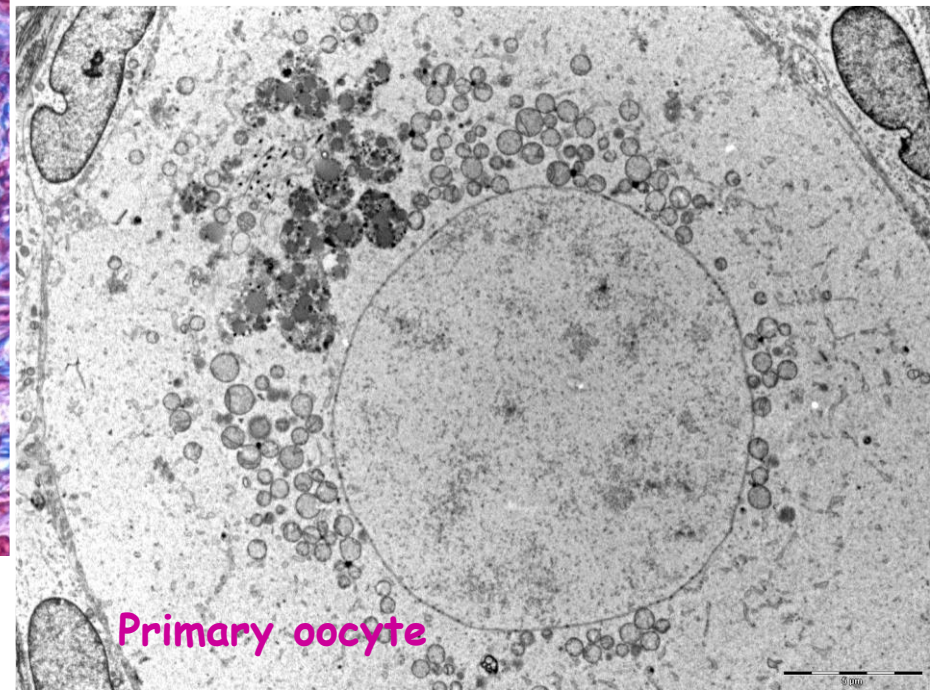
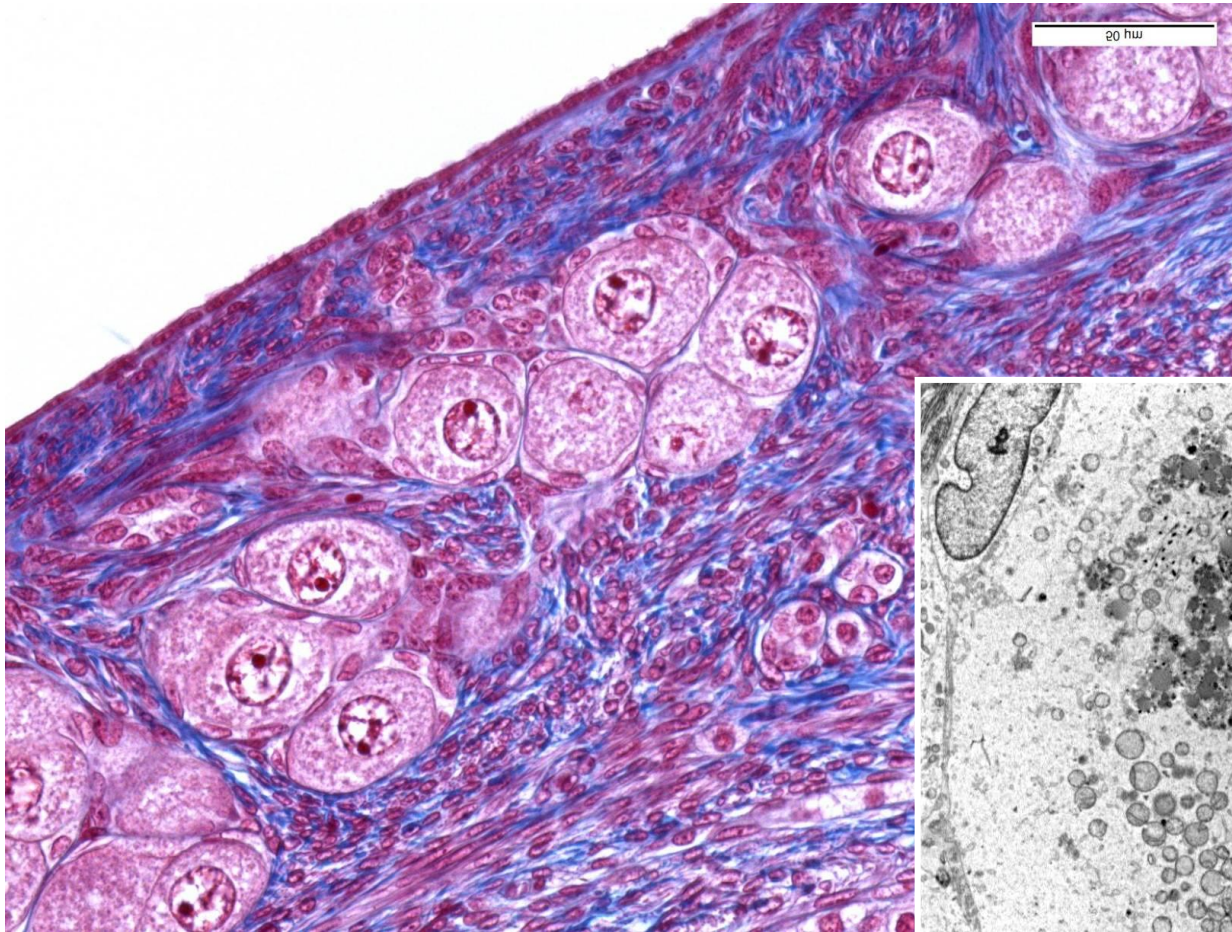
# Oogenesis - Overall picture inside the ovary



Copyright © 2005 Pearson Education, Inc., publishing as Benjamin Cummings.

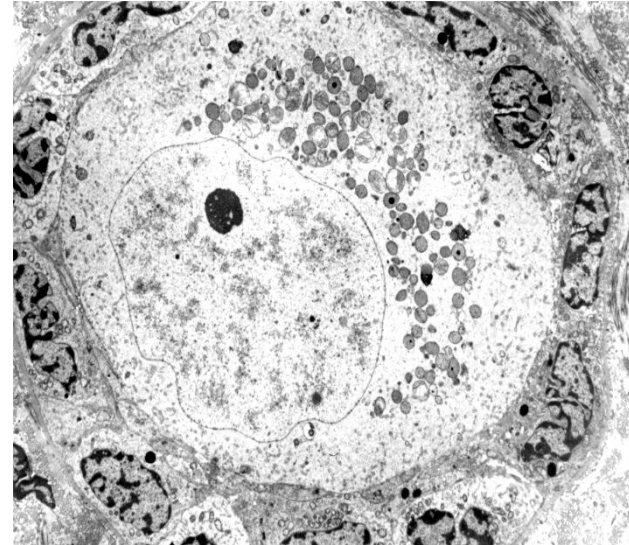
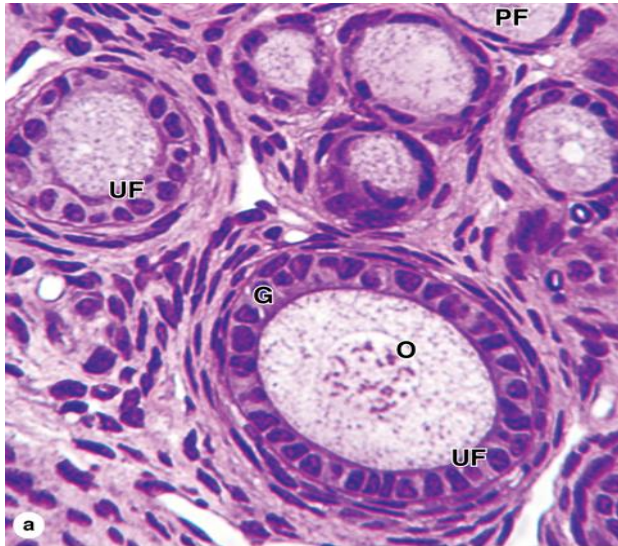


# Oogenesis - Primordial follicles

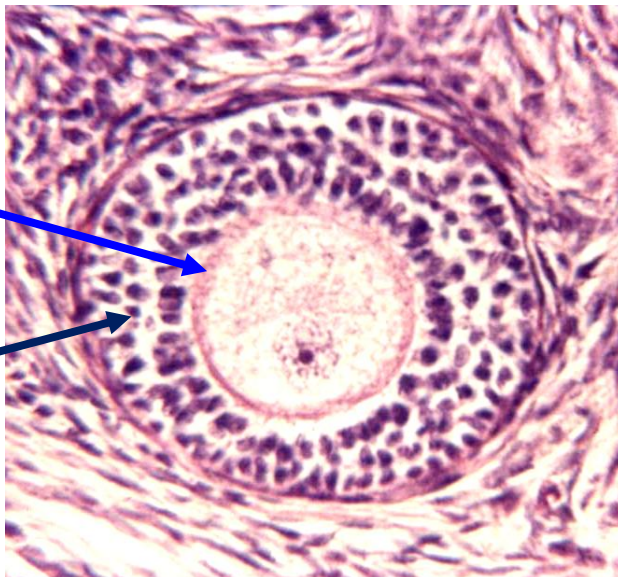

- Organelles around nucleus
- Abundant mitochondria
- Abundant RER

# Oogenesis - Primary follicles

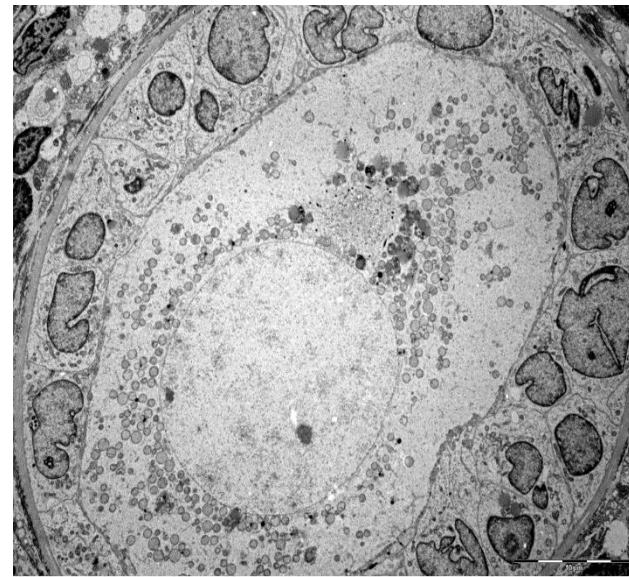


**Unilaminar**



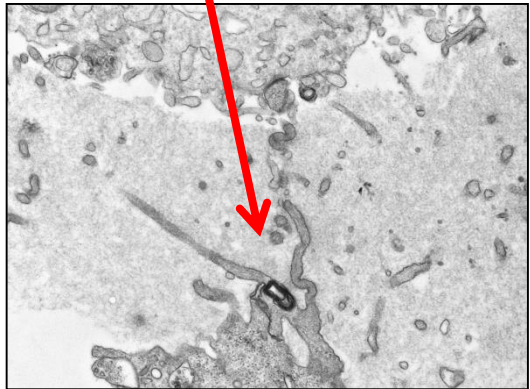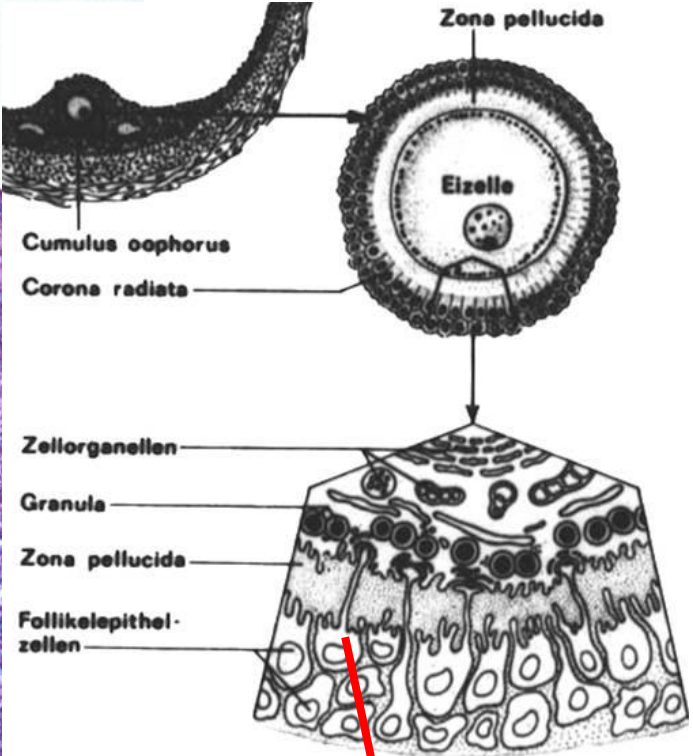
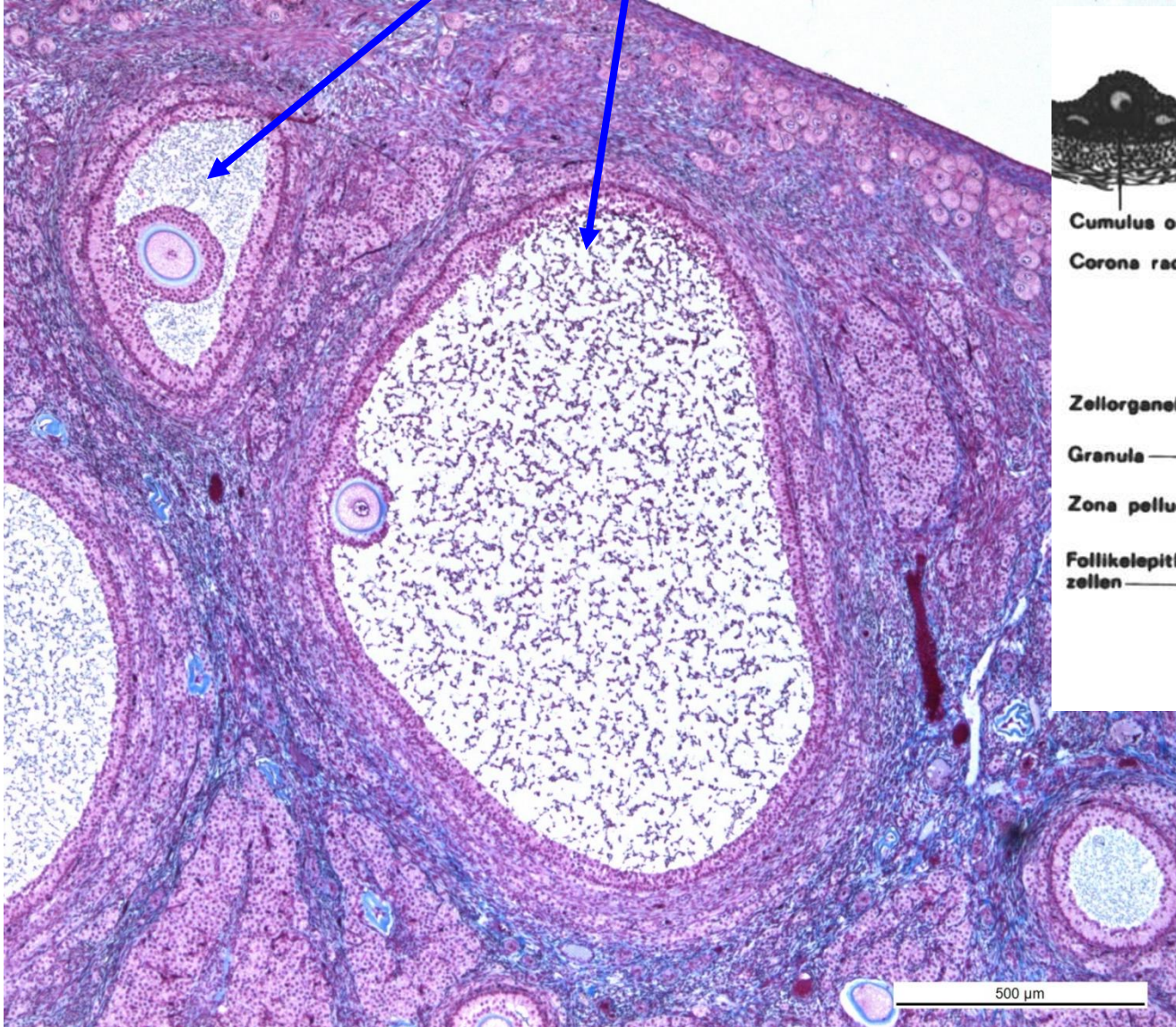
Zona pellucida  
(5-10  $\mu\text{m}$ )

Granulosa cells

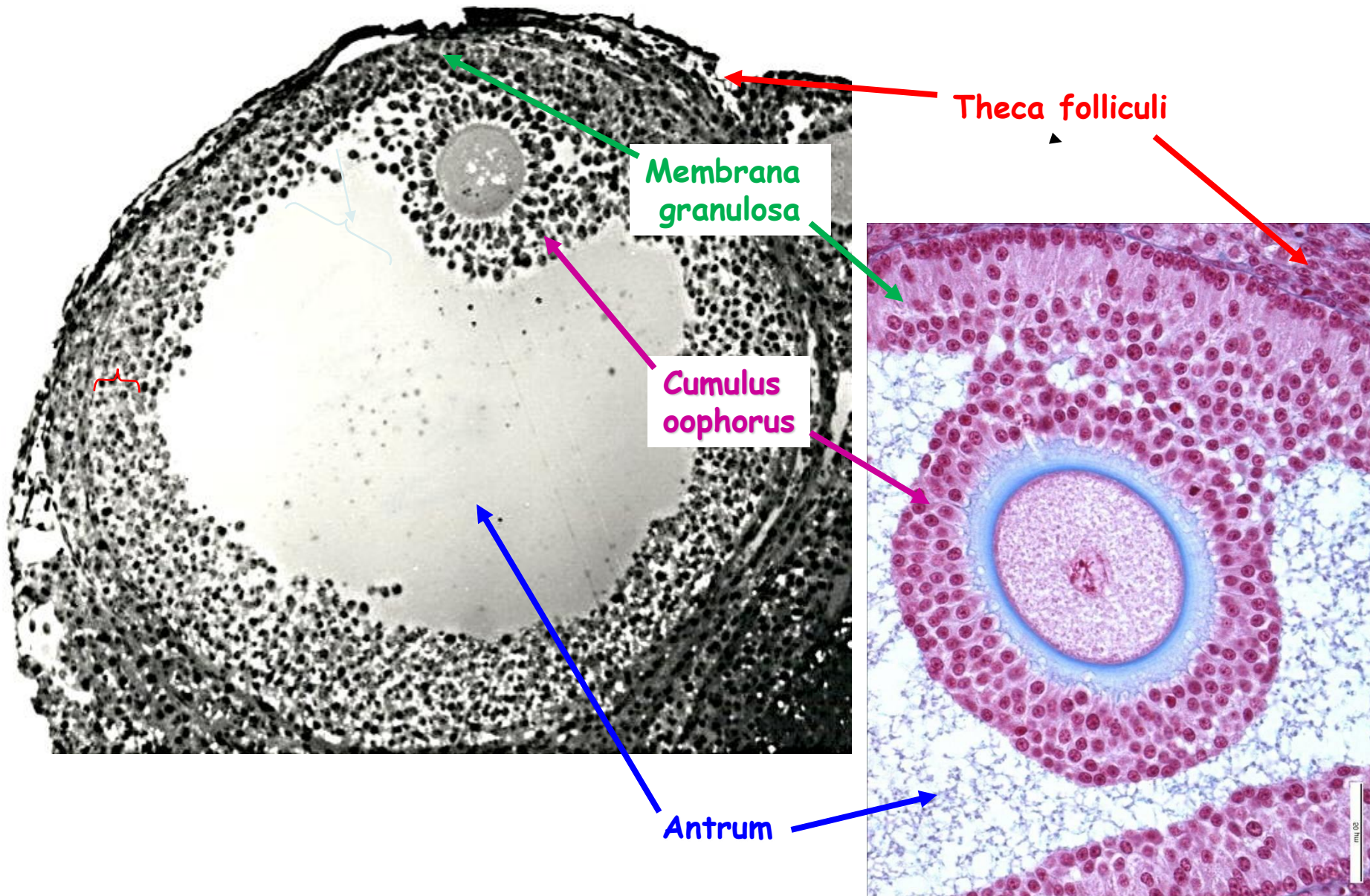


**Multilaminar**

# Oogenesis - Secondary (antral) follicles

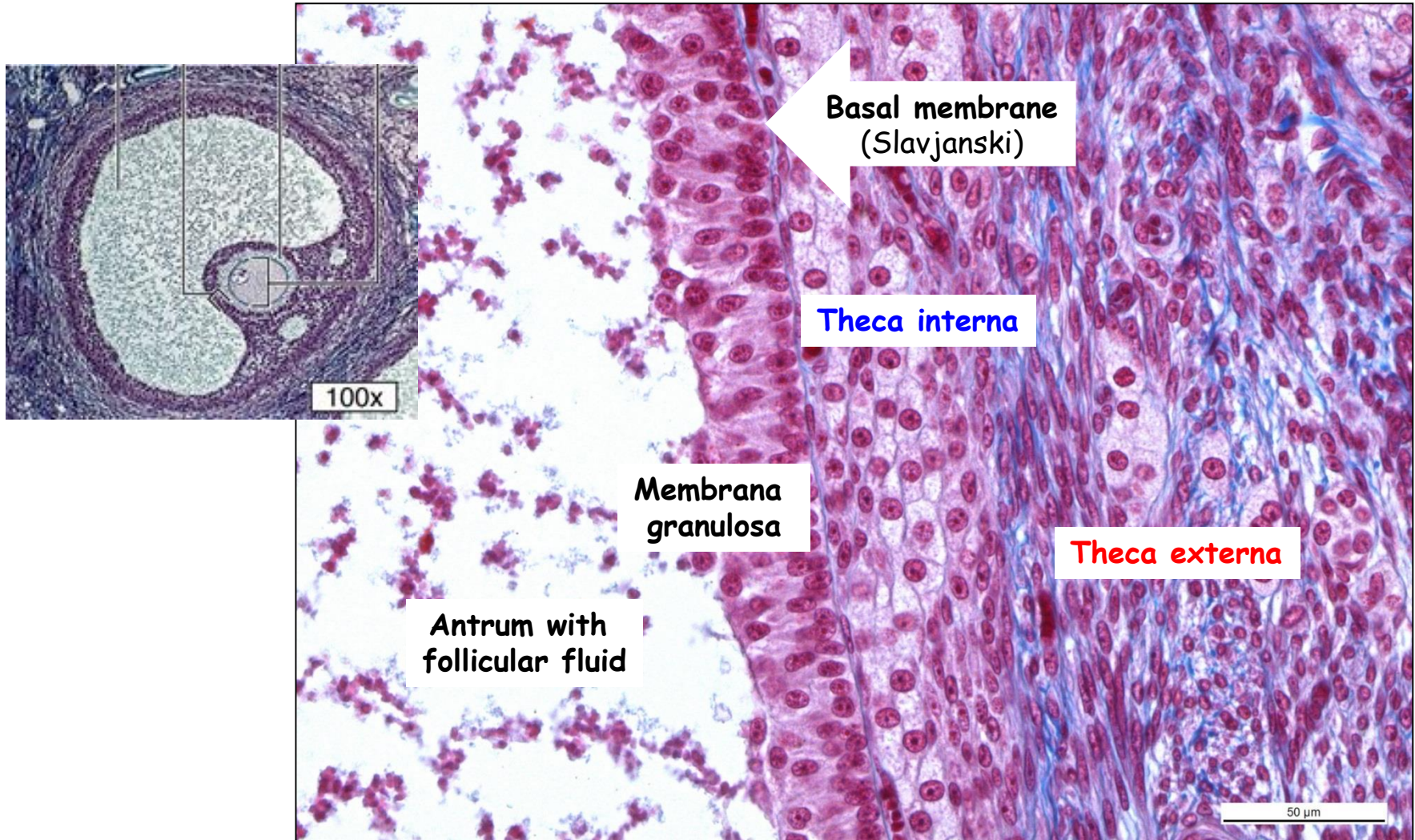


# Oogenesis - Tertiary (Graafian, preovulatory) follicle





# Oogenesis - Wall of tertiary follicle



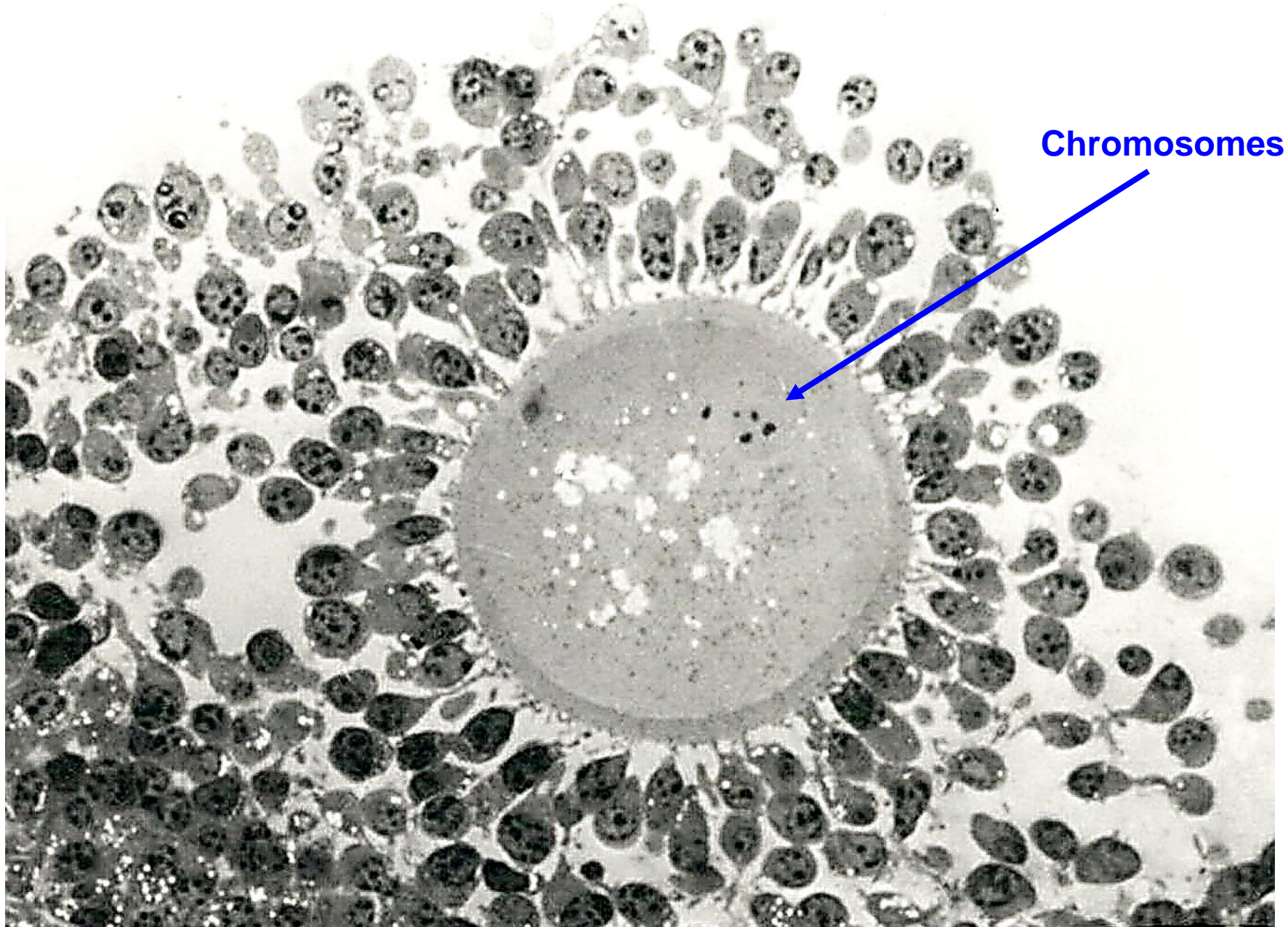
## Theca interna

- Vascularized
- Androstendione to granulosa cells - estradiol

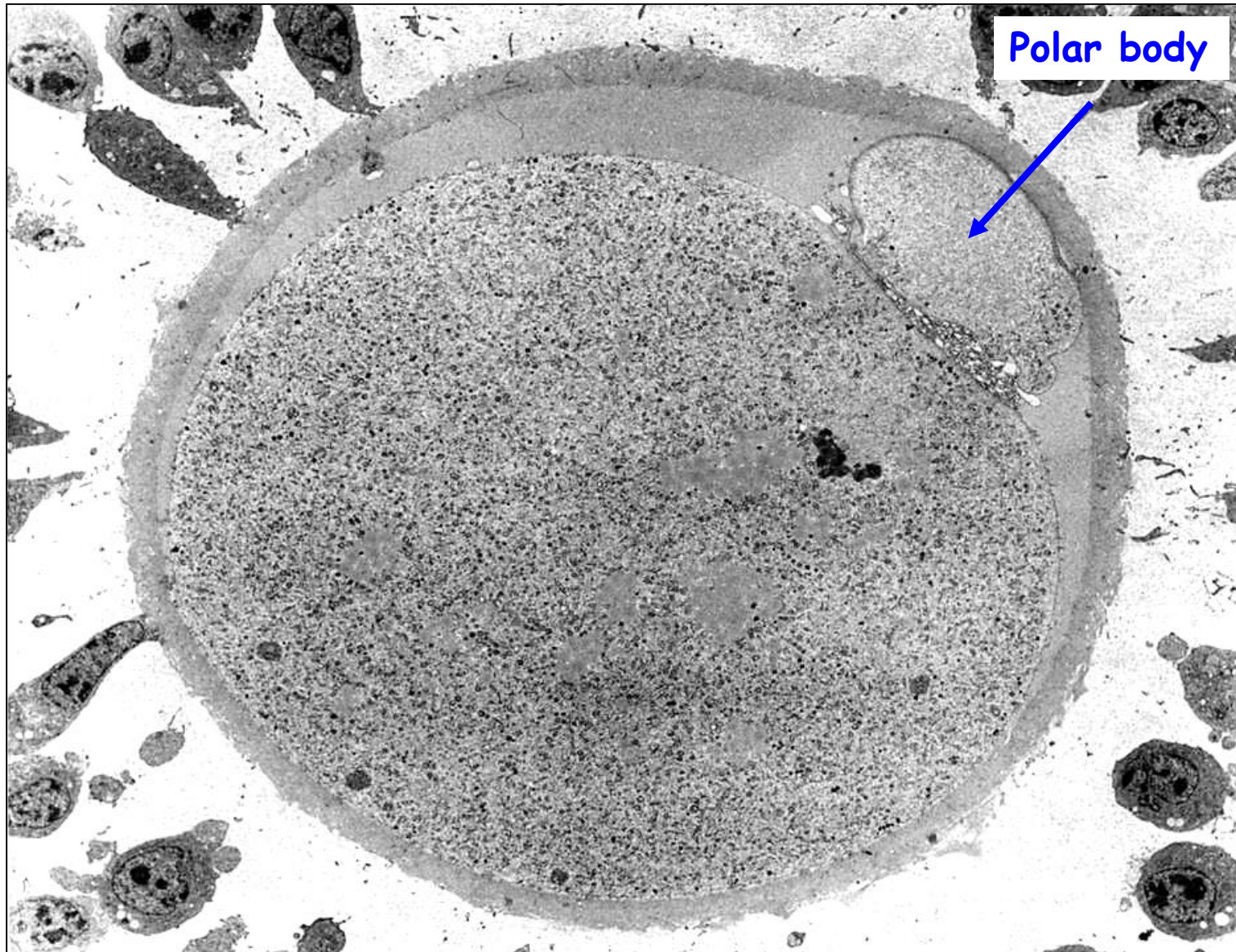
## Theca externa

- Fibrous with smooth m. cells

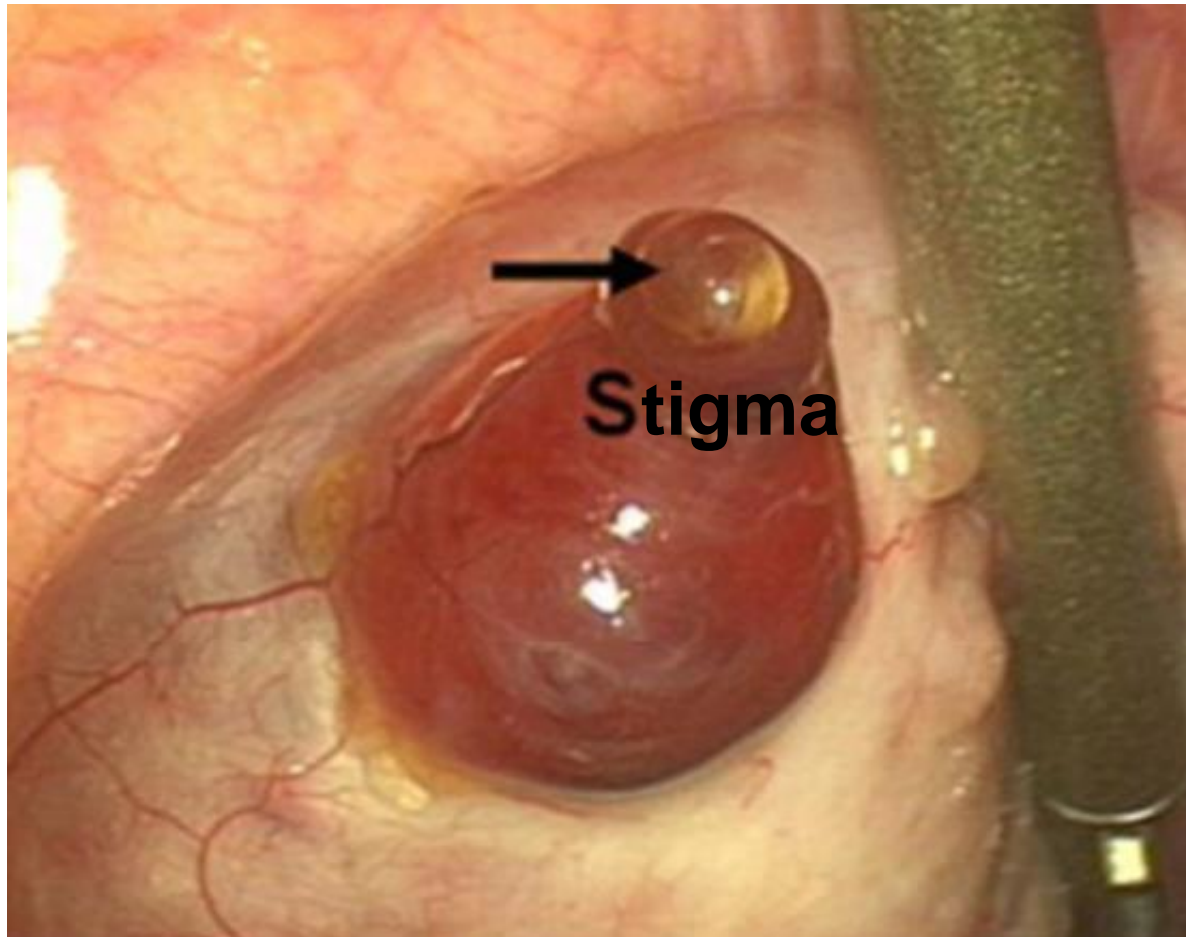
# Oogenesis - MI phase oocyte surrounded by corona radiata



# Oogenesis - MII phase oocyte

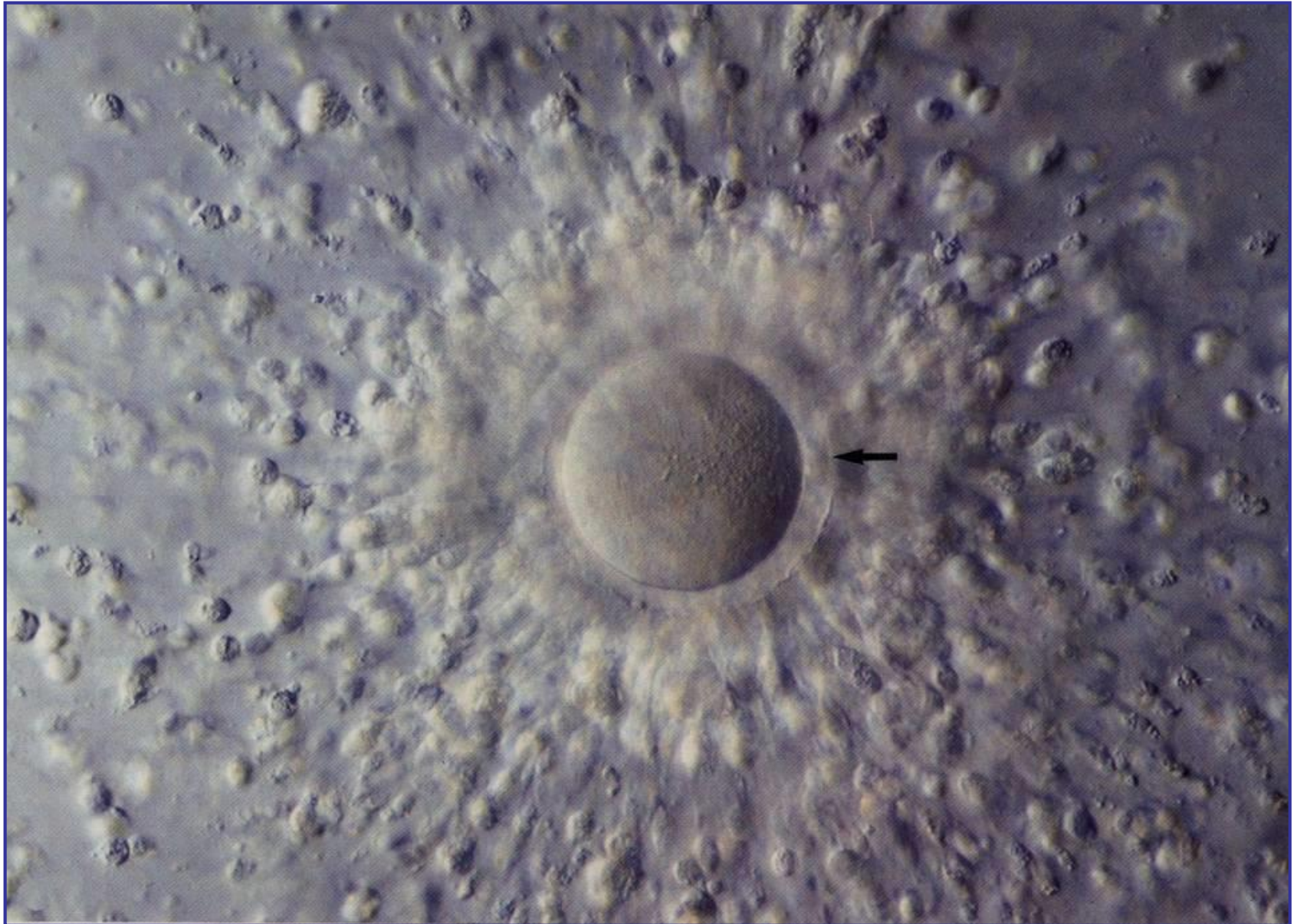


## Oogenesis - Ovulation

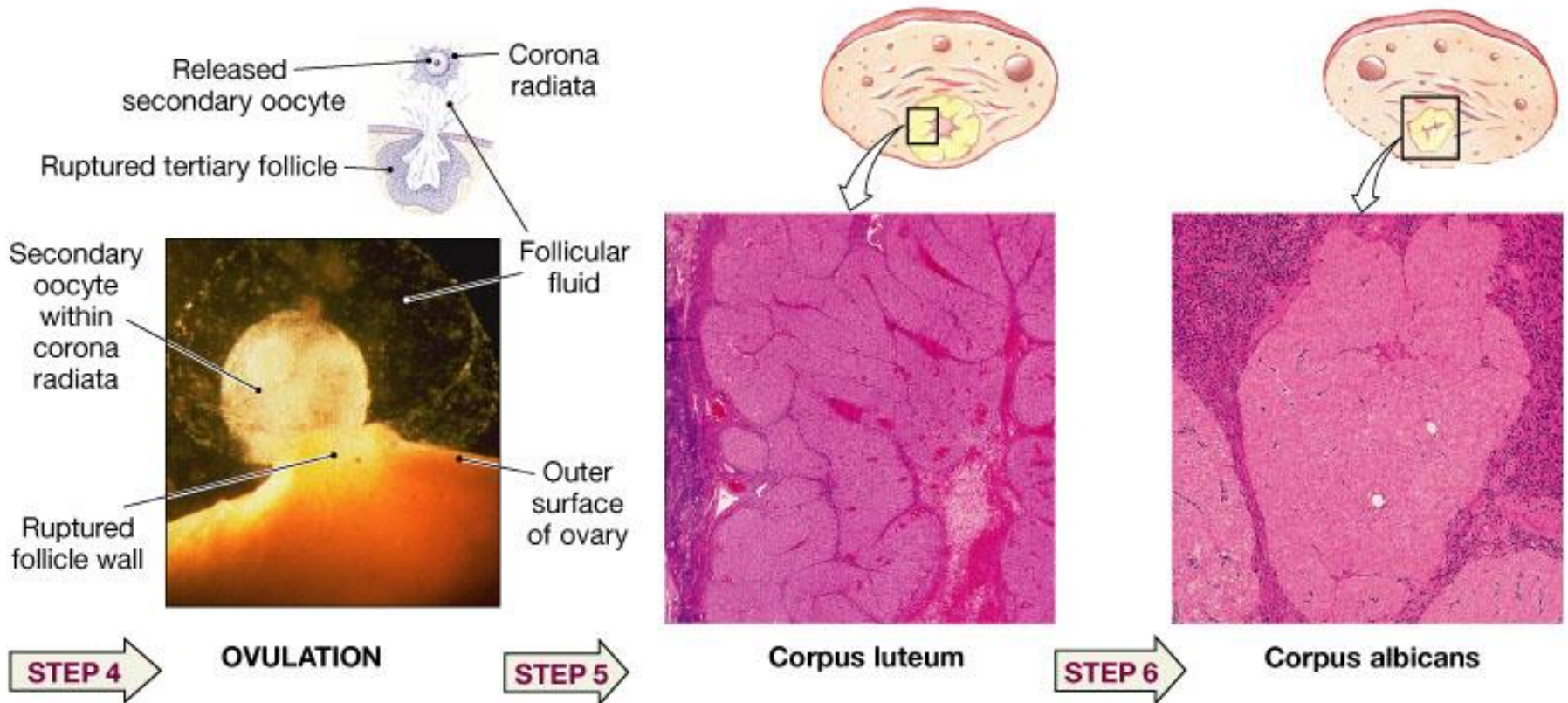


- initiated by LH surge
- no blood flow at stigma - ischemia
- smooth muscle contractions - theca f. externa

# Oogenesis - Ovulated oocyte



# Corpus luteum 1



Copyright © 2004 Pearson Education, Inc., publishing as Benjamin Cummings.

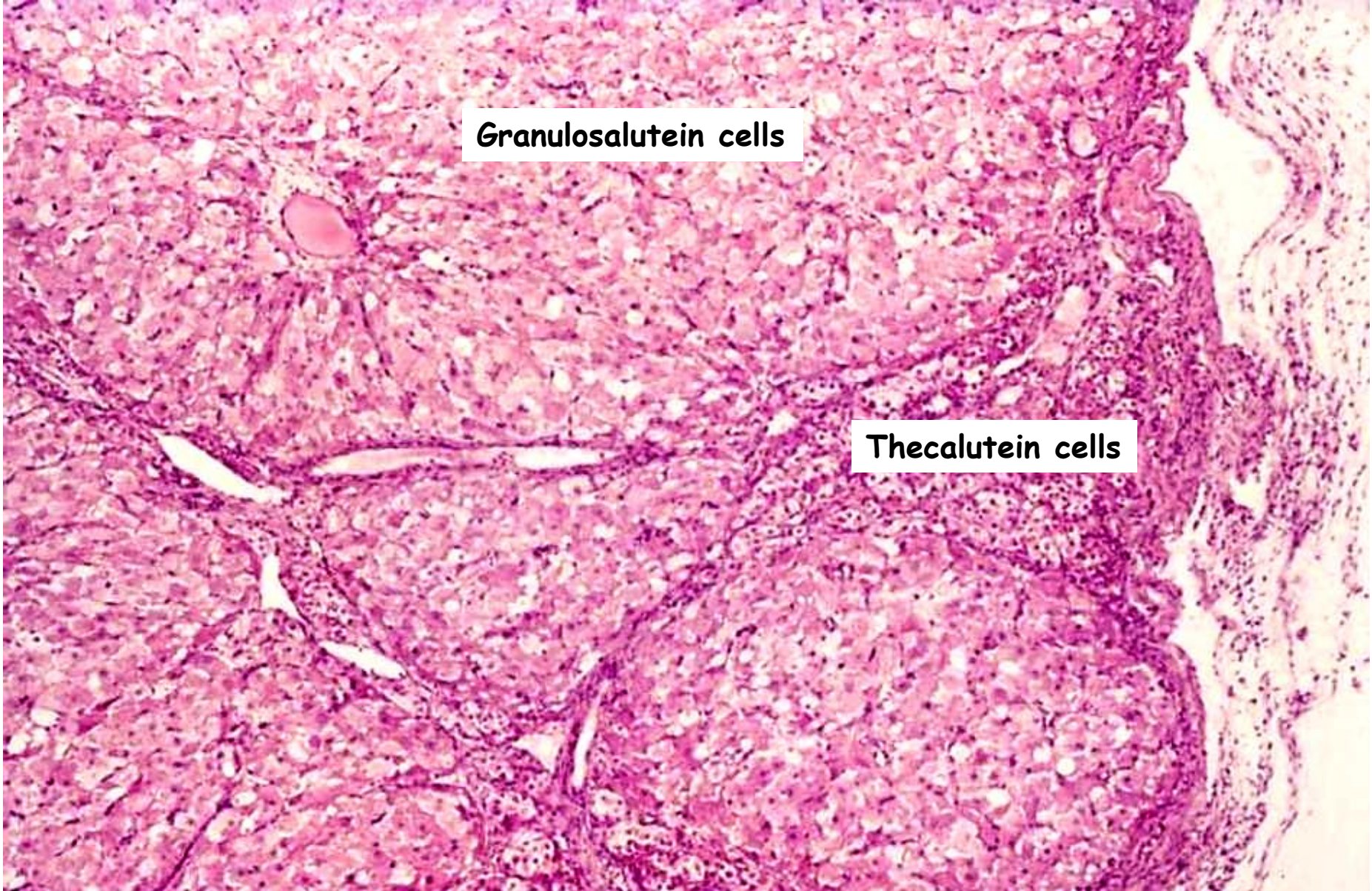
## Granulosa cells - Granulosa lutein cells

- large (20-30  $\mu\text{m}$ )
- 80 % of CL
- convert androstendione to progesterone and estradiol

## Theca interna cells - Theca lutein cells

- smaller (10-15  $\mu\text{m}$ )
- production of steroids
- vascularized - fenestrated caps.

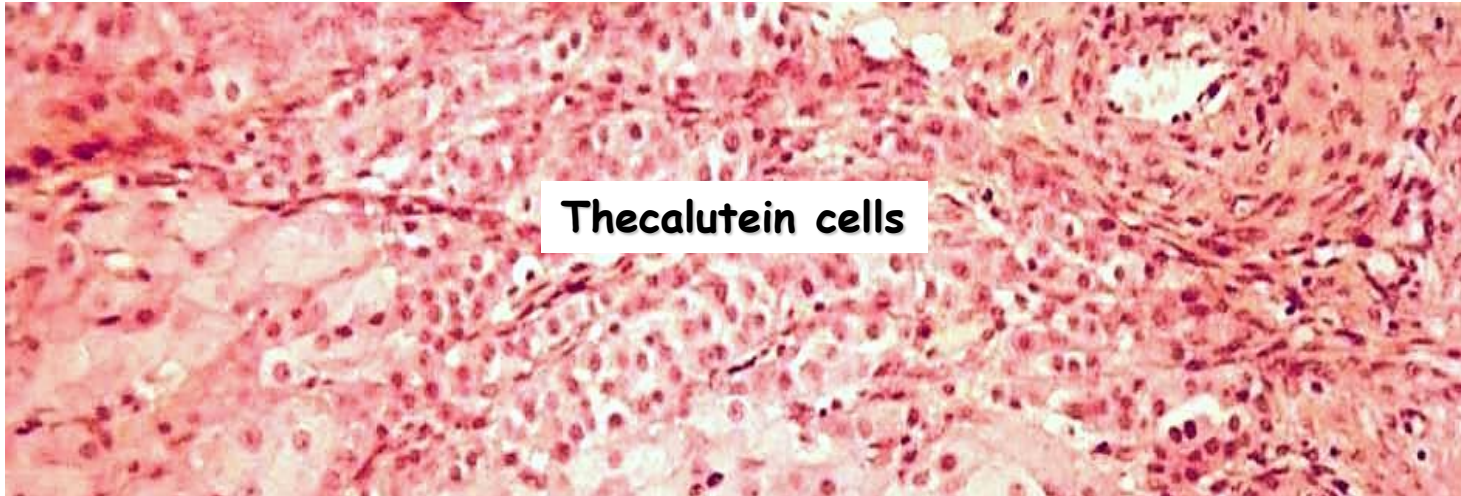# Corpus luteum 2



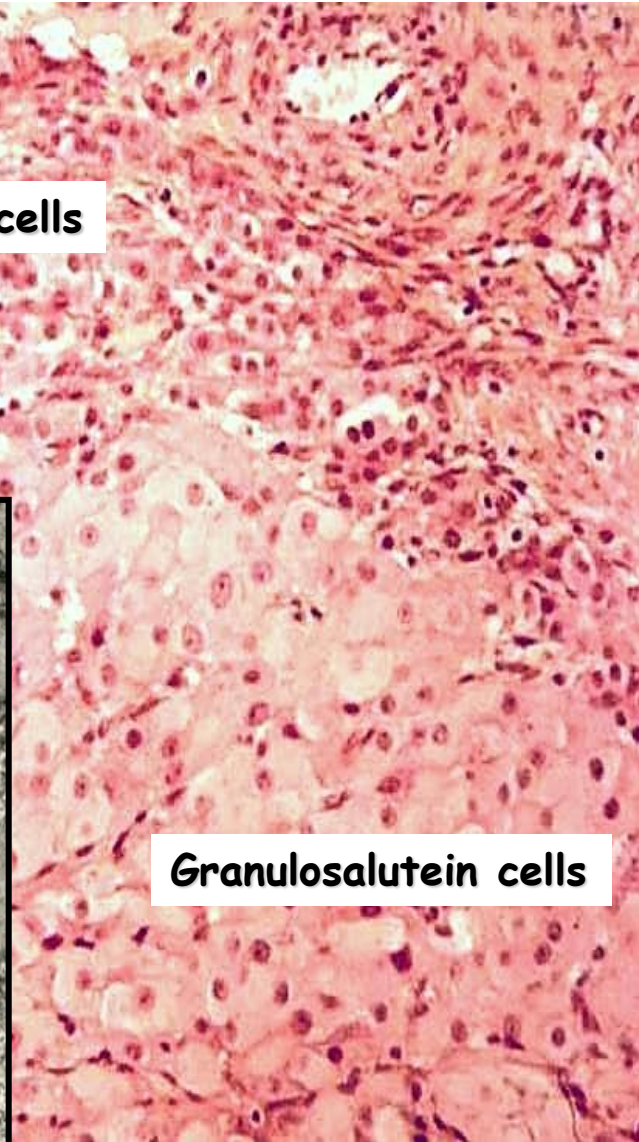
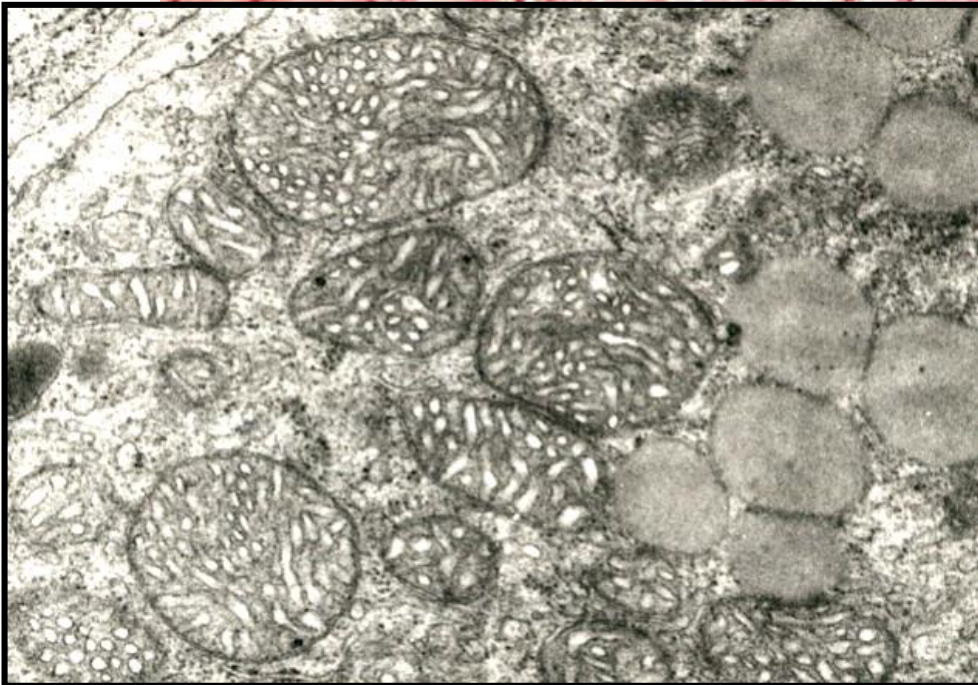Granulosalutein cells

Thecalutein cells

# Corpus luteum 3



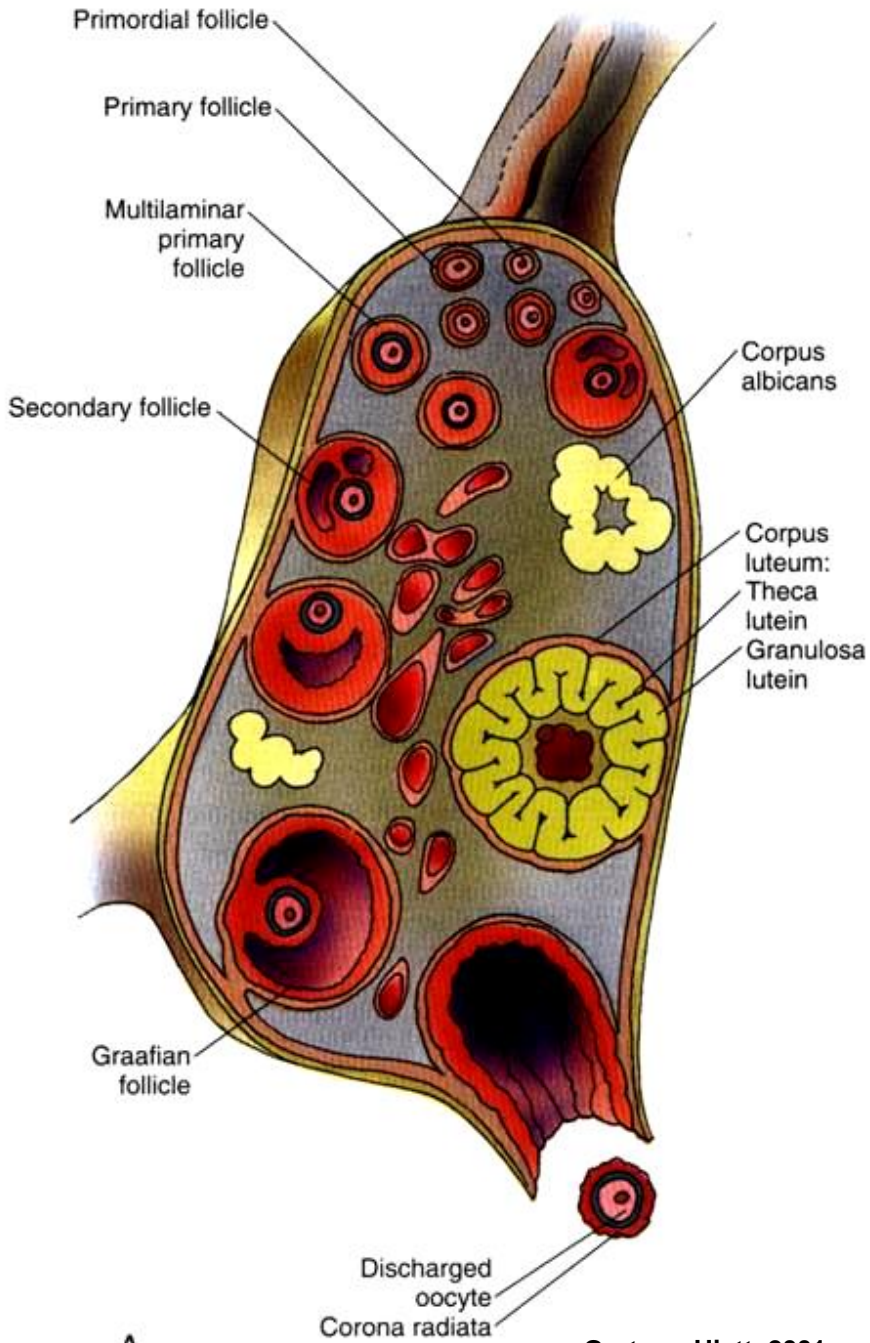
Thecalutein cells



Granulosalutein cells



# Corpus luteum 4



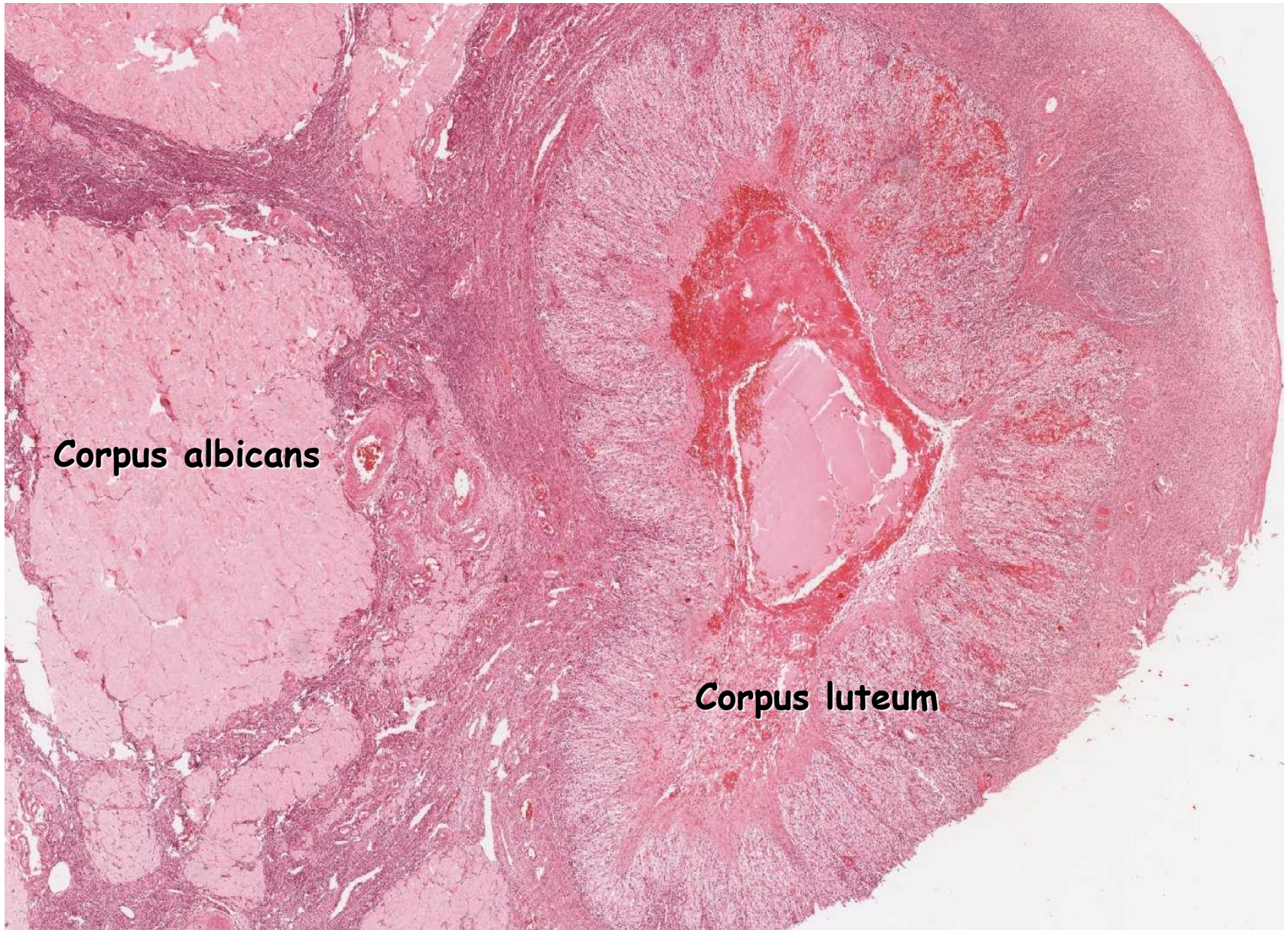
## CL graviditatis

- diameter 2 - 3 cm
- maintains pregnancy
- maintained by chorionic gonadotropin (HCG)
- maximal at 2 months
- changes to c. albicans at month 4-5

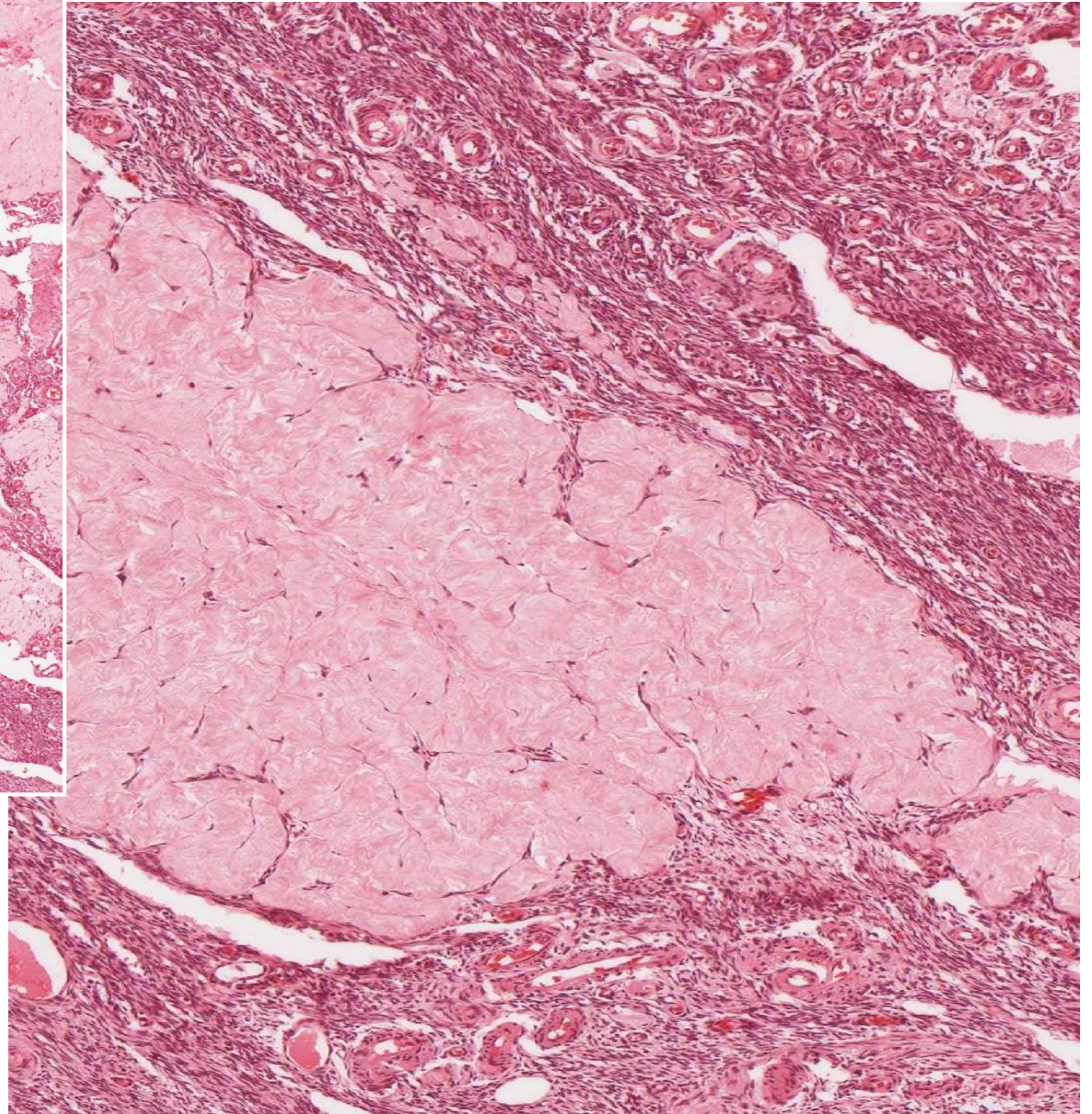
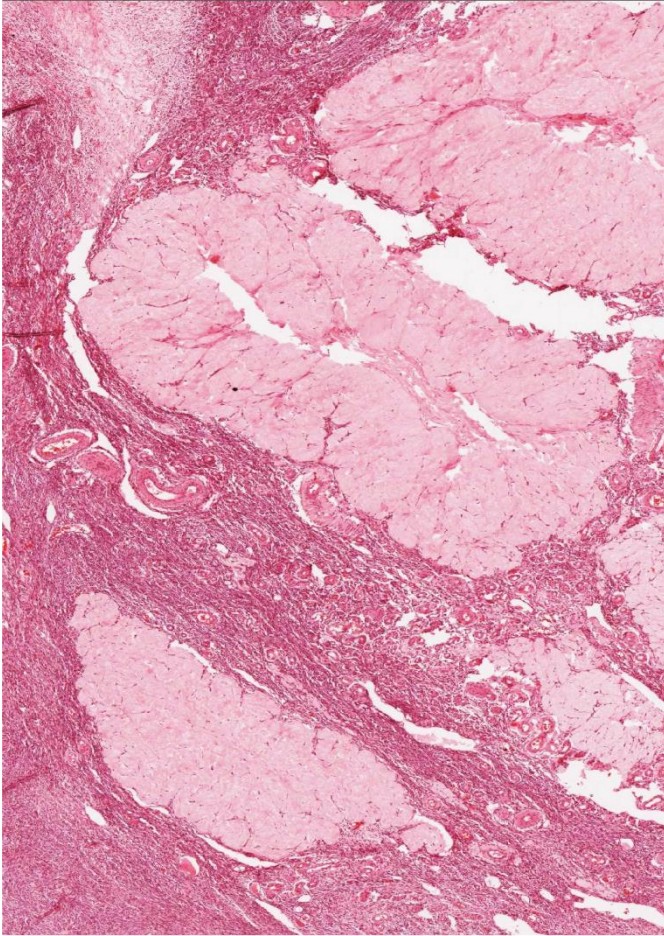
## CL menstruationis

- 10 - 12 days
- changes to c. albicans  
(dense connective tissue - collagen + fibroblasts)

# Corpus luteum & albicans

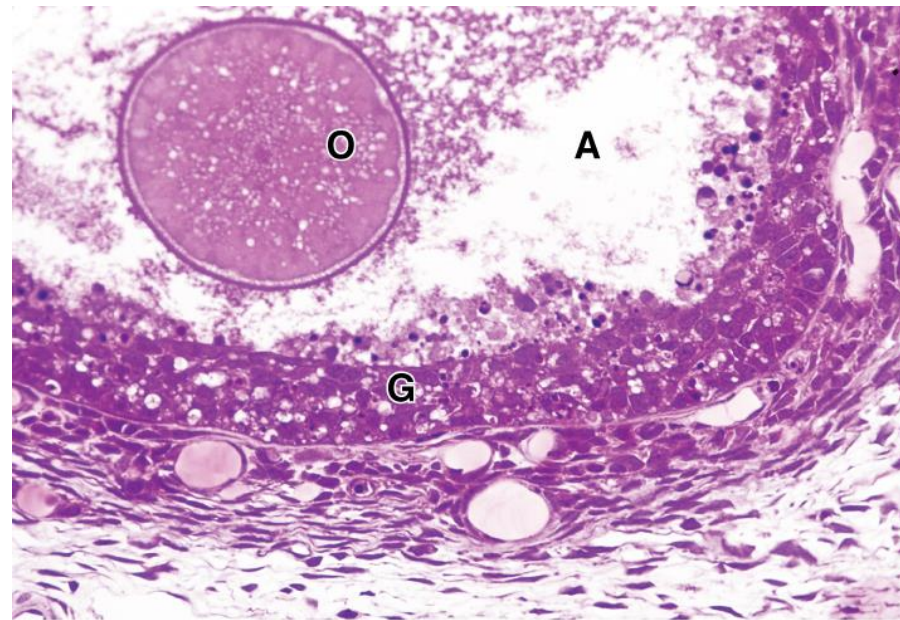
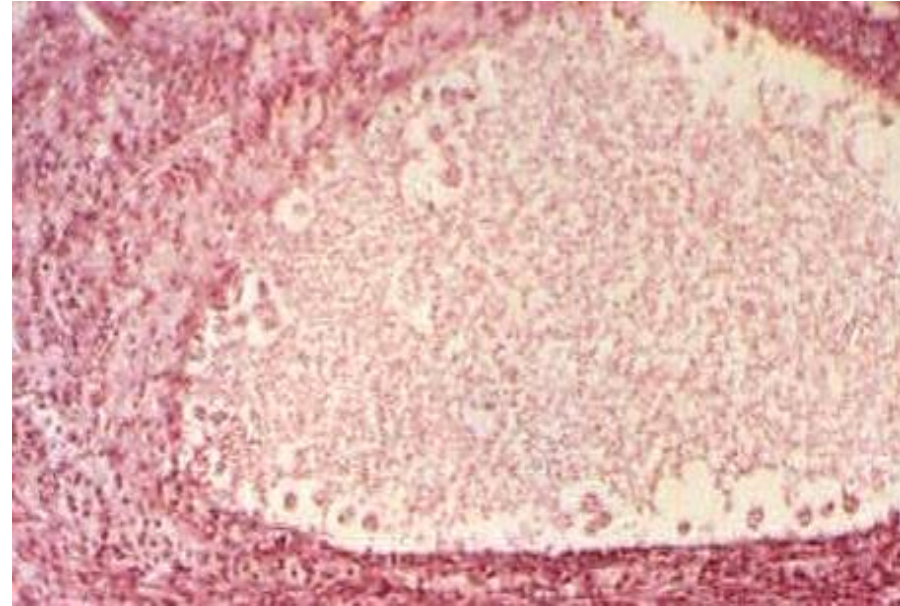


# Corpus albicans



# Follicular atresia

- all types of follicles
- apoptosis of follicular cells
- autolysis (autophagy) oocytes
- phagocytosis by macrophages
- zona pellucida and basal lamina persist the longest time



# Ovarian cycle - 28 days

## Preovulatory phase

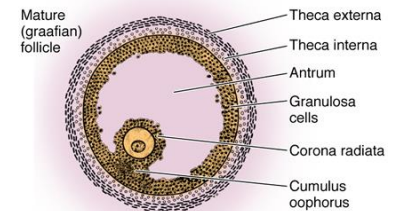
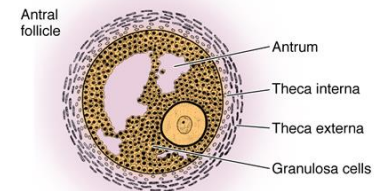
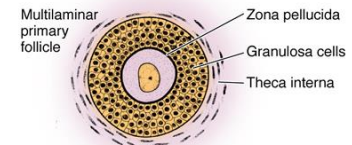
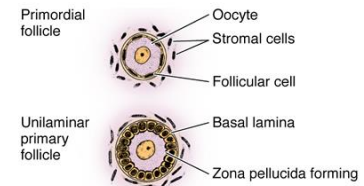
- days 1 to 14
- growth and maturation of follicles
- production of steroid hormones

## Ovulation

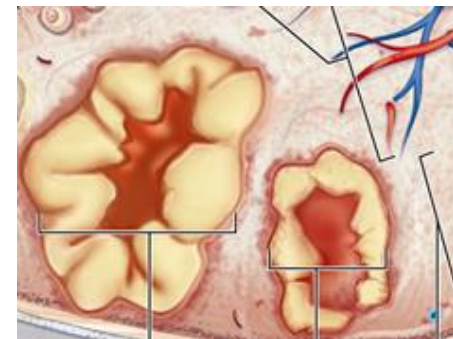
- at day 15

## Postovulatory phase

- days 16 to 28
- corpus luteum
- production of progesterone

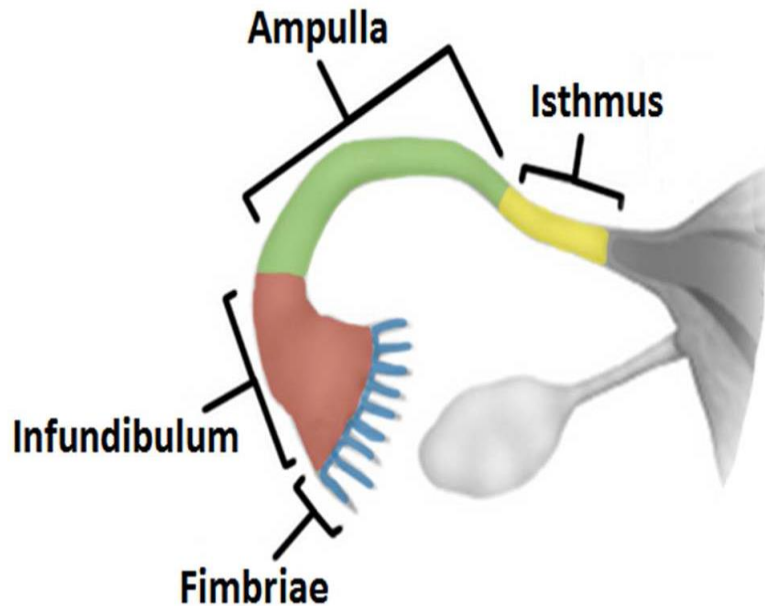


Mescher, 2010

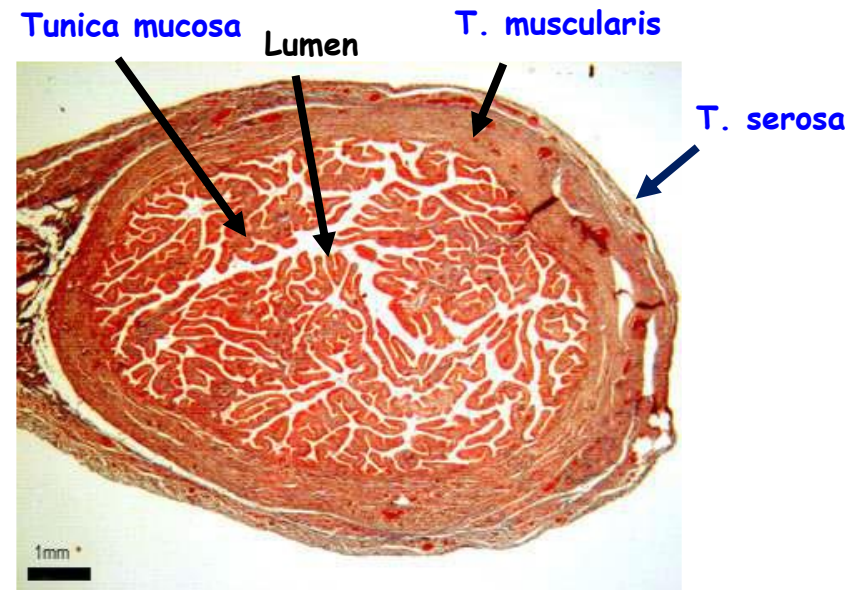


# Uterine tubes = Fallopian tubes = Oviducts

- connect the ovaries to the uterus
- 12 to 15 cm long x 0.7 to 5 cm in diameter
- location of fertilization and early embryonic development

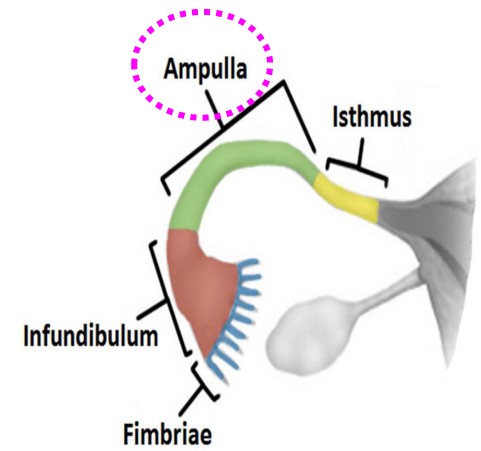
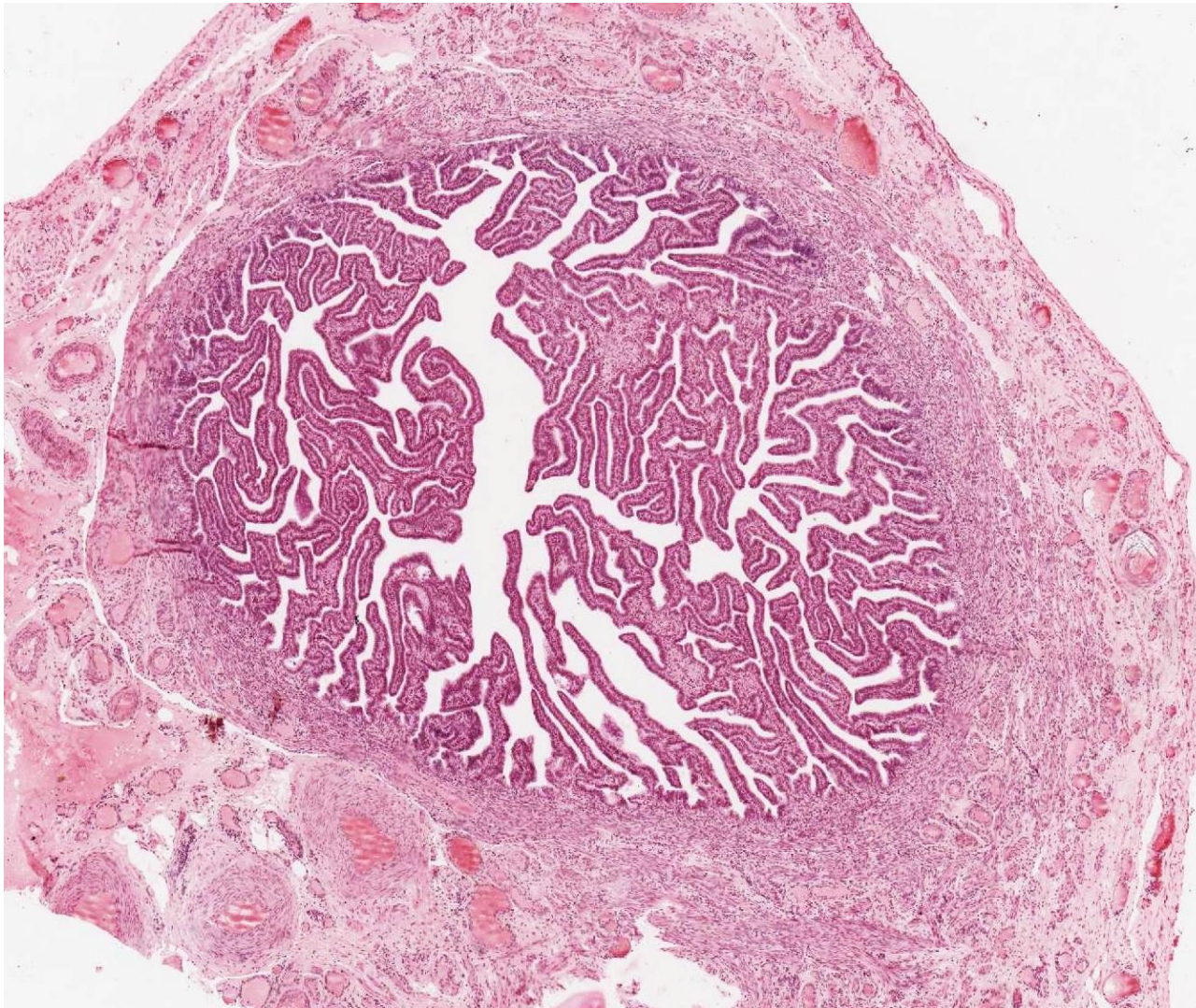


Teachmeanatomy.info



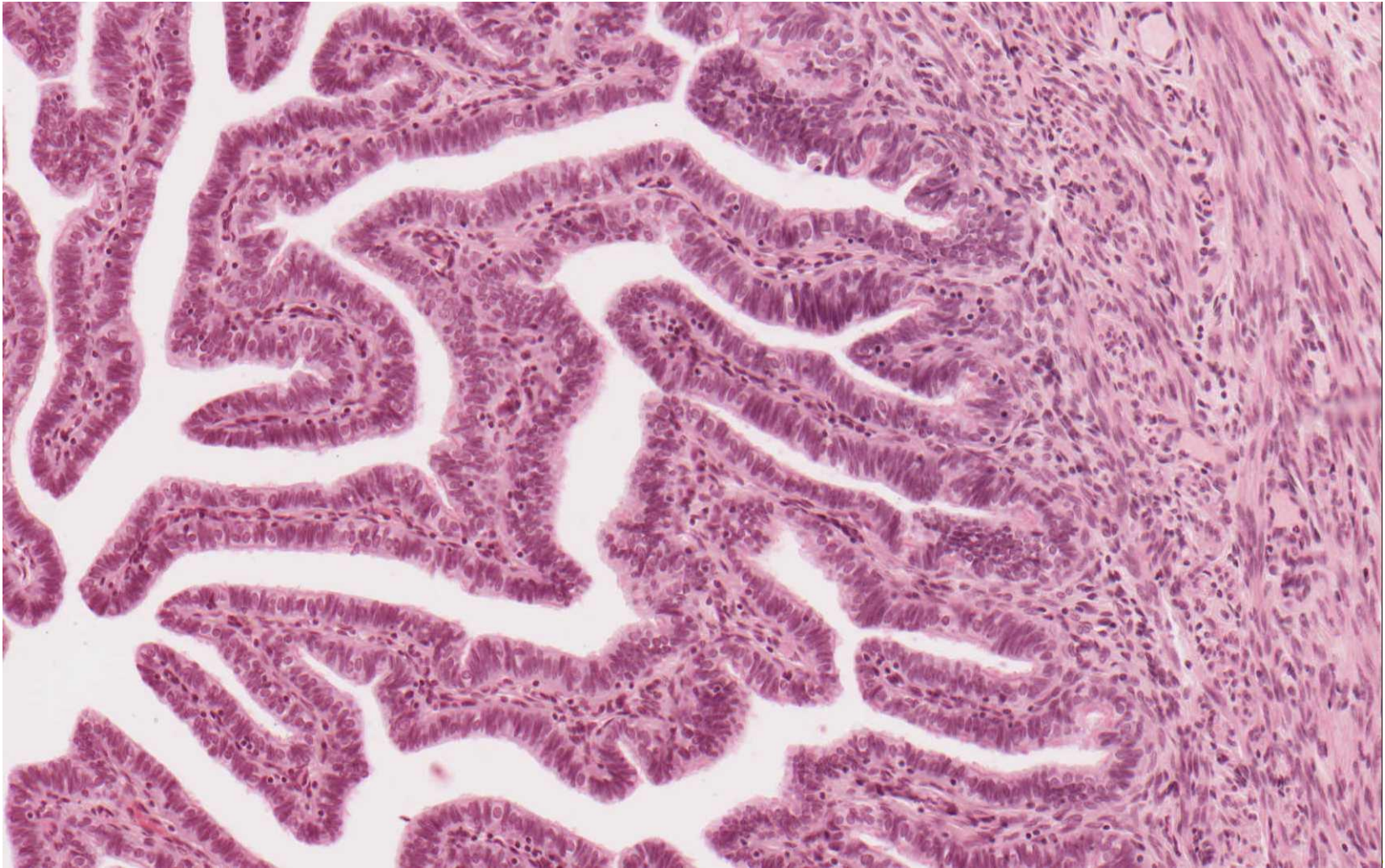
University of Leeds Histology, histology.leeds.ac.uk

# Oviduct - Ampulla



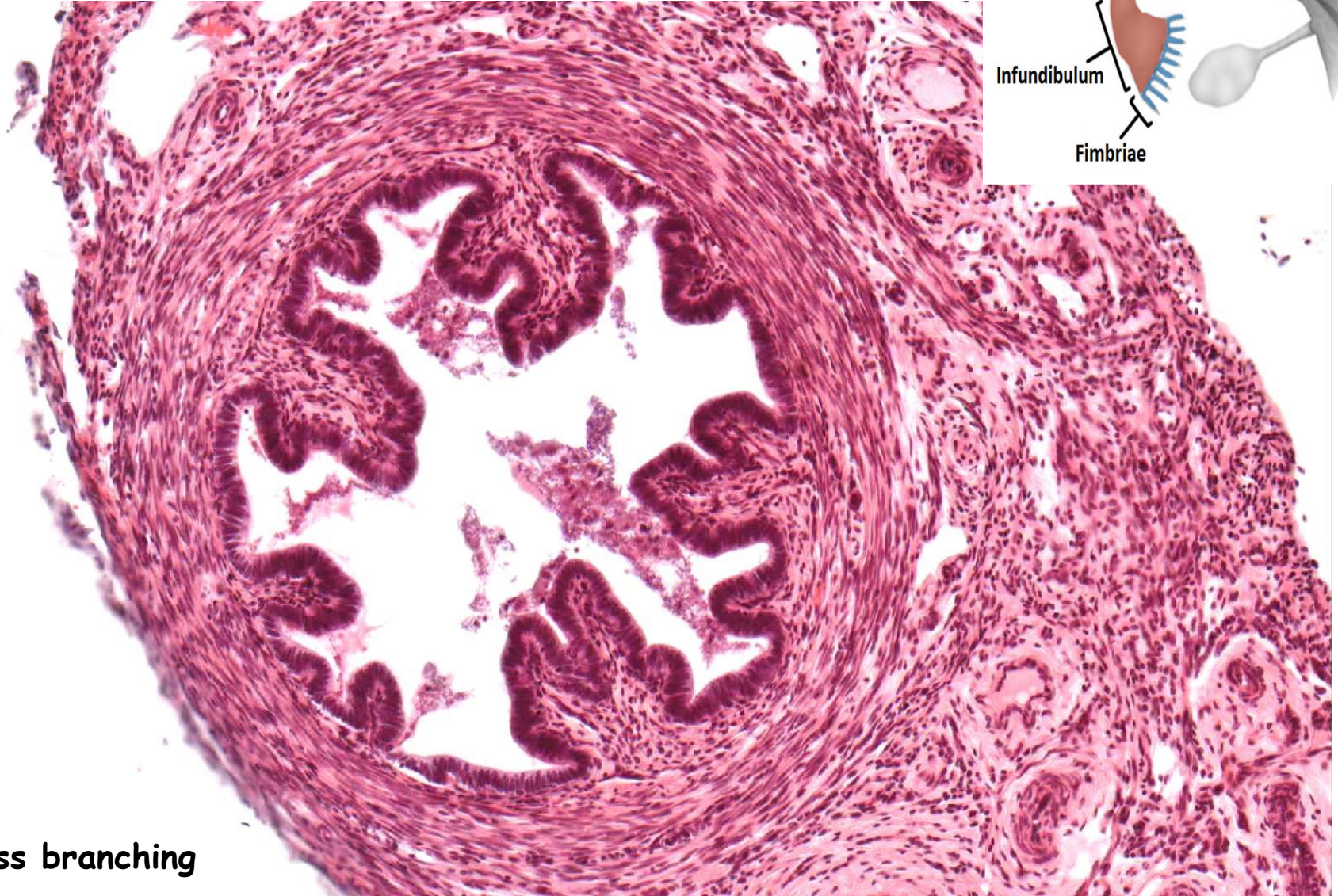
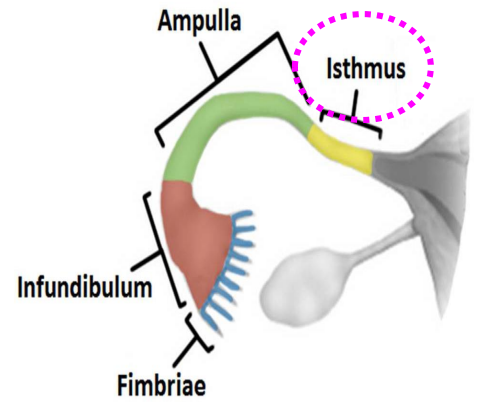
- highly branched mucosa
- longitudinal folds
- labyrinth

## Oviduct - Ampulla



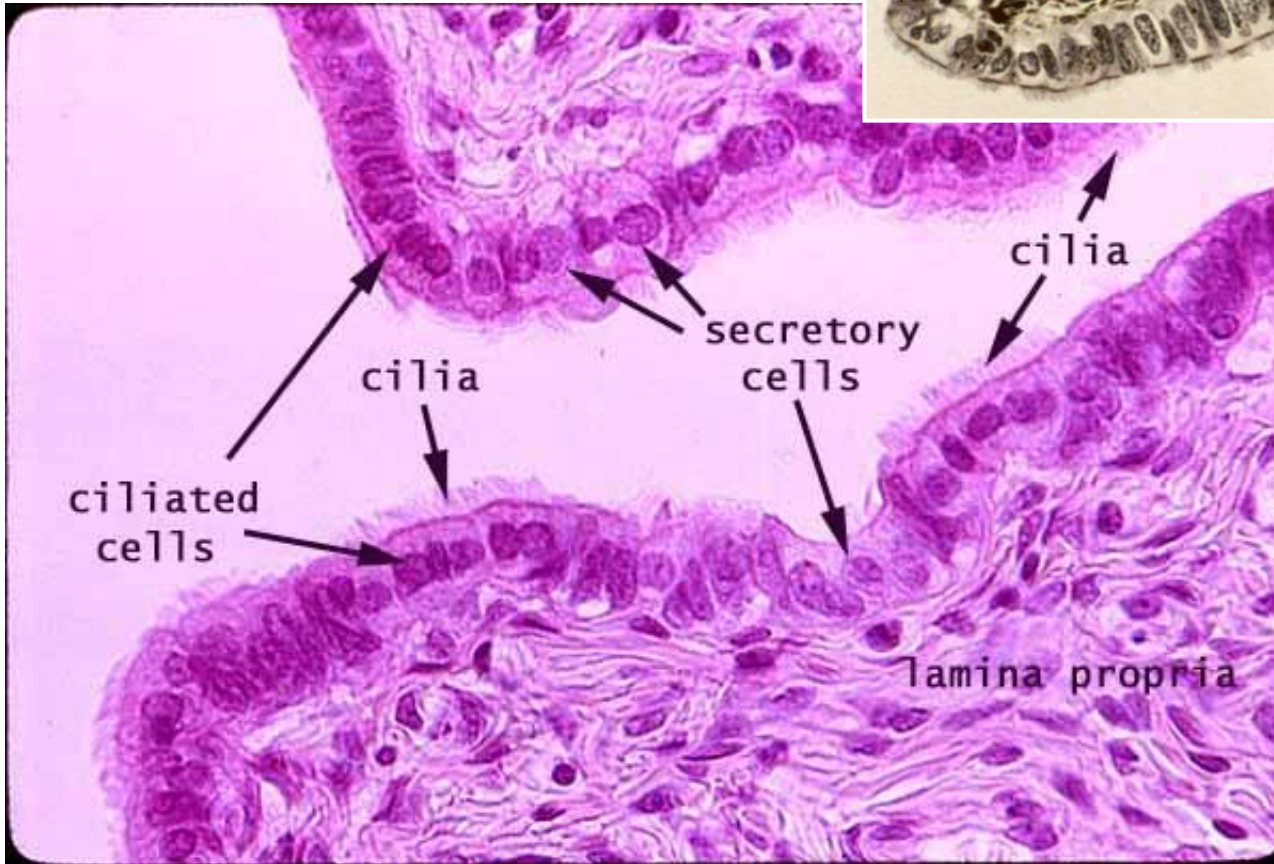


# Oviduct - Isthmus



- less branching

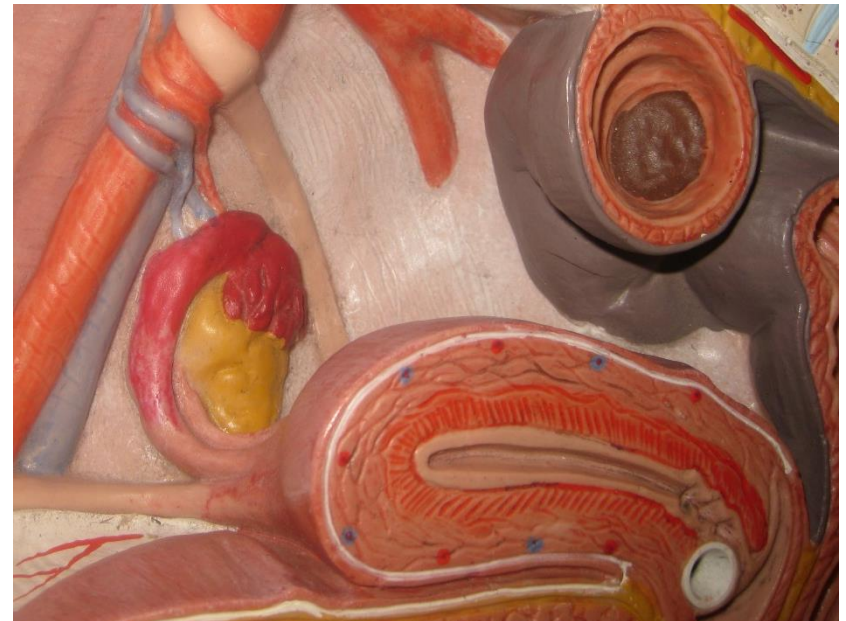
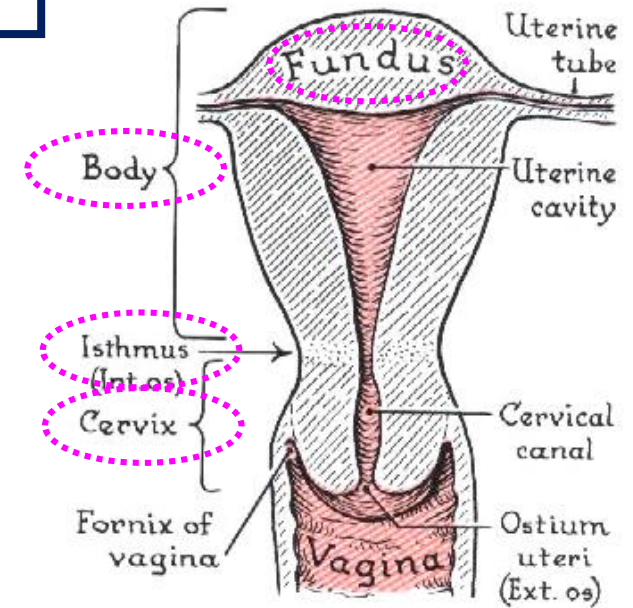
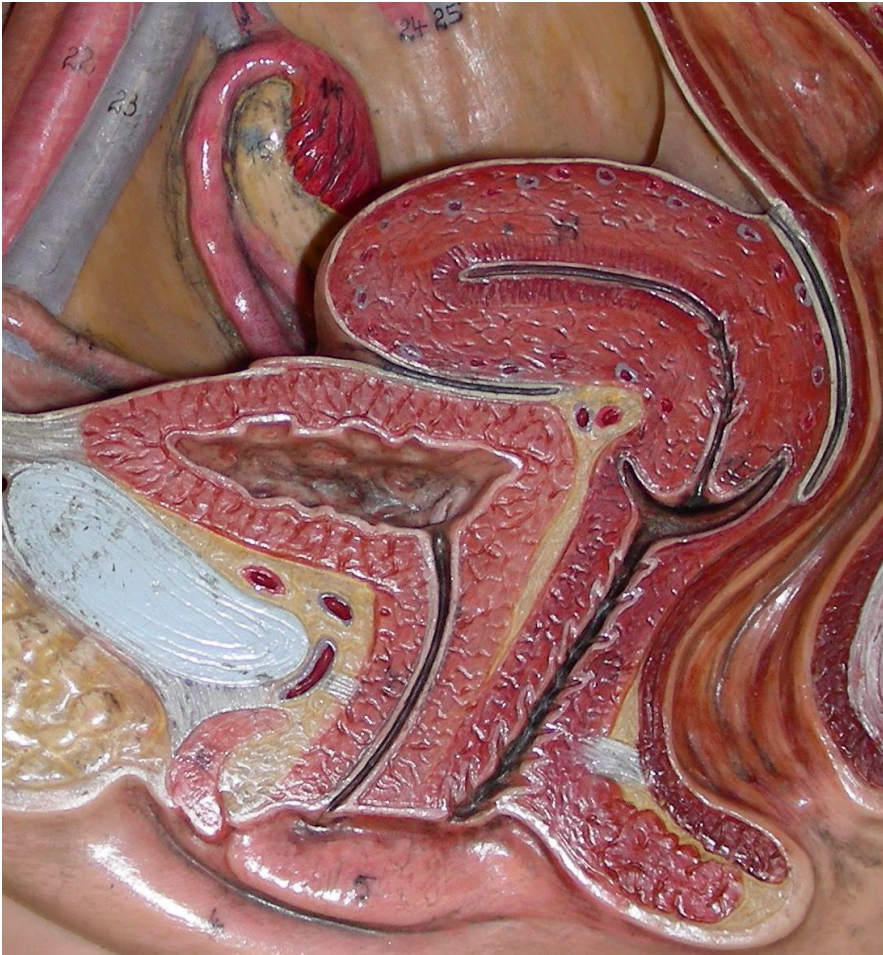# Oviduct



## Tunica mucosa

- *lamina epithelialis* - simple columnar epithelium
  - 1.) **CILIATED CELLS** - possess many cilia- transport of the ovum and embryo
  - 2.) **SECRETORY CELLS (PEG)** - secrete a nutrient rich medium
- *lamina propria* - loose connective tissue (is richly vascularized!)

# Uterus 1

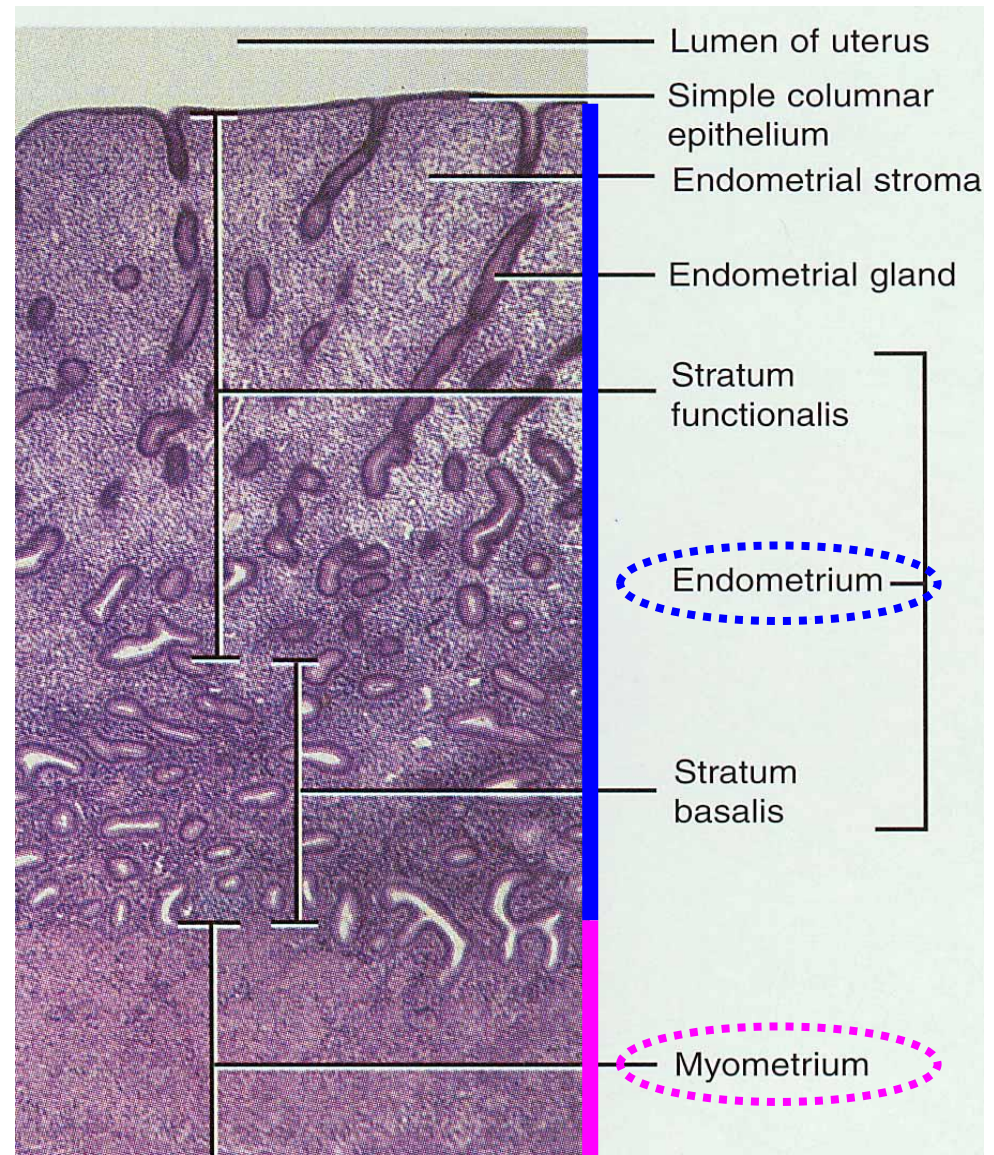


- **Mechanical protection and nutritional support to developing embryo**
- **Bends anteriorly (anteflexion)**
- **Stabilized by broad, uterosacral, round, and lateral ligaments**

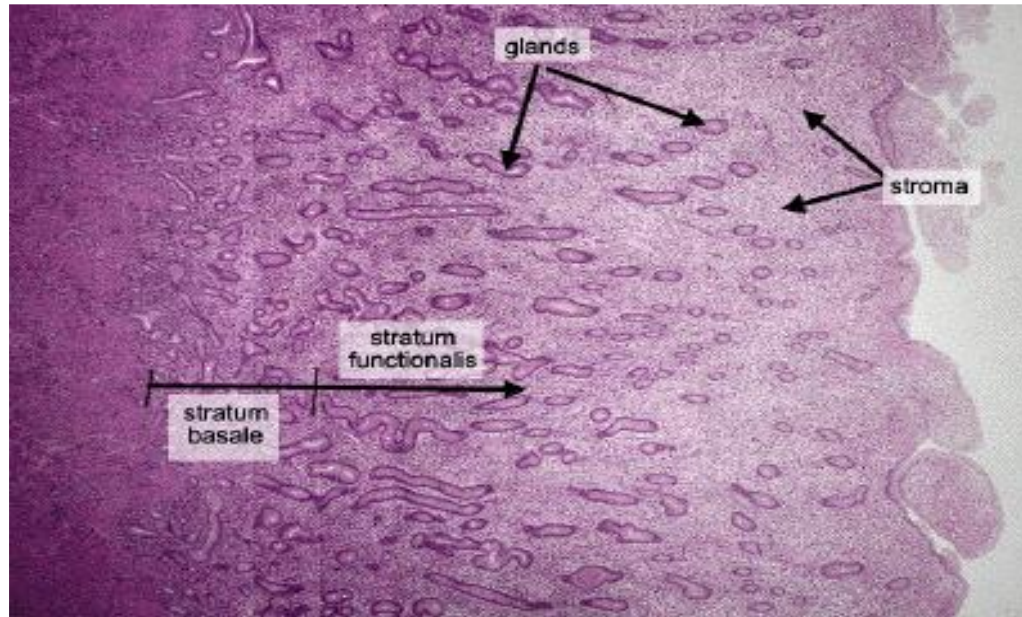
# Uterus 2

Uterine wall ~ 1.5 - 2 cm

1. Endometrium - *T. Mucosa*
2. Myometrium - *T. muscularis*
3. Perimetrium - *T. Serosa*



# Uterus - Endometrium 1



Dartmouth Medical School, Virtual Histology  
<http://www.dartmouth.edu/~anatomy/Histo>

- consists of *lamina epithelialis* and *lamina propria*
- epithelial lining - simple columnar epithelium containing secretory and ciliated cells
- lamina propria - loose connective tissue with many stellate fibroblasts, contains abundant amorphous ground substance → uterine glands - simple tubular glands (covered by simple columnar epithelial cells)

## 1. Stratum functionalis (~ 5 mm)

- exhibit dramatic changes during menstrual cycle every month (hormone-driven)
- shed during menstruation!

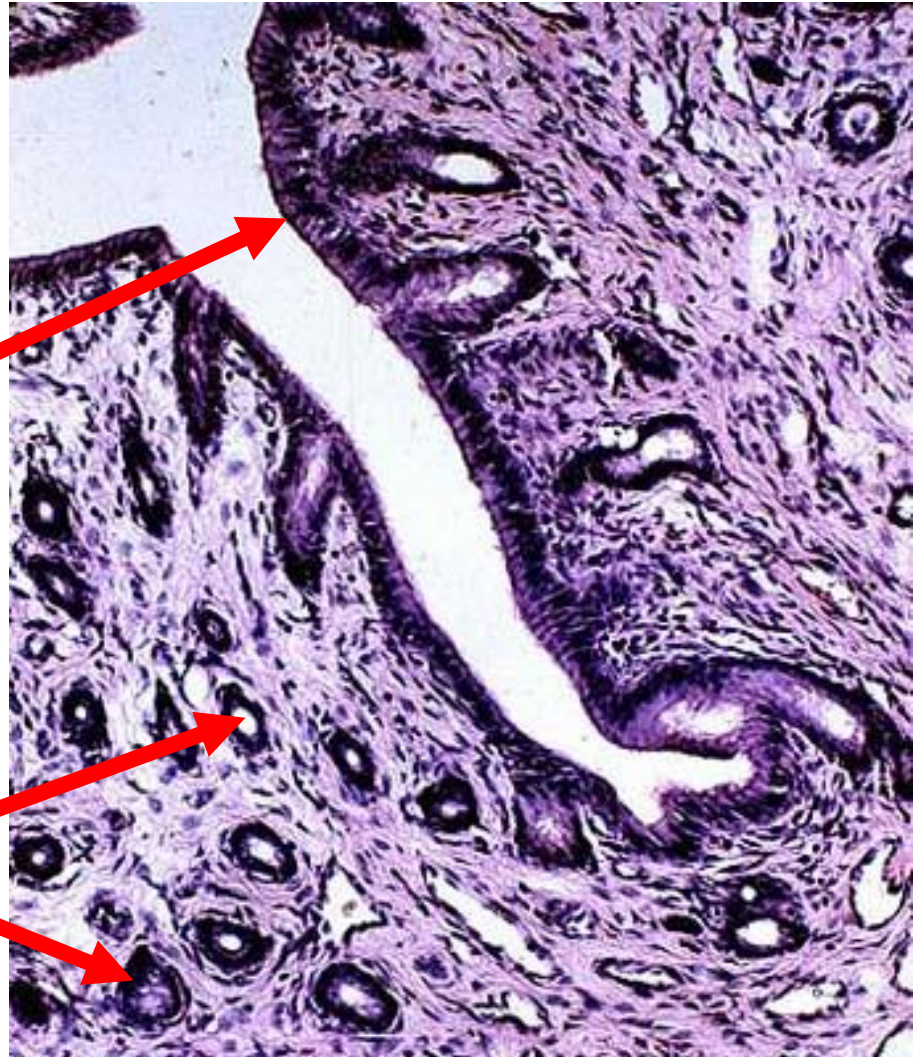## 2. Stratum basale (~ 1 mm)

- undergoes little changes during the menstrual cycle
- not shed during menstruation!
- provides a new epithelium and lamina propria for the renewal of the endometrium!

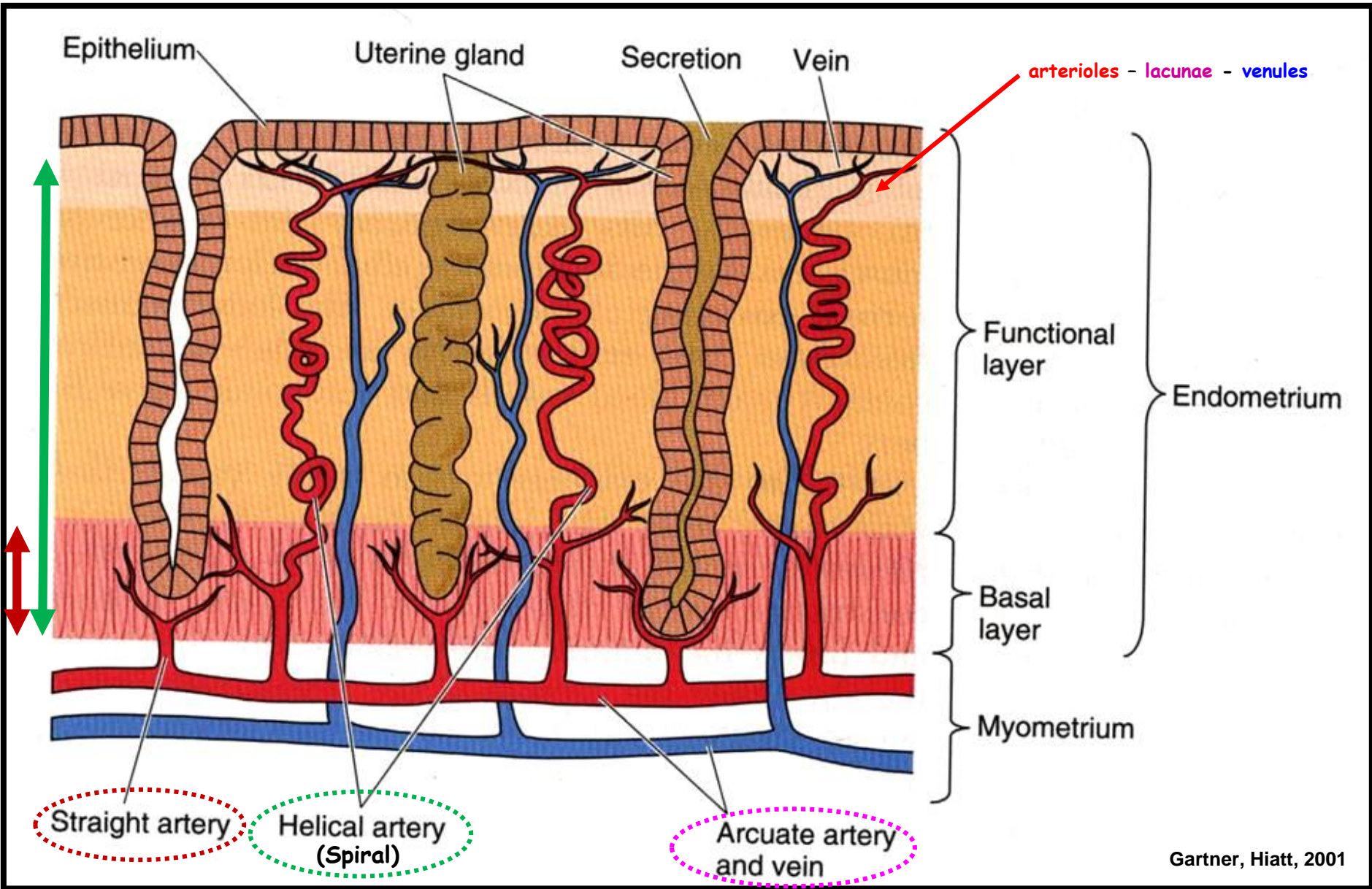
## Uterus - Endometrium 2

Simple  
columnar  
epithelium

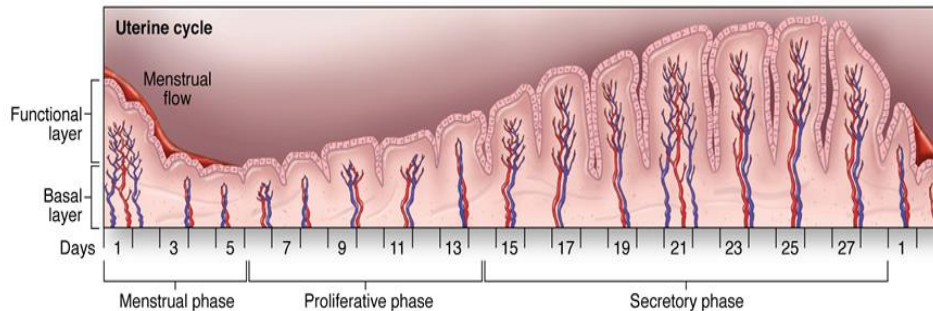
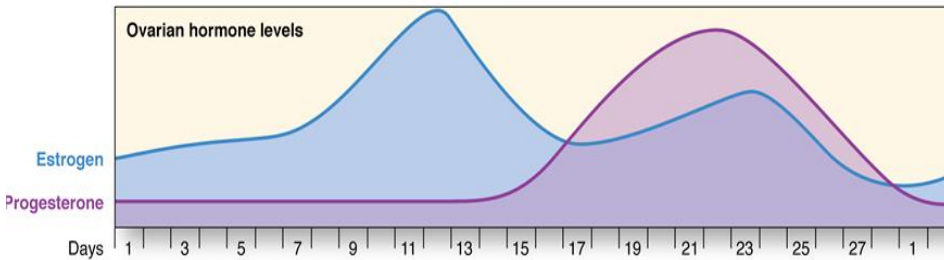
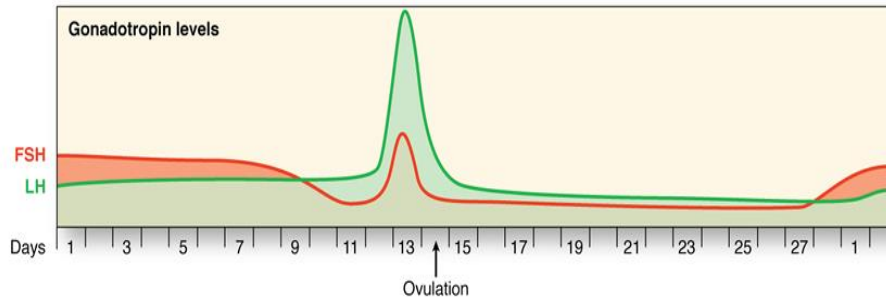
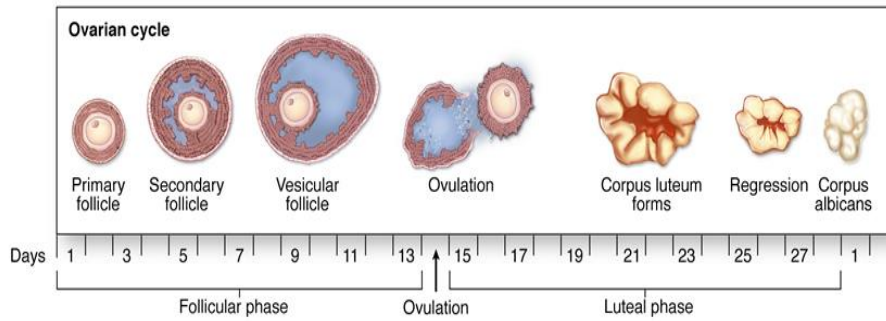
Endometrial  
glands



# Uterus - Endometrium - Blood supply



# Uterus - Menstrual cycle (28 days)



**Menstrual phase (days 1 - 4)**

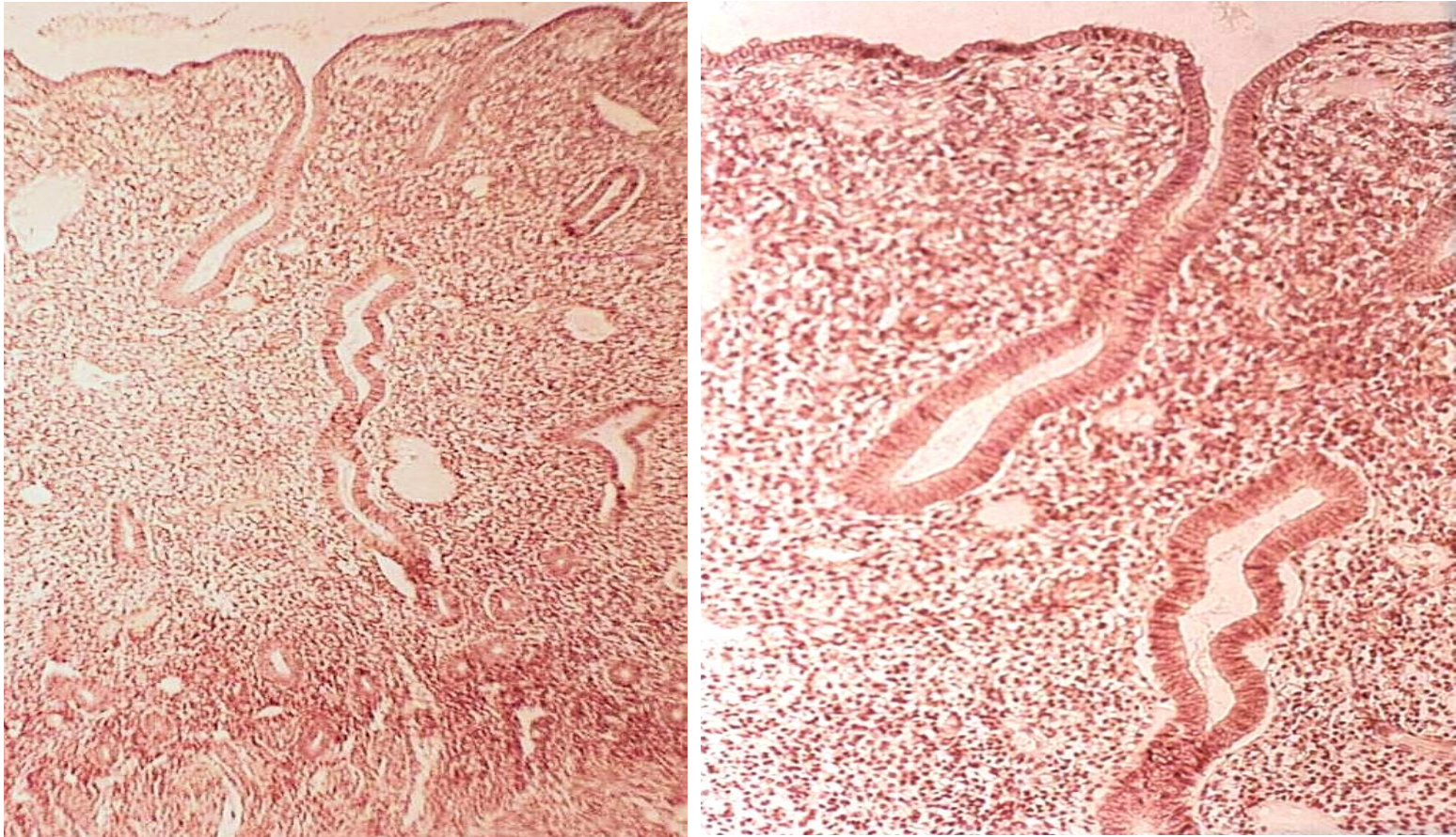
**Proliferative phase (days 5 - 15)**  
(driven by estrogens)

**Secretory phase (days 16 - 27)**  
(driven by progesterone)

**Ischemic phase (day 28)**

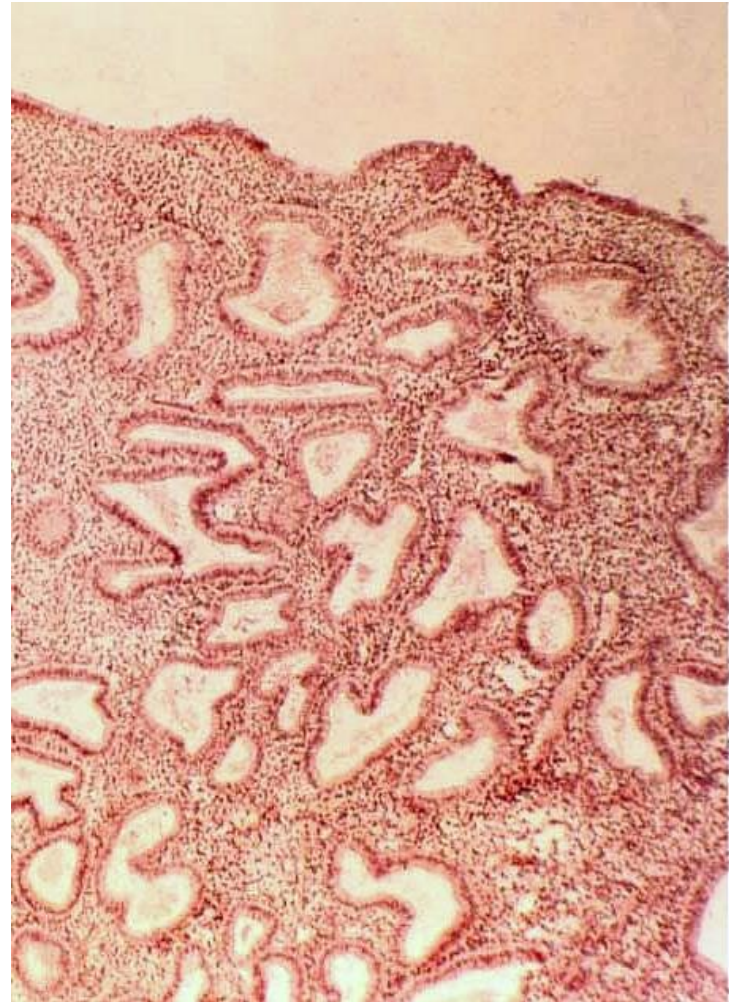
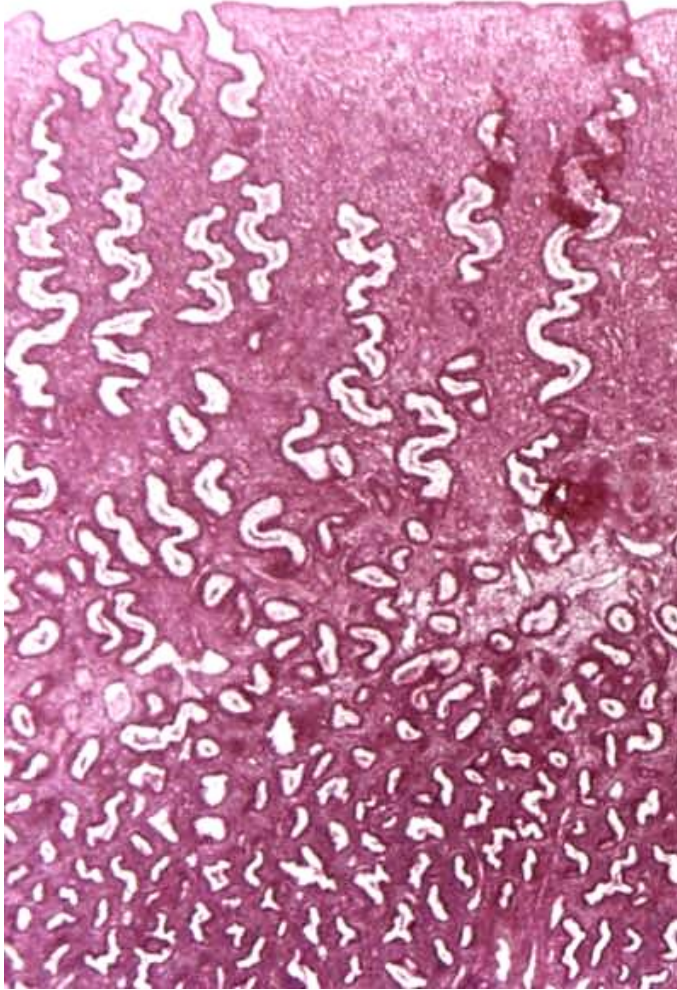


# Endometrium - Proliferative phase



- rising estrogen from the developing follicles
- the stratum basalis is regrowing the stratum functionalis - new glands form
- long and straight uterine glands which are not yet functional

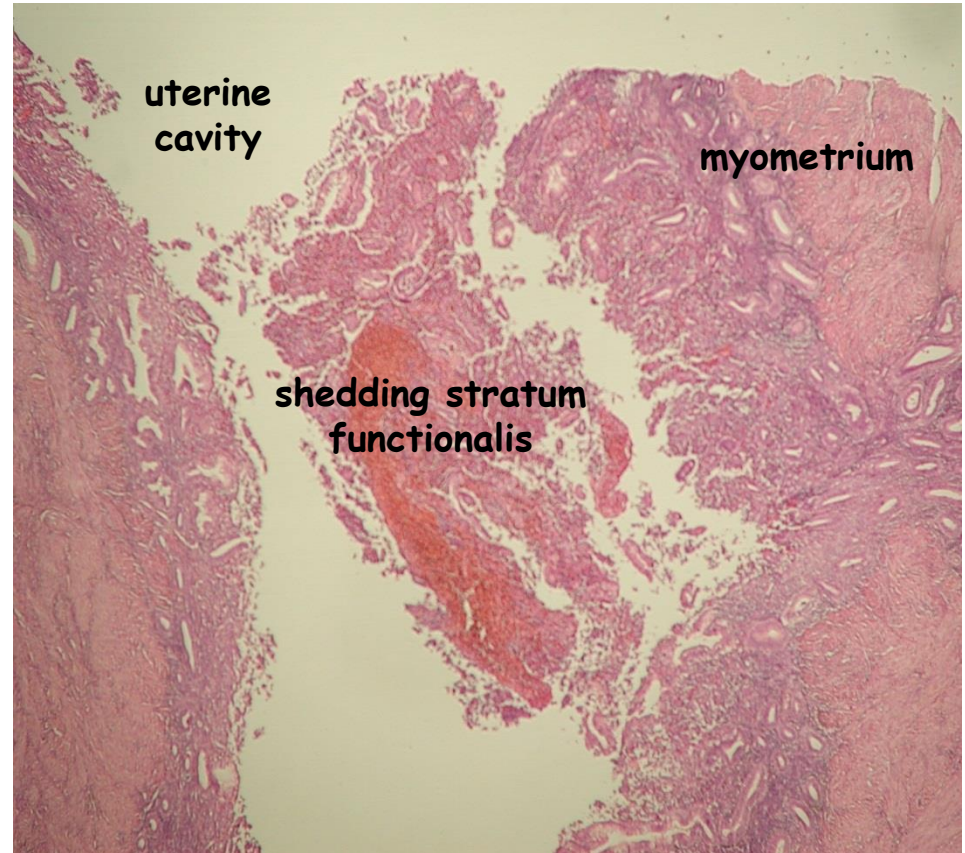
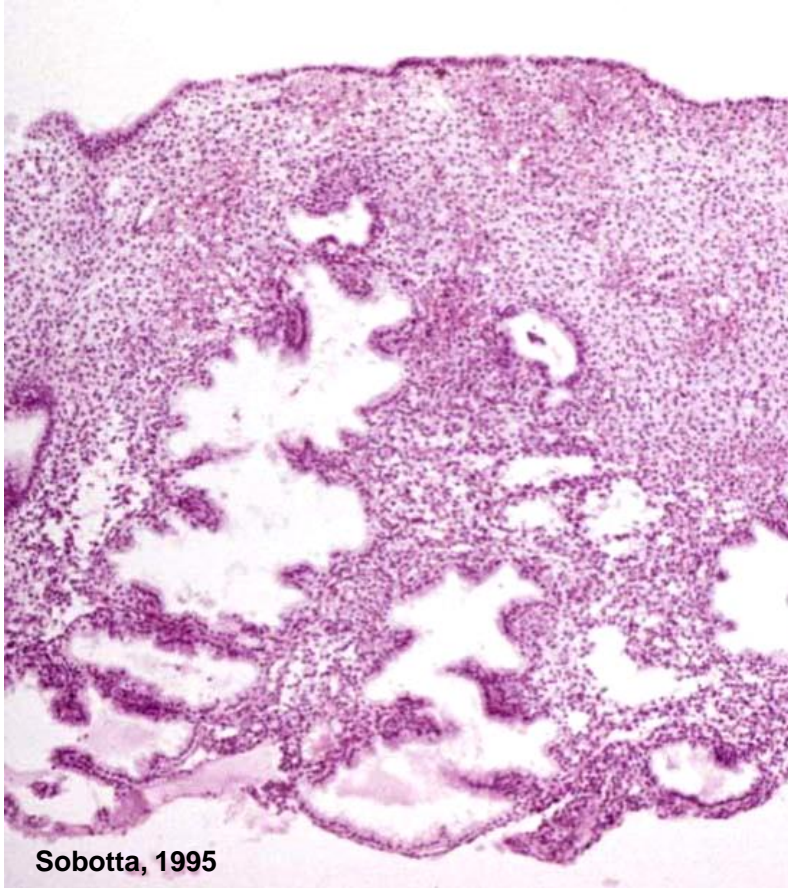
## Endometrium - Secretory phase



Sobotta, 1995

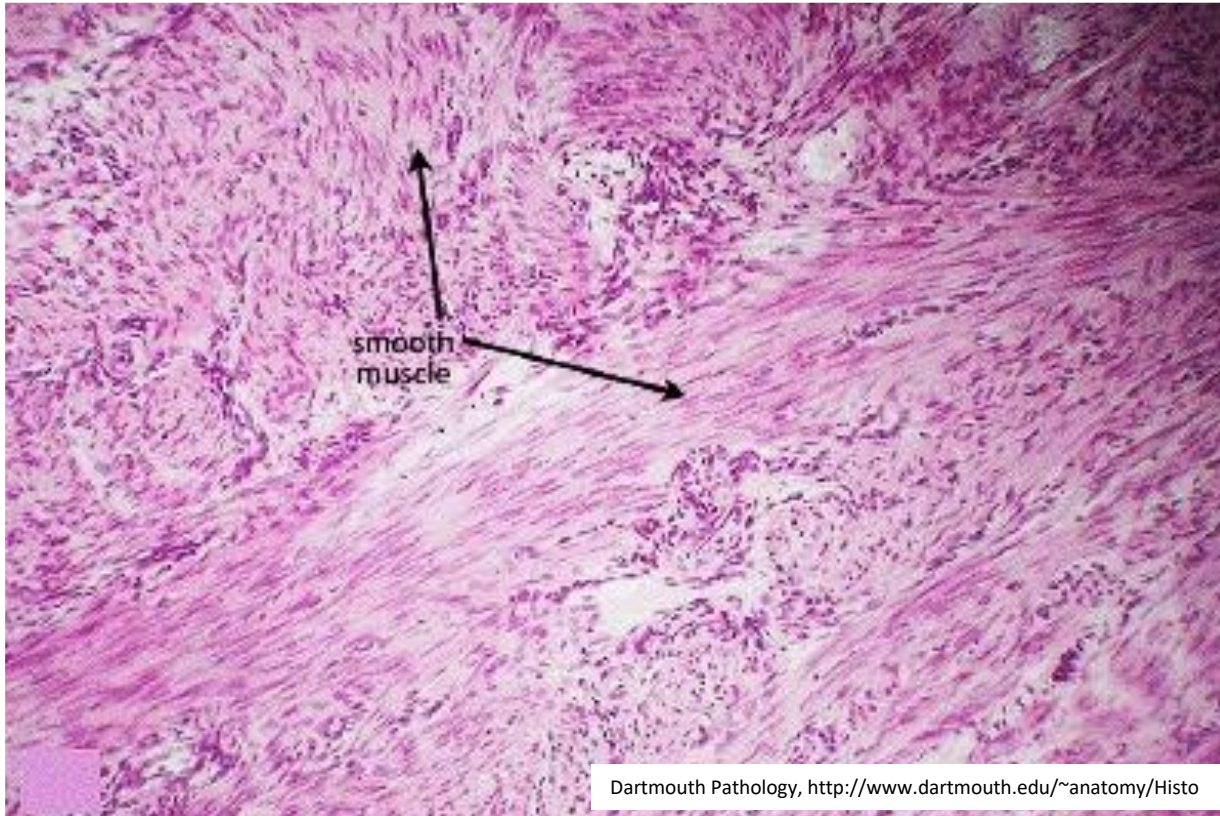
- under the control of estrogen and progesterone from the corpus luteum
- the uterine glands of the stratum functionalis begin to function, producing glycogen
- **the curvy and dilated glands and elongated spiral arteries**

# Endometrium - Menstrual phase



- lack of estrogen and progesterone from the dead corpus luteum
- the stratum functionalis dies and loses its anatomical integrity, breaking loose and shedding from the stratum basalis

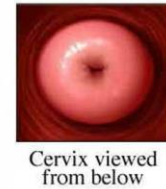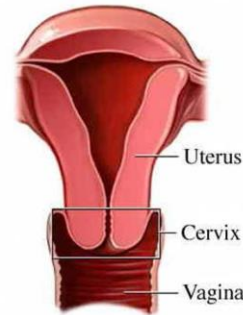
# Uterus - Myometrium



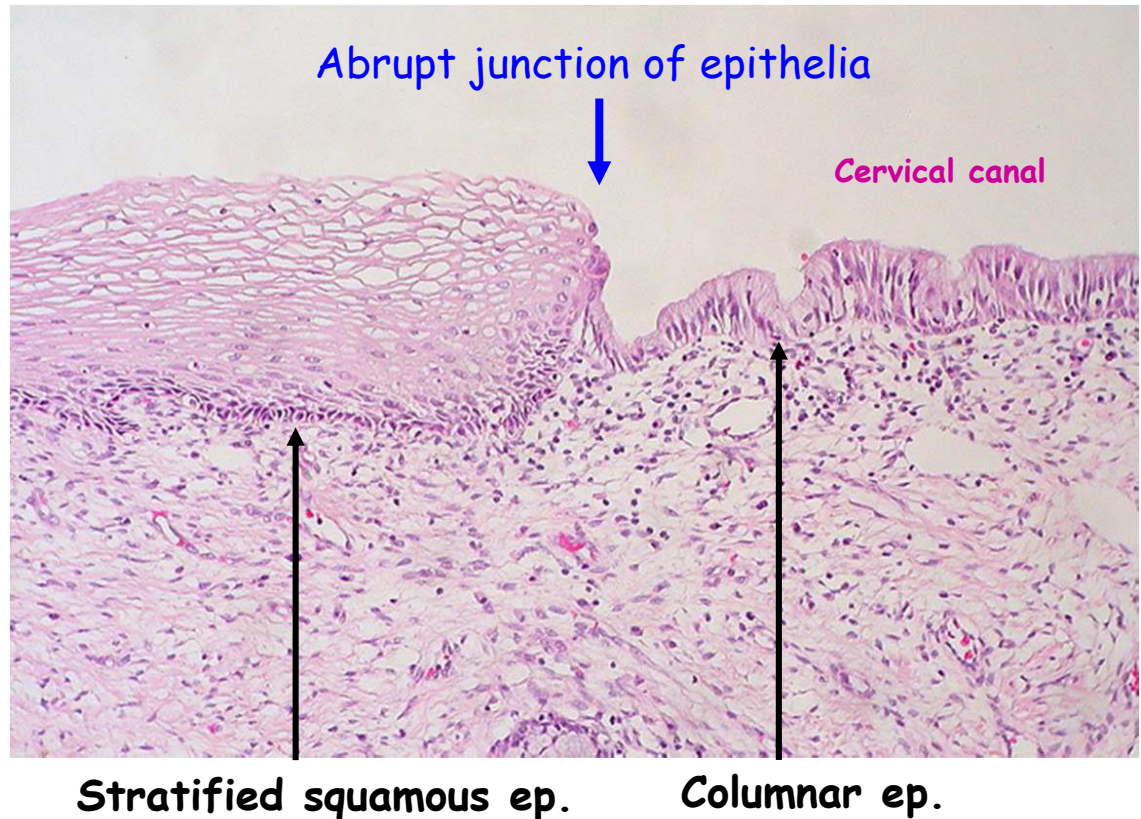
- **three interwoven layers** of smooth muscle
- during pregnancy - smooth muscle cell **hyperplasia + hypertrophy**
- contract in response to oxytocin during labor to expel the fetus from the uterus

# The Cervix + Orificium externum uteri

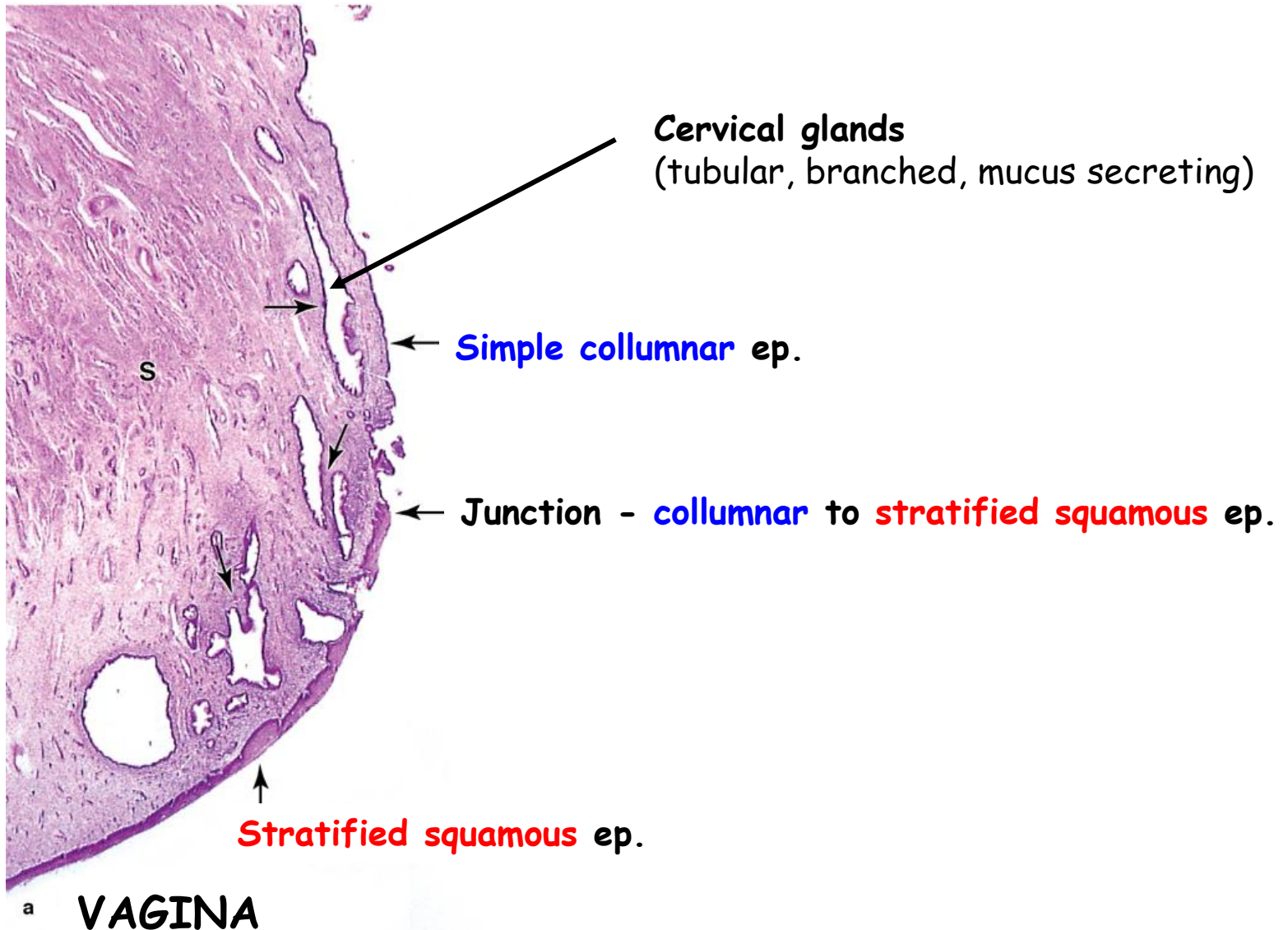
- 2-3 cm in length
- **cylindrical shape**
- cervical canal connects lumen of uterus to lumen of vagina
- numerous **mucous glands**
- changes thickness throughout ovulation cycle
- important for pregnancy and childbirth
- contributes to **capacitation**



uvahealth.com



# The Cervix

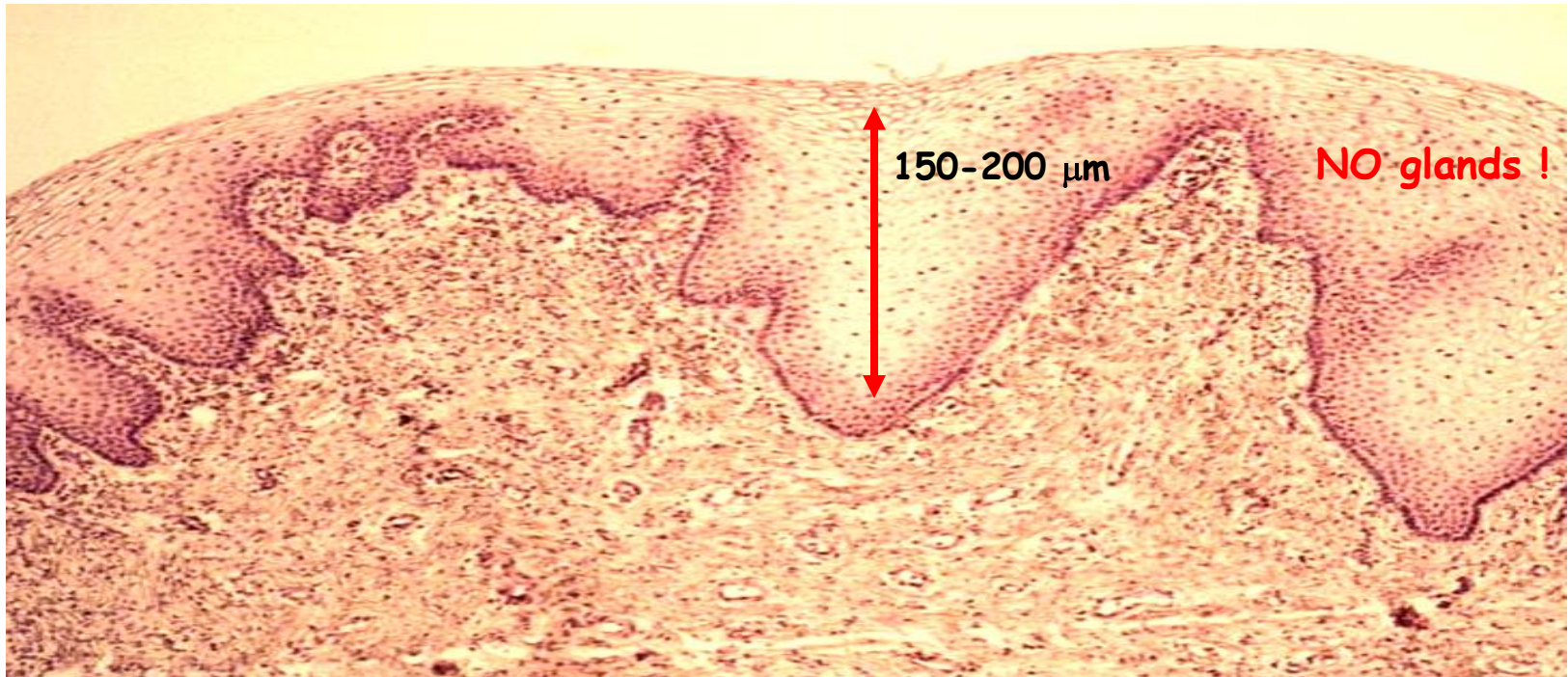


# Vagina 1

- receives sperm during copulation
- serves as birth canal

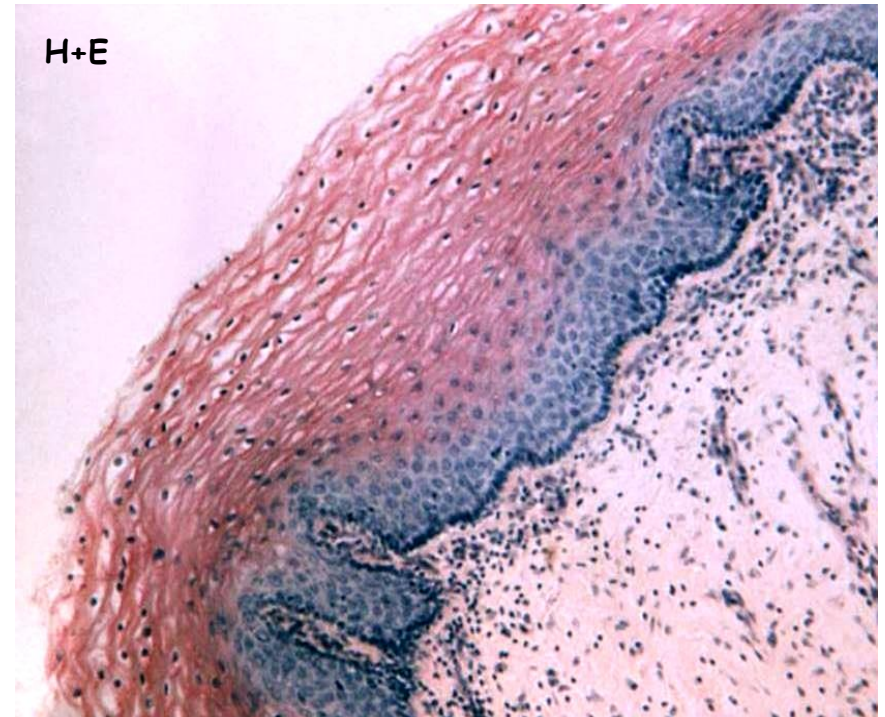
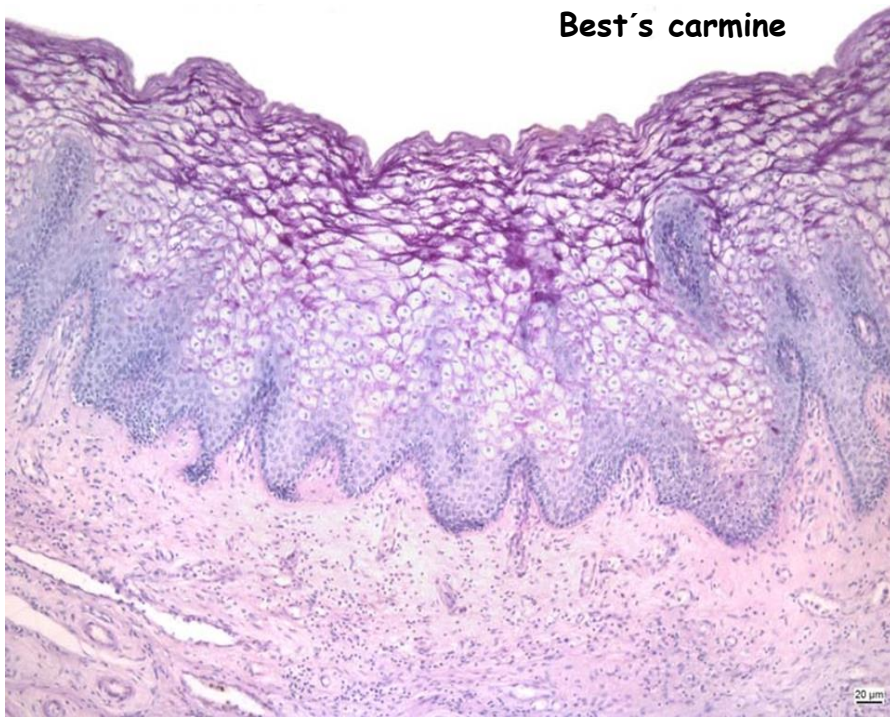## 3 tissue layers

- a) mucosal layer - inner layer; **non-keratinizing stratified squamous**
- b) muscular layer - middle layer; **smooth muscle in two layers**
- c) adventitia - outer layer; areolar connective tissue



## Vagina 2

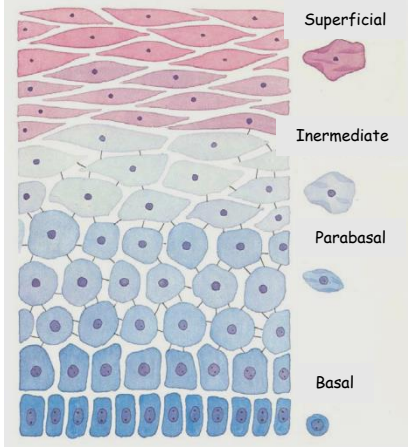
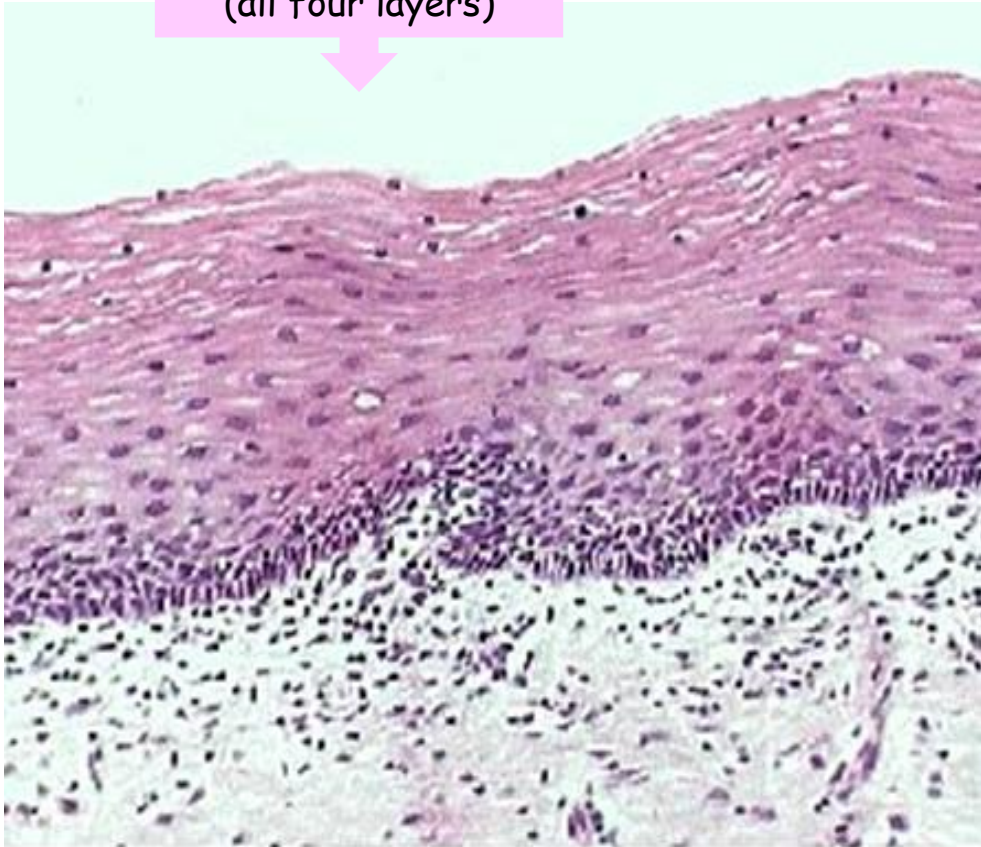
Epithelial cells synthesize and accumulate **glycogen** (upon stimulation by estrogens)





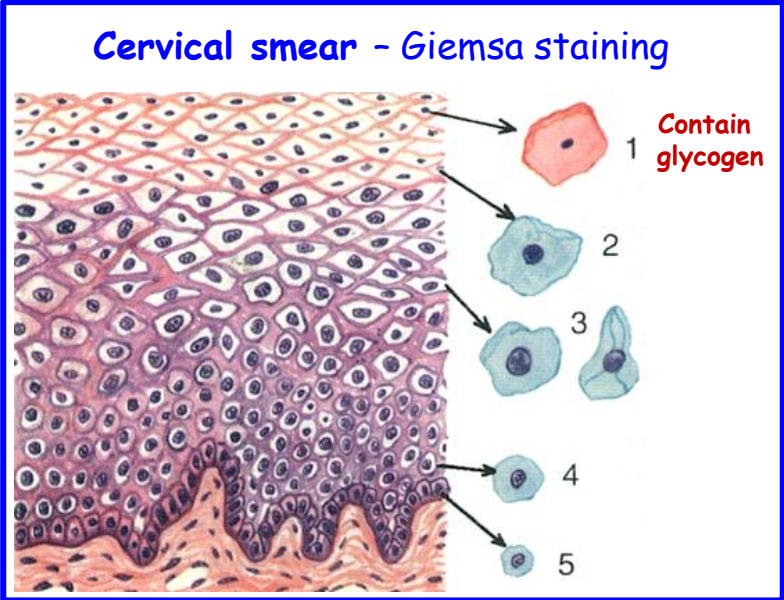
# Vagina 3

Preovulatory state  
(all four layers)



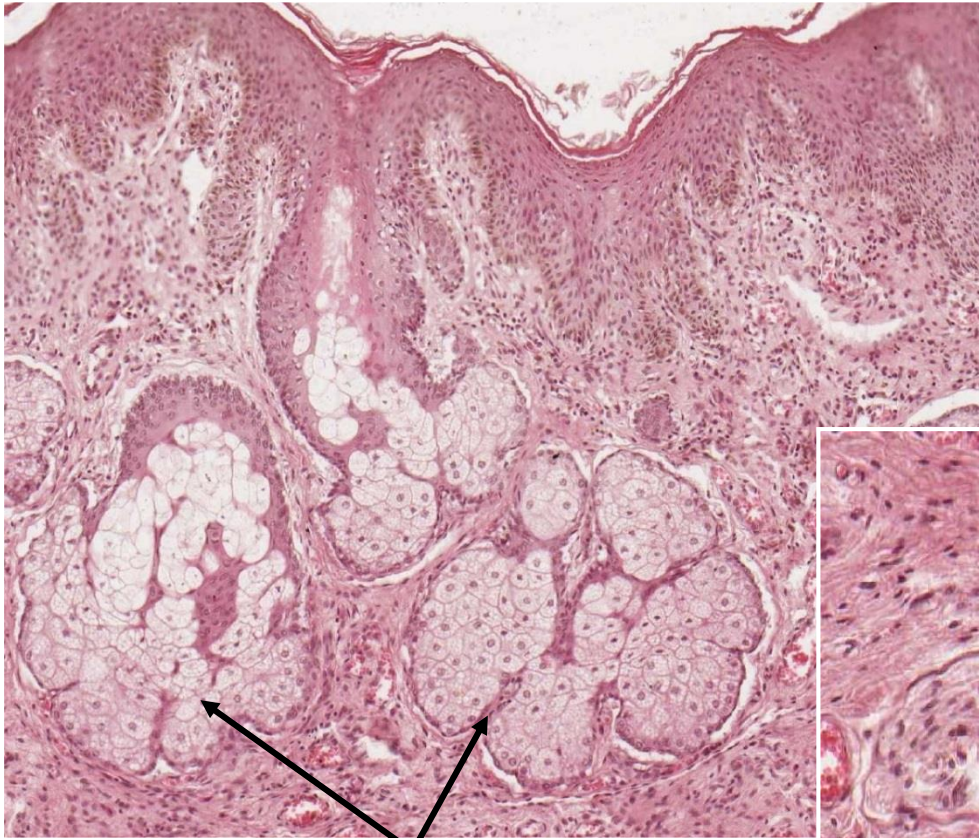
Released after ovulation

- glycogen
- Lactobacillus
- acidification



# Labia minora

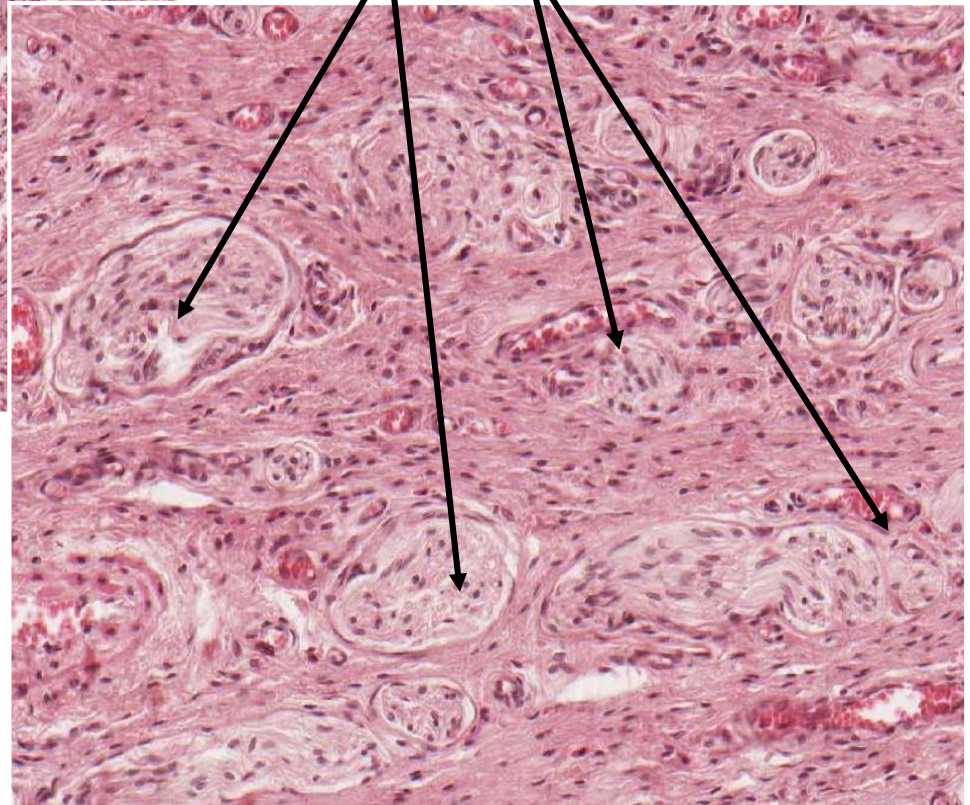
Covered by hairless skin



Sebaceous glands

Nerves

Veins



# Placenta 1

Temporary organ

## Functions

- 1) **transport** (water, oxygen, carbon dioxide, nutrients, antibodies, drugs, waste, ...)
- 2) **metabolism** (synthesis of glycogen, cholesterol, fatty acids)
- 3) **hormonal production**

**steroids:** progesteron, estrogen - maintenance of pregnancy

**peptides:** human chorionic gonadotropin, human placentar lactogen, relaxin, leptin, growth factors)

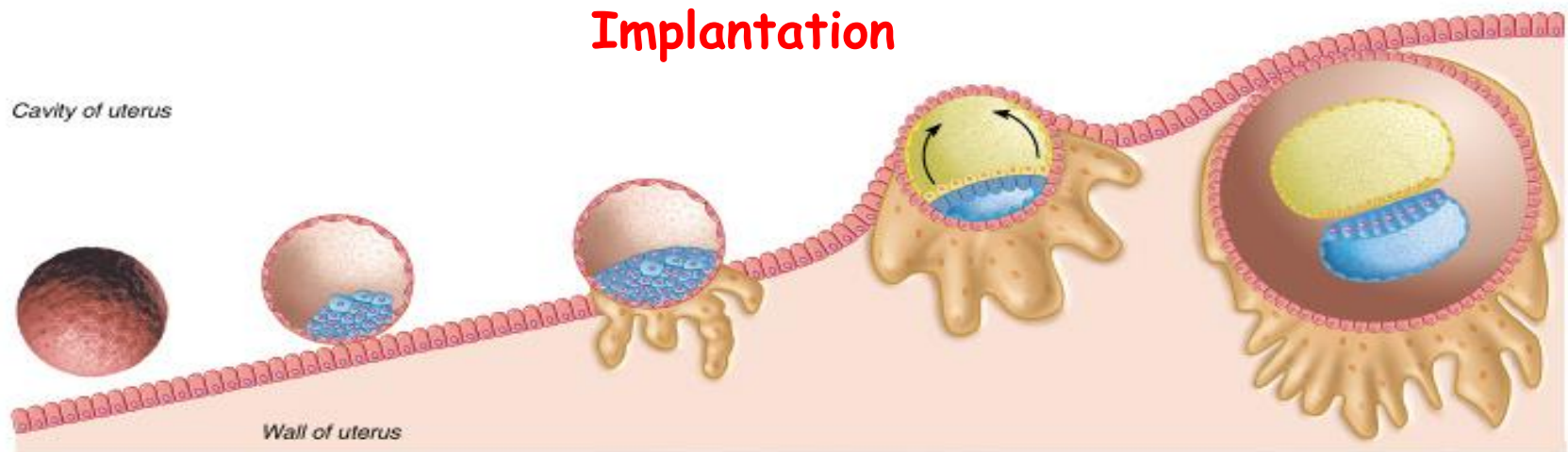
(a) Day 5

(b) Day 6

(c) Day 7

(d) Day 9

(e) Day 11

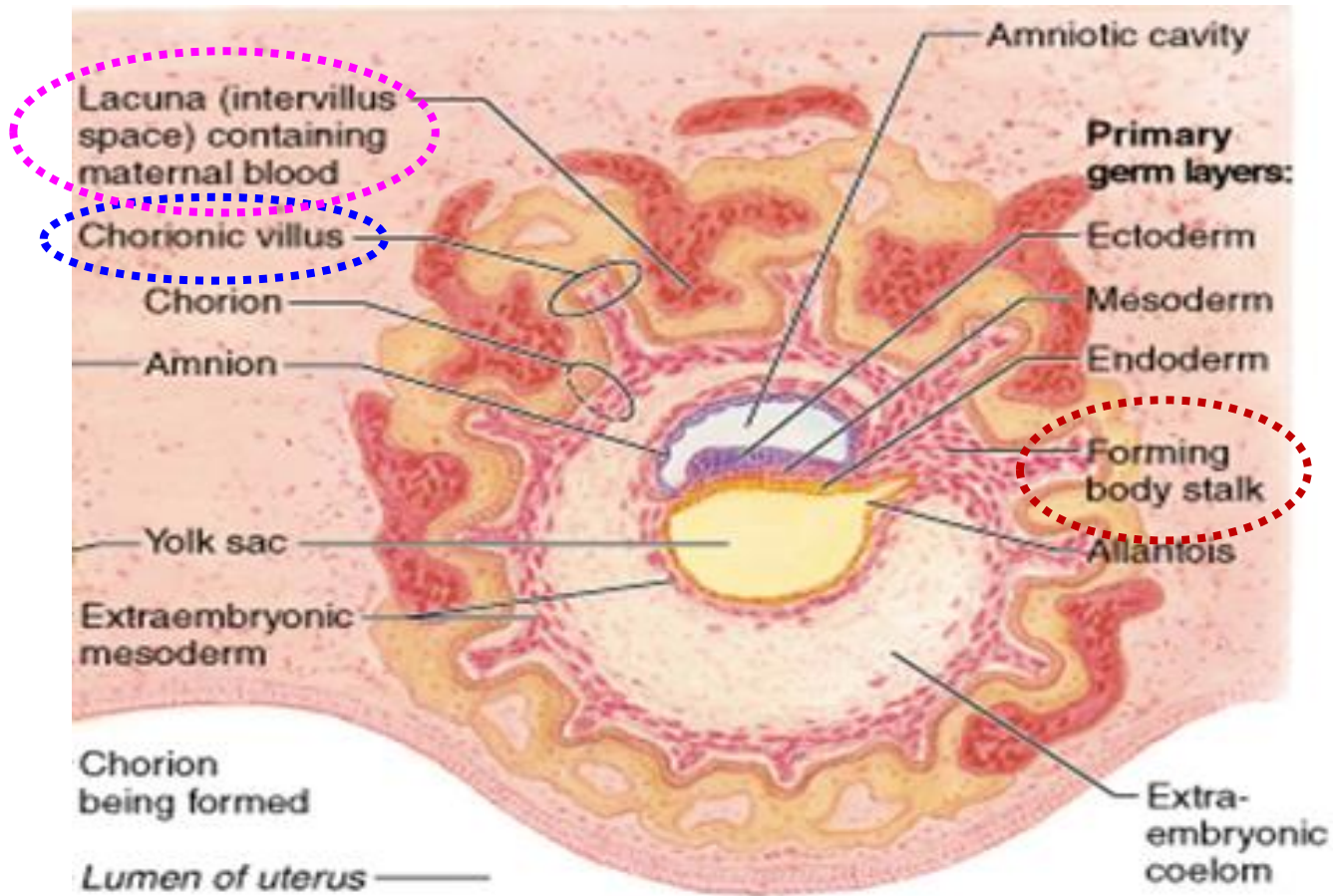


## Implantation

Copyright © Pearson Education, Inc., publishing as Benjamin Cummings.

Syncytiotrophoblast invades the surrounding stroma

# Placenta 2



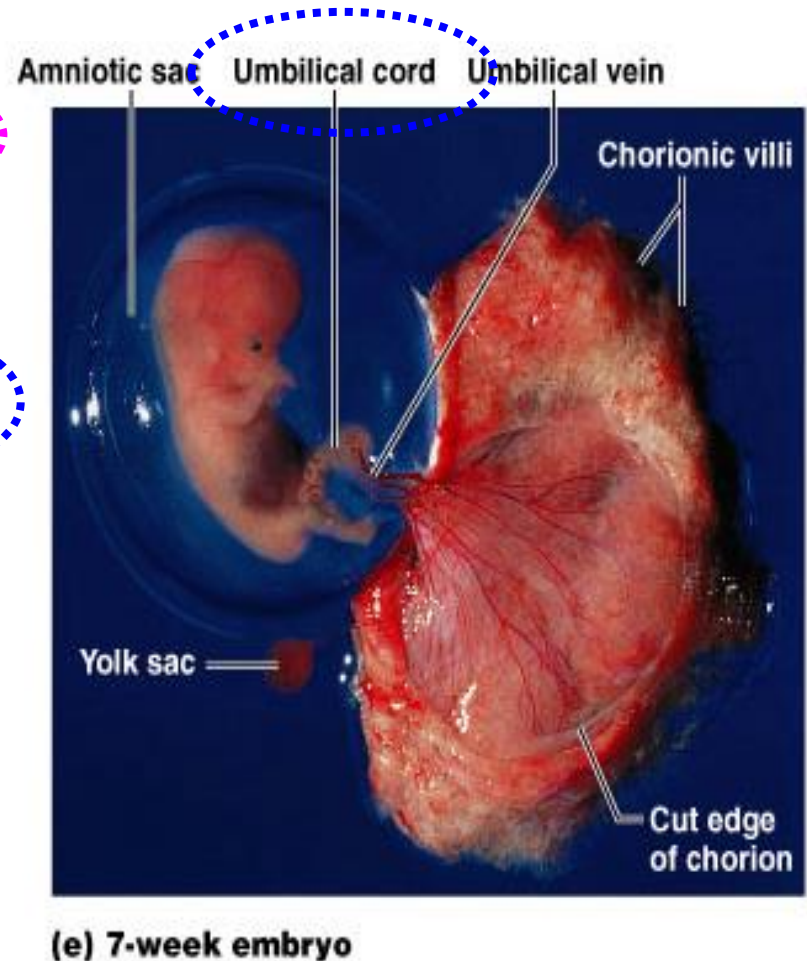
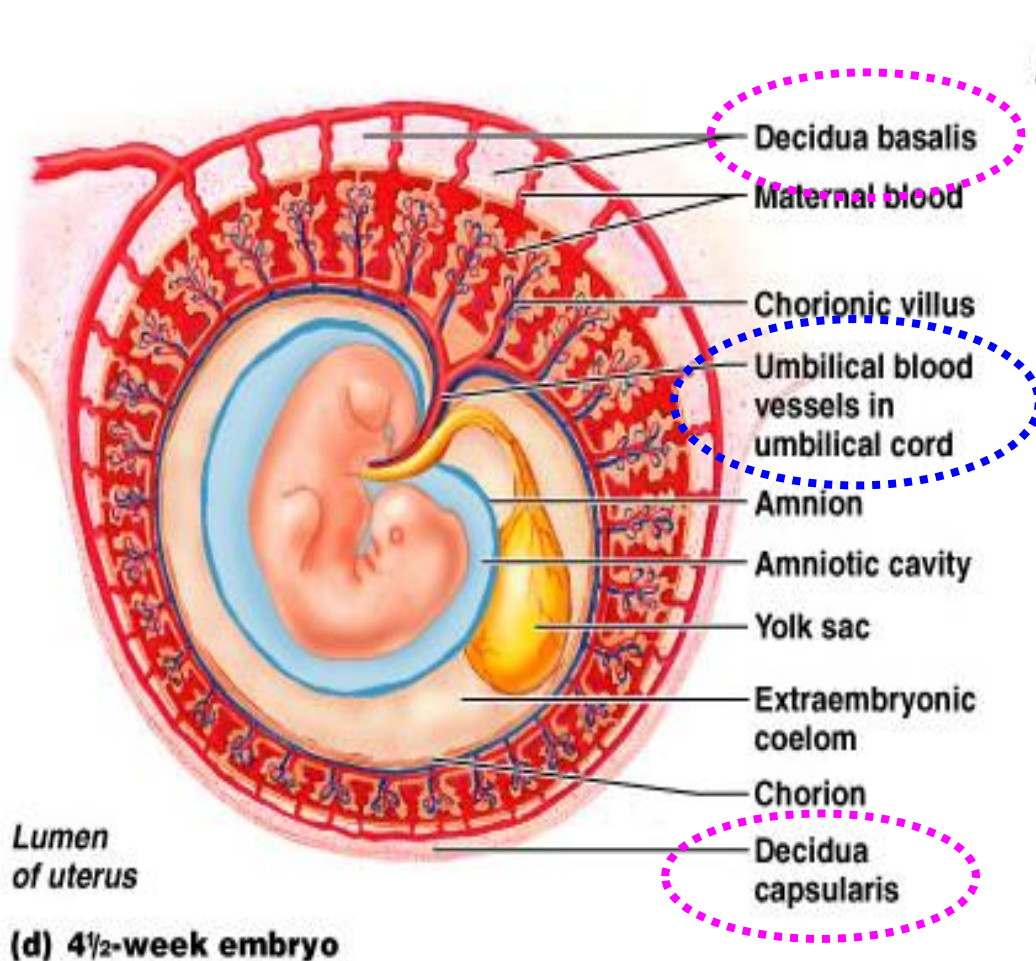
(c) 16-day embryo

**Chorionic villi** - finger like projection of embryonic tissue that come in contact with bleeding endometrium

**Decidual cells** - fibroblast of endometrium (large, cuboidal, very active proteosynthesis)

**Placenta** - thick disk made by decidua and chorionic villi (formed at the start of month 4)

# Placenta 3

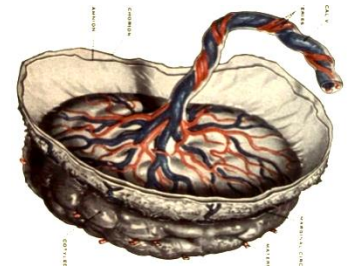


**Decidua basalis** - between embryo and myometrium

**Decidua capsularis** - between embryo and the uterine lumen (thins as the embryo grows)

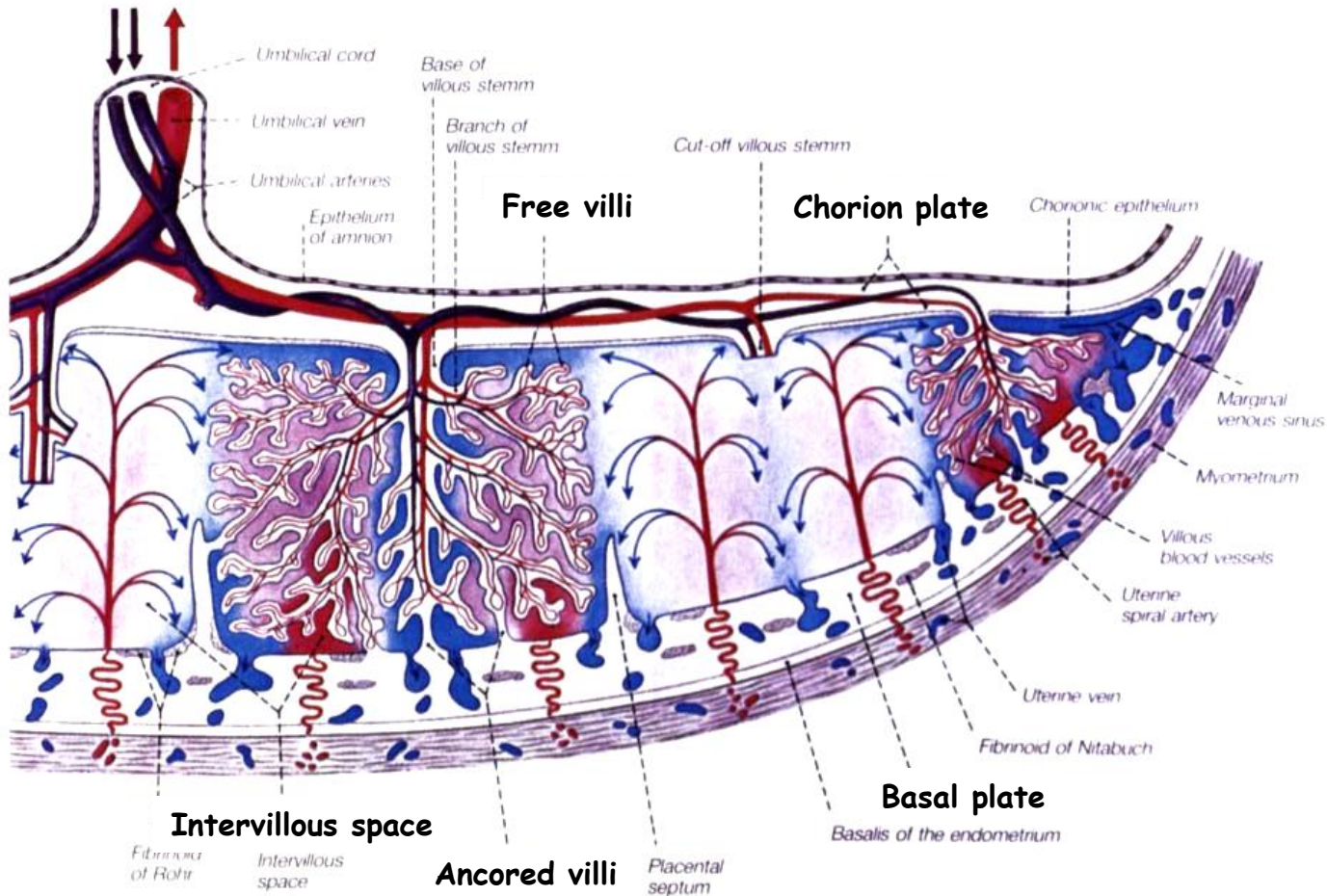
discoid  
15 - 20 cm  
400 - 600 g

# Placenta 4

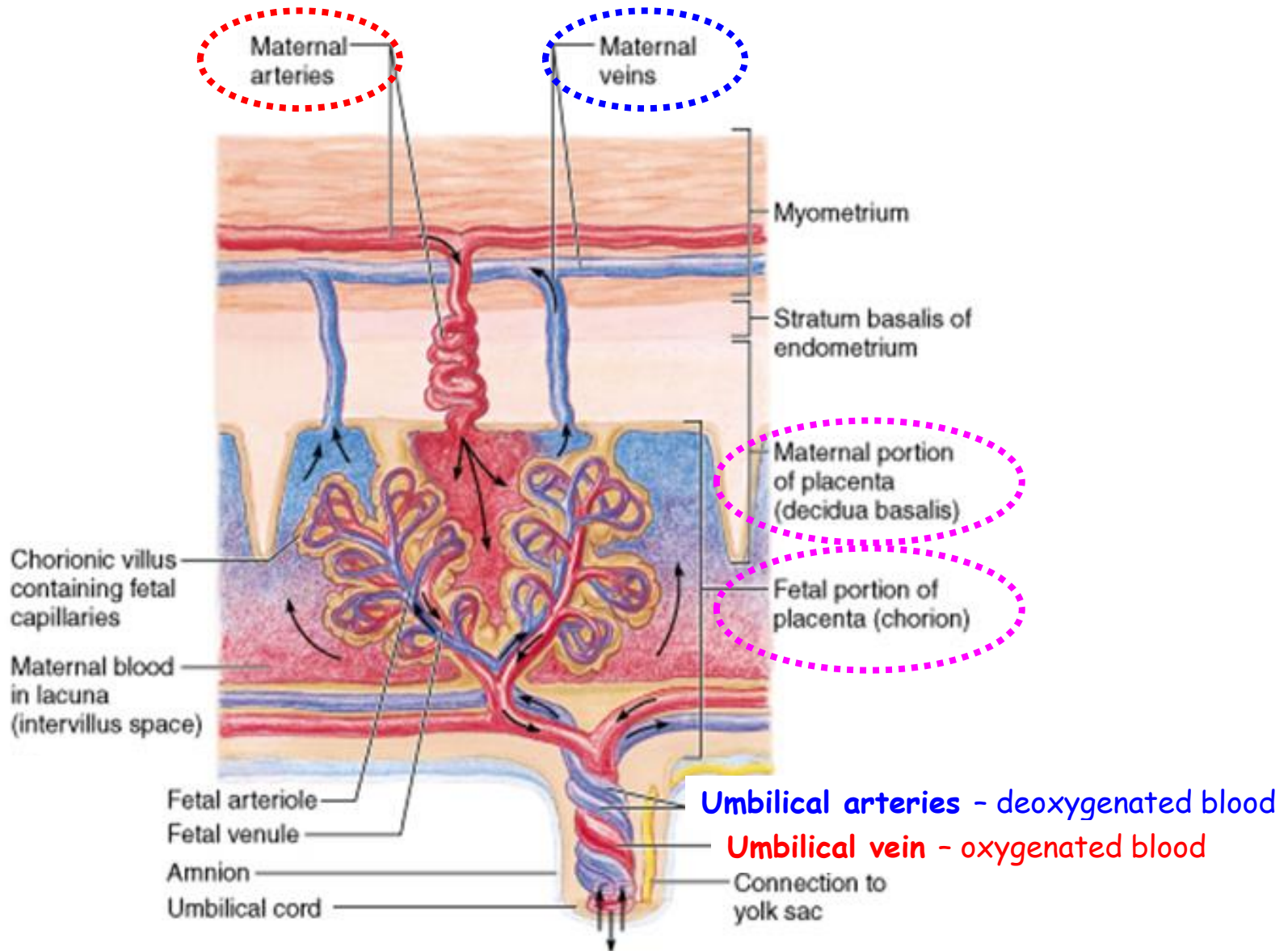


**Discoidalis + Hemochorialis**

- **pars fetalis** - chorion plate, chorion villi (anchored, free = terminal)
- **pars materna** - decidua basalis
- **intervillous spaces** - develop from lacunes



# Placenta 5



# Placenta 6

Ambiotic epithelium  
(ectoderm)

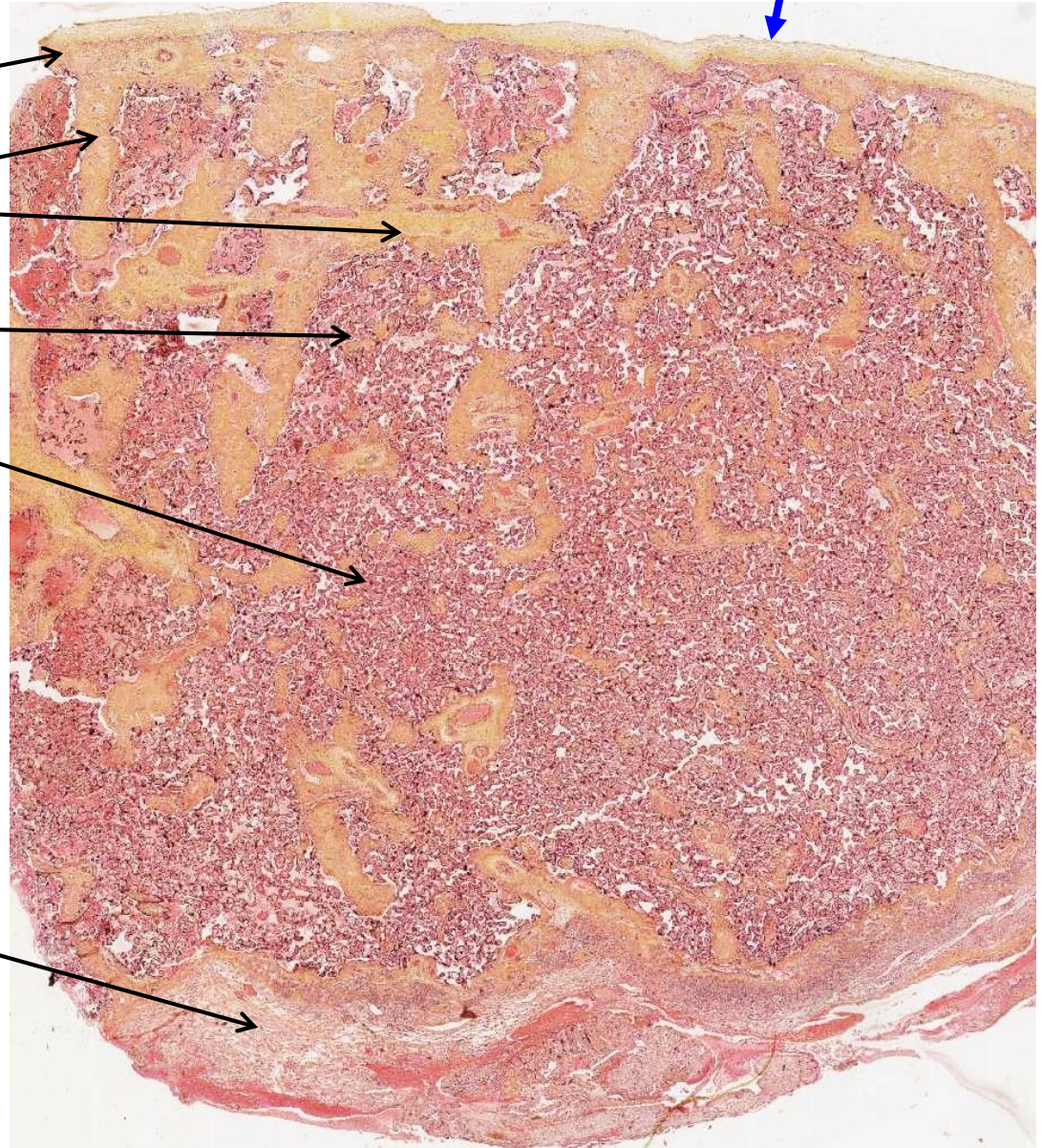
Pars fetalis

Chorion plate

Anchored villi

Free villi

Pars materna



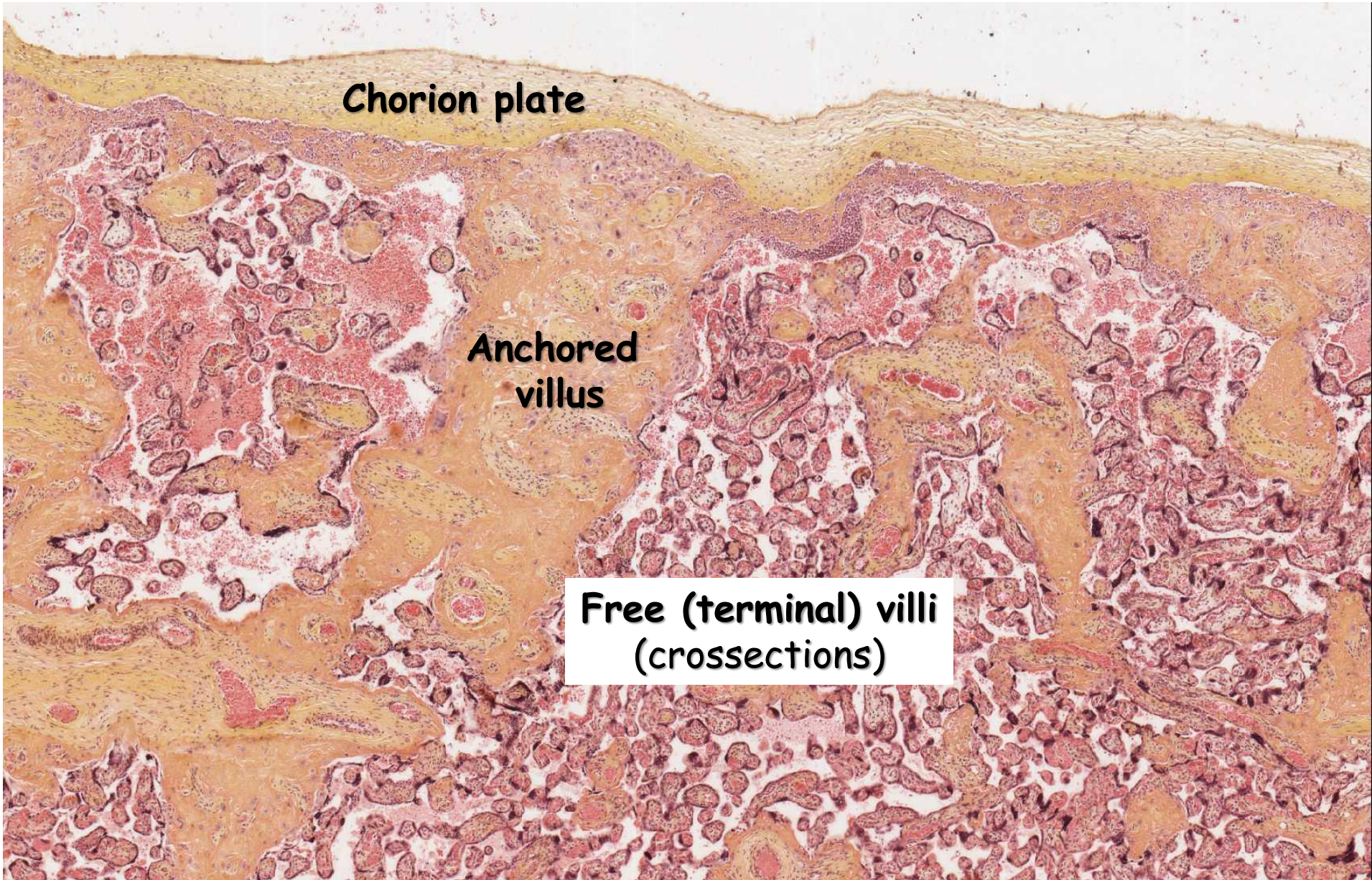


# Placenta 7

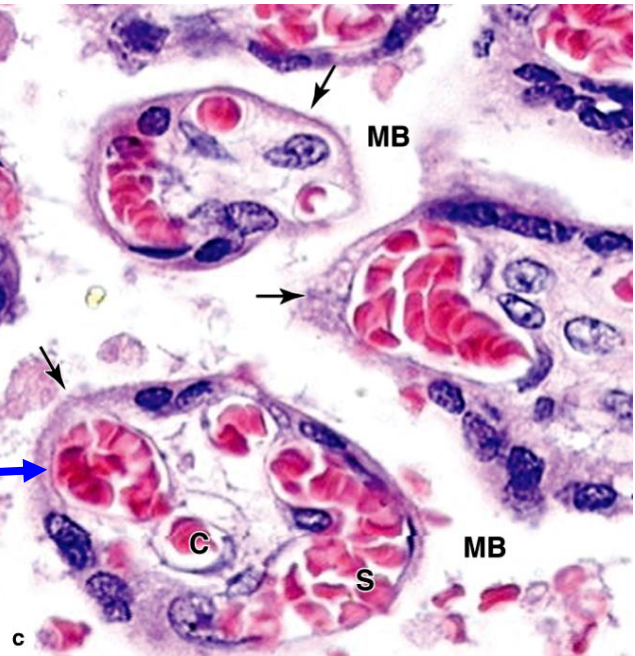
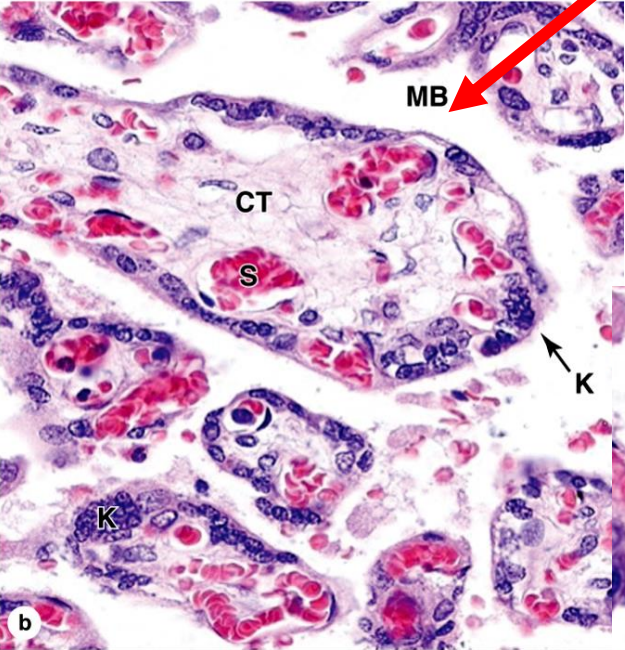
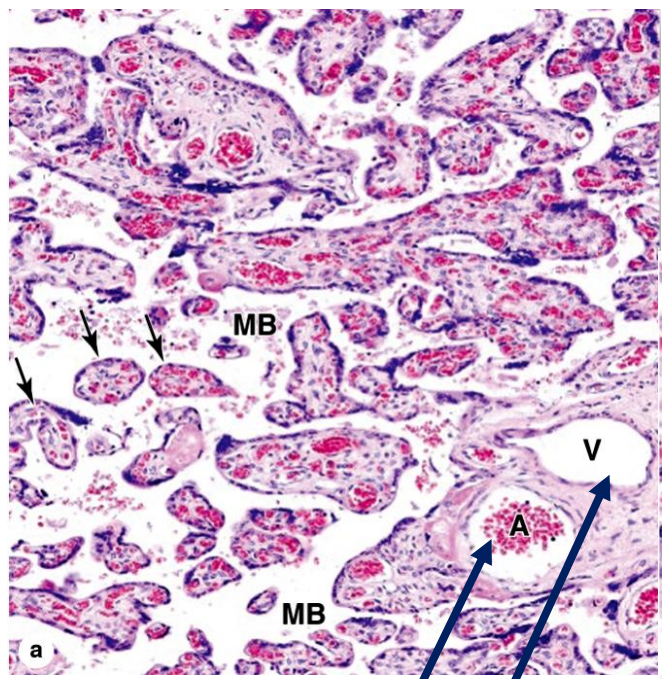
**Chorion plate**

**Anchored villus**

**Free (terminal) villi  
(crosssections)**



# Placenta 8 - Free villi



Extraembryonic vasculature

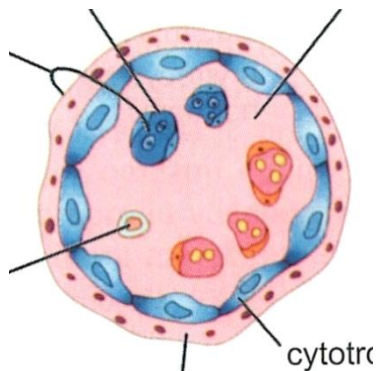
Syncytiotrophoblast

Maternal blood

# Placental barrier

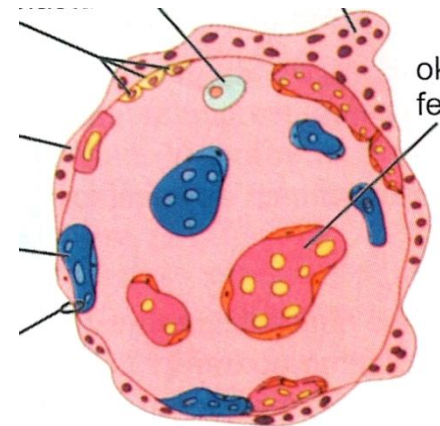
## Until mid pregnancy

- capillary endothelium
- basal lamina of endothelium
- mucous connective tissue
- cytotrophoblast
- basal lamina of syncytiotrophoblast
- syncytiotrophoblast



## Since month 5

- capillary endothelium
- basal lamina of endothelium
- basal lamina of syncytiotrophoblast
- syncytiotrophoblast



# Umbilical cord

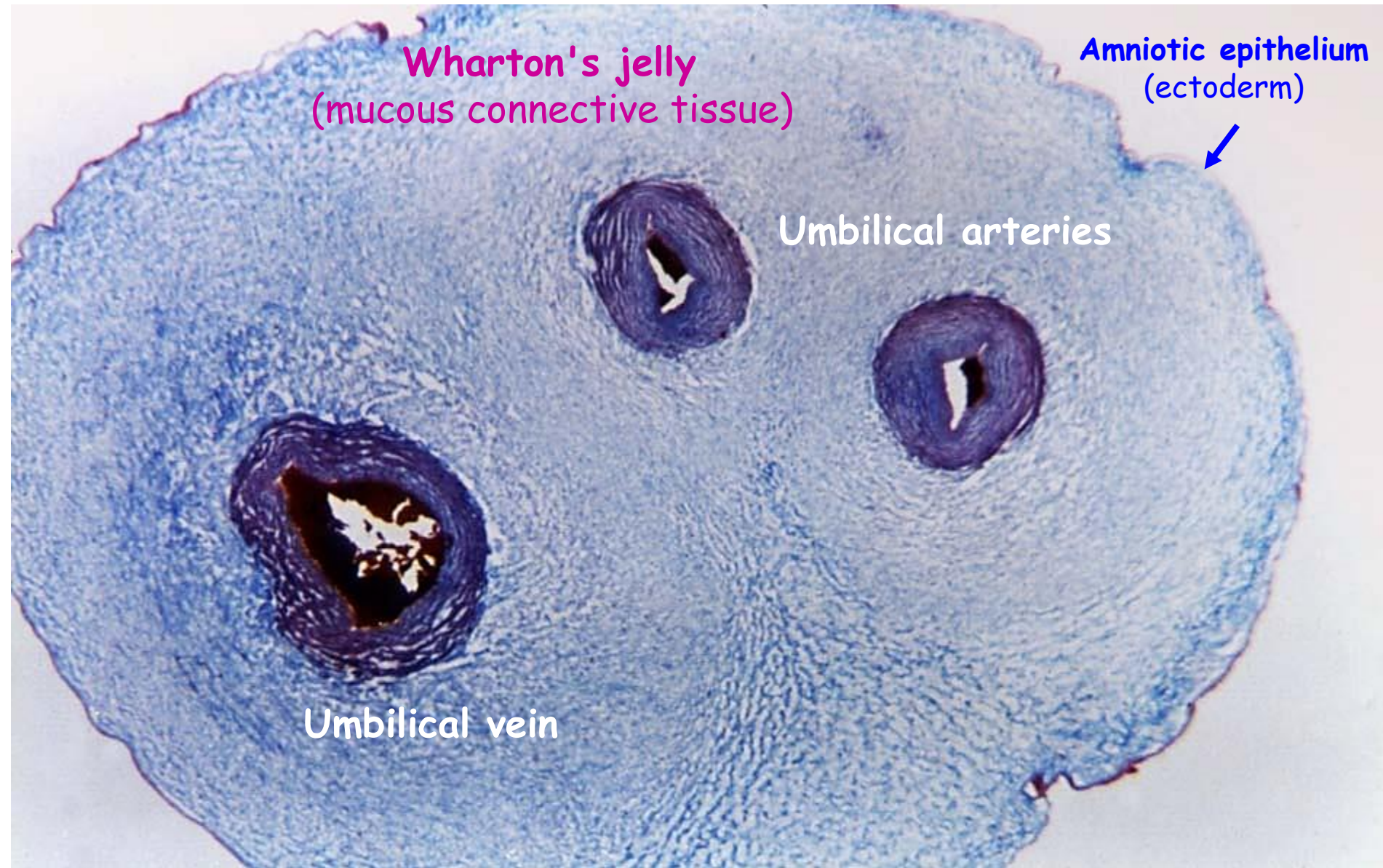
- links foetus to placenta
- about 55 cm in length

Wharton's jelly  
(mucous connective tissue)

Amniotic epithelium  
(ectoderm)

Umbilical arteries

Umbilical vein



**Thank you for your attention !**

Questions and comments at:  
[ahampl@med.muni.cz](mailto:ahampl@med.muni.cz)