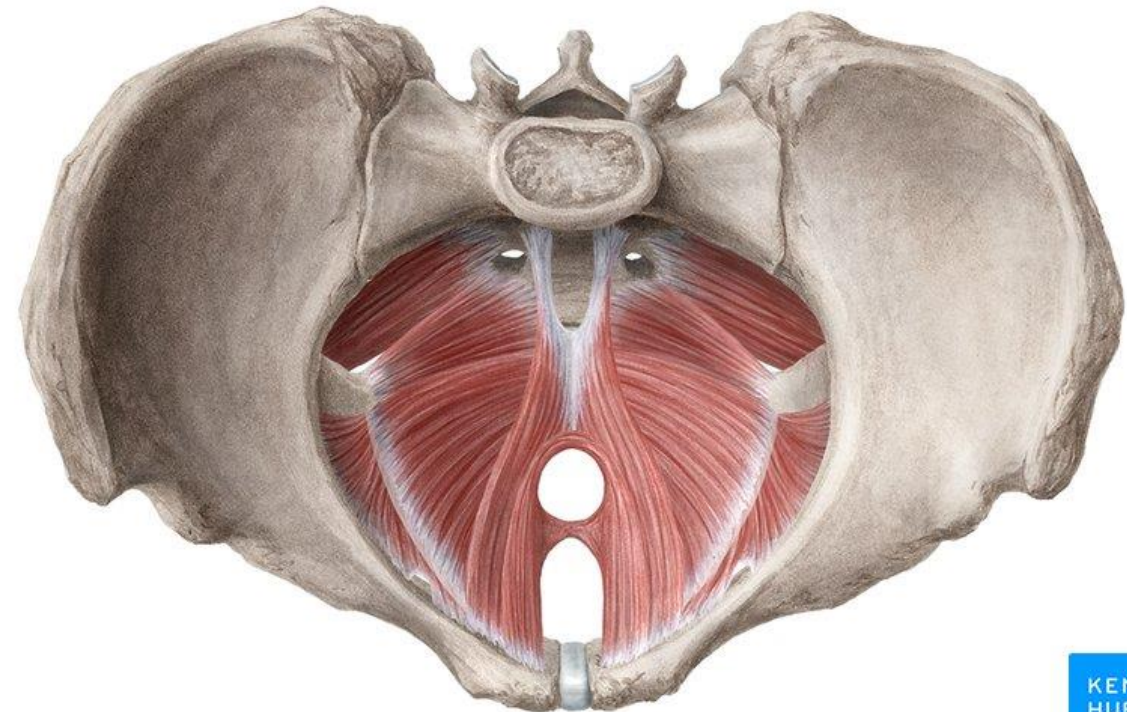
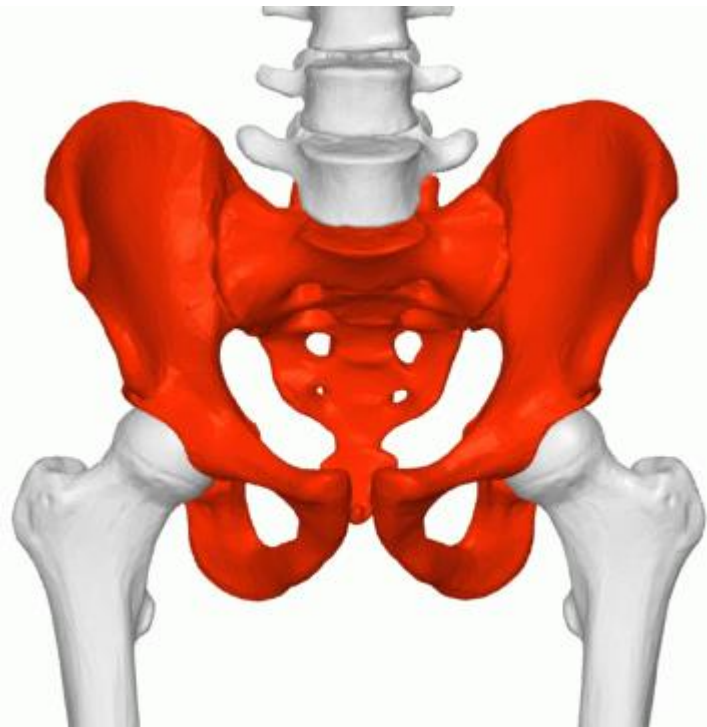


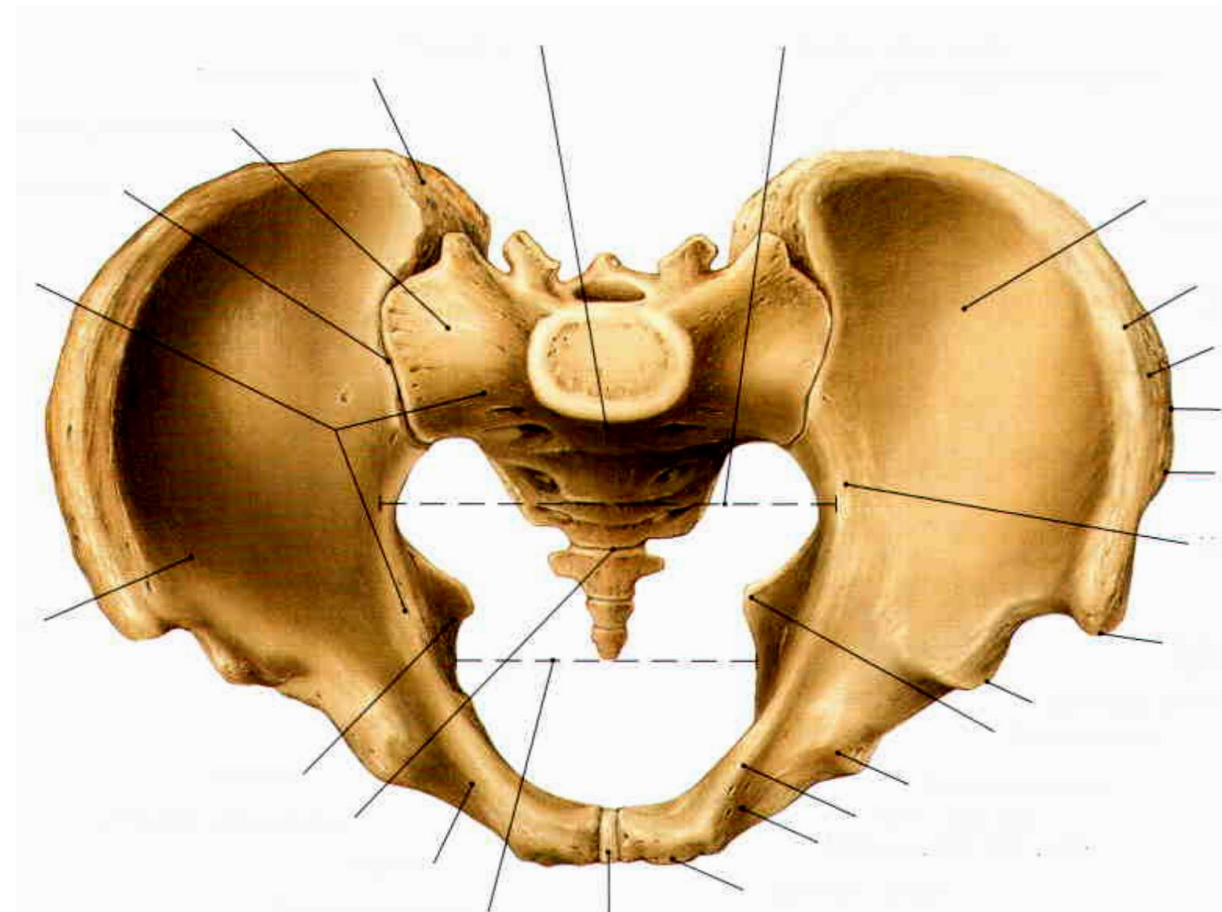
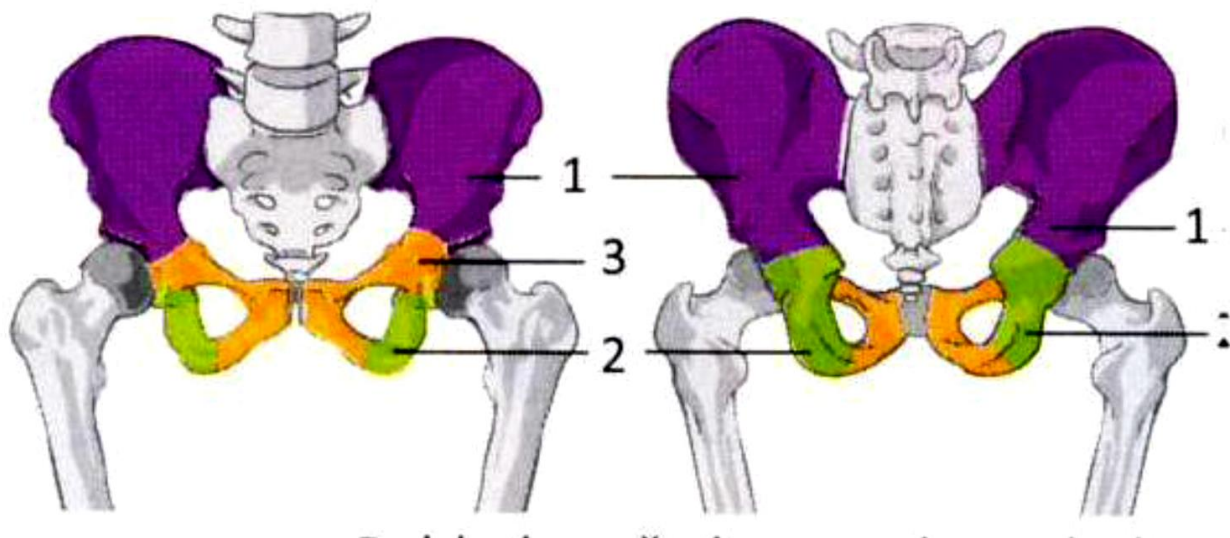
Svalové dno pánevní



Os ilium – kyčelní kost

Os ischii – sedací kost

Os pubis – stydká kost

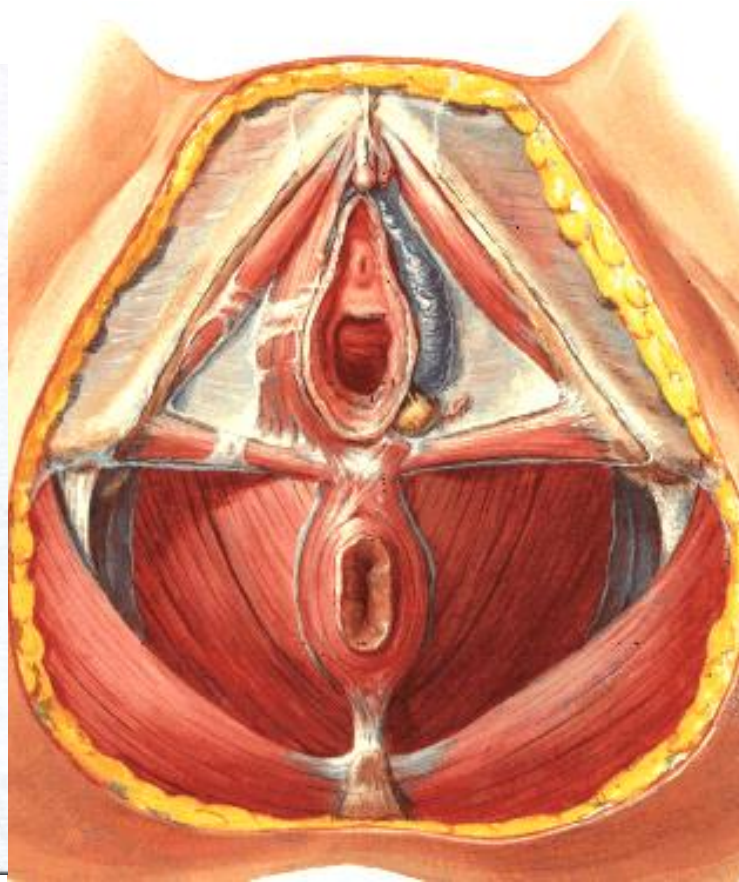
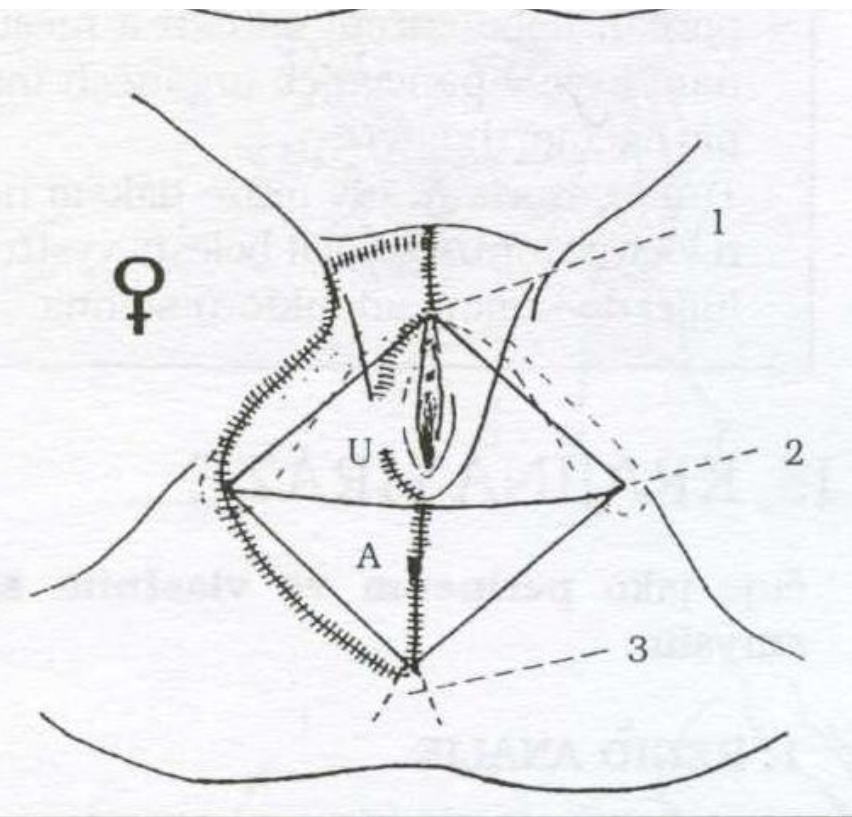


PERINEUM – prostor mezi vnějšími pohlavními orgány a řitním otvorem (**u ženy commisura labiorum posterior a canalis analis**)

Pánevní východ

a) **Trigonum urogenitale** – přední trojúhelník

b) **Trigonum anale** – zadní trojúhelník

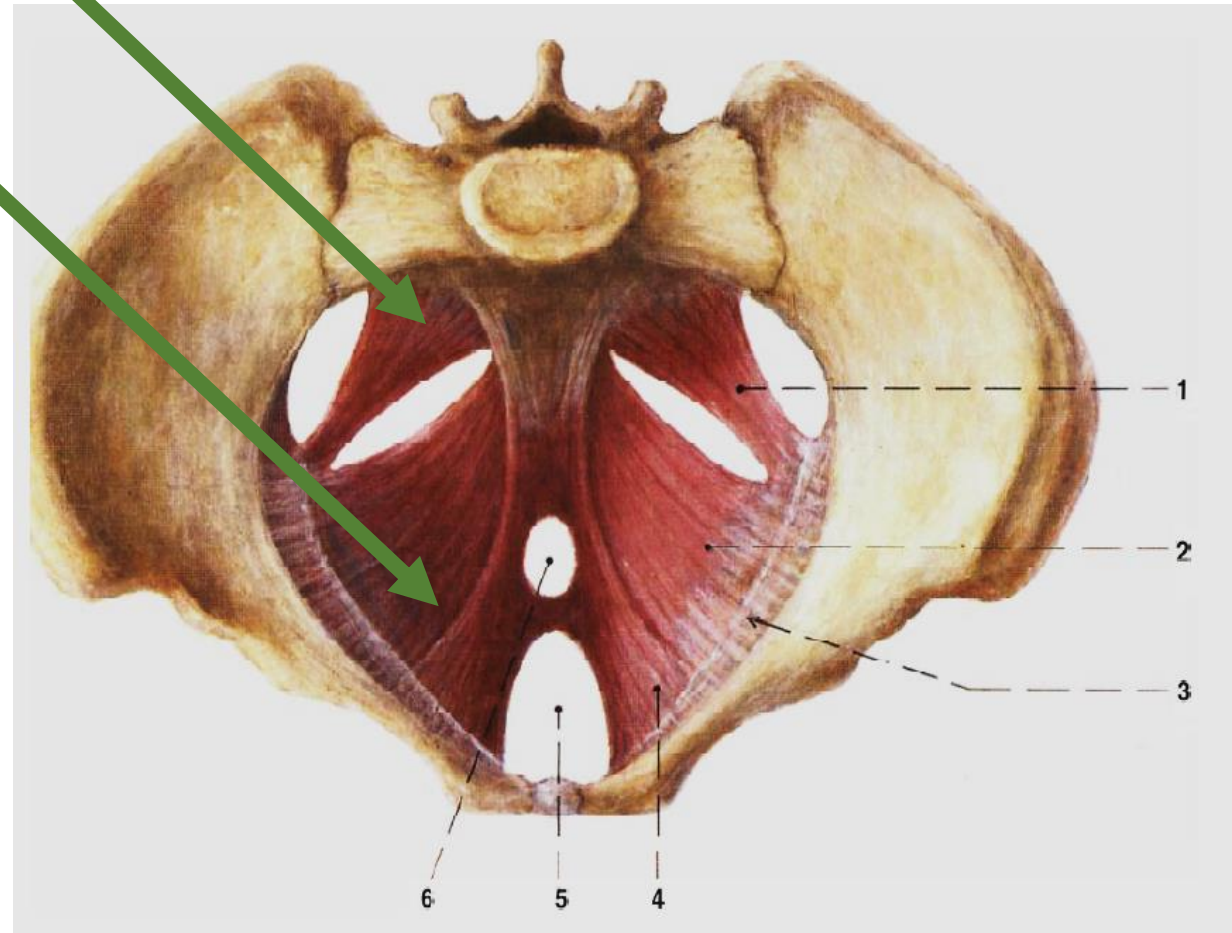


Diaphragma pelvis – pánevní dno

Diaphragma urogenitale – močopohlavní dno

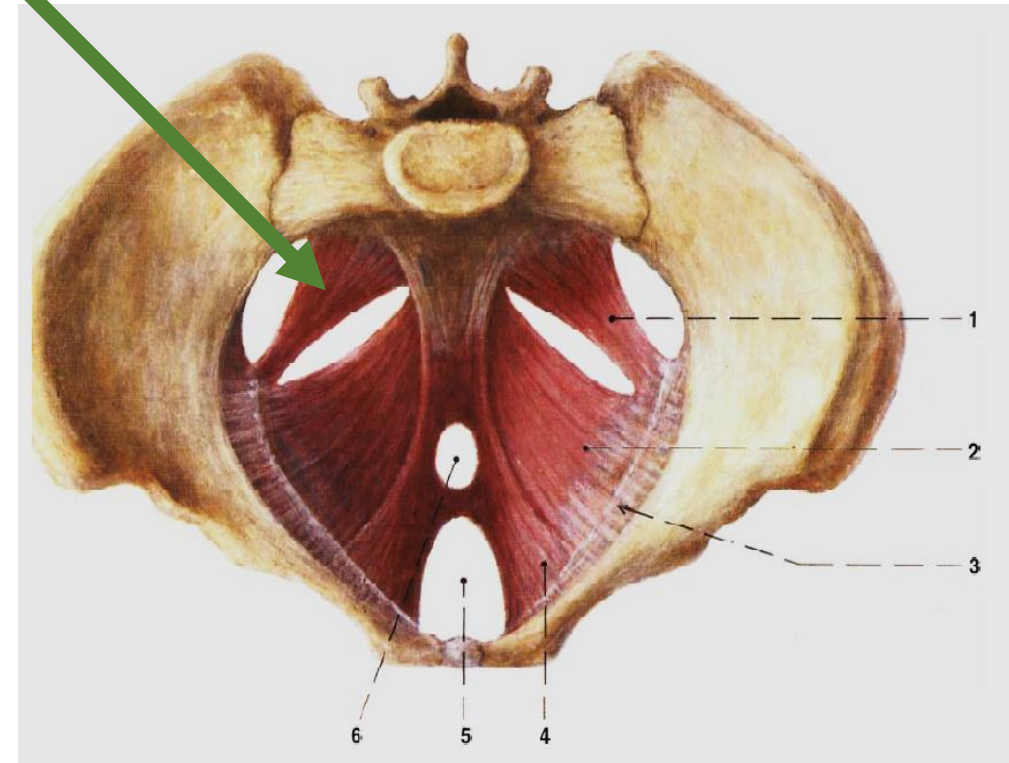
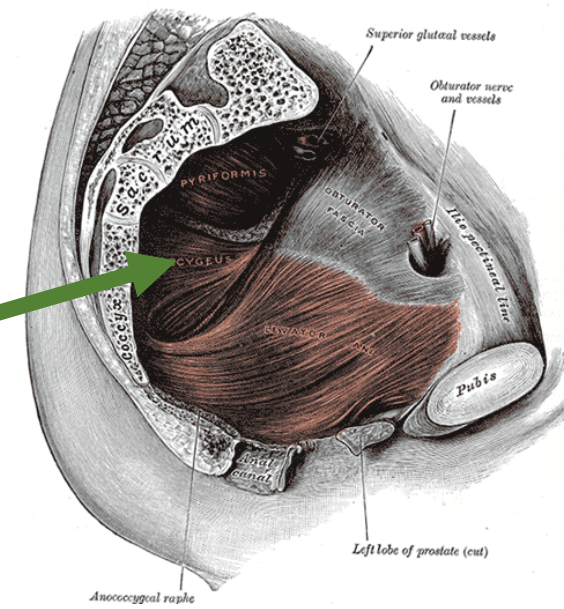
DIAPHRAGMA PELVIS

1. **Musculus ischiococcygeus** – sedokostrční sval
2. **Musculus levator ani** – řitní zdvihač



DIAPHRAGMA PELVIS

1. Musculus ischiococcygeus (spina ischiadica – kostrč a obratel S5)



DIAPHRAGMA PELVIS

2. Musculus levator ani

a) **Pars pubica** = m. pubococcygeus

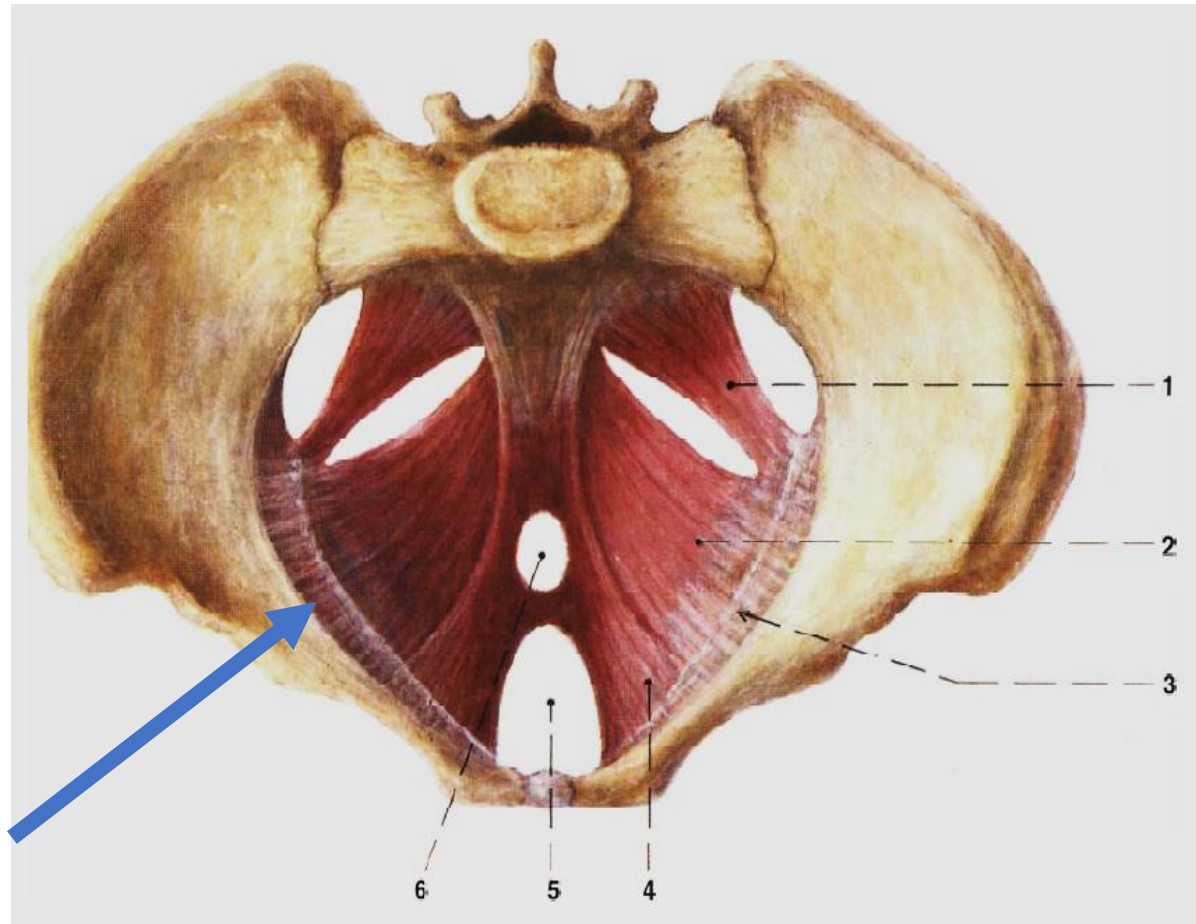
b) **Pars iliaca** = m. iliococcygeus

c) **M. puborectalis**
(*pubovaginalis*)

- *lig. anococcygeum*

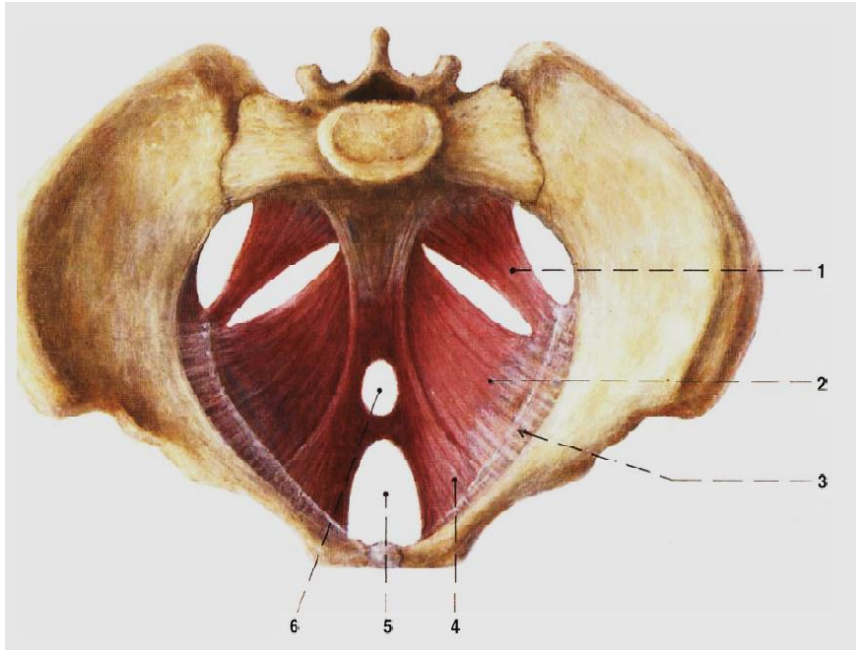
- *arcus tendineus muscoli levatoris ani*

- *hiatus urogenitalis*



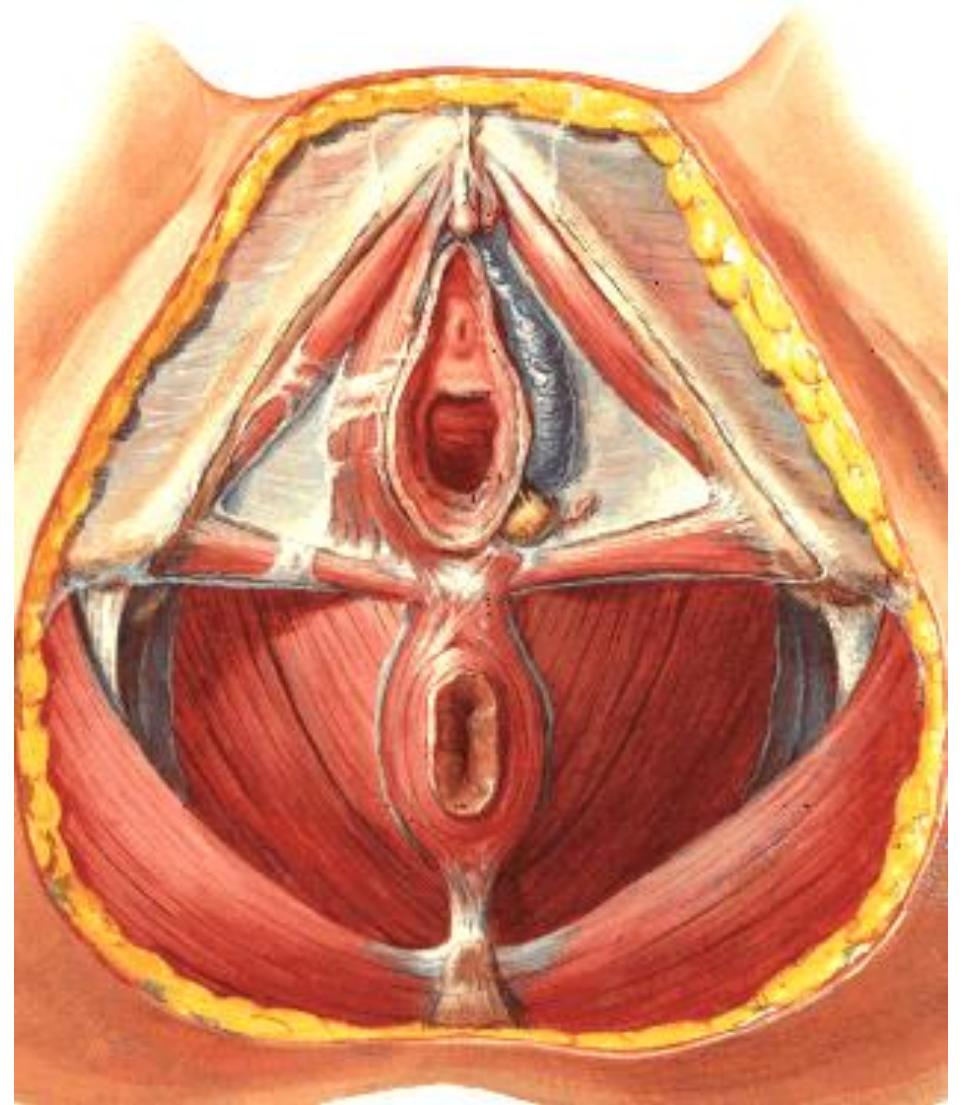
DIAPHRAGMA PELVIS

Povázky



a) **Fascia diaphragmatis pelvis superior** – na vnitřní straně pánve

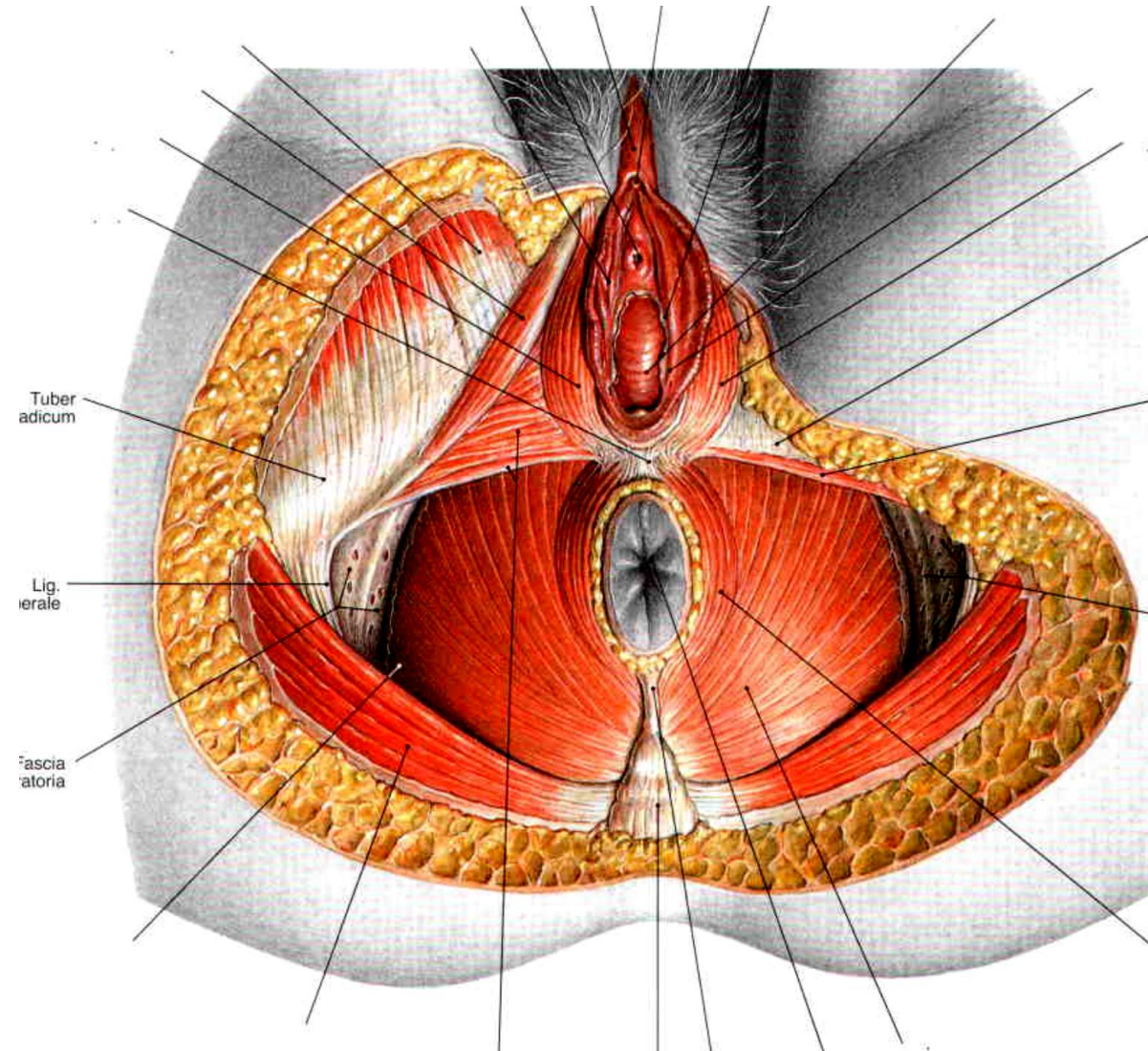
b) **Fascia diaphragmatis pelvis inferior** – na vnější hrázové straně pánve



DIAPHRAGMA UROGENITALE

1. Musculus transversus perinei profundus
(ramus ossis ischii → centrum tendineum)

2. Musculus transversus perinei superficialis
(tuber ischiadicum → centrum tendineum)



DIAPHRAGMA UROGENITALE

1. Musculus ischiocavernosus

Tuber ischiadicum → crus clitoridis

2. Musculus bulbospongiosus

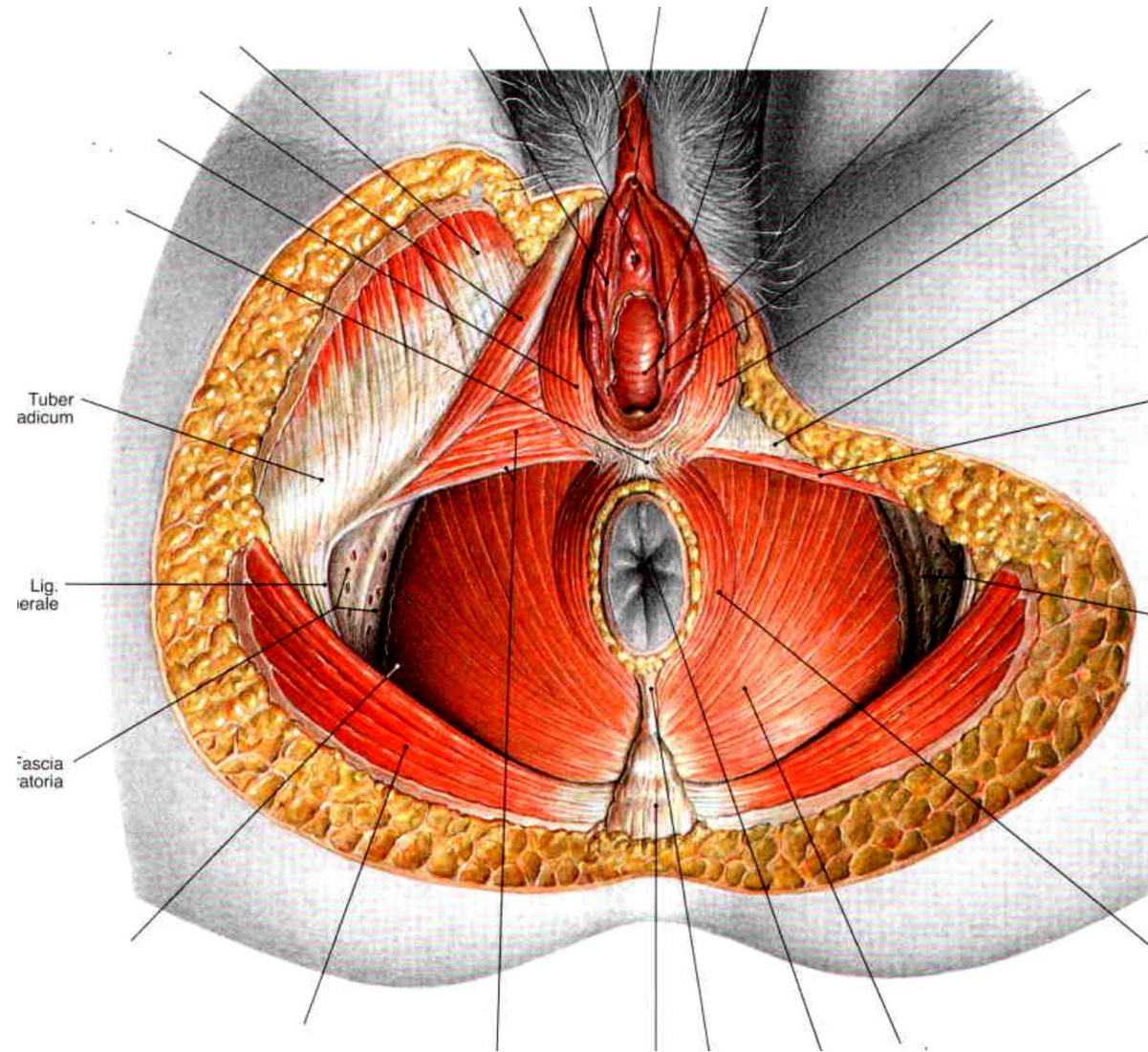
Centrum tendineum → dorsum clitoridis

3. Svaly močové trubice

- M. sphincter urethrae externus
- M. compressor urethrae
- M. sphincter urethrovaginalis

4. Musculus sphincter ani externus

- zdola přiložený k m. levator ani

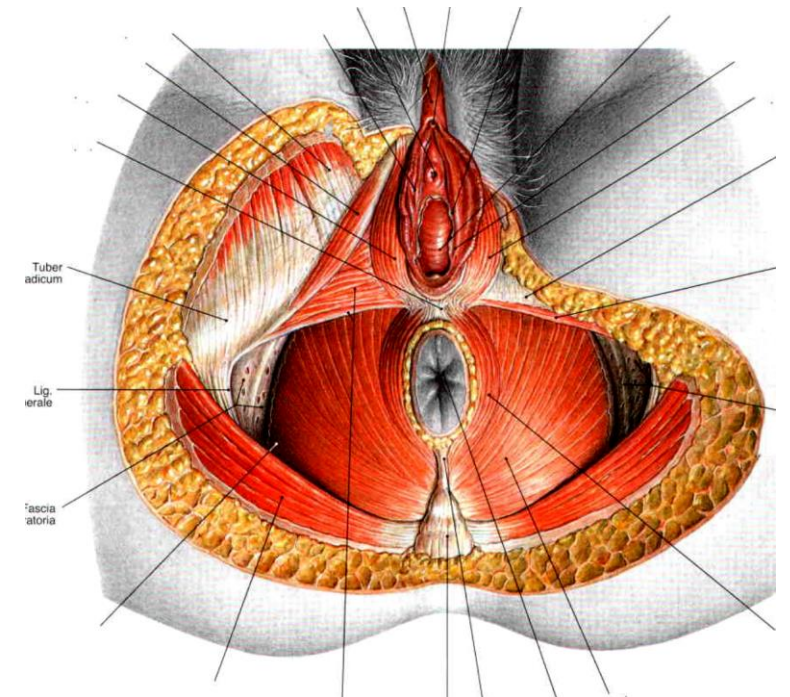


DIAPHRAGMA UROGENITALE

Fascie

Fascia diaphragmatis urogenitalis inferior – vazivová ploténka na spodní ploše musculus transversus perinei profundus.

Fascia diaphragmatis urogenitalis superior – označuje fascii na horní ploše musculus transversus perinei profundus.



Použitá literatura:

Čihák R: Anatomie 2 (Splanchnologia). Avicenum, zdravotnické nakladatelství, Praha, 1988.

Netter F. H.: Interactive Atlas of Clinical Anatomy. Illinois, 1997

Atlas der Anatomie des Menschen/Sobotta.

HUDÁK, Radovan a David KACHLÍK. *Memorix anatomie.*