

A

H

P

F

35

17  
18

7

33

19

26

20

24

25

29

- 1 Medulla spinalis
- 2 Discus intervertebralis
- 3 Spatium subarachnoideum (liquor cerebrospinalis)
- 4 Processus spinosus
- 5 Conus medullaris
- 6 Cauda equina
- 7 Musculus psoas major
- 8 Foramen intervertebrale
- 9 os ilium
- 10 Rectum
- 11 Colon descendens
- 12 Aorta abdominalis
- 13 Processus articularis superior
- 14 Processus articularis inferior
- 15 Truncus coeliacus
- 16 Arteria mesenterica superior
- 17 Arteria renalis sinistra
- 18 Vena renalis sinistra
- 19 Arteria iliaca communis sinistra
- 20 Vena iliaca communis sinistra
- 21 Arteria iliaca communis dextra
- 22 Vena cava inferior
- 23 Vena iliaca communis dextra
- 24 nervus spinalis S1
- 25 nervus spinalis S2
- 26 nervus spinalis L5
- 27 nervus spinalis L4
- 28 myometrium
- 29 uterus
- 30 endometrium
- 31 musculus quadratus lumborum
- 32 musculus iliocostalis
- 33 musculus longissimus dorsi
- 34 musculi spinosiales
- 35 hepar

A

P

F

- 1 Medulla spinalis
- 2 Discus intervertebralis
- 3 Spatium subarachnoideum (liquor cerebrospinalis)
- 4 Processus spinosus
- 5 Conus medullaris
- 6 Cauda equina
- 7 Musculus psoas major
- 8 Foramen intervertebrale
- 9 os ilium
- 10 Rectum
- 11 Colon descendens
- 12 Aorta abdominalis
- 13 Processus articularis superior
- 14 Processus articularis inferior
- 15 Truncus coeliacus
- 16 Arteria mesenterica superior
- 17 Arteria renalis sinistra
- 18 Vena renalis sinistra
- 19 Arteria iliaca communis sinistra
- 20 Vena iliaca communis sinistra
- 21 Arteria iliaca communis dextra
- 22 Vena cava inferior
- 23 Vena iliaca communis dextra
- 24 nervus spinalis S1
- 25 nervus spinalis S2
- 26 nervus spinalis L5
- 27 nervus spinalis L4
- 28 myometrium
- 29 uterus
- 30 endometrium
- 31 musculus quadratus lumborum
- 32 musculus iliocostalis
- 33 musculus longissimus dorsi
- 34 musculi spinospinales
- 35 hepar

A

H

P

F

35

15

12

2

33

8

14

19

13

26

20

L5

S1

24

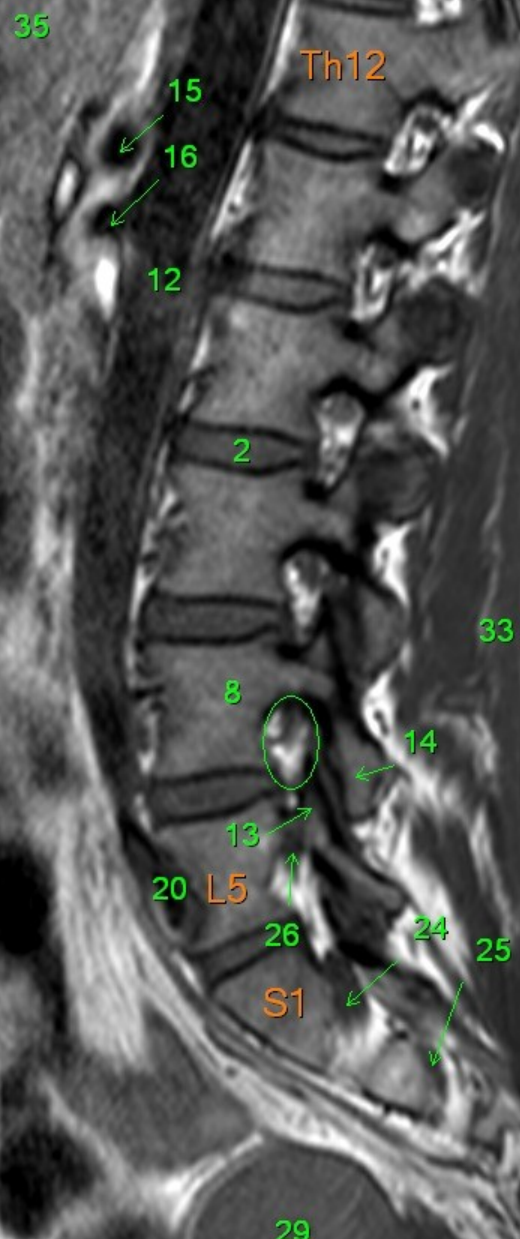
25

29

- 1 Medulla spinalis
- 2 Discus intervertebralis
- 3 Spatium subarachnoideum (liquor cerebrospinalis)
- 4 Processus spinosus
- 5 Conus medullaris
- 6 Cauda equina
- 7 Musculus psoas major
- 8 Foramen intervertebrale
- 9 os ilium
- 10 Rectum
- 11 Colon descendens
- 12 Aorta abdominalis
- 13 Processus articularis superior
- 14 Processus articularis inferior
- 15 Truncus coeliacus
- 16 Arteria mesenterica superior
- 17 Arteria renalis sinistra
- 18 Vena renalis sinistra
- 19 Arteria iliaca communis sinistra
- 20 Vena iliaca communis sinistra
- 21 Arteria iliaca communis dextra
- 22 Vena cava inferior
- 23 Vena iliaca communis dextra
- 24 nervus spinalis S1
- 25 nervus spinalis S2
- 26 nervus spinalis L5
- 27 nervus spinalis L4
- 28 myometrium
- 29 uterus
- 30 endometrium
- 31 musculus quadratus lumborum
- 32 musculus iliocostalis
- 33 musculus longissimus dorsi
- 34 musculi spinospinales
- 35 hepar

A

P

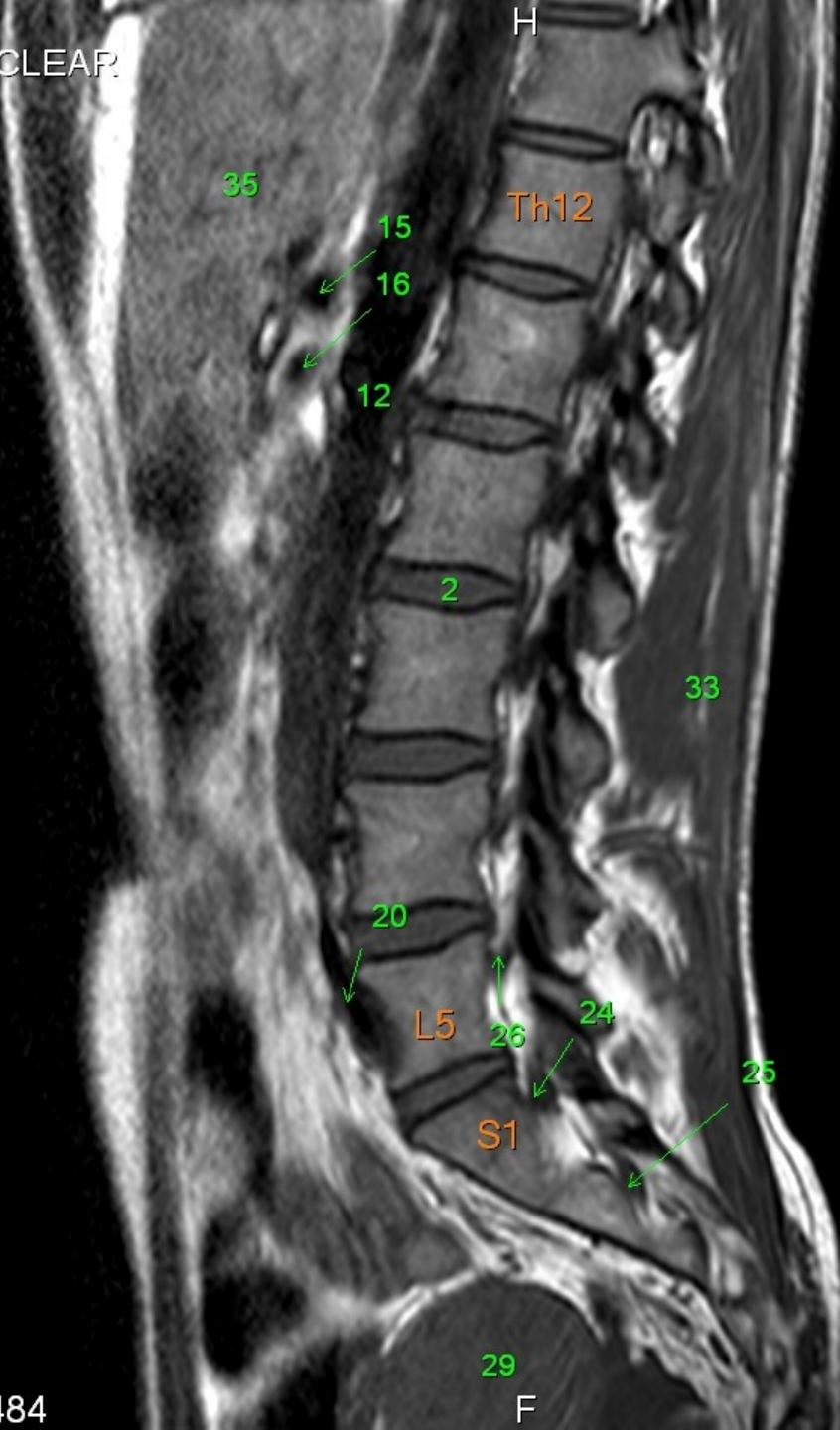


- 1 Medulla spinalis
- 2 Discus intervertebralis
- 3 Spatium subarachnoideum (liquor cerebrospinalis)
- 4 Processus spinosus
- 5 Conus medullaris
- 6 Cauda equina
- 7 Musculus psoas major
- 8 Foramen intervertebrale
- 9 os ilium
- 10 Rectum
- 11 Colon descendens
- 12 Aorta abdominalis
- 13 Processus articularis superior
- 14 Processus articularis inferior
- 15 Truncus coeliacus
- 16 Arteria mesenterica superior
- 17 Arteria renalis sinistra
- 18 Vena renalis sinistra
- 19 Arteria iliaca communis sinistra
- 20 Vena iliaca communis sinistra
- 21 Arteria iliaca communis dextra
- 22 Vena cava inferior
- 23 Vena iliaca communis dextra
- 24 nervus spinalis S1
- 25 nervus spinalis S2
- 26 nervus spinalis L5
- 27 nervus spinalis L4
- 28 myometrium
- 29 uterus
- 30 endometrium
- 31 musculus quadratus lumborum
- 32 musculus iliocostalis
- 33 musculus longissimus dorsi
- 34 musculi spinosiales
- 35 hepar

F

A

P



- 1 Medulla spinalis
- 2 Discus intervertebralis
- 3 Spatium subarachnoideum (liquor cerebrospinalis)
- 4 Processus spinosus
- 5 Conus medullaris
- 6 Cauda equina
- 7 Musculus psoas major
- 8 Foramen intervertebrale
- 9 os ilium
- 10 Rectum
- 11 Colon descendens
- 12 Aorta abdominalis
- 13 Processus articularis superior
- 14 Processus articularis inferior
- 15 Truncus coeliacus
- 16 Arteria mesenterica superior
- 17 Arteria renalis sinistra
- 18 Vena renalis sinistra
- 19 Arteria iliaca communis sinistra
- 20 Vena iliaca communis sinistra
- 21 Arteria iliaca communis dextra
- 22 Vena cava inferior
- 23 Vena iliaca communis dextra
- 24 nervus spinalis S1
- 25 nervus spinalis S2
- 26 nervus spinalis L5
- 27 nervus spinalis L4
- 28 myometrium
- 29 uterus
- 30 endometrium
- 31 musculus quadratus lumborum
- 32 musculus iliocostalis
- 33 musculus longissimus dorsi
- 34 musculi spinospinales
- 35 hepar

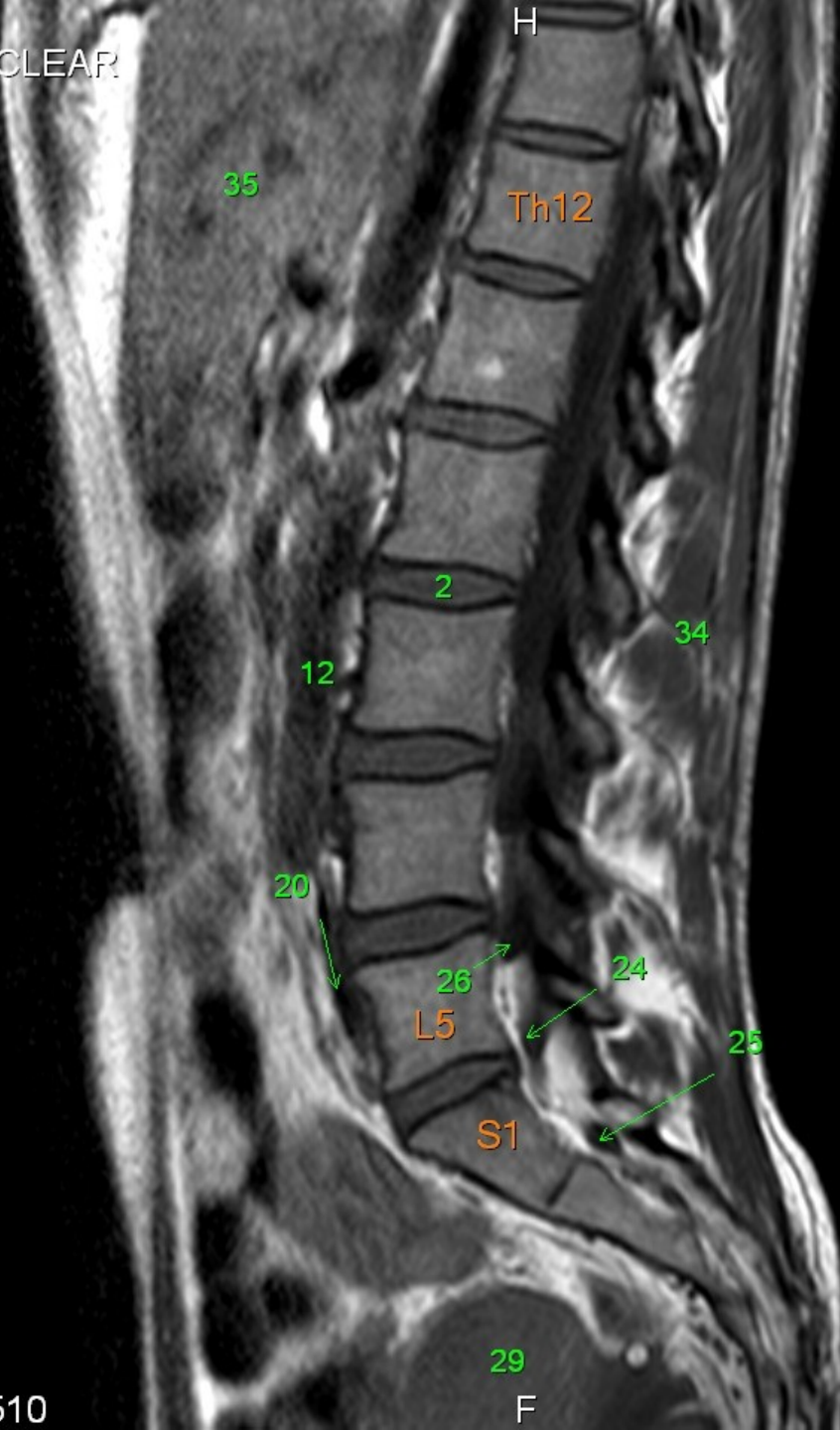
F

A

P

F

- 1 Medulla spinalis
- 2 Discus intervertebralis
- 3 Spatium subarachnoideum (liquor cerebrospinalis)
- 4 Processus spinosus
- 5 Conus medullaris
- 6 Cauda equina
- 7 Musculus psoas major
- 8 Foramen intervertebrale
- 9 os ilium
- 10 Rectum
- 11 Colon descendens
- 12 Aorta abdominalis
- 13 Processus articularis superior
- 14 Processus articularis inferior
- 15 Truncus coeliacus
- 16 Arteria mesenterica superior
- 17 Arteria renalis sinistra
- 18 Vena renalis sinistra
- 19 Arteria iliaca communis sinistra
- 20 Vena iliaca communis sinistra
- 21 Arteria iliaca communis dextra
- 22 Vena cava inferior
- 23 Vena iliaca communis dextra
- 24 nervus spinalis S1
- 25 nervus spinalis S2
- 26 nervus spinalis L5
- 27 nervus spinalis L4
- 28 myometrium
- 29 uterus
- 30 endometrium
- 31 musculus quadratus lumborum
- 32 musculus iliocostalis
- 33 musculus longissimus dorsi
- 34 musculi spinospinales
- 35 hepar



A

P

F

35

Th12

1

3

2

6

21

L5

S1

29

- 1 Medulla spinalis
- 2 Discus intervertebralis
- 3 Spatium subarachnoideum (liquor cerebrospinalis)
- 4 Processus spinosus
- 5 Conus medullaris
- 6 Cauda equina
- 7 Musculus psoas major
- 8 Foramen intervertebrale
- 9 os ilium
- 10 Rectum
- 11 Colon descendens
- 12 Aorta abdominalis
- 13 Processus articularis superior
- 14 Processus articularis inferior
- 15 Truncus coeliacus
- 16 Arteria mesenterica superior
- 17 Arteria renalis sinistra
- 18 Vena renalis sinistra
- 19 Arteria iliaca communis sinistra
- 20 Vena iliaca communis sinistra
- 21 Arteria iliaca communis dextra
- 22 Vena cava inferior
- 23 Vena iliaca communis dextra
- 24 nervus spinalis S1
- 25 nervus spinalis S2
- 26 nervus spinalis L5
- 27 nervus spinalis L4
- 28 myometrium
- 29 uterus
- 30 endometrium
- 31 musculus quadratus lumborum
- 32 musculus iliocostalis
- 33 musculus longissimus dorsi
- 34 musculi spinospinales
- 35 hepar

A

P

F

35

H

1

Th12

5

3

2

4

21

L5

S1

29

- 1 Medulla spinalis
- 2 Discus intervertebralis
- 3 Spatium subarachnoideum (liquor cerebrospinalis)
- 4 Processus spinosus
- 5 Conus medullaris
- 6 Cauda equina
- 7 Musculus psoas major
- 8 Foramen intervertebrale
- 9 os ilium
- 10 Rectum
- 11 Colon descendens
- 12 Aorta abdominalis
- 13 Processus articularis superior
- 14 Processus articularis inferior
- 15 Truncus coeliacus
- 16 Arteria mesenterica superior
- 17 Arteria renalis sinistra
- 18 Vena renalis sinistra
- 19 Arteria iliaca communis sinistra
- 20 Vena iliaca communis sinistra
- 21 Arteria iliaca communis dextra
- 22 Vena cava inferior
- 23 Vena iliaca communis dextra
- 24 nervus spinalis S1
- 25 nervus spinalis S2
- 26 nervus spinalis L5
- 27 nervus spinalis L4
- 28 myometrium
- 29 uterus
- 30 endometrium
- 31 musculus quadratus lumborum
- 32 musculus iliocostalis
- 33 musculus longissimus dorsi
- 34 musculi spinospinales
- 35 hepar

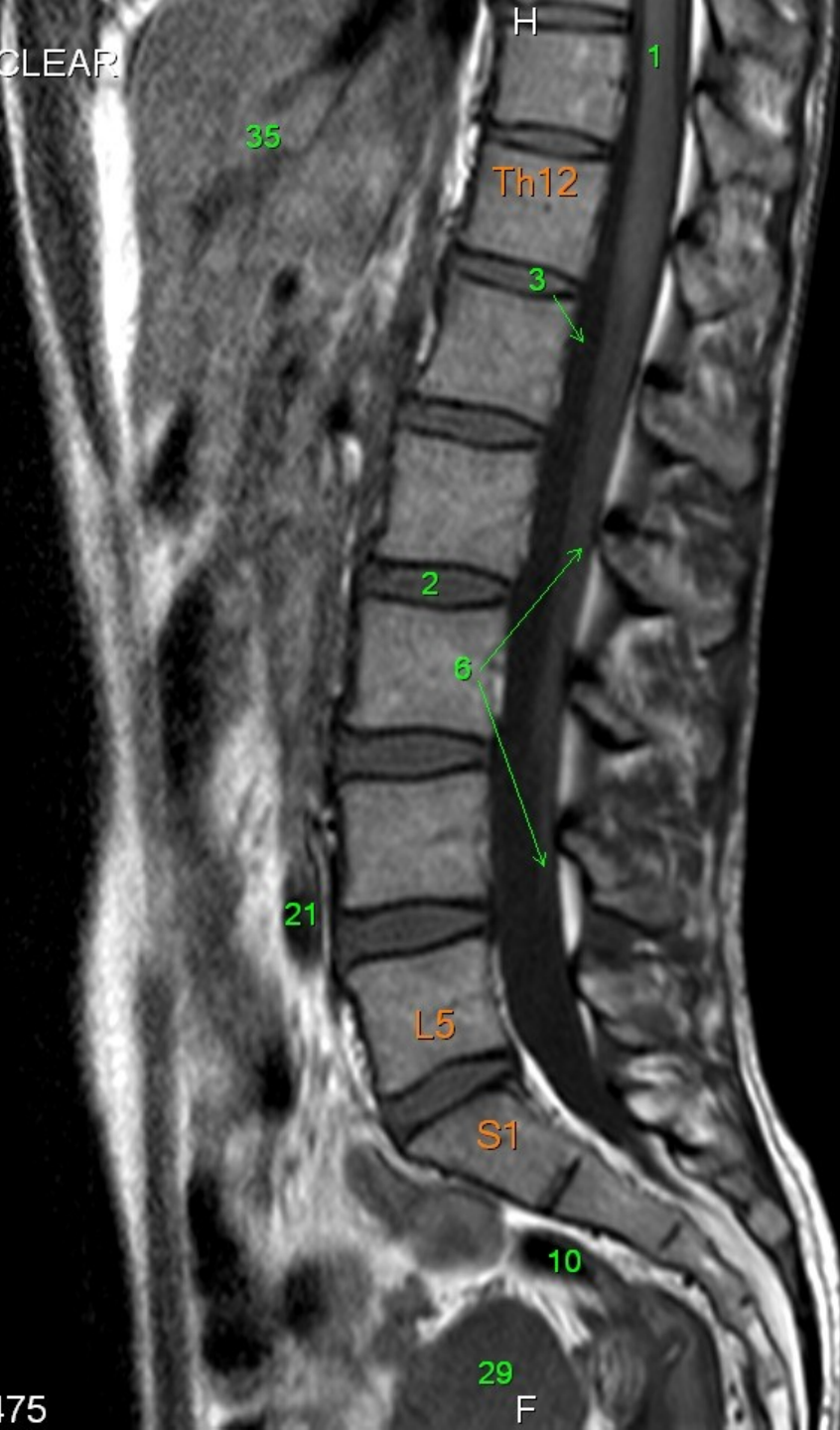


A

P

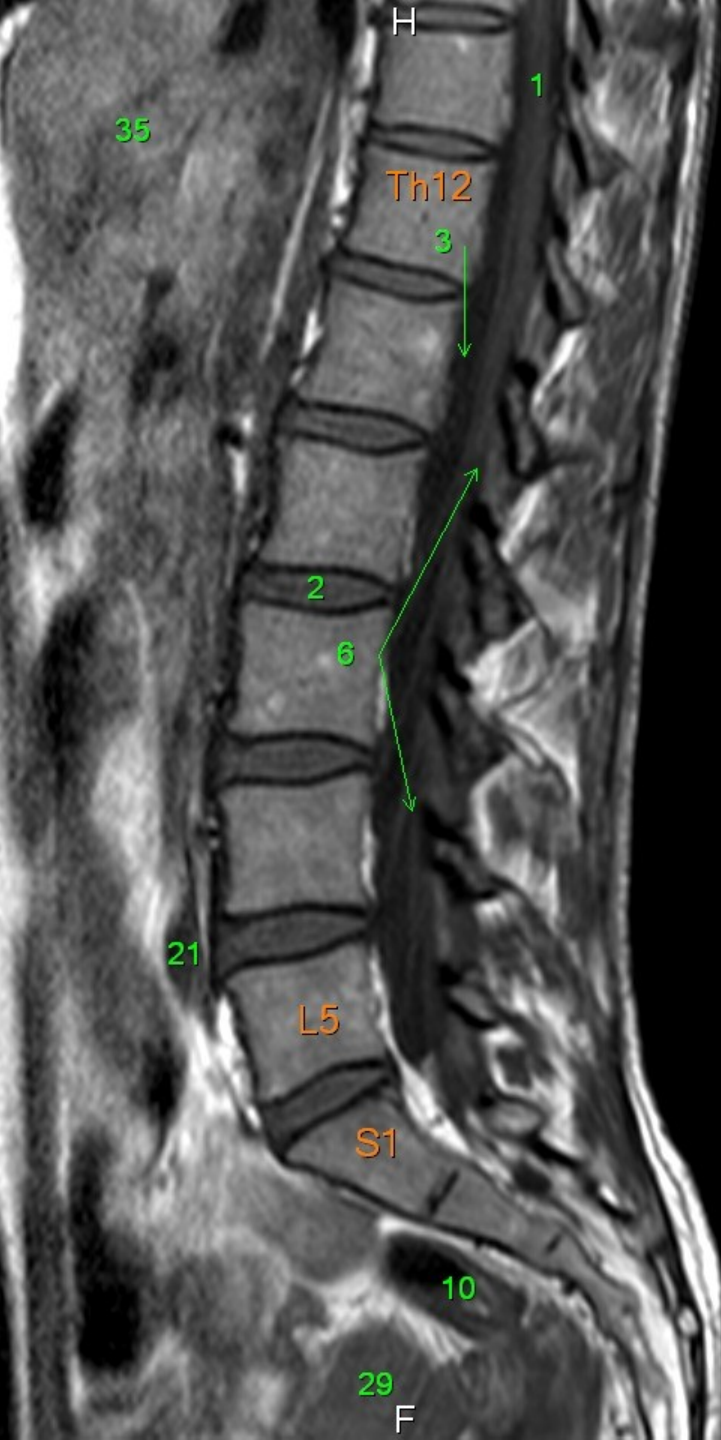F

- 1 Medulla spinalis
- 2 Discus intervertebralis
- 3 Spatium subarachnoideum (liquor cerebrospinalis)
- 4 Processus spinosus
- 5 Conus medullaris
- 6 Cauda equina
- 7 Musculus psoas major
- 8 Foramen intervertebrale
- 9 os ilium
- 10 Rectum
- 11 Colon descendens
- 12 Aorta abdominalis
- 13 Processus articularis superior
- 14 Processus articularis inferior
- 15 Truncus coeliacus
- 16 Arteria mesenterica superior
- 17 Arteria renalis sinistra
- 18 Vena renalis sinistra
- 19 Arteria iliaca communis sinistra
- 20 Vena iliaca communis sinistra
- 21 Arteria iliaca communis dextra
- 22 Vena cava inferior
- 23 Vena iliaca communis dextra
- 24 nervus spinalis S1
- 25 nervus spinalis S2
- 26 nervus spinalis L5
- 27 nervus spinalis L4
- 28 myometrium
- 29 uterus
- 30 endometrium
- 31 musculus quadratus lumborum
- 32 musculus iliocostalis
- 33 musculus longissimus dorsi
- 34 musculi spinospinales
- 35 hepar



A

P

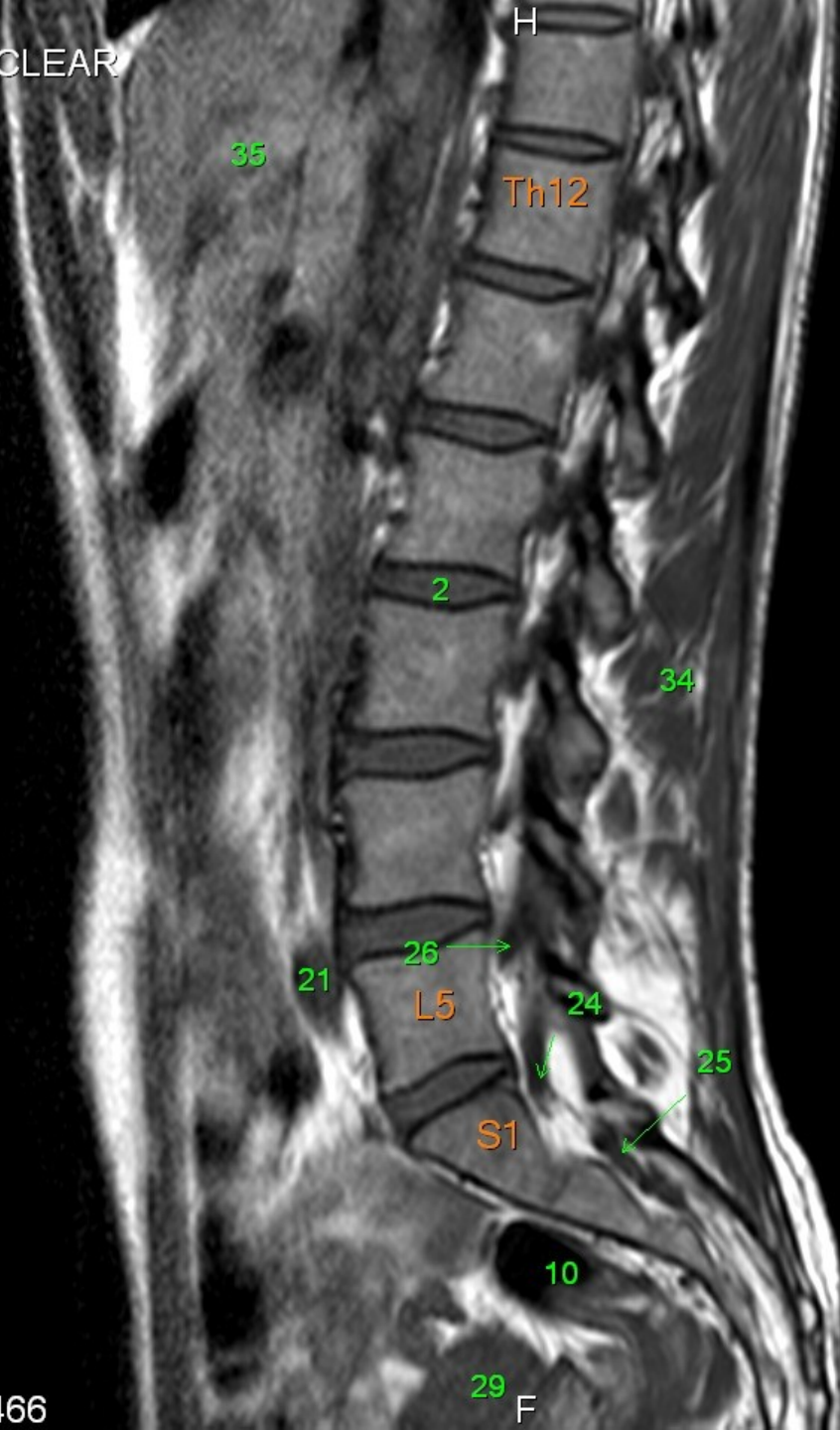


- 1 Medulla spinalis
- 2 Discus intervertebralis
- 3 Spatium subarachnoideum (liquor cerebrospinalis)
- 4 Processus spinosus
- 5 Conus medullaris
- 6 Cauda equina
- 7 Musculus psoas major
- 8 Foramen intervertebrale
- 9 os ilium
- 10 Rectum
- 11 Colon descendens
- 12 Aorta abdominalis
- 13 Processus articularis superior
- 14 Processus articularis inferior
- 15 Truncus coeliacus
- 16 Arteria mesenterica superior
- 17 Arteria renalis sinistra
- 18 Vena renalis sinistra
- 19 Arteria iliaca communis sinistra
- 20 Vena iliaca communis sinistra
- 21 Arteria iliaca communis dextra
- 22 Vena cava inferior
- 23 Vena iliaca communis dextra
- 24 nervus spinalis S1
- 25 nervus spinalis S2
- 26 nervus spinalis L5
- 27 nervus spinalis L4
- 28 myometrium
- 29 uterus
- 30 endometrium
- 31 musculus quadratus lumborum
- 32 musculus iliocostalis
- 33 musculus longissimus dorsi
- 34 musculi spinospinales
- 35 hepar

29  
F

A

P

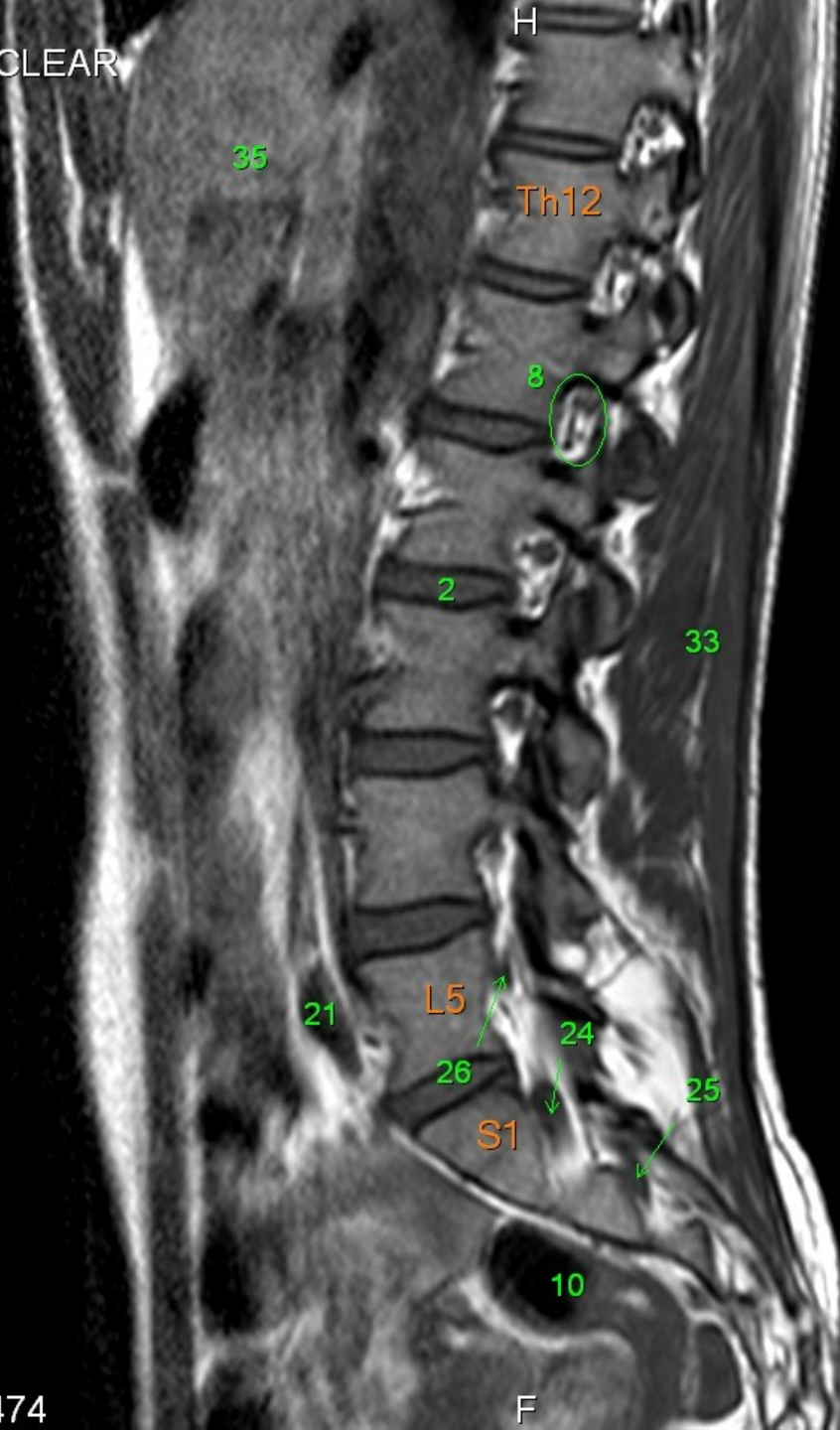

- 1 Medulla spinalis
- 2 Discus intervertebralis
- 3 Spatium subarachnoideum (liquor cerebrospinalis)
- 4 Processus spinosus
- 5 Conus medullaris
- 6 Cauda equina
- 7 Musculus psoas major
- 8 Foramen intervertebrale
- 9 os ilium
- 10 Rectum
- 11 Colon descendens
- 12 Aorta abdominalis
- 13 Processus articularis superior
- 14 Processus articularis inferior
- 15 Truncus coeliacus
- 16 Arteria mesenterica superior
- 17 Arteria renalis sinistra
- 18 Vena renalis sinistra
- 19 Arteria iliaca communis sinistra
- 20 Vena iliaca communis sinistra
- 21 Arteria iliaca communis dextra
- 22 Vena cava inferior
- 23 Vena iliaca communis dextra
- 24 nervus spinalis S1
- 25 nervus spinalis S2
- 26 nervus spinalis L5
- 27 nervus spinalis L4
- 28 myometrium
- 29 uterus
- 30 endometrium
- 31 musculus quadratus lumborum
- 32 musculus iliocostalis
- 33 musculus longissimus dorsi
- 34 musculi spinospinales
- 35 hepar

A

P

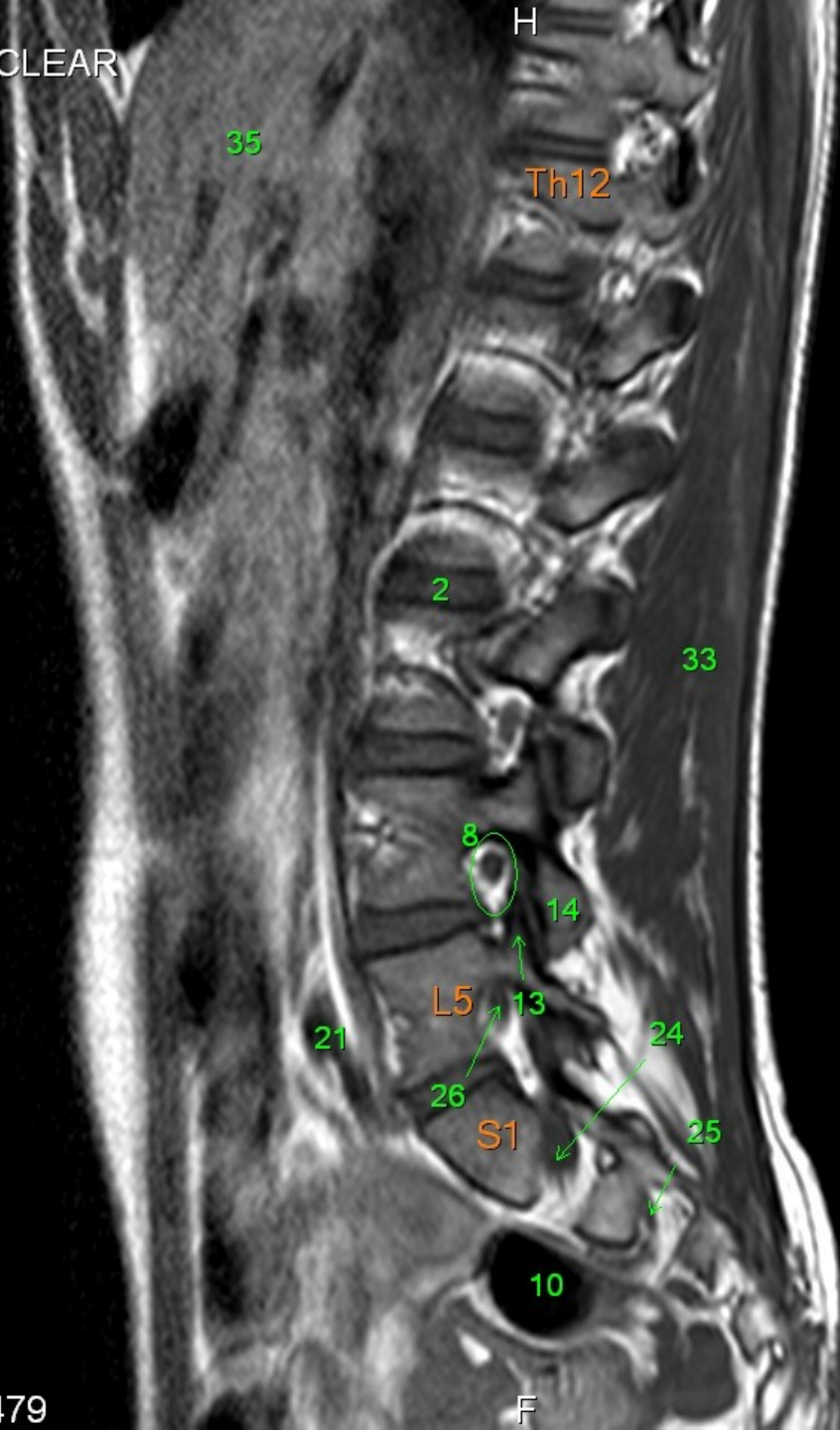F



- 1 Medulla spinalis
- 2 Discus intervertebralis
- 3 Spatium subarachnoideum (liquor cerebrospinalis)
- 4 Processus spinosus
- 5 Conus medullaris
- 6 Cauda equina
- 7 Musculus psoas major
- 8 Foramen intervertebrale
- 9 os ilium
- 10 Rectum
- 11 Colon descendens
- 12 Aorta abdominalis
- 13 Processus articularis superior
- 14 Processus articularis inferior
- 15 Truncus coeliacus
- 16 Arteria mesenterica superior
- 17 Arteria renalis sinistra
- 18 Vena renalis sinistra
- 19 Arteria iliaca communis sinistra
- 20 Vena iliaca communis sinistra
- 21 Arteria iliaca communis dextra
- 22 Vena cava inferior
- 23 Vena iliaca communis dextra
- 24 nervus spinalis S1
- 25 nervus spinalis S2
- 26 nervus spinalis L5
- 27 nervus spinalis L4
- 28 myometrium
- 29 uterus
- 30 endometrium
- 31 musculus quadratus lumborum
- 32 musculus iliocostalis
- 33 musculus longissimus dorsi
- 34 musculi spinospinales
- 35 hepar

A

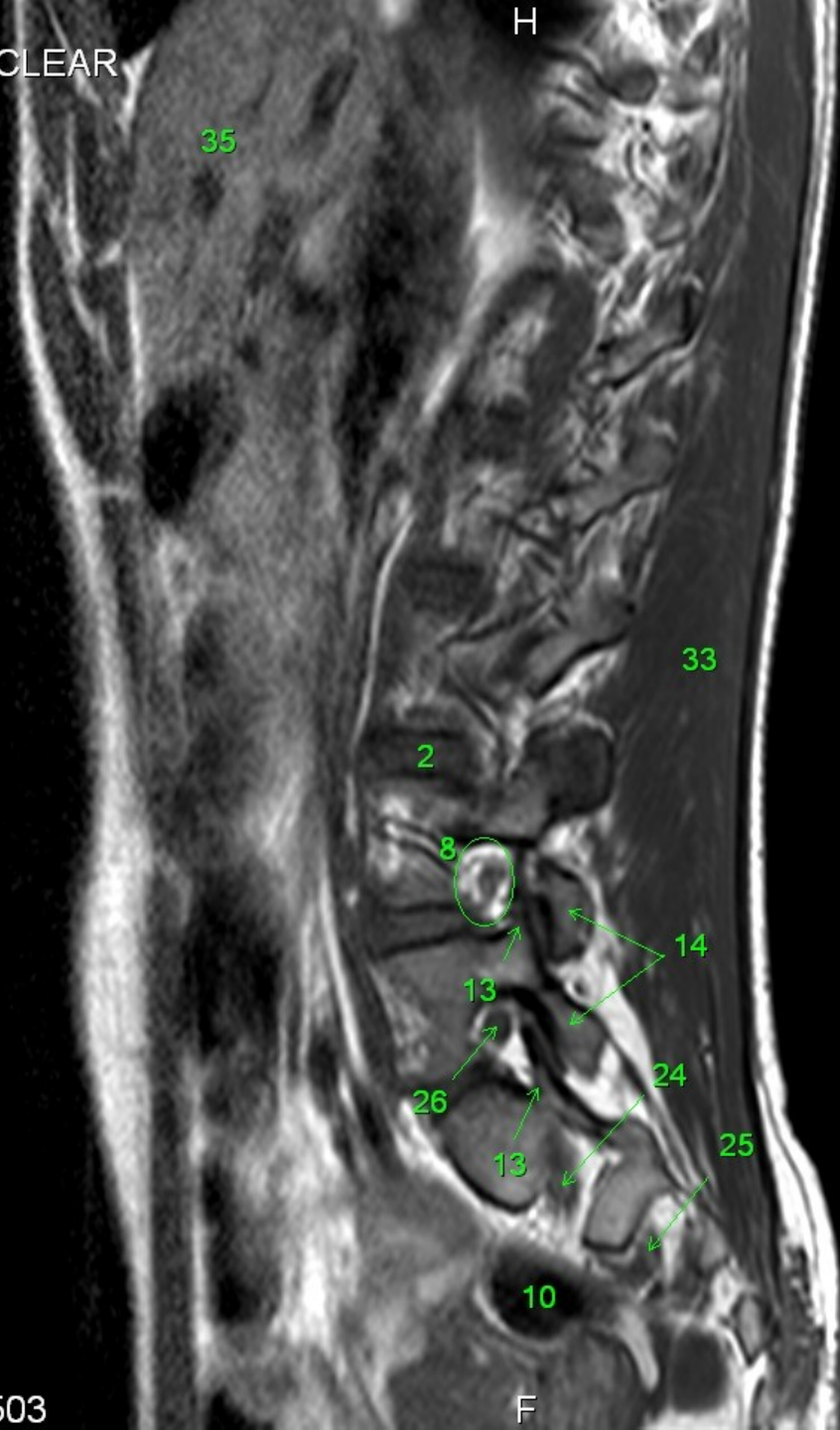P



- 1 Medulla spinalis
- 2 Discus intervertebralis
- 3 Spatium subarachnoideum (liquor cerebrospinalis)
- 4 Processus spinosus
- 5 Conus medullaris
- 6 Cauda equina
- 7 Musculus psoas major
- 8 Foramen intervertebrale
- 9 os ilium
- 10 Rectum
- 11 Colon descendens
- 12 Aorta abdominalis
- 13 Processus articularis superior
- 14 Processus articularis inferior
- 15 Truncus coeliacus
- 16 Arteria mesenterica superior
- 17 Arteria renalis sinistra
- 18 Vena renalis sinistra
- 19 Arteria iliaca communis sinistra
- 20 Vena iliaca communis sinistra
- 21 Arteria iliaca communis dextra
- 22 Vena cava inferior
- 23 Vena iliaca communis dextra
- 24 nervus spinalis S1
- 25 nervus spinalis S2
- 26 nervus spinalis L5
- 27 nervus spinalis L4
- 28 myometrium
- 29 uterus
- 30 endometrium
- 31 musculus quadratus lumborum
- 32 musculus iliocostalis
- 33 musculus longissimus dorsi
- 34 musculi spinospinales
- 35 hepar

F

A



- 1 Medulla spinalis
- 2 Discus intervertebralis
- 3 Spatium subarachnoideum (liquor cerebrospinalis)
- 4 Processus spinosus
- 5 Conus medullaris
- 6 Cauda equina
- 7 Musculus psoas major
- 8 Foramen intervertebrale
- 9 os ilium
- 10 Rectum
- 11 Colon descendens
- 12 Aorta abdominalis
- 13 Processus articularis superior
- 14 Processus articularis inferior
- 15 Truncus coeliacus
- 16 Arteria mesenterica superior
- 17 Arteria renalis sinistra
- 18 Vena renalis sinistra
- 19 Arteria iliaca communis sinistra
- 20 Vena iliaca communis sinistra
- 21 Arteria iliaca communis dextra
- 22 Vena cava inferior
- 23 Vena iliaca communis dextra
- 24 nervus spinalis S1
- 25 nervus spinalis S2
- 26 nervus spinalis L5
- 27 nervus spinalis L4
- 28 myometrium
- 29 uterus
- 30 endometrium
- 31 musculus quadratus lumborum
- 32 musculus iliocostalis
- 33 musculus longissimus dorsi
- 34 musculi spinospinales
- 35 hepar

P

F

A

P

F

35

22

7

33

2

26

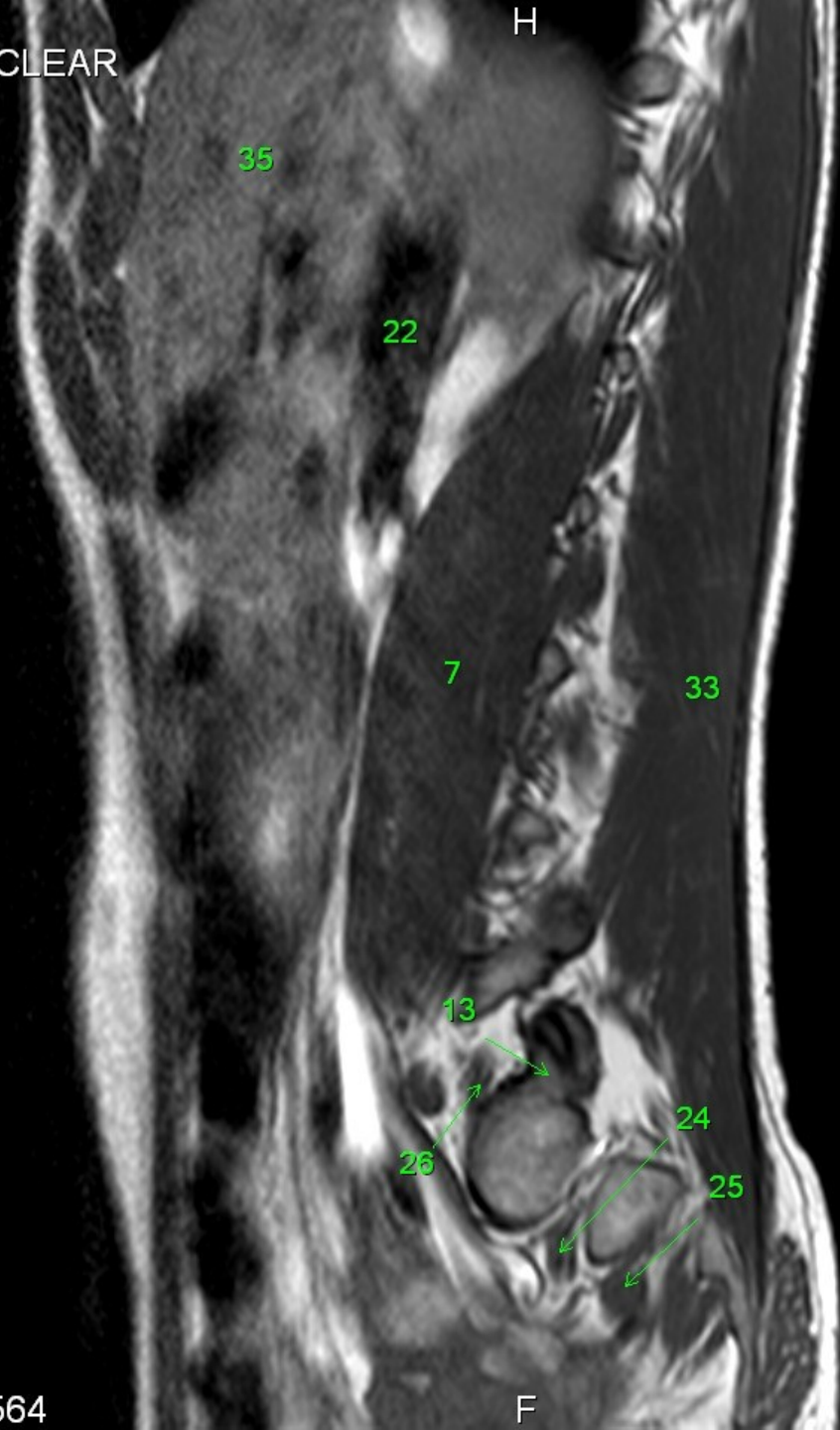
24

25

10

- 1 Medulla spinalis
- 2 Discus intervertebralis
- 3 Spatium subarachnoideum (liquor cerebrospinalis)
- 4 Processus spinosus
- 5 Conus medullaris
- 6 Cauda equina
- 7 Musculus psoas major
- 8 Foramen intervertebrale
- 9 os ilium
- 10 Rectum
- 11 Colon descendens
- 12 Aorta abdominalis
- 13 Processus articularis superior
- 14 Processus articularis inferior
- 15 Truncus coeliacus
- 16 Arteria mesenterica superior
- 17 Arteria renalis sinistra
- 18 Vena renalis sinistra
- 19 Arteria iliaca communis sinistra
- 20 Vena iliaca communis sinistra
- 21 Arteria iliaca communis dextra
- 22 Vena cava inferior
- 23 Vena iliaca communis dextra
- 24 nervus spinalis S1
- 25 nervus spinalis S2
- 26 nervus spinalis L5
- 27 nervus spinalis L4
- 28 myometrium
- 29 uterus
- 30 endometrium
- 31 musculus quadratus lumborum
- 32 musculus iliocostalis
- 33 musculus longissimus dorsi
- 34 musculi spinospinales
- 35 hepar

A



- P
- 1 Medulla spinalis
  - 2 Discus intervertebralis
  - 3 Spatium subarachnoideum (liquor cerebrospinalis)
  - 4 Processus spinosus
  - 5 Conus medullaris
  - 6 Cauda equina
  - 7 Musculus psoas major
  - 8 Foramen intervertebrale
  - 9 os ilium
  - 10 Rectum
  - 11 Colon descendens
  - 12 Aorta abdominalis
  - 13 Processus articularis superior
  - 14 Processus articularis inferior
  - 15 Truncus coeliacus
  - 16 Arteria mesenterica superior
  - 17 Arteria renalis sinistra
  - 18 Vena renalis sinistra
  - 19 Arteria iliaca communis sinistra
  - 20 Vena iliaca communis sinistra
  - 21 Arteria iliaca communis dextra
  - 22 Vena cava inferior
  - 23 Vena iliaca communis dextra
  - 24 nervus spinalis S1
  - 25 nervus spinalis S2
  - 26 nervus spinalis L5
  - 27 nervus spinalis L4
  - 28 myometrium
  - 29 uterus
  - 30 endometrium
  - 31 musculus quadratus lumborum
  - 32 musculus iliocostalis
  - 33 musculus longissimus dorsi
  - 34 musculi spinospinales
  - 35 hepar

F



A

P

F

35

18

17

7

33

19

20

24

28

30

- 1 Medulla spinalis
- 2 Discus intervertebralis
- 3 Spatium subarachnoideum (liquor cerebrospinalis)
- 4 Processus spinosus
- 5 Conus medullaris
- 6 Cauda equina
- 7 Musculus psoas major
- 8 Foramen intervertebrale
- 9 os ilium
- 10 Rectum
- 11 Colon descendens
- 12 Aorta abdominalis
- 13 Processus articularis superior
- 14 Processus articularis inferior
- 15 Truncus coeliacus
- 16 Arteria mesenterica superior
- 17 Arteria renalis sinistra
- 18 Vena renalis sinistra
- 19 Arteria iliaca communis sinistra
- 20 Vena iliaca communis sinistra
- 21 Arteria iliaca communis dextra
- 22 Vena cava inferior
- 23 Vena iliaca communis dextra
- 24 nervus spinalis S1
- 25 nervus spinalis S2
- 26 nervus spinalis L5
- 27 nervus spinalis L4
- 28 myometrium
- 29 uterus
- 30 endometrium
- 31 musculus quadratus lumborum
- 32 musculus iliocostalis
- 33 musculus longissimus dorsi
- 34 musculi spinospinales
- 35 hepar

A

P

F

- 1 Medulla spinalis
- 2 Discus intervertebralis
- 3 Spatium subarachnoideum (liquor cerebrospinalis)
- 4 Processus spinosus
- 5 Conus medullaris
- 6 Cauda equina
- 7 Musculus psoas major
- 8 Foramen intervertebrale
- 9 os ilium
- 10 Rectum
- 11 Colon descendens
- 12 Aorta abdominalis
- 13 Processus articularis superior
- 14 Processus articularis inferior
- 15 Truncus coeliacus
- 16 Arteria mesenterica superior
- 17 Arteria renalis sinistra
- 18 Vena renalis sinistra
- 19 Arteria iliaca communis sinistra
- 20 Vena iliaca communis sinistra
- 21 Arteria iliaca communis dextra
- 22 Vena cava inferior
- 23 Vena iliaca communis dextra
- 24 nervus spinalis S1
- 25 nervus spinalis S2
- 26 nervus spinalis L5
- 27 nervus spinalis L4
- 28 myometrium
- 29 uterus
- 30 endometrium
- 31 musculus quadratus lumborum
- 32 musculus iliocostalis
- 33 musculus longissimus dorsi
- 34 musculi spinospinales
- 35 hepar

35

18

2

33

26

19

20

24

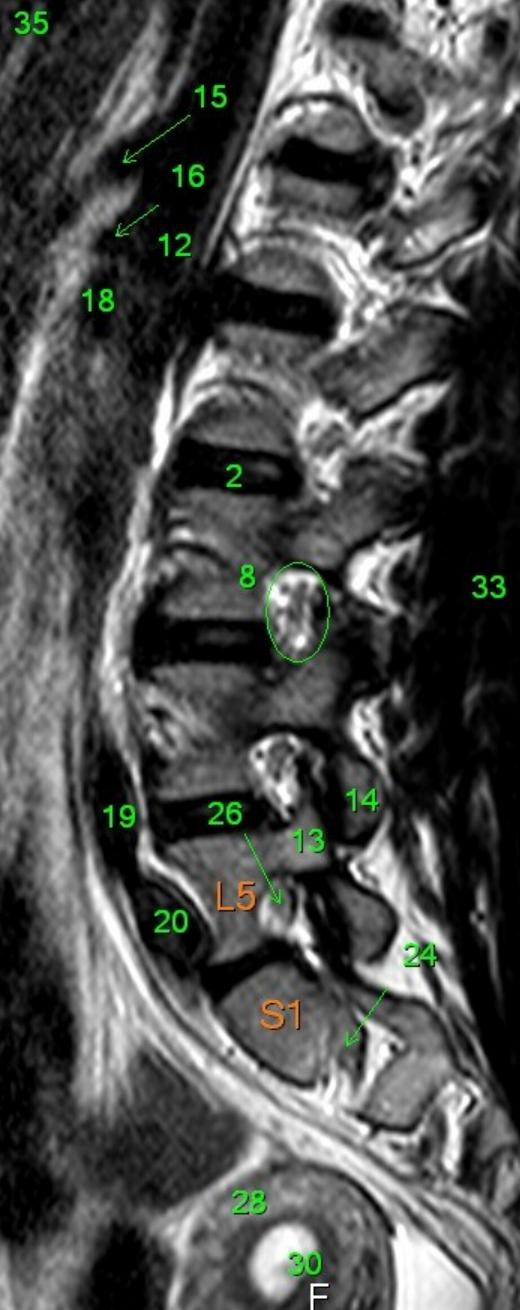
28

30

H

A

P

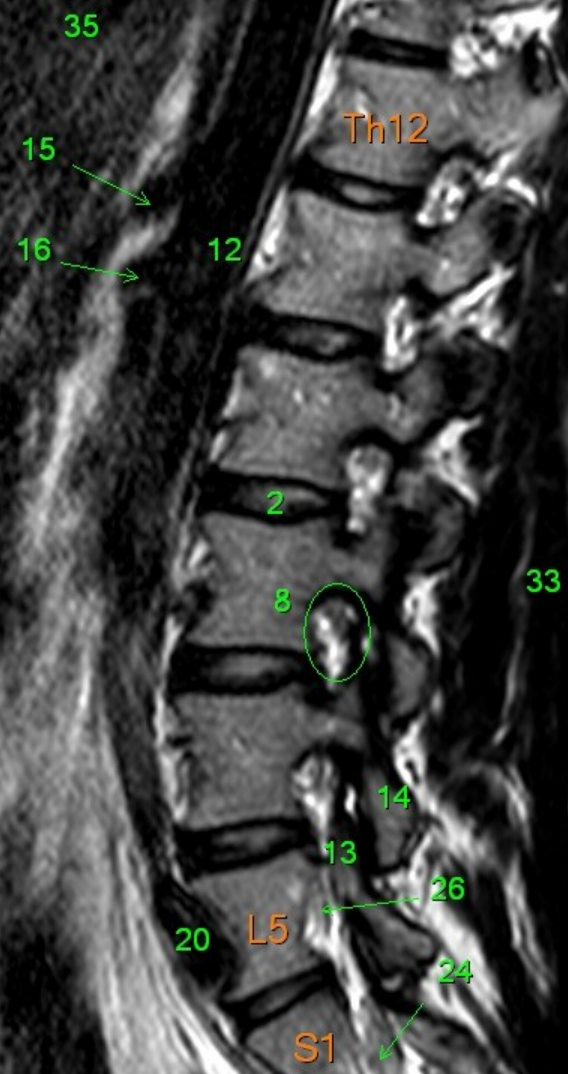


- 1 Medulla spinalis
- 2 Discus intervertebralis
- 3 Spatium subarachnoideum (liquor cerebrospinalis)
- 4 Processus spinosus
- 5 Conus medullaris
- 6 Cauda equina
- 7 Musculus psoas major
- 8 Foramen intervertebrale
- 9 os ilium
- 10 Rectum
- 11 Colon descendens
- 12 Aorta abdominalis
- 13 Processus articularis superior
- 14 Processus articularis inferior
- 15 Truncus coeliacus
- 16 Arteria mesenterica superior
- 17 Arteria renalis sinistra
- 18 Vena renalis sinistra
- 19 Arteria iliaca communis sinistra
- 20 Vena iliaca communis sinistra
- 21 Arteria iliaca communis dextra
- 22 Vena cava inferior
- 23 Vena iliaca communis dextra
- 24 nervus spinalis S1
- 25 nervus spinalis S2
- 26 nervus spinalis L5
- 27 nervus spinalis L4
- 28 myometrium
- 29 uterus
- 30 endometrium
- 31 musculus quadratus lumborum
- 32 musculus iliocostalis
- 33 musculus longissimus dorsi
- 34 musculi spinospinales
- 35 hepar

F

A

P

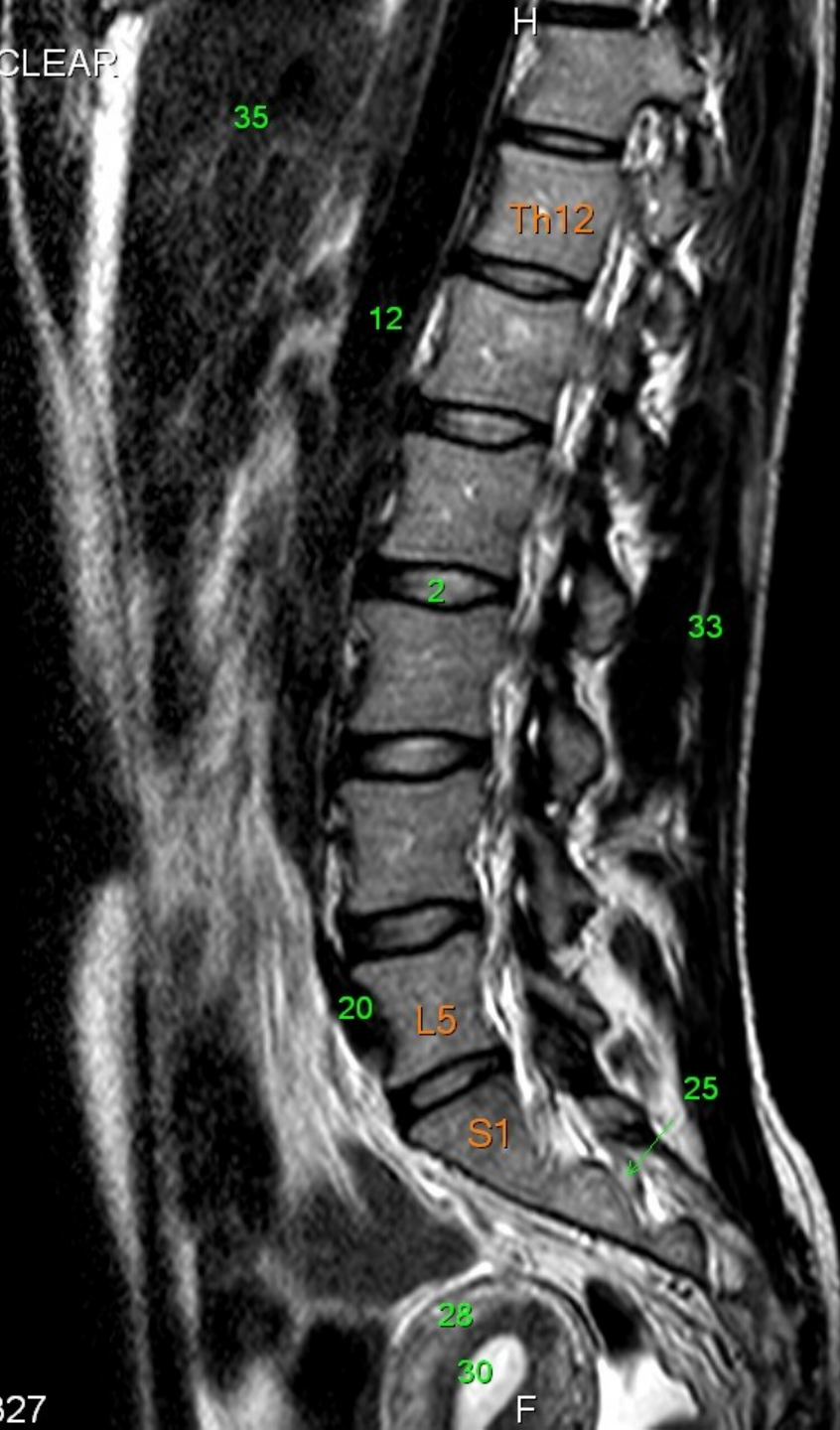


- 1 Medulla spinalis
- 2 Discus intervertebralis
- 3 Spatium subarachnoideum (liquor cerebrospinalis)
- 4 Processus spinosus
- 5 Conus medullaris
- 6 Cauda equina
- 7 Musculus psoas major
- 8 Foramen intervertebrale
- 9 os ilium
- 10 Rectum
- 11 Colon descendens
- 12 Aorta abdominalis
- 13 Processus articularis superior
- 14 Processus articularis inferior
- 15 Truncus coeliacus
- 16 Arteria mesenterica superior
- 17 Arteria renalis sinistra
- 18 Vena renalis sinistra
- 19 Arteria iliaca communis sinistra
- 20 Vena iliaca communis sinistra
- 21 Arteria iliaca communis dextra
- 22 Vena cava inferior
- 23 Vena iliaca communis dextra
- 24 nervus spinalis S1
- 25 nervus spinalis S2
- 26 nervus spinalis L5
- 27 nervus spinalis L4
- 28 myometrium
- 29 uterus
- 30 endometrium
- 31 musculus quadratus lumborum
- 32 musculus iliocostalis
- 33 musculus longissimus dorsi
- 34 musculi spinospinales
- 35 hepar

F

A

P

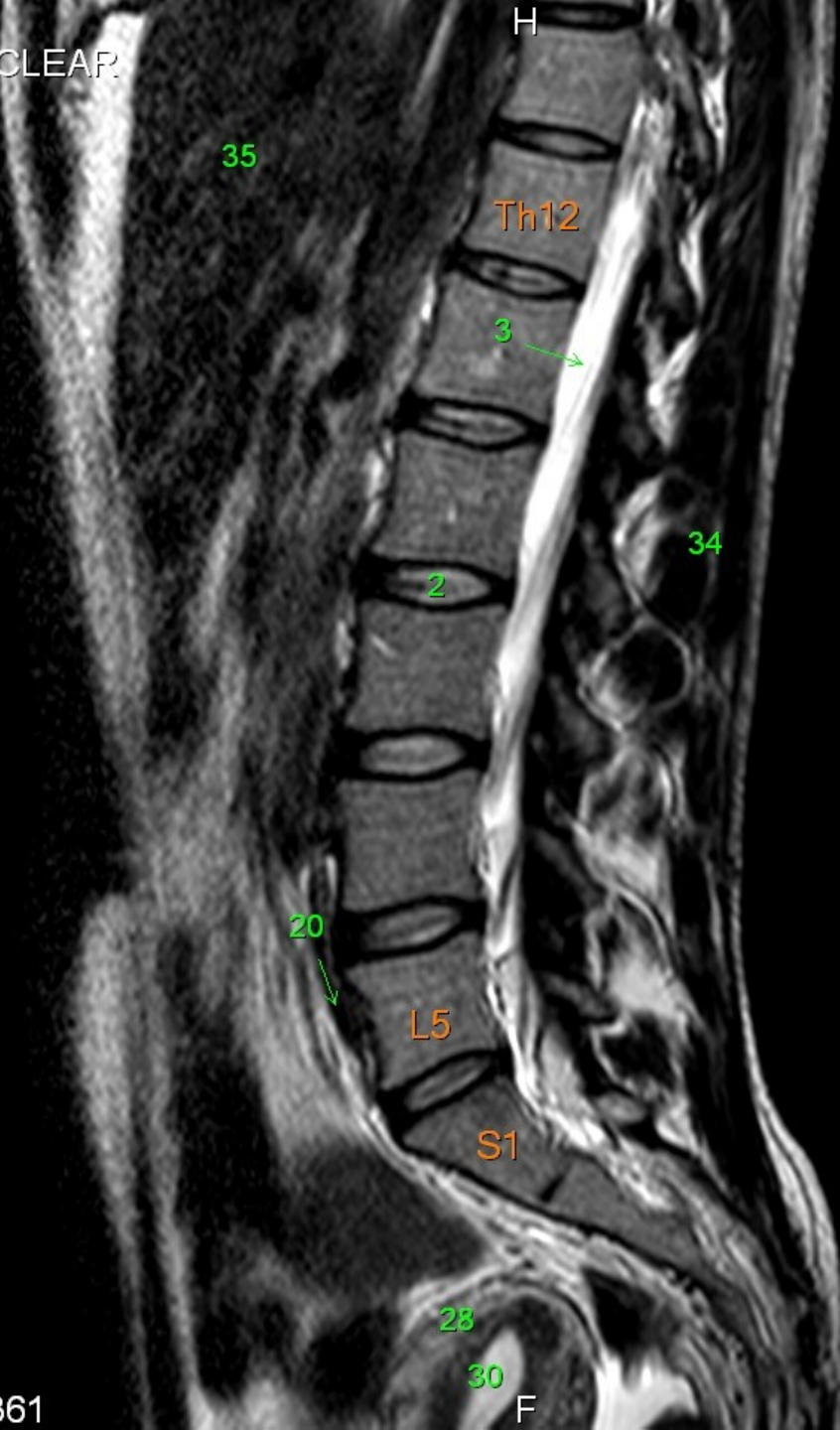

- 1 Medulla spinalis
- 2 Discus intervertebralis
- 3 Spatium subarachnoideum (liquor cerebrospinalis)
- 4 Processus spinosus
- 5 Conus medullaris
- 6 Cauda equina
- 7 Musculus psoas major
- 8 Foramen intervertebrale
- 9 os ilium
- 10 Rectum
- 11 Colon descendens
- 12 Aorta abdominalis
- 13 Processus articularis superior
- 14 Processus articularis inferior
- 15 Truncus coeliacus
- 16 Arteria mesenterica superior
- 17 Arteria renalis sinistra
- 18 Vena renalis sinistra
- 19 Arteria iliaca communis sinistra
- 20 Vena iliaca communis sinistra
- 21 Arteria iliaca communis dextra
- 22 Vena cava inferior
- 23 Vena iliaca communis dextra
- 24 nervus spinalis S1
- 25 nervus spinalis S2
- 26 nervus spinalis L5
- 27 nervus spinalis L4
- 28 myometrium
- 29 uterus
- 30 endometrium
- 31 musculus quadratus lumborum
- 32 musculus iliocostalis
- 33 musculus longissimus dorsi
- 34 musculi spinospinales
- 35 hepar

F

A

P



- 1 Medulla spinalis
- 2 Discus intervertebralis
- 3 Spatium subarachnoideum (liquor cerebrospinalis)
- 4 Processus spinosus
- 5 Conus medullaris
- 6 Cauda equina
- 7 Musculus psoas major
- 8 Foramen intervertebrale
- 9 os ilium
- 10 Rectum
- 11 Colon descendens
- 12 Aorta abdominalis
- 13 Processus articularis superior
- 14 Processus articularis inferior
- 15 Truncus coeliacus
- 16 Arteria mesenterica superior
- 17 Arteria renalis sinistra
- 18 Vena renalis sinistra
- 19 Arteria iliaca communis sinistra
- 20 Vena iliaca communis sinistra
- 21 Arteria iliaca communis dextra
- 22 Vena cava inferior
- 23 Vena iliaca communis dextra
- 24 nervus spinalis S1
- 25 nervus spinalis S2
- 26 nervus spinalis L5
- 27 nervus spinalis L4
- 28 myometrium
- 29 uterus
- 30 endometrium
- 31 musculus quadratus lumborum
- 32 musculus iliocostalis
- 33 musculus longissimus dorsi
- 34 musculi spinospinales
- 35 hepar

F

A

P

F

35

Th12

3

2

6

21

L5

S1

28

30

- 1 Medulla spinalis
- 2 Discus intervertebralis
- 3 Spatium subarachnoideum (liquor cerebrospinalis)
- 4 Processus spinosus
- 5 Conus medullaris
- 6 Cauda equina
- 7 Musculus psoas major
- 8 Foramen intervertebrale
- 9 os ilium
- 10 Rectum
- 11 Colon descendens
- 12 Aorta abdominalis
- 13 Processus articularis superior
- 14 Processus articularis inferior
- 15 Truncus coeliacus
- 16 Arteria mesenterica superior
- 17 Arteria renalis sinistra
- 18 Vena renalis sinistra
- 19 Arteria iliaca communis sinistra
- 20 Vena iliaca communis sinistra
- 21 Arteria iliaca communis dextra
- 22 Vena cava inferior
- 23 Vena iliaca communis dextra
- 24 nervus spinalis S1
- 25 nervus spinalis S2
- 26 nervus spinalis L5
- 27 nervus spinalis L4
- 28 myometrium
- 29 uterus
- 30 endometrium
- 31 musculus quadratus lumborum
- 32 musculus iliocostalis
- 33 musculus longissimus dorsi
- 34 musculi spinospinales
- 35 hepar

A

P

F

- 1 Medulla spinalis
- 2 Discus intervertebralis
- 3 Spatium subarachnoideum (liquor cerebrospinalis)
- 4 Processus spinosus
- 5 Conus medullaris
- 6 Cauda equina
- 7 Musculus psoas major
- 8 Foramen intervertebrale
- 9 os ilium
- 10 Rectum
- 11 Colon descendens
- 12 Aorta abdominalis
- 13 Processus articularis superior
- 14 Processus articularis inferior
- 15 Truncus coeliacus
- 16 Arteria mesenterica superior
- 17 Arteria renalis sinistra
- 18 Vena renalis sinistra
- 19 Arteria iliaca communis sinistra
- 20 Vena iliaca communis sinistra
- 21 Arteria iliaca communis dextra
- 22 Vena cava inferior
- 23 Vena iliaca communis dextra
- 24 nervus spinalis S1
- 25 nervus spinalis S2
- 26 nervus spinalis L5
- 27 nervus spinalis L4
- 28 myometrium
- 29 uterus
- 30 endometrium
- 31 musculus quadratus lumborum
- 32 musculus iliocostalis
- 33 musculus longissimus dorsi
- 34 musculi spinospinales
- 35 hepar

35

Th12

3

2

4

21

20

L5

S1

28

F



A

P

F

35

Th12

L5

S1

21

20

10

28

1

3

2

6

- 1 Medulla spinalis
- 2 Discus intervertebralis
- 3 Spatium subarachnoideum (liquor cerebrospinalis)
- 4 Processus spinosus
- 5 Conus medullaris
- 6 Cauda equina
- 7 Musculus psoas major
- 8 Foramen intervertebrale
- 9 os ilium
- 10 Rectum
- 11 Colon descendens
- 12 Aorta abdominalis
- 13 Processus articularis superior
- 14 Processus articularis inferior
- 15 Truncus coeliacus
- 16 Arteria mesenterica superior
- 17 Arteria renalis sinistra
- 18 Vena renalis sinistra
- 19 Arteria iliaca communis sinistra
- 20 Vena iliaca communis sinistra
- 21 Arteria iliaca communis dextra
- 22 Vena cava inferior
- 23 Vena iliaca communis dextra
- 24 nervus spinalis S1
- 25 nervus spinalis S2
- 26 nervus spinalis L5
- 27 nervus spinalis L4
- 28 myometrium
- 29 uterus
- 30 endometrium
- 31 musculus quadratus lumborum
- 32 musculus iliocostalis
- 33 musculus longissimus dorsi
- 34 musculi spinospinales
- 35 hepar

A

P

35

H

Th12

1

3

2

6

20

21

L5

S1

10

28

F

- 1 Medulla spinalis
- 2 Discus intervertebralis
- 3 Spatium subarachnoideum (liquor cerebrospinalis)
- 4 Processus spinosus
- 5 Conus medullaris
- 6 Cauda equina
- 7 Musculus psoas major
- 8 Foramen intervertebrale
- 9 os ilium
- 10 Rectum
- 11 Colon descendens
- 12 Aorta abdominalis
- 13 Processus articularis superior
- 14 Processus articularis inferior
- 15 Truncus coeliacus
- 16 Arteria mesenterica superior
- 17 Arteria renalis sinistra
- 18 Vena renalis sinistra
- 19 Arteria iliaca communis sinistra
- 20 Vena iliaca communis sinistra
- 21 Arteria iliaca communis dextra
- 22 Vena cava inferior
- 23 Vena iliaca communis dextra
- 24 nervus spinalis S1
- 25 nervus spinalis S2
- 26 nervus spinalis L5
- 27 nervus spinalis L4
- 28 myometrium
- 29 uterus
- 30 endometrium
- 31 musculus quadratus lumborum
- 32 musculus iliocostalis
- 33 musculus longissimus dorsi
- 34 musculi spinospinales
- 35 hepar

A

P

F

35

Th12

2

34

21

L5

25

S1

10

- 1 Medulla spinalis
- 2 Discus intervertebralis
- 3 Spatium subarachnoideum (liquor cerebrospinalis)
- 4 Processus spinosus
- 5 Conus medullaris
- 6 Cauda equina
- 7 Musculus psoas major
- 8 Foramen intervertebrale
- 9 os ilium
- 10 Rectum
- 11 Colon descendens
- 12 Aorta abdominalis
- 13 Processus articularis superior
- 14 Processus articularis inferior
- 15 Truncus coeliacus
- 16 Arteria mesenterica superior
- 17 Arteria renalis sinistra
- 18 Vena renalis sinistra
- 19 Arteria iliaca communis sinistra
- 20 Vena iliaca communis sinistra
- 21 Arteria iliaca communis dextra
- 22 Vena cava inferior
- 23 Vena iliaca communis dextra
- 24 nervus spinalis S1
- 25 nervus spinalis S2
- 26 nervus spinalis L5
- 27 nervus spinalis L4
- 28 myometrium
- 29 uterus
- 30 endometrium
- 31 musculus quadratus lumborum
- 32 musculus iliocostalis
- 33 musculus longissimus dorsi
- 34 musculi spinospinales
- 35 hepar

A

P

35

Th12

8

33

21

L5

S1

10

F

- 1 Medulla spinalis
- 2 Discus intervertebralis
- 3 Spatium subarachnoideum (liquor cerebrospinalis)
- 4 Processus spinosus
- 5 Conus medullaris
- 6 Cauda equina
- 7 Musculus psoas major
- 8 Foramen intervertebrale
- 9 os ilium
- 10 Rectum
- 11 Colon descendens
- 12 Aorta abdominalis
- 13 Processus articularis superior
- 14 Processus articularis inferior
- 15 Truncus coeliacus
- 16 Arteria mesenterica superior
- 17 Arteria renalis sinistra
- 18 Vena renalis sinistra
- 19 Arteria iliaca communis sinistra
- 20 Vena iliaca communis sinistra
- 21 Arteria iliaca communis dextra
- 22 Vena cava inferior
- 23 Vena iliaca communis dextra
- 24 nervus spinalis S1
- 25 nervus spinalis S2
- 26 nervus spinalis L5
- 27 nervus spinalis L4
- 28 myometrium
- 29 uterus
- 30 endometrium
- 31 musculus quadratus lumborum
- 32 musculus iliocostalis
- 33 musculus longissimus dorsi
- 34 musculi spinospinales
- 35 hepar

A

P

35

Th12

8

33

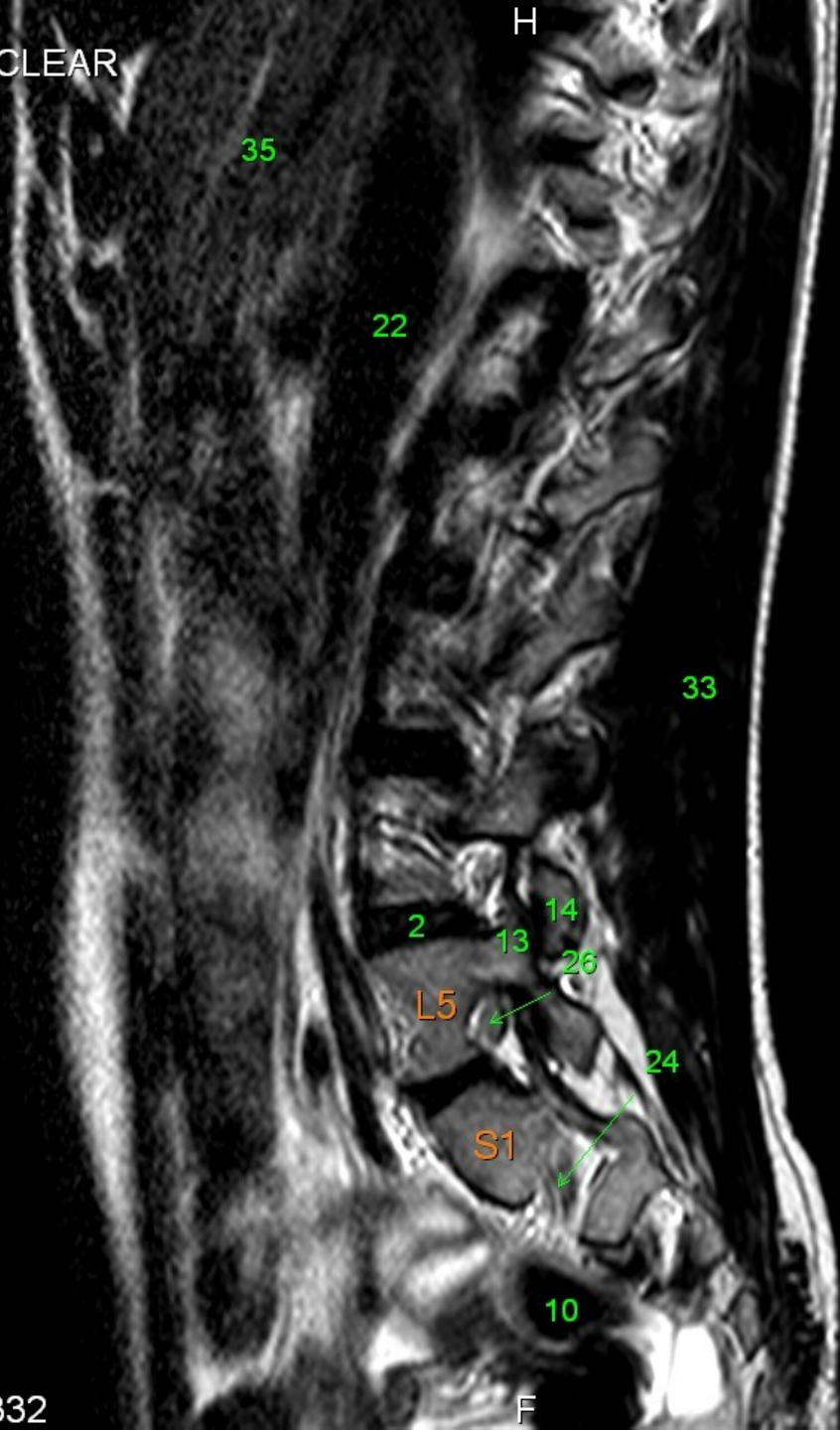
2  
13  
14  
21  
23  
L5  
26  
24  
S1

10

F

- 1 Medulla spinalis
- 2 Discus intervertebralis
- 3 Spatium subarachnoideum (liquor cerebrospinalis)
- 4 Processus spinosus
- 5 Conus medullaris
- 6 Cauda equina
- 7 Musculus psoas major
- 8 Foramen intervertebrale
- 9 os ilium
- 10 Rectum
- 11 Colon descendens
- 12 Aorta abdominalis
- 13 Processus articularis superior
- 14 Processus articularis inferior
- 15 Truncus coeliacus
- 16 Arteria mesenterica superior
- 17 Arteria renalis sinistra
- 18 Vena renalis sinistra
- 19 Arteria iliaca communis sinistra
- 20 Vena iliaca communis sinistra
- 21 Arteria iliaca communis dextra
- 22 Vena cava inferior
- 23 Vena iliaca communis dextra
- 24 nervus spinalis S1
- 25 nervus spinalis S2
- 26 nervus spinalis L5
- 27 nervus spinalis L4
- 28 myometrium
- 29 uterus
- 30 endometrium
- 31 musculus quadratus lumborum
- 32 musculus iliocostalis
- 33 musculus longissimus dorsi
- 34 musculi spinospinales
- 35 hepar

A



P

- 1 Medulla spinalis
- 2 Discus intervertebralis
- 3 Spatium subarachnoideum (liquor cerebrospinalis)
- 4 Processus spinosus
- 5 Conus medullaris
- 6 Cauda equina
- 7 Musculus psoas major
- 8 Foramen intervertebrale
- 9 os ilium
- 10 Rectum
- 11 Colon descendens
- 12 Aorta abdominalis
- 13 Processus articularis superior
- 14 Processus articularis inferior
- 15 Truncus coeliacus
- 16 Arteria mesenterica superior
- 17 Arteria renalis sinistra
- 18 Vena renalis sinistra
- 19 Arteria iliaca communis sinistra
- 20 Vena iliaca communis sinistra
- 21 Arteria iliaca communis dextra
- 22 Vena cava inferior
- 23 Vena iliaca communis dextra
- 24 nervus spinalis S1
- 25 nervus spinalis S2
- 26 nervus spinalis L5
- 27 nervus spinalis L4
- 28 myometrium
- 29 uterus
- 30 endometrium
- 31 musculus quadratus lumborum
- 32 musculus iliocostalis
- 33 musculus longissimus dorsi
- 34 musculi spinospinales
- 35 hepar

F

A

P

F

35

22

7

33

26

14

13

S1

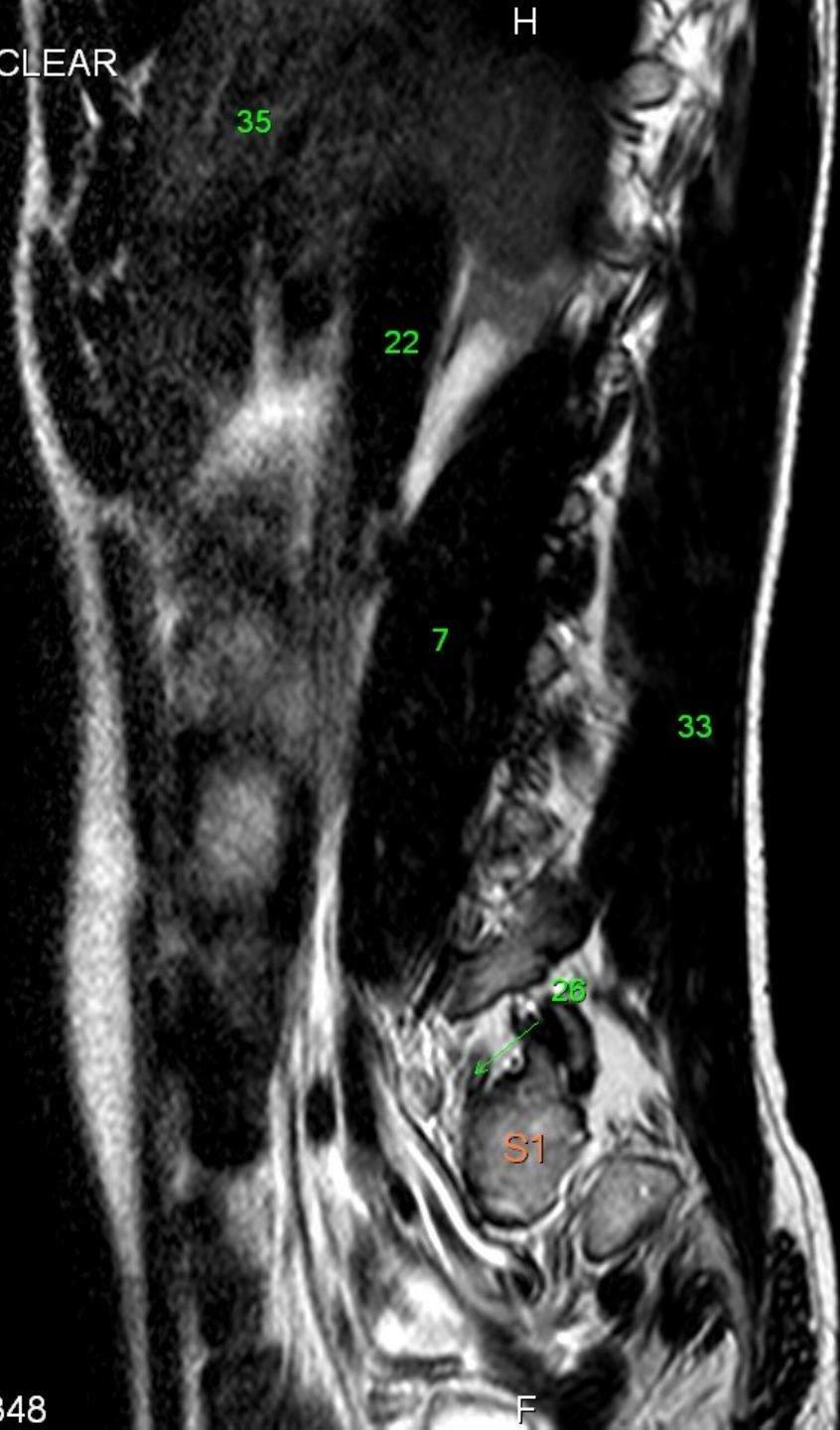
24

10

- 1 Medulla spinalis
- 2 Discus intervertebralis
- 3 Spatium subarachnoideum (liquor cerebrospinalis)
- 4 Processus spinosus
- 5 Conus medullaris
- 6 Cauda equina
- 7 Musculus psoas major
- 8 Foramen intervertebrale
- 9 os ilium
- 10 Rectum
- 11 Colon descendens
- 12 Aorta abdominalis
- 13 Processus articularis superior
- 14 Processus articularis inferior
- 15 Truncus coeliacus
- 16 Arteria mesenterica superior
- 17 Arteria renalis sinistra
- 18 Vena renalis sinistra
- 19 Arteria iliaca communis sinistra
- 20 Vena iliaca communis sinistra
- 21 Arteria iliaca communis dextra
- 22 Vena cava inferior
- 23 Vena iliaca communis dextra
- 24 nervus spinalis S1
- 25 nervus spinalis S2
- 26 nervus spinalis L5
- 27 nervus spinalis L4
- 28 myometrium
- 29 uterus
- 30 endometrium
- 31 musculus quadratus lumborum
- 32 musculus iliocostalis
- 33 musculus longissimus dorsi
- 34 musculi spinosiales
- 35 hepar

A

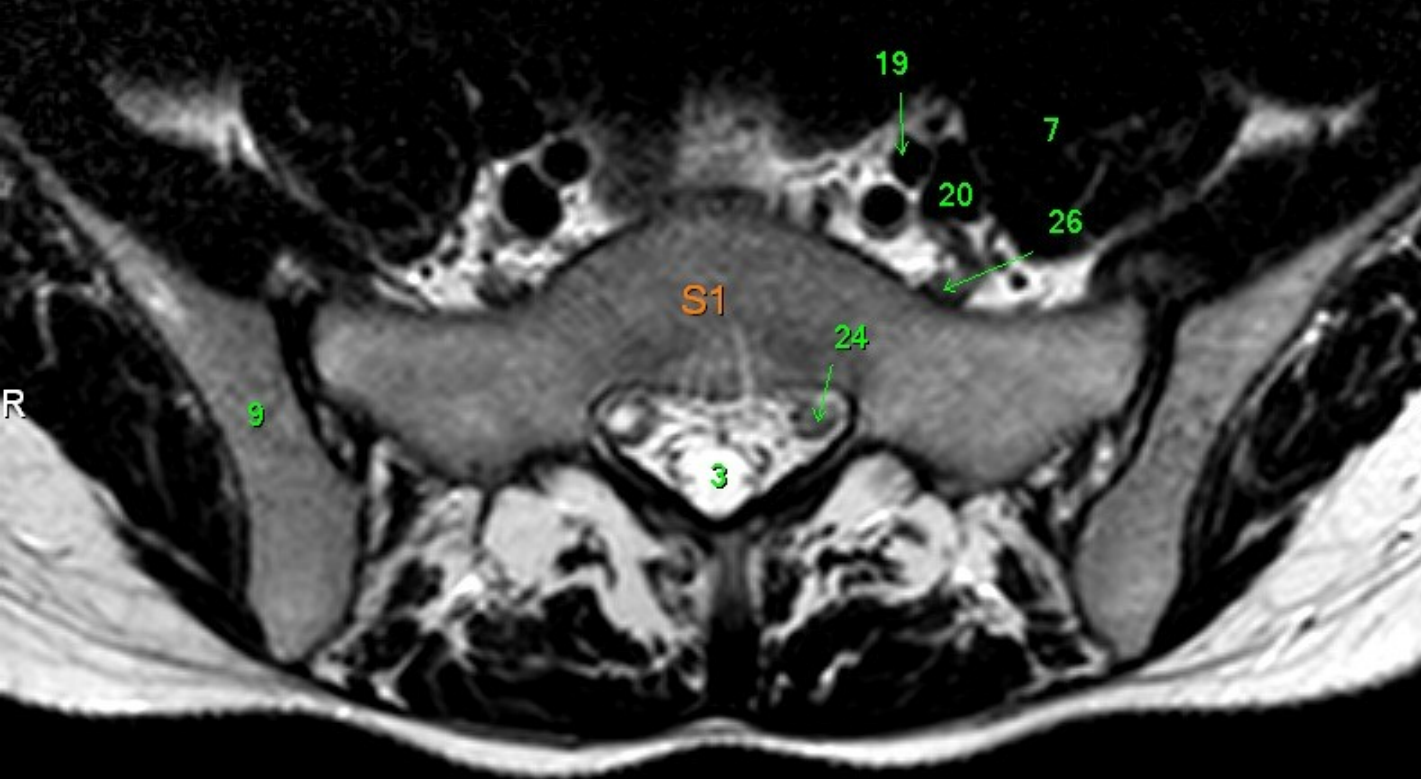
P



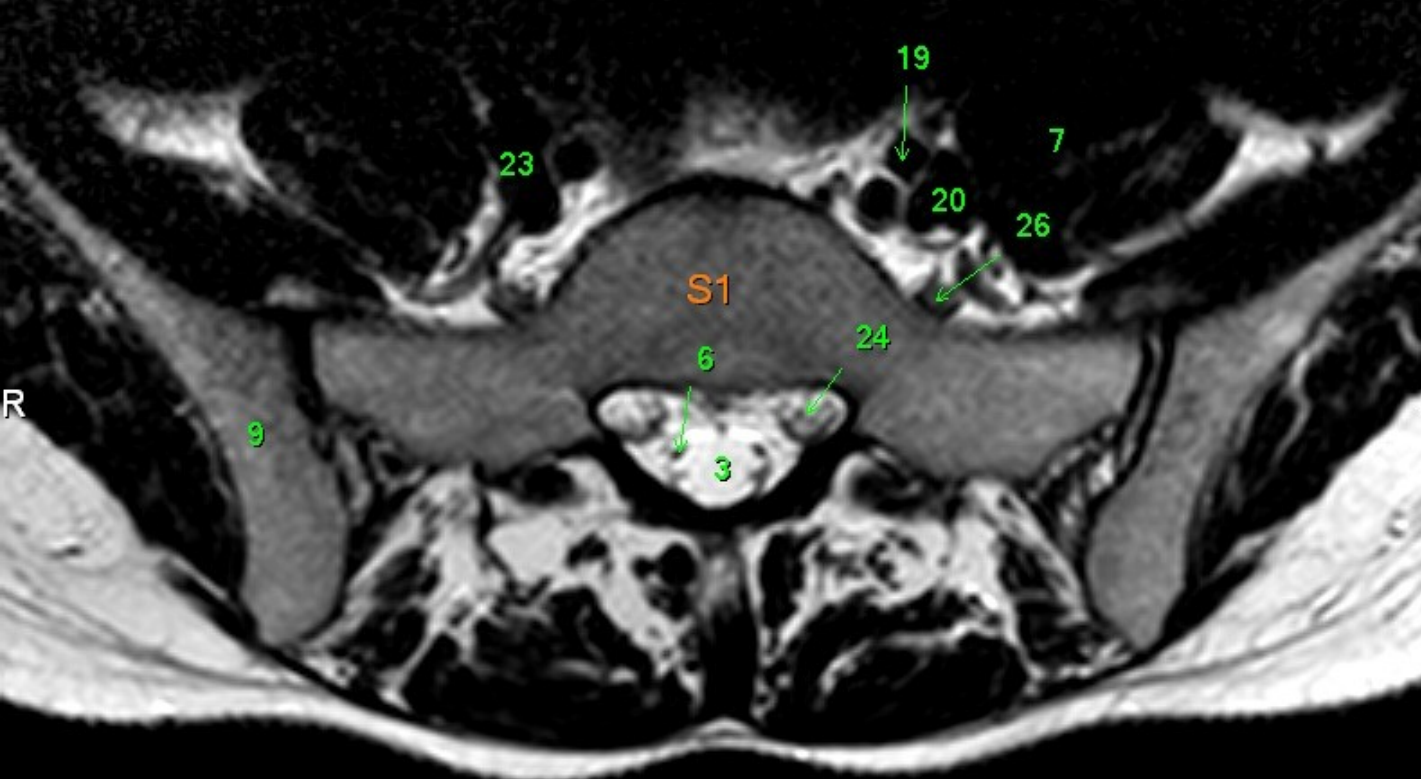
- 1 Medulla spinalis
- 2 Discus intervertebralis
- 3 Spatium subarachnoideum (liquor cerebrospinalis)
- 4 Processus spinosus
- 5 Conus medullaris
- 6 Cauda equina
- 7 Musculus psoas major
- 8 Foramen intervertebrale
- 9 os ilium
- 10 Rectum
- 11 Colon descendens
- 12 Aorta abdominalis
- 13 Processus articularis superior
- 14 Processus articularis inferior
- 15 Truncus coeliacus
- 16 Arteria mesenterica superior
- 17 Arteria renalis sinistra
- 18 Vena renalis sinistra
- 19 Arteria iliaca communis sinistra
- 20 Vena iliaca communis sinistra
- 21 Arteria iliaca communis dextra
- 22 Vena cava inferior
- 23 Vena iliaca communis dextra
- 24 nervus spinalis S1
- 25 nervus spinalis S2
- 26 nervus spinalis L5
- 27 nervus spinalis L4
- 28 myometrium
- 29 uterus
- 30 endometrium
- 31 musculus quadratus lumborum
- 32 musculus iliocostalis
- 33 musculus longissimus dorsi
- 34 musculi spinospinales
- 35 hepar

F

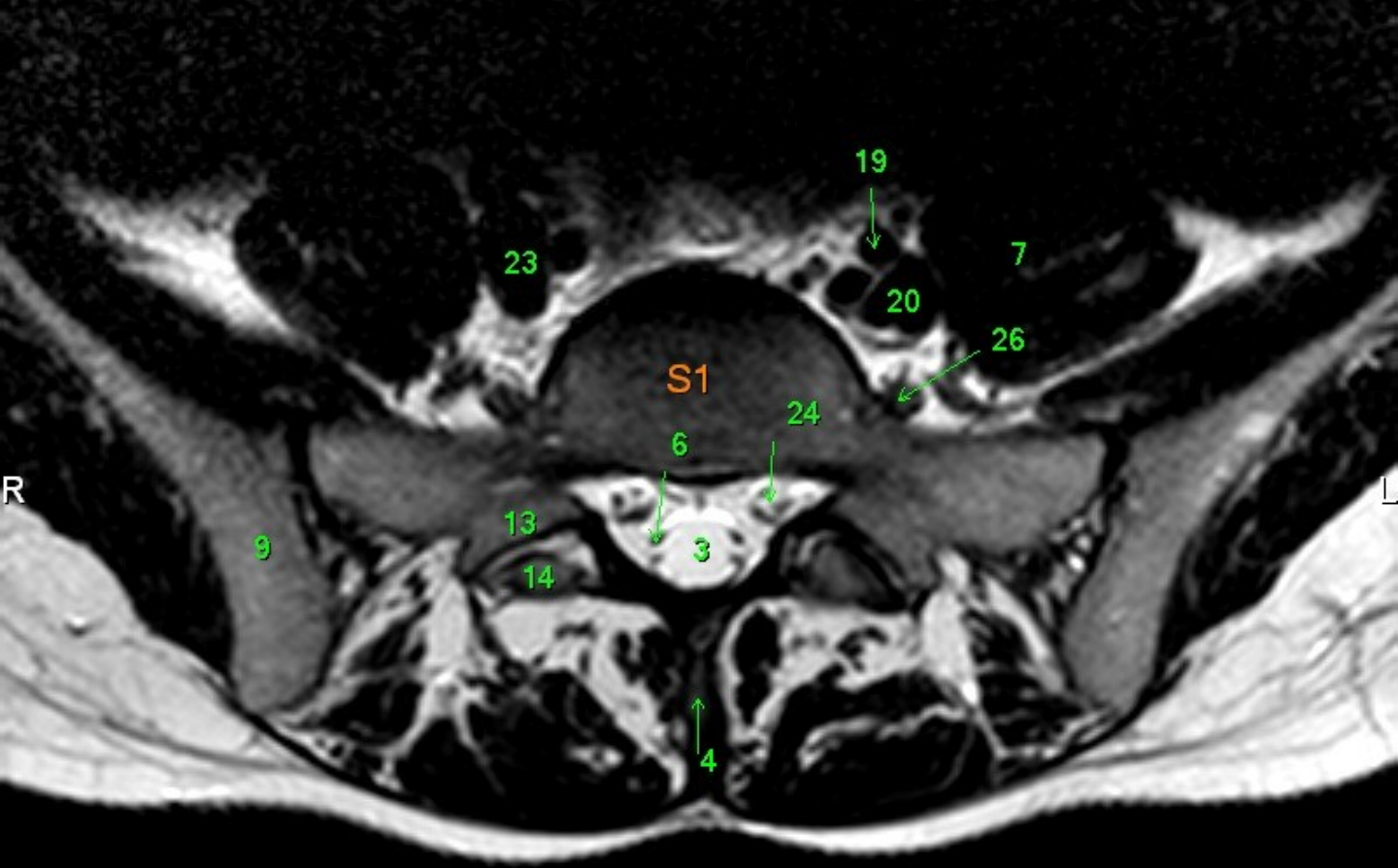




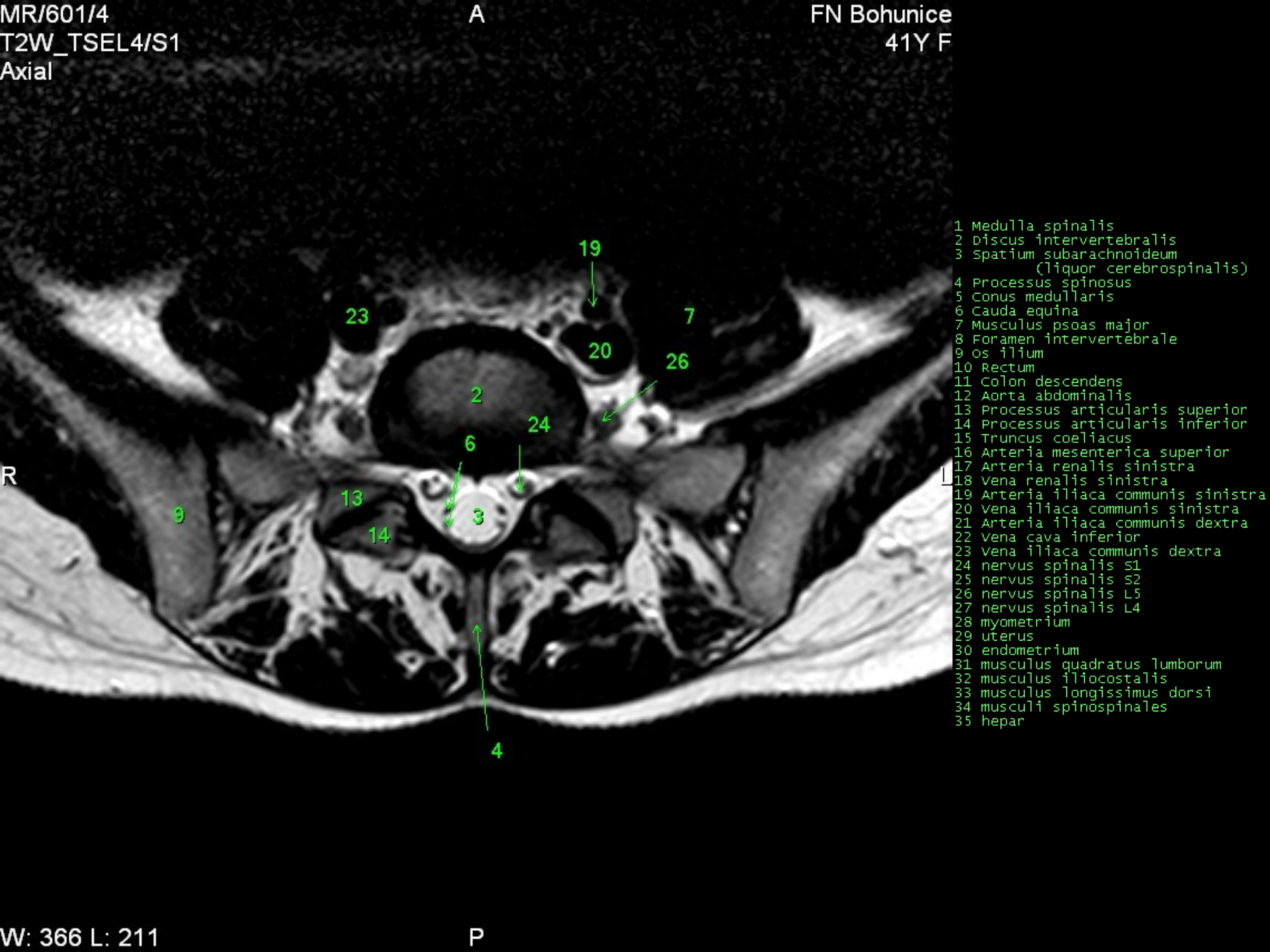
- 1 Medulla spinalis
- 2 Discus intervertebralis
- 3 Spatium subarachnoideum (liquor cerebrospinalis)
- 4 Processus spinosus
- 5 Conus medullaris
- 6 Cauda equina
- 7 Musculus psoas major
- 8 Foramen intervertebrale
- 9 os ilium
- 10 Rectum
- 11 Colon descendens
- 12 Aorta abdominalis
- 13 Processus articularis superior
- 14 Processus articularis inferior
- 15 Truncus coeliacus
- 16 Arteria mesenterica superior
- 17 Arteria renalis sinistra
- 18 Vena renalis sinistra
- 19 Arteria iliaca communis sinistra
- 20 Vena iliaca communis sinistra
- 21 Arteria iliaca communis dextra
- 22 Vena cava inferior
- 23 Vena iliaca communis dextra
- 24 nervus spinalis S1
- 25 nervus spinalis S2
- 26 nervus spinalis L5
- 27 nervus spinalis L4
- 28 myometrium
- 29 uterus
- 30 endometrium
- 31 musculus quadratus lumborum
- 32 musculus iliocostalis
- 33 musculus longissimus dorsi
- 34 musculi spinospinales
- 35 hepar



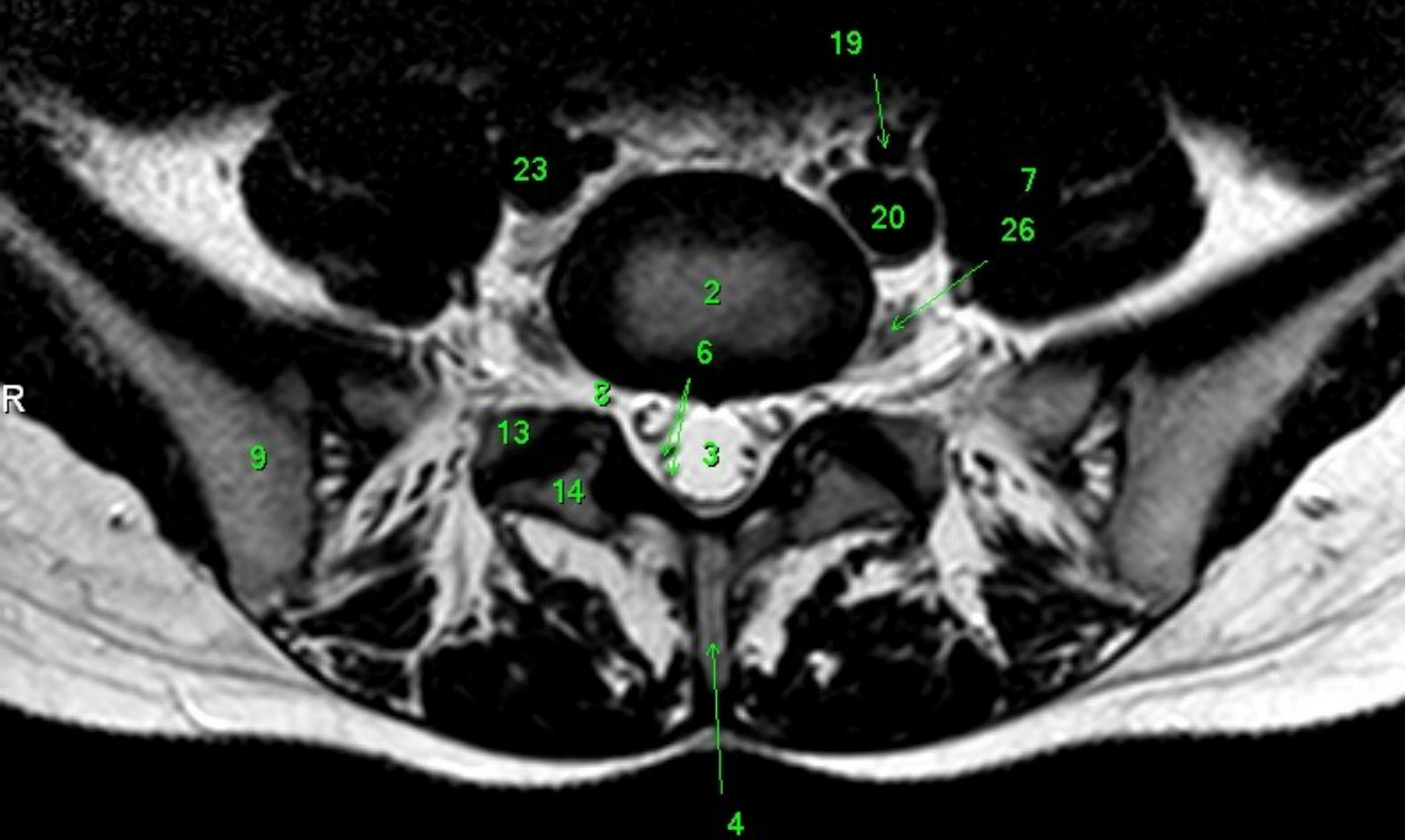
- 1 Medulla spinalis
- 2 Discus intervertebralis
- 3 Spatium subarachnoideum (liquor cerebrospinalis)
- 4 Processus spinosus
- 5 Conus medullaris
- 6 Cauda equina
- 7 Musculus psoas major
- 8 Foramen intervertebrale
- 9 os ilium
- 10 Rectum
- 11 Colon descendens
- 12 Aorta abdominalis
- 13 Processus articularis superior
- 14 Processus articularis inferior
- 15 Truncus coeliacus
- 16 Arteria mesenterica superior
- 17 Arteria renalis sinistra
- 18 Vena renalis sinistra
- 19 Arteria iliaca communis sinistra
- 20 Vena iliaca communis sinistra
- 21 Arteria iliaca communis dextra
- 22 Vena cava inferior
- 23 Vena iliaca communis dextra
- 24 nervus spinalis S1
- 25 nervus spinalis S2
- 26 nervus spinalis L5
- 27 nervus spinalis L4
- 28 myometrium
- 29 uterus
- 30 endometrium
- 31 musculus quadratus lumborum
- 32 musculus iliocostalis
- 33 musculus longissimus dorsi
- 34 musculi spinospinales
- 35 hepar



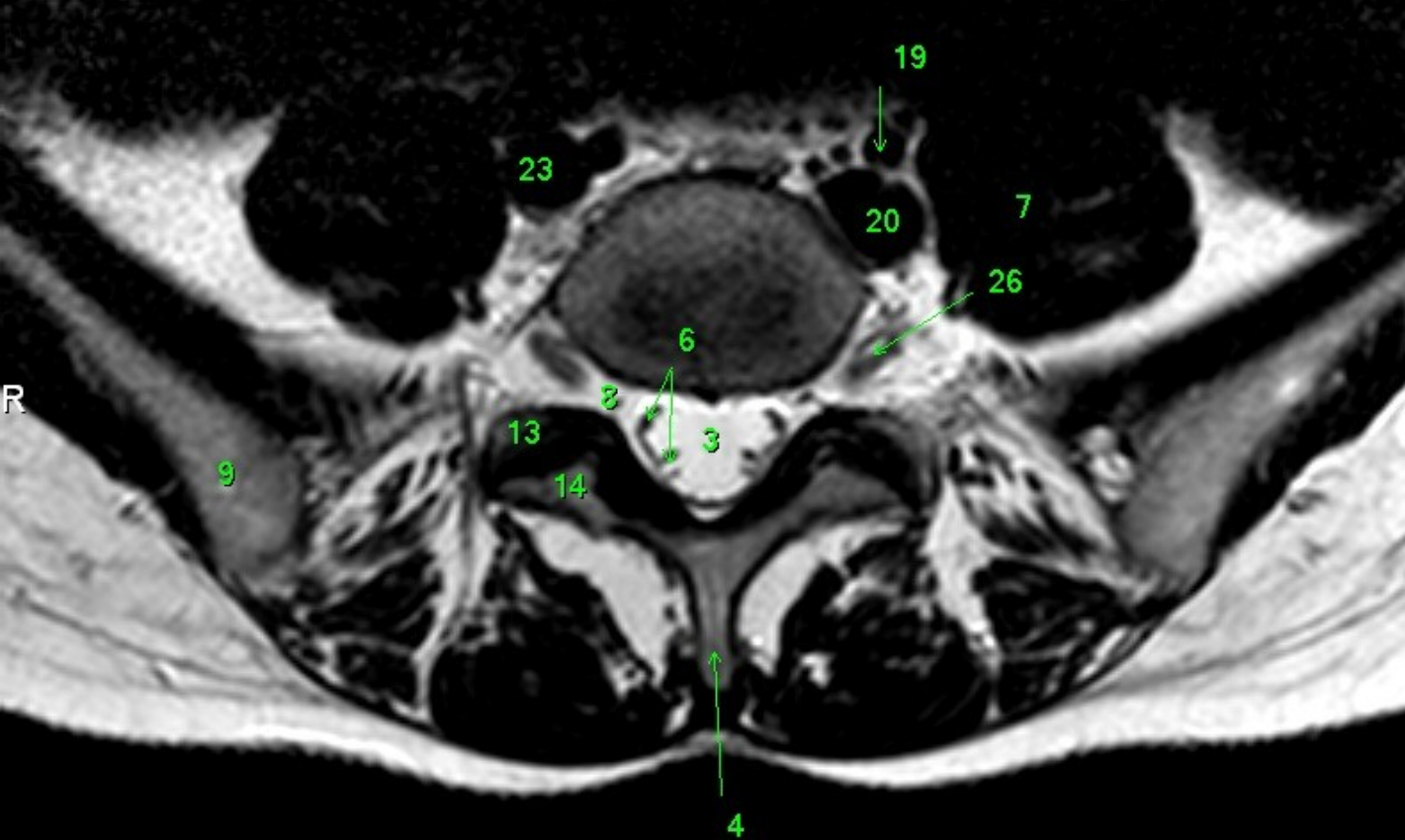
- 1 Medulla spinalis
- 2 Discus intervertebralis
- 3 Spatium subarachnoideum (liquor cerebrospinalis)
- 4 Processus spinosus
- 5 Conus medullaris
- 6 Cauda equina
- 7 Musculus psoas major
- 8 Foramen intervertebrale
- 9 os ilium
- 10 Rectum
- 11 Colon descendens
- 12 Aorta abdominalis
- 13 Processus articularis superior
- 14 Processus articularis inferior
- 15 Truncus coeliacus
- 16 Arteria mesenterica superior
- 17 Arteria renalis sinistra
- 18 Vena renalis sinistra
- 19 Arteria iliaca communis sinistra
- 20 Vena iliaca communis sinistra
- 21 Arteria iliaca communis dextra
- 22 Vena cava inferior
- 23 Vena iliaca communis dextra
- 24 nervus spinalis S1
- 25 nervus spinalis S2
- 26 nervus spinalis L5
- 27 nervus spinalis L4
- 28 myometrium
- 29 uterus
- 30 endometrium
- 31 musculus quadratus lumborum
- 32 musculus iliocostalis
- 33 musculus longissimus dorsi
- 34 musculi spinospinales
- 35 hepar



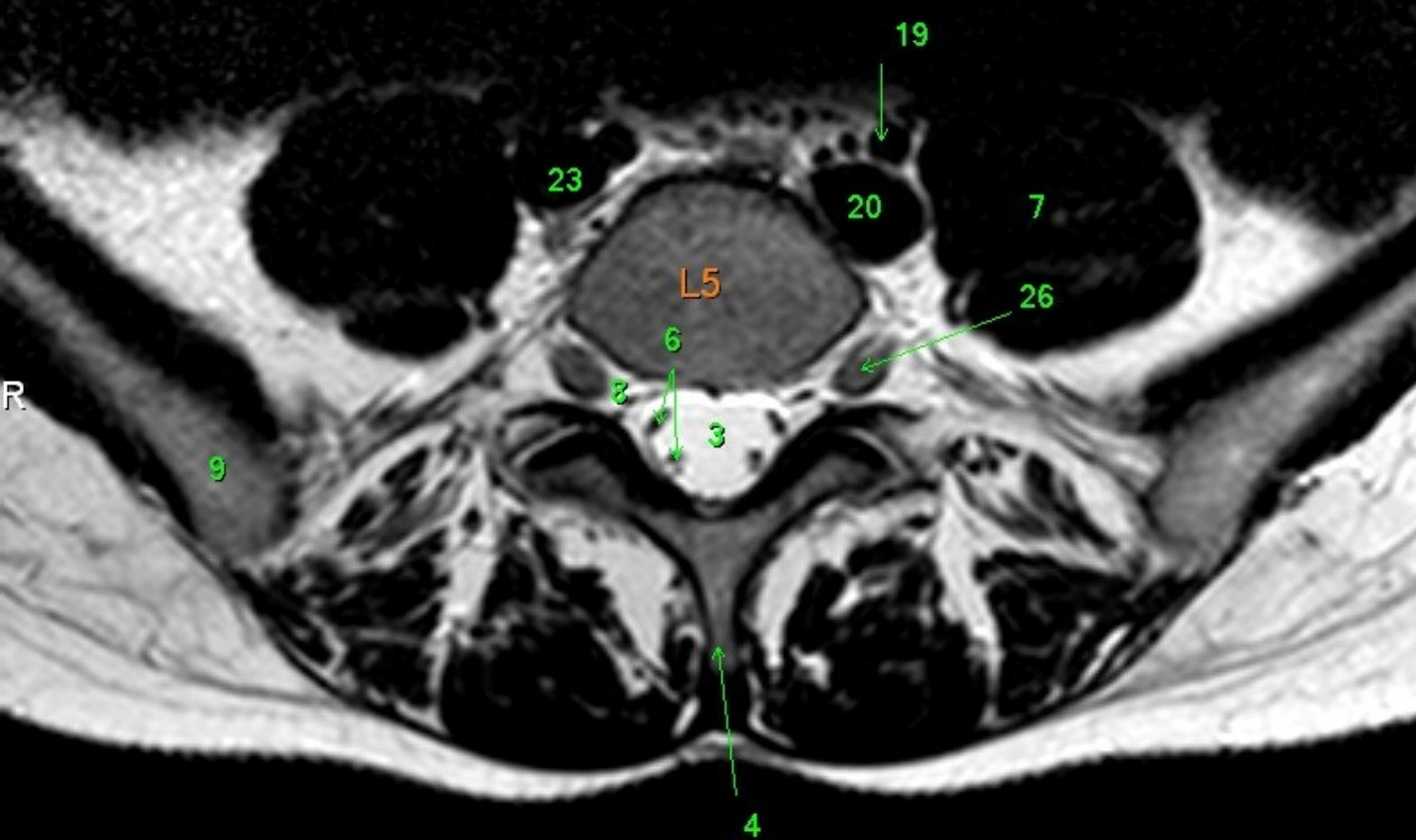
- 1 Medulla spinalis
- 2 Discus intervertebralis
- 3 Spatium subarachnoideum (liquor cerebrospinalis)
- 4 Processus spinosus
- 5 Conus medullaris
- 6 Cauda equina
- 7 Musculus psoas major
- 8 Foramen intervertebrale
- 9 os ilium
- 10 Rectum
- 11 Colon descendens
- 12 Aorta abdominalis
- 13 Processus articularis superior
- 14 Processus articularis inferior
- 15 Truncus coeliacus
- 16 Arteria mesenterica superior
- 17 Arteria renalis sinistra
- 18 Vena renalis sinistra
- 19 Arteria iliaca communis sinistra
- 20 Vena iliaca communis sinistra
- 21 Arteria iliaca communis dextra
- 22 Vena cava inferior
- 23 Vena iliaca communis dextra
- 24 nervus spinalis S1
- 25 nervus spinalis S2
- 26 nervus spinalis L5
- 27 nervus spinalis L4
- 28 myometrium
- 29 uterus
- 30 endometrium
- 31 musculus quadratus lumborum
- 32 musculus iliocostalis
- 33 musculus longissimus dorsi
- 34 musculi spinospinales
- 35 hepar



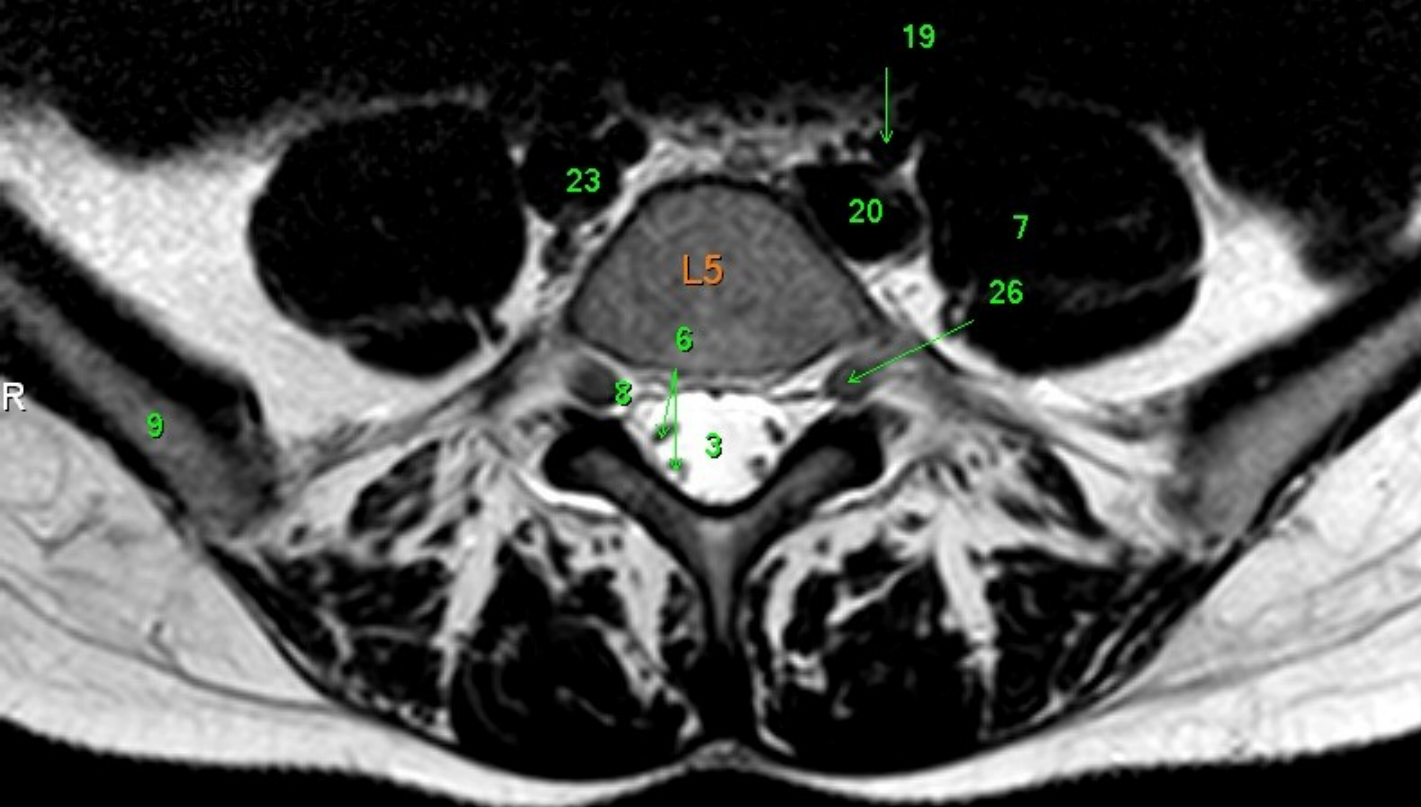
- 1 Medulla spinalis
- 2 Discus intervertebralis
- 3 Spatium subarachnoideum (liquor cerebrospinalis)
- 4 Processus spinosus
- 5 Conus medullaris
- 6 Cauda equina
- 7 Musculus psoas major
- 8 Foramen intervertebrale
- 9 os ilium
- 10 Rectum
- 11 Colon descendens
- 12 Aorta abdominalis
- 13 Processus articularis superior
- 14 Processus articularis inferior
- 15 Truncus coeliacus
- 16 Arteria mesenterica superior
- 17 Arteria renalis sinistra
- 18 Vena renalis sinistra
- 19 Arteria iliaca communis sinistra
- 20 Vena iliaca communis sinistra
- 21 Arteria iliaca communis dextra
- 22 Vena cava inferior
- 23 Vena iliaca communis dextra
- 24 nervus spinalis S1
- 25 nervus spinalis S2
- 26 nervus spinalis L5
- 27 nervus spinalis L4
- 28 myometrium
- 29 uterus
- 30 endometrium
- 31 musculus quadratus lumborum
- 32 musculus iliocostalis
- 33 musculus longissimus dorsi
- 34 musculi spinospinales
- 35 hepar



- 1 Medulla spinalis
- 2 Discus intervertebralis
- 3 Spatium subarachnoideum (liquor cerebrospinalis)
- 4 Processus spinosus
- 5 Conus medullaris
- 6 Cauda equina
- 7 Musculus psoas major
- 8 Foramen intervertebrale
- 9 os ilium
- 10 Rectum
- 11 Colon descendens
- 12 Aorta abdominalis
- 13 Processus articularis superior
- 14 Processus articularis inferior
- 15 Truncus coeliacus
- 16 Arteria mesenterica superior
- 17 Arteria renalis sinistra
- 18 Vena renalis sinistra
- 19 Arteria iliaca communis sinistra
- 20 Vena iliaca communis sinistra
- 21 Arteria iliaca communis dextra
- 22 Vena cava inferior
- 23 Vena iliaca communis dextra
- 24 nervus spinalis S1
- 25 nervus spinalis S2
- 26 nervus spinalis L5
- 27 nervus spinalis L4
- 28 myometrium
- 29 uterus
- 30 endometrium
- 31 musculus quadratus lumborum
- 32 musculus iliocostalis
- 33 musculus longissimus dorsi
- 34 musculi spinosiales
- 35 hepar

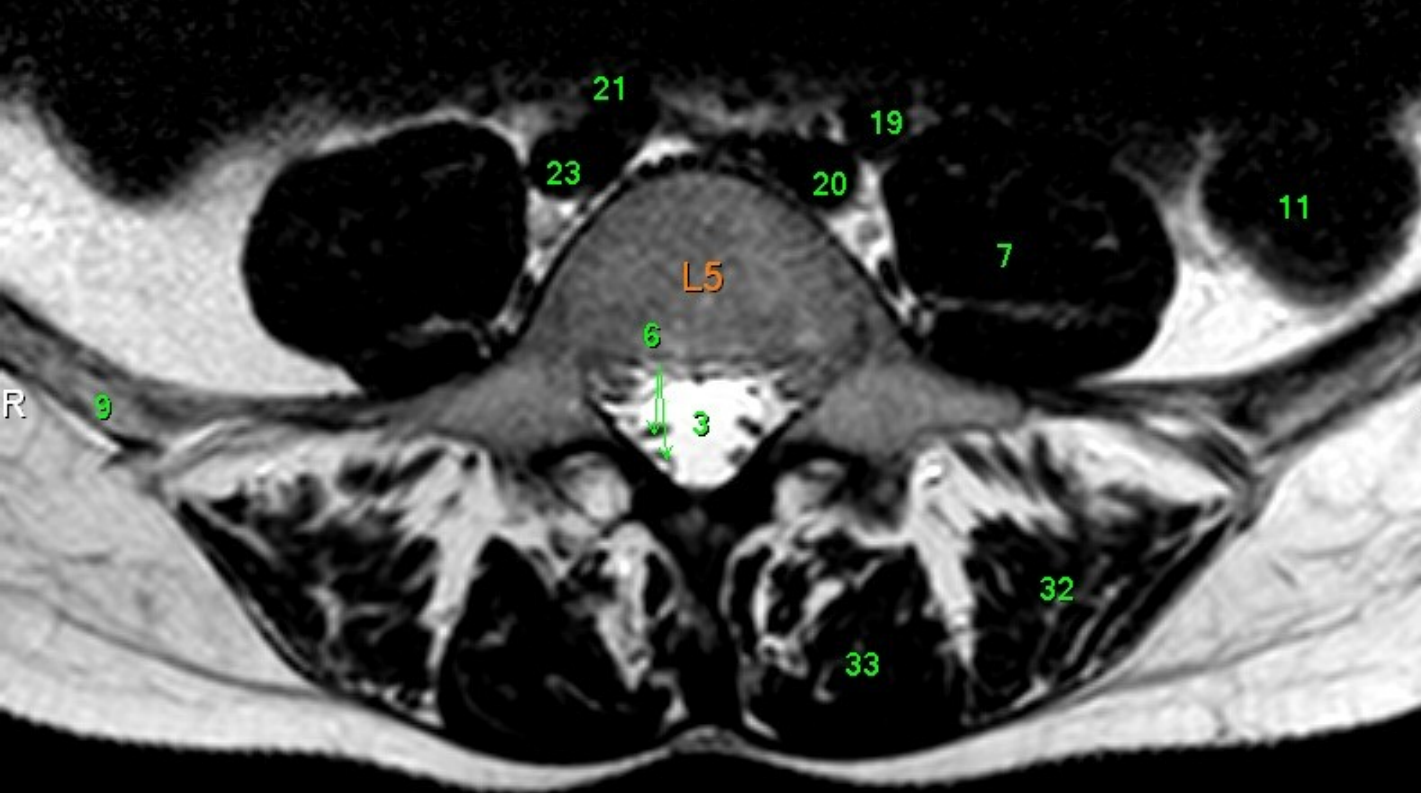


- 1 Medulla spinalis
- 2 Discus intervertebralis
- 3 Spatium subarachnoideum (liquor cerebrospinalis)
- 4 Processus spinosus
- 5 Conus medullaris
- 6 Cauda equina
- 7 Musculus psoas major
- 8 Foramen intervertebrale
- 9 os ilium
- 10 Rectum
- 11 Colon descendens
- 12 Aorta abdominalis
- 13 Processus articularis superior
- 14 Processus articularis inferior
- 15 Truncus coeliacus
- 16 Arteria mesenterica superior
- 17 Arteria renalis sinistra
- 18 Vena renalis sinistra
- 19 Arteria iliaca communis sinistra
- 20 Vena iliaca communis sinistra
- 21 Arteria iliaca communis dextra
- 22 Vena cava inferior
- 23 Vena iliaca communis dextra
- 24 nervus spinalis S1
- 25 nervus spinalis S2
- 26 nervus spinalis L5
- 27 nervus spinalis L4
- 28 myometrium
- 29 uterus
- 30 endometrium
- 31 musculus quadratus lumborum
- 32 musculus iliocostalis
- 33 musculus longissimus dorsi
- 34 musculi spinosiales
- 35 hepar

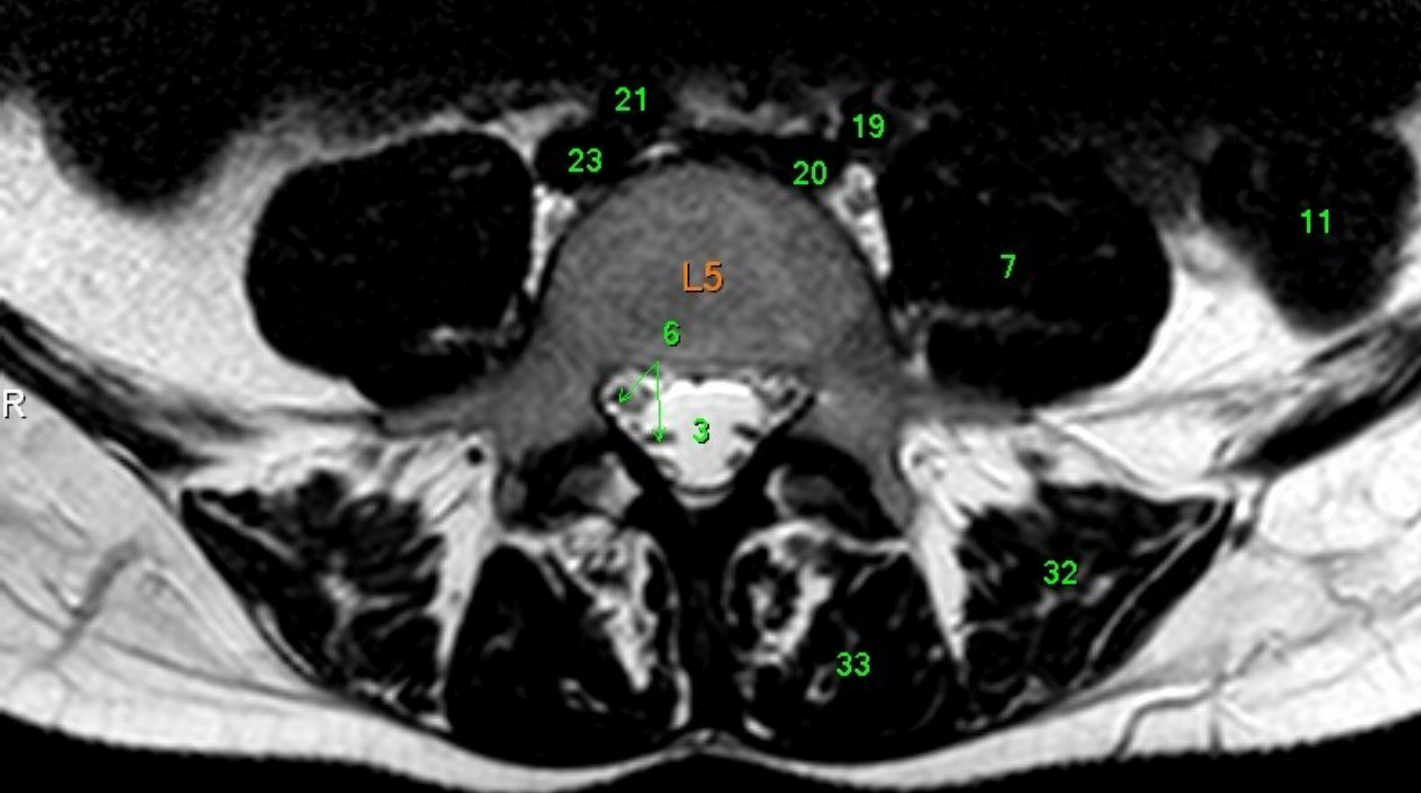


- 1 Medulla spinalis
- 2 Discus intervertebralis
- 3 Spatium subarachnoideum (liquor cerebrospinalis)
- 4 Processus spinosus
- 5 Conus medullaris
- 6 Cauda equina
- 7 Musculus psoas major
- 8 Foramen intervertebrale
- 9 os ilium
- 10 Rectum
- 11 Colon descendens
- 12 Aorta abdominalis
- 13 Processus articularis superior
- 14 Processus articularis inferior
- 15 Truncus coeliacus
- 16 Arteria mesenterica superior
- 17 Arteria renalis sinistra
- 18 Vena renalis sinistra
- 19 Arteria iliaca communis sinistra
- 20 Vena iliaca communis sinistra
- 21 Arteria iliaca communis dextra
- 22 Vena cava inferior
- 23 Vena iliaca communis dextra
- 24 nervus spinalis S1
- 25 nervus spinalis S2
- 26 nervus spinalis L5
- 27 nervus spinalis L4
- 28 myometrium
- 29 uterus
- 30 endometrium
- 31 musculus quadratus lumborum
- 32 musculus iliocostalis
- 33 musculus longissimus dorsi
- 34 musculi spinospinales
- 35 hepar

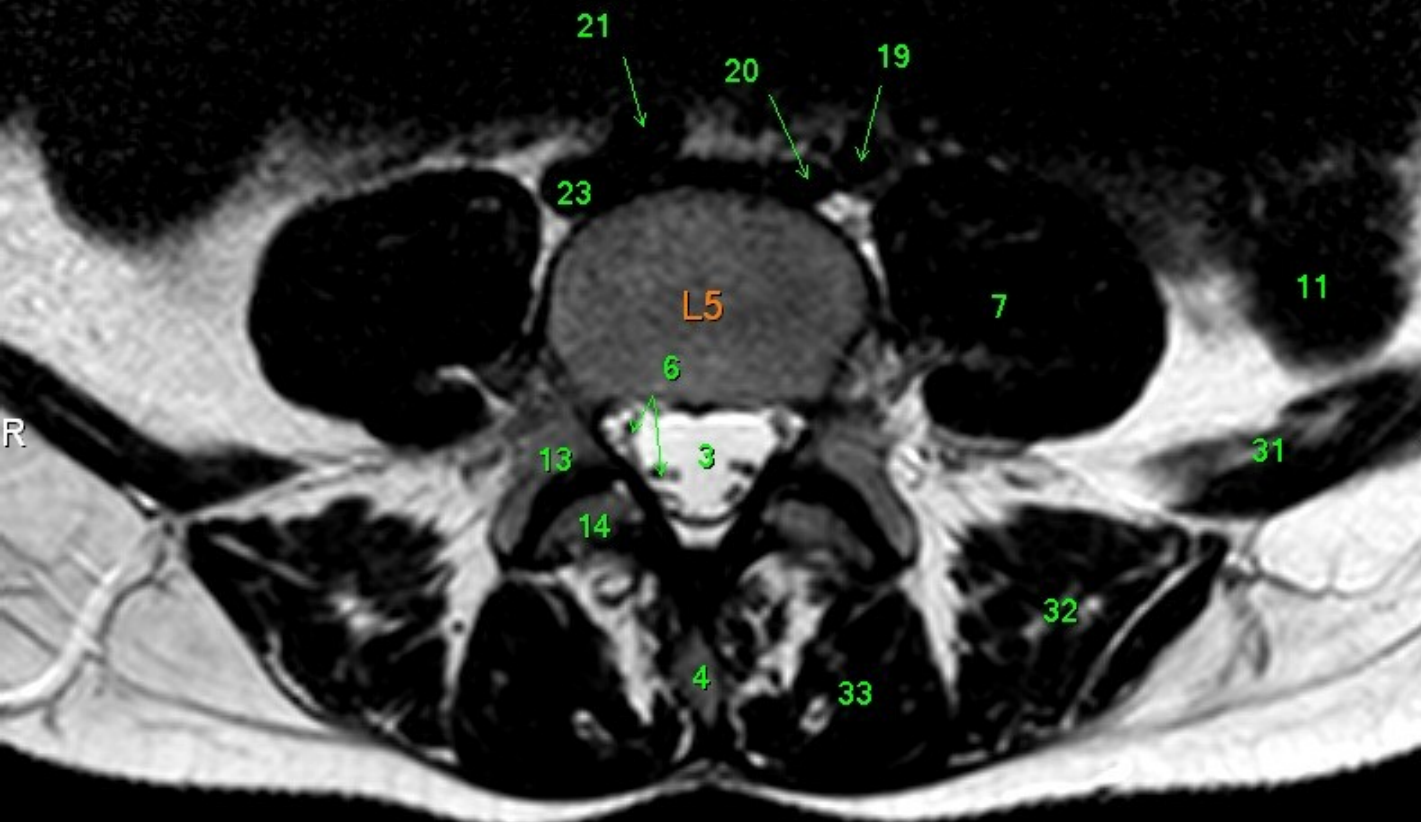




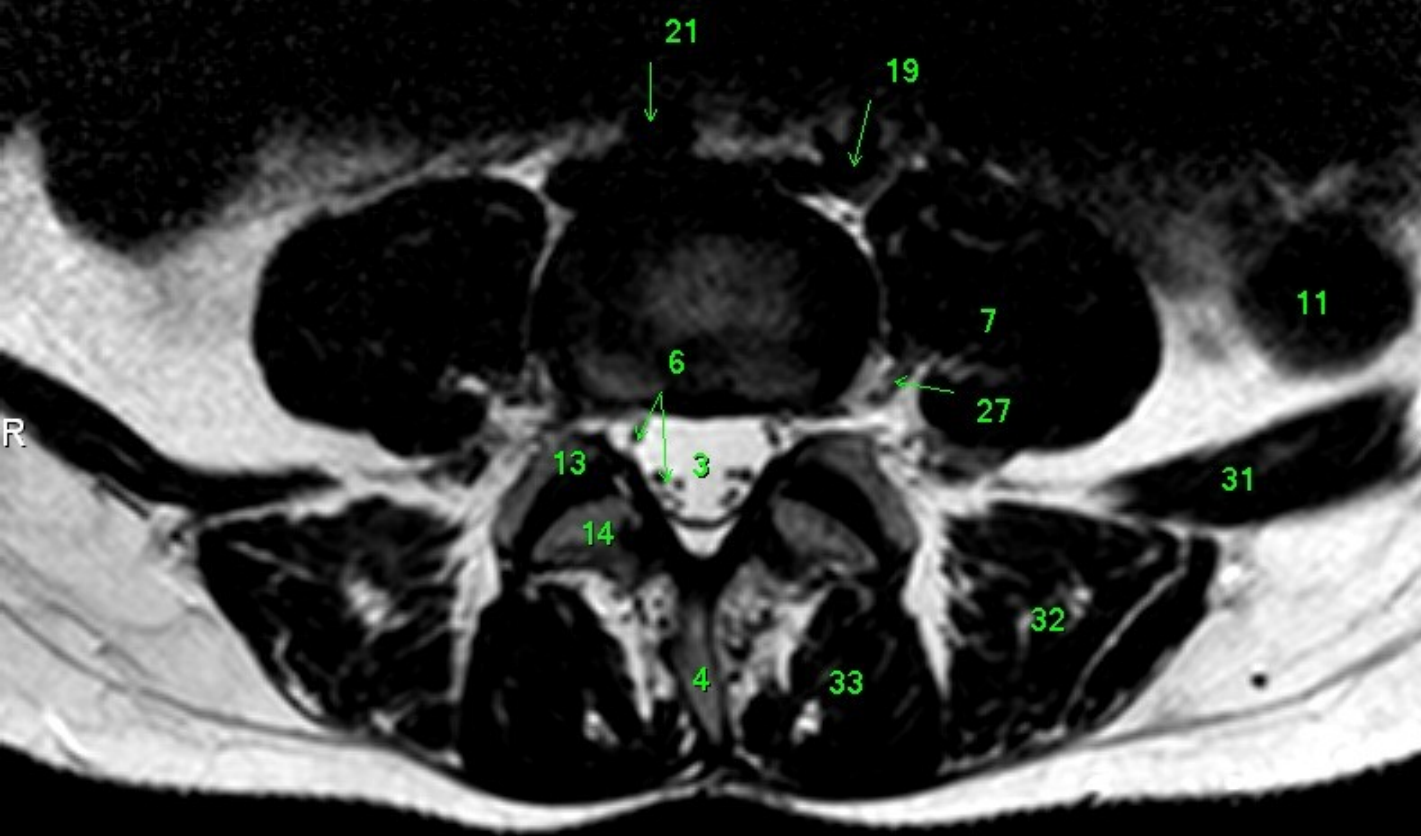
- 1 Medulla spinalis
- 2 Discus intervertebralis
- 3 Spatium subarachnoideum (liquor cerebrospinalis)
- 4 Processus spinosus
- 5 Conus medullaris
- 6 Cauda equina
- 7 Musculus psoas major
- 8 Foramen intervertebrale
- 9 os ilium
- 10 Rectum
- 11 Colon descendens
- 12 Aorta abdominalis
- 13 Processus articularis superior
- 14 Processus articularis inferior
- 15 Truncus coeliacus
- 16 Arteria mesenterica superior
- 17 Arteria renalis sinistra
- 18 Vena renalis sinistra
- 19 Arteria iliaca communis sinistra
- 20 Vena iliaca communis sinistra
- 21 Arteria iliaca communis dextra
- 22 Vena cava inferior
- 23 Vena iliaca communis dextra
- 24 nervus spinalis S1
- 25 nervus spinalis S2
- 26 nervus spinalis L5
- 27 nervus spinalis L4
- 28 myometrium
- 29 uterus
- 30 endometrium
- 31 musculus quadratus lumborum
- 32 musculus iliocostalis
- 33 musculus longissimus dorsi
- 34 musculi spinosiales
- 35 hepar



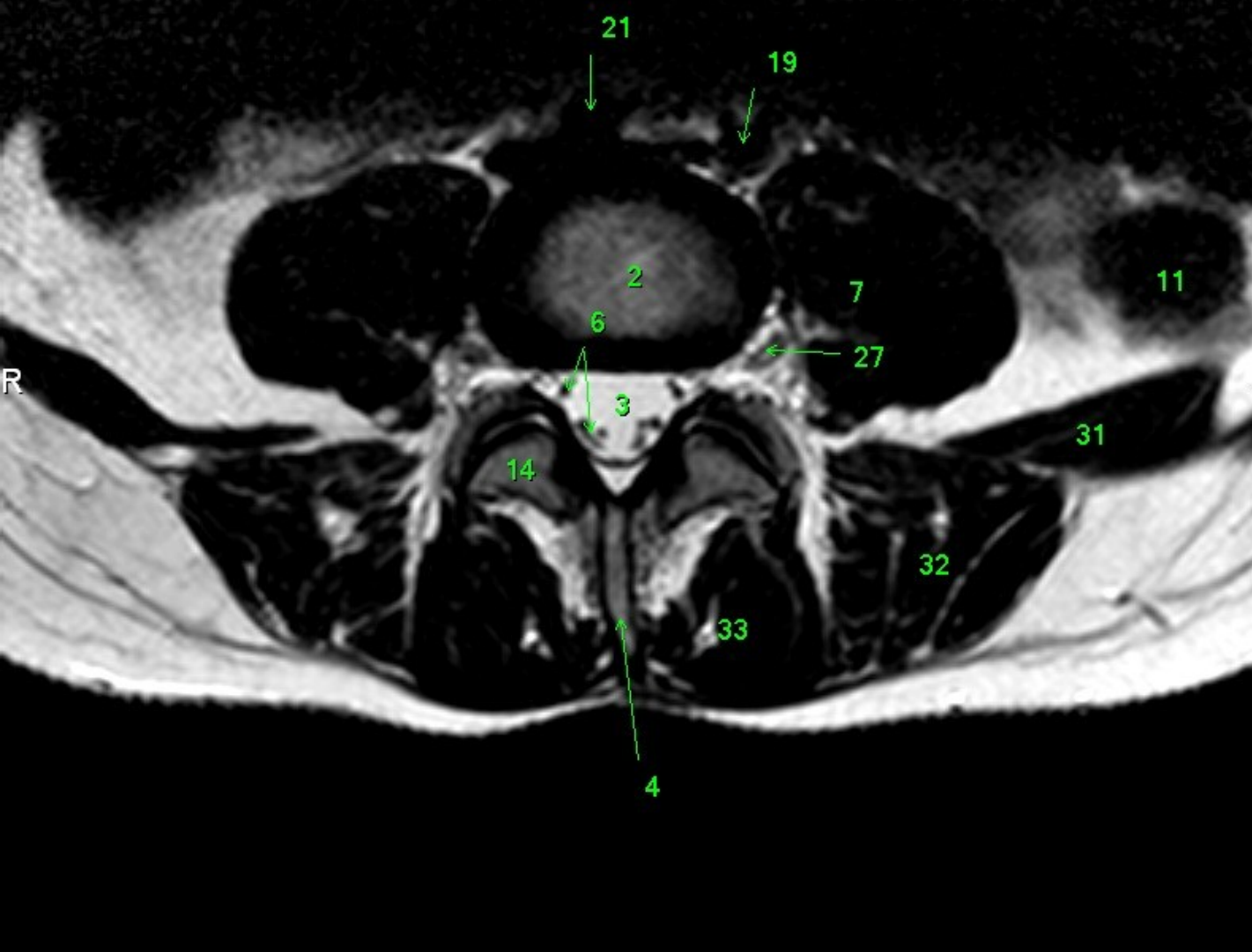
- 1 Medulla spinalis
- 2 Discus intervertebralis
- 3 Spatium subarachnoideum (liquor cerebrospinalis)
- 4 Processus spinosus
- 5 Conus medullaris
- 6 Cauda equina
- 7 Musculus psoas major
- 8 Foramen intervertebrale
- 9 os ilium
- 10 Rectum
- 11 Colon descendens
- 12 Aorta abdominalis
- 13 Processus articularis superior
- 14 Processus articularis inferior
- 15 Truncus coeliacus
- 16 Arteria mesenterica superior
- 17 Arteria renalis sinistra
- 18 Vena renalis sinistra
- 19 Arteria iliaca communis sinistra
- 20 Vena iliaca communis sinistra
- 21 Arteria iliaca communis dextra
- 22 Vena cava inferior
- 23 Vena iliaca communis dextra
- 24 nervus spinalis S1
- 25 nervus spinalis S2
- 26 nervus spinalis L5
- 27 nervus spinalis L4
- 28 myometrium
- 29 uterus
- 30 endometrium
- 31 musculus quadratus lumborum
- 32 musculus iliocostalis
- 33 musculus longissimus dorsi
- 34 musculi spinosiales
- 35 hepar



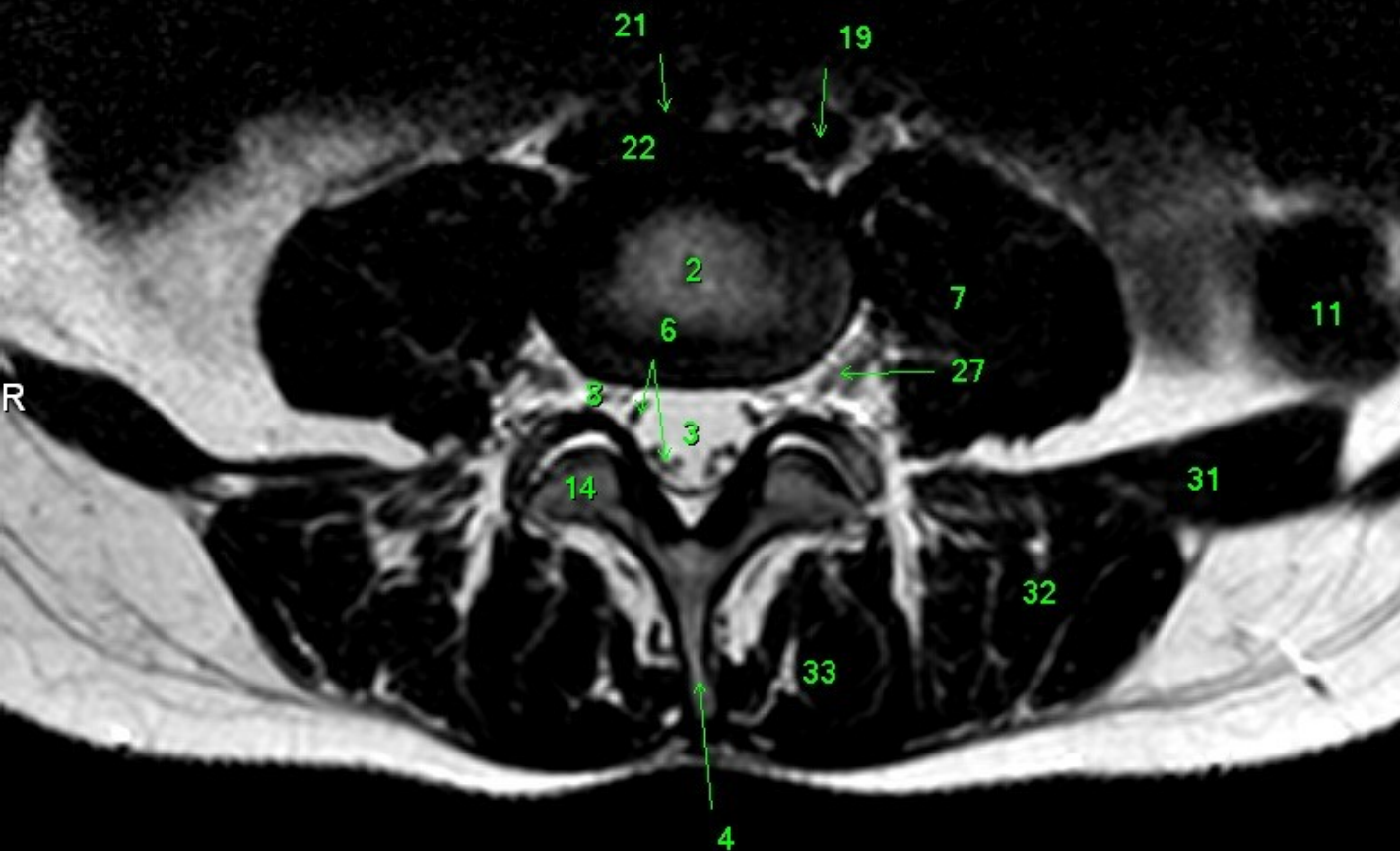
- 1 Medulla spinalis
- 2 Discus intervertebralis
- 3 Spatium subarachnoideum (liquor cerebrospinalis)
- 4 Processus spinosus
- 5 Conus medullaris
- 6 Cauda equina
- 7 Musculus psoas major
- 8 Foramen intervertebrale
- 9 os ilium
- 10 Rectum
- 11 Colon descendens
- 12 Aorta abdominalis
- 13 Processus articularis superior
- 14 Processus articularis inferior
- 15 Truncus coeliacus
- 16 Arteria mesenterica superior
- 17 Arteria renalis sinistra
- 18 Vena renalis sinistra
- 19 Arteria iliaca communis sinistra
- 20 Vena iliaca communis sinistra
- 21 Arteria iliaca communis dextra
- 22 Vena cava inferior
- 23 Vena iliaca communis dextra
- 24 nervus spinalis S1
- 25 nervus spinalis S2
- 26 nervus spinalis L5
- 27 nervus spinalis L4
- 28 myometrium
- 29 uterus
- 30 endometrium
- 31 musculus quadratus lumborum
- 32 musculus iliocostalis
- 33 musculus longissimus dorsi
- 34 musculi spinospinales
- 35 hepar



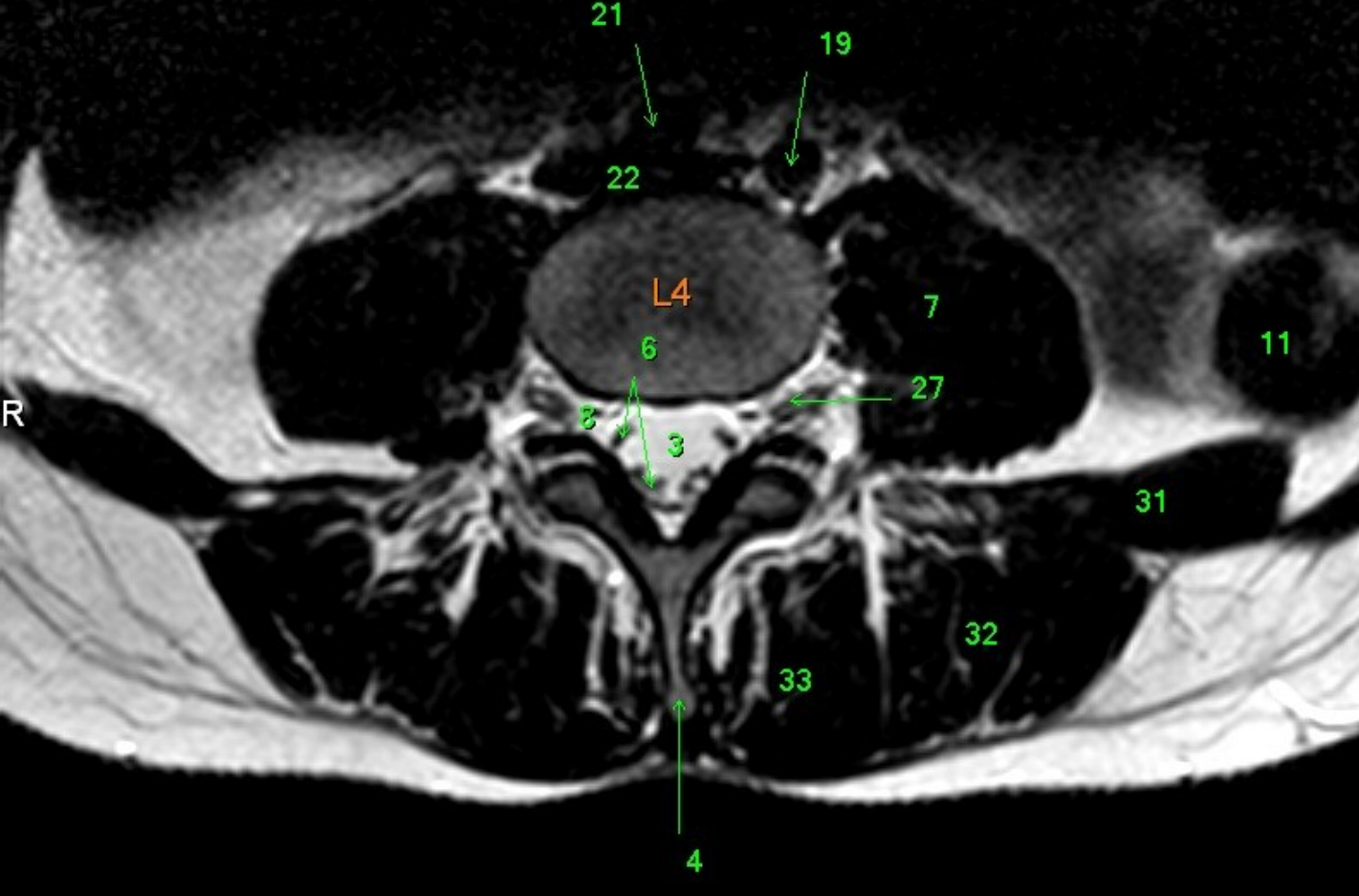
- 1 Medulla spinalis
- 2 Discus intervertebralis
- 3 Spatium subarachnoideum (liquor cerebrospinalis)
- 4 Processus spinosus
- 5 Conus medullaris
- 6 Cauda equina
- 7 Musculus psoas major
- 8 Foramen intervertebrale
- 9 os ilium
- 10 Rectum
- 11 Colon descendens
- 12 Aorta abdominalis
- 13 Processus articularis superior
- 14 Processus articularis inferior
- 15 Truncus coeliacus
- 16 Arteria mesenterica superior
- 17 Arteria renalis sinistra
- 18 Vena renalis sinistra
- 19 Arteria iliaca communis sinistra
- 20 Vena iliaca communis sinistra
- 21 Arteria iliaca communis dextra
- 22 Vena cava inferior
- 23 Vena iliaca communis dextra
- 24 nervus spinalis S1
- 25 nervus spinalis S2
- 26 nervus spinalis L5
- 27 nervus spinalis L4
- 28 myometrium
- 29 uterus
- 30 endometrium
- 31 musculus quadratus lumborum
- 32 musculus iliocostalis
- 33 musculus longissimus dorsi
- 34 musculi spinosiales
- 35 hepar



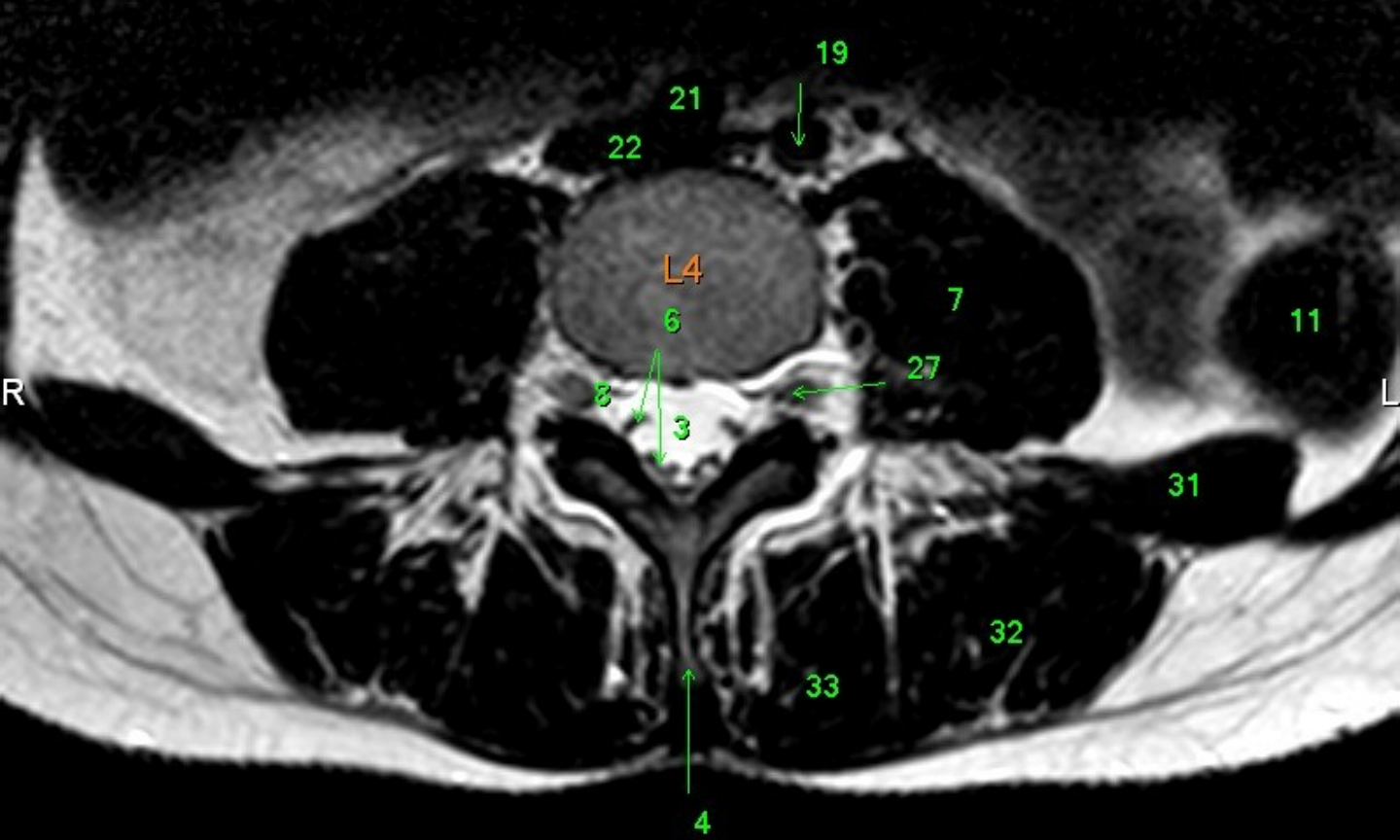
- 1 Medulla spinalis
- 2 Discus intervertebralis
- 3 Spatium subarachnoideum (liquor cerebrospinalis)
- 4 Processus spinosus
- 5 Conus medullaris
- 6 Cauda equina
- 7 Musculus psoas major
- 8 Foramen intervertebrale
- 9 os ilium
- 10 Rectum
- 11 Colon descendens
- 12 Aorta abdominalis
- 13 Processus articularis superior
- 14 Processus articularis inferior
- 15 Truncus coeliacus
- 16 Arteria mesenterica superior
- 17 Arteria renalis sinistra
- 18 Vena renalis sinistra
- 19 Arteria iliaca communis sinistra
- 20 Vena iliaca communis sinistra
- 21 Arteria iliaca communis dextra
- 22 Vena cava inferior
- 23 Vena iliaca communis dextra
- 24 nervus spinalis S1
- 25 nervus spinalis S2
- 26 nervus spinalis L5
- 27 nervus spinalis L4
- 28 myometrium
- 29 uterus
- 30 endometrium
- 31 musculus quadratus lumborum
- 32 musculus iliocostalis
- 33 musculus longissimus dorsi
- 34 musculi spinospinales
- 35 hepar



- 1 Medulla spinalis
- 2 Discus intervertebralis
- 3 Spatium subarachnoideum (liquor cerebrospinalis)
- 4 Processus spinosus
- 5 Conus medullaris
- 6 Cauda equina
- 7 Musculus psoas major
- 8 Foramen intervertebrale
- 9 os ilium
- 10 Rectum
- 11 Colon descendens
- 12 Aorta abdominalis
- 13 Processus articularis superior
- 14 Processus articularis inferior
- 15 Truncus coeliacus
- 16 Arteria mesenterica superior
- 17 Arteria renalis sinistra
- 18 Vena renalis sinistra
- 19 Arteria iliaca communis sinistra
- 20 Vena iliaca communis sinistra
- 21 Arteria iliaca communis dextra
- 22 Vena cava inferior
- 23 Vena iliaca communis dextra
- 24 nervus spinalis S1
- 25 nervus spinalis S2
- 26 nervus spinalis L5
- 27 nervus spinalis L4
- 28 myometrium
- 29 uterus
- 30 endometrium
- 31 musculus quadratus lumborum
- 32 musculus iliocostalis
- 33 musculus longissimus dorsi
- 34 musculi spinospinales
- 35 hepar



- 1 Medulla spinalis
- 2 Discus intervertebralis
- 3 Spatium subarachnoideum (liquor cerebrospinalis)
- 4 Processus spinosus
- 5 Conus medullaris
- 6 Cauda equina
- 7 Musculus psoas major
- 8 Foramen intervertebrale
- 9 os ilium
- 10 Rectum
- 11 Colon descendens
- 12 Aorta abdominalis
- 13 Processus articularis superior
- 14 Processus articularis inferior
- 15 Truncus coeliacus
- 16 Arteria mesenterica superior
- 17 Arteria renalis sinistra
- 18 Vena renalis sinistra
- 19 Arteria iliaca communis sinistra
- 20 Vena iliaca communis sinistra
- 21 Arteria iliaca communis dextra
- 22 Vena cava inferior
- 23 Vena iliaca communis dextra
- 24 nervus spinalis S1
- 25 nervus spinalis S2
- 26 nervus spinalis L5
- 27 nervus spinalis L4
- 28 myometrium
- 29 uterus
- 30 endometrium
- 31 musculus quadratus lumborum
- 32 musculus iliocostalis
- 33 musculus longissimus dorsi
- 34 musculi spinospinales
- 35 hepar



- 1 Medulla spinalis
- 2 Discus intervertebralis
- 3 Spatium subarachnoideum (liquor cerebrospinalis)
- 4 Processus spinosus
- 5 Conus medullaris
- 6 Cauda equina
- 7 Musculus psoas major
- 8 Foramen intervertebrale
- 9 os ilium
- 10 Rectum
- 11 Colon descendens
- 12 Aorta abdominalis
- 13 Processus articularis superior
- 14 Processus articularis inferior
- 15 Truncus coeliacus
- 16 Arteria mesenterica superior
- 17 Arteria renalis sinistra
- 18 Vena renalis sinistra
- 19 Arteria iliaca communis sinistra
- 20 Vena iliaca communis sinistra
- 21 Arteria iliaca communis dextra
- 22 Vena cava inferior
- 23 Vena iliaca communis dextra
- 24 nervus spinalis S1
- 25 nervus spinalis S2
- 26 nervus spinalis L5
- 27 nervus spinalis L4
- 28 myometrium
- 29 uterus
- 30 endometrium
- 31 musculus quadratus lumborum
- 32 musculus iliocostalis
- 33 musculus longissimus dorsi
- 34 musculi spinospinales
- 35 hepar