

# Skin lesions - terminology

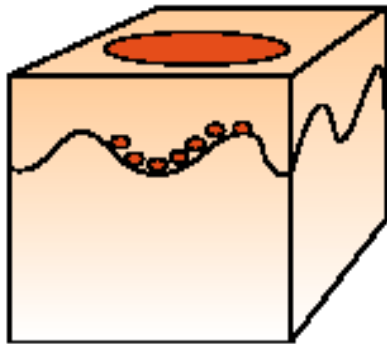


# Skin lesions

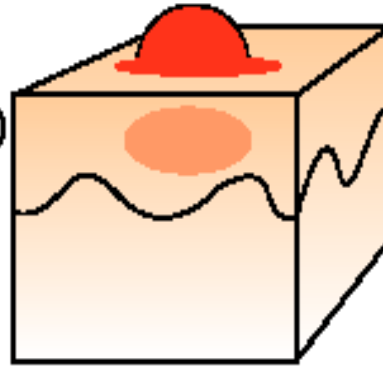
- A **lesion** is any single area of altered **skin**
  - **Primary** - macule, papule, nodule, wheal, vesicle, bulla, pustule
  - **Secondary** – scale, crust, fissure, erosion, excoriation
  - Other –plaque, cyst
- 
- A rash is a widespread eruption of **lesions**
  - Exanthema - generalized, symmetric
  - Enanthema – mucous membranes

Macule –papule- pustule – vesicle –bulla –blister- pomphus-wheal- tuber- nodule

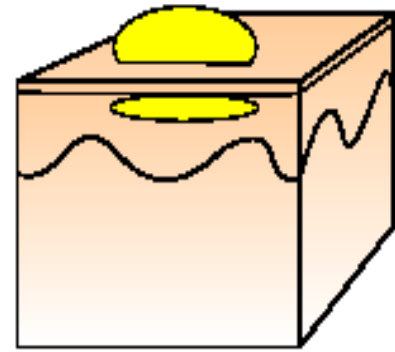
**Makula**  
(Lentigo)



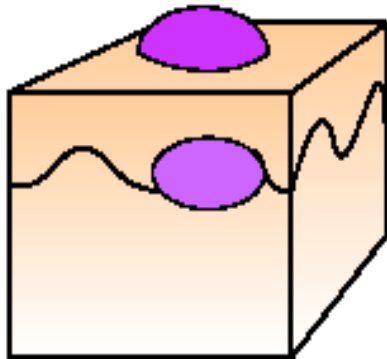
**Papula**  
(Ekzémová)



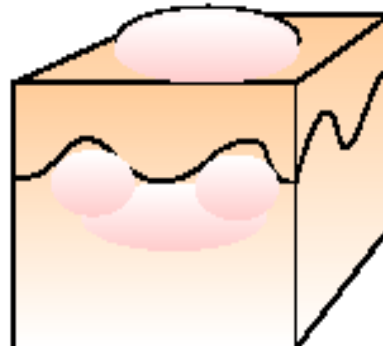
**Pustula**  
(Subkorneální)




**Vezikula**



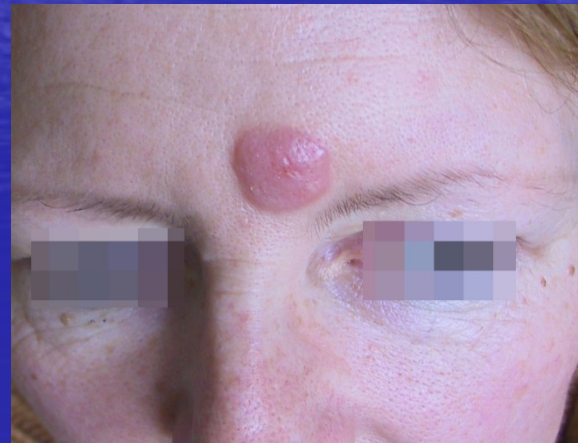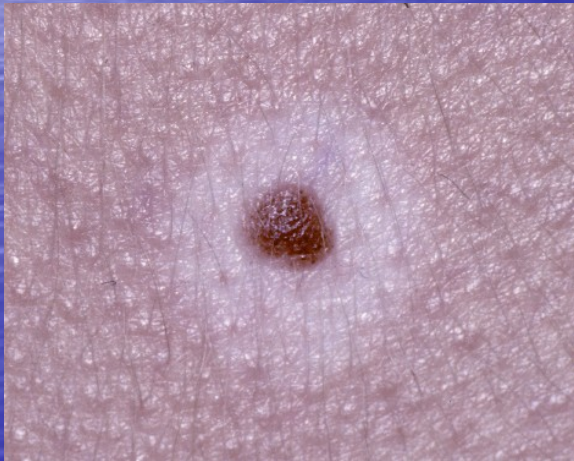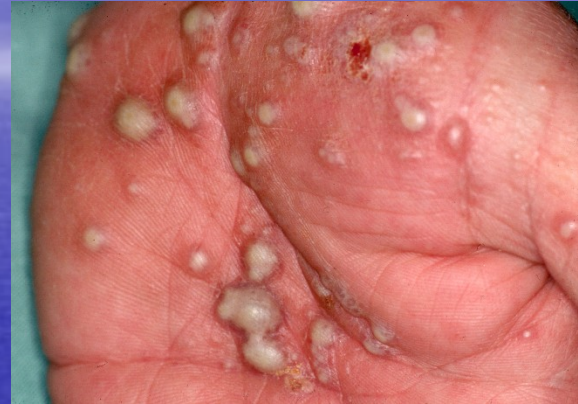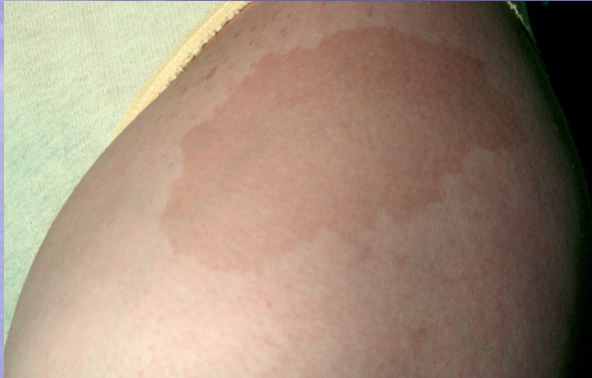**Pomphus**



**Tuber**

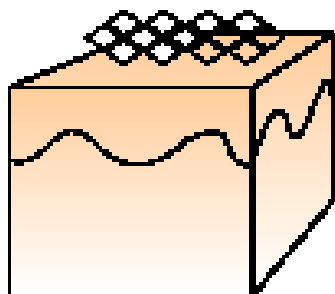




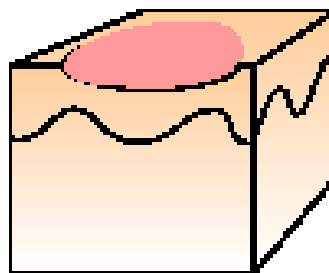


Scale – erosion - excoriation – fissure – ulcer –crust - necrosis

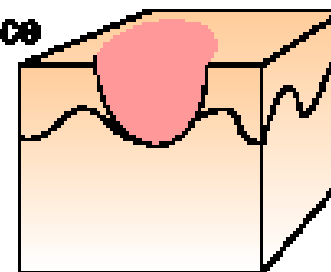
Šupina



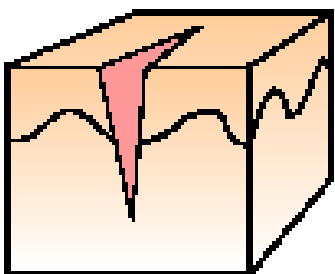
Eroze



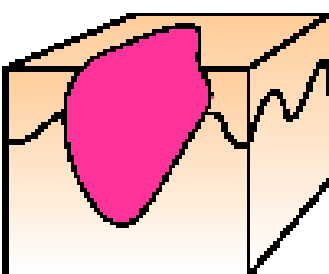
Exkorlace



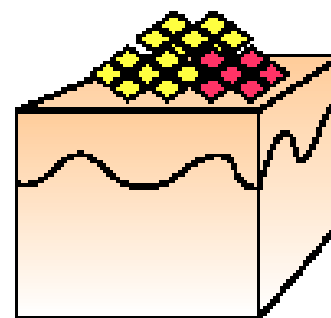
Razgáda



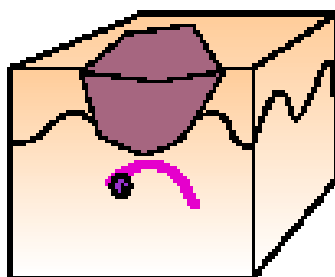
Ulkus



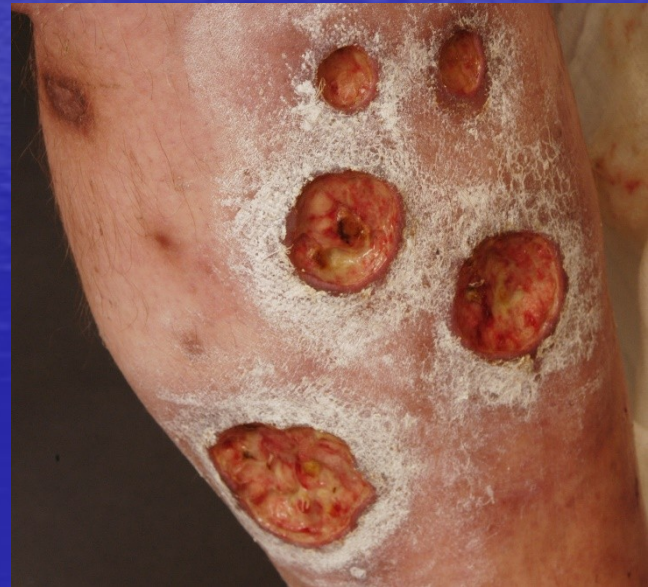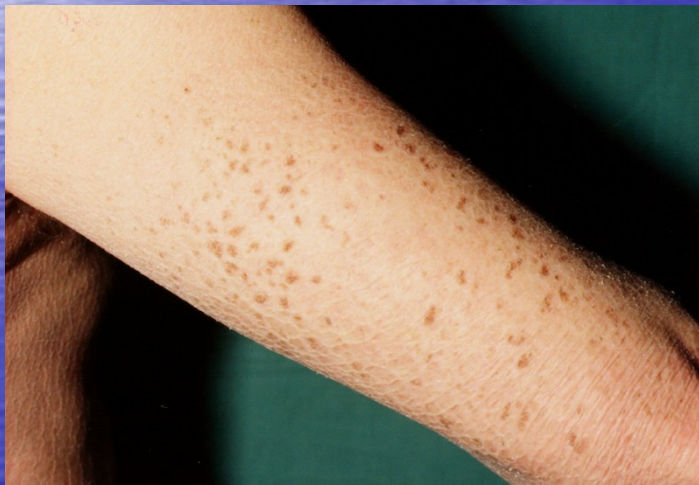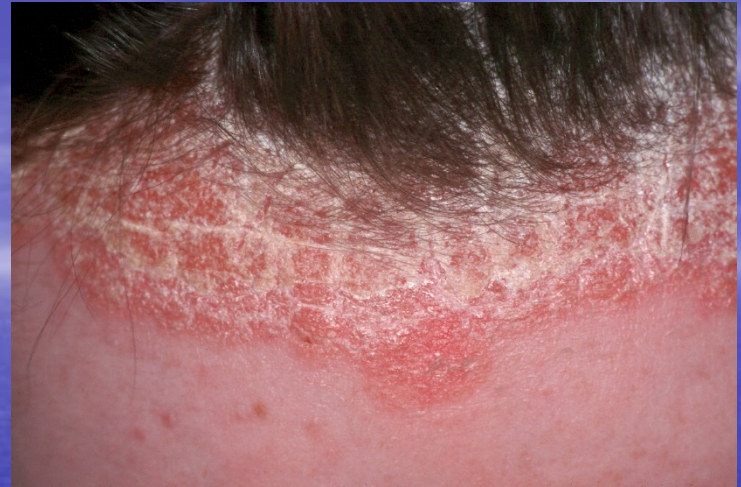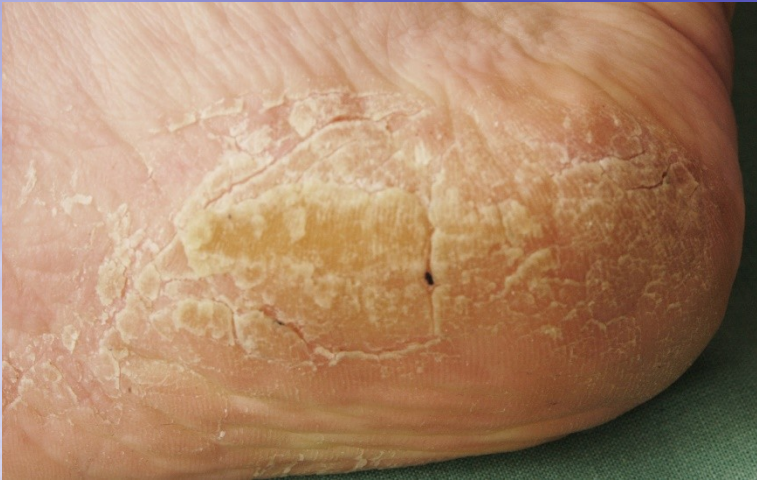Krusta



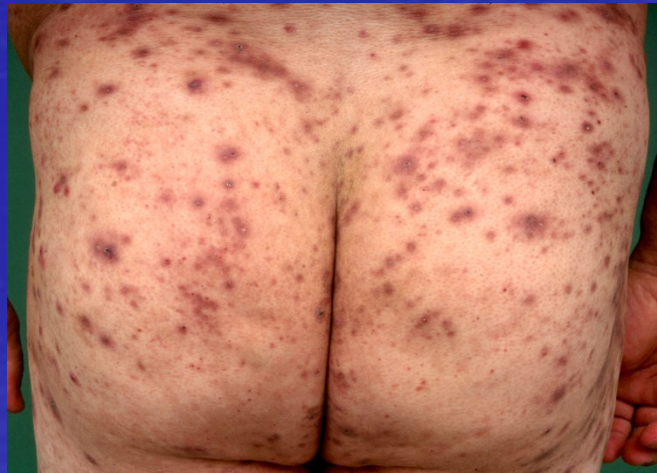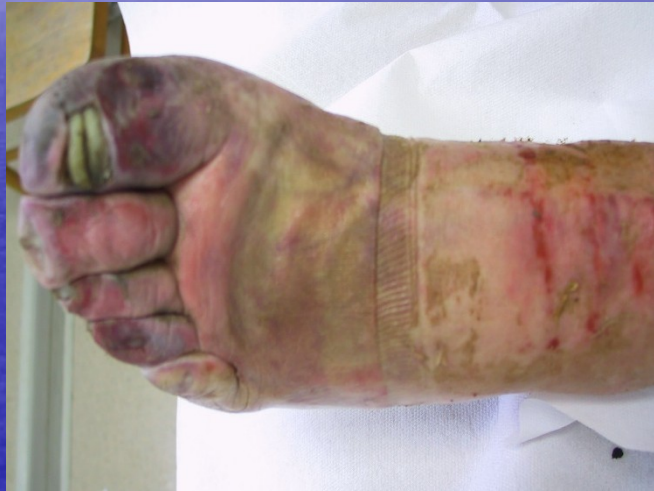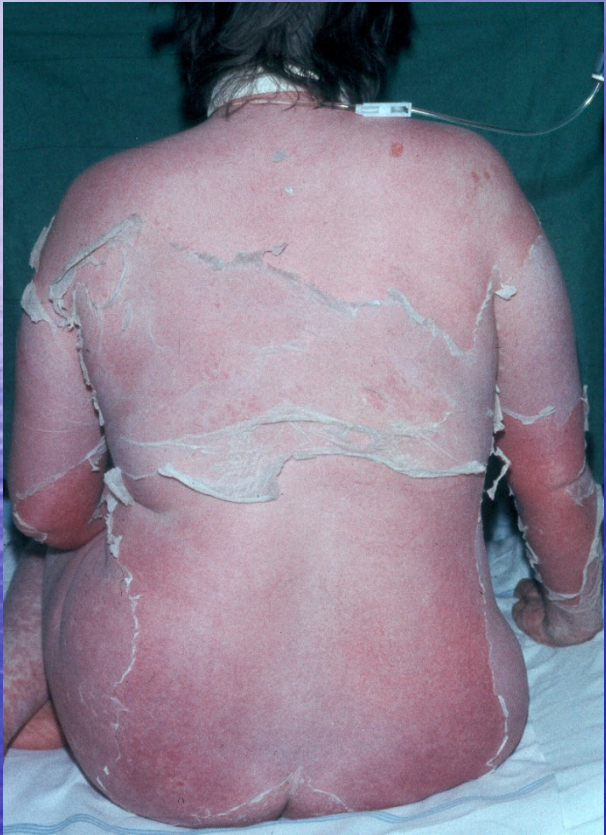Eschara





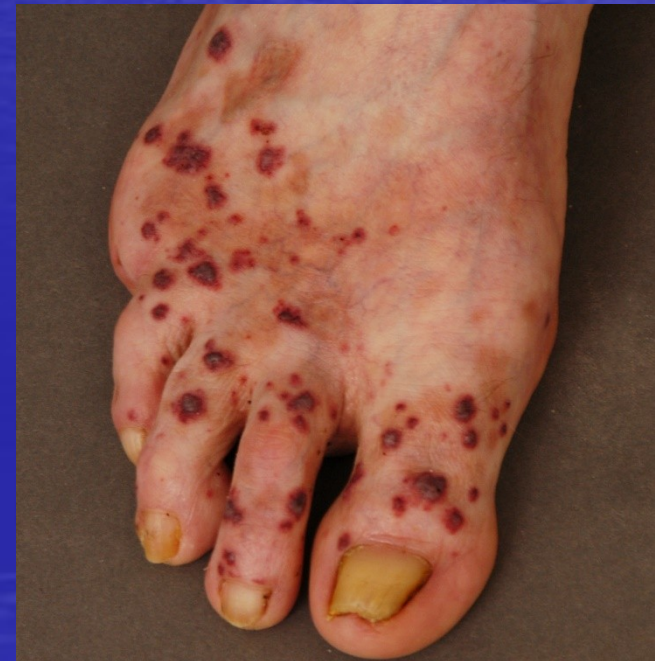
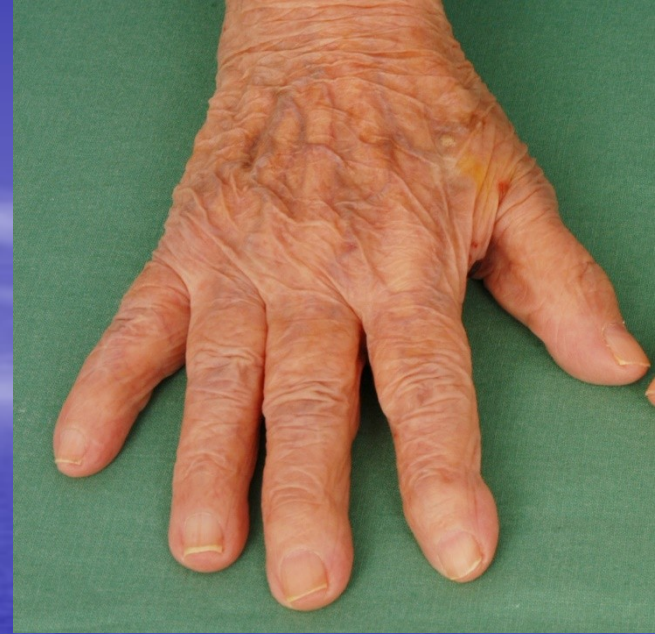






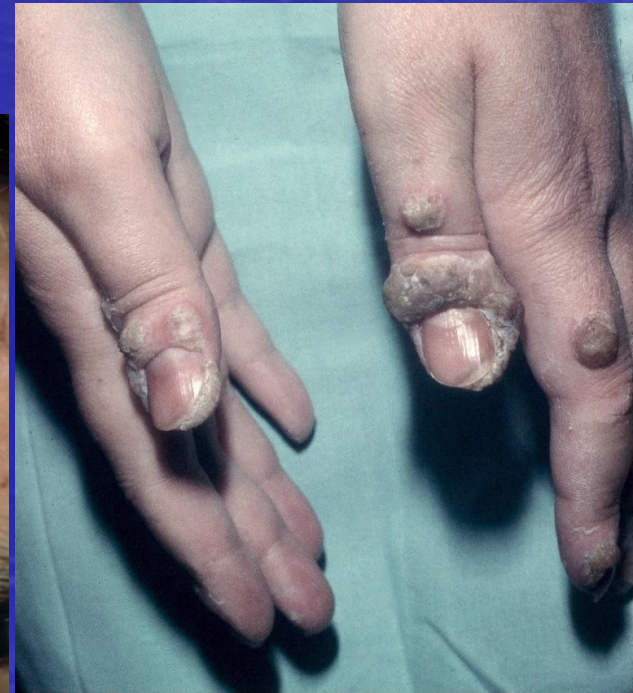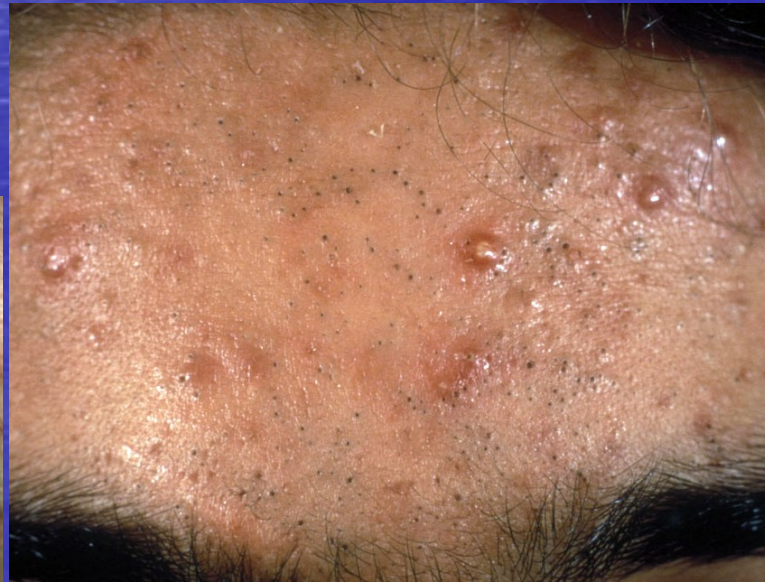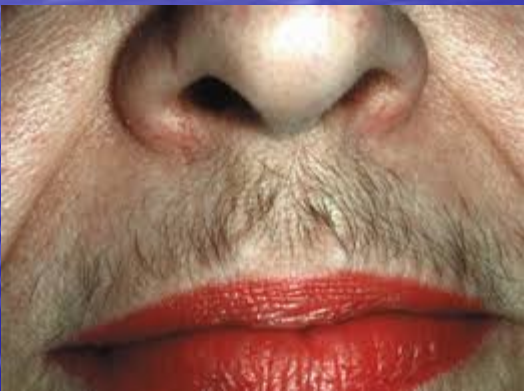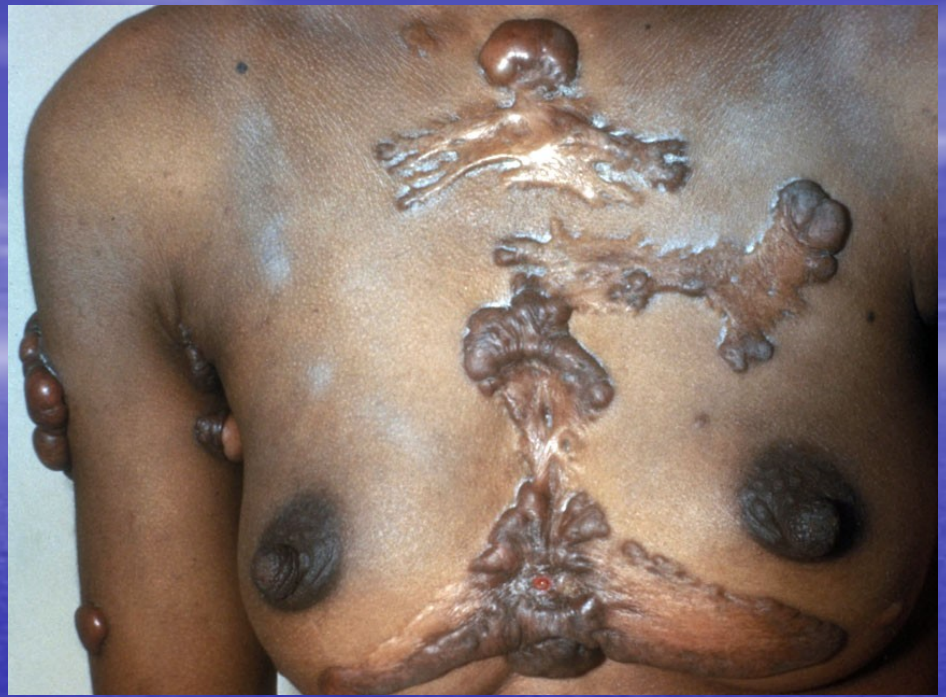- Erythema
- Hyperpigmentation, freckle, lentigo
- Depigmentation
- Sclerosis, scleroderma
- Purpura, ecchymosis, petechia
- Telangiectasia
- Alopecia
- Effluvium diffuse





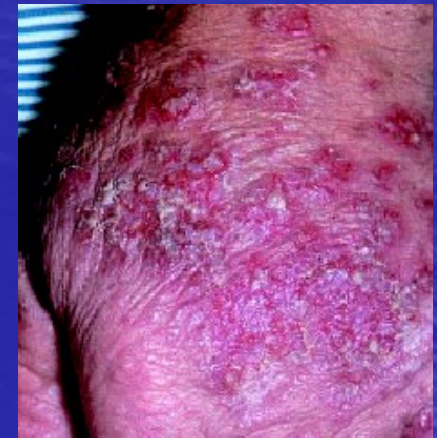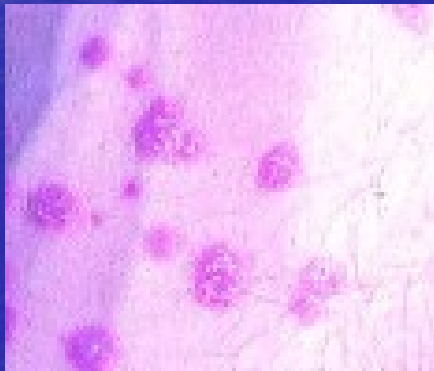
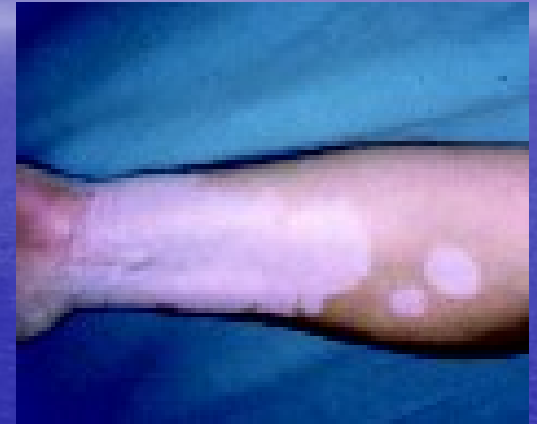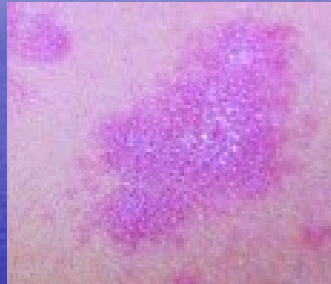- Comedo
- Atrophy, hypertrophy, scar, keloid, stria
- Folliculitis
- Cellulitis
- Hypertrichosis
- Hirsuties
- Lichenification
- Keratosis
- Wart





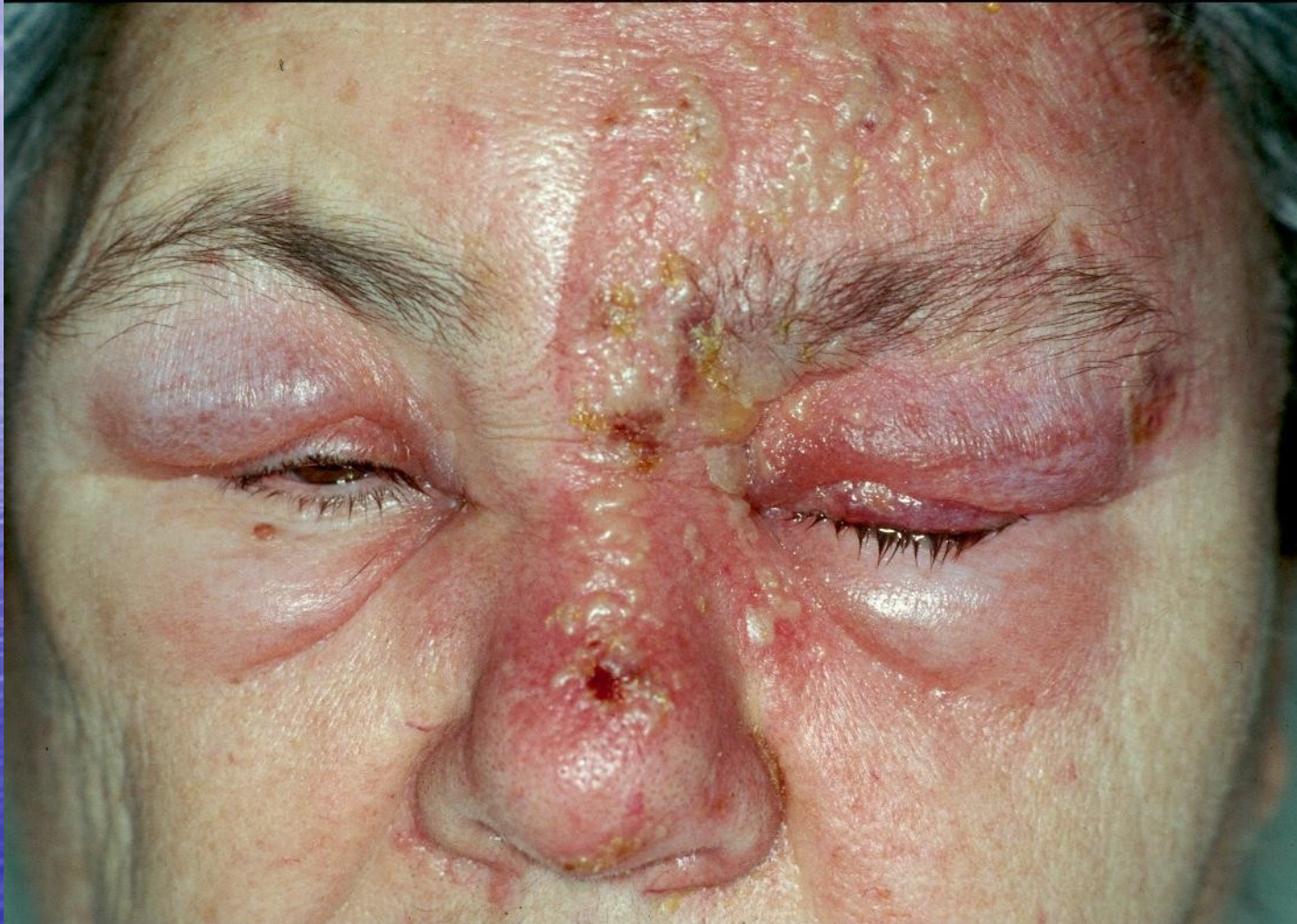# Lesions

- Size
- Colour
- Texture
- Border
- Surface
- Symmetry
- Symptoms





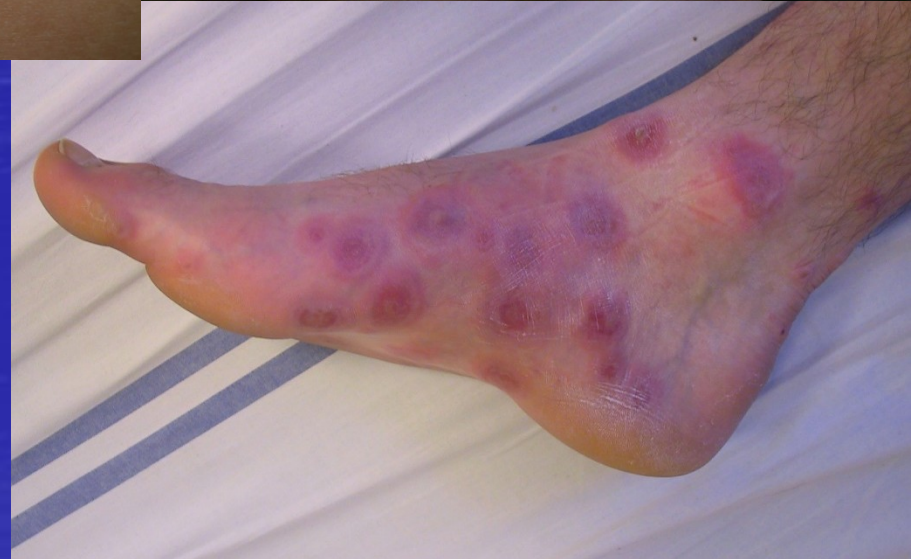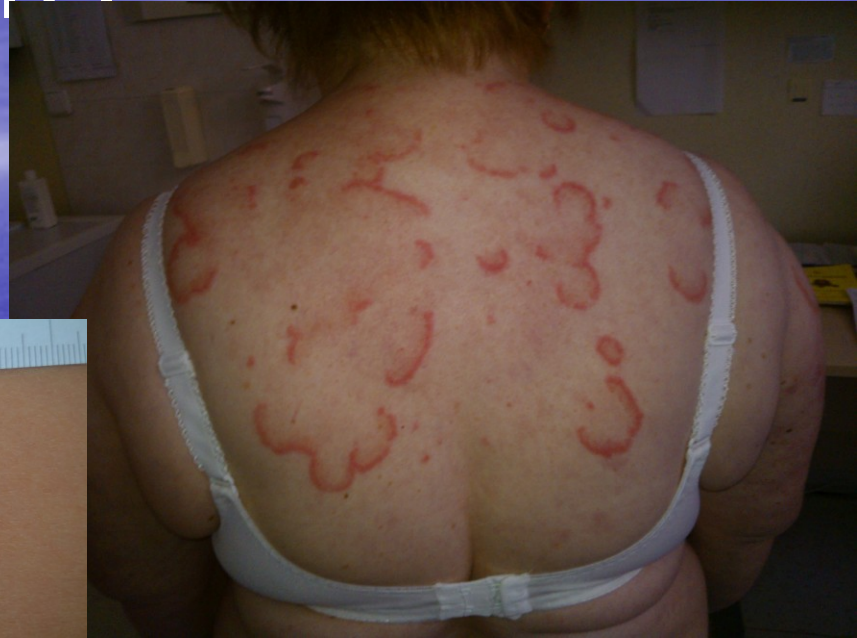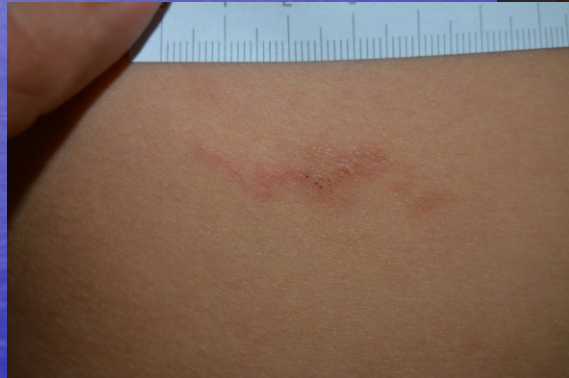# Herpes zoster ophthalmicus





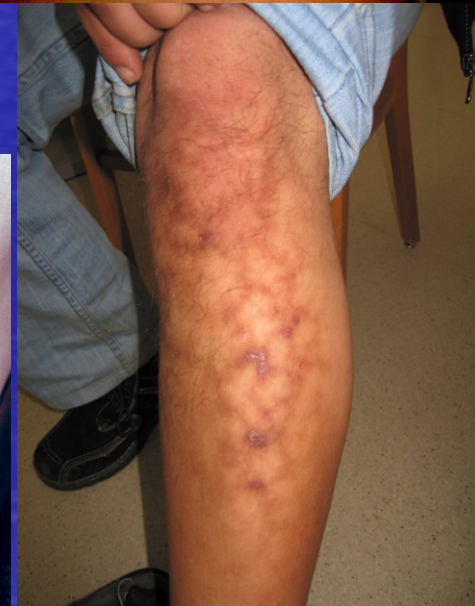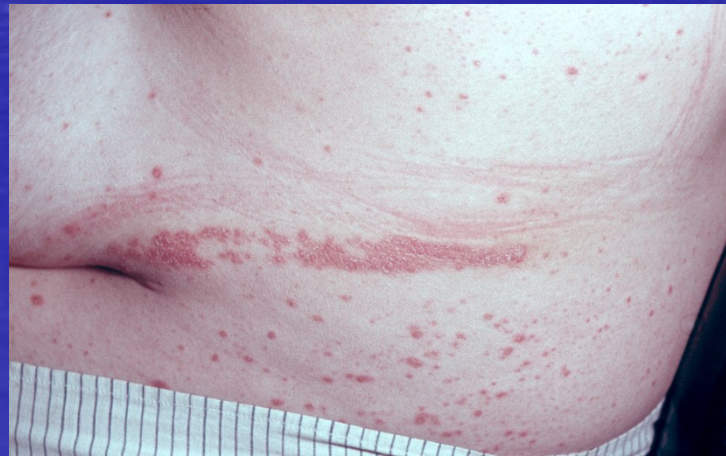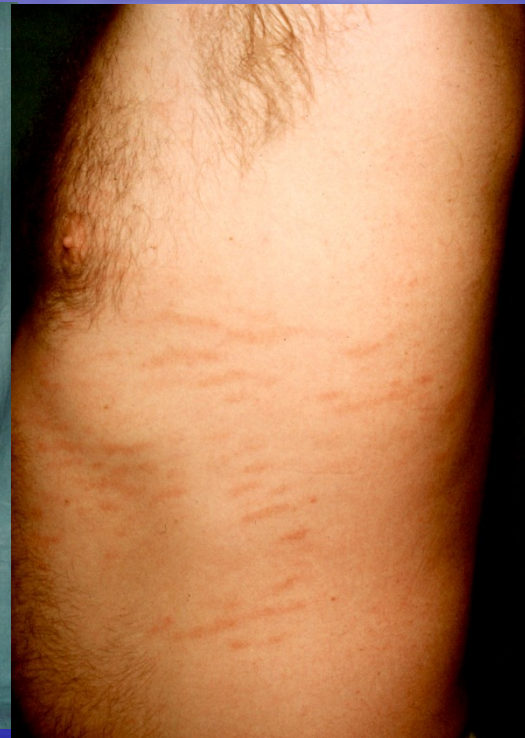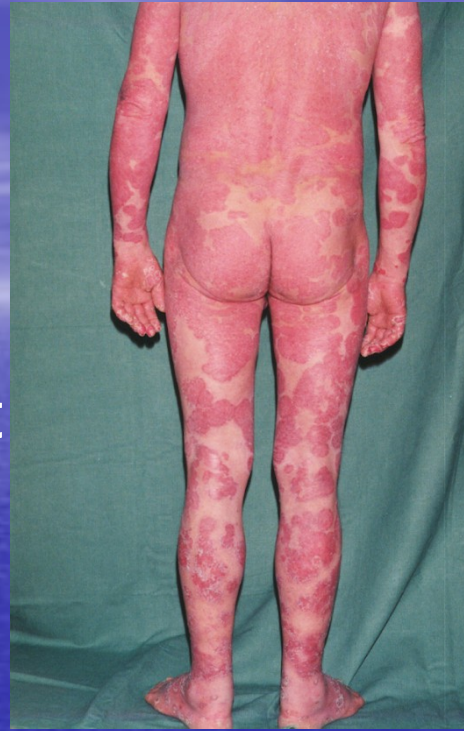# Shapes and patterns

- Annular, circinate, arcuate, polycyclic
- Disseminated
- Follicular
- Geographic
- Herpetiform
- Target
- Linear
- Cribriform
- Nummular and discoid
- Serpiginous
- Zosteriform - dermatomal

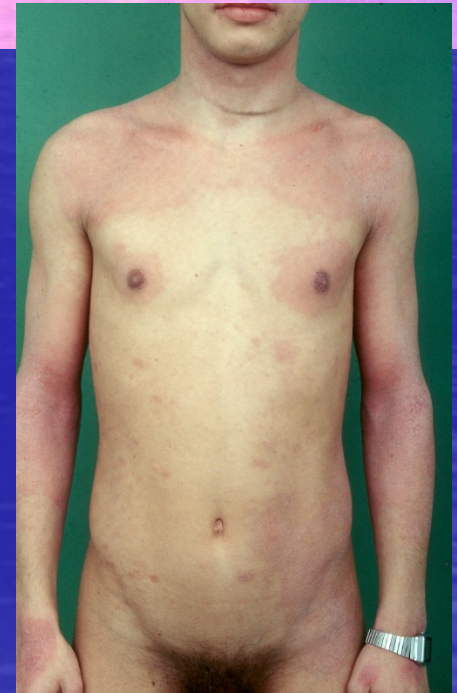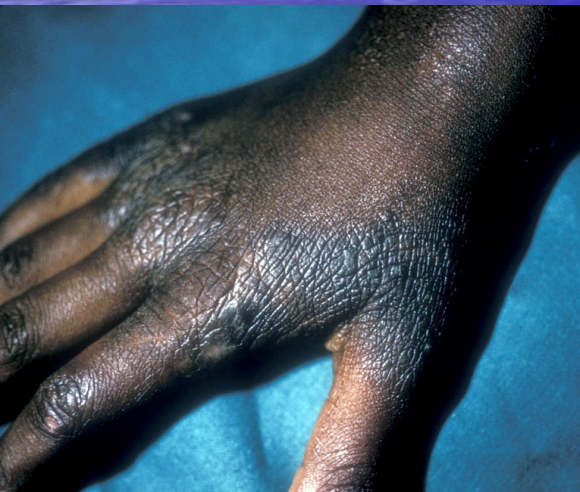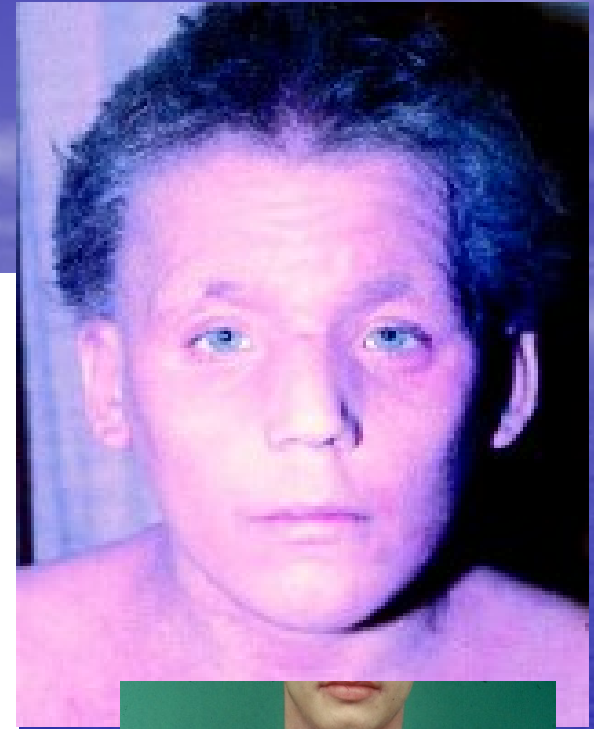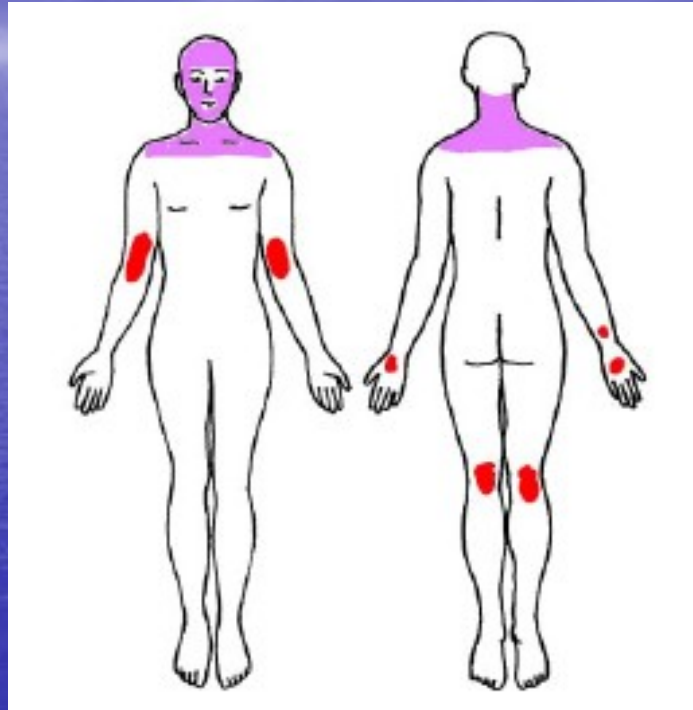
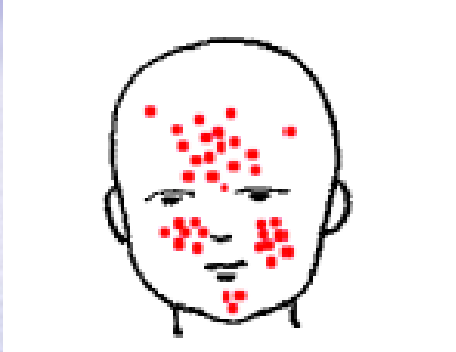




- Generalized – exanthematous, confluent
- Morbilliform
- Oval, digitate –fir tree pattern
- Lymphatic spread
- Koebner phenomenon
- Reticulate
- Livedo
- Erythroderma



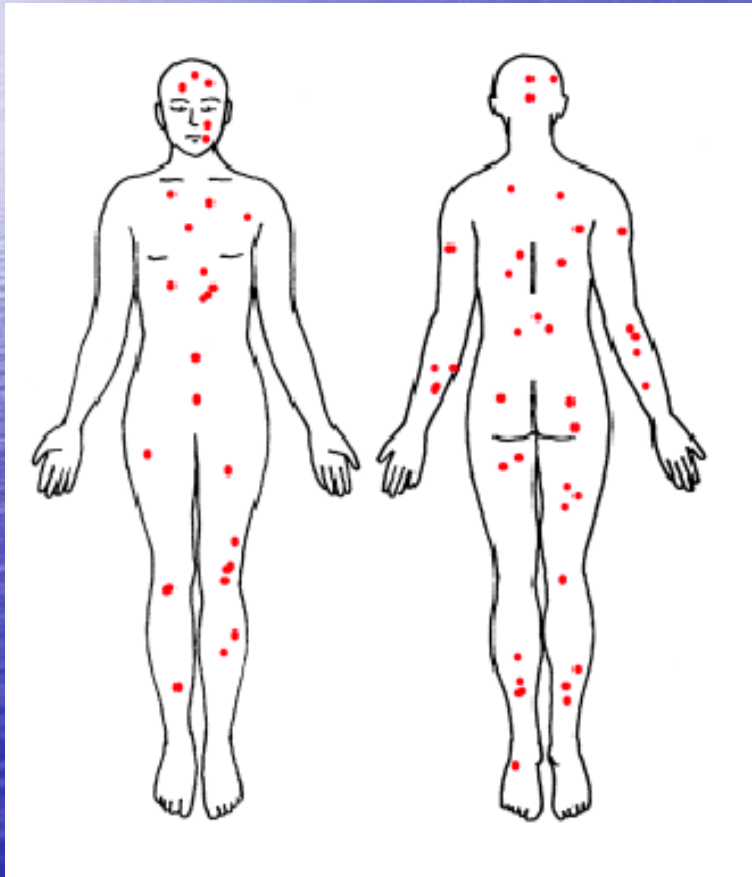
# Atopic dermatitis



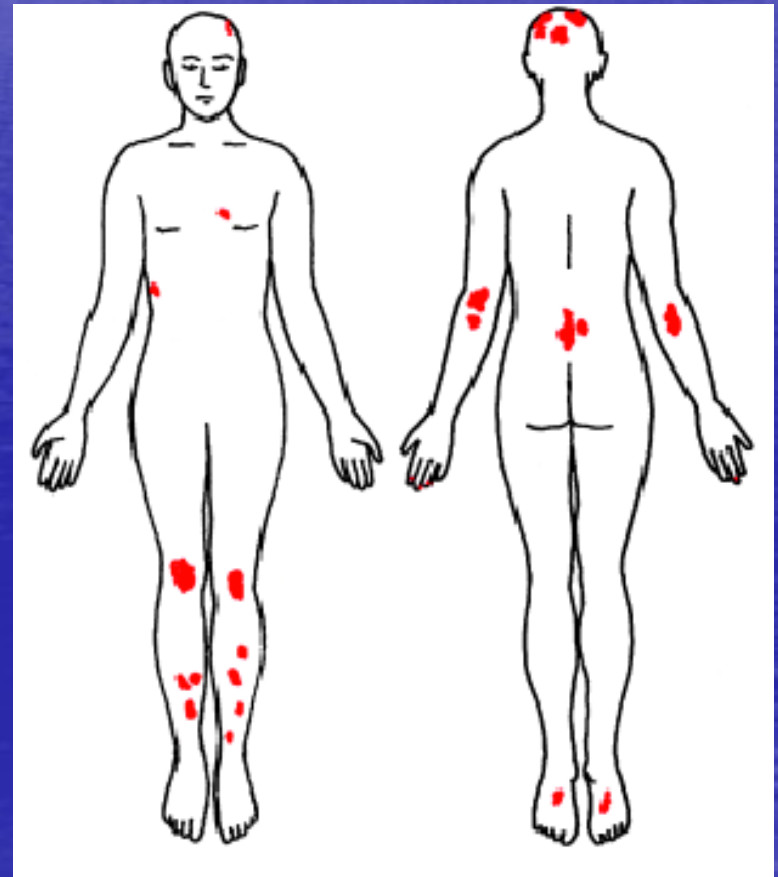


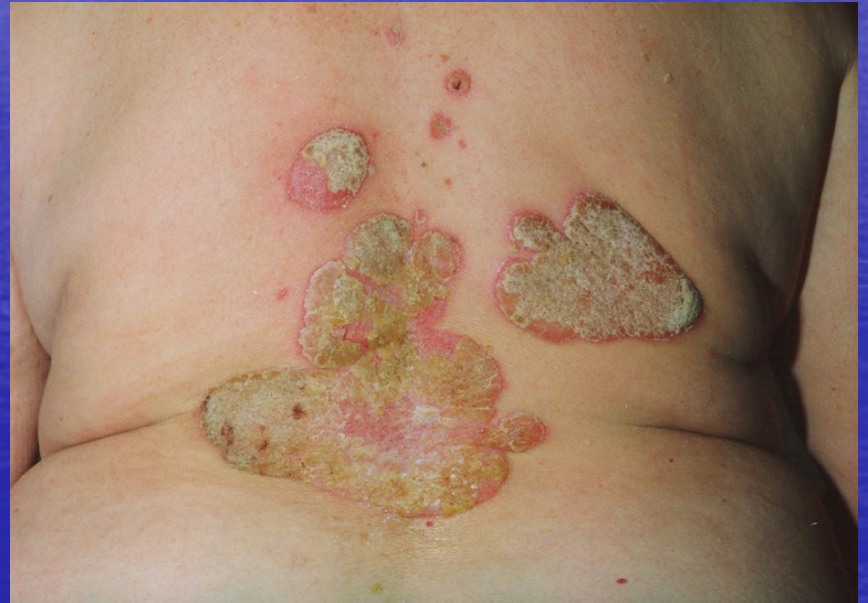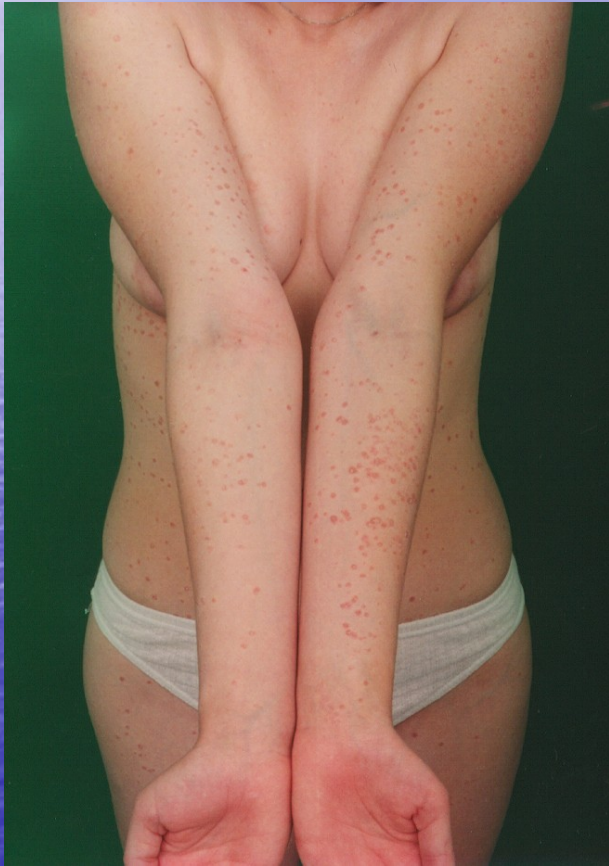# Psoriasis

- acute



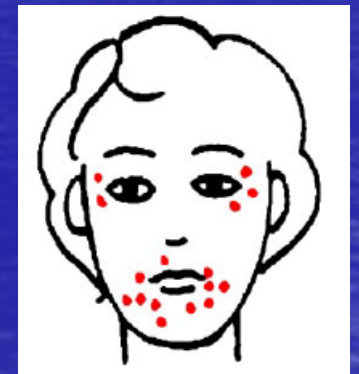
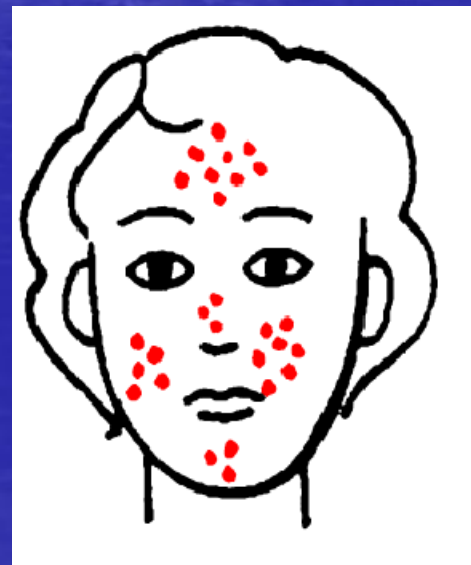
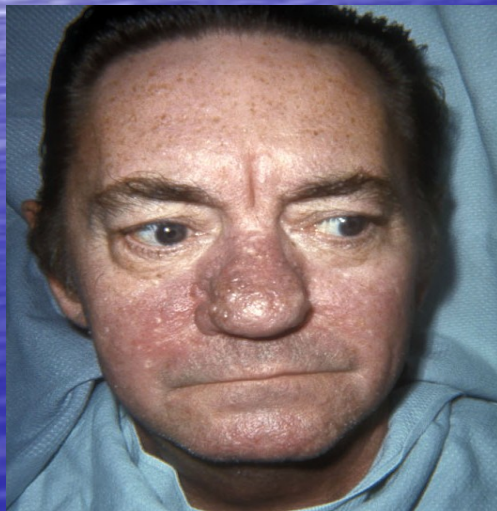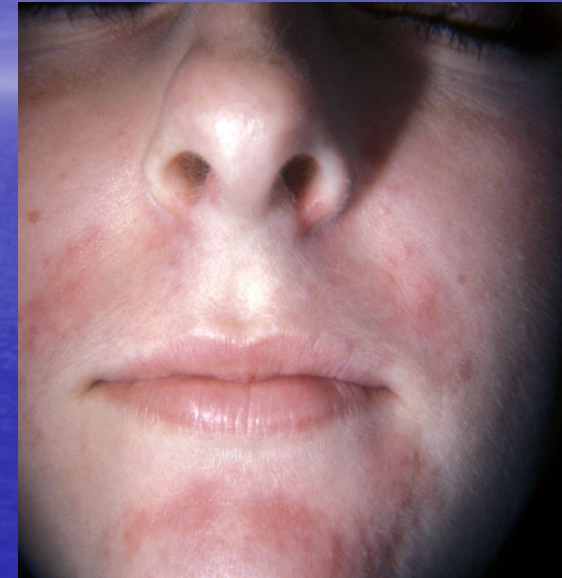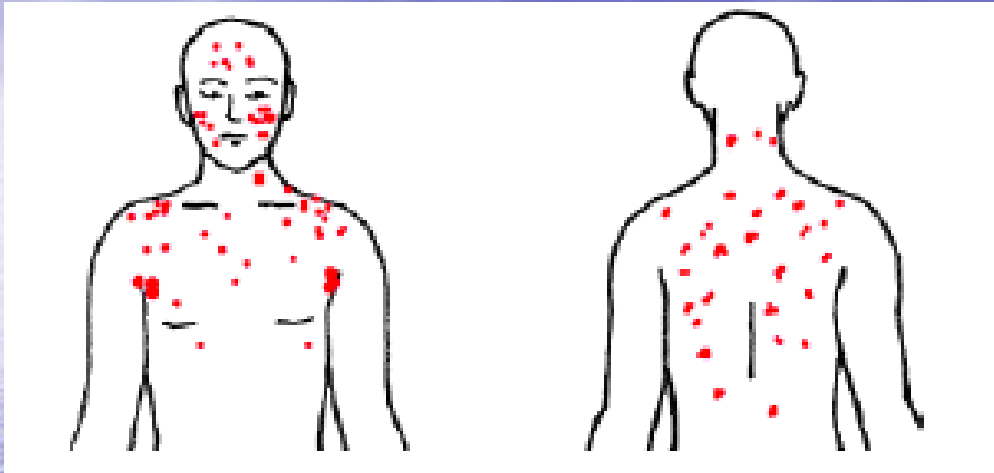
- chronic



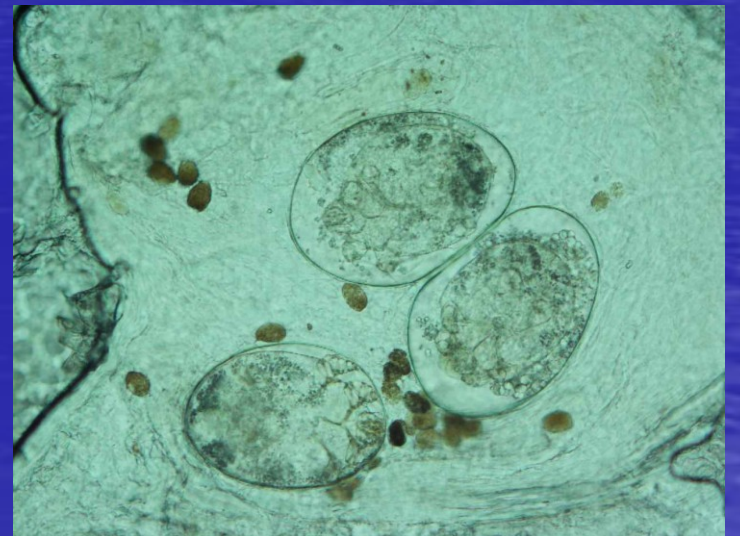
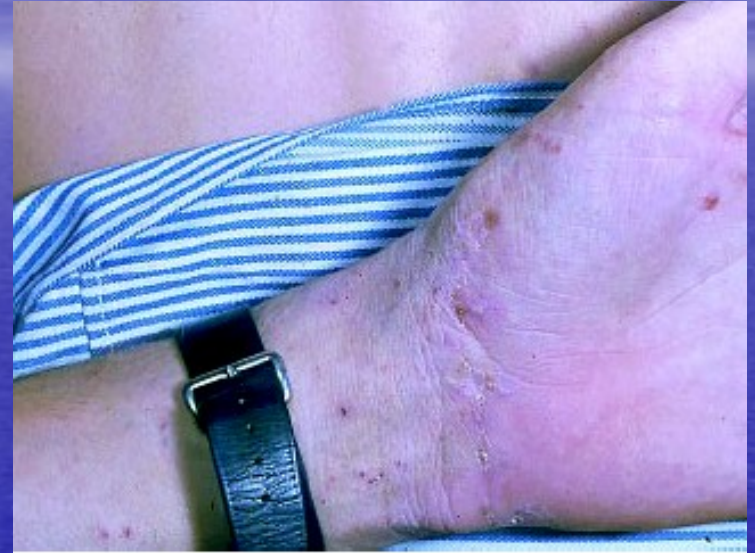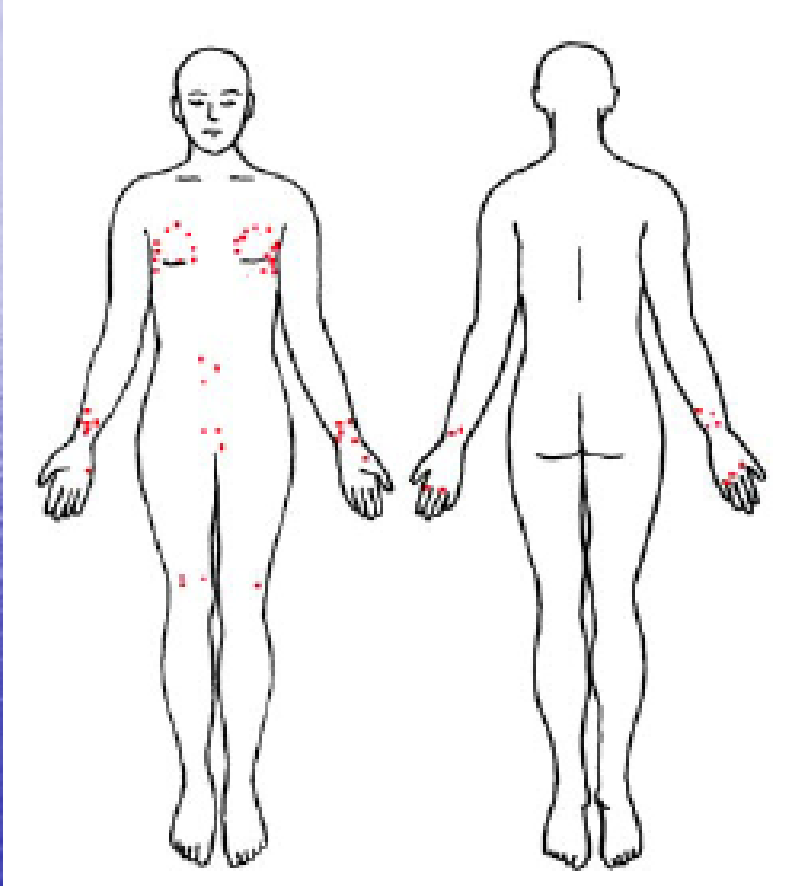




# Acne – rosacea \* perioral dermatitis

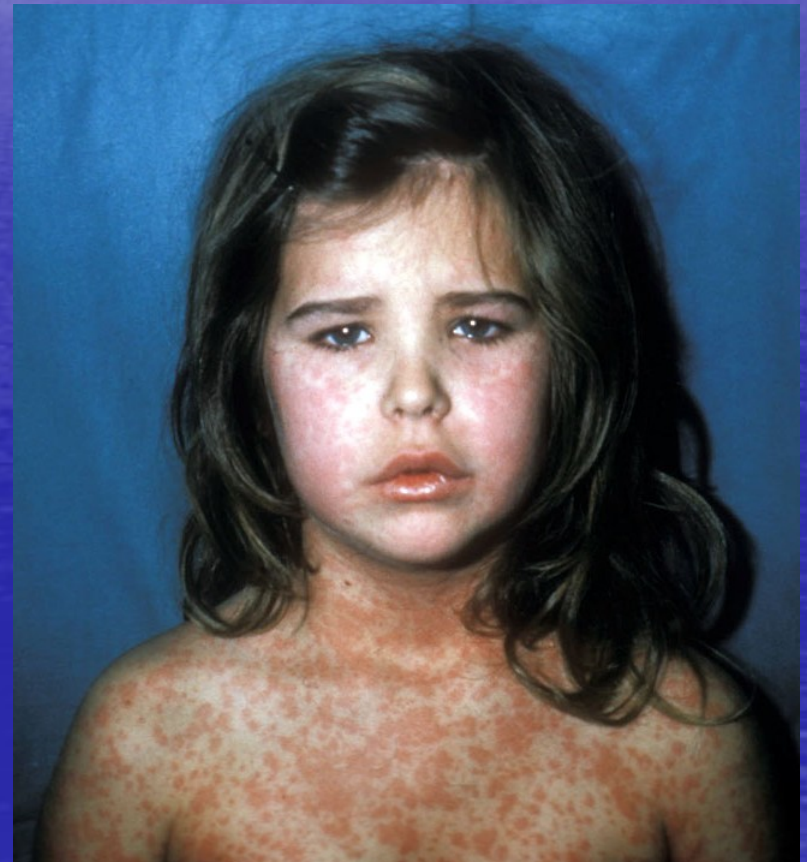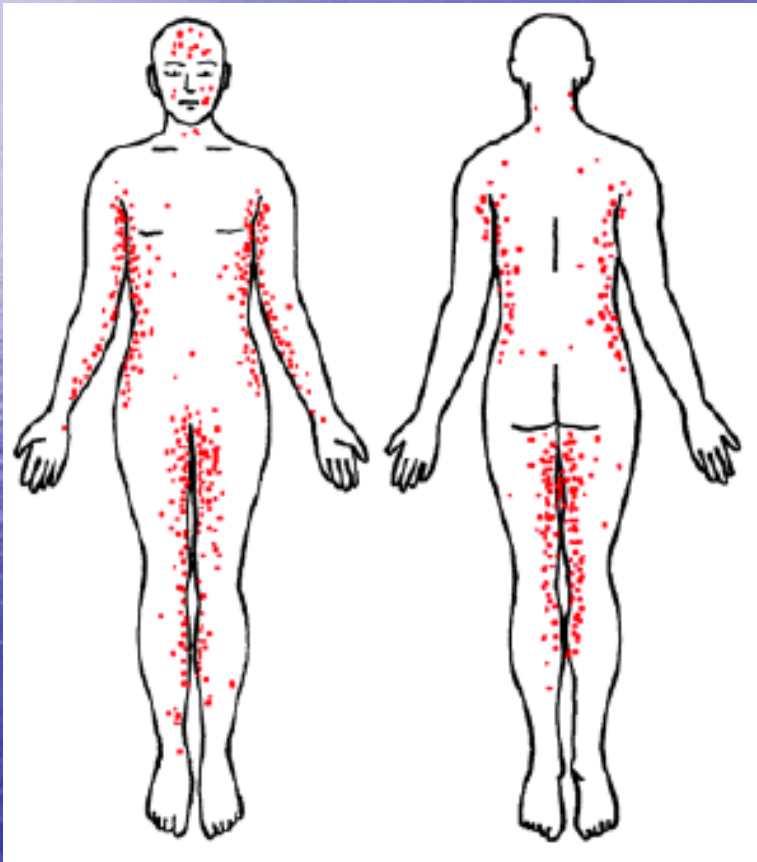


# Scabies

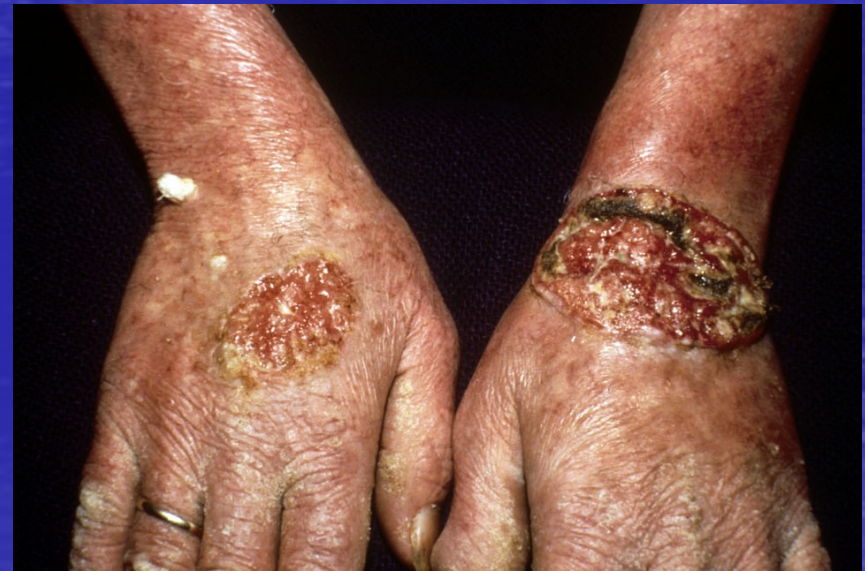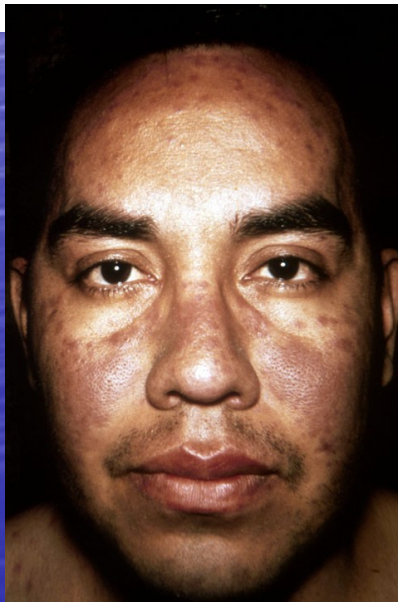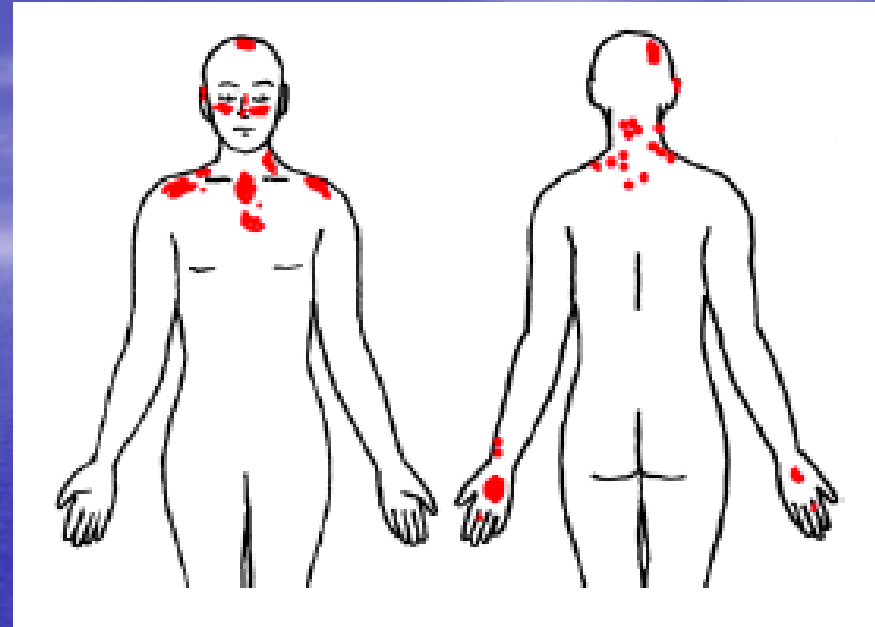
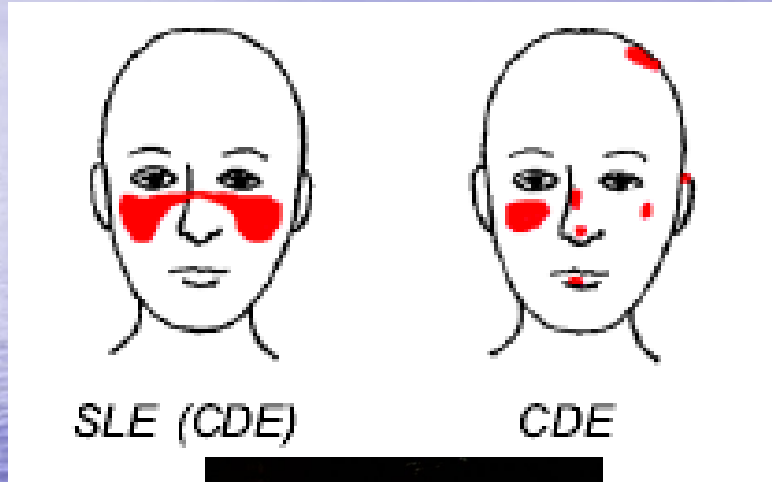




# Drug eruptions

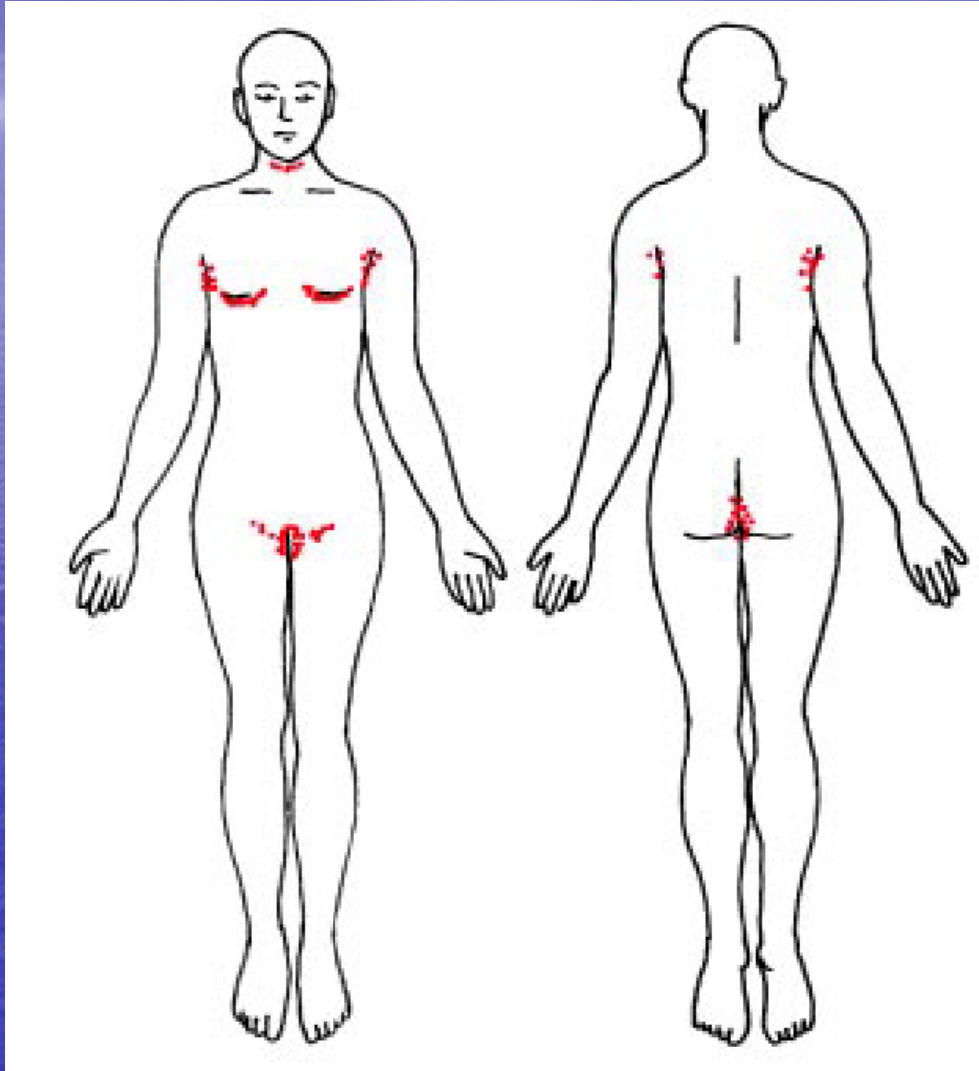


# Photosensitive

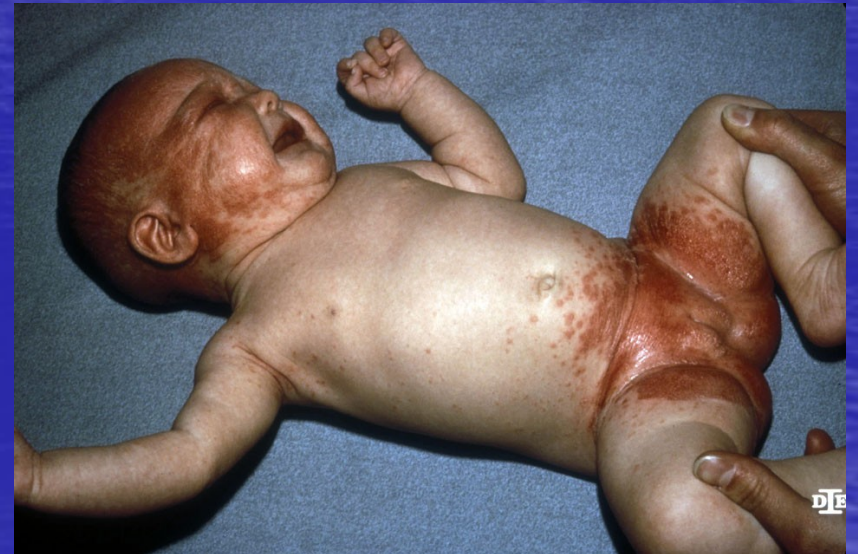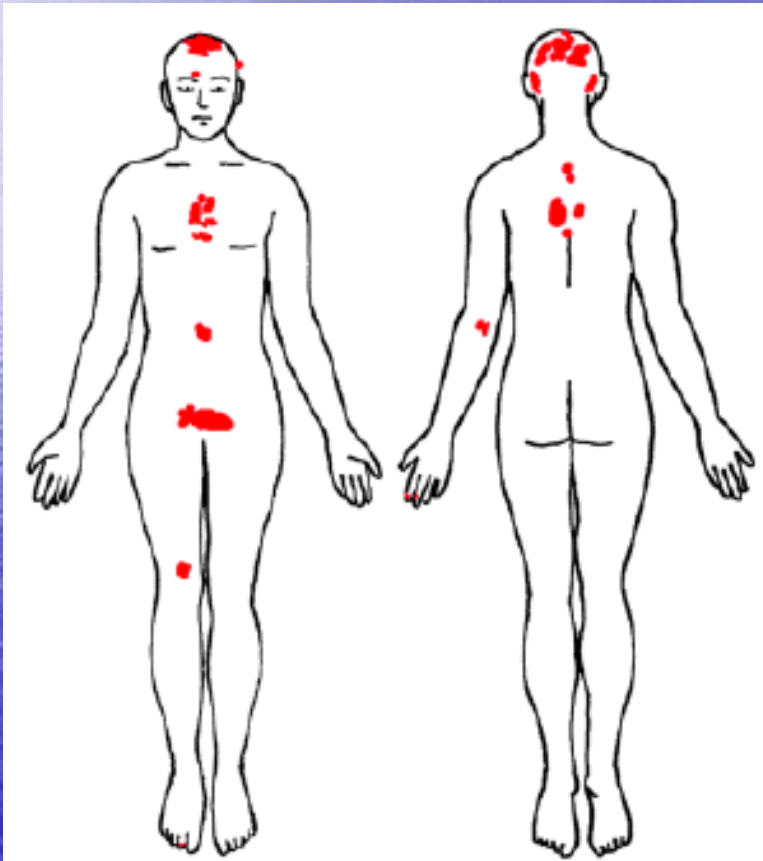

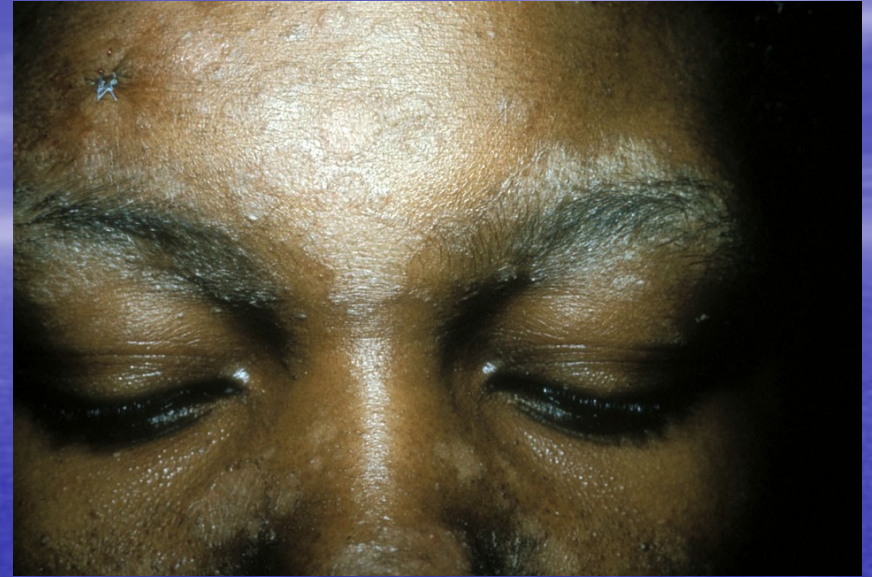


# Intertrigineous



# Seborrhoeic





# Ulcers

