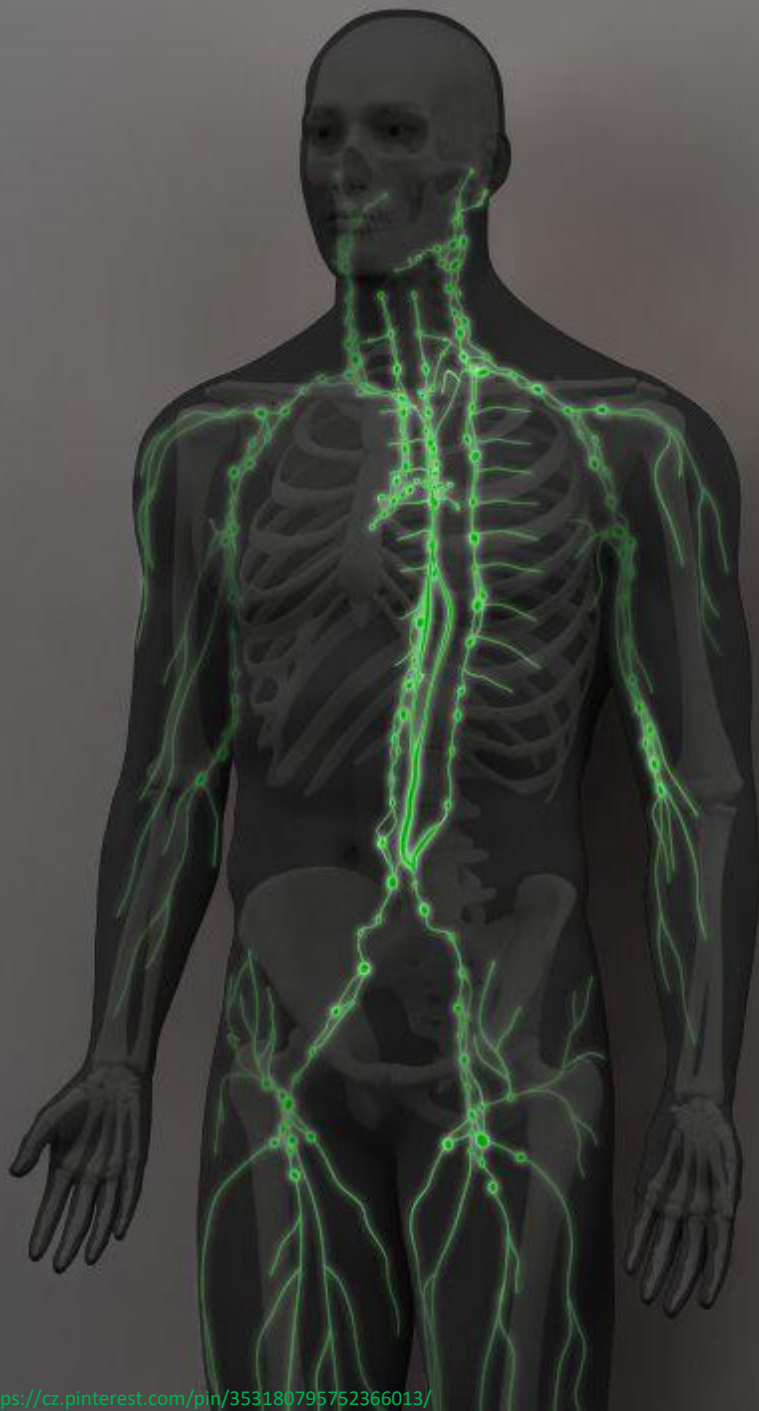

# LYMPHATIC SYSTEM

Petr Vaňhara  
2022

**MUNI** Department  
of Histology  
and Embryology  
**MED**

# LECTURE CONTENT

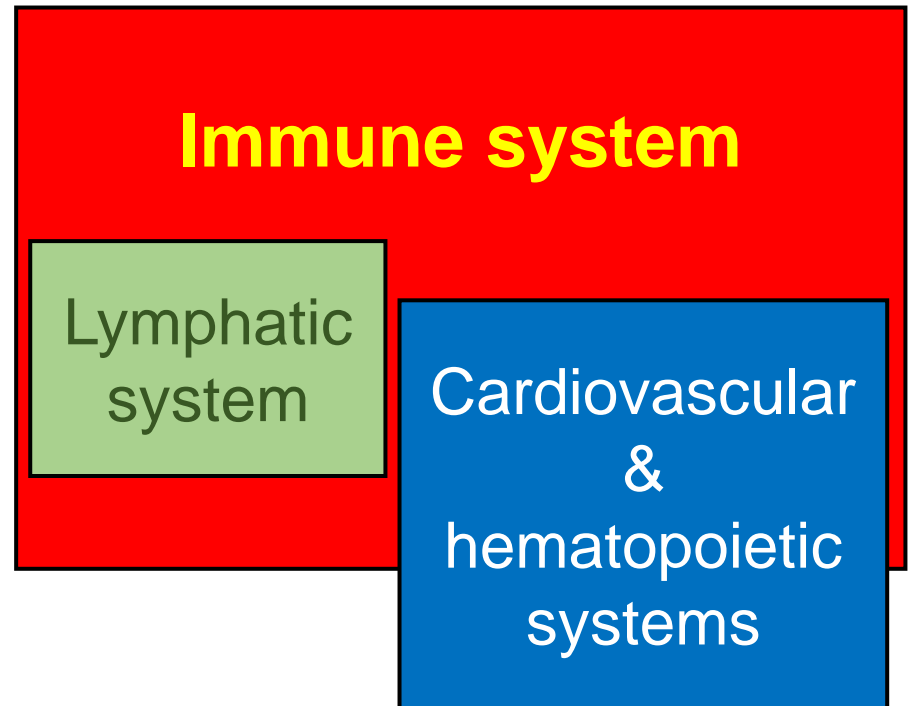
- Principles of immune response
  - Innate and acquired immunity
  - Humoral and cellular immunity

Useful for understanding

- Structures essential for functioning of immune system

- Lymphatic circuitry
- Lymphatic follicles
- Lymph nodes
- Spleen
- Thymus
- MALT

Important for our course



- Development of lymphatic system

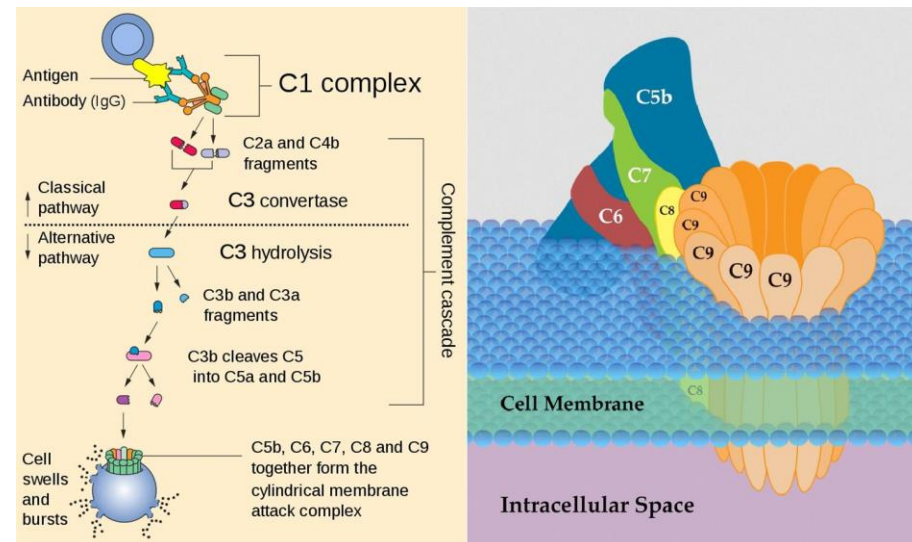
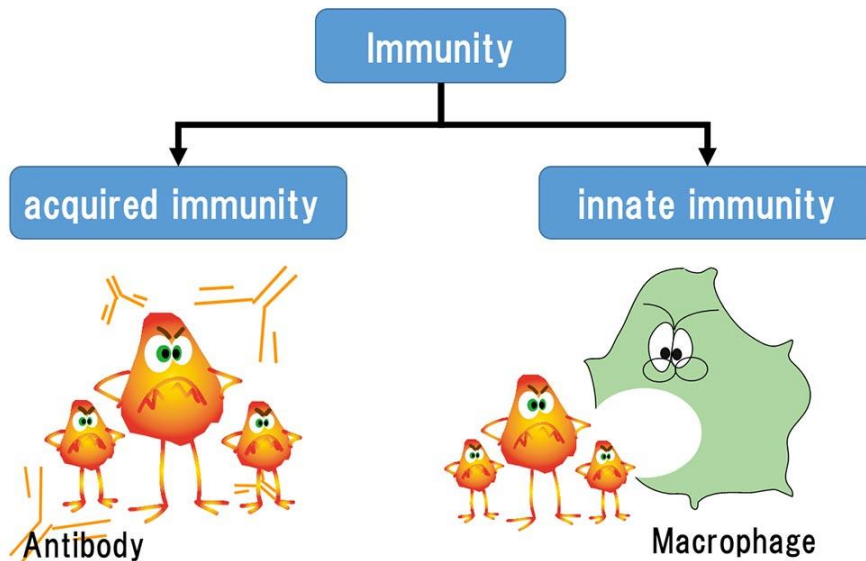
# IMMUNE SYSTEM

## Immunity = self defense

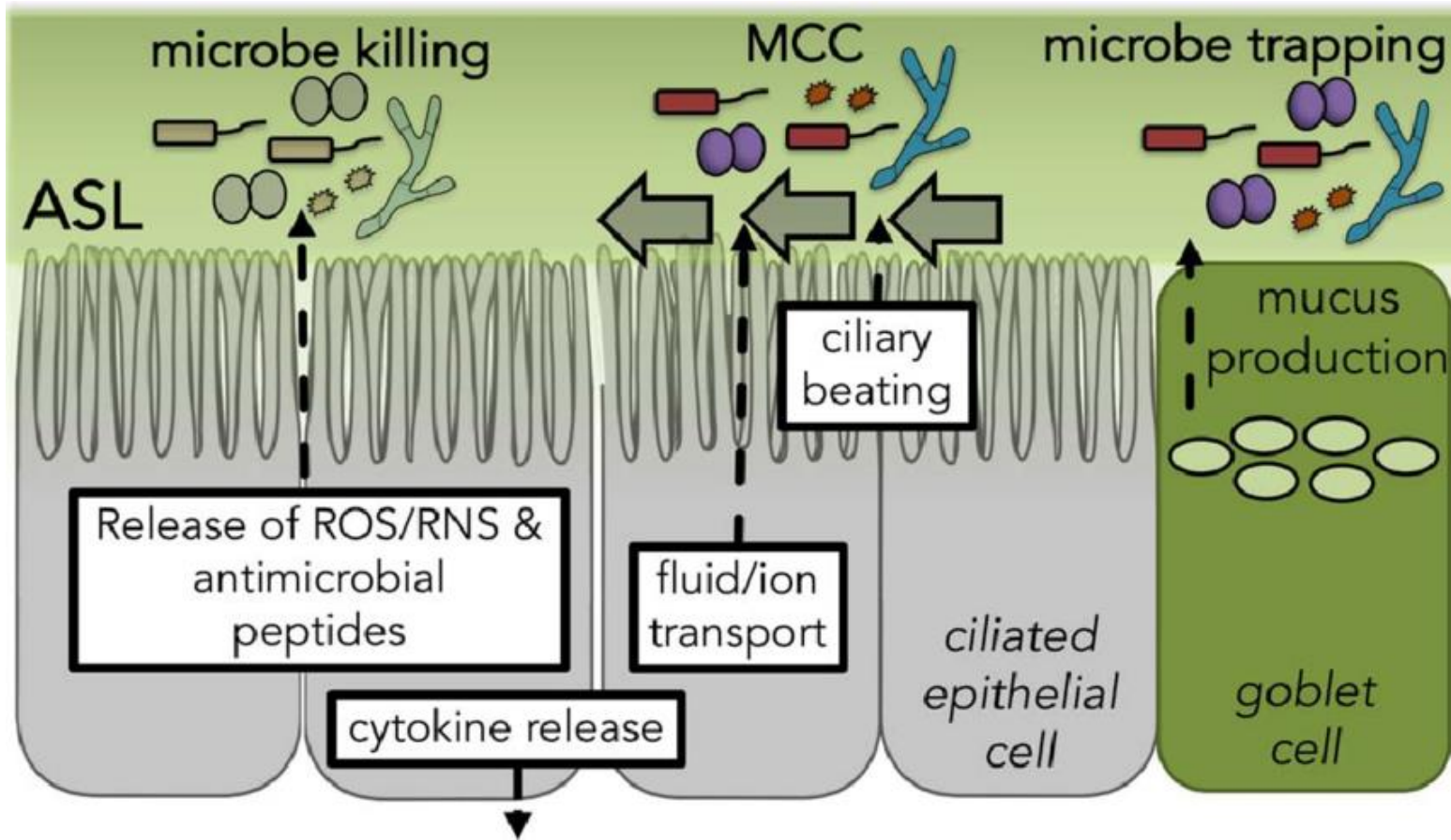
- **Epithelial:** epithelial barriers equipped with antimicrobial substances
- **Innate:** complement, macrophages and neutrophils, natural killers
- **Acquired:** T and B lymphocytes

## Clinical relevance?

- Autoimmune disorders
- Immunodeficiency

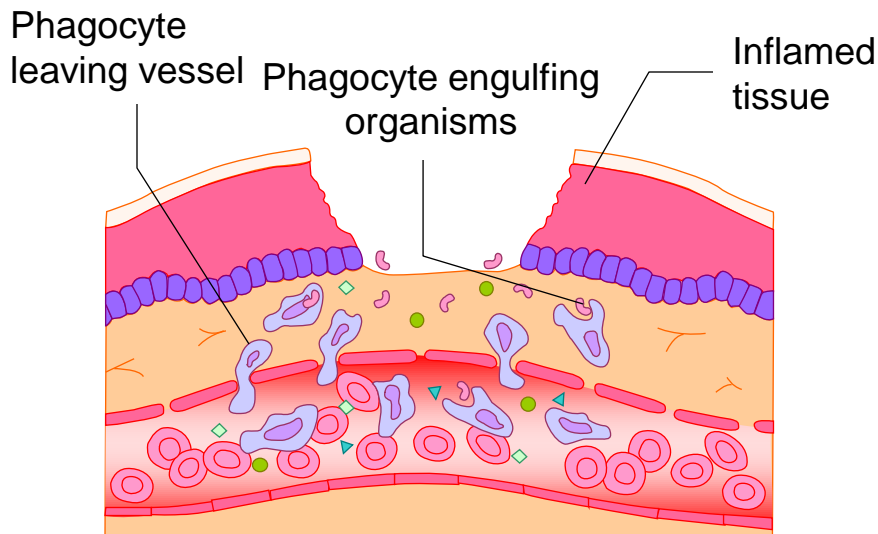
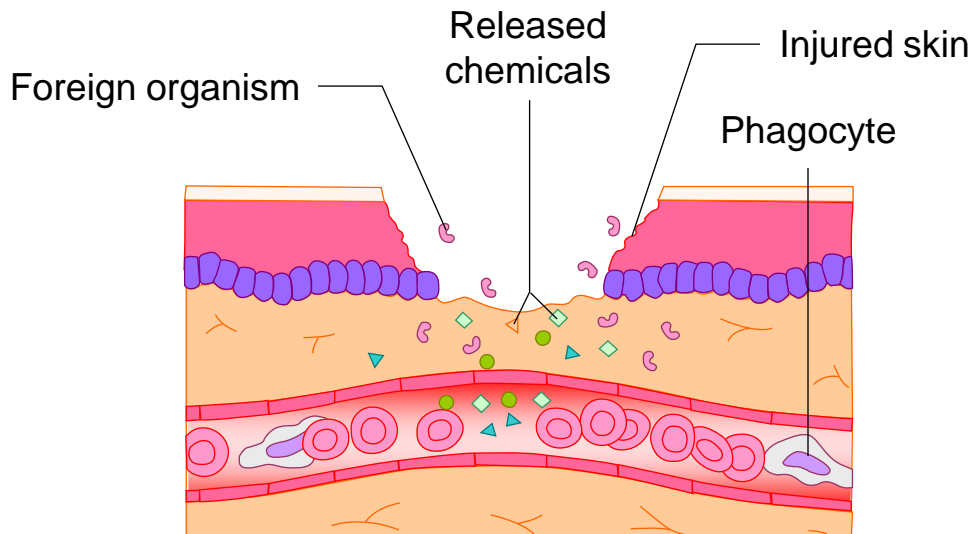


# EPITHELIAL IMMUNE RESPONSE




## EPITHELIUM OF RESPIRATORY PASSAGES

# EPITHELIAL INFLAMMATORY RESPONSE

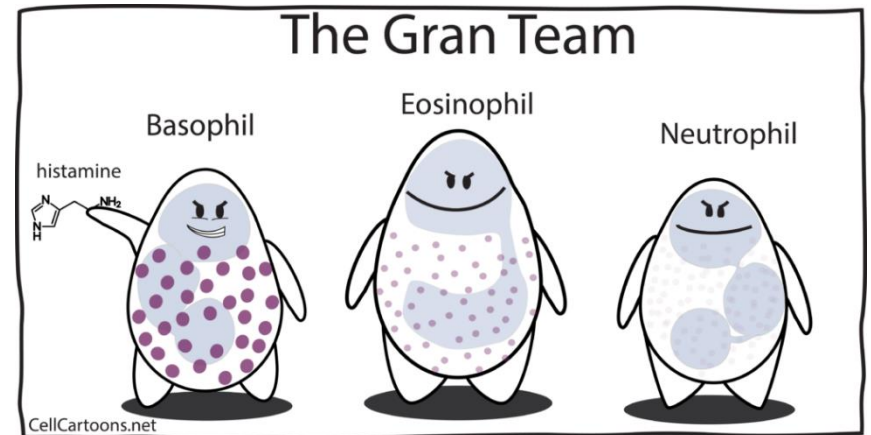

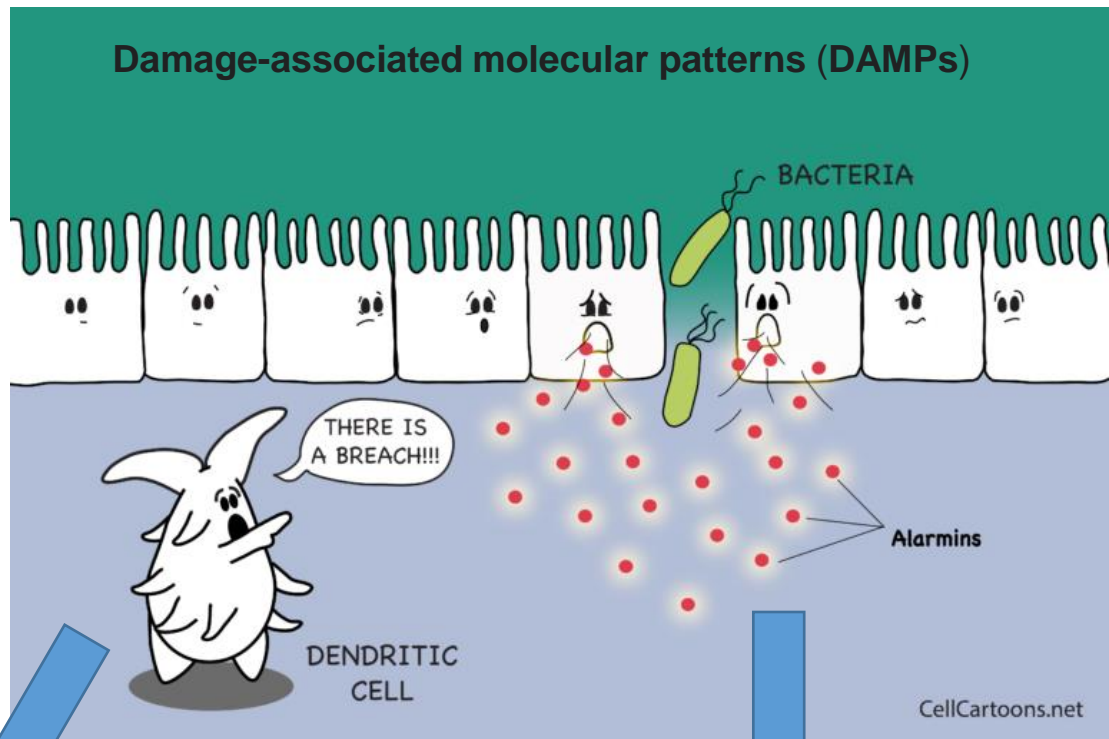


- Chemotaxis and extravasation of leukocytes, mostly neutrophils, monocytes and dendritic cells to the site of inflammation
- Pro-inflammatory cytokines
  - interleukins (e.g. IL-1, IL-8)
  - TNF $\alpha$ , TGF $\beta$
  - interferons
- Other signaling molecules
  - prostaglandins
  - GM-CSF, M-CSF

and many others

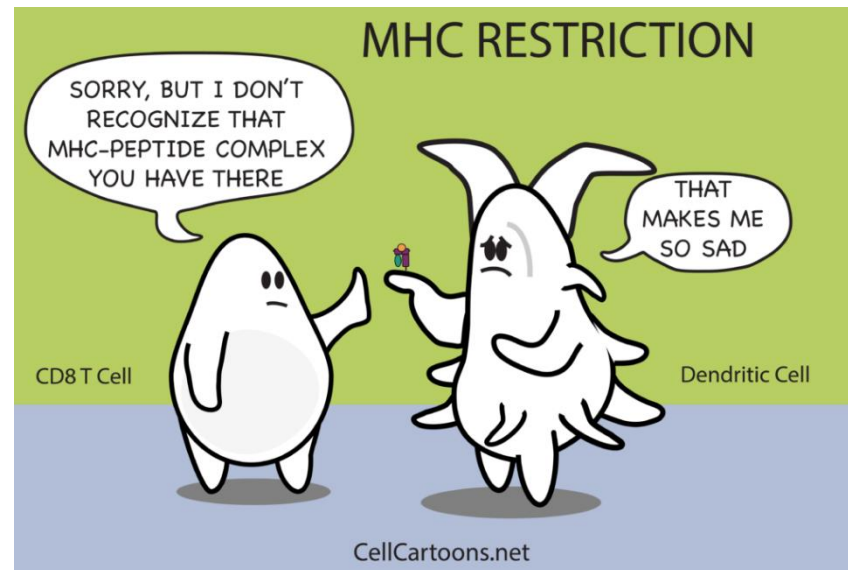
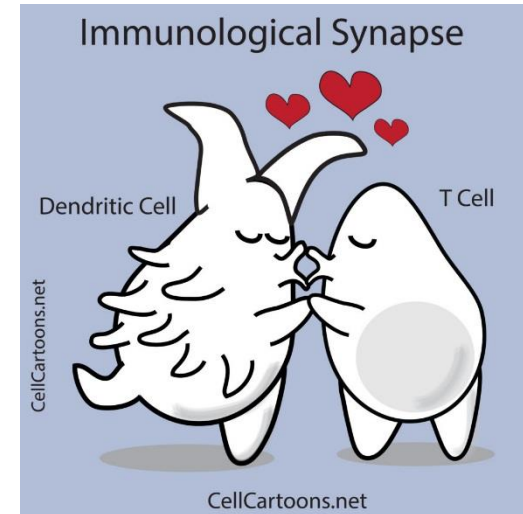


# EPITHELIAL IMMUNE RESPONSE

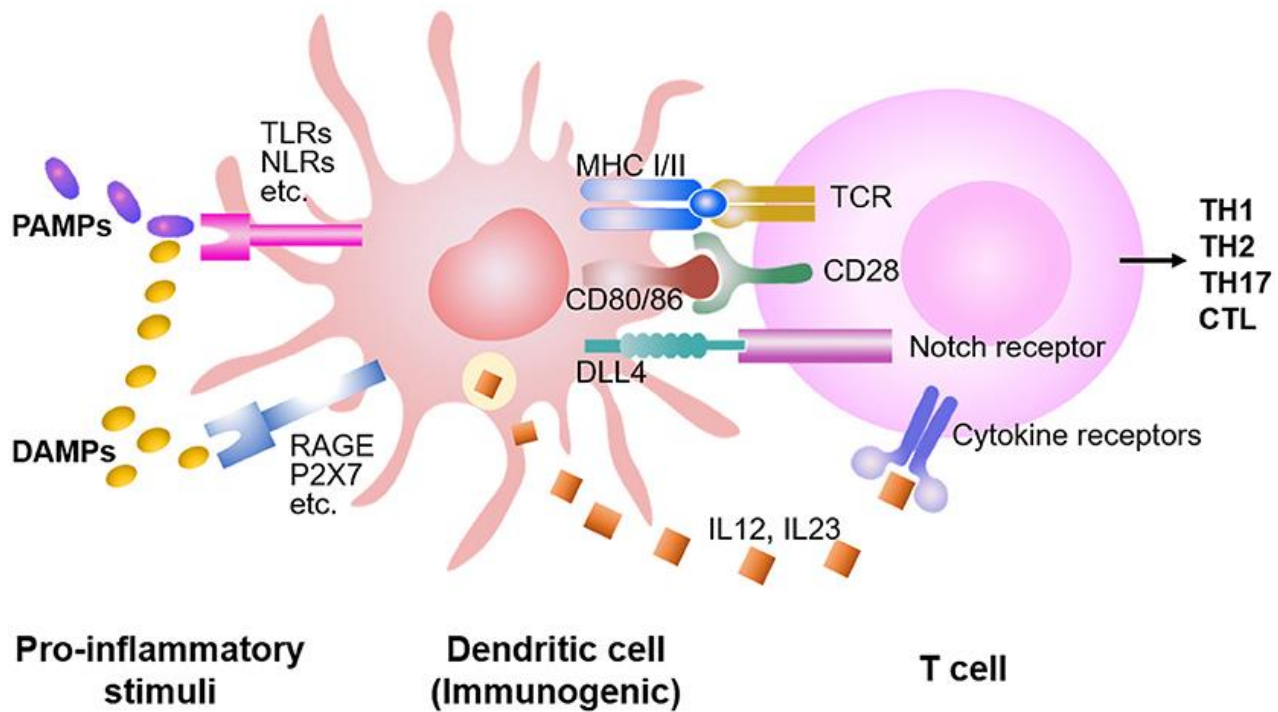


# DENDRITIC CELLS

- „professional“ antigen presentation = activation of immune cells with high efficiency
  - antigen processing – MHC II
  - cytokine production
  - component of monocyte-macrophage system
  - lymphatic organs, epithelia, connective tissue
- 
- **TCR** recognizing antigen presented in **MHC complex** is essential for activation of **T-cells**
  - **Highly regulated mechanism**
  - **MHC restriction**



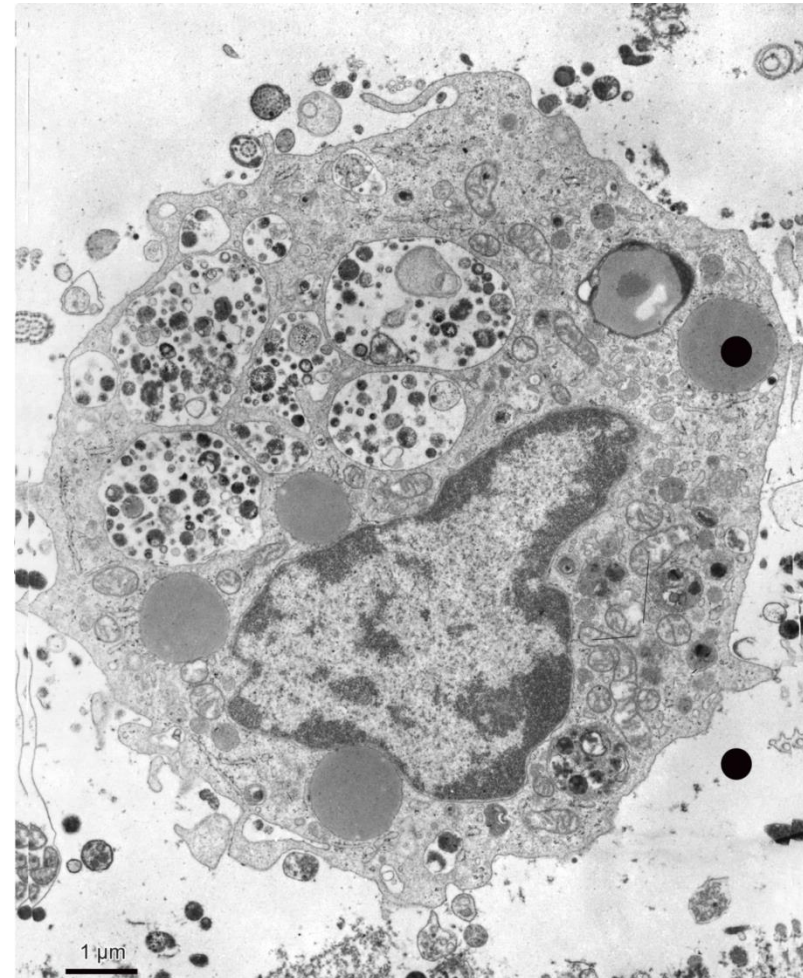
# DENDRITIC CELLS





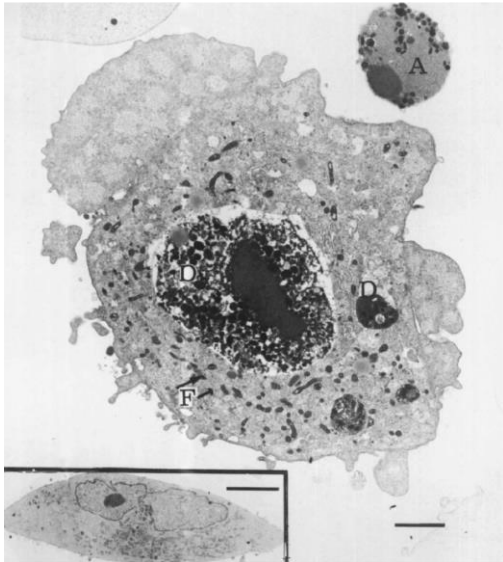
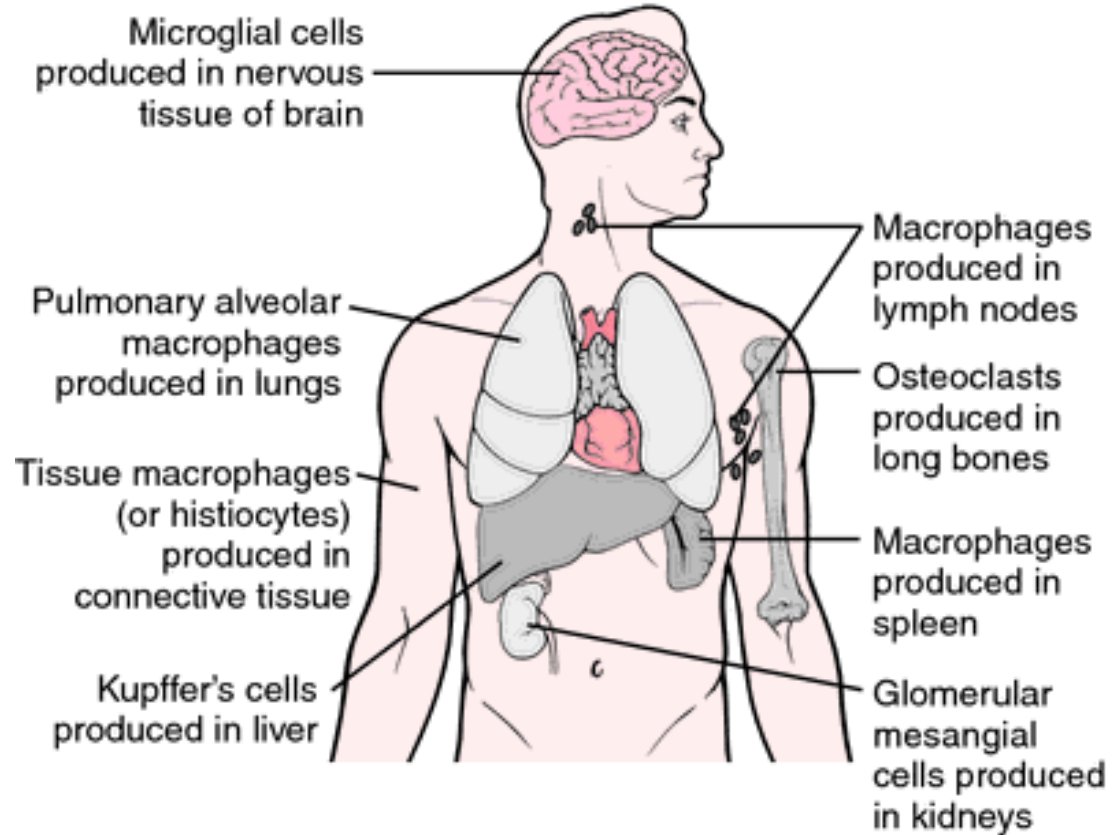
# MONOCYTE-MACROPHAGE SYSTEM

- mononuclear phagocytic system, reticuloendothelial system
- originate in bone marrow: monoblasts → monocytes
- after extravasation → macrophages
- irregular surface (hallmark of phagocytosis)
- numerous lysosomes
- Golgi apparatus and rER
- long-living cells (months)
- phagocytosis (large particles)



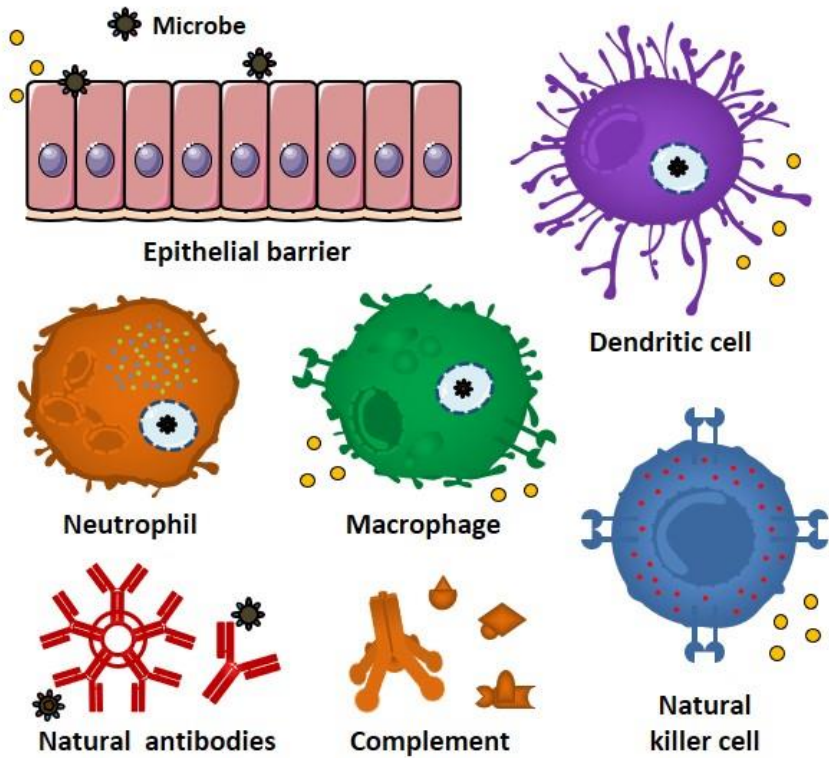
# MONOCYTE-MACROPHAGE SYSTEM

- monocytes (circulation)
- macrophages (histiocytes) of c.t.
- Kupffer cells (liver)
- osteoclasts (bones)
- microglia (CNS)
- alveolar macrophages (lungs)
- macrophages and dendritic cells (lymphatic organs, epithelia, c.t.)
- Langerhans cells (skin)
- mesangial cells (kidney)



# INNATE AND ACQUIRED IMMUNITY

## Innate Immunity



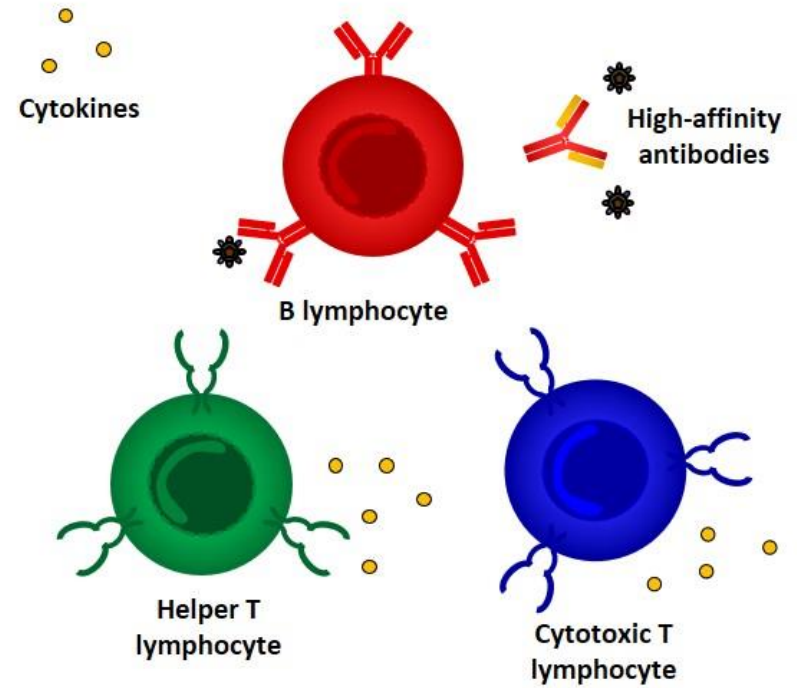
Hours

0

6

12

## Adaptive Immunity




Days

1

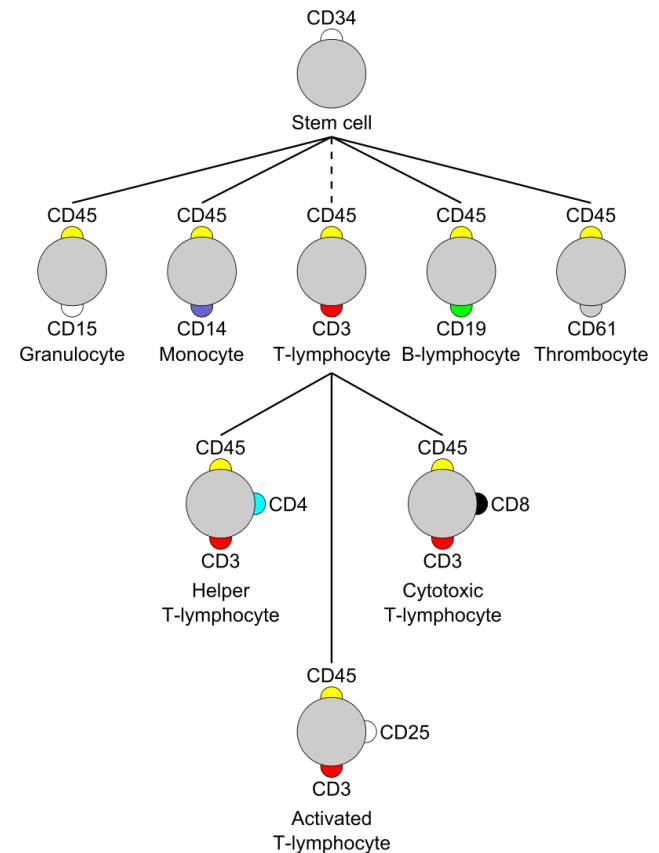
2

3

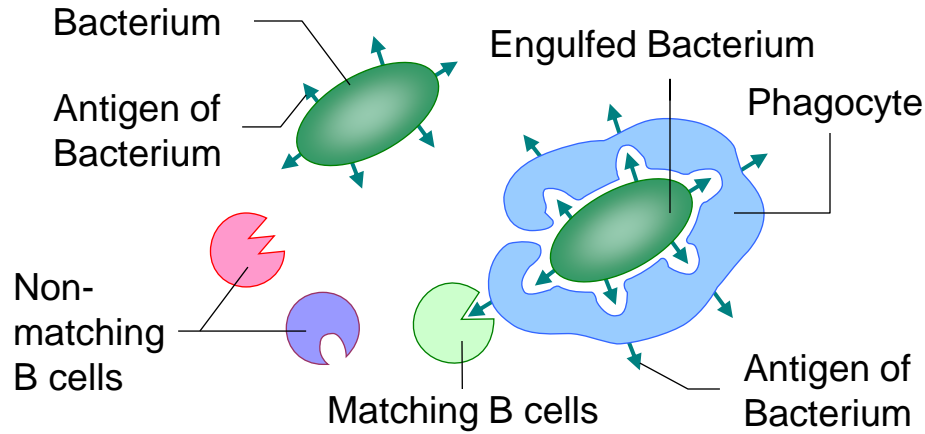
# LYMPHOCYTES



- „Clusters of differentiation“, CD
- Surface molecules constituting immunophenotype
- Molecular signaling regulating immune response
- Clinically relevant in diagnostics and therapy

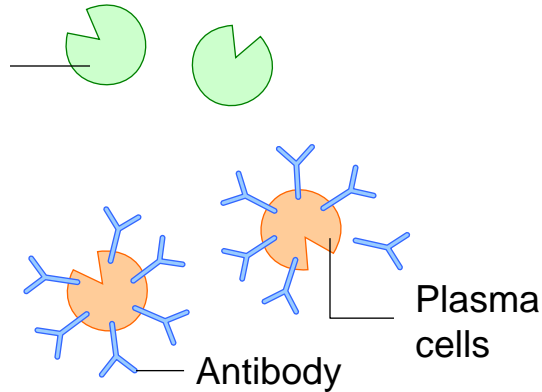


# ANTIBODY (HUMORAL) RESPONSE

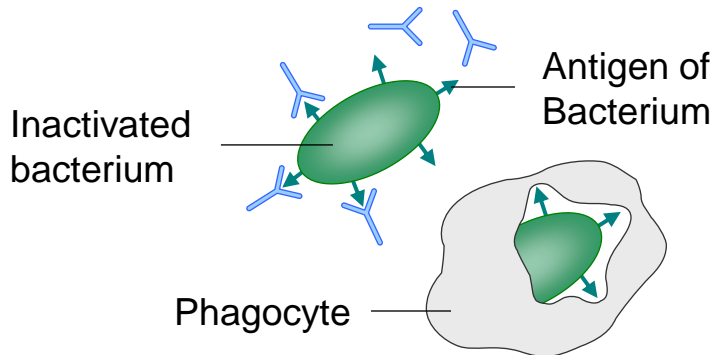


1. Antigen presentation and activation of B-cells

**Memory B cell**  
Second exposure to the same bacteria activates this cell to rapidly produce plasma cells

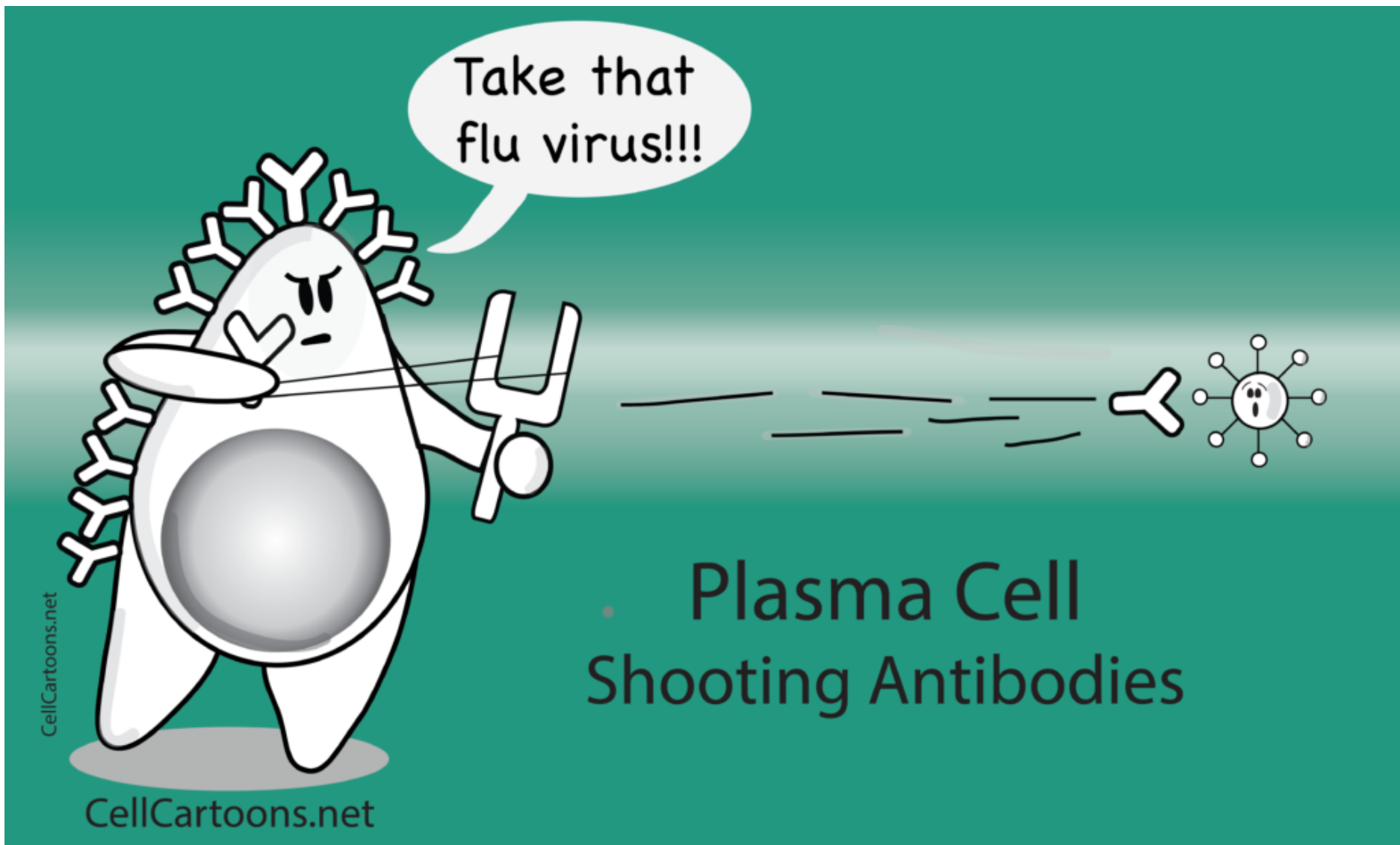


2. Activated B-cells proliferate and expand



3. Most of B-cells differentiate to plasma cells, some will convert to memory cells

# ANTIBODY (HUMORAL) RESPONSE



Take that flu virus!!!

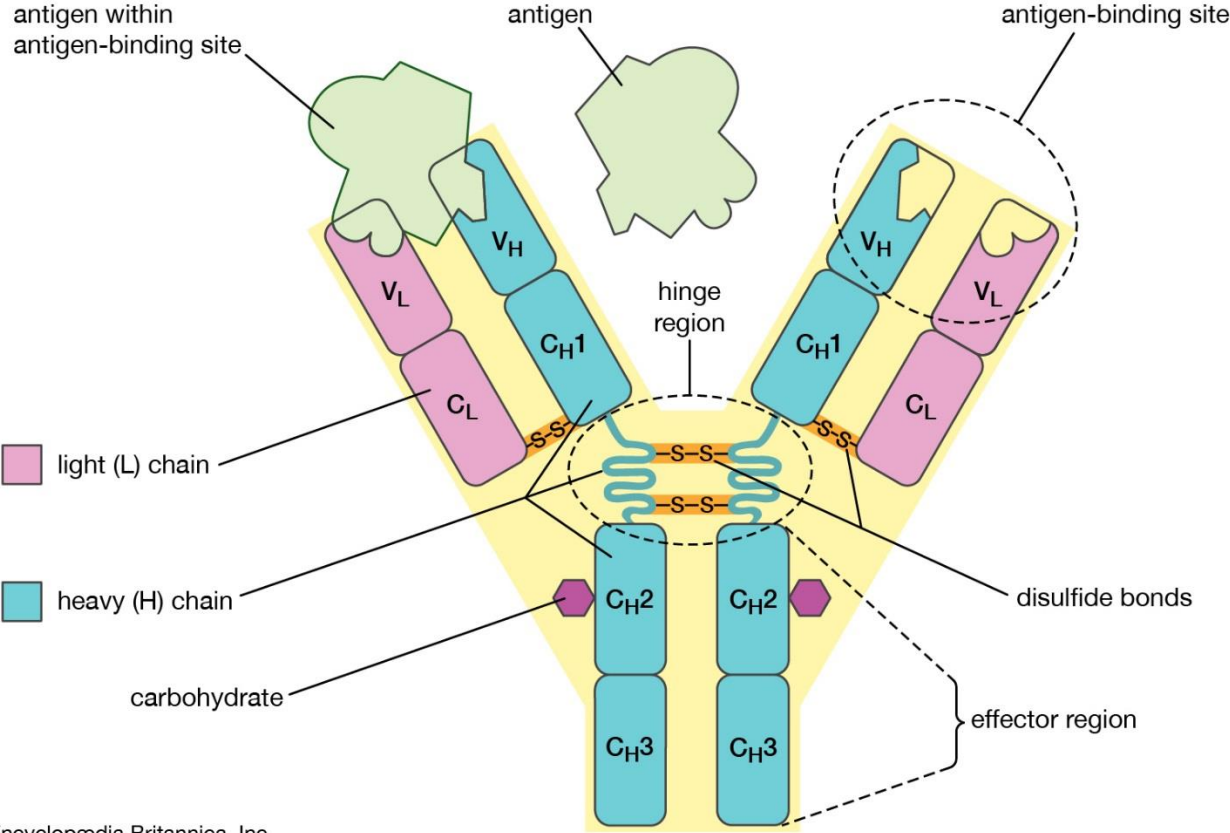
Plasma Cell Shooting Antibodies

CellCartoons.net

CellCartoons.net

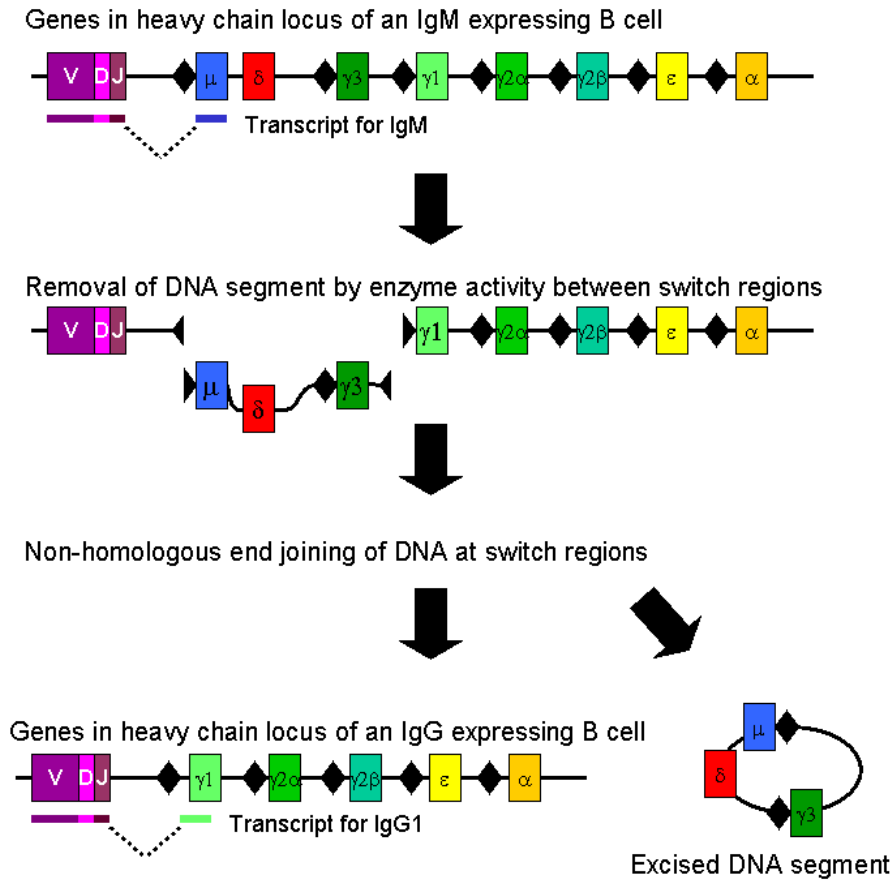
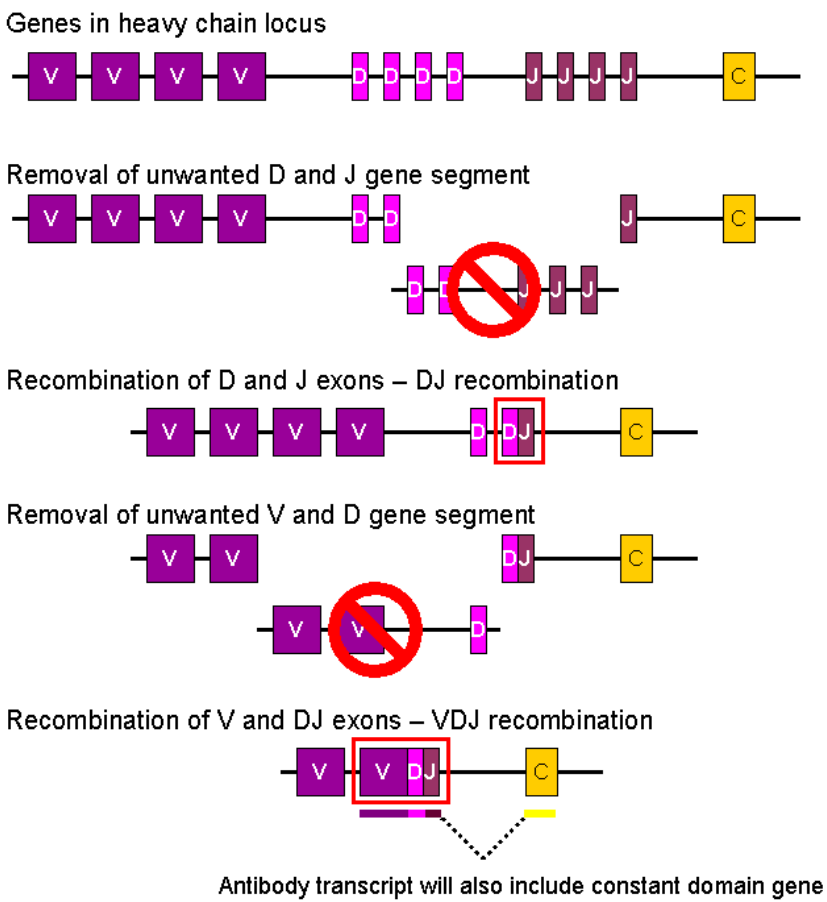
# ANTIBODIES

- Immunoglobulins
- Large proteins with defined structure capable of binding antigens
- Variable and constant regions
- Fc region bound by Fc receptor on immune cells



# ANTIBODIES

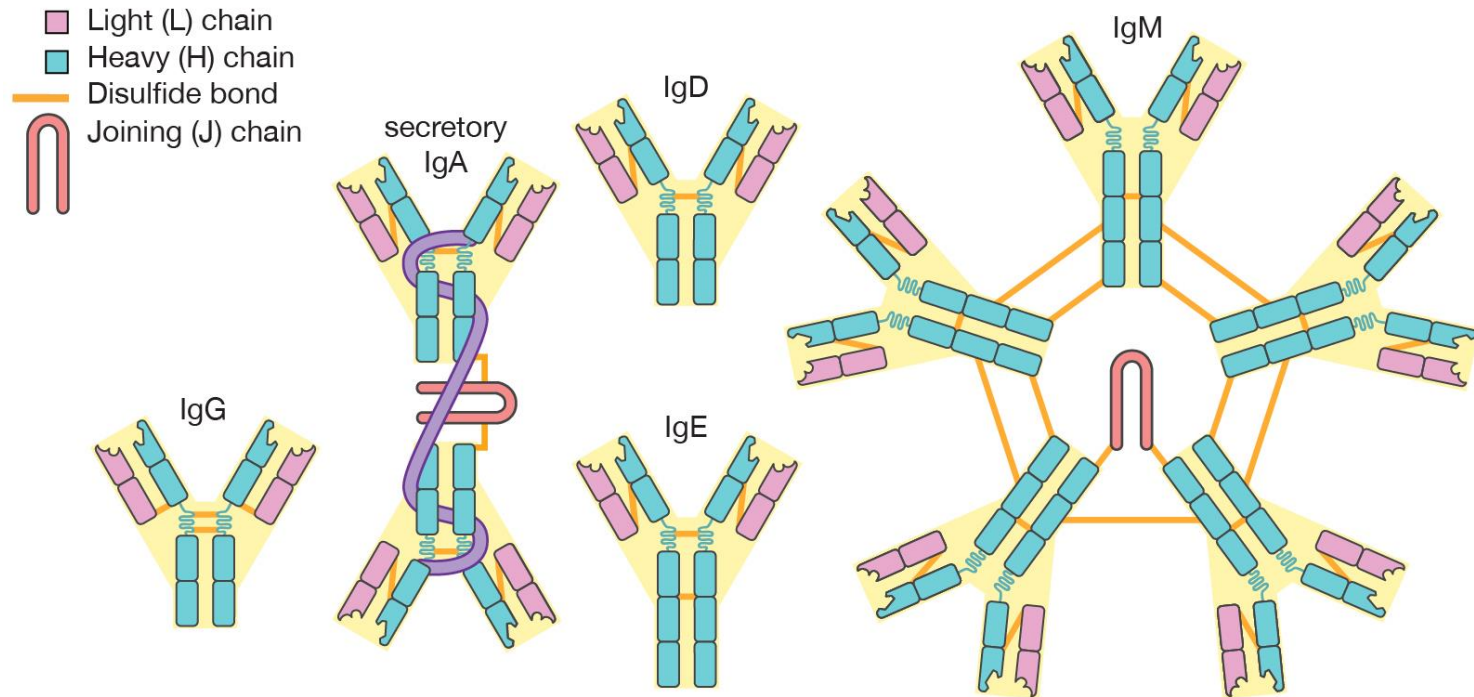
- Genome rearrangements leading to generation of unique antibody transcripts (>10 billions)
- V(D)J recombination during development
- Isotype switching





# ANTIBODIES

- Five principal classes
  - IgG: most common (>75%), soluble, stable
  - IgA: in exocrine secretions, mucosa
  - IgM: natural immunity, activator of complement
  - IgE: activator of mast cells
  - IgD: B-cells activators

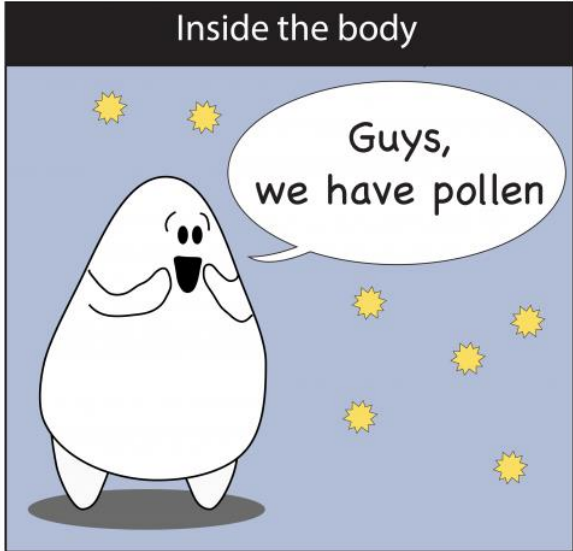


# ANTIBODIES

- IgE: activator of mast cells

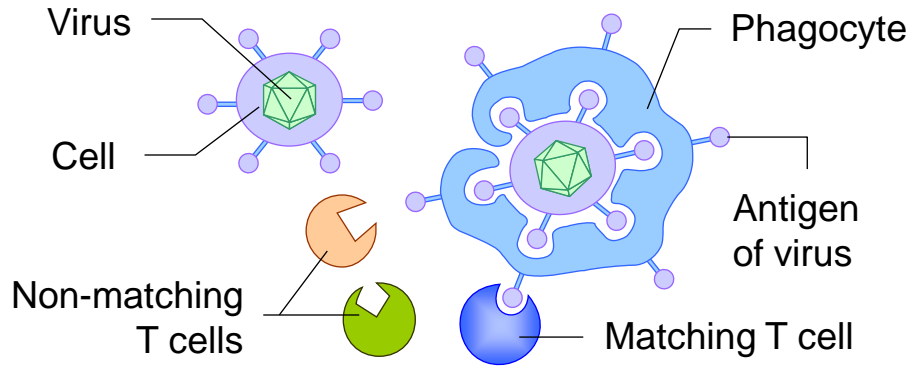


CellCartoons.net

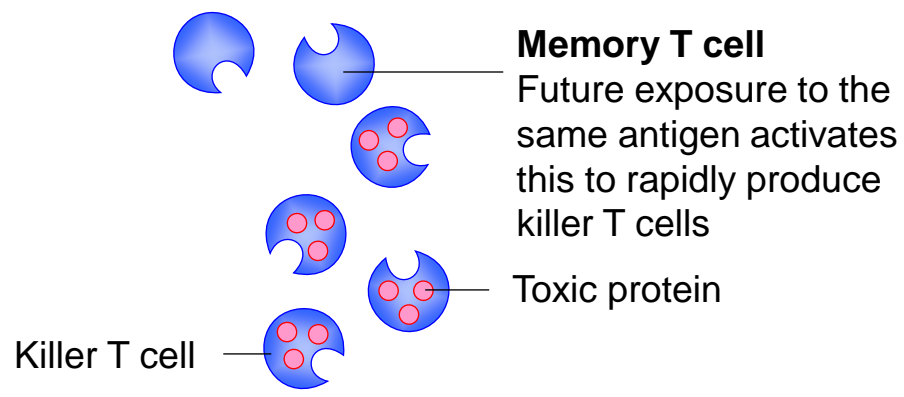


CellCartoons.net

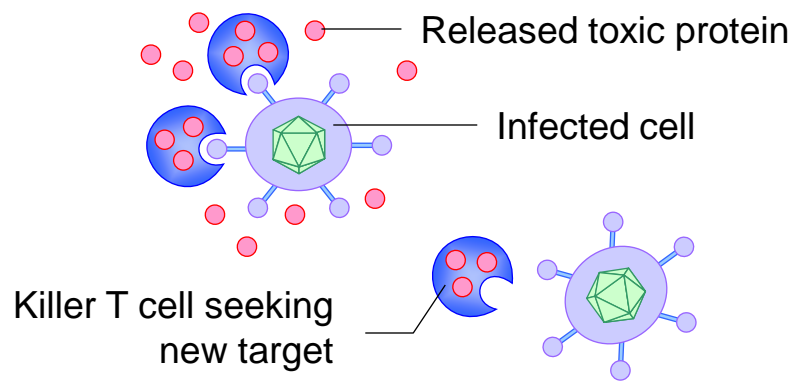
# CELLULAR RESPONSE



1. Antigen presentation and activation of T-cells




2. T-cells differentiate to cytotoxic Tc cells, memory t cells or regulatory cells




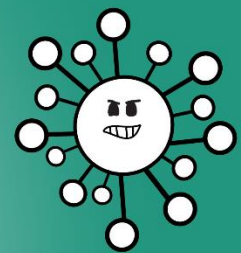
3. Cytotoxic Tc eliminate abnormal cells

# CELLULAR RESPONSE



Oh nooo!  
I'm shedding virus particles!  
Does that mean I'm infected?  
What will happen to me?


VIRAL PARTICLES



INFECTED CELL

CellCartoons.net

I'M READY TO FIND AND  
KILL THOSE INFECTED CELLS!

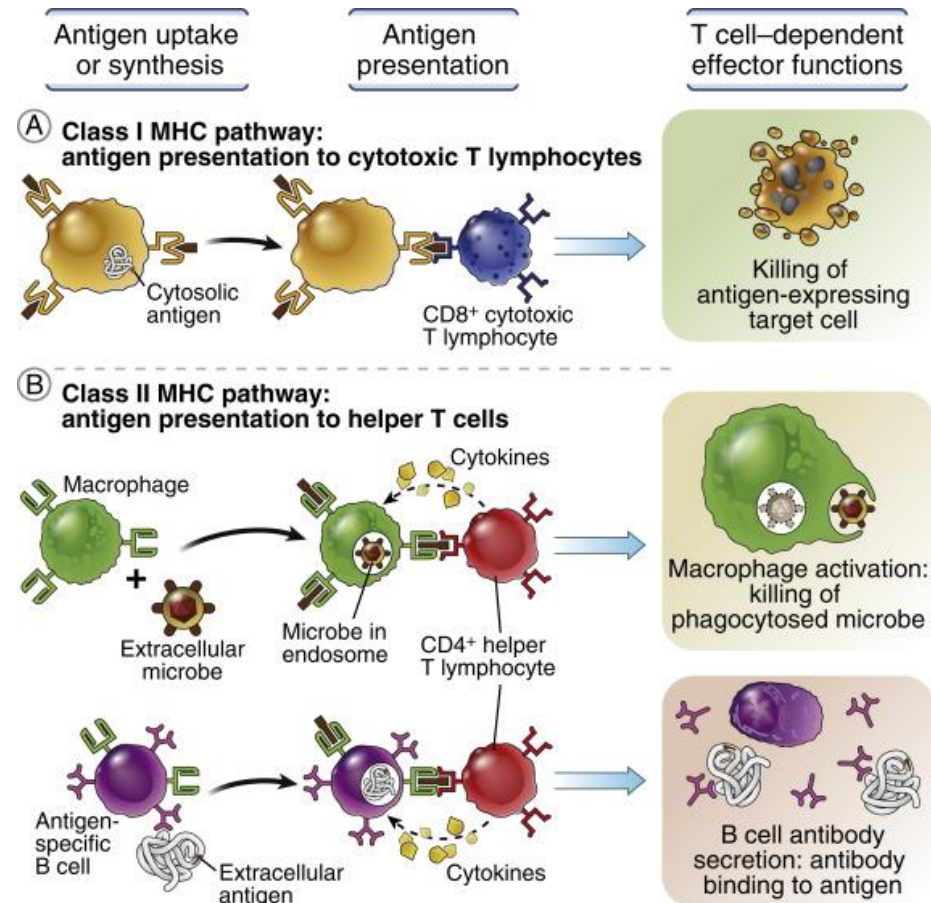
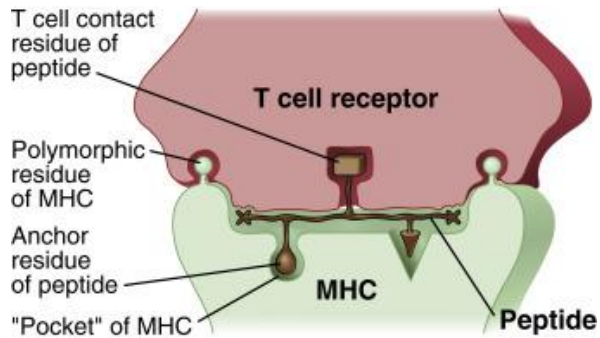


CD8 Cytotoxic T Cell  
a.k.a 'Killer T cell'

CellCartoons.net

# MHC PROTEINS

- Major histocompatibility complex
- Activation or attenuation of T-cell response
- Peptide display
- MHC I: all nucleated cells and platelets
- MHC II: antigen presenting cells
- (MHC III: structurally similar to MHC I and II, but with rather unknown function in immune response)



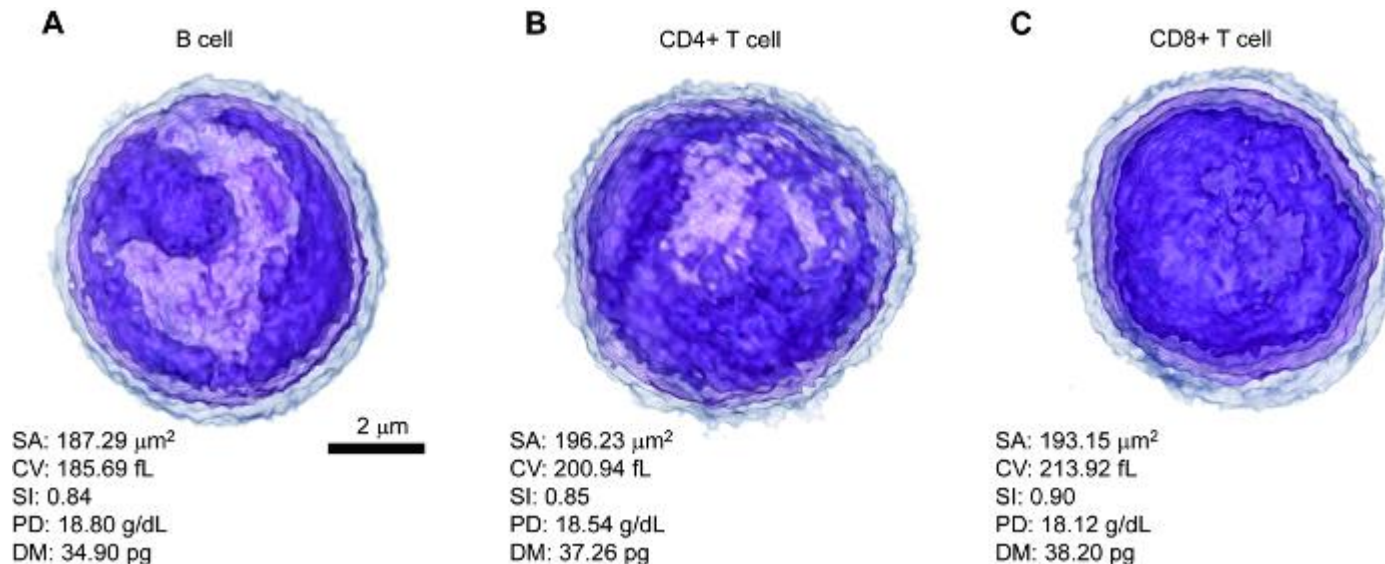
# B- AND T- LYMPHOCYTES IN HUMAN BODY

## T-lymphocytes

- paracortical zone of lymph nodes
- white pulp of spleen (periarteriolar lymphatic sheath, PALS)
- interfollicular regions in other lymphatic organs (tonsils)

## B-lymphocytes

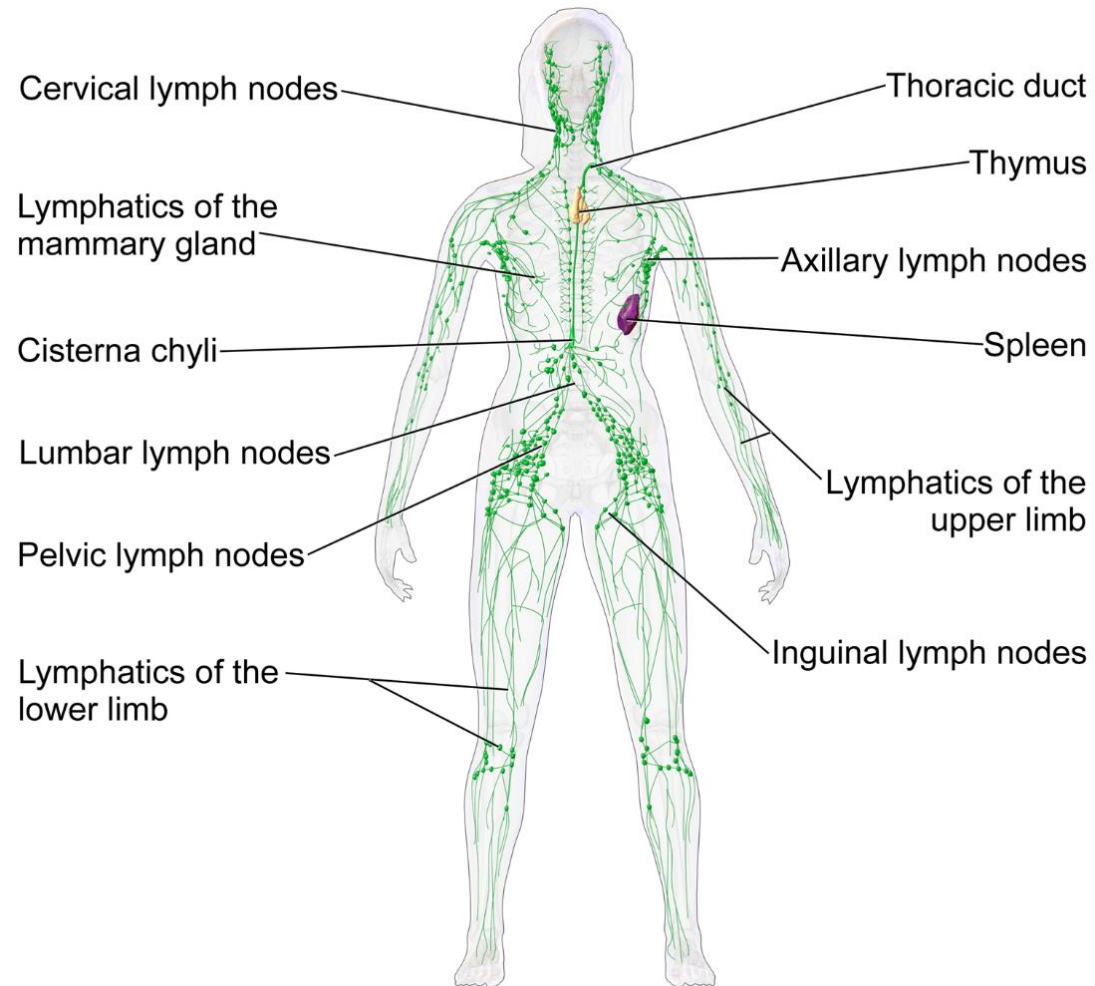
- lymphatic follicles and medullary cords of lymph nodes
- spleen follicles and marginal zone of white pulp
- lymphatic follicles in other organs



# ACQUIRED IMMUNITY

## Histology:

- Leukocytes
  - Lymphocytes
  - Antigen presenting cells
- Lymphatic organs



# LYMPHATIC ORGANS

## Development of lymphocytes and APC:

### Primary lymphatic organs

- bone marrow
- thymus

### Secondary lymphatic organs

- lymph nodes
- spleen
- MALT including tonsils and appendix

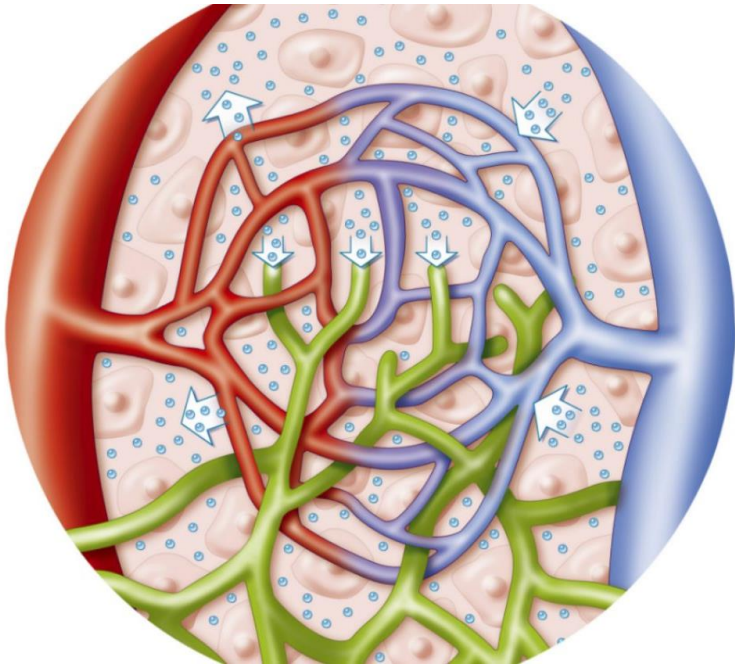
### Tissues

- blood
- lymph
- epithelia
- connective tissues



# LYMPHATIC CIRCULATION

## Lymph vessels



## Function

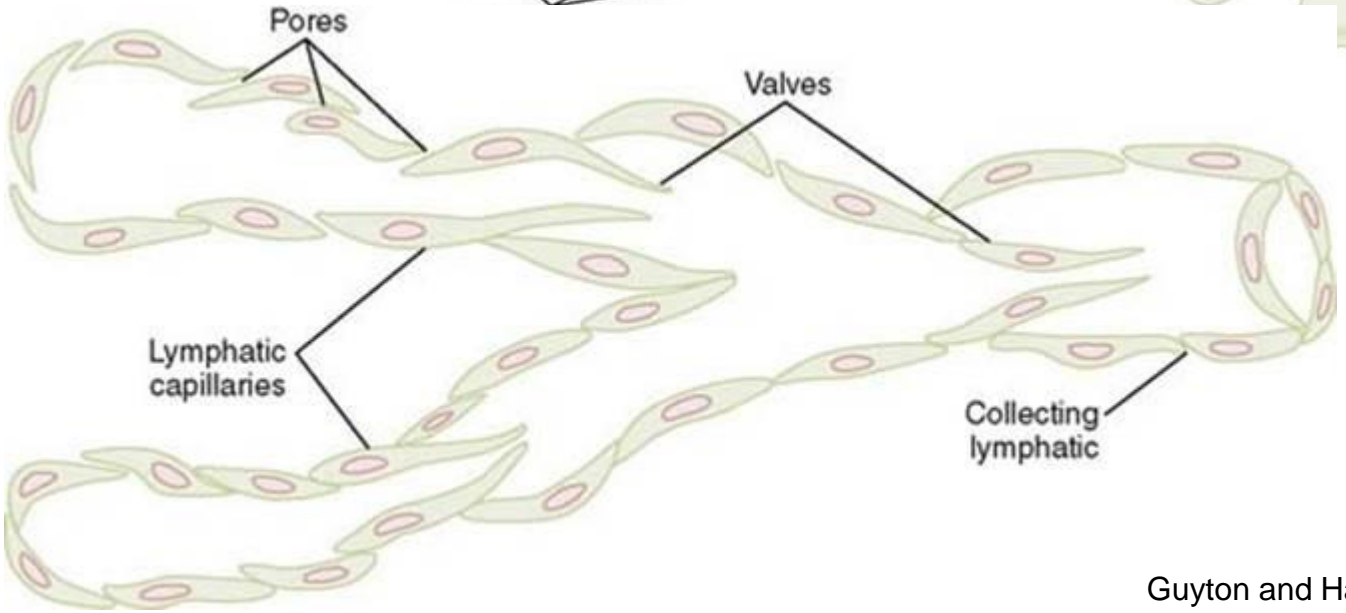
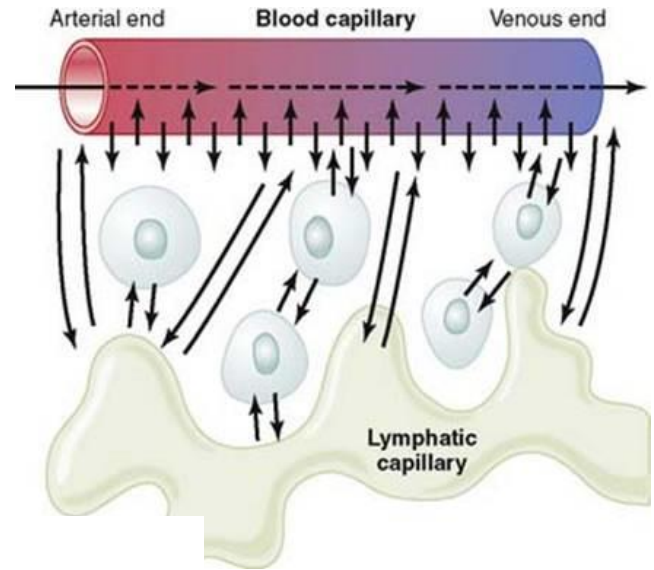
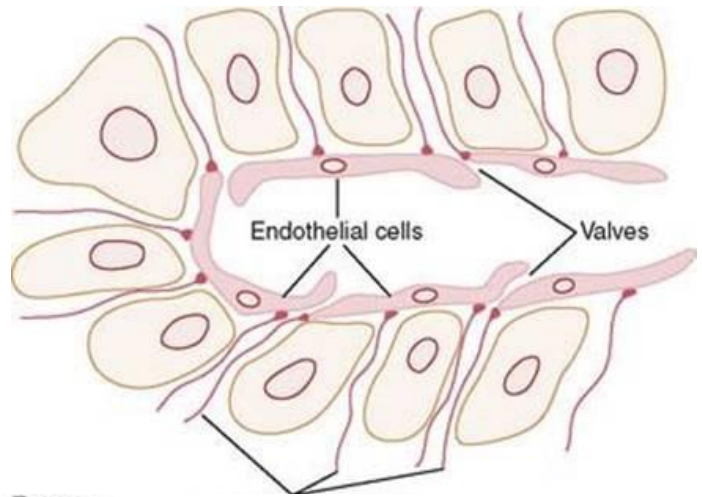
- Collect interstitial fluid
- Microenvironment for lymphocyte development and maturation
- Lipid transport (chylomicrons)

## Histology

- Lymph capillaries
  - Thin walled, blunt ended vessels with irregular lamina basalis
  - Anchoring filaments, tiny valves
- Lymph vessels
  - T. intima – endothelium and subendothelial c.t.
  - T. media - few layers of smooth muscle cells
  - T. adventitia - collagen c.t.
- Similar to small veins
- Valves derived from t. intima
- Open to d. thoracicus and d. lymphaticus dx. → v. subclavia (at v. jugularis int.)

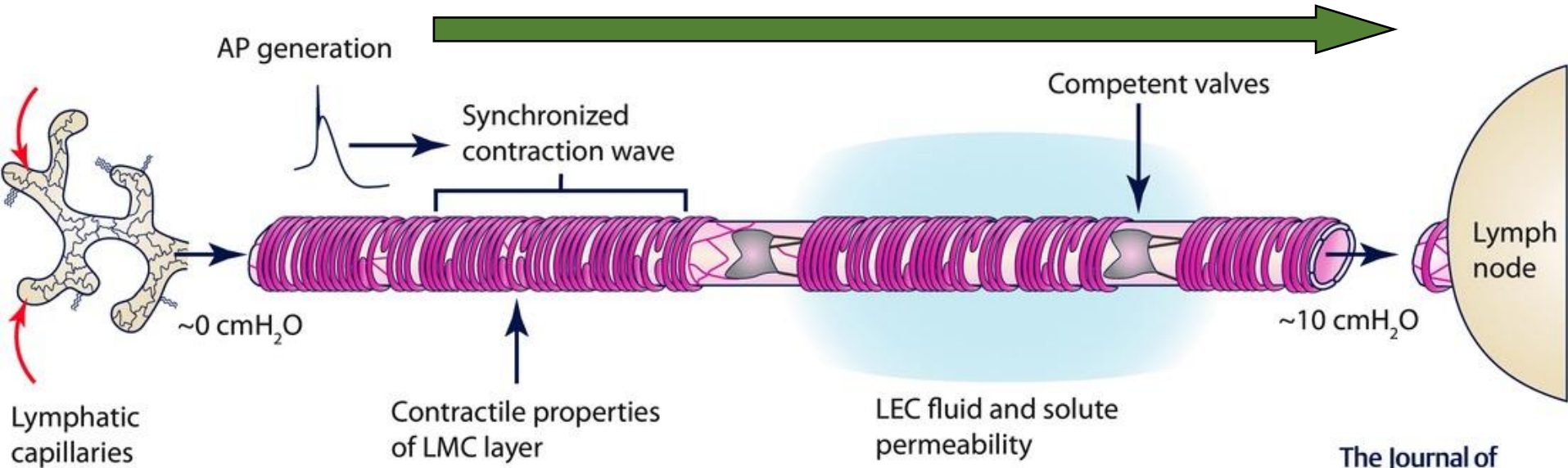
# LYMPHATIC CIRCULATION

## Lymph capillaries



# LYMPHATIC CIRCULATION

## Lymph flow is unidirectional



The Journal of  
**Physiology**

<https://doi.org/10.1113/JP272088>

## Lymph composition

- Contains similar concentration of ions to plasma, but lower levels of proteins
- Lipid-rich lymph from intestine - chylus
- Immune cells
- Volume in the circulation ca. 1L (2-2.5L new lymph from interstitial fluid per day)

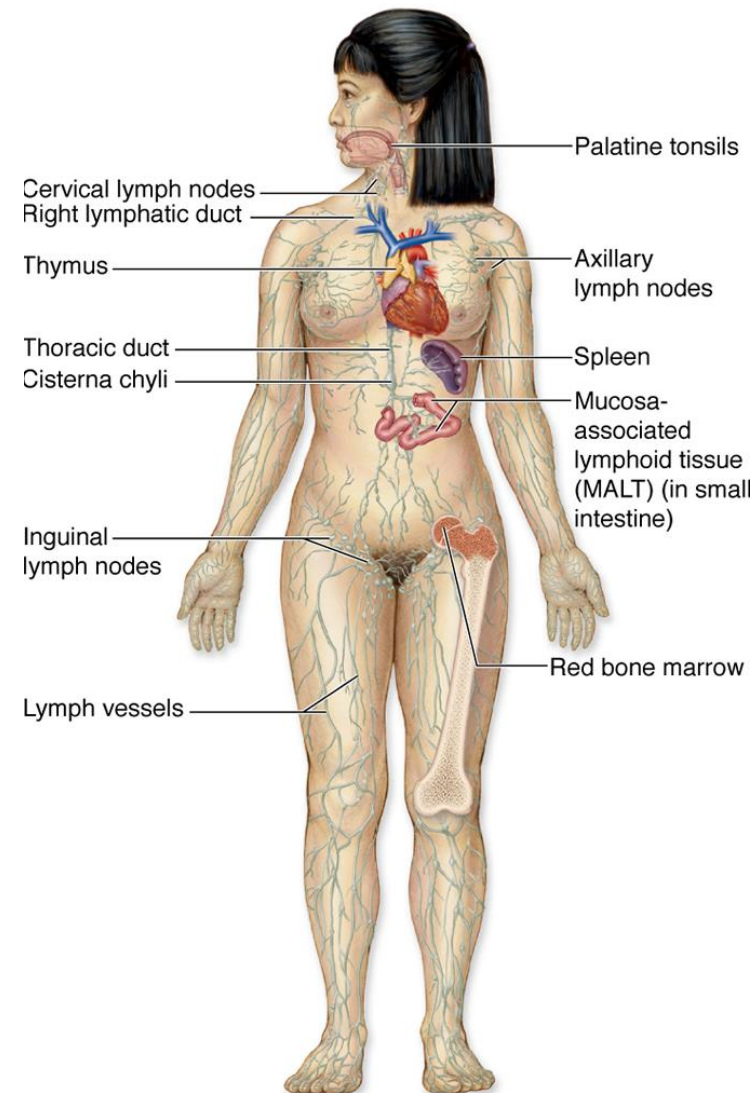
# LYMPHATIC ORGANS

## central:

- thymus
- bone marrow

## peripheral:

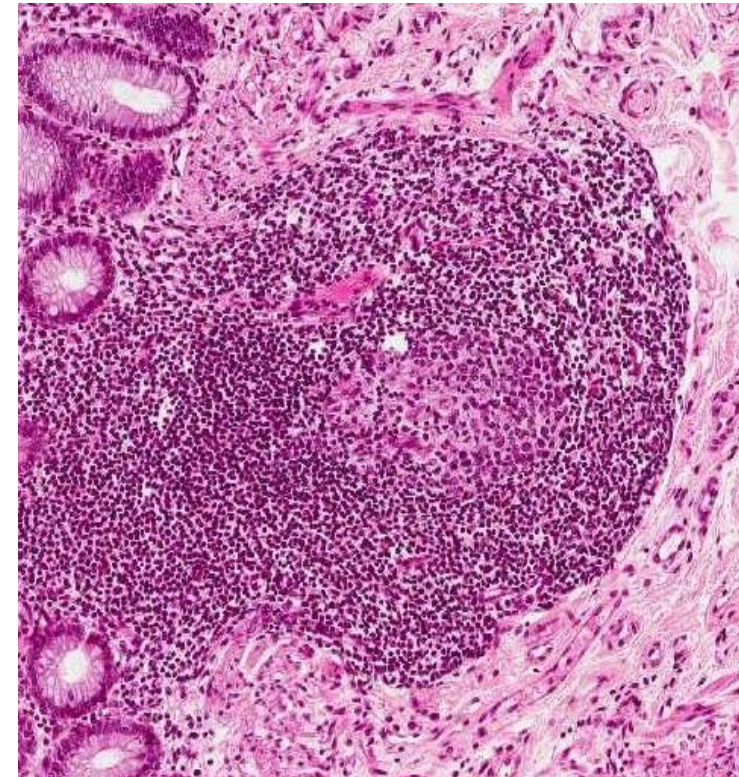
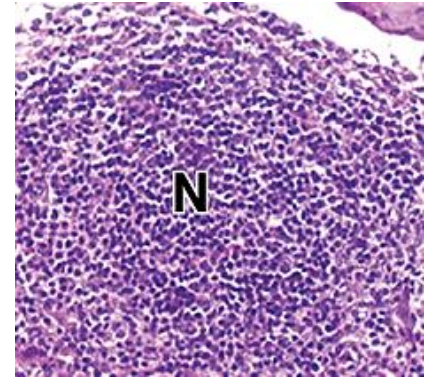
- encapsulated – lymph node, spleen
- mucosa associated lymphoid tissue – MALT
  - tonsils (partially encapsulated)
  - lymphatic follicles in mucosa of hollow organs



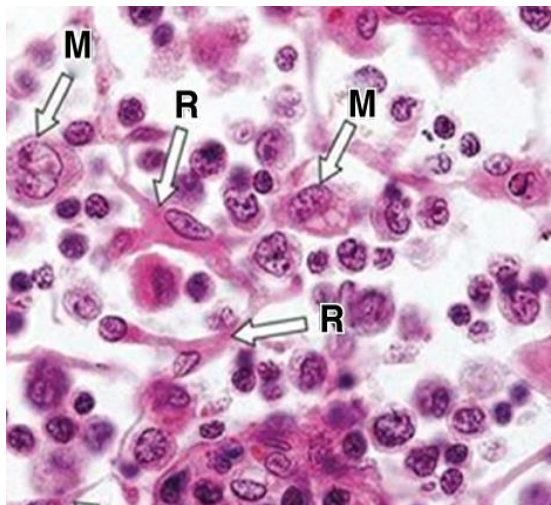
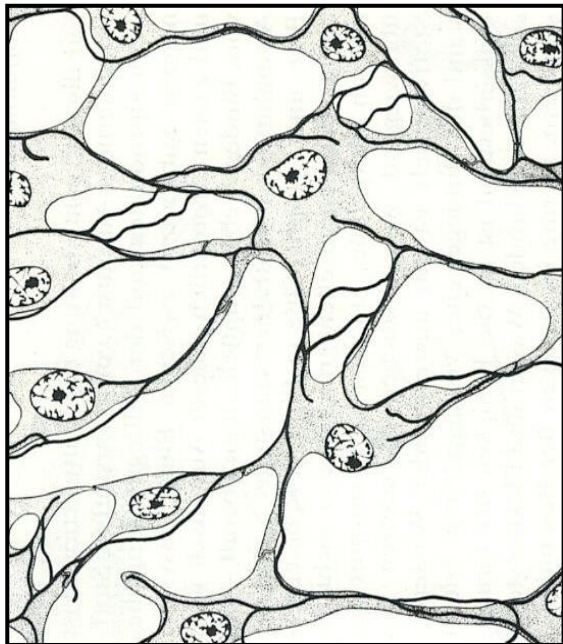
# LYMPHATIC FOLLICLE

## Folliculus, nodulus lymphaticus

- non-encapsulated aggregates of reticular connective tissue and lymphocytes
- peripheral lymphatic organs
- mucosa of hollow organs (GIT, respiratory, urinary, reproductive system)
- **primary** – prior any contact with antigen
- **secondary** – stimulated by antigen
  - pale germinative center
  - dark mantle zone

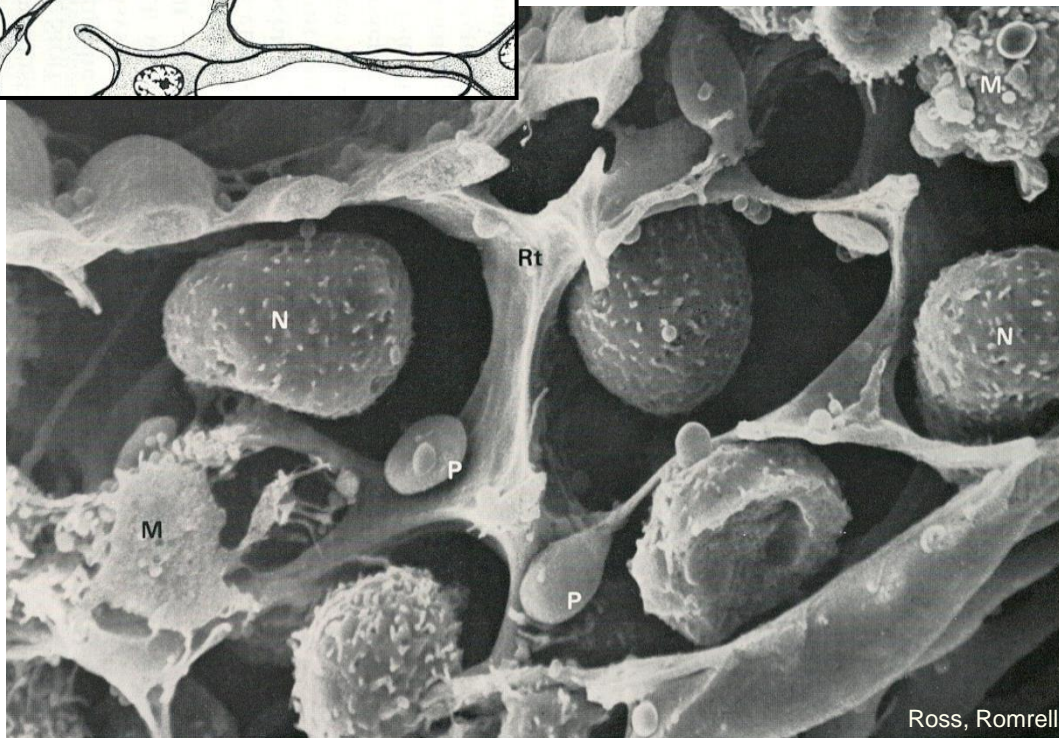


# LYMPHATIC (LYMPHORETICULAR) TISSUE

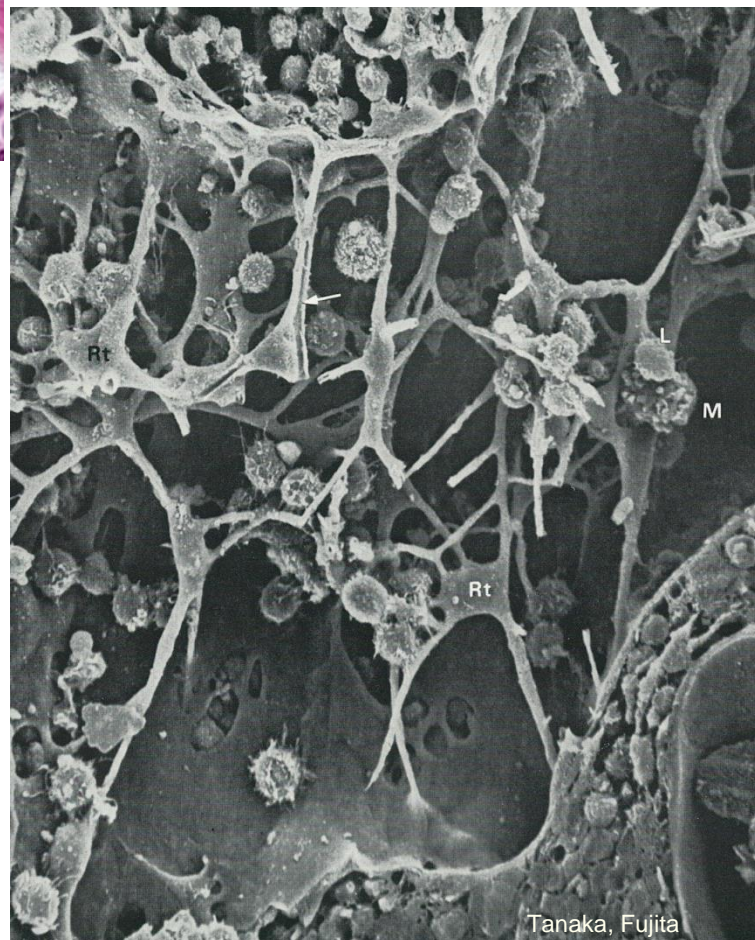


Mescher

- reticular connective tissue + lymphocytes



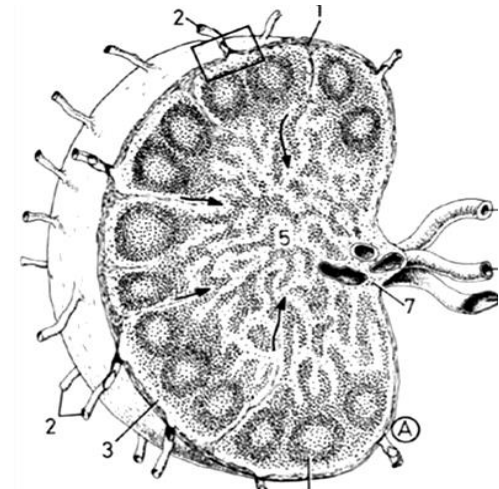
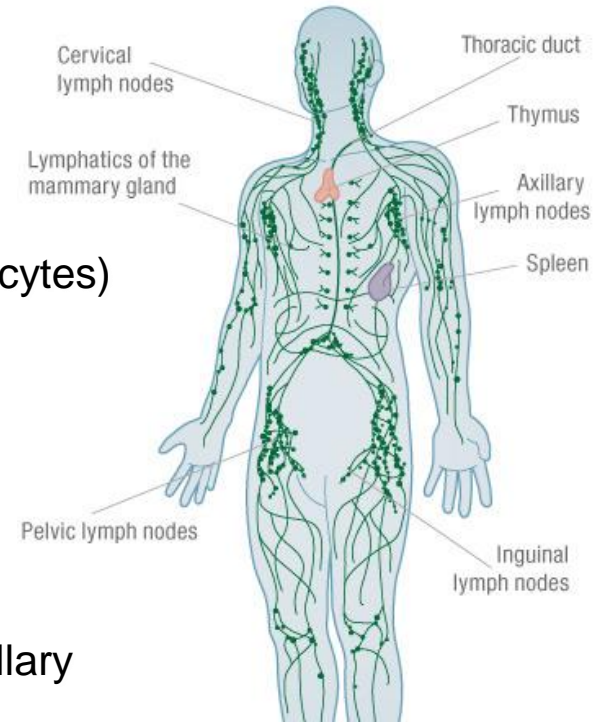
Ross, Romrell



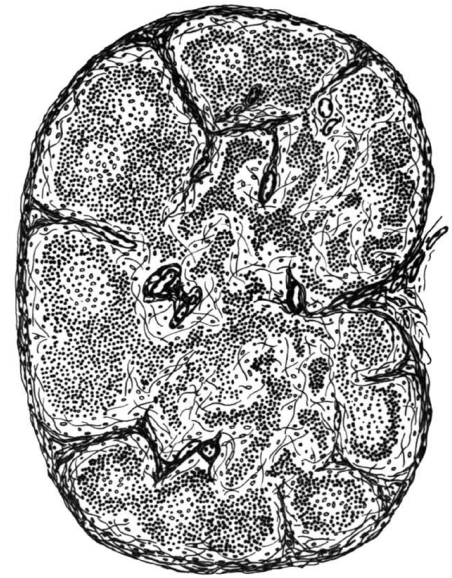
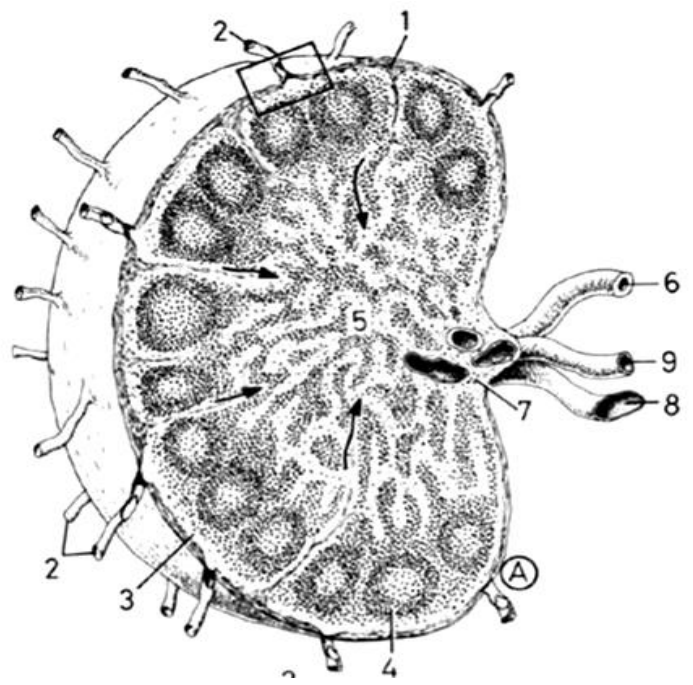
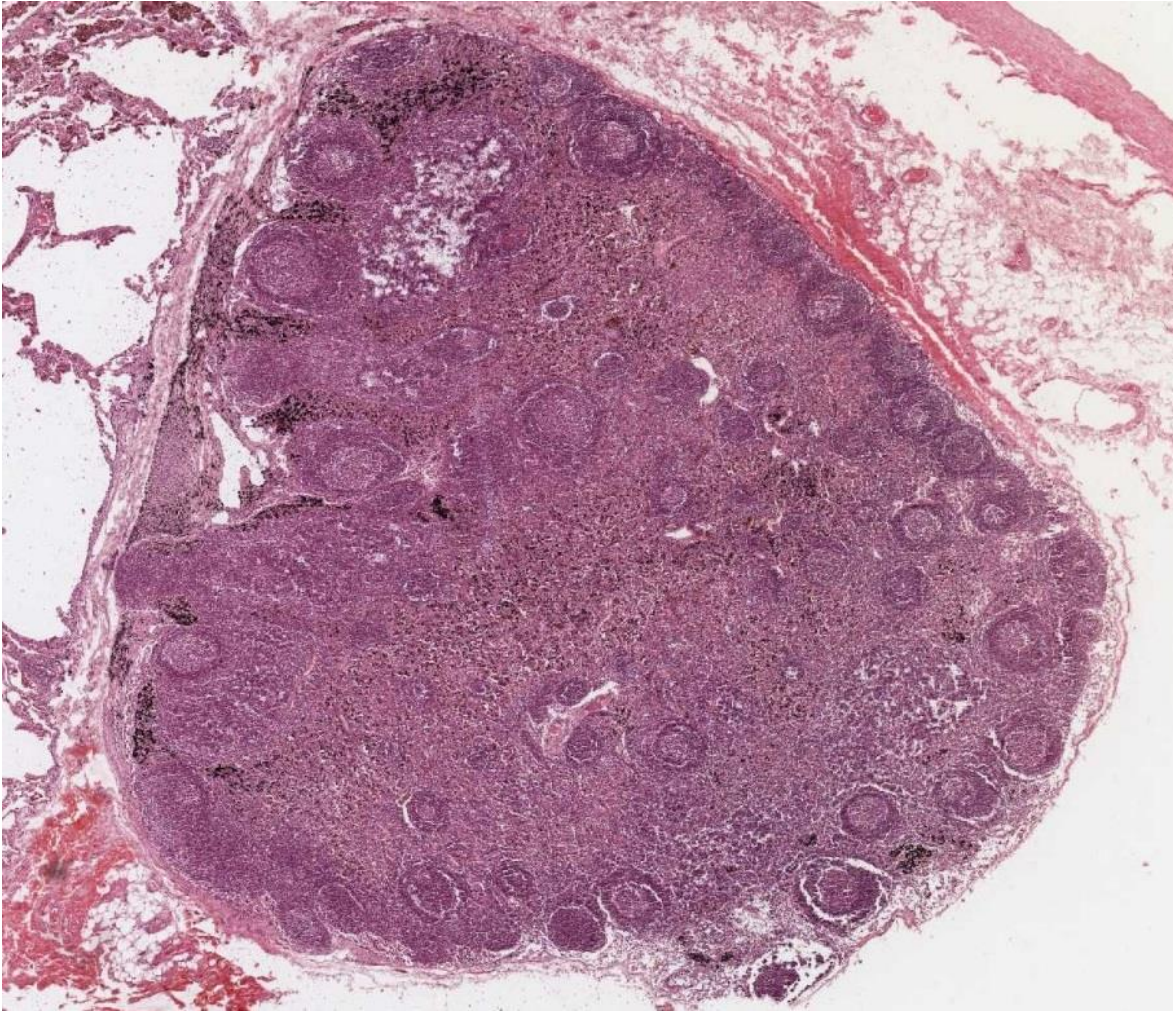
Tanaka, Fujita

# LYMPH NODE (nodus lymphaticus, lymphonodus)

- C.t. capsule containing *hilus* with vessels
- parenchyma = lymphoreticular tissue (reticular c.t. and lymphocytes)
  - **cortex** (lymphatic follicles and sinuses) (B-cells)
  - **medulla** (cords and sinuses) (B-cells)
- paracortical region (T-cells)
- **sinuses**: subcapsular (marginal), perifollicular (cortical), medullary
- *Littoral cells* – lining of sinuses, phagocytosis

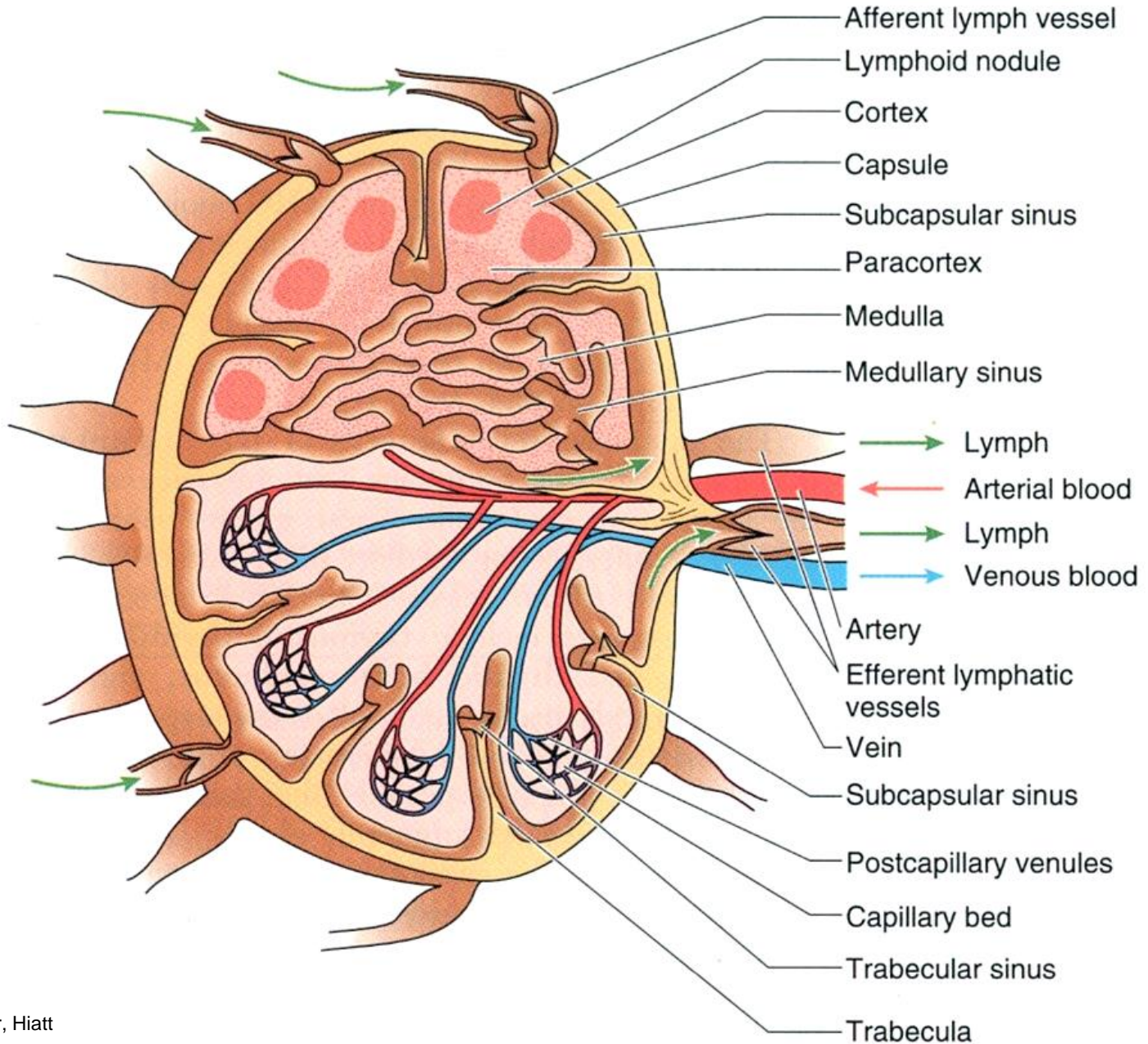


# LYMPH NODE (NODUS LYMPHATICUS, LYMPHONODUS)

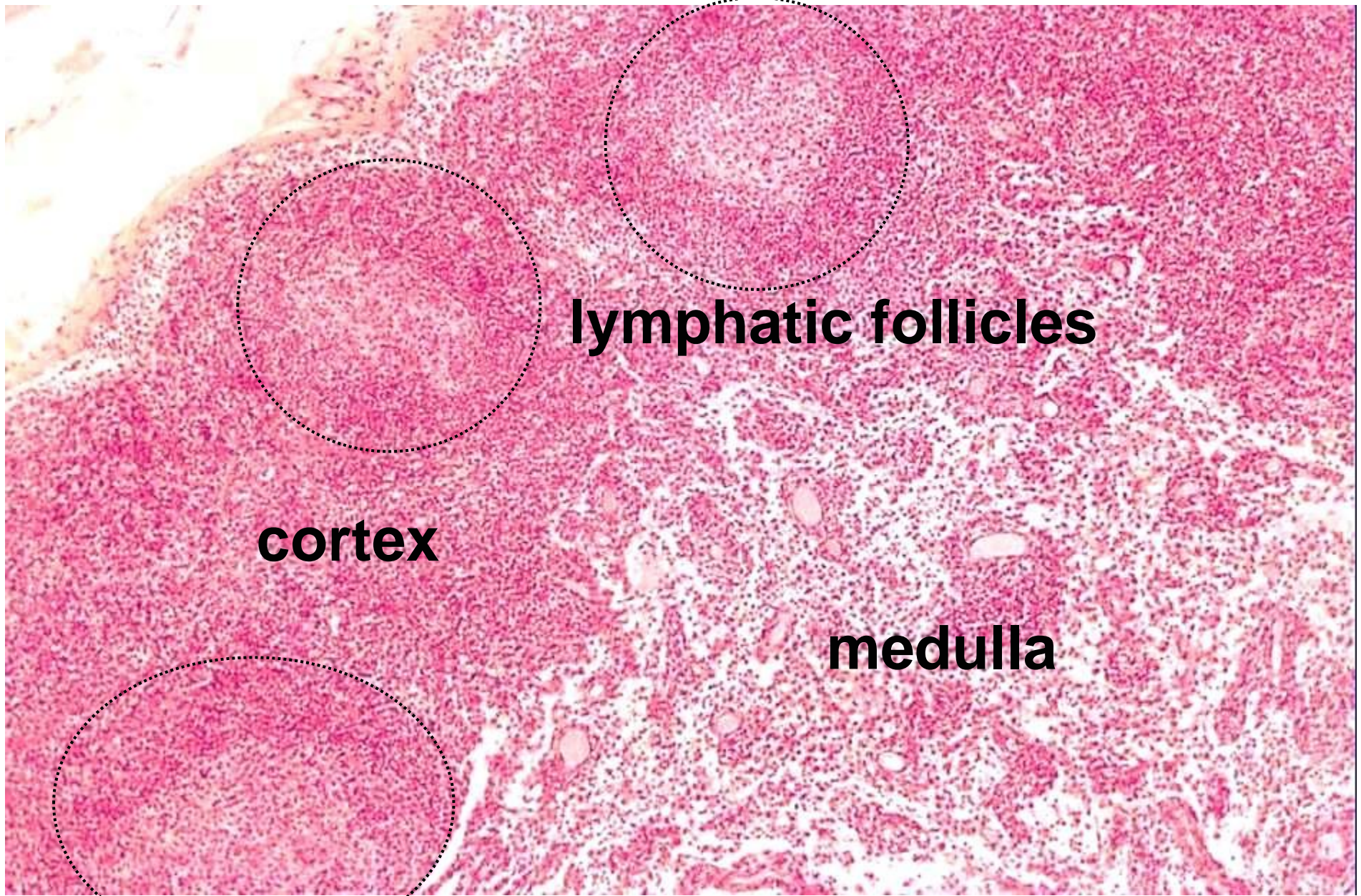




# LYMPH NODE CIRCULATION (BLOOD AND LYMPH)



**LYMPH NODE (NODUS LYMPHATICUS, LYMPHONODUS)**



**lymphatic follicles**

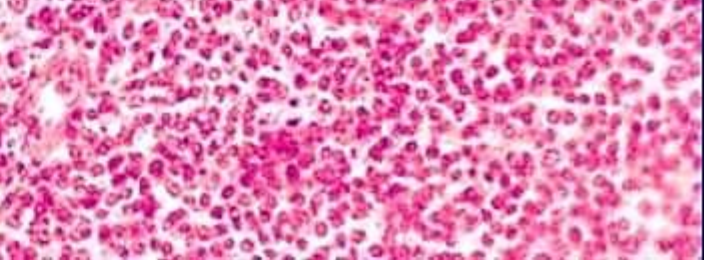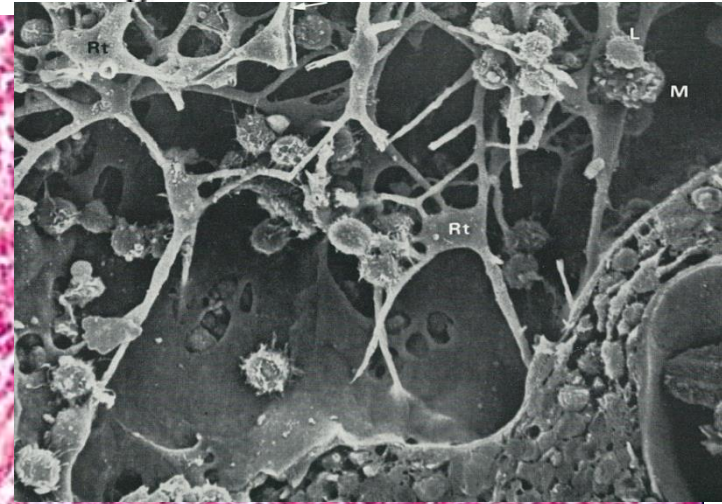
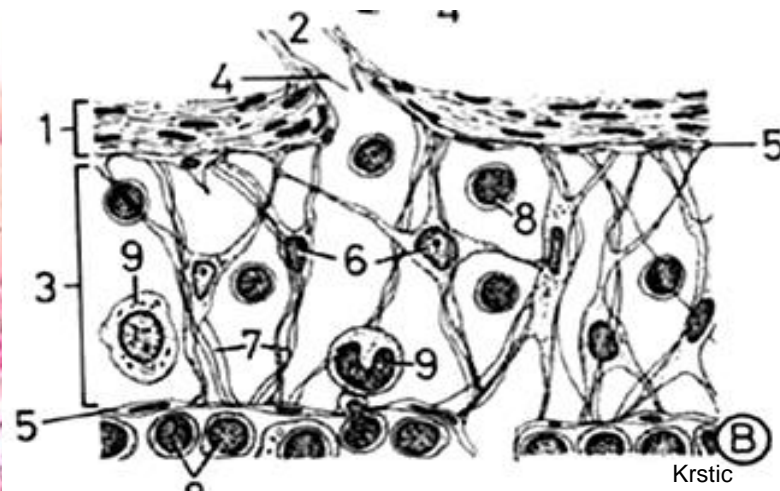
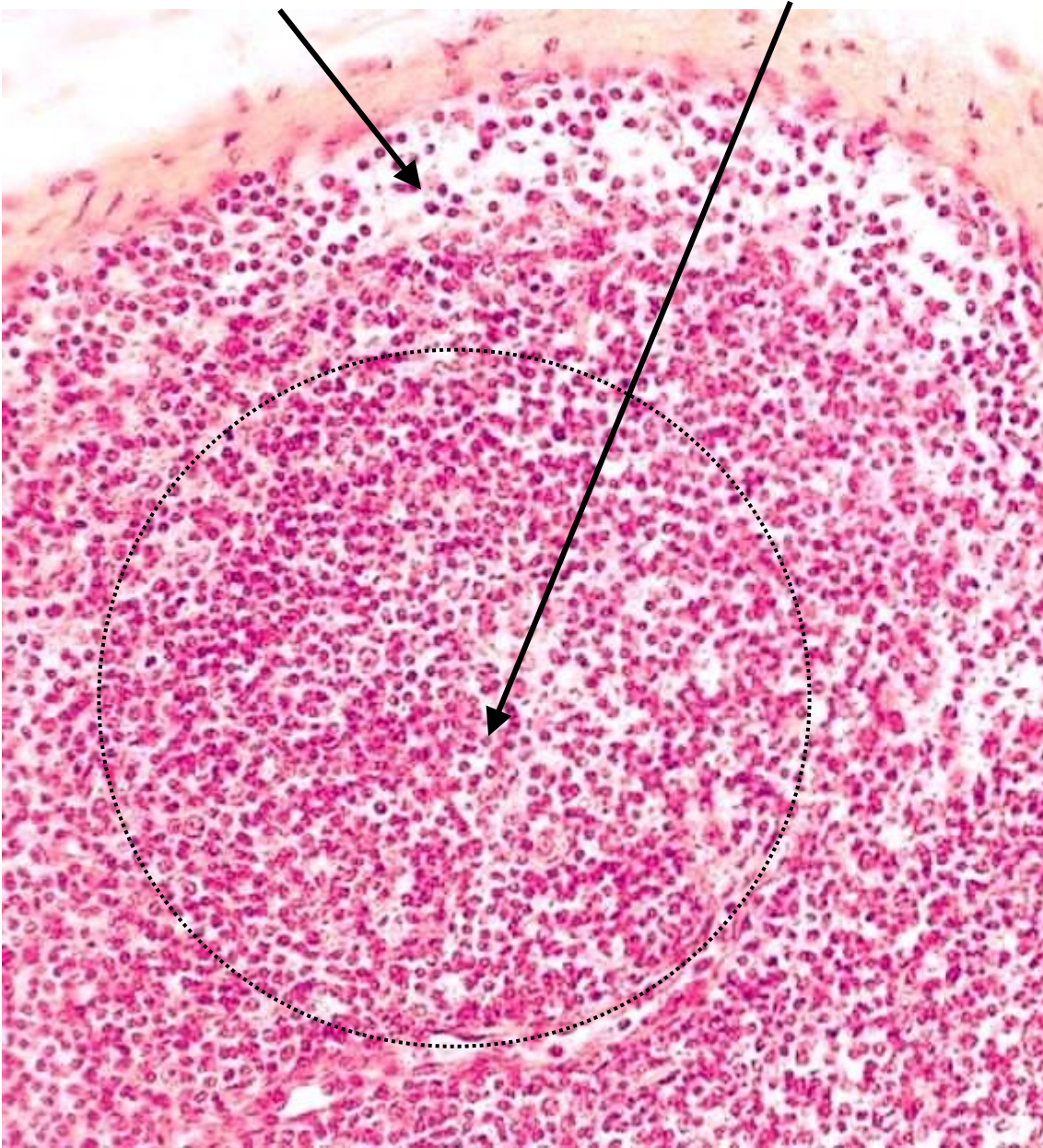
**cortex**

**medulla**

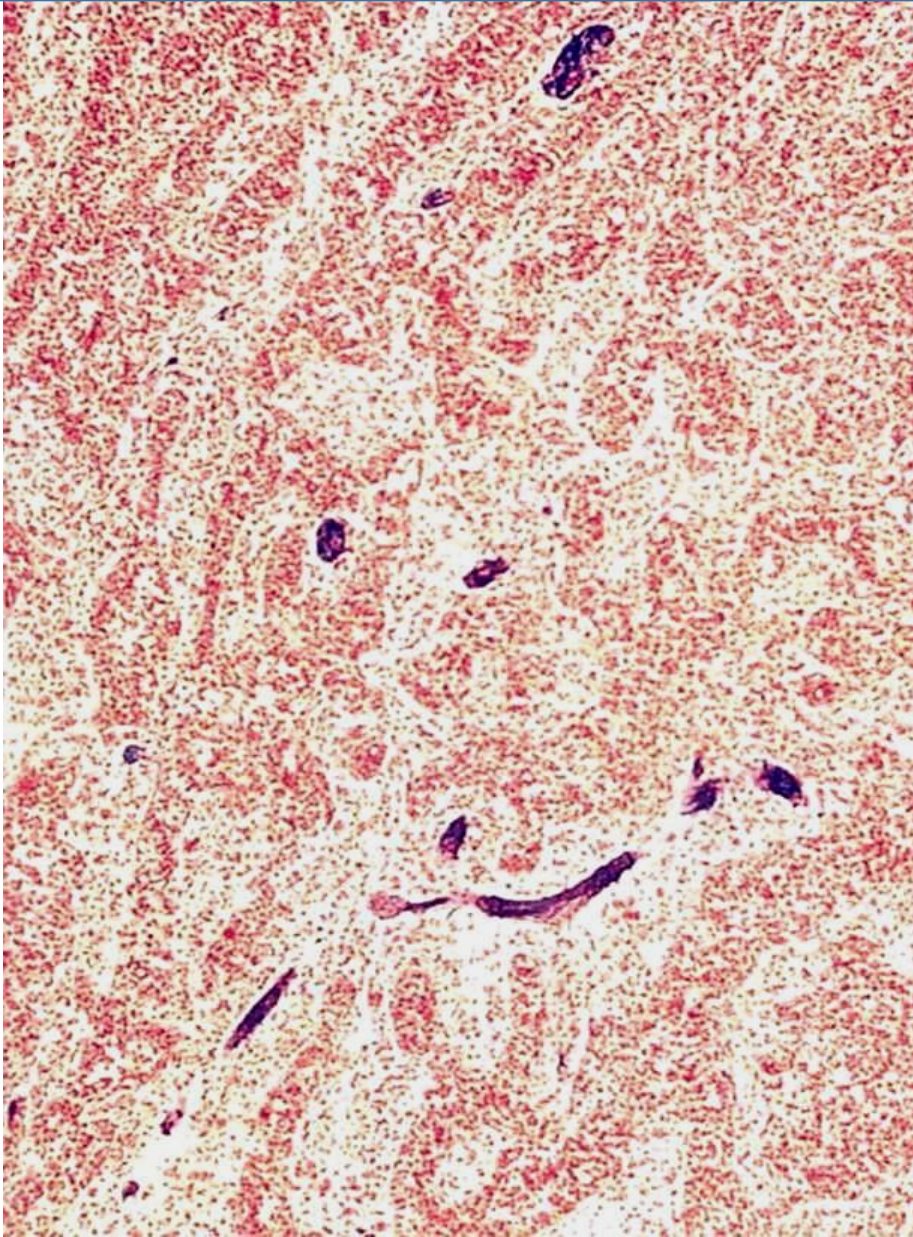
# LYMPH NODE (NODUS LYMPHATICUS, LYMPHONODUS)

subcapsular sinus

lymphatic follicle

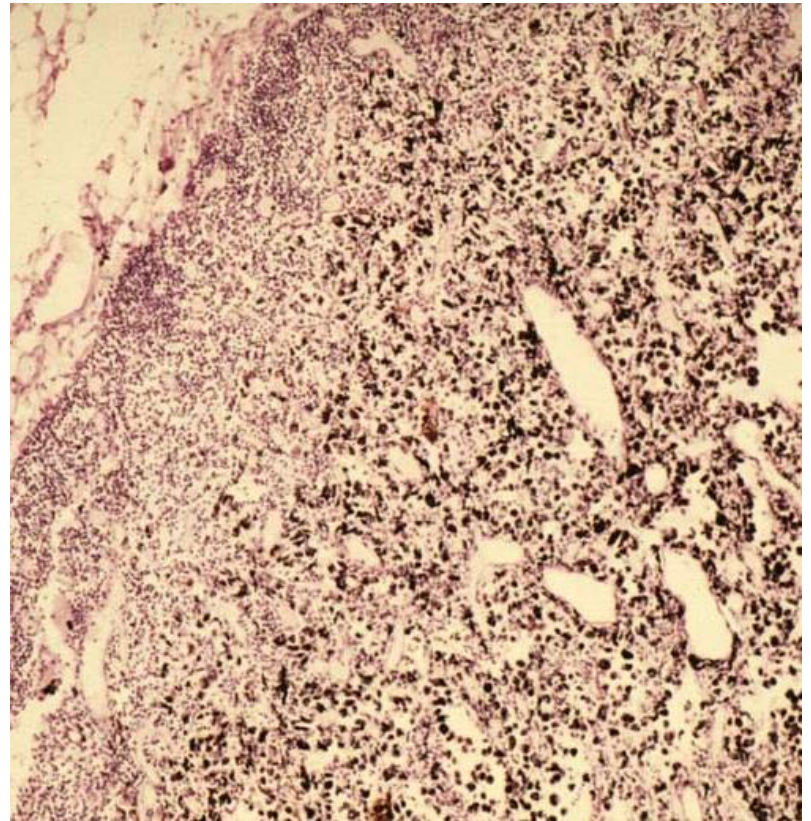


# LYMPH NODE MEDULLA

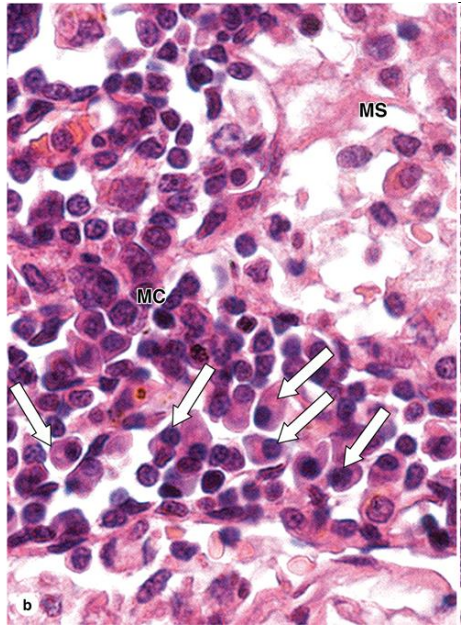
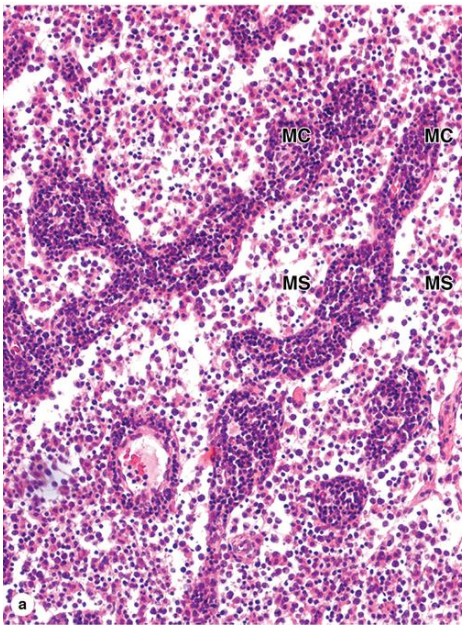


## Medullary cords and sinuses

Lymph node from lung hilus with dust (carbon) deposits



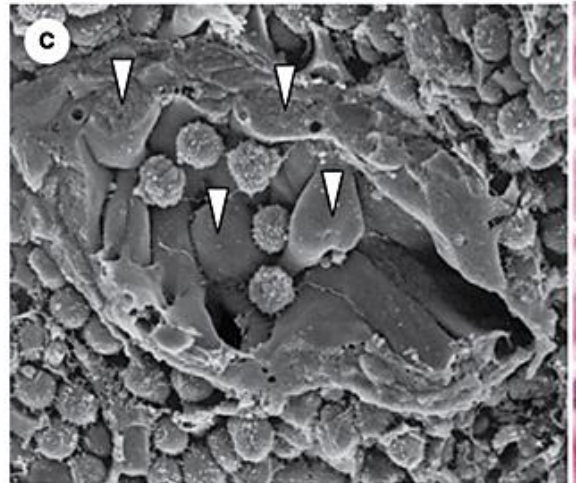
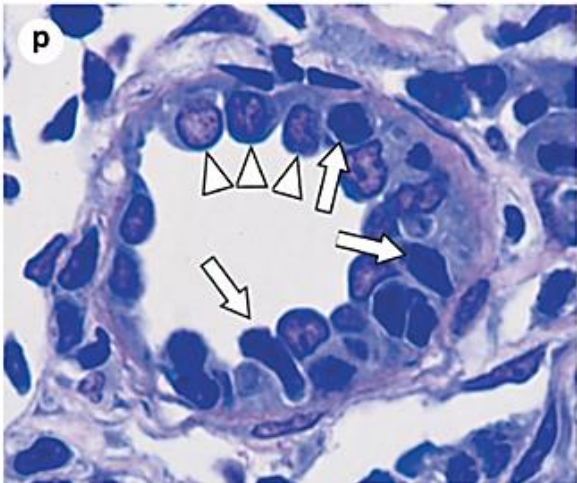
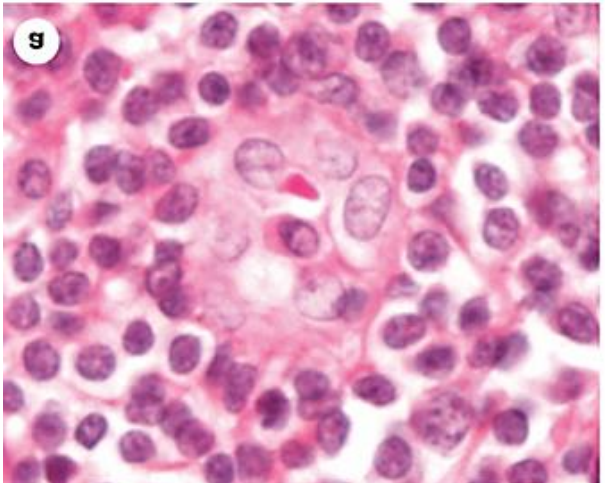
# LYMPH NODE MEDULLA



## Medullary cords and sinuses

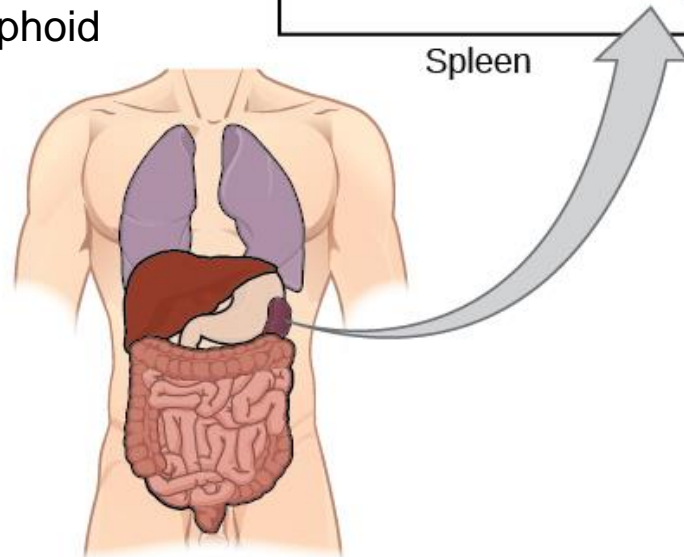
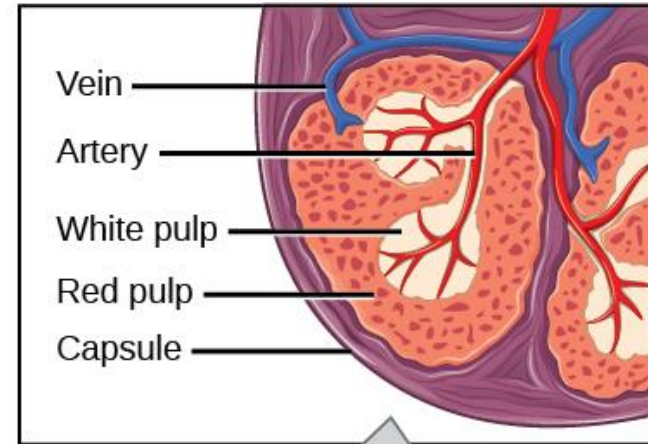
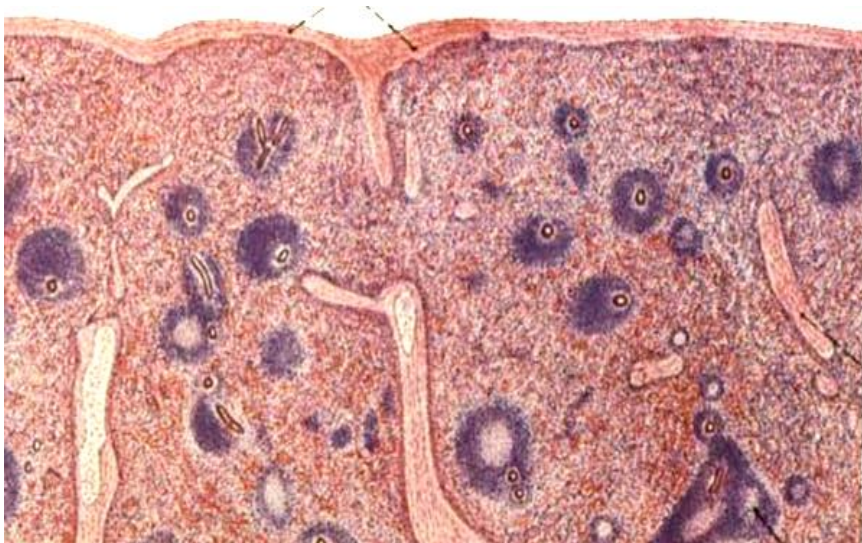
- Plasma cells in medullary cords
- High endothelium post-capillary venules – extravasation of leukocytes from blood to lymph node parenchyma

Mescher

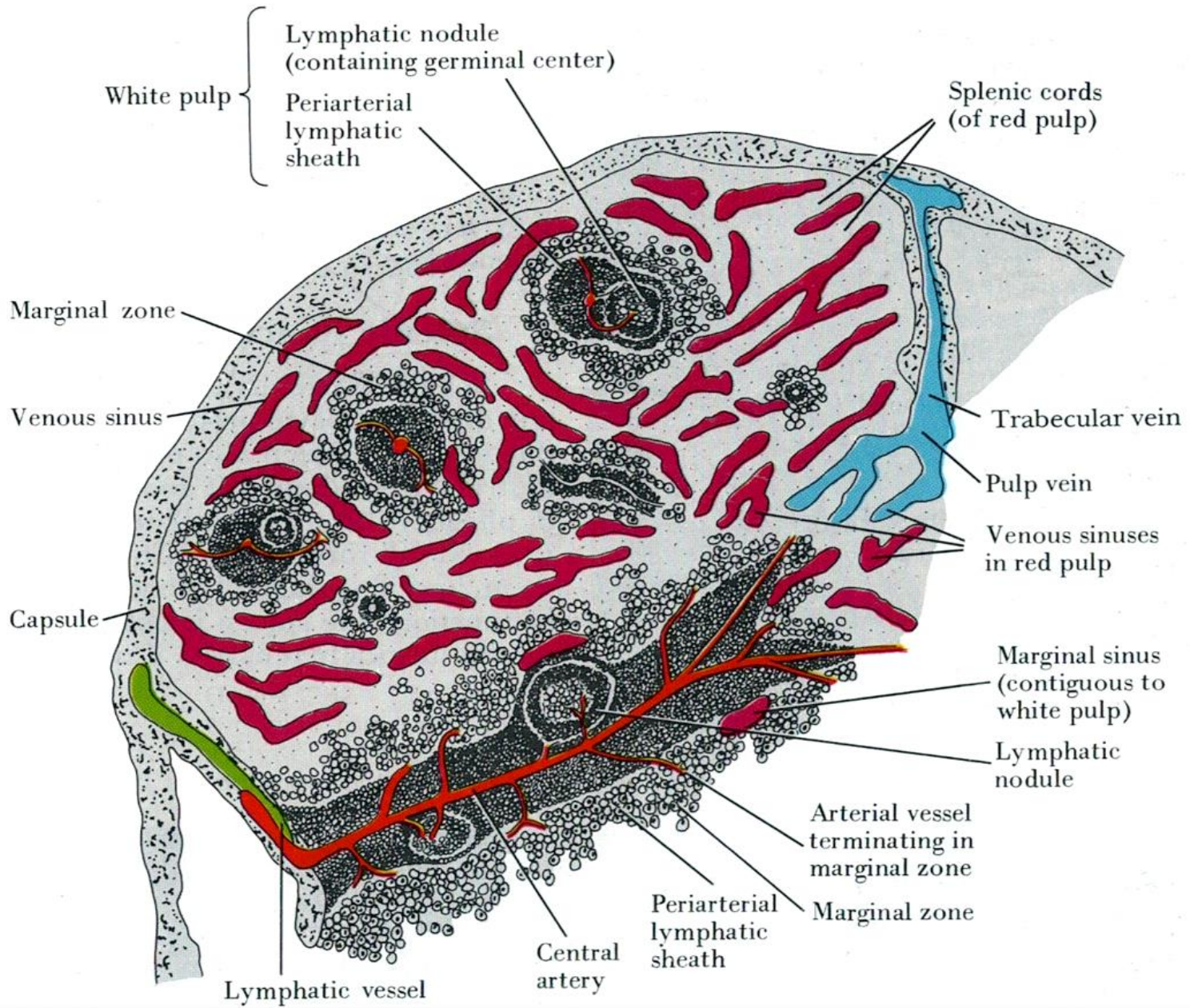


# SPLEEN (LIEN)

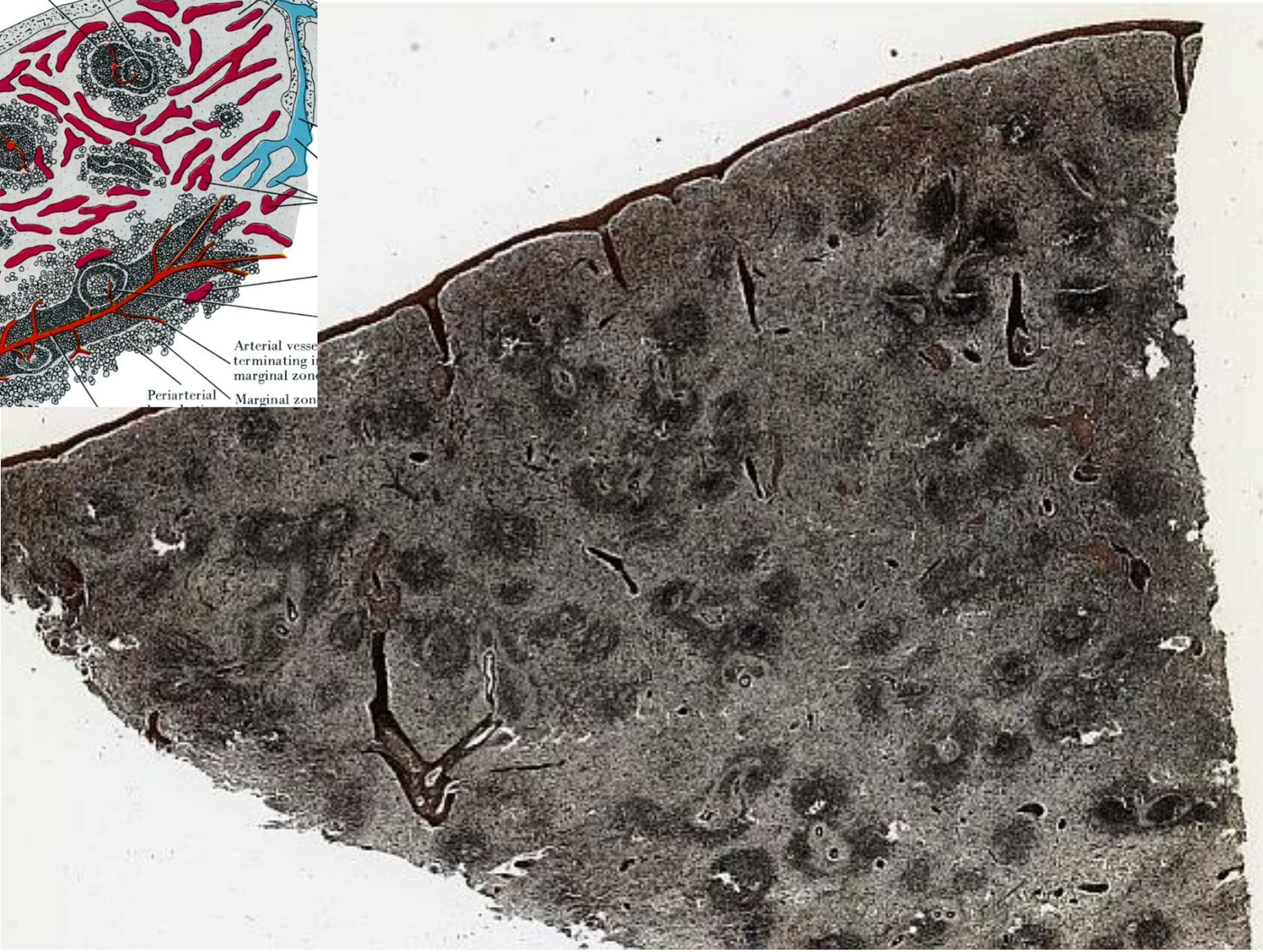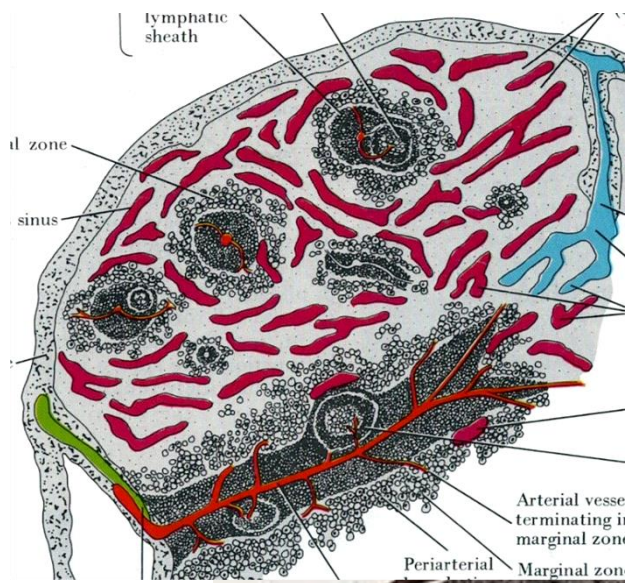
- C.t. capsule and trabecules
- Parenchyma = pulp
- **white** (lymphoid)
  - periarteriolar lymphatic sheath - PALS
  - Malpighian bodies - follicles)
- **red** (non-lymphoid)
  - cords of Billroth
  - venous sinuses
- **marginal zone** between lymphoid and non-lymphoid regions in the spleen



# SPLEEN (LIEN)

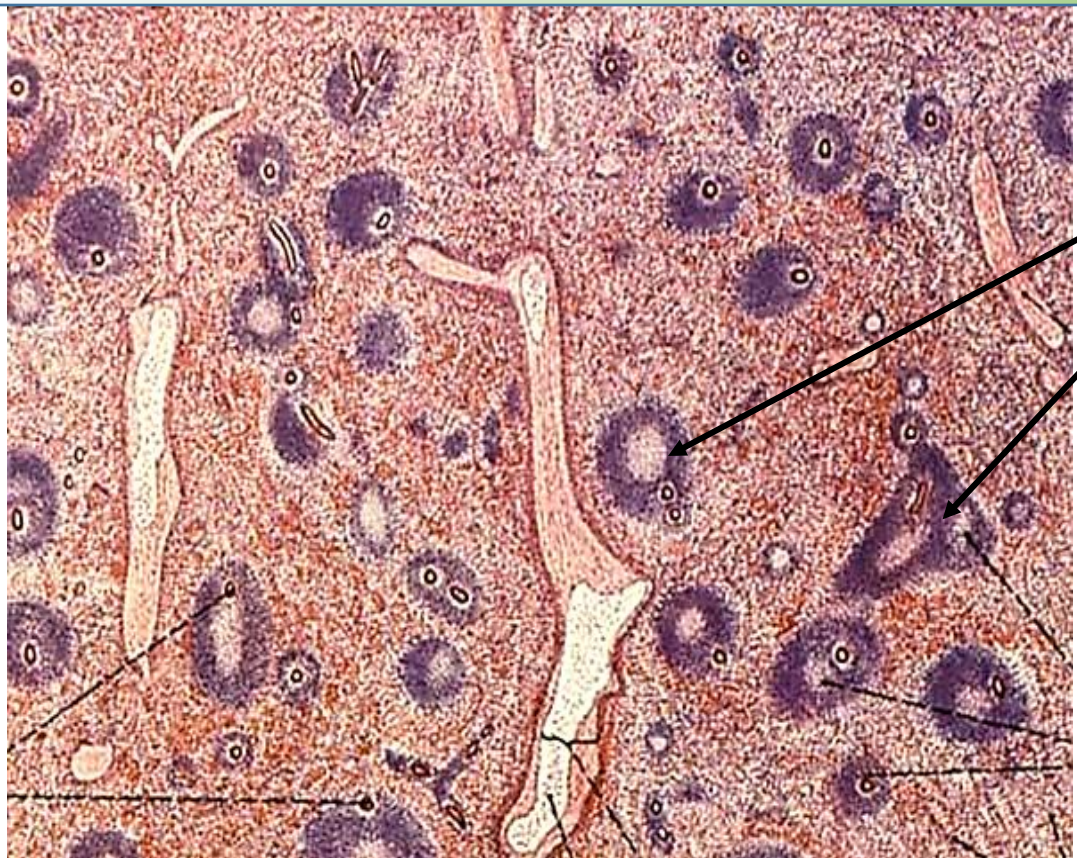


# SPLEEN (LIEN)

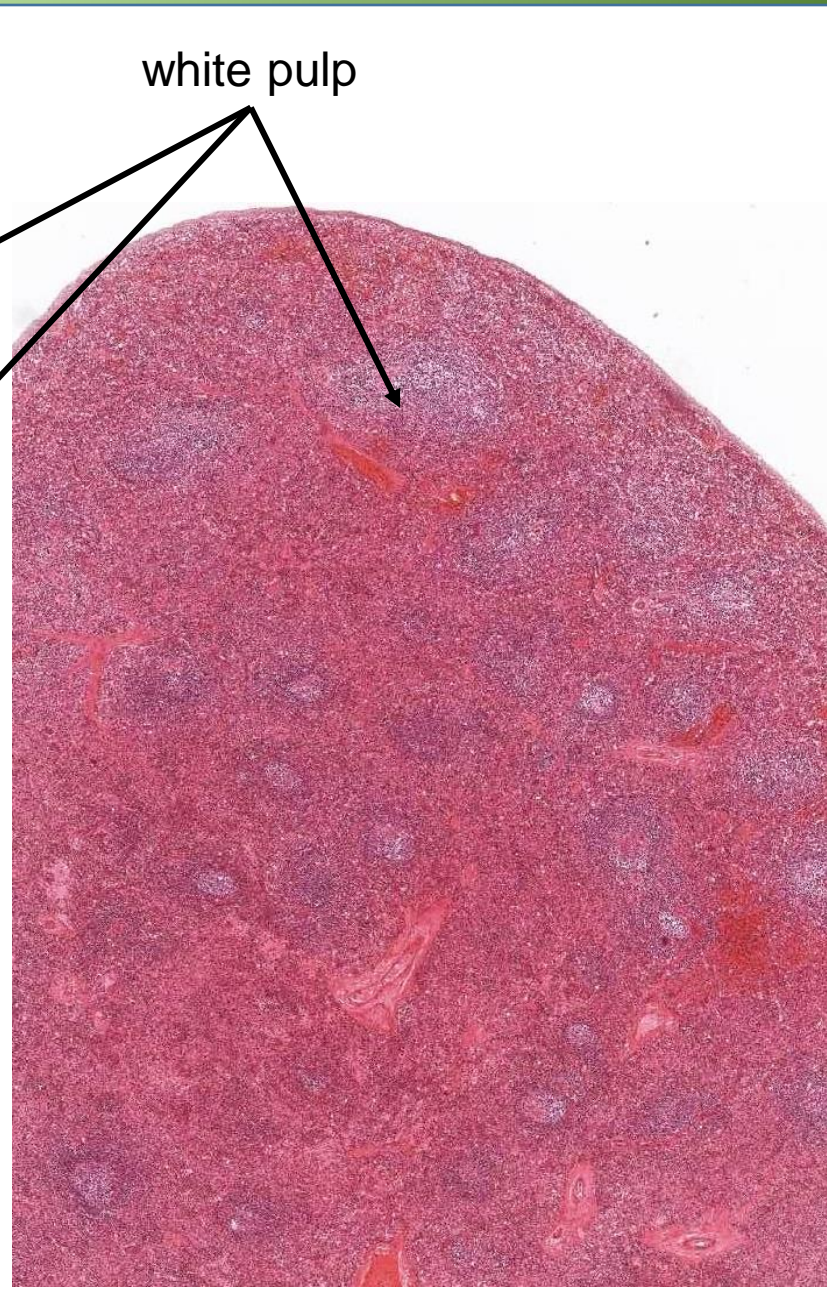



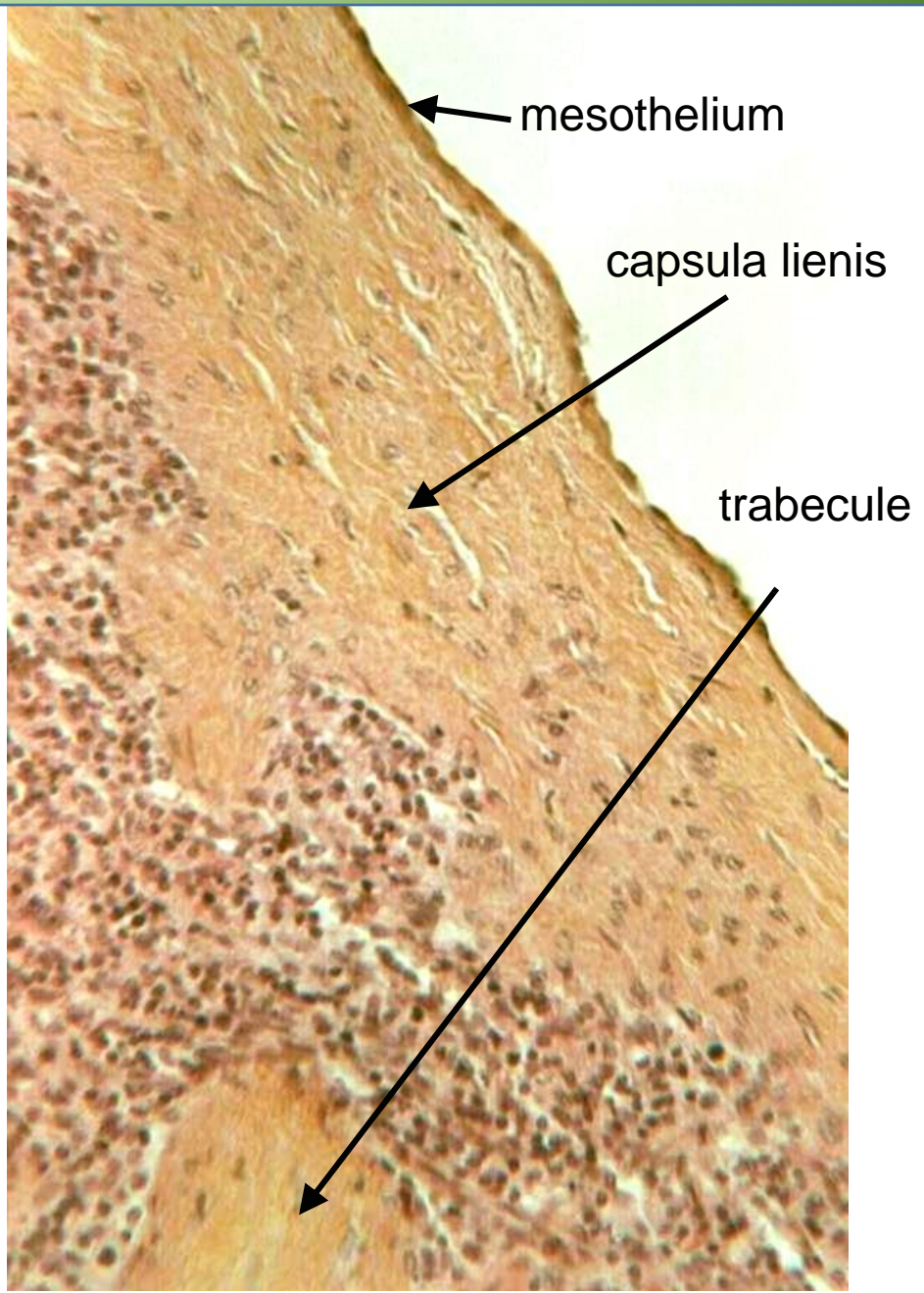
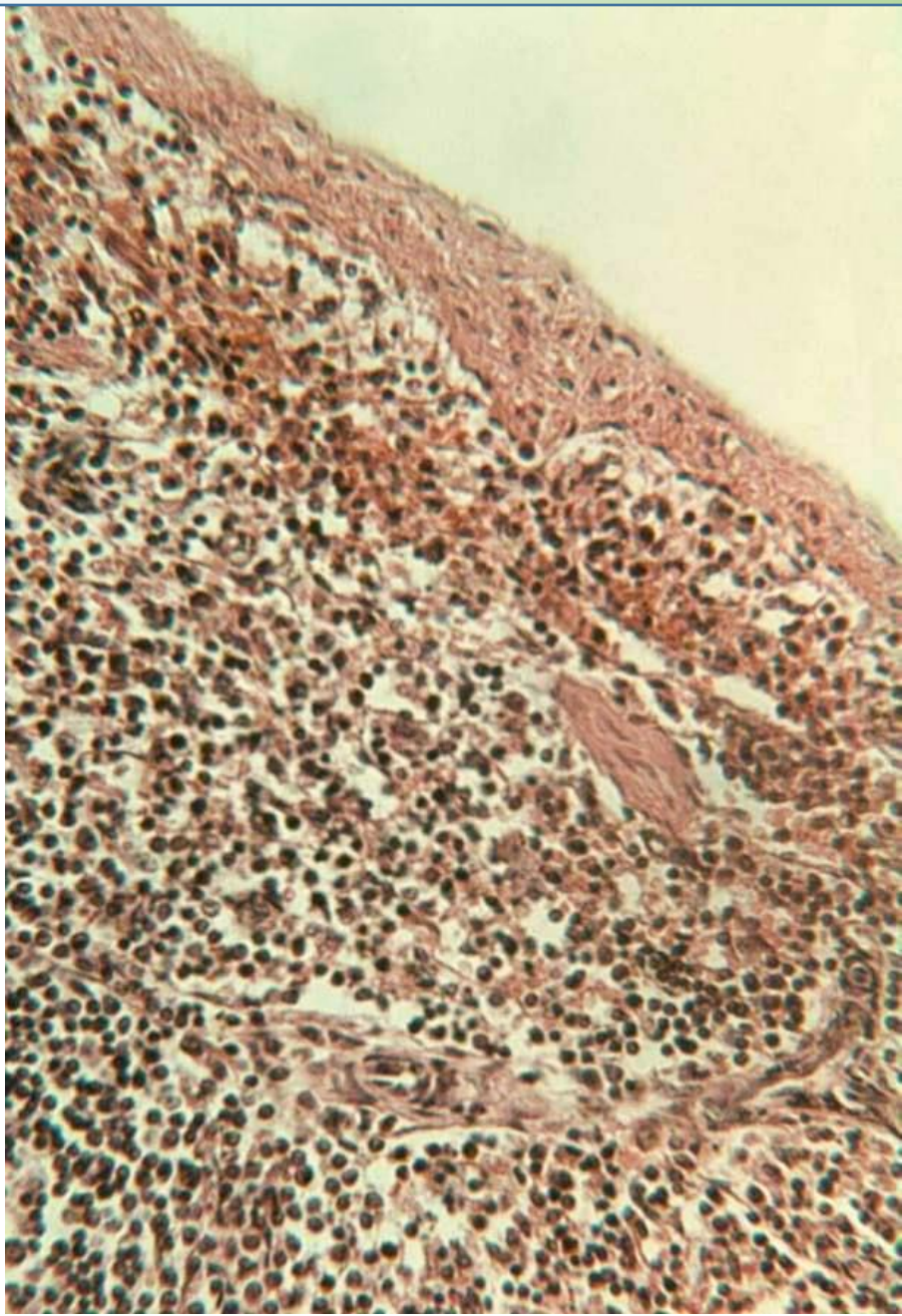
# SPLEEN (LIEN)



Sobotta



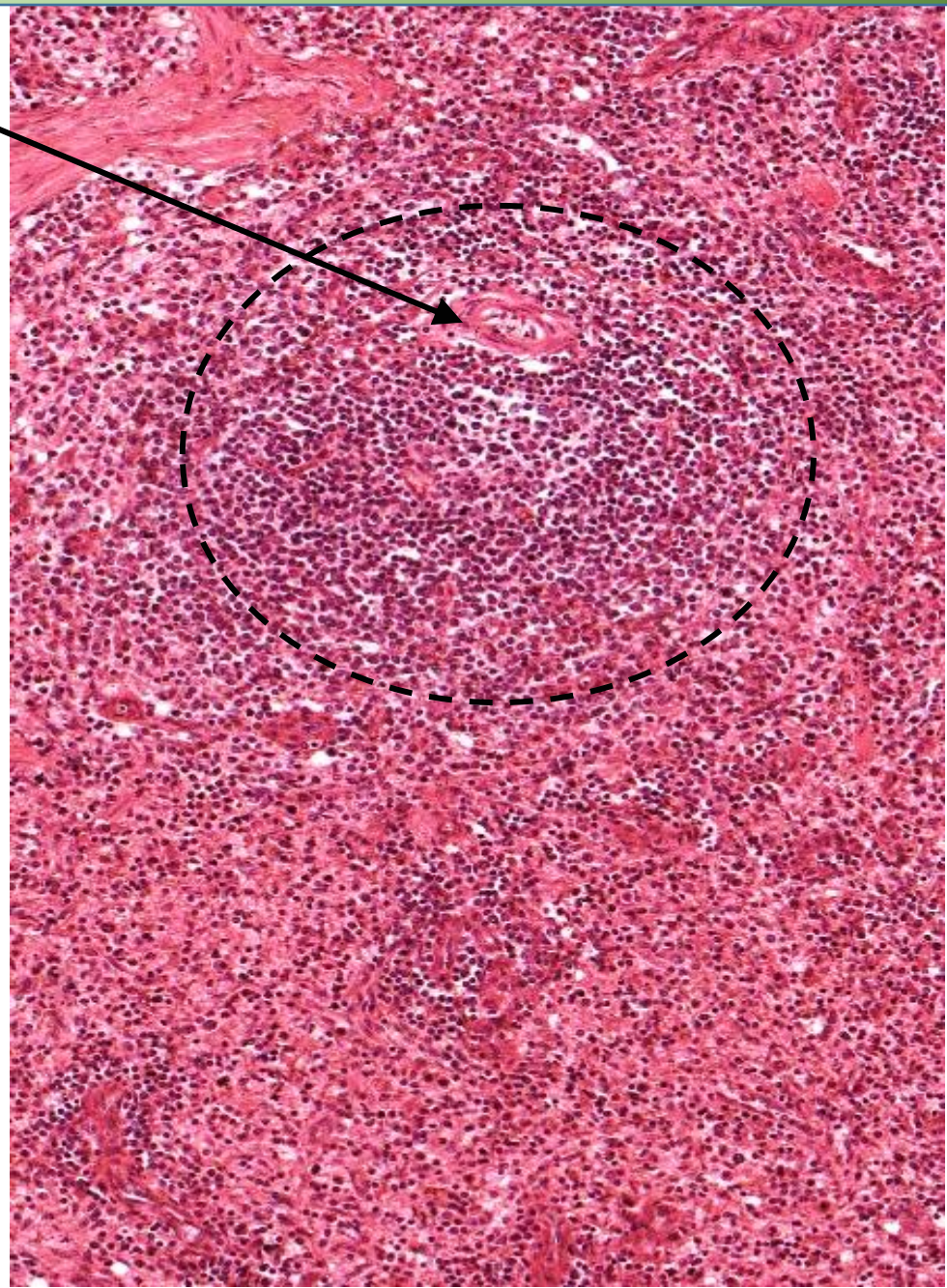
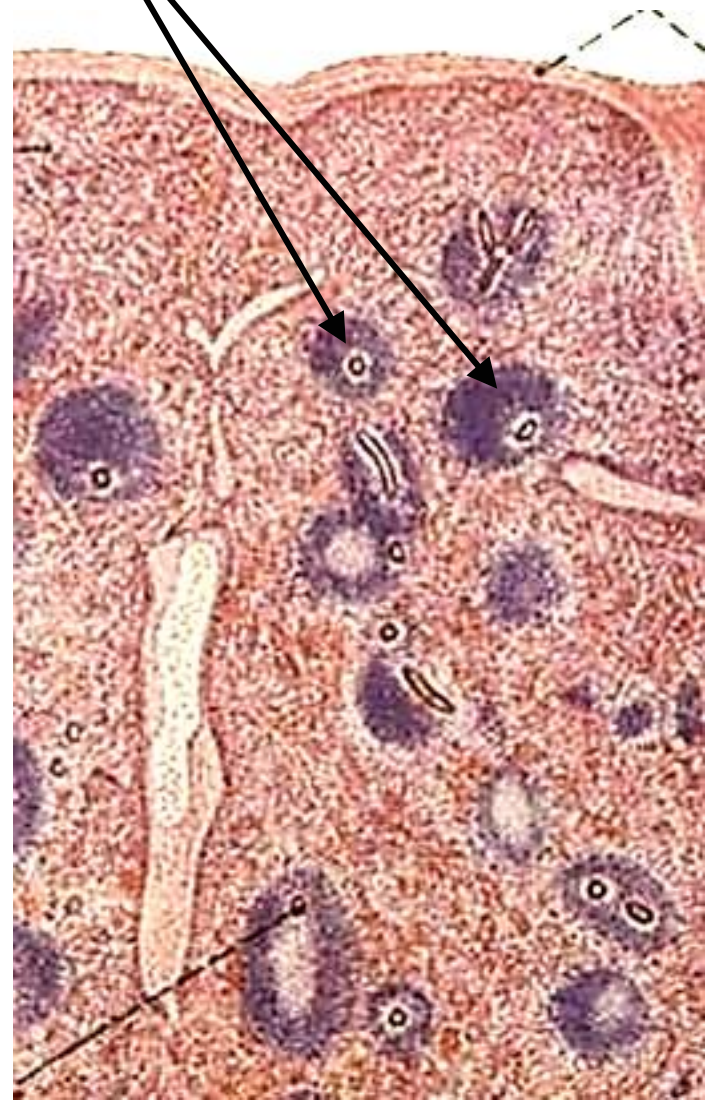# SPLEEN (LIEN)



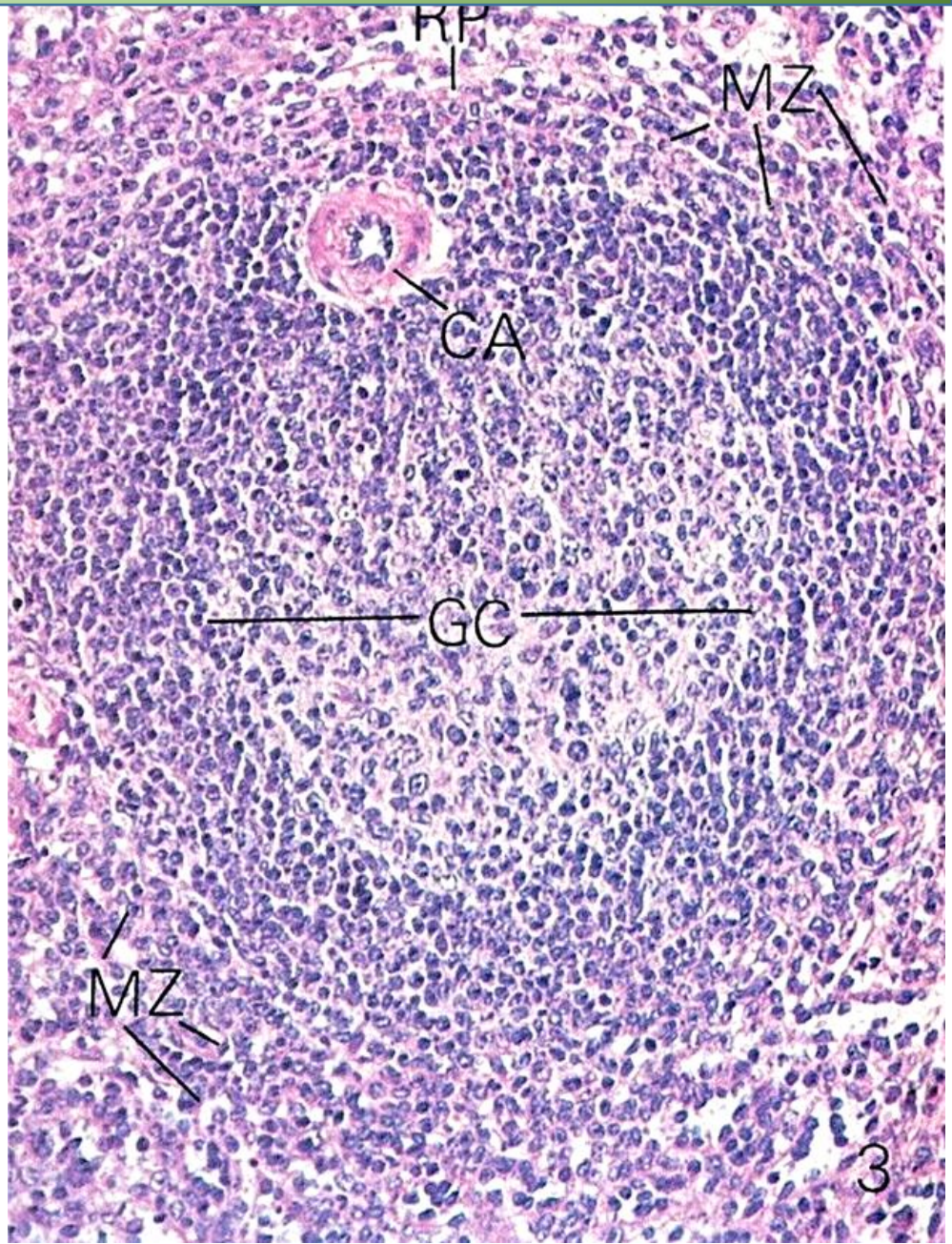
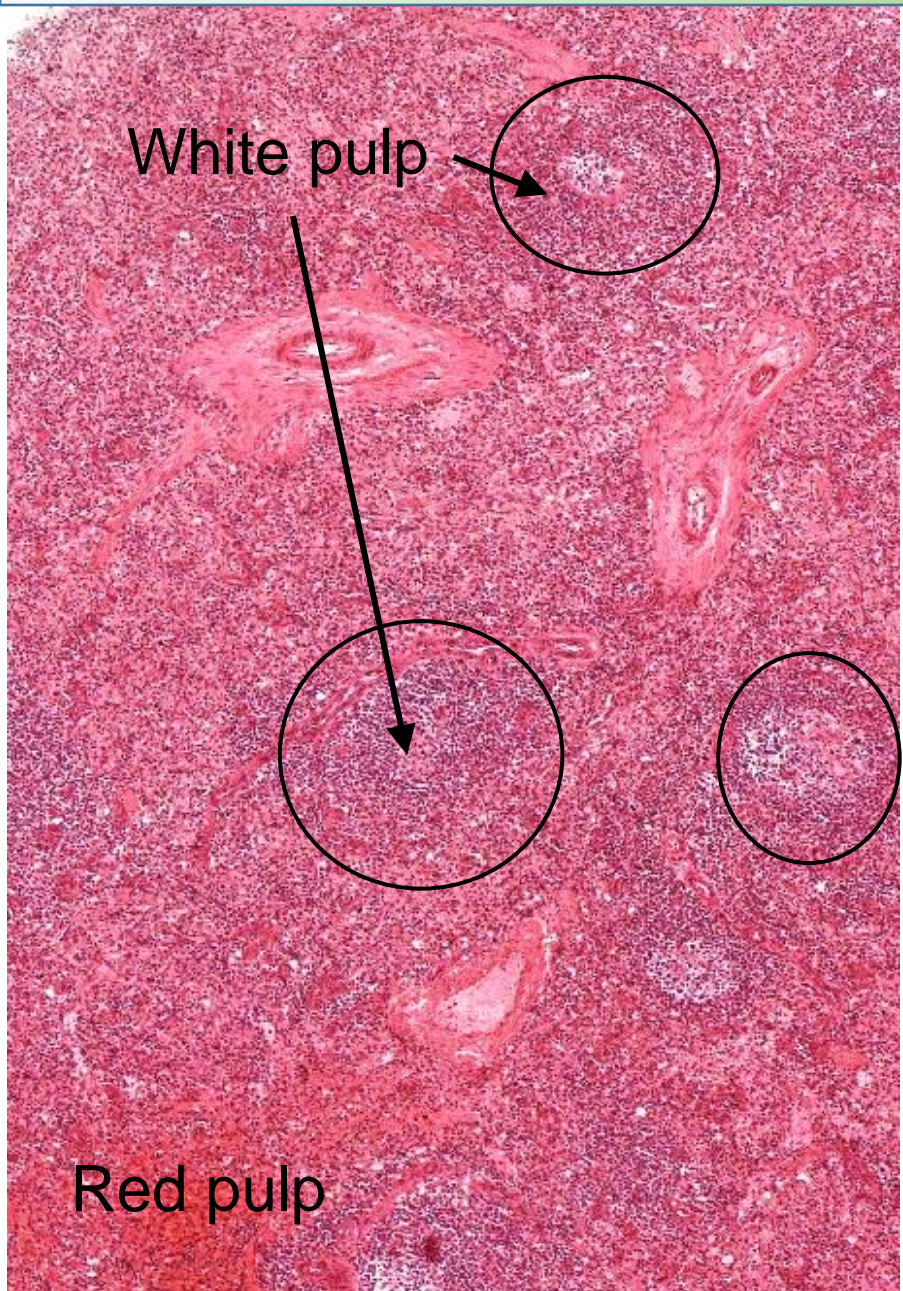# SPLEEN (LIEN)

White pulp


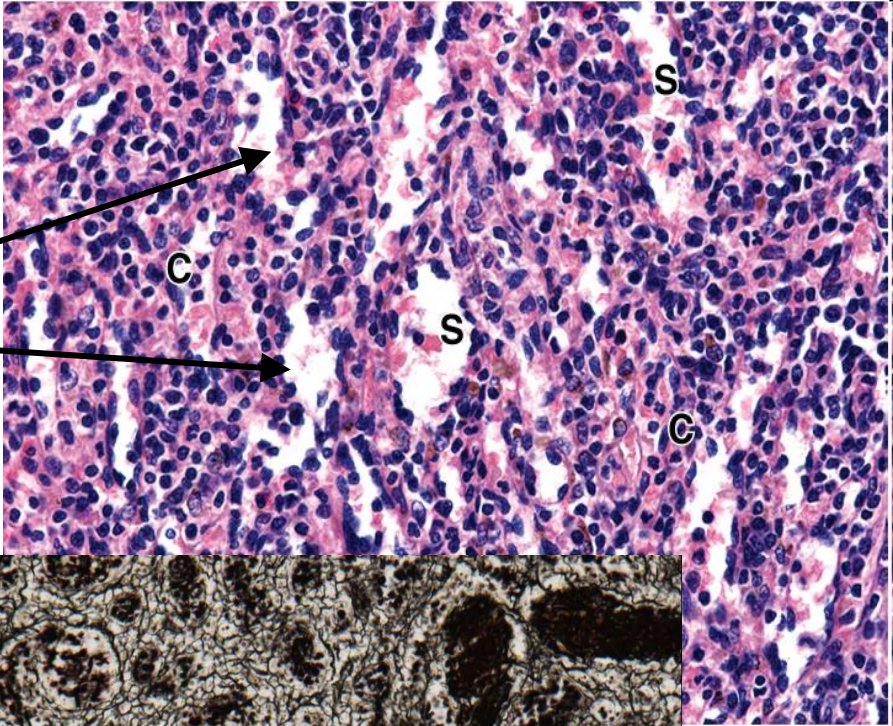
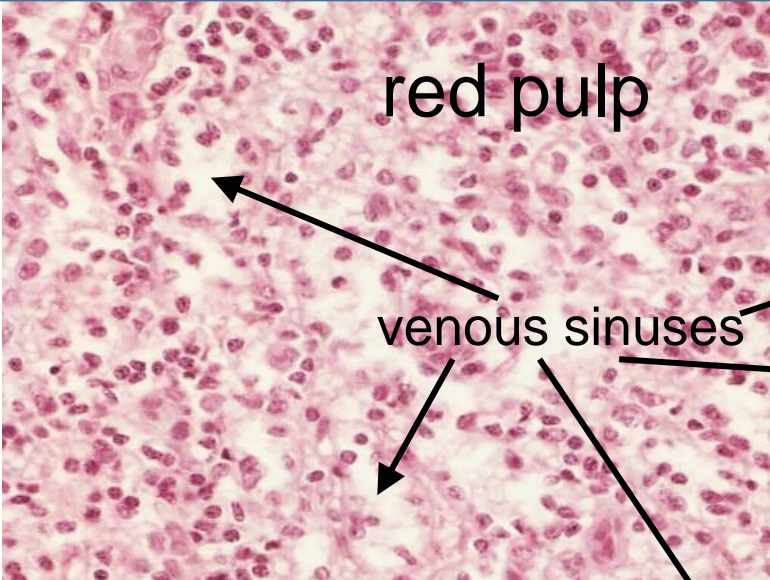
a. centralis



# SPLEEN (LIEN)



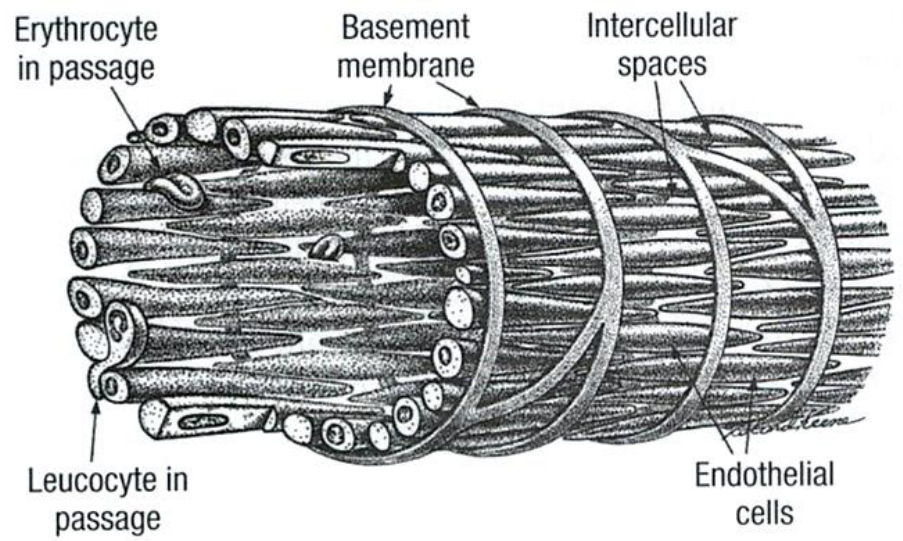
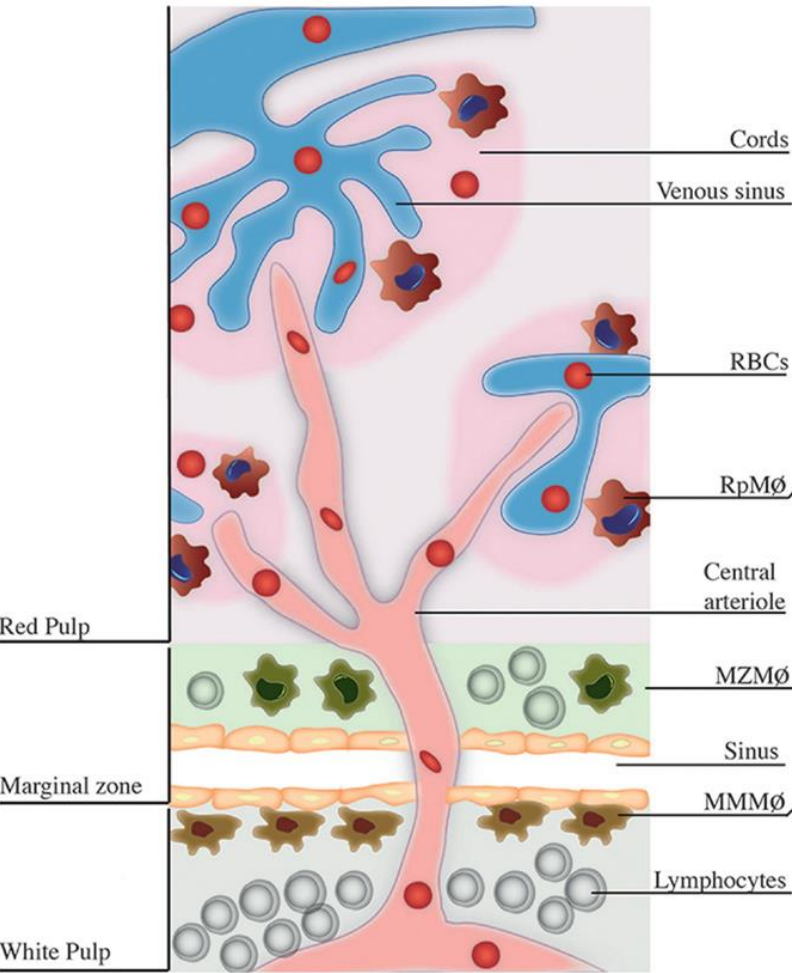
# SPLEEN (LIEN)



Mescher

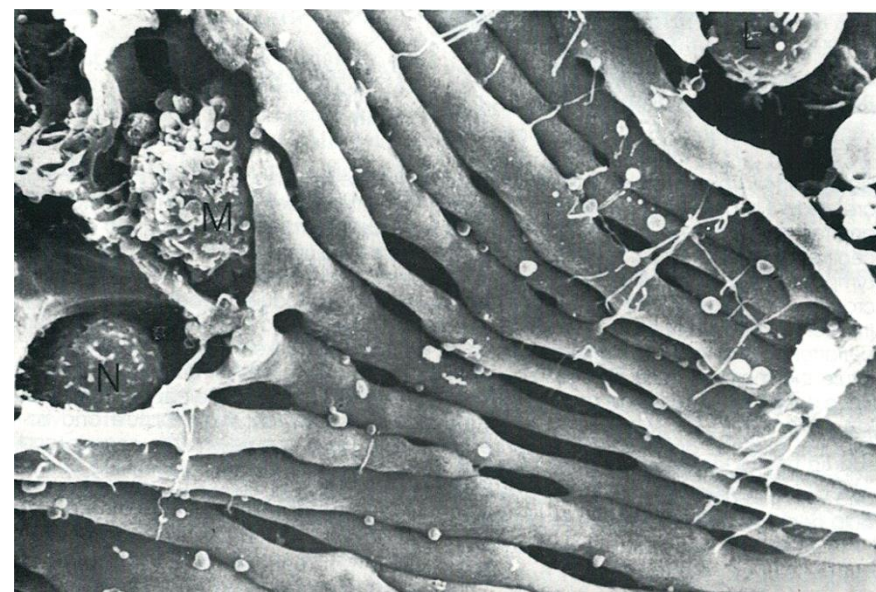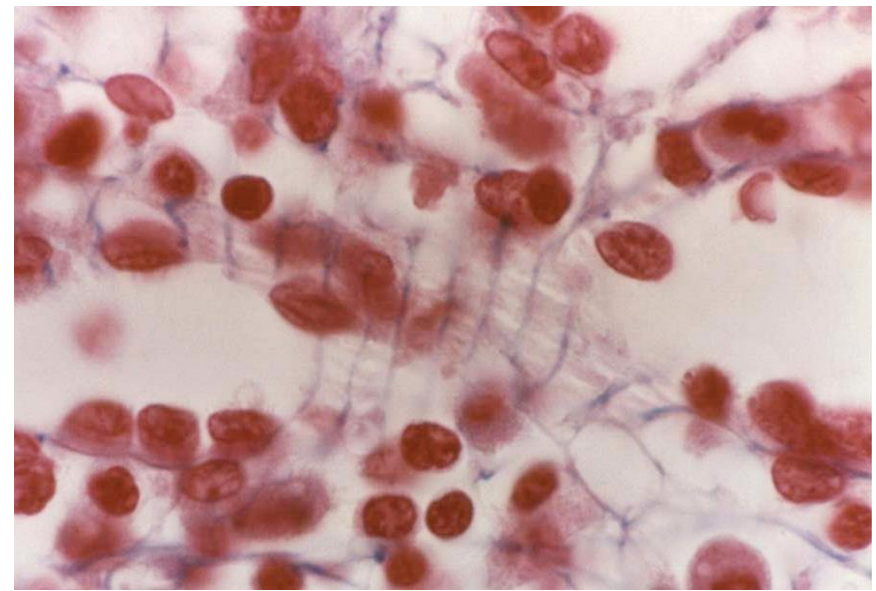
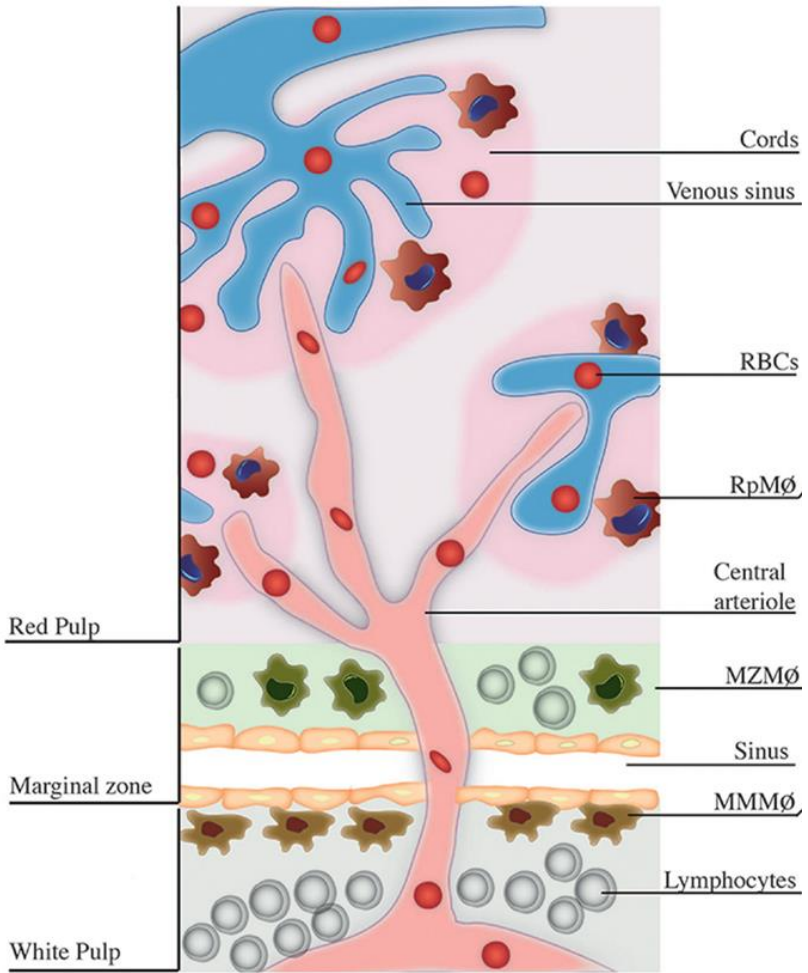
# SPLEEN (LIEN)

- Venous sinuses of red pulp
- Removal of abnormal erythrocytes



# SPLEEN (LIEN)

- Venous sinuses of red pulp
- Removal of abnormal erythrocytes

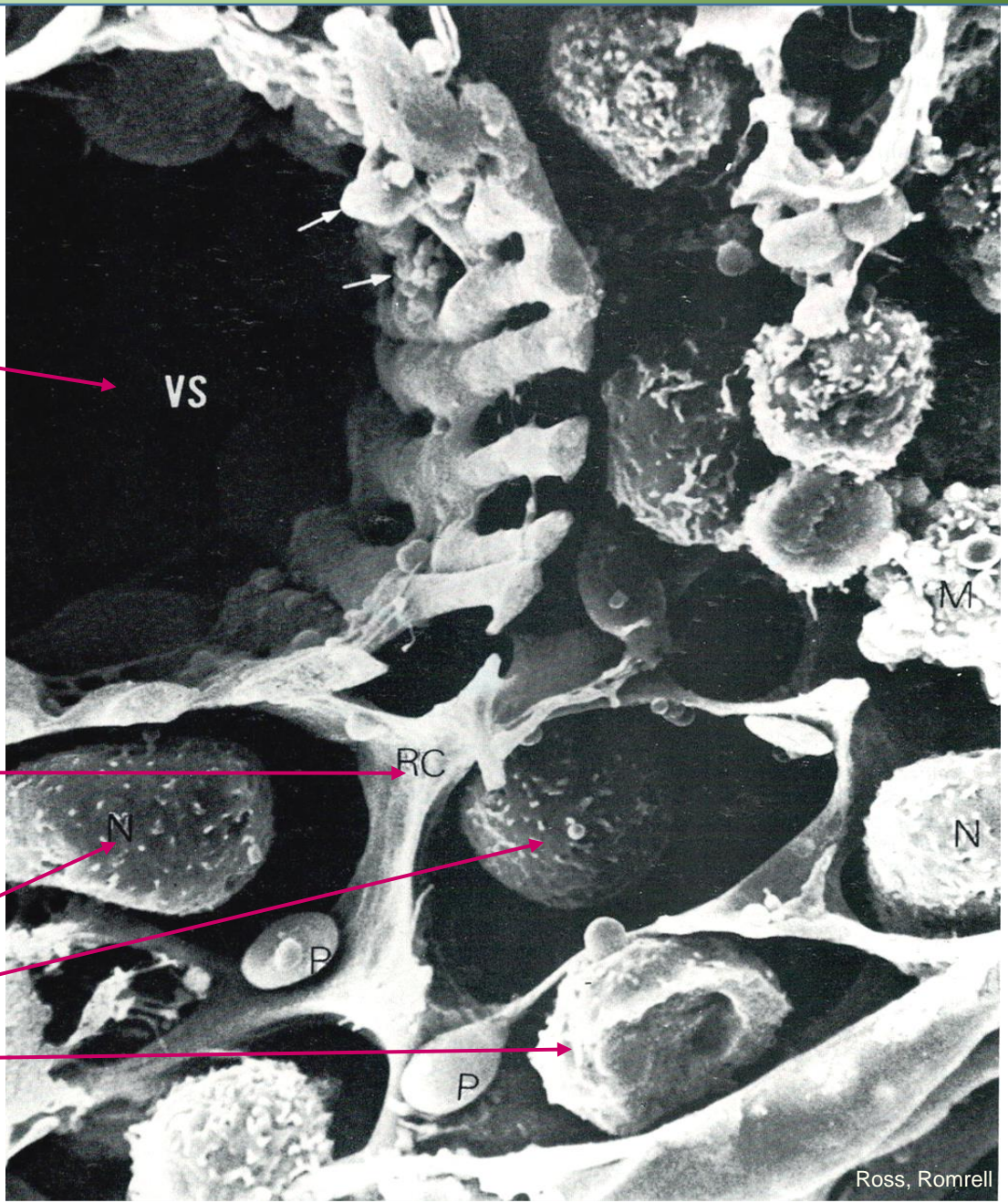


# SPLEEN (LIEN)

Venous sinus

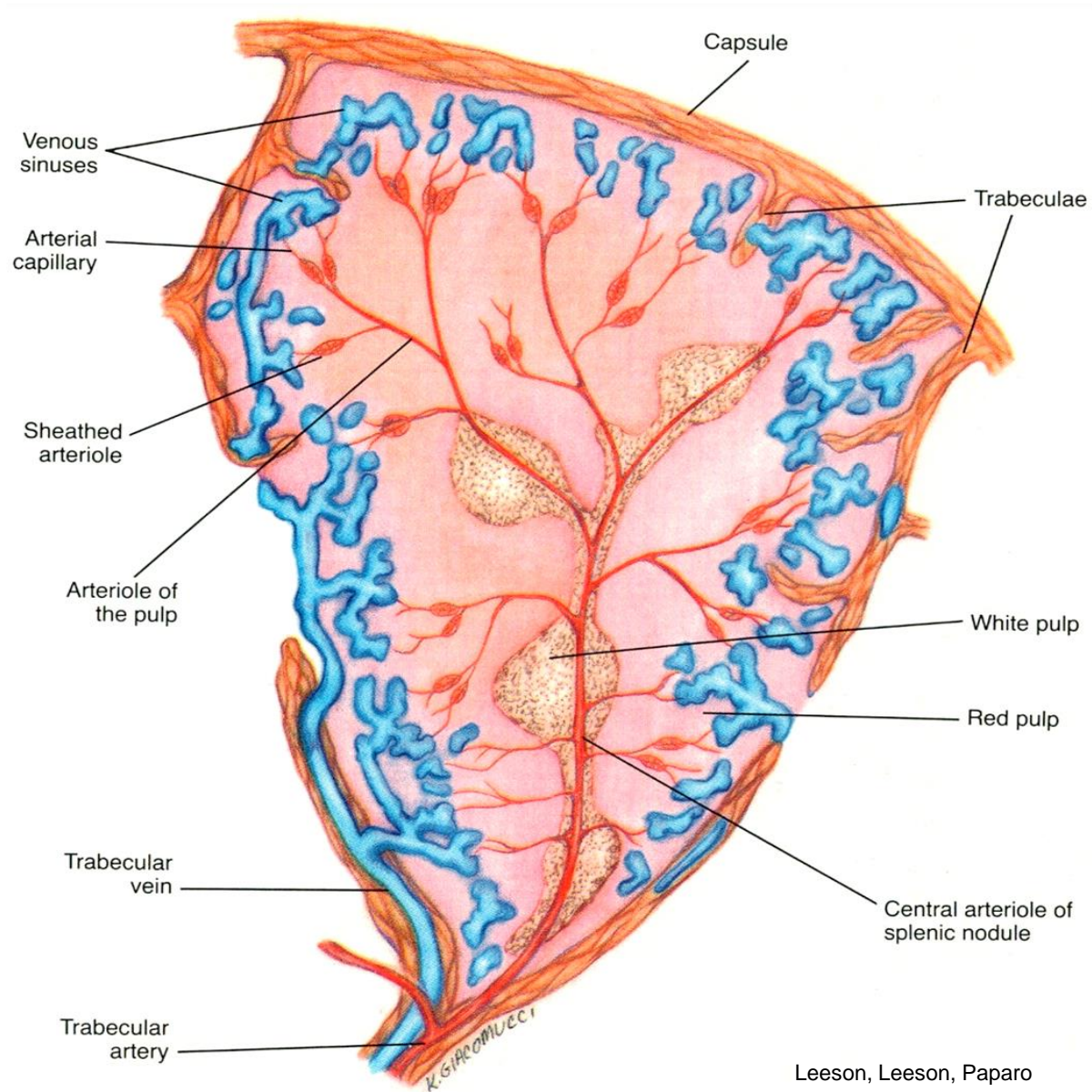
Reticular cell

Cells in circulation





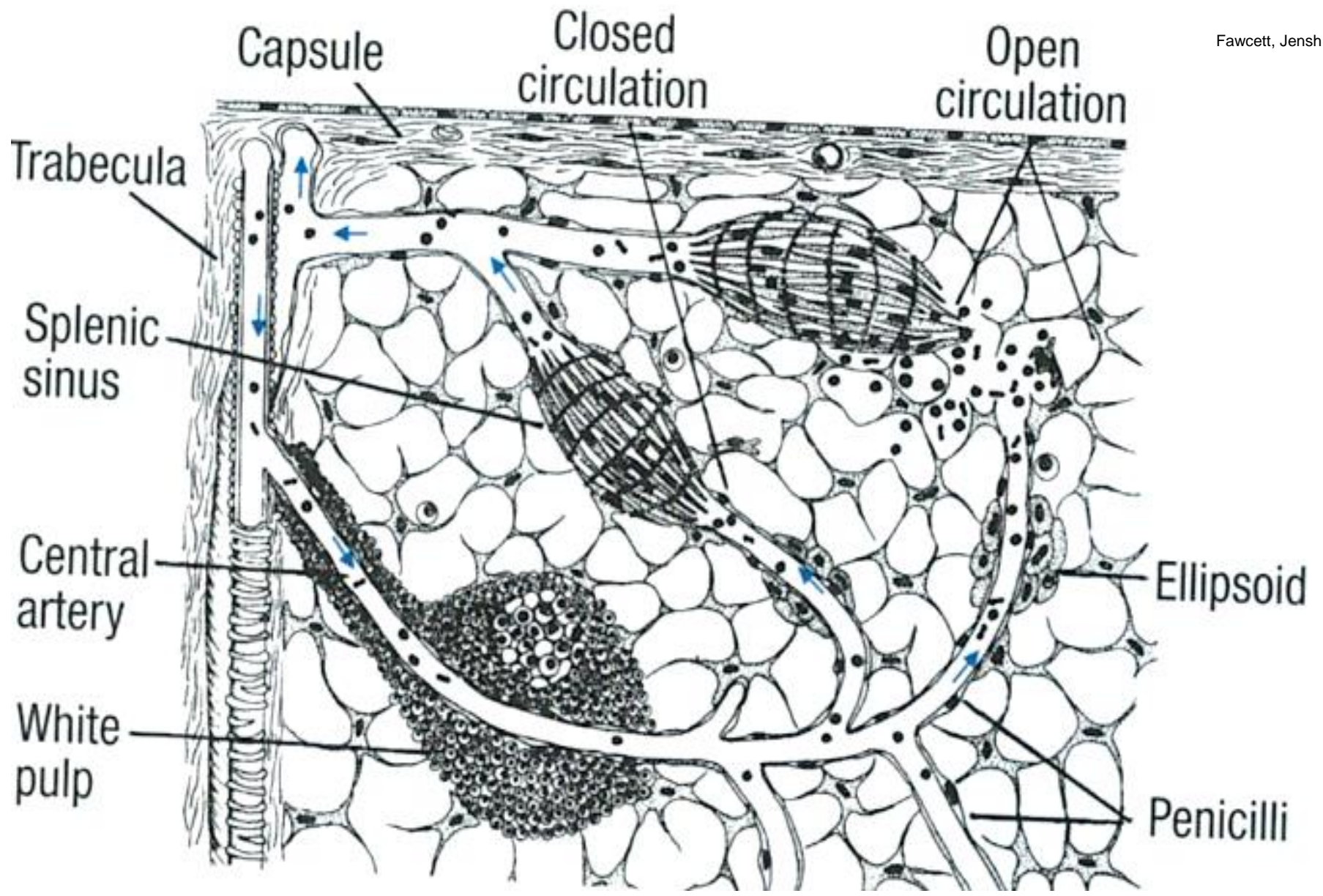
# SPLEEN BLOOD CIRCULATION



- a. lienalis
- aa. trabeculares
- aa. centrales
- arteriolae penicillatae
- (*arteriole of the pulp, sheathed arteriole*)
- venous sinuses
- veins of the pulp
- vv. trabeculares
- v. lienalis

# SPLEEN – OPEN AND CLOSED CIRCULATION

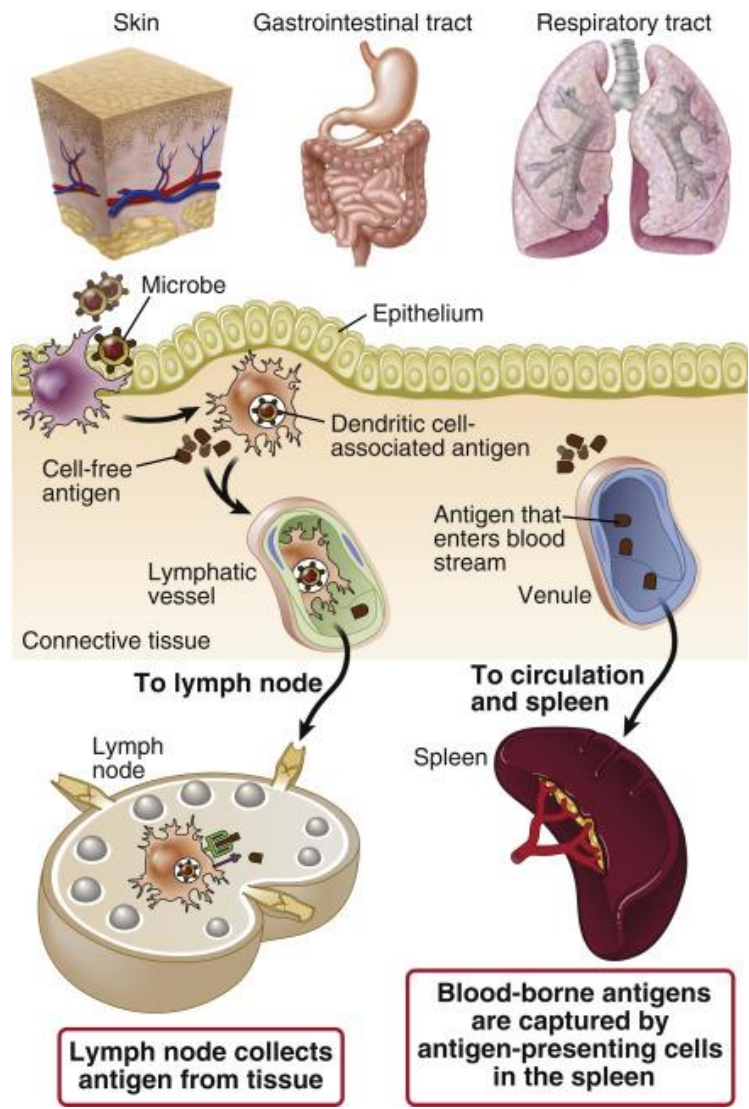
Fawcett, Jensch



# SPLEEN AND LYMPH NODE IN ANTIGEN RECOGNITION

Lymph node

Spleen

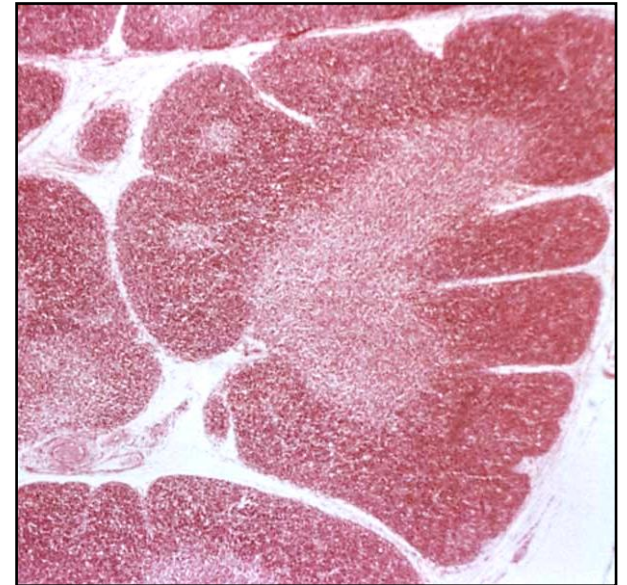
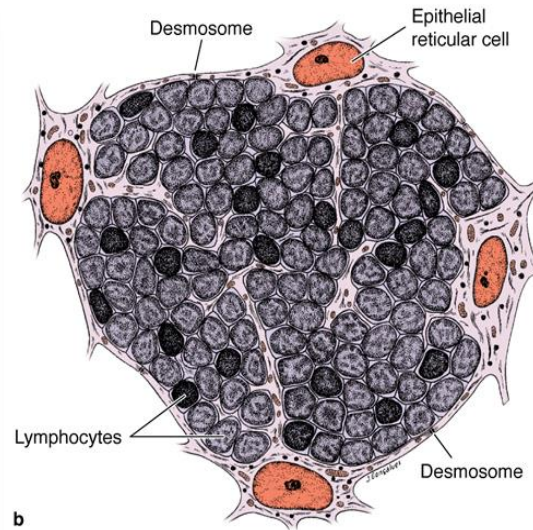
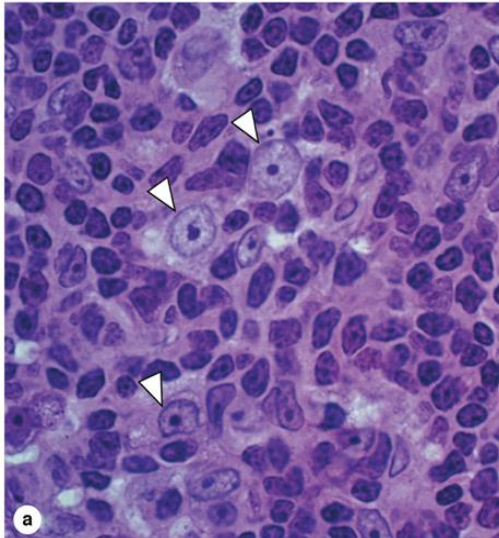
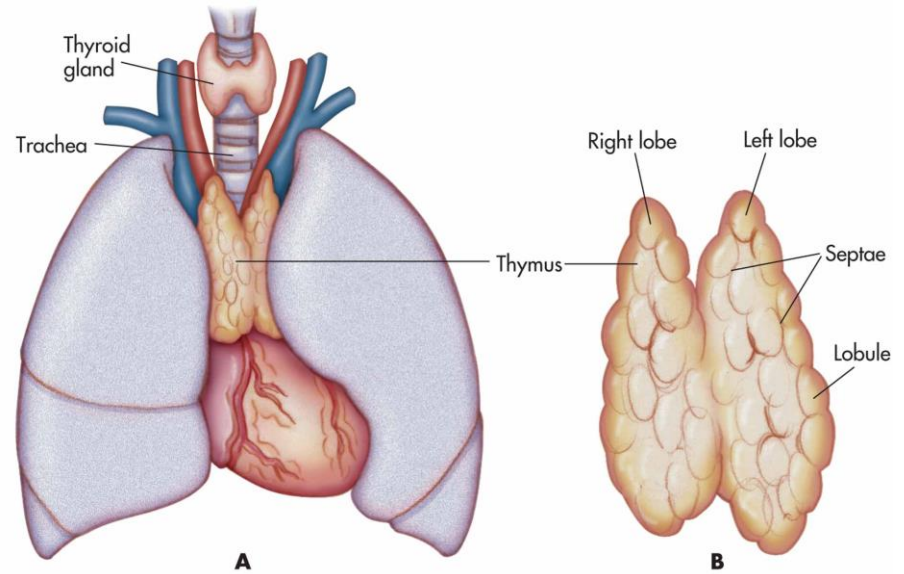


Lymph filter

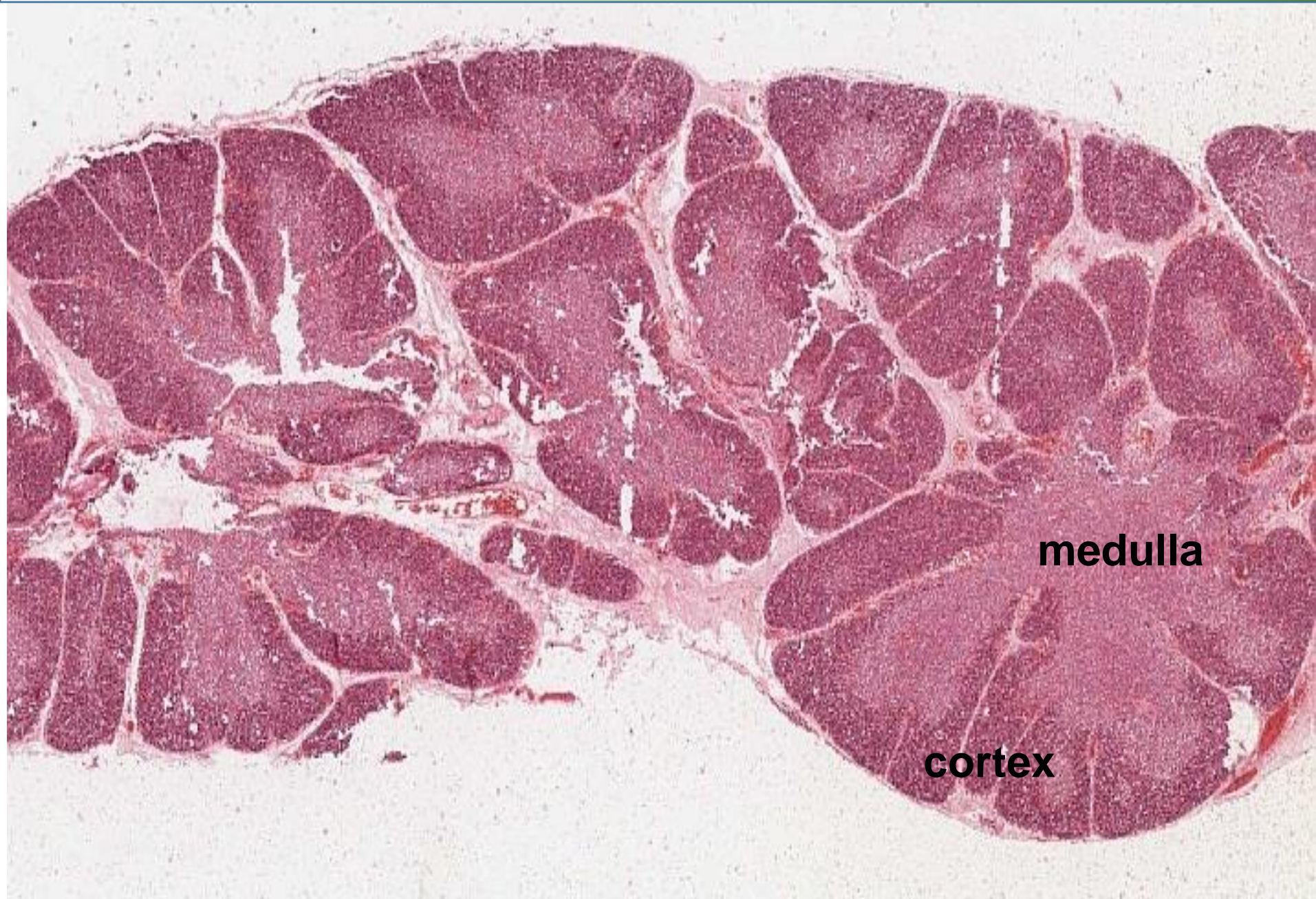Blood filter

# THYMUS

- c.t. capsule
- parenchyma: cortex and medulla
- epithelial reticulum and T-cells
- Hassal bodies



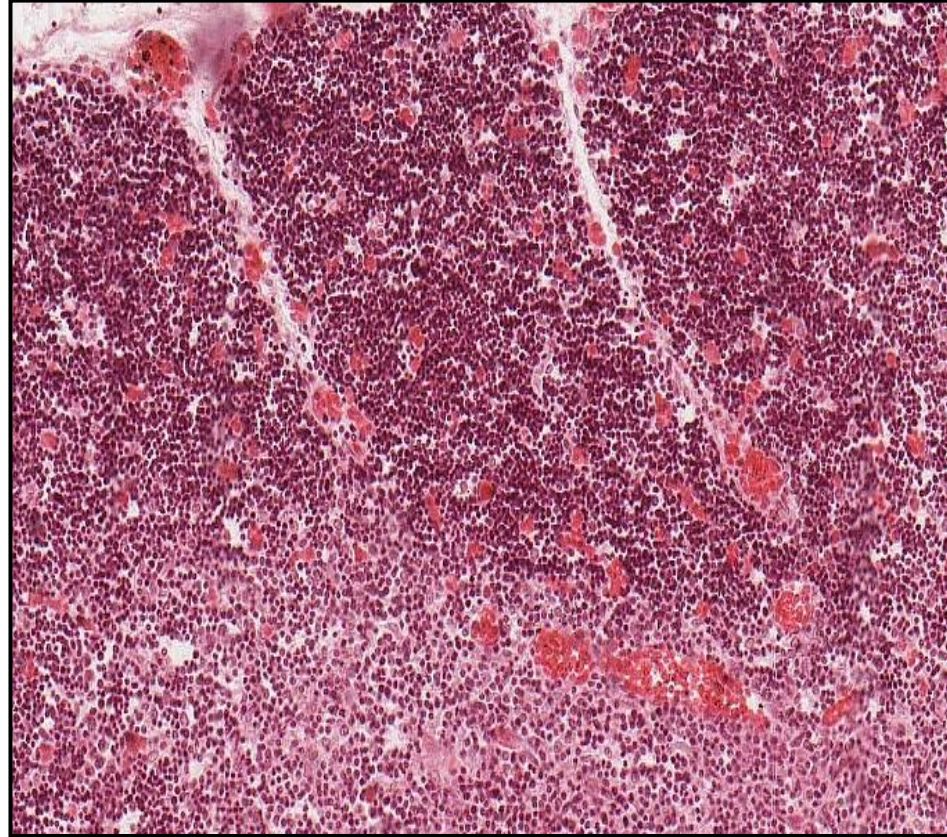
# THYMUS (YOUNG)



# THYMUS (CORTEX)

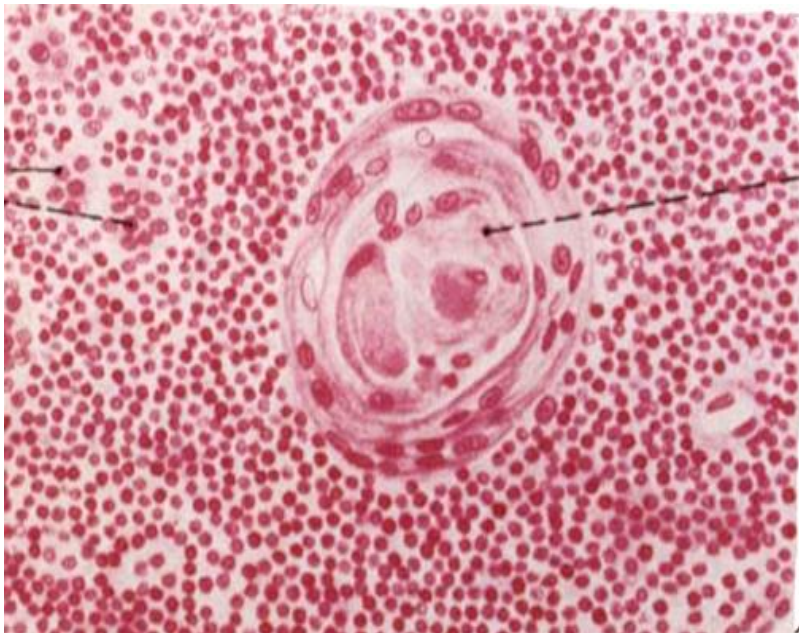
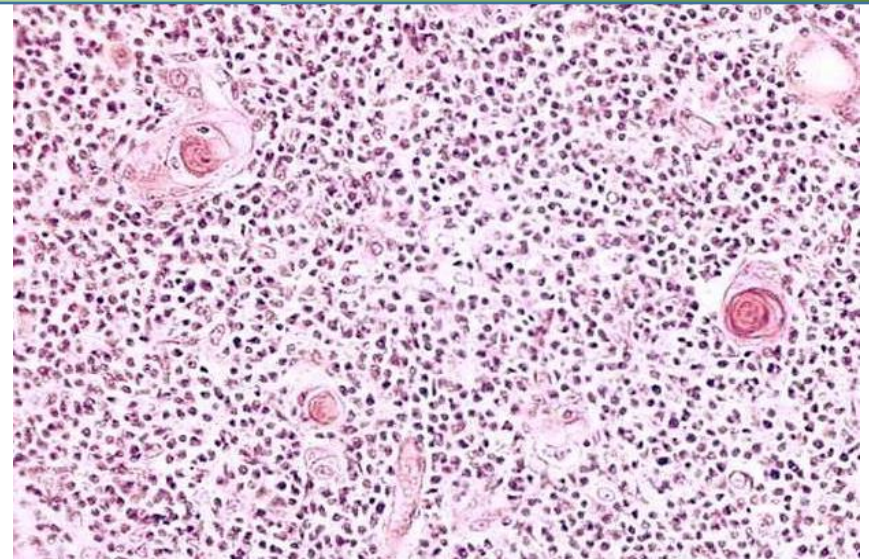
## Cortex:

- T-cell proliferation, acquisition of **immunocompetence**
- **positive selection** (functional TCR → survival)
- **hemato-thymic barrier** (endothelium + basal lamina + cell of cytotreticulum)
- prevents premature contact with antigens

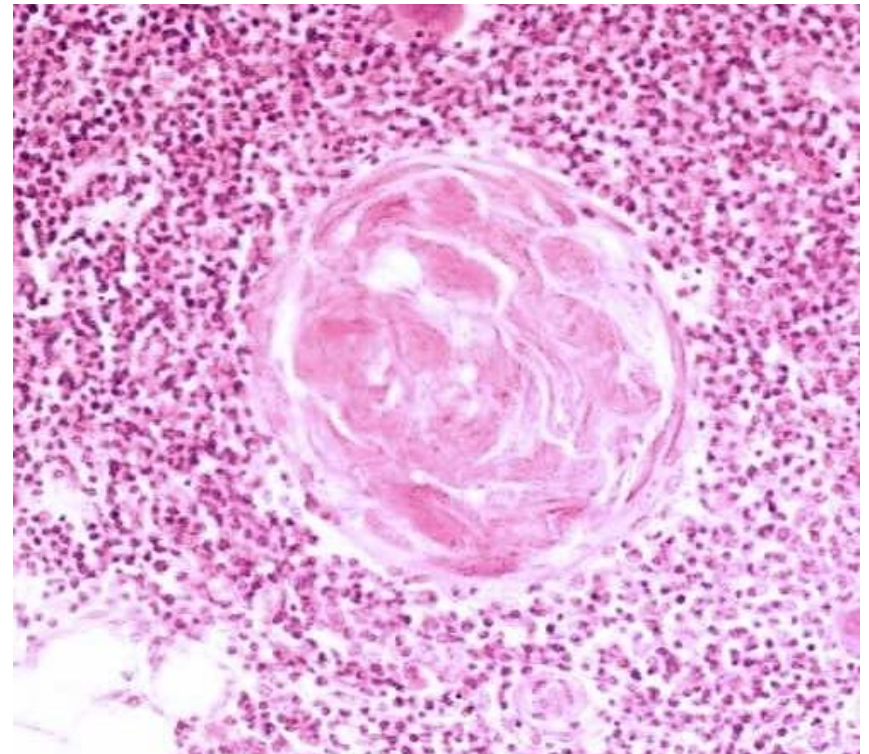


# THYMUS (MEDULLA)

- **negative selection**
- prevention of autoimmune reaction
- overall survival 2-3%
- cytotreticulum
- hemato-thymic barrier absent

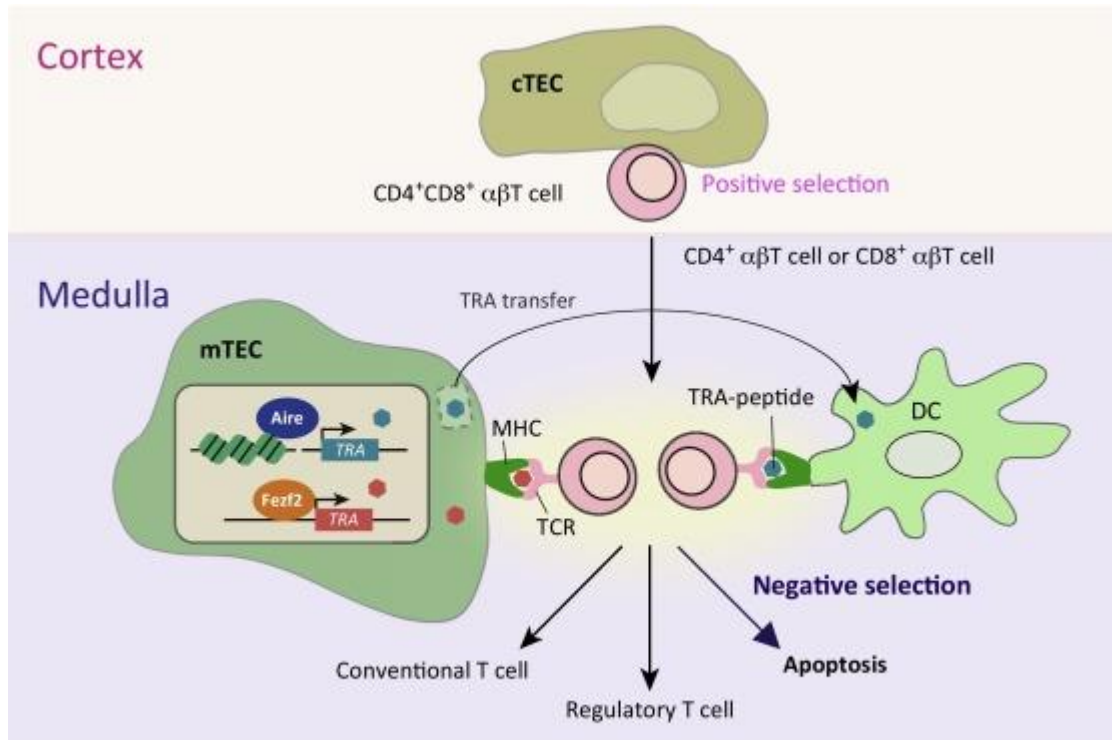


Hassal bodies in medulla



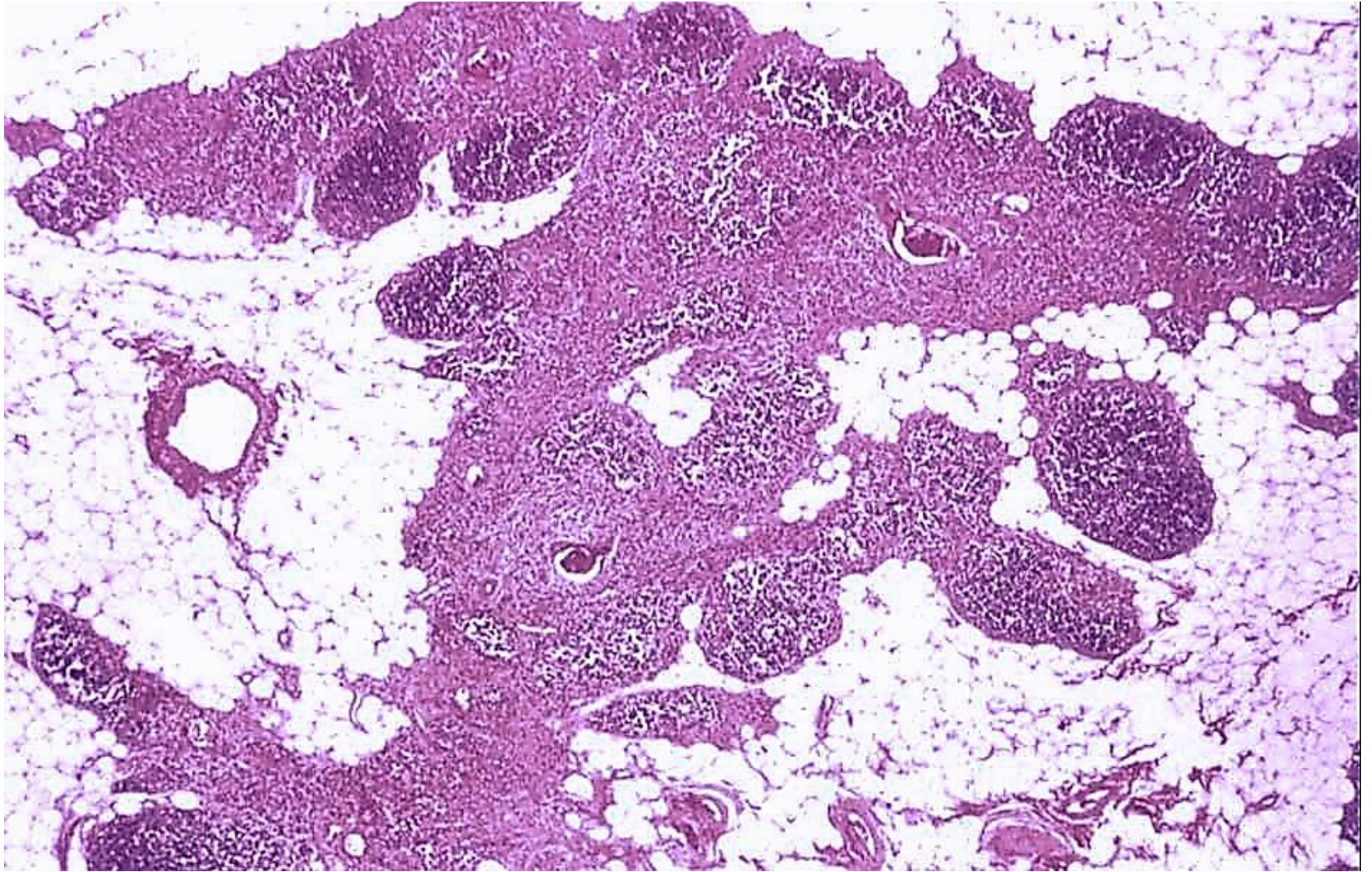
# T-CELL SELECTION

- positive: CD4+ CD8+
- tissue-restricted antigens (TRAs)





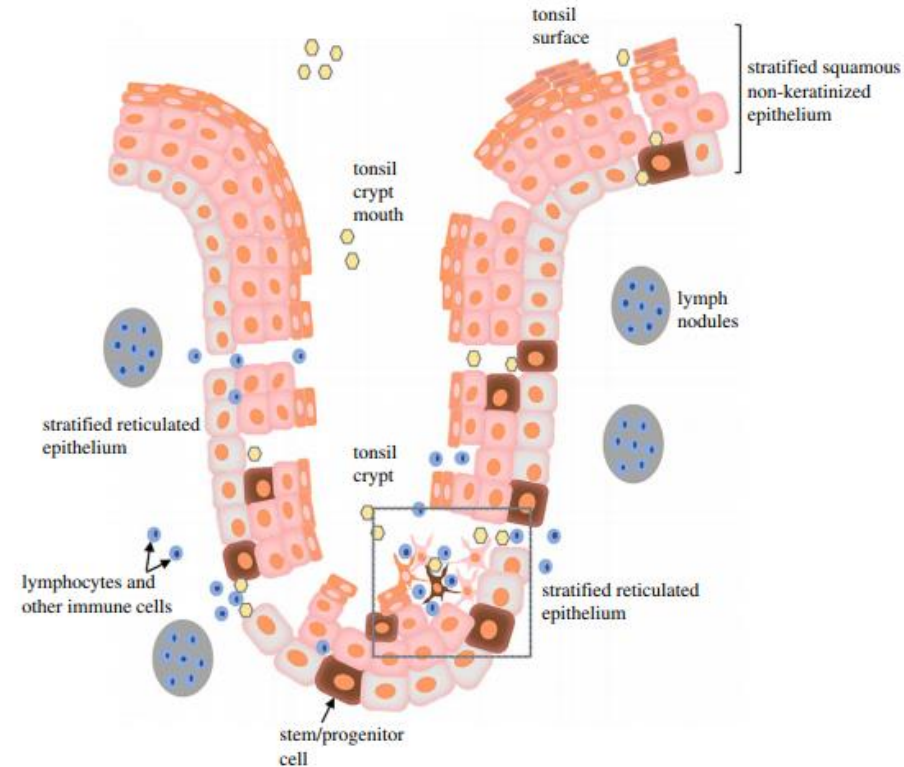
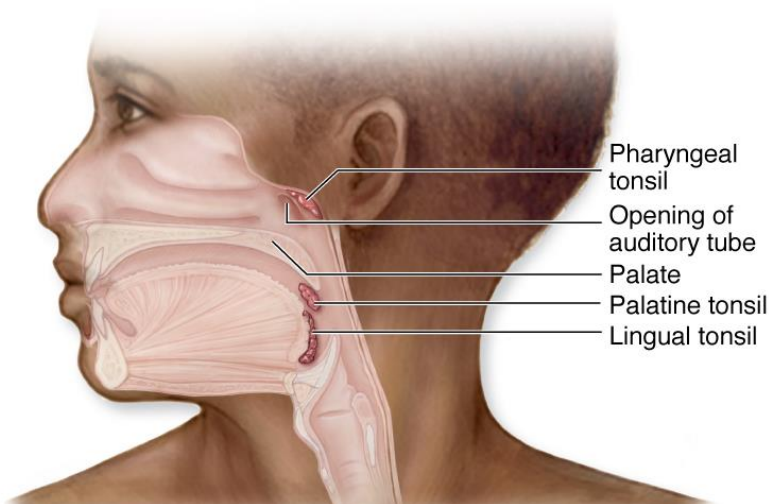
# THYMUS (INVOLUTION)



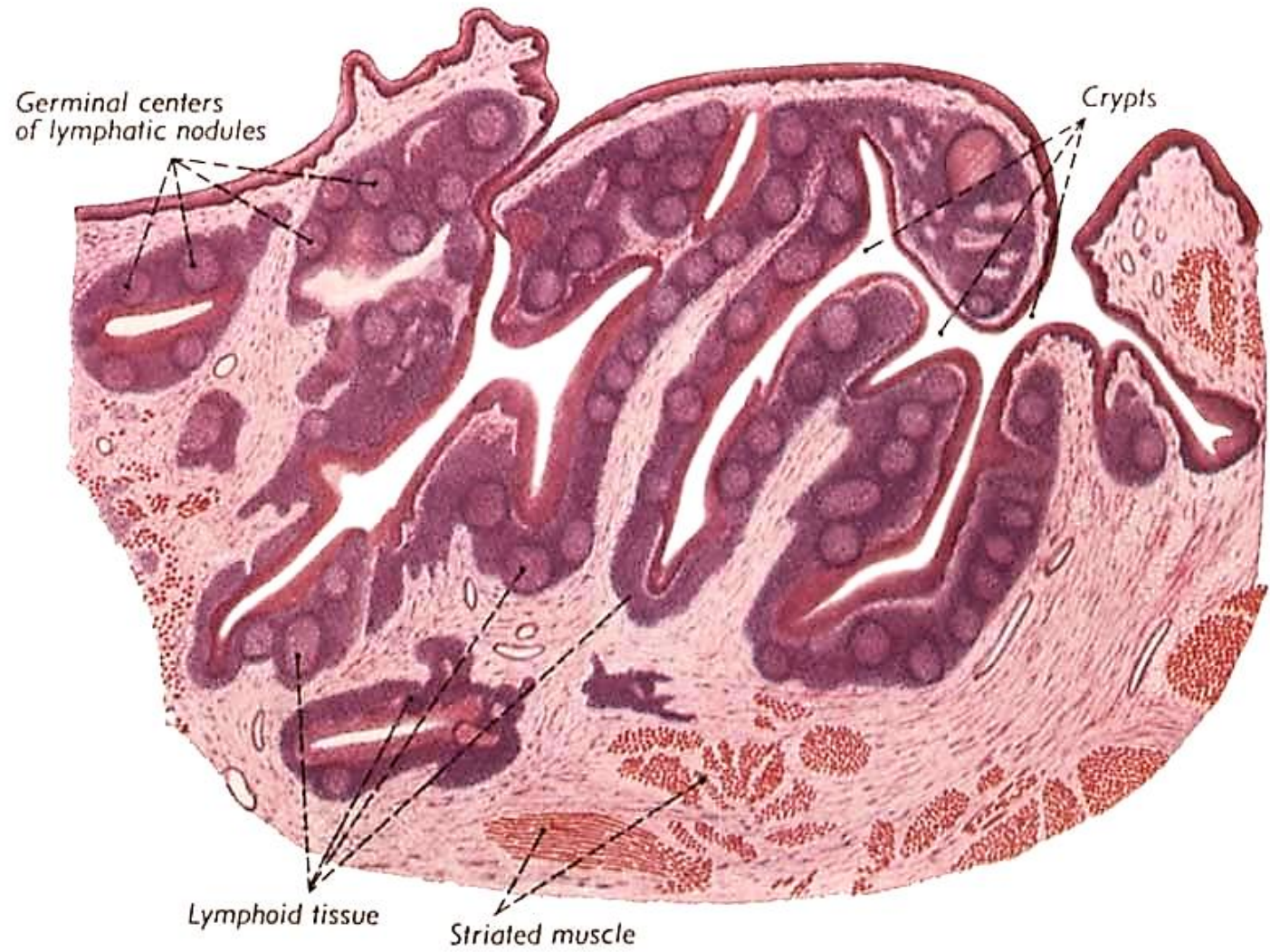
# TONSILS

- incomplete encapsulation by connective tissue
- aggregations of lymphatic tissue (follicles) covered by epithelium of crypt
- crypts – deep and branched invaginations lined by epithelium
- reticulated epithelium

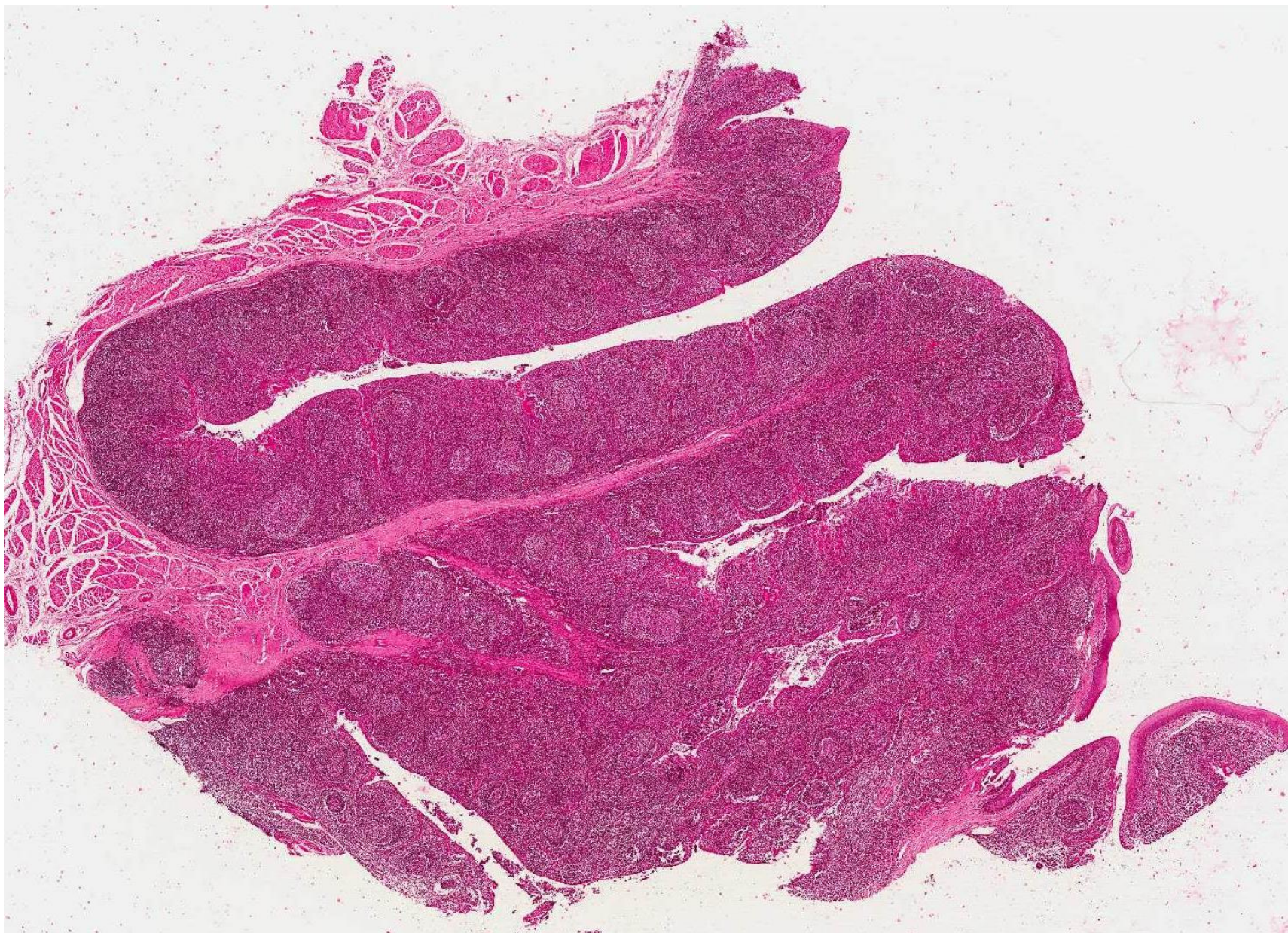
- **t. palatina** – stratified squamous e.
- **t. lingualis** – stratified squamous e.
- **t. pharyngea** – pseudostratified columnar e.
- **t. tubaria** – pseudostratified columnar e.



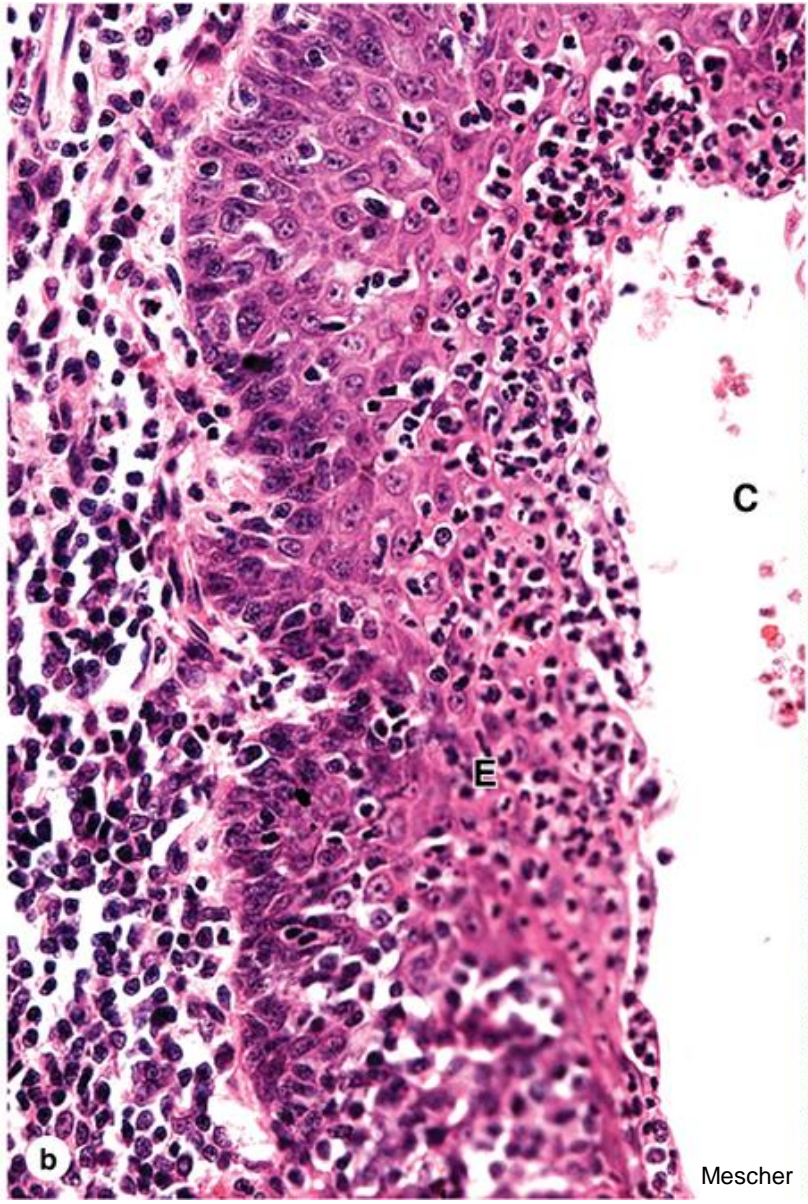
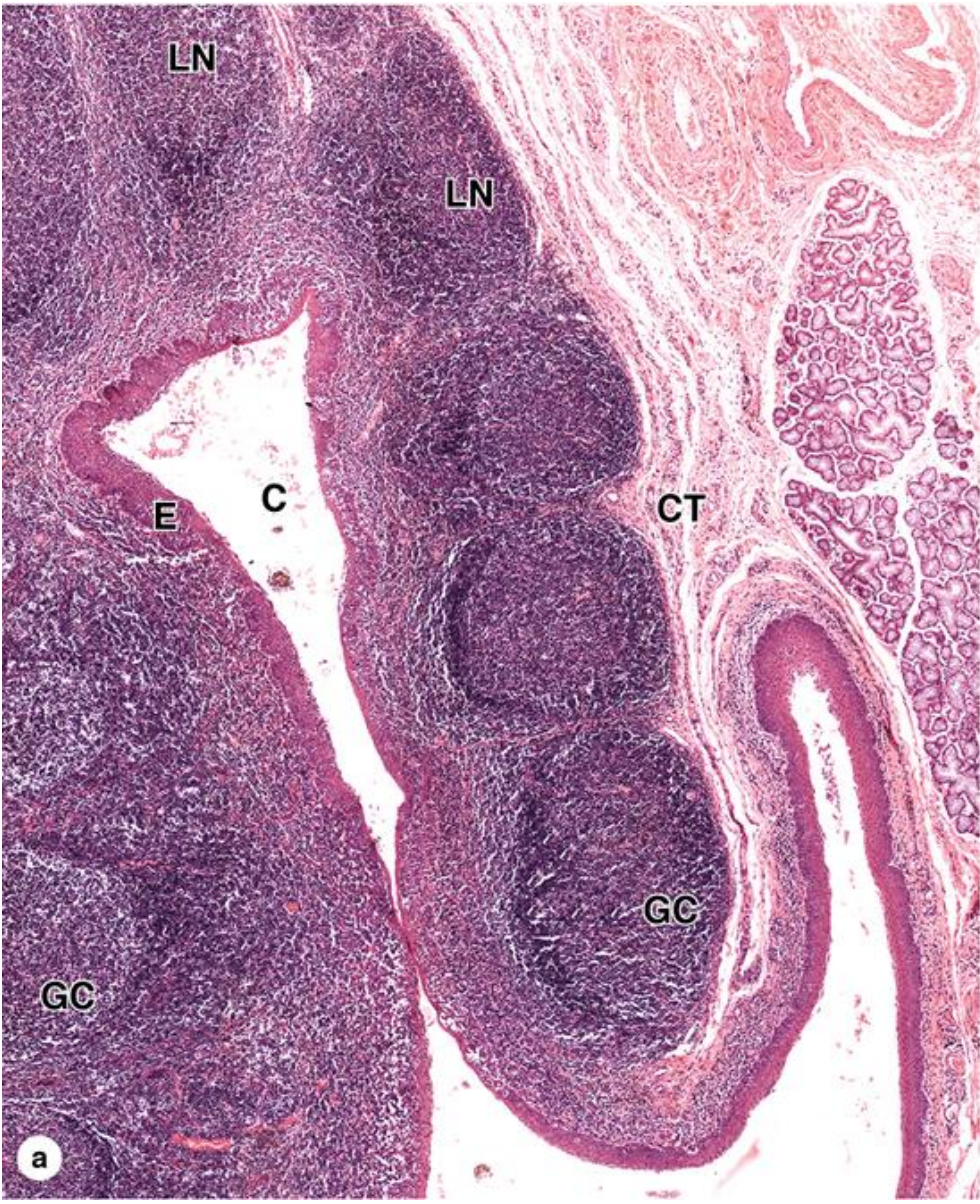
# TONSILLA PALATINA



# TONSILLA PALATINA



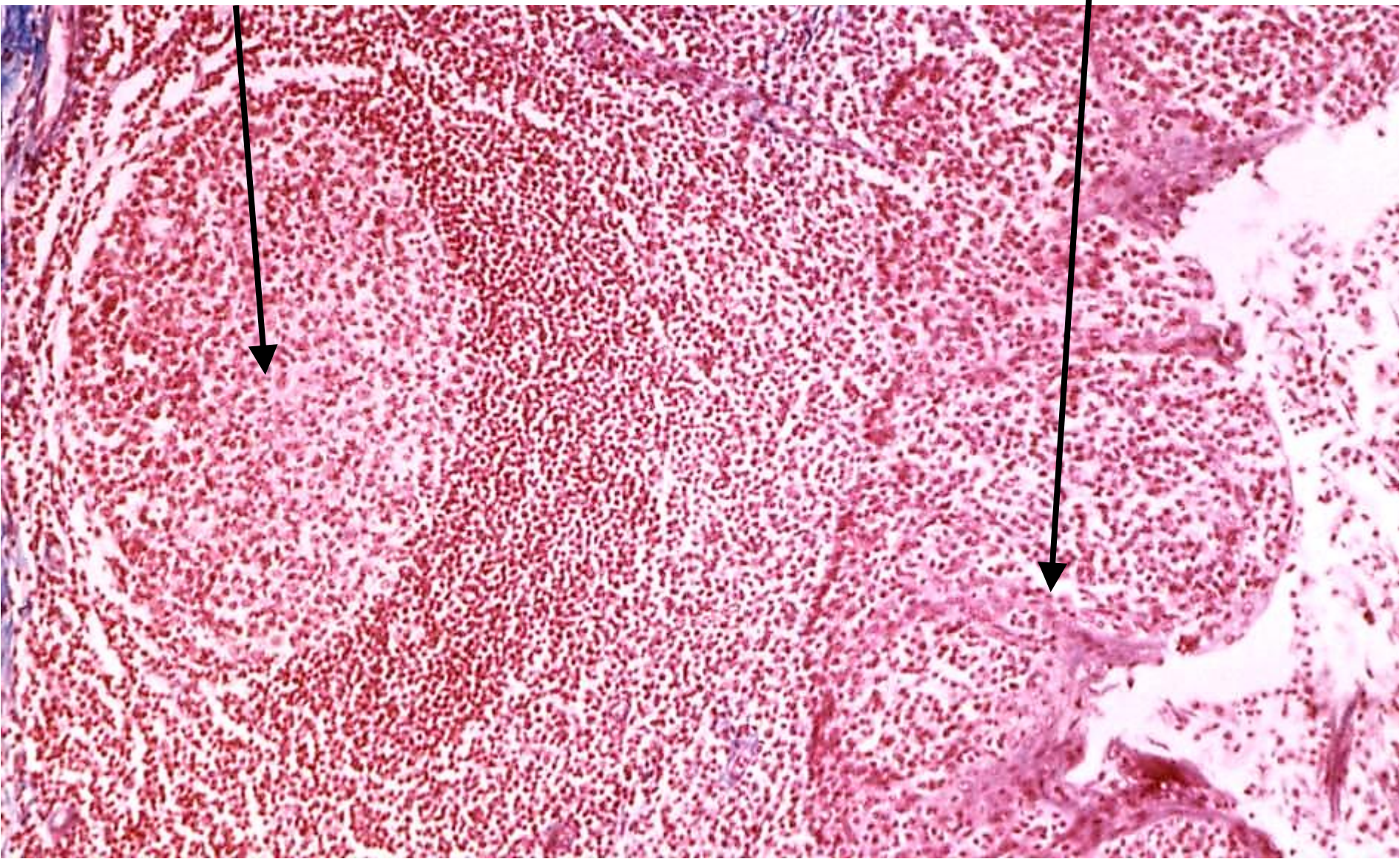
# TONSILLA PALATINA



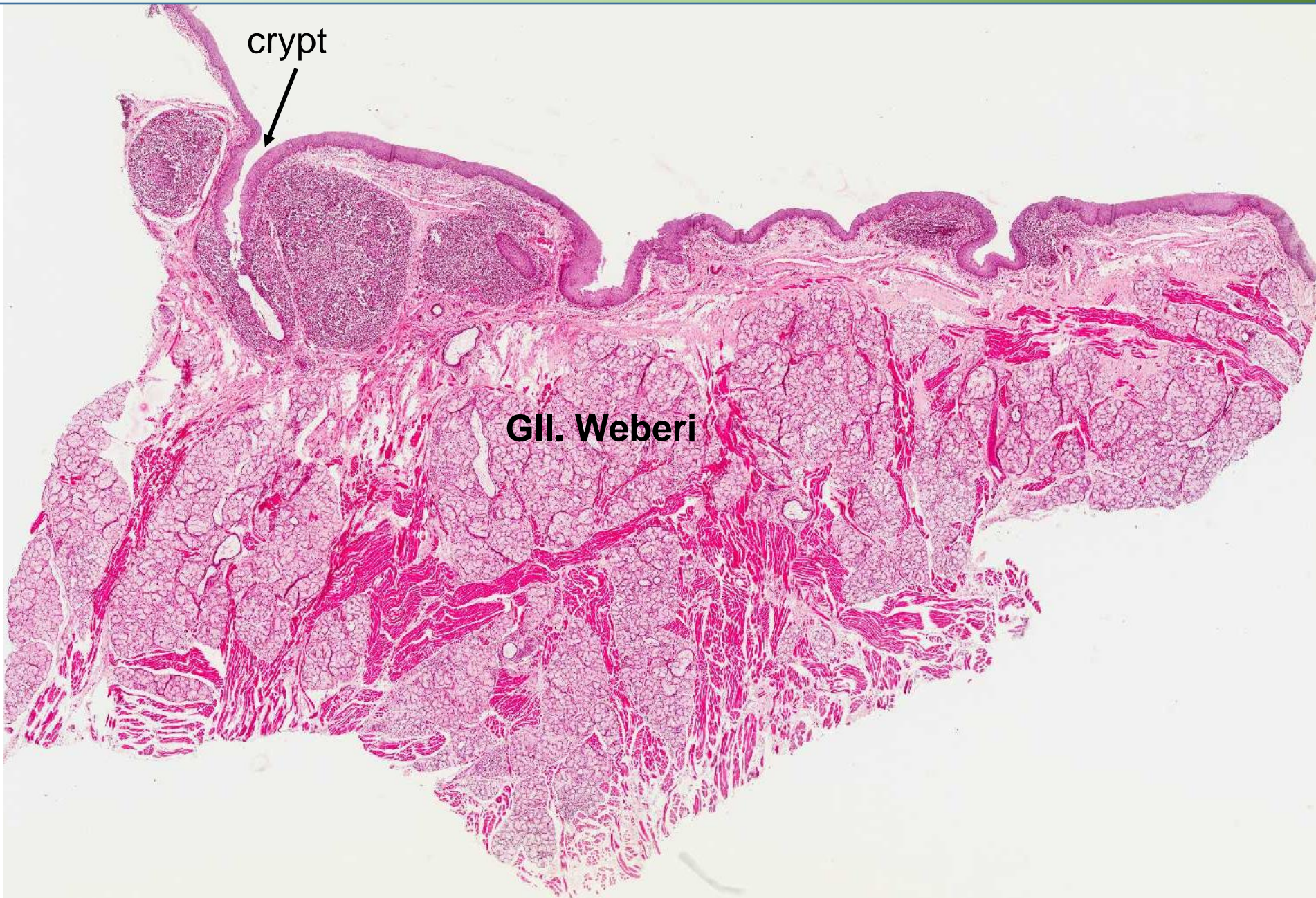
# TONSILLA PALATINA

lymphatic follicle

reticulated epithelium



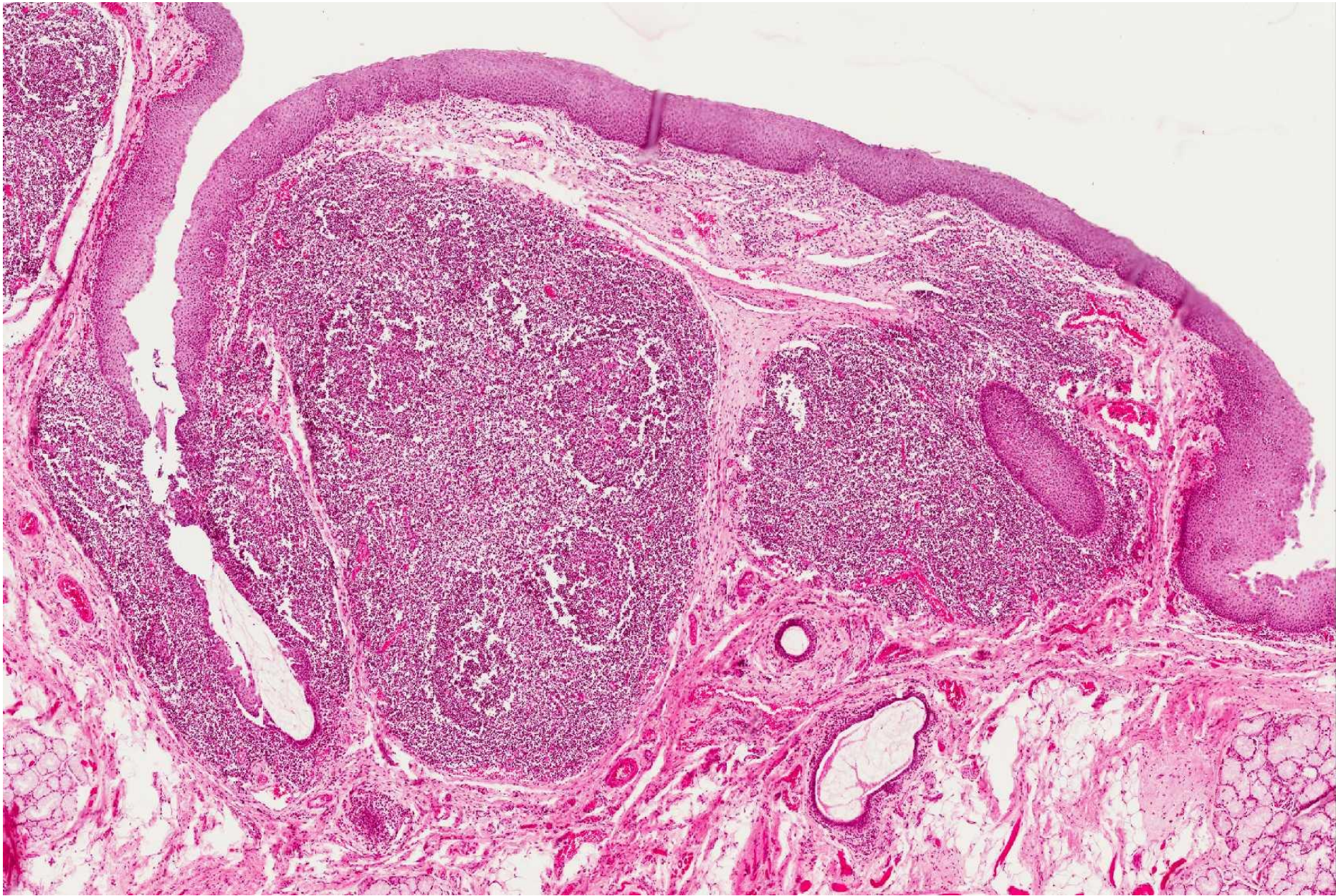
# TONSILLA LINGUALIS



crypt

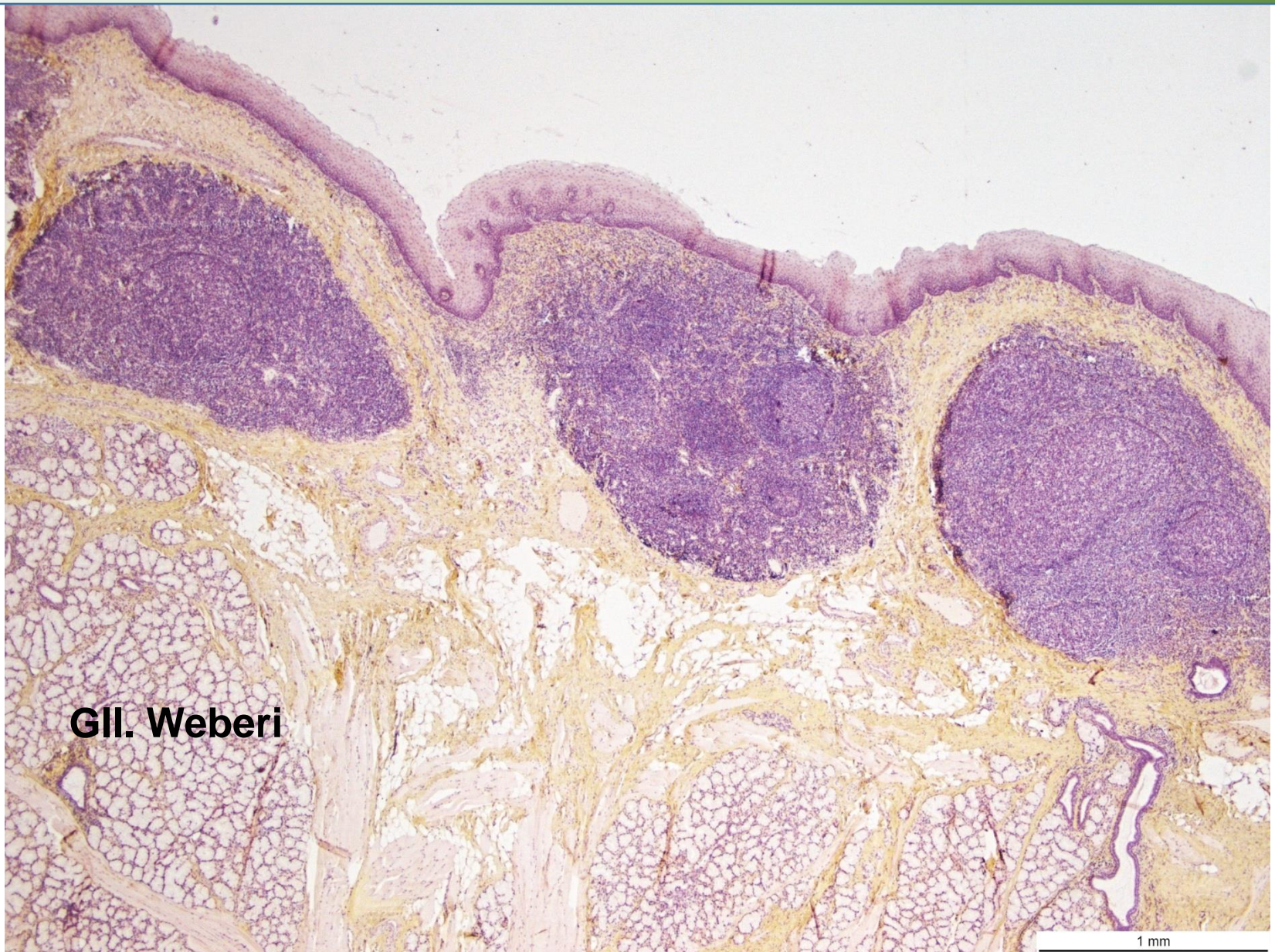
Gll. Weberi

# TONSILLA LINGUALIS



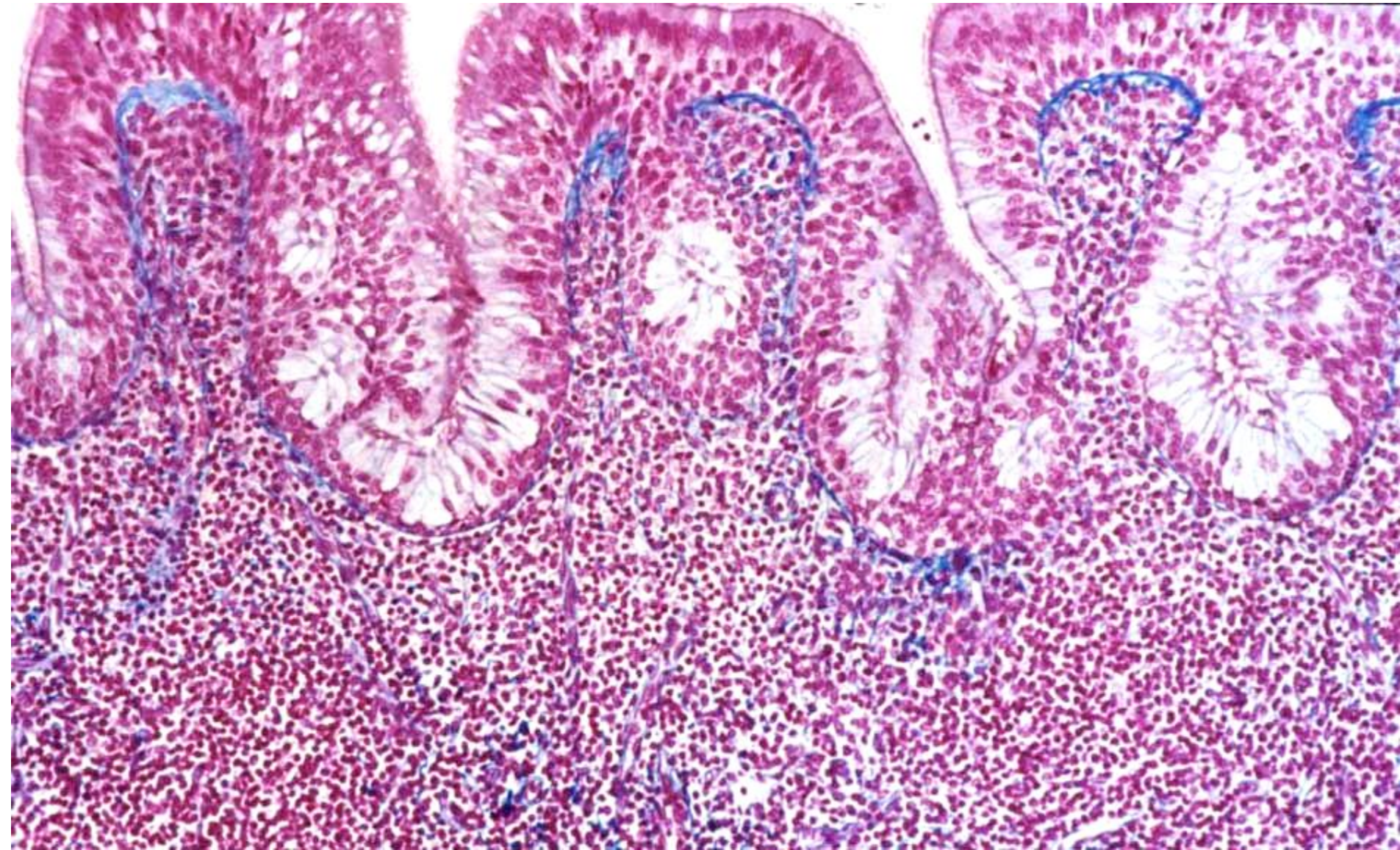


# TONSILLA LINGUALIS



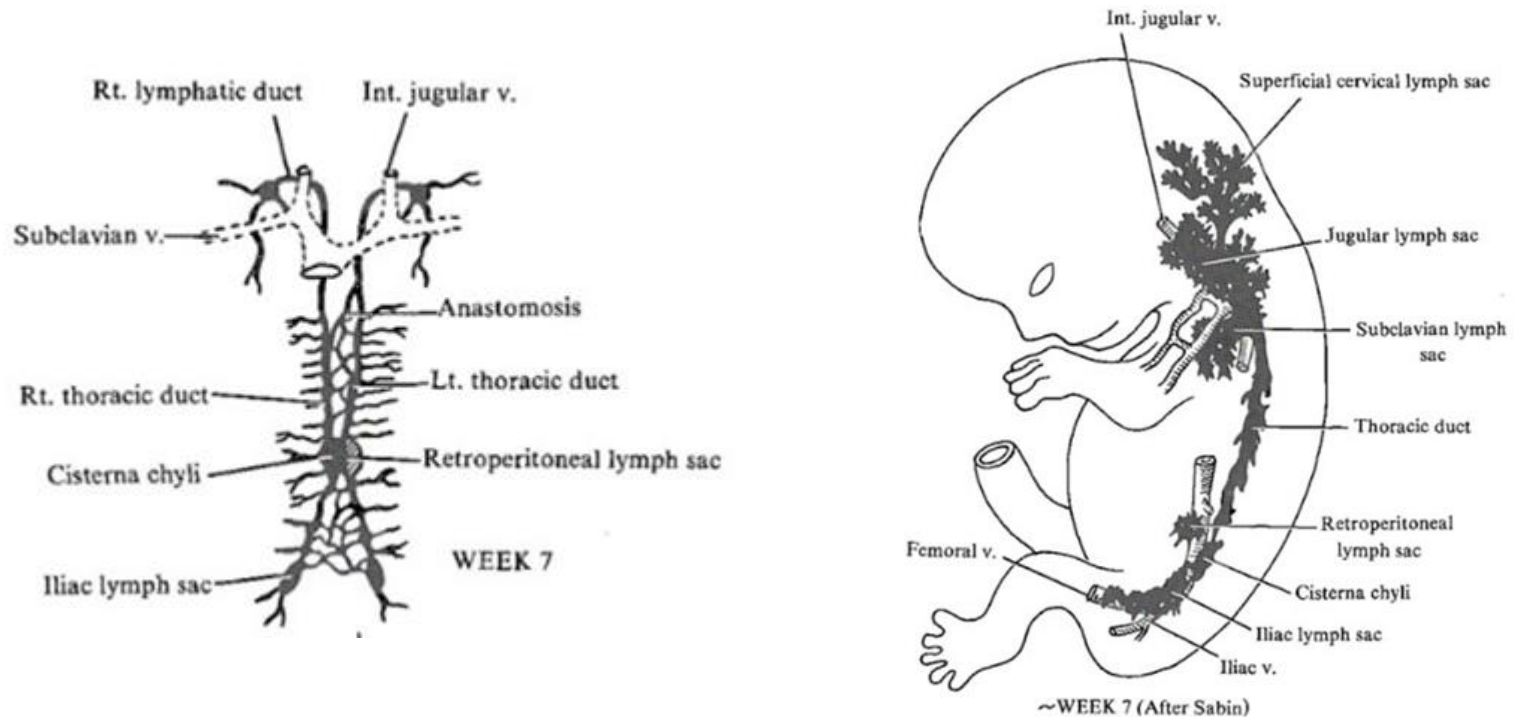
Gll. Weberi

# TONSILLA PHARYNGEA



# DEVELOPMENT OF LYMPHATIC SYSTEM

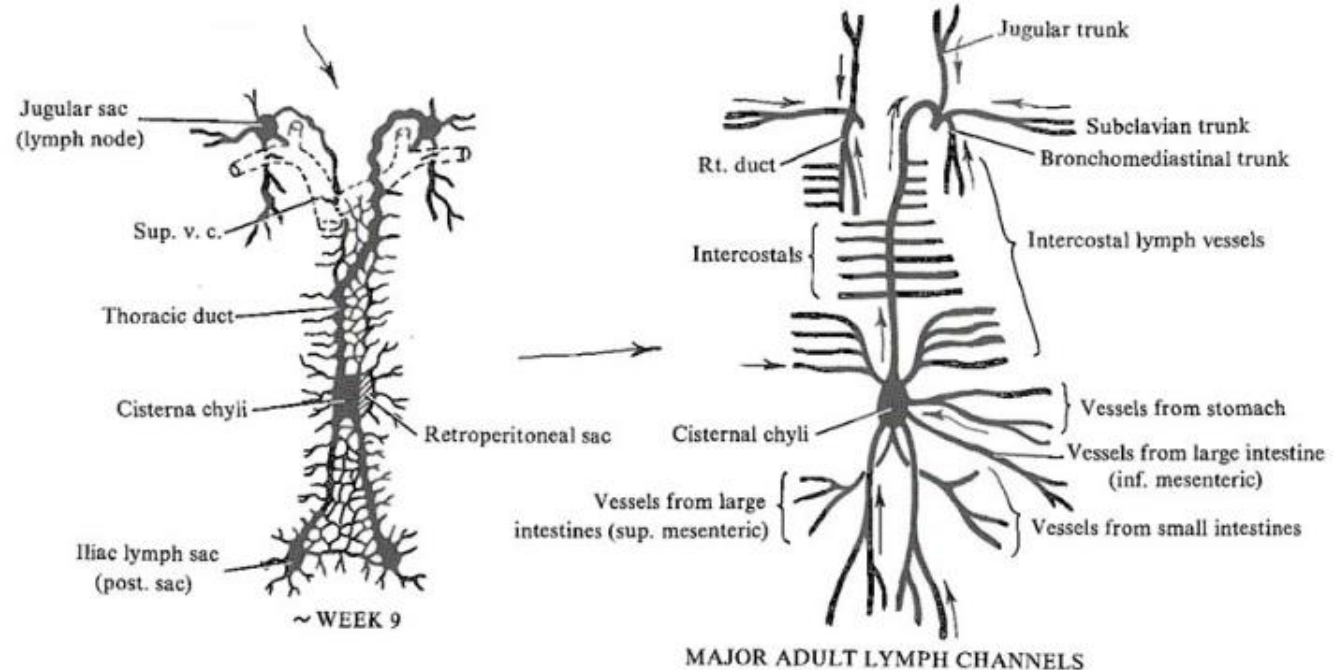
- development starts at week 5
- origin unclear, presumably from mesenchyme or as outgrowths of primitive endothelium



- **Week 6-9**, six primary lymph sacs from local dilatations
  1. **Two** jugular (junction of the subclavian veins with the v. precardinales (→ v. jugularis int.)
  2. **Two** iliac lymph sacs near the junction of the iliac veins with the v. postcardinales
  3. **Single** retroperitoneal lymph sac
  4. **Single** cisterna chyli dorsal to the retroperitoneal lymph sac

# DEVELOPMENT OF LYMPHATIC SYSTEM

- **Lymph vessels grow from lymph sacs**
  - jugular: head, neck, thorax, upper limbs
  - iliac: trunk, lower limbs from iliac
  - retroperitoneal and cisterna chyli: intestine
- **Development of lymphatic ducts**
  - left and right thoracic duct connecting c. chyli and jugular sacs
  - anastomoses
  - D. thoracicus: caudal part of right thoracic duct, cranial part of left thoracic duct
  - D. lymphaticus dx.: cranial part of right thoracic duct



# DEVELOPMENT OF LYMPHATIC SYSTEM

- **Development of lymph nodes**

- lymph sacs (except for c. chyli) are invaded by mesenchymal cells and constitute apparent clusters of lymph nodes
- B-cell compartments (follicles) develop around birth, lack germinalive centers (naive)
- lymph nodes develop along lymph vessels by similar mechanism

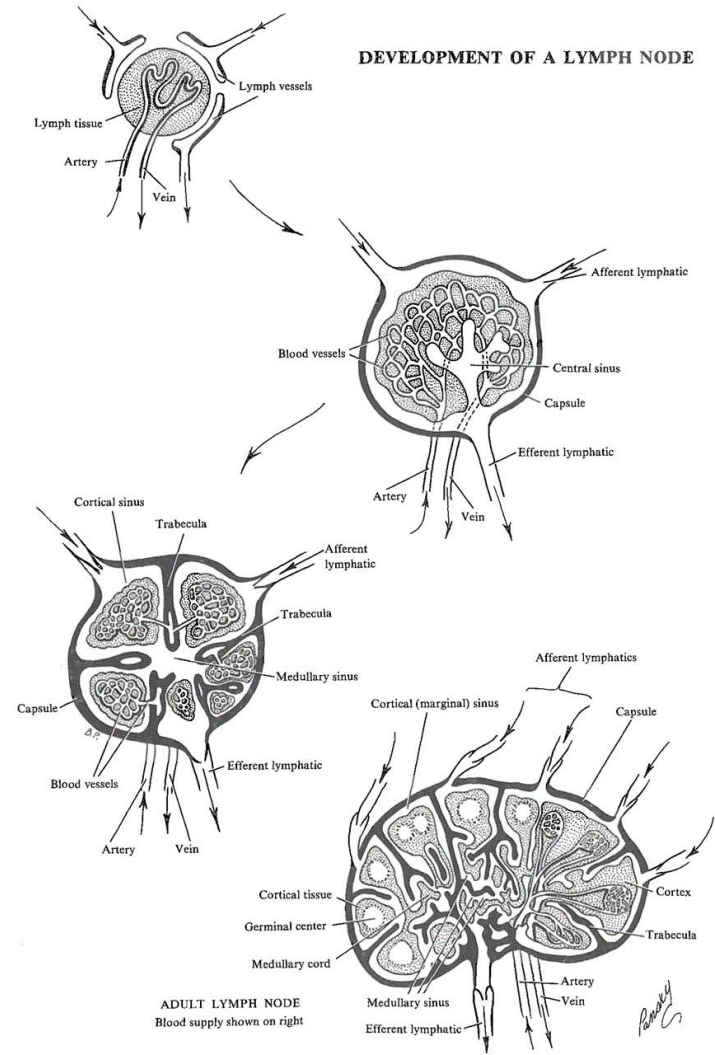
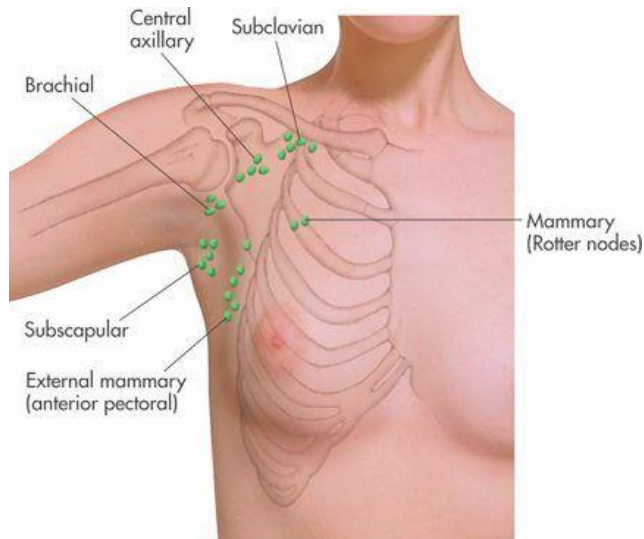
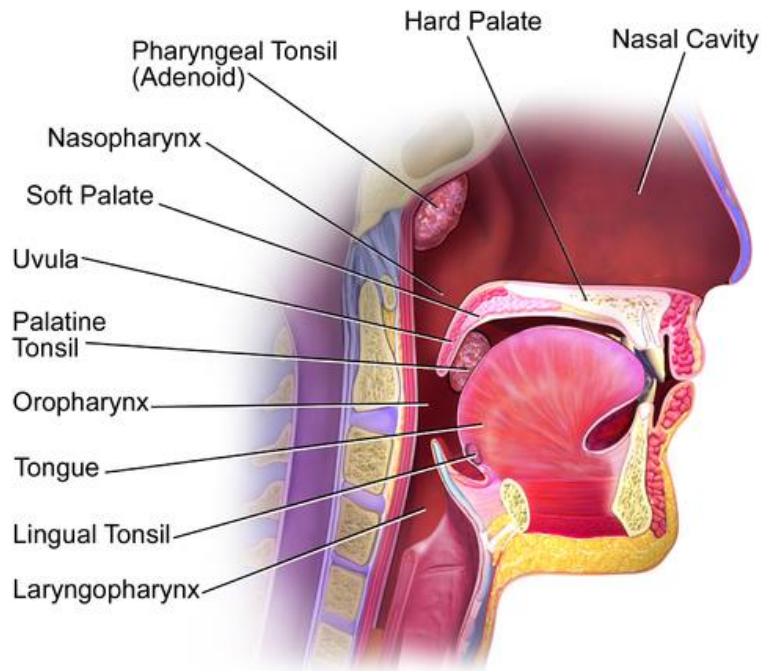


FIGURE 55. Development of a lymph node.

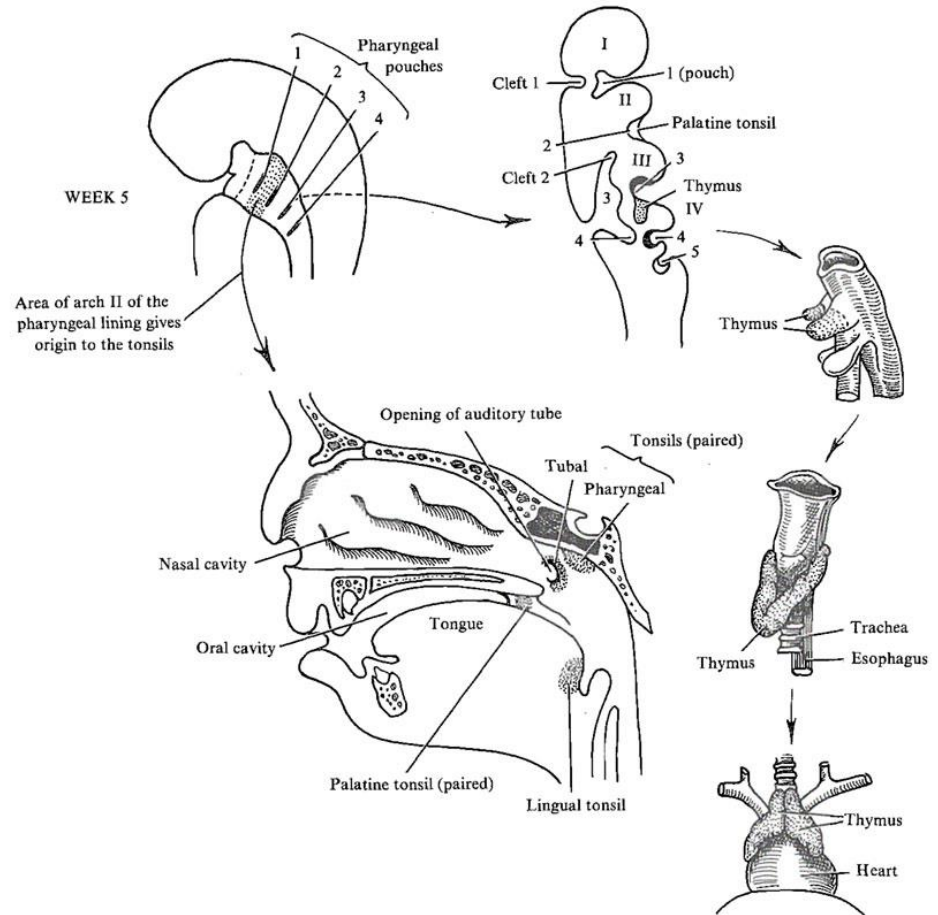
# DEVELOPMENT OF TONSILS AND THYMUS

- **Tonsilla palatina**
  - second pharyngeal pouch (fossa)
- **Tonsilla pharyngea, tubaria and lingualis**
  - aggregation of lymph nodules in the nasopharynx, by opening of tuba auditiva or lingual root
- **Thymus**
  - third pharyngeal pouch



Tonsils and Throat

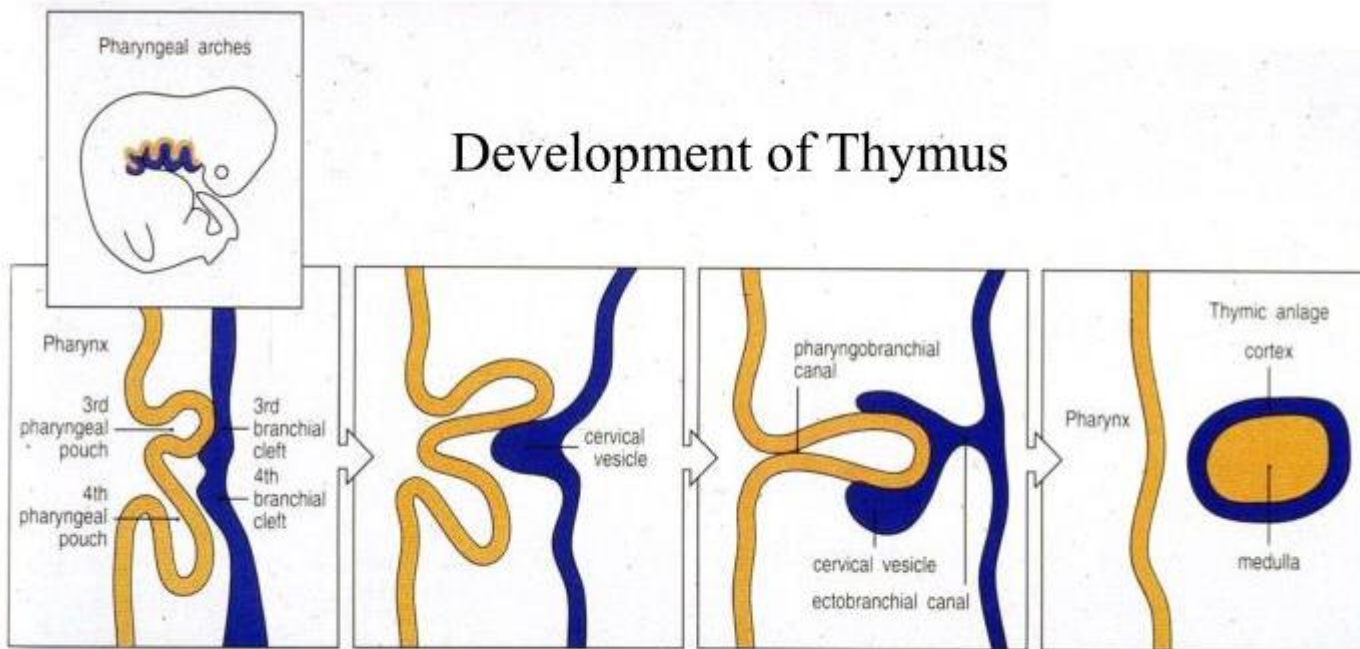
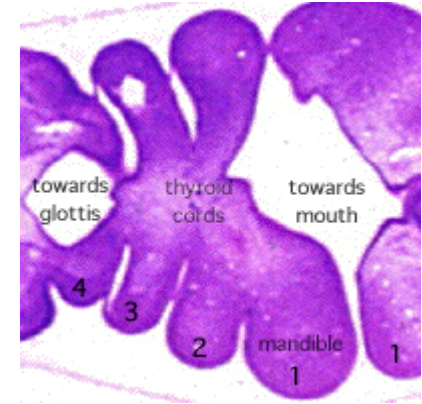
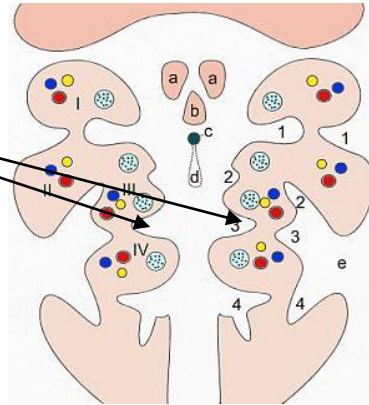
## DEVELOPING TONSILS AND THYMUS GLAND



# DEVELOPMENT OF THYMUS

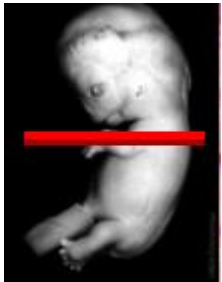
- **Thymus**

- third pharyngeal pouch



Bone marrow cells colonize thymic anlage in fetus

# DEVELOPMENT OF THYMUS



Week 8

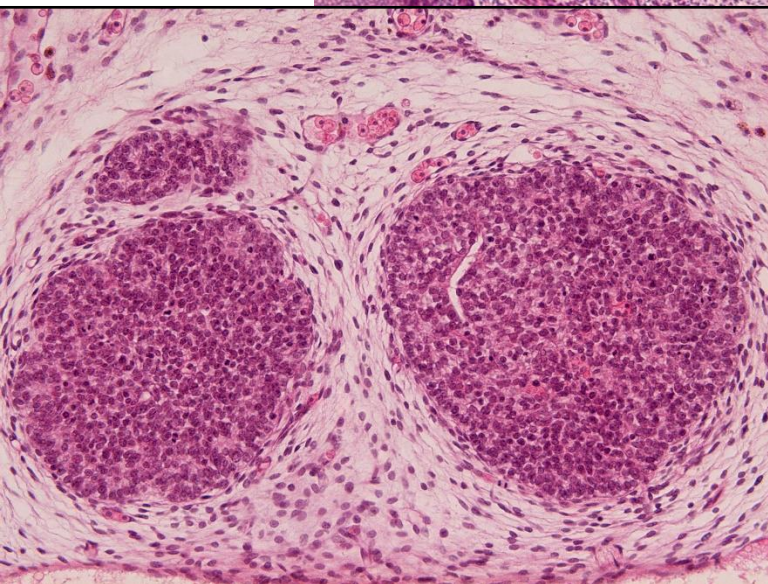
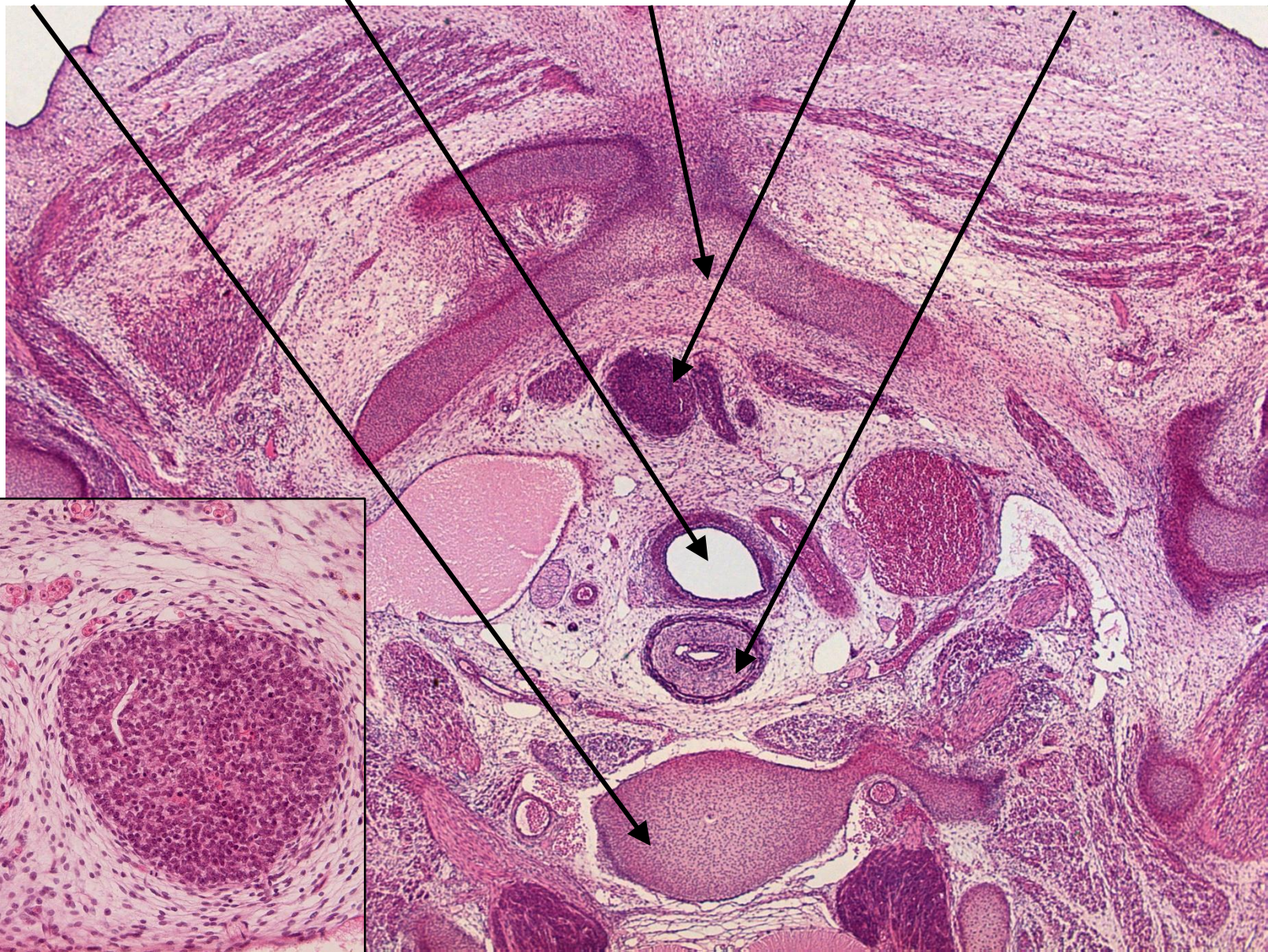
Vertebral cartilage

trachea

sternum and ribs

thymus

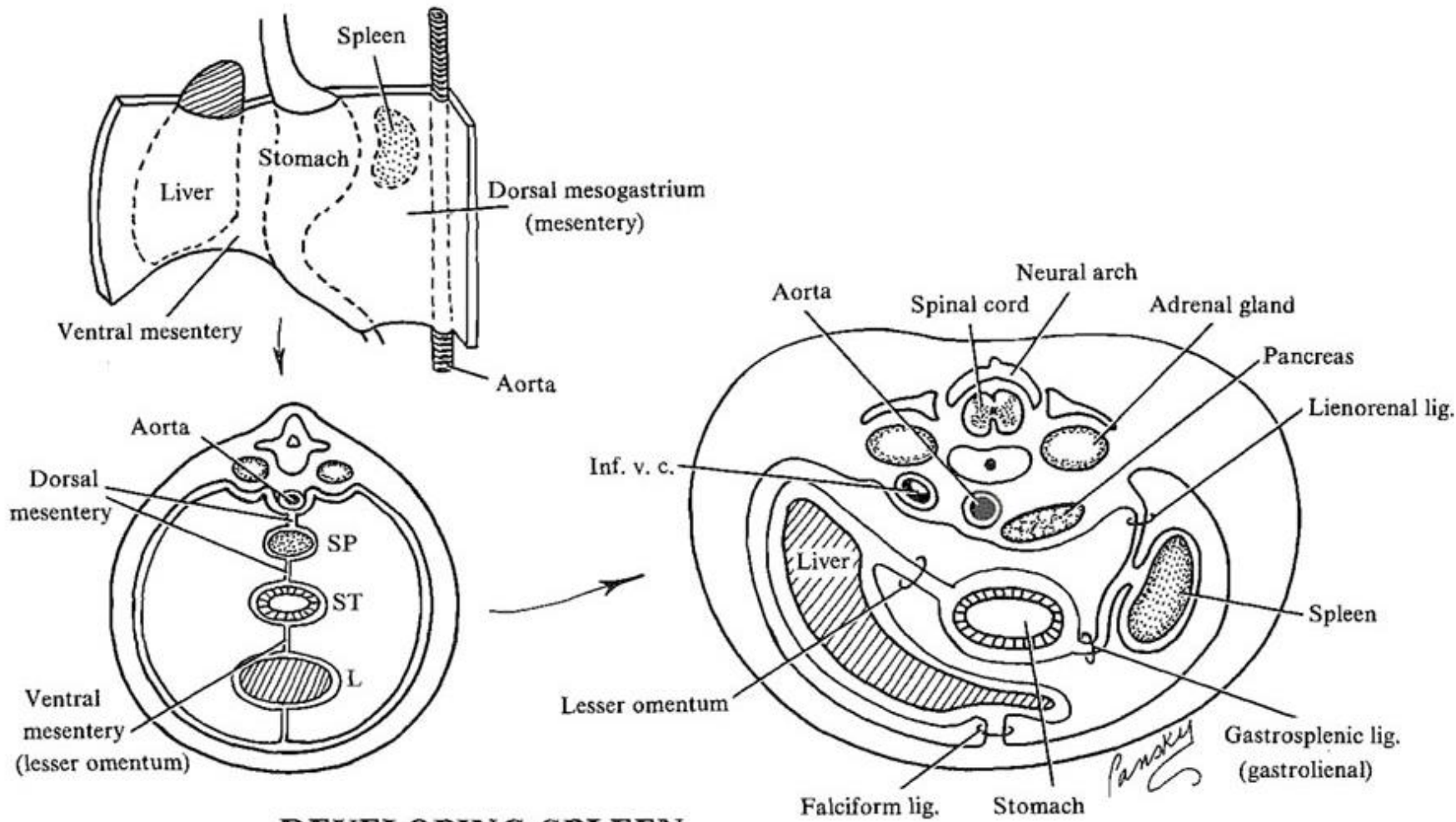
esophagus





# DEVELOPMENT OF SPLEEN

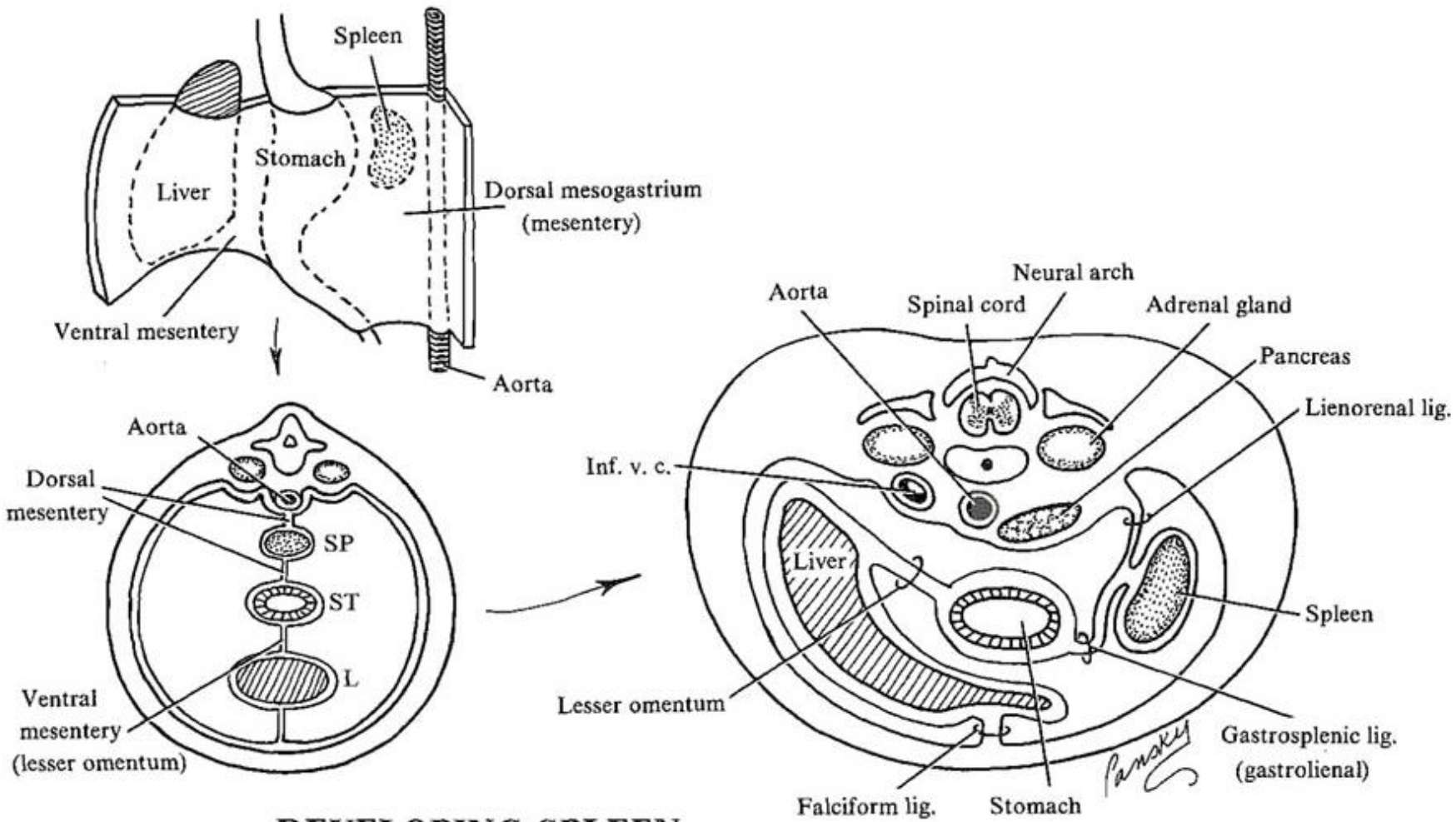
- Dorsal mesentery of stomach
- Mesenchymal origin



**DEVELOPING SPLEEN**

# DEVELOPMENT OF SPLEEN

- Dorsal mesentery of stomach
- Mesenchymal origin



**DEVELOPING SPLEEN**

# DEVELOPMENT OF SPLEEN

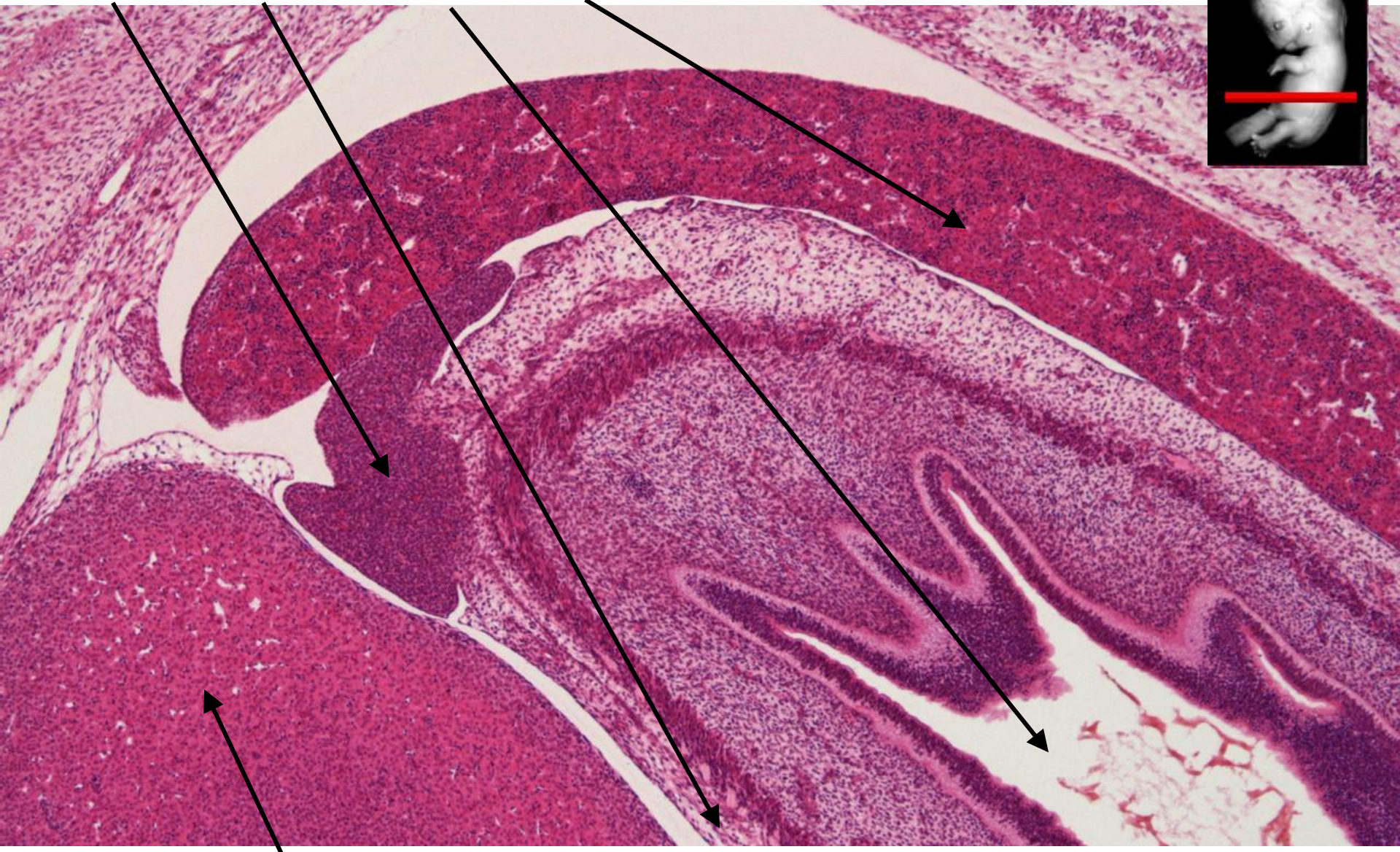
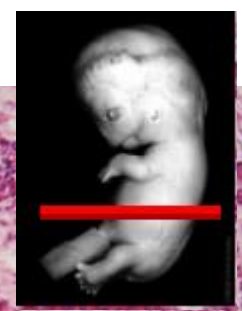Spleen

Pancreas

Stomach

Liver

Week 8



Gl. suprarenalis sin.

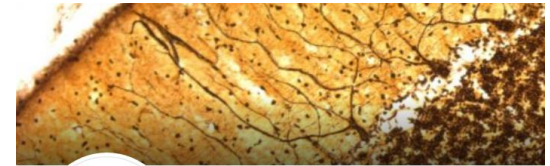
# Thank you for attention

## Questions? Comments?

pvanhara@med.muni.cz

MUNI  
MED

Department  
of Histology  
and Embryology



Departme  
Histology a  
Embryol

**HistoKlub MED MUNI**

@HistoKlubMEDMUNI - Vzdělávací web

Dendritic Cell



CD4 T Cell



Macrophage



B Cell



Cell  
Cartoons

CellCartoons.net

Special thanks to CellCartoons.net