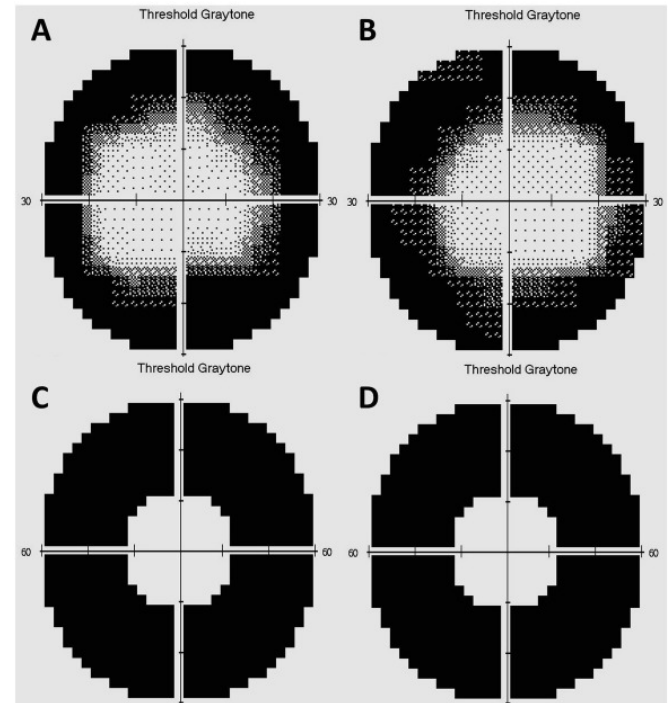
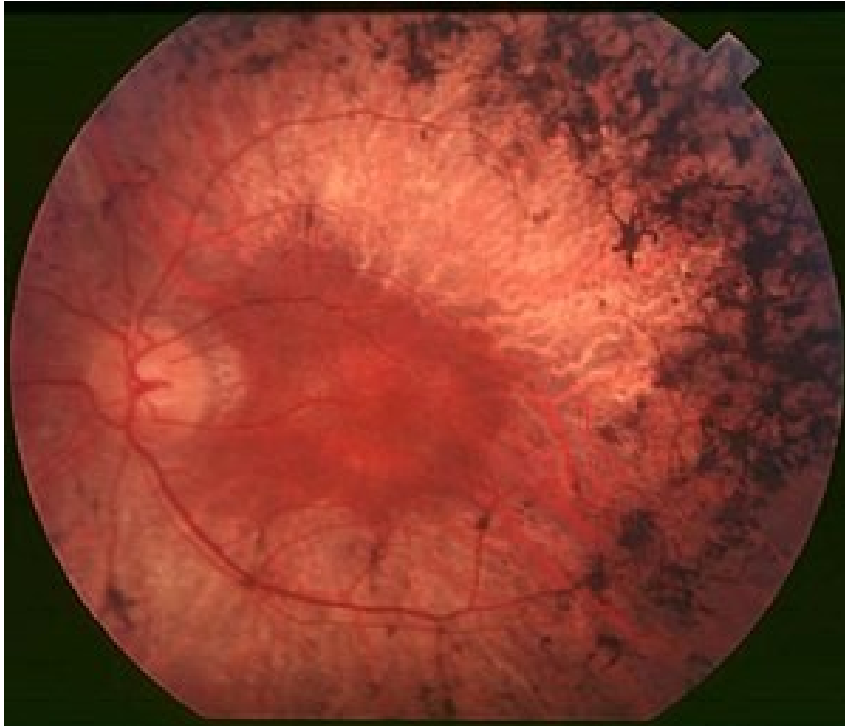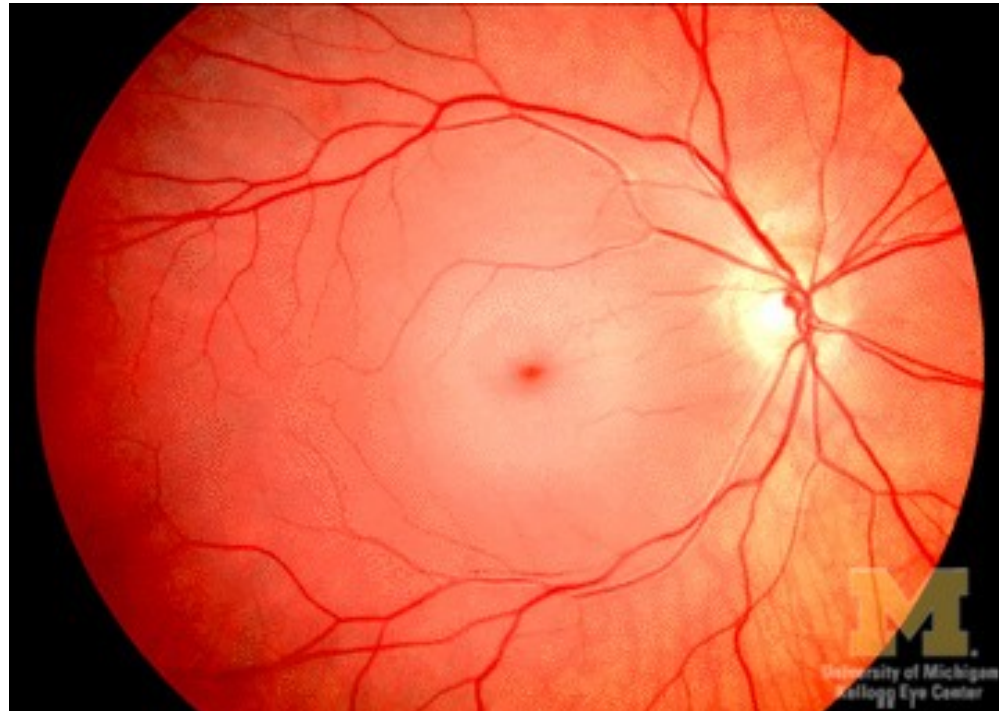


Retina – the rest

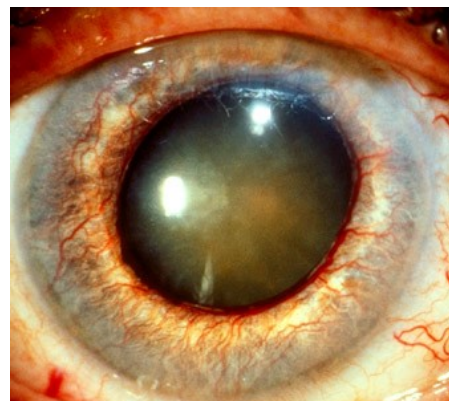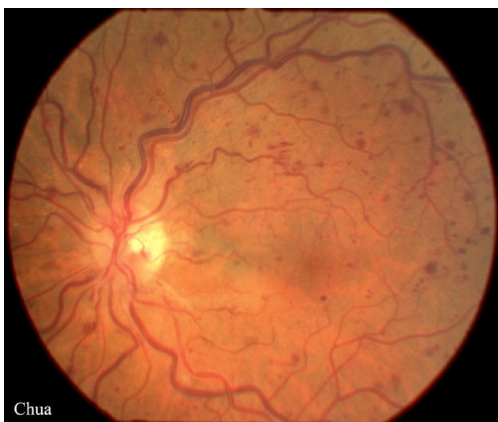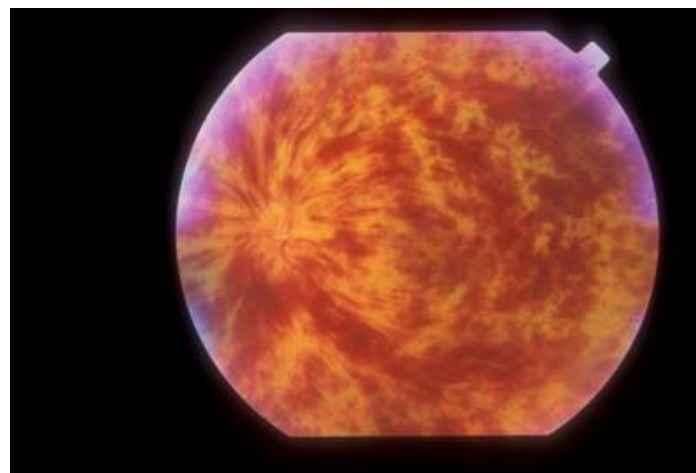
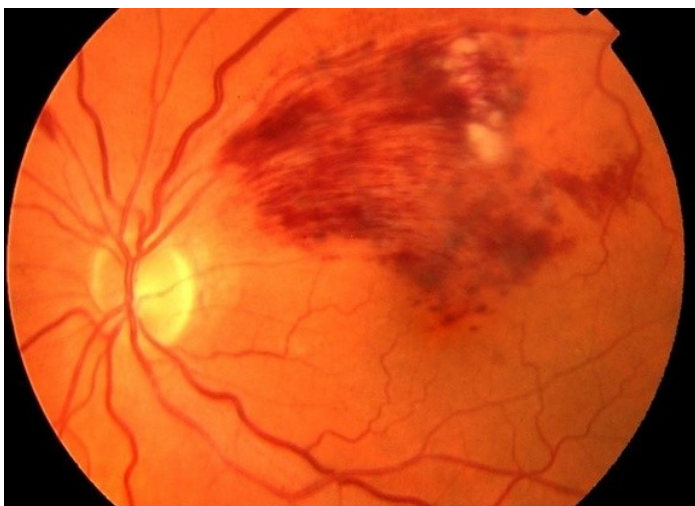
Retinitis pigmentosa



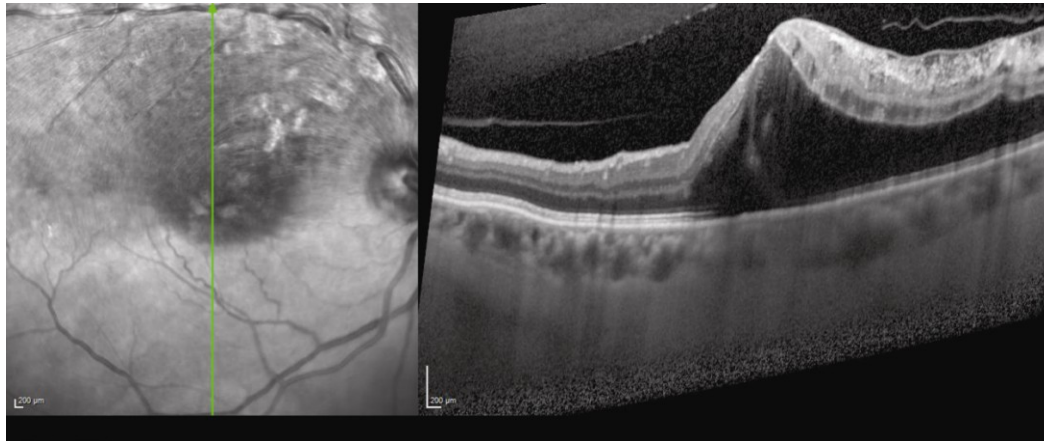
Occlusion of central retinal artery



Retinal vein occlusion



Macular oedema - RVO



- Laser photocoagulation
- Anti VEGF