

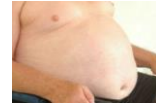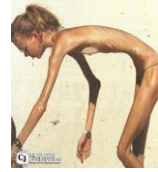Digestive system – Part I

MUDr. Marek Joukal, Ph.D.

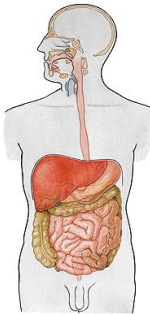
Department of Anatomy

Digestive system functions:

- food intake
- mechanical and chemical processes
- absorption of substances
- excretion of the wasting products and useless remains



Digestive system structure:



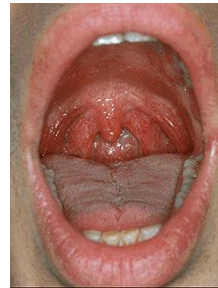Digestive tube:

- oral cavity
- pharynx
- oesophagus
- stomach
- small intestine
- large intestine

Glands:

- liver
- pancreas

Oral cavity – cavitas oris



Borders:

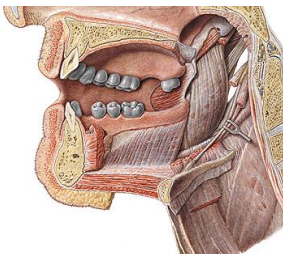
- Rima oris
- Isthmus faucium
- Lips, buccae
- Palatum
- Diaphragma oris

Content:

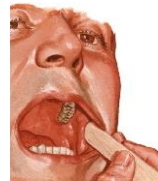- Tongue
- Teeth

CAVITAS ORIS

vestibulum oris cavum oris proprium



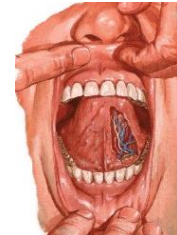
Vestibulum oris



Tremata

Trigonum retromolare

Papilla parotidea



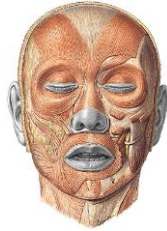Fornix vestibuli sup. (frenulum labii sup.)

Fornix vestibuli inf. (frenulum labii inf.)

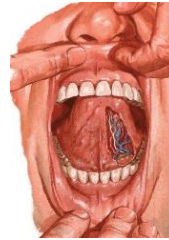
Lips (labia oris) and cheek (bucca, mala)



Sulcus nasolabialis et mentolabialis
Philtrum, tuberculum labii sup.

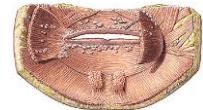

Corpus adiposum buccae

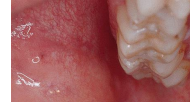

Frenulum labii superioris

Frenulum labii inferioris

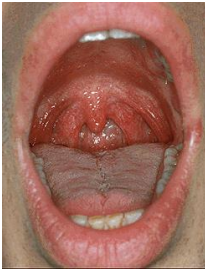

Glandulae labiales at buccales



Papilla parotidea

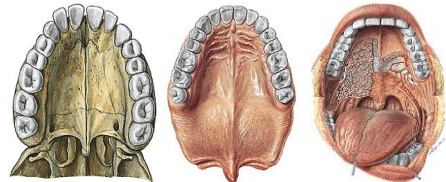
Proper oral cavity



Borders:

- Teeth
- Isthmus faucium
- Palatum
- Diaphragma oris

Palatum durum

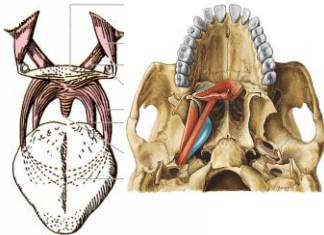


Papilla incisiva (dustus incisivi, nervus nasopalatinus)

Plicae palatinae transversae

Glandulae palatinae

Soft palate



- Uvula palatina
- Aponeurosis palatina
- Muscles of the soft palate

Muscles of the soft palate

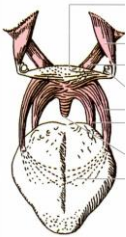Musculus tensor veli palatini

- O: scaphoid fossa, lateral plate of the auditory tube cartilage, spina ossis sphenoidalis
- I: palatine aponeurosis
- F: elevation and tension of the soft palate
- In: Nervus mandibularis (CN V3)

Musculus levator veli palatini

- O: inferior surface of the pars petrosa
- I: Palatine aponeurosis
- F: Elevation of the soft palate
- In: Pharyngeal plexus

Muscles of the soft palate



Musculus palatoglossus

O: palatine aponeurosis
I: lateral margin of the tongue
F: elevation of the root of the tongue
In: plexus pharyngeus

Musculus uvulae

O: palatine aponeurosis
I: mucosa of the uvula
F: elevation and retraction of the uvula
In: plexus pharyngeus

Musculus palatopharyngeus

O: palatine aponeurosis
I: lateral wall of the pharynx
F: Elevation of the pharynx
In: plexus pharyngeus

Diaphragma oris

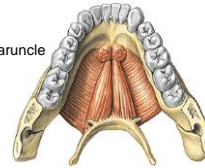
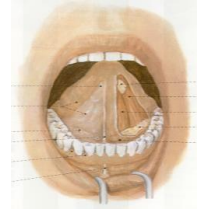
Musculus geniohyoideus

Musculus mylohyoideus

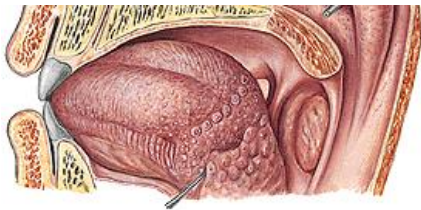
Sublingual gland

Tongue

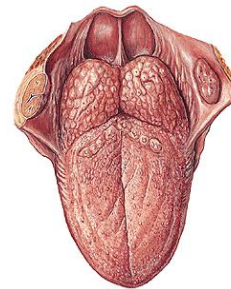
Sublingual fold and caruncle



Tongue (lingua, glossa)

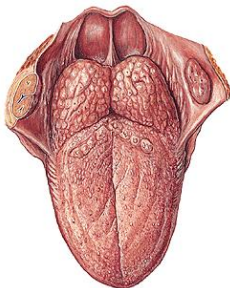


1. Pars oralis (corpus, apex)
2. Pars pharyngea (radix)

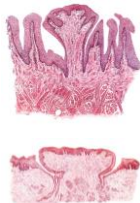

- Radix linguae
- Corpus linguae
- Apex linguae
- Sulcus terminalis
- Sulcus medianus
- Foramen caecum
- Margines linguae

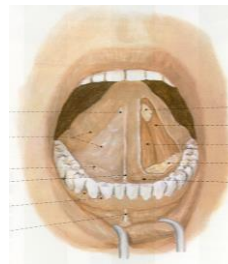
Dorsum linguae



- Papillae filiformes
- Papillae fungiformes
- Papillae foliatae
- Papillae vallatae

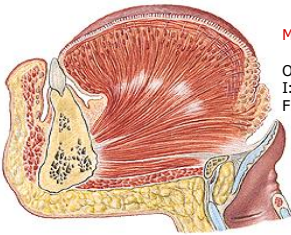


Inferior surface of the tongue

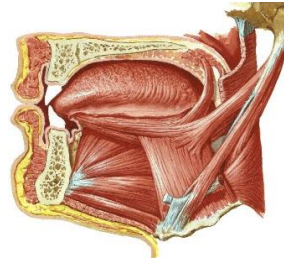


- Plica fimbriata
- Plica sublingualis
- Frenulum linguae

Extraglossal muscles



Musculus genioglossus
 O: spina mentalis
 I: aponeurosis linguae
 F: pulls the tongue anteriorly



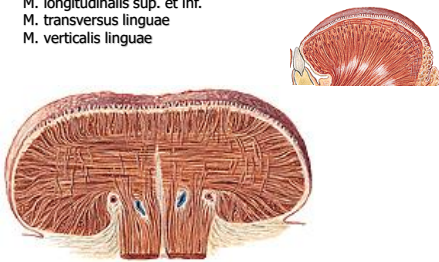
Musculus hyoglossus
 O: greater horn of the hyoid bone
 I: lateral margin of the tongue
 F: pulls the tongue downwards and backwards

Musculus styloglossus
 O: styloid process
 I: lateral margin of the tongue
 F: pulls the tongue backwards and upwards

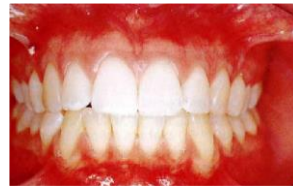Musculus palatoglossus

Intraglossal muscles

M. longitudinalis sup. et inf.
 M. transversus linguae
 M. verticalis linguae

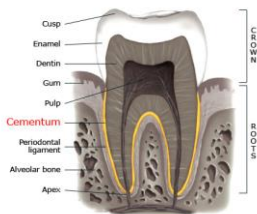


Gingiva



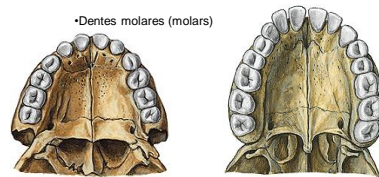
Alveolar mucous membrane
 Gingiva marginalis et alveolaris (paramarginal line)
 Papillae gingivales, gingivodental closure, sulcus gingivalis

Teeth (dentes)



Heterodont teeth:

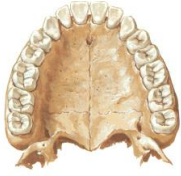- Dentes incisivi (incisors)
- Dentes canini (canines)
- Dentes praemolares (premolars)
- Dentes molares (molars)



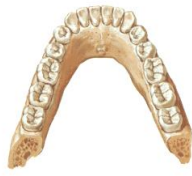Deciduous teeth

Adult (permanent) teeth

Arcus dentalis superior
(half of ellipse)



Arcus dentalis inferior
(parabola)

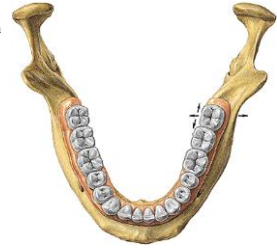


Facies oclusalis
- tubercula dentalia
- margo incisalis

Facies approximates
- f. mesialis (prox.)
- f. distalis

Facies vestibularis
- f. labialis
- f. buccalis

Facies oralis
- f. palatina
- f. lingualis

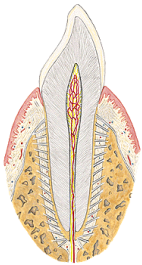


Fixation of the teeth:

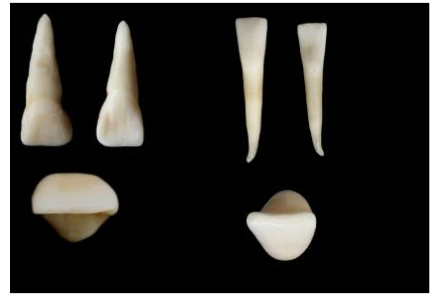Type: Comphosis

Periodontium (fixative ligaments):
(apical, alveolar, transseptal, gingival)

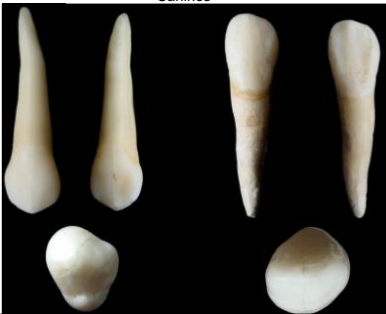Parodontium:
all of the fixative structures of the tooth
(periost, periodontium, cementum, gingiva)



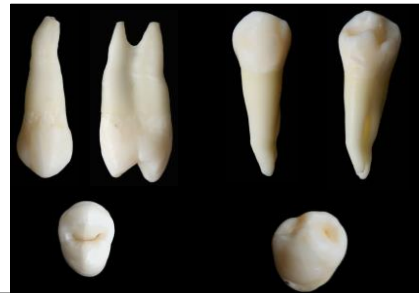Incisors



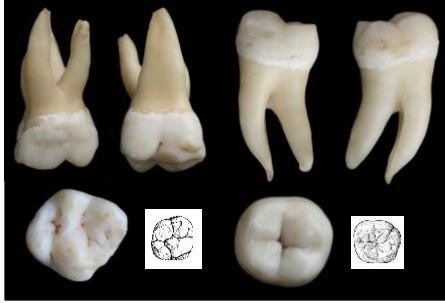
Canines



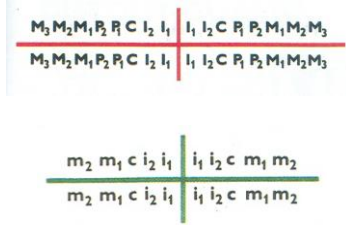Premolars



Molars



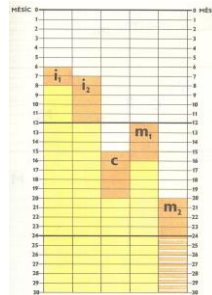
Dental formula



18 17 16 15 14 13 12 11 | 21 22 23 24 25 26 27 28
48 47 46 45 44 43 42 41 | 31 32 33 34 35 36 37 38


55 54 53 52 51 | 61 62 63 64 65
85 84 83 82 81 | 71 72 73 74 75

Tooth eruption - primary teeth



- Sequence:
 First incisor (6 months)
 Second incisor
 First molar
 Canine
 Second molar (2-2,5 yrs)

Eruption - adult teeth



- Sequence:
 First incisor, first molar
 Second incisor
 First premolar
 Canine
 Second molar
 Second premolar
 Third molar

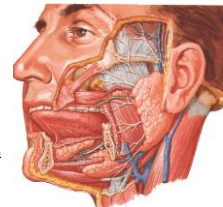
Salivary glands

GLANDULAE SALIVARIAE MINORES

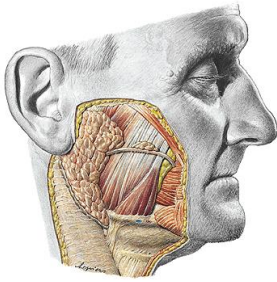
- glandulae labiales
- glandulae buccales
- glandulae palatinae
- glandulae linguales

GLANDULAE SALIVARIAE MAJORES

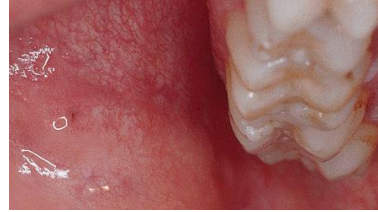- glandula parotidea
- glandula submandibularis
- glandula sublingualis



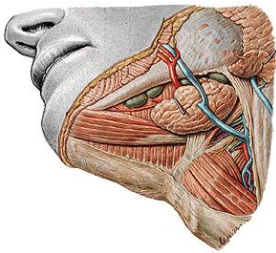
GLANDULA PAROTIDEA



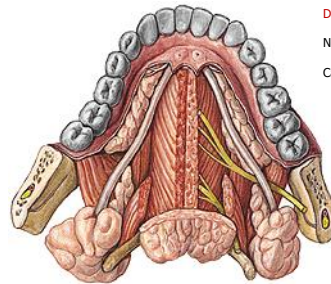
- Monostomatic
- Serous
- Lobus superficialis
- Lobus profundus
- Nervus facialis
- Ductus parotideus
- Glandula parotidea accessoria



GLANDULA SUBMANDIBULARIS

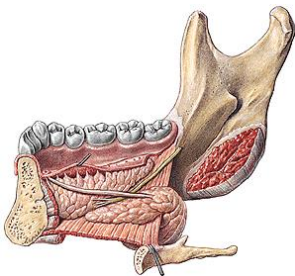


- Monostomatic
- Seromucinosus
- Arteria et vena facialis
- Ductus submandibularis



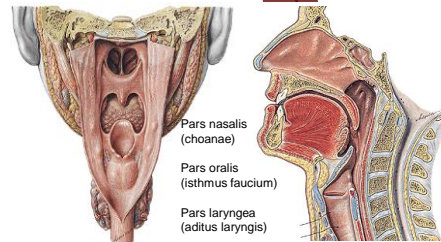
- Ductus submandibularis
- Nervus lingualis
- Caruncula sublingualis

GLANDULA SUBLINGUALIS



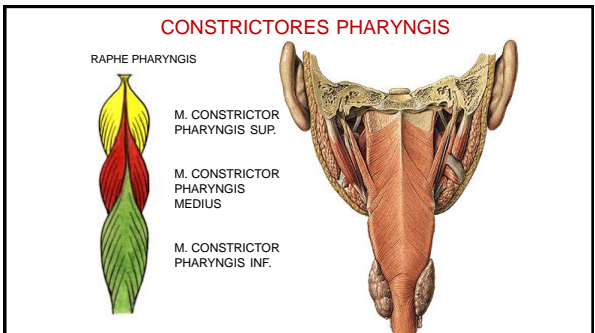
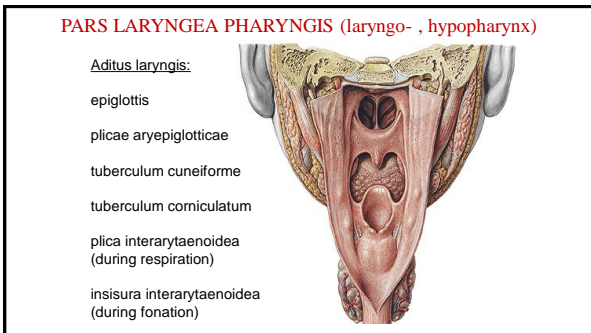
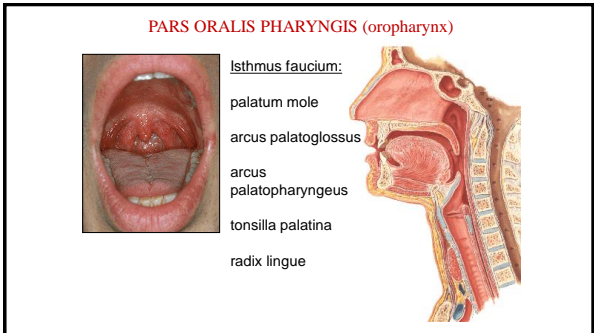
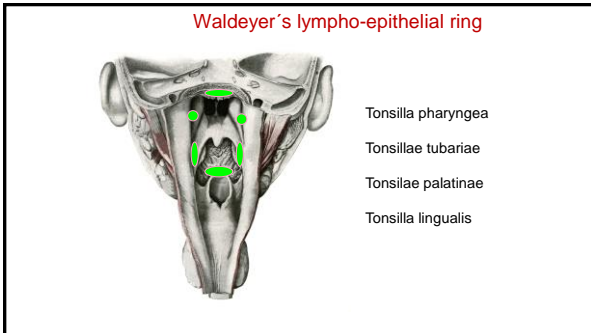
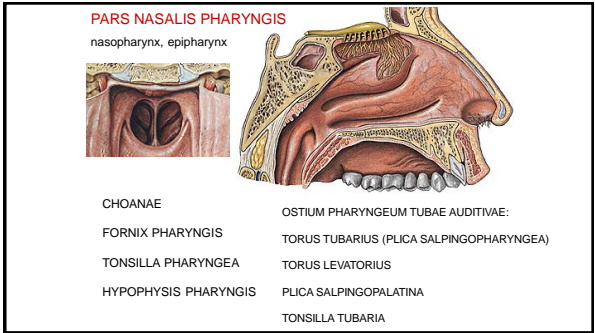
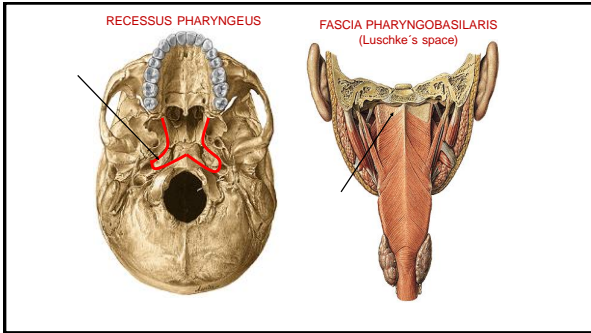
- Polystomatic
- Ductus sublingualis major
- Ductus sublinguales minores (20)
- Plica sublingualis
- Caruncula sublingualis

Pharynx

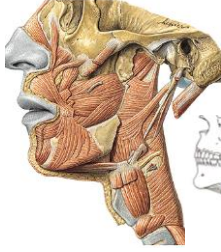


Base of skull – C6

cavum pharyngis
fornix pharyngis

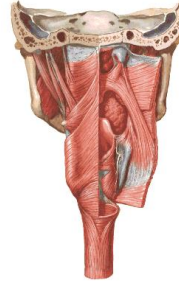


CONSTRICTORES PHARYNGIS



- M. CONSTRICTOR PHAR. SUP.
- PARS PTERYGOPHARYNGEA
- BUCOPHARYNGEA
- MYLOPHARYNGEA
- GLOSSOPHARYNGEA
- M. CONSTRICTOR PHAR. MED.
- PARS CHONDROPHARYNGEA
- CERATOPHARYNGEA
- M. CONSTRICTOR PHAR. INF.
- PARS THYROPHARYNGEA
- CRICOPHARYNGEA

LEVATORES PHARYNGIS



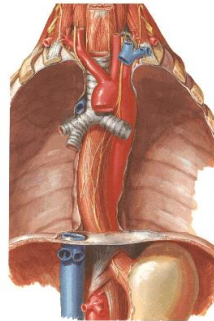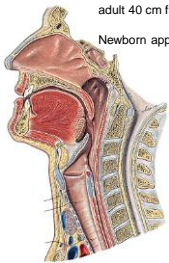
- M. STYLOPHARYNGEUS (proc. styloideus)
- M. SALPINGOPHARYNGEUS (tuba auditiva)
- M. PALATOPHARYNGEUS (aponeurosis palatina)

OESOPHAGUS (C6 - Th11)

Ostium cardiacum:

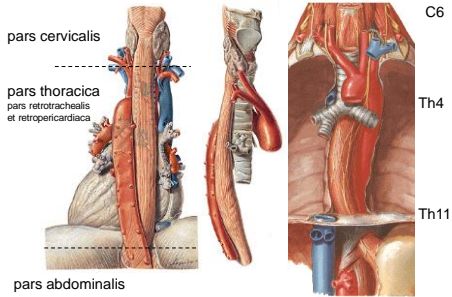
adult 40 cm from inferior incisors

Newborn approx. 14 cm

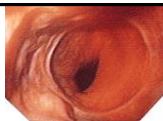

pars cervicalis

pars thoracica
pars retrotrachealis
et retropericardica



pars abdominalis

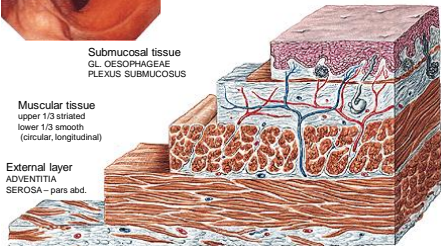


Mucous membrane
JUNCTION GASTROESOPHAGEALIS
LONGITUDINAL FOLDS

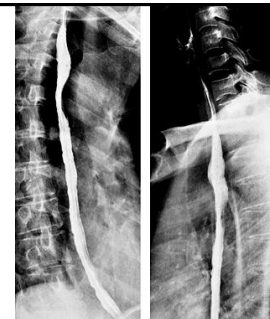Submucosal tissue
GL. OESOPHAGEAE
PLEXUS SUBMUCOSUS

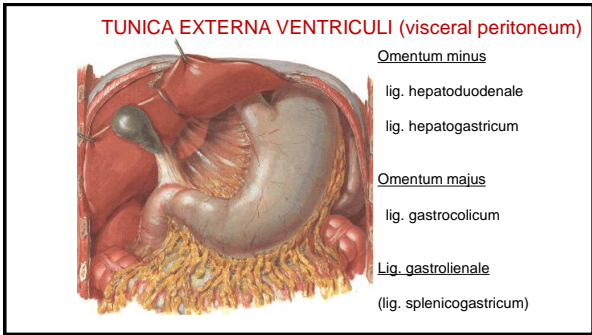
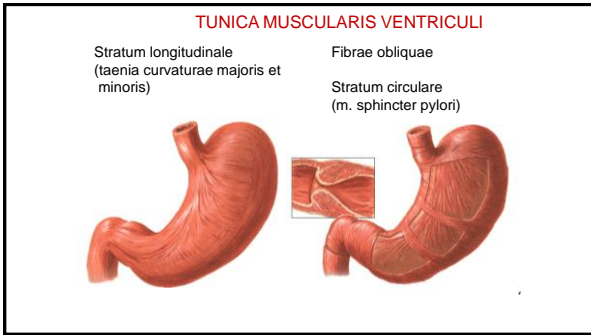
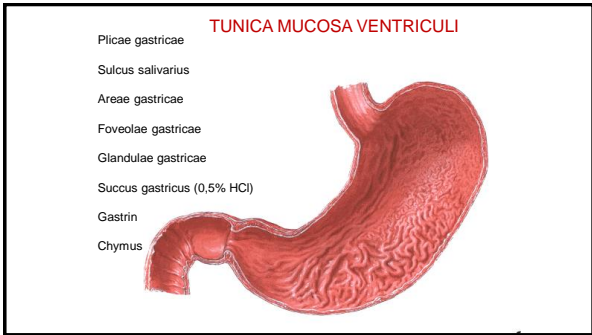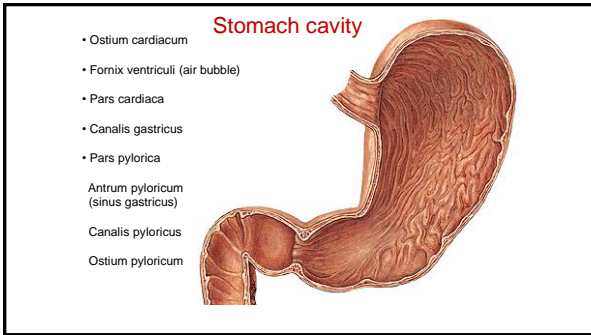
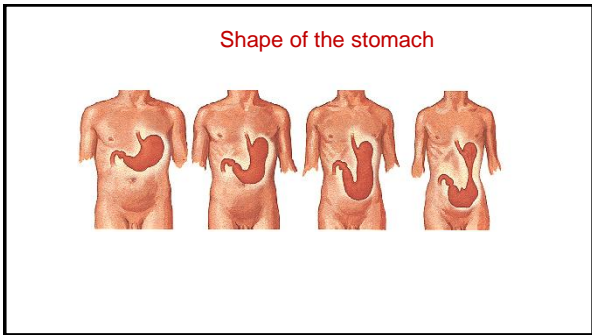
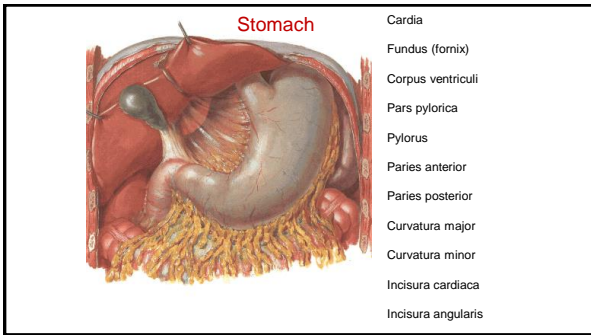
Muscular tissue
upper 1/3 striated
lower 1/3 smooth
(circular, longitudinal)

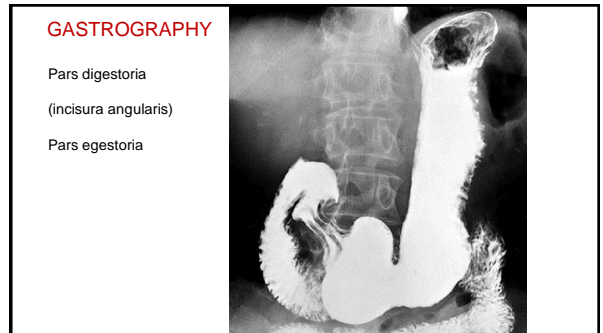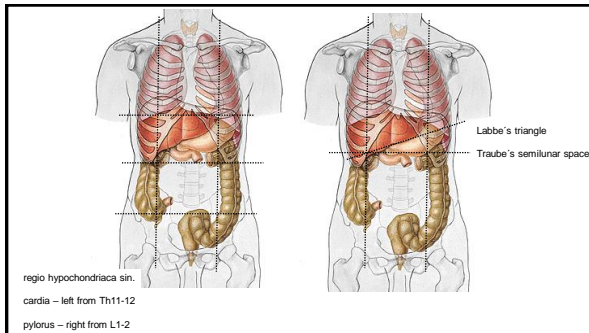
External layer
ADVENTITIA
SEROSEA - pars abd.



ESOPHAGOGRAPHY







References:

Putz, R. (2008):

Atlas of Human Anatomy Sobotta. Elsevier Books.

Keith L. Moore, Arthur F. Dalley (2005):

Clinically Oriented Anatomy. Williams and Wilkins.

Platzer, W., Kahle, W., Leonhardt H. (1992):

Locomotor system. Georg Thieme Verlag, Stuttgart, New York, 4th edition.

Čihák, R. (1987):

Anatomie 1. Avicenum, Zdravotnické nakladatelství.

Netter, F. H. (1997):

Interactive Atlas of Clinical Anatomy. Novartis, USA.