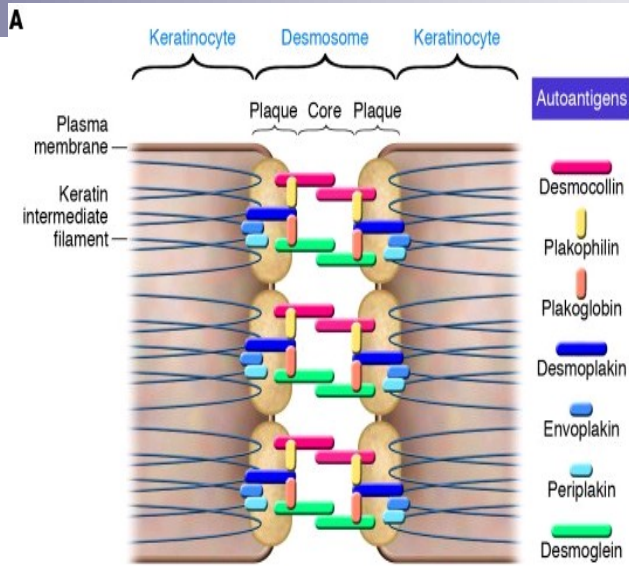
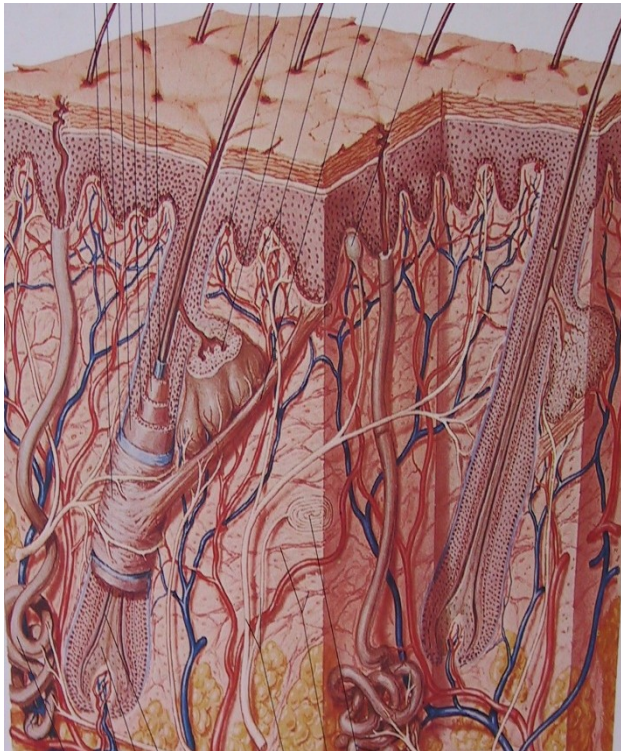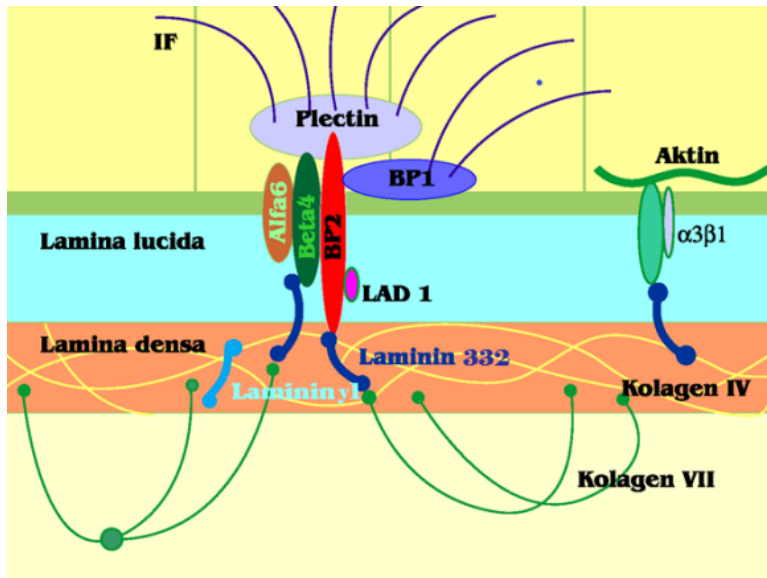


Autoimmune bullous diseases

- Intraepidermal – pemphigus
- Subepidermal – pemphigoid group, DHD
- Diagnostics – (Tzanck test), histology, immunofluorescence direct & indirect, ELISA, immunoblot

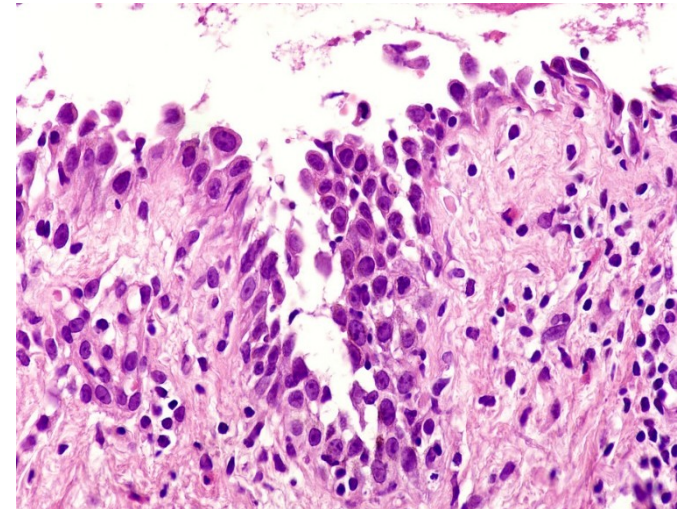


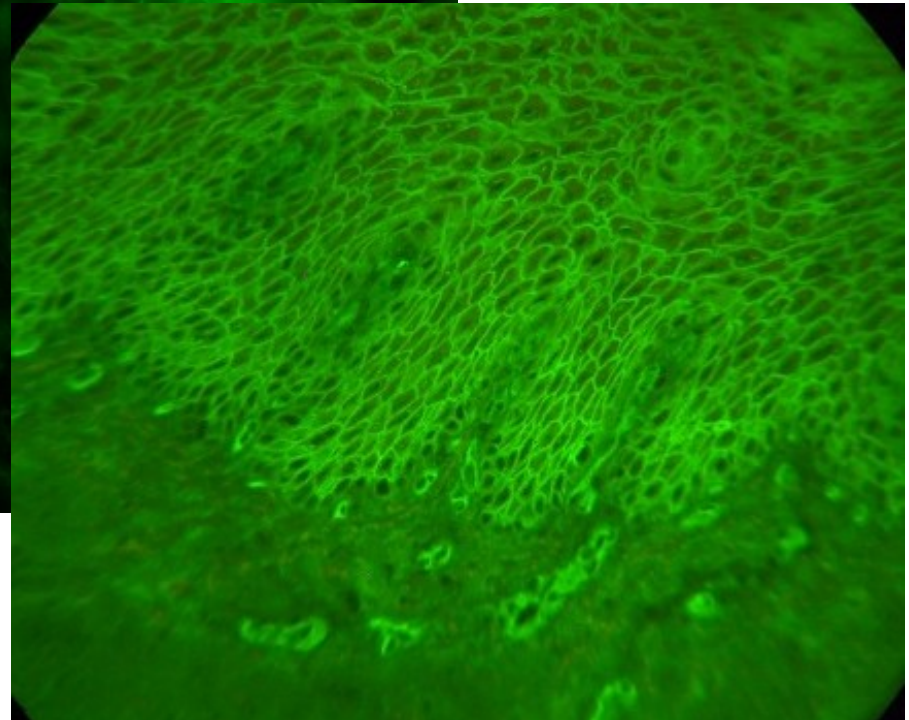
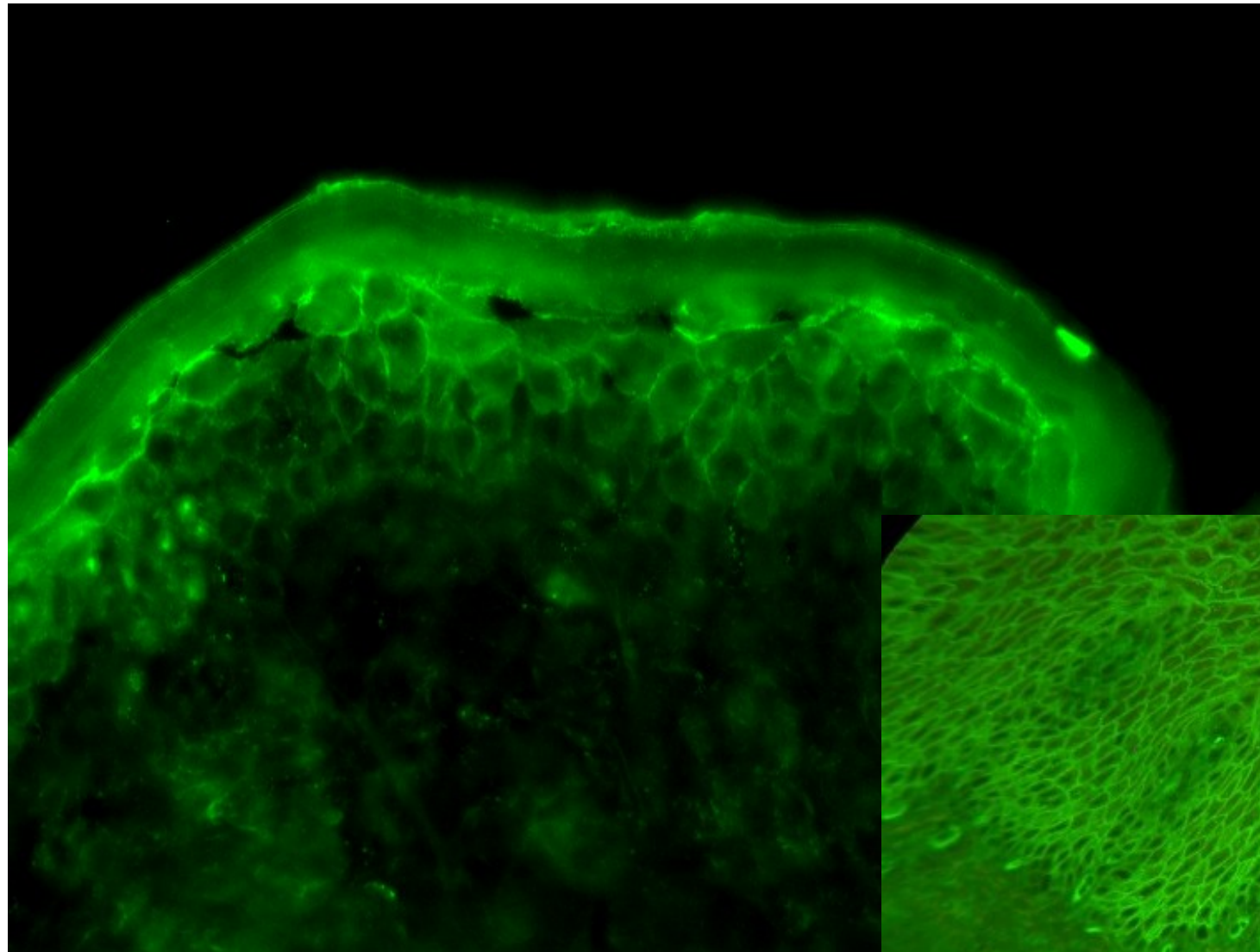
B



Pemphigus

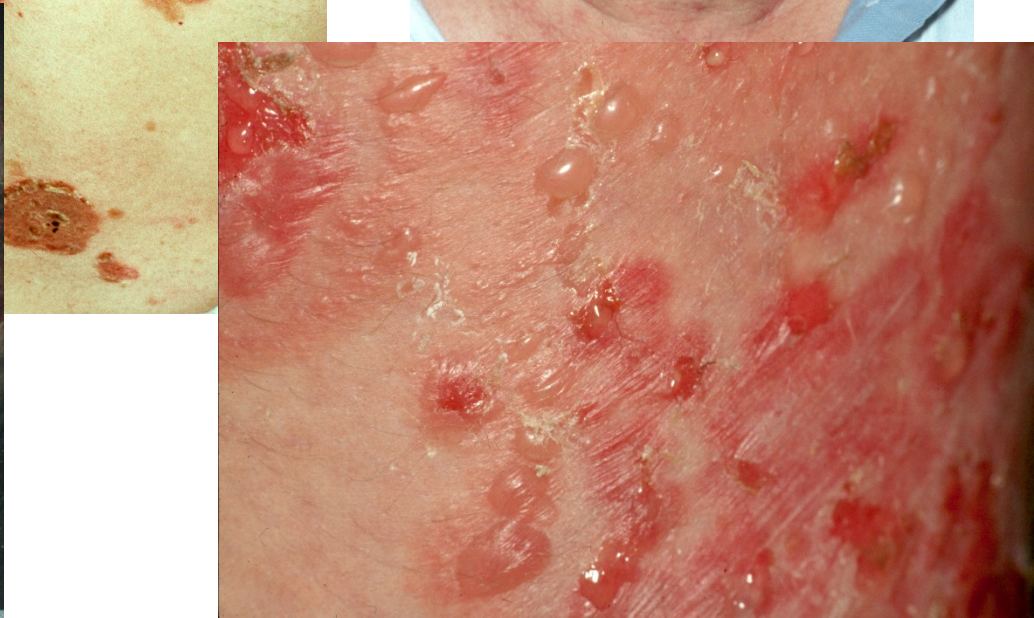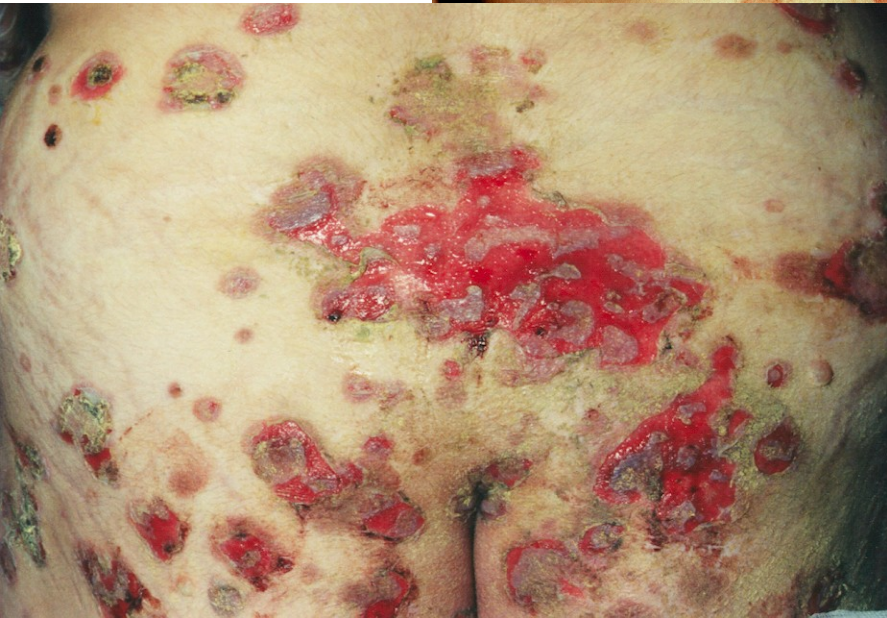
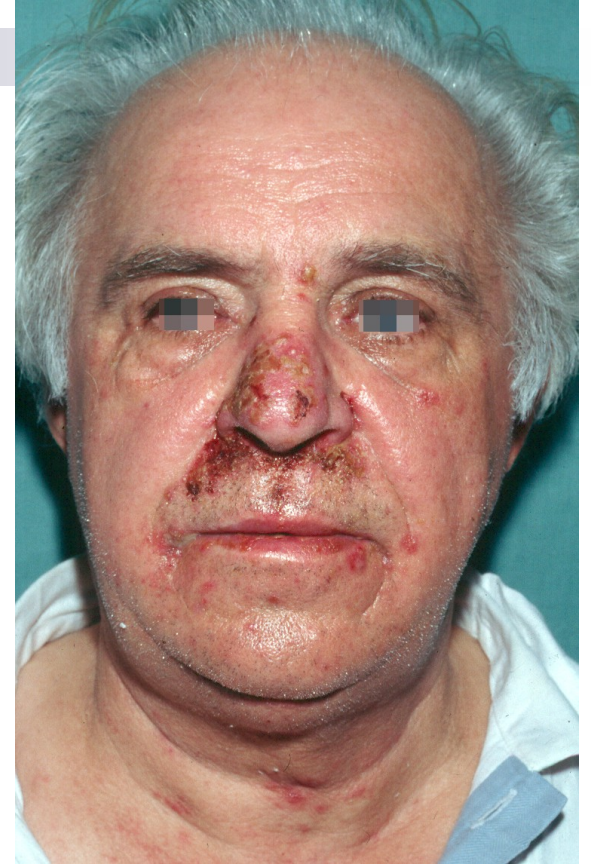
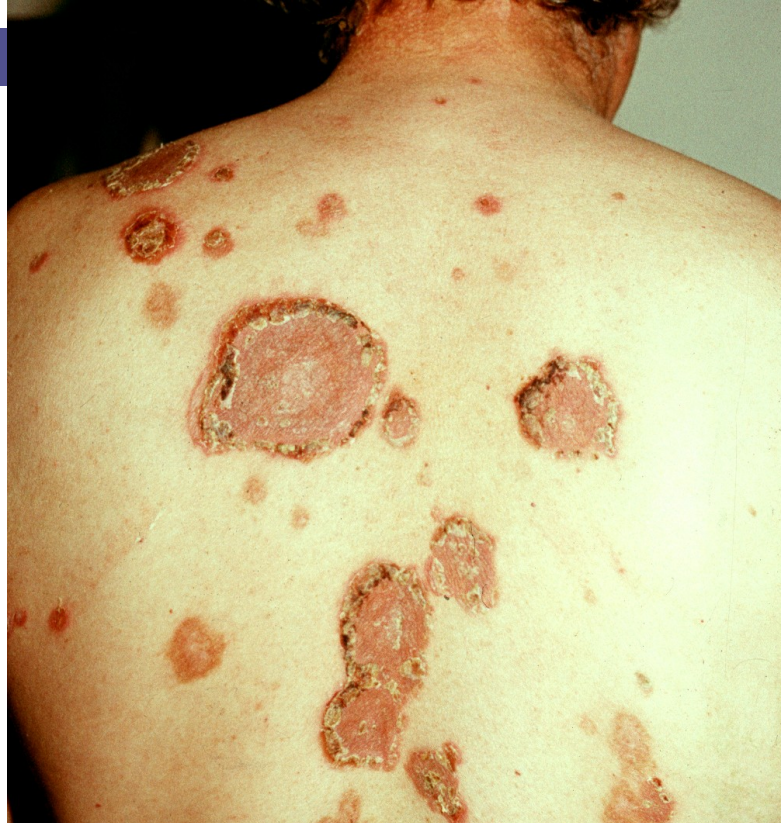- rare bullous disorder with autoantibody-induced intraepidermal blisters (desmosomes - acantholysis)
- chronic disease, can be lethal
- average age 40-60 years
- drug induced
- paraneoplastic pemphigus



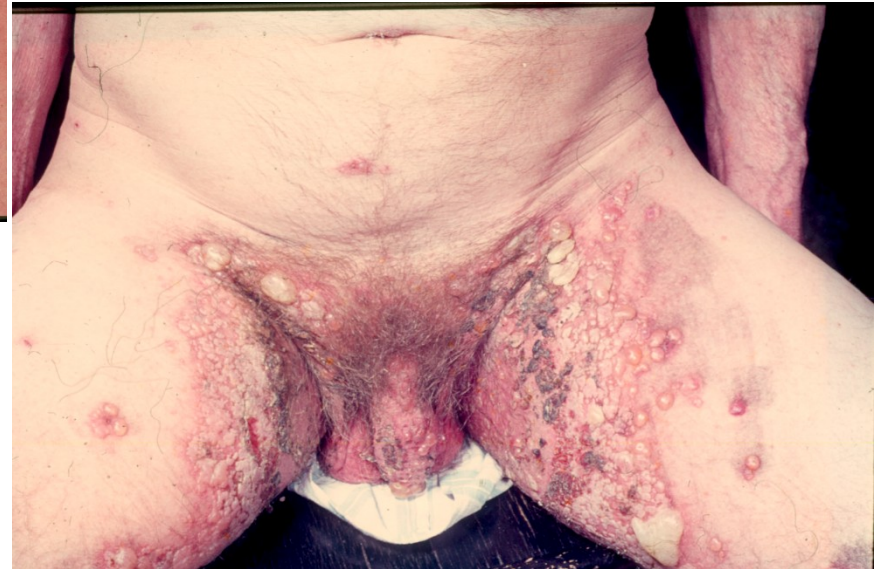
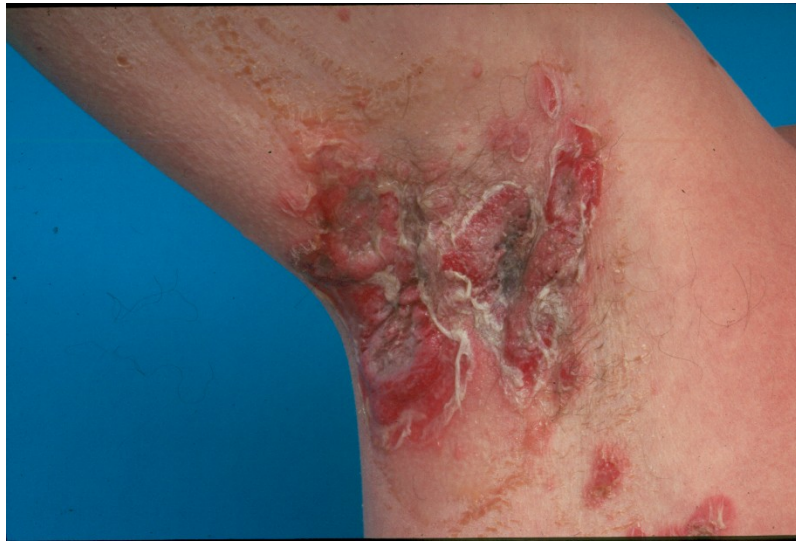
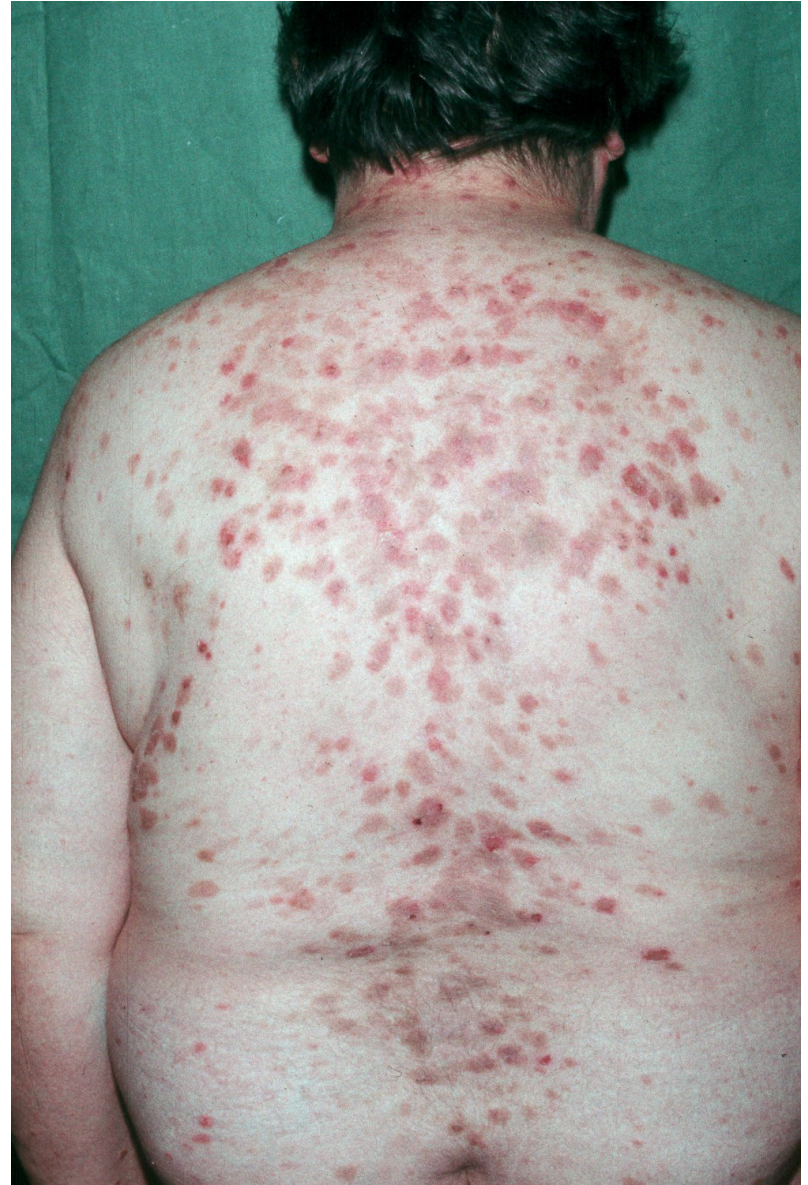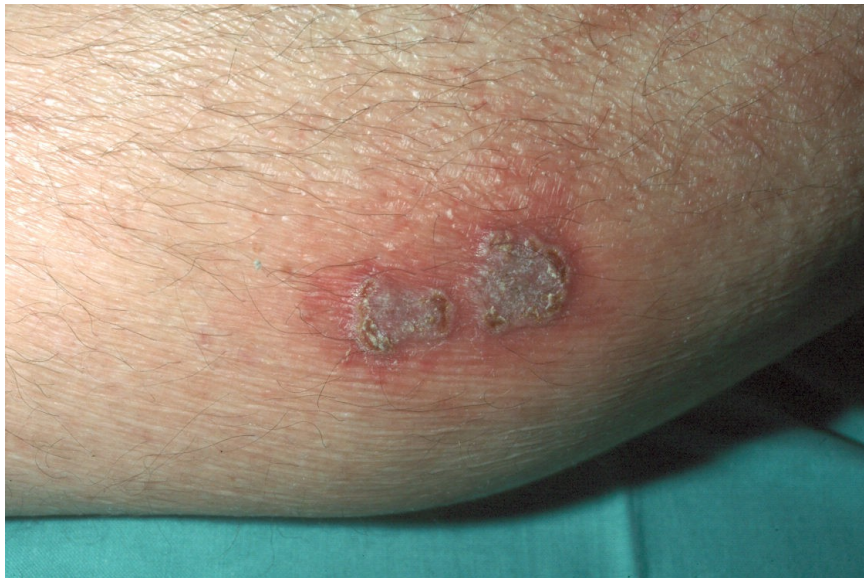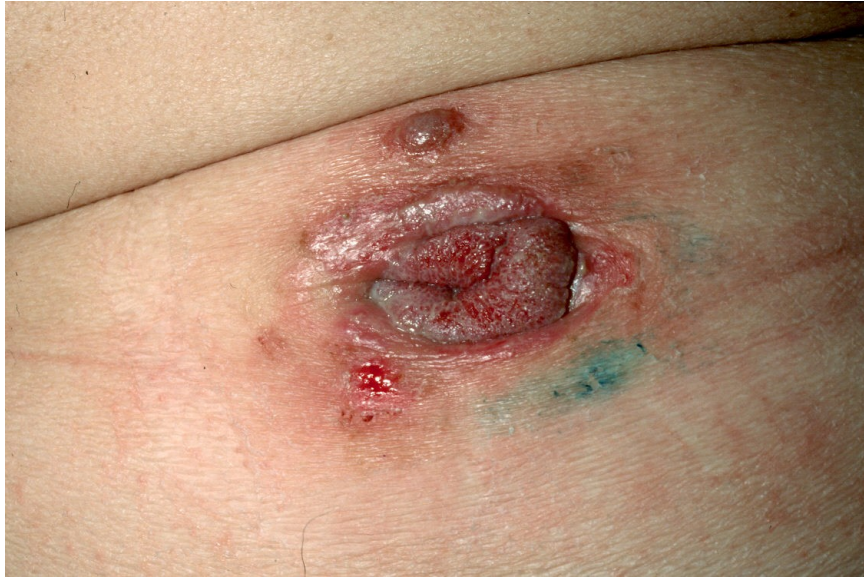Pemphigus

- Suprabasal – pemphigus vulgaris
vegetans
- Superficial – pemphigus foliaceus
fogo selvagem
drug induced (thiol group)
pemphigus erythematosus



Pemphigus vegetans





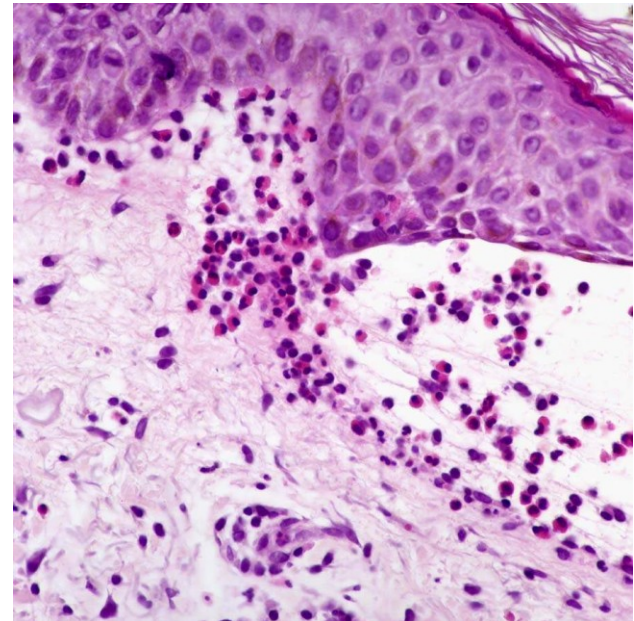
Pemphigus

Therapy

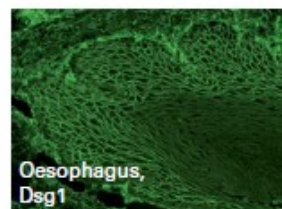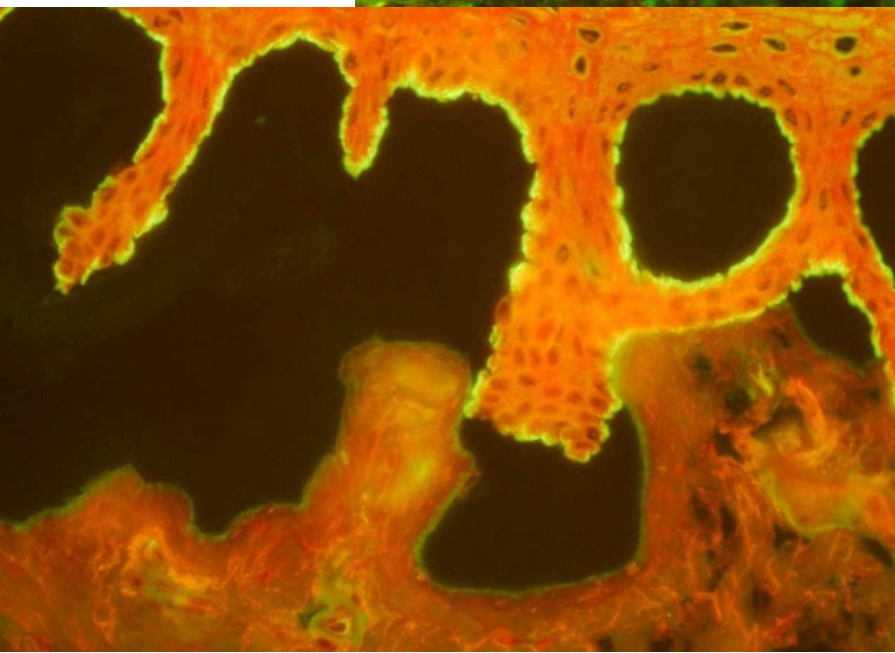
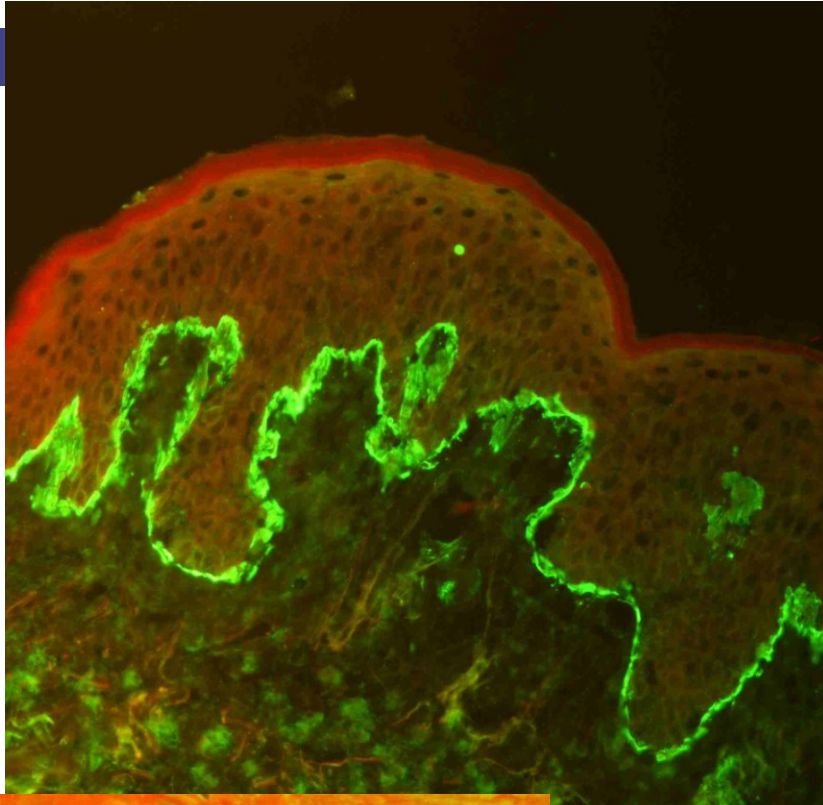
- Corticosteroids (Prednisone 1-1,5mg/kg/d)
- Immunosuppressives – mycophenolate mofetil
 - Cyclophosphamide
 - Azathioprine
- Rituximab anti CD20 antibody
- IVIG
- Immunoabsorption

Pemphigoid bullosus

- Relatively rare disorder with autoantibody-induced subepidermal blisters (basement membrane – hemidesmosomes)
- Bullous pemphigoid
- Cicatricial pemphigoid
- Epidermolysis bullosa acquisita
- IgA linear dermatosis

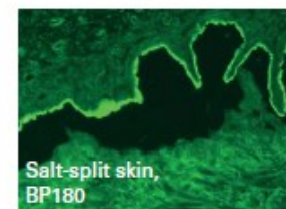

Hypertext atlas dermatopathology



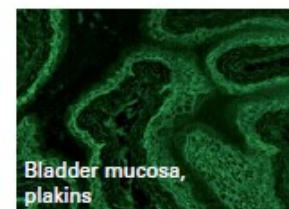Oesophagus,
Dsg1

Oesophagus: detection of antibodies against prickle-cell desmosomes (pemphigus) and basal lamina (pemphigoid).



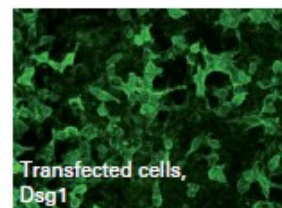
Salt-split skin,
BP180

Salt-split skin: differentiation of autoantibodies against antigens of the epidermal (BP180, BP230) and dermal (collagen type VII, laminin 332, p200) sides of the skin.

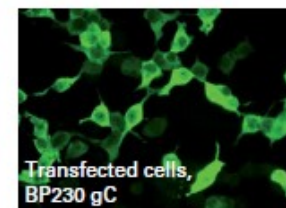


Bladder mucosa,
plakins

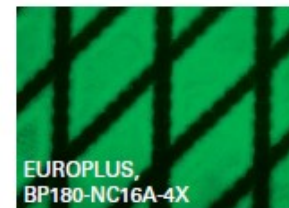
Bladder mucosa: detection of autoantibodies against plakins (paraneoplastic pemphigus).



Transfected cells,
Dsg1



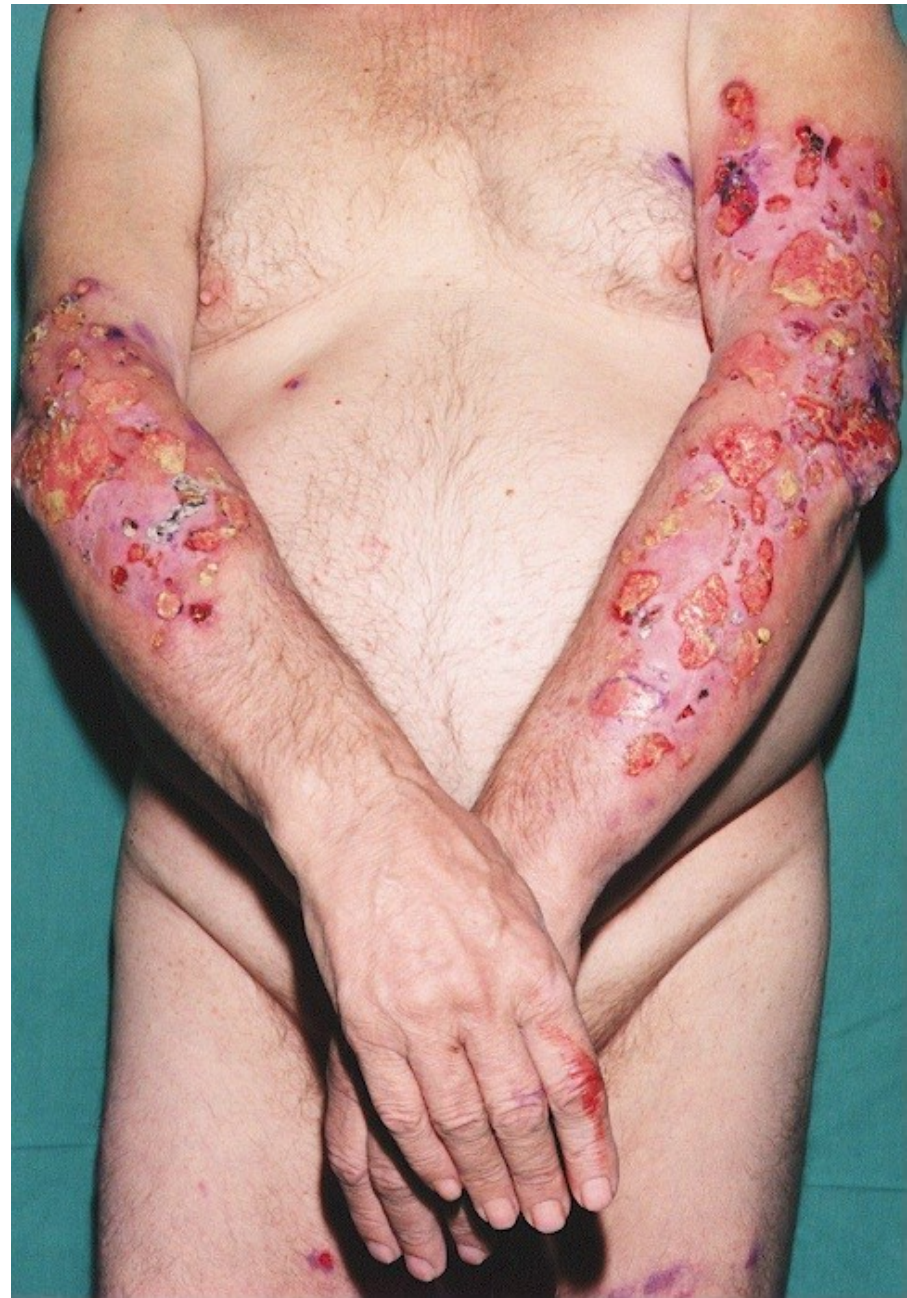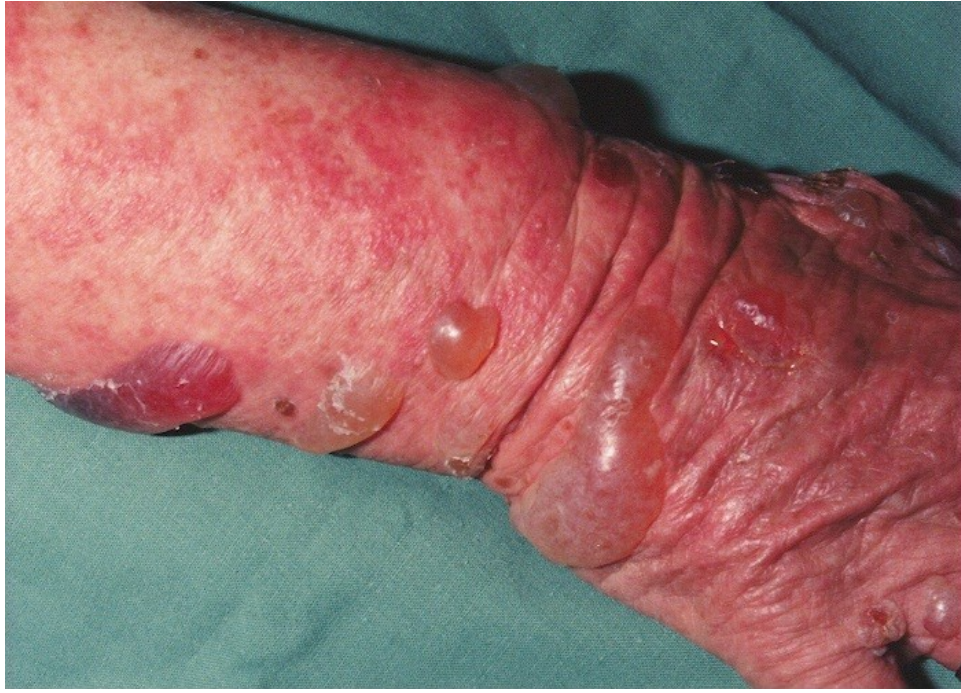Transfected cells,
BP230 gC

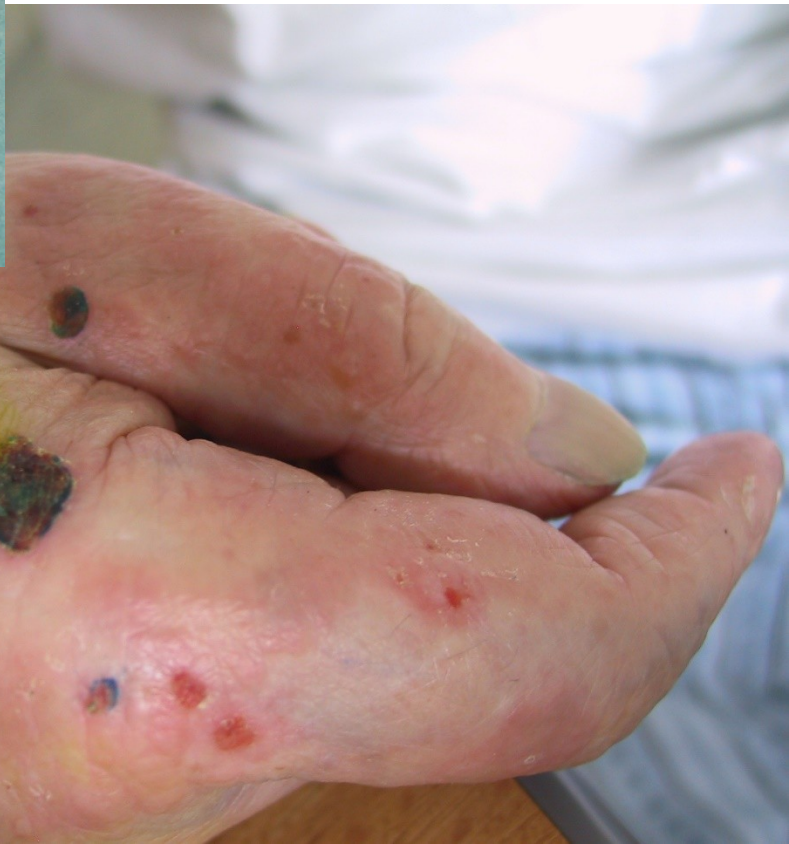
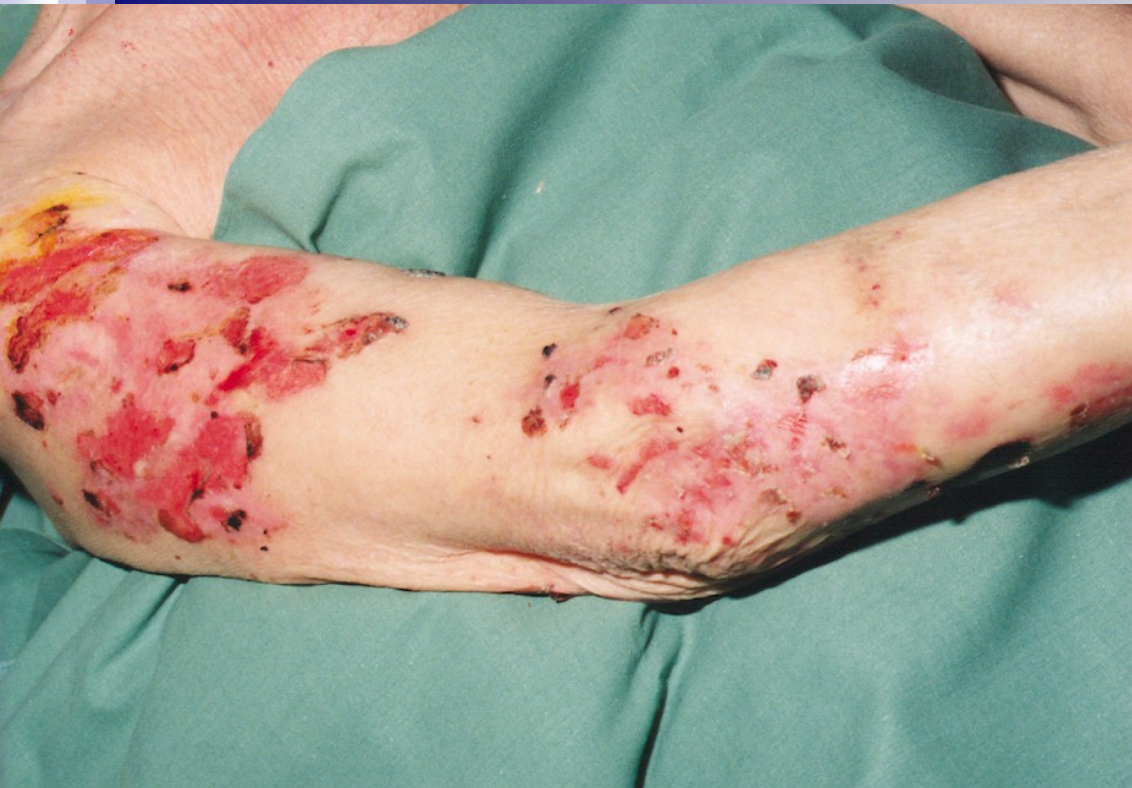
EUROPLUS,
BP180-NC16A-4X

Pemphigoid bullosus

- Elder people – over 70 years
- Paraneoplastic disease (13%)
- Drug induced (gliptins, ACE inhibitors)
- Many concomittant diseases
- Neurodegenerative diseases! (40%)





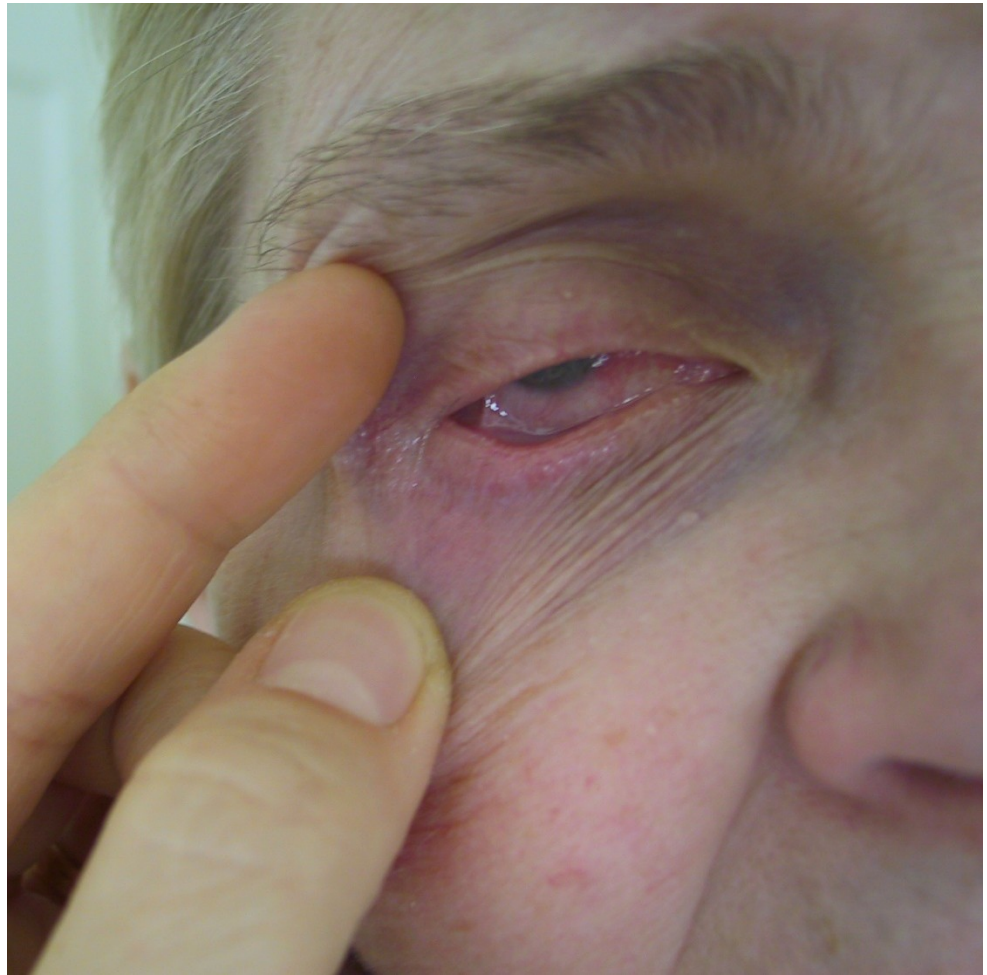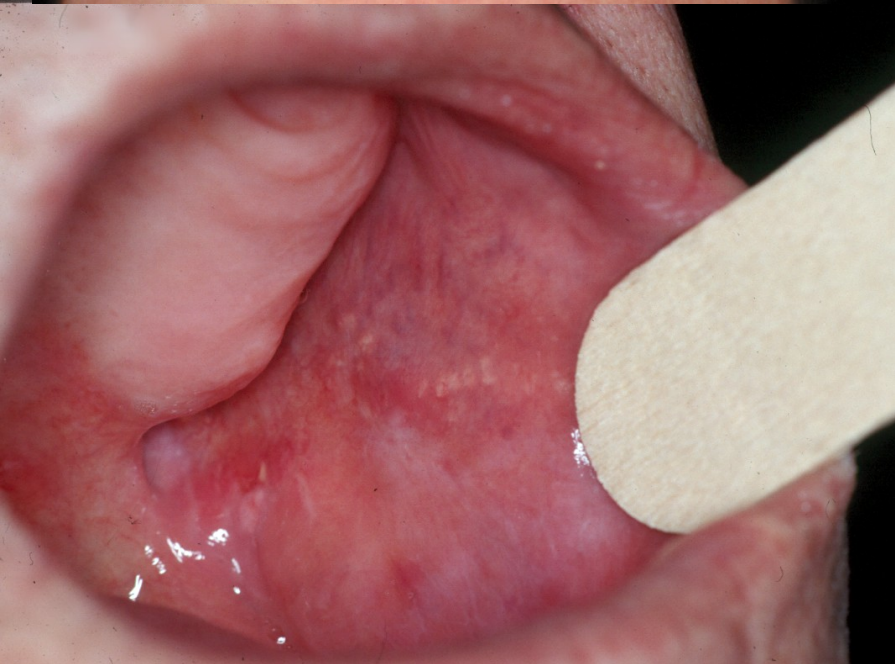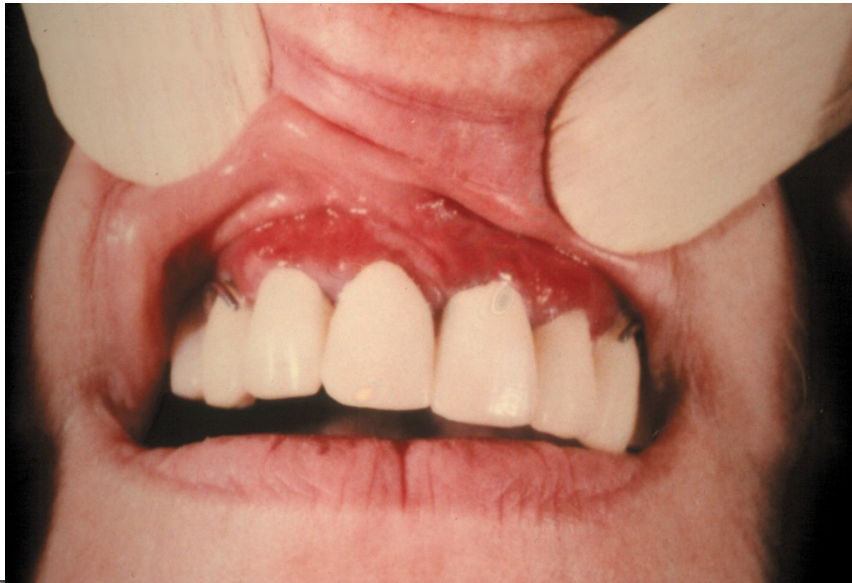Pemphigoid bullosus

Therapy

- Corticosteroids (Prednisone 40-60mg)
- Immunosuppressives (azathioprine, methotrexate)
- Dapsone
- Potent topical corticosteroids

Cicatricial pemphigoid

- Mucose membranes
- Conjunctiva → blindness
- Pharynx, larynx, genital area → stenosis, scarring



Dermatitis herpetiformis Dühring

- gluten sensitive enteropathy – coeliacia
- IgA antibodies against endomysium (tissue transglutaminase)
- cross reaction with eTG on reticulin fibers in dermal papillae
- Sensitivity to gluten, iodine



Dermatitis herpetiformis Duhring

- Young adults
- HLA DQ2 association

Therapy

- Gluten free diet
- Dapsone
- Topical corticosteroids

