

MUNI
MED

Spirometric examination

Recording of forced vital capacity

Physiology I – practice

Autumn, weeks 7–9

Static lung volumes

– Static lung volumes:

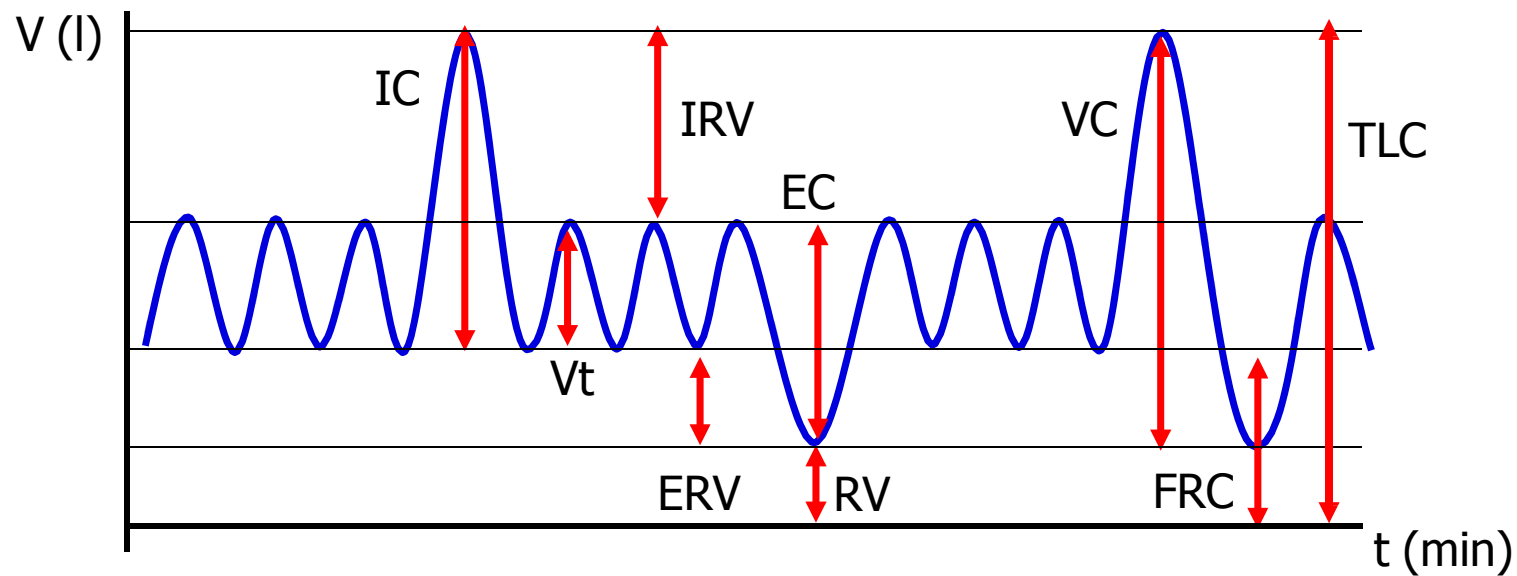
- Tidal volume V_t (0.5 L)
- Inspiratory reserve volume IRV (2.5 L)
- Expiratory reserve volume of the ERV (1.5 L)
- Residual volume RV (1.5 L)

– Static lung capacity:

- Vital capacity of lungs VC (4.5 L)
= IRV+ V_t +ERV
- Total lung capacity TLC (6 L)
= IRV+ V_t +ERV+RV
- Inspiratory capacity IC (3 L)
= IRV+ V_t
- Functional residual capacity FRC (3 L)
= ERV+RV

- Depends on height, weight, age and gender – RV increases, VC decreases with age
- All volumes can be measured with spirometer except RV and FRC

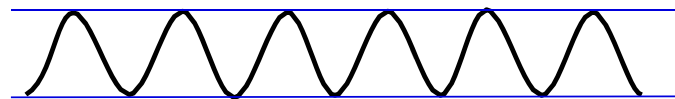
Static lung volumes



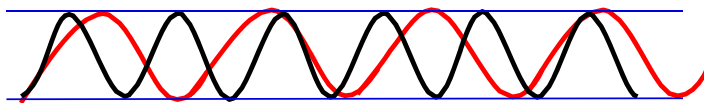
Frequency and depth of breathing

- Changes in **respiration rate**
- Changes in **respiratory depth**

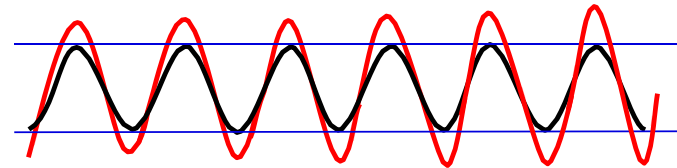
Eupnea – resting respiration



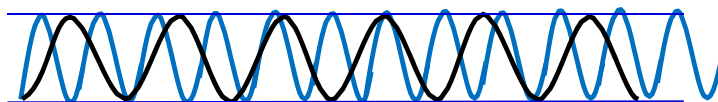
Bradypnea – slow respiration



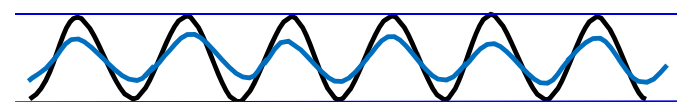
Hyperpnea – deep respiration



Tachypnea – fast respiration

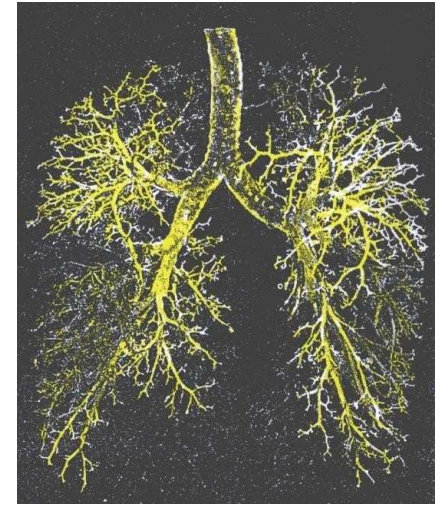


Hypopnea – shallow respiration



Dead space

- Dead space represents the volume of ventilated air that does not participate in gas exchange
- There are two types of dead space:
 - Anatomic – represented by the volume of air that fills the conducting zone of respiration made up by the nose, trachea, and bronchi (this volume is considered to be 30% of normal tidal volume (500 mL); therefore, the value of anatomic dead space is 150 mL)
 - Physiologic or total dead space is equal to anatomic plus alveolar dead space which is the volume of air in the respiratory zone (respiratory bronchioles, alveolar duct, alveolar sac, and alveoli) that does not take part in gas exchange
- In a healthy adult physiologic dead space is equivalent to anatomic



Dynamic lung volumes

- Resting respiration:
 - Respiratory rate 10-18 breaths/min
 - Minute ventilation – air volume at respiration per minute ($V_t \times$ respiration rate)
5-9 l/min
- Maximum voluntary ventilation (MVV) – the amount of air that can be ventilated at maximum effort (up to 160 l/min)
 - Ventilation is increased by increasing both the respiration rate and depth of the respiration
- Respiratory reserve = maximum ventilation / resting ventilation
- Parameters of forced vital capacity

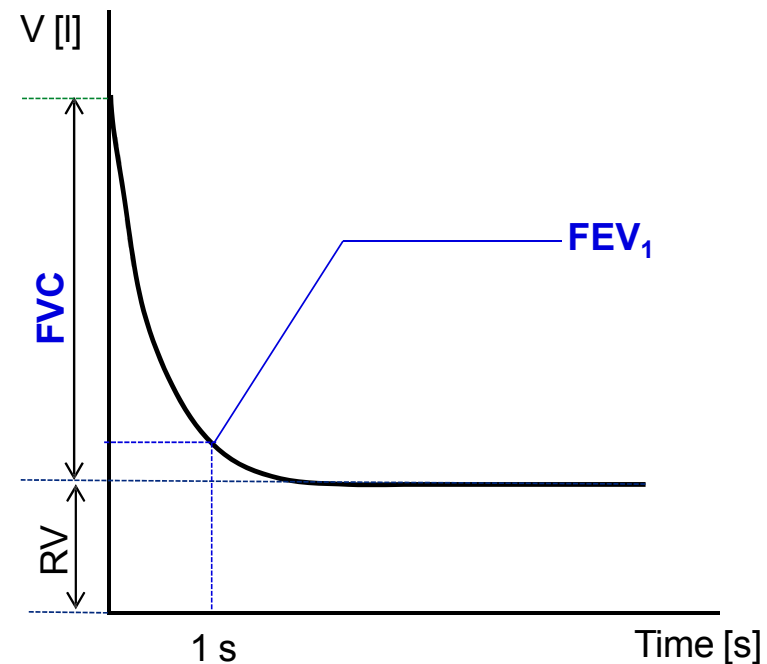
Recording of forced vital capacity

Lung diseases

- **Obstruction:** increased airway resistance (asthma, bronchitis, vocal cord swelling, tracheal stenosis, COPD, tumor in the airways)
- **Restrictions:** decreased lung volumes (tumor, inflammation, swelling of the lungs, pneumothorax...)
- An increase in the respiratory rate at a constant tidal volume leads to a relative increase in dead space

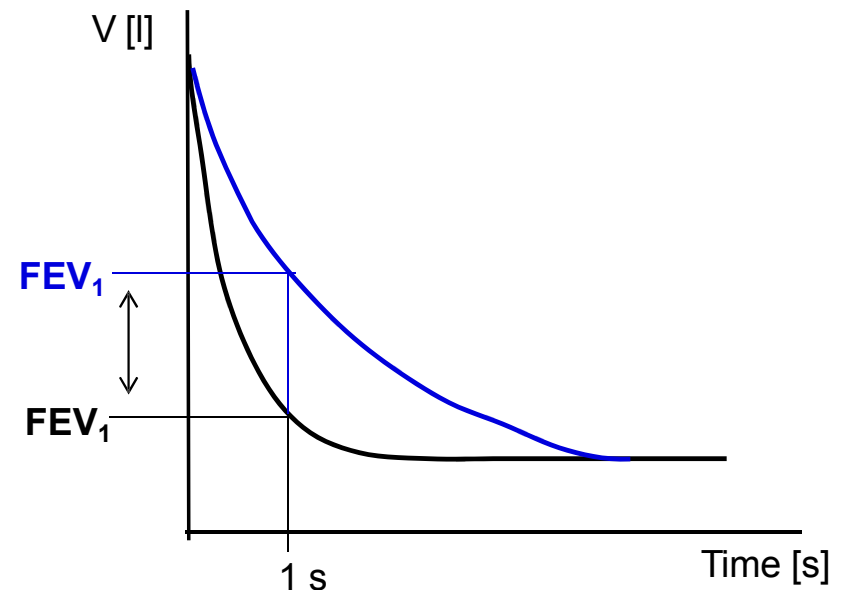
Recording of forced vital capacity

- Dynamic lung volumes
 - **FVC** – **forced vital capacity** – the maximum volume of air that can be exhaled after maximum inhale
 - **FEV₁** – **forced expiratory volume in 1 second** – the volume of air exhaled with the greatest effort in 1st second after maximum inhale
 - **FEV₁/FVC ratio** (%) – relative forced expiratory volume in 1 second = Tiffeneau index
0.7-1.0 (70%-100%)



Recording of forced vital capacity

- Obstructive diseases:
 - Obstruction → increased resistance in the airways
 - Causes: asthma, bronchitis, vocal cord swelling, tracheal stenosis, COPD, tumor in the airways
 - FVC normal, $FEV_1 \downarrow$, Tiffeneau index \downarrow (<0.7)



Airway resistance (Hagen-Poiseuille law)

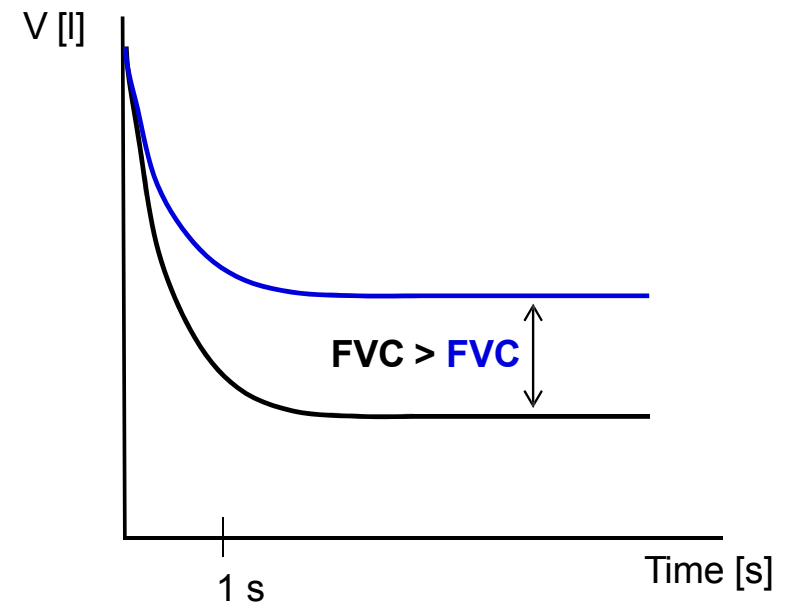
- Airway resistance (R_d) arises as a result of internal friction between the flowing gas and the airway wall.

$$R_d = \frac{\Delta P}{Q} = \frac{8 \cdot l \cdot \eta}{\pi \cdot r_d^4}$$

- A small change in the radius of the airways (r_d) causes a significantly larger change in the resistance to airflow (R_d).
- Narrowing (obstruction) of the airways occurs when the chest is compressed, the mucous membrane becomes swollen, the vocal cords swell, the smooth muscles of the airways are constricted, when a foreign body is inhaled, during an asthma attack or other allergic reaction
- Bronchioles are the most involved in resistance: they possess a large proportion of smooth muscle and no cartilaginous reinforcement, they also contain receptors for various agents (histamine – bronchioloconstriction, adrenaline – bronchiolodilation)

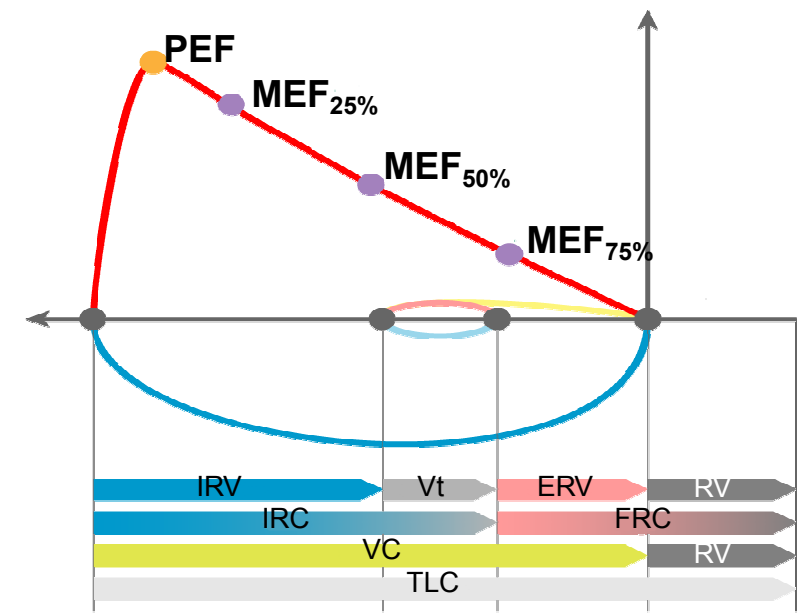
Recording of forced vital capacity

- Restrictive diseases:
 - Restriction: decreased lung volumes
 - Causes: pulmonary (fibrosis, resection, edema, pneumonia) or extrapulmonary (ascites, kyphoscoliosis, burns, elevated diaphragm)
 - FVC ↓, FEV₁ N or ↓, Tiffeneau index N or ↑
 - If the expiratory muscles are strong enough, Tiffeneau index value can be 100% and it is not a pathology. Therefore, its usage during the diagnosis of a restrictive disorder is not suitable.



Maximal respiratory flow – volume curve

- Principle: the measurement of the airflow velocity according to the speed of the turbine. Then the volumes are calculated.
- **PEF** – peak expiratory flow; the highest speed of airflow at peak of exhale
- **MEF** – maximum expiratory flow rates at different FVC levels, which is still to be exhaled (75%, 50% and 25% of FVC)



Pneumothorax

- Accumulation of air or other gas in the pleural cavity with a partial or complete collapse of the lung
 - It can be traumatic (chest injury, rib fracture), spontaneous (unknown origin), caused by a disease (COPD, cystic fibrosis) or caused by surgery
 - Symptoms: shortness of breath, pain, higher lung resistance, decreased heart filling, decrease in blood pressure, tachycardia, decreased blood oxygen saturation
 - Tension pneumothorax: occurs in the so-called valve mechanism, when air penetrates into the pleural cavity during inhalation and during exhalation the defect closes which leads to an air accumulation in the cavity. It is the most dangerous type of pneumothorax because the air accumulating in the thoracic cavity gradually oppresses all the mediastinal organs to the unaffected side, thereby oppressing even the second lung, worsening the functions of the heart and causing damage to large vessels.

