

## 18. Elevated liver enzymes in biliary obstruction

Elevation of liver enzymes (GGT and ALP) is present in biliary obstruction, but also in liver damage due to other causes. In biliary obstruction, this condition is accompanied by jaundice due to increased level of bilirubin in the blood.

*Jaundice is a clinical condition of yellowing of the skin and mucous membranes caused by increased bilirubin. In the laboratory, we are usually able to distinguish whether it is an obstructive (posthepatic) or non-obstructive jaundice.*

Obstructive jaundice can be divided into painful and painless. Painful jaundice indicates biliary obstruction by stones (choledocholithiasis). On the contrary, painless jaundice is in the vast majority of cases of tumor etiology (cholangiocellular carcinoma, tumor of pancreatic head, or multiple liver metastases, hepatocellular carcinoma), less often benign etiology (stenosis of hepaticojejunal anastomosis). Thus, obstructive jaundice is usually accompanied by dilatation of the bile ducts, however, in benign etiologies the dilatation may not be significant or not present at all.

### Ultrasound

The method of choice for confirming dilatation of the bile ducts is **ultrasound**. Dilated bile ducts appear as anechoic non-vascularized tubular structures pointing towards the hepatic hilum, where ductus hepatocholedochus is formed and flows into the duodenum via papilla Vateri.

Ultrasound shows possible tumor of the liver, in cases with good ultrasound visibility also the level of biliary tract obstruction and possible choledocholithiasis or pancreatic tumor. Based on the ultrasound examination, other imaging or therapeutic methods are chosen.

*The gallbladder and bile ducts should be examined on an empty stomach, otherwise the image is postprandially distorted. Cholecystolithiasis<sup>1</sup> is very common, especially in middle-aged women. Although the stones in the gallbladder themselves do not obstruct the outflow of bile from the liver to the duodenum, a smaller stone may travel and consequently wedge during the choledochus and causes obstructive **choledocholithiasis**. It is important to realize that **only about 20% of stones are visible on X-ray or CT**. Therefore, the first choice method is ultrasonography, whose sensitivity to diagnose stones in the gallbladder is up to 100%. The stones appear as hyperechogenic objects with dorsal acoustic shading, and when the patient's position changes, the position of the stones also changes. Although less frequently, stones may primarily form directly in the bile ducts. Because the bile ducts are often not visible in the whole extent, sonography is less reliable in detection of bile duct stones, and we can only detect bile duct dilatation above the obstruction.*

### CT

**CT** serves to clarify the cause of bile duct obstruction in painless jaundice and to evaluate the extent of potential cancer (staging).

*CT is necessary to perform even after intravenous administration of a contrast agent, both in the portal venous phase (sufficient for multiple metastases) and the arterial phase (necessary for imaging of pancreatic tumors and primary liver tumors) (for more details, see the question regarding liver foci). Under CT guidance, it is also possible to perform a biopsy of the liver tumor for histopathological examination, which is necessary for initiation of appropriate oncological treatment (chemotherapy, biological treatment).*

### MRI

In patients with chronically elevated obstructive enzymes, **MRCP** (MR cholangiopancreatography - uses a hyperintense bile signal in a T2-weighted sequence) is indicated. The role of MRCP is to visualize possible stones in the bile ducts (which were not seen on ultrasound) and bile duct stenoses of non-

---

<sup>1</sup> Cholecystolithiasis is also referred to as cholelithiasis

tumorous etiology (e.g. primary sclerosing cholangitis, fibrotic stenoses in chronic cholangitis). MRCP is usually performed without intravenous application of a paramagnetic contrast agent.

### Acute cholangitis

All cases of obstructive jaundice can be complicated by **acute cholangitis** (clinically pain, fever, and chills), which is an indication for acute biliary recanalization by ERCP (endoscopic retrograde cholangiopancreatography) or PTD (percutaneous transhepatic drainage).

***Cholangitis** is most often caused by infectious injury to the bile ducts by bacteria migrating (ascending) from the intestinal tract. It is primarily a clinical and laboratory diagnosis. On imaging methods, only dilatation of the bile ducts is usually observed. Rarely, thickening of the wall of the bile ducts, edematous infiltration of the surroundings, and air in the bile ducts may also be visible.*

### ERCP (endoscopic retrograde cholangiopancreatography)

**ERCP** is a method of choice for treatment of acute cholangitis.

In painful jaundice (choledocholithiasis), ERCP is performed after ultrasound examination. It is used to remove stones (basket and balloon) and to perform sphincterotomy of papilla Vateri for easier removal of any residual stones.

In the event of tumor obstruction (based on CT), it serves to introduce the duodenobiliary drain and restore the passage of bile into the duodenum. Introduction of duodenobiliary drain is important only for stenoses in the area of hepatocholedochus— in hilar stenoses, this solution is usually insufficient and more invasive PTD is necessary (PTD can be performed initially in these cases). In case of repeated failure of bile duct recanalization via ERCP, PTD can be also indicated (e.g. pancreatic head tumor that infiltrates or disfigures papilla Vateri, difficulties with Vateri papilla catheterization via ERCP).

*ERCP (Endoscopic Retrograde cholangiopancreatography) is performed by gastroenterologists, when a fiberscope is inserted into the duodenum and papilla Vateri is catheterized. Iodine contrast is injected through the papilla Vateri to visualize the bile ducts and pancreatic duct under fluoroscopy.*

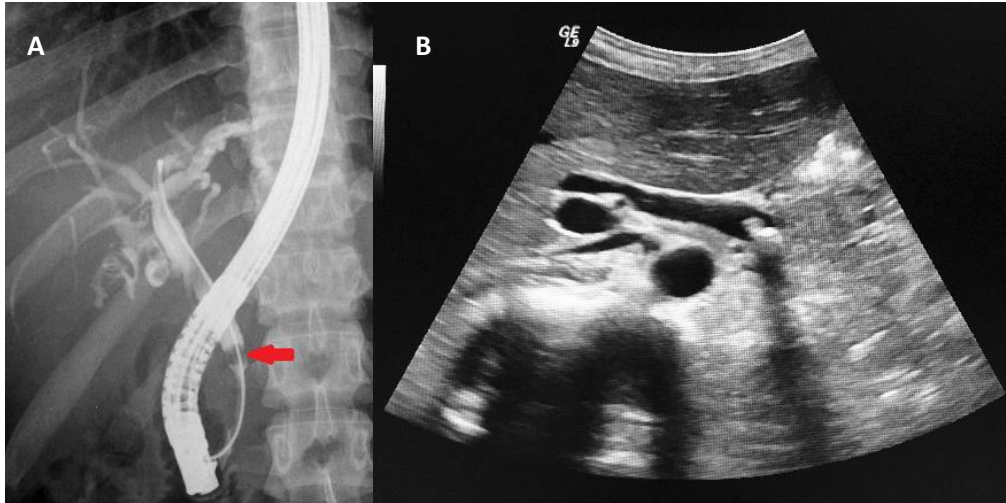
### PTD

**PTD** (percutaneous transhepatic drainage) is a therapeutic intervention method also used to restore bile passage into the duodenum. Usually 1-3 **external-internal plastic drains** are inserted to allow bile to drain from as much of the liver as possible (the outer part of the drain is closed on the patient's surface, the inner ends in the form of a "pigtail" in the duodenum; pigtail = twisted inner end of the drain to prevent its dislocation). Due to the need for daily care of the outer part of the drain and the deteriorating quality of life, the external-internal drain is replaced by a **metal stent** in patients with relatively good life expectancy (estimated survival of more than 3 months).

*In case of stent obstruction, it is necessary to perform a new PTD and insert a new external-internal drain, the stent can then be recanalized by **endoluminal radiofrequency ablation** via the inserted drain. Another therapeutic option for cholangiocellular carcinomas is **endoluminal brachytherapy** (introduction of a radioactive emitter via the bile ducts into the site of tumor obstruction), which slows tumor growth and serves to prevent stent obstruction.*

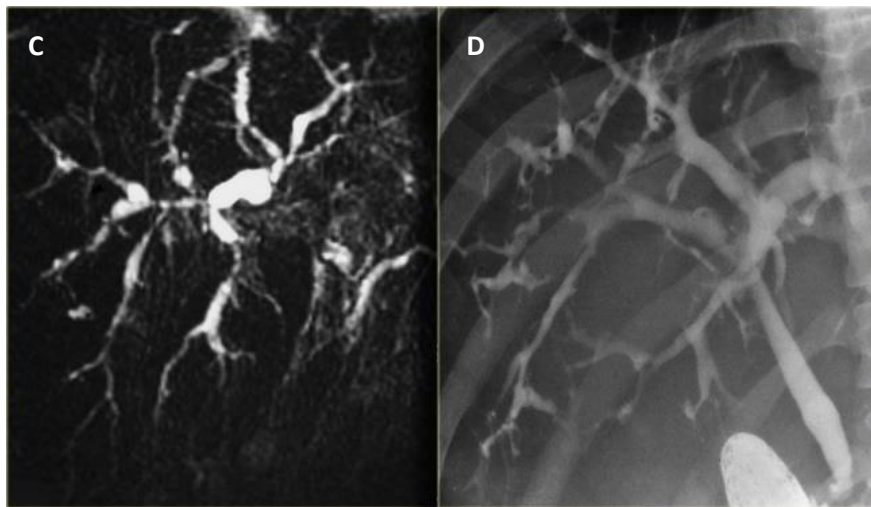
***PTC / PTD** (Percutaneous transhepatic cholangiography/drainage – a drain is introduced through the skin into the dilated bile ducts, the drain ends in duodenum; iodine contrast is used for visualization of bile ducts; procedure is performed with fluoroscopy guidance). The procedure is performed under analgesedation. As a standard, external-internal-drainage is performed to preserve the passage of bile into the duodenum and allow proper digestion of lipids. In the event that the tumor stenosis is too tight to pass into the duodenum on the first attempt, external drainage is temporarily left. After the swelling subsides, in vast majority of cases, at a second attempt we pass through the stenosis into the duodenum and the external drain is replaced to the external-internal one.*

**Primary sclerosing cholangitis (PSC)** is an inflammation of the bile ducts of unknown etiology, which occurs in up to half of the cases in patients with idiopathic bowel disease. PSC is characterized by multiple bile duct stenoses and MRCP is most often used for their visualization.



**Fig. A - ERCP** – defect in contrast filling of ductus choledochus (arrow) corresponds to the location of the bile stone (choledocholithiasis), dilated bile ducts

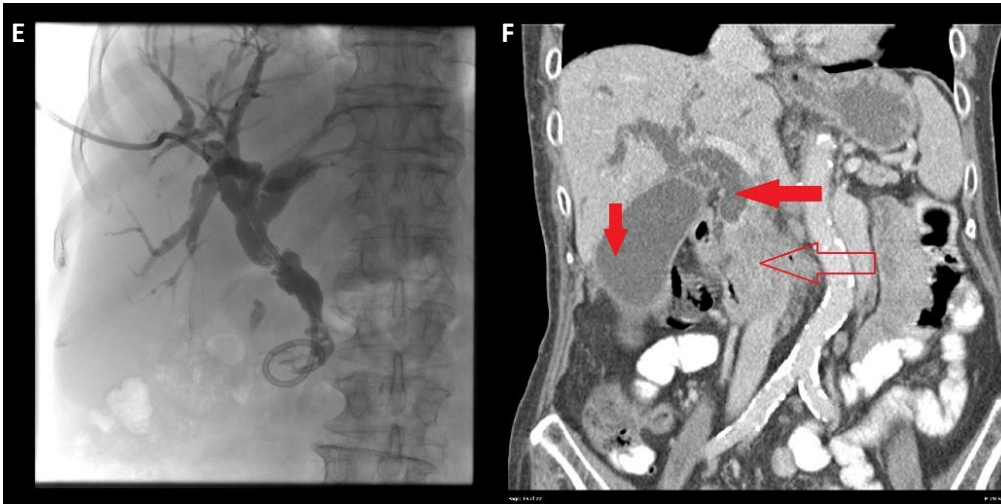
**Fig. B - Ultrasound** – hyperechoic stone with dorsal acoustic shadow in ductus choledochus, dilated ductus choledochus



**Fig. C - MRCP**

**Fig. D – fluoroscopy of biliary tree via ERCP**

In both images irregular diameter and multiple stenoses of bile ducts.



**Fig. E - PTC** – Dilated bile ducts, percutaneous drain from the right side through the stenosis of common bile duct to duodenum (ending in duodenum creates „pigtail“)

**Fig. F – Contrast enhanced CT** (portal phase, coronal plane): **transparent arrow** inhomogeneous tumor of the pancreas, **horizontal red arrow** – dilated bile ducts above the stenosis, **vertical red arrow** – hydrops of gallbladder