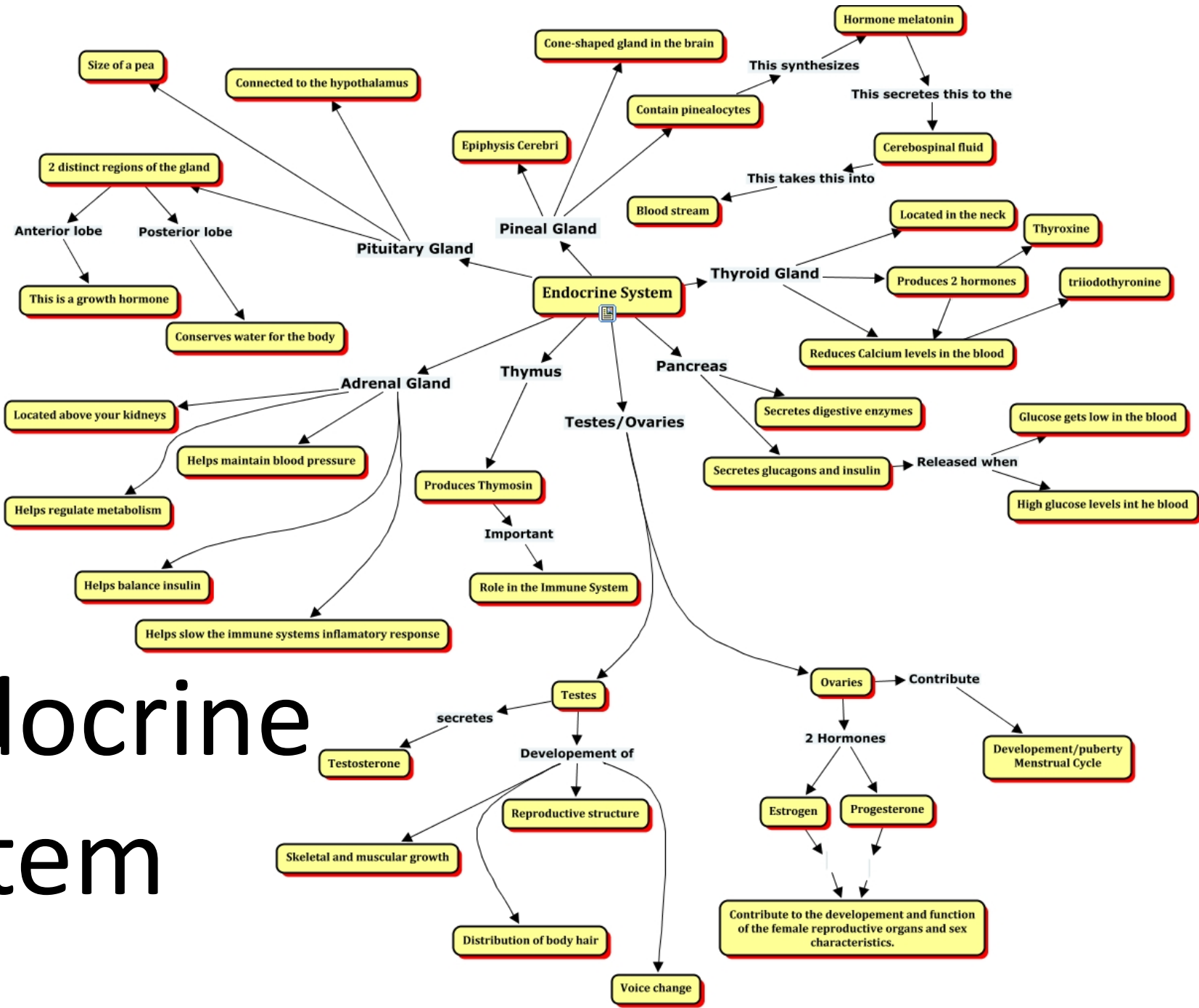
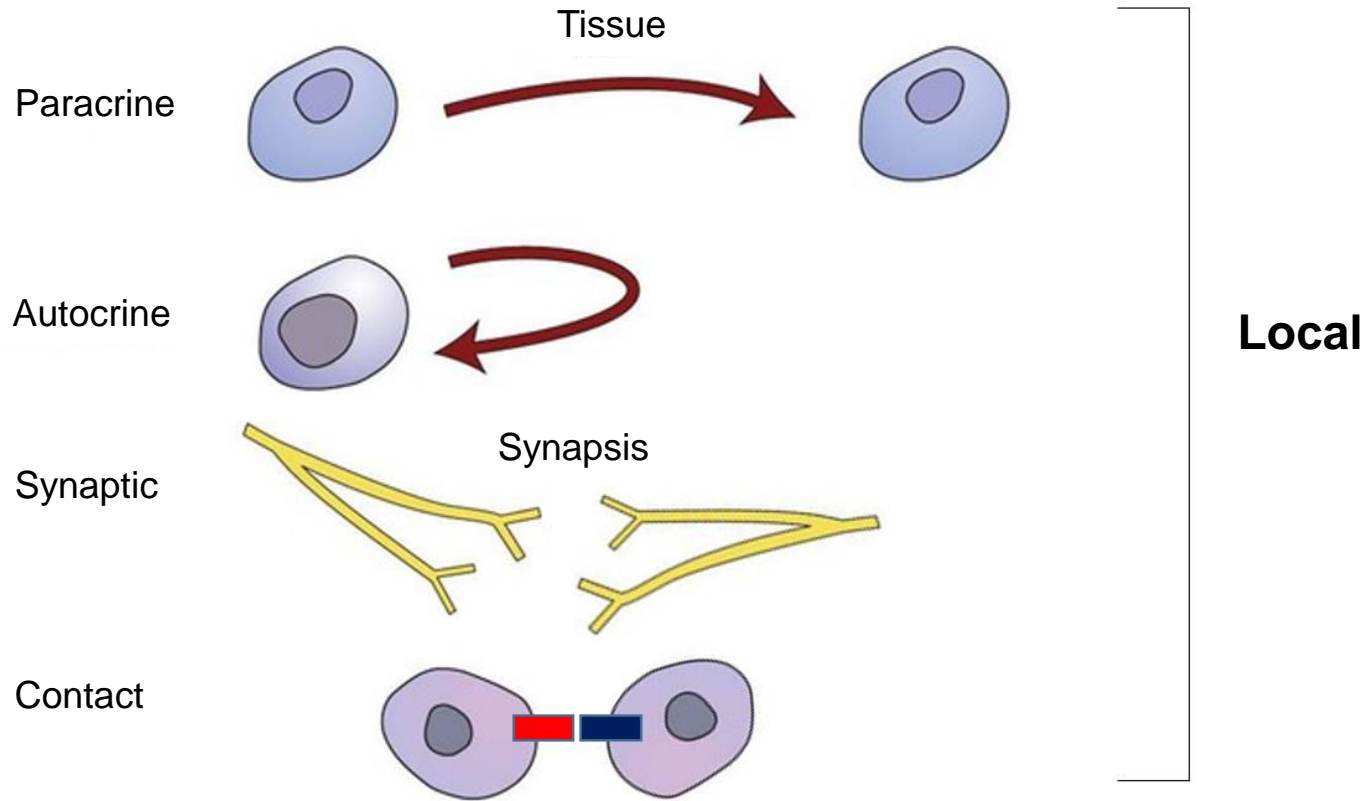


# Endocrine system

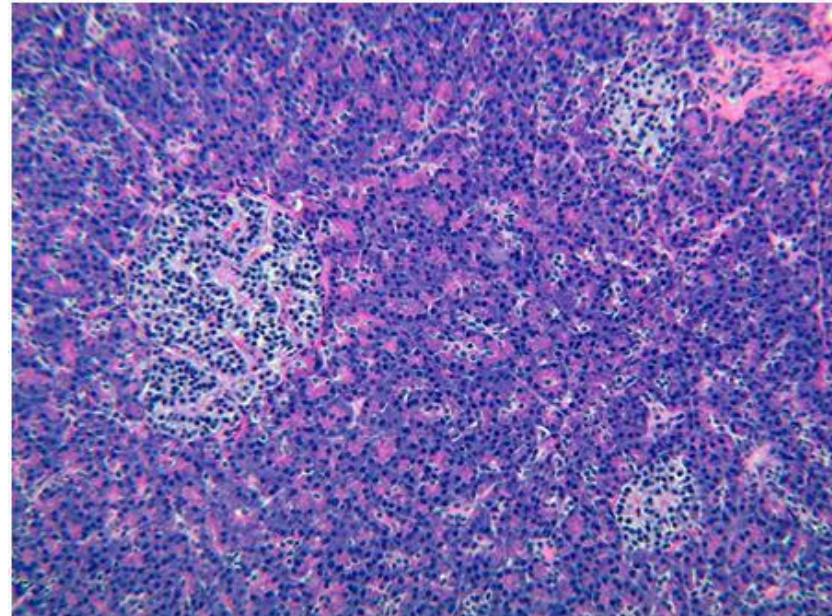
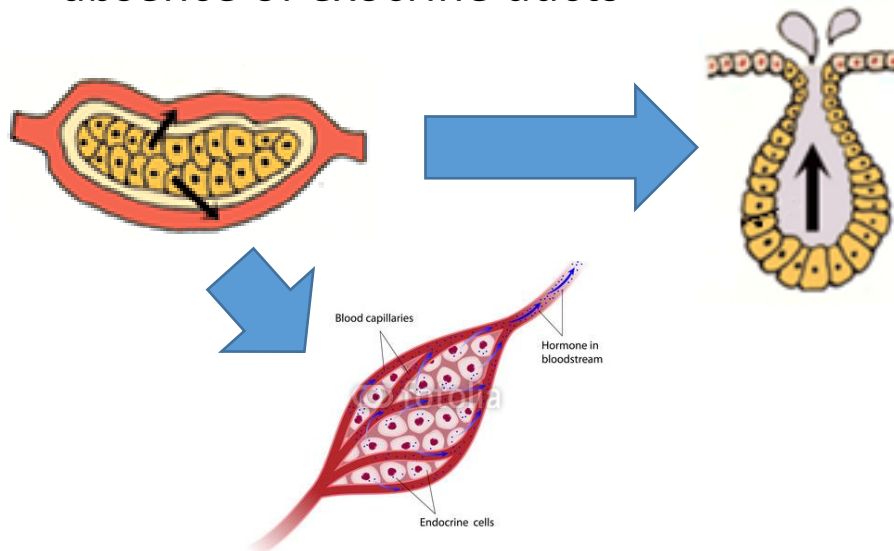


# INTERCELLULAR COMMUNICATIONS



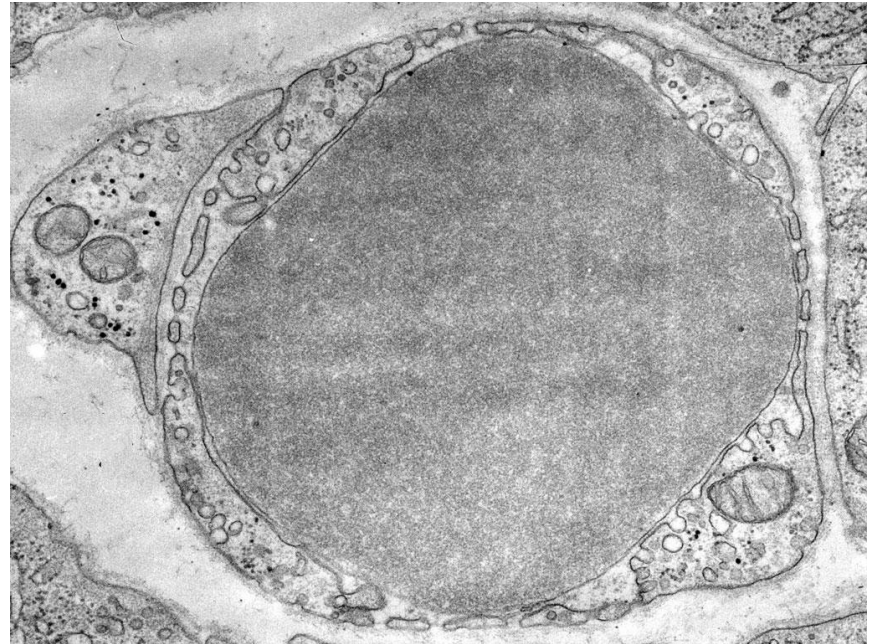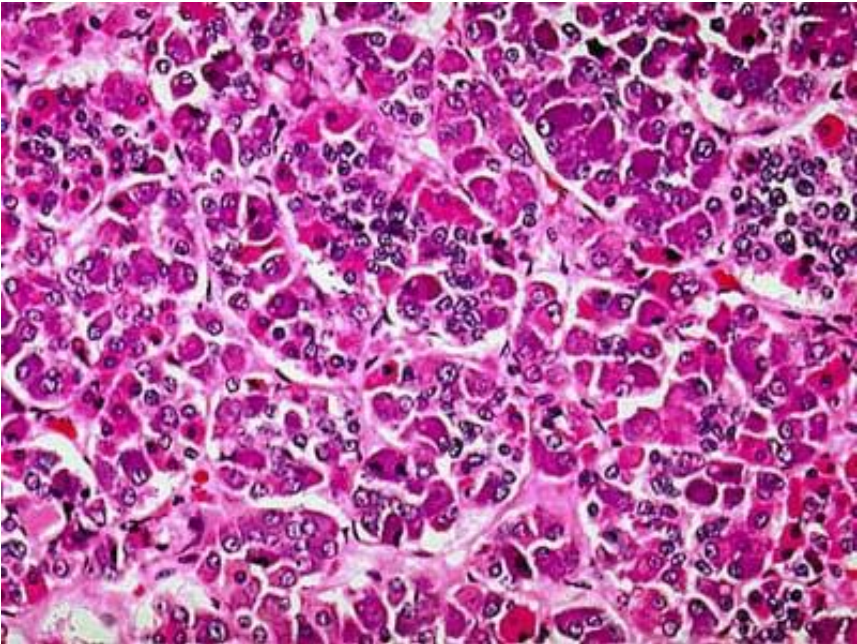
# GENERAL PROPERTIES OF ENDOCRINE ORGANS

- **Endocrine organs** (e.g. pituitary, thyroid, parathyroid, adrenal)
- **Endocrine tissue within other organs**  
(pancreas, gonads, kidneys, placenta)
- **Isolated endocrine cells** (DNES, APUD)
- **Neuroendocrine cells**
- **Common developmental scheme**
  - invagination of epithelial layer
  - contact with original tissue lost during development
  - absence of exocrine ducts



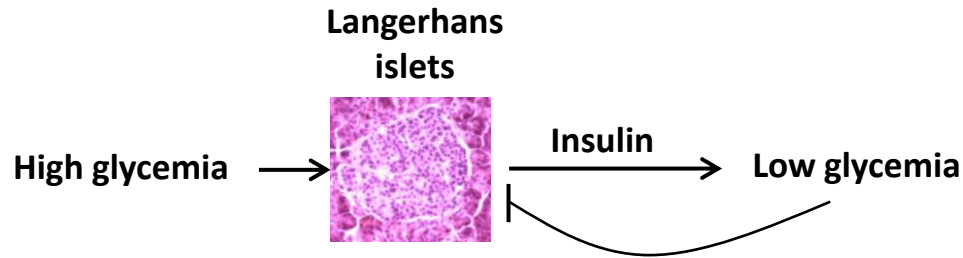
# GENERAL PROPERTIES OF ENDOCRINE ORGANS

- C.t. capsule + septs
- **Trabecules** of glandular epithelium or **follicles** or **clusters** of glandular cells
- **Capillary network**
  - Fenestrated capillaries
  - Sinusoids

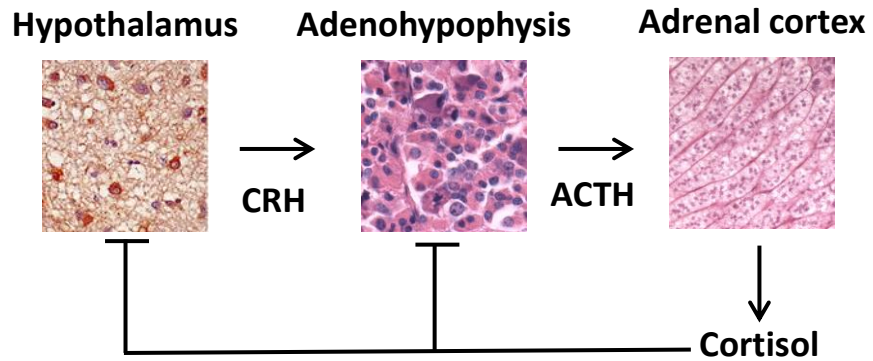


# REGULATION OF HORMONE SECRETION

## 1. Negative feedback by change of metabolic state

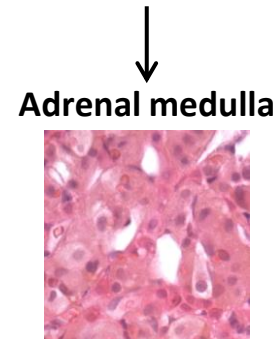


## 2. Negative feedback by increased concentration of secreted hormone



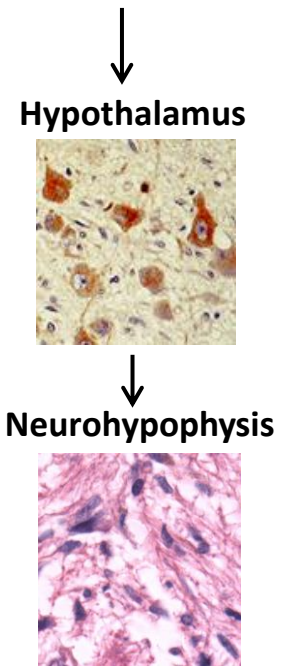
## 3. Nerve system – direct innervation

CNS (sympathicus)



Adrenalin

CNS



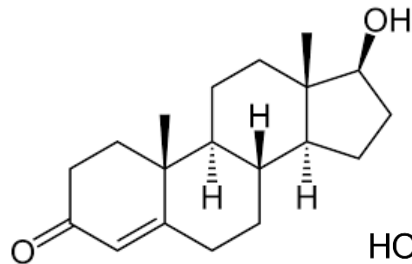
ADH

# GENERAL PROPERTIES OF HORMONES

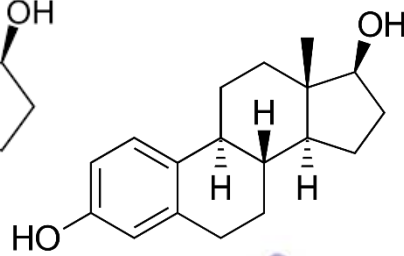
- hormones are chemical messengers delivered by bloodstream to target cells and tissues
- chemical nature of hormone determines its function
  
- classification
  - **water soluble**
  - **water insoluble**
  
  - **surface receptors**
  - **nuclear receptors**

# GENERAL PROPERTIES OF HORMONES

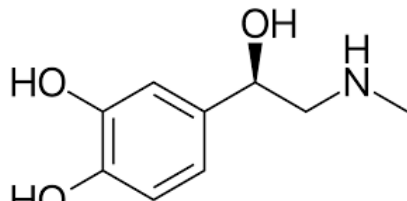
- **steroids** – hydrophobic, intracytoplasmic or nuclear receptors (sex hormones, corticosteroids)
- **proteins and polypeptides** – hydrophilic, plasma membrane receptors (insulin, pituitary hormones, PTH, ...)
- **aminoacids** and their amine derivatives (adrenalin, noradrenalin, thyroxin)



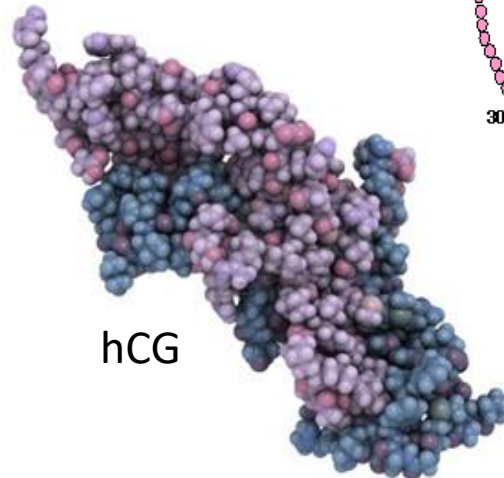
Testosterone



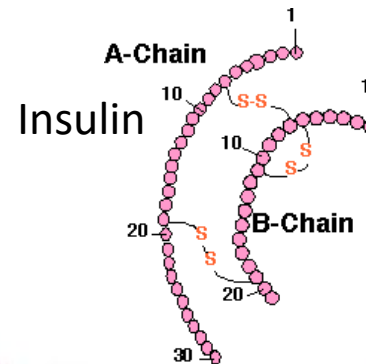
Estradiol



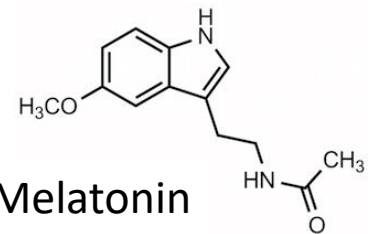Adrenalin



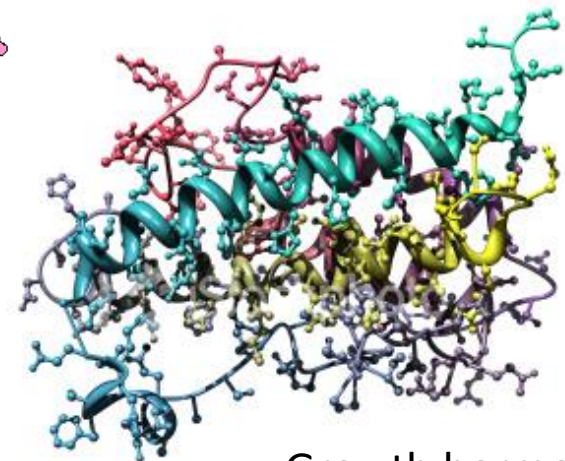
hCG



Insulin

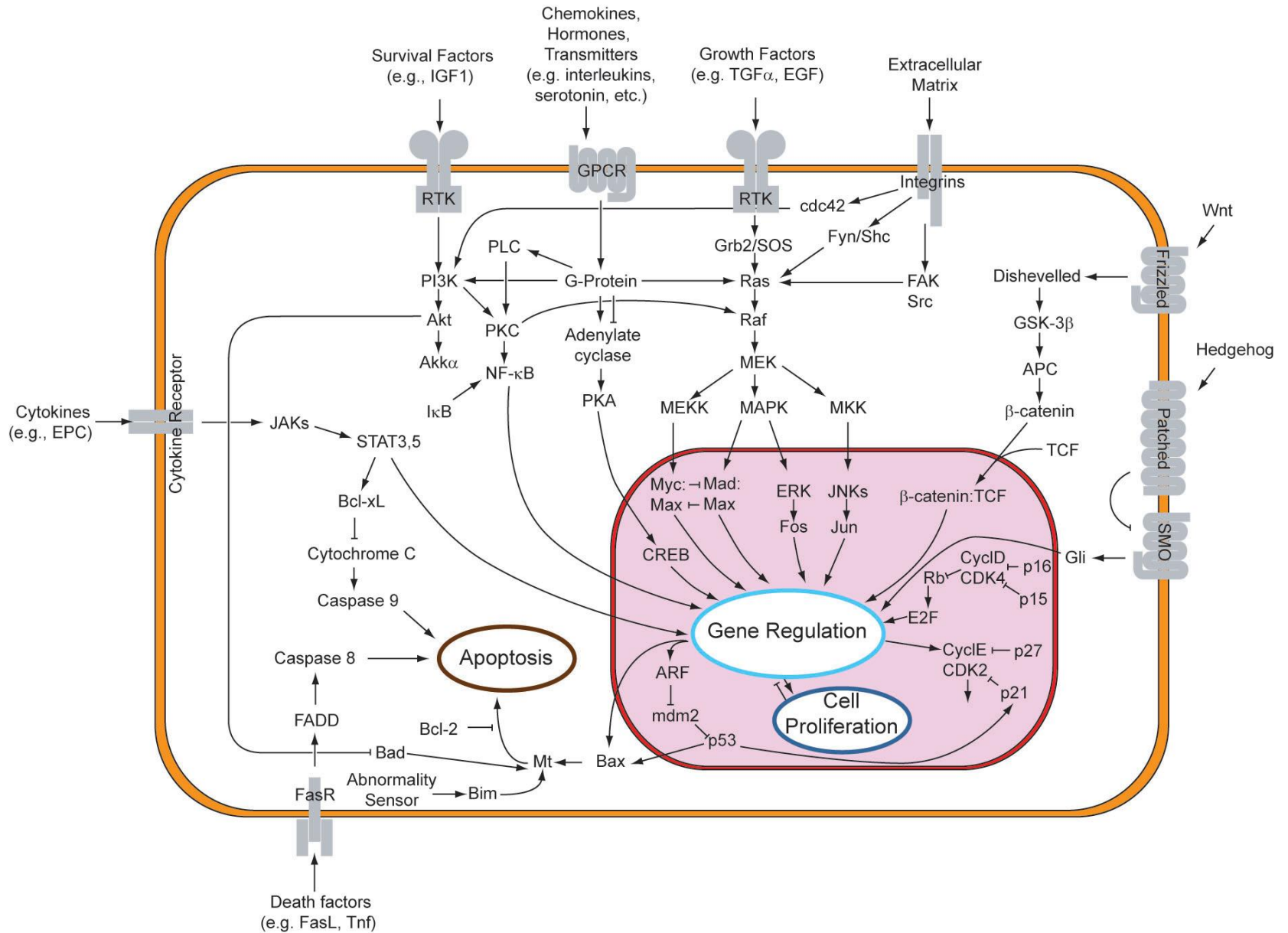


Melatonin



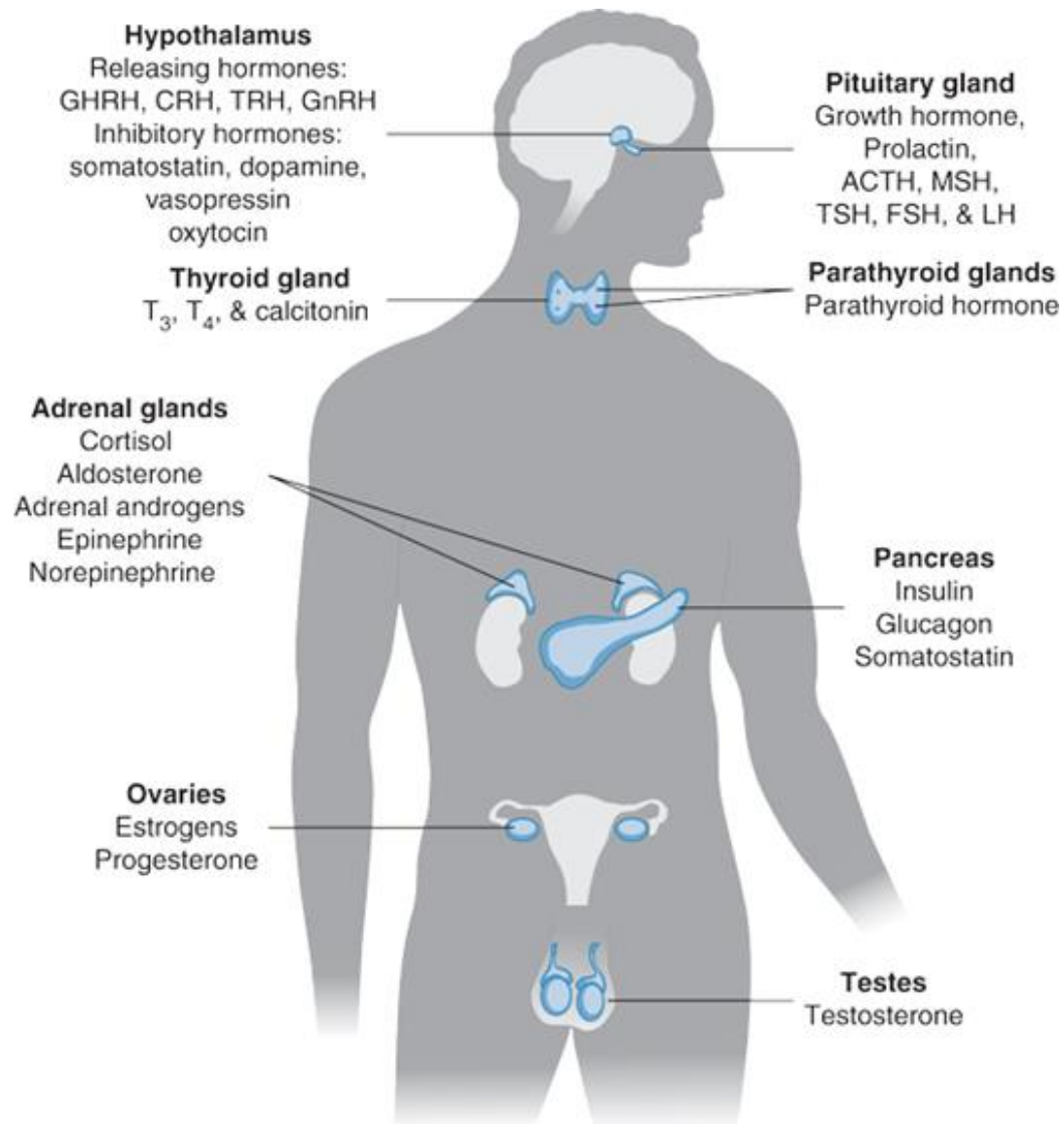
Growth hormone

# GENERAL PROPERTIES OF HORMONES

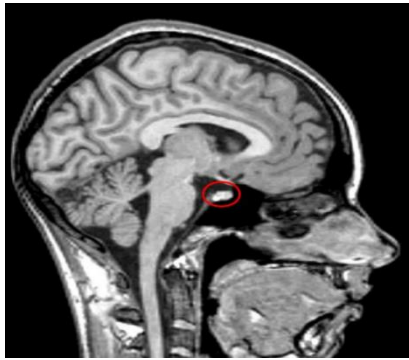



# ENDOCRINE GLANDS



# PITUITARY GLAND (GL. PITUITARIA)



Corpus callosum

Hypothalamus

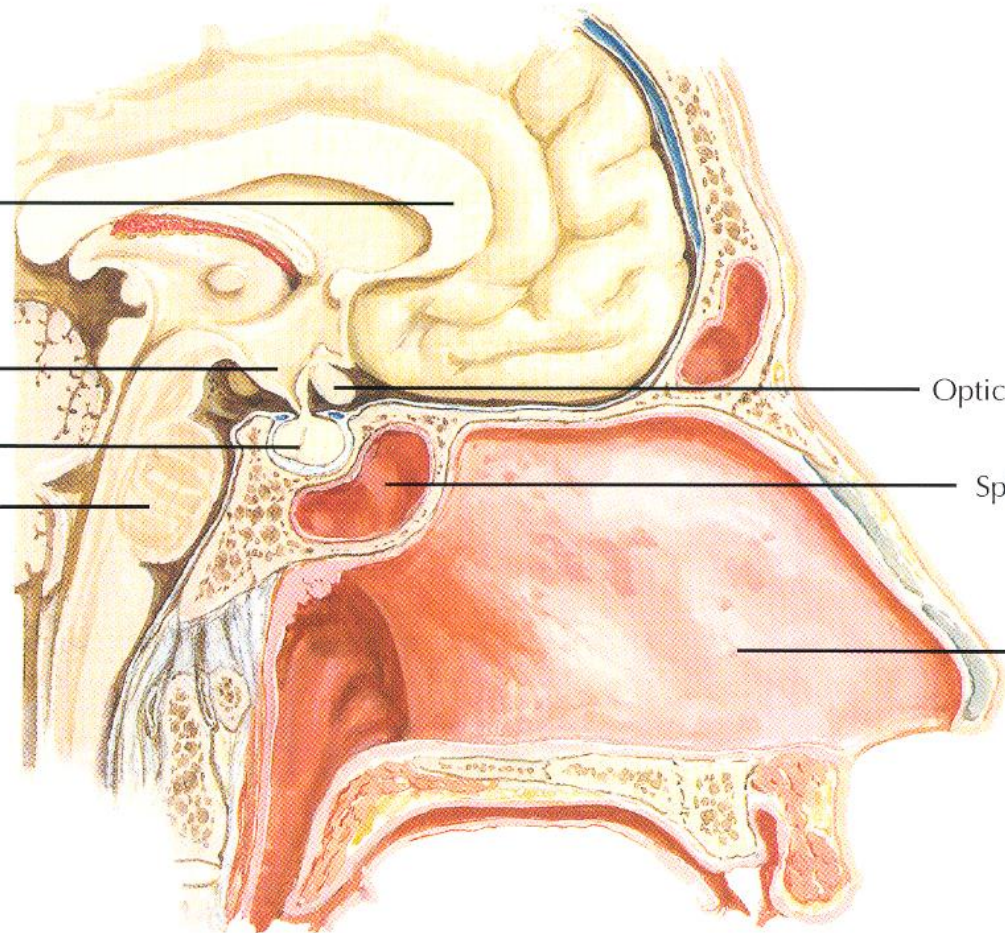
Pituitary gland

Brainstem (pons)

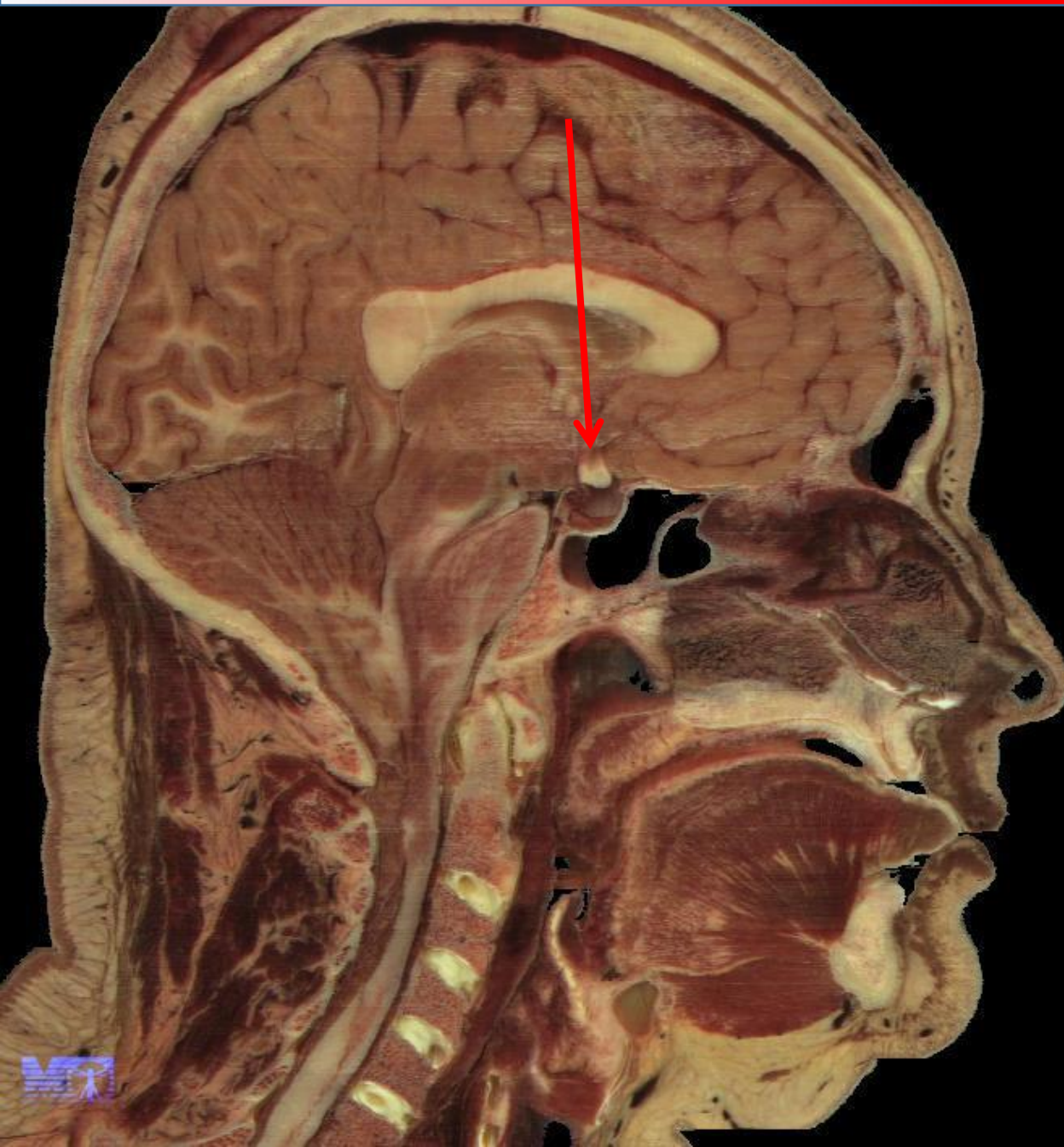
Optic chiasm

Sphenoid sinus

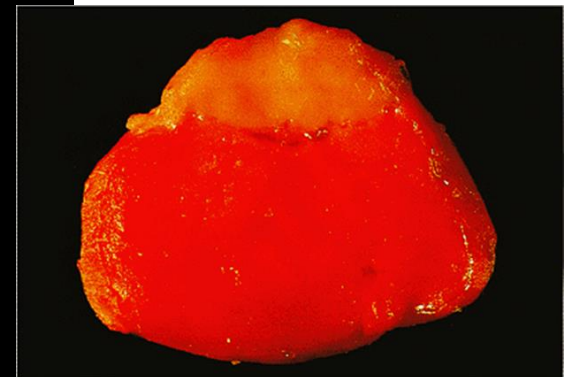
Nasal septum



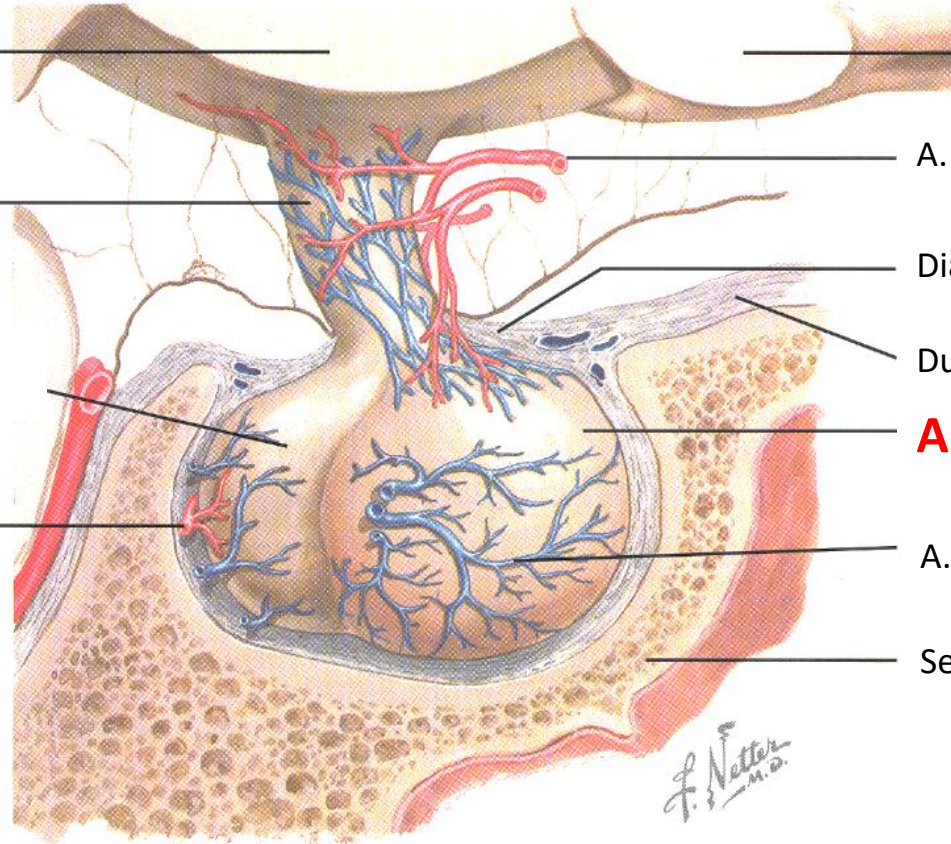
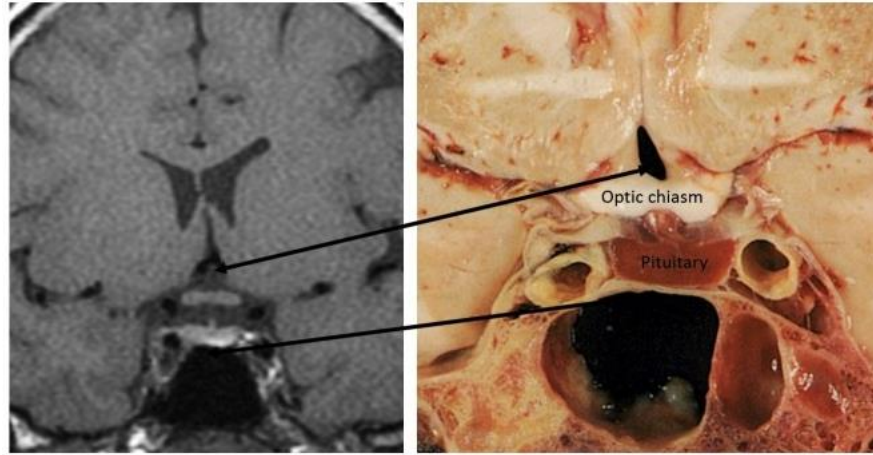
# PITUITARY GLAND (GL. PITUITARIA)



- hypothalamus
- sella turcica
- fossa hypophysialis
- optic chiasm



# PITUITARY (GL. PITUITARIA)



Chiasma opticum

A. hypophysialis sup.

Diaphragma sellae

Dura mater

**ANTERIOR LOBE**

A. hypophysialis inf.

Sella turcica of sphenoid bone

*F. Netter M.D.*

**HYPOTHALAMUS**

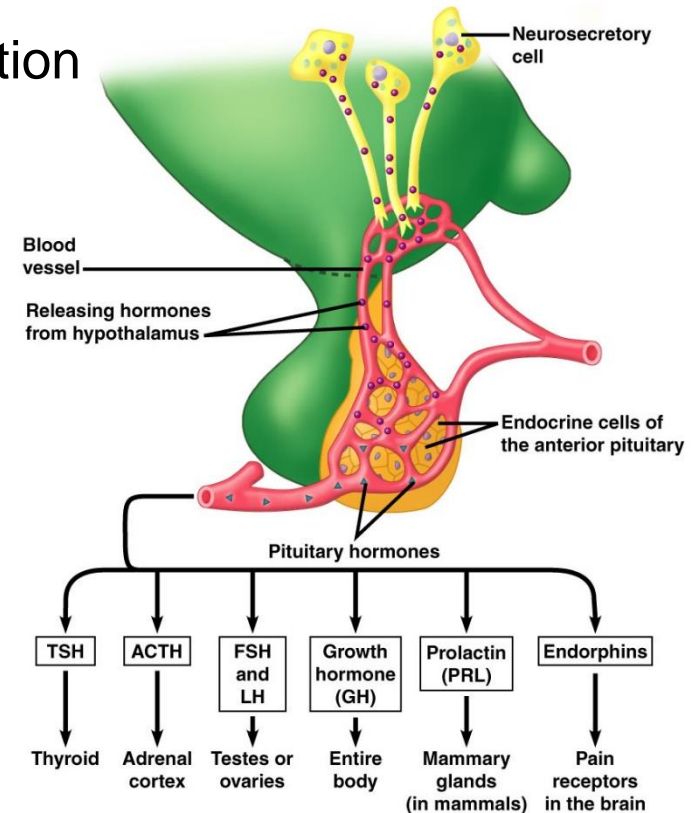
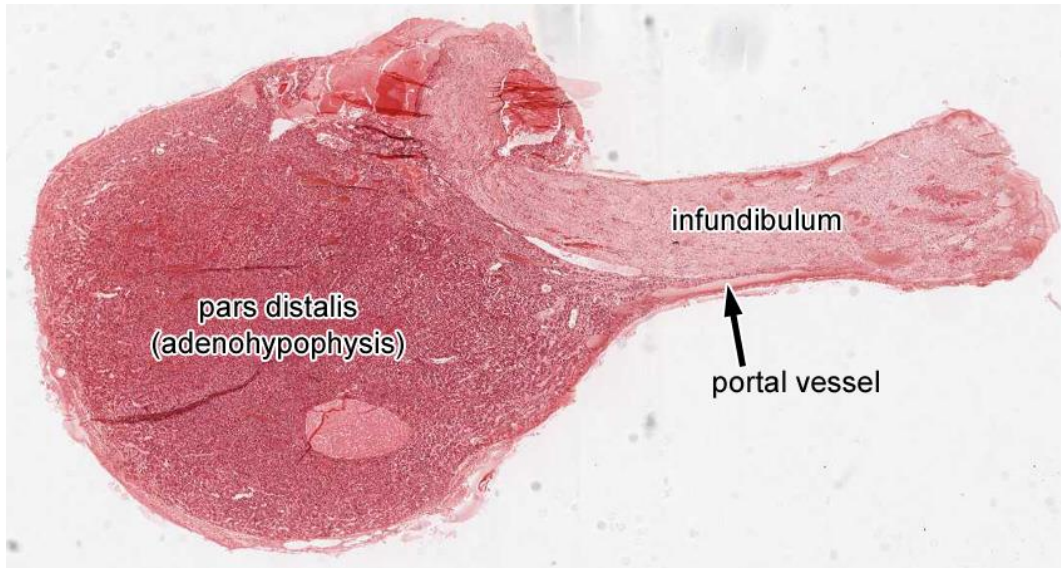
INFUNDIBULUM

**POSTERIOR LOBE**

A. hypophysialis inf.

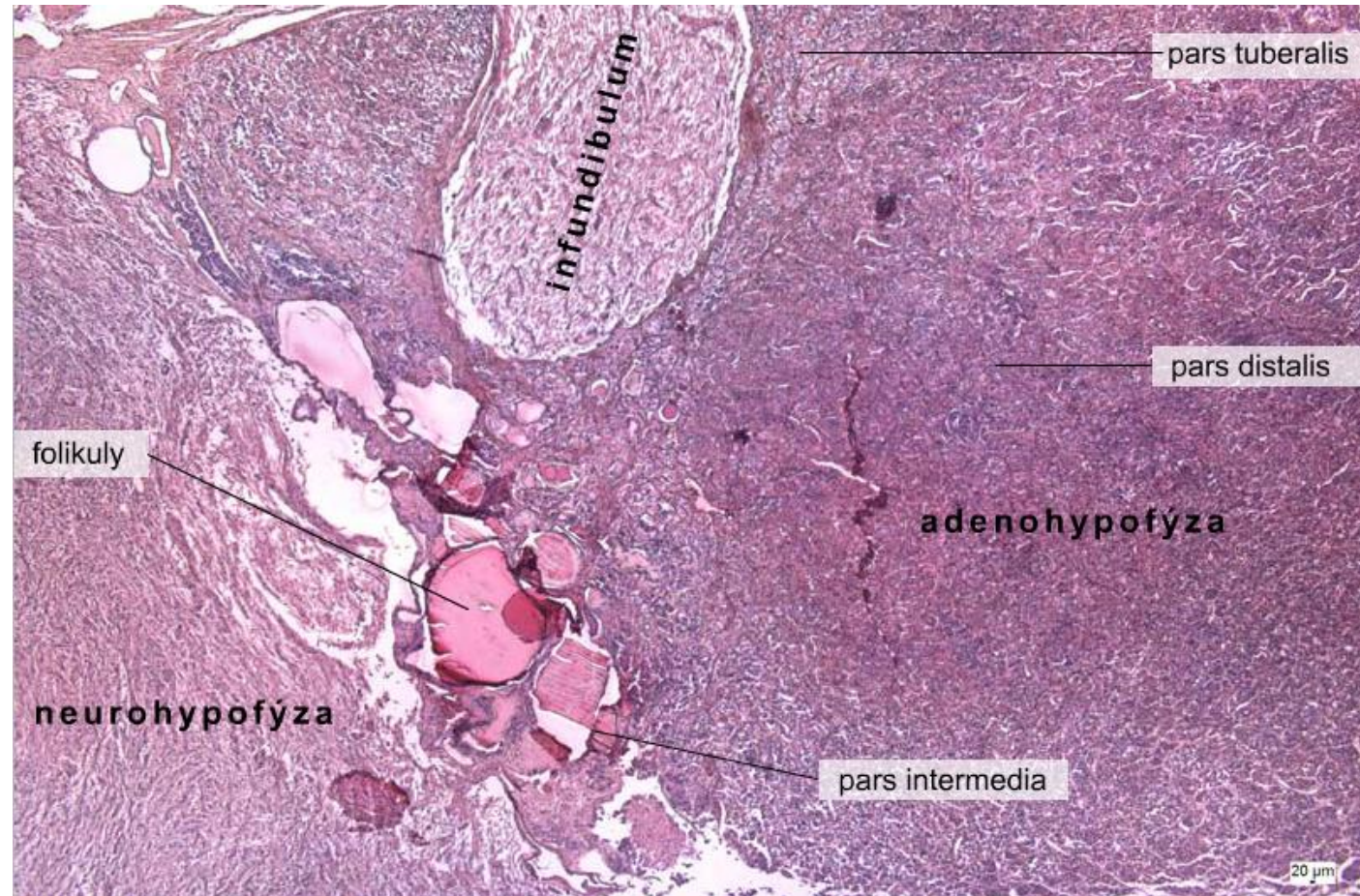
# PITUITARY GLAND (GL. PITUITARIA)

- adenohypophysis - glandotropic hormones, prolactin, GH
- neurohypophysis - hypothalamic hormones - ADH, oxytocin
- anatomical and functional association with hypothalamus
- capillary systems and neuroendocrine secretion

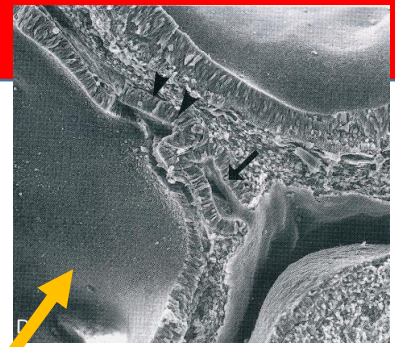

# PITUITARY GLAND (GL. PITUITARIA)

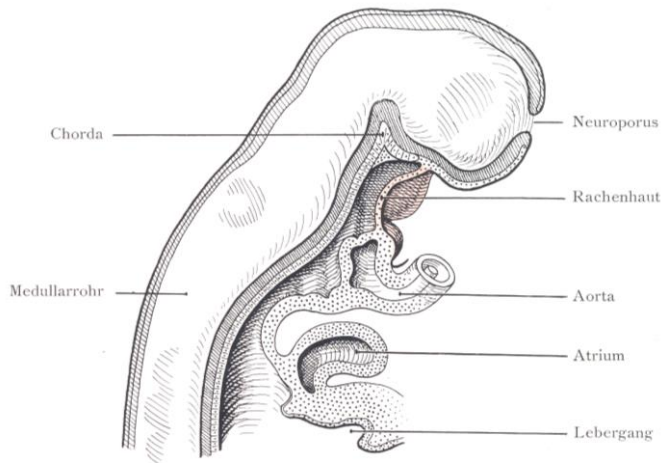
- adenohypophysis (*pars distalis, pars tuberalis, pars intermedia*)
- neurohypophysis (*pars nervosa*)
- *infundibulum, eminentia mediana*



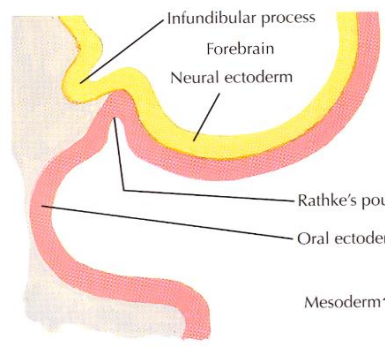
# EMBRYONIC DEVELOPMENT OF PITUITARY GLAND



- Ectoderm of stomodeum (Rathke's pouch)
- Neuroectoderm of ventral wall of diencephalon

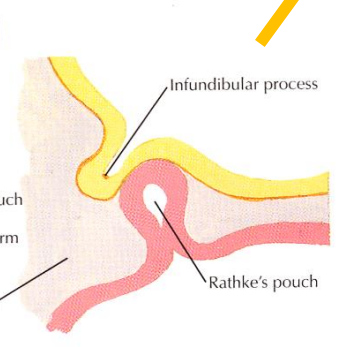


~ week 3



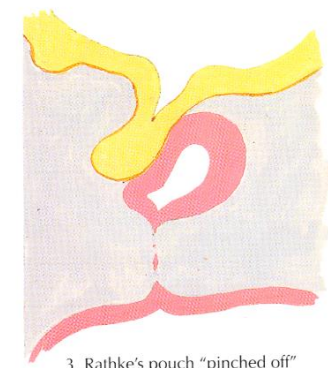
1. Beginning formation of Rathke's pouch and infundibular process

~ week 6

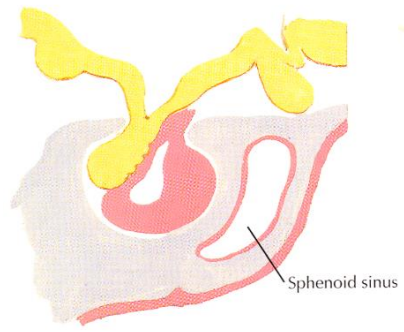
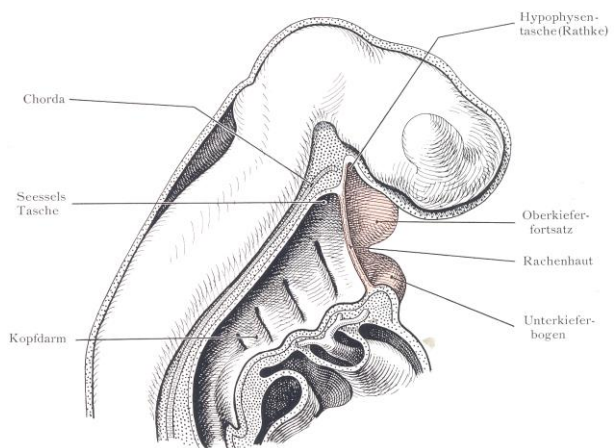


2. Neck of Rathke's pouch constricted by growth of mesoderm

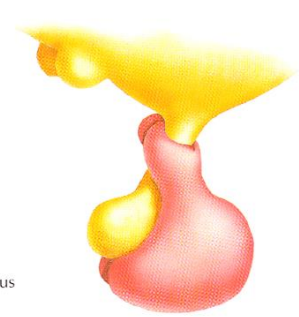
~ week 8



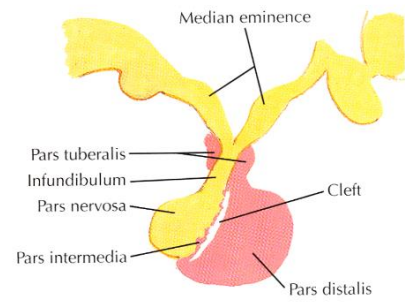
3. Rathke's pouch "pinched off"



4. "Pinched off" segment conforms to neural process, forming pars distalis, pars intermedia and pars tuberalis



5. Pars tuberalis encircles infundibular stalk (lateral surface view)



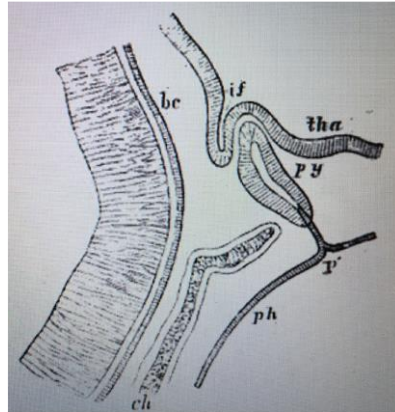
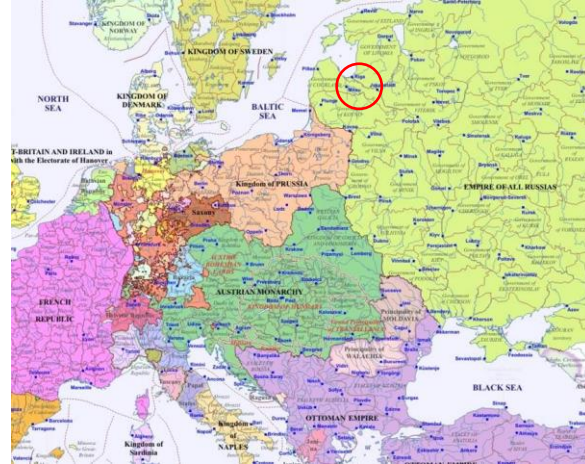6. Mature form

~ week 11

~ week 16

*F. Netter M.D.*

# MARTIN HEINRICH RATHKE (1793 – 1860)



## Ueber die Entstehung der Glandula pituitaria.

Von  
HEINRICH RATHKE.

Schon längst bemerkte ich bei mehreren Thieren in einer sehr frühen Zeit des Fruchtlebens, bei Säugethieren namentlich geraume Zeit früher, als sich der Gaumen bildet, ganz hinten in der Mundhöhle, unterhalb der Grundfläche des Schädels eine kleine unregelmässig rundliche Vertiefung, die der Schleimhaut des Mundes angehörte und offenbar eine dünnwandige Aussackung derselben war. Lange aber wusste ich sie nicht zu deuten, zumal da ich sie bei älteren Embryonen, wenn ich die Mundhöhle untersuchte, nicht mehr wiederfand. Endlich ward ich gewahrt, dass diese Vertiefung den ersten Schritt zur Bildung des Hirnanhanges (Gland. pituitaria) bezeichnet.

Bevor ich nun aber das weitere Verhalten derselben schildere, sehe ich mich genöthigt ein Paar Worte über den Schädel vorzuschicken. Der Stern von der Chorda dorsalis reicht, wie es allen Anschein hat, vielleicht bei allen Wirbelthieren nur bis zwischen die beiden Knorpelkapseln, welche bei den mit einem Knochenskelett versehenen Thieren zu den

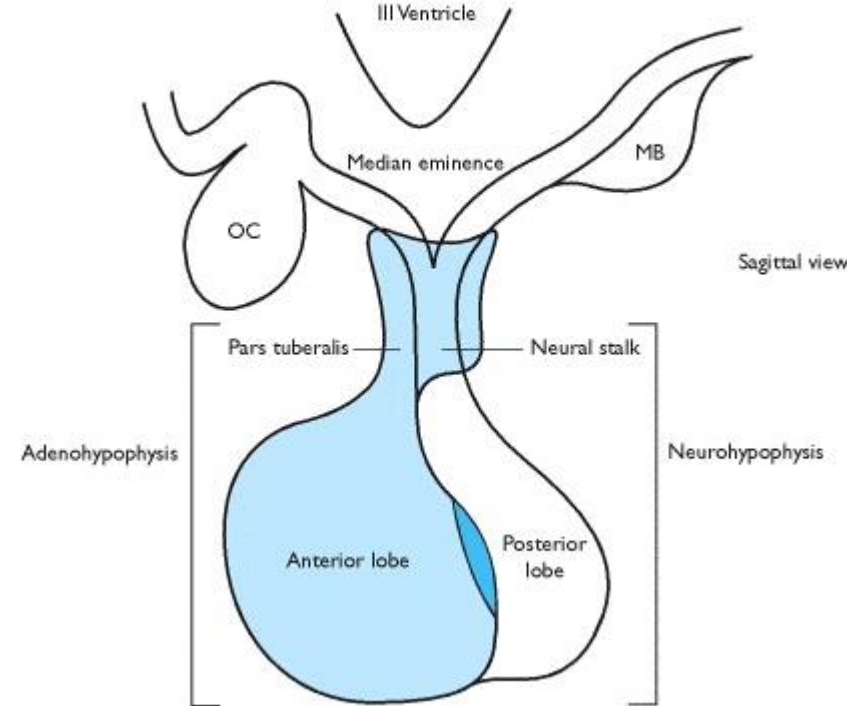
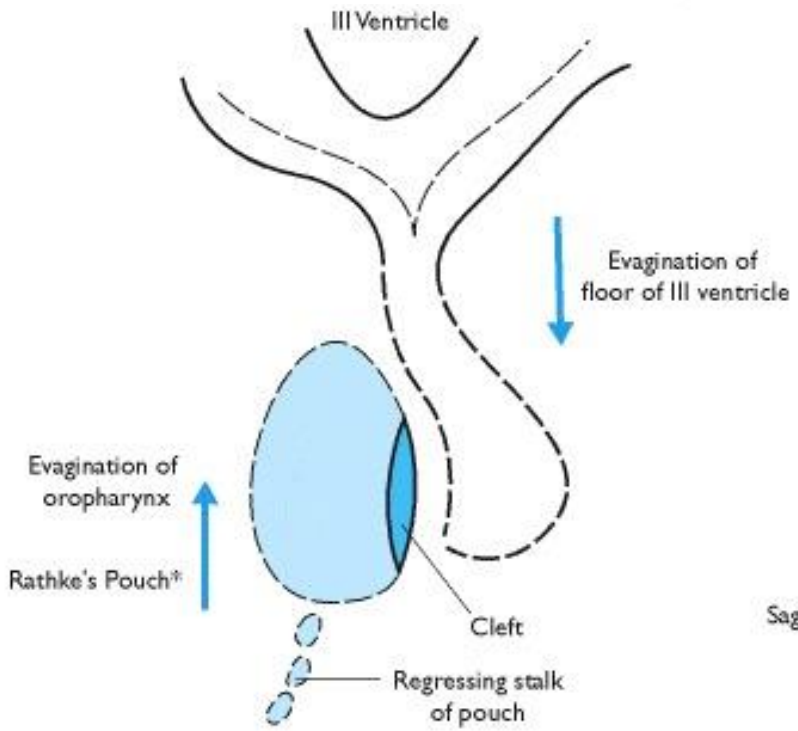
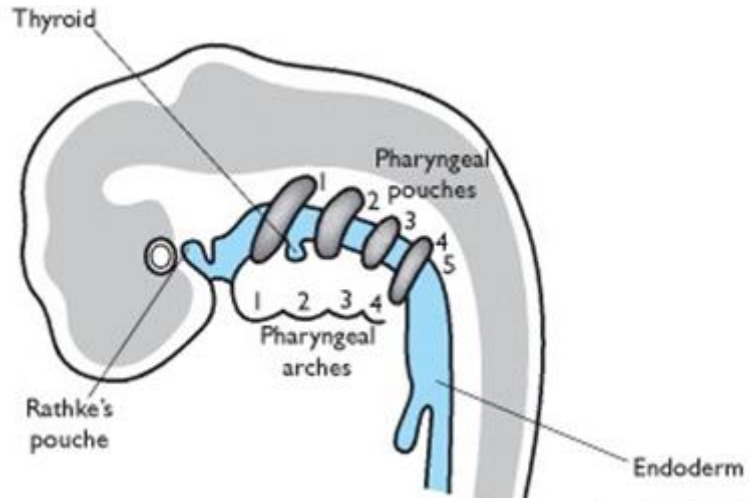
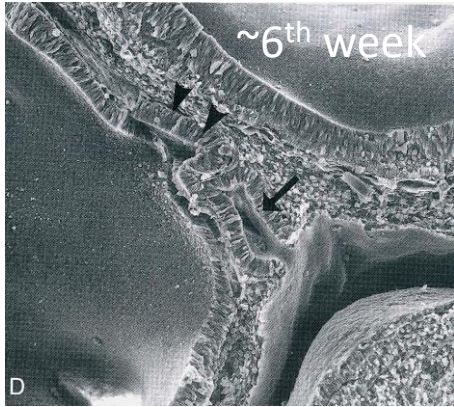
- Physician, anatomist, embryologist, zoologist
- One of founding fathers of modern embryology

"For a long time I have observed in several animals ... a small irregularly rounded depression which belongs to the mucous membrane of the mouth, of which it is clearly a thin-walled outpocketing. ... Finally I saw that this depression represents the first step in the formation of the pituitary gland" (p. 482).

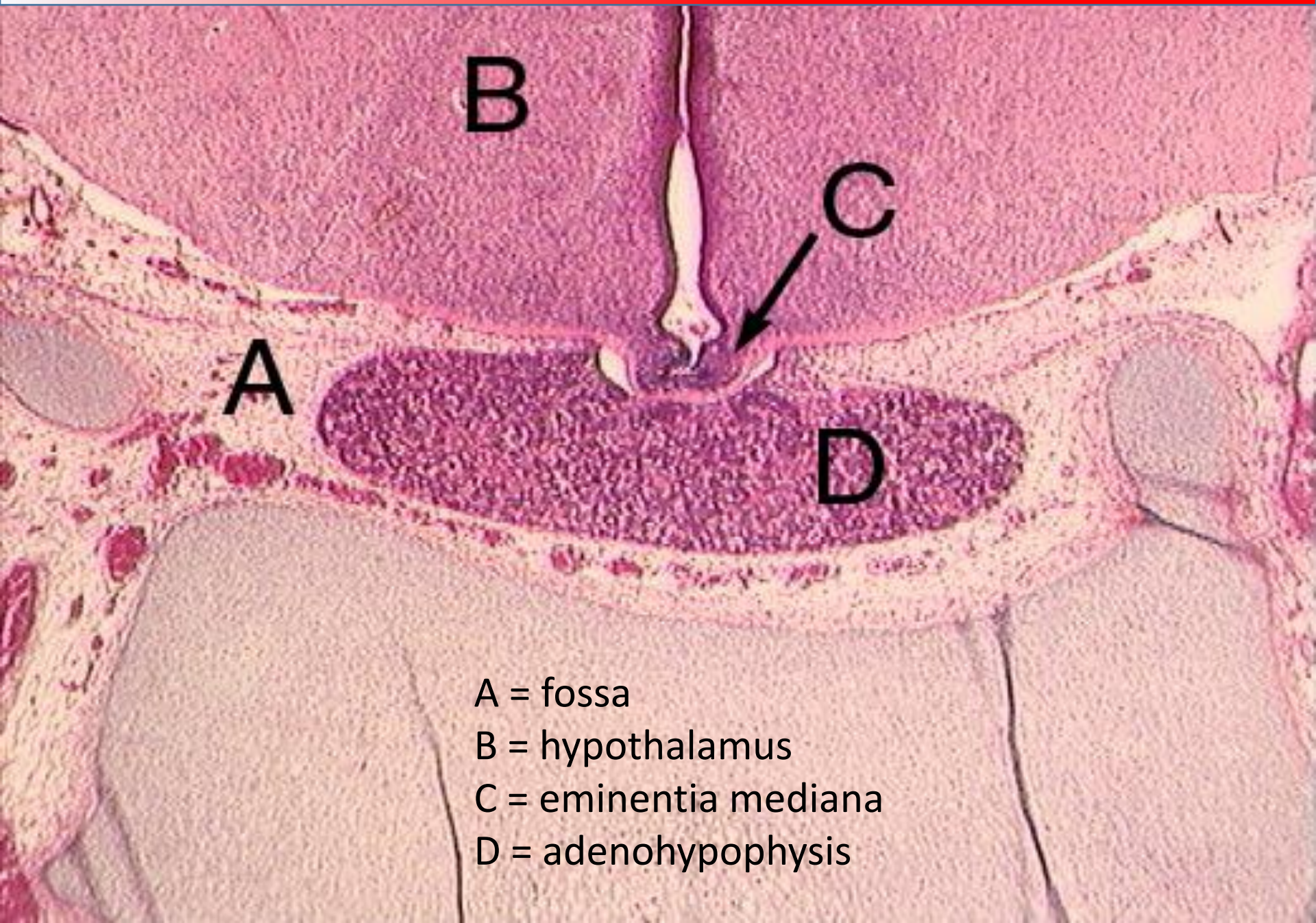
Rathke, H. : *Ueber die Entstehung der glandula pituitaria*. Arch, f. Anat., Phys. und wiss. Med. S. 482-85. **1838**



# EMBRYONIC DEVELOPMENT OF PITUITARY GLAND



# EMBRYONIC DEVELOPMENT OF PITUITARY GLAND



A = fossa

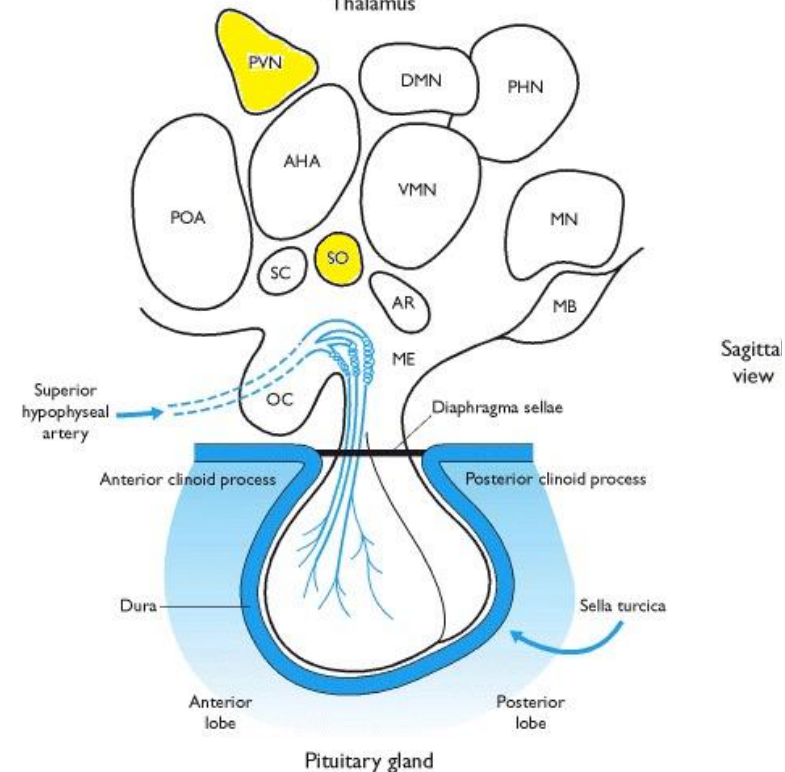
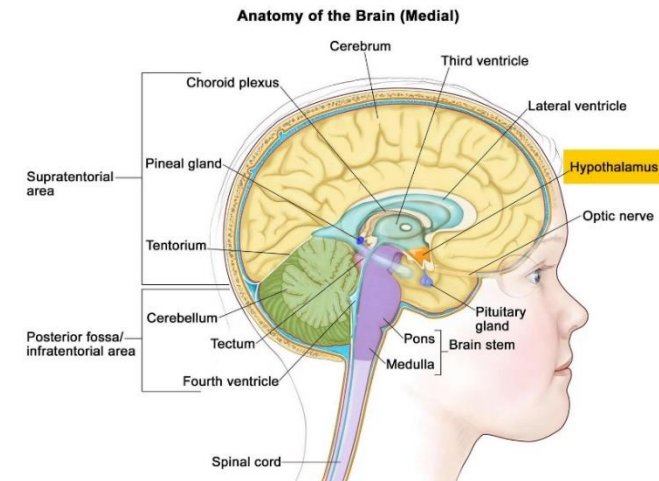
B = hypothalamus

C = eminentia mediana

D = adenohypophysis

# HYPOTHALAMUS

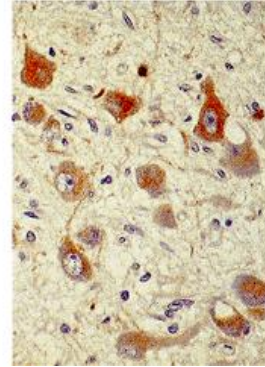
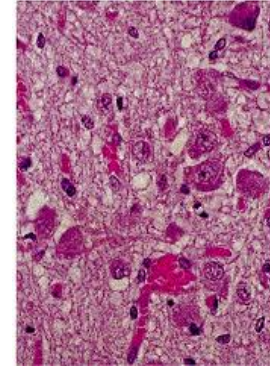
- small region of diencephalon
- complex neuroarchitecture
- core of the limbic system
- complex functions
- regulation of temperature, emotions, eating behavior, circadian rhythms
- hormonal regulation controlled by various stimuli (osmoreception, concentration of nutrients, electrolytes, systemic functions - pain)
- **neurosecretion from hypothalamic nuclei**
  - *n. supraopticus, n. paraventricularis*
  - magnocellular neurons - **tractus hypothalamo-hypophysialis** - **oxytocin and ADH through neurohypophysis**
  - parvocellular neurons - capillaries in *eminentia mediana* - **statins and liberins regulating secretion from adenohypophysis through hypothalamo-hypophyseal portal system**



# MECHANISM OF NEUROSECRETION

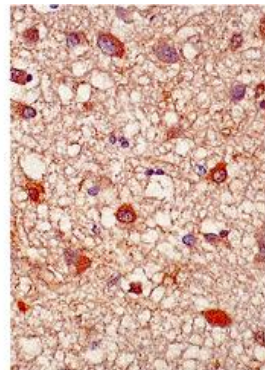
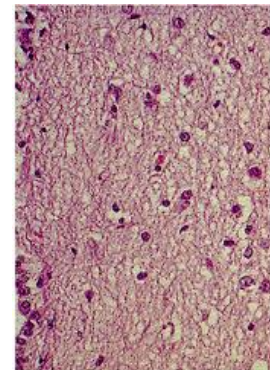
## Tractus hypothalamo-hypophysialis

- axons of magnocellular neurons in *nucleus supraopticus* and *paraventricularis*
- terminating on fenestrated capillaries in neurohypophysis
- synthesis of prohormones → maturation during axonal transport
- capillary plexus from *arteria hypophysialis inferior* (branch of *a. carotis interna* → *sinus cavernosus*)



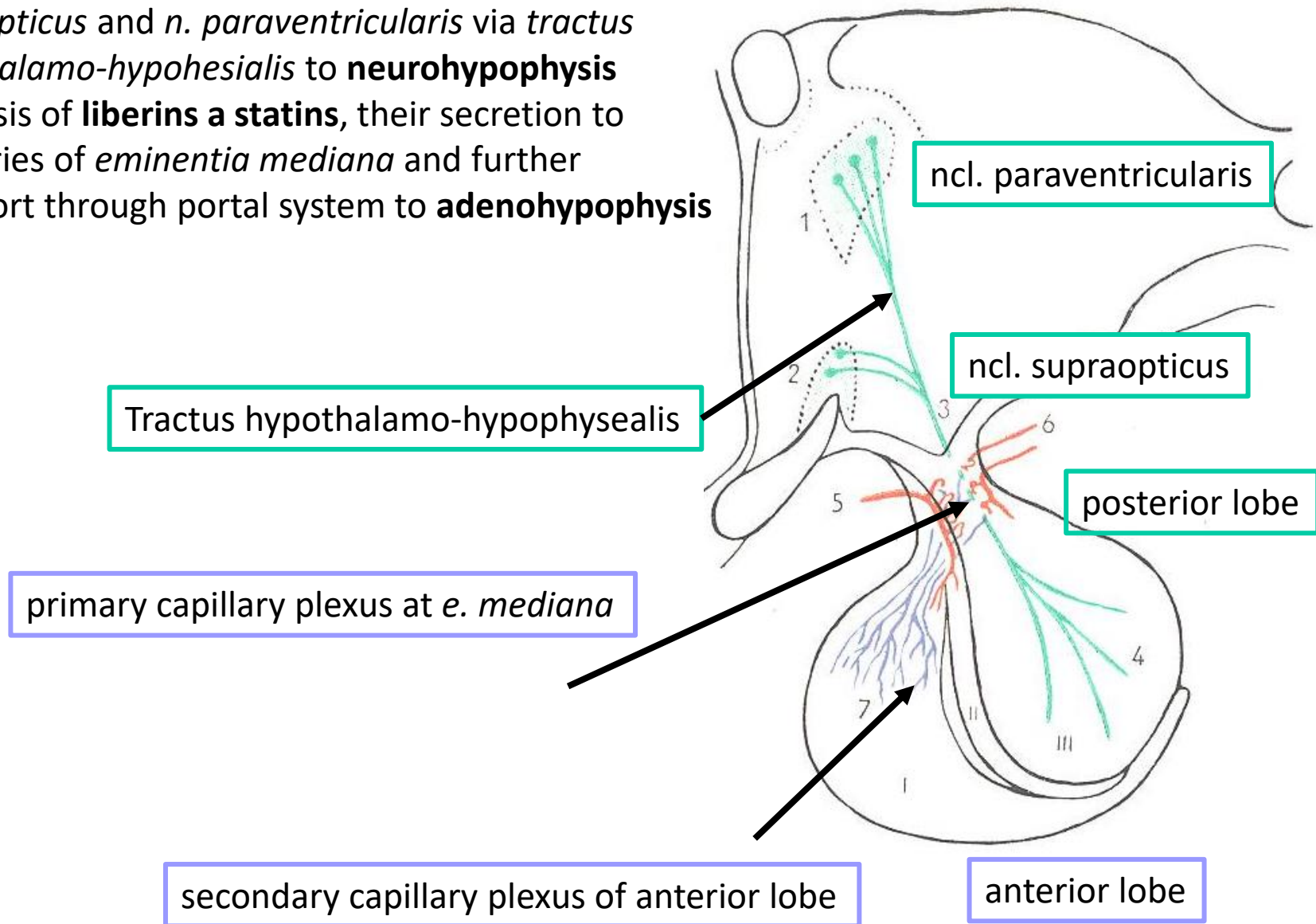
## Hypophyseal portal system

- parvocellular neurons e.g. in *nucleus arcuatus*, *preopticus*, *paraventricularis* and *nuclei tuberales*
- axonal transport onto primary capillary plexus in ***eminetia mediana*** (from anterior and posterior superior hypophyseal arteries) → hypophyseal portal veins → secondary capillary plexus in adenohypophysis → inferior hypophyseal portal veins → *vv. jugulares internae*

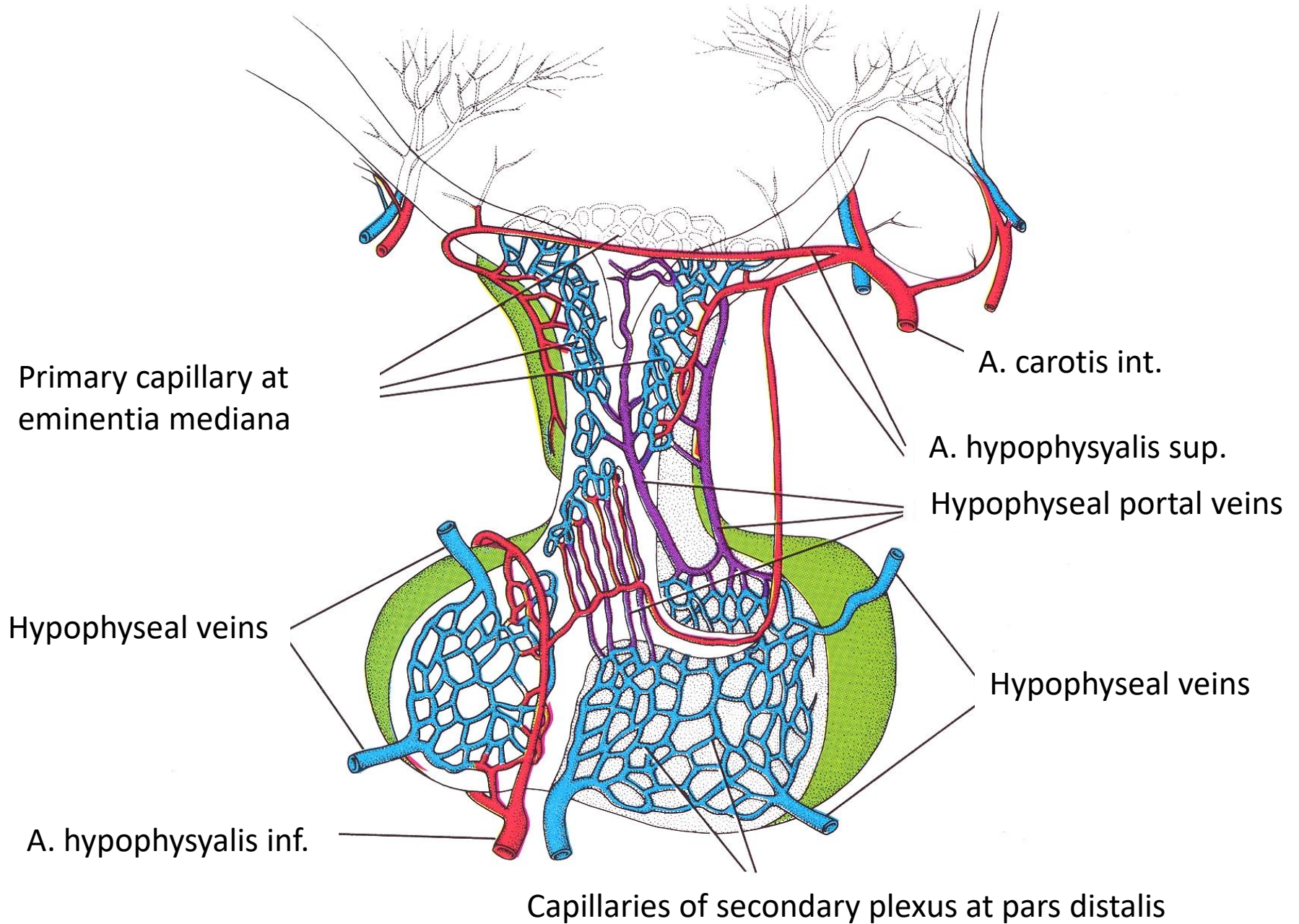


# MECHANISM OF NEUROSECRETION

- synthesis and transport of **effector hormones** from *n. supraopticus* and *n. paraventricularis* via *tractus hypothalamo-hypohesialis* to **neurohypophysis**
- synthesis of **liberins a statins**, their secretion to capillaries of *eminentia mediana* and further transport through portal system to **adenohypophysis**

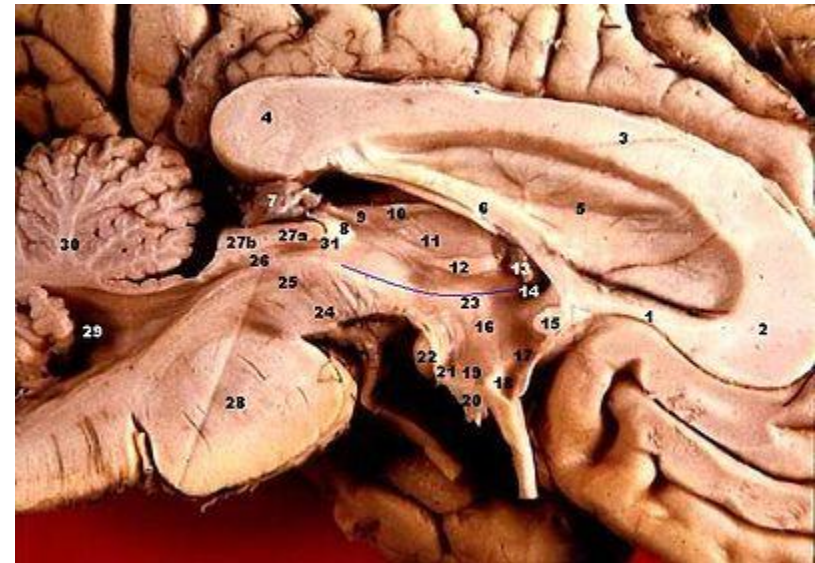
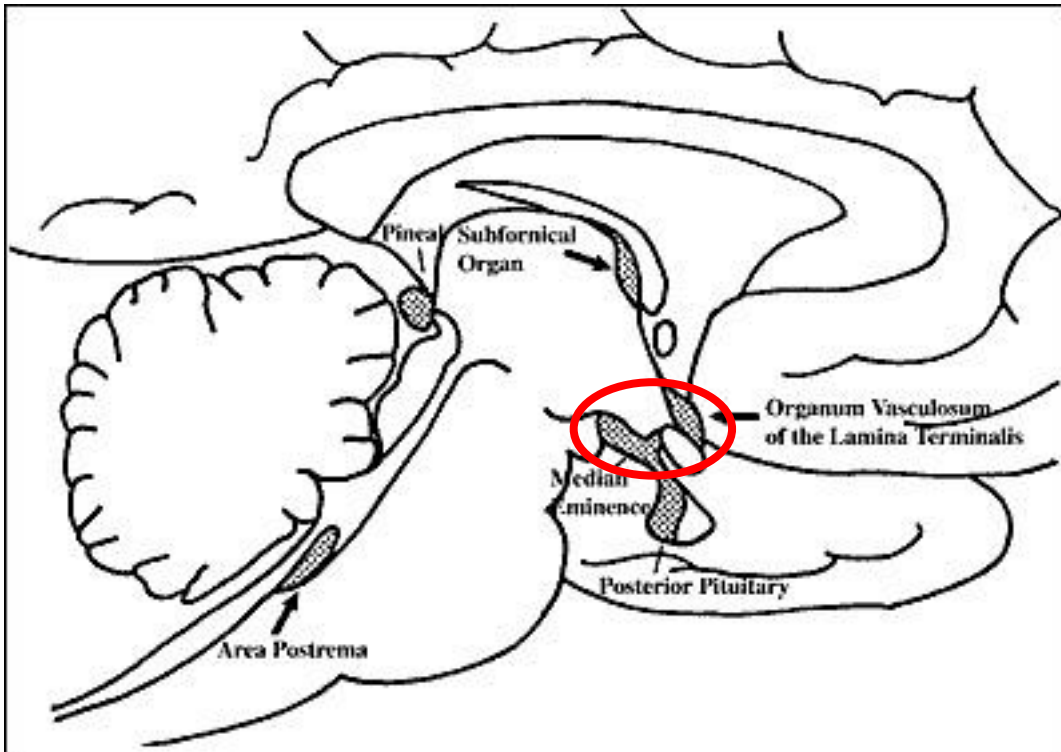


# CAPILLARY SYSTEMS OF HYPOPHYSIS



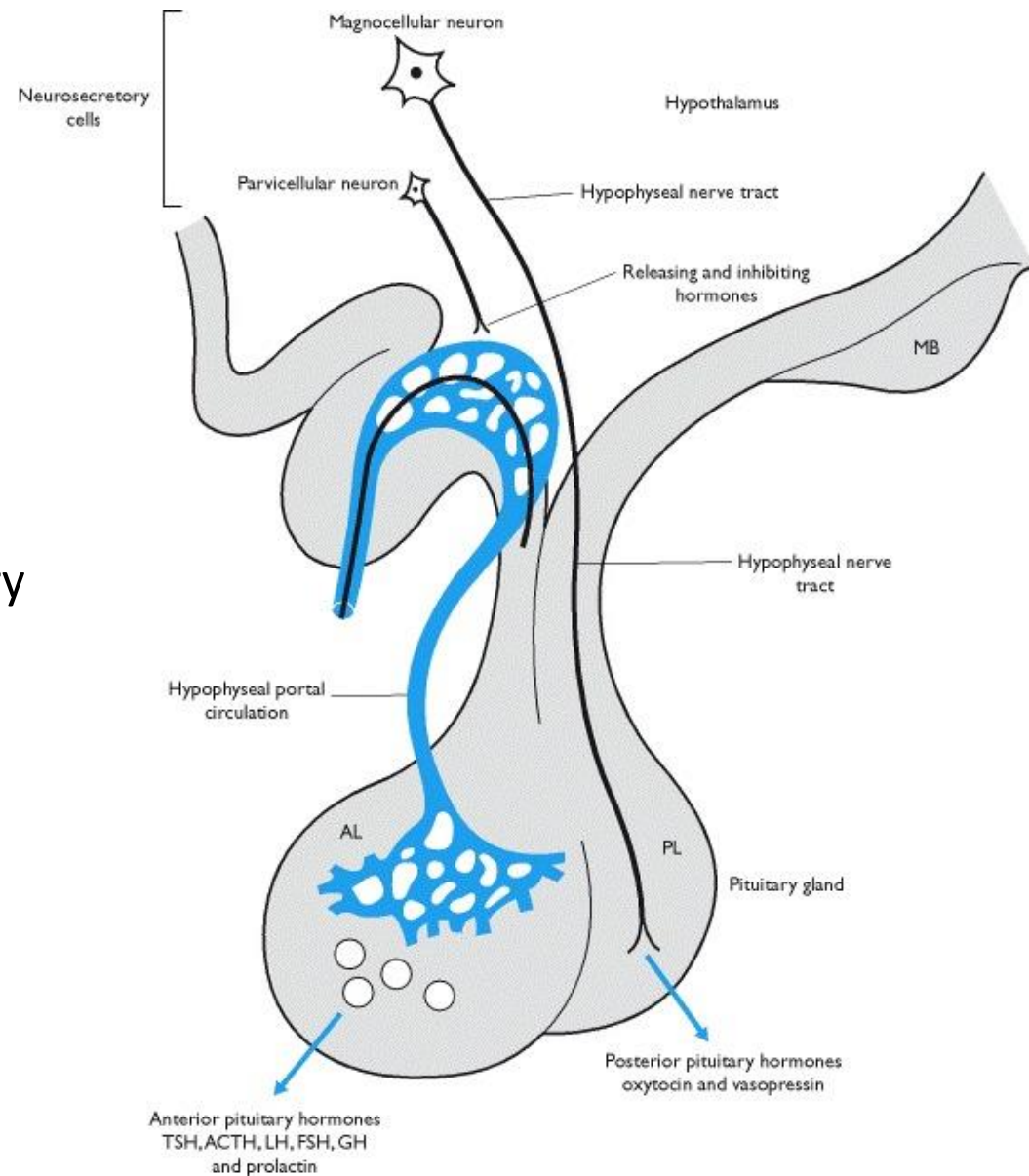
# EMINENTIA MEDIANA

- elevated part of *tuber cinereum* (detachment of infundibulum *p. nervosa*)
- neurohemal area - hematoencephalic barrier is open here
- fenestrated capillaries with large perivascular spaces



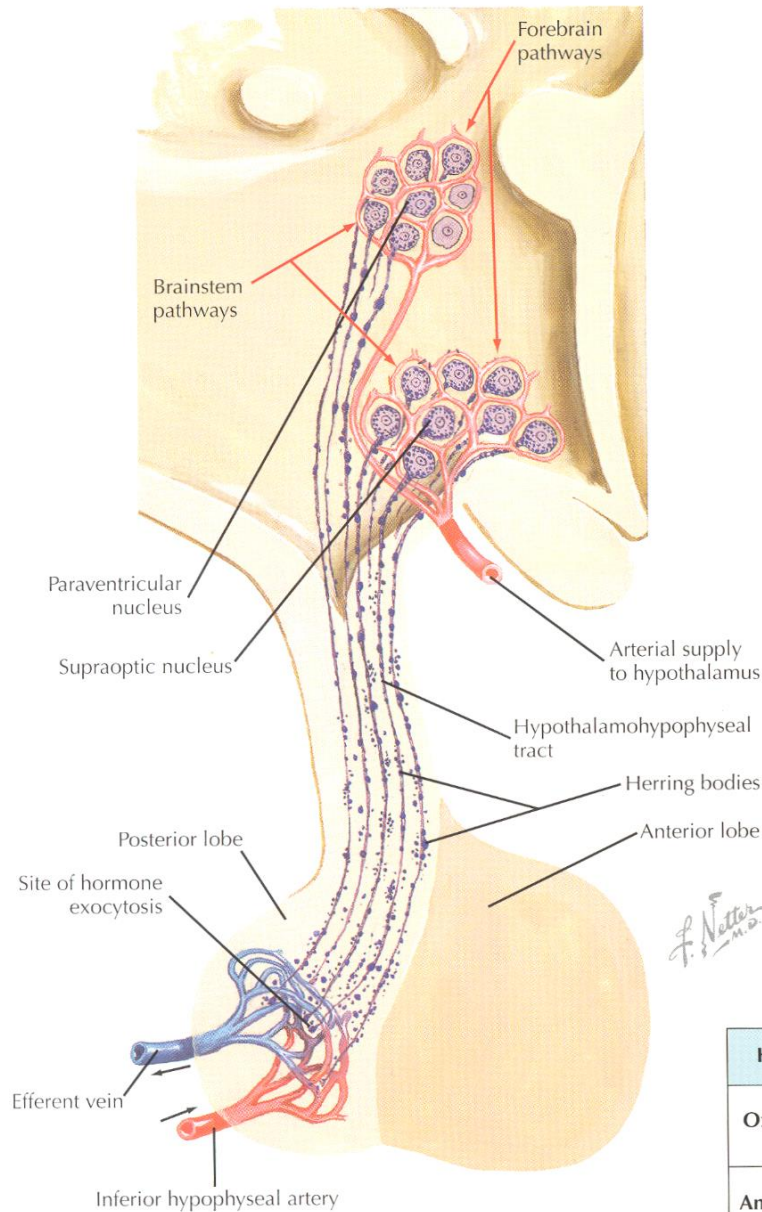
# NEUROHYPOPHYSIS (POSTERIOR LOBE)

- **Nonmyelinated nerve fibers**
  - axons of neurosecretory cells (c.a. 100 000) of hypothalamic nuclei (n. supraopticus and paraventricularis)
- **Pituicytes** (neuroglia)
  - astrocyte-like (intermediate filaments, GFAP)
  - local control of secretion from neurosecretory termini
  - Herring bodies – neurosecretory endings – dilatation close to capillaries
- **Hormones**
  - oxytocin (OT)
  - antidiuretic hormone (ADH, vasopressin)

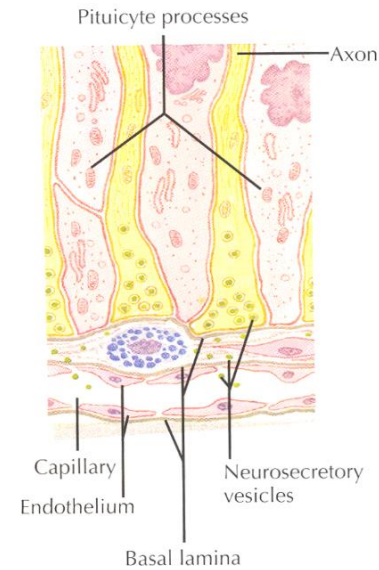




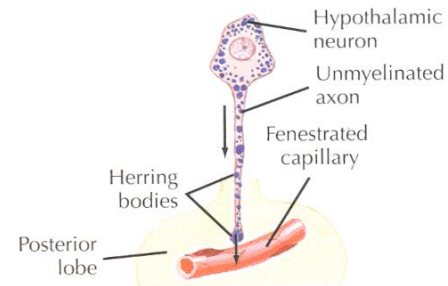
# NEUROHYPOPHYSIS (POSTERIOR LOBE)



## ▼ Neurosecretory Ending (posterior pituitary).

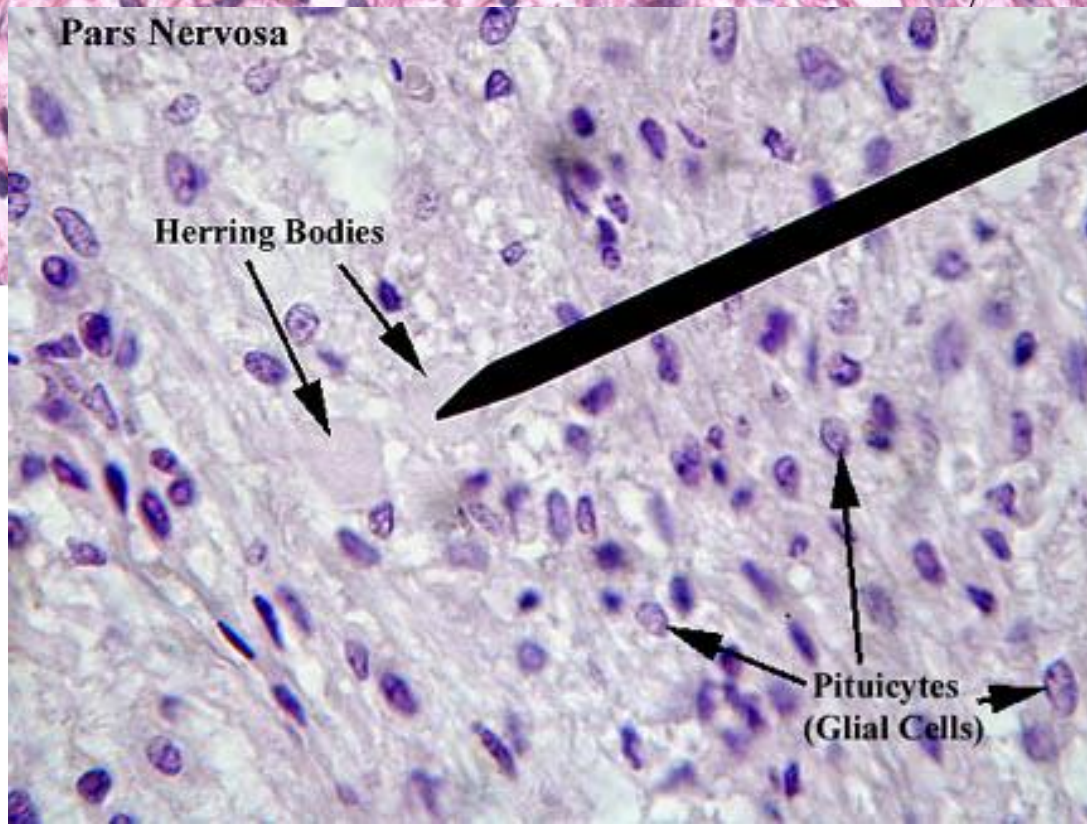
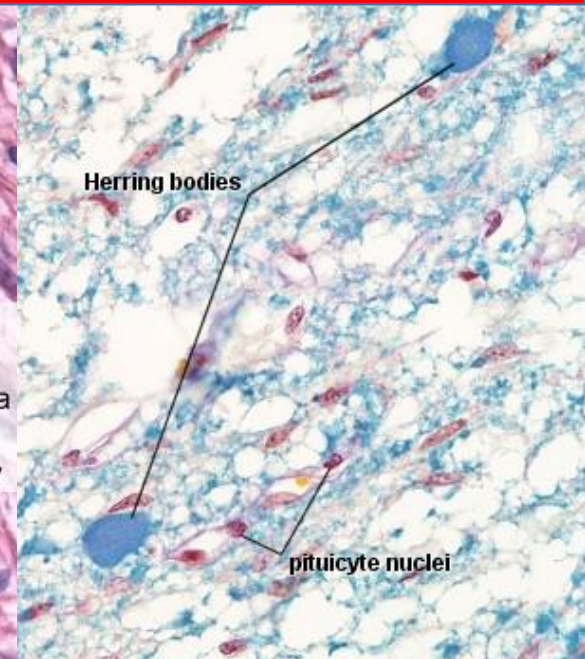
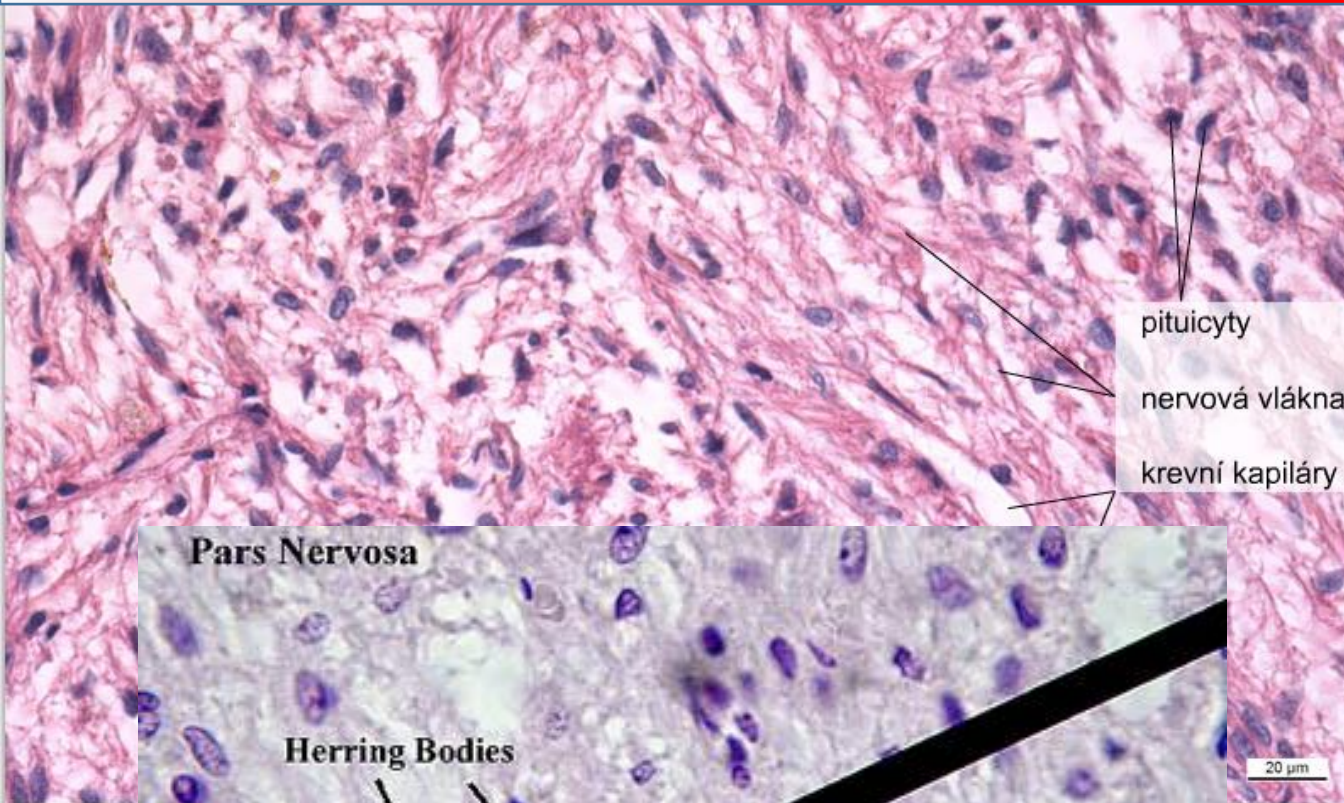


## ▼ Origin of ADH.



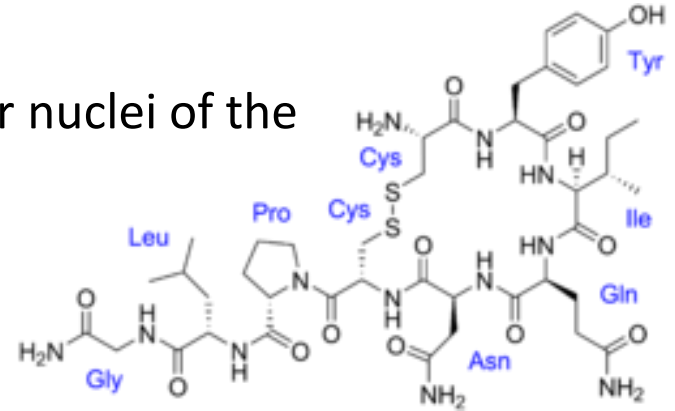
Hormone	Principal Action	Principal Nucleus of Origin
<b>Oxytocin (OXY)</b>	Uterine contraction, milk ejection	Paraventricular
<b>Anti-diuretic hormone (ADH)</b>	Water excretion in kidney, arteriolar constriction	Supraoptic

# NEUROHYPOPHYSIS (POSTERIOR LOBE)



## Oxytocin

- nonapeptide
- magno-cellular supraoptic and paraventricular nuclei of the hypothalamus
- OR - G-coupled receptor
- lactation reflex
- uterine contraction
- social behavior



## Vasopressin

- nonapeptide
- retention of water
- effective in collecting duct and distal convoluted tubule (aquaporin translocations)
- blood pressure regulation by affecting t. media
- diabetes insipidus, hypernatremia, polyuremia



# ADENOHYPHYSIS (ANTERIOR LOBE)

## Chromophilic cells

### Acidophils

#### **Nonglandotropic**

- direct effect on target tissues

### Basophils

#### **Glandotropic**

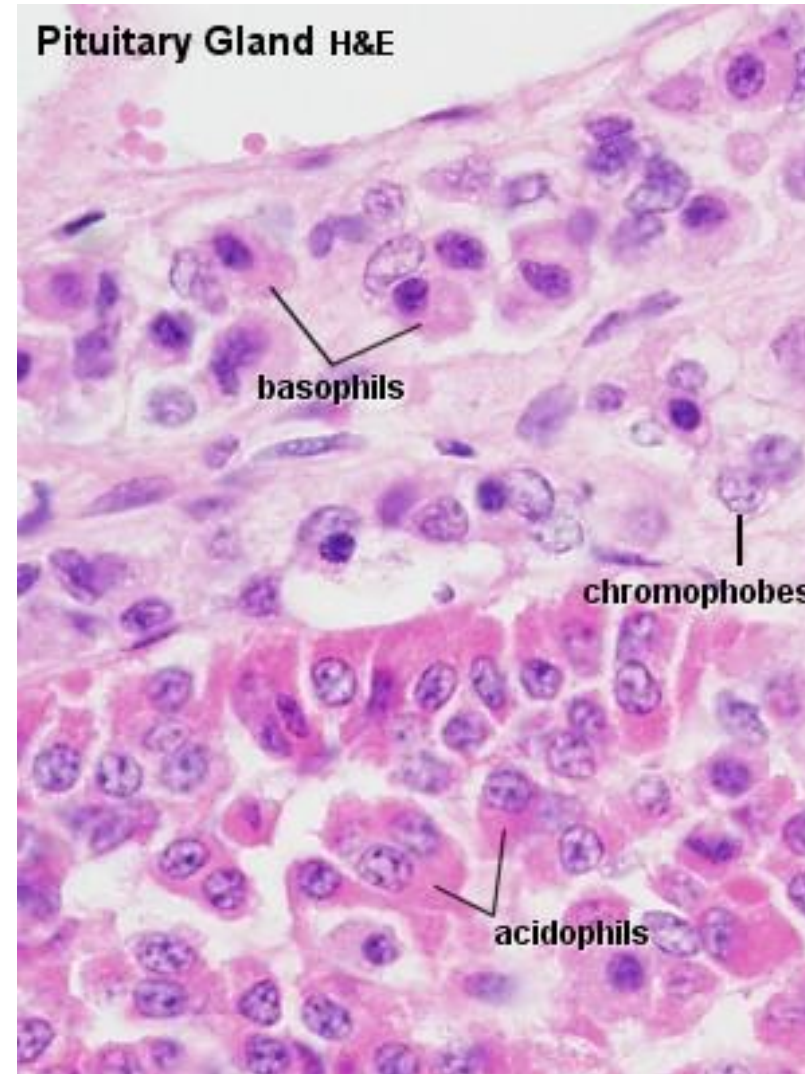- regulation of other endocrine glands

## Chromophobic cells

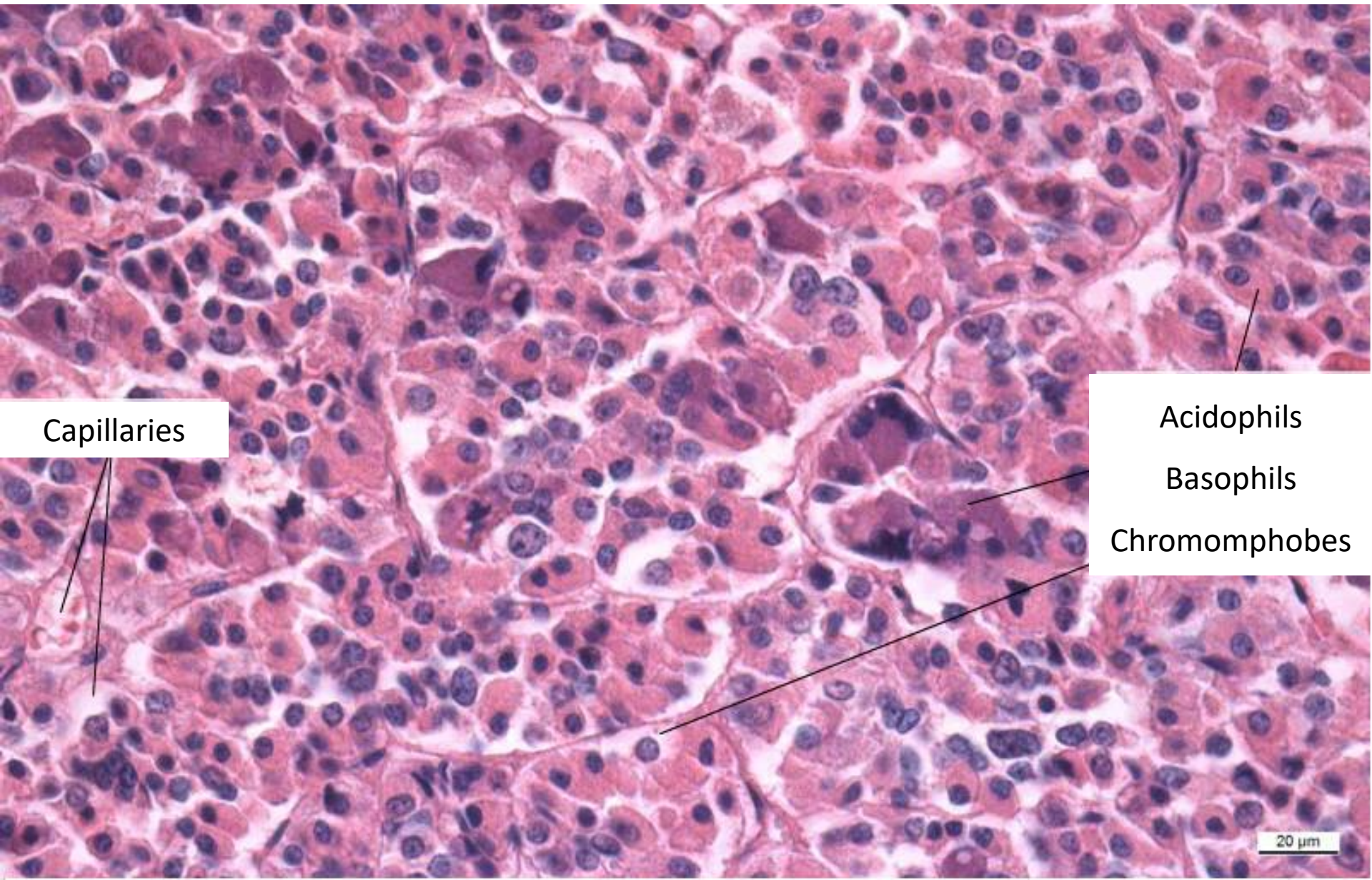
- undifferentiated cells
- degranulated (“empty”) chromophils
- stromal cells

## Folliculo-stellate cells (FS-cells)

- unclear function, putative stem cells
- cytokine production



# ADENOHYPHYSIS (ANTERIOR LOBE)



Capillaries

Acidophils

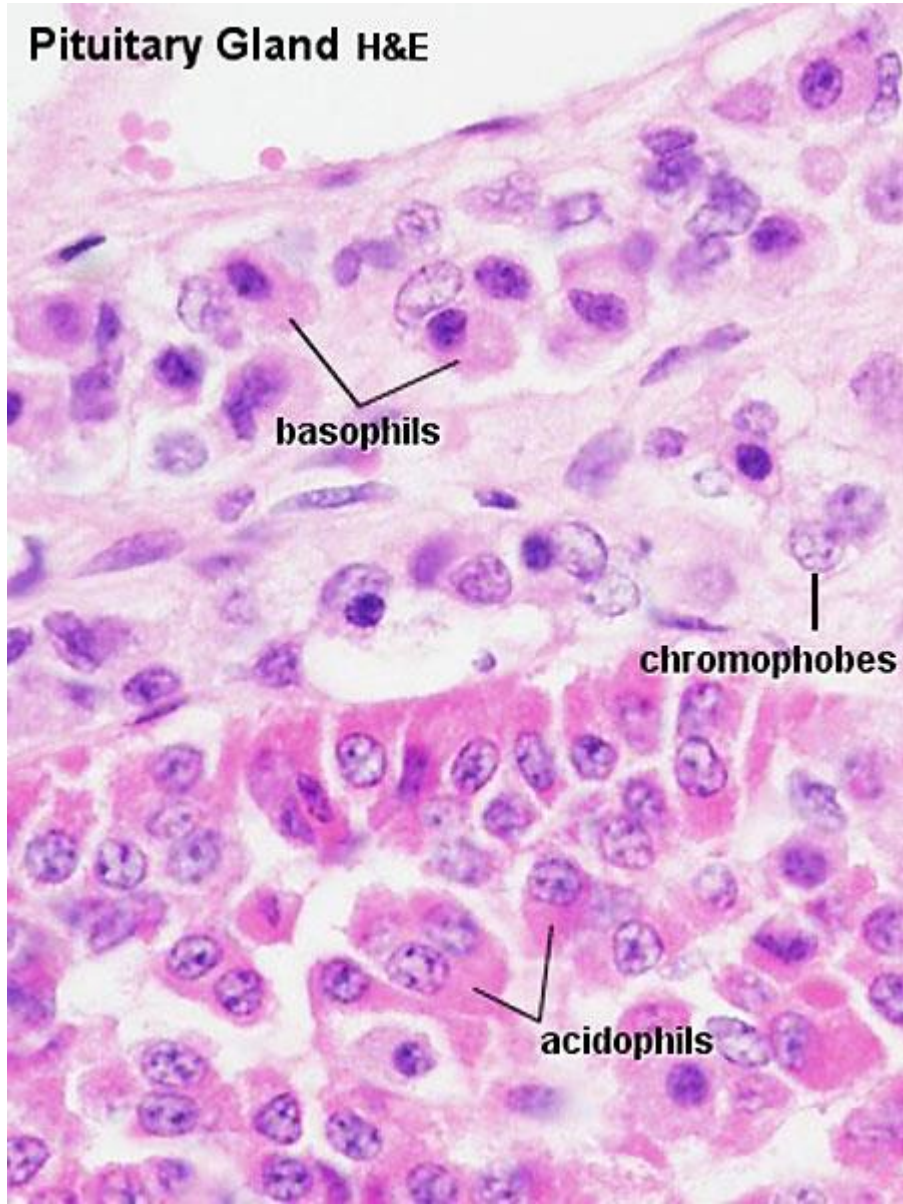
Basophils

Chromophobes

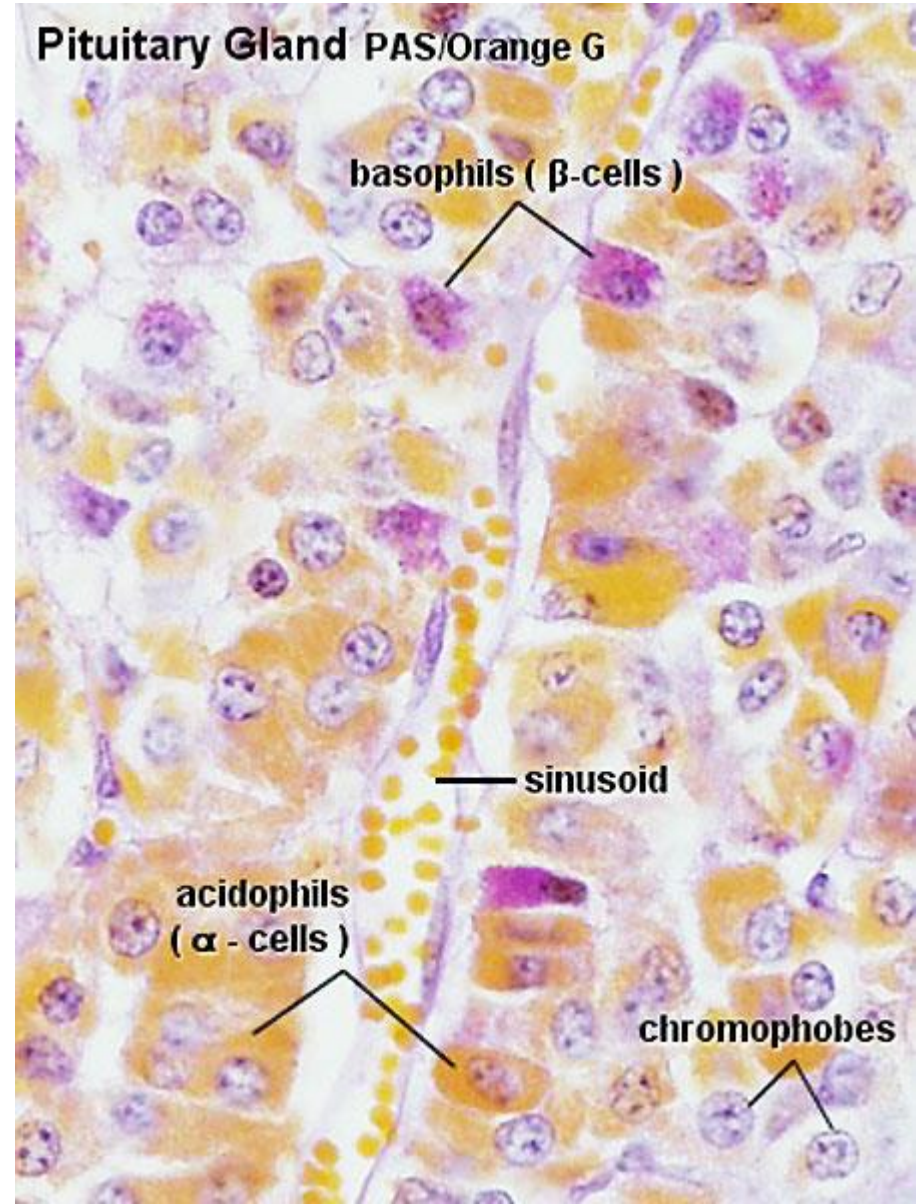
20  $\mu$ m

# ADENOHYPHYSIS (ANTERIOR LOBE)

Pituitary Gland H&E

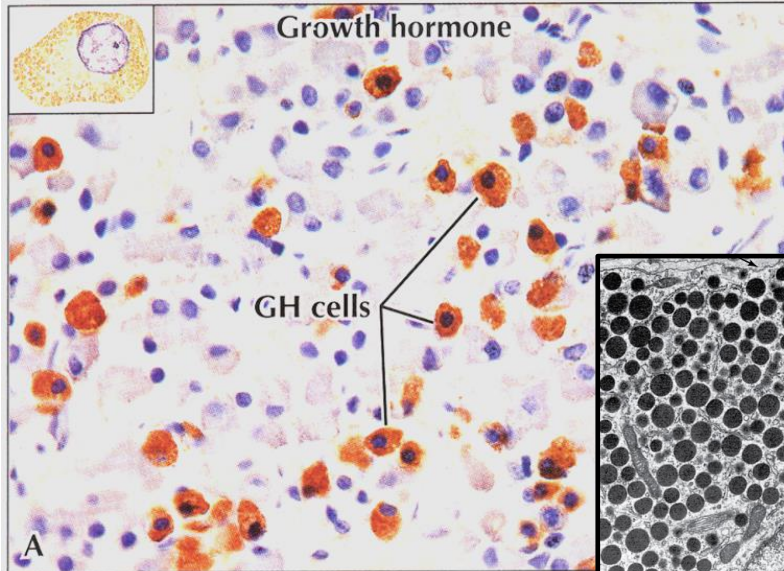


Pituitary Gland PAS/Orange G

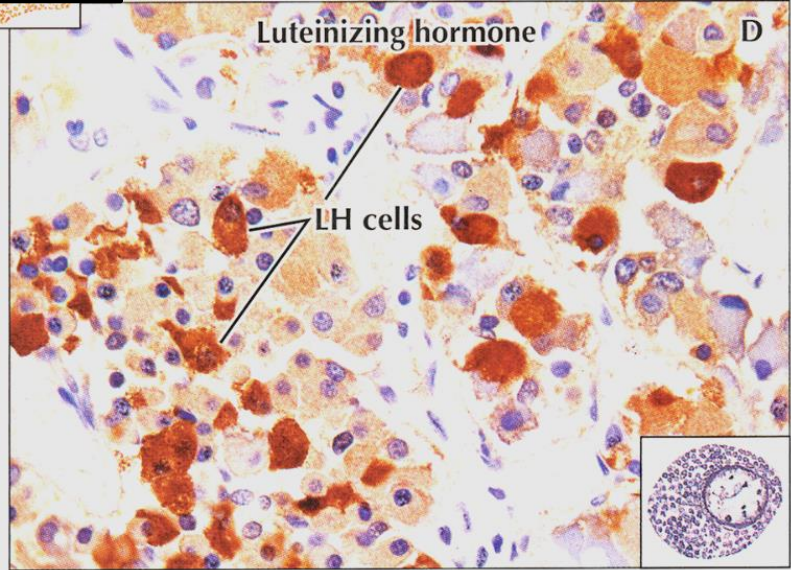
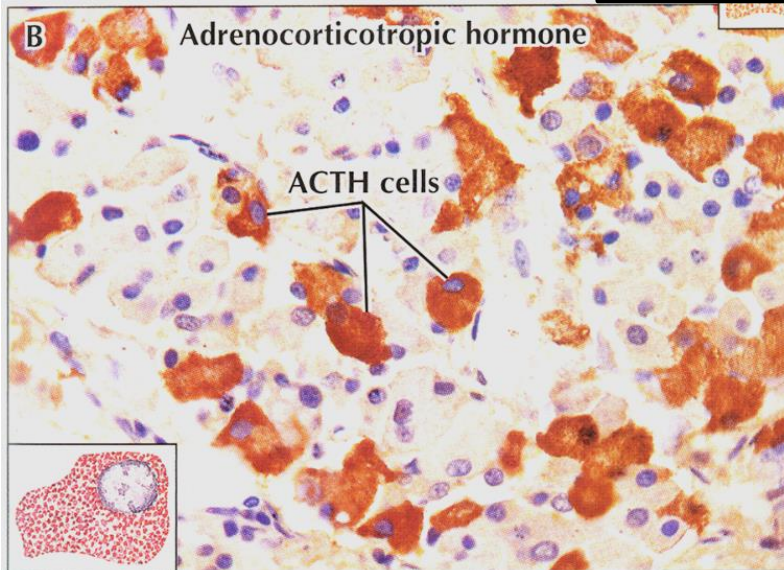
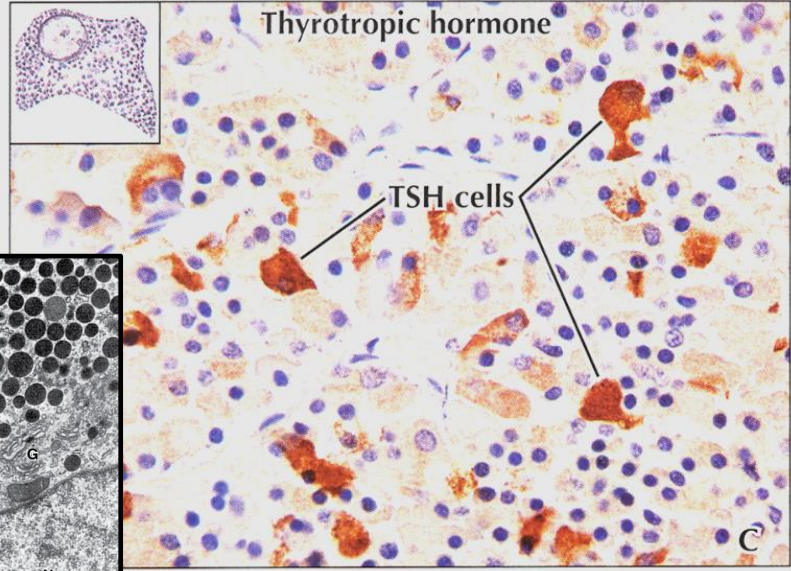


# ADENOHYPHYSIS (ANTERIOR LOBE)

## Acidophils producing GH



## Basophils producing glandotropic hormones



## REGULATION BY HYPOTHALAMIC HORMONES

- gonadoliberin → FSH a LH
- corticoliberin → cortikotropin
- thyreoliberin → thyreotropin
- *prolactin releasing hormone (?)* → *prolactin*
- somatoliberin → somatotropin
- follistatin — FSH a LH
- somatostatin — somatotropin, TSH
- dopamin — prolactin

### ”FLAT PEG”

- FSH
- LH
- ACTH
- TSH
- Prolactin
- Endorphins
- Growth hormone

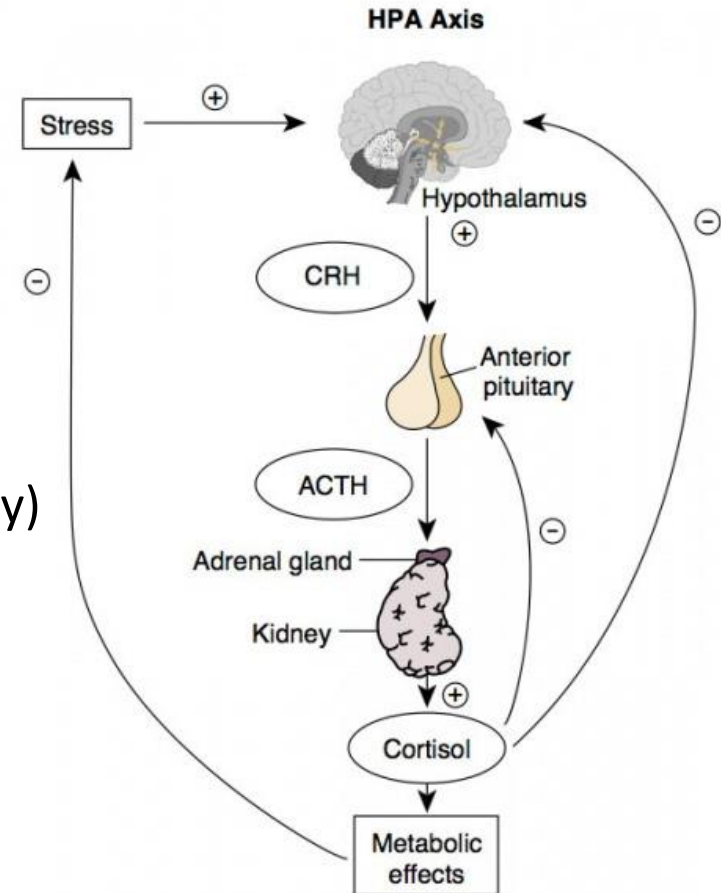
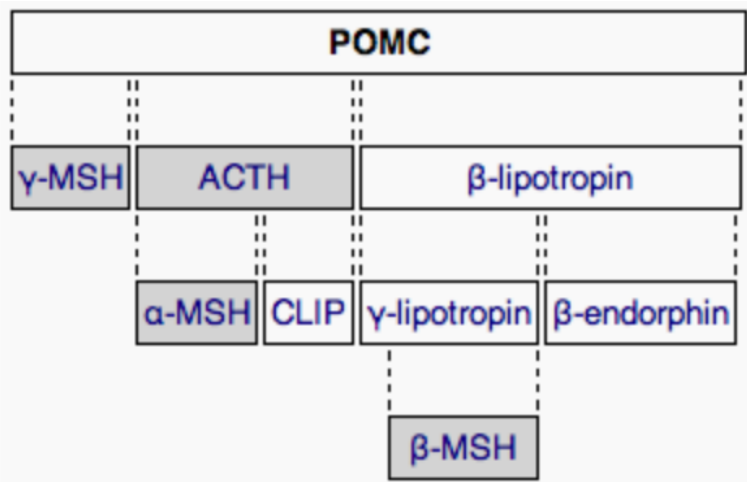


## Pro-opio-melanocortin (POMC)

rough ER → pre-prohormon  
produced by various tissues

cleavage to

- ACTH (target: adrenal cortex → cortisol)
- MSH (target: melanocytes - mostly in paracrine way)
- lipotropin (lipolysis, steroidogenesis)
- endorphins



## FSH (folitropin), LH (lutropin)

- gonadotropic cells of adenohypophysis stimulated by GnRH
- glycoproteins, 30kDa
- heterodimer, two noncovalent bound subunits (**a/α** - common for - LH, FSH, TSH, hCG, **b/β** - specific)
- FSH receptor (testes, ovarium, uterus) G-protein coupled receptor
  - glycosylated extracellular domain of 11 leucine rich repeats specific to FSH
  - after ligand binding, activation of G-protein and cAMP signaling
  - alternative activation of MAPK cascade (ERK)
  - complex signaling response (prostaglandins, PLPc, NO)

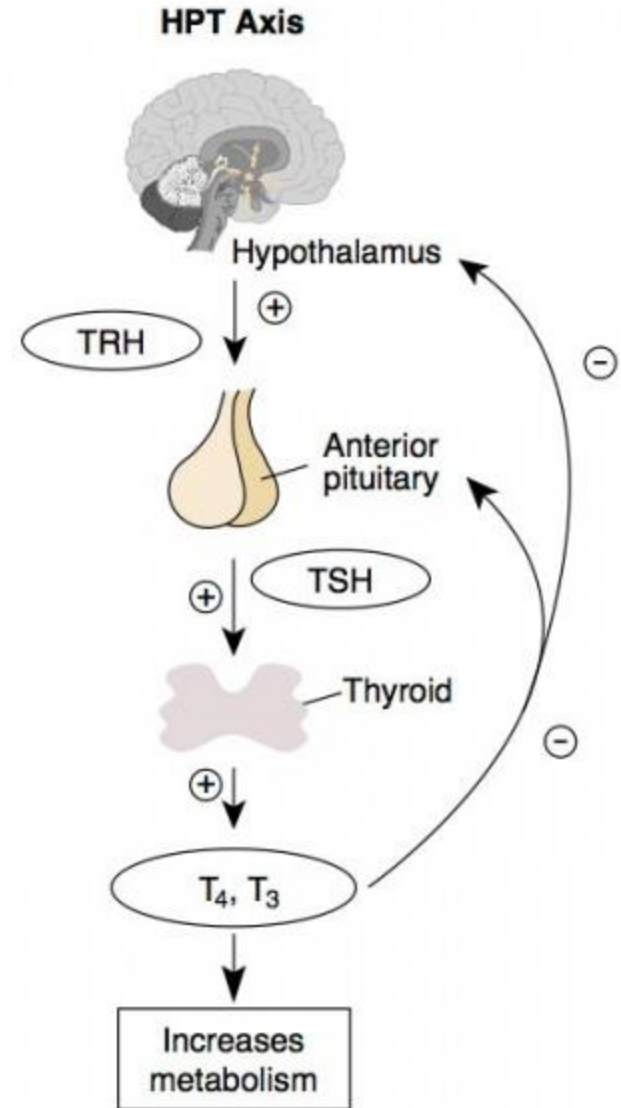
### FSH

### LH

ovarium	follicle development (FSHR in m. <i>granulosa cells</i> )	ovulation, development of corpus luteum, production of androgens in thecal cells
testes	spermatogenesis, FSHR in Sertoli cells	production of testosterone in Leydig cells (expression of LHR)
extragonadal	FSHR in secretory endometrium of luteal phase uterus (endometrial functions, embryo-endometrial interactions)	uterus, seminal vesicles, prostate, skin... unknown function

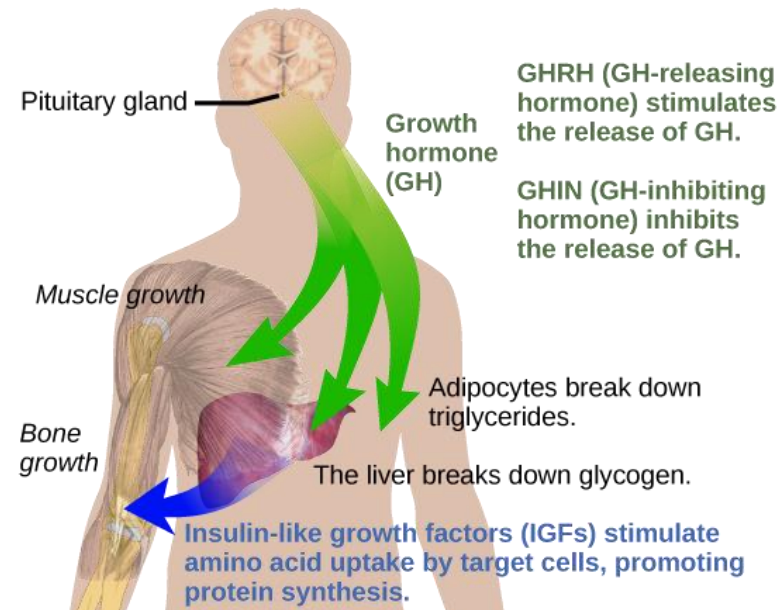
## TSH, thyrotropin

- thyrotropic cells of adenohypophysis stimulated by TRH
- production of T<sub>4</sub> (thyroxin) a T<sub>3</sub> (triiodothyronin) by thyroid gland
- glycoprotein, 28,5 kDa, heterodimer, two noncovalent bound subunits (α, β)
- TSH receptor on thyroid follicular cells
- G-protein signaling → adenylylcyklase → cAMP
- cAMP → iodide channels (pendrin), transcription of thyreoglobulin, endo- and exocytic pathway
- cross-reactivity with hCG → in pregnancy - alterations in synthesis of thyroid hormones (**gestational hyperthyroidism**)



## GH, somatotropin, growth hormone

- somatotrophic cells of adenohypophysis stimulated by GHRH (somatocrinin)
- several molecular isoforms (alternative splicing), ~20-24 kDa
- broad spectrum of target cell types and physiological circuits
  - transcription of DNA, translation of RNA, proteosynthesis
  - lipid use (fatty acid mobilization, conversion to acetyl-CoA)
  - inhibition of direct use of glucose, stimulation of glukoneogenesis
  - transmembrane transport of aminoacids
  - proteosynthesis in chondrocytes and osteoblasts, proliferation, osteogenesis
- GHR in various tissues
  - RTK, JAK-STAT
- somatomedins
  - small proteins (MW 7,5 kDa), IGF-like
  - produced by liver
- various pathologies associated with GH



# ADENOHYPHYPHYSIS – HORMONES

**Table 2. Nonclassical Anterior Pituitary Substances and Cell(s) of Origin**

<i>Substances</i>	<i>Cell Types</i>
<b>PEPTIDES</b>	
ACTIVIN B, INHIBIN, FOLLISTATIN	F,G
ALDOSTERONE STIMULATING FACTOR	UN
ANGIOTENSIN II (ANGIOTENSINOGEN, ANGIOTENSIN I CONVERTING ENZYME, CATHEPSIN B, RENIN)	C,G,L,S
ATRIAL NATURETIC PEPTIDE	G
CORTICOTROPIN-RELEASING HORMONE-BINDING PROTEIN	C
DYNORPHIN	G
GALANIN	L,S,T
GAWK (CHROMOGRANIN B)	G
GROWTH HORMONE RELEASING HORMONE	UN
HISTIDYL PROLINE DIKETOPIPERAZINE	UN
MOTILIN	S
NEUROMEDIN B	T
NEUROMEDIN U	C
NEUROPEPTIDE Y	T
NEUROTENSIN	UN
PROTEIN 7B2	G,T
SOMATOSTATIN 28	UN
SUBSTANCE P (SUBSTANCE K)	G,L,T
THYROTROPIN RELEASING HORMONE	G,L,S,T
VASOACTIVE INTESTINAL POLTPEPTIDE	G,L,T
<b>GROWTH FACTORS</b>	
BASIC FIBROBLAST GROWTH FACTOR	C,F
CHONDROCYTE GROWTH FACTOR	UN
EPIDERMAL GROWTH FACTOR	G,T
INSULIN-LIKE GROWTH FACTOR I	S,F
NERVE GROWTH FACTOR	UN
PITUITARY CYTOTROPIC FACTOR	UN
TRANSFORMING GROWTH FACTOR ALPHA	L,S,G
VASCULAR ENDOTHELIAL GROWTH FACTOR	F
<b>CYTOKINES</b>	
INTERLEUKIN-1 BETA	T
INTERLEUKIN-6	F
LEUKEMIA INHIBITORY FACTOR	C,F
<b>NEUROTRANSMITTERS</b>	
ACETYLCHOLINE	C,L
NITRIC OXIDE	F


C = corticotroph, F = folliculostellate cell, G = gonadotroph, L = lactotroph, S = somatotroph, T = thyrotroph, UN = unknown

## Hypophyseal tumors

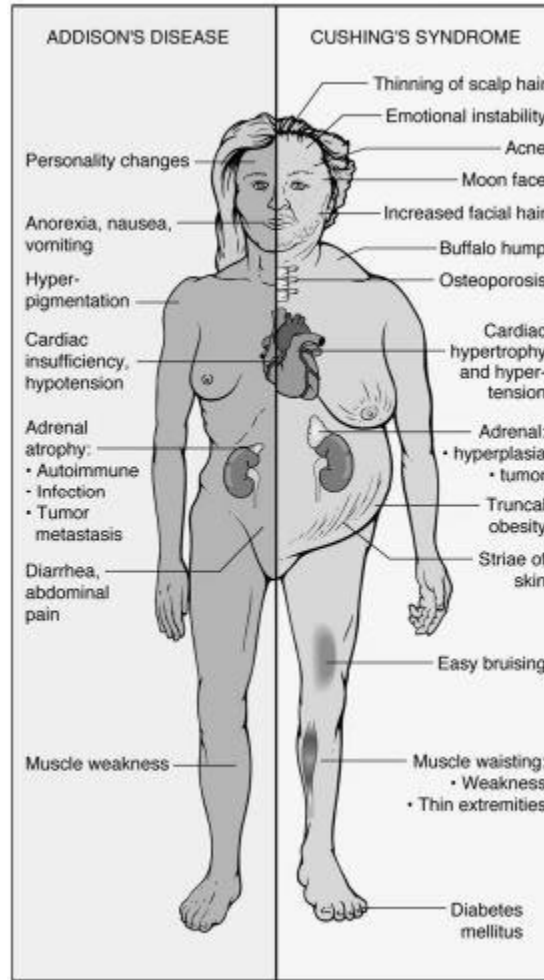
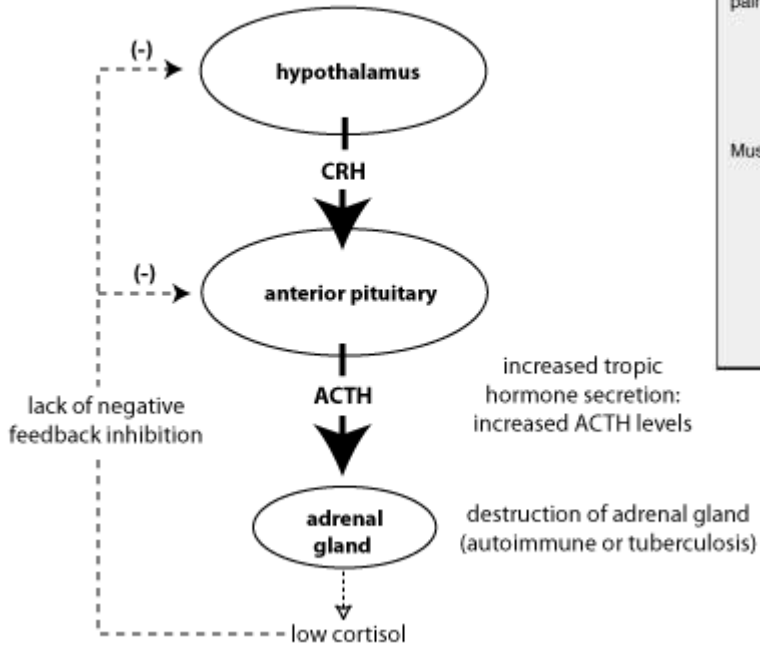
- compression of surrounding structures (e.g. optic chiasma)
- hyperfunction of endocrine component
  - prolactinoma - galactorrhea
  - hypogonadism (alterations of GnRH)
  - gigantism - acromegaly
  - nanism



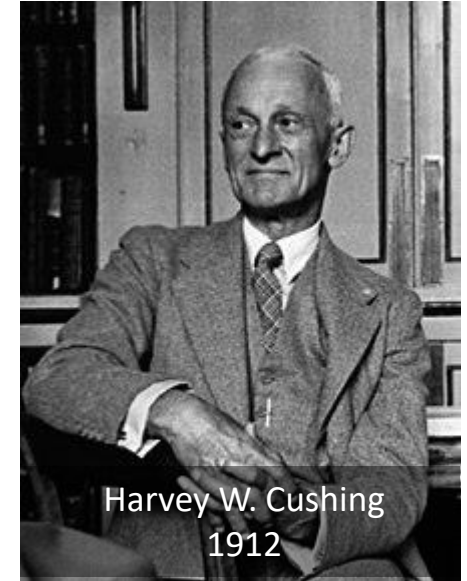
## Corticotrophs hypofunction



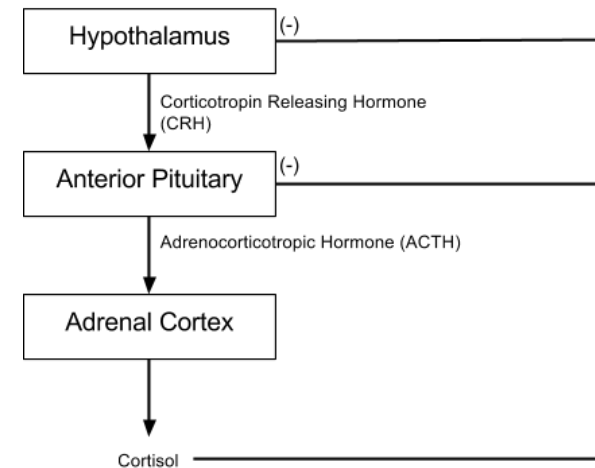
### Addison's Disease



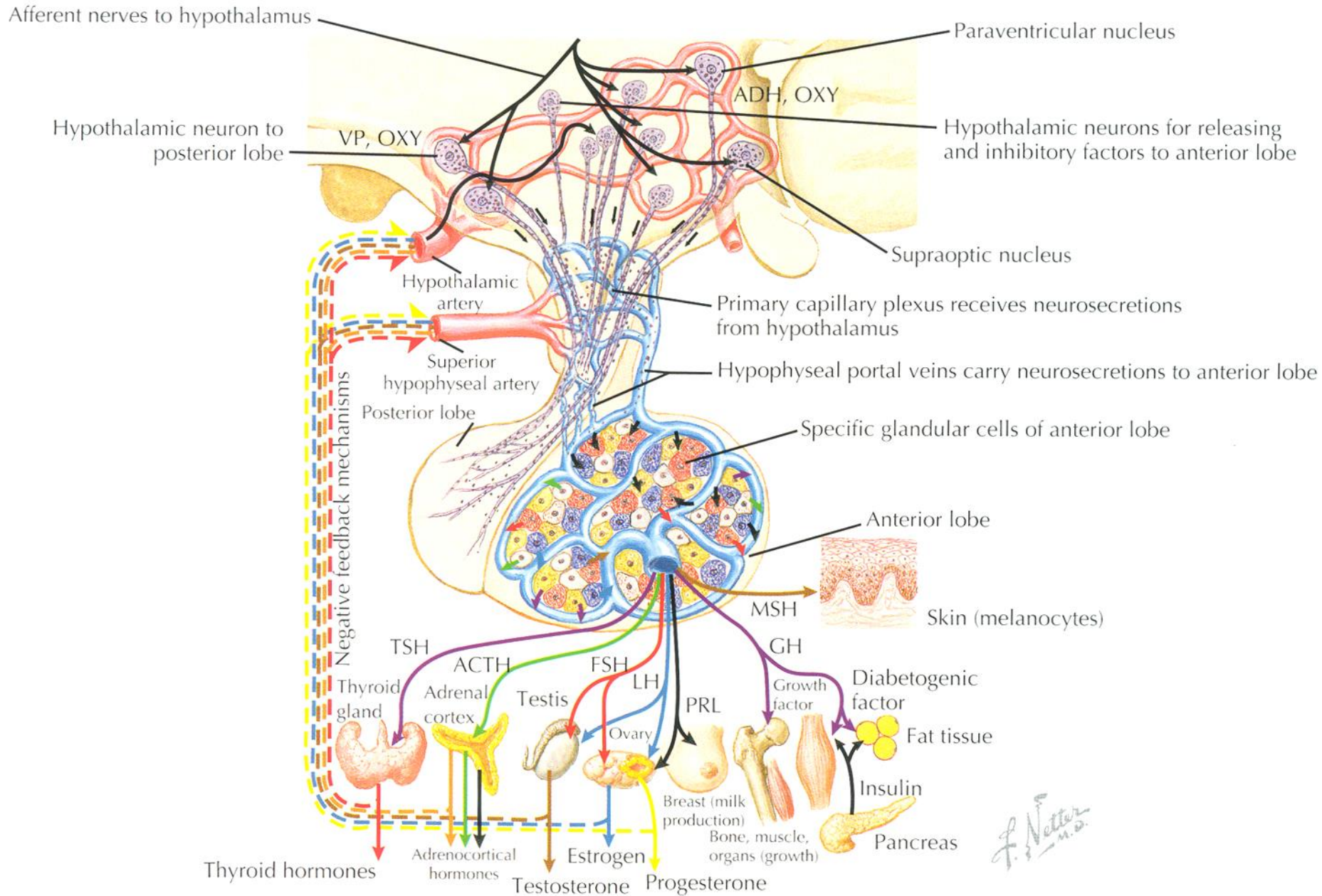
## Corticotrophs hyperfunction



### Cushing's syndrome



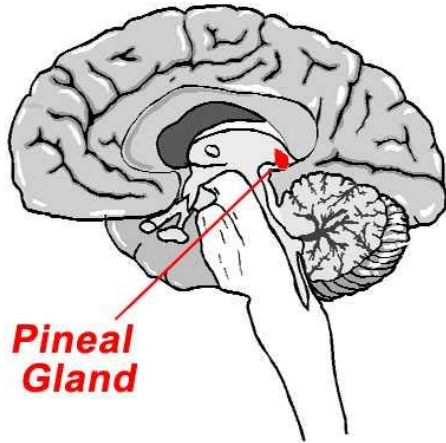
# PITUITARY GLAND SUMMARY



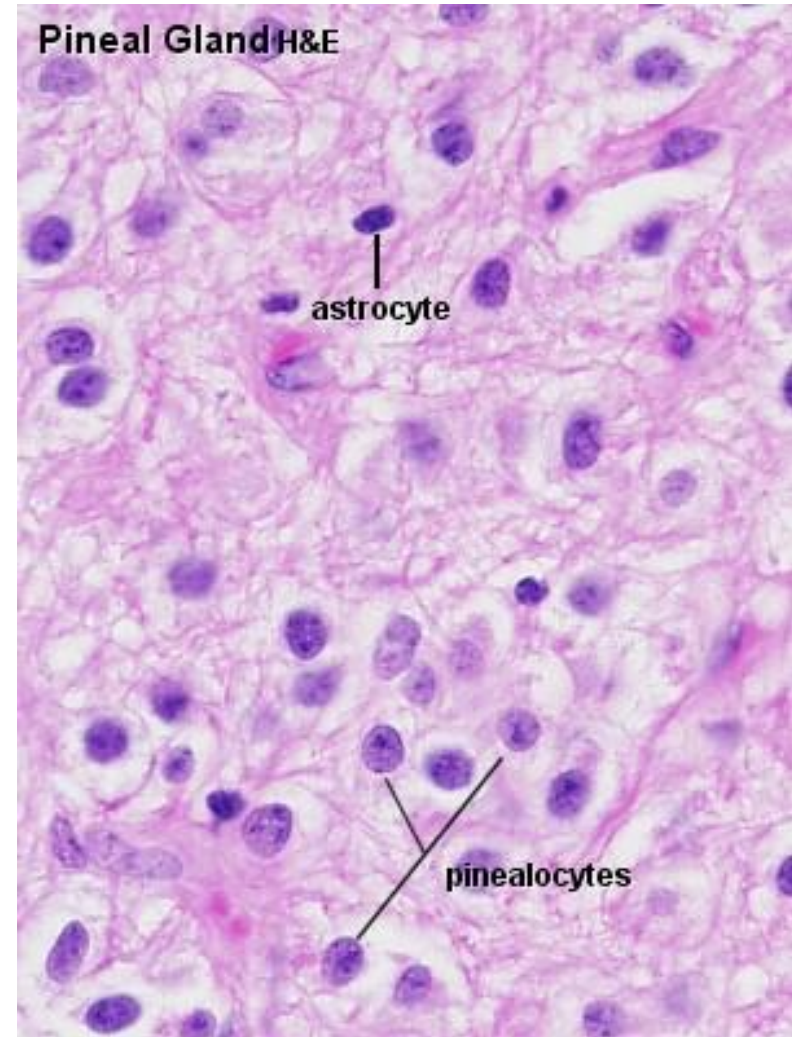

Anatomy		Microscopic anatomy		Hormones and target tissues				
Anterior lobe (adenohypophysis)	pars distalis	<p>superior hypophyseal arteries</p> <p>→ primary capillary plexus at eminentia mediana</p> <p>→ hypophyseal portal veins</p> <p>→ secondary capillary plexus in adenohypophysis</p>	trabecular epithelium in cords and clusters, reticular fibers; agranular folliculo-stellate cells with so far unclear function		lack hormonal activity			
			chromophobes	undifferentiated cells degranulated chromophilic cells stromal cells				
			chromophils	acidophilic nonglandotropic			mammotrophic cells	small polypeptides
	somatotropic cells				somatostatin (GHIH) ⊥ GHRH → somatotropin (STH)	directly liver and growth plates other tissues via somatomedins		
	basophilic glandotropic			corticotrophic cells	glycoproteins	CRH → ACTH, MSH	adrenal cortex → cortisol melanocytes	
				thyrotrophic cells		TRH → TSH	thyroid → thyroxin, T3	
	gonadotropic cells		GnRH → FSH (ICSH), LH	gonads → androgens, estrogens, progesterone				
pars tuberalis								
pars intermedia	Rathke's cysts							
Posterior lobe (neurohypophysis)	eminetia mediana → infundibulum	<p>inferior hypophyseal arteries</p> <p>→ capillary plexus in neurohypophysis</p>	<p>nonmyelinated <b>axons</b></p> <p>of hypothalamic neurons n. supraopticus, n. paraventricularis (tractus hypothalamohypophysialis), <b>pituicytes</b></p>		small peptides	ADH	tubulus reuniens, ductus colligens t.media of vessels	
	pars nervosa					oxytocin	myometrium of uterus during gravidity myoepithelium of lactating mammary gland	

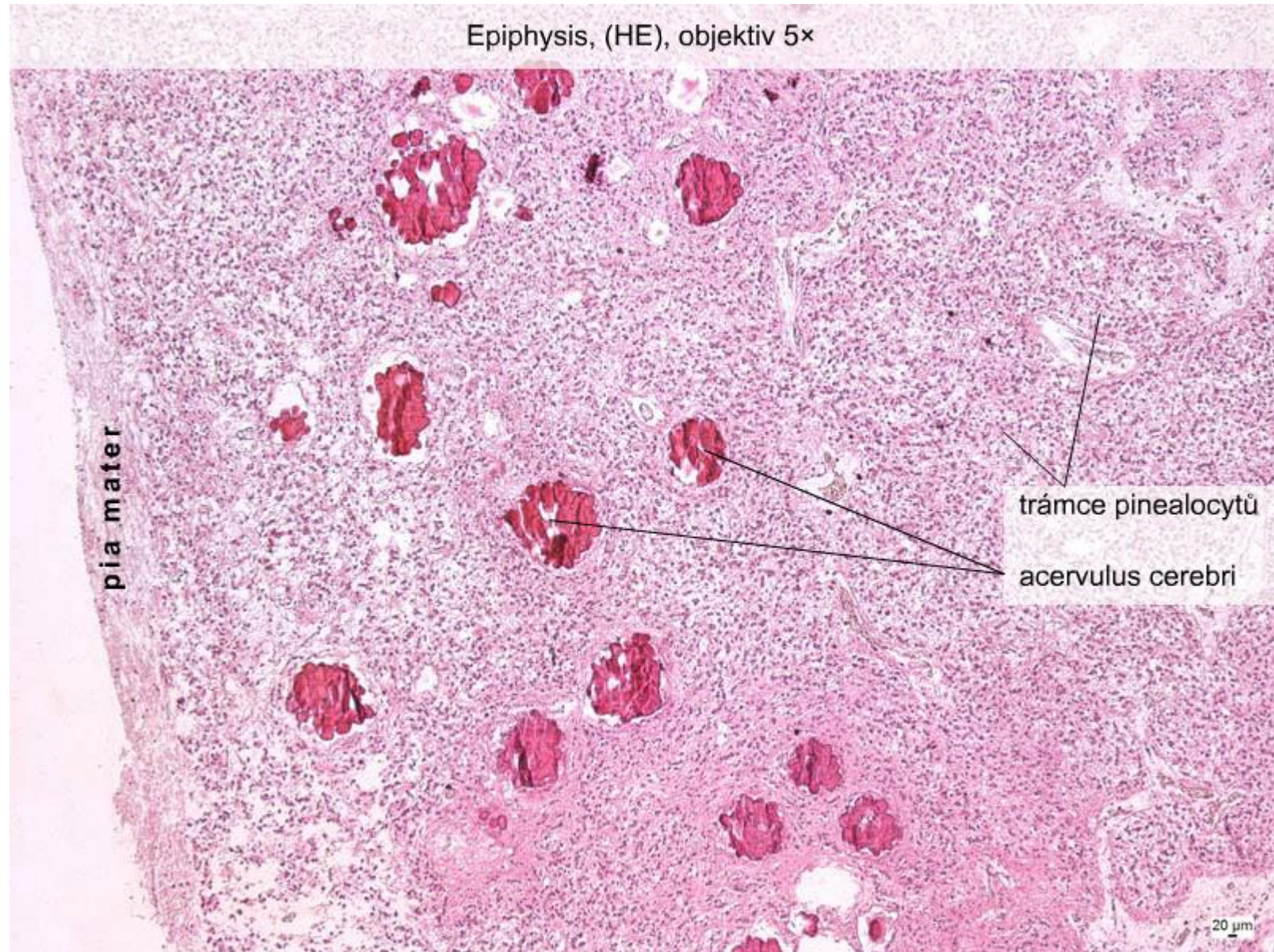
# EPIPHYSIS (C. PINEALE)





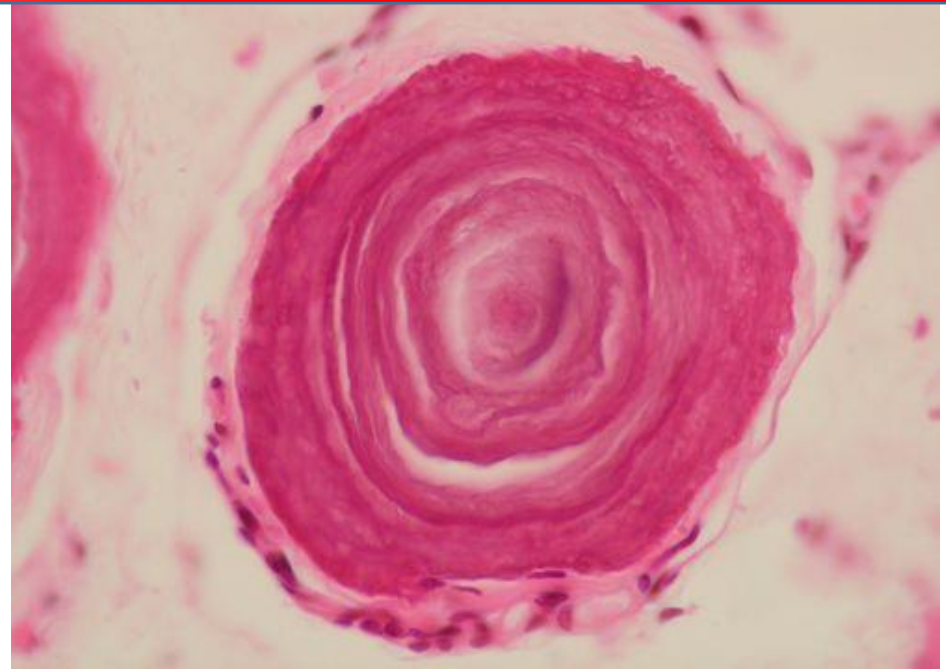
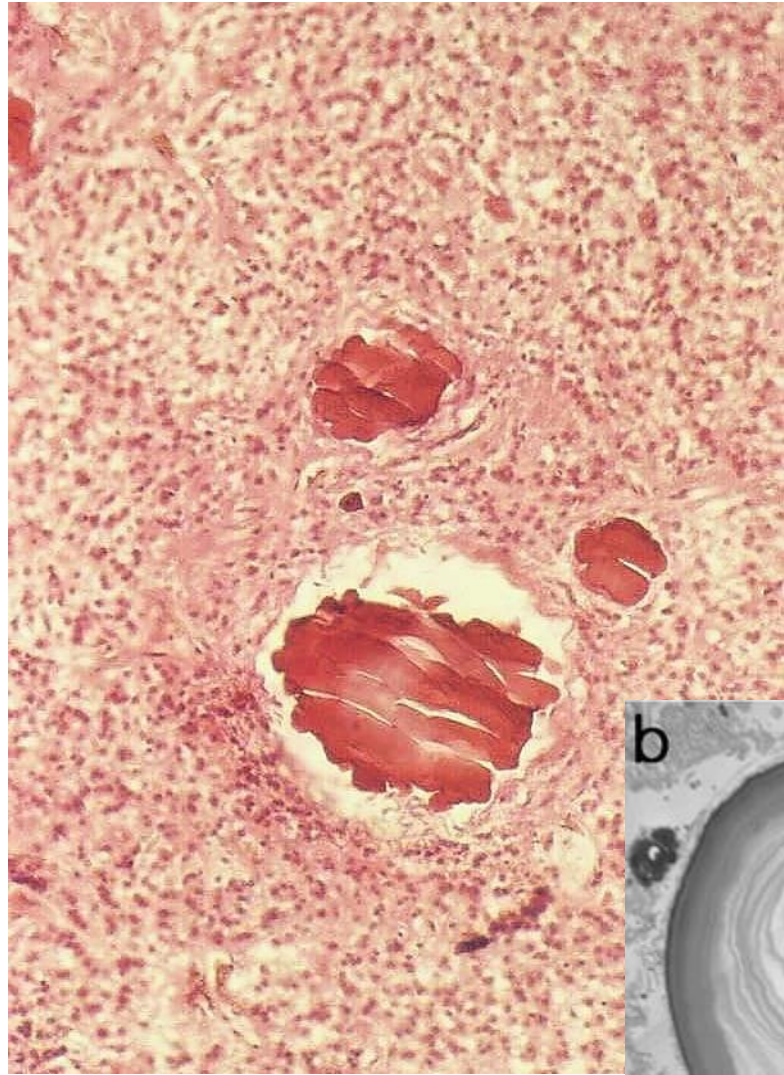
- epithalamus
- c.t. capsule continuous to pia mater
- thin c.t. septa
- non-myelinated nerve fibers
- **pinealocytes** (95%, large, pale, round nuclei)
- interstitial neuroglia (astrocytes, dark, elongated nuclei)
- *acervulus cerebri*
- melatonin



# EPIPHYSIS (C. PINEALE)

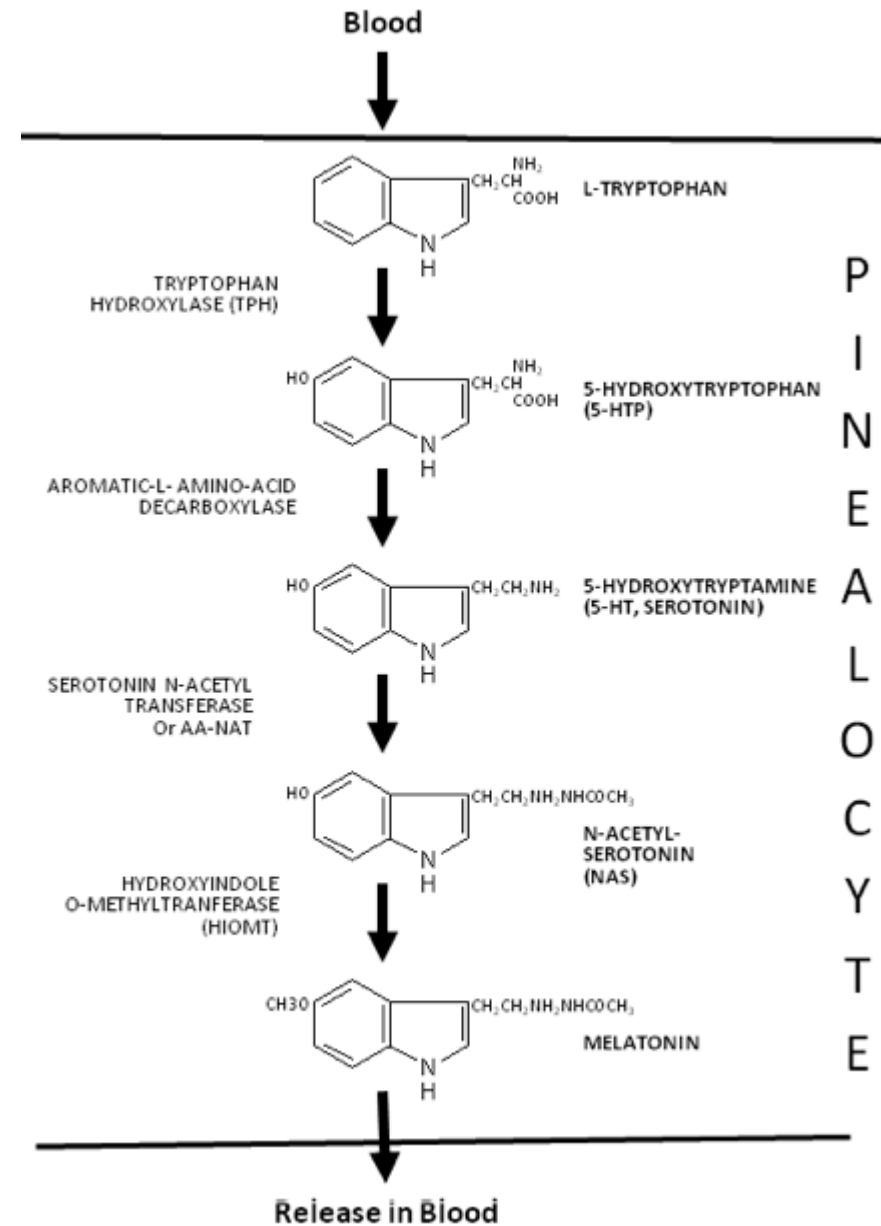


# EPIPHYSIS - ACERVULUS CEREBRI



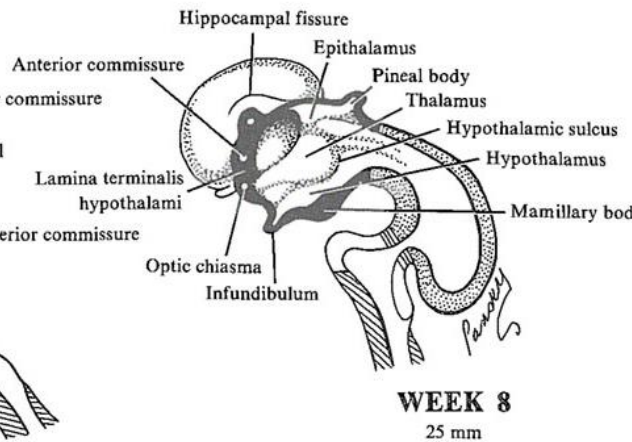
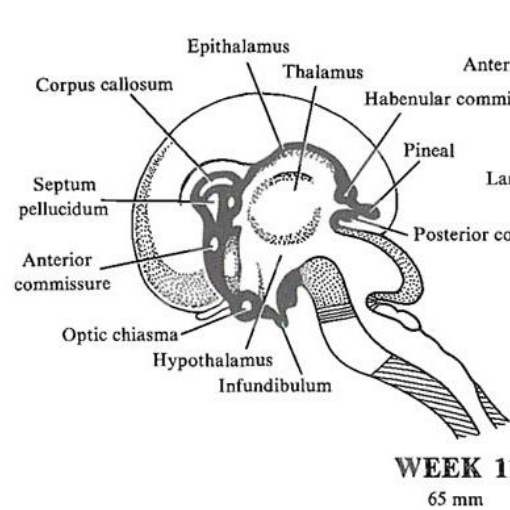
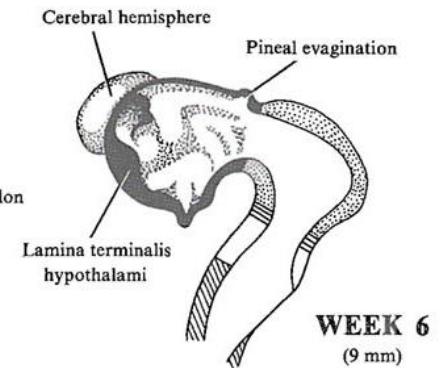
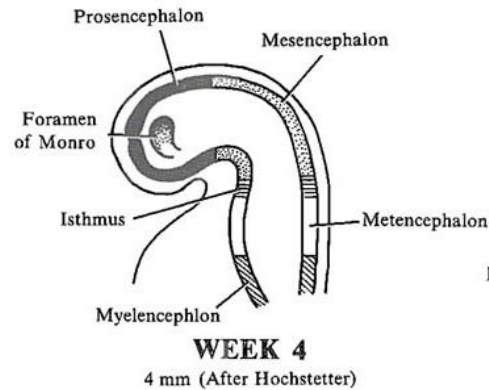
# EPIPHYSIS (*C. PINEALE*)

- pinealocytes
- star-like, modified neurons in trabecules
- association with fenestrated capillaries
- neurosecretory dilatations
- nonvisual photoreception



# EMBRYONIC DEVELOPMENT OF EPIPHYSIS

- thickening of caudal part of ependyma that does not contribute to development of choroid plexus at the roof of diencephalon
- neuroectoderm



**Anolis**



**Parietal eye**



**Sphenodon**



# THYROID GLAND (GL. THYROIDEA)

- Follicular cells → thyroid hormones (T3, T4)
- **C cells** → calcitonin

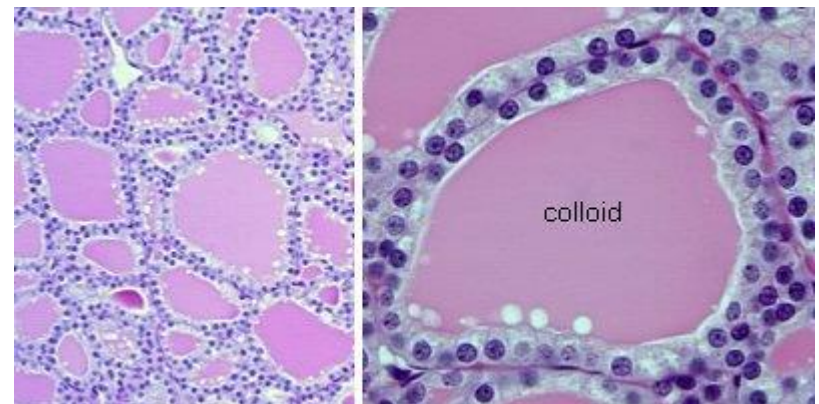
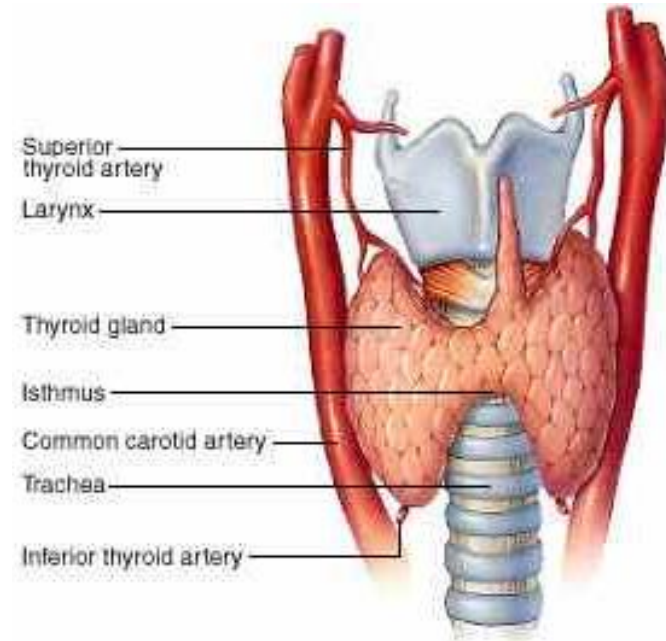
**C.t. capsule, septa**

**Lobes → lobuli - follicles**

**Follicles** (50  $\mu\text{m}$  - 1 mm)

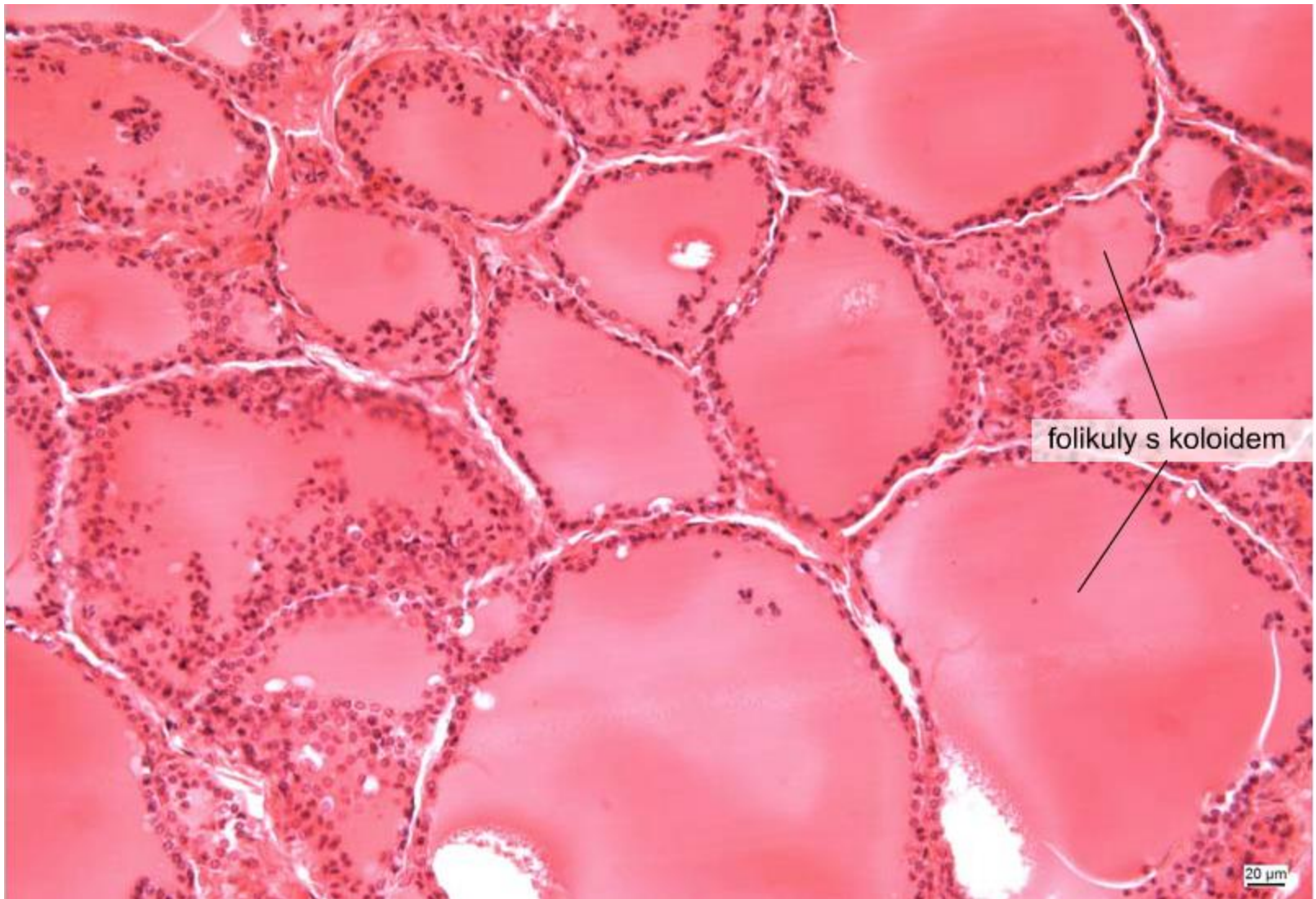
- separated by interstitial loose collagen c.t.
- simple epithelium (flat to cubic, according to their secretory activity)
- colloid

Capillary network from thyroid arteries

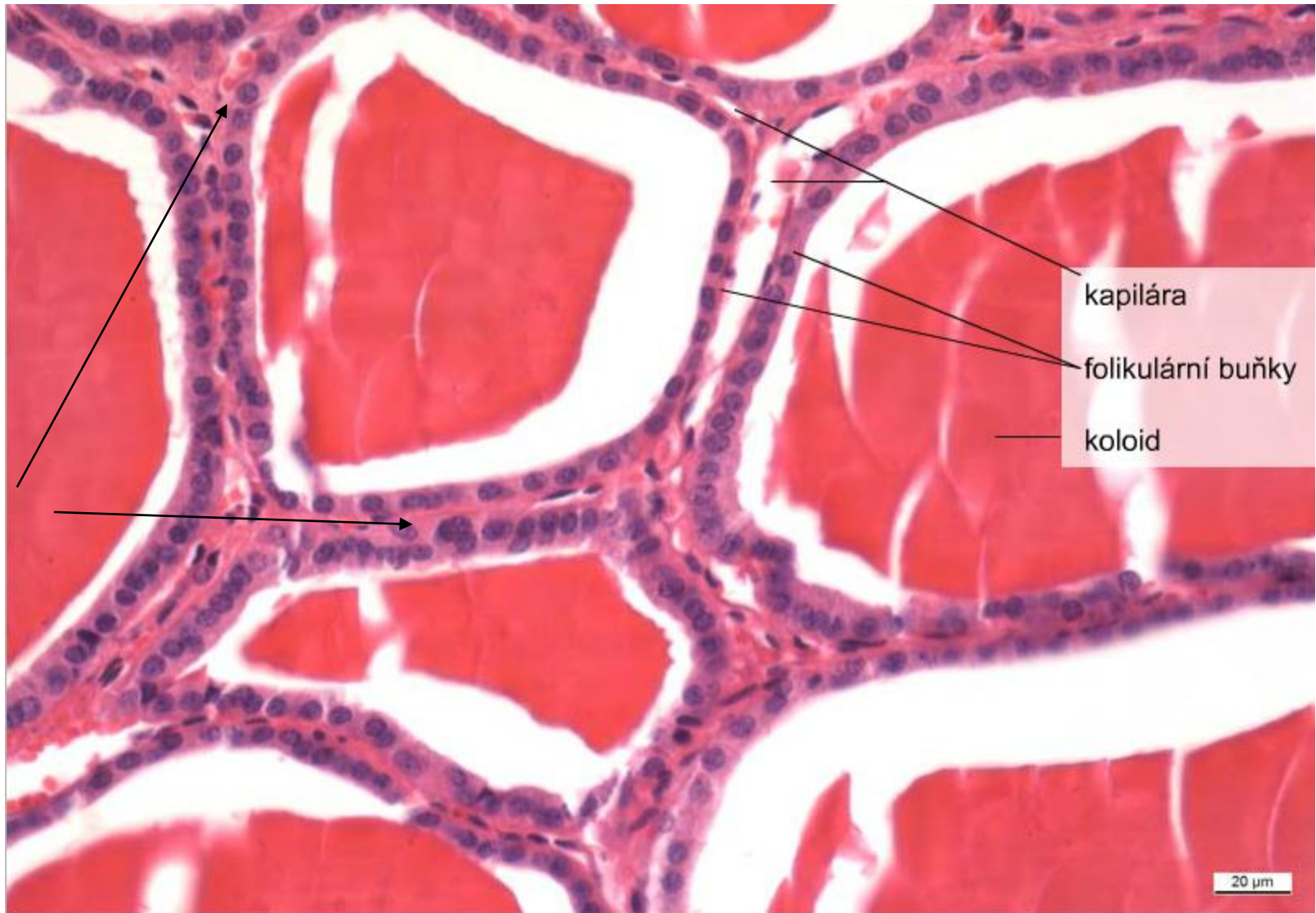




# THYROID GLAND - FOLLICLES



# THYROID GLAND - FOLLICLES



C-cells

kapilára

folikulární buňky

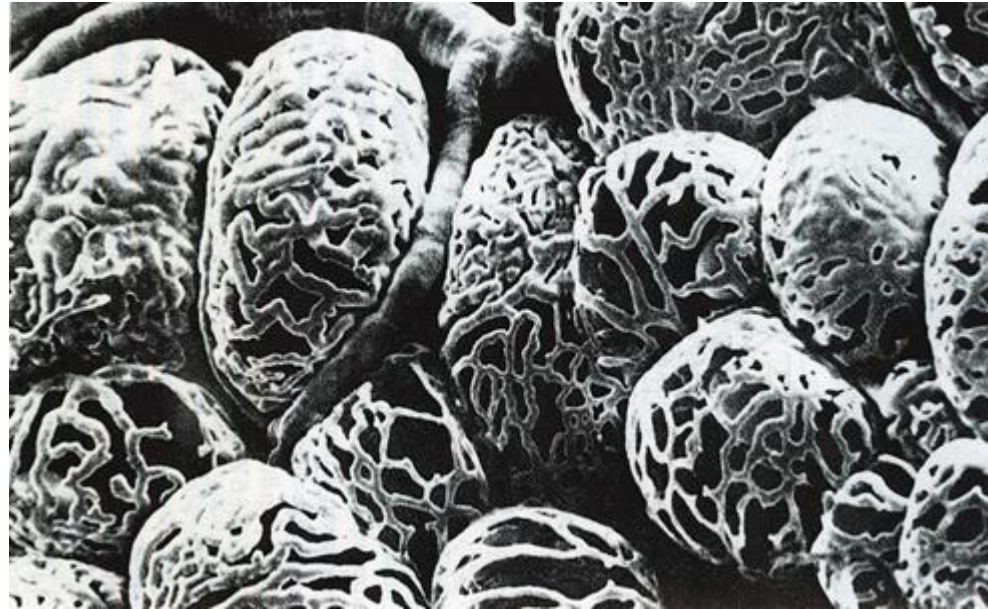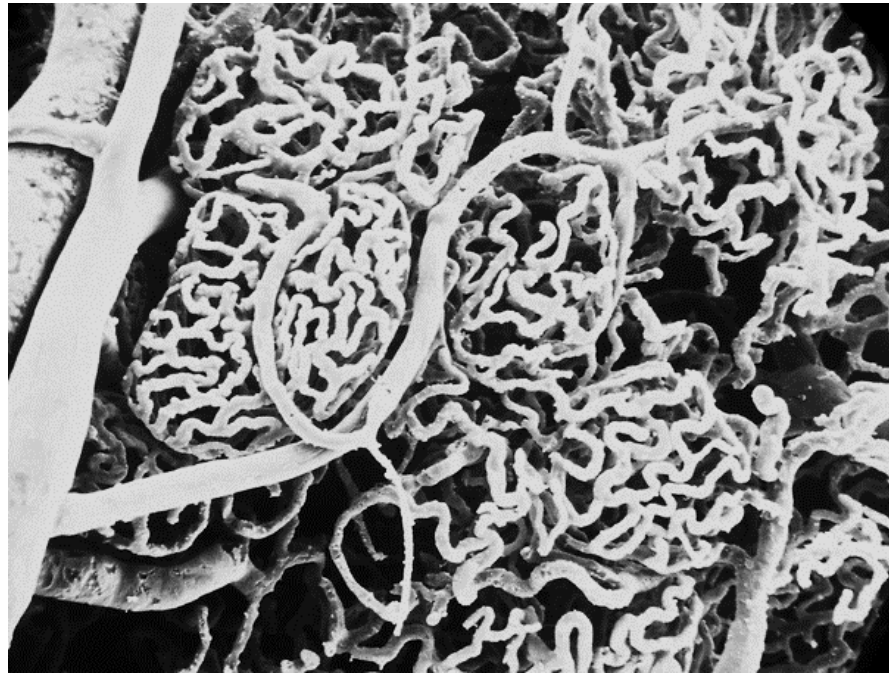koloid

20 µm

**Follicular cells and C-cells (parafollicular)**

# FOLLICLES OF THYROID GLAND

Capillaries around thyroid follicles



## T3 and T4

### T4 synthesis in thyroid

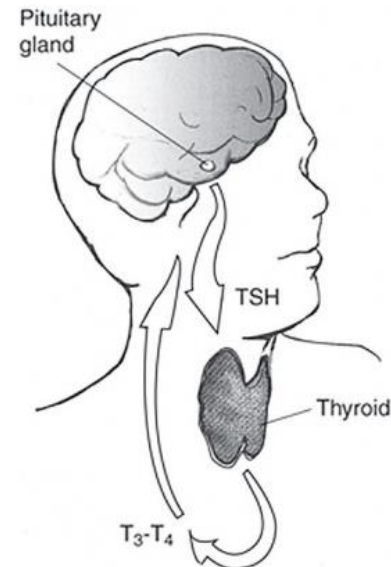
- sodium-iodide symporter transports two  $\text{Na}^+$  and one  $\text{I}^-$  across the basement
- $\text{I}^-$  is moved across the apical membrane into the colloid of the follicle.
- thyroperoxidase oxidises  $2 \text{I}^- \rightarrow \text{I}_2$ .
- thyroperoxidase iodinates the tyrosyl residues of thyroglobulin
- (TSH) stimulates the endocytosis of the colloidal content
- endocytic vesicles + lysosomes, lysosomal enzymes cleave  $\text{T}_4$  from the iodinated thyroglobulin
- exocytosis

### T3 synthesis from T4

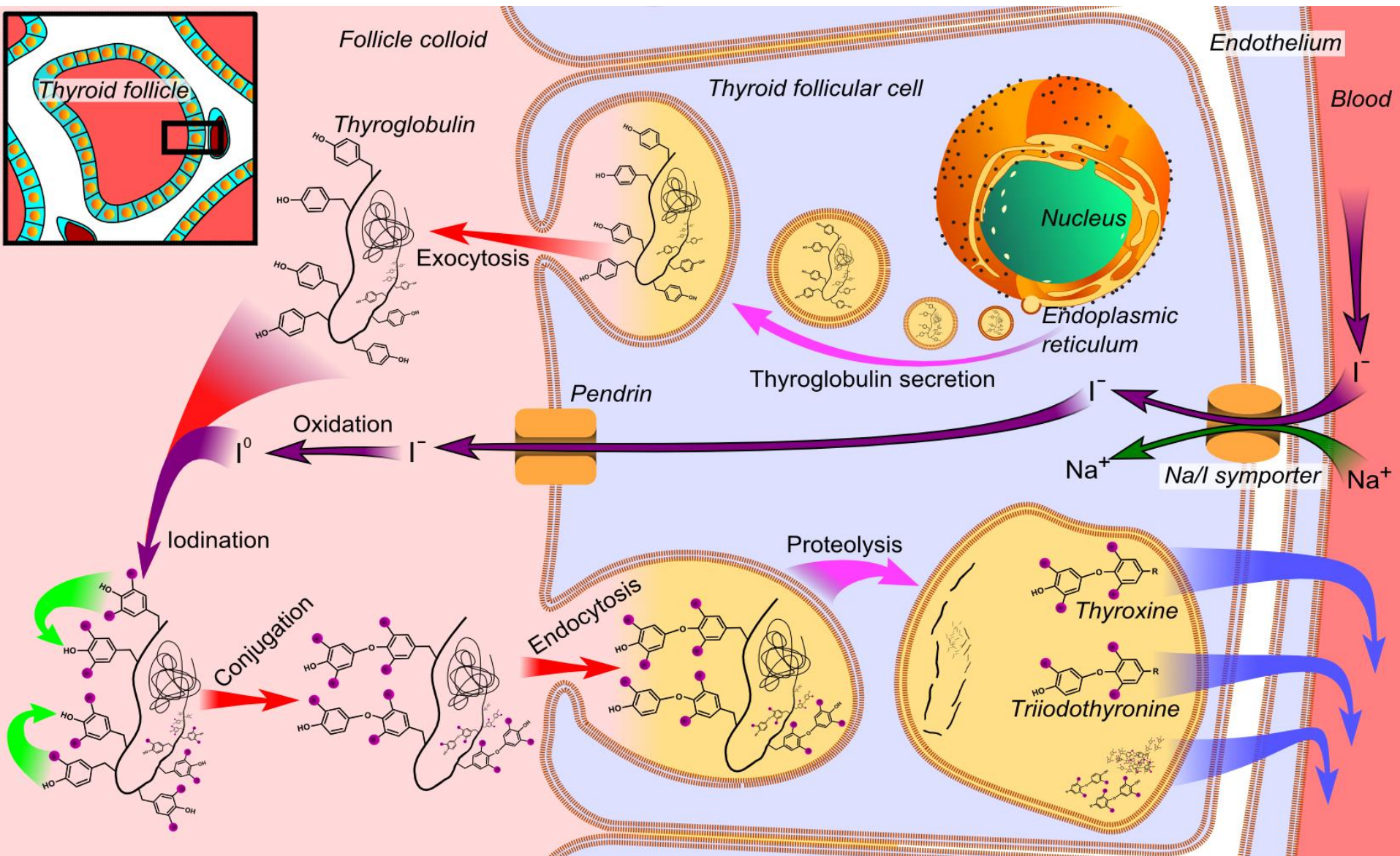
- T4 half-life in blood 6.5 days, T3 2.5 (T4 is a reservoir for T3)
- deiodination by tissue specific deiodinase enzymes generates T3

### Critical for brain development

### Metabolism (nitrogen balance, proteosynthesis, lipolysis)



# THYROID GLAND – T3 AND T4 HORMONES



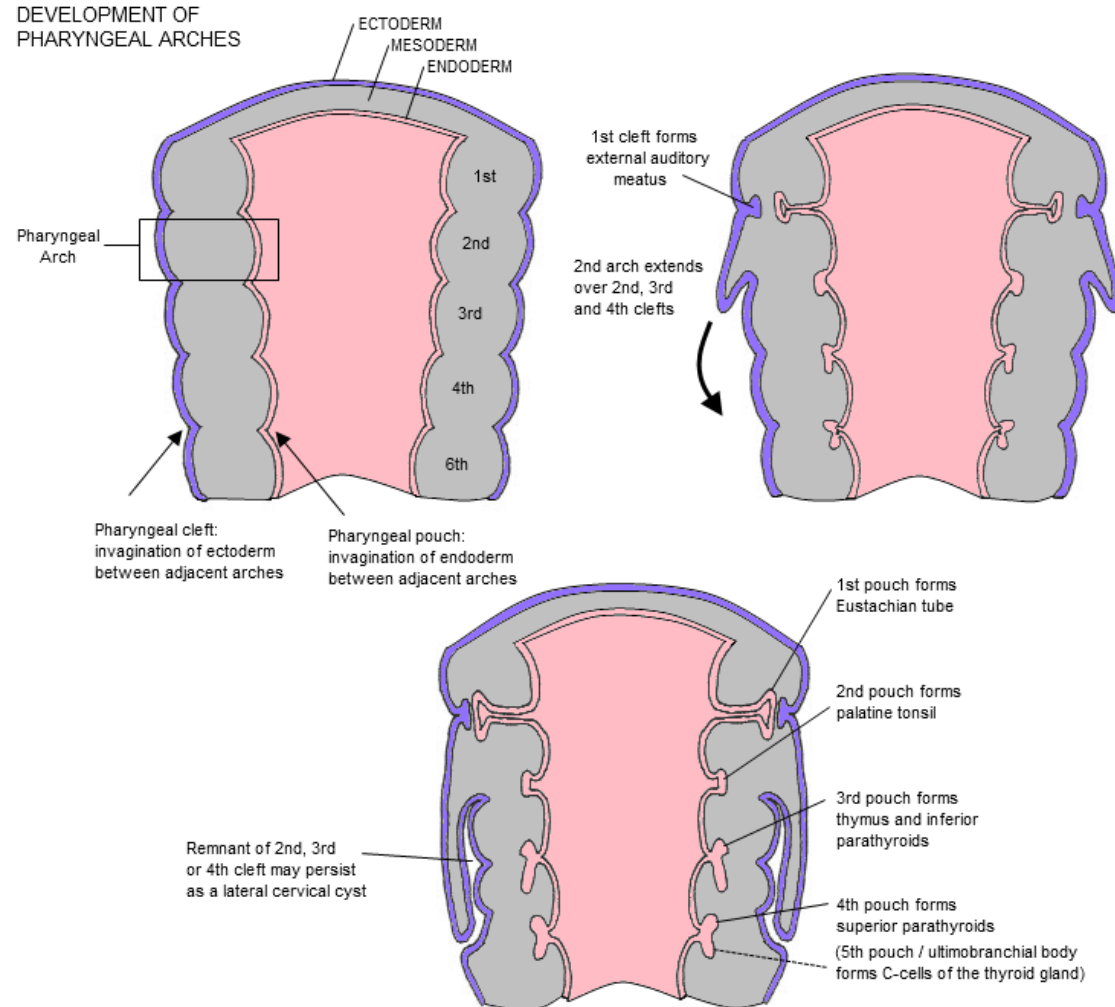
## C cells of thyroid

### Neuroendocrine cells

- pale staining
- epithelial basis, under basal lamina no contact with colloid
- derived from neural crest
- associate with ultimobranchial body, (derivative of the 4th pharyngeal pouch)

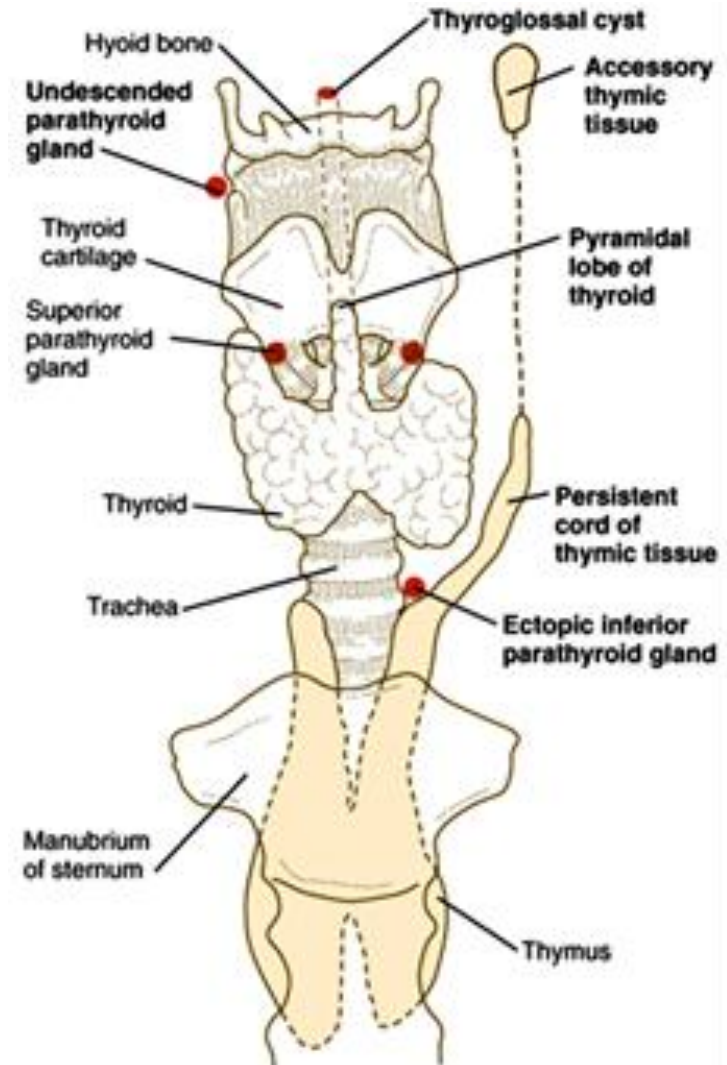
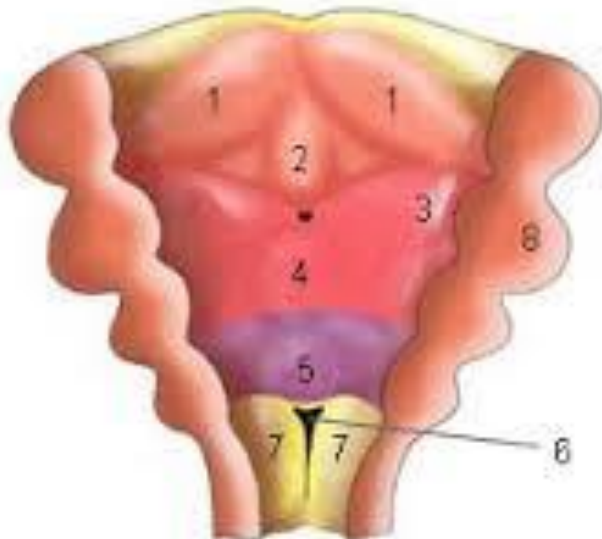
### Calcitonin

- inhibition of osteoclasts



# EMBRYONIC DEVELOPMENT OF THYROID GLAND

- endodermal proliferation of pharyngeal floor
- ductus thyreoglossus originates between tuberculum impar and copula
- bilobed diverticulum, lobus pyramidalis
- obliterated d. thyreoglossus – foramen caecum
- ectopic thyroid tissue



# PARATHYROID GLAND (GL. PARATHYREOIDEA)

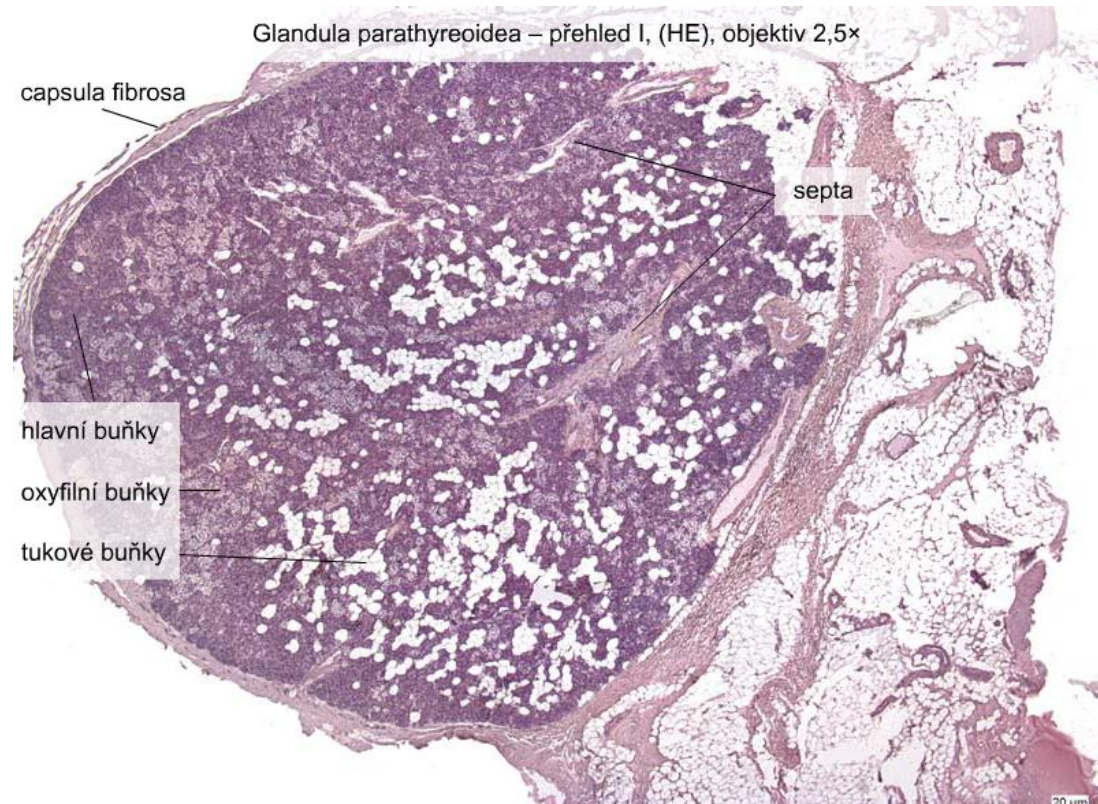
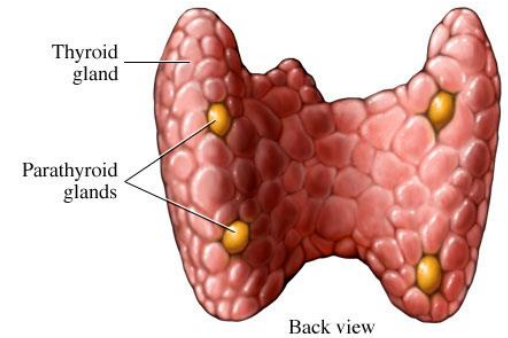
6 mm, 130 mg

c.t. capsule and septa

Capillary network

**Cords and clusters of glandular cells**

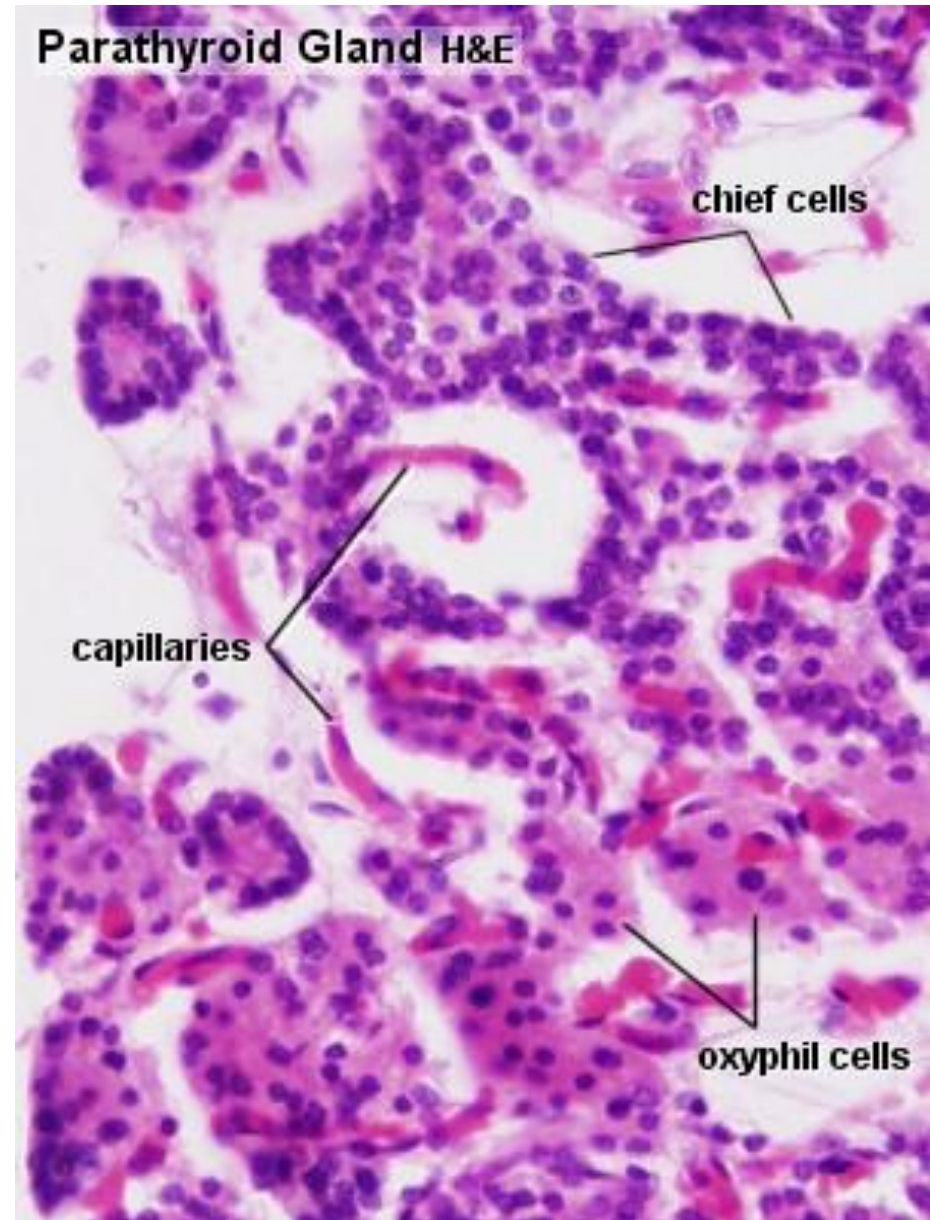
- Chief
- Oxyphilic
- Adipose



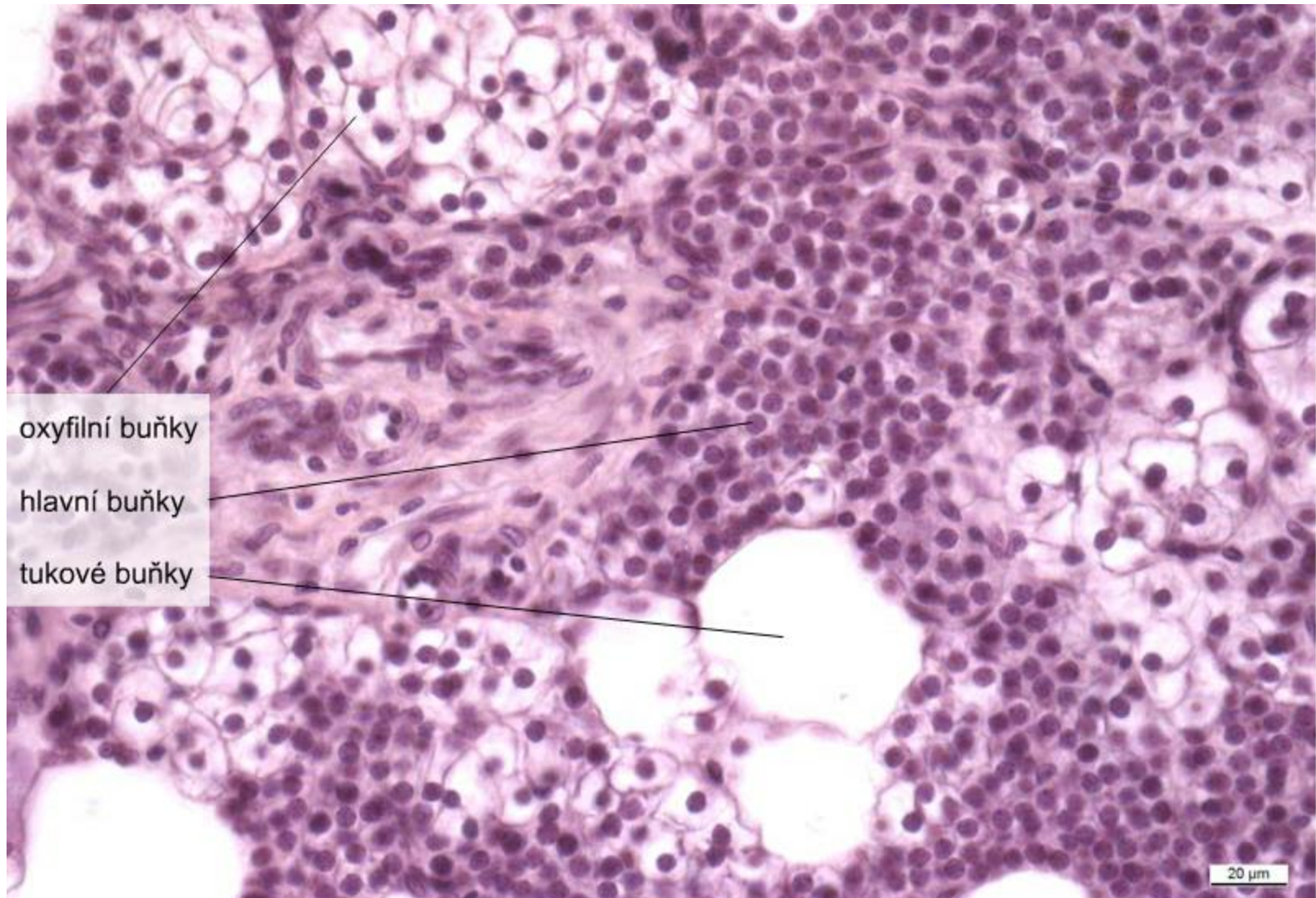


# PARATHYROID GLAND (GL. PARATHYREOIDEA)

- **Chief**
  - most abundant
  - small cells (7-10 $\mu$ m, big nucleus
  - mildly acidophilic
  - PTH – calcium metabolism
  
- **Oxyphylic**
  - large, polyhedral,
  - strongly acidophilic
  - round nucleus
  - glycogen

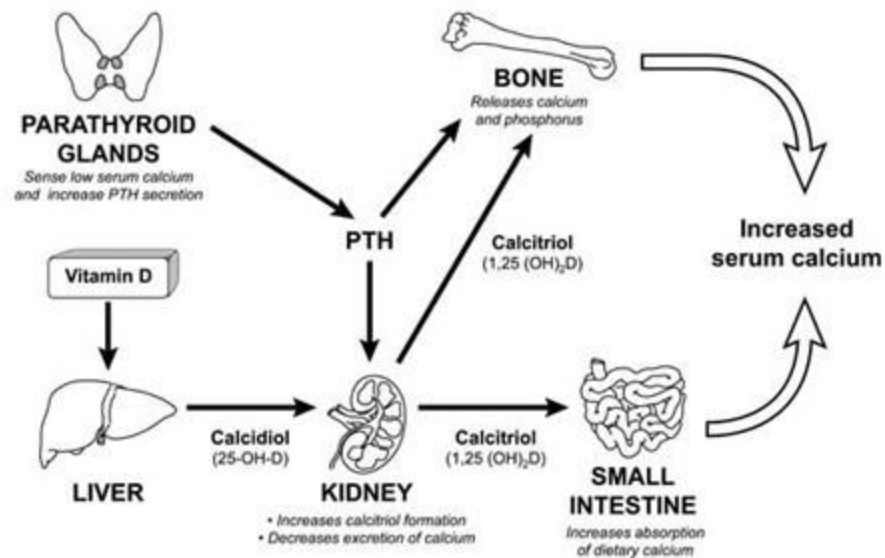
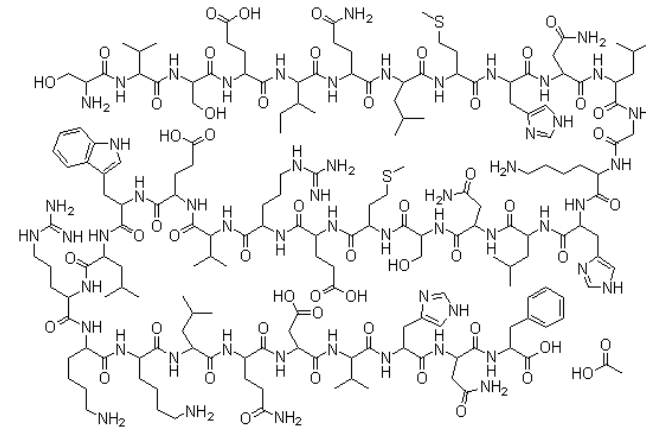


# PARATHYROID GLAND (GL. PARATHYREOIDEA)

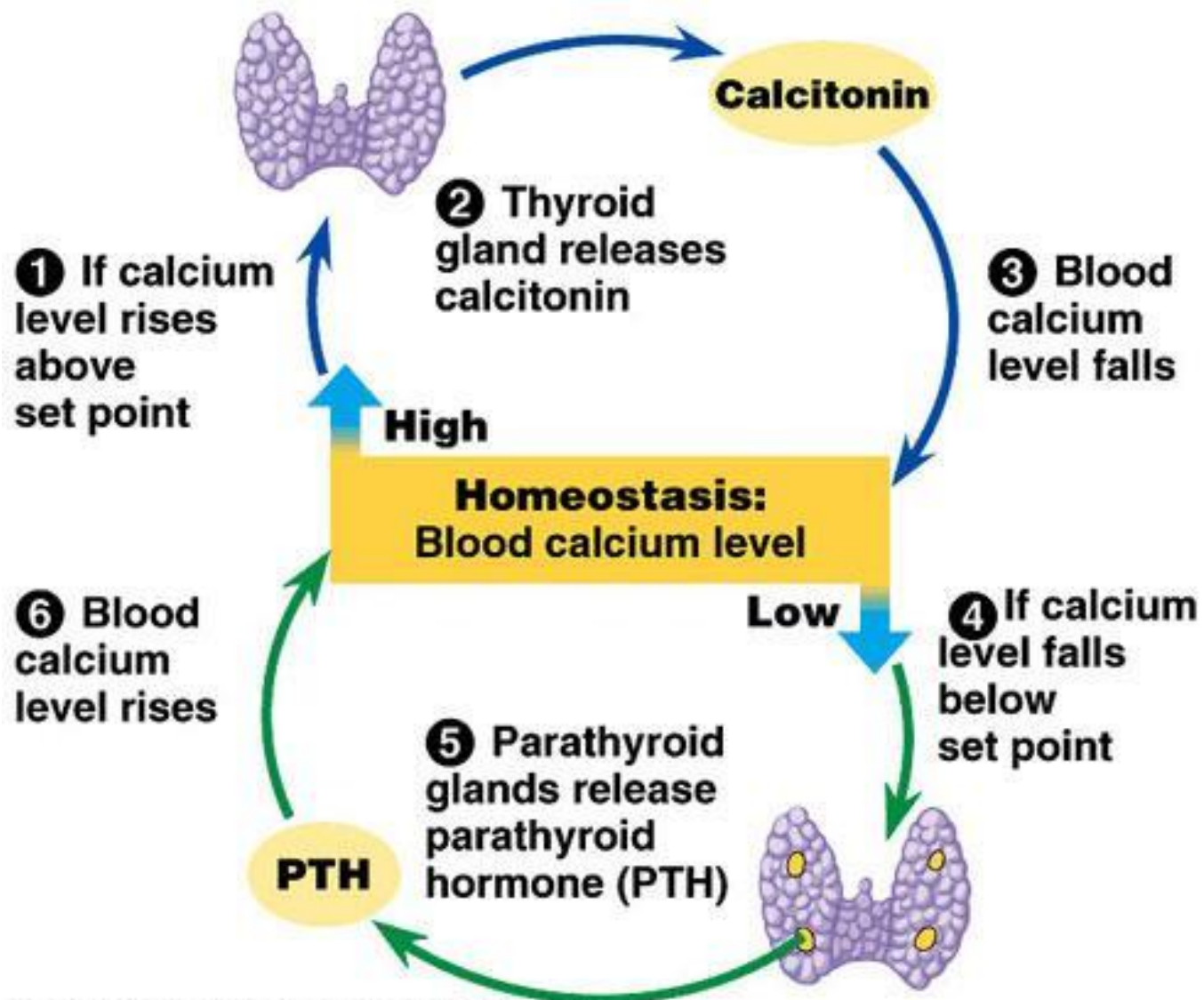


# PARATHYROID HORMONE (PTH, PARATHORMONE, PARATHYRIN)

- 84 aminoacids
- stimulates resorption by osteoclasts
- enhances resorption of calcium and magnesium in distal tubules and thick ascending limb
- enhances absorption in the intestine (via vD3)

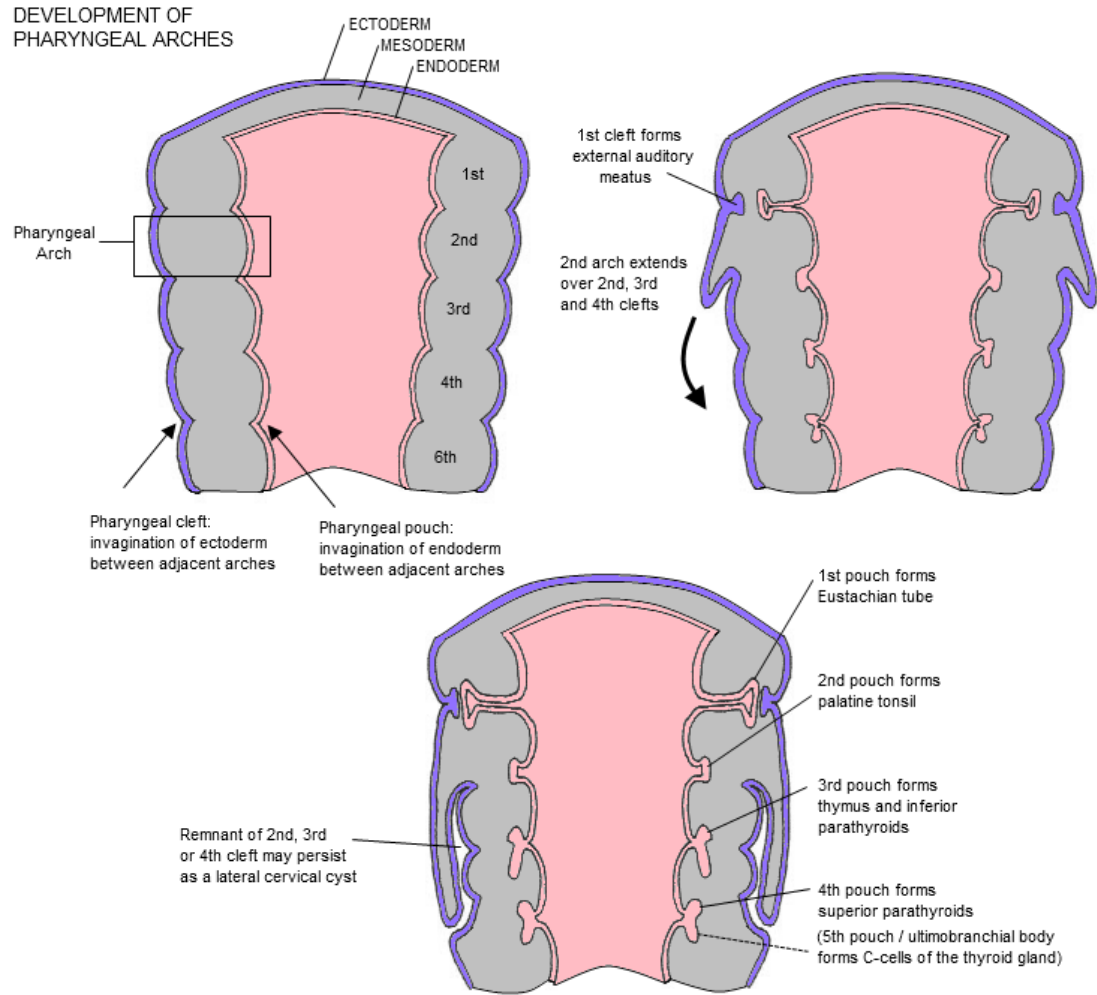


# PTH vs. CALCITONIN

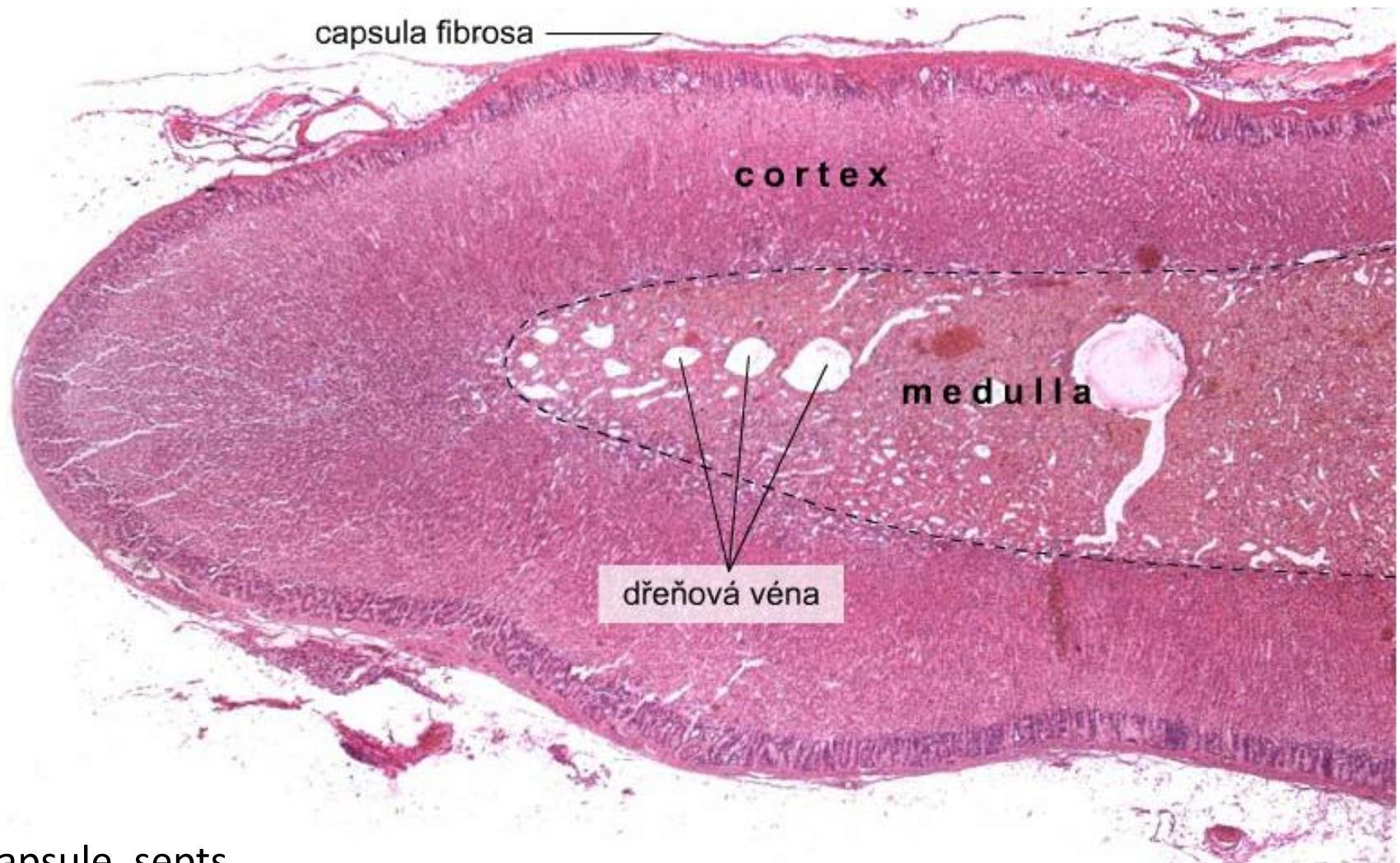


# EMBRYONIC DEVELOPMENT OF PARATHYROID GLAND

- *glandulae parathyroideae superiores* from endoderm of **4<sup>th</sup> pharyngeal pouch**
- *glandulae parathyroideae inferiores* from dorsal process of **3<sup>rd</sup> pharyngeal pouch**
- together with thymus descend to lower poles of thyroid
- ectopic PTH gland in thymus or mediastinum



# ADRENAL GLAND (*CORPUS SUPRARENALE*)



c.t. capsule, septs  
capillary plexus

# ADRENAL GLAND DEVELOPMENT

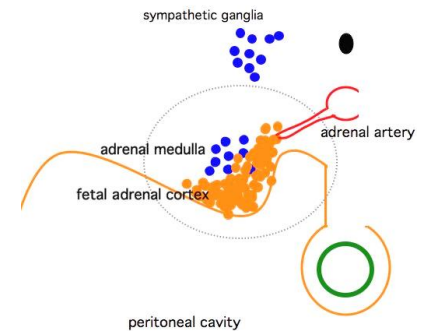
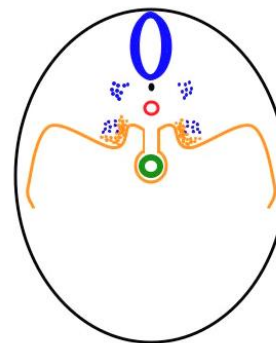
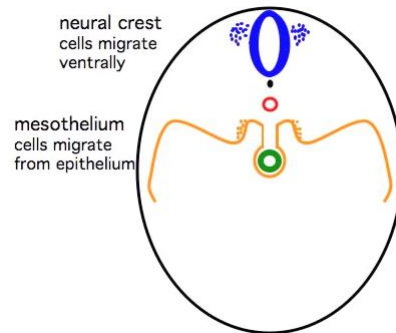
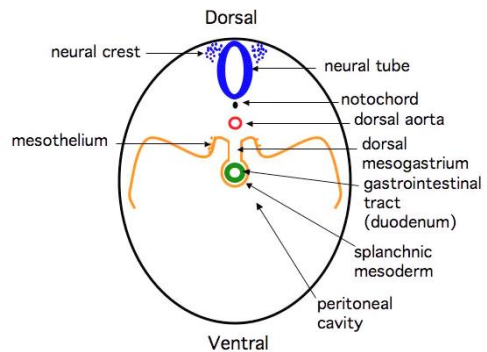
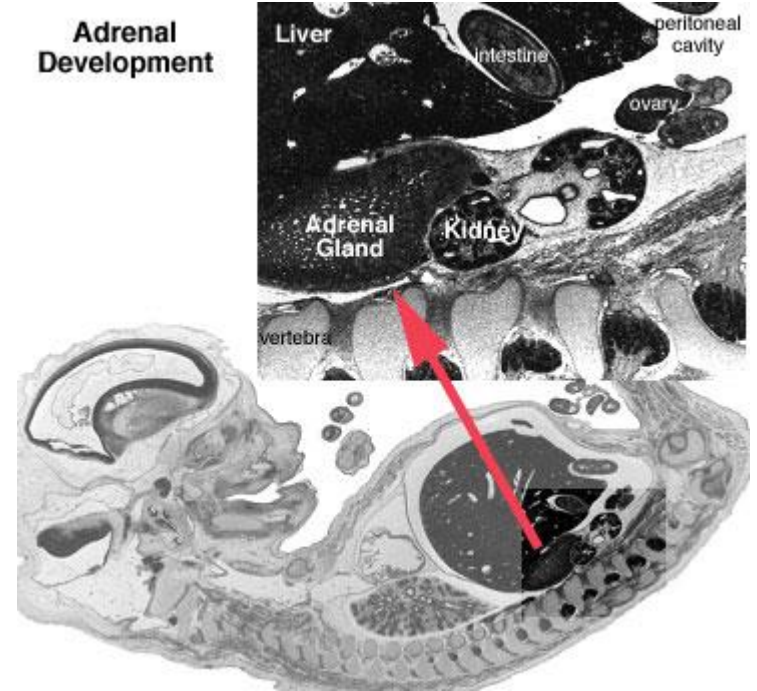
## cortex

- mesoderm
- mesothelium, coelomic epithelium

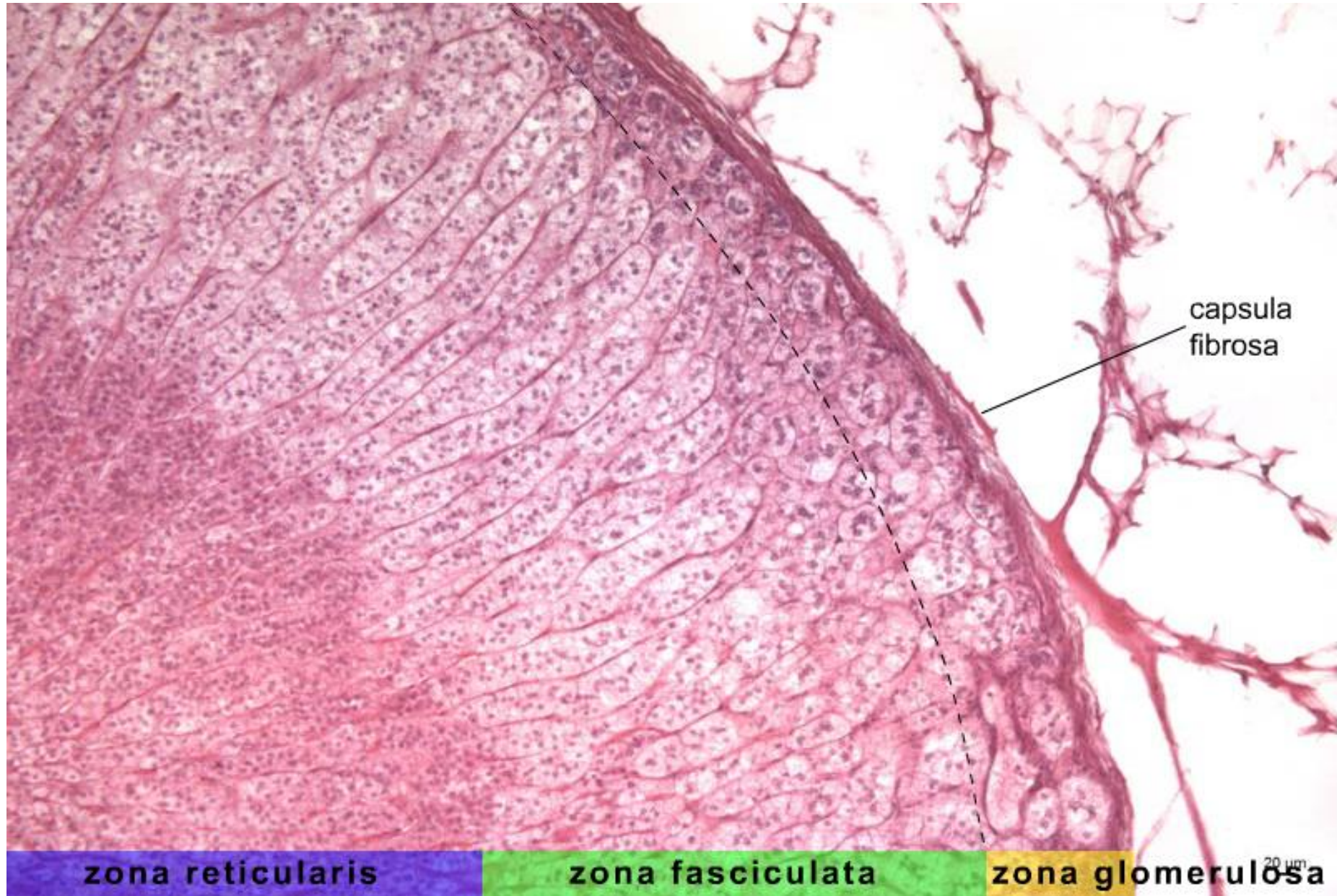
## medulla

- neural crest

Adrenal Development



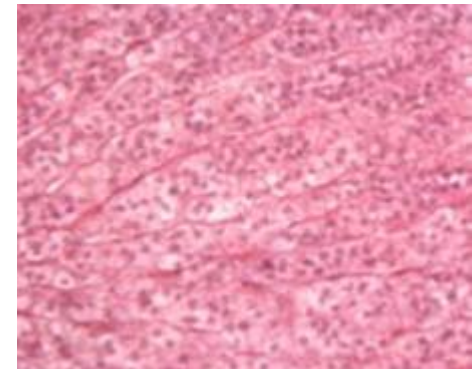
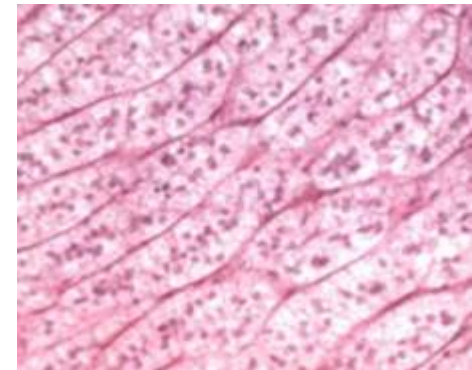
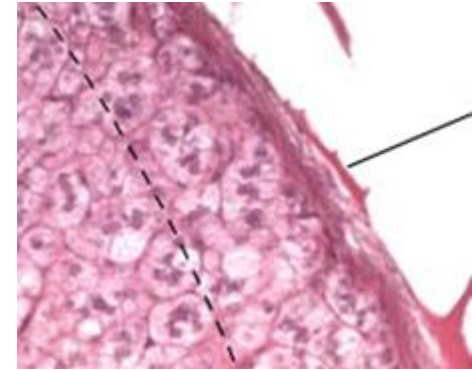
# ADRENAL CORTEX





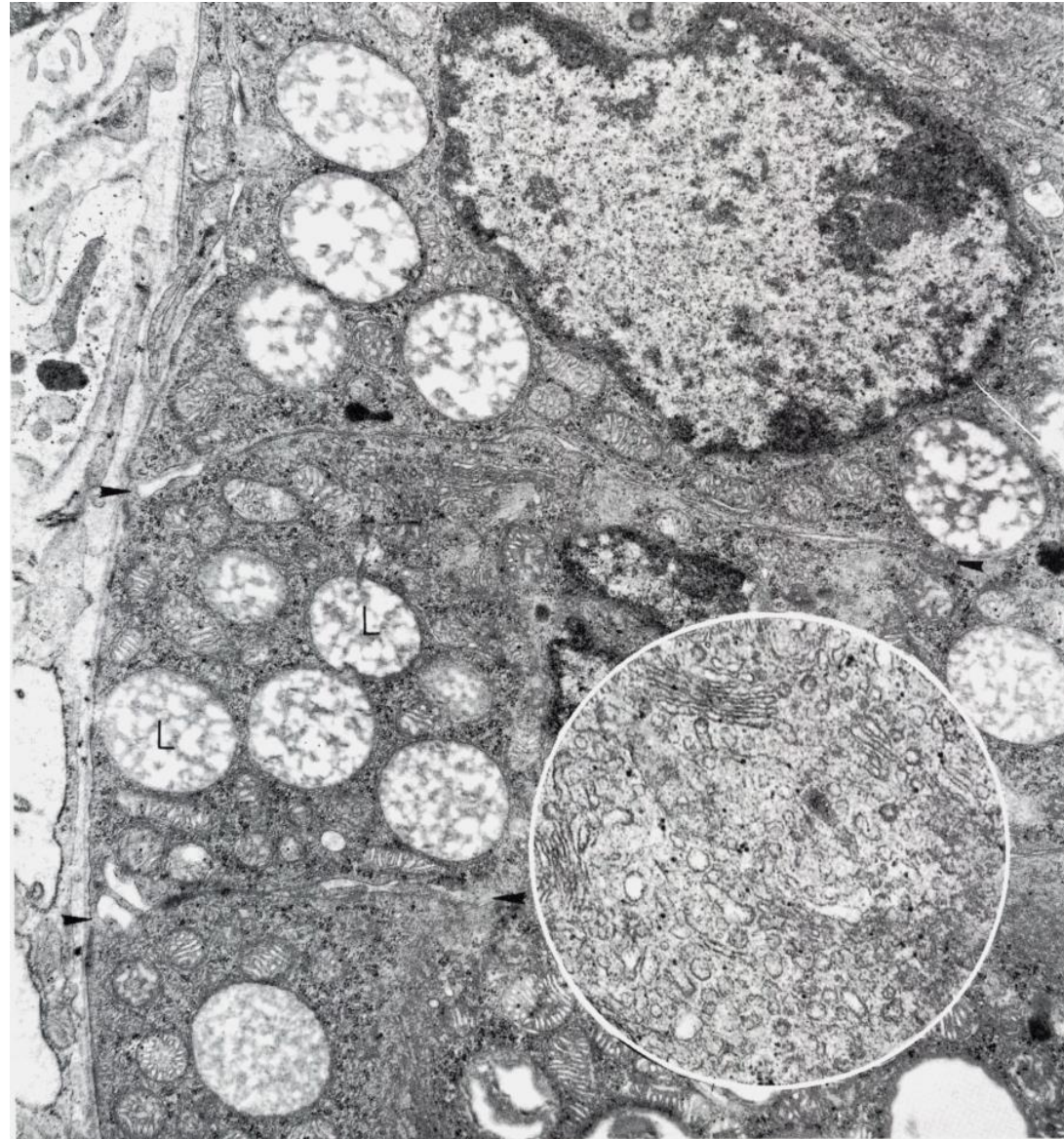# ADRENAL CORTEX

- **Zona glomerulosa (1/10)**
  - thin layer under c.t. capsule
  - relatively small cells in coiled glomeruli
  - not so abundant lipid droplets
  - **mineralocorticoids**
- **Zona fasciculata (6/10)**
  - radially arranged trabeculae
  - lipid droplets in cytoplasm
  - **glucocorticoids**
- **Zona reticularis (3/10)**
  - branched trabeculae
  - small, acidophilic cells
  - lipofuscin
  - **androgen precursors**

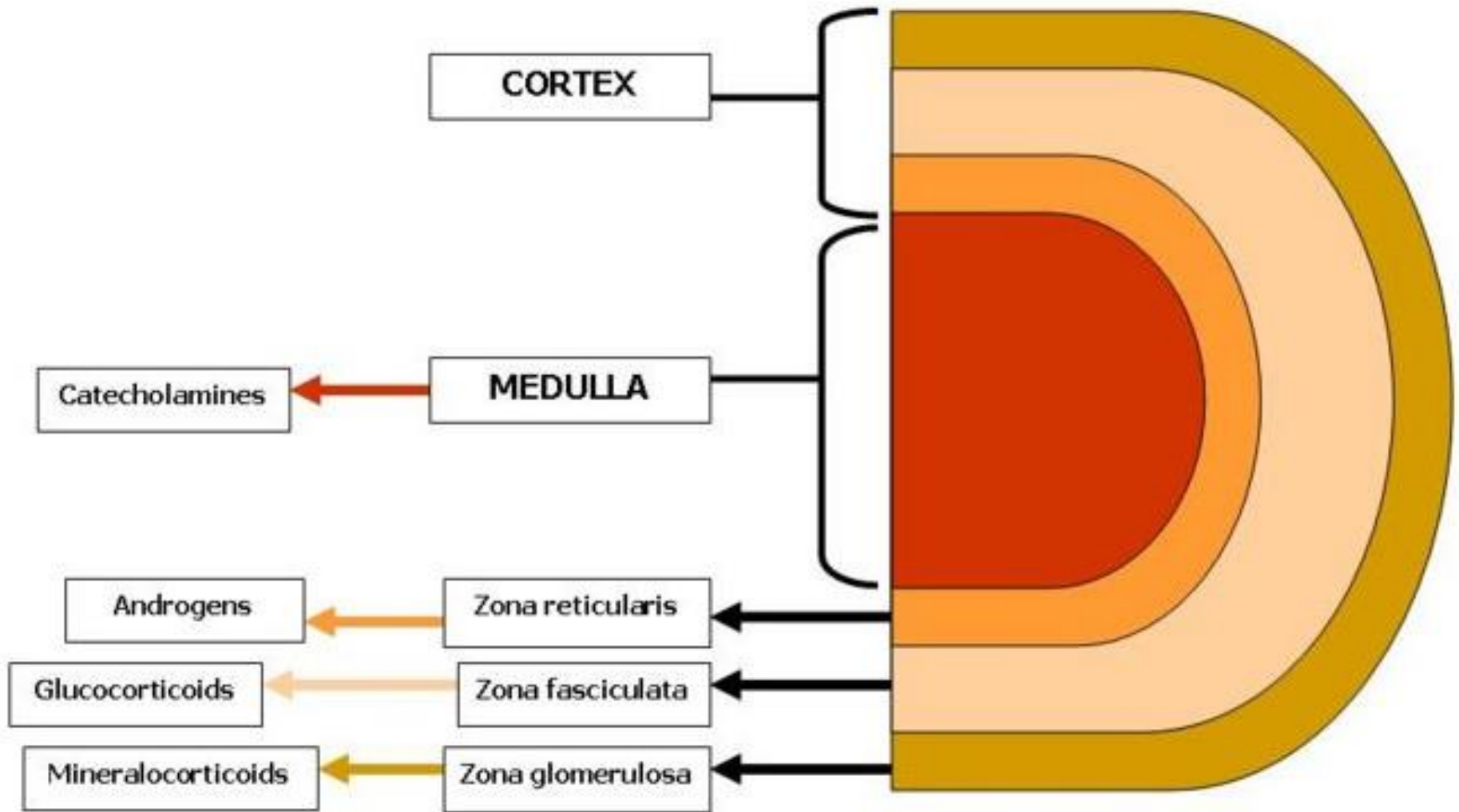


# ADRENAL CORTEX HORMONE

- Steroids produced in cortex = CORTICOSTEROIDS
- Steroidogenic cells
  - SER, lipid droplets, mitochondria
  - *mineralocorticoids*
  - *glucocorticoids*
- **Aldosteron** – *zona glomerulosa*
- **Cortisol** – *zona fasciculata*
- **Androgens, estrogens, progesteron** – *zona reticularis*



# ADRENAL HORMONES

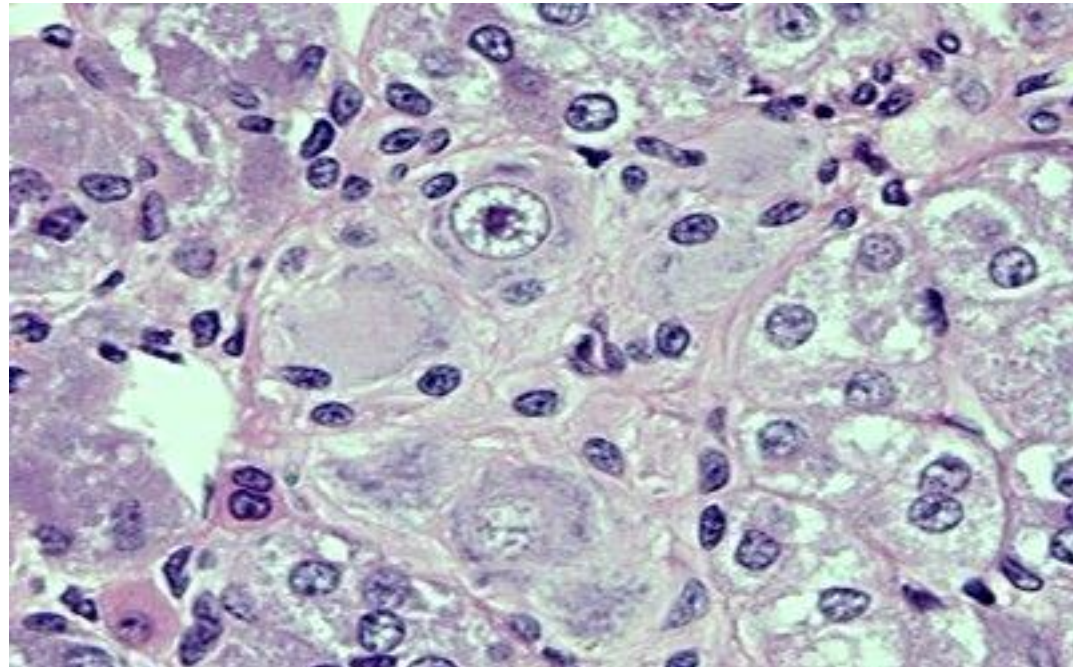


# ADRENAL MEDULLA

Clusters of glandular cells in reticular c.t.

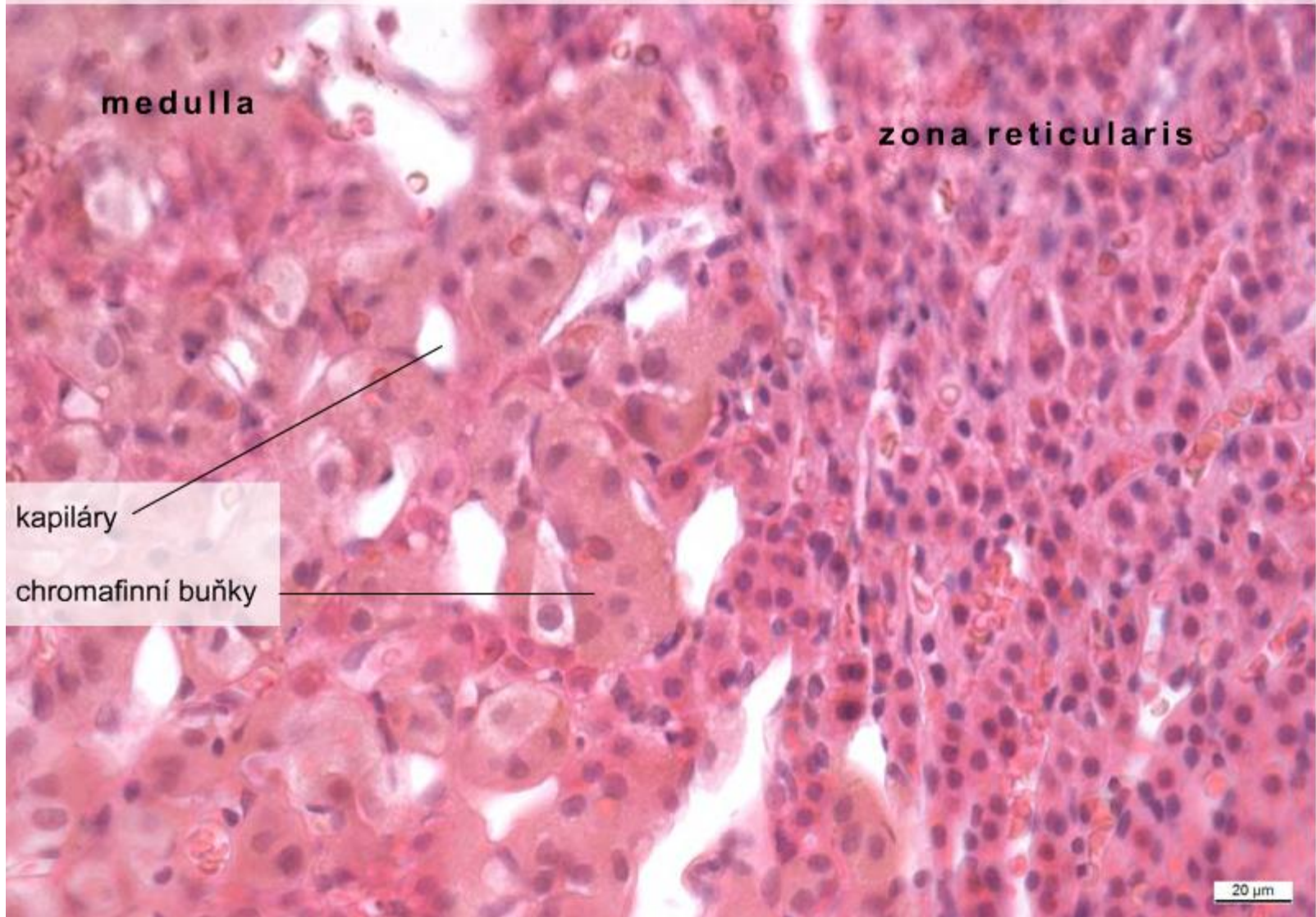
- chromaffin cells – modified postganglionic neurons
- ganglionic cells
- capillaries, venules, nerve fibers
- **adrenaline and noradrenaline**

**Neural crest origin**



# ADRENAL MEDULLA

Corpus suprarenale – medulla, (HE), objektiv 40×



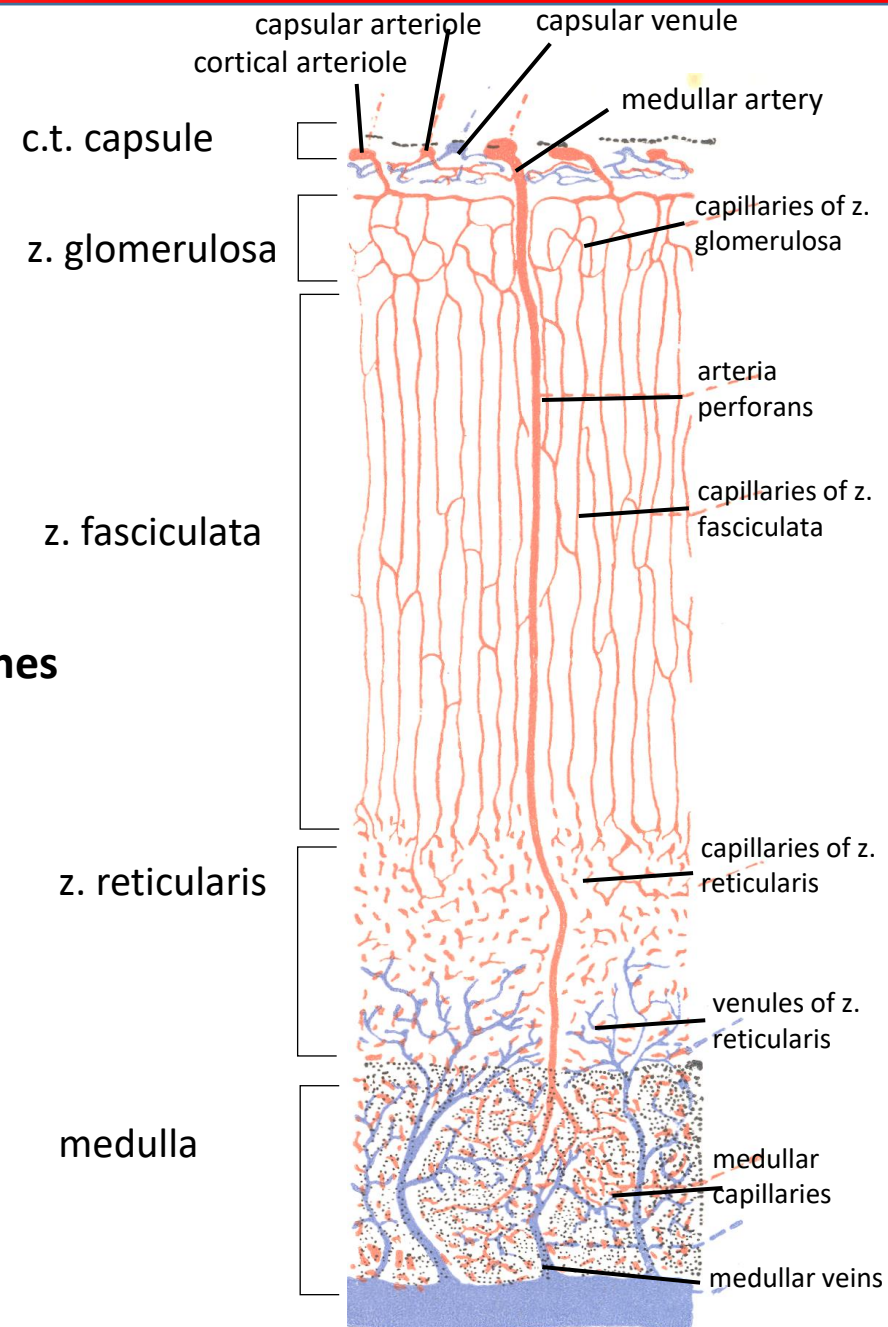
# ADRENAL VASCULARISATION

*arteriae suprarenales* (3) → arterial plexus in cortex under c.t. capsule → radially oriented fenestrated sinusoid capillaries continuous with medullar capillaries → medullar veins → *v. suprarenalis*

→ Medullary cells influenced by cortical hormones

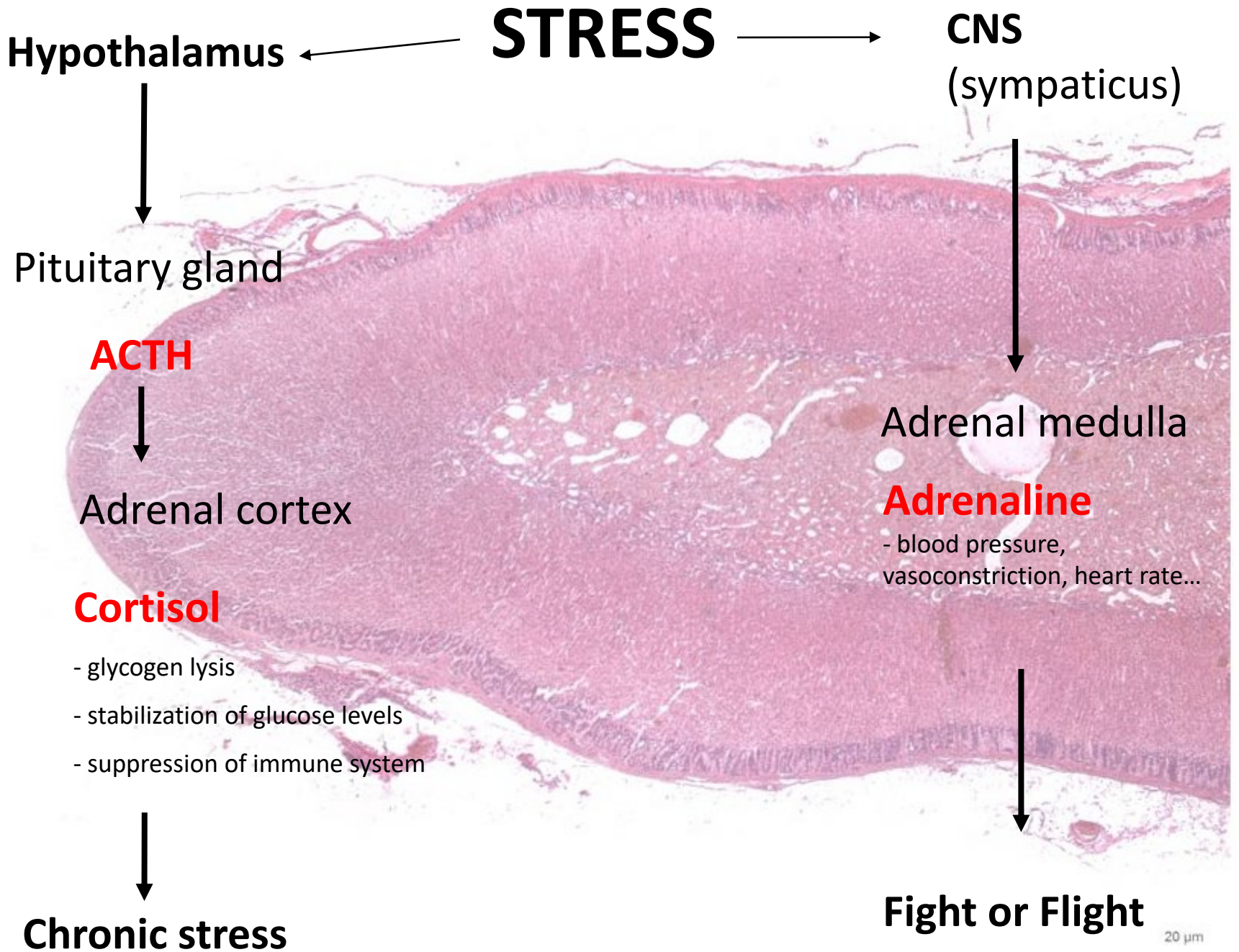
## three arterial regions

- 1) c.t. capsule and superior parts of cortex
- 2) radial capillaries of cortex continuing to medulla
- 3) medullar capillaries from *aa. perforantes*



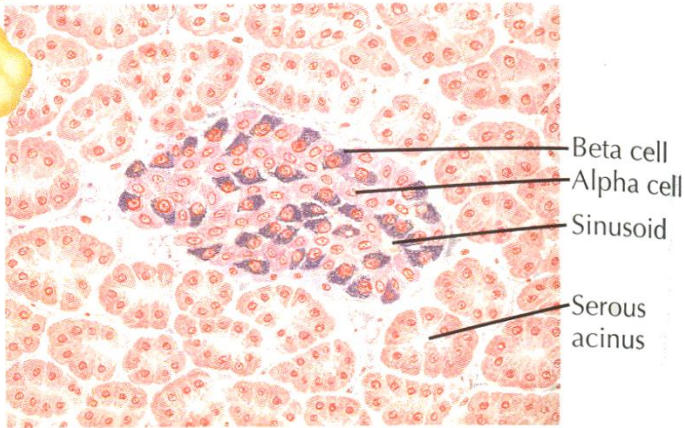
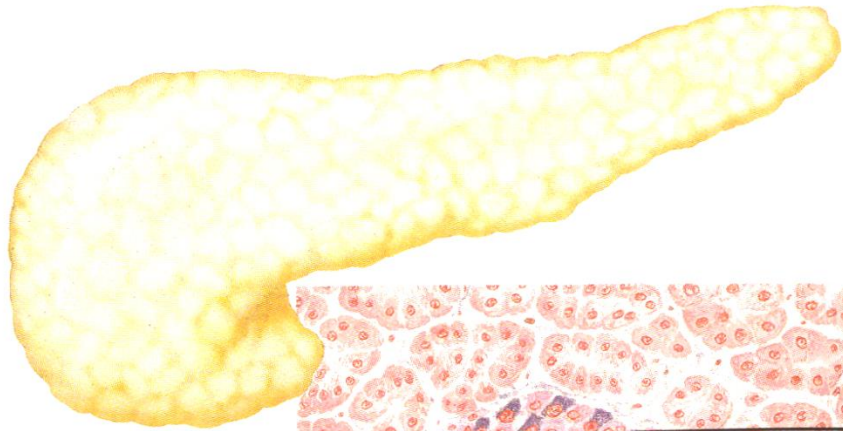
# Adrenal hormones

Region (zone)		Hormone	Target tissue	Hormonal effect	Control
<b>Cortex</b>	Zona glomerulosa	Mineralocorticoids (aldosteron)	Kidney	Increased renal reabsorption of Na <sup>+</sup> and water Synergic to ADH Excretion of K <sup>+</sup>	renin-angiotensin system, high level of K <sup>+</sup> low level of Na <sup>+</sup>
	Zona fasciculata	Glucocorticoids (hydrocortison)	Most cells	Release of aminoacids from muscles and lipids from fat tissue, peripheral utilization of lipids, antiinflammatory effects	Stimulation by ACTH
	Zona reticularis	Androgens (dehydroepiandrosterone)	Most cells	In adult males not significant Children and women growth of bones, muscles, hematopoiesis	Stimulation by ACTH
<b>Medulla</b>		Epinefrine, norepinefrine	Most cells	Increased heart activity, centralization of circulation, bronchodilatation, glycogenolysis, regulation of glycemia	Sympaticus





# ISLETS OF LANGERHANS



**Paul Langerhans**  
1847 – 1888)

Beiträge  
zur mikroskopischen Anatomie der  
Bauchspeicheldrüse.

INAUGURAL-DISSERTATION,

zur  
ERLANGUNG DER DOCTORWÜRDE

IN DER

**MEDICIN UND CHIRURGIE**

VORGELEGT DER

MEDICINISCHEN FACULTÄT

DER FRIEDRICH-WILHELMS-UNIVERSITÄT

ZU BERLIN

UND ÖFFENTLICH SO VORZULESEN

am 18. Februar 1869

VON

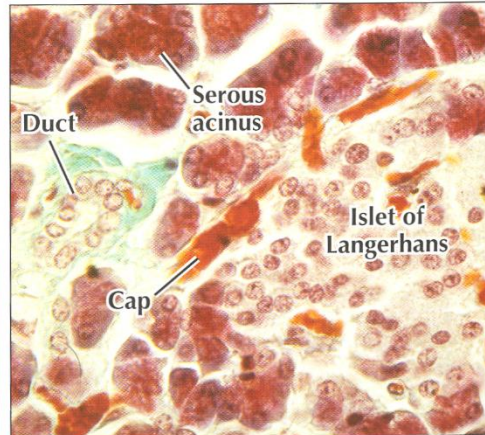
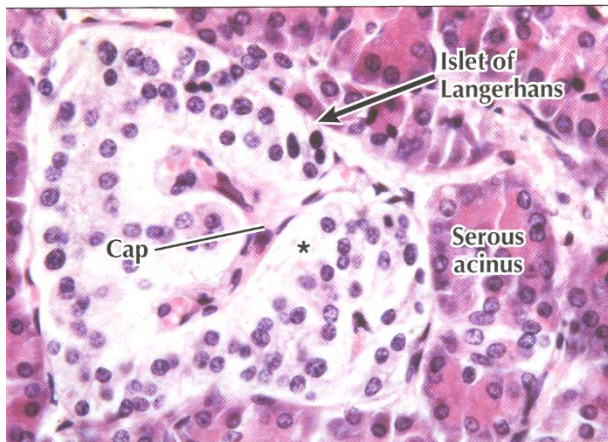
**Paul Langerhans**  
aus Berlin.

OPPONENTEN:

O. Locillet de Mars, Dd. med.  
O. Soltmann, Dd. med.  
Paul Ruge, Stud. med.

BERLIN.

BLUMBERGER STRASSE VON CUSTAV LANGBE.



# ISLETS OF LANGERHANS



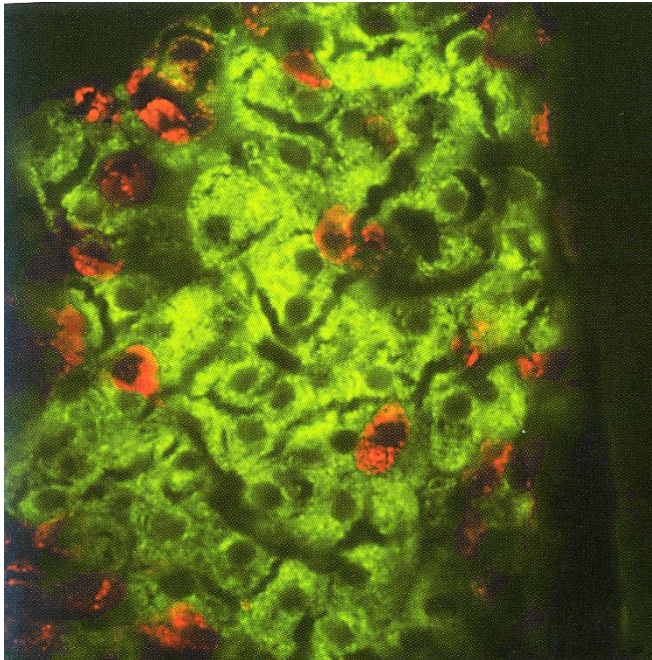
Laguesse E. Sur la formation des ilots de Langerhans dans le pancreas. Comptes Rend SocBiol **1893**;5 (Series 9k.819-20



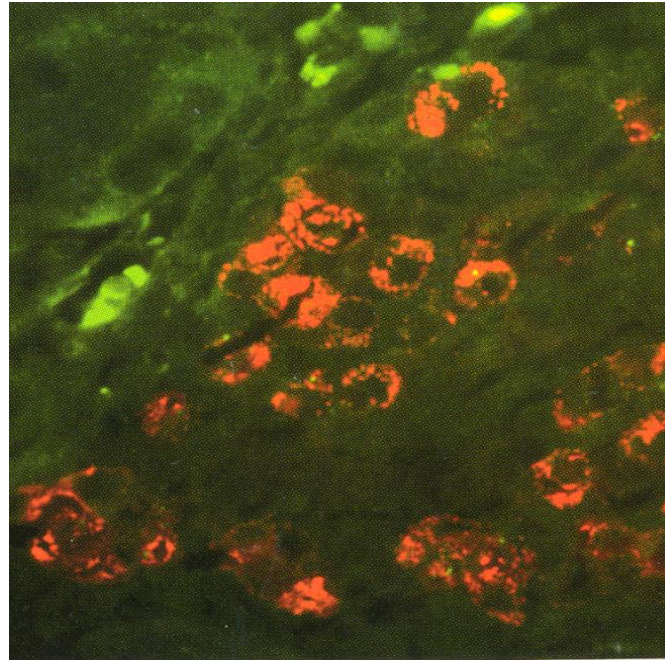
On July 27, **1921**, Sir Frederick Banting and Charles Best succeeded in isolating insulin from canine pancreases and thereby discovered the first effective treatment for diabetes mellitus.

# ISLETS OF LANGERHANS

HEALTHY



DIABETES TYPE I



B-cells producing insulin



Ab-anti insulin –Alexa Fluor

A-cells producing glucagon



Ab-anti glukagon –Texas Red



Thank you for  
attention

Comments and questions:

[pvanhara@med.muni.cz](mailto:pvanhara@med.muni.cz)