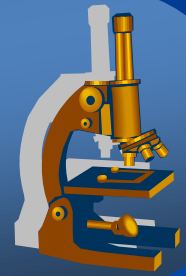
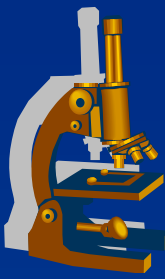


General pathology III.

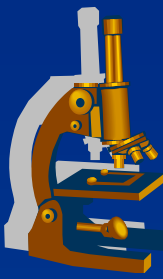


Inflammation II. (proliferative,
granulomatous).
Progressive changes.
General oncology.



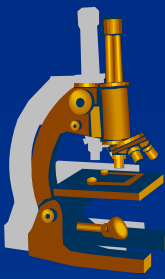
Inflammation II.

Proliferative inflammation



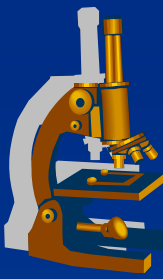
- ✗ Healing (reparation) of defects (wound, regressive changes, postinflammatory etc.) → granulation tissue → scar
- ✗ often pronounced in chronic inflammation
- ✗ primary proliferative inflammation uncommon (fibromatosis)
- ✗ reactive fibro/myofibroblastic lesions
 - ⇒ *proliferation of myofibroblasts, occasionally forming tumour-like masses*
 - nodular fasciitis, myositis ossificans – may be posttraumatic, often idiopathic

Chronic inflammation



- ✗ prolonged duration
- ✗ tissue injury + inflammatory reaction + repair
- ✗ Causes: persistent infection, immune mediated inflammatory reaction, prolonged exposure to harmful agents (toxin)

Granulation tissue



- × Major repair instrument

- × In:

 - ⇒ *wound, fracture, ulcer, necrosis healing; thrombus, haematoma organisation*

- × Gross:

 - ⇒ *soft red tissue, granular surface (capillary loops)*

- × Micro:

 - ⇒ *fibrin fibers*

 - ⇒ *inflammatory reaction*

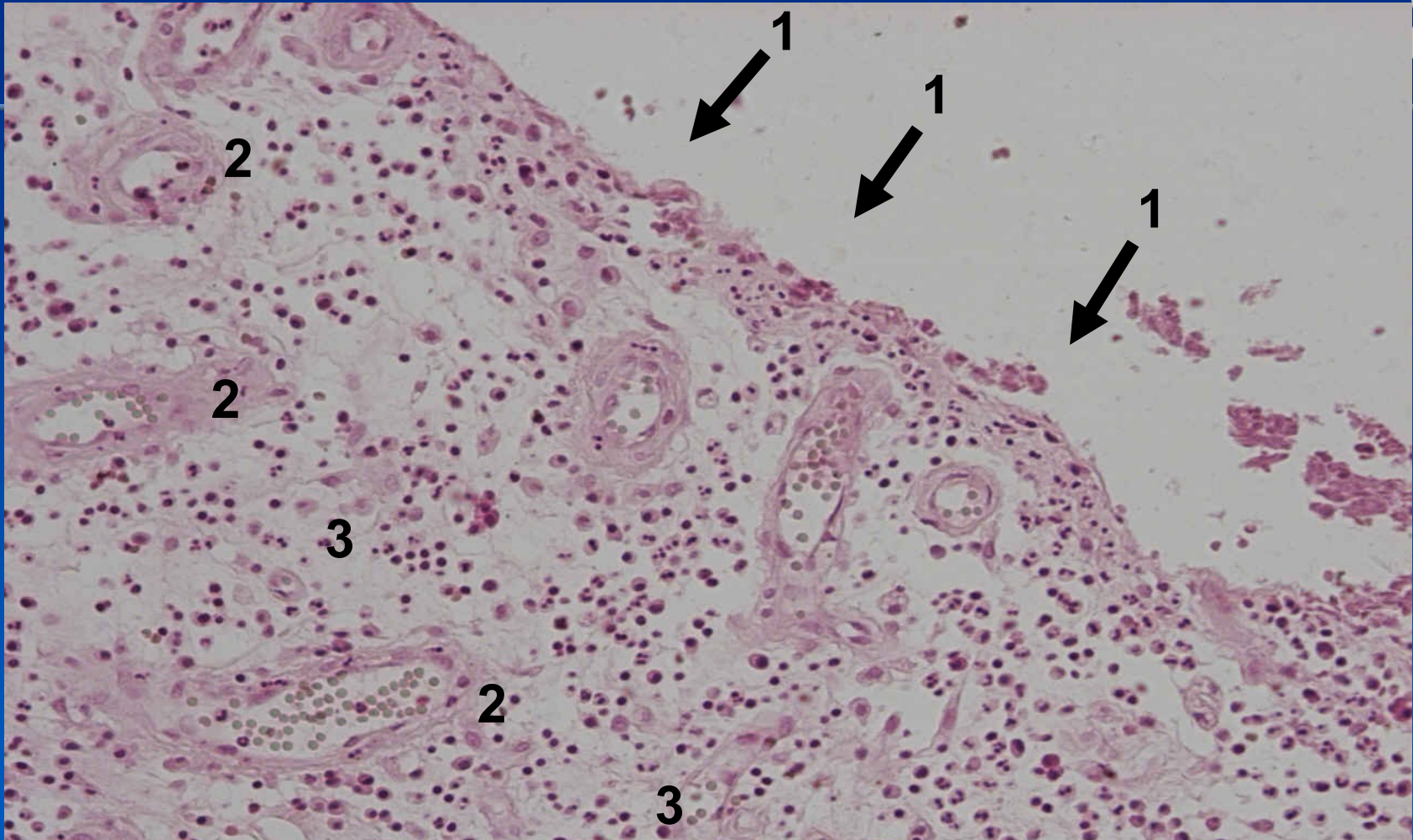
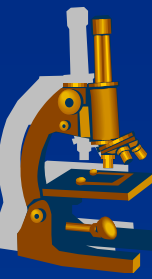
 - ⇒ *fibroblasts, myofibroblasts*

 - ⇒ *starting collagen fibers production*

 - ⇒ *proliferating capillaries – angiogenesis*

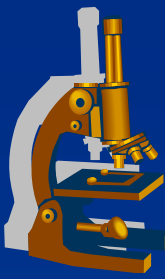
 - ⇒ *later intercellular matrix + tissue remodeling, retraction – scar formation*

Granulation tissue – inflammatory cells



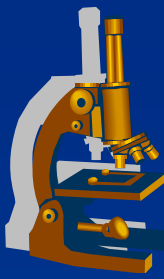
- 1** surface
- 2** proliferation of capillaries
- 3** tissue with inflammatory cells

Granulomatous inflammation



- × **distinctive pattern of chronic inflammation**
- × **historical classification:**
 - ⇒ „*non-specific*“ *infl.*
 - common general microscopic picture, i.e. purulent infl.
 - ⇒ *specific*“
 - micro typical for a specific cause
- × **aggregated macrophages unable to destroy cause → transformation into epithelioid and multinuclear cells → granuloma**
- × **delayed type hypersensitivity (T-cells, macrophages, sometimes eosinophils)**
- × **foreign body granuloma x immune granuloma**

Granulomatous inflammation



× causes of granulomatous disease:

⇒ specific infections

- mycobacteria (e.g. Tuberculosis, leprosy, atypical mycobacteria), many types of fungi, parasites...)

⇒ foreign bodies (undigestible)

- endogenous (keratin, necrotic bone, cholesterol crystals, urate ...)
- exogenous (e.g. suture material, silica, talc, asbestos,...)

⇒ chemicals and drugs

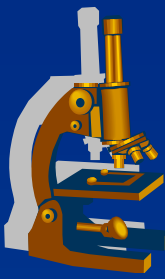
- beryllium, sulphonamides

⇒ unknown ? - pathologic hypersensitive reaction to some common antigens (combination of inborn and external factors)

- Crohn's disease, sarcoidosis, Wegener's granulomatosis

⇒ stromal and lymph node reaction in some tumors (Hodgkin's malignant lymphoma)

Tuberculosis



x etiology

⇒ *Mycobacterium tuberculosis*

- Ziehl-Neelsen staining, acid-resistant bacteria , culture or PCR detection

x tuberculous granuloma - basic morphology:

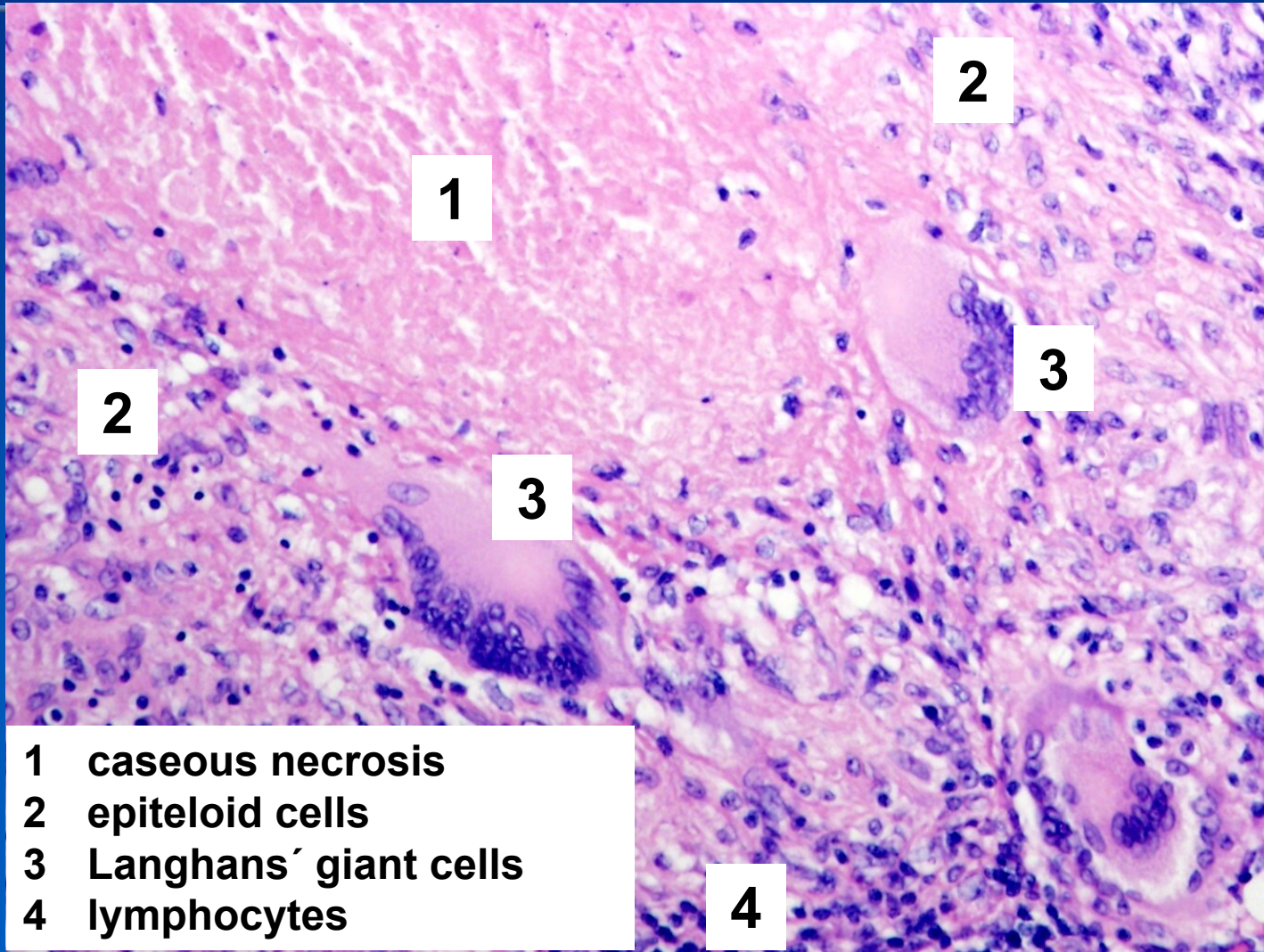
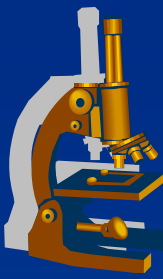
⇒ central caseous necrosis (basophilic nuclear fragments)

⇒ epithelioid macrophages

⇒ multinucleated Langhans' giant cells (fusion of macrophages)

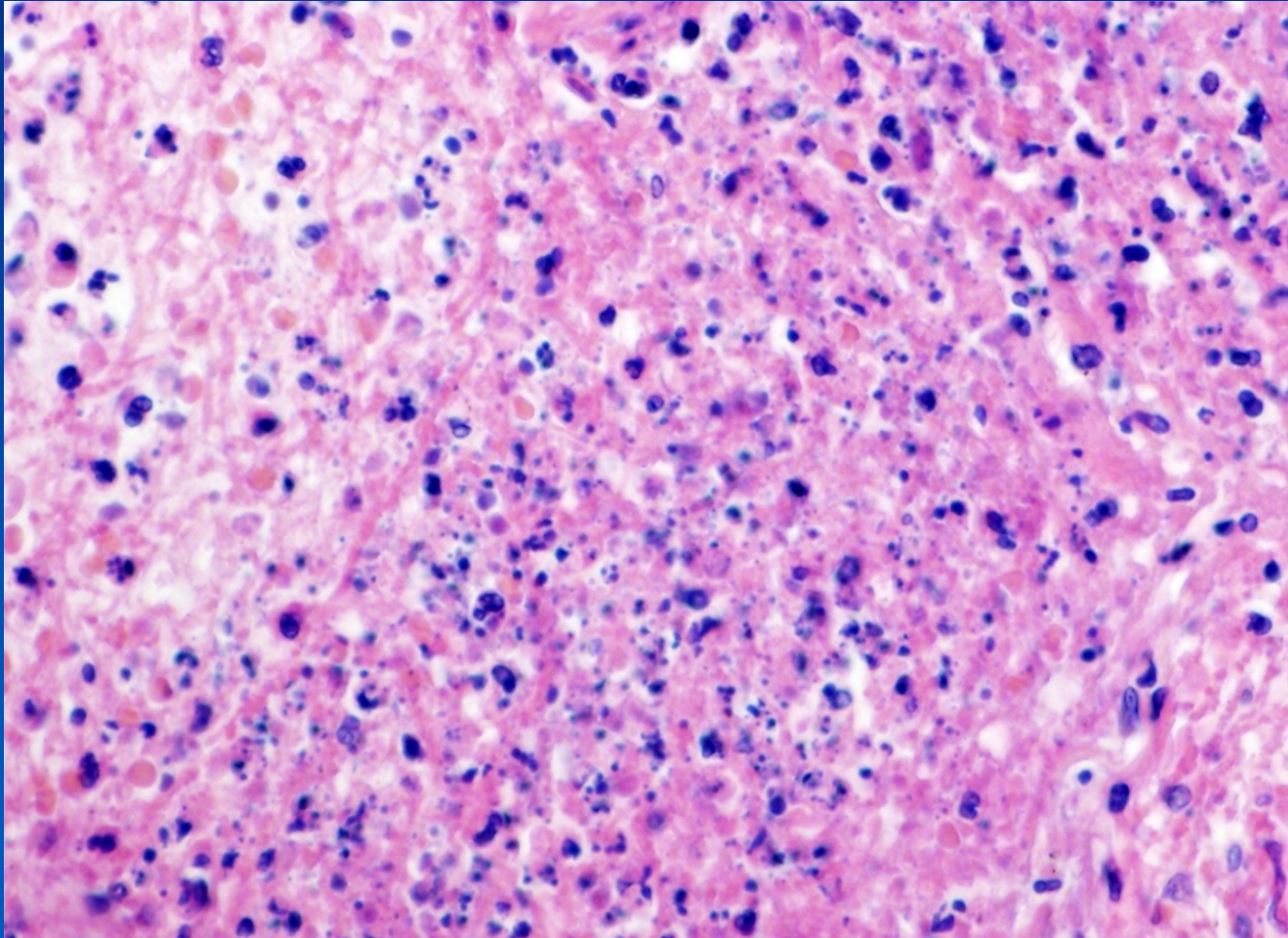
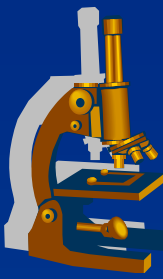
⇒ rim of T-cells

Tuberculous granuloma



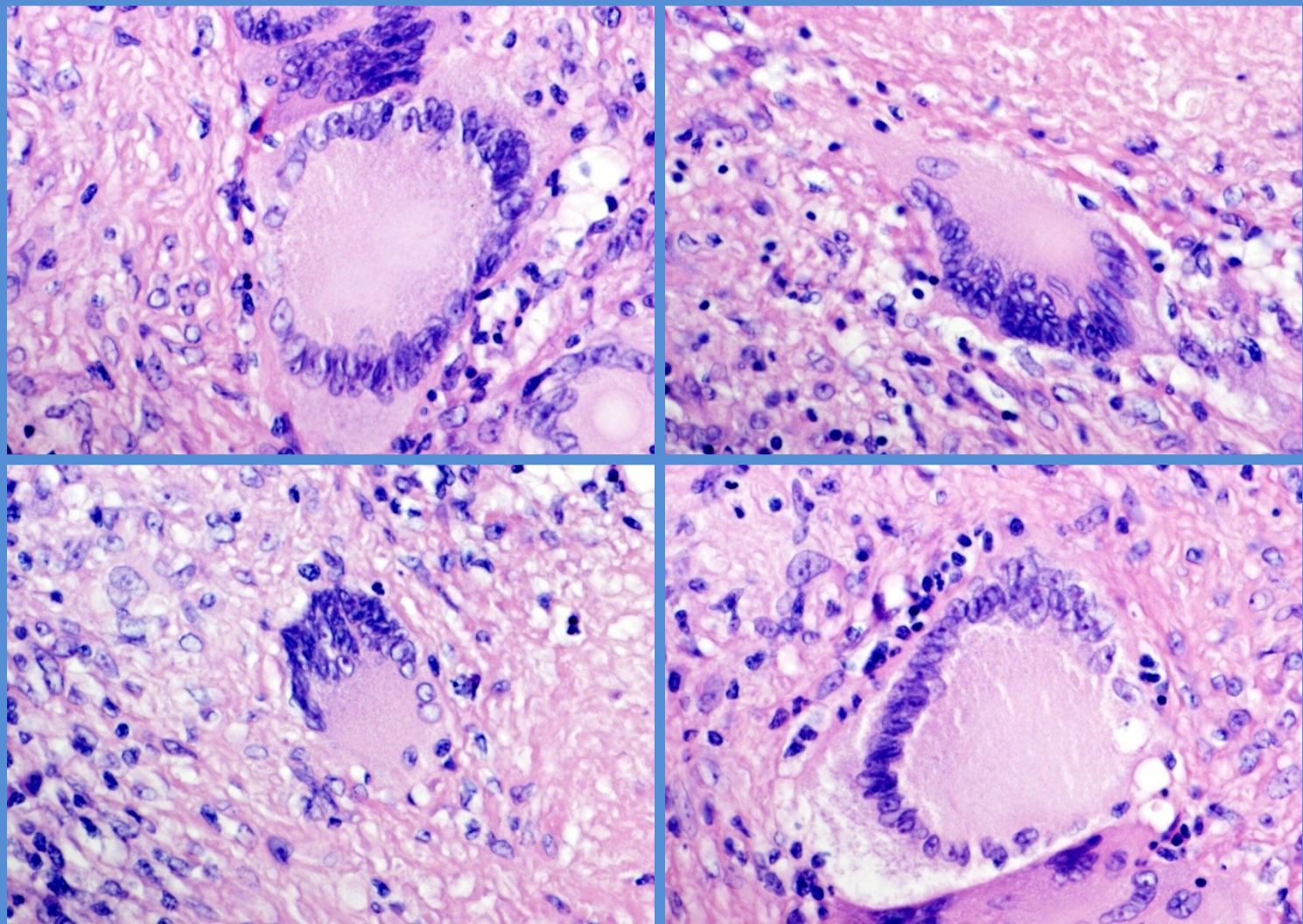
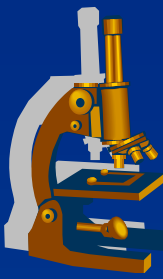
- 1 caseous necrosis
- 2 epithelioid cells
- 3 Langhans' giant cells
- 4 lymphocytes

caseous necrosis

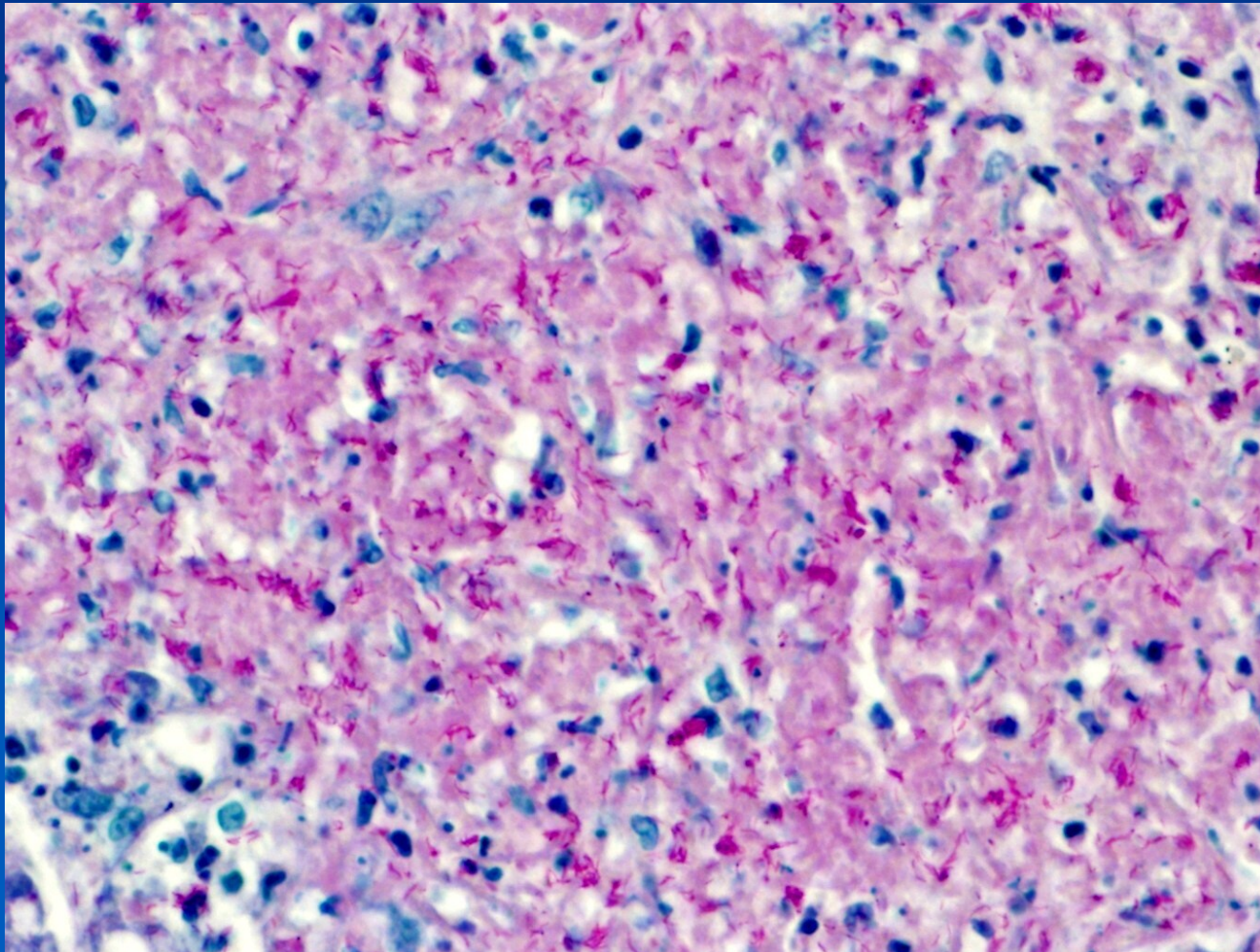
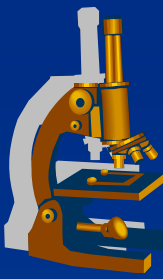


HE staining shows amorphous eosinophilic area stoppled by haematoxyphilic nuclear debris

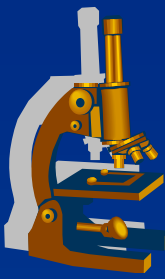
Langhans' giant cell



Ziehl-Neelsen staining, acid-resistant bacteria

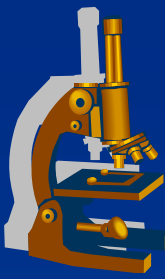


TB - morphology



- ✘ TB exudate – serofibrinous exudate + macrophages with M.tbc – Orth cells
- ✘ TB granuloma (tubercle) - proliferative form
- ✘ caseification
- ✘ colliquation
- ✘ calcification

Tuberculosis



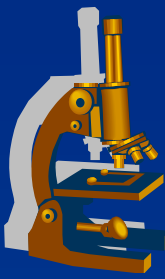
x Primary tuberculosis

- ⇒ lungs usually first site of contact (GIT, skin)
- ⇒ Ghon complex – focus of primary infection , similar granulomas in lymph nodes draining the affected portion of lung
- ⇒ primary lesion usually organise -> fibrocalcific nodule (tubercle bacilli may be still present) x complications

x Secondary tuberculosis: in previously sensitized host

- ⇒ mostly caused by reactivation of old primary infection (event. reinfection)
- ⇒ in lung - apical foci + cavitation, porogenous spread
- ⇒ isolated organ tb (renal, adrenal, meningeal, osteomyelitis, salpingitis)
- ⇒ progression -> organism virulence x host sensitivity

Tuberculosis

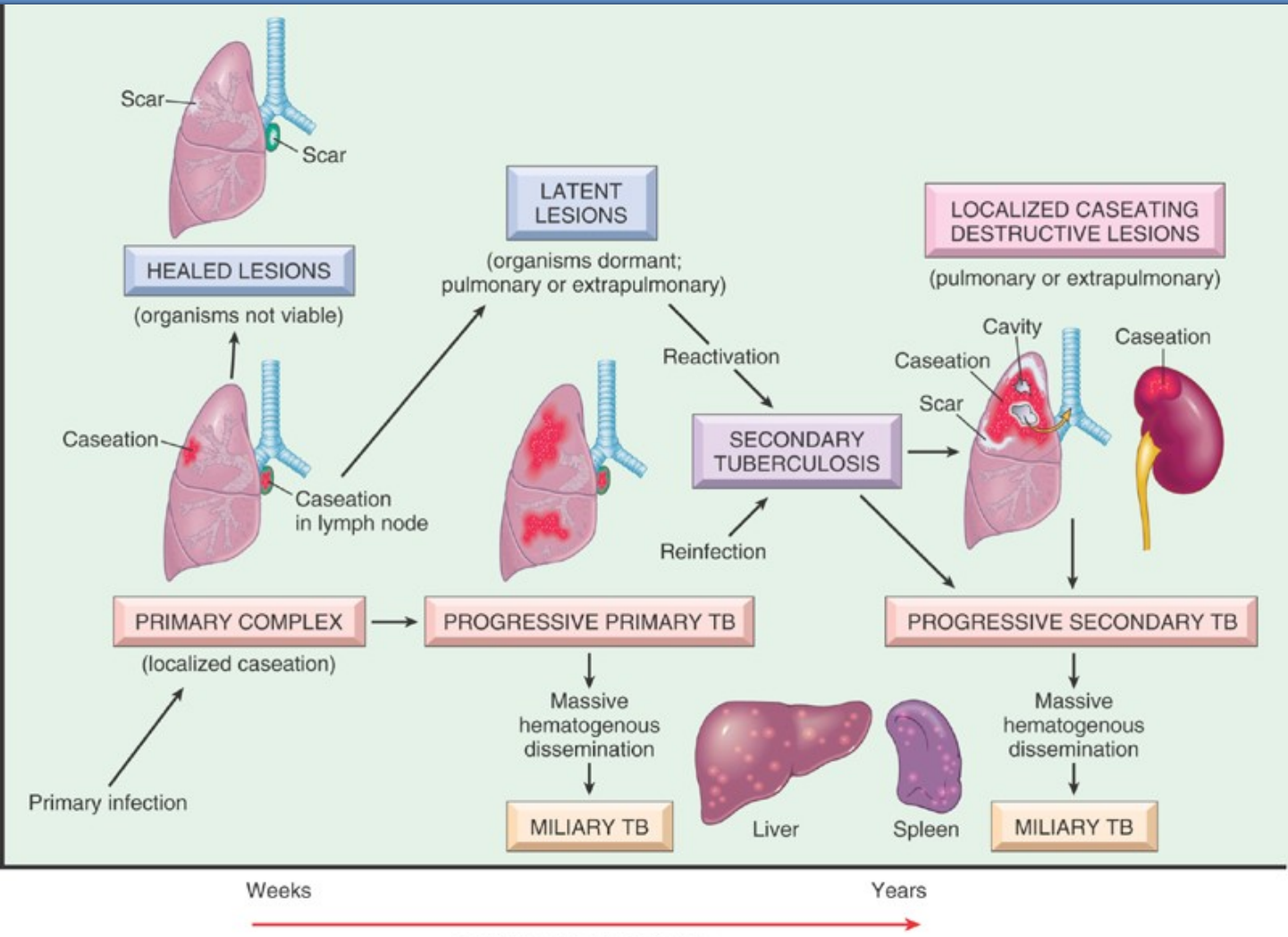
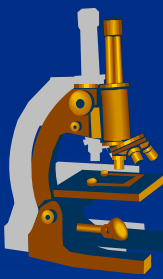


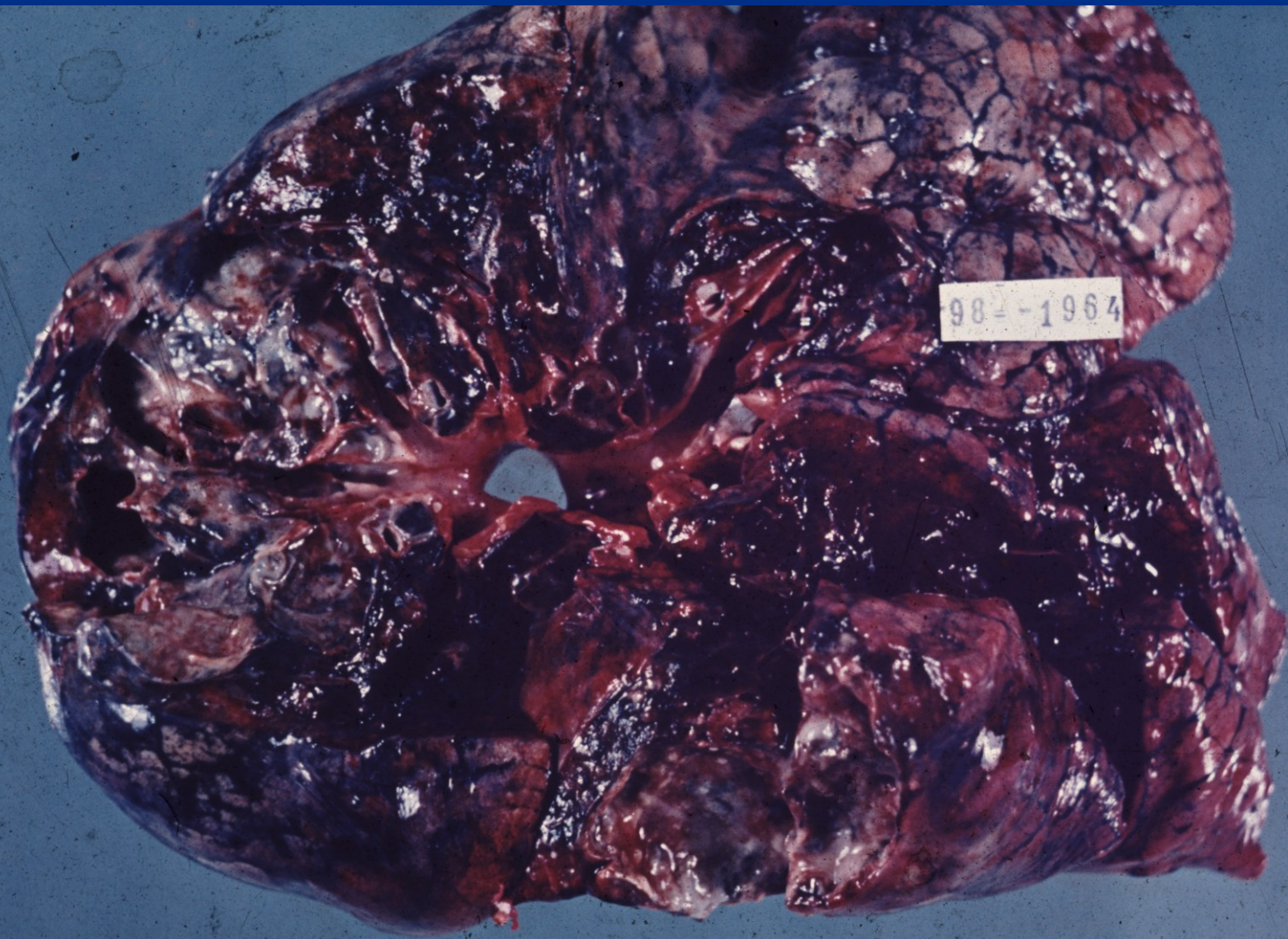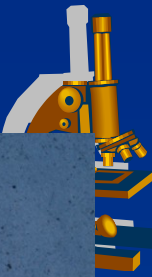
x **miliary (disseminated) tuberculosis**

- ⇒ may be consequence of either primary or secondary tb
- ⇒ hematogenous dissemination -> numerous small granulomas in many organs (lungs, meninges, kidneys, bone marrow, liver, ...)
- ⇒ serious condition (untreated nearly 100% fatal)

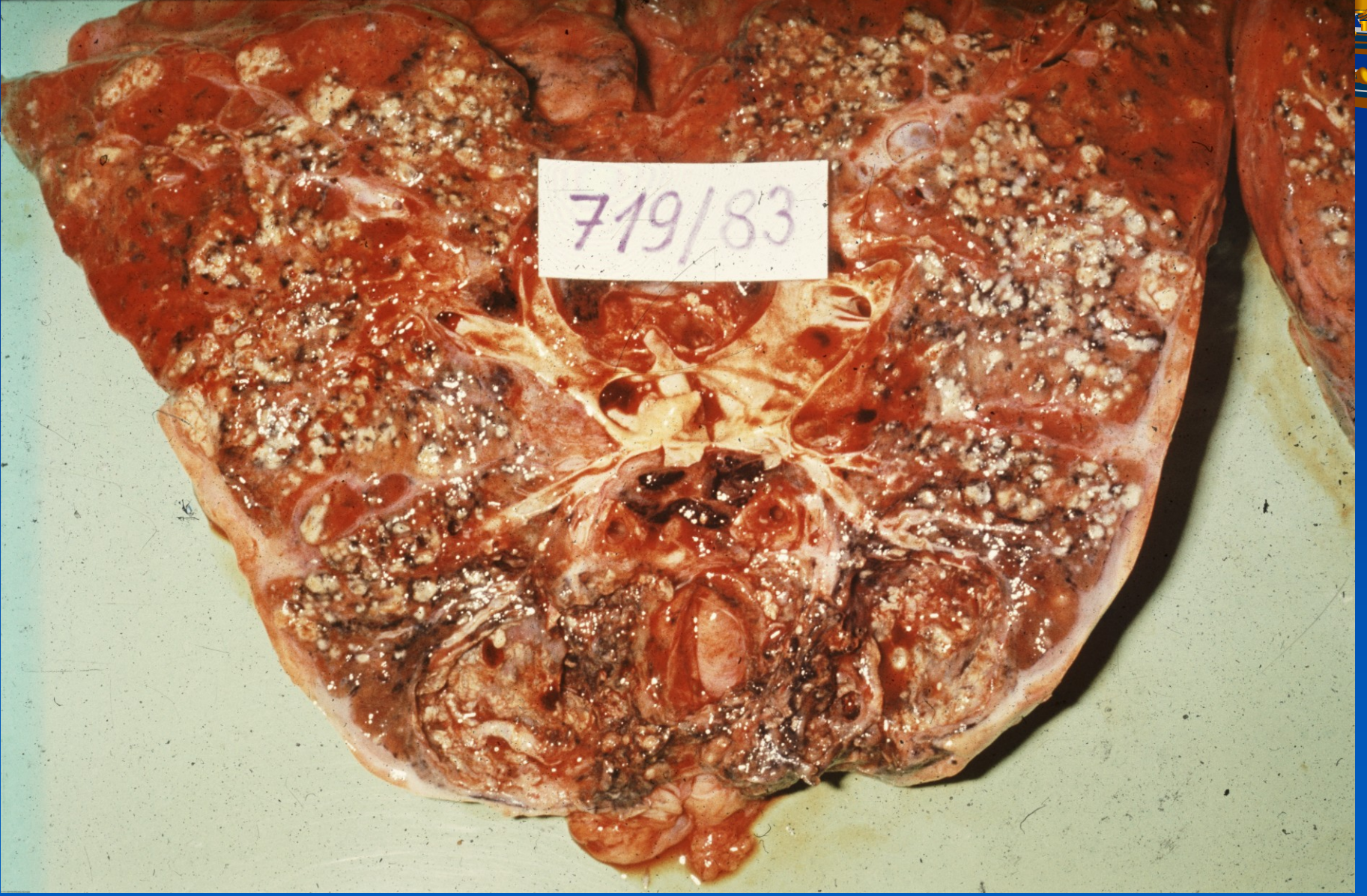
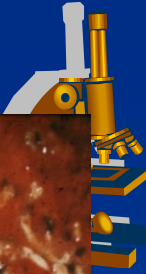Complications:

- ⇒ vessel arosion + rupture – hemoptysis / hemoptoe
- ⇒ spine deformities (heart + lung function problems)
- ⇒ secondary amyloidosis
- ⇒ infertility
- ⇒ ...



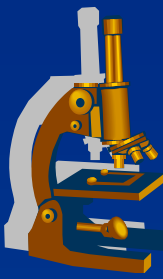


98-1964



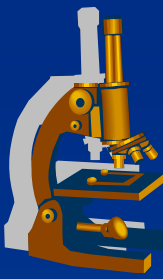
719/83

Sarcoidosis



- ✗ systemic chronic granulomatous inflammatory disease, direct etiology unknown (disordered immune regulation in genetically predisposed hosts exposed to certain environmental agents), \uparrow CD4⁺ T-cells
- ✗ mostly in mediastinal LN, lung, skin, eye; any localisation possible
- ✗ regular small „tuberculoid“ granulomas without caseous necrosis (asteroid inclusions, Schaumann's inclusions in Langerhans' cells) \rightarrow x TBC (\rightarrow biopsy, dg. per exclusionem)

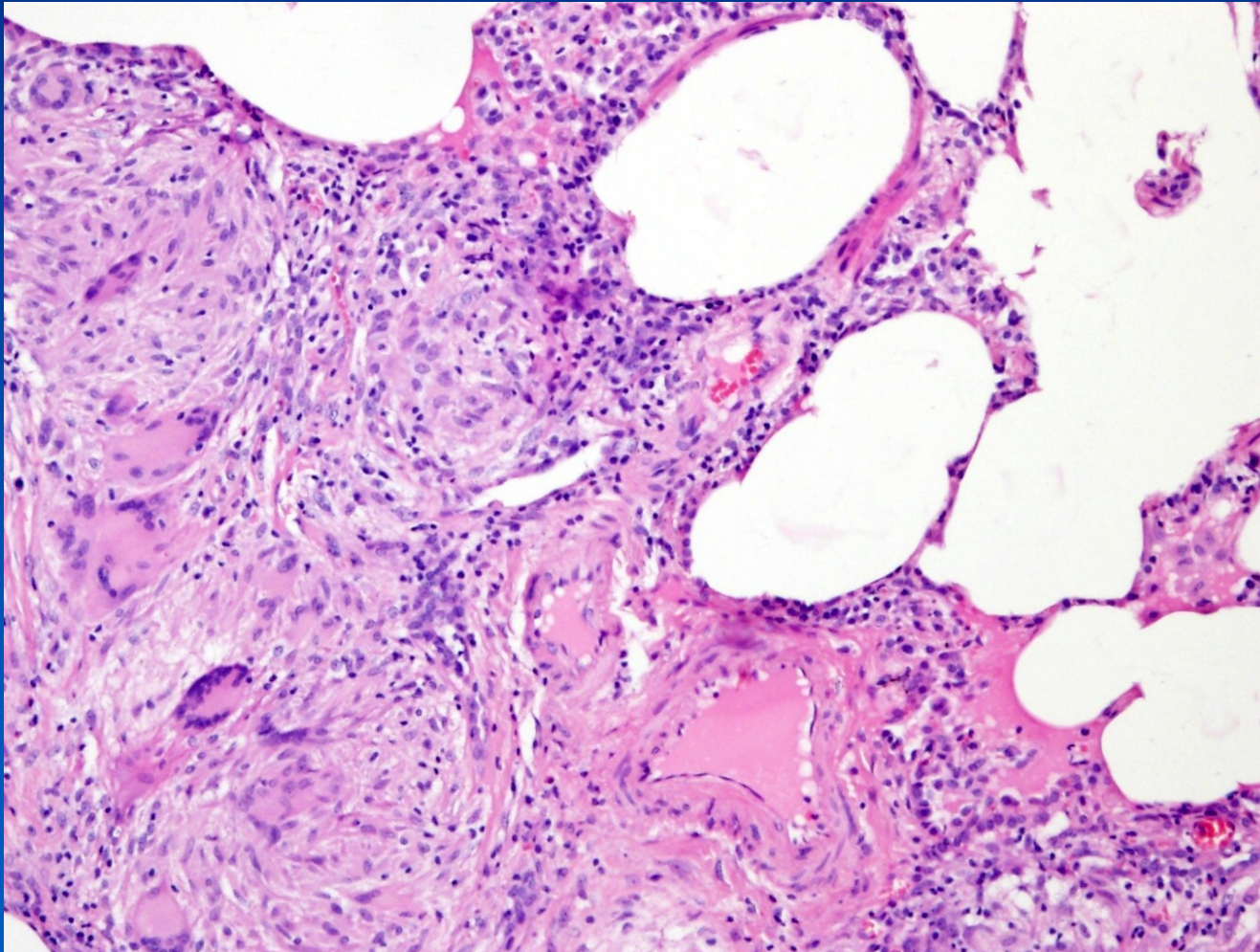
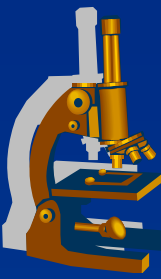
Sarcoidosis



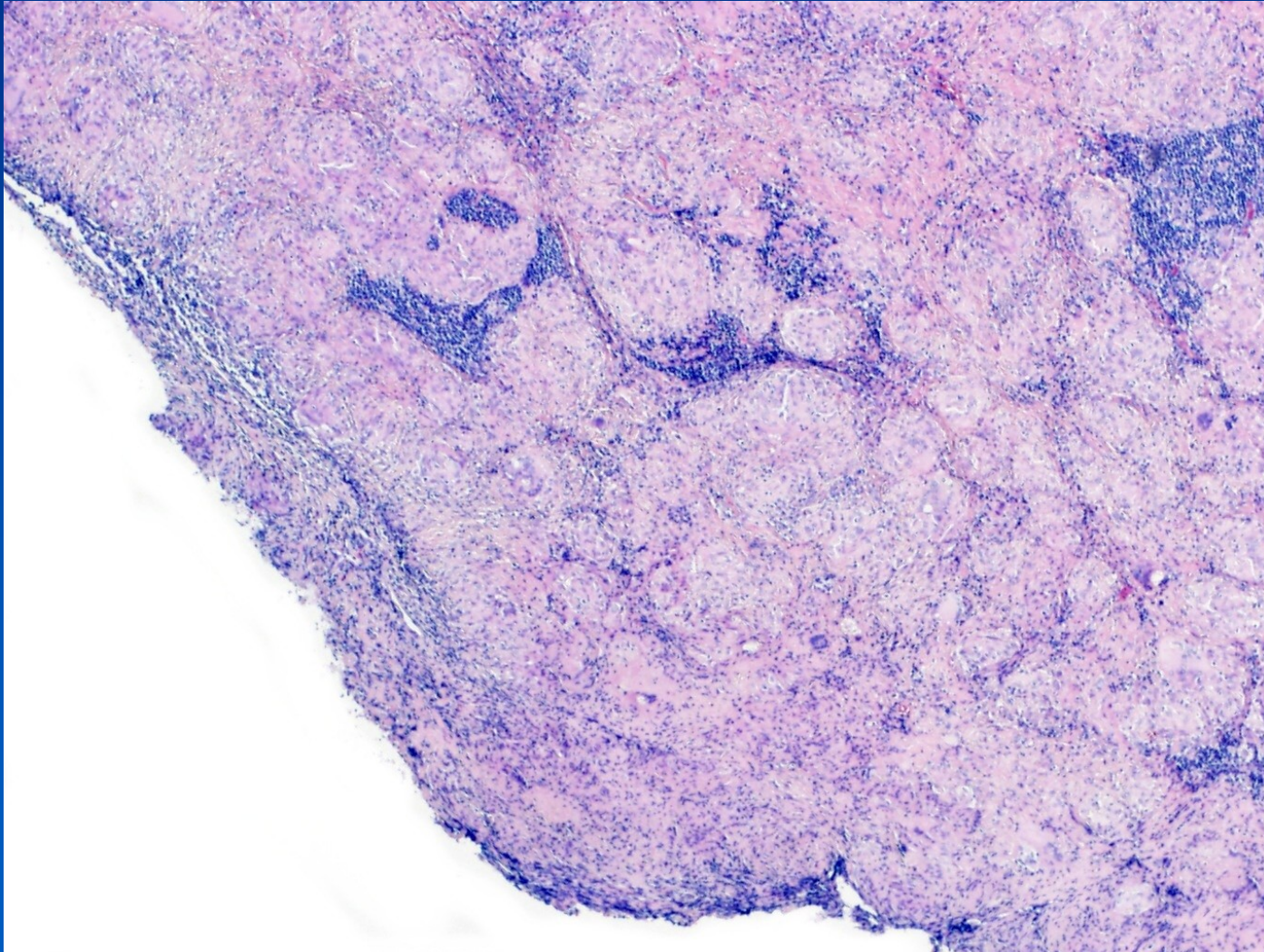
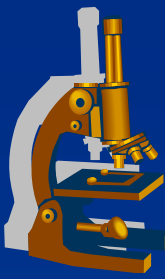
x clinically:

- ⇒ may be asymptomatic
- ⇒ chest X-ray – bilateral lymphadenopathy
- ⇒ ↑ IgG, Ca²⁺, angiotensin converting enzyme (ACE) in serum
- ⇒ slow progression or variable remission + healing
- ⇒ 10% mortality (lung fibrosis, cor pulmonale)
- ⇒ 20% lung or ocular dysfunction
- ⇒ treatment: ***corticosteroids***

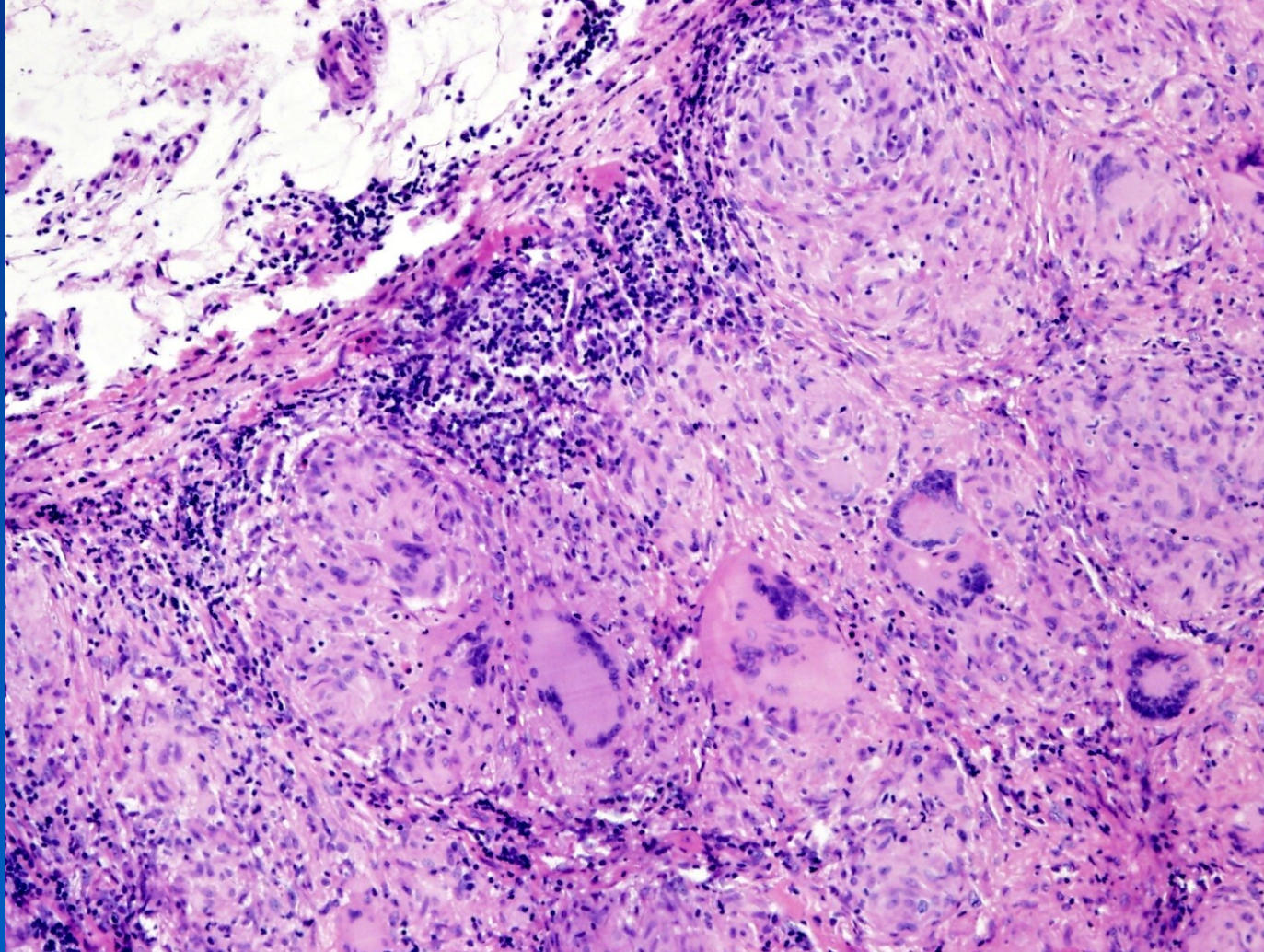
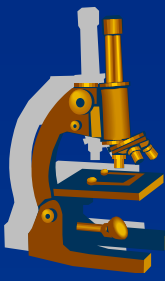
lung sarcoidosis



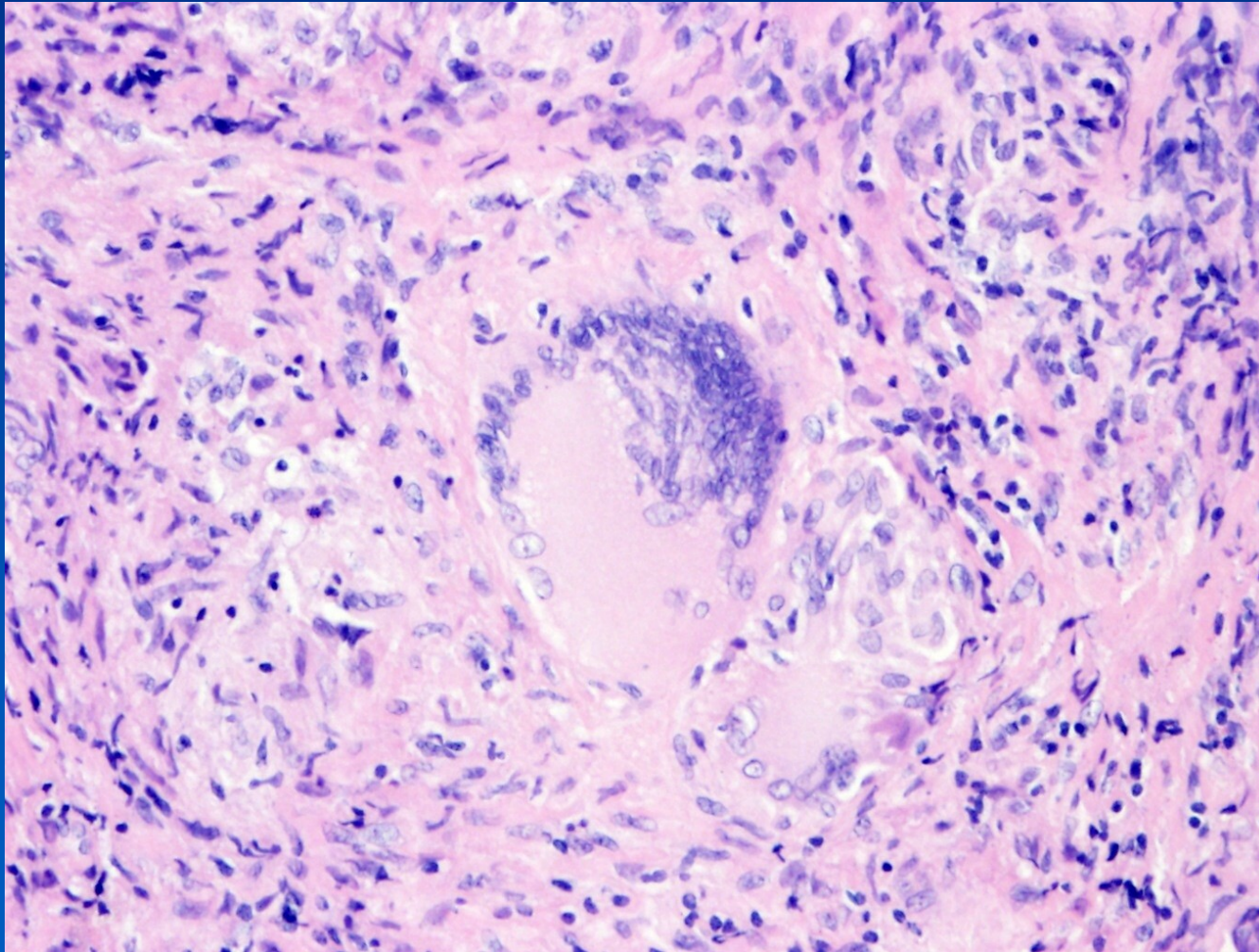
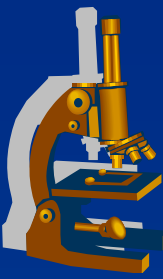
lymph node sarcoidosis



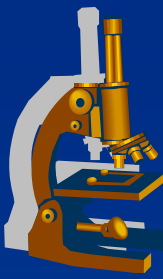
lymph node sarcoidosis



lymph node sarcoidosis



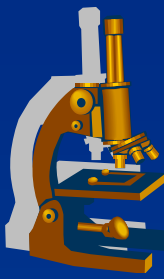
syphilis (lues)



- ✗ *Treponema pallidum* – spirochaete

- ✗ forms:
 - ⇒ **acquired** (mostly STD) – 3 stages
 - ⇒ **congenital** (transplacental transmission)
 - late abortion or stillbirth
 - infantile liver and lung fibrosis, osteochondritis
 - childhood – keratitis, deafness, teeth anomalies

syphilis (lues) - acquired



⇒ **primary chancre**

- typically acquired by direct sexual contact
- primary chancre (skin lesion) appears in the entry site 3 wks after contact
- *Primary chancre - single, firm, painless, non-itchy skin ulceration with a clean base and sharp borders between 0.3 and 3.0 cm in size, serous exudate + treponemata*
- associated with unilateral or bilateral inguinal lymphadenitis
- without treatment heals in a few weeks (3-6) -> atrophic scars

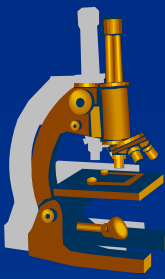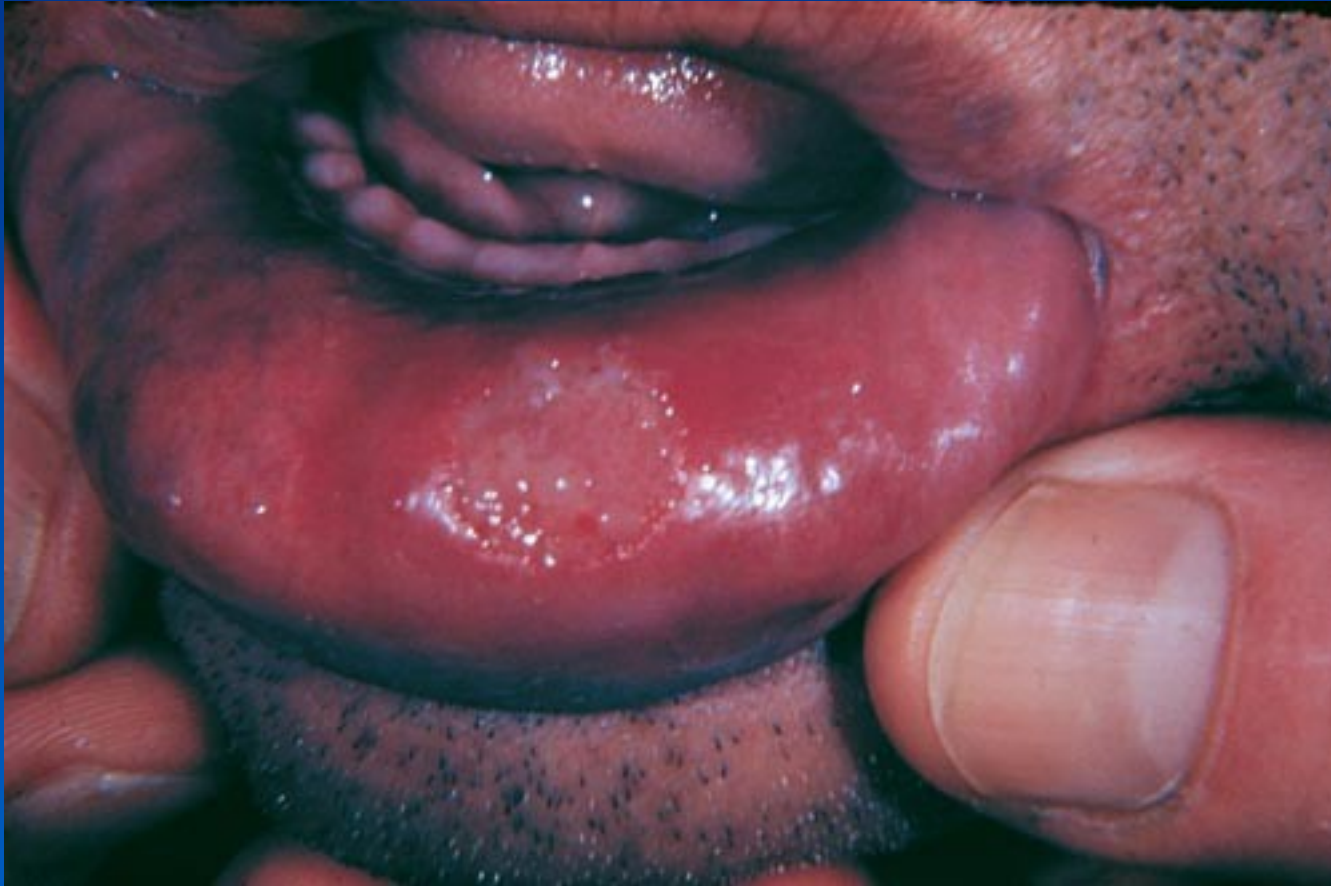
⇒ **secondary**

- early generalisation – transient skin and mucosal rash, generalised lymphadenitis in many cases, non-specific + gen. signs (fever, sore throat, weight loss, ...), numerous plasma cells in infiltrate in condylomata lata on moist skin, erosion on mucosa

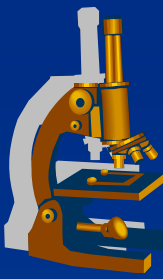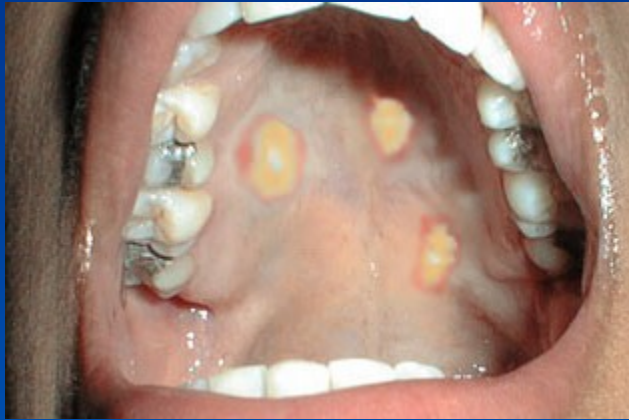
⇒ **tertiary**

- specific changes, 8 – 25 years after primary infection,
- symptoms according to localisation of gummata (cerebral cortical atrophy, progressive paralysis, aortic aneurysm)
- gumma: mm-cm, tuberculoid granuloma without complete caseous necrosis (rubbery consistency)

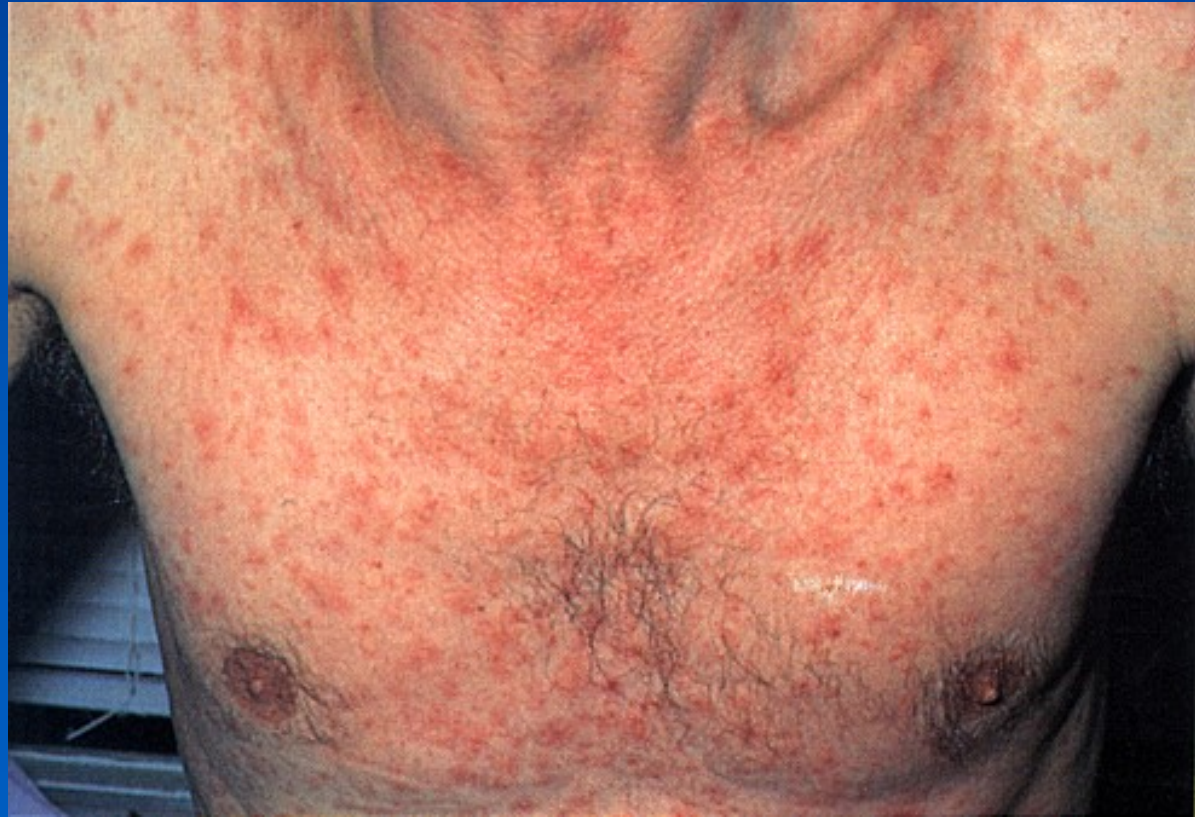Syphilis – primary



Syphilis - secondary



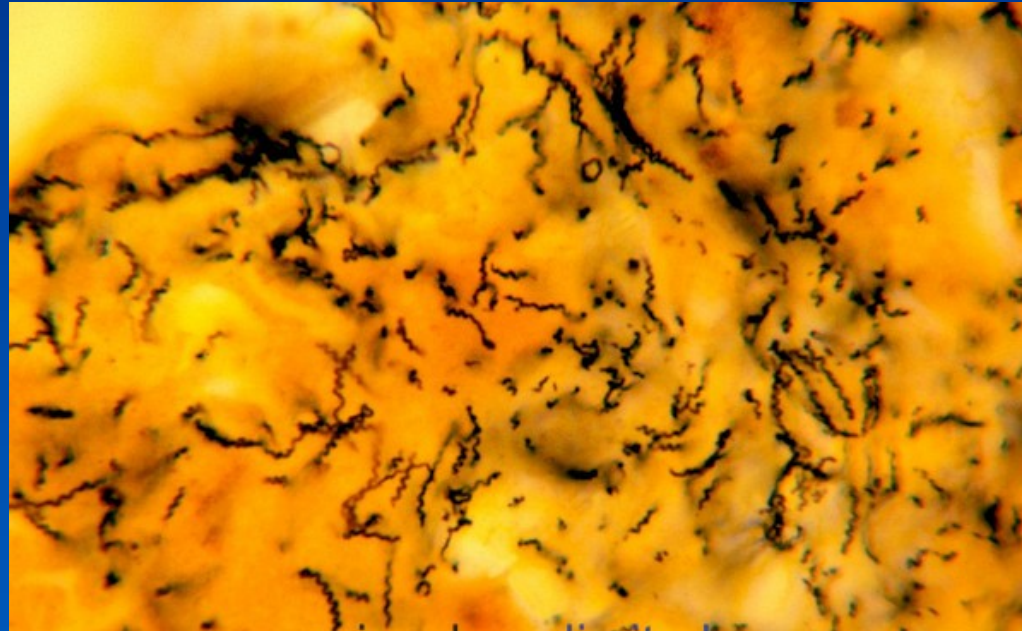
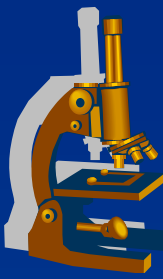
Syphilitic rash



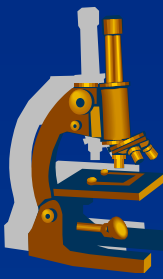
Condylomata lata

Treponema pallidum

(spirochetes visualized by silver staining)



Leprosy



× *Mycobacterium leprae*

⇒ in developed countries very rare, usually imported

× *formy*:

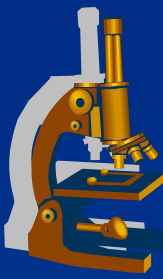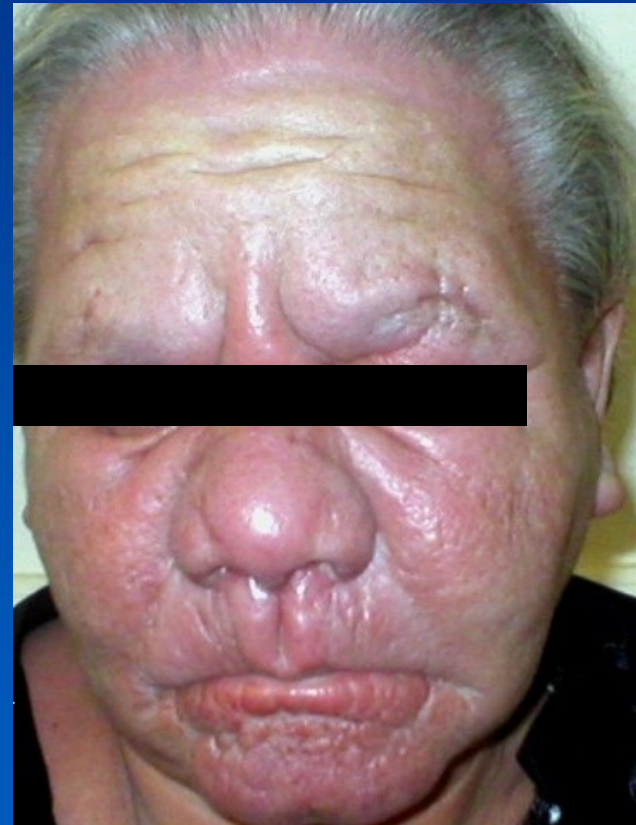
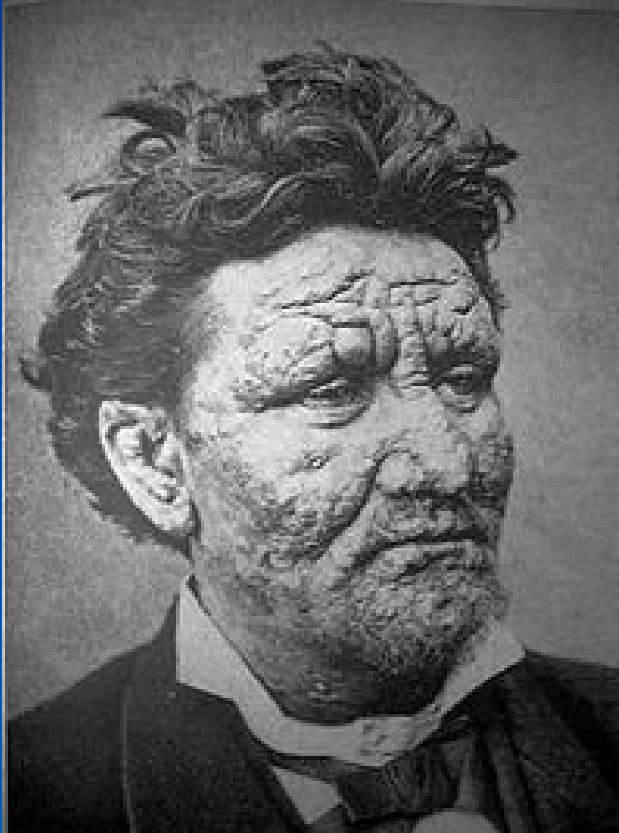⇒ **tuberculoid form**

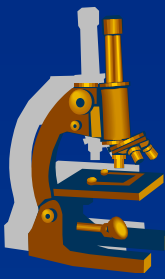
- vigorous immunological T_H1 reaction -> granulomas without caseous necrosis in the skin, perineural – ulcers, paralysis, atrophy

⇒ **lepromatous form**

- multiple and diffuse infiltrates in the skin (facies leontina), eyes (blindness), lymph nodes, spleen
- foamy macrophages + mycobacteria
- often progressive (anergic host)

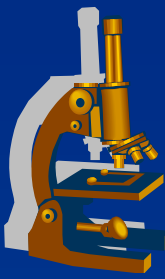
Leprosy – facies leontina





PROGRESSIVE CHANGES

Progressive changes



✗ healing of tissue defects

⇒ *regeneration*

⇒ *repair*

- regeneration and repair often in combination

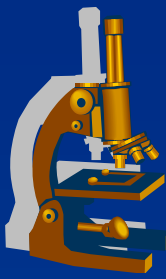
✗ tissue adaptation to the changed conditions

⇒ *hypertrophy*

⇒ *hyperplasia*

⇒ *metaplasia*

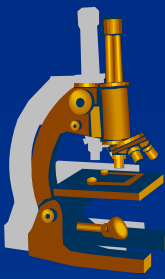
REGENERATION



- × replacement by identical tissue (morphology, function)

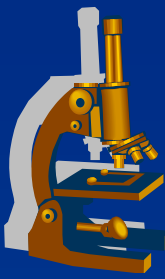
- × according to regenerative ability:
 - ⇒ **labile cells**
 - epithelial cells of skin, gut,..., bone marrow,...,
 - permanent regeneration from stem cells (rapid „turn-over time“)
 - ⇒ **stable**
 - liver, kidney (proximal tubule epithelial cells), smooth muscle
 - regeneration on demand in tissue loss
 - ⇒ **permanent (postmitotic)**
 - neurons, cardiac muscle cells
 - mostly no complete functional regeneration

REPAIR



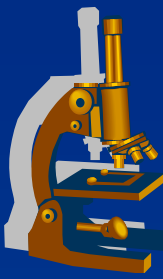
- ✗ replacement of lost tissue usually by granulation tissue
→ fibrotic scar
- ✗ may affect the function of the organ
 - ⇒ *scar after myocardial infarction*
 - ⇒ *lung fibrosis, cirrhosis,...*

Chronic hepatitis



- × > 6 months
- × causes:
 - ⇒ viral hepatitis HBV , HCV, HDV, (HEV, HGV)
 - ⇒ non-alcoholic fatty liver disease
 - ⇒ toxic (alcohol, drugs)
 - ⇒ autoimmune (antibodies antinuclear, x smooth muscle, x microsomal)
 - ⇒ inborn metabolic defects (Wilson disease, haemochromatosis, alfa-1-antitrypsin deficiency, etc.)
- × gross: enlargement, tougher consistency, rougher surface
- × combination of damage, fibrosis, irregular hyperplasia of hepatocytes
- × progression to nodular transformation - cirrhosis

Chronic hepatitis



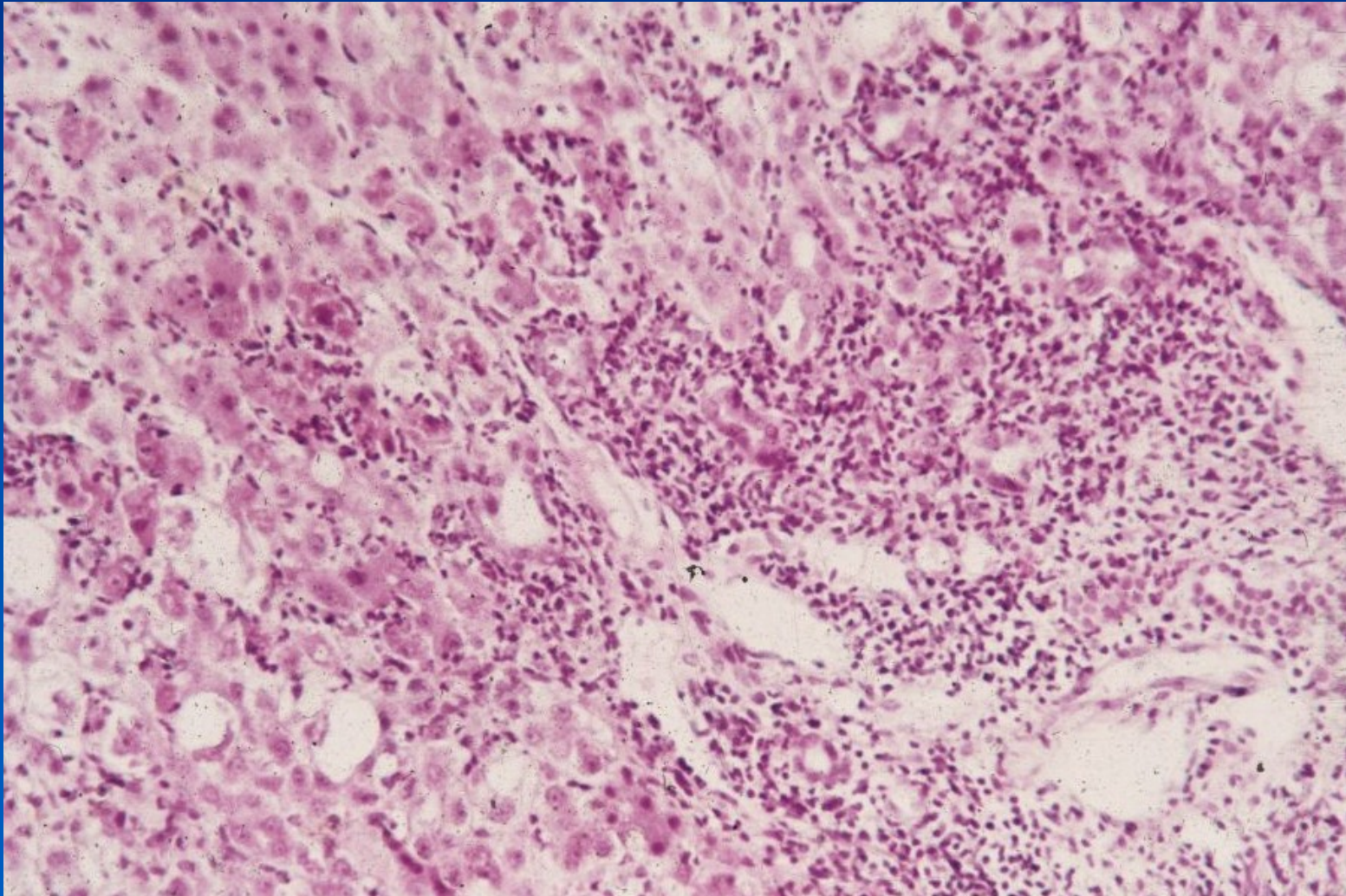
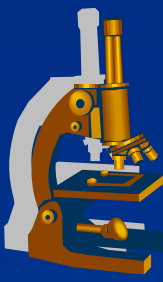
Disease activity (grade):

- ✘ interface activity (periportal necrosis)
- ✘ portal inflammatory infiltrate
- ✘ intralobular necroinflammatory activity

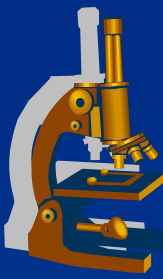
Extent of fibrosis (stage):

- ✘ fibrotic septa
- ✘ bridging
- ✘ nodule formation
- ✘ cirrhosis

Chronic hepatitis



Cirrhosis



× Etiology:

⇒ *massive acute necrosis*

⇒ *chronic hepatitis*

⇒ *biliary diseases*

- inborn (atresia),
- acquired: autoimmune (primary biliary cirrhosis, prim. sclerosing cholangitis), sec. biliary cirrhosis (chronic obstruction)

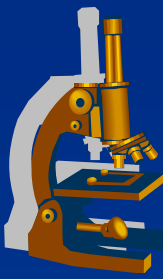
⇒ *cryptogenic cirrhosis*

× Gross: tough, usually diminished size

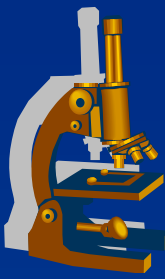
⇒ *micronodular*

⇒ *macronodular*

Cirrhosis



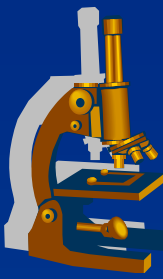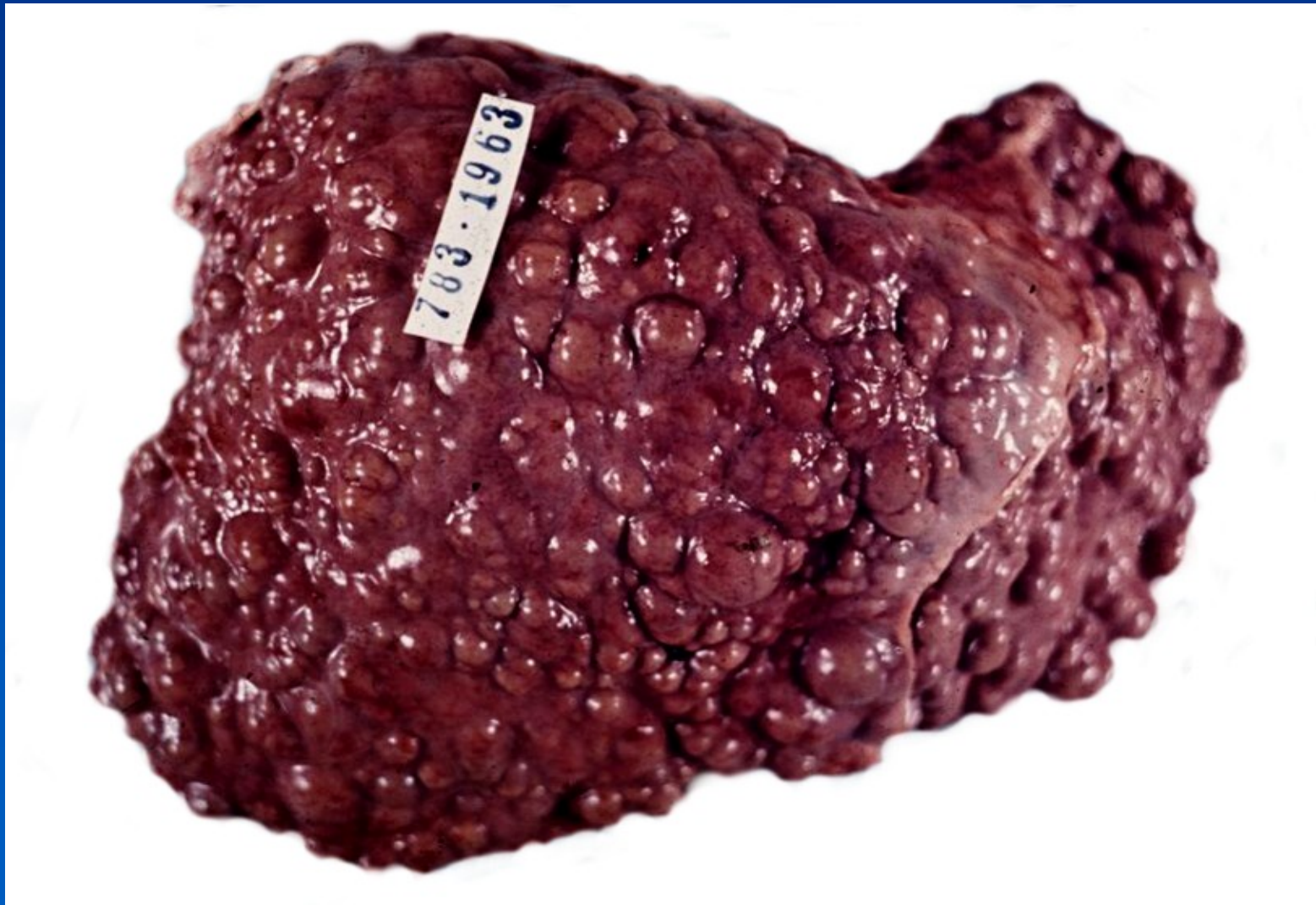
- ✘ diffuse parenchymal injury + consequent fibrosis (bridging septa)
- ✘ nodular transformation (hepatocyte regeneration x failure of architectural reconstruction), persisting regressive changes
- ✘ reorganisation of vascular architecture
- ✘ changes of intrahepatic biliary tract, incl. ductular hyperplasia



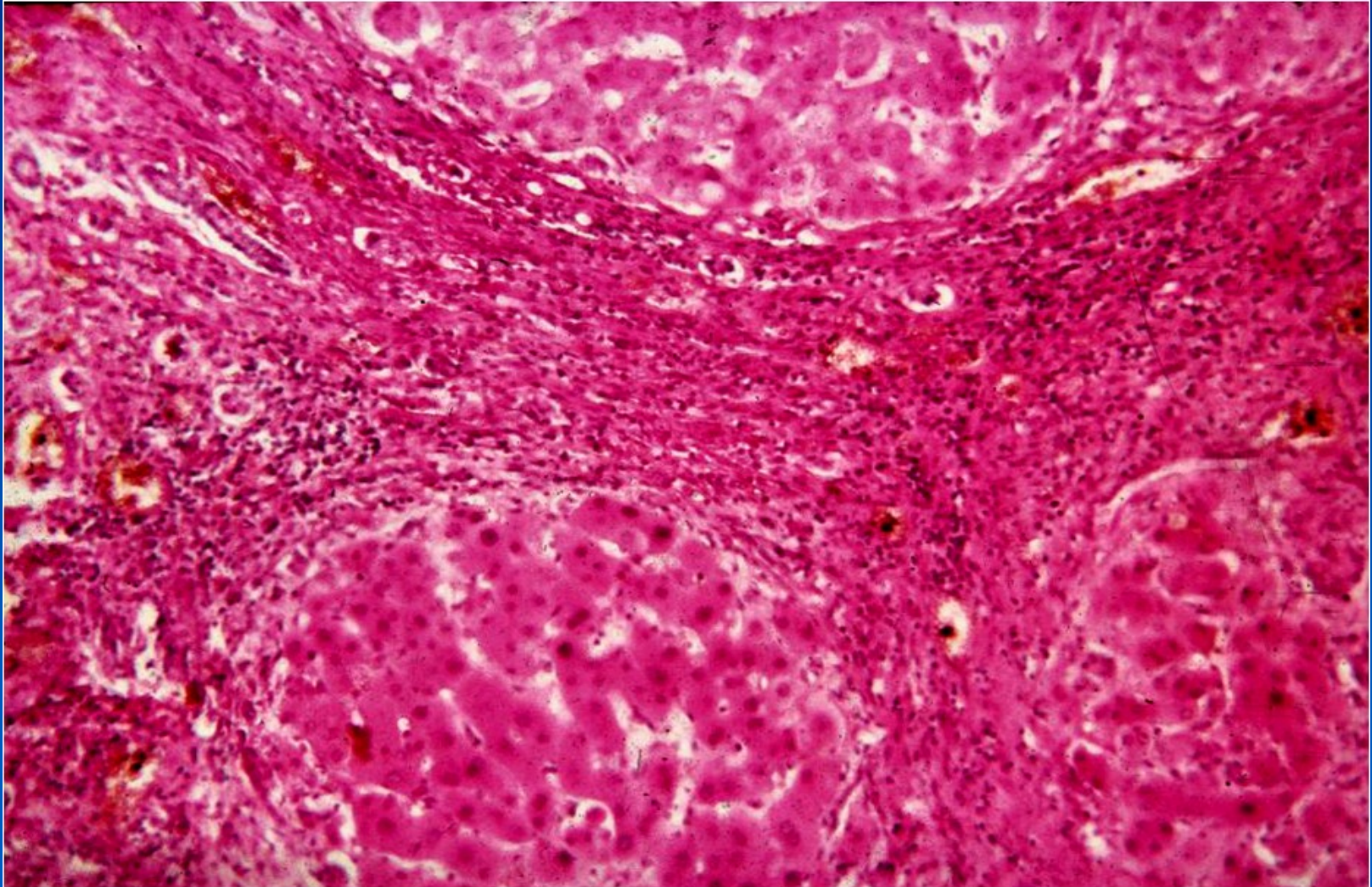
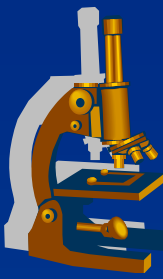
Complications of cirrhosis

- ✘ liver failure: inadequate synthesis, inadequate detoxication, insufficient Kupffer cell function
- ✘ portal hypertesion: splenomegaly, intestinal venous congestion (! infarsation, inflammation)
ascites (! peritonitis), portocaval anastomoses
- ✘ carcinoma (usually hepatocellular)

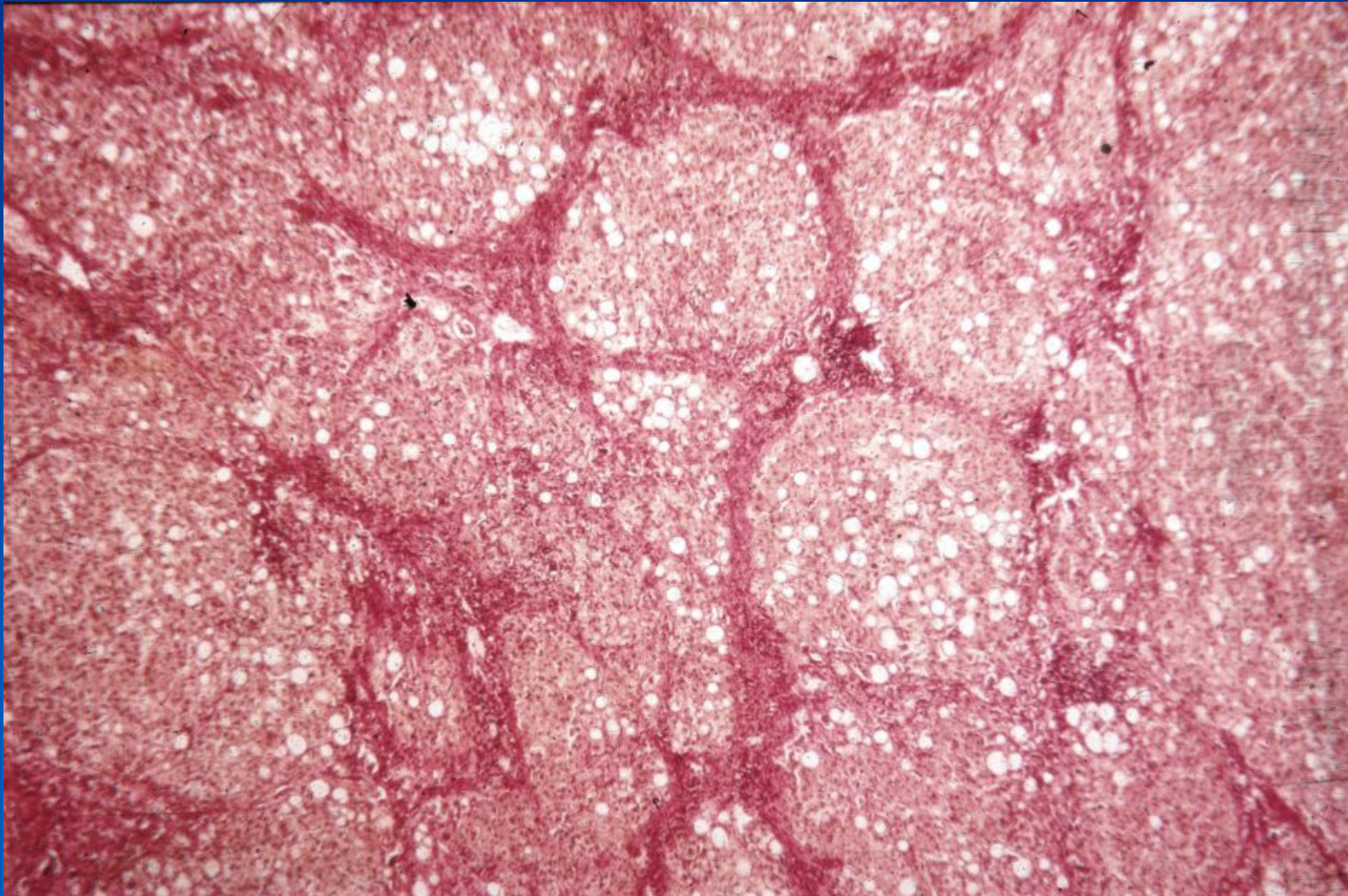
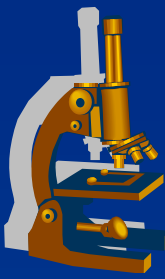
Cirrhosis – nodular transformation



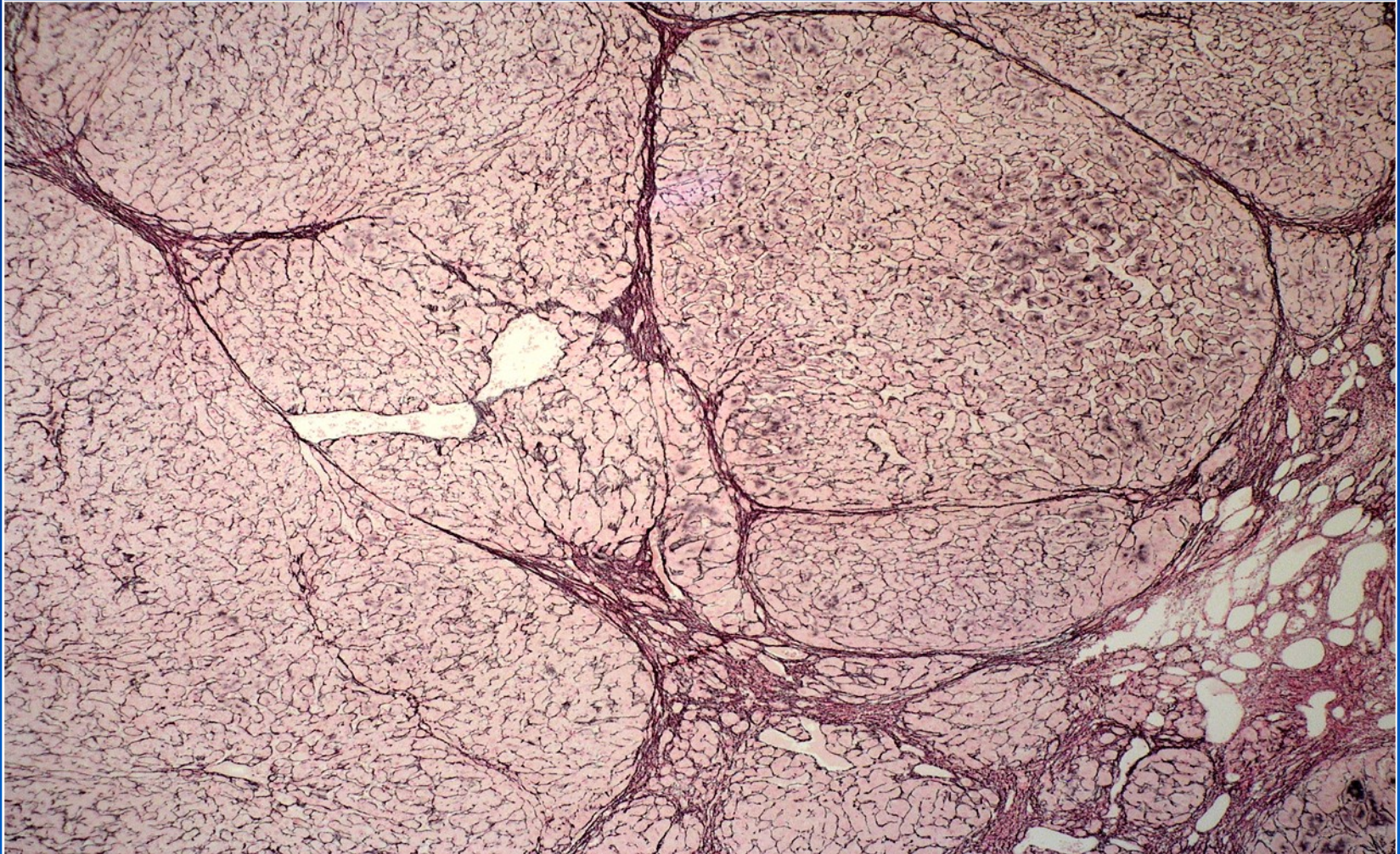
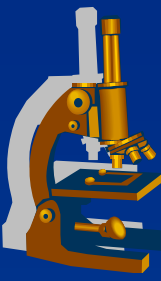
Cirrhosis – nodular transformation, chronic hepatitis, cholestasis



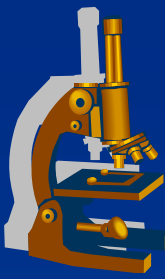
Cirrhosis



Cirrhosis

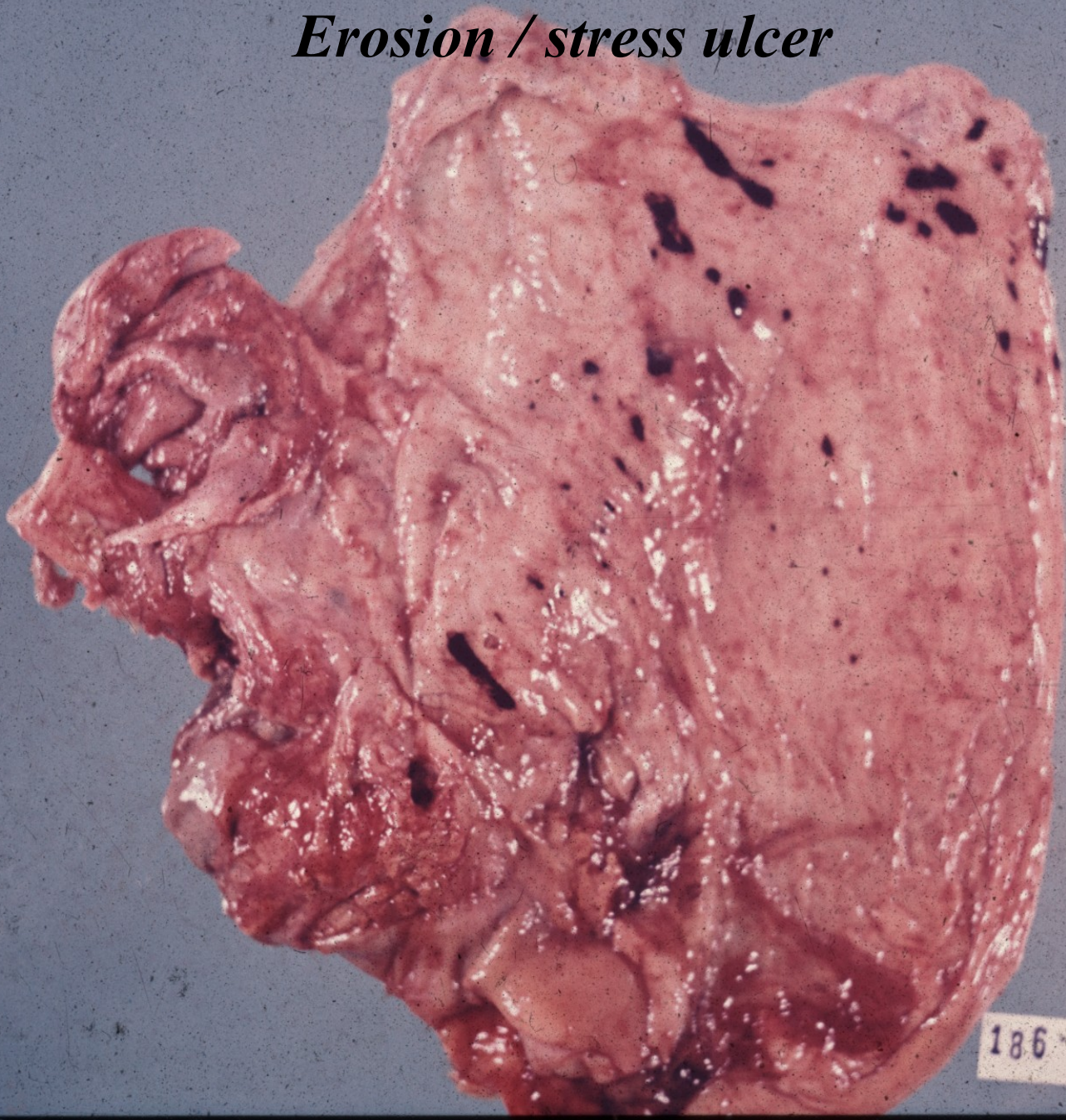


Stomach erosions



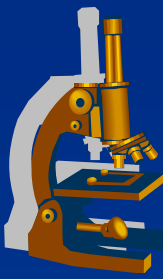
- × NSAIDs + other drugs, alcohol, vomiting, stress, burns, infection, raised intracranial pressure
- × antrum and body, multiple
- × microcirculation disorder, capillary rupture, acid hypersecretion
- × < 3 mm
- × limited by m. mucosae !!!
- × healing by regeneration

Erosion / stress ulcer

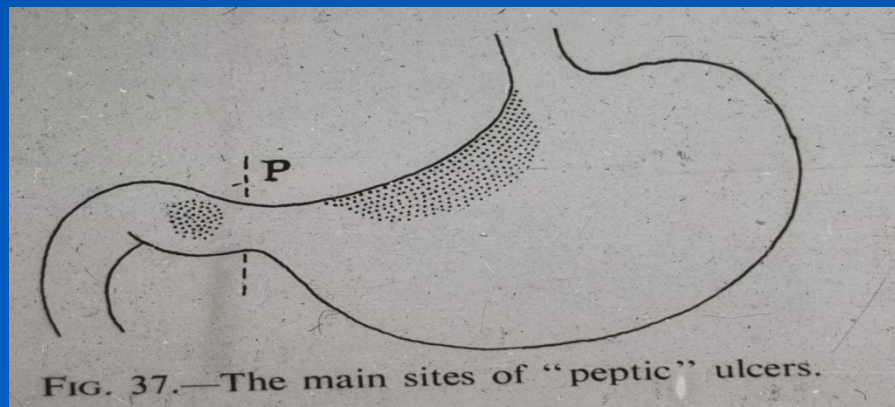


186 1963

Chronic peptic ulcer



- ✗ chronic, **usually solitary** lesion in GIT parts exposed to acid and peptic juices, commonly at mucosal junction
- ✗ **extends through m. mucosae** into submucosa or deeper
- ✗ bulbus duodeni, stomach antrum, GE junction, stomic junction, Meckel diverticulum
- ✗ imbalance between mucosal defence and damage by gastric juices/bile, drugs, ischaemia (stress)
- ✗ *H. pylori* (100% in duodenal ulcers, cca 70% in gastric ulcers), but only 10-20% of infected develop ulcer



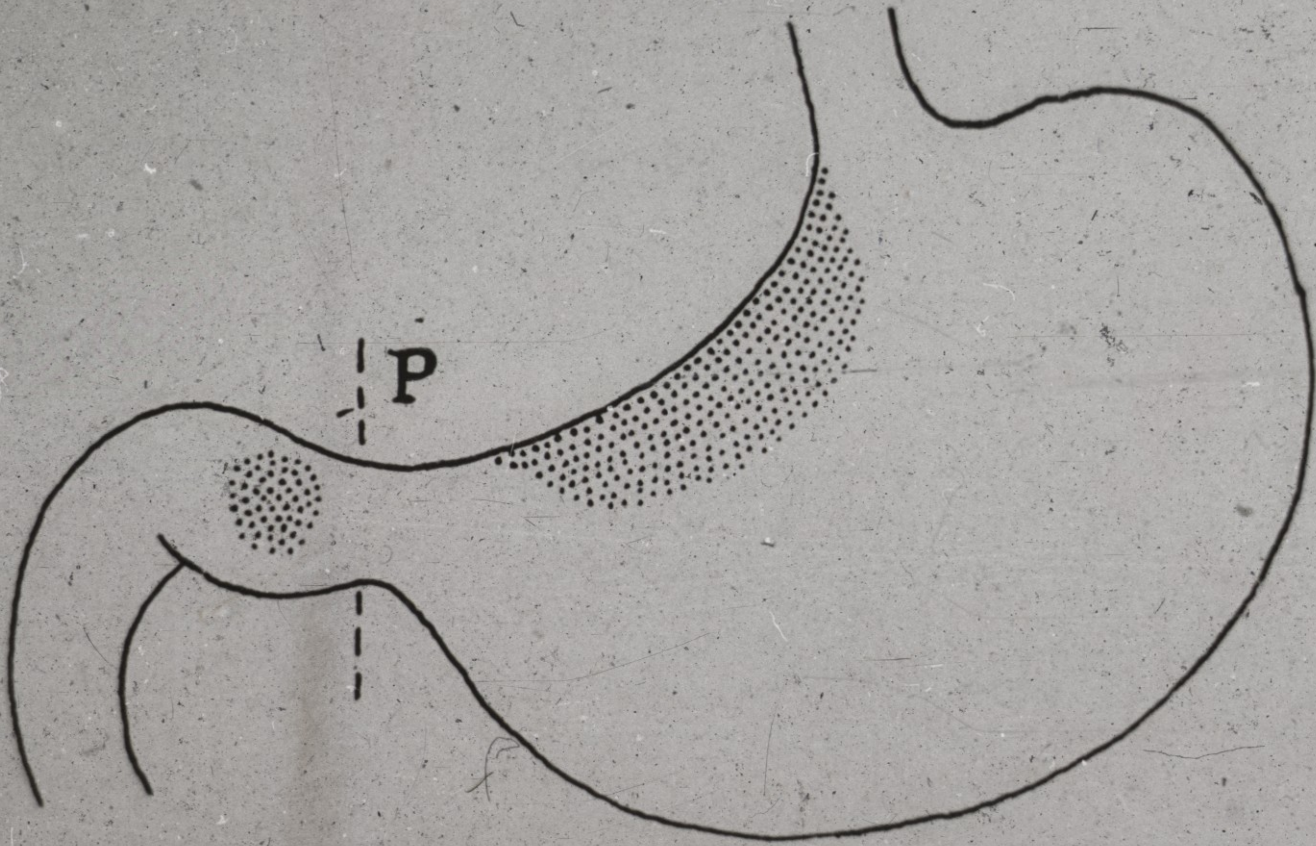
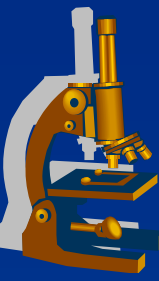
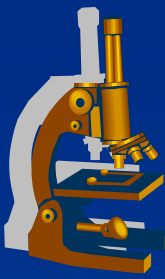


FIG. 37.—The main sites of “peptic” ulcers.

Chronic peptic ulcer

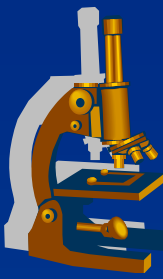


- ✗ gross: starts as sharply demarcated defect, 4 – 40 mm, straight walls, haemorrhagic base

- ✗ later overhanging mucosa, sometimes slightly elevated borders, smooth base, scarring

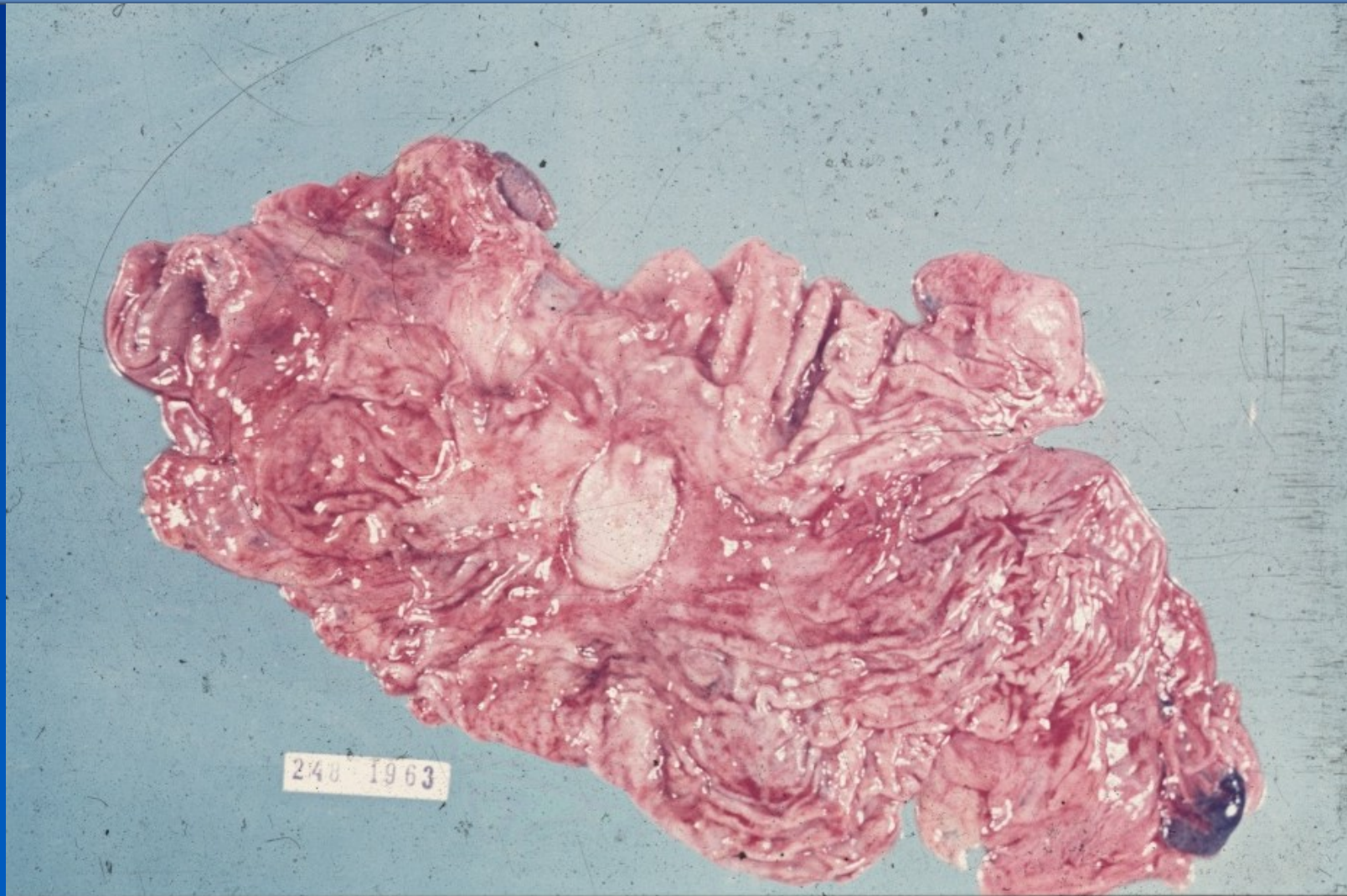
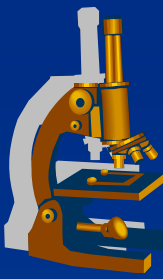
- ✗ histology: in active ulcer 4 layers
 - ⇒ cell debris and fibrinoid necrosis
 - ⇒ mixed inflammatory infiltrate
 - ⇒ granulation tissue
 - ⇒ fibrotic scar

complications

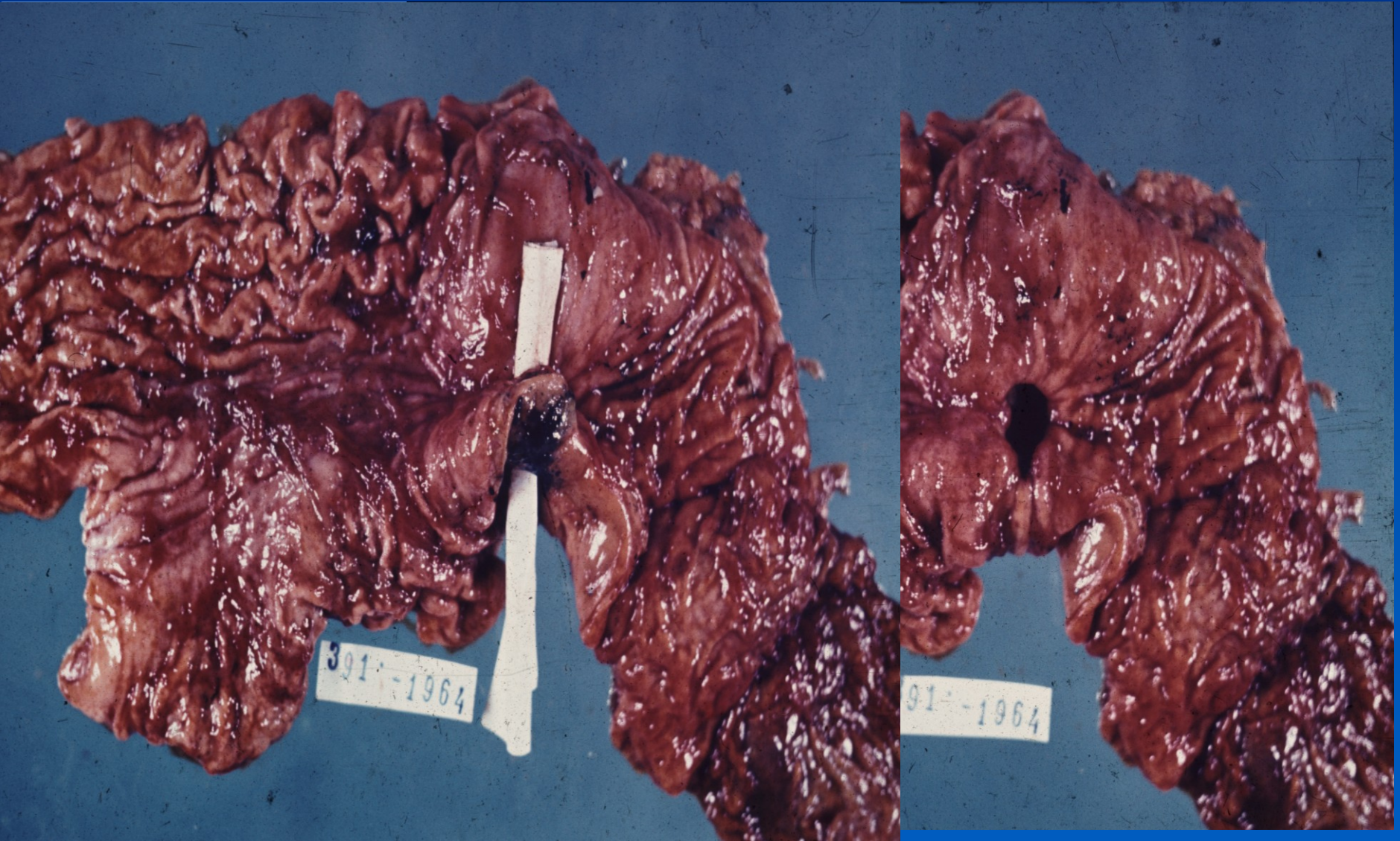
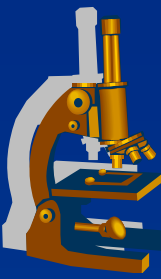


- ✗ haemorrhage (overt, occult, anaemia)
- ✗ perforation, shock, peritonitis
- ✗ penetration into adjacent organs
- ✗ scarring, stenosis
- ✗ malignant transformation (stomach)

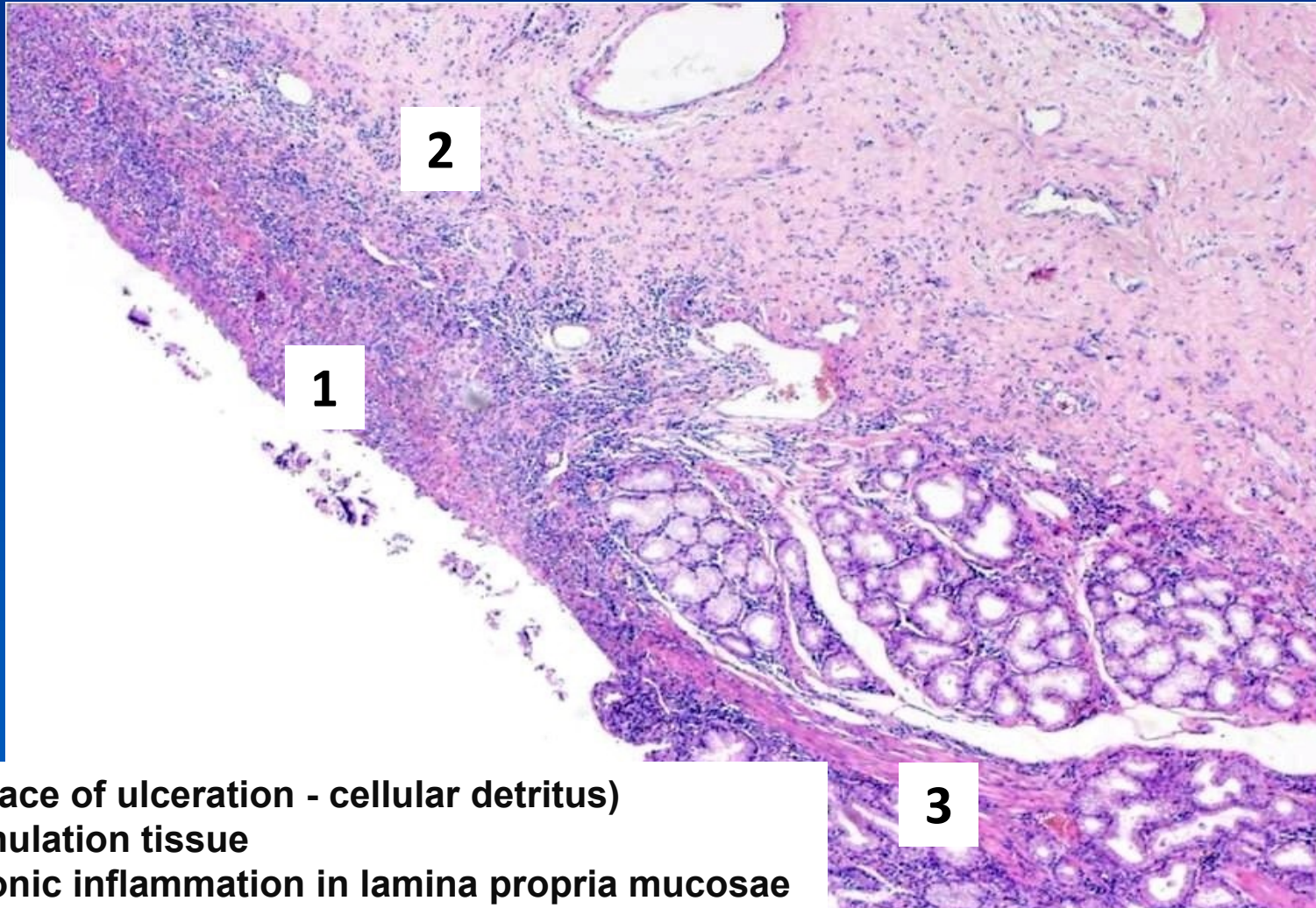
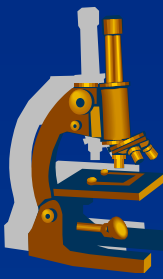
Chronic peptic ulcer



Perforated duodenal ulcer

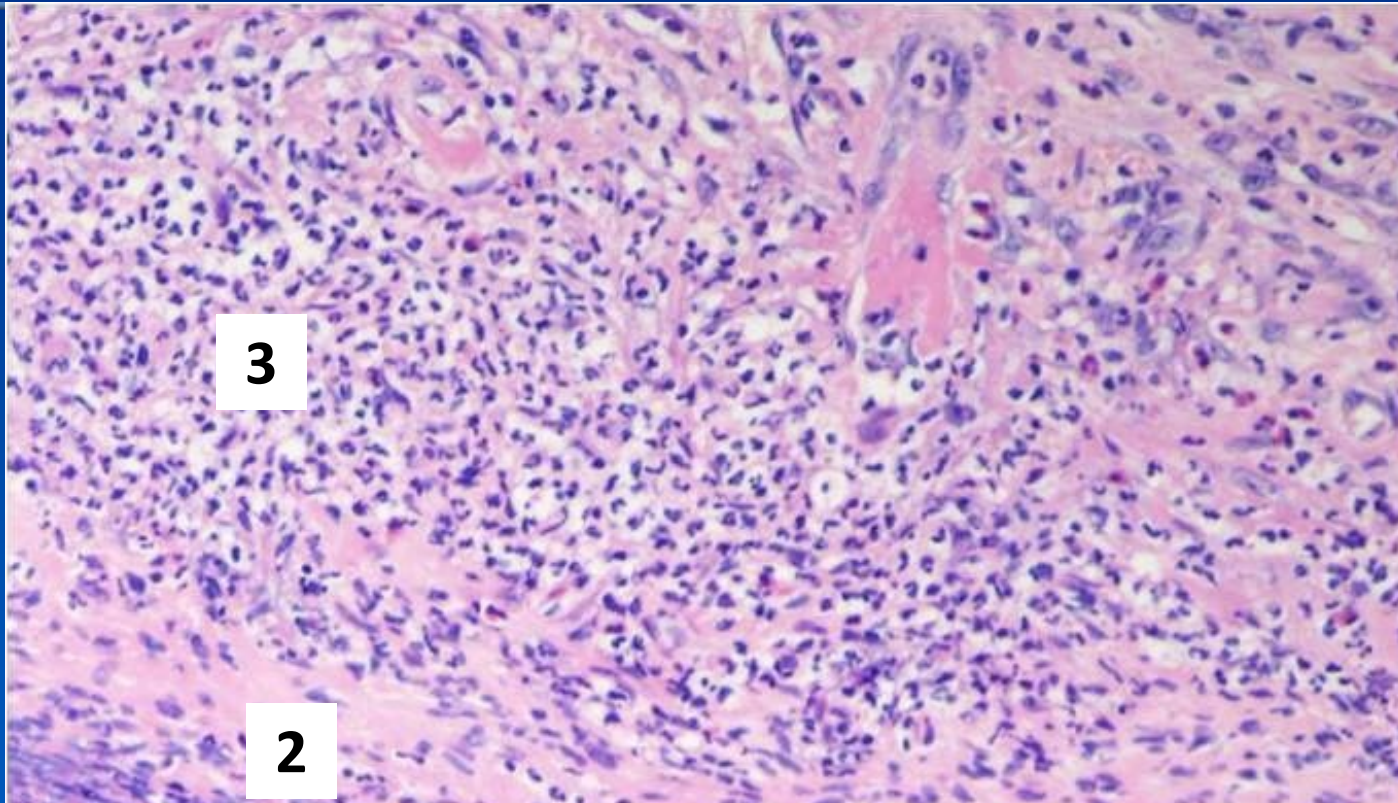
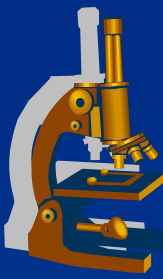


Chronic peptic ulcer - duodenum



- 1 surface of ulceration - cellular detritus)
- 2 granulation tissue
- 3 chronic inflammation in lamina propria mucosae

Chronic peptic ulcer - duodenum



1

3

2

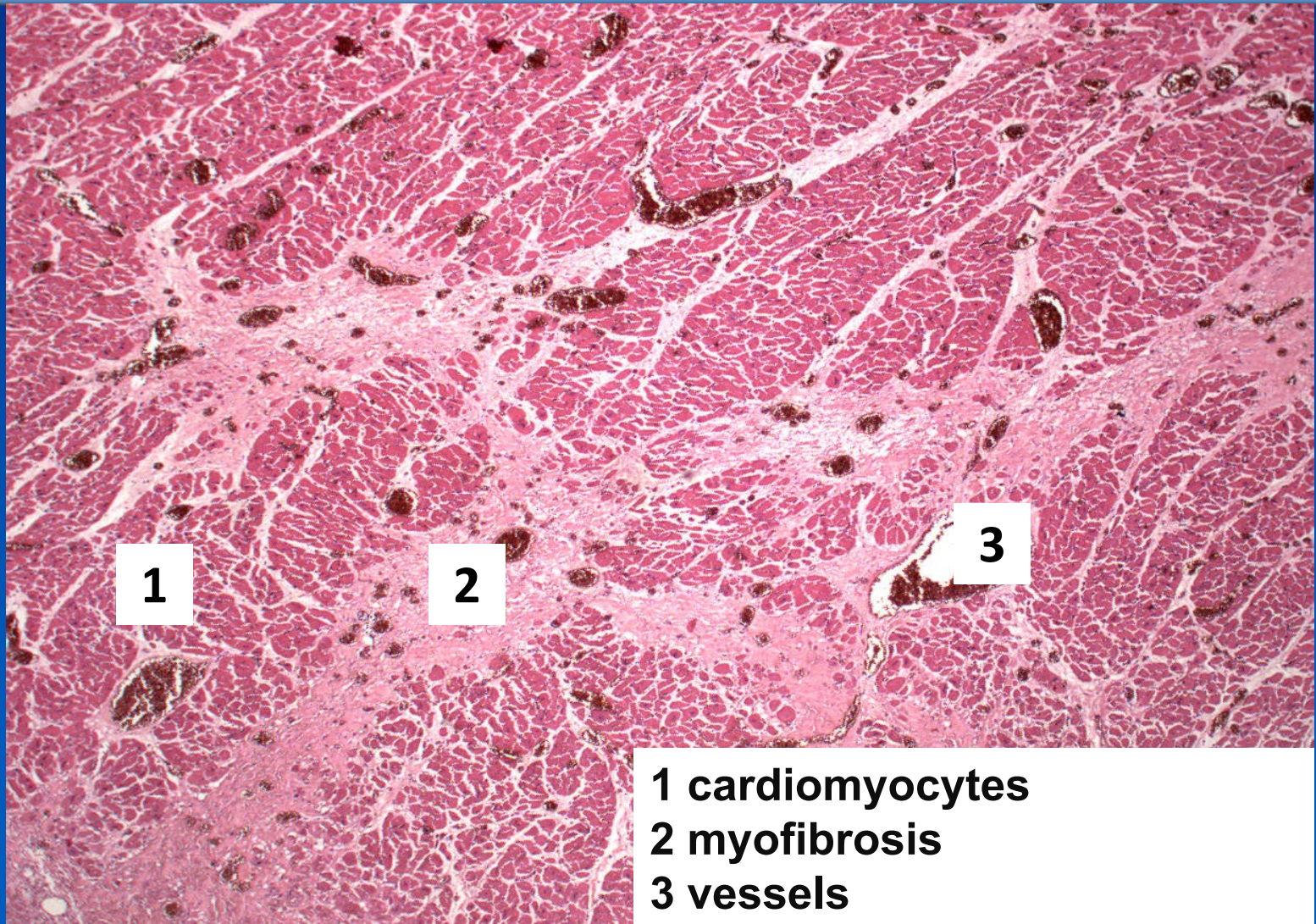
1 surface of ulceration - cellular detritus)
2 Fibrinoid necrosis
3 granulation tissue with mixed inflammatory infiltrate

MYOFIBROSIS DISPERSA CORDIS



- ✘ Repeated multiple microinfarcts/myomalatia of cardiomyocytes („angina pectoris“)
- ✘ Repair by granulation tissue, scarring
- ✘ Disperse scars – small whitish foci in myocardium

MYOFIBROSIS DISPERSA CORDIS



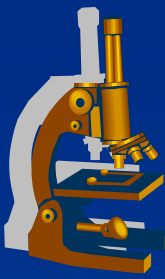
1

2

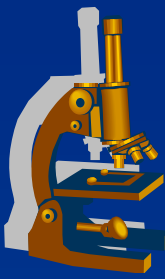
3

- 1 cardiomyocytes
- 2 myofibrosis
- 3 vessels

Hyperplasia



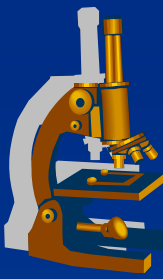
- × increase in cell number by cell division → tissue/organ enlargement
- × physiological: hormonal, compensatory
 - ⇒ Hyperplasia of breast tissue (in puberty, pregnancy, lactation)
- × pathological: excess of hormones / growth factors, still under control (autonomous exceptions rare)
 - ⇒ Benign prostatic hyperplasia
 - ⇒ Endometrial hyperplasia
 - ⇒ Thyroid hyperplasia (goiter)



BENIGN PROSTATIC HYPERPLASIA

- ✗ common in older men, high incidence > 60 yrs
- ✗ adenomyomatous hyperplasia
 - ⇒ *stromal (smooth muscle, fibrotic tissue)*
 - ⇒ *+ glandular, alternating with atrophy, cystic and regressive changes*
 - ⇒ *!!! two cellular layers – outer myoepithelial, inner secretory !!!*
- ✗ gross: enlarged, nodular, tougher
- ✗ main changes in central (periurethral) region

BENIGN PROSTATIC HYPERPLASIA

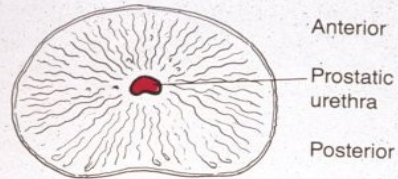
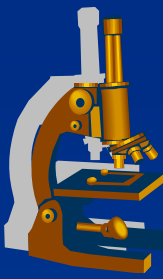


- ✗ Outcome:

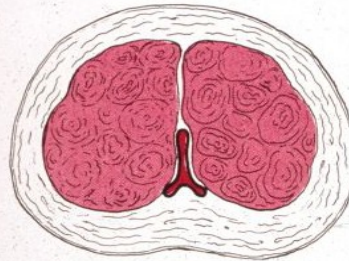
- ⇒ *partial → complete urethra obstruction -> urinary residuum, risk of infection (+ ascending – pyelonephritis)*
- ⇒ *bladder trabecular hypertrophy*
- ⇒ *hydronephrosis*

- ✗ Benign, but setting for possible preneoplastic changes

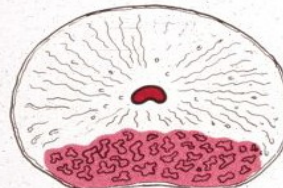
- ✗ Th: surgery, drugs



NORMAL PROSTATE



NODULAR PROSTATIC
HYPERPLASIA

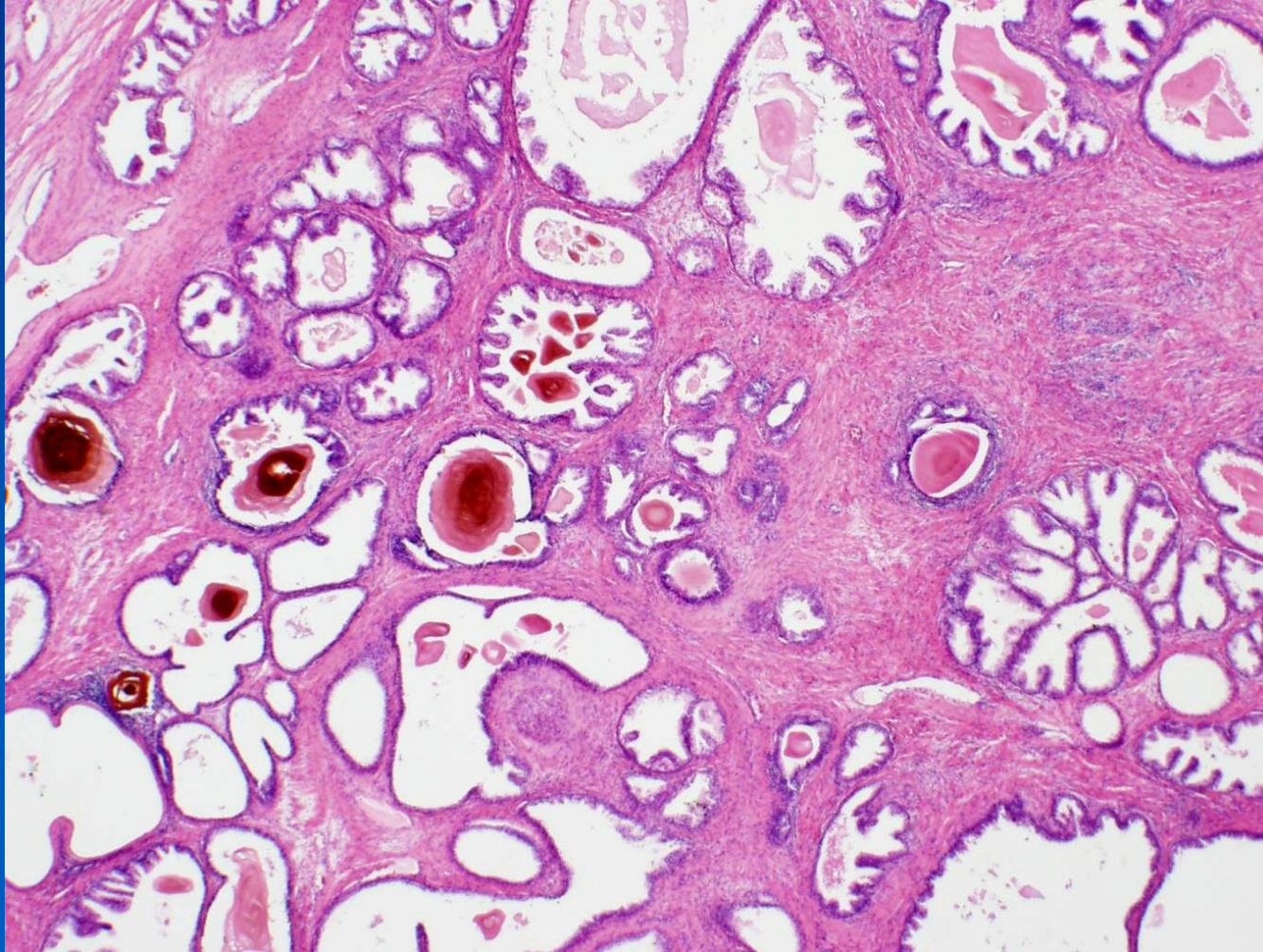
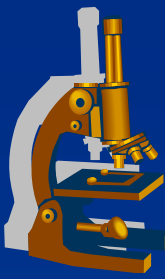


CARCINOMA
OF PROSTATE

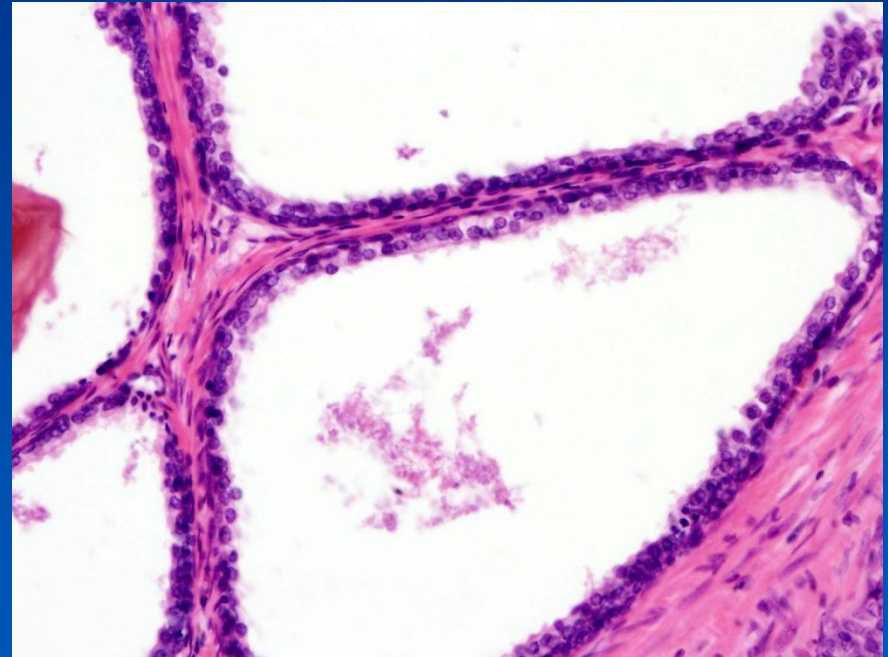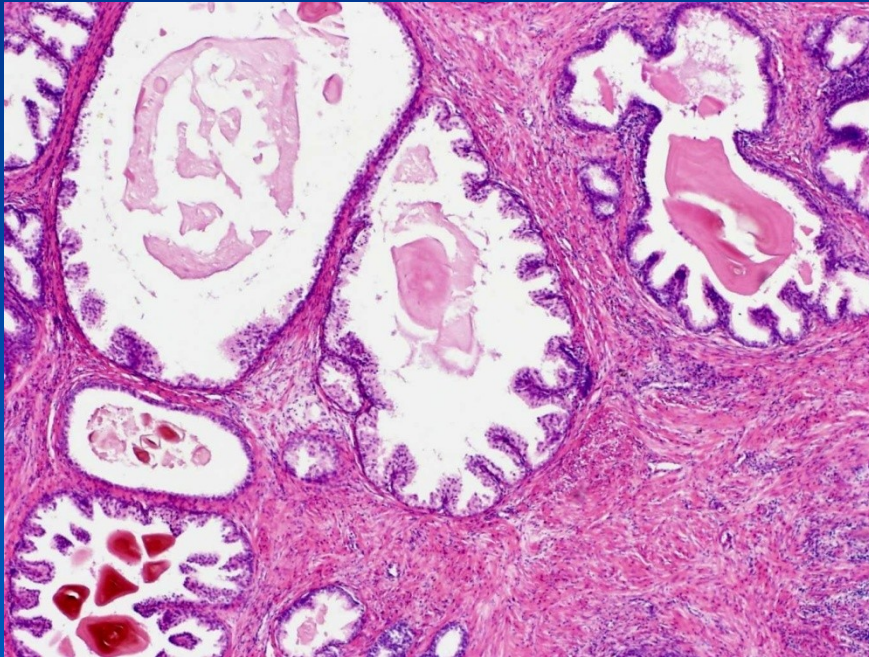
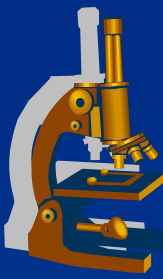
FIGURE 17-35

Normal prostate, nodular hyperplasia, and adenocarcinoma. In prostatic hyperplasia the nodules distort and compress the urethra and exert pressure on the surrounding normal prostatic tissue. Prostatic carcinoma usually arises from peripheral glands, in which case it does not compress the urethra.

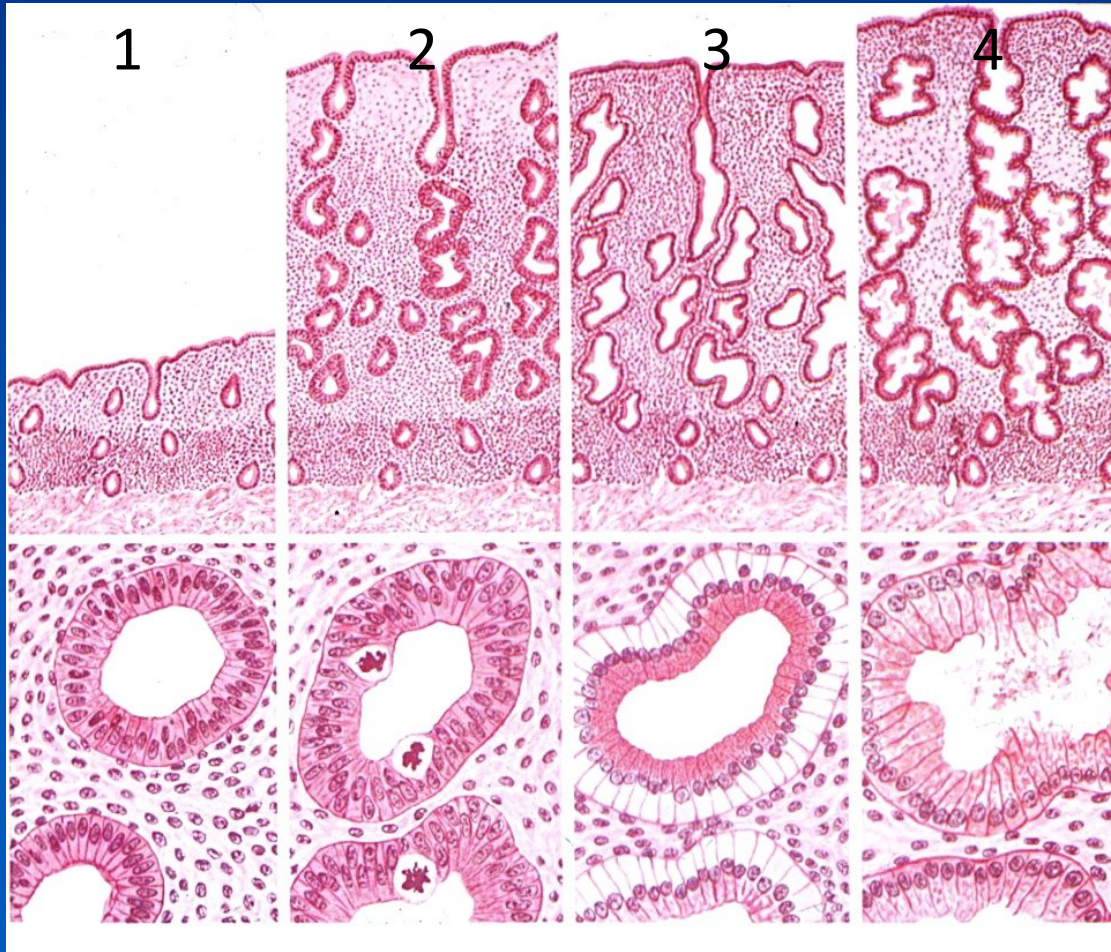
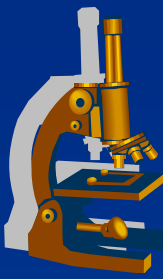
BENIGN PROSTATIC HYPERPLASIA



BENIGN PROSTATIC HYPERPLASIA

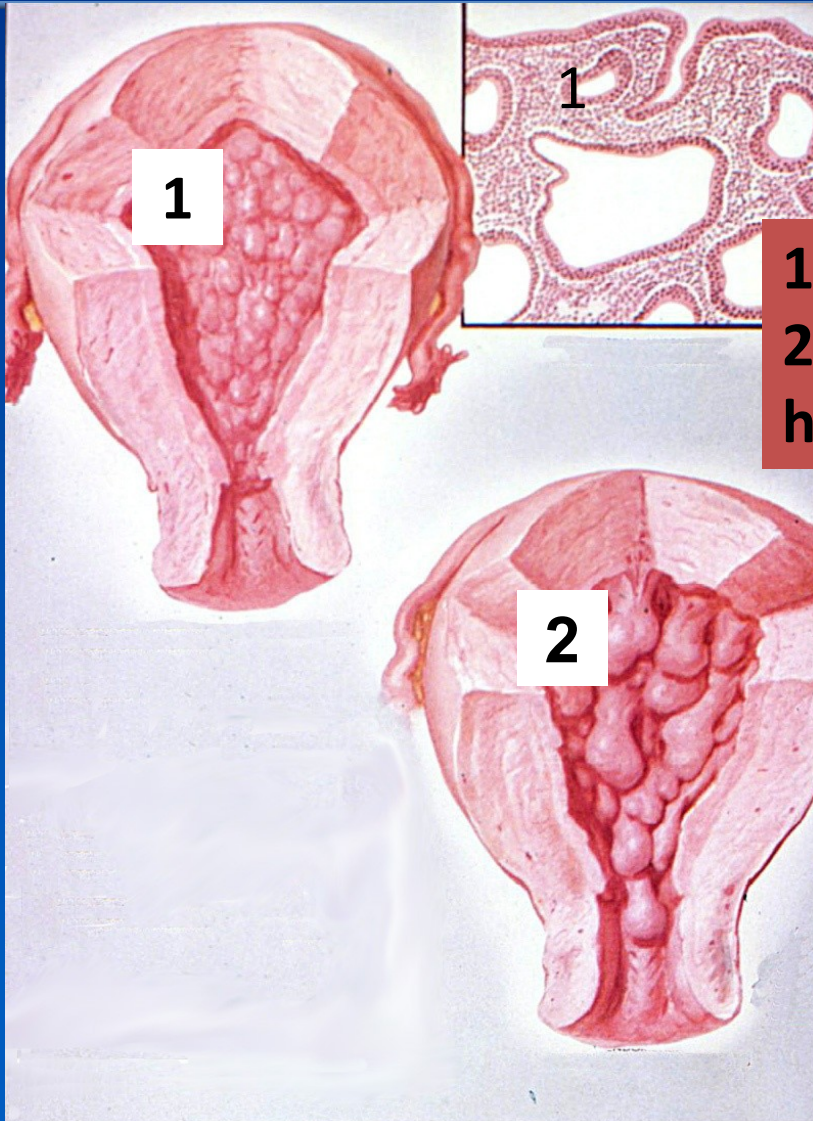
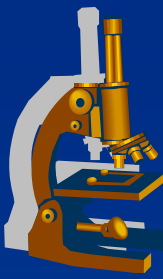


Endometrium, menstrual cycle



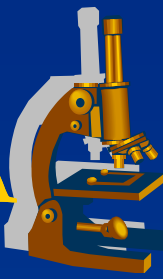
- 1 early proliferative
- 2 late proliferative
- 3 early secretory
- 4 mid/late secretory

Hyperplastic endometrium



1 endometrial hyperplasia
2 Polypous endometrial hyperplasia

ENDOMETRIAL HYPERPLASIA



× **Gross:** *thicker mucosa (USG)*

× **Micro:**

⇒ *both glandular and stromal proliferation*

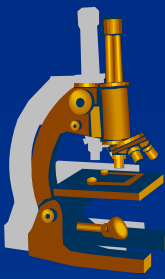
⇒ *glands more numerous (norm 1:1)*

⇒ *architectonics simple (cystic dilatation) or complex*

⇒ *proliferative epithelium (basal nuclei, possible stratification)*

⇒ *ATYPIA: nuclear enlargement, hyperchromasia, distinctive nucleoli, mitotic activity, anisokaryosis.*

Classification of endometrial hyperplasia



✘ Simple

- ⇒ *cystic glandular dilatation*
- ⇒ *increased glandular + stromal cellularity*
- ⇒ *no atypias*

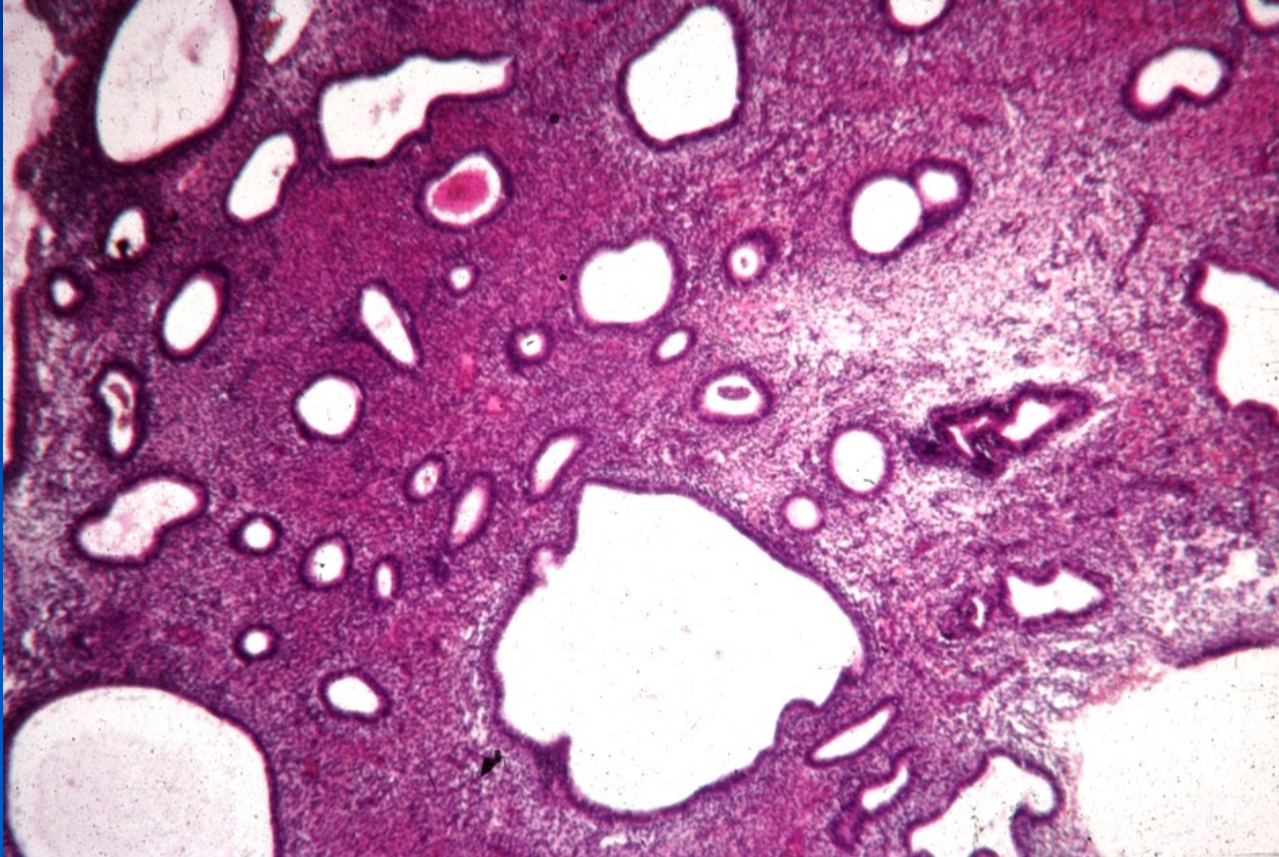
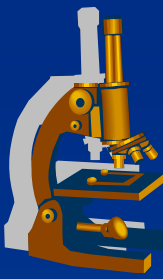
✘ Complex

- ⇒ *major architectural change – infoldings*
- ⇒ *lower amount of stroma – crowding*

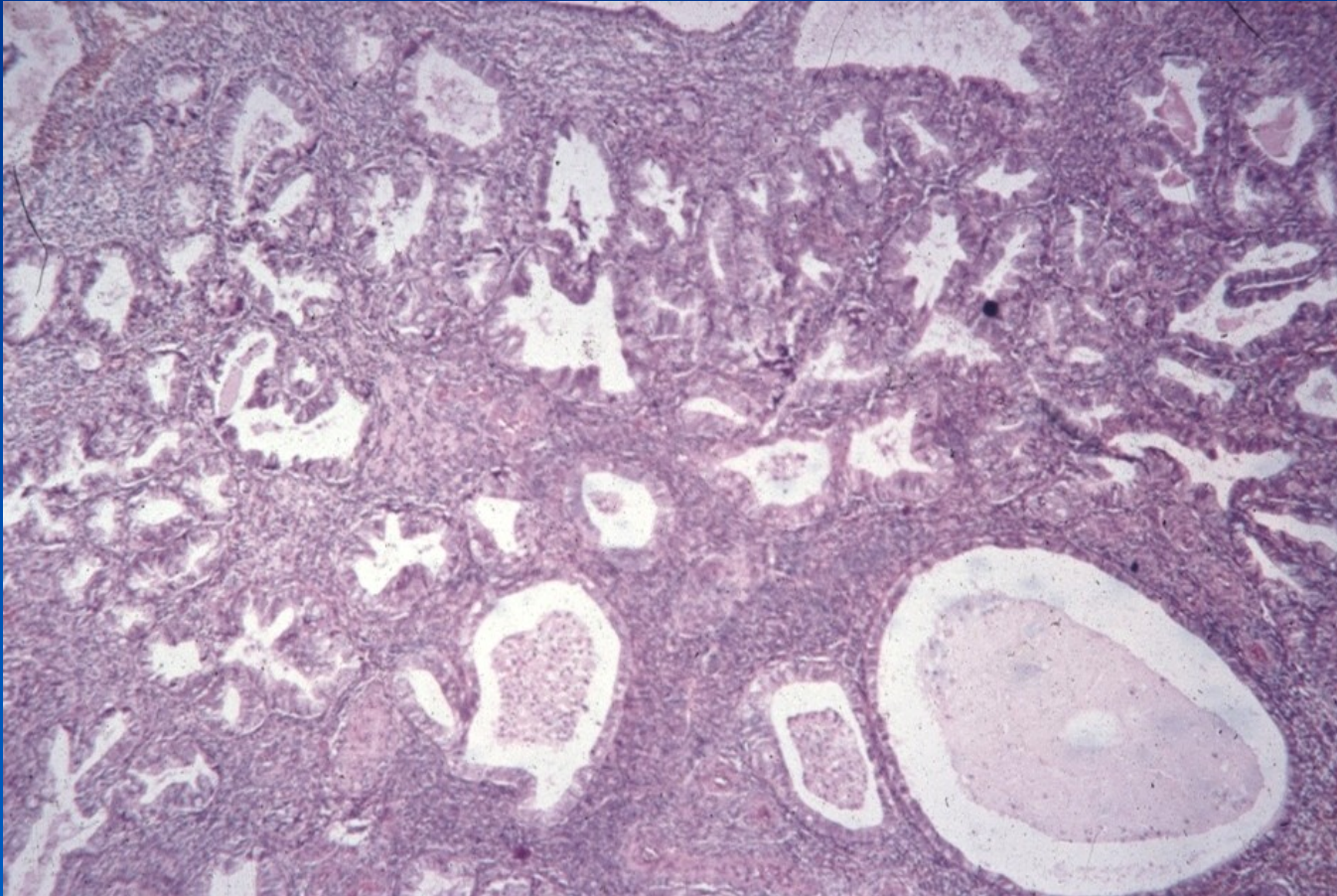
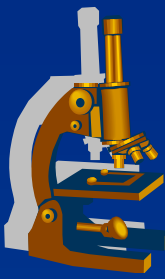
✘ Atypical (simple or complex)

- ⇒ *specify architecture: simple or complex + cellular atypia*
- ⇒ *endometrial intraepithelial neoplasia*

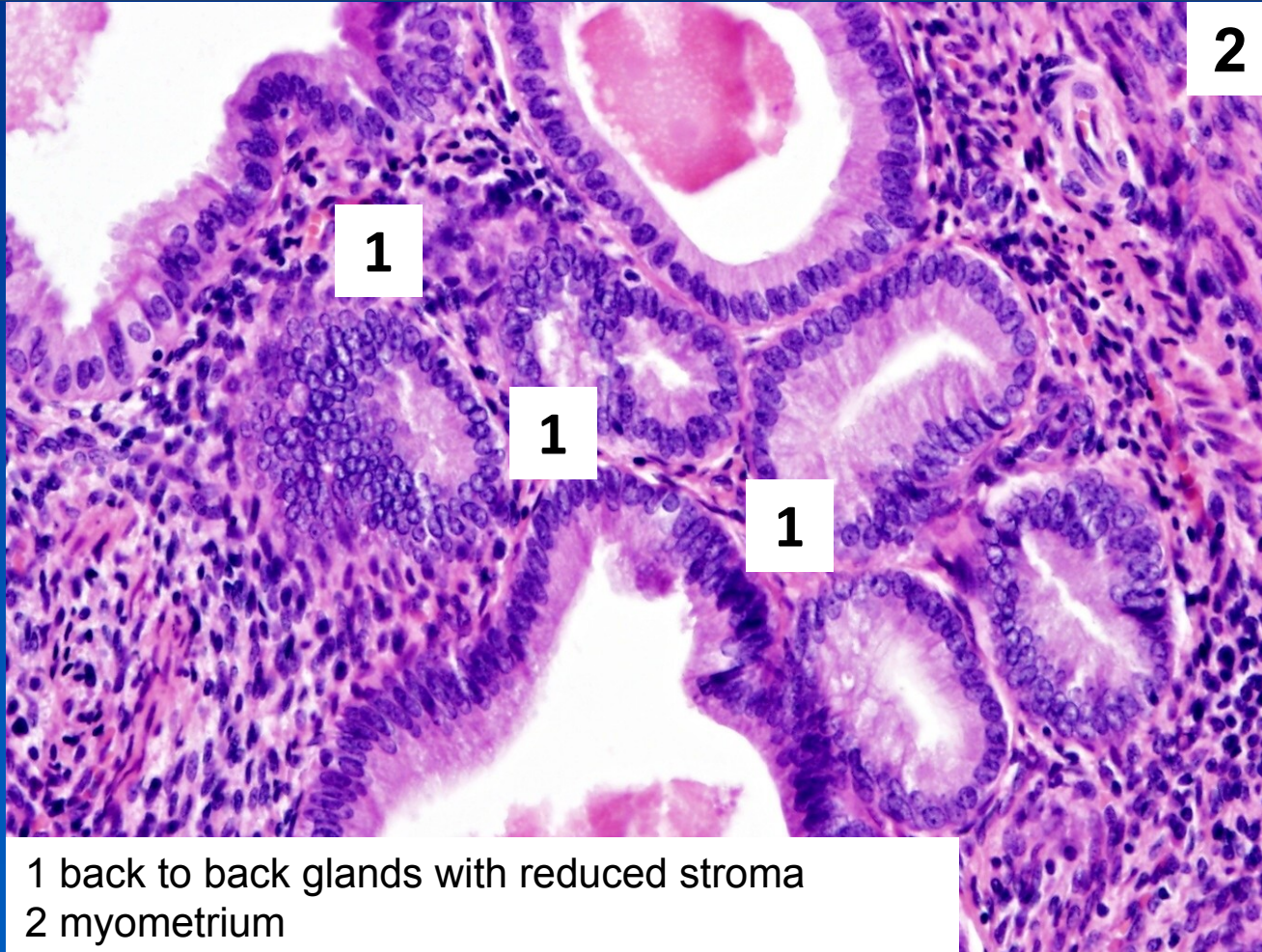
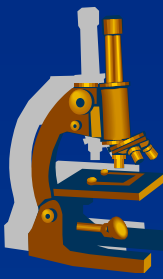
Simple hyperplasia



Complex hyperplasia

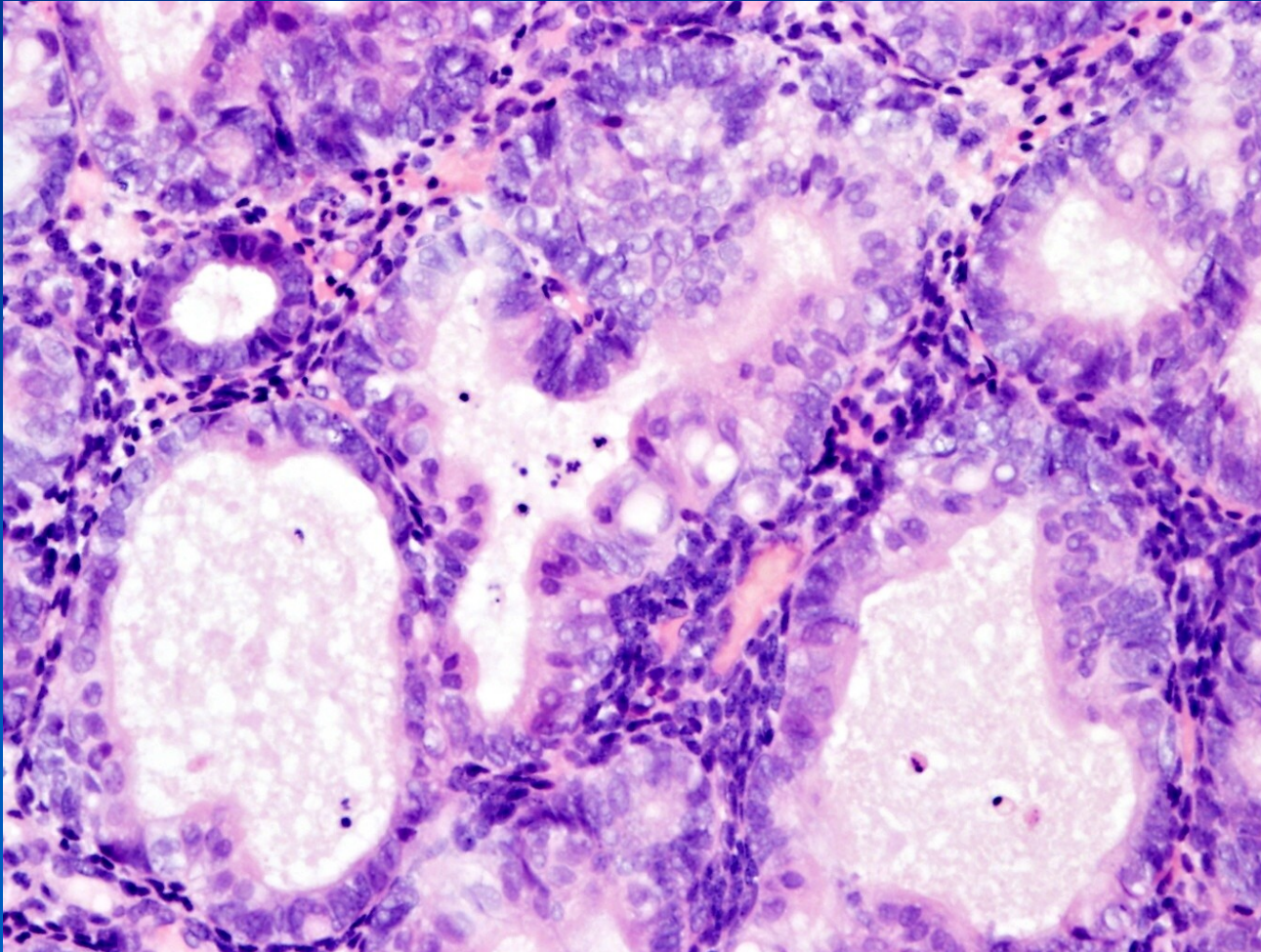
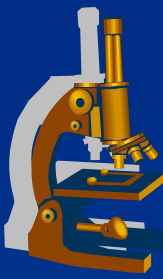


complex hyperplasia without atypia

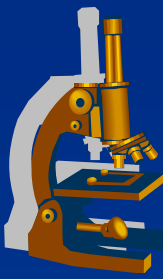


1 back to back glands with reduced stroma
2 myometrium

Complex hyperplasia with atypia



Thyroid hyperplasia



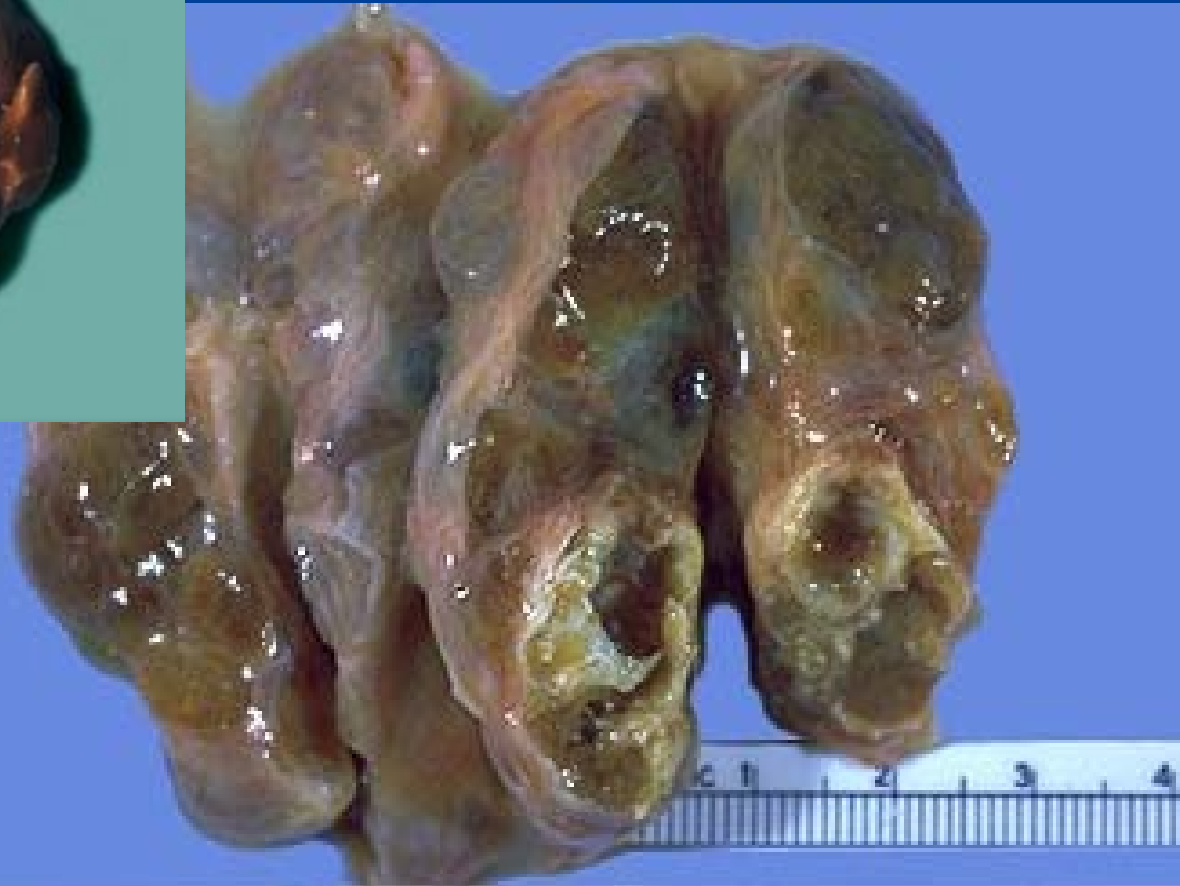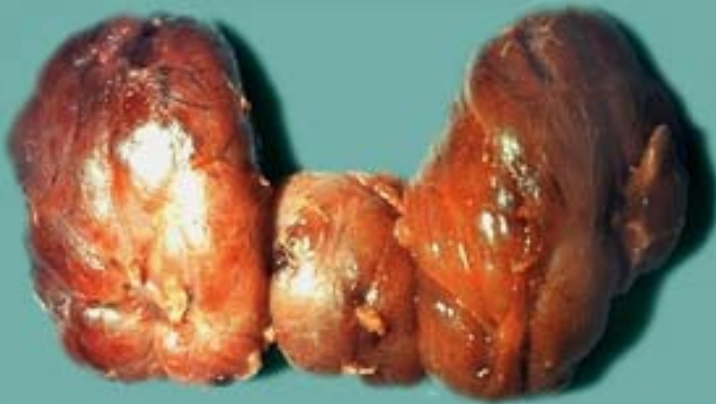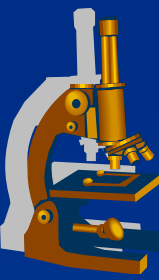
✗ Goiter

⇒ *diffuse*

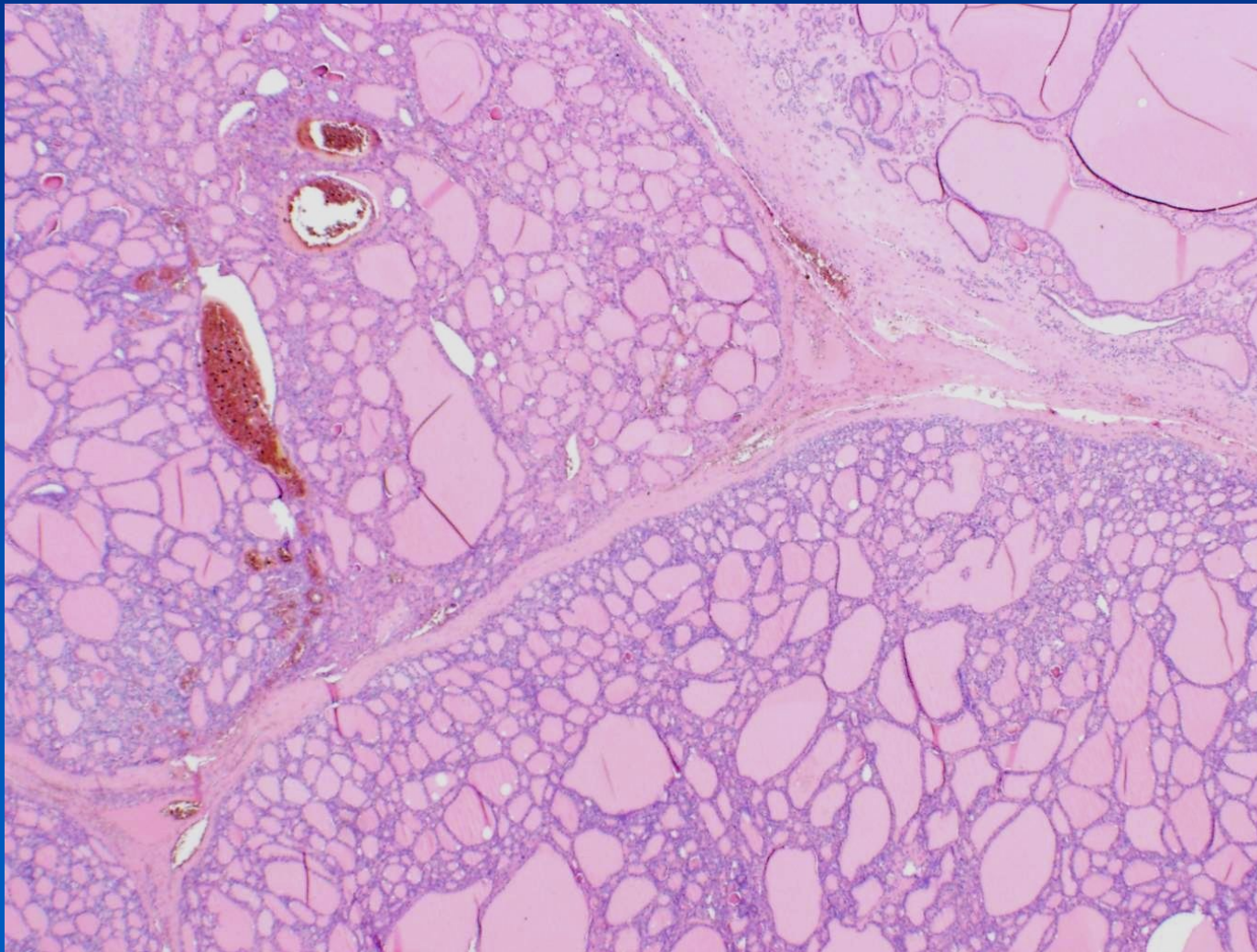
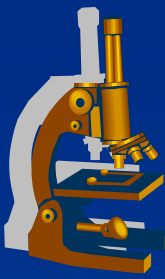
- simple – nontoxic
- Graves disease – autoimmune,
- diff. hyperplasia

✗ Nodular goiter

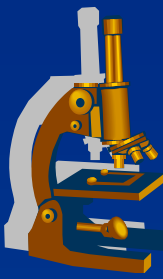
- ⇒ *activation of hypothalamic-pituitary-thyroidal axis (iodine deficiency)*
- ⇒ *hyperplastic phase, colloid transformation – involution*
- ⇒ *mixture of dilated follicles, regressive fibrosis, bleeding, calcification*



Thyroid hyperplasia nodular goiter

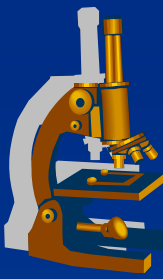


Graves' disease



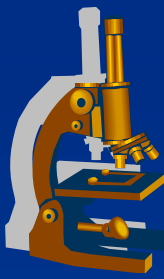
- × Hyperplastic thyroid → hyperthyroidism
- × Graves' (Basedow) disease
 - ⇒ *organ-specific AI,*
 - ⇒ *autoantibodies bind on TSH receptor – long-acting thyroid stimulator (LATS)*
- × **Gross** – *enlarged, firm, red*
- × **Micro** – *follicular hyperplasia, papillary, colloid reduction, stromal hyperaemia*

Hypertrophy



- × **increase in cell size without cell division** - ↑
production of cellular proteins
- × **physiological:**
 - ⇒ *muscle hypertrophy (response to increased workload)*
 - ⇒ *hormone-induced (pregnant uterus)*
- × **pathological conditions:**
 - ⇒ *myocardial hypertrophy – essential hypertension, valvular disease (aortal, mitral stenosis, etc)*
 - ⇒ *arterial wall hypertrophy in hypertension*

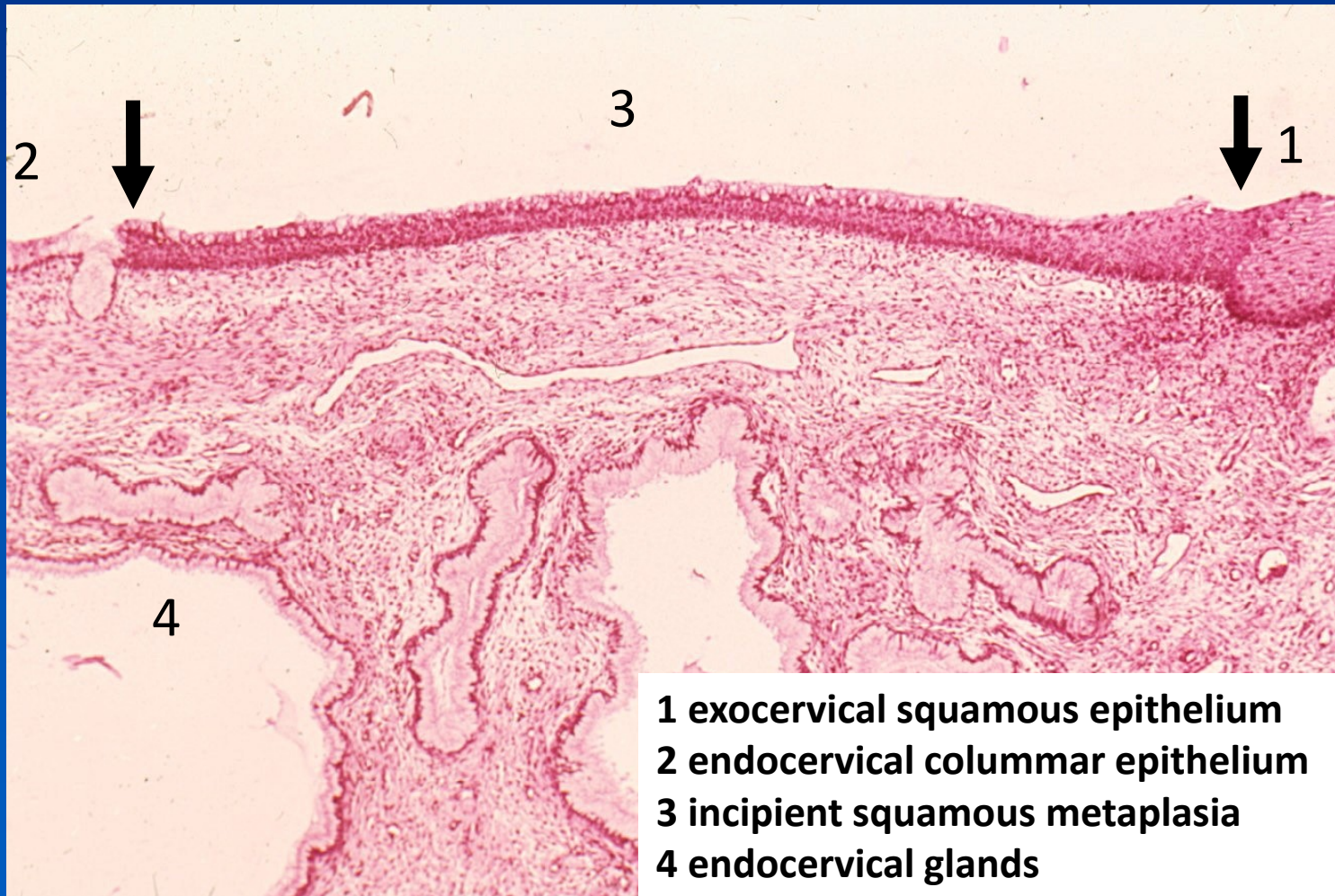
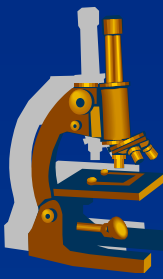
Metaplasia



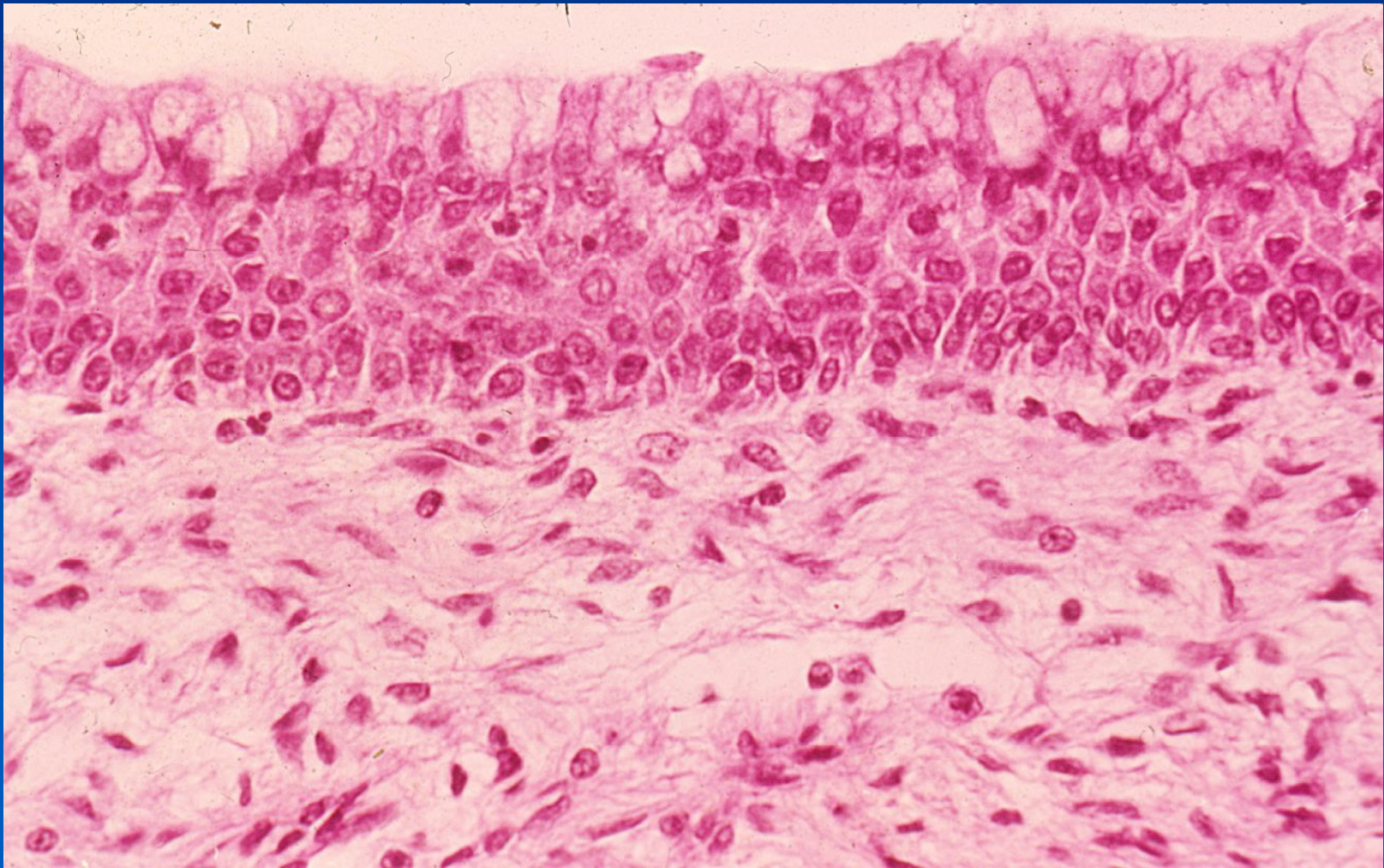
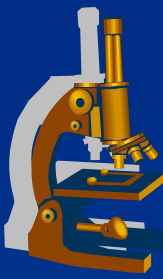
- ✗ reversible replacement of one mature differentiated cell type by another via stem cells (adaptive substitution under stress conditions)
- ✗ exaggerated differentiation (non-keratinizing squamous epithelium into keratinizing, cartilage ossification, ...)
- ✗ (rarely direct transformation of a cell by de-differentiation followed by different differentiation)
- ✗ epithelial or mesenchymal cells
- ✗ may undergo further indirect transformation to neoplasia via dysplasia

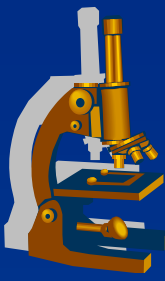
- ✗ chronic cell injury – smoking, reflux of gastric acid to oesophagus, etc.
 - ⇒ **squamous metaplasia (columnar → squamous)**
 - bronchial epithelium – smokers
 - endocervical mucosa
 - ⇒ **intestinal metaplasia**
 - Barret's oesophagus in reflux, gastric mucosa in chronic gastritis

Incipient squamous metaplasia of endocervical columnar epithelium

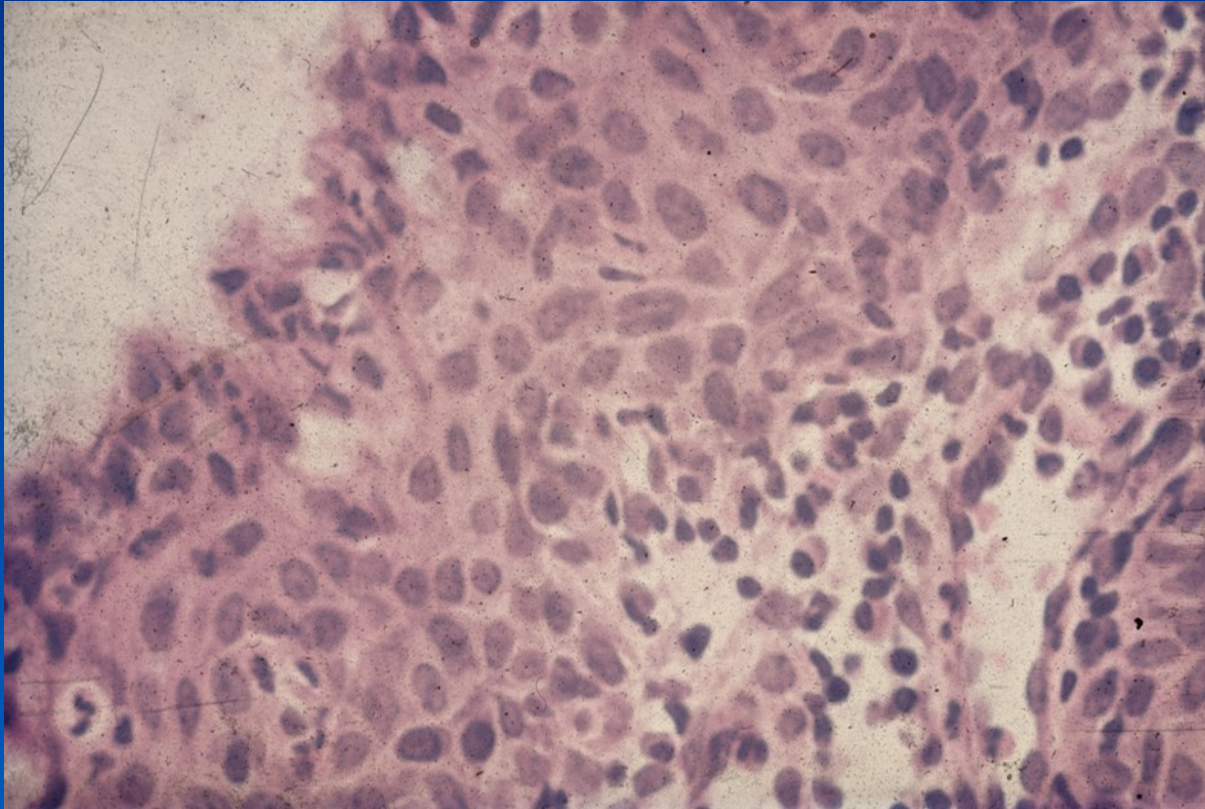


Incipient squamous metaplasia of endocervical columnar epithelium

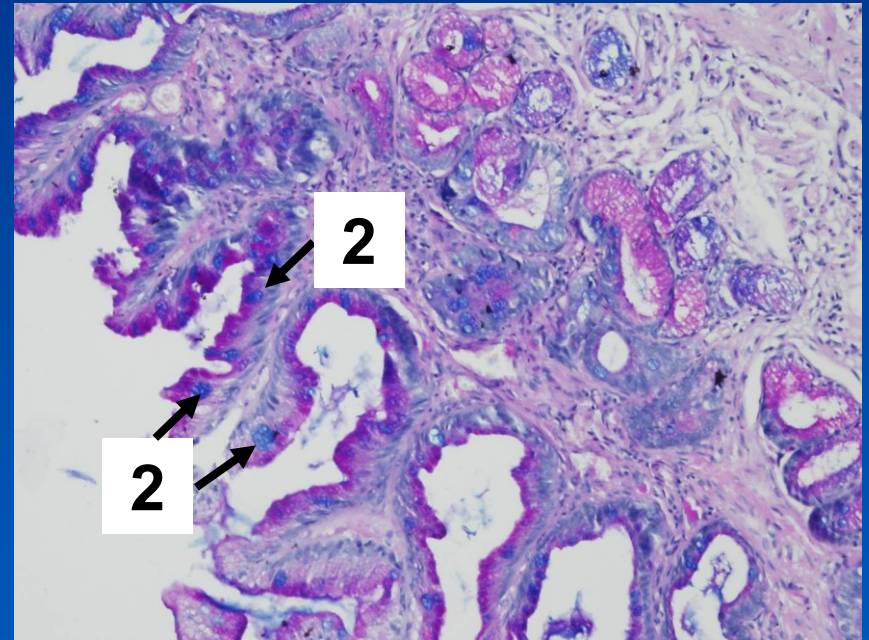
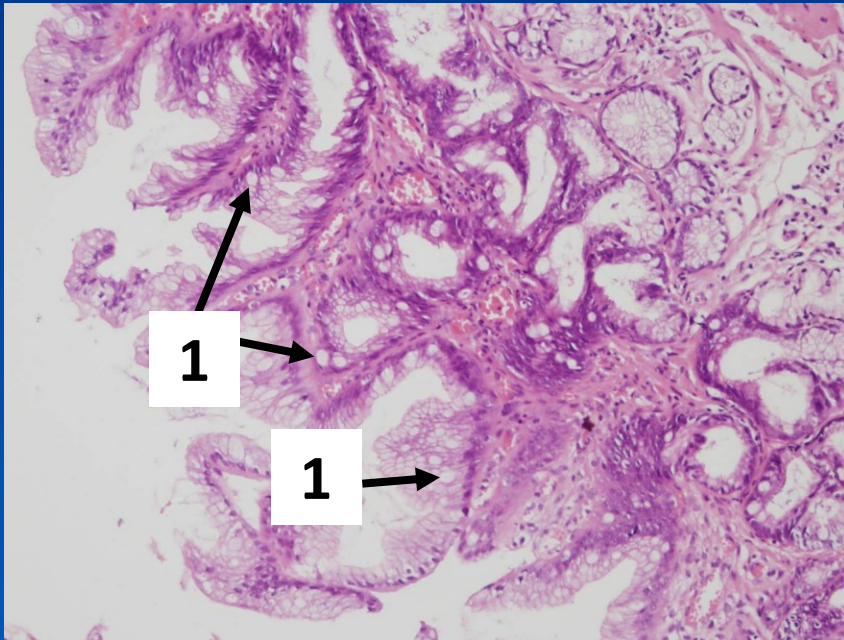
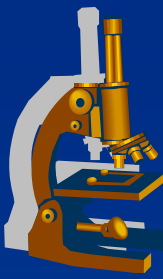




Immature sq. metaplasia

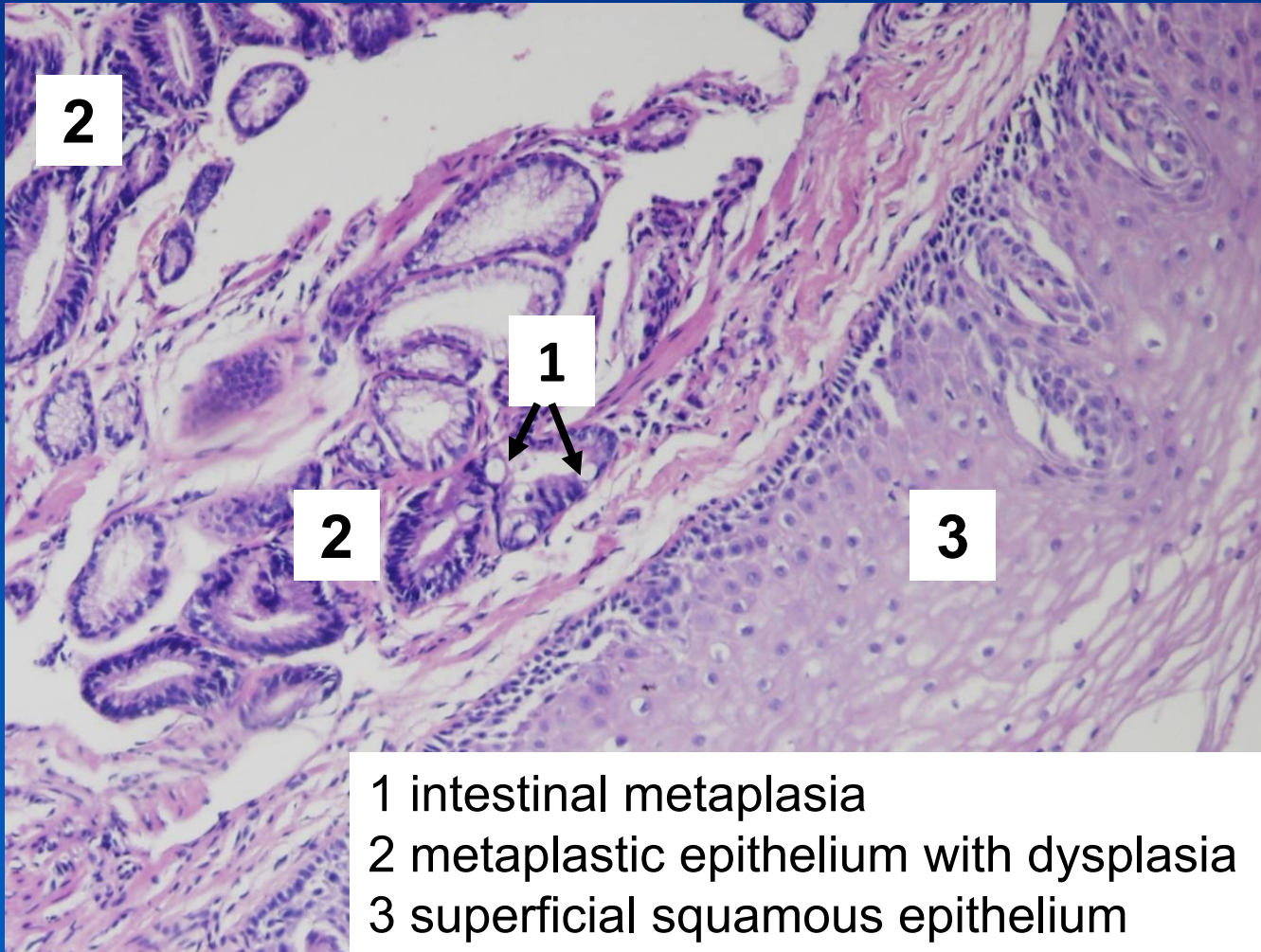
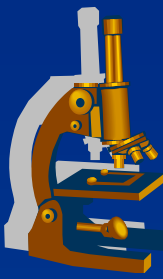


Barrett's oesophagus



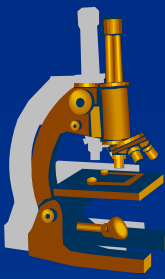
1 intestinal metaplasia (goblet cells)
2 PAS staining – acid mucin substances detection in metaplastic cells

Barrett's oesophagus



- 1 intestinal metaplasia
- 2 metaplastic epithelium with dysplasia
- 3 superficial squamous epithelium

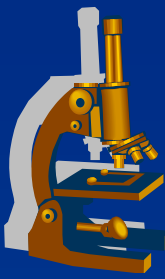
Tumour-like lesion



- ✗ a nonneoplastic demarcated growing focal lesion that resembles a true neoplasm (by naked eye or microscopy)
 - ⇒ *progressive changes*
 - ⇒ *cysts, pseudocysts*
 - ⇒ *chronic inflammation (inflammatory pseudotumor)*
 - ⇒ *embryonal development changes (hamartoma, choristoma)*

Tumour-like lesion

Progressive changes

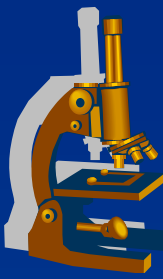


- × **Sometimes a preneoplastic change**
- × **hyperplasia, hypertrophy, hyperregeneration**
 - ⇒ e.g. nodular hyperplasia
 - nodular goiter,
 - benign prostatic hyperplasia, etc.

 - ⇒ **pseudoepitheliomatous hyperplasia** epithelial hyperplasia associated with chronic irritation and inflammatory response
 - e.g. squamous epithelium in the border of varicose ulcer

Tumour-like lesion

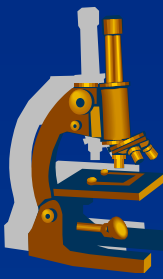
Cysts, pseudocysts



- ✗ cyst – pathological cavity lined by epithelium, usually fluid-filled
- ✗ pseudocysts lack epithelial / endothelial / mesothelial lining cells
 - ⇒ e.g. pancreatic pseudocyst, postmalatic pseudocyst

Tumour-like lesion

Cysts, pseudocysts

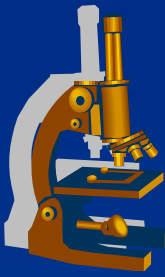


x common types of cysts:

- ⇒ **congenital** – due to embryonal defect
 - branchial, thyroglossal, familial polycystic disease
- ⇒ **retention** – epidermoid, pilar cysts of the skin
- ⇒ **implantation** – as a result of surgical or accidental implantation of epidermis
- ⇒ **parasitic** – hydatid cysts due to Echinococcus
- ⇒ **neoplastic - true tumors**– e.g. cystadenoma, cystadenocarcinoma

Tumour-like lesion

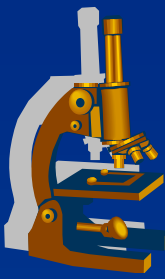
Cysts, pseudocysts



- x solitary x multiple / polycystosis**
- x according to content (serous, mucinous, sebaceous, colloid, hemorrhagic, ...)**

Tumour-like lesion

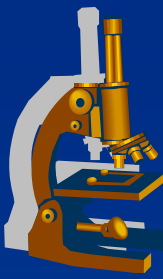
Chronic inflammation



- ✗ part of a repair process (suture granuloma)
- ✗ relapsing/chronic purulent inflammation (pelvic inflammatory disease, actinomycosis)
- ✗ xanthoma (accentuated macrophagic reaction, yellow color)
- ✗ inflammatory polyp/hyperplasia

Tumour-like lesion

Embryonal maldevelopment



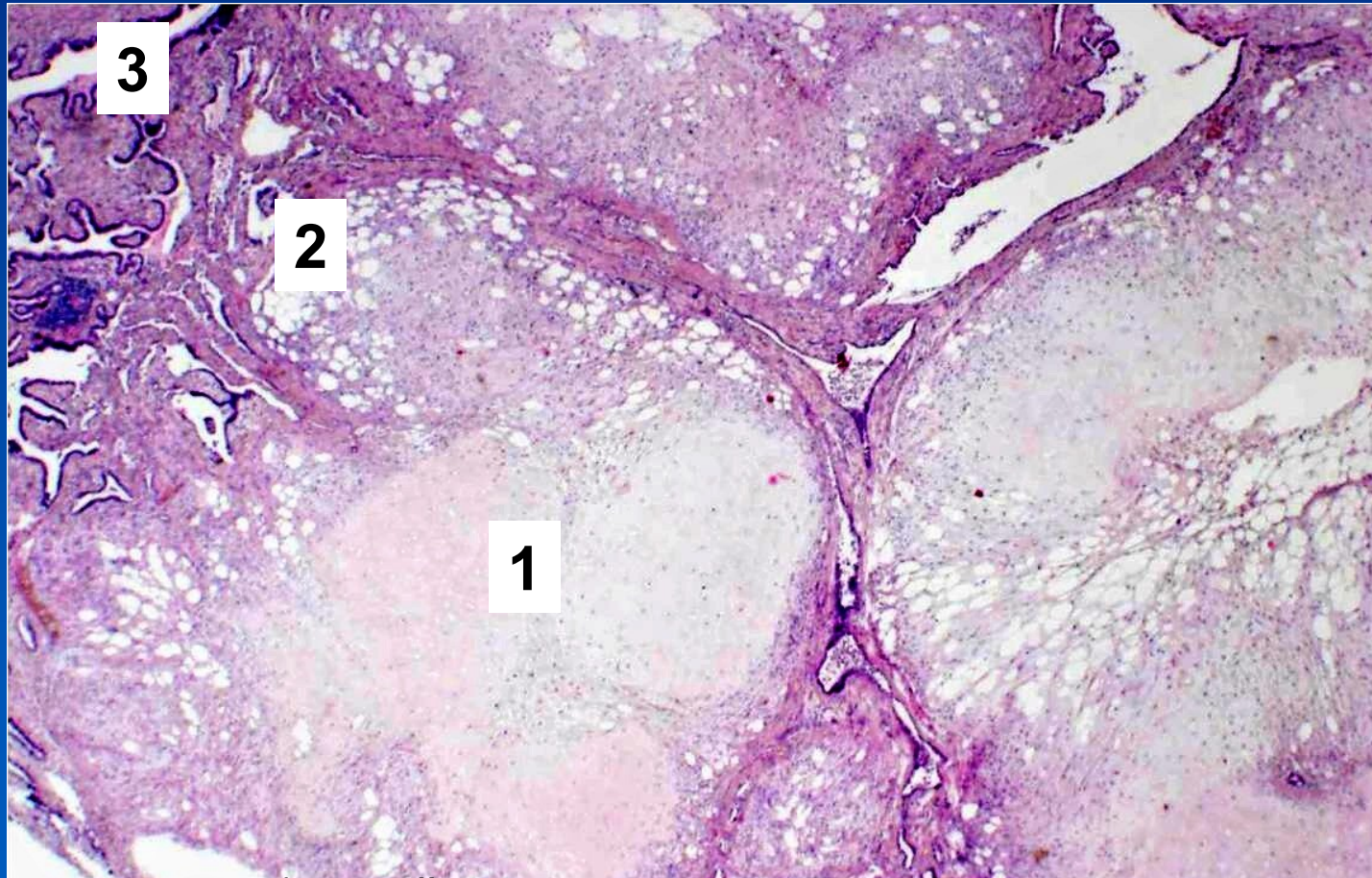
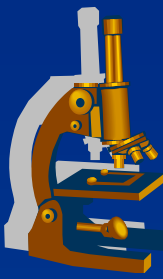
× **choristoma**

- ⇒ mass of histologically normal tissue that is present in an abnormal location – heterotopic tissue rest
- ⇒ adrenal choristoma in kidney, etc.

× **hamartoma**

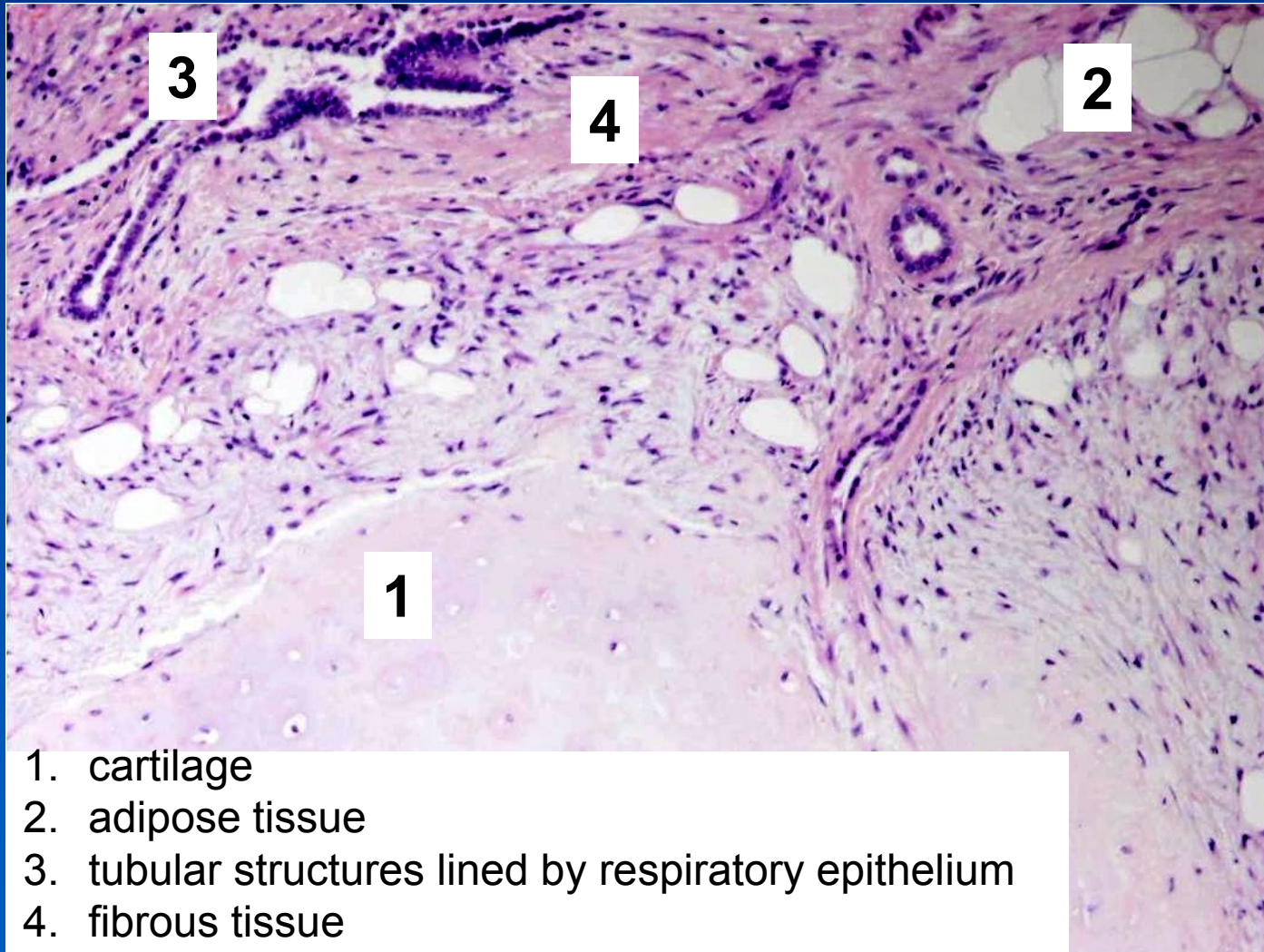
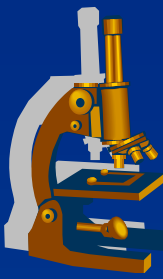
- ⇒ benign malformation consisting of an disorganized abnormal mixture of mature indigenous cells and tissues
- ⇒ chondrohamartoma of lung (possibly a true tumor) , etc.

chondrohamartoma of lung

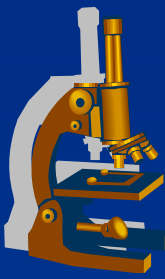


1. cartilage
2. adipose tissue
3. tubular structures lined by respiratory epithelium

chondrohamartoma of lung

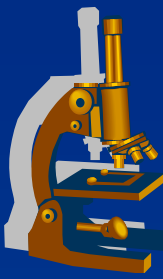


1. cartilage
2. adipose tissue
3. tubular structures lined by respiratory epithelium
4. fibrous tissue



General oncology

General oncology



× tumour

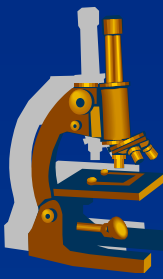
⇒ lesion with persistent autonomous abnormal growth / unregulated cell division

× tumour structure:

⇒ parenchyma (neoplastic cells)

⇒ stroma (connective tissue - support and nutrition) – inadequate stroma → possible regressive changes

General oncology



x **epithelial dysplasia** = premalignant condition

⇒ *micro:*

- **loss of normal maturation/differentiation**
- **cellular atypia**
 - cellular pleomorphism, ↑ N/C ratio, hyperchromatism
- changes in the structural arrangement of cells in the epithelium

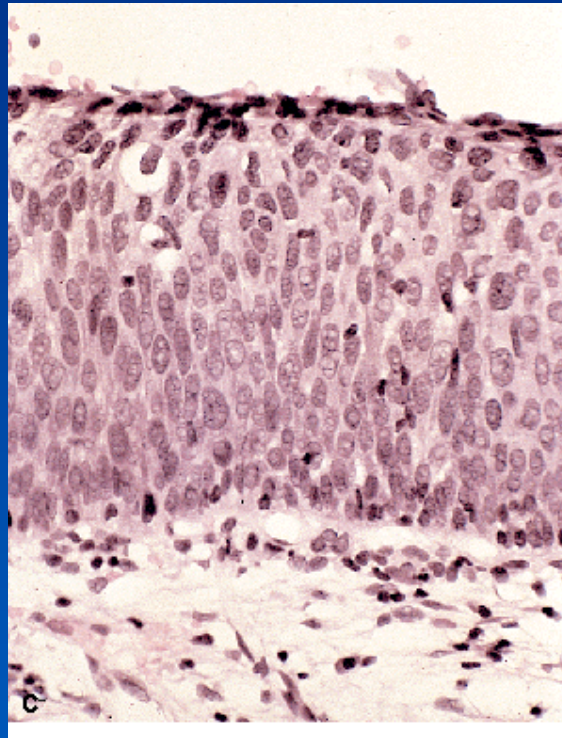
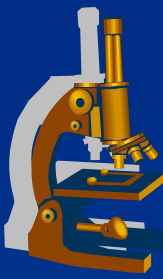
⇒ *classification:*

- **Low-grade (mild) x high-grade (moderate/severe) dysplasia**

⇒ *may be caused by chronic inflammation, irritation (physical or chemical injury), carcinogenic agents (HPV)*

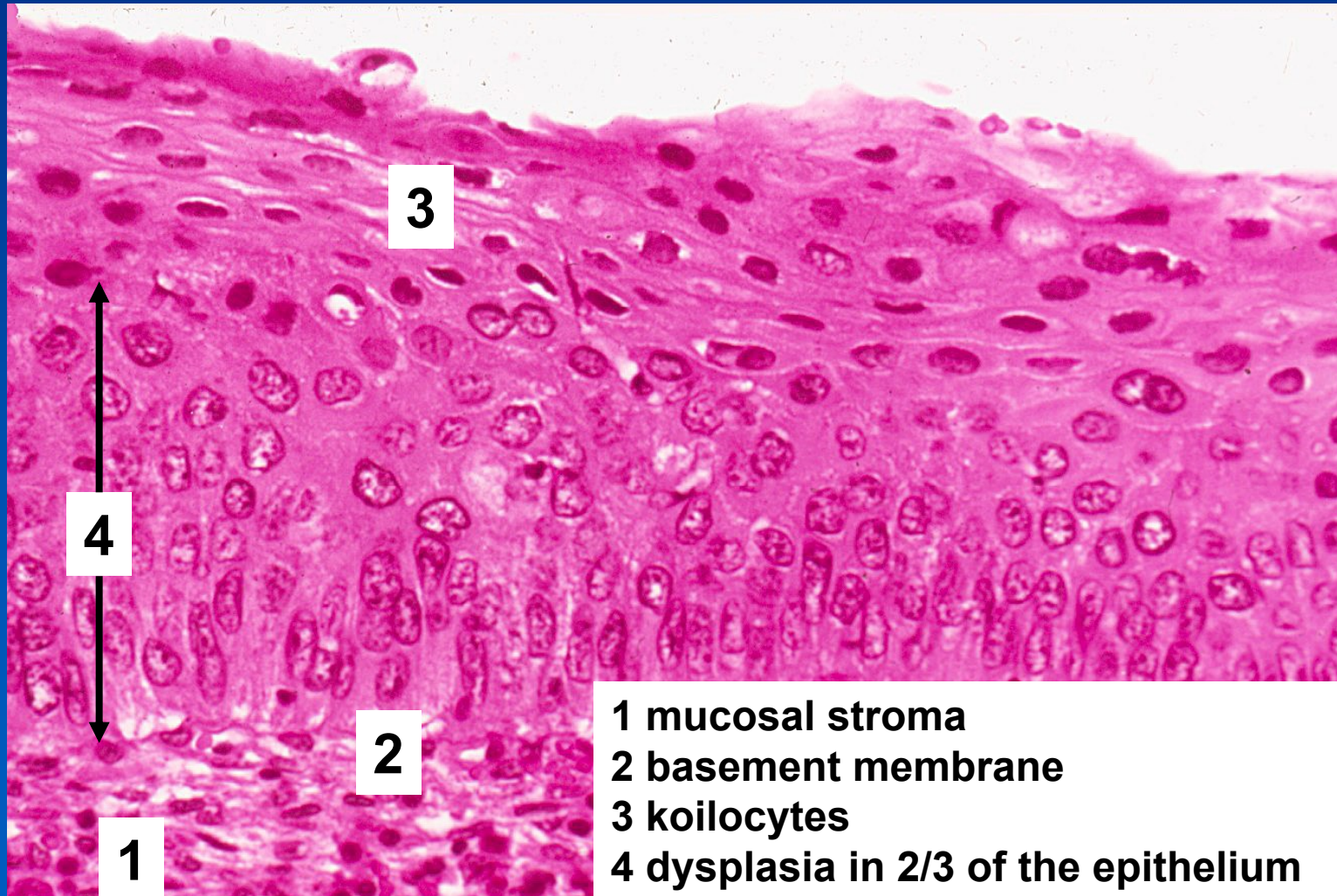
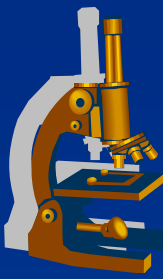
⇒ *may be reversible in early stages (low-grade dysplasia), high-grade dysplasia has a higher risk of progression to carcinoma in situ or invasive carcinoma*

Cervical dysplasia
High-grade CIN (CIN II)



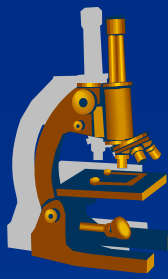
Cervical dysplasia

High-grade CIN (CIN II)



- 1 mucosal stroma
- 2 basement membrane
- 3 koilocytes
- 4 dysplasia in 2/3 of the epithelium

General oncology



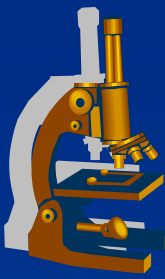
x anaplasia

- ⇒ *loss of cell differentiation*
- ⇒ *morphology of anaplastic tumors may mimic immature/embryonal tissue*

x carcinoma in situ

- ⇒ *localized epithelial neoplasm with all the cellular features of malignancy, but without invasion through epithelial basement membrane*
- ⇒ *often together with dysplasia in the group (concept) of intraepithelial neoplasia (named after localisation – CIN, PIN, VIN, PanIN, etc.)*

General oncology



x **invasive carcinoma**

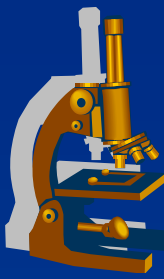
- ⇒ *the final step in the process of carcinogenesis*
- ⇒ *invasion of tumor cells through the basement membrane*
- ⇒ *metastatic potential*

x **desmoplasia / desmoplastic stromal reaction**

- ⇒ *proliferation of connective tissue, stromal response to neoplastic process.*

General oncology

Carcinogenesis



x Multifactorial, complex

⇒ external factors

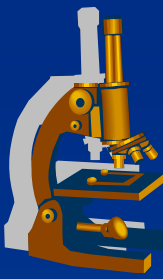
- ionising, non-ionising radiation
- carcinogens (tobacco smoke, aflatoxins, nitrosamines)
- oncogenic viruses (HPV, EBV, HTLV-1, HSV-8), bacteria (Helicobacter)

⇒ endogenous factors - hereditary

- approx. 15% of malignancies due to genetic factors
- inherited tumor risk – breast/ovary carcinoma by mutation *BRCA1* či *BRCA2*; *familial polyposis coli*, *neurofibromatosis*, *retinoblastoma*, *Li-Fraumeni syndrome*

General oncology

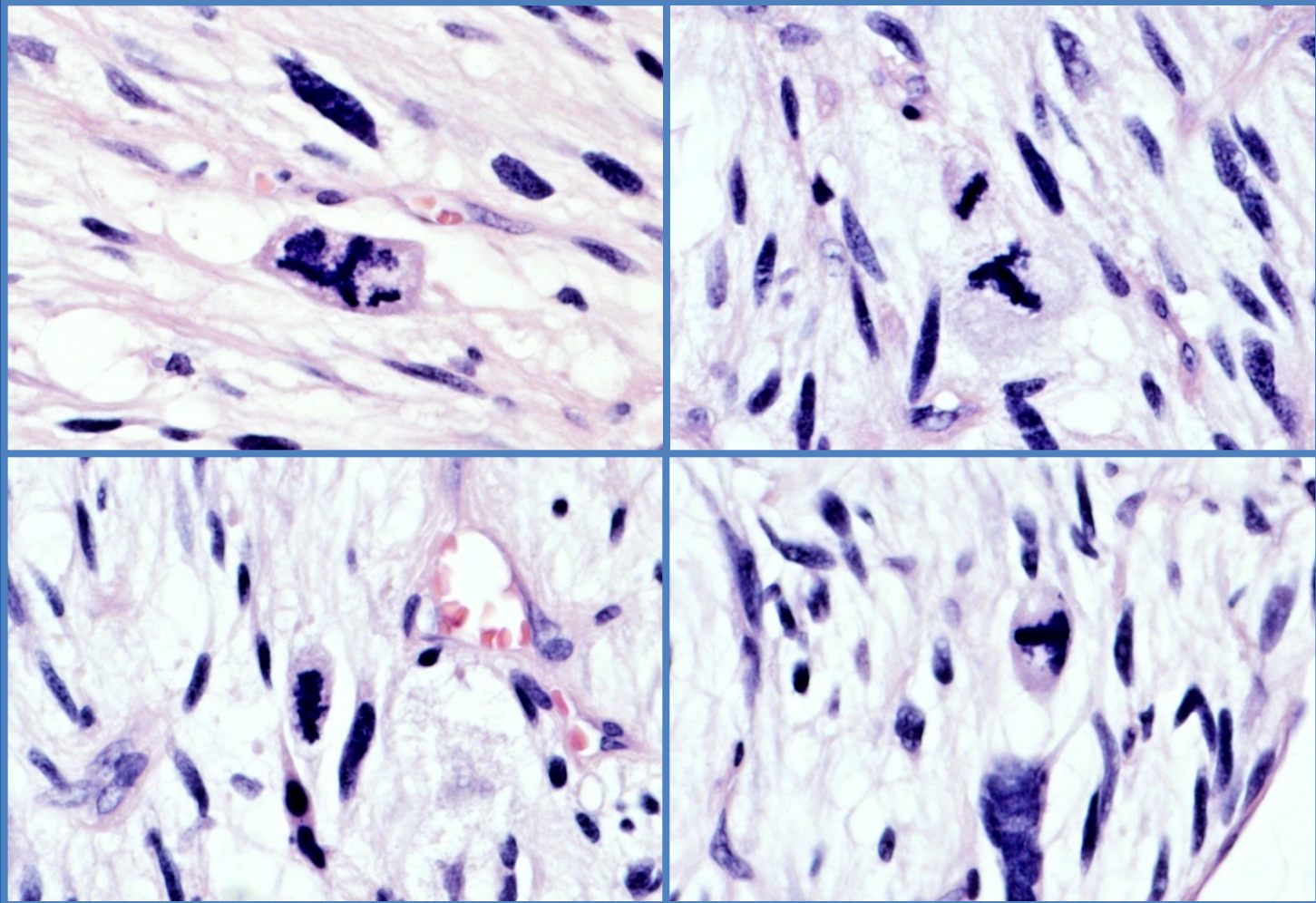
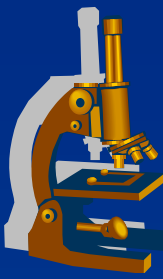
signs of malignancy

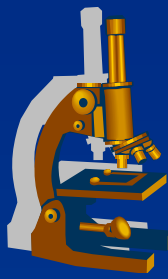


x CYTOLOGIC CHANGES (ATYPIA) :

- ⇒ *cytologic and/or nuclear pleomorphism, anisokaryosis, anisocytosis*
- ⇒ *nuclear enlargement*
- ⇒ *increased nucleocytoplasmatic index (N/C)*
- ⇒ *nuclear hyperchromasia*
- ⇒ *irregular chromatin texture*
- ⇒ *irregular shape of the nuclear membrane (grooves)*
- ⇒ *increased mitotic activity*
- ⇒ *atypical mitoses (tripolar, multi-center, asymmetrical)*
- ⇒ *sometimes multinucleated cells*

Atypical mitosis (tripolar)

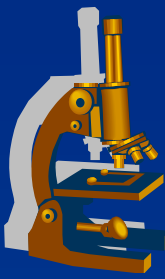




Principal characteristics of benign and malignant tumors

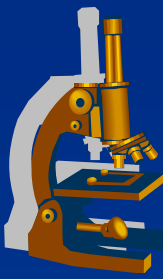
	benign	malignant
Histological resemblance to normal tissue	Good	Variable, often poor
Mitotic activity	Low	High + atypical
Grow rate	Slow	Relatively rapid
Nuclear morphology	Often normal	Usually hyperchromatic
Border	Often circumscribed or encapsulated	Often poorly defined or irregular
Necrosis	Rare	Common
Invasion	No	<u>Yes (often)</u>
Metastases	Never	Frequent

Nomenclature of tumours



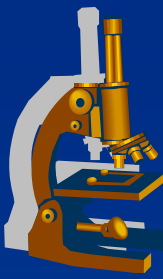
- ✘ All have the suffix „-oma“
- ✘ Benign epithelial tumor: papilloma, adenoma
- ✘ Benign connective tissue have a prefix denoting the cell of origin (fibr- , leiomyo-, hemangio -, lipo - ,...)
- ✘ Malignant epithelial tumors are carcinomas
- ✘ Malignant connective tissue tumors are sarcomas

Examples of tumour nomenclature



Type	Benign	Malignant
Epithelial Squamous cell Glandular	Squamous cell papilloma Adenoma	Squamous cell carcinoma Adenocarcinoma
Mesenchymal Smooth muscle Adipose tissue Blood vessels	Leiomyoma Lipoma Angioma	Leiomyosarcoma Liposarcoma Angiosarcoma

TUMOUR DIAGNOSIS



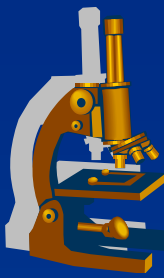
1. MICROSCOPIC

⇒ + *event. IHC, electron microscopy, molecular biology, genetics*

2. TUMOUR TYPE (histogenetic)

- epithelial,
- mesenchymal
- neuroectodermal
- germinal
- mixed
- (choriocarcinoma)
- (mesothelial)

TUMOUR DIAGNOSIS



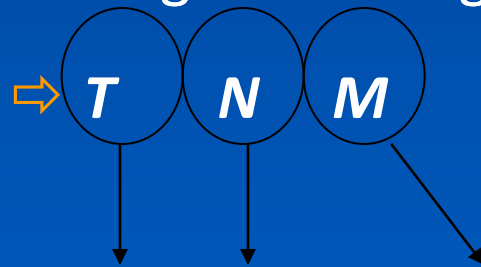
3. GRADING

⇒ histologic grade of malignancy » possible biologic behaviour

⇒ G1 – G4 well differentiated - undifferentiated

4. STAGING

⇒ stage according TNM classification



tumor node metastasis

diagnostic algorithm



clinical signs
clinical examination



cancer suspicion

yes

no

diagnostic imaging techniques
(x-ray, CT, MRI, ...USG, ...)



no

suspected cancer

yes

benign tumor,
pseudotumor

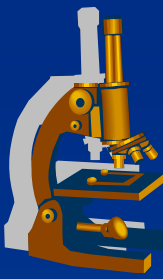
Cancer staging →
therapy

exploratory biopsy

typing,
grading,
staging

malignant
tumor

Tumor code

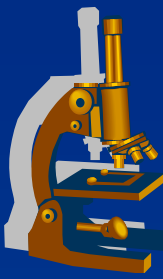


- ✘ WHO International Classification of Diseases for Oncology (ICD-O):
 - ⇒ *numerical classification and coding system by topography and morphology*

- ✘ TNM Classification of Malignant Tumors (UICC), AJCC Cancer Staging Manual:
 - ⇒ *coding system of tumor stage*

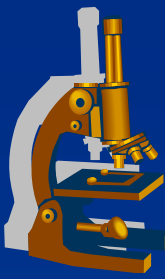
- ✘ WHO Classification of Tumours, Pathology and Genetics:
 - ⇒ *histologic classification by organ system*

Tumor code



- ✘ Topography (localization) C00.0 – C80.9
(lip – unknown primary localization)
- ✘ Subdivision: C34 lung
 - C34.0 main bronchus
 - C34.1 upper lobe
 - ...

Tumor code



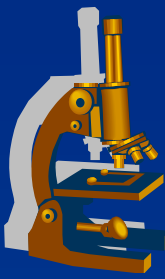
Morphology (histology): digital

× 4 digits – basic histogenetic structure

8070 – tumor of squamous cell

8140 – tumor of glandular cell

Tumor code



Morphology (histology): digital

×5. digit – biologic behaviour

/0 benign (incl. low grade dysplasia)

/1 uncertain, intermediate biologic behaviour, low malignant potential

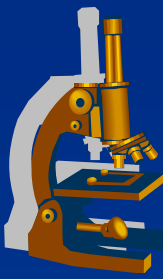
/2 high grade dysplasia, carcinoma/melanoma in situ

/3 malignant, primary localization

/6 malignant, metastasis

/9 malignant, unknown if primary or metastatic

Tumor code



Morphology (histology): digital

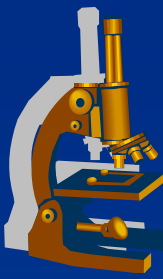
× 6. digit : grading/differentiation of malignant tumors

1 – 4 well – moderate – low – undifferentiated

8140/0 adenoma

8140/31: well differentiated adenocarcinoma in primary localization

Tumor code

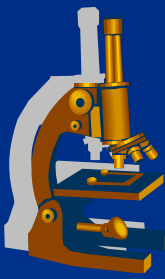


Staging

T size or contiguous extension of the primary tumor

N absence or presence/extent of cancer in the regional draining lymph nodes

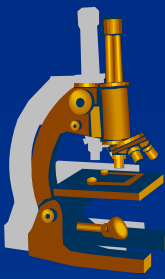
M absence or presence of distant spread or metastasis



Tumor code

- × **T0** no evidence of primary tumor
- × **Tis** tumor in situ
- × **T1, T2, T3, T4** increasing size/local extension
- × **TX** primary tumor cannot be assessed
- × similarly **N0, N1-4, NX**
- × **M0, M1**

Tumor code



Example:

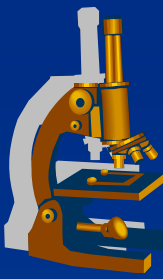
C16.1

M-8140/33

pT3,pN3,pM1

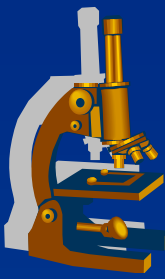
Poorly differentiated adenocarcinoma of stomach fundus with extension into subserosal connective tissue, metastases in 7 or more LN, with distant metastases

Treatment of tumors



- ✗ cancer treatment is striving to reduce (ideally eliminate) all tumor cells
- ✗ problems: inoperable tumors, resistance to therapy, toxicity of therapy, late side effects of treatment
- ✗ palliative care
 - ⇒ *supportive care provided to patients with incurable diseases in order to improve the quality (often not the quantity) of life*
- ✗ **prevention is the most effective !!!**

Treatment of tumors



x surgery

- ⇒ *cancer location !!! Mostly solid tumors x leukemia*
- ⇒ *the goal of treatment is usually to remove the tumor with surgery*

x chemotherapy

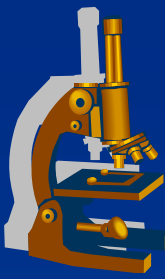
- ⇒ *are most often used for treating leukemia, lymphoma*
- ⇒ *neoadjuvant therapy*
 - aims to reduce the size or extent of the cancer before using radical treatment intervention)

x radiation

x hormone therapy

- ⇒ *breast carcinoma, prostatic carcinoma,...*
- ⇒ *the histological examination determined the presence of hormone receptors on tumor cells*

Treatment of tumors



- ✘ biological therapy

- ⇒ *type of treatment that works with your immune system*

- X chemotherapy attacks the cancer cells directly*

- ⇒ *cytokines (IFN α , IFN γ , IL-2), monoclonal antibodies*

- ✘ gene therapy in the future ???