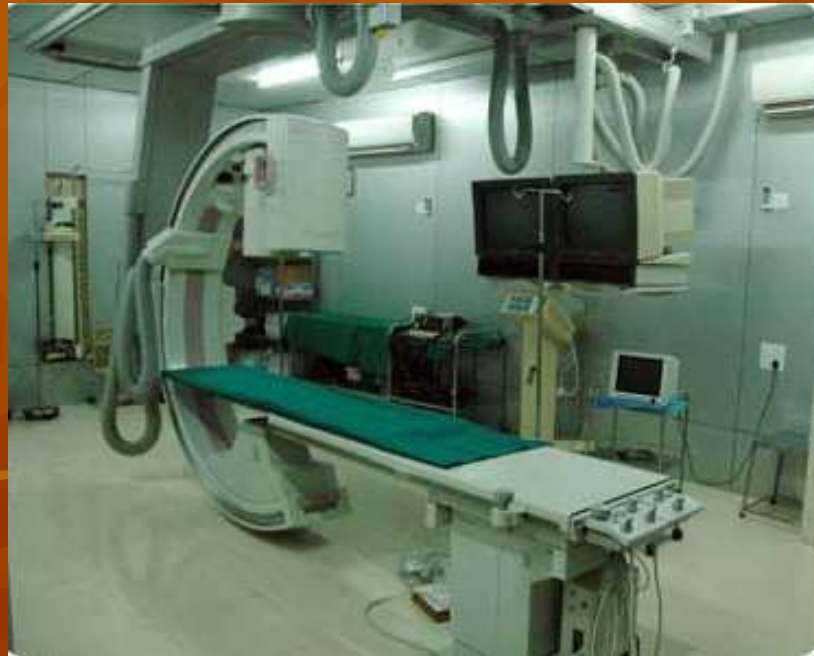

Examination of arterial system

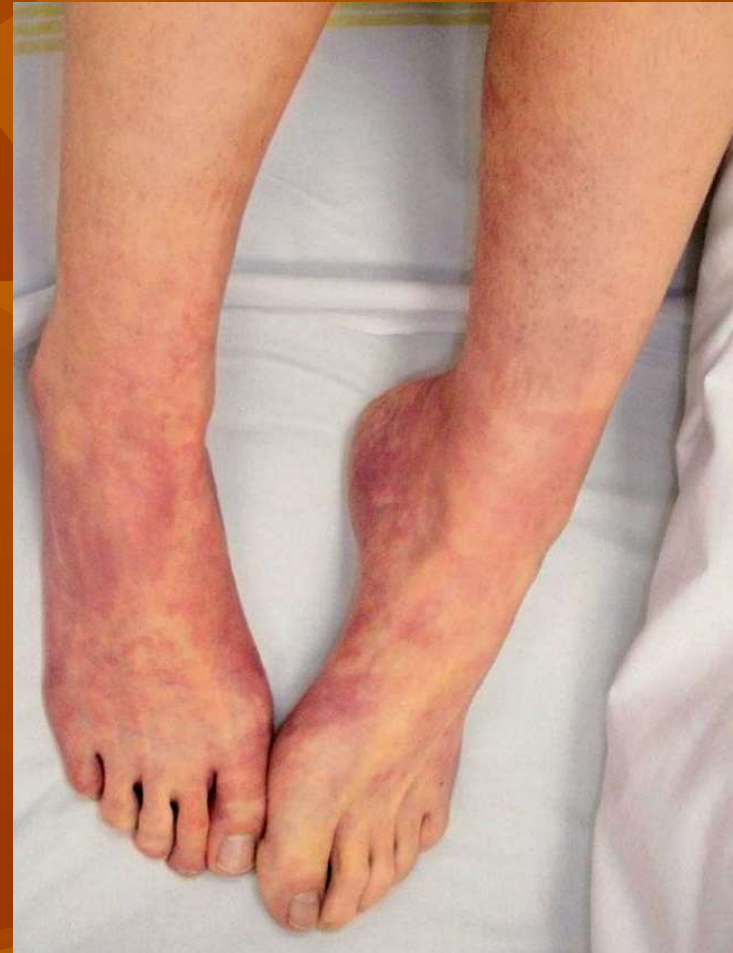

Methods:

- Invasivity:
 - Invasive
 - Non-invasive
- Modality used in the method
 - Physical examination
 - Acoustic
 - Electromagnetic
 - Magnetic resonance
- Most methods try to verificate or visualise stenosis caused by atherosclerotic lesion

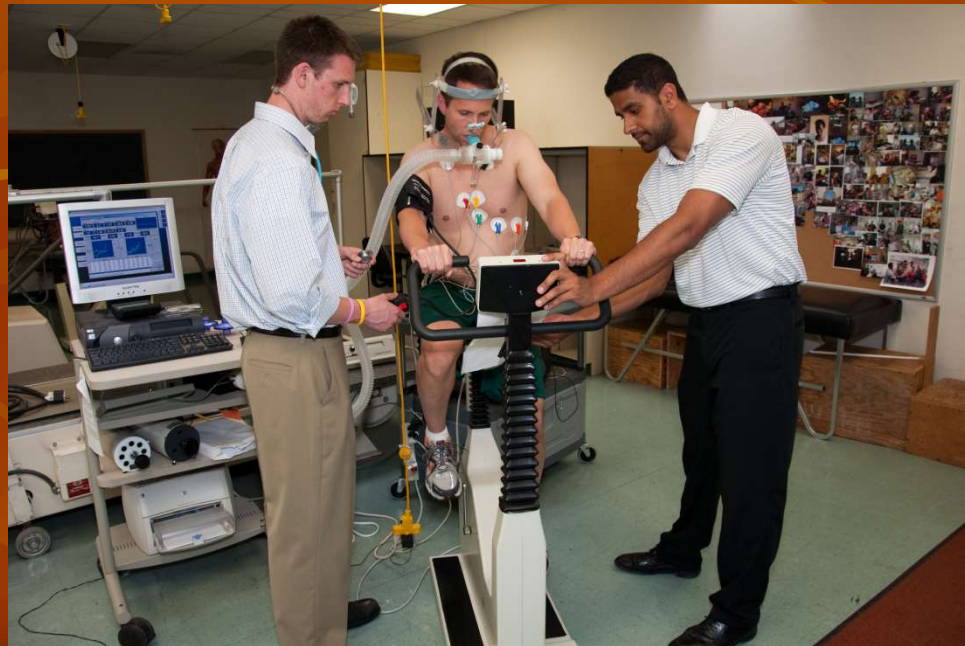Physical examinations

- Can be used in the neck or extremities
- Inspection – trophic changes in ischemia, pale to „marbled“ periphery of an extremity
- Auscultation – stenosis can be manifested by a murmur (turbulent flow)
- Palpation – pulse can't be palpated distally of obstruction, difference in temperature between healthy and ischemized extremity



Stress tests

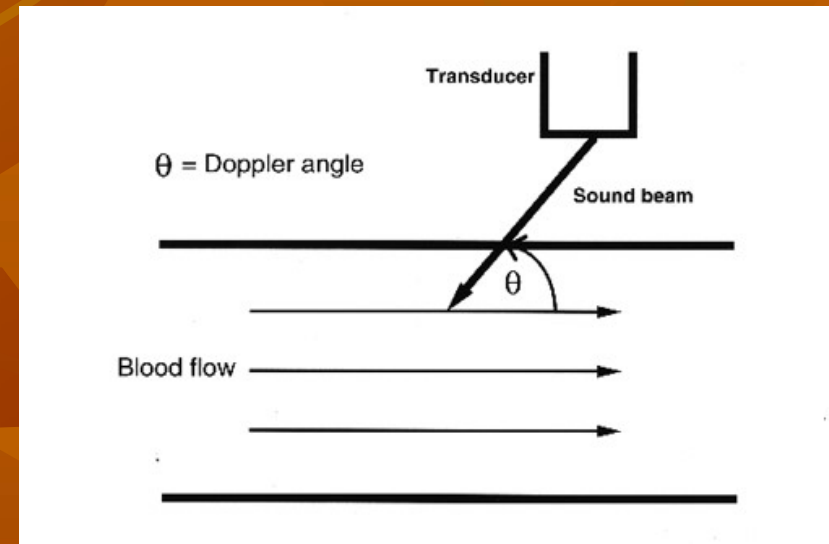
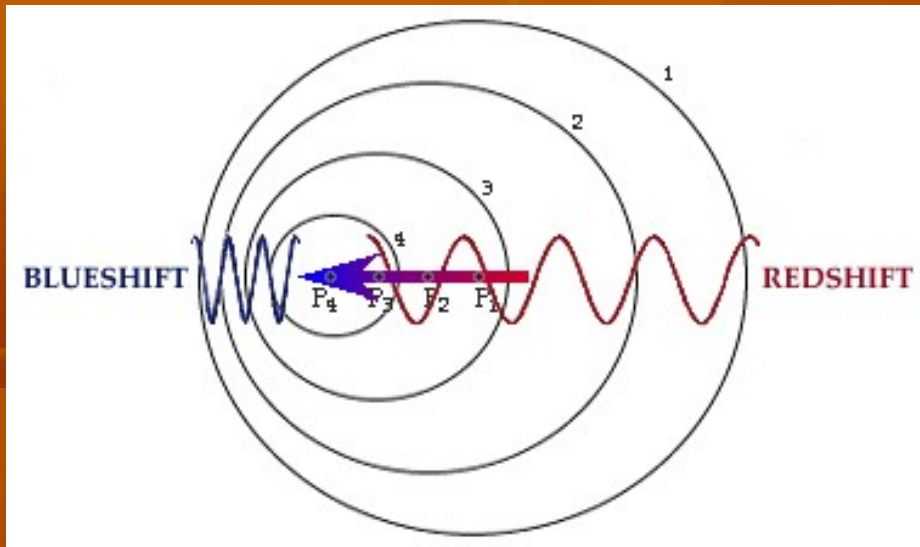
- Are used to triggering ischemia during the labour of skeletal or heart muscle, which leads into ischemic pain
- Treadmill or exercise bike can be used to provoke ischemia
- If there is a suspicion for IHD, 12-lead ECG can be recorded to verificate ischemic changes



UltraSonoGraphy (USG)

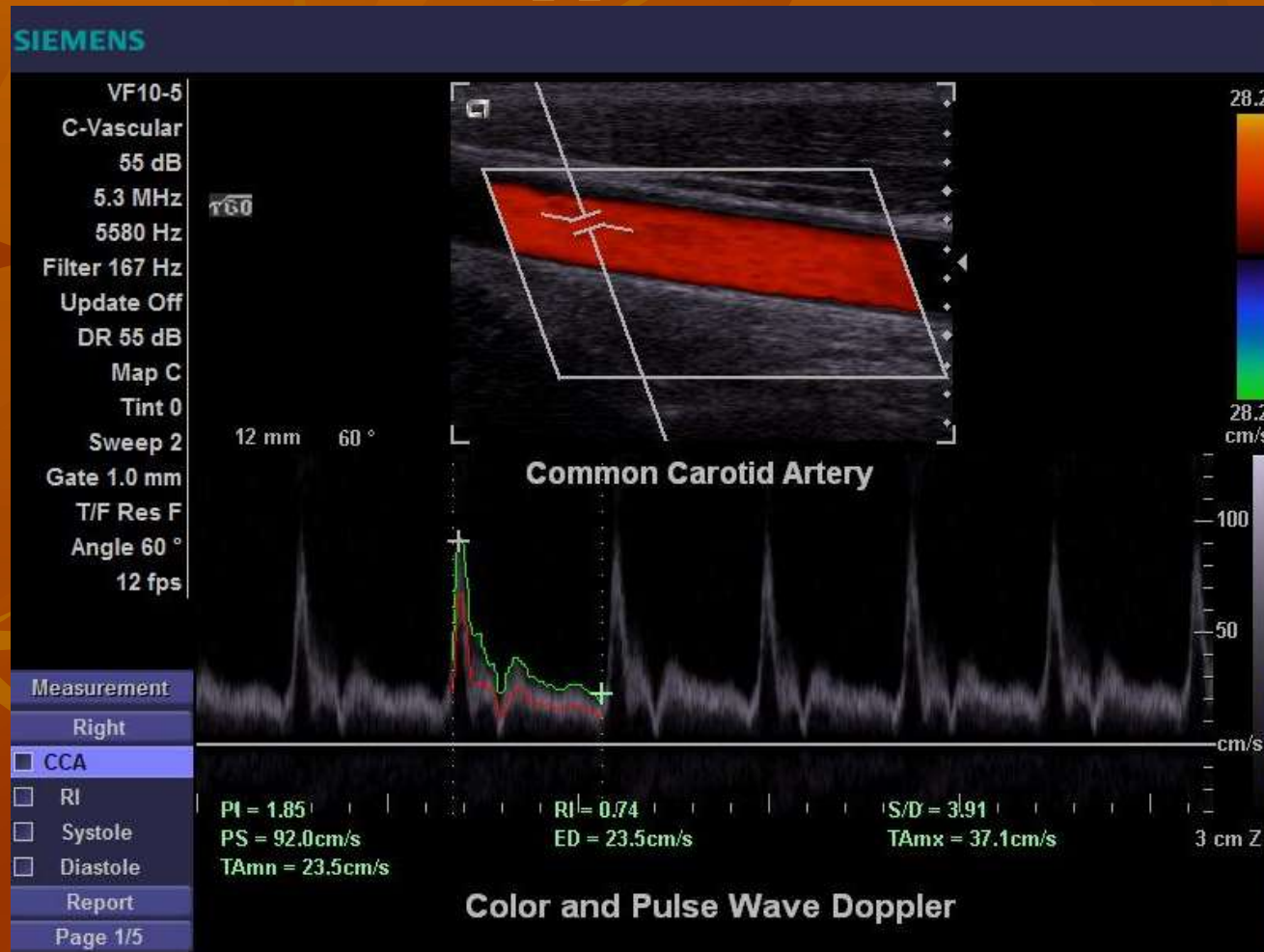
- In the diagnostics of atherosclerosis, two-dimensional image together with doppler examination is used (duplex USG)
- By common devices, large vessels, vessels of extremities or neck, and renal arteries can be investigated (also the heart)
- In brain arteries, modified transcranial doppler can be used

Doppler effect



- The principle is different frequency of waves in front of and behind moving source
- Electromagnetic waves are used e.g. in astronomy or in police radars (speed measuring), acoustic waves e.g. in sonars or in medical applications
- In USG, the source and receiver is stationary, but it is reflected by moving particles (blood cells). Frequency is higher when cells move towards the source, lower when they move away

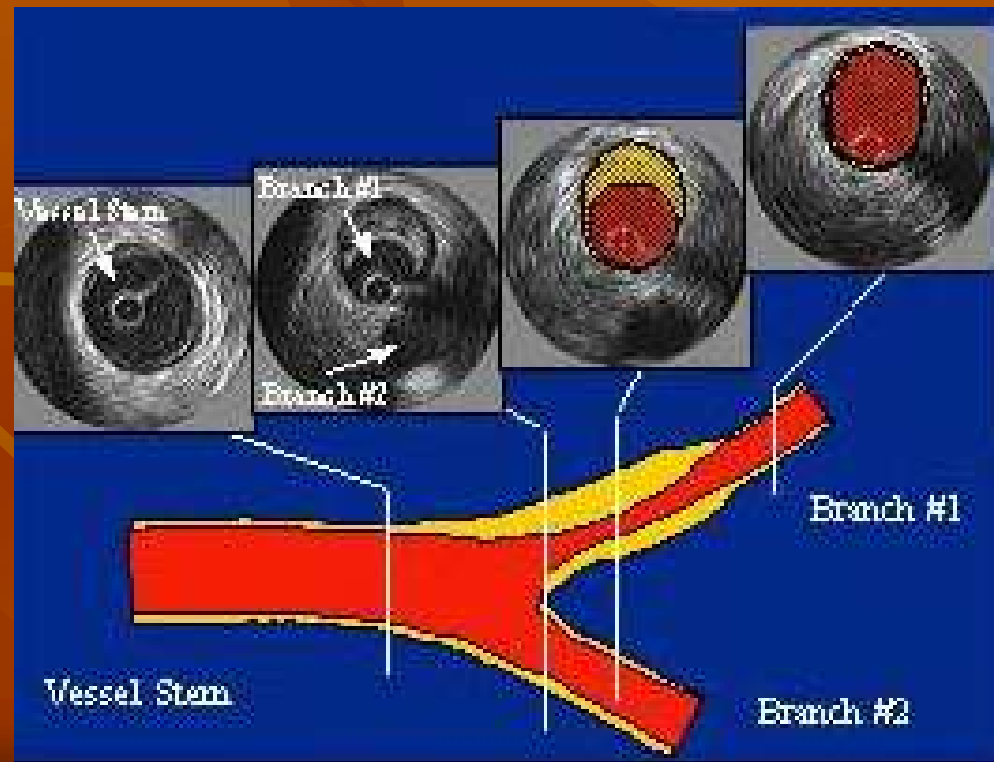
Duplex USG – combination of 2D image and Doppler USG



! The thinner is the stenosis, the faster is the blood flow!

IntraVascular UltraSonography (IVUS)

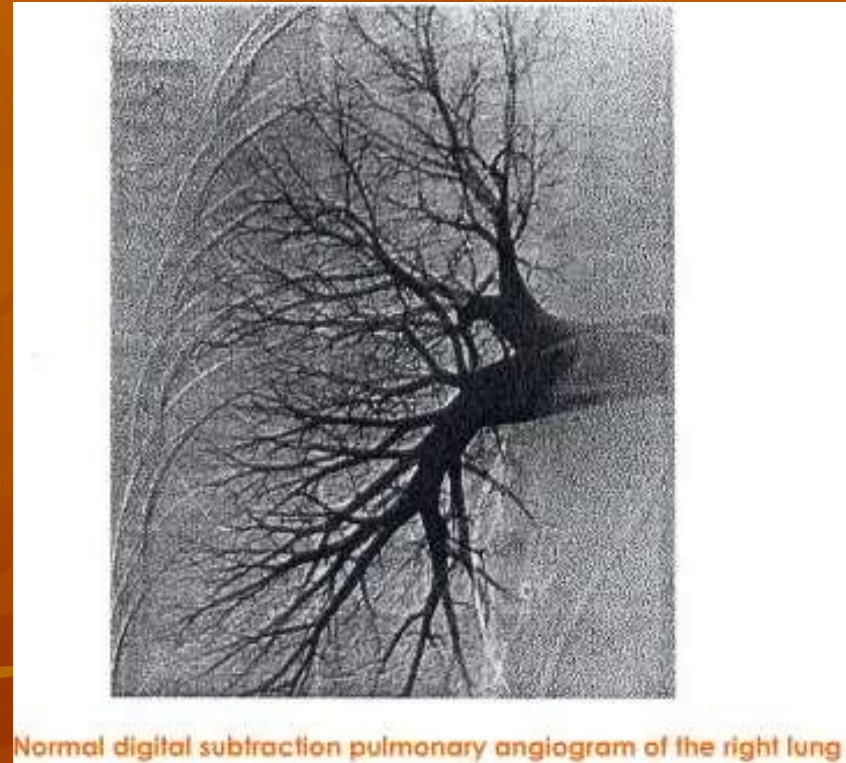
- Invasive method, used as supplement of angiographic examination
- The probe is carried by a catheter directly into the vessel to gain more exact information about the morphology of atherosclerotic lesion



Angiography

- In wide sense all methods, where the vessels are visualized using contrast matter
- In narrow sense, it is used for skiascopy-based methods
 - Advantages: detailed view of long vessel sections
real-time picture
 - Disadvantages: invasive method – risk of an injury (on the other hand, this can be an advantage – angioplasty)
needs expensive equipment
radiation load on both patient and staff
- Less invasive alternatives are CT and MR angiography

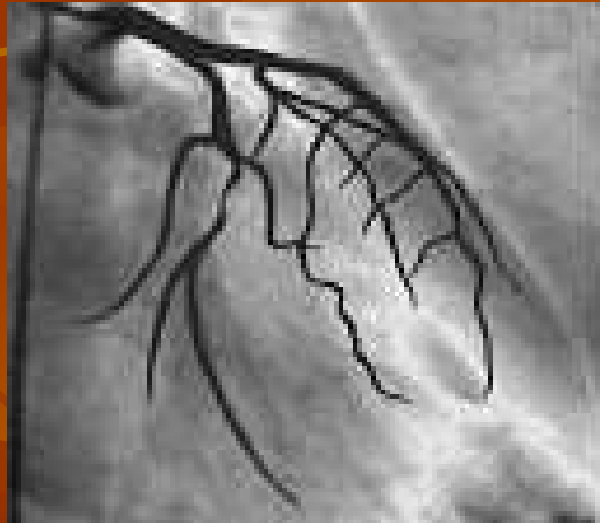Angiographic picture



- Digital subtraction angiography – the signal noise of other tissues is digitally removed

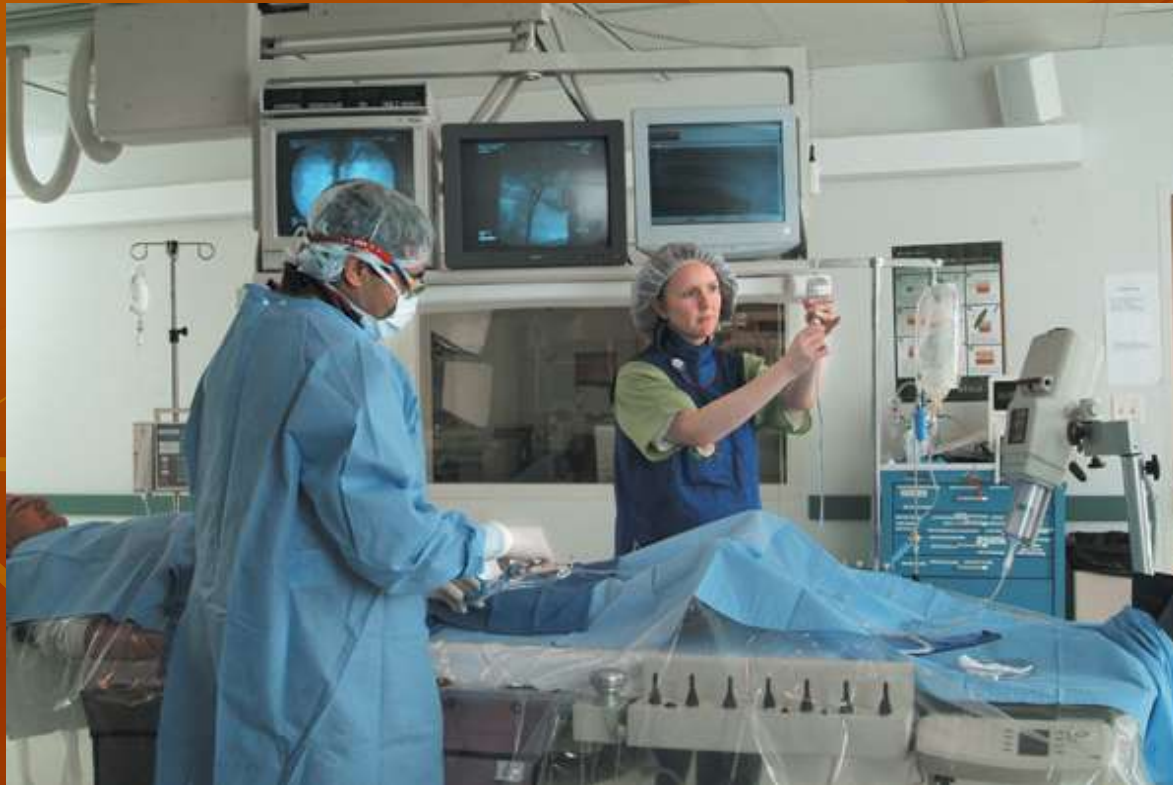Coronary angiography

- After cathetrization, the contrast matter (mostly iodine) is injected into left and right coronary artery
- The examination of arteries is usually followed by visualization of left ventricle (ventriculography)
- In case of need, therapeutic intervention on the artery can be performed



Coronary angiography 2

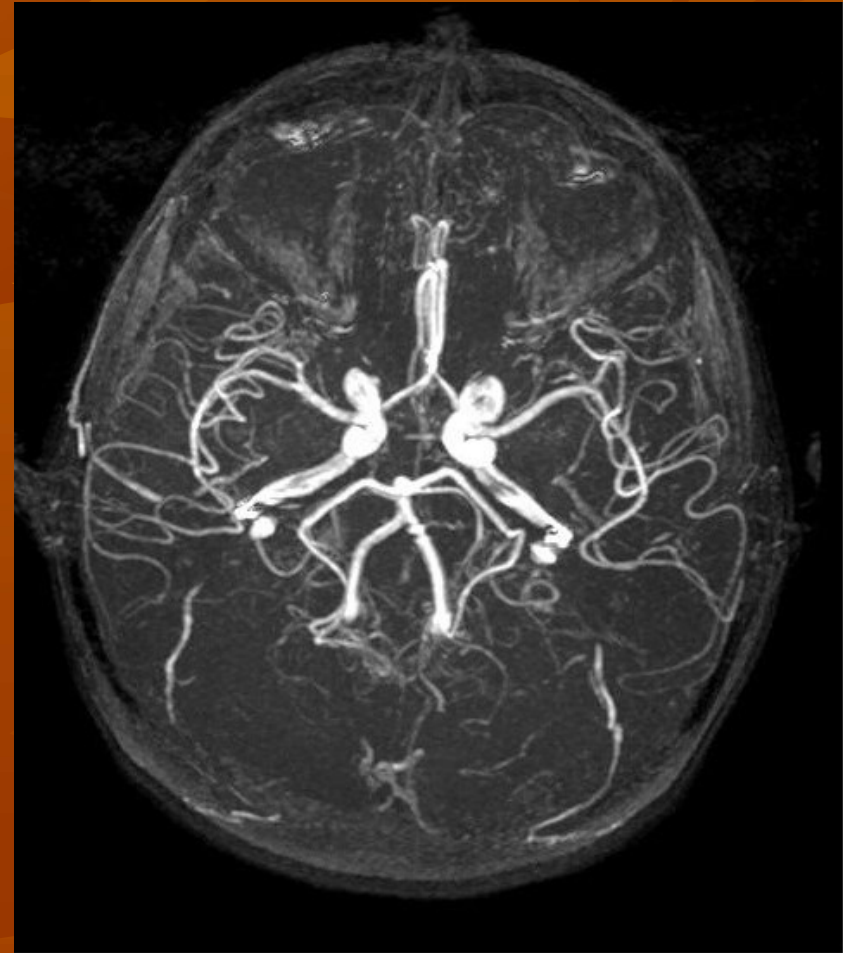- Anti-radiation measures must be taken during the examination



CathLab – Cathetrization Laboratory

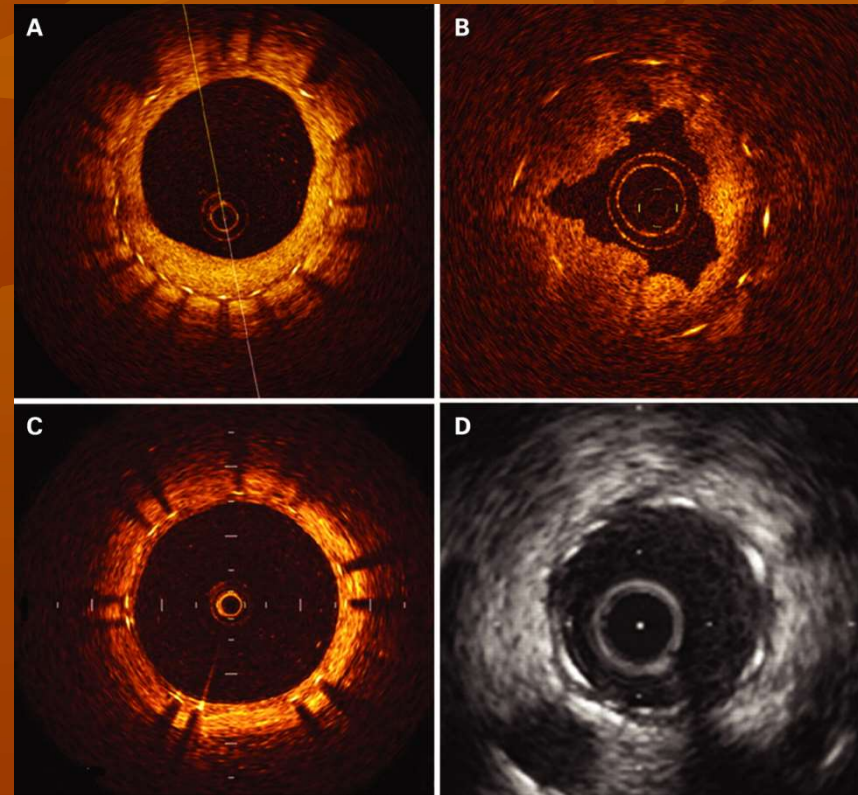
CT and MR angiography

- CT and MR AG can display large parts of arterial system
- In MR angiography, there is not radiation exposition
- As a disadvantage, there is not a possibility of real-time picture and of an intervention



OCT (optical coherent tomography)

- Invasive method similar to IVUS
- Based on echolocation, instead of ultrasound waves it uses IR electromagnetic radiation ($\lambda \sim 1300 \text{ nm}$)
- More exact than IVUS
- The tissue can be displayed only up to 1-2 mm



Pictures: artery after stent implantation

NIRS

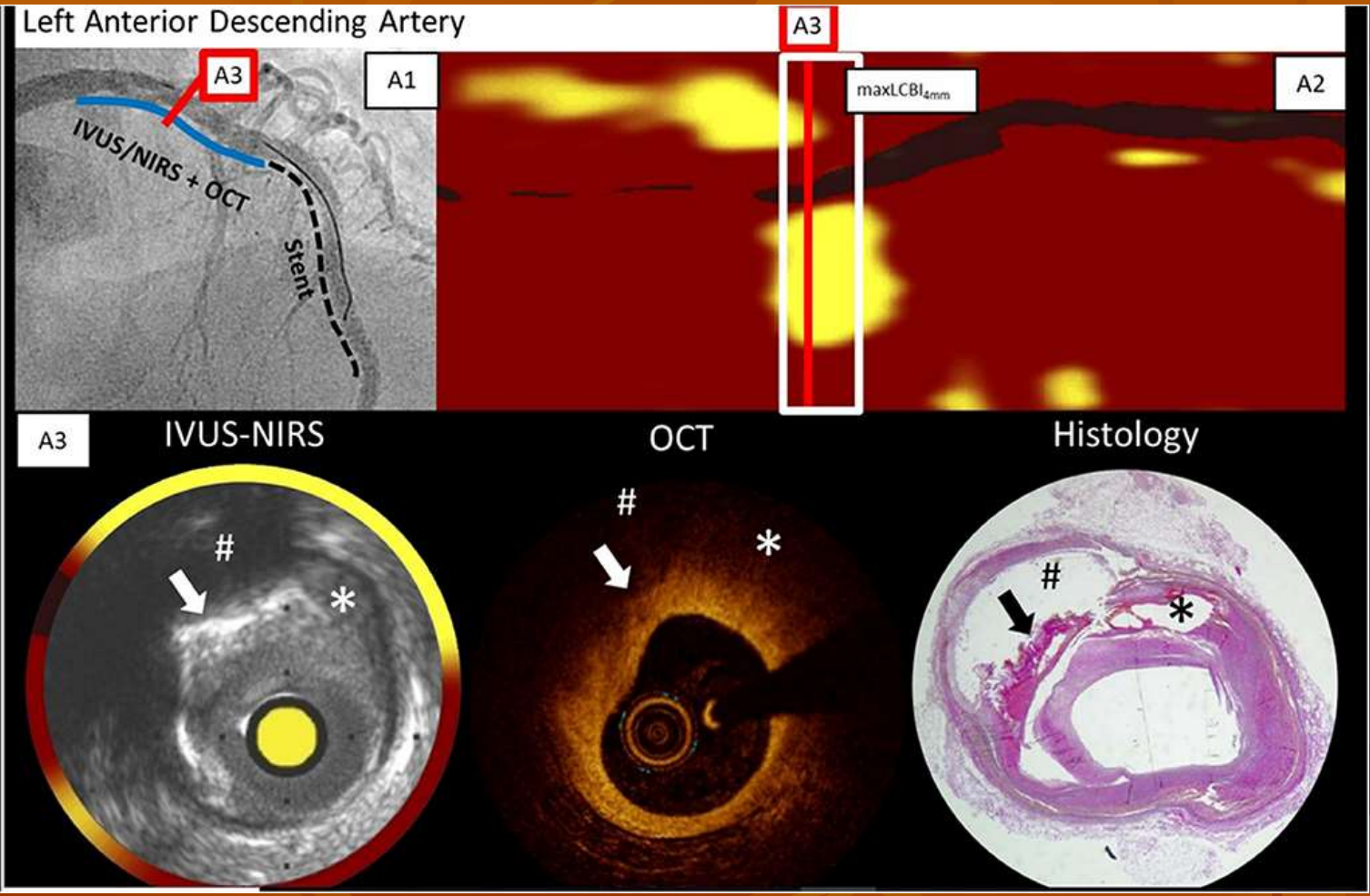
- Near infrared spectroscopy
- May be combined with IVUS or OCT
- Valuable in the detection of necrotic core, especially when hidden behind dense material (calcium deposits)

modalities	Angiography OCT IVUS NIRS			
	Angiography	OCT	IVUS	NIRS
Plaque volume	—	—	++	—
Calcification	++	+	++	—
Cap thickness	—	++	+	+
Thrombus	+	++	+	+
Lipid core	—	+	+	++
Remodeling	—	—	++	—
Stent strut expansion	—	++	++	—
Neointimal hyperplasia	+	++	+	—
Requires blood-free field of view	No	Yes	No	No

++, Direct, robust and/or validated; +, indirect, inferred, and/or unvalidated; — not applicable

Combination of imaging methods

NIRS



IVUS +
NIRS
(outer
circle)

↓ - fibrous cap with calcifications; # - necrotic core; * - other lipid deposits

Blood testing

- Focused on known risk factors (lipid spectrum, hyperglycemia)
- In familiar atherosclerosis in young age, it is suitable to perform genetic tests with respect to known risky alleles