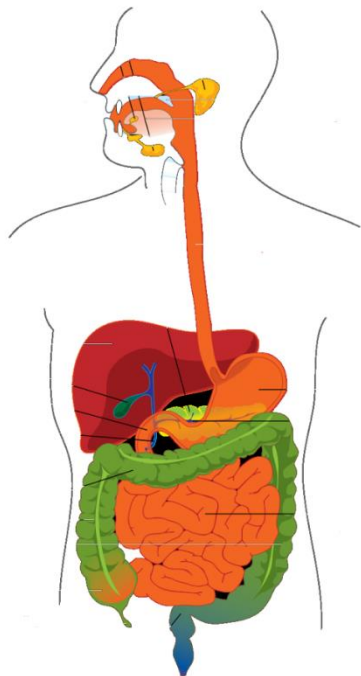


MICROSCOPIC ANATOMY AND DEVELOPMENT OF GIT I



Petr Vaňhara, PhD

Department of Histology and Embryology LF MU
pvanhara@med.muni.cz

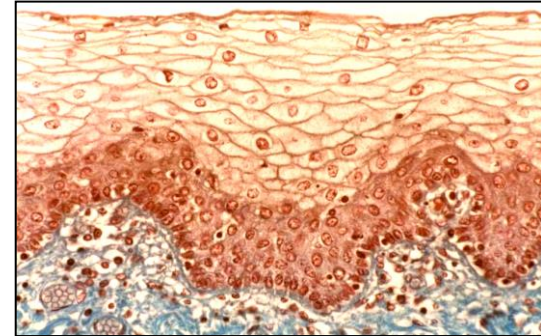
ORAL CAVITY



- Upper and lower lip
- Vestibulum oris
- Soft and hard palate
- Tooth and gingiva
- Tongue

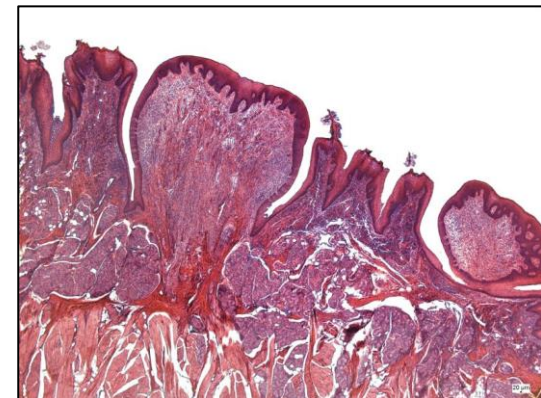
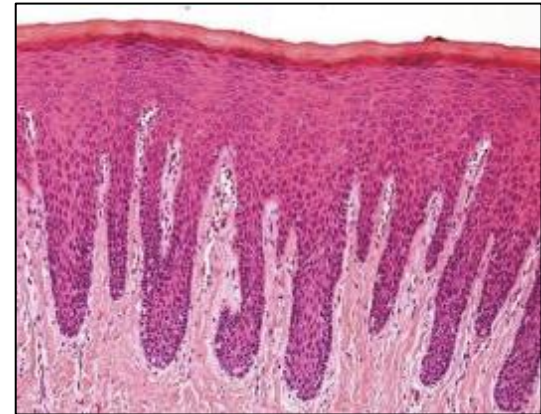
ORAL MUCOSA

- ***lamina epithelialis mucosae***
stratified squamous epithelium
- ***lamina propria mucosae***
loose collagen C.T.

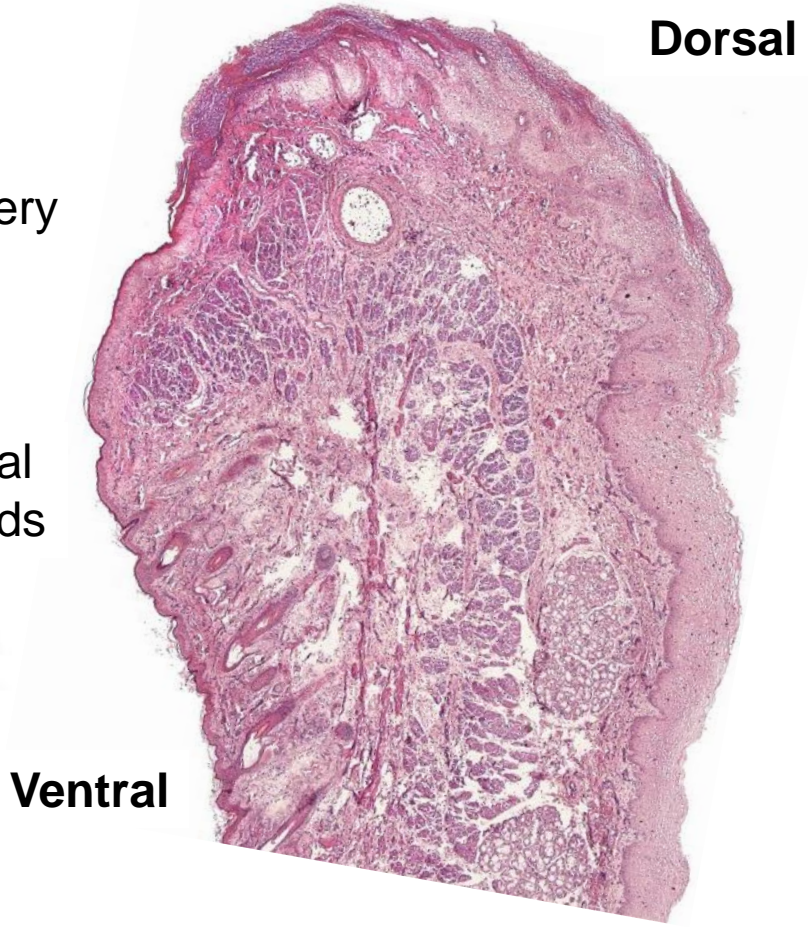
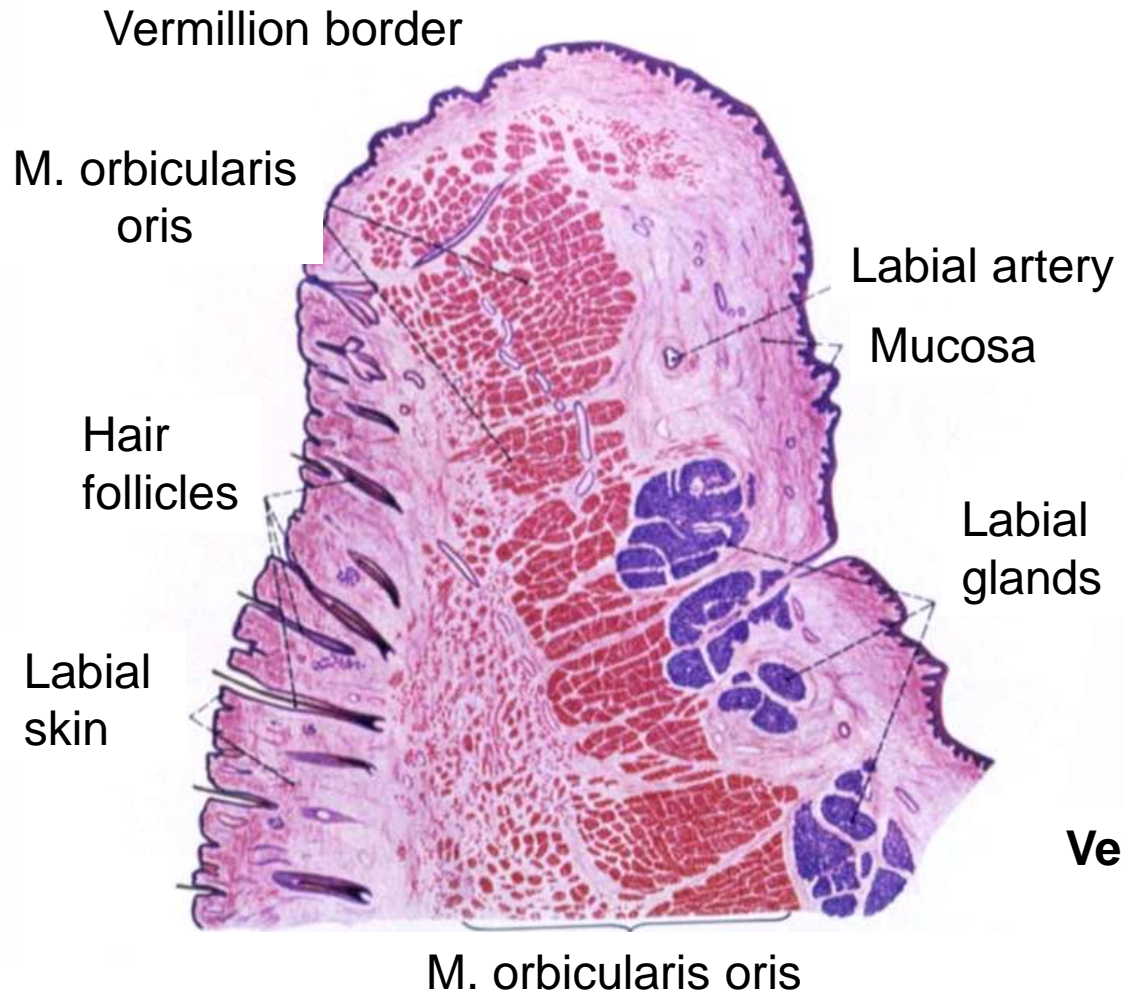


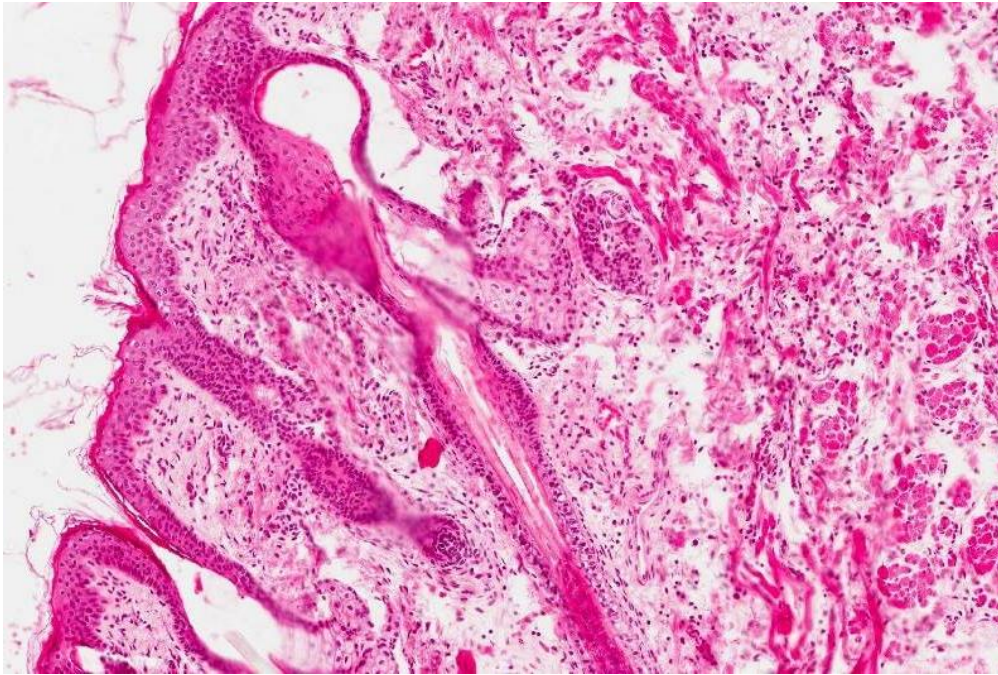
Types of oral mucosa

- **lining mucosa**
 - mucosal and submucosal C.T.
- **masticatory mucosa**
 - parakeratinized epithelium
 - directly on periost (mucoperiosteum)
 - no submucosa
- **specialized mucosa**
 - dorsum linguae – papillae



LIP

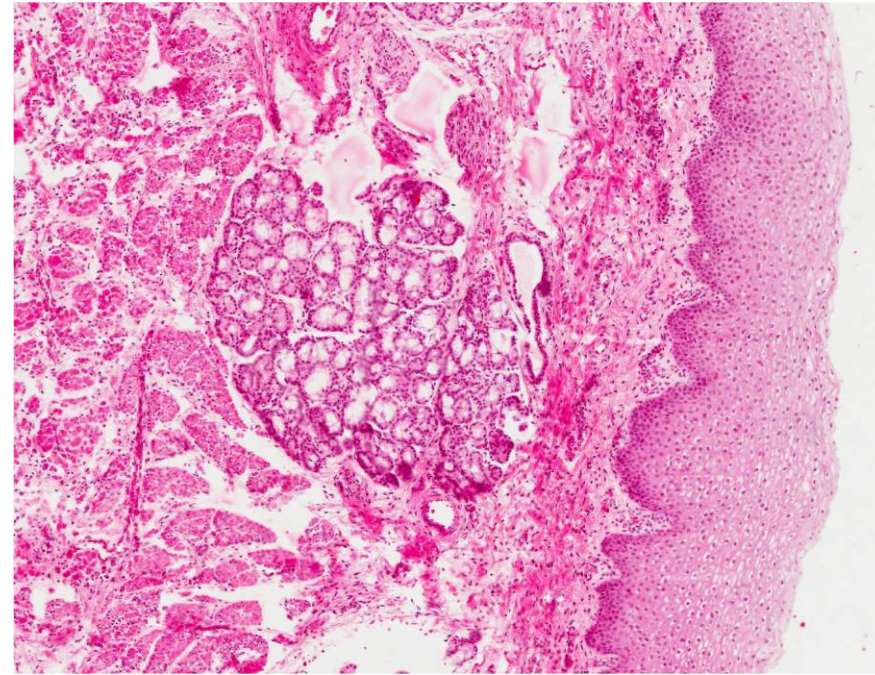


Skin side (ventral)**Epidermis**

- Keratinized stratified squamous epithelium

Dermis

- Loose collagen C.T.
- Hair follicles
- Sebaceous glands
- Sweat glands

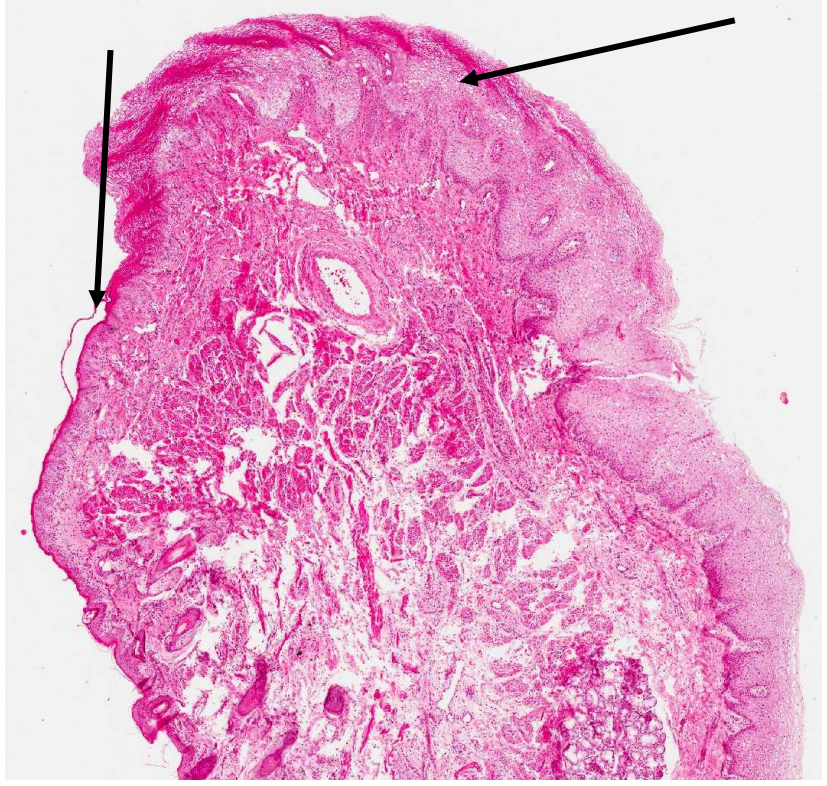Oral side (dorsal)**Oral mucosa**

- Stratified squamous epithelium
- Loose collagen C.T.
- Small salivary labial mixed glands

LIP

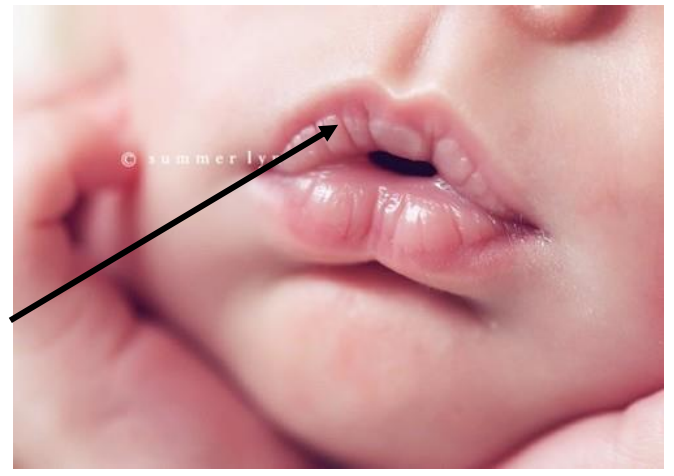
pars glabra

pars villosa



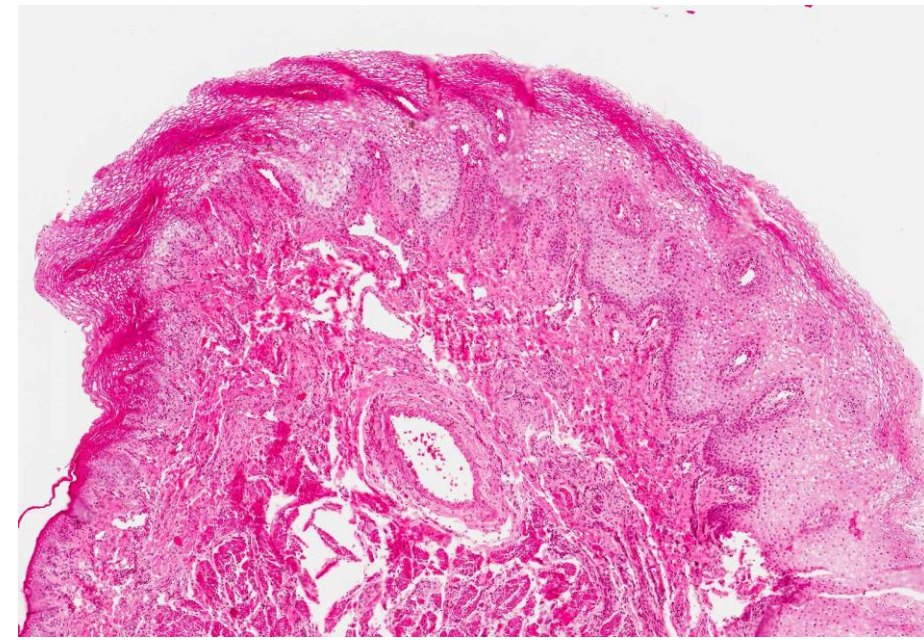
newborns

torus labialis

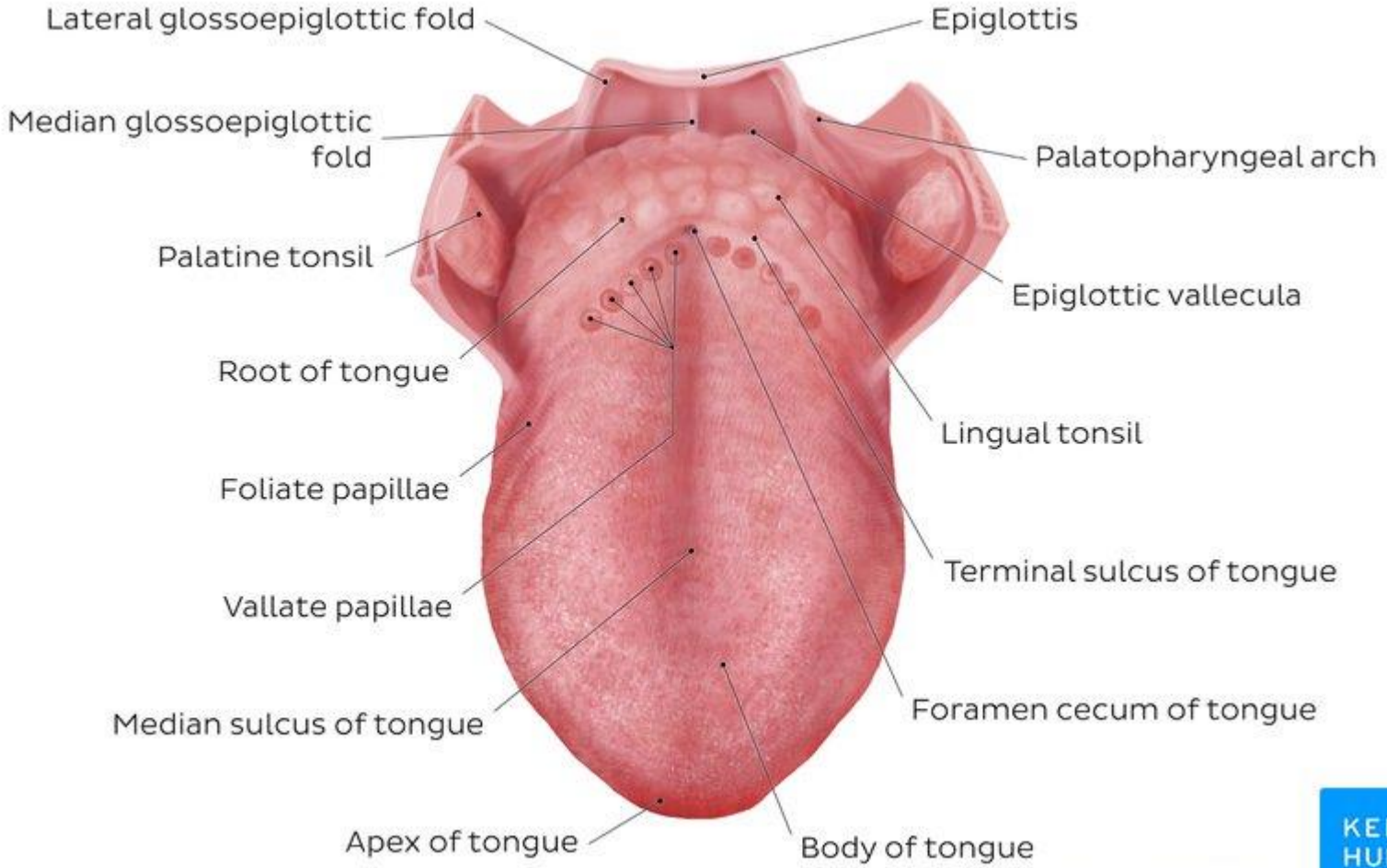


Vermillion border

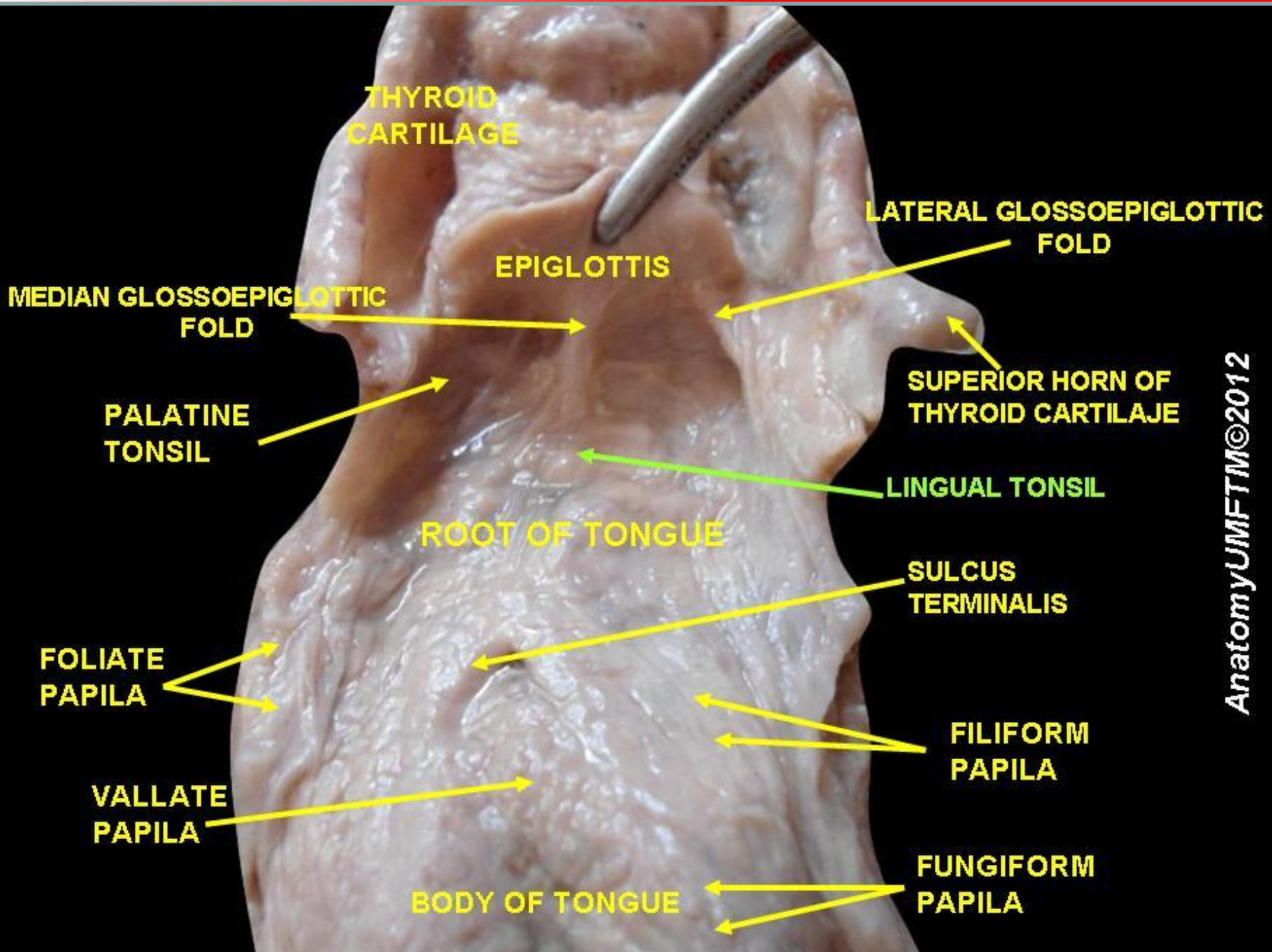
- Eleidin protein
- salivary glands hair follicles, sweat glands absent
- high c.t. papillae, capillaries
- nerve endings, Meissner's corpuscles



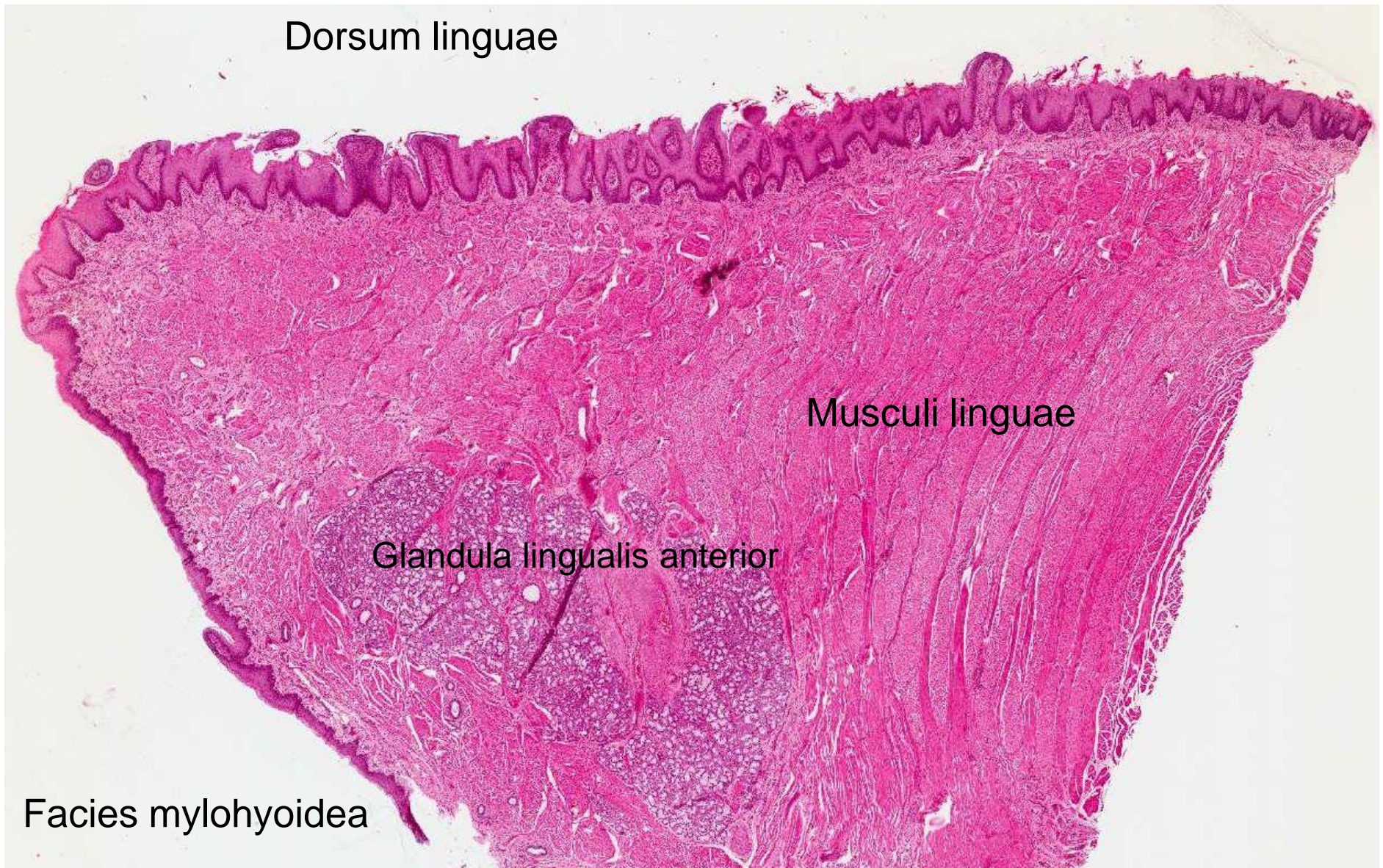
TONGUE



TONGUE



TONGUE – APEX LINGUAE



Dorsum linguae

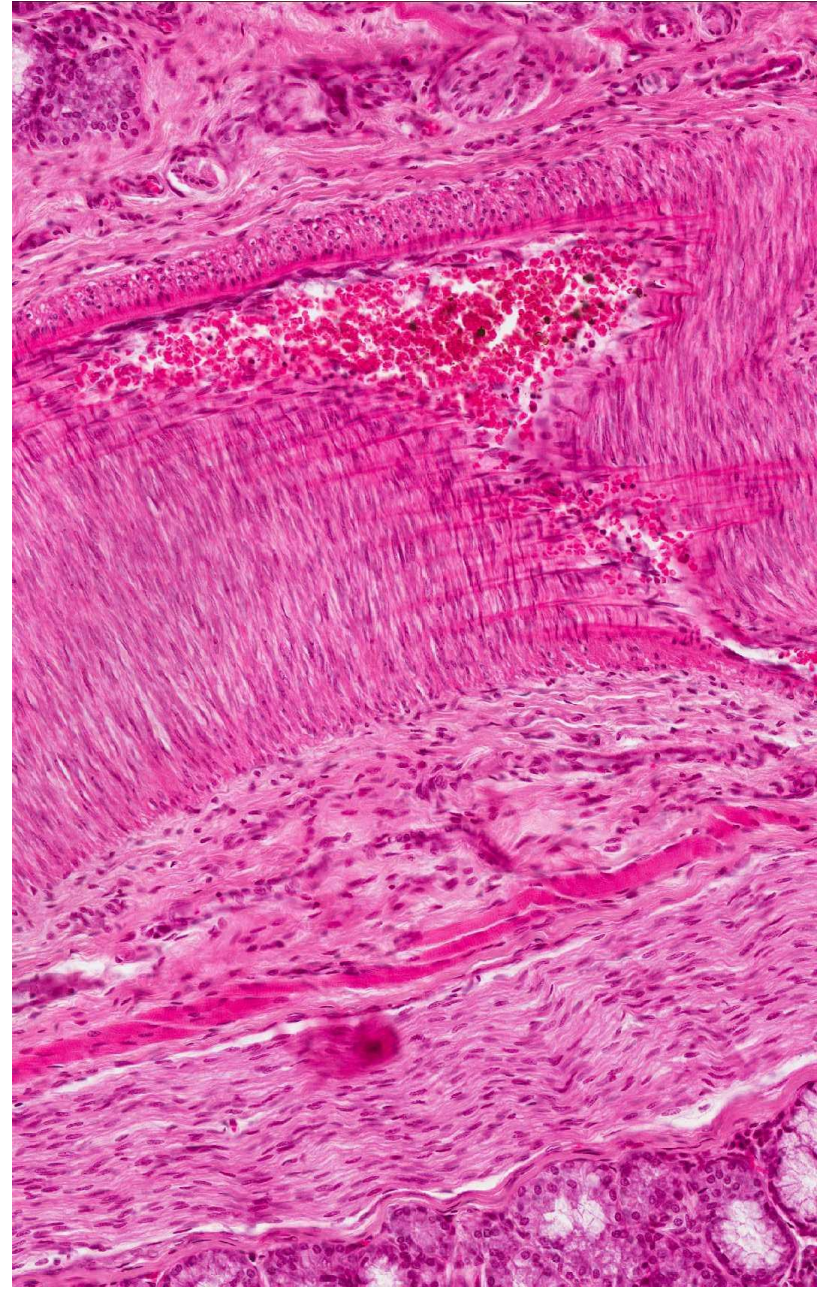
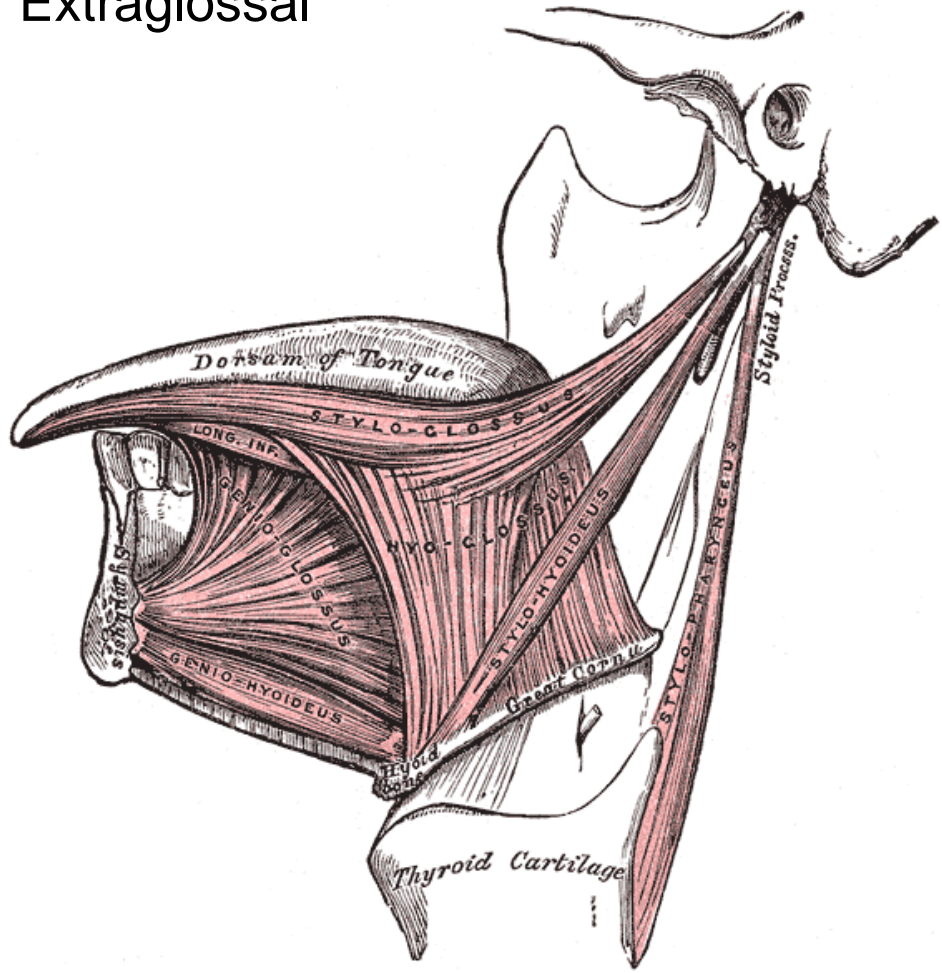
Musculi linguae

Glandula lingualis anterior

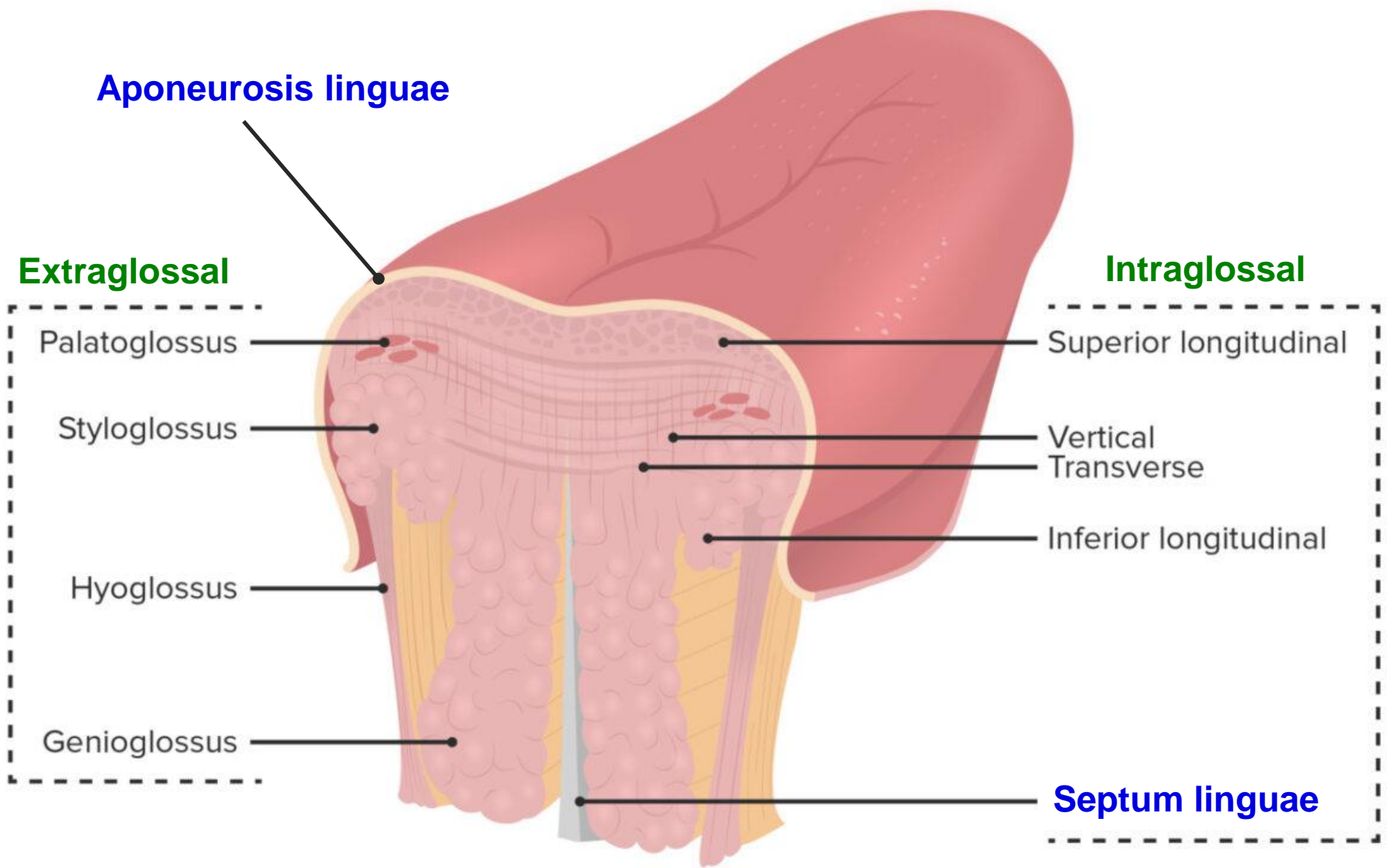
Facies mylohyoidea

TONGUE – MUSCLES

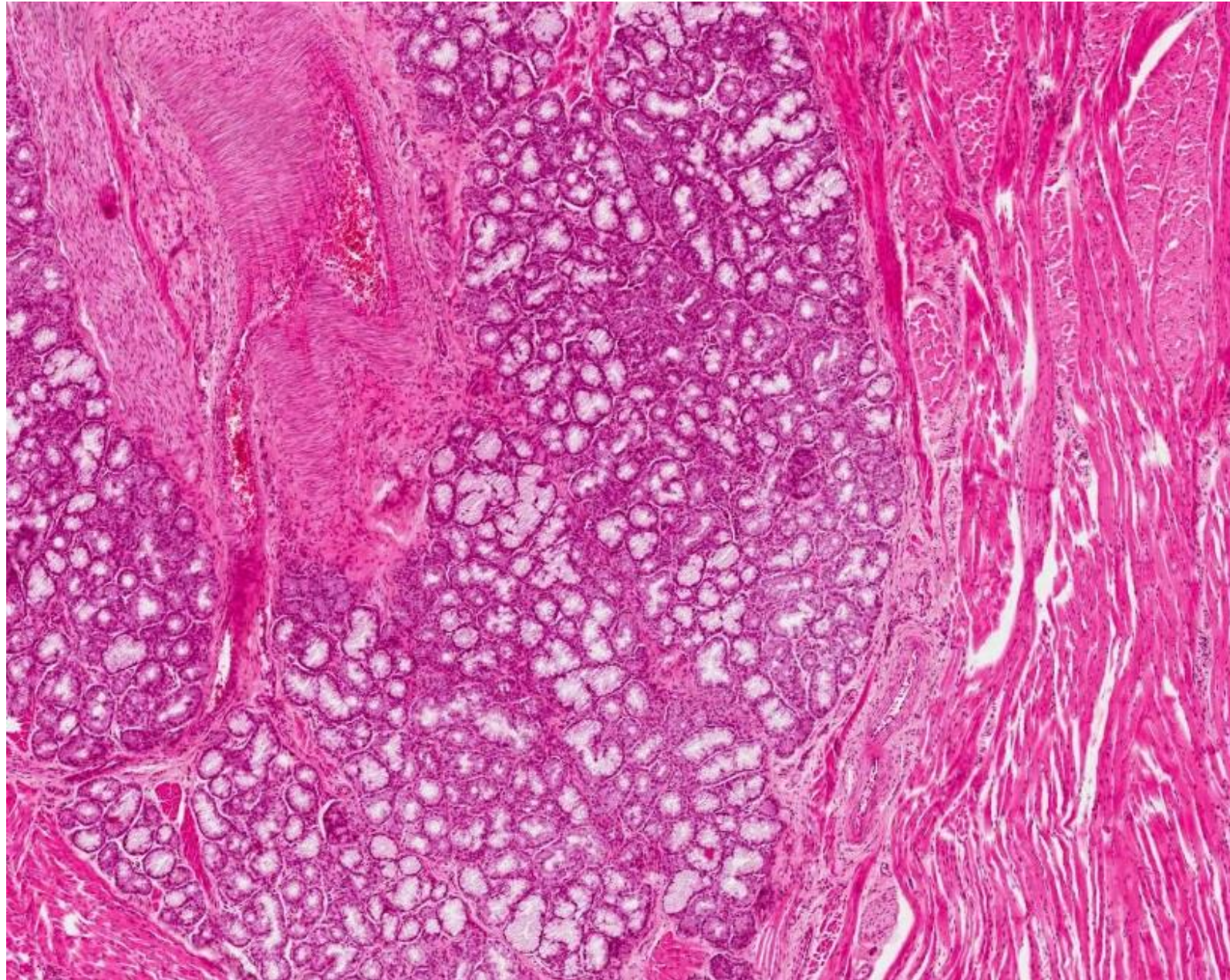
- Intraglossal
- Extraglossal



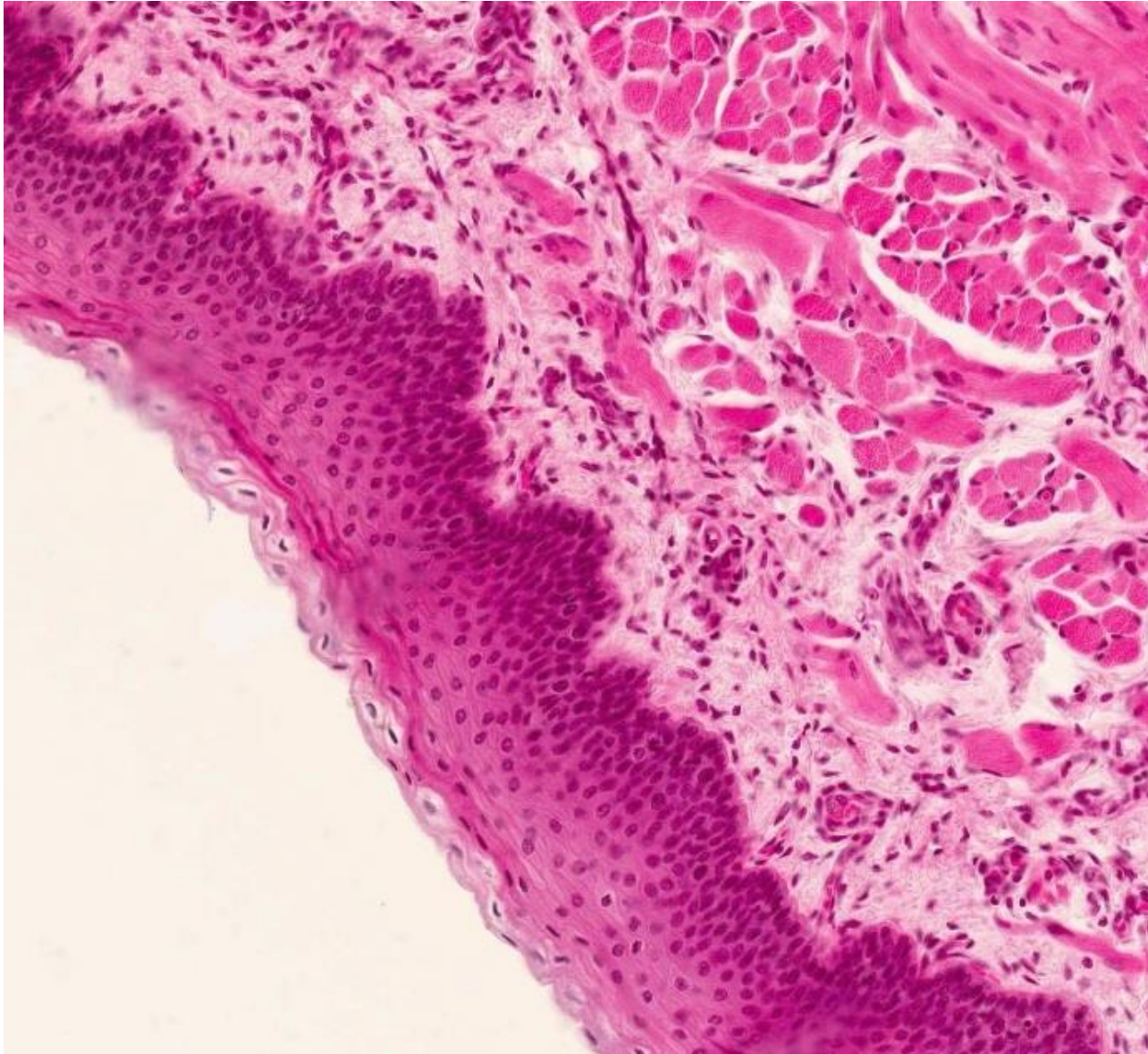
TONGUE – MUSCLES



TONGUE – GLL. LINGUALES ANTERIORES (BLANDINI)

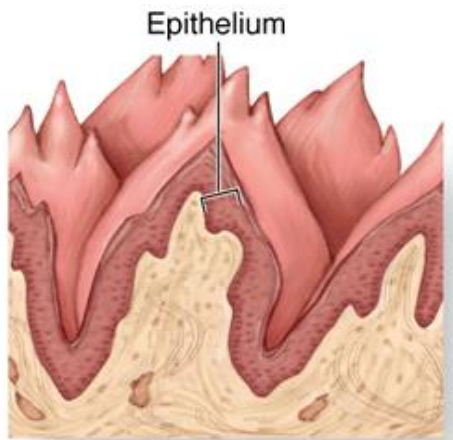


TONGUE – FACIES MYLOHYOIDEA

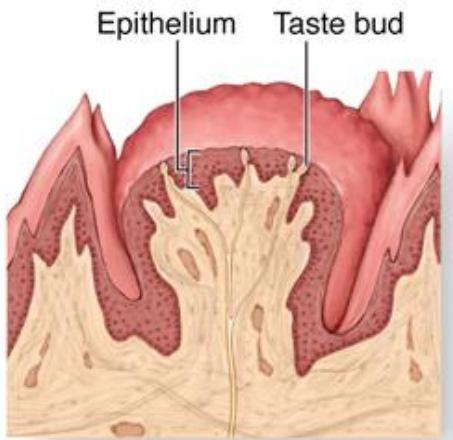


TONGUE – DORSUM LINGUAE

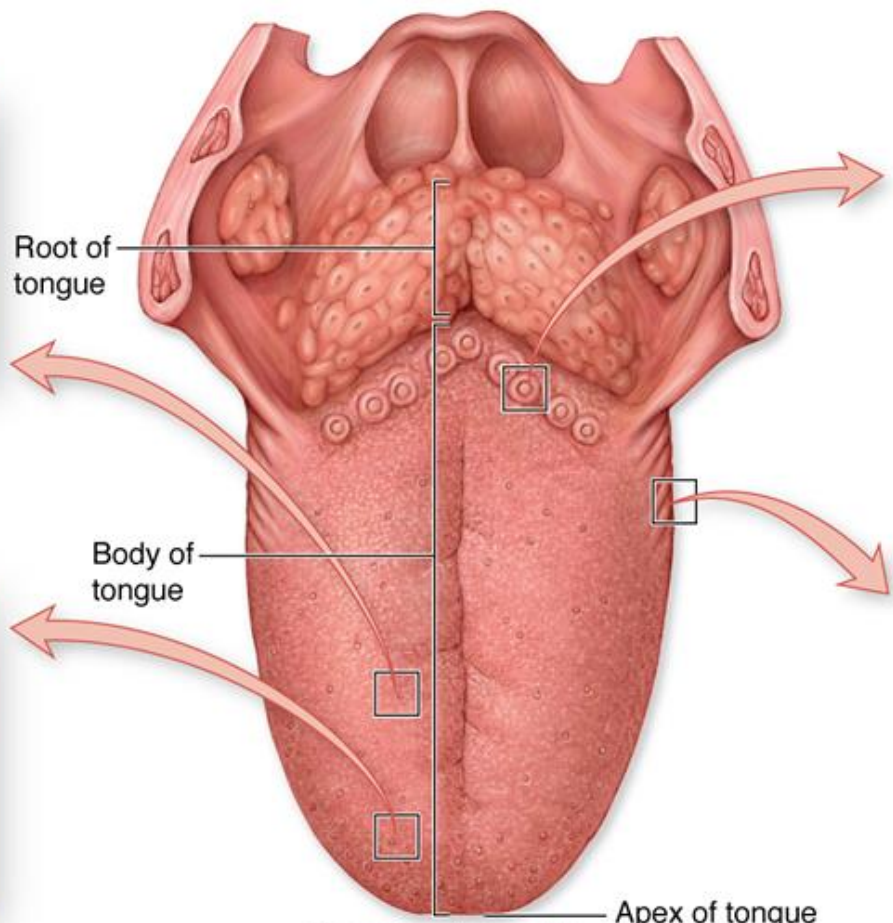
- specialized mucosal structures - **papillae**
- submucosal C.T. is absent



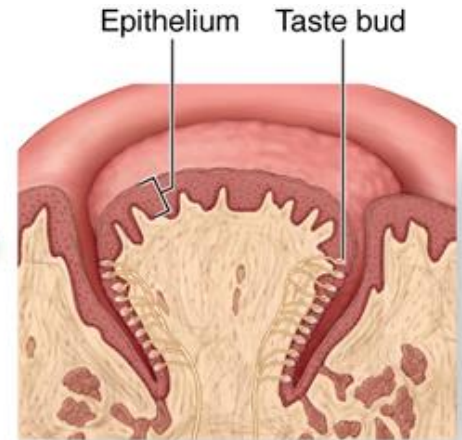
Filiform papilla



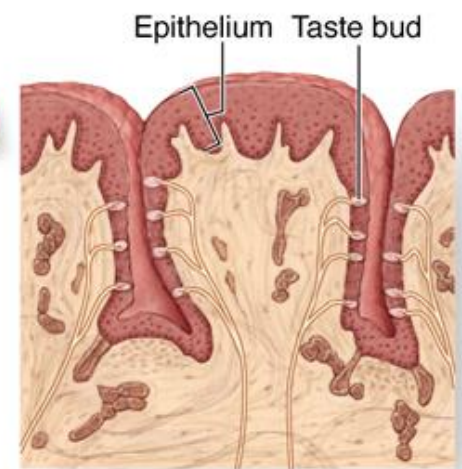
Fungiform papilla



Dorsal surface of tongue



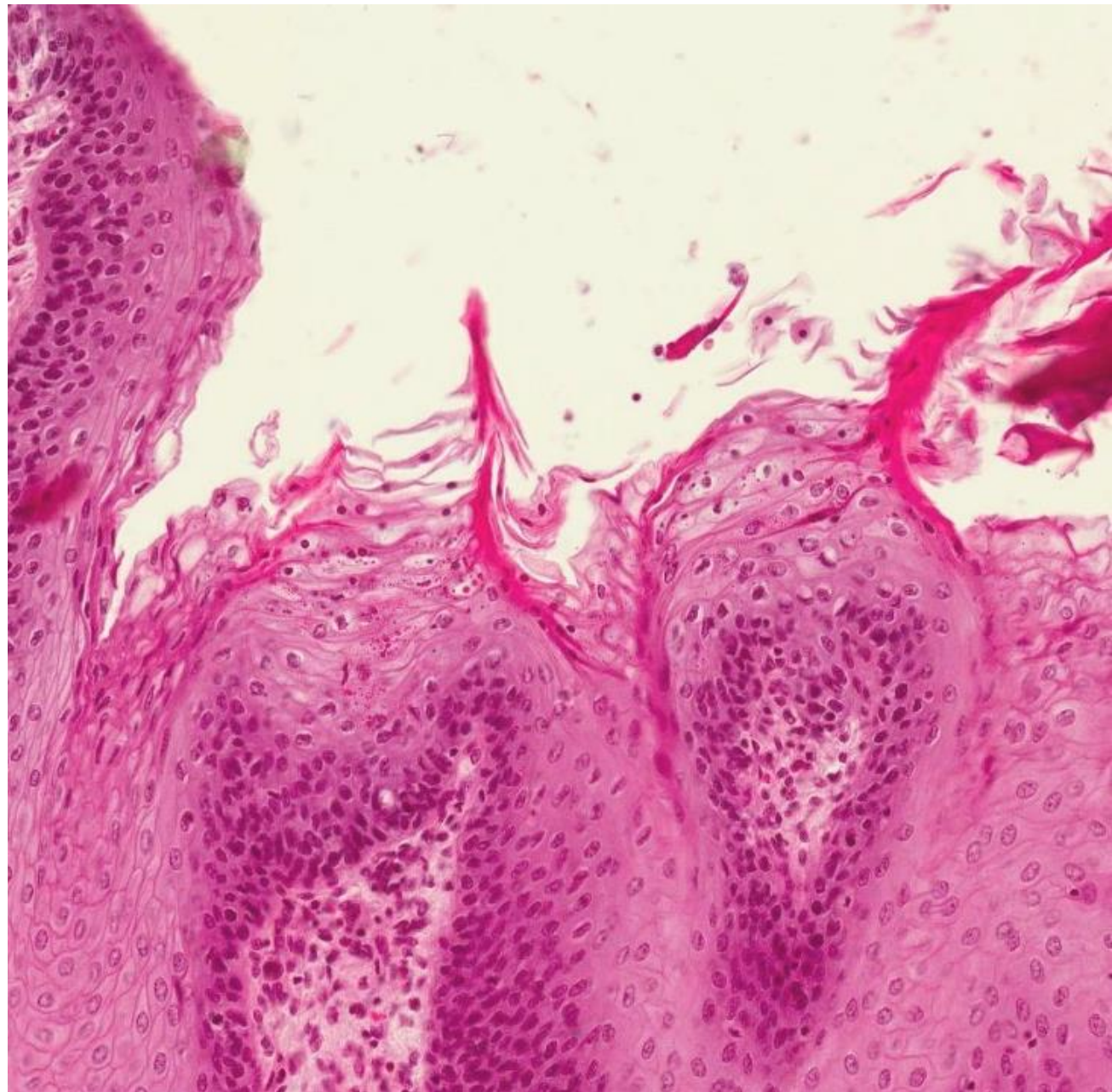
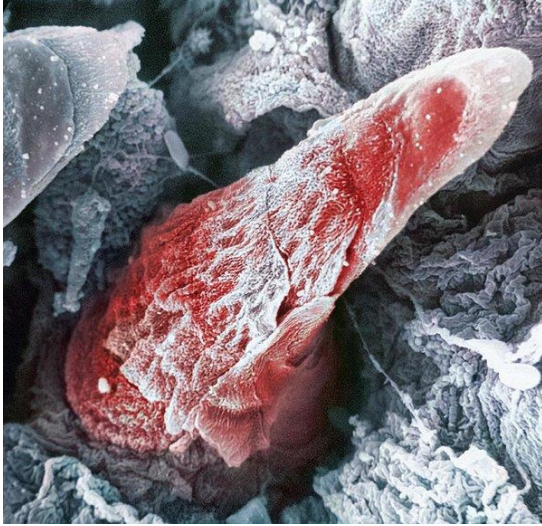
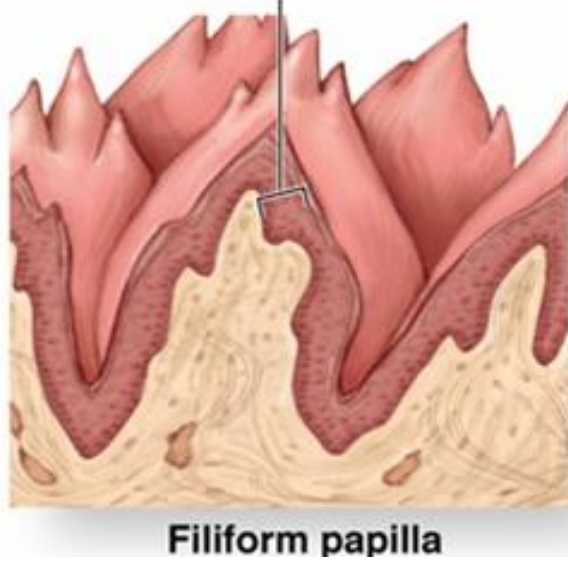
Vallate papilla



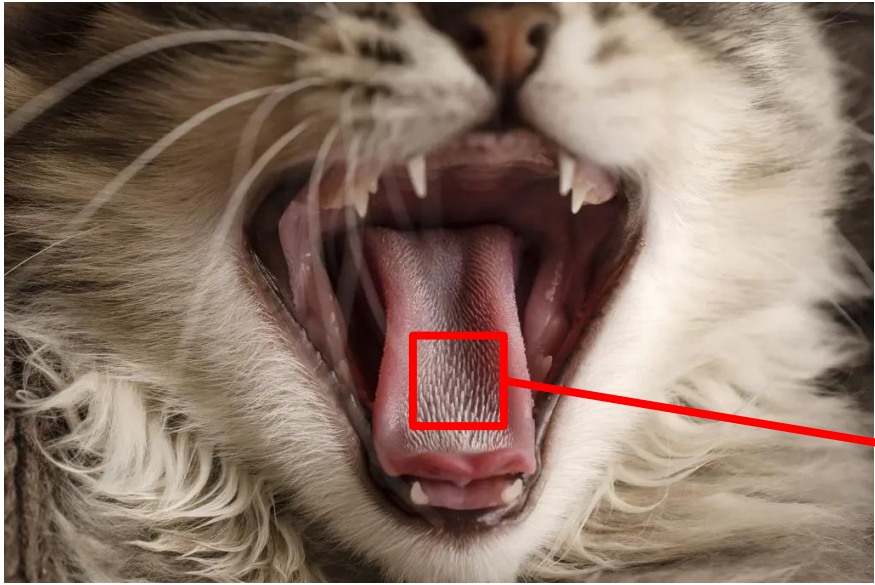
Foliate papilla

TONGUE – FILLIFORM PAPILLAE

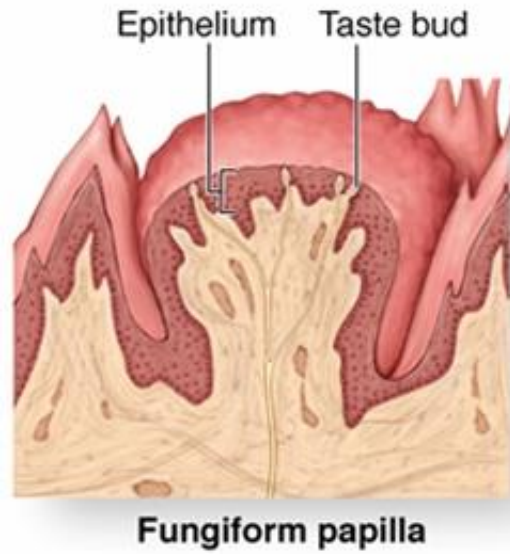
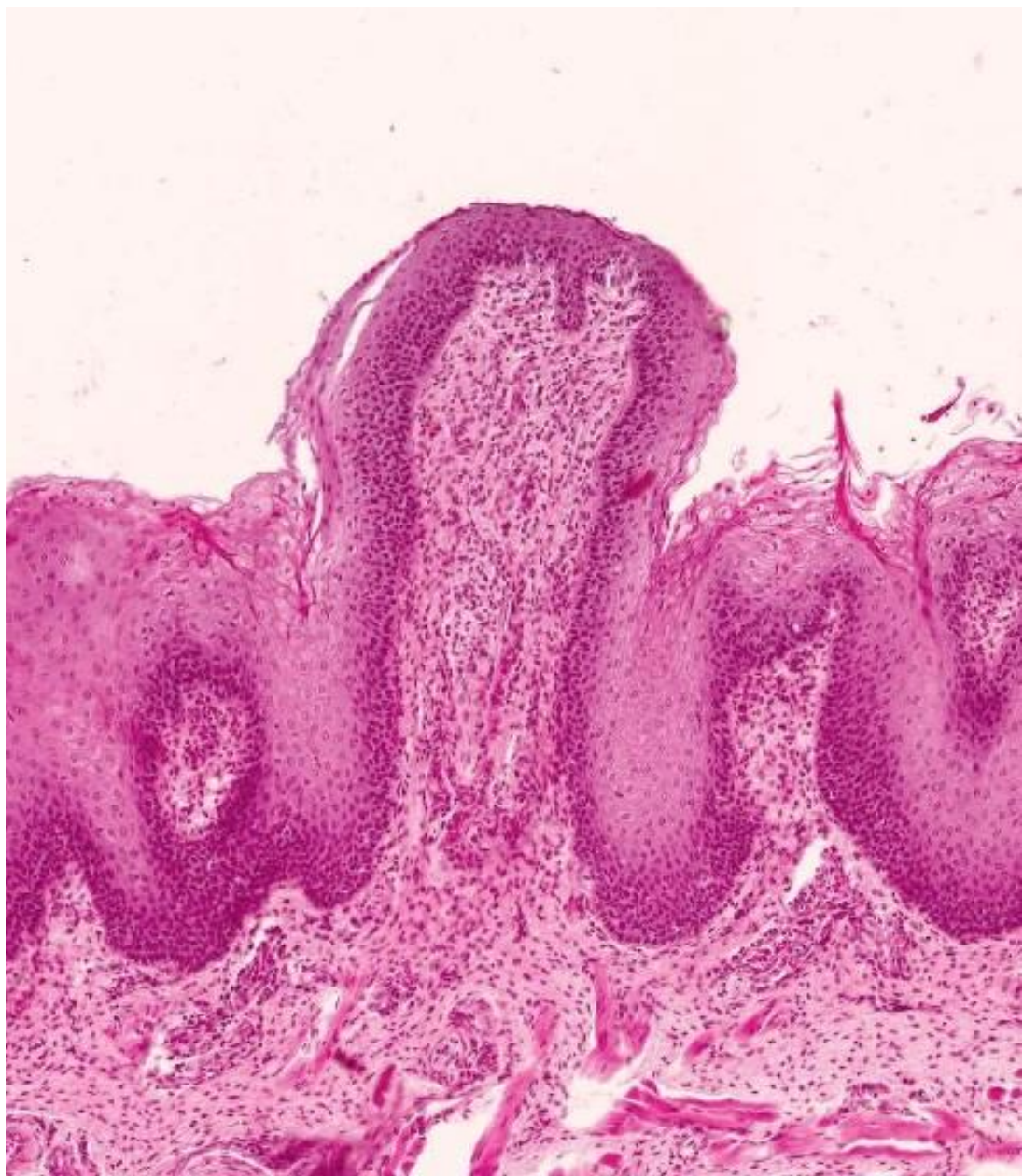
Epithelium



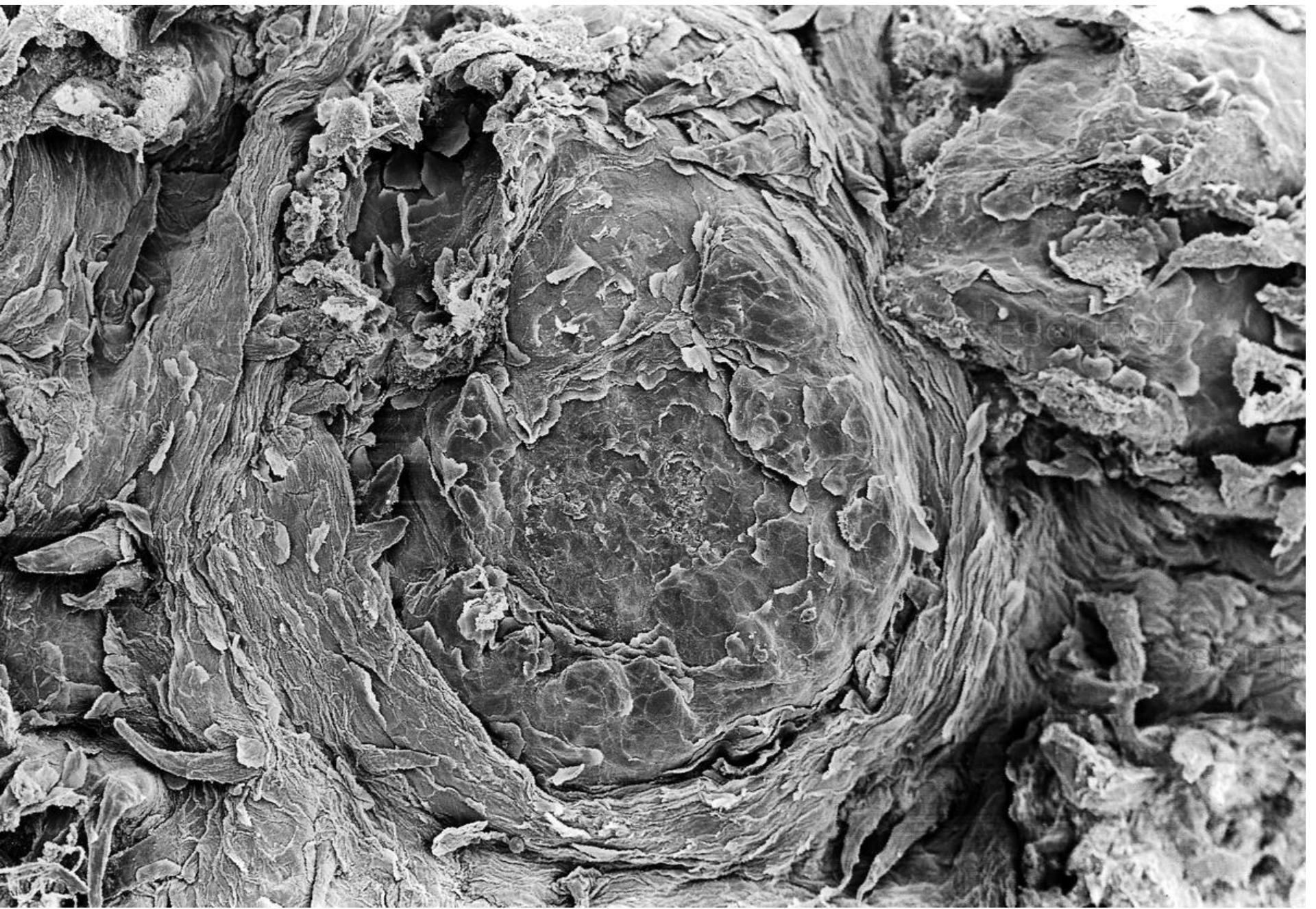
TONGUE – FILLIFORM PAPILLAE



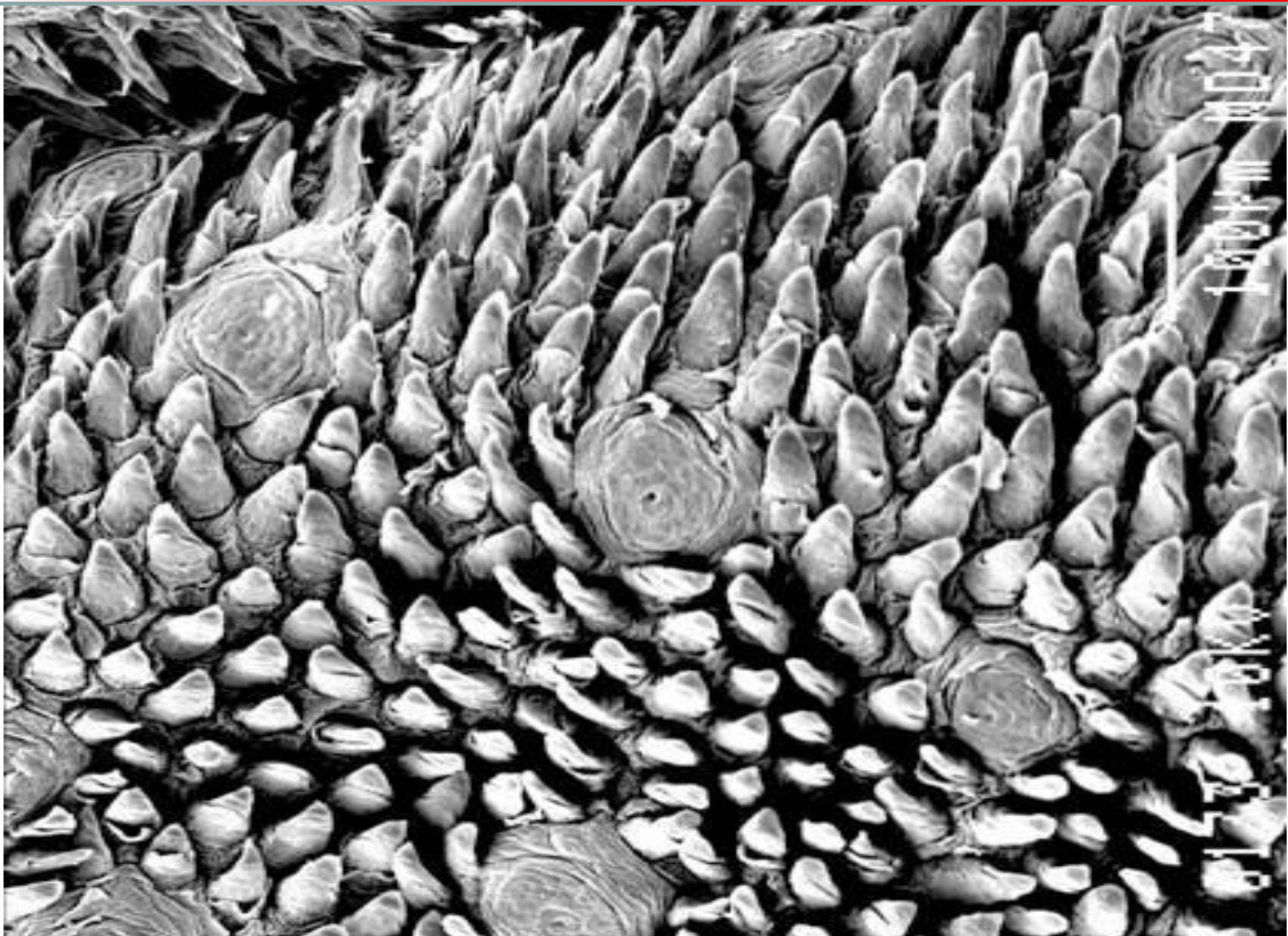
TONGUE – FUNGIFORM PAPILLAE



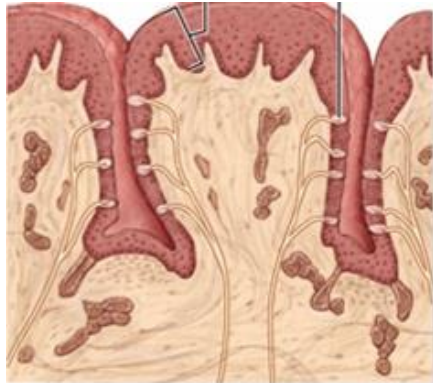
TONGUE – FUNGIFORM PAPILLAE



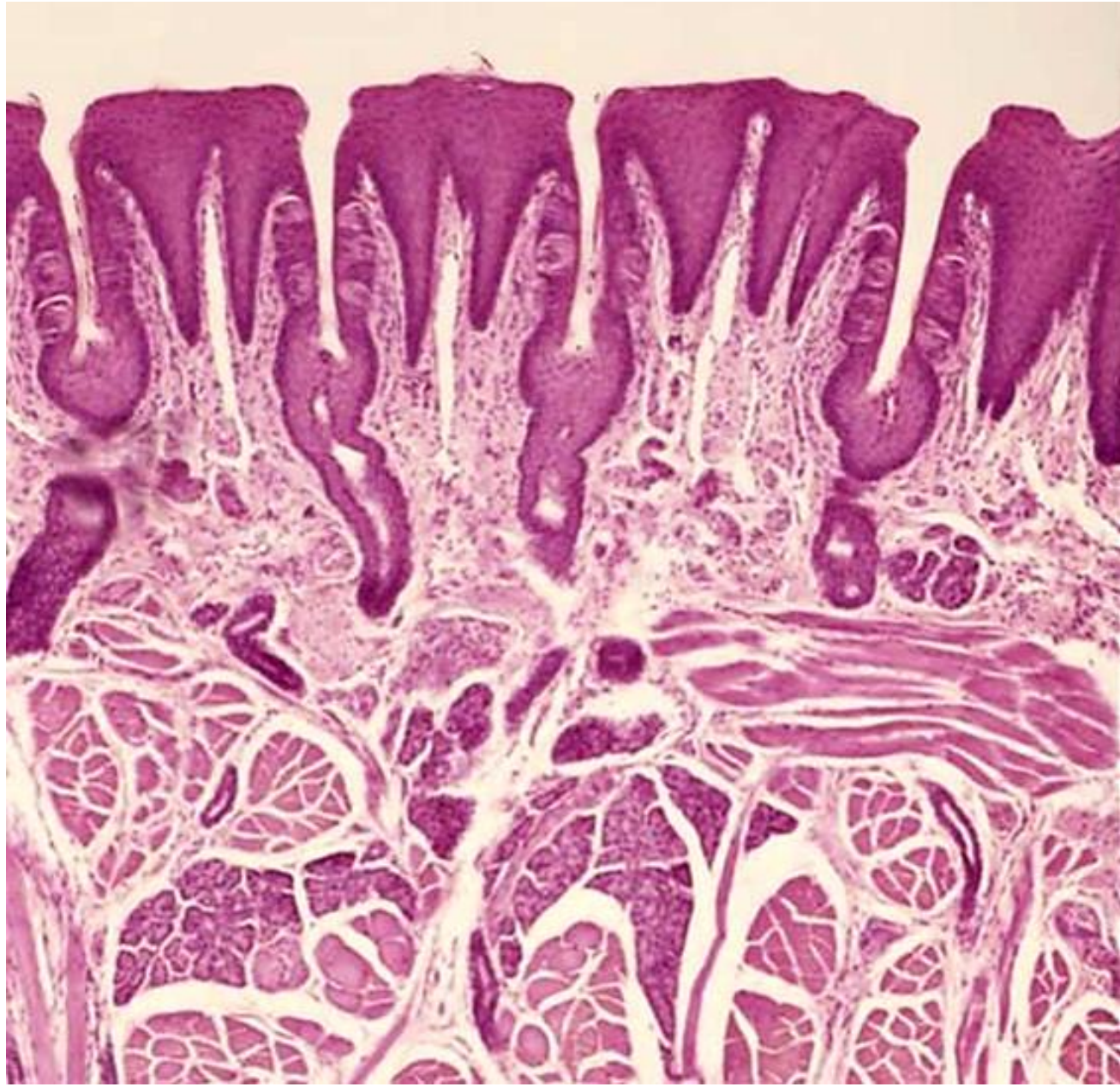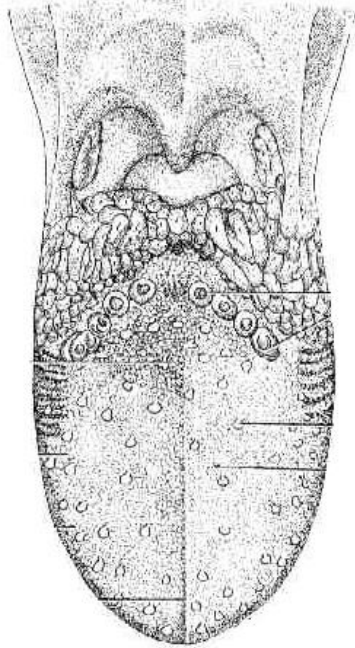
TONGUE – FILLIFORM AND FUNGIFORM PAPILLAE



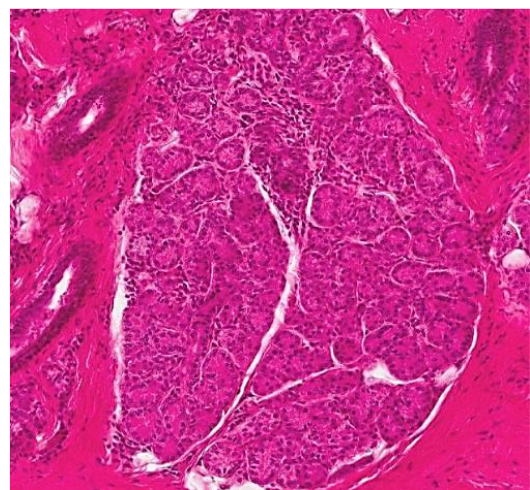
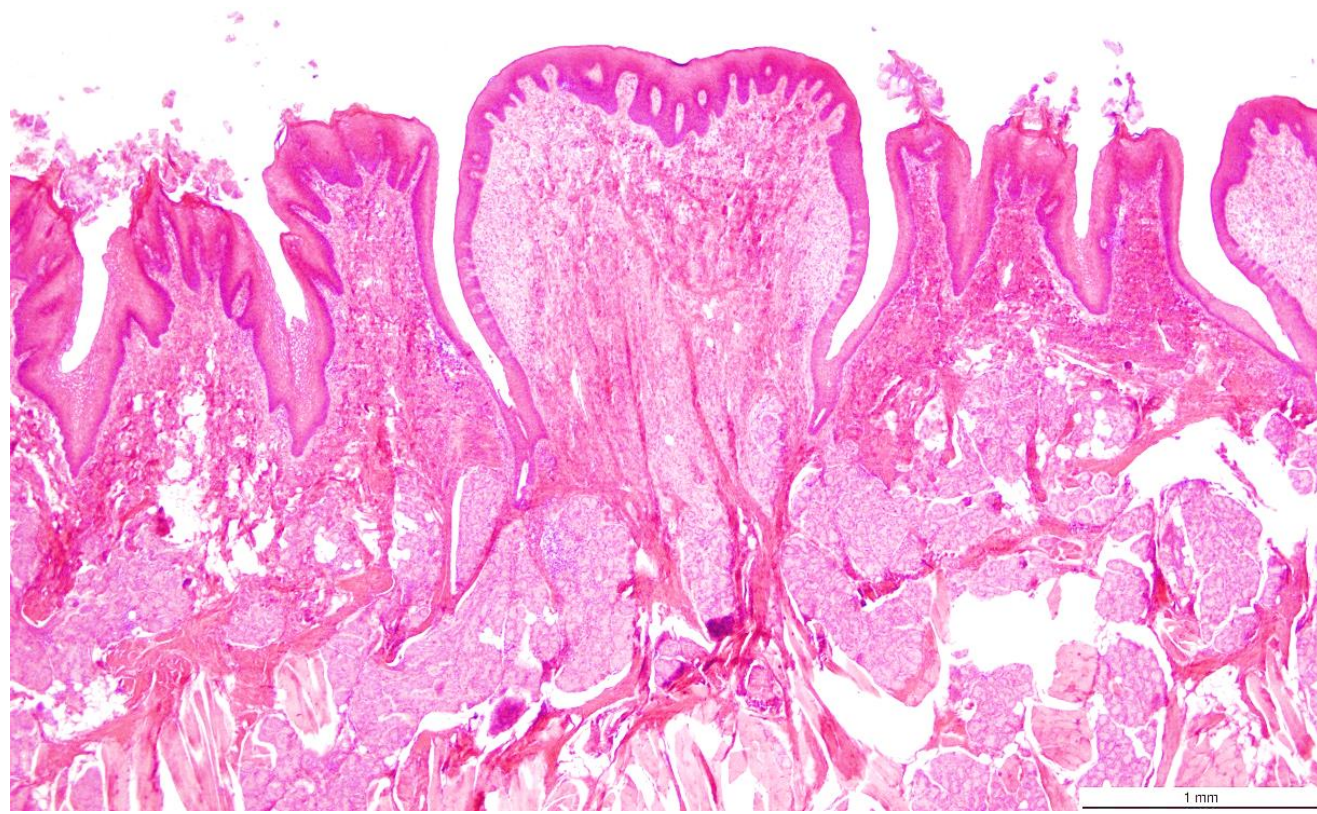
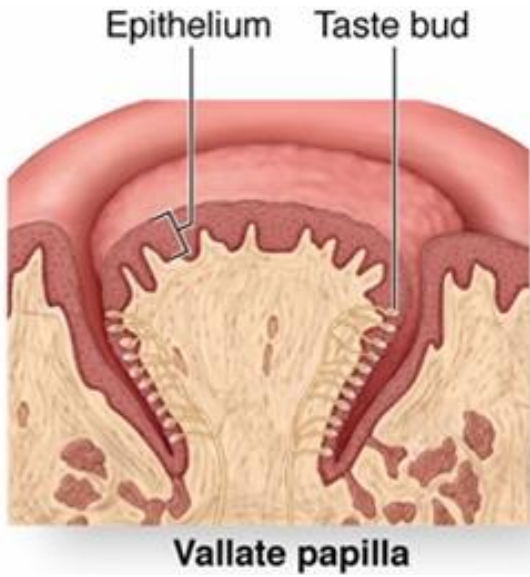
TONGUE – FOLIATE PAPILLAE



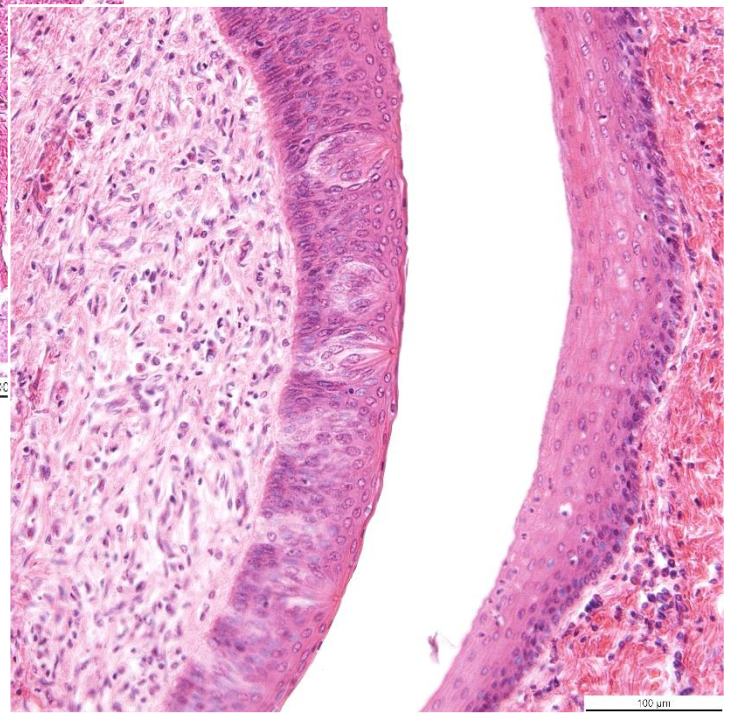
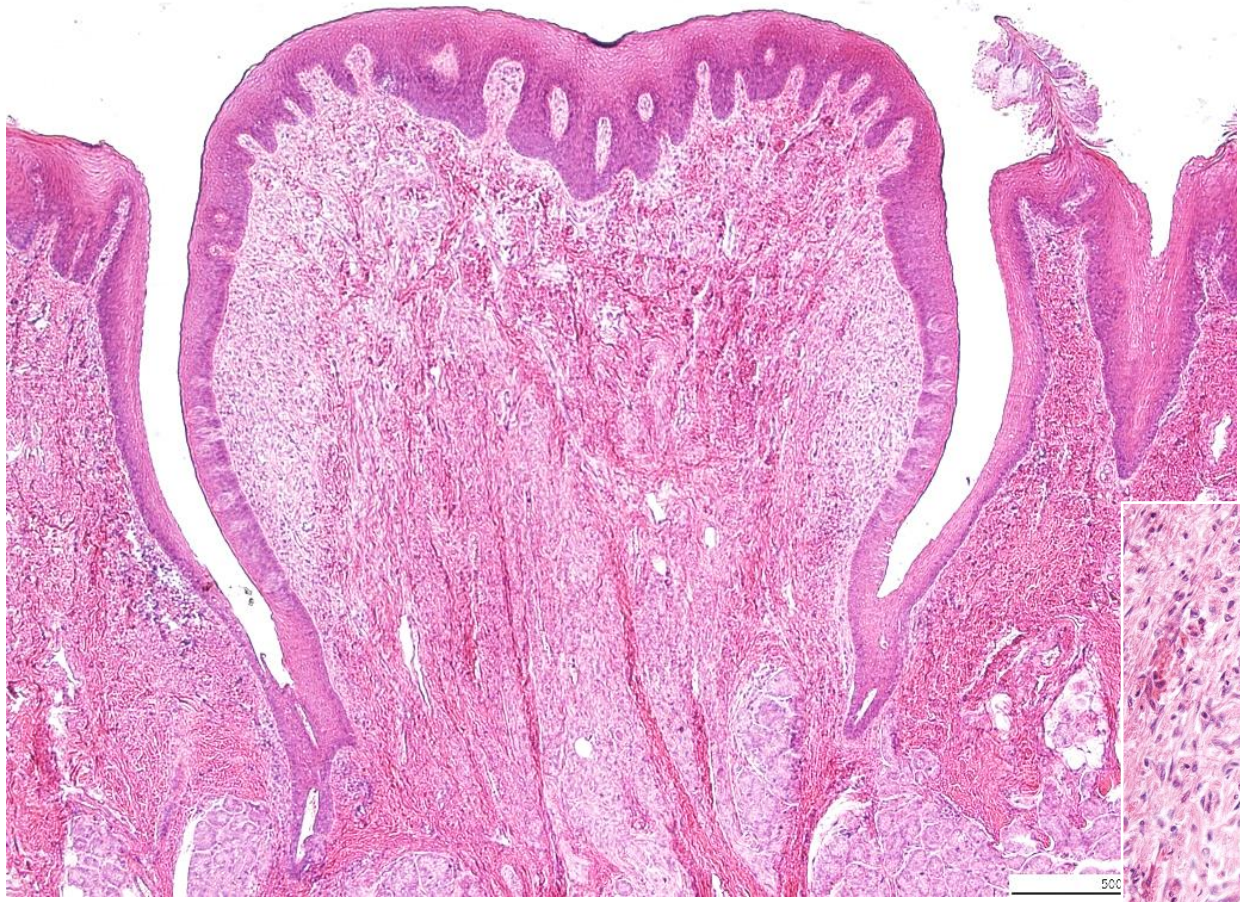Foliate papilla



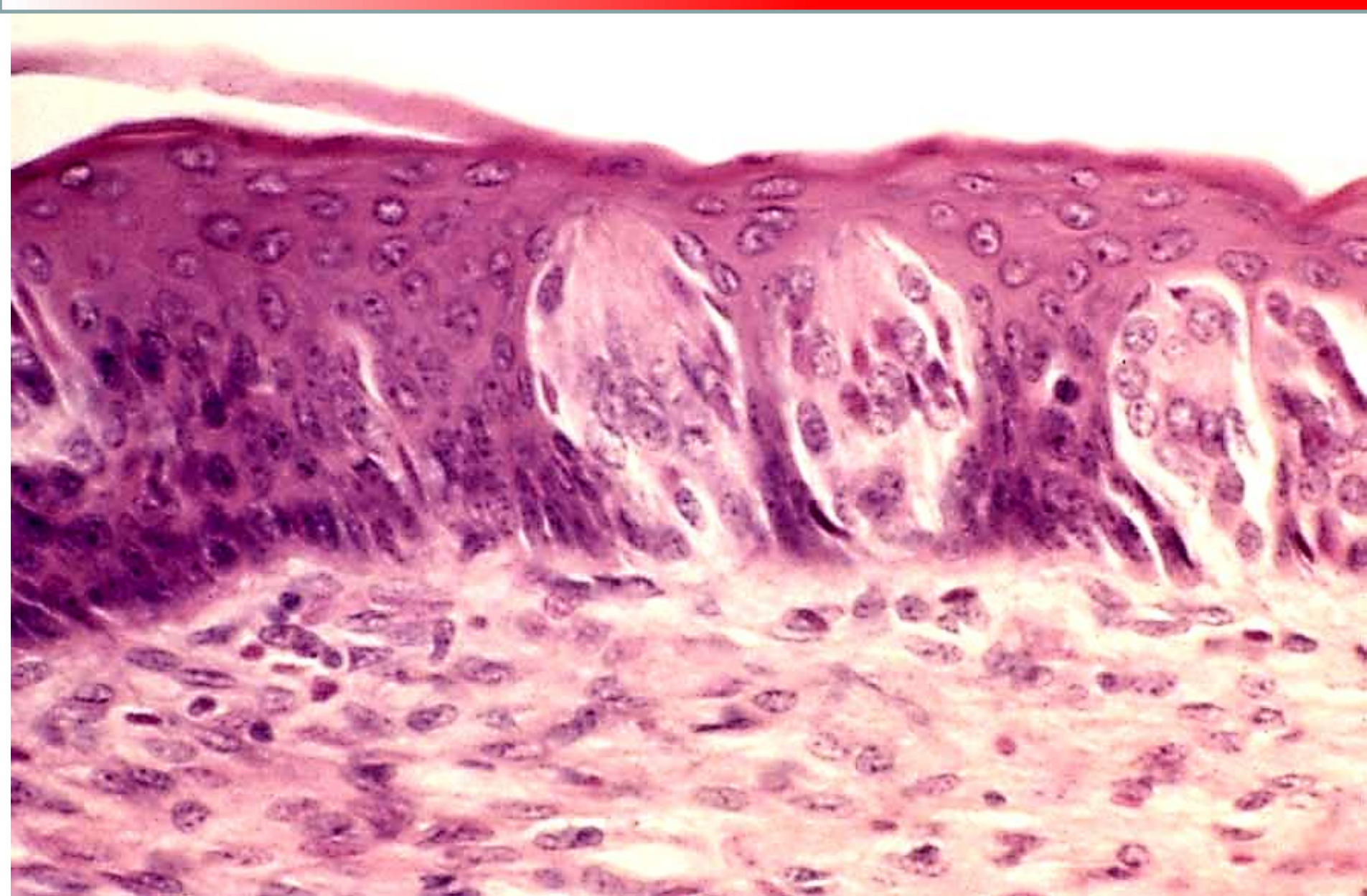
TONGUE – VALLATE PAPILLAE



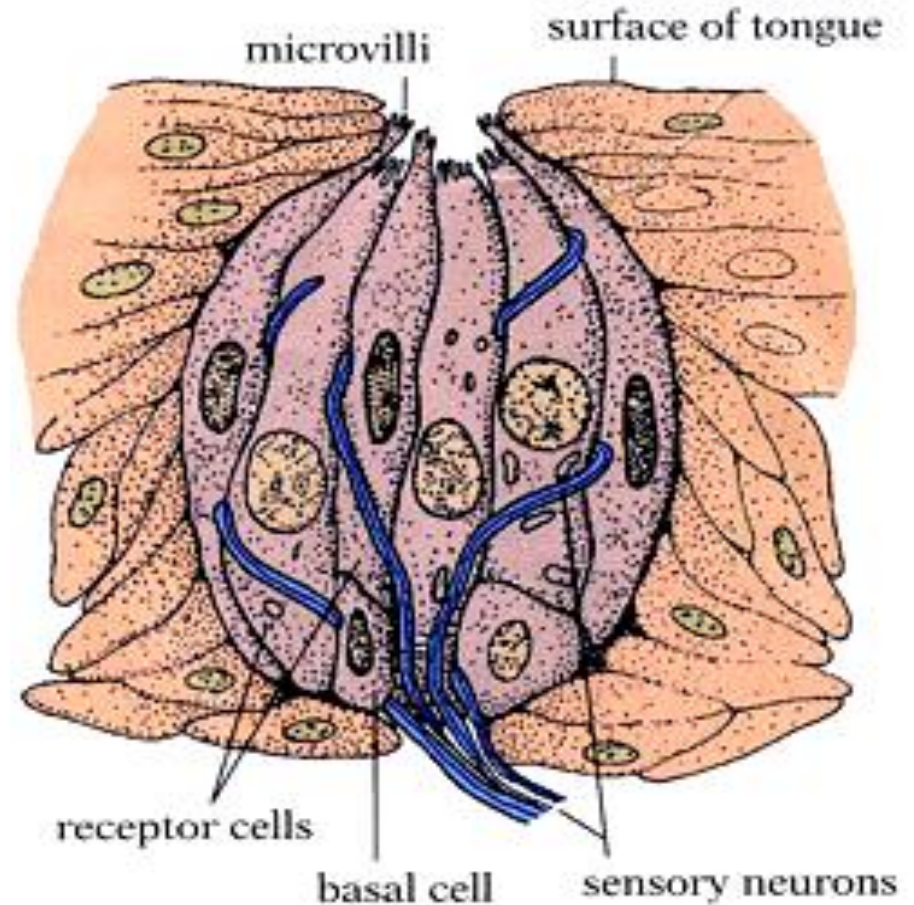
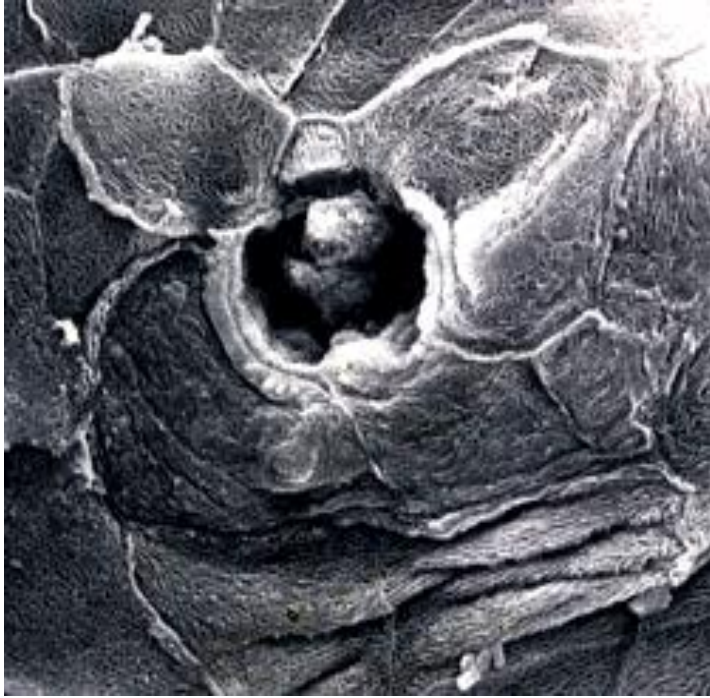TONGUE – VALLATE PAPILLAE



TONGUE – TASTE BUDS

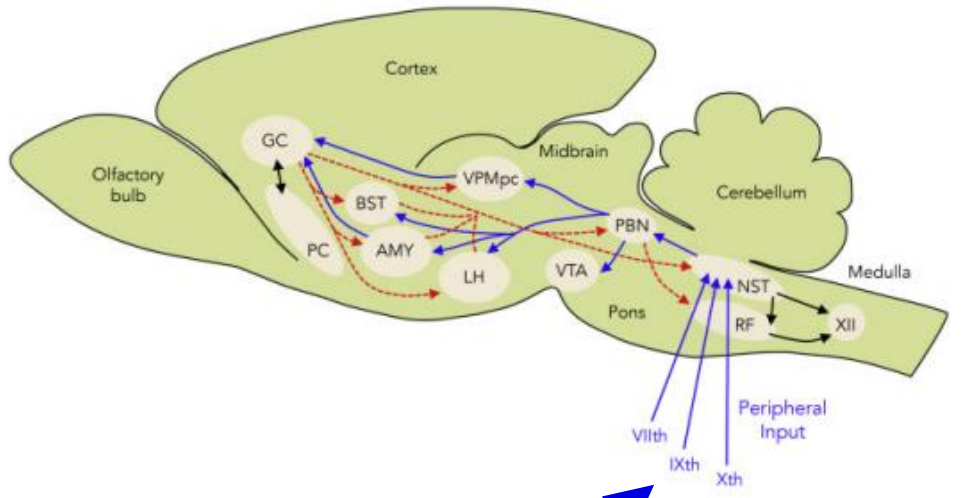
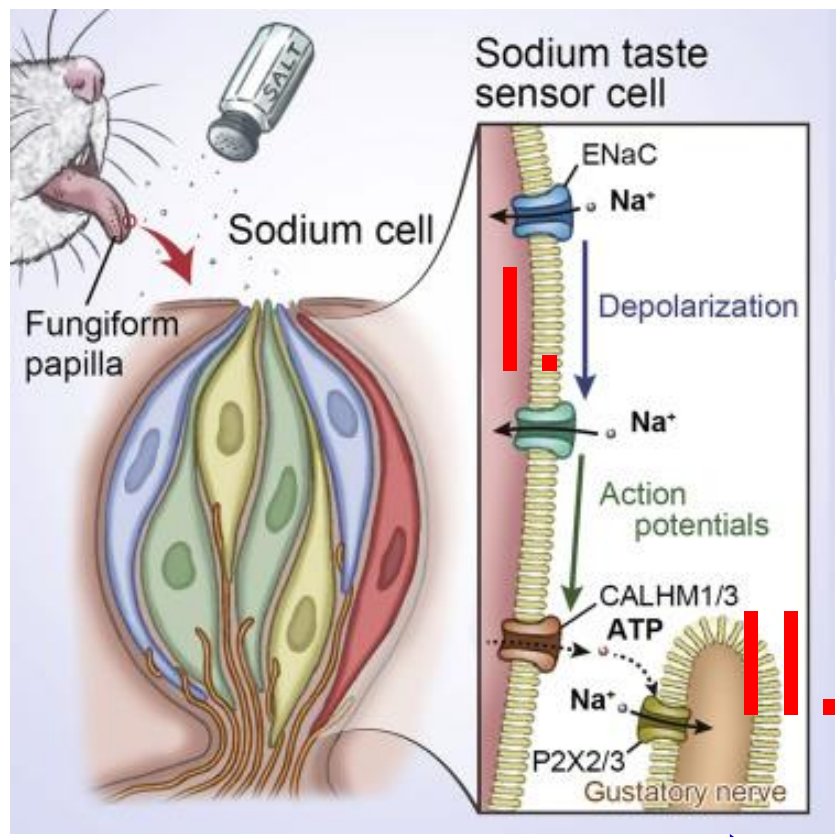


TONGUE – TASTE BUD



- Intraepithelial
- porus gustatorius
- 2000-8000 in oral cavity
- 60-80 cells
- 70-80 μm \times 30-40 μm
- microvilli on sensory cells
- nerve fibers

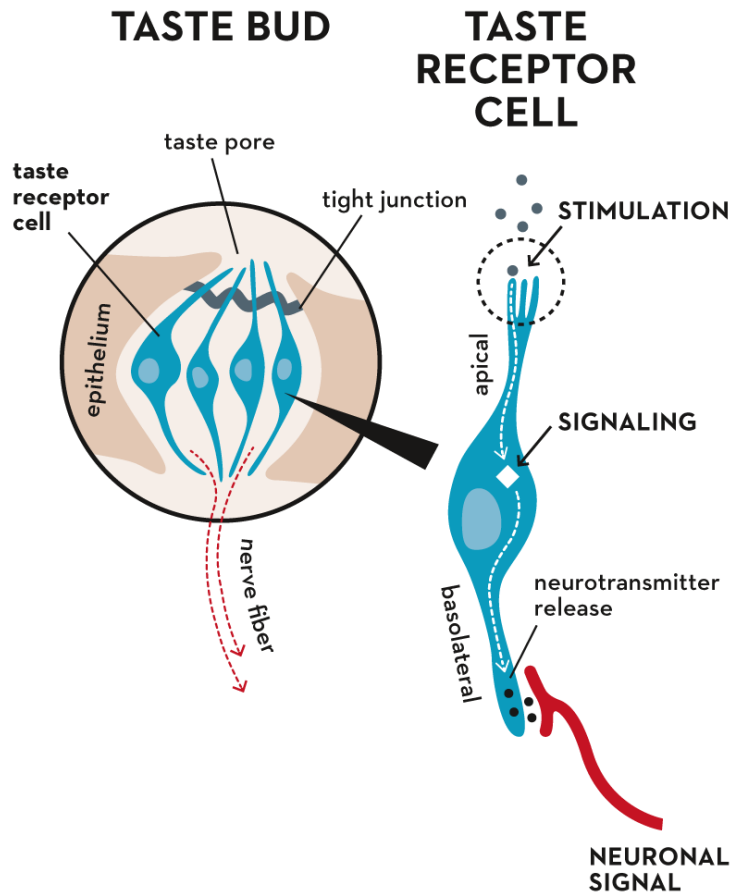
TONGUE – TASTE BUD



- secondary sensory epithelium

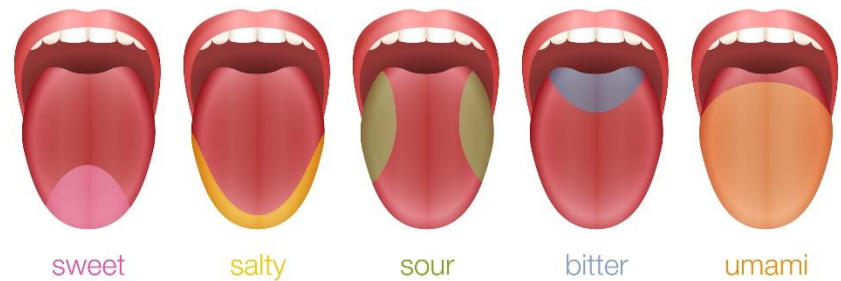
- n. vagus
- n. facialis
- n. glossopharyngeus

TONGUE – TASTE BUD

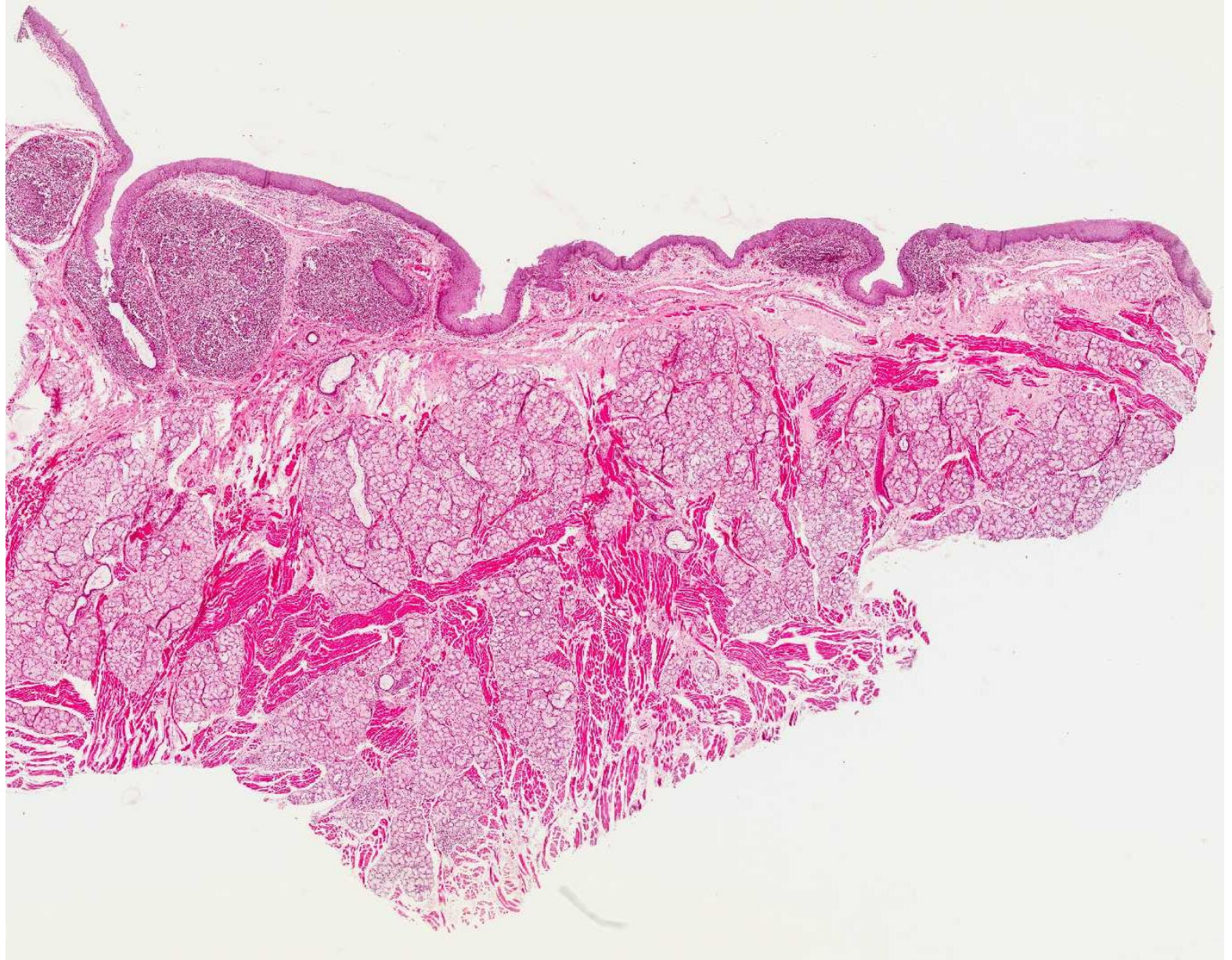


- bitter
- sweet
- umami (glutamate)
- G-protein-coupled receptors
- salt
- acid
- ion channels
- CD36
- fatty acid transporter

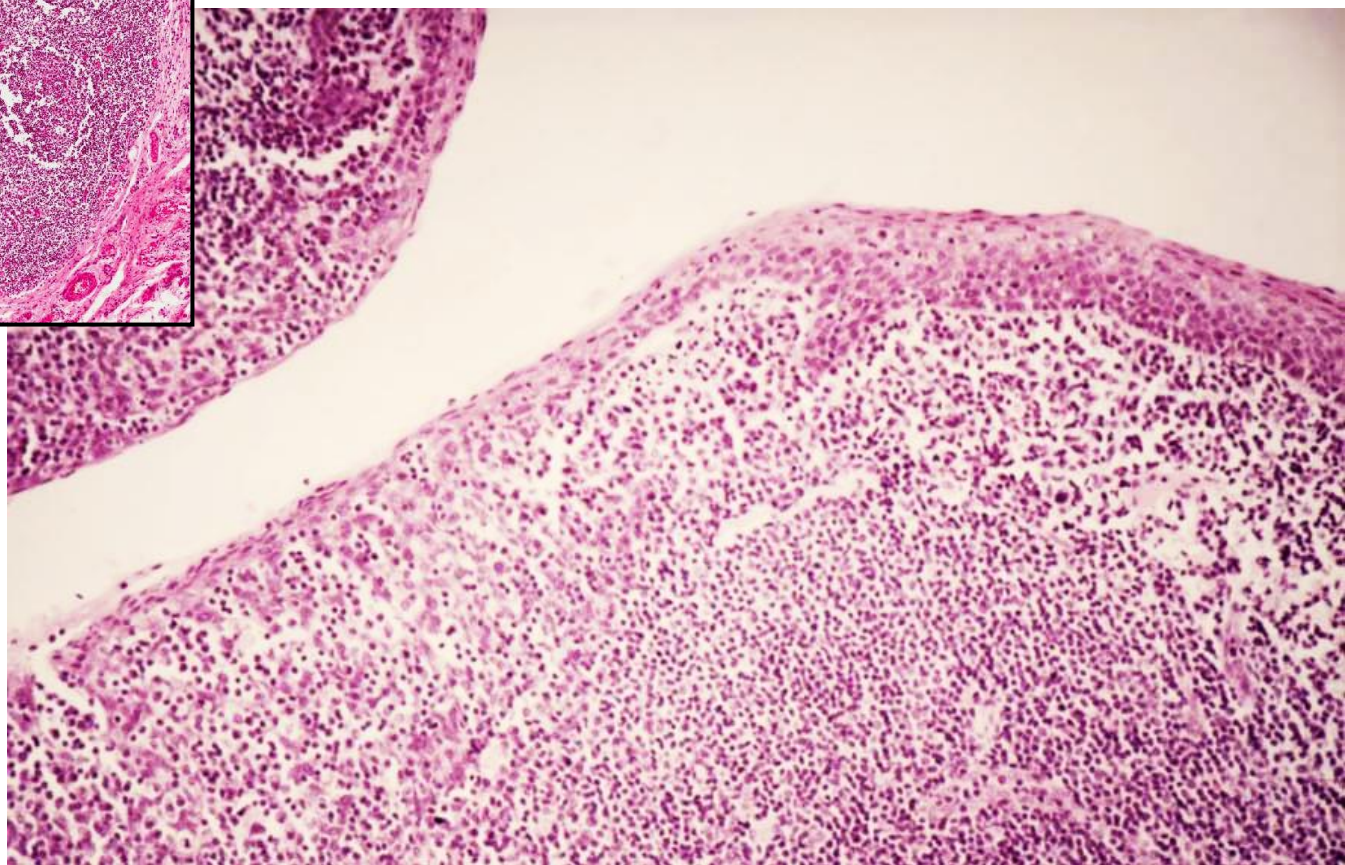
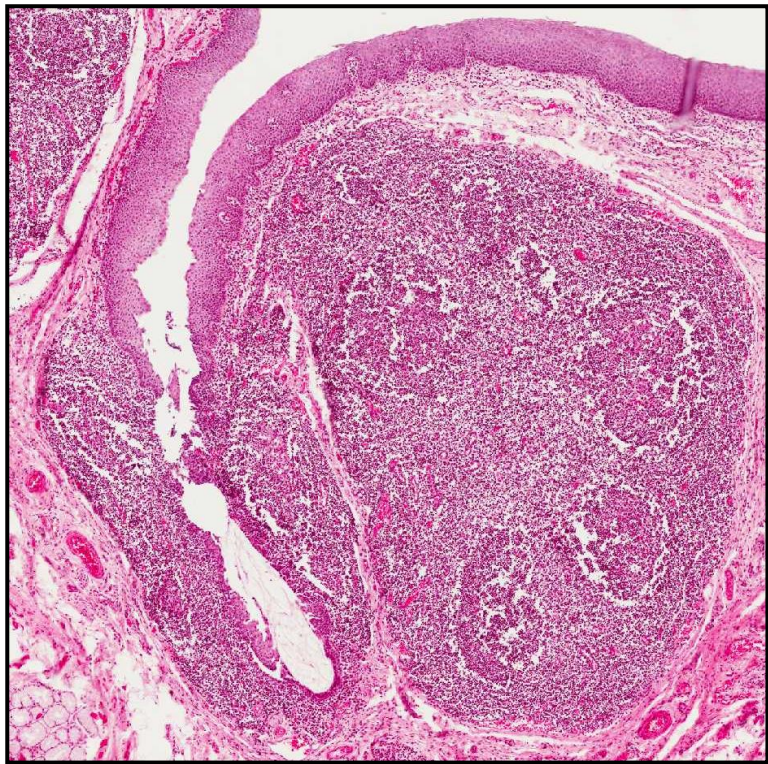
- in taste sensing olfactory epithelium is involved



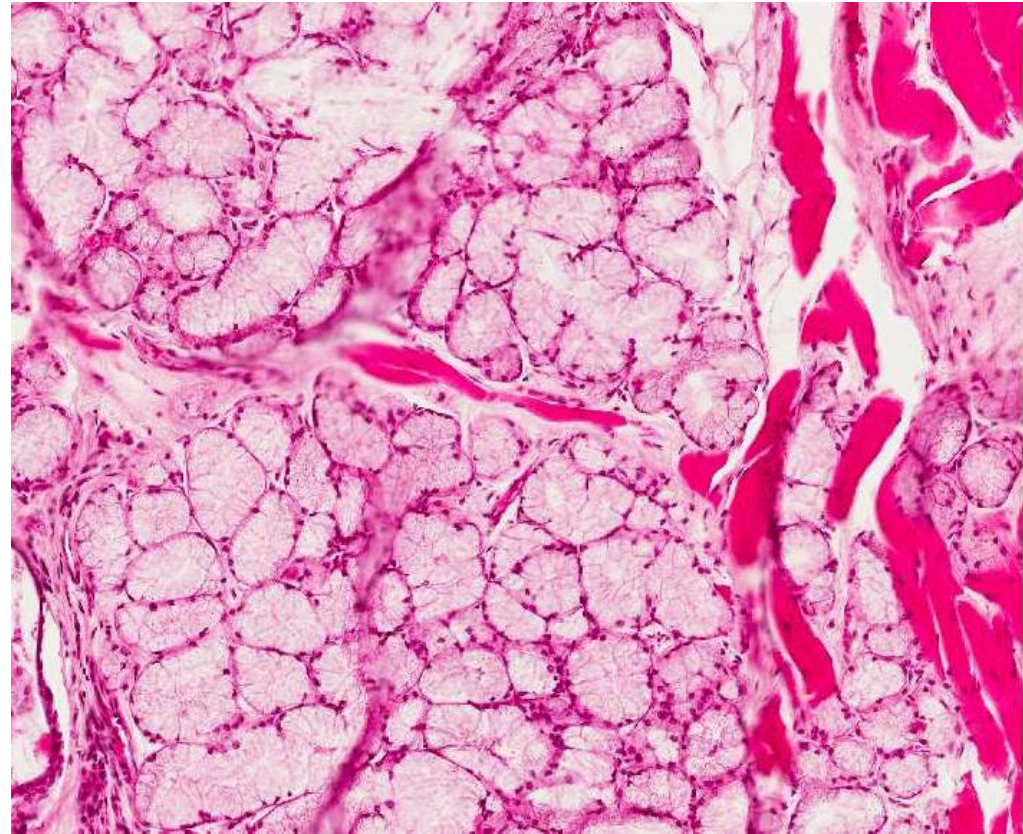
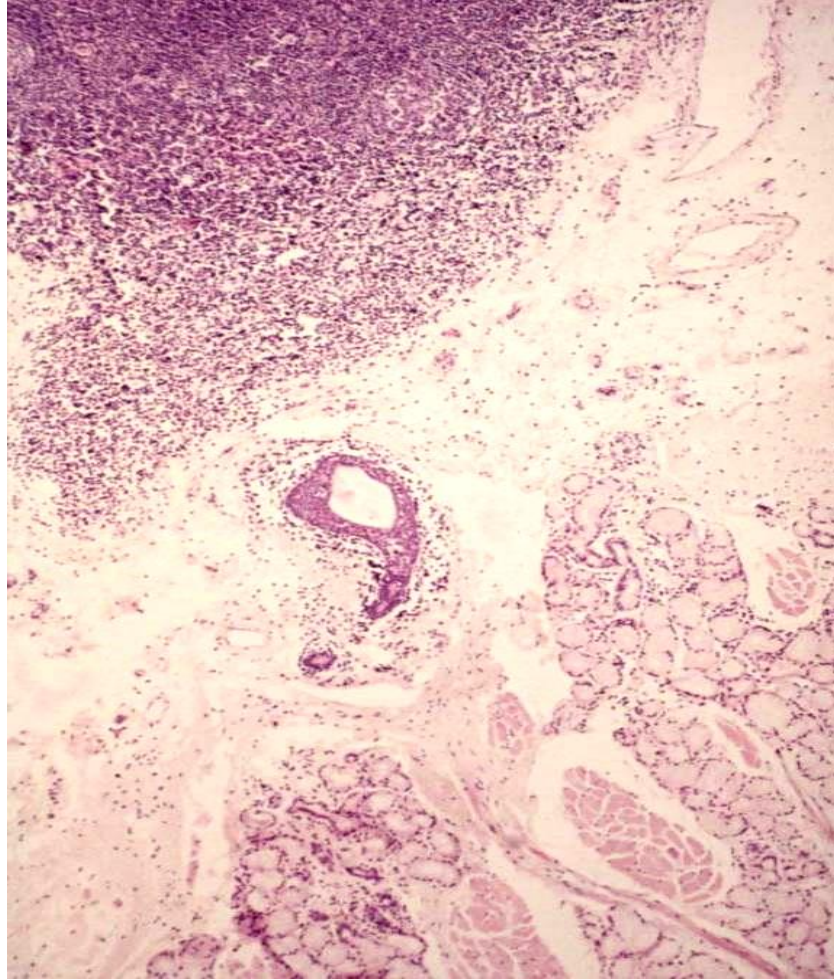
TONGUE – RADIX, TONSILLA LINGUALIS



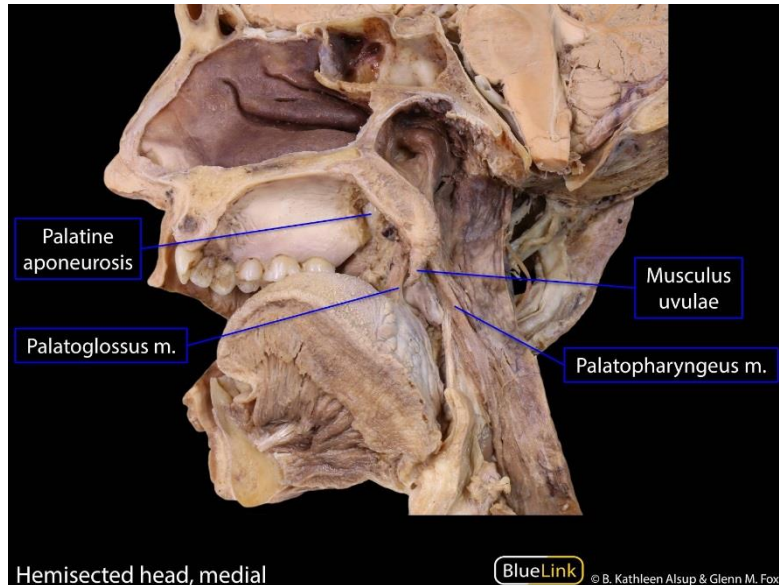
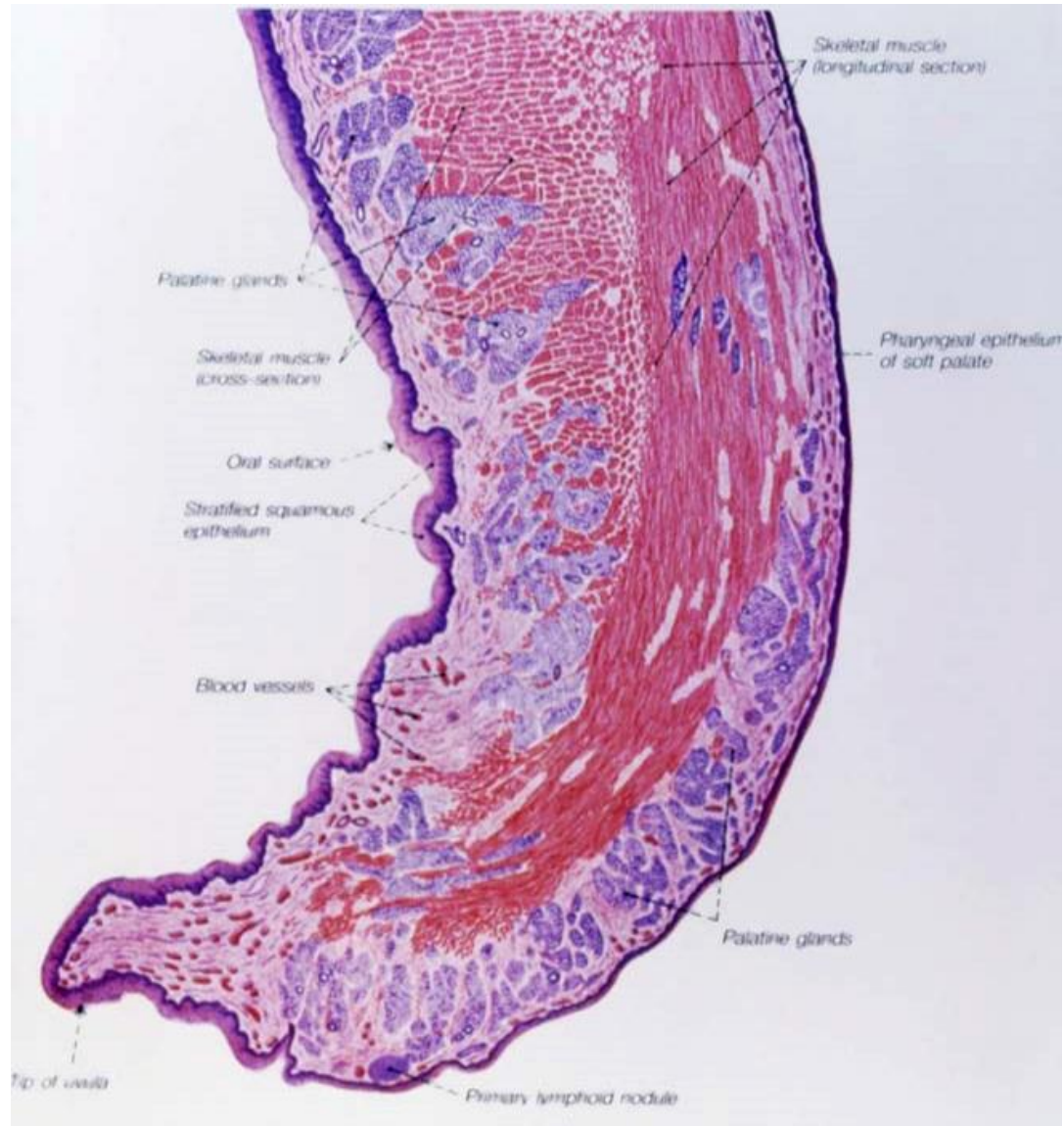
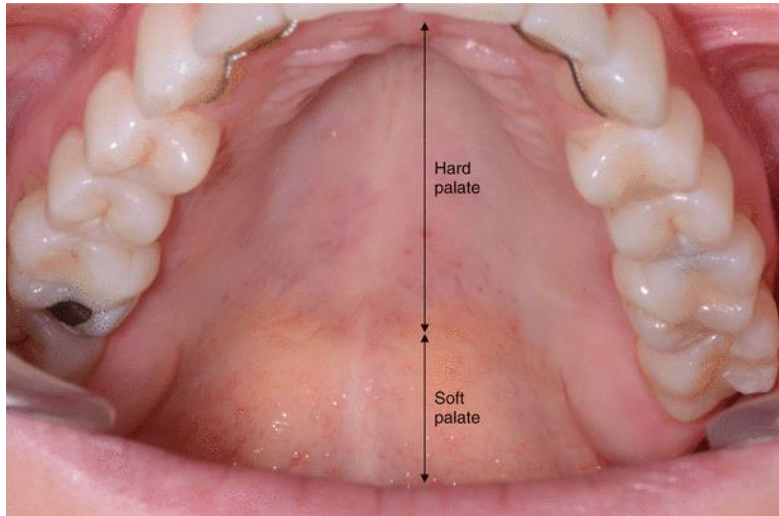
TONGUE – RADIX, TONSILLA LINGUALIS



TONGUE – RADIX, TONSILLA LINGUALIS, WEBER'S GLANDS

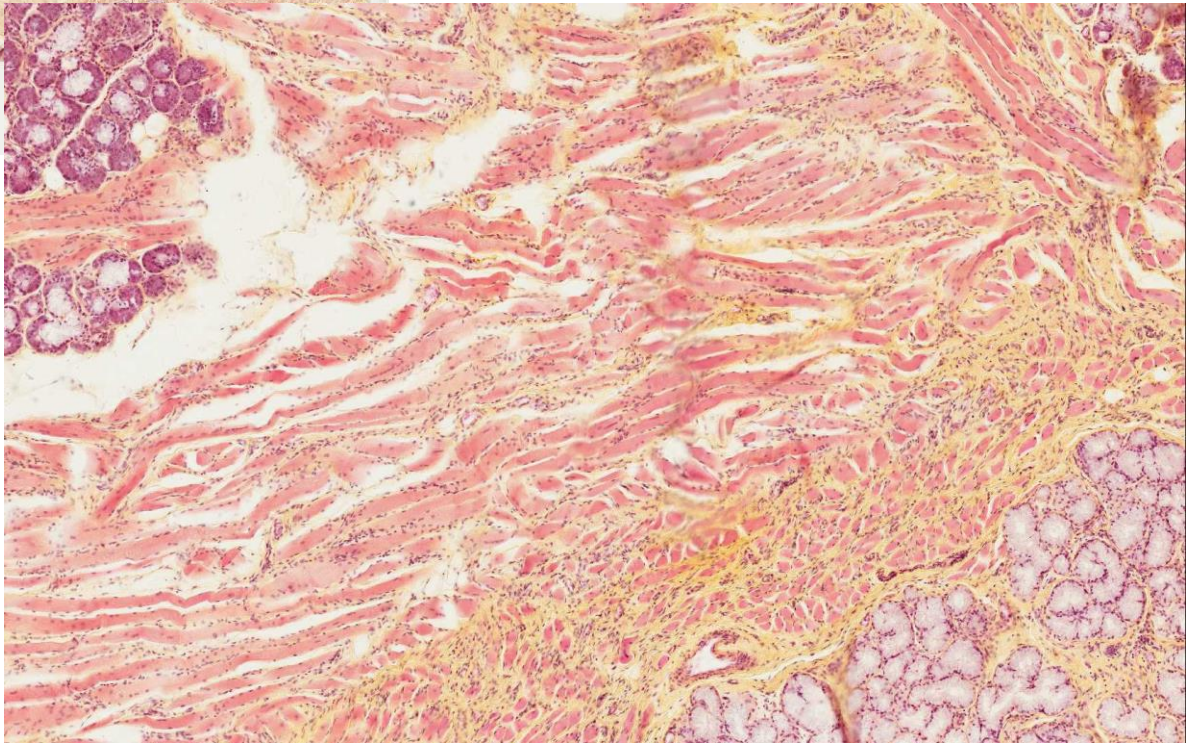
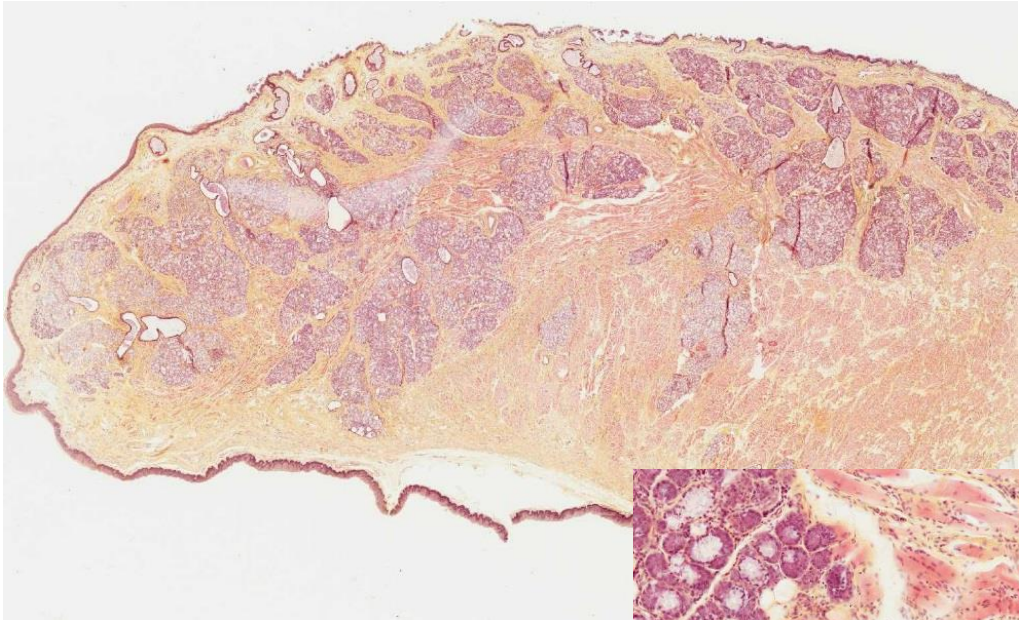


PALATE

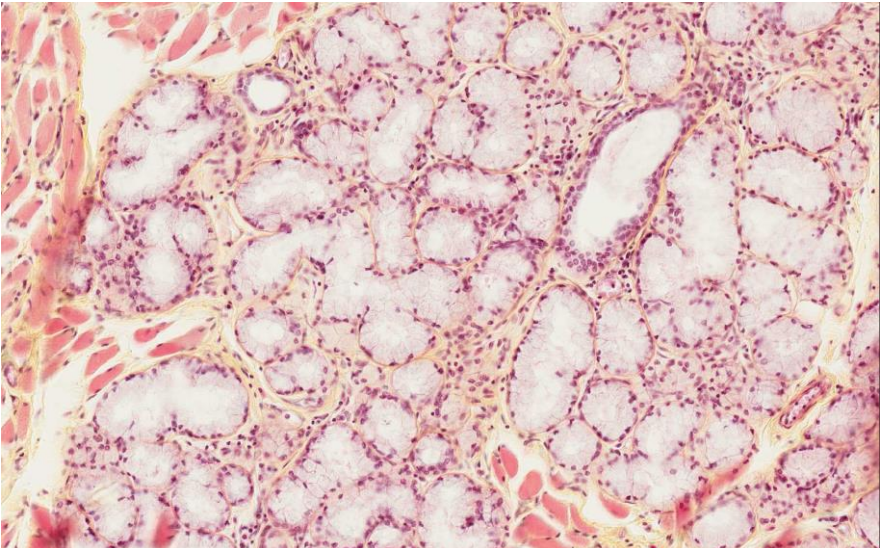
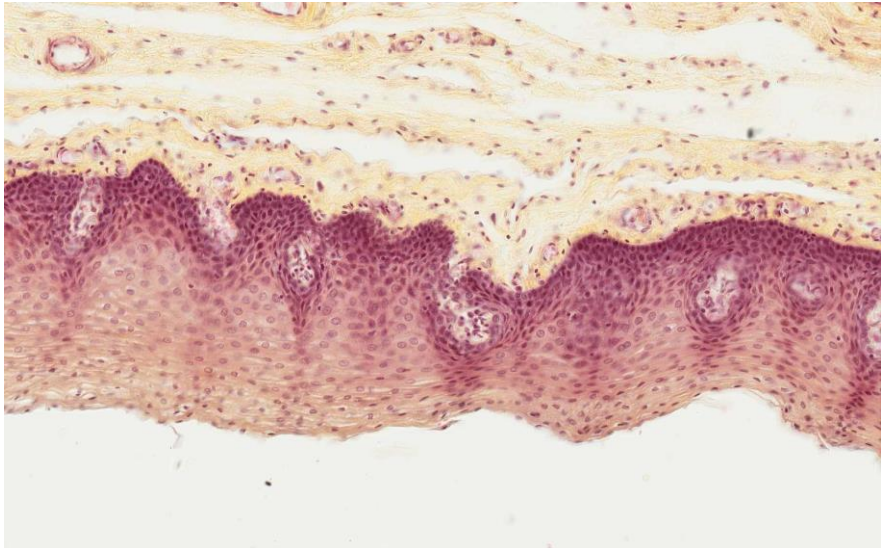
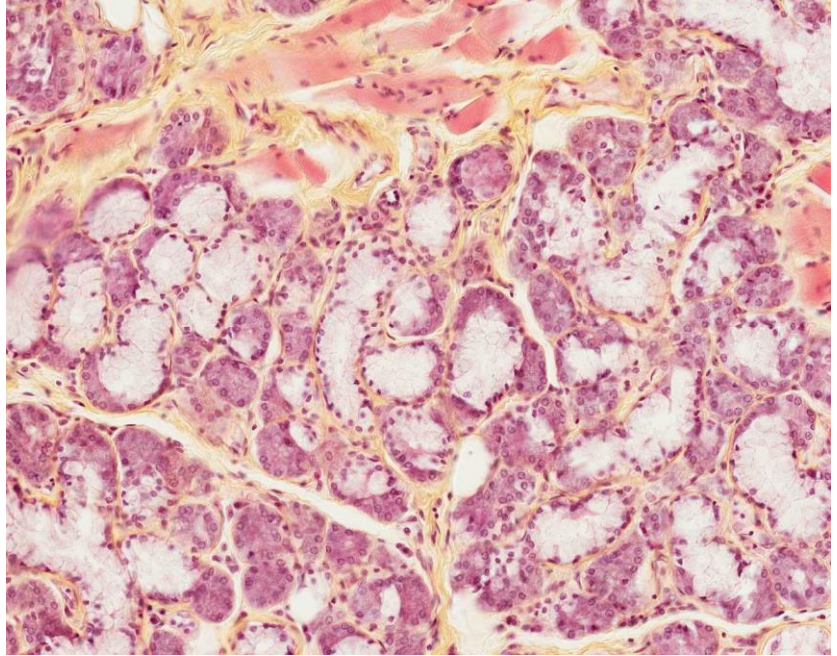
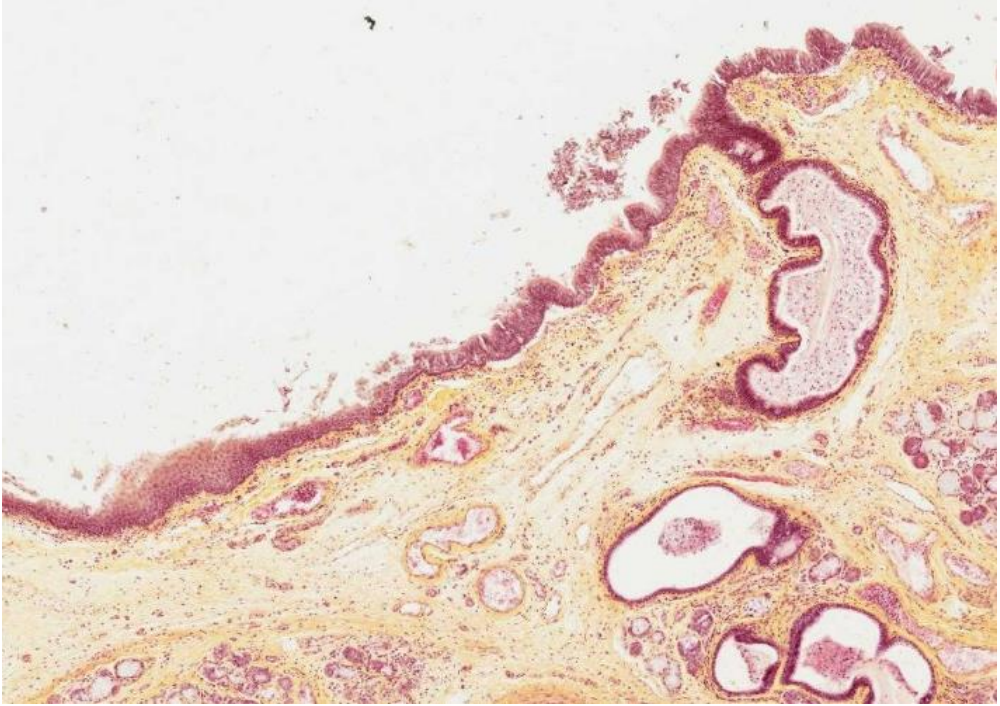


Hemisected head, medial

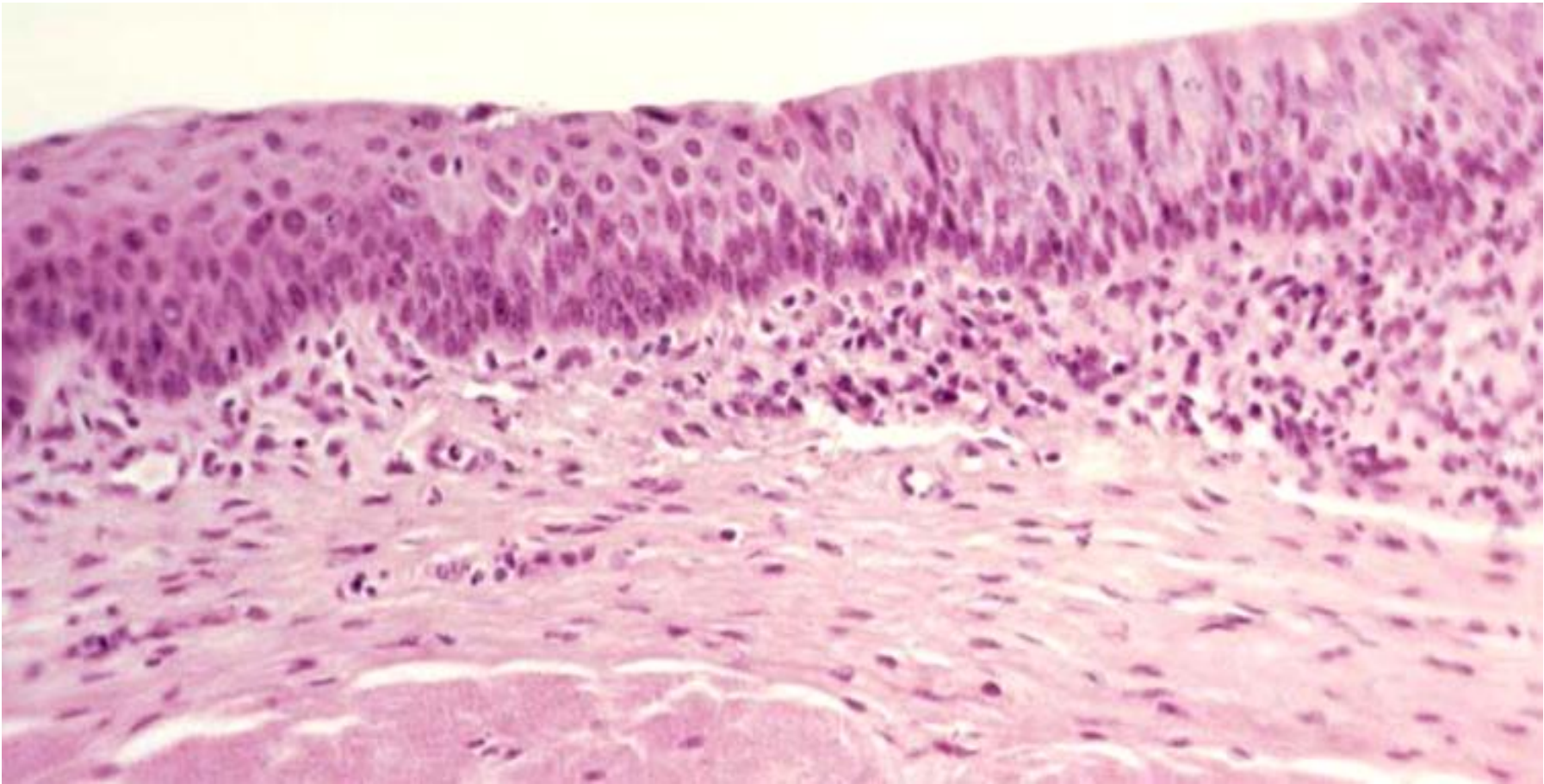
SOFT PALATE



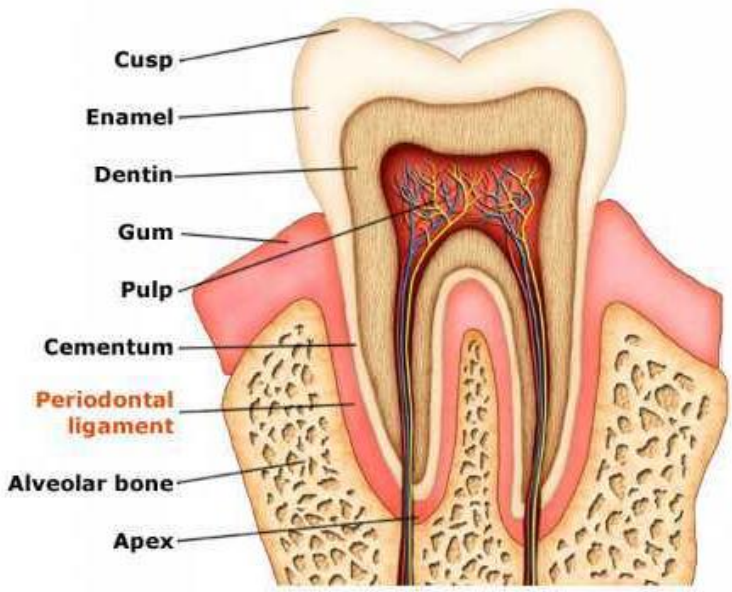
SOFT PALATE



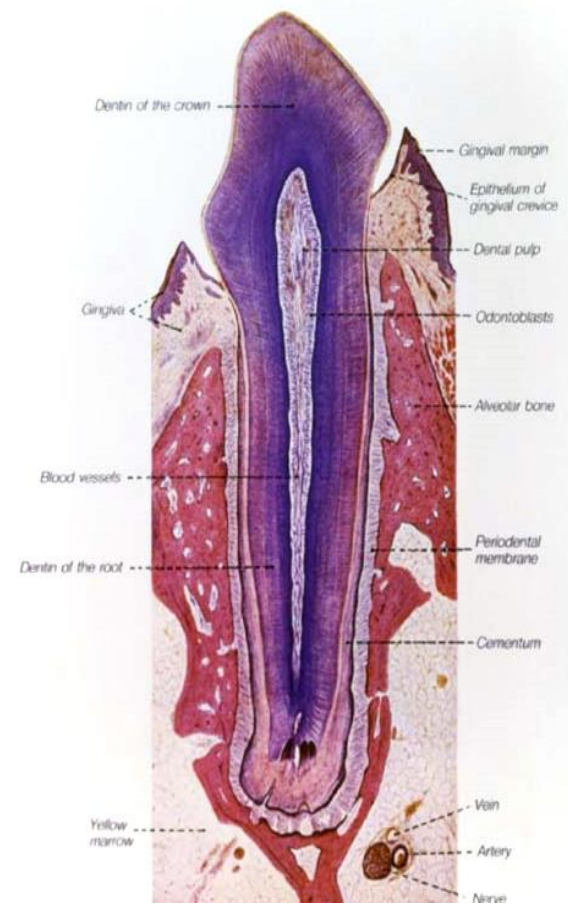
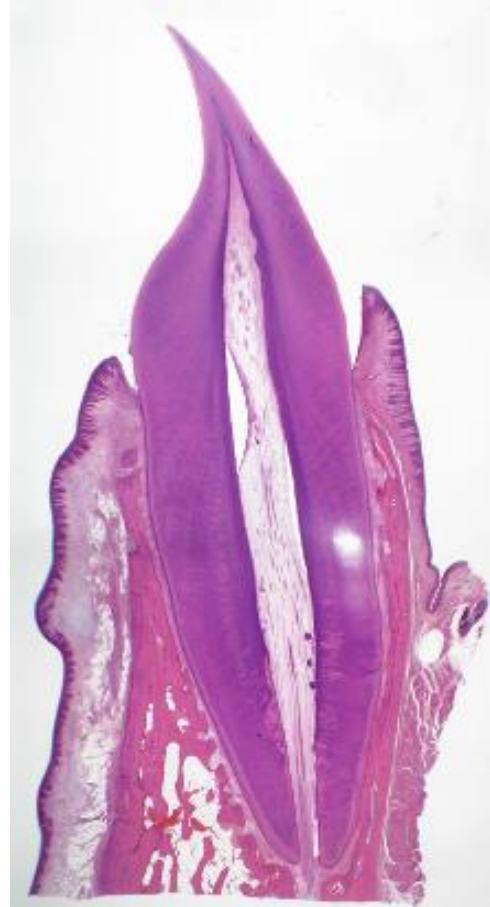SOFT PALATE – EPITHELIAL CHANGE



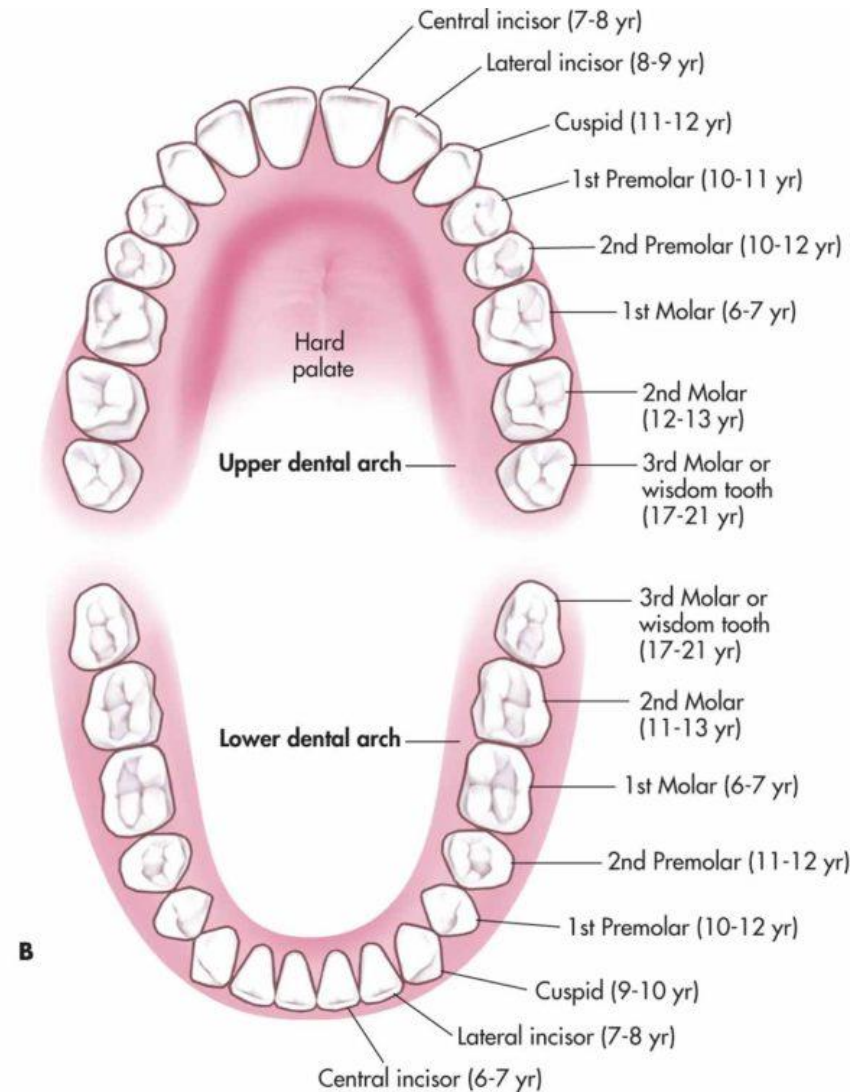
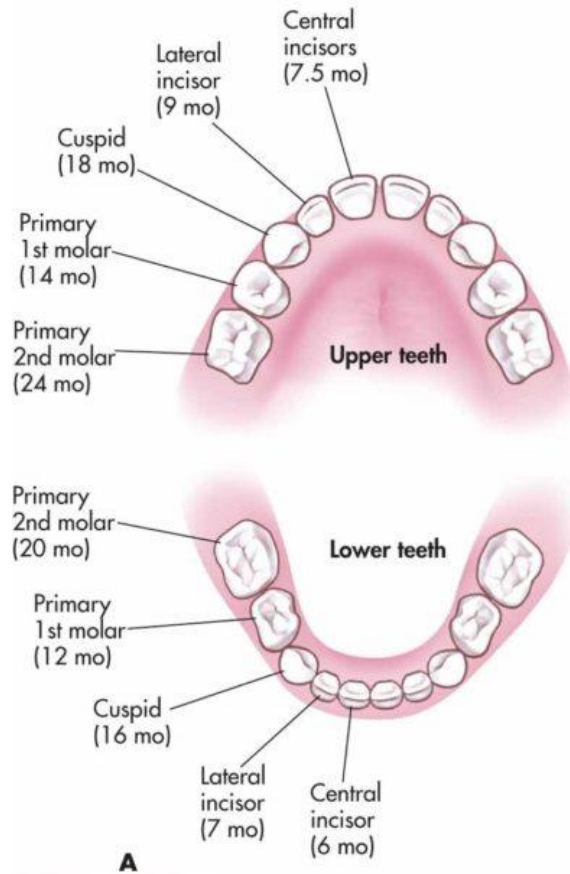
TOOTH



- Anatomical × clinical crown
- Neck (cementoenamel junction)
- Root



DECIDUAL AND PERMANENT TEETH



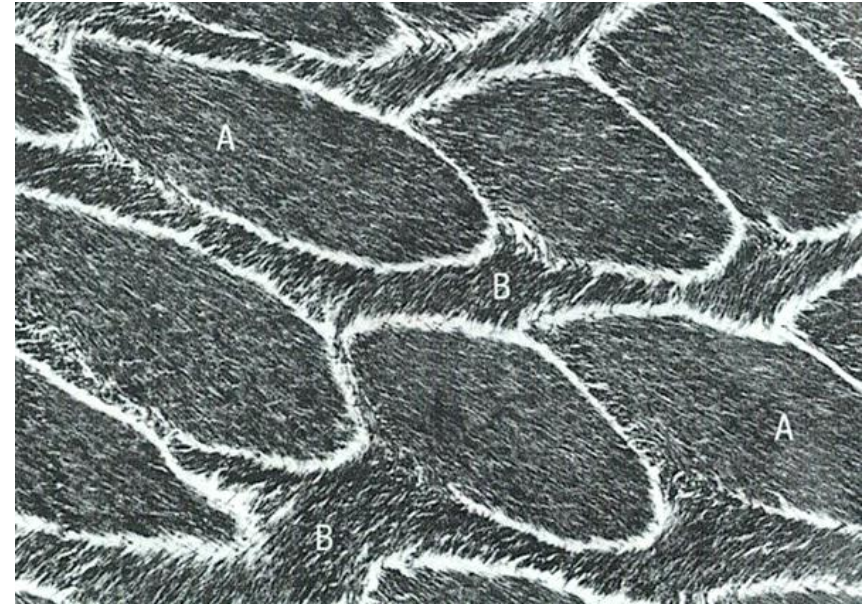
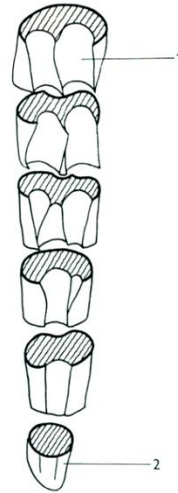
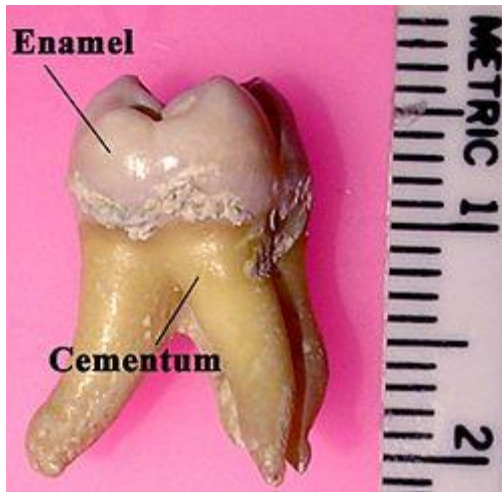Vzorec mléčného chrupu:

m_2	m_1	c	i_2	i_1	i_1	i_2	c	m_1	m_2
m_2	m_1	c	i_2	i_1	i_1	i_2	c	m_1	m_2

Vzorec definitivního chrupu:

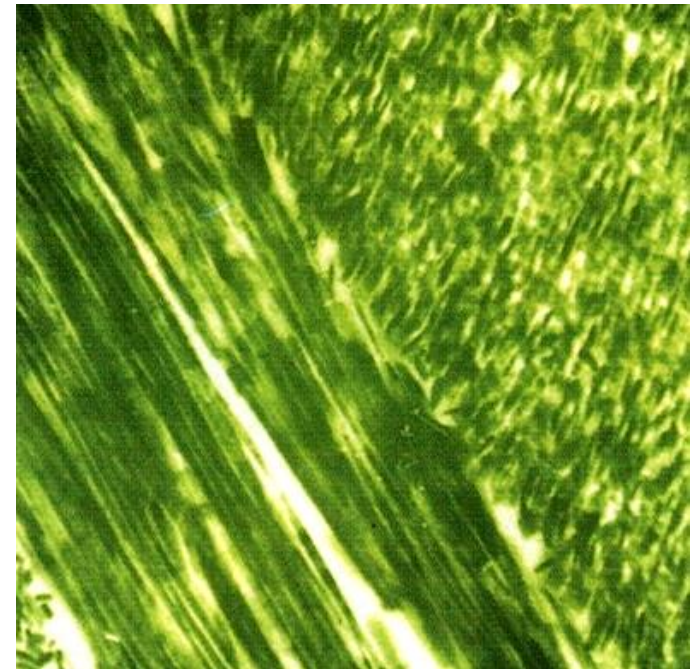
M_3	M_2	M_1	P_2	P_1	C	I_2	I_1	I_1	I_2	C	P_1	P_2	M_1	M_2	M_3
M_3	M_2	M_1	P_2	P_1	C	I_2	I_1	I_1	I_2	C	P_1	P_2	M_1	M_2	M_3

TOOTH – ENAMEL

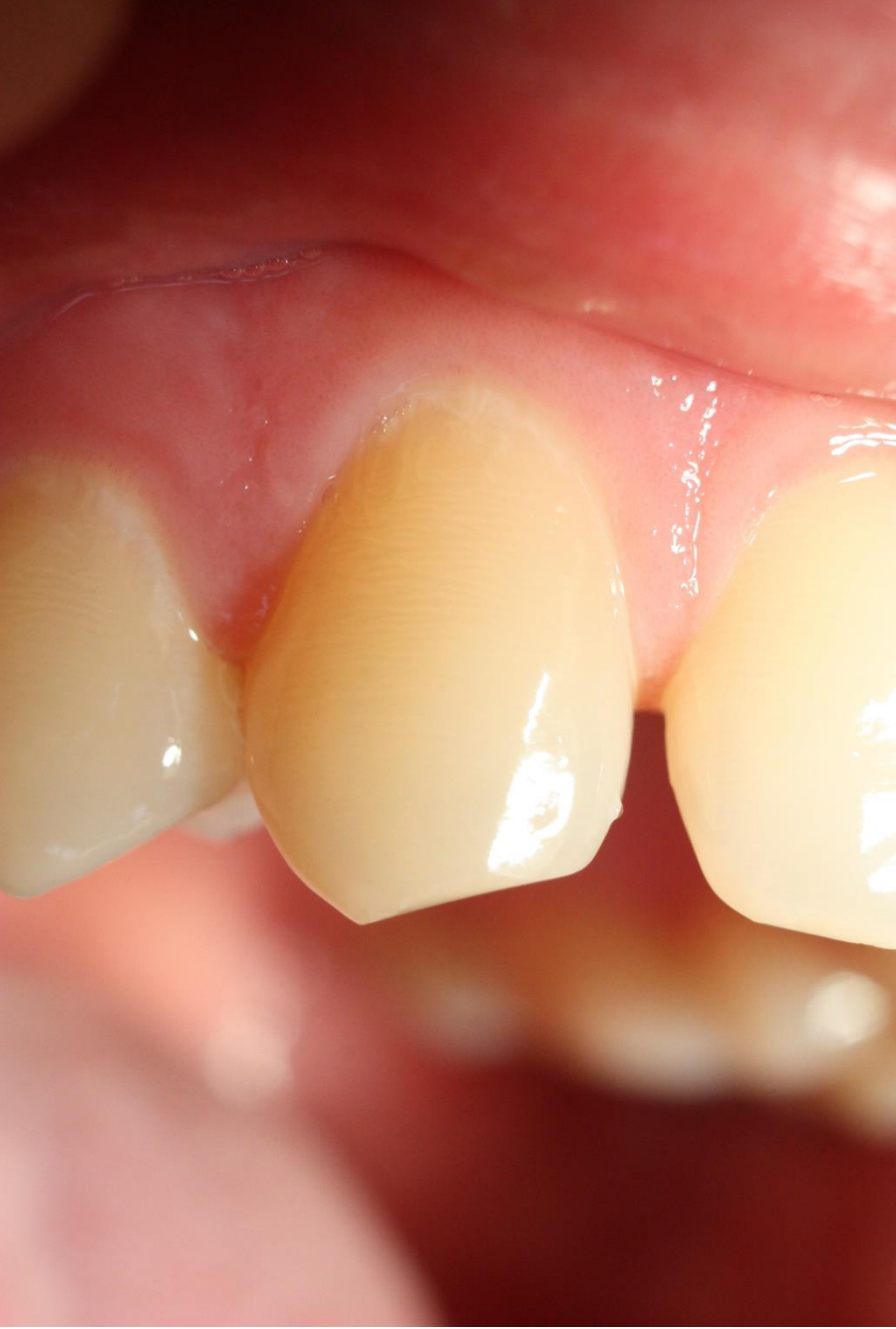



Enamel, 1-2 mm

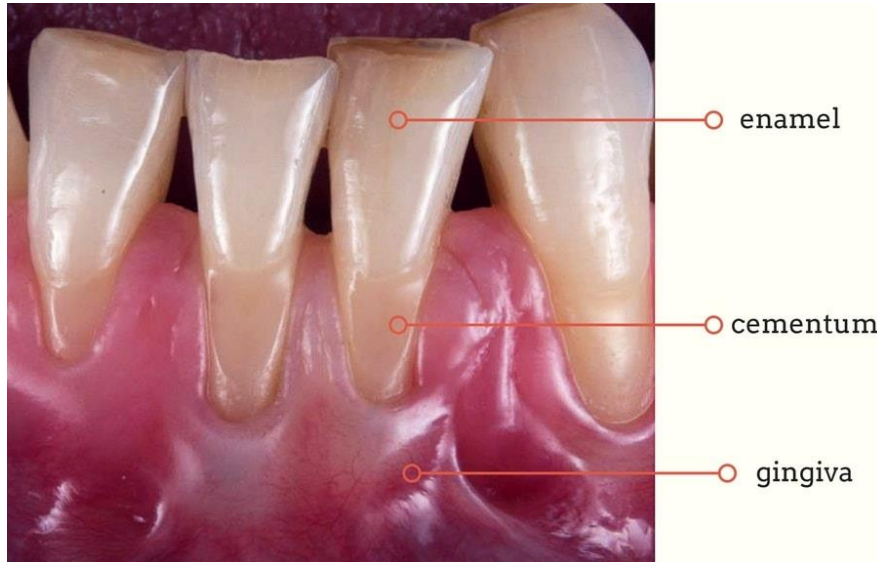
- Covers the crown
- Made by ameloblasts, but after eruption acellular
- No regeneration
- 96% Ca-hydroxyapatite, enamel prisms
- Enamelins, amelogenins, ameloblastins
- Striae of *Retzius* (incremental growth lines)



TOOTH – ENAMEL

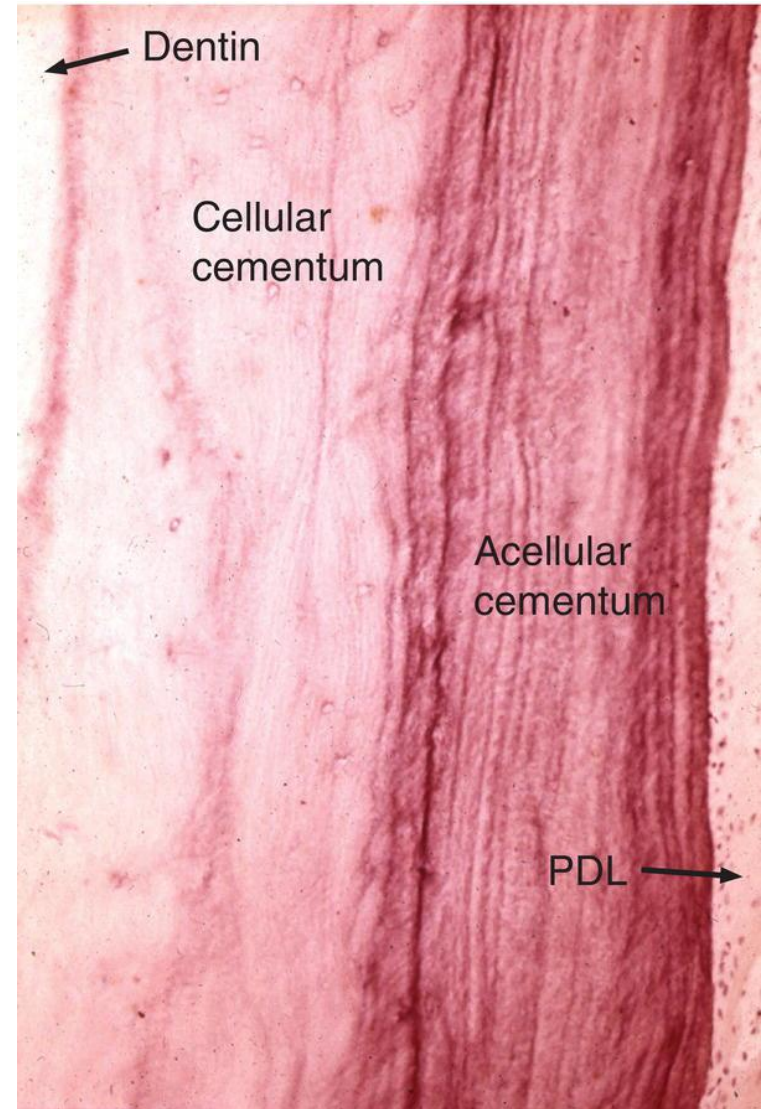


TOOTH – CEMENTUM

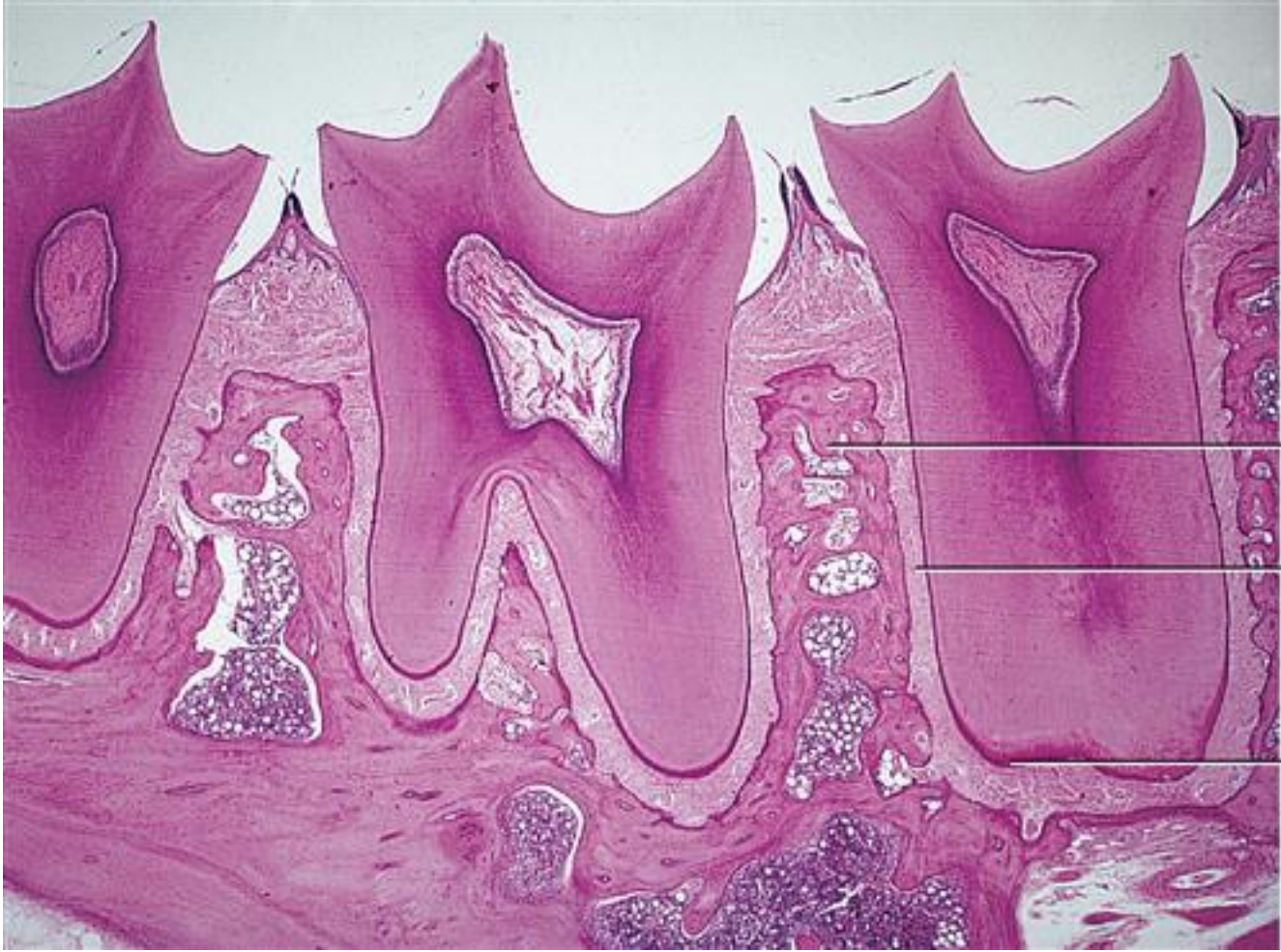

Cementum, 100-500 μm

- Covers root and neck
- Cementoblasts/cementocytes
- Regenerates
- 50% Ca-hydroxyapatite
- Collagen I, III, XII, GAGs, proteoglycans
- Sharpey's fibers – fibrillar cementum
- Periodontal ligaments – tooth alveolus



TOOTH – CEMENTUM



Alveolar bone

Periodontal ligament


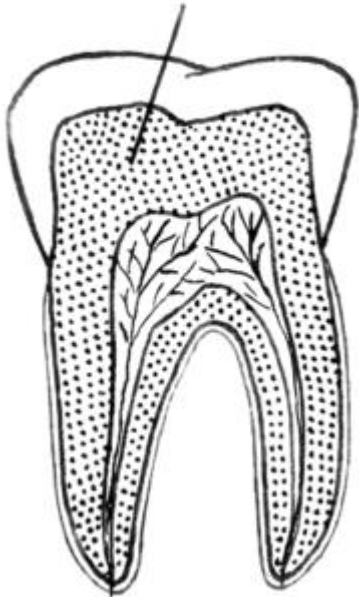
Cementum

TOOTH – DENTIN

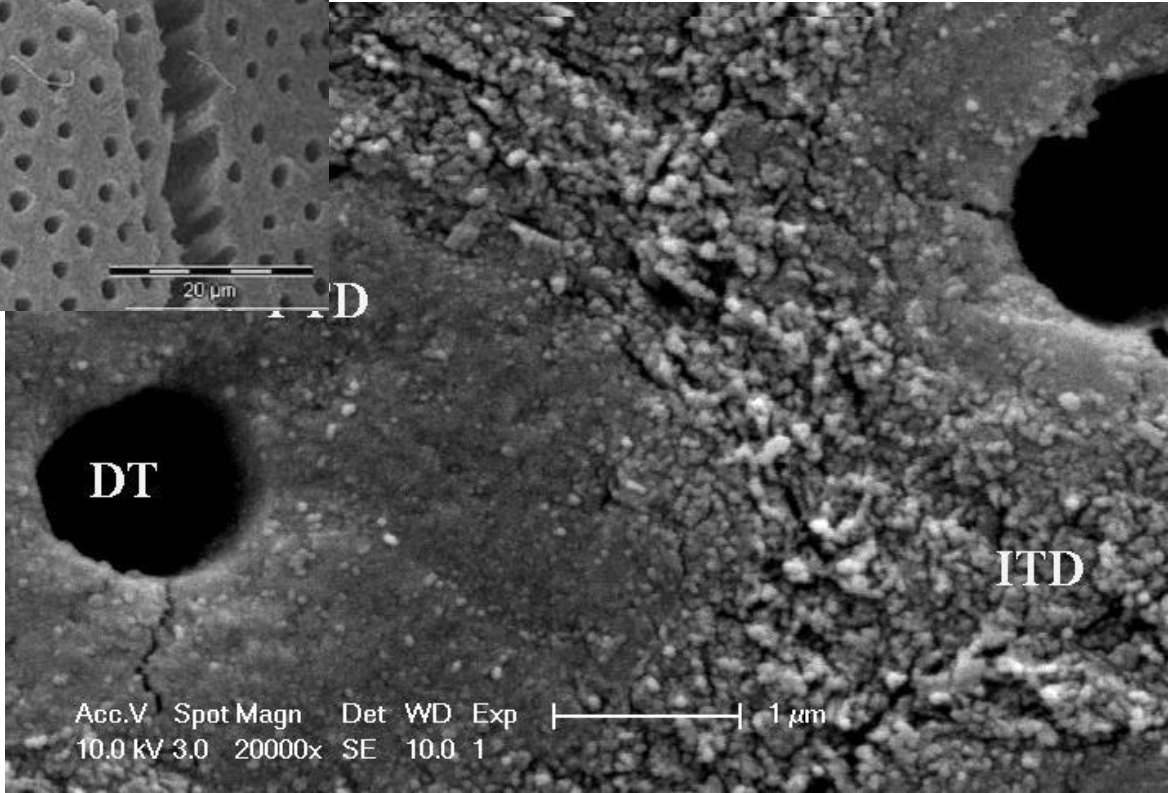
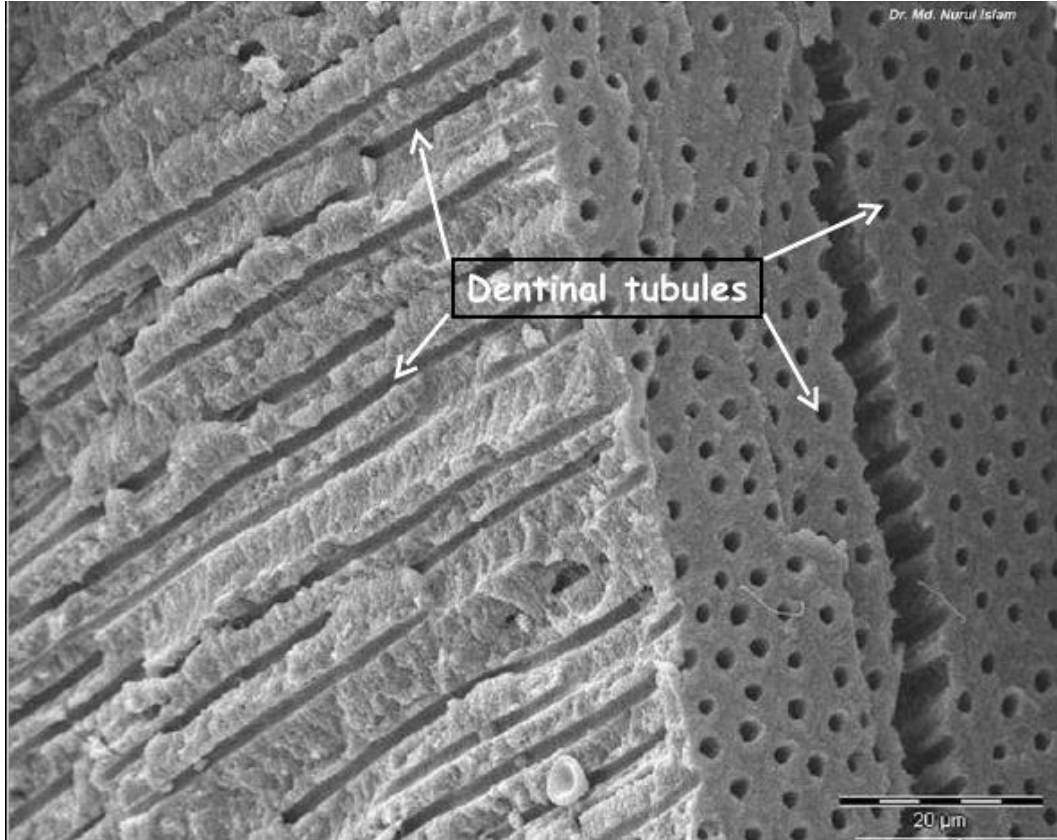
Dentin

- Odontoblasts
- Regenerates
- 70% Ca-hydroxyapatite
- Collagen I, glykoproteins, proteoglycans
- Odontoblast processes –Tomes' fibers
- Owen's lines
- Von Ebner's lines (incremental)
- Nerve fibers


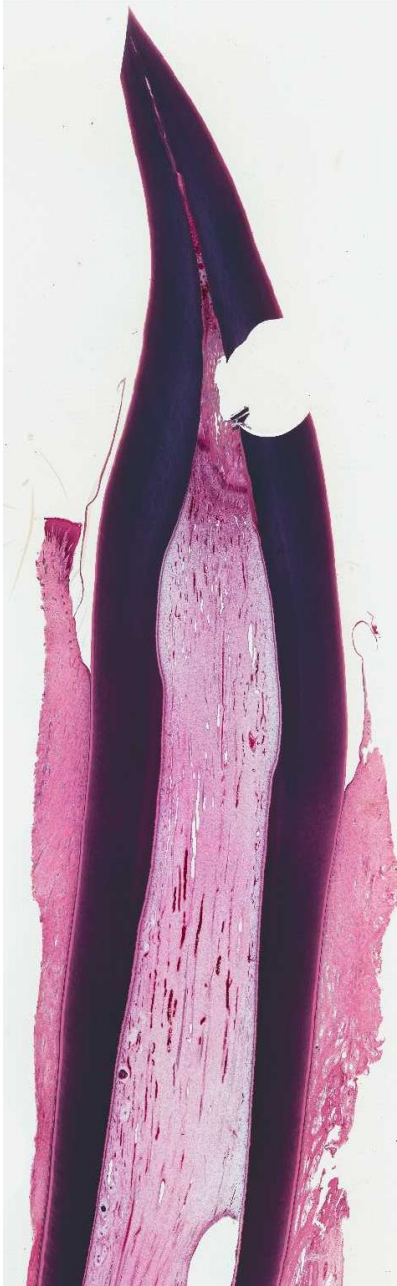
DENTIN



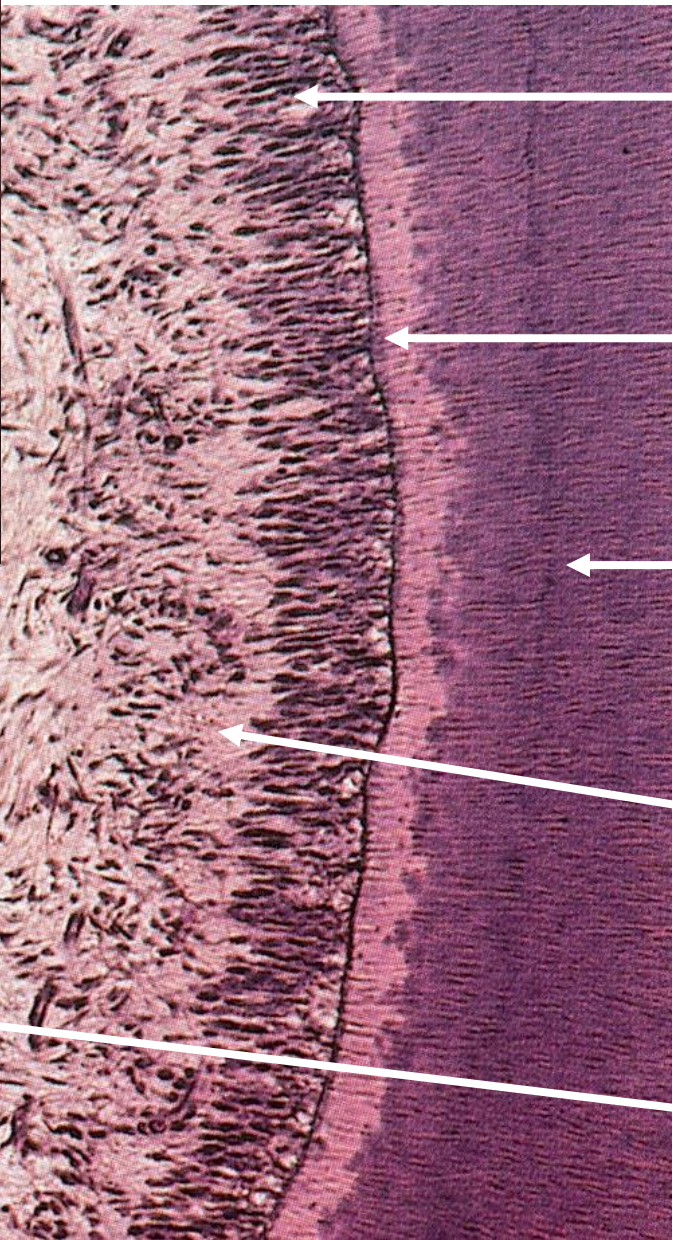

TOOTH – DENTIN



TOOTH – ODONTOBLASTS



TOOTH – ODONTOBLASTS



odontoblasts

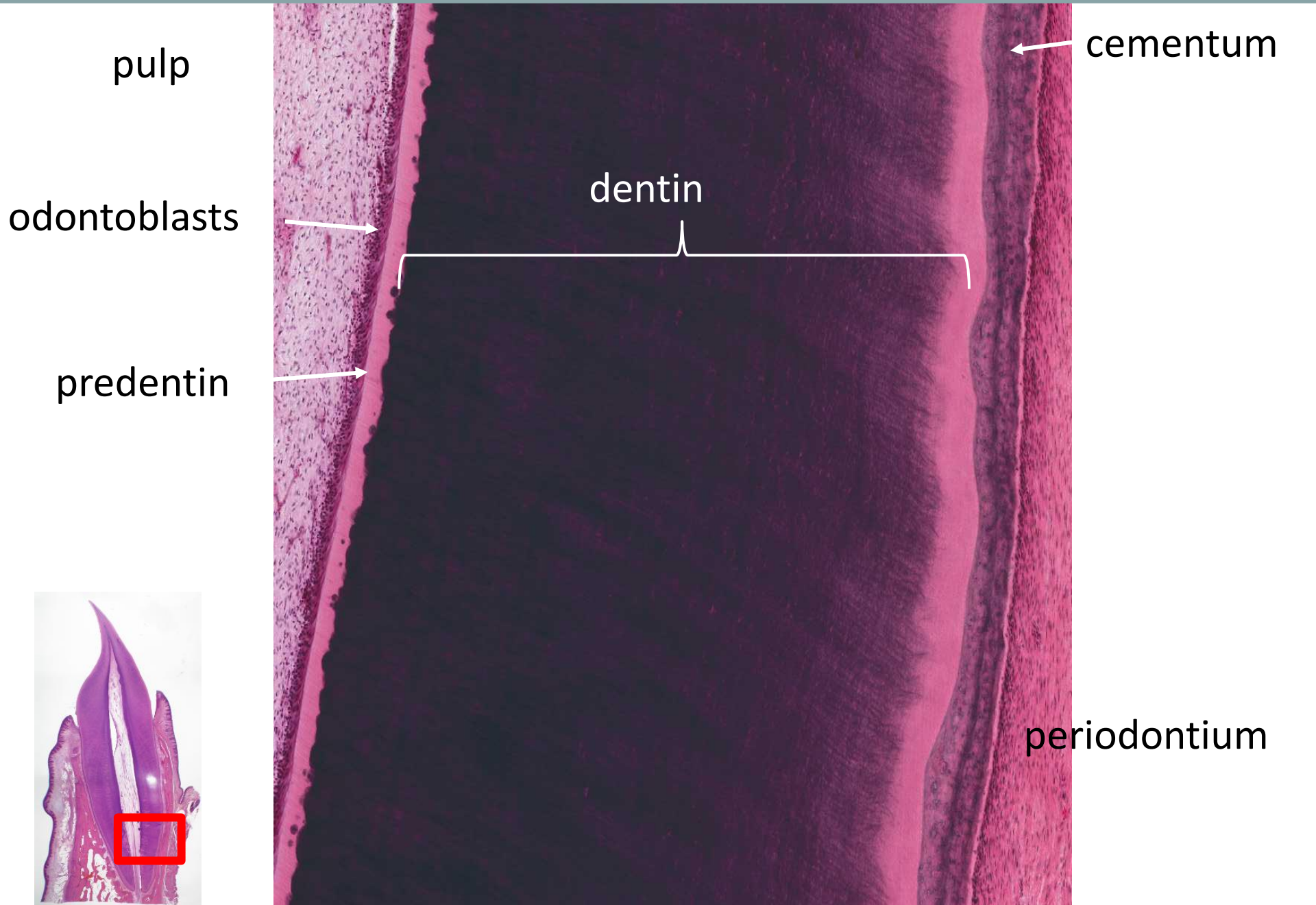
predentin

dentin

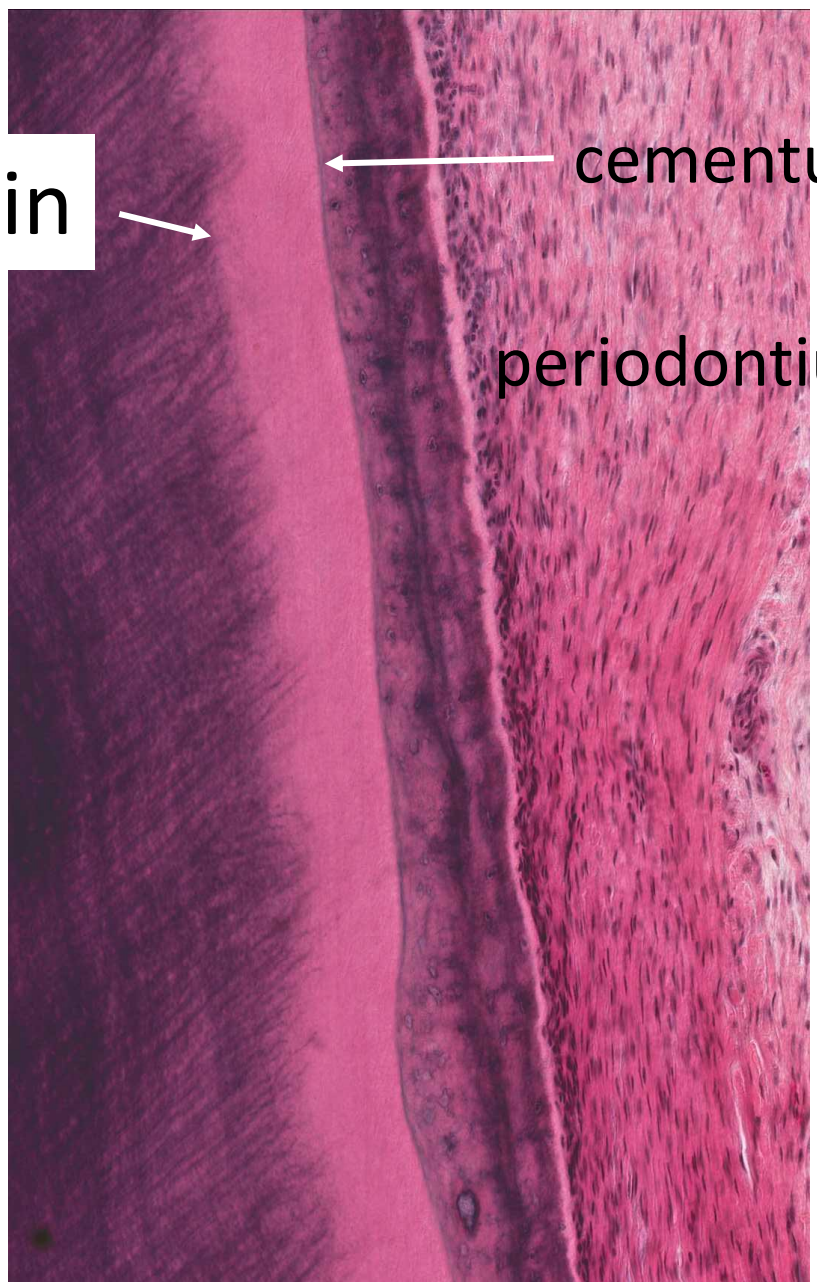
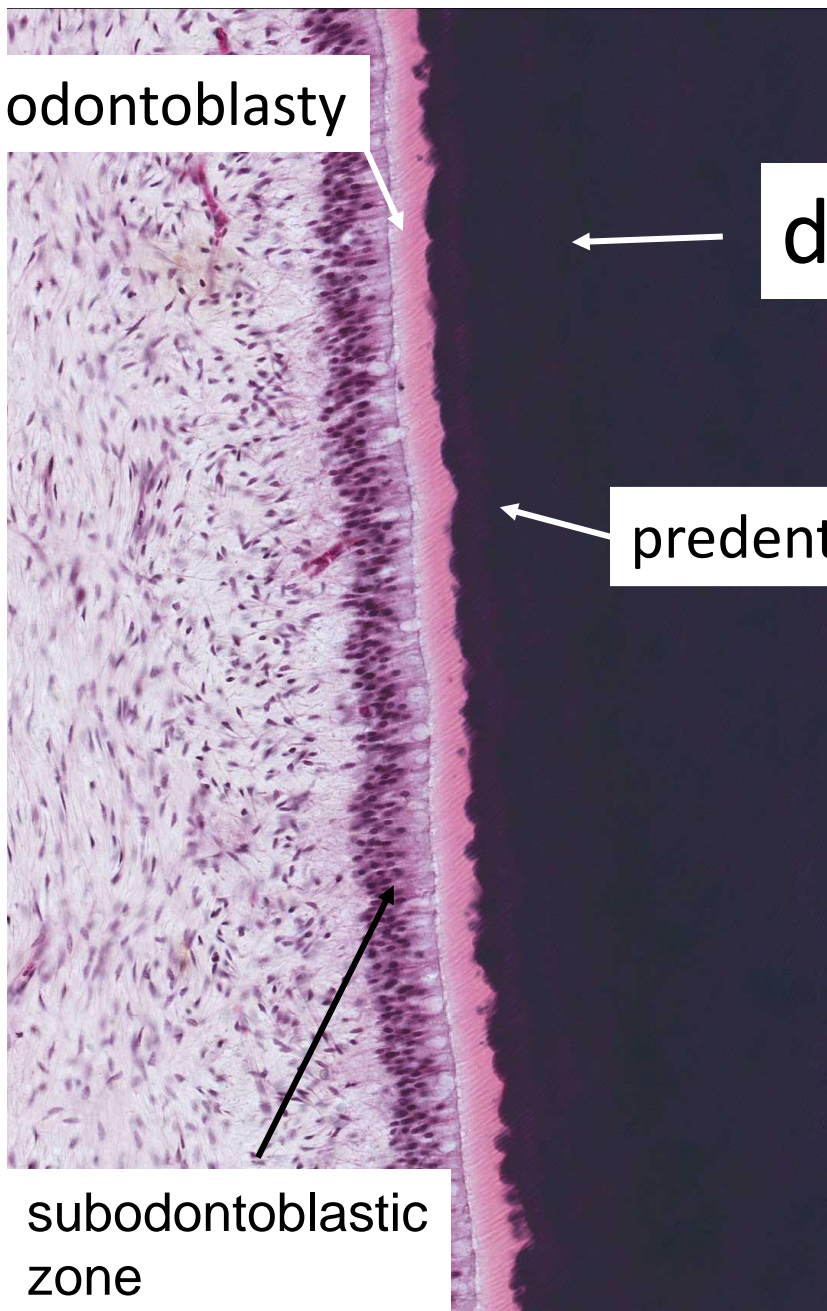
subodontoblastic zone

pulp

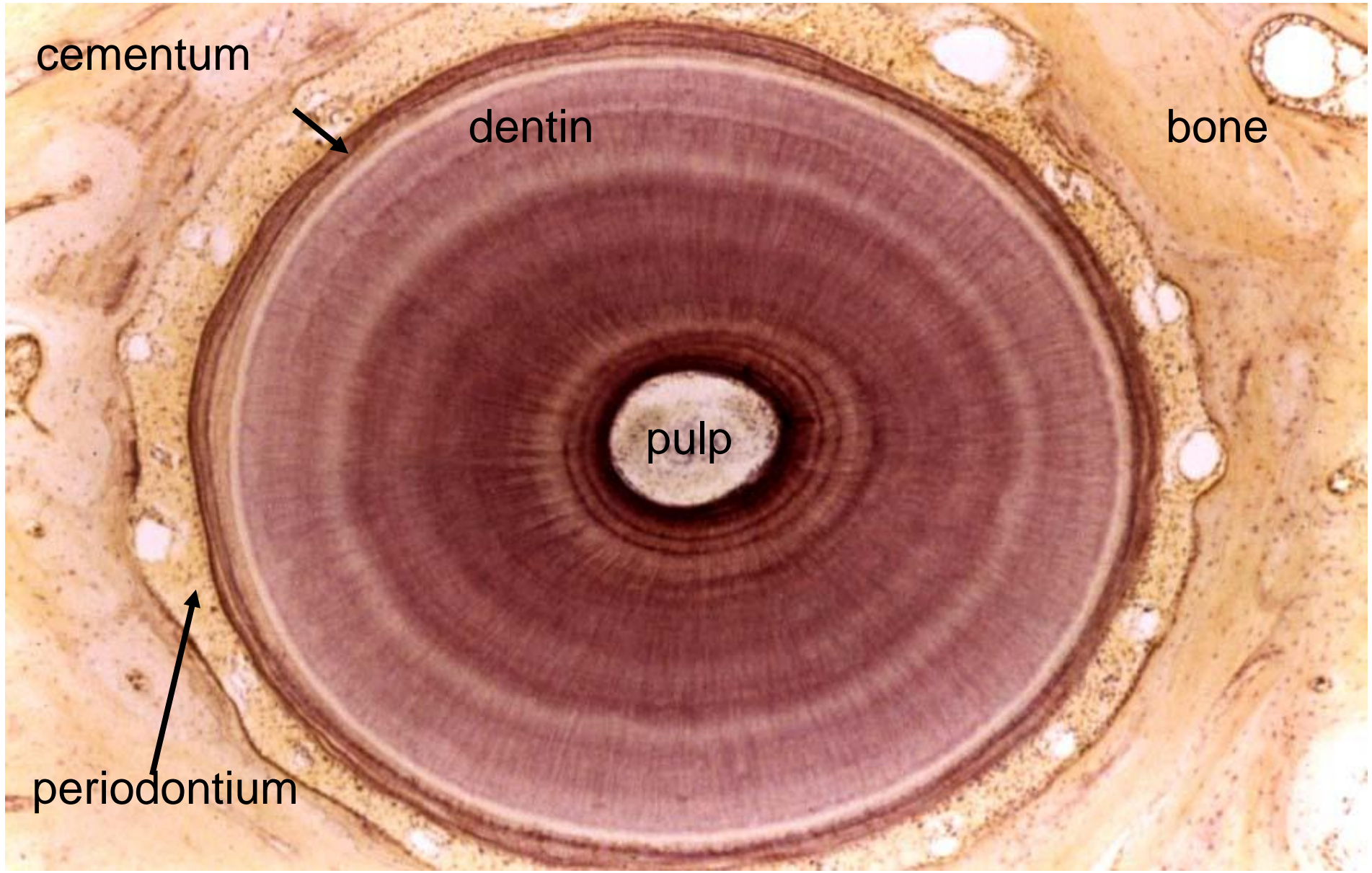
TOOTH – DENTIN



TOOTH



TOOTH



cementum



dentin

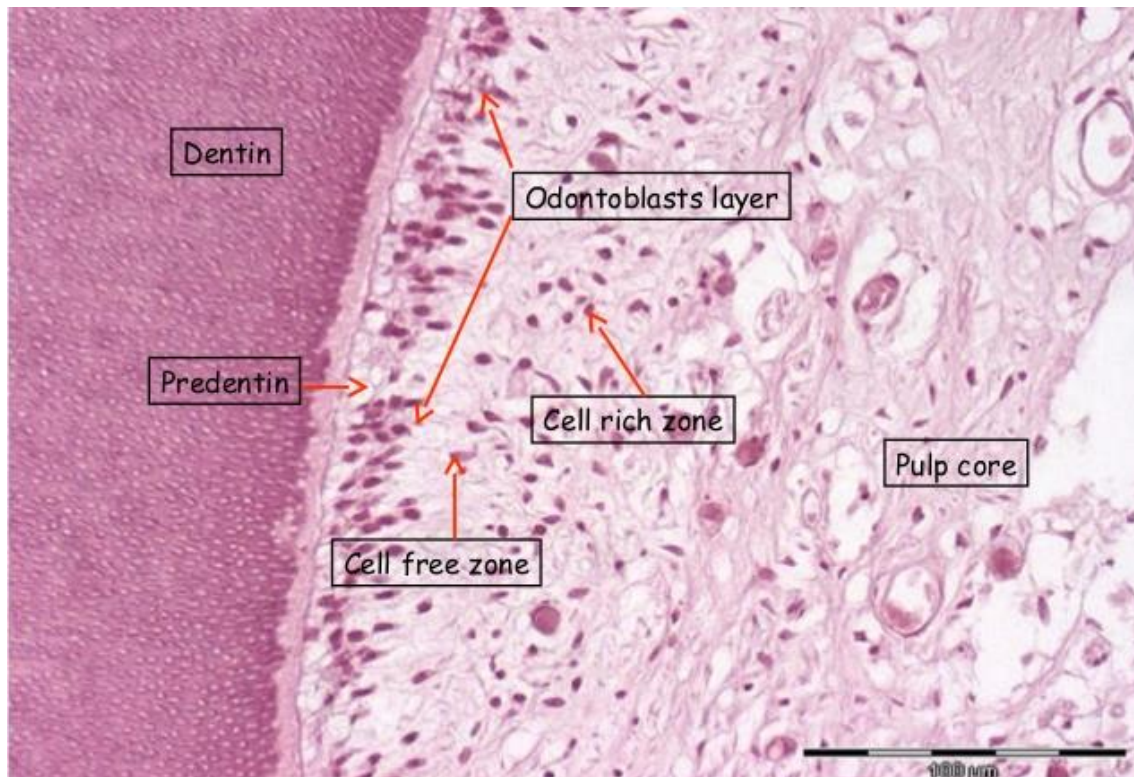
bone

pulp

periodontium

TOOTH – PULP

- soft connective tissue similar to embryonic mesenchyme
- rich vascularisation and innervation
- crown pulp and root canal
- foramen apicale - periodontium
- odontoblasts
- nociceptive nerve plexus (plexus Raschkowi)

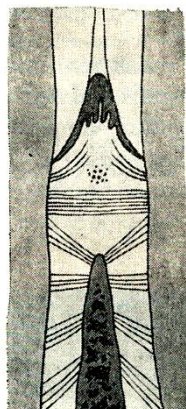
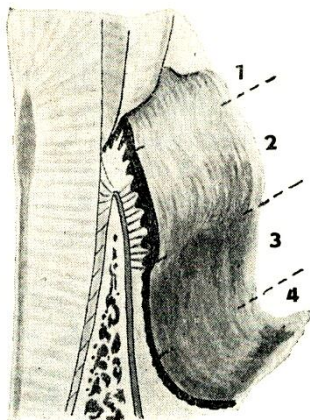
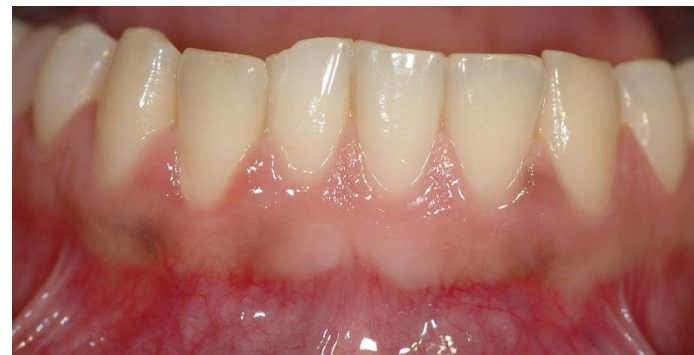

<https://www.slideshare.net/hesham63/pulp-15597098>

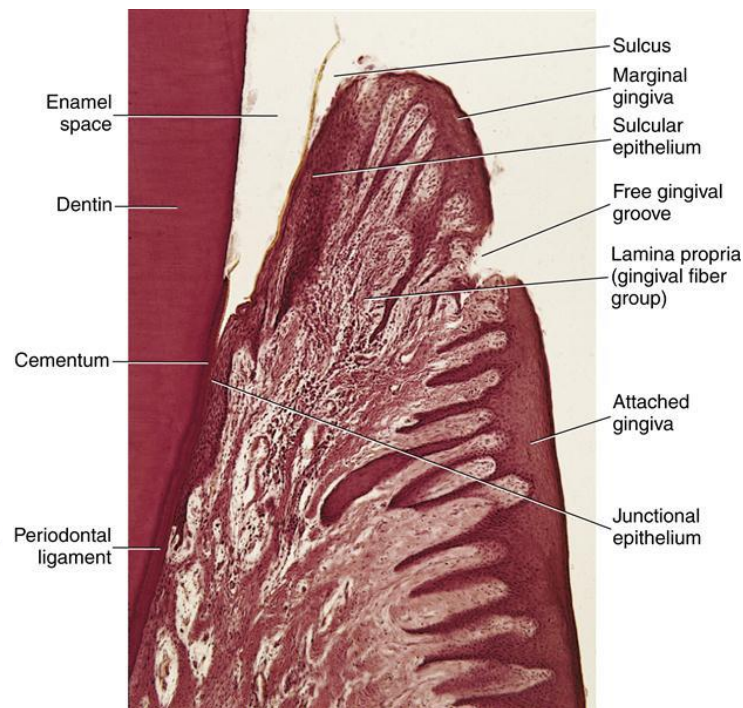
TOOTH – PERIODONTIUM AND GINGIVA

Gingiva

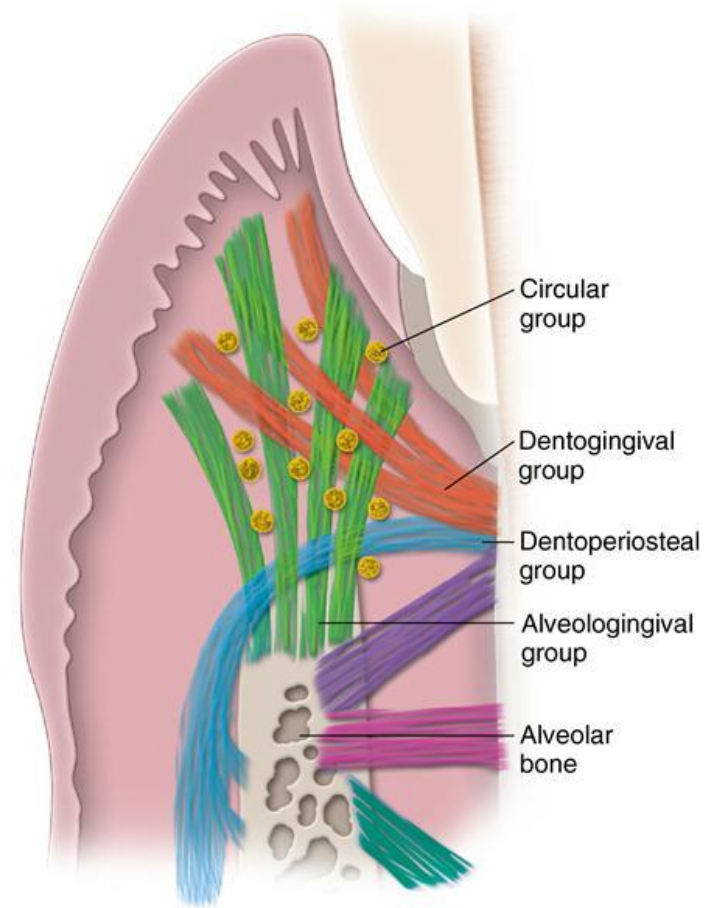
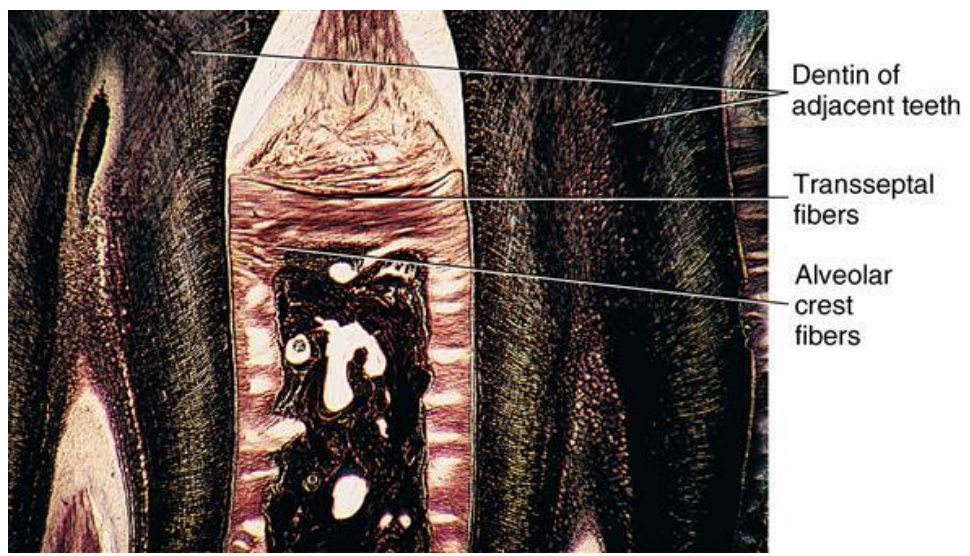
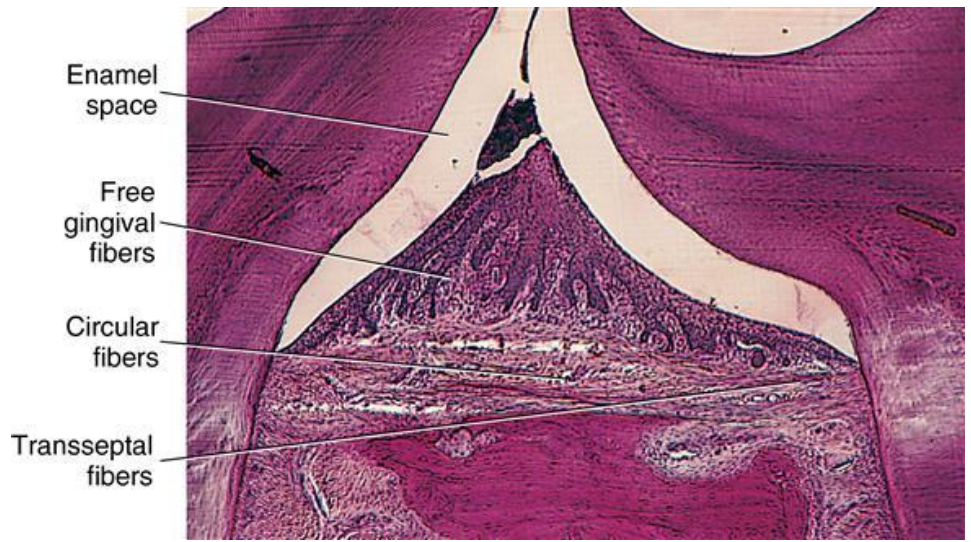
- free (marginal, g. libera)
 - attached (g. affixa)
 - paramarginal groove (outer gingival groove)
 - sulcus gingivalis
 - gingivodental junction of Gotlieb
-
- stratified squamous epithelium
 - lamina propria mucosae – dense collagen c.t.



Obr. 8. Schéma gingivy. 1 — volná gingiva, 2 — připojená gingiva, 3 — alveolární sliznice, 4 — vestibulární sliznice

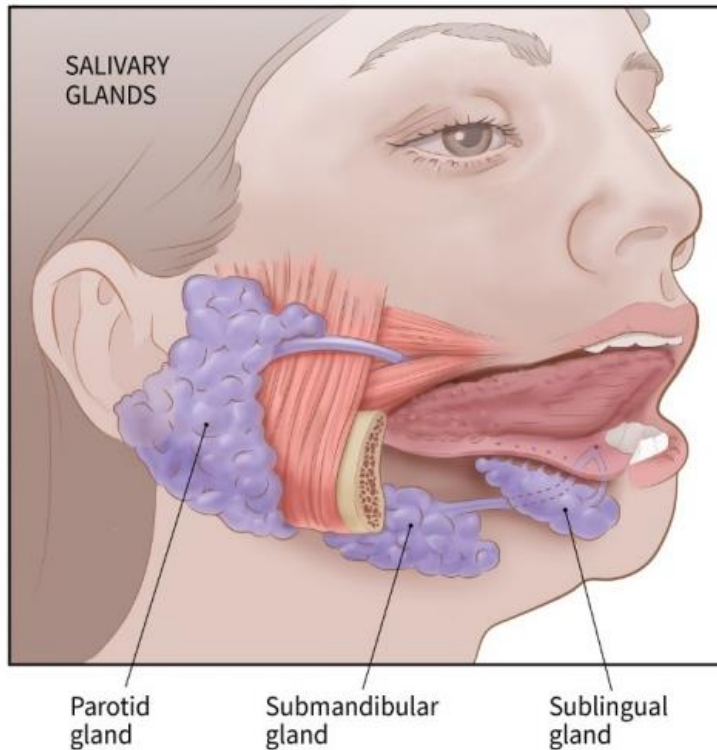


TOOTH – PERIODONTIUM AND GINGIVA



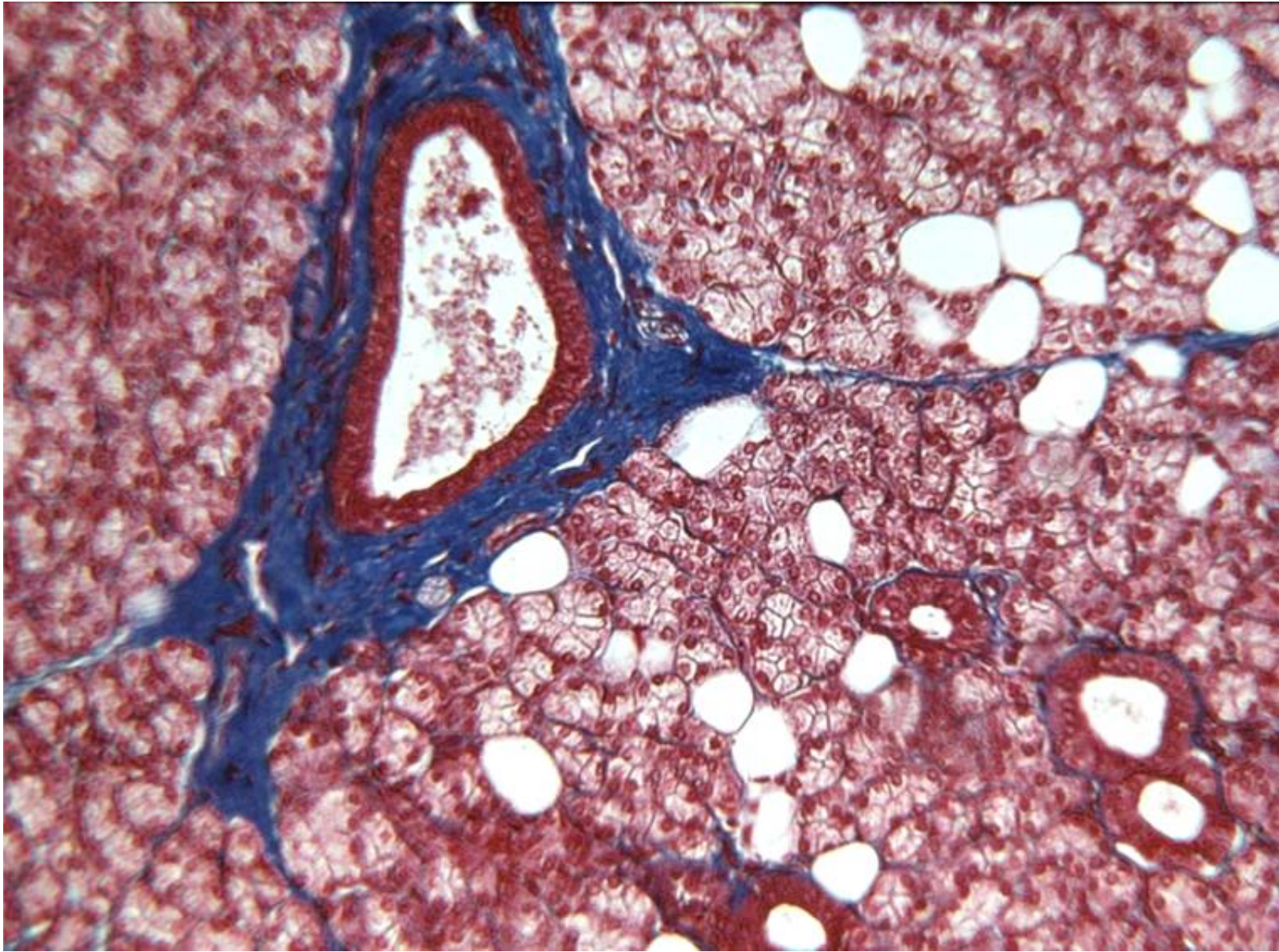
SALIVARY GLANDS

- small (gl. labiales, buccales, retromolares, palatinae, gl. lingualis anterior, gl. Ebneri, gl. Weberi)
- large (gl. parotis, gl. submandibularis, gl. sublingualis)

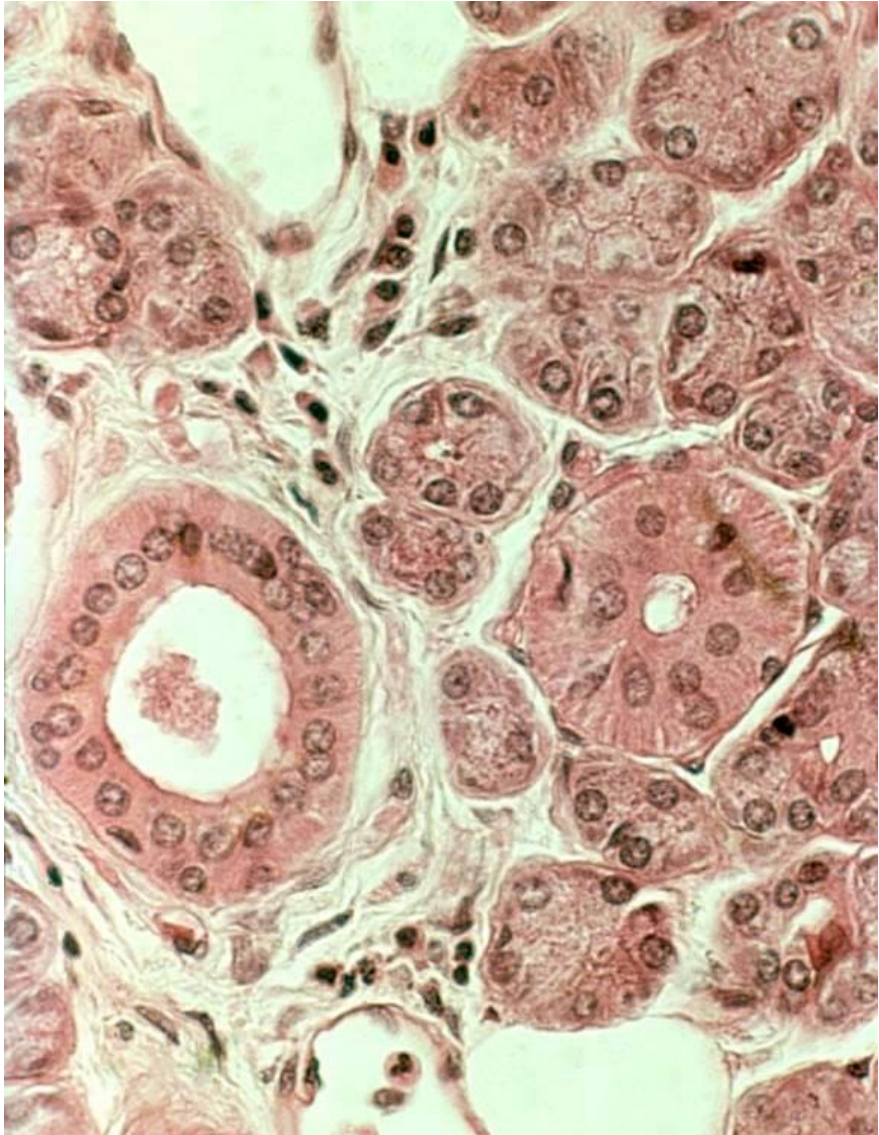
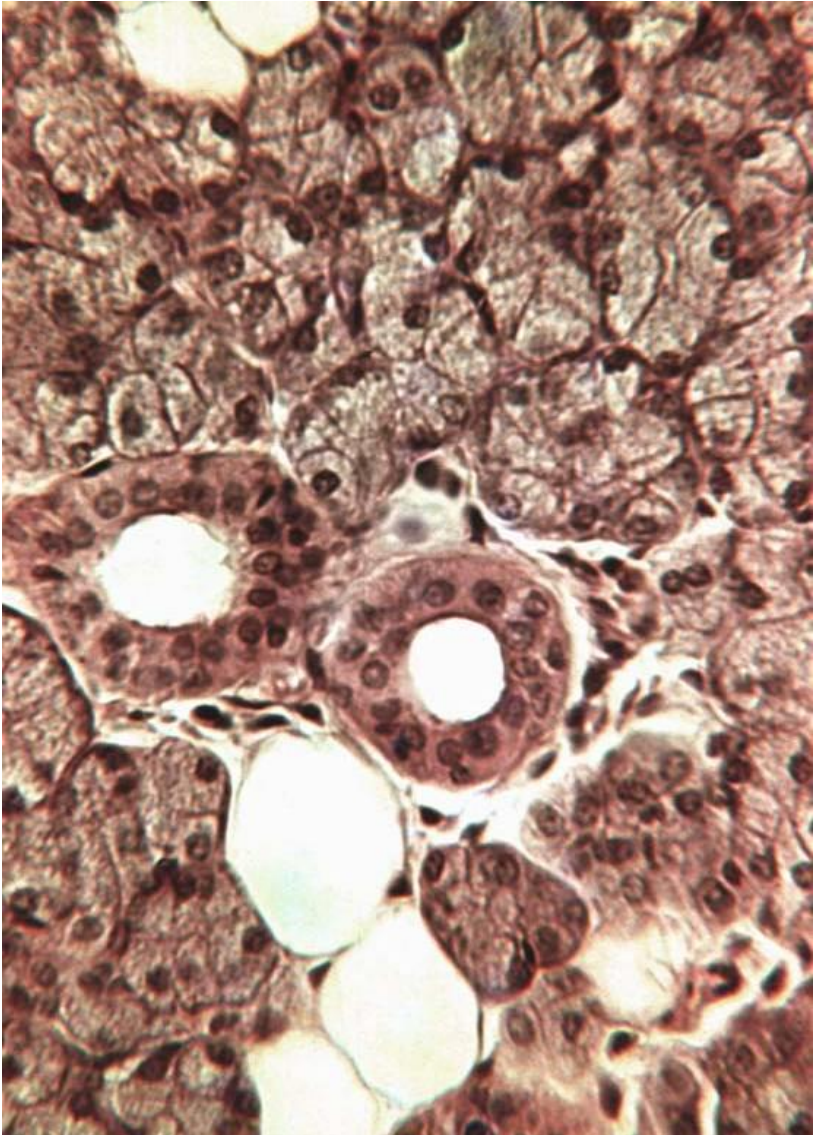


see GIT 3

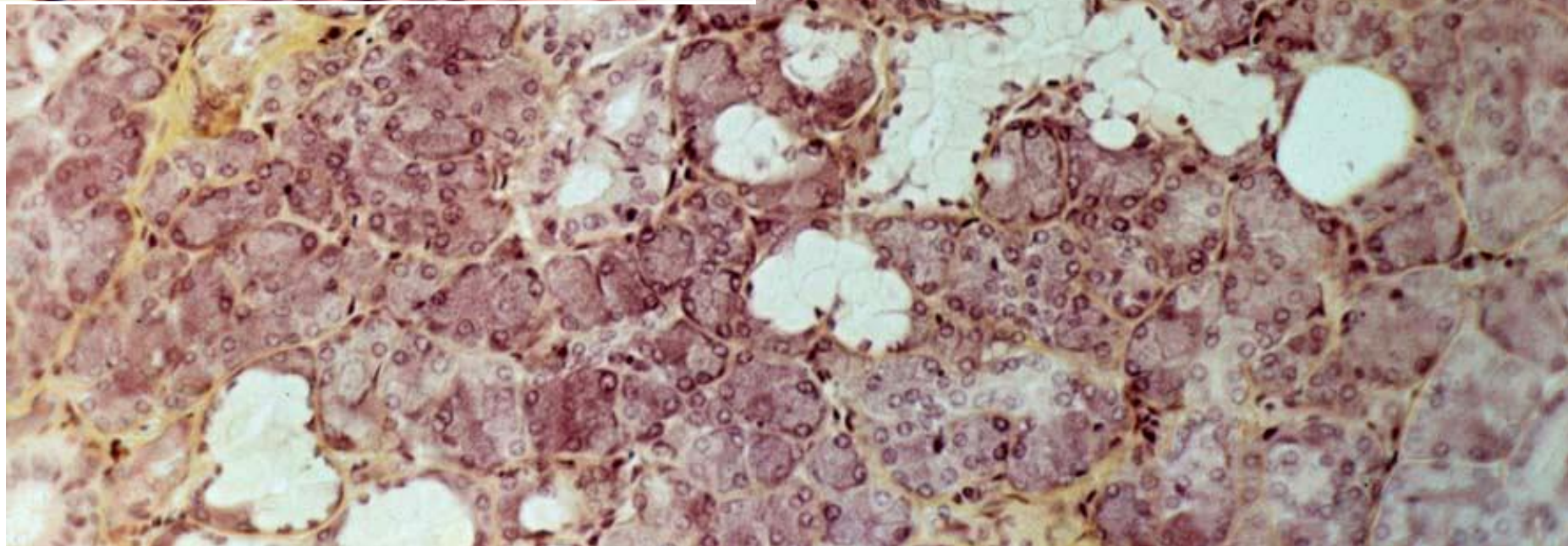
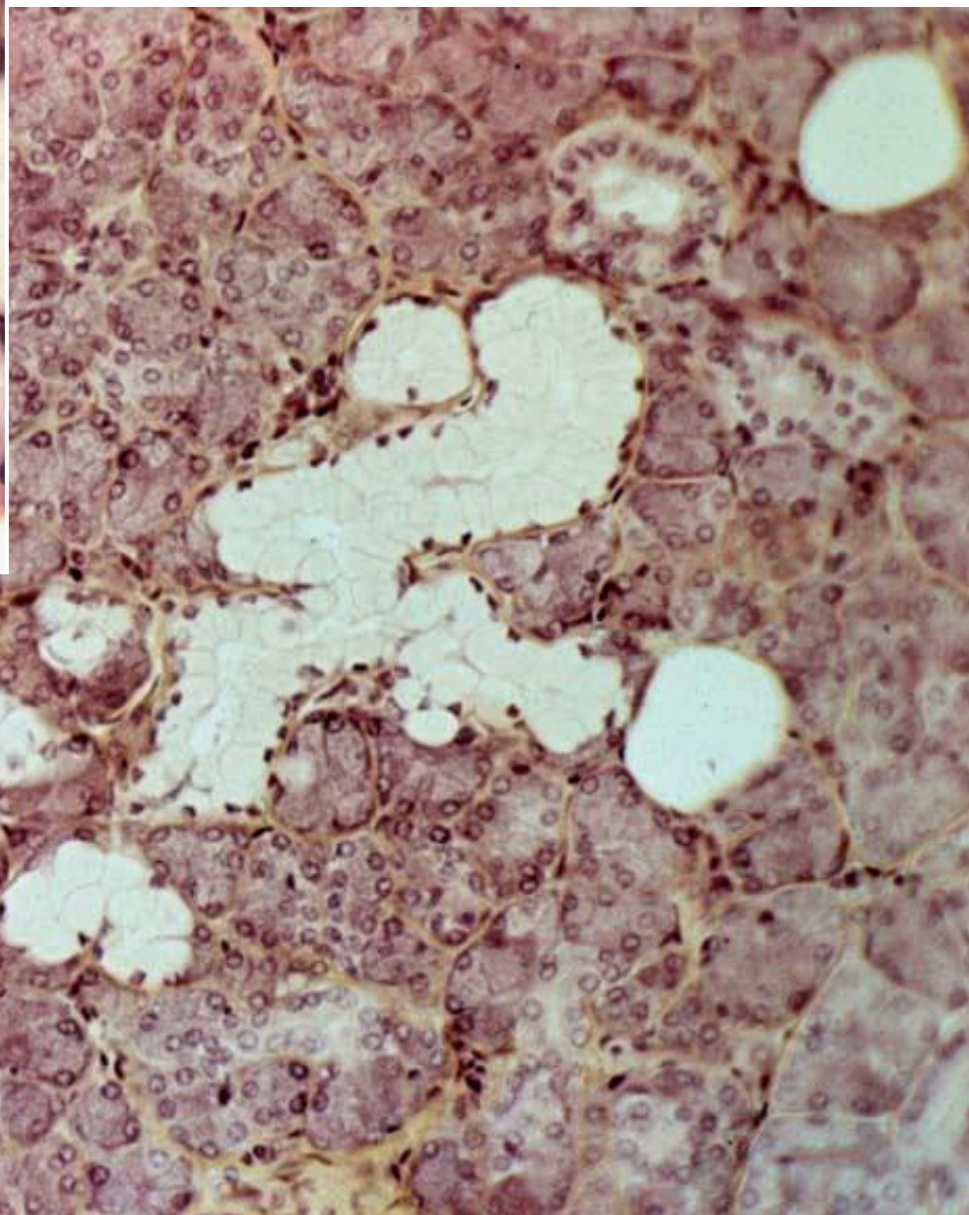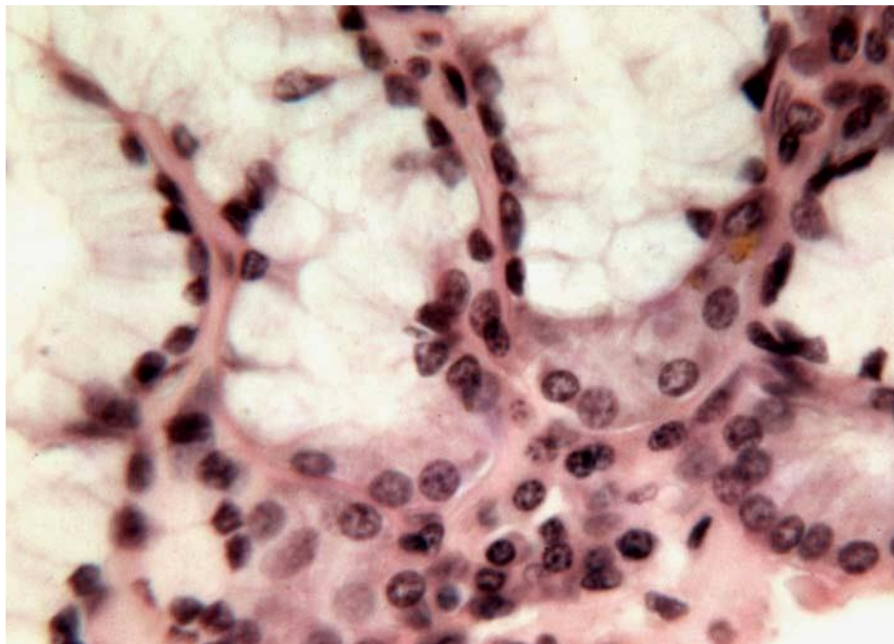
SALIVARY GLANDS – GL. PAROTIS



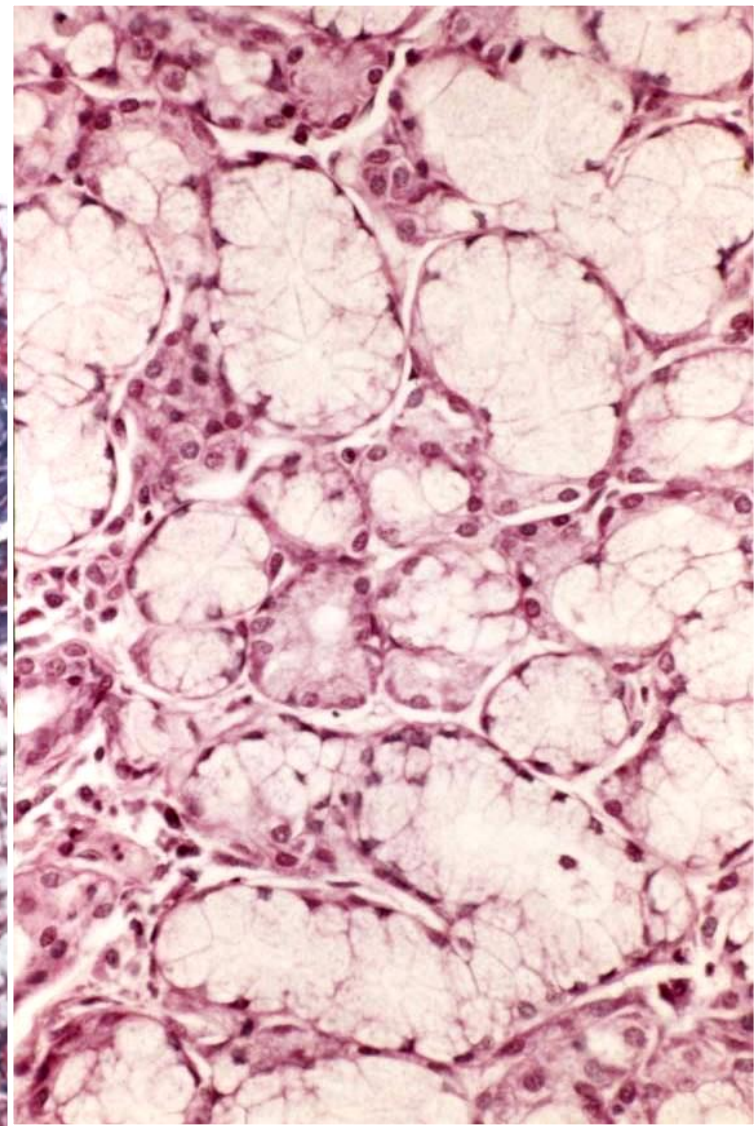
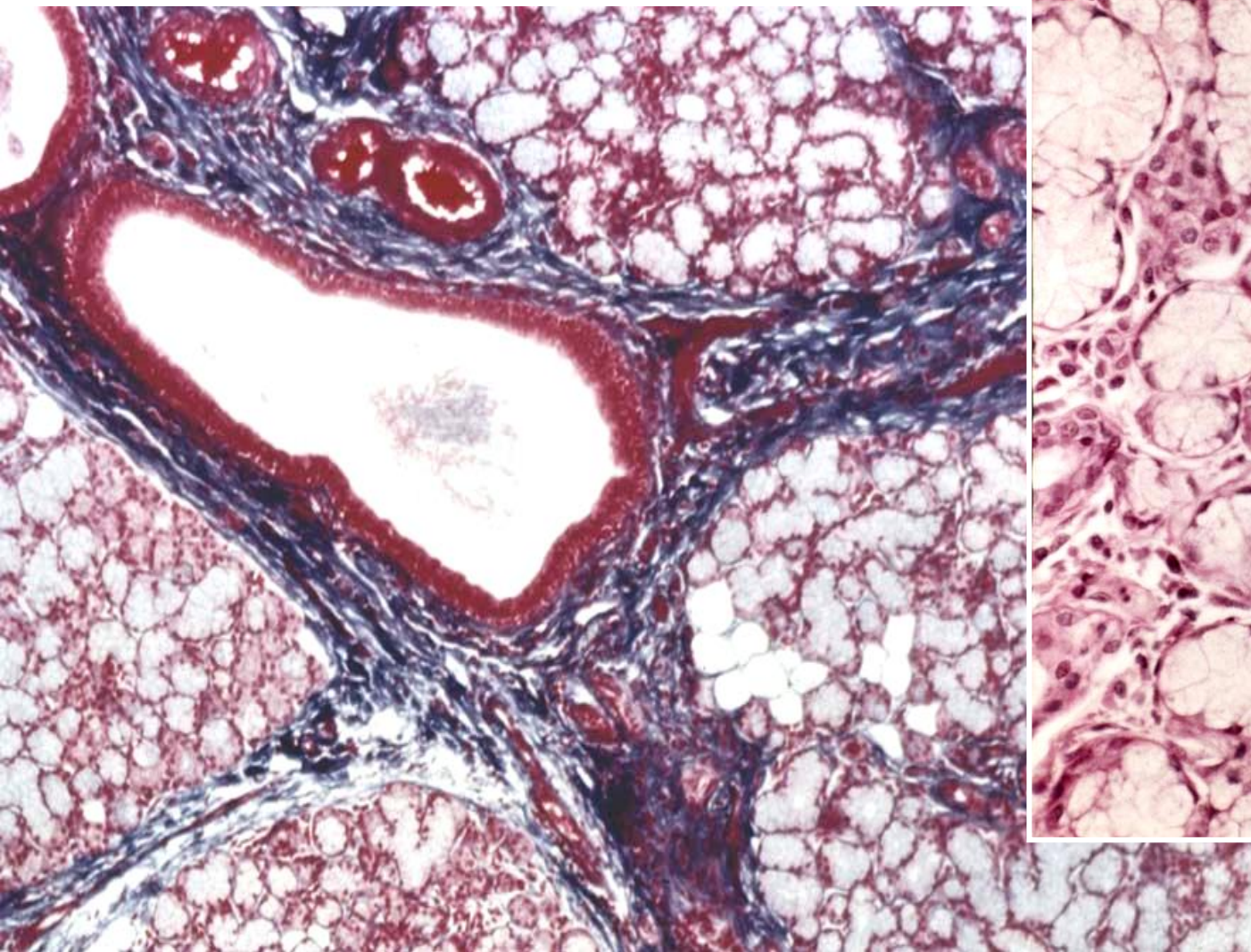
SALIVARY GLANDS – GL. PAROTIS



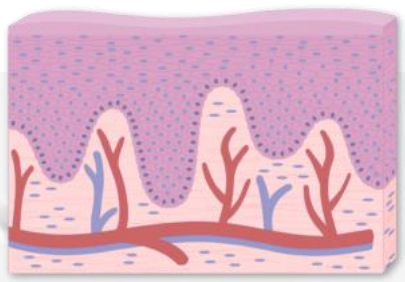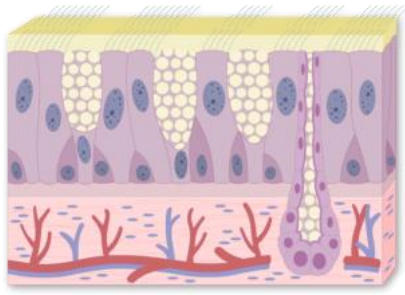
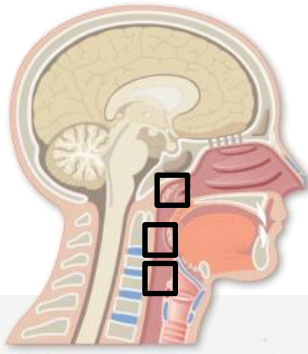
SALIVARY GLANDS – GL. SUBMANDIBULARIS



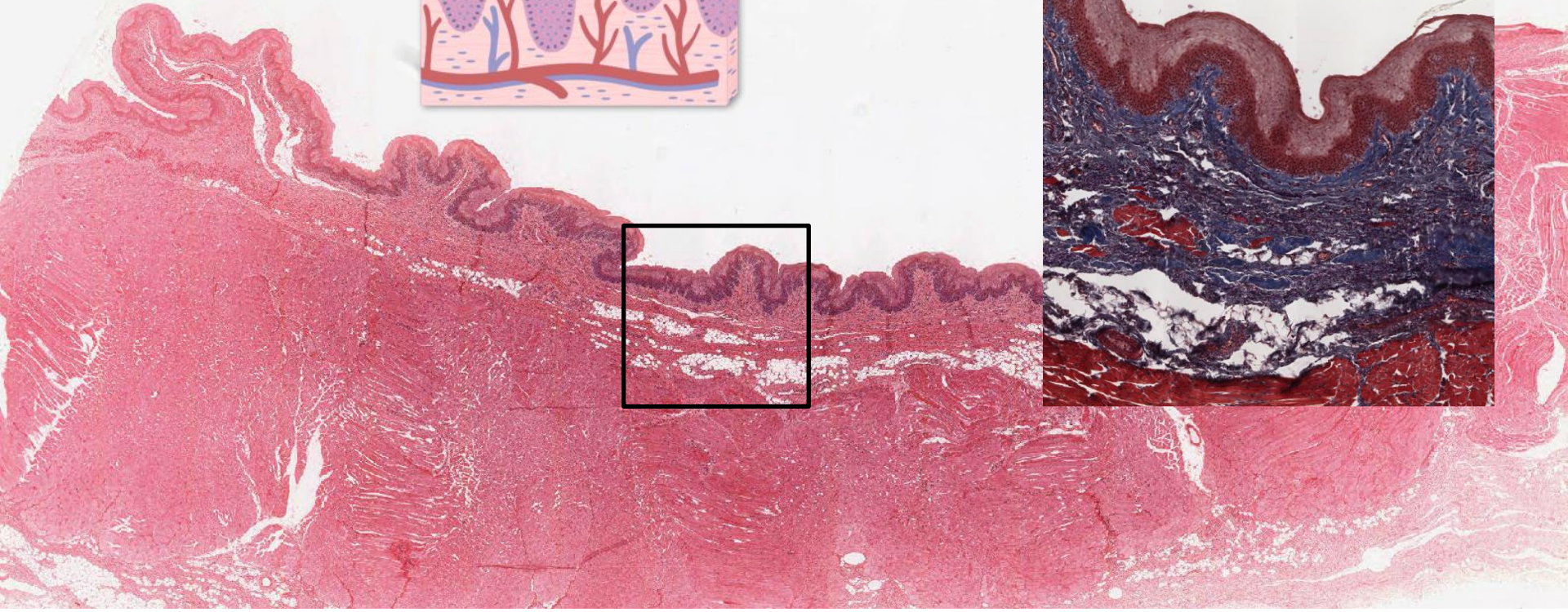
SALIVARY GLANDS – GL. SUBLINGUALIS



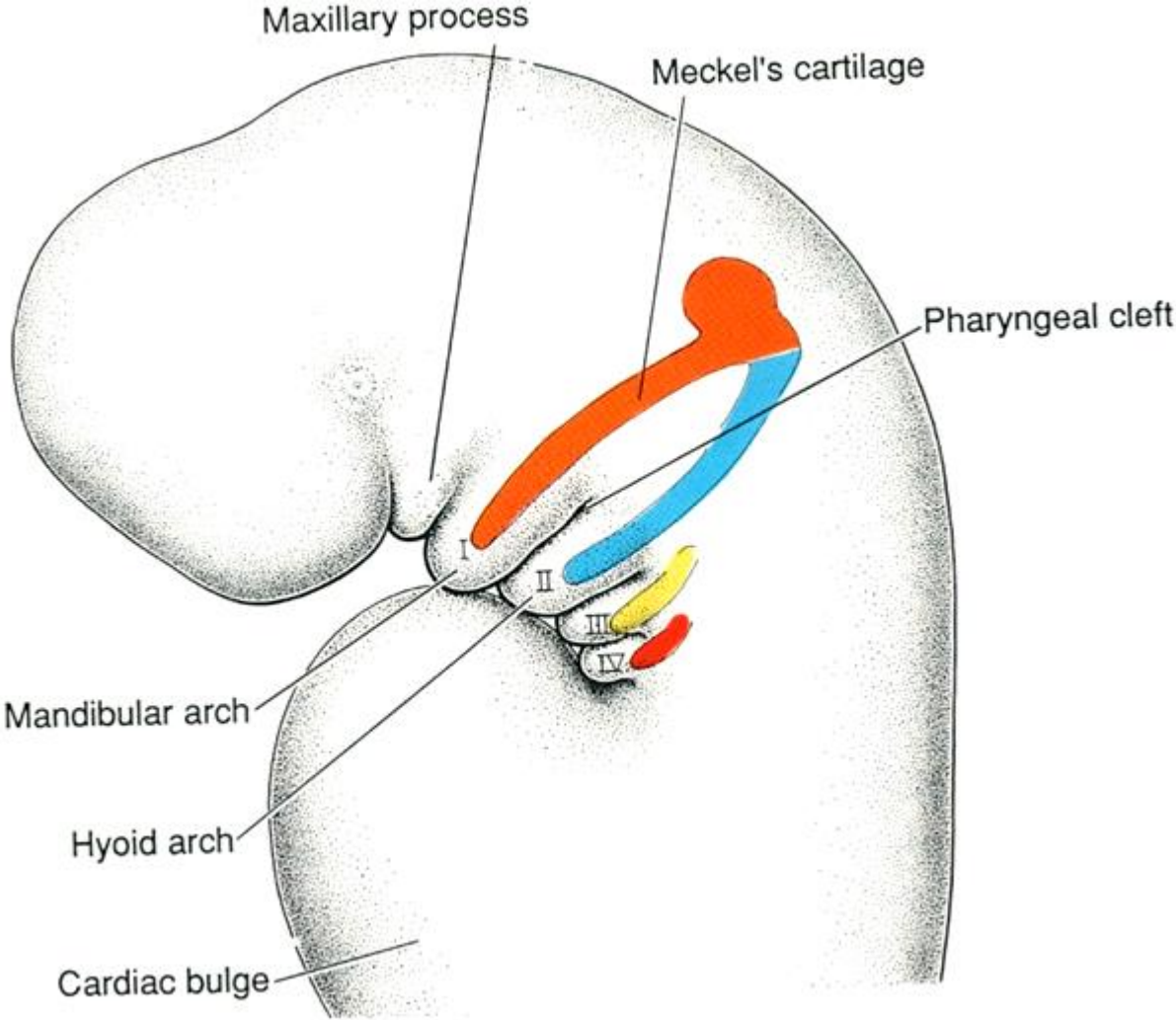
PHARYNX



- nasopharynx
- oropharynx
- laryngopharynx

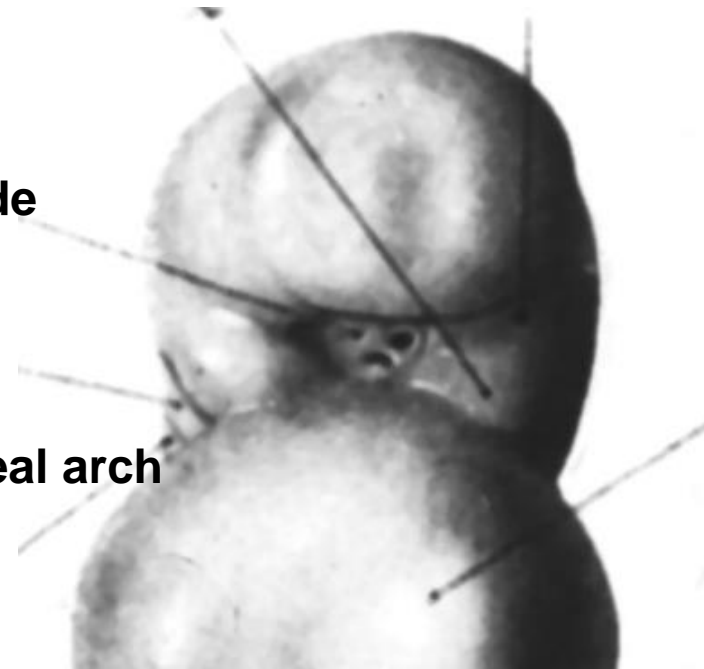
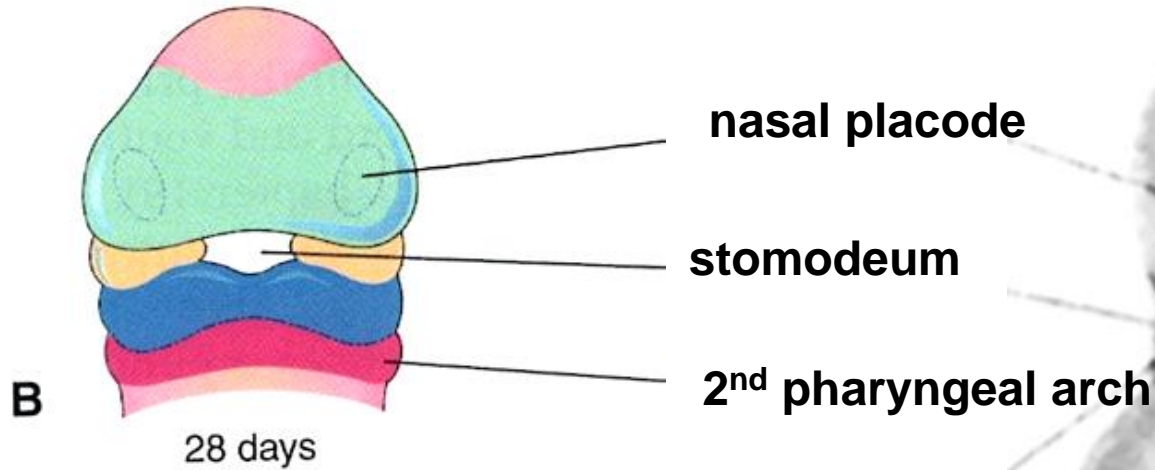
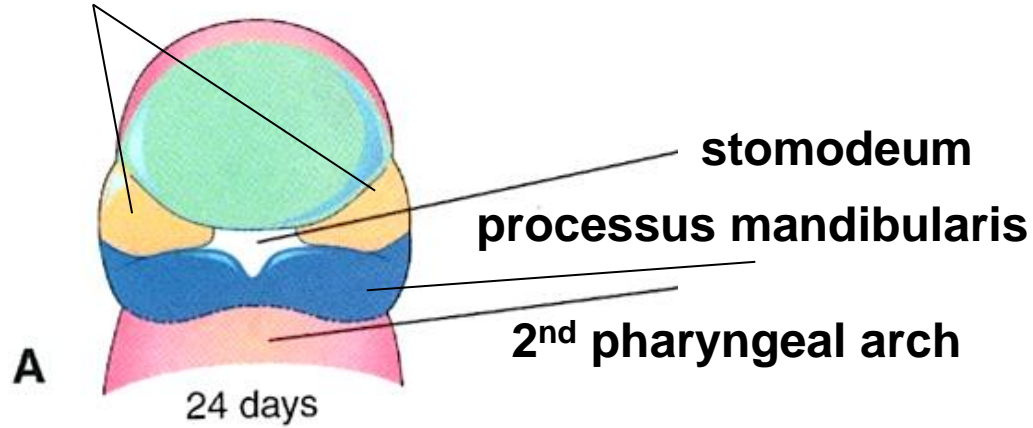


DEVELOPMENT OF FACE



DEVELOPMENT OF FACE

processus maxillares

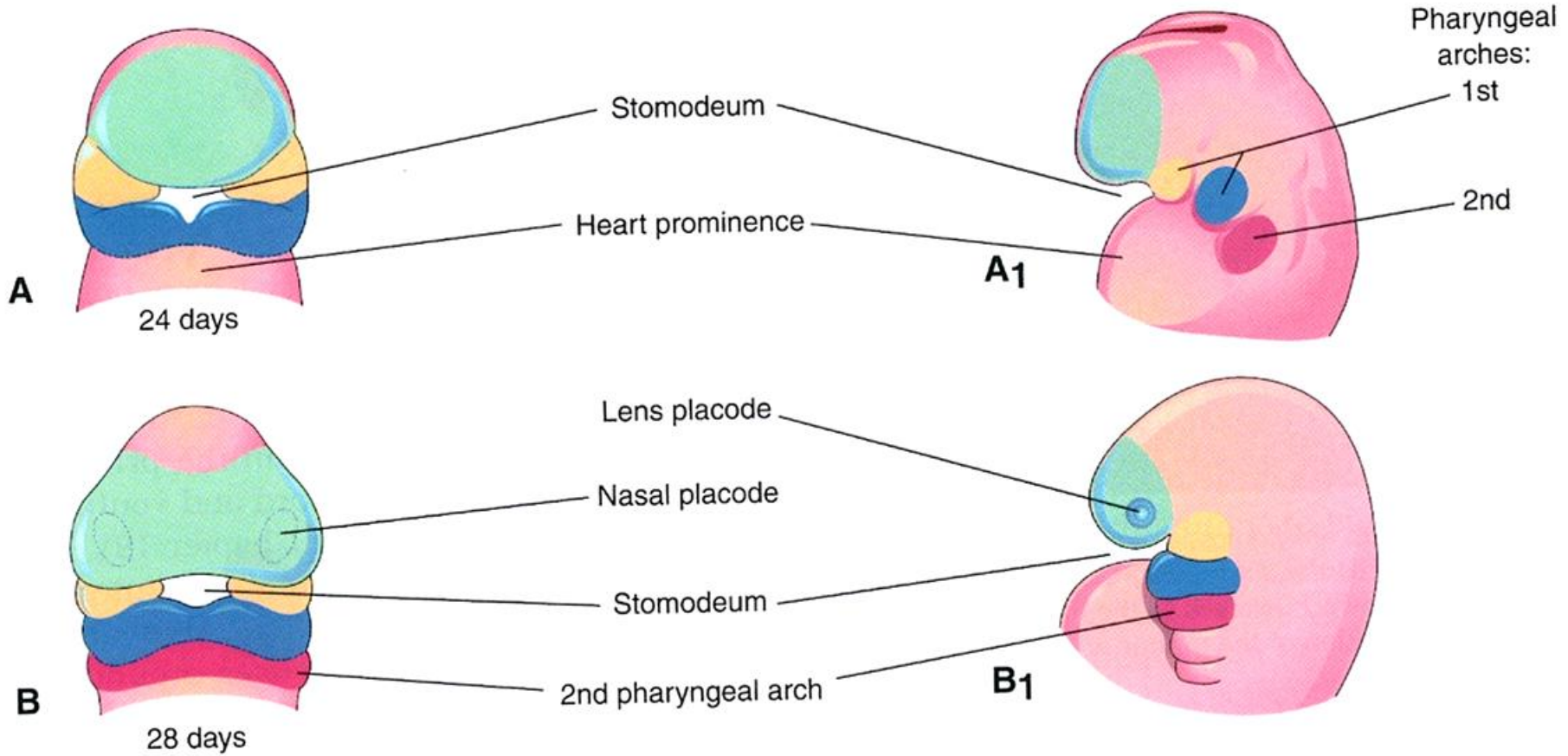


DEVELOPMENT OF FACE

Frontonasal prominence

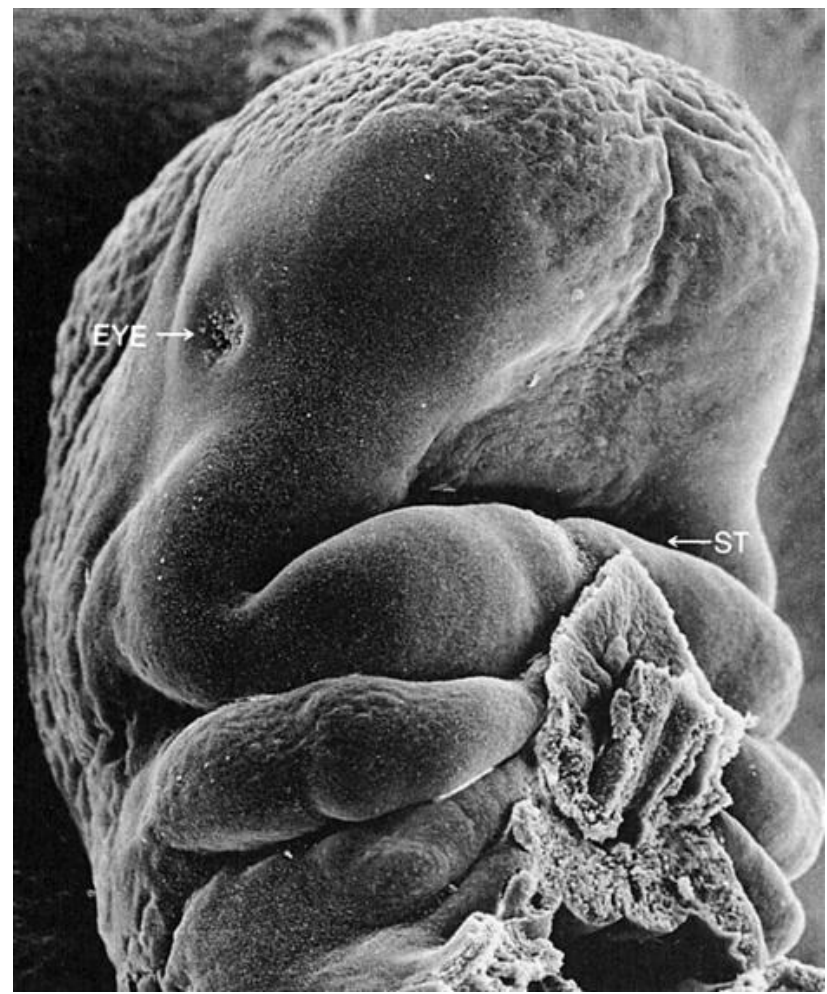
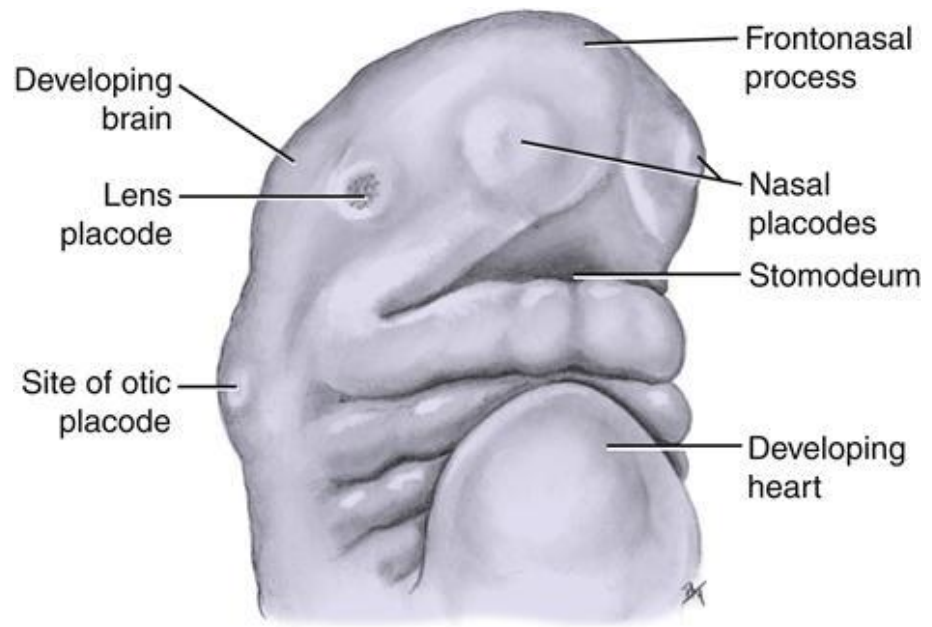
Maxillary prominence

Mandibular prominence

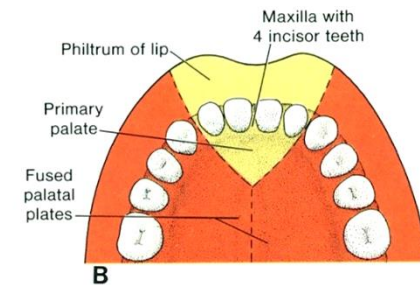
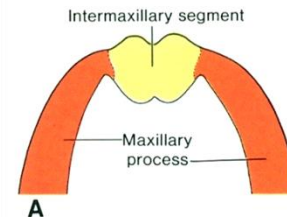
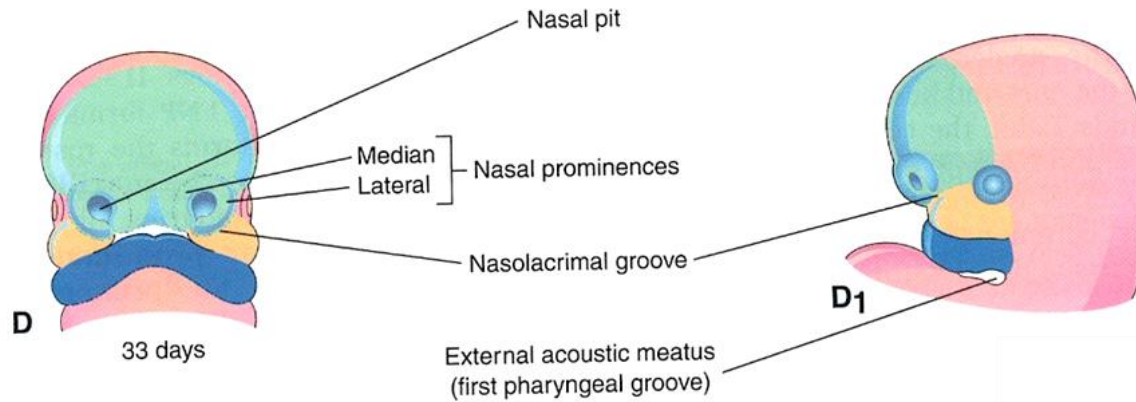
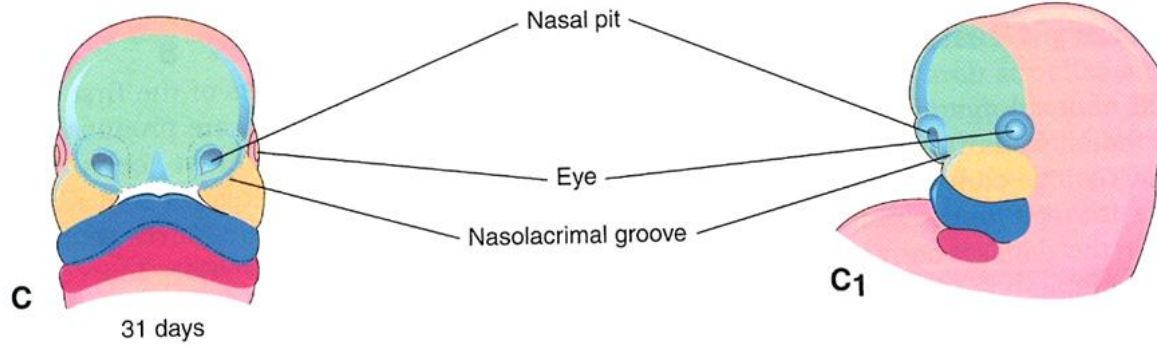


DEVELOPMENT OF FACE

4th week

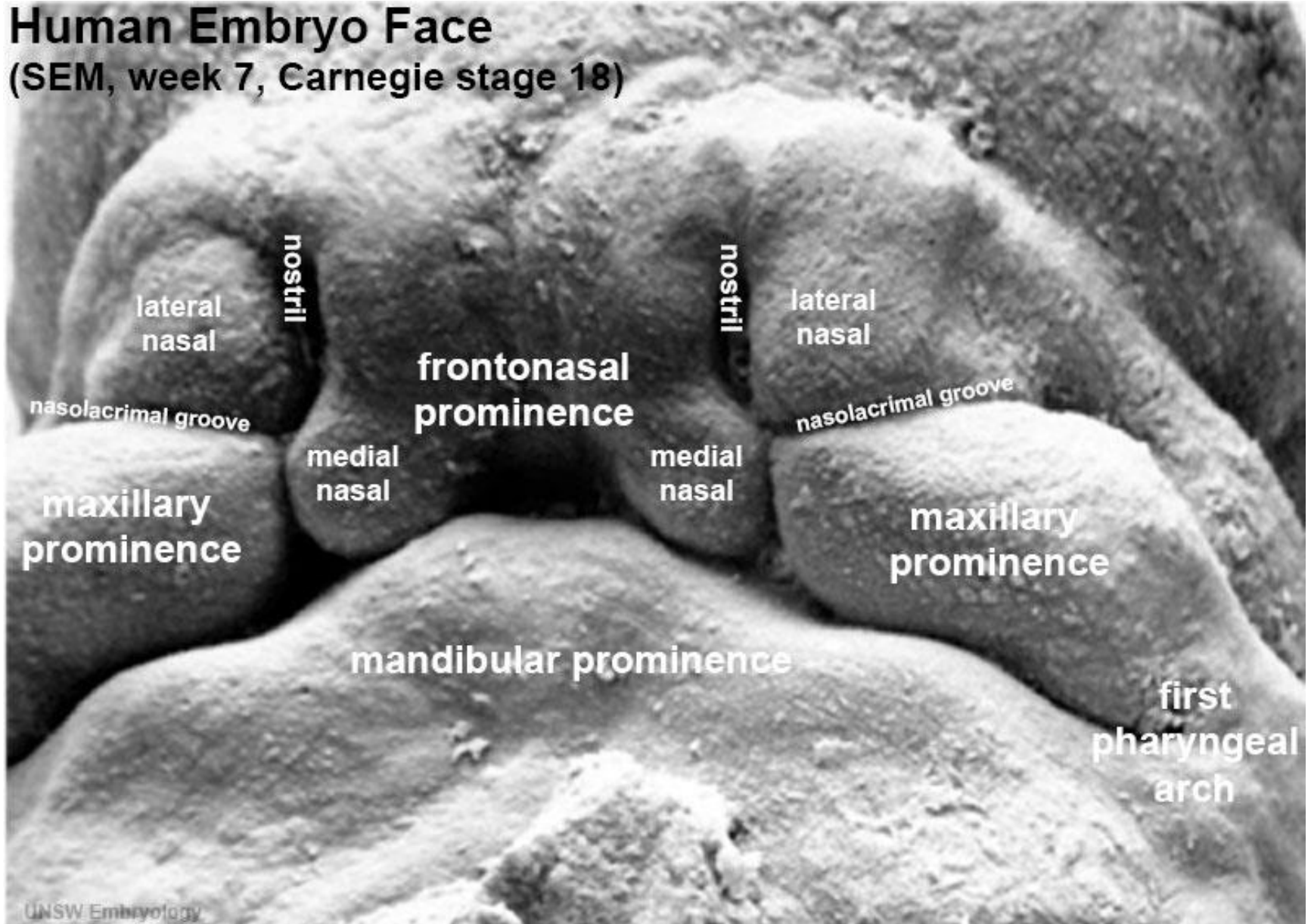


DEVELOPMENT OF FACE

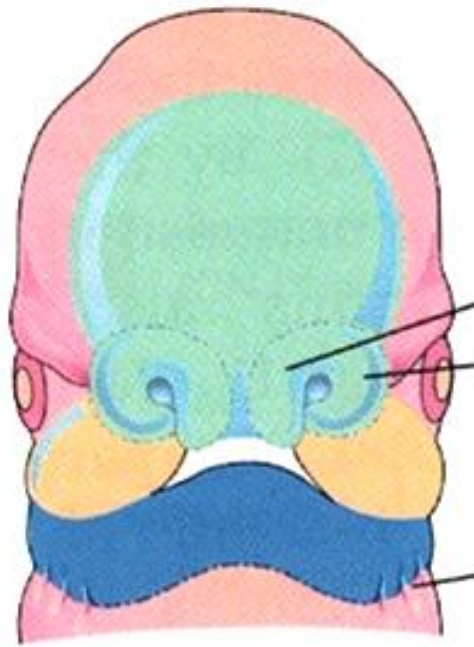


- nasal pits surrounded by paired prominences – **medial and lateral nasal prominence**
- **area triangularis** (nose)
- **intermaxillary segment** (medial part of upper lip, part of upper jaw, primary palate)

Human Embryo Face (SEM, week 7, Carnegie stage 18)

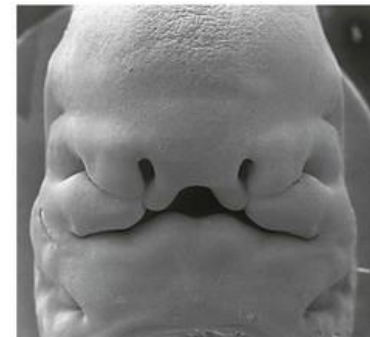
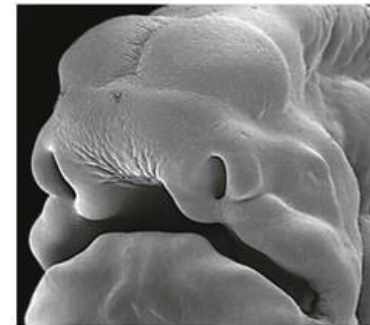
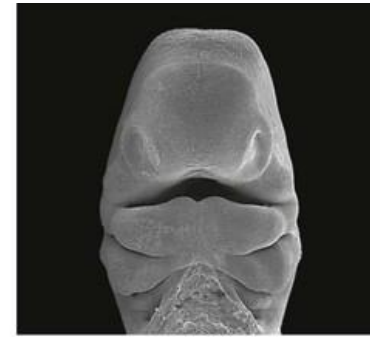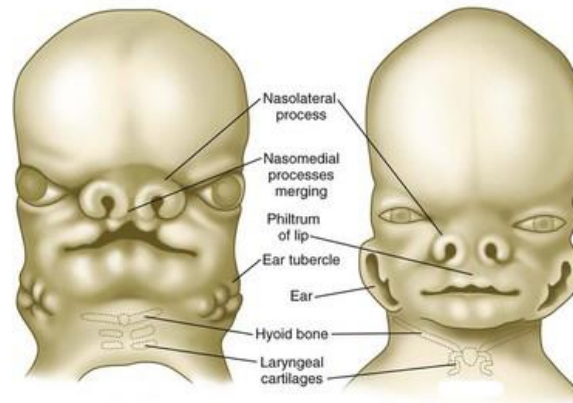
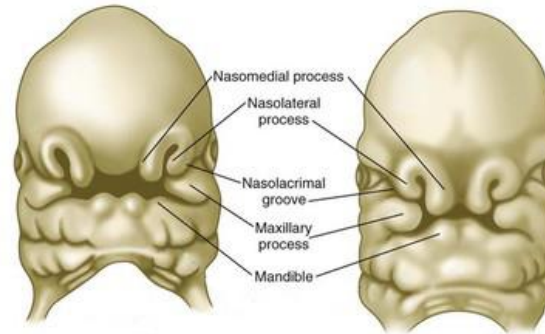
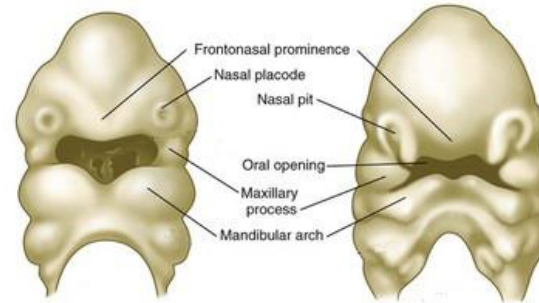


DEVELOPMENT OF FACE



35 days

- maxillary prominences fuse with
 1. intermaxillary segment
 2. lateral nasal prominences
- sulcus nasolacrimalis



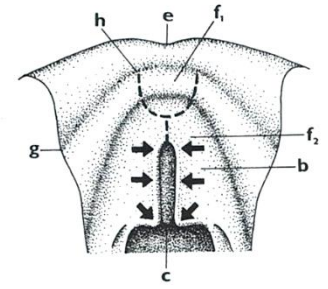
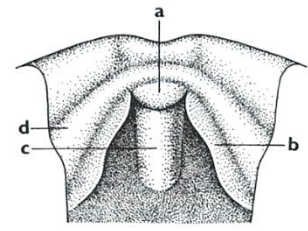
DEVELOPMENT OF FACE



<http://www.youtube.com/watch?v=4LQJIf0XLP0>

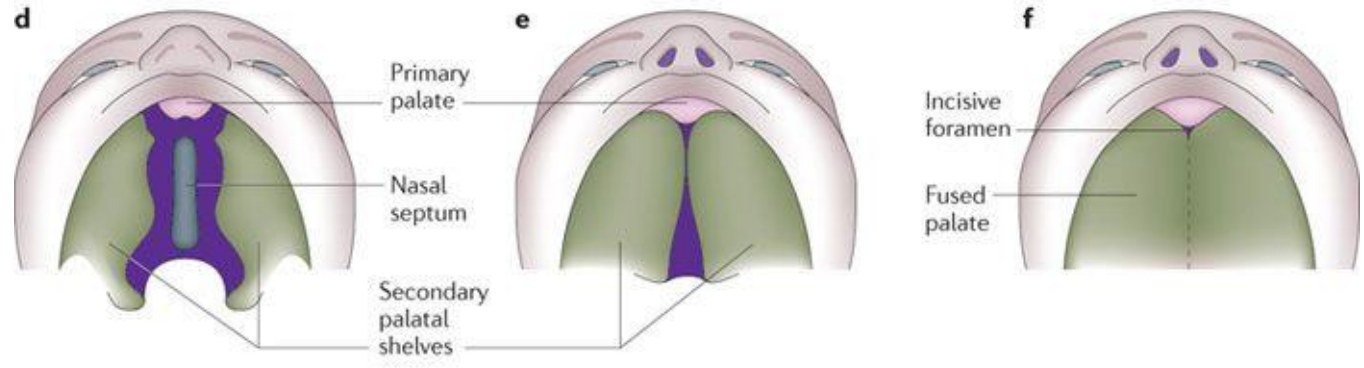
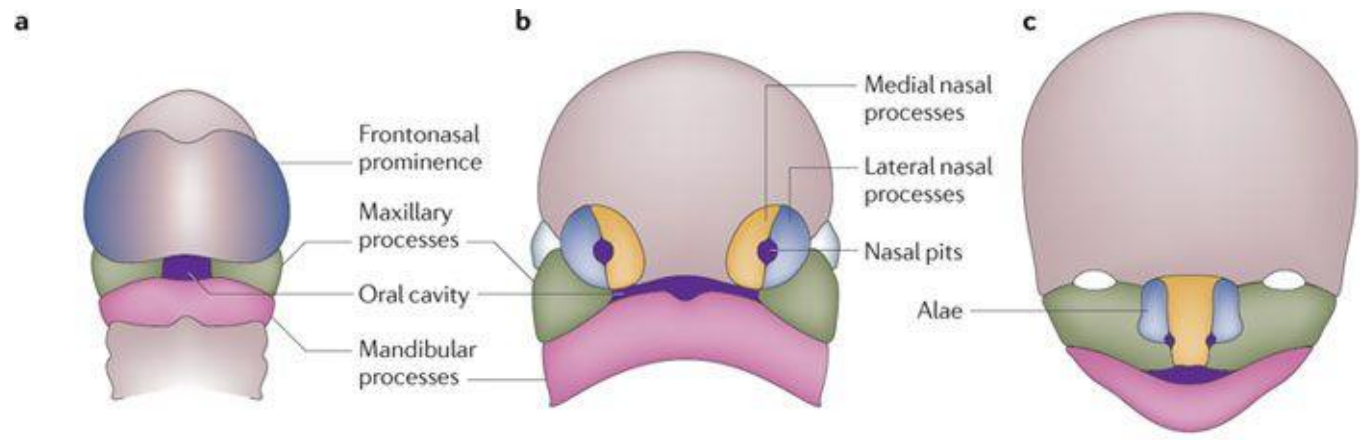
DEVELOPMENT OF FACE - PALATE

- **primary palate** (intermaxillary segment)
- **secondary palate** (lateral palate shelves)

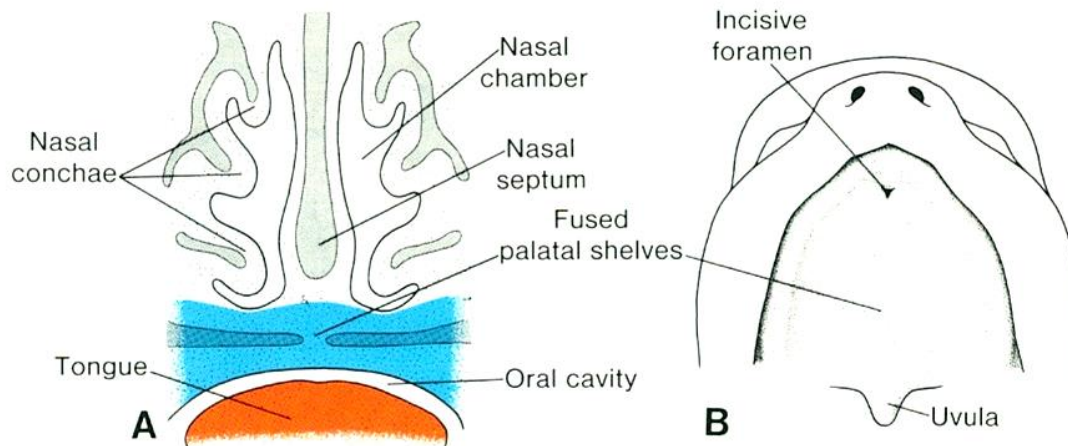
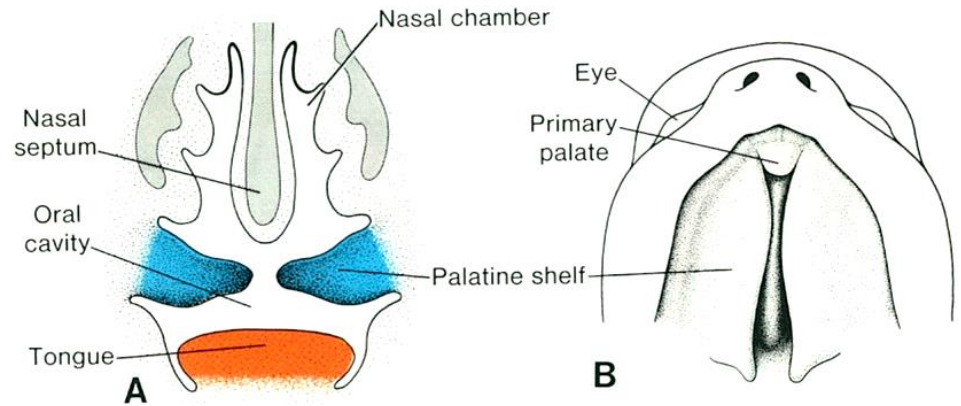
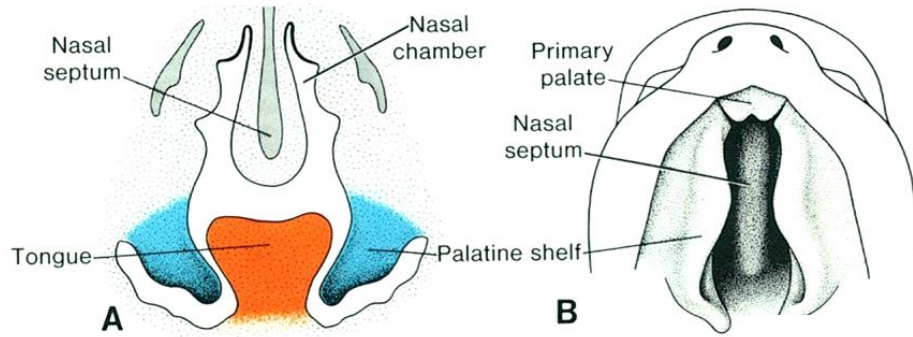


A

B



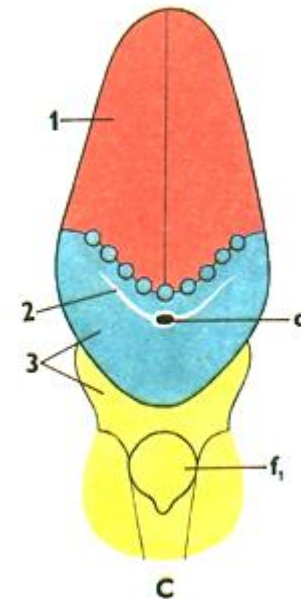
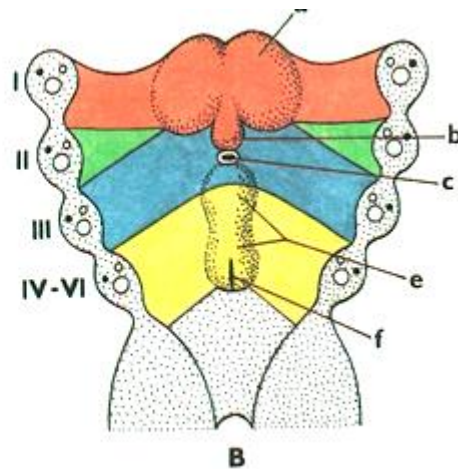
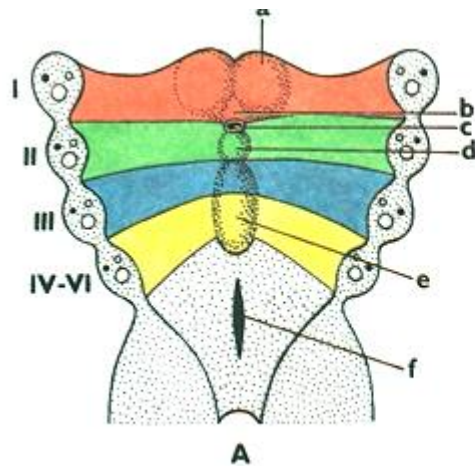
DEVELOPMENT OF FACE - PALATE



Pharyngeal arches:

I. tuberculum linguale laterale (dx. wt sin.) (paired) and tuberculum impar → **apex and corpus**

III and IV. copula and eminentia hypobranchialis → **radix**

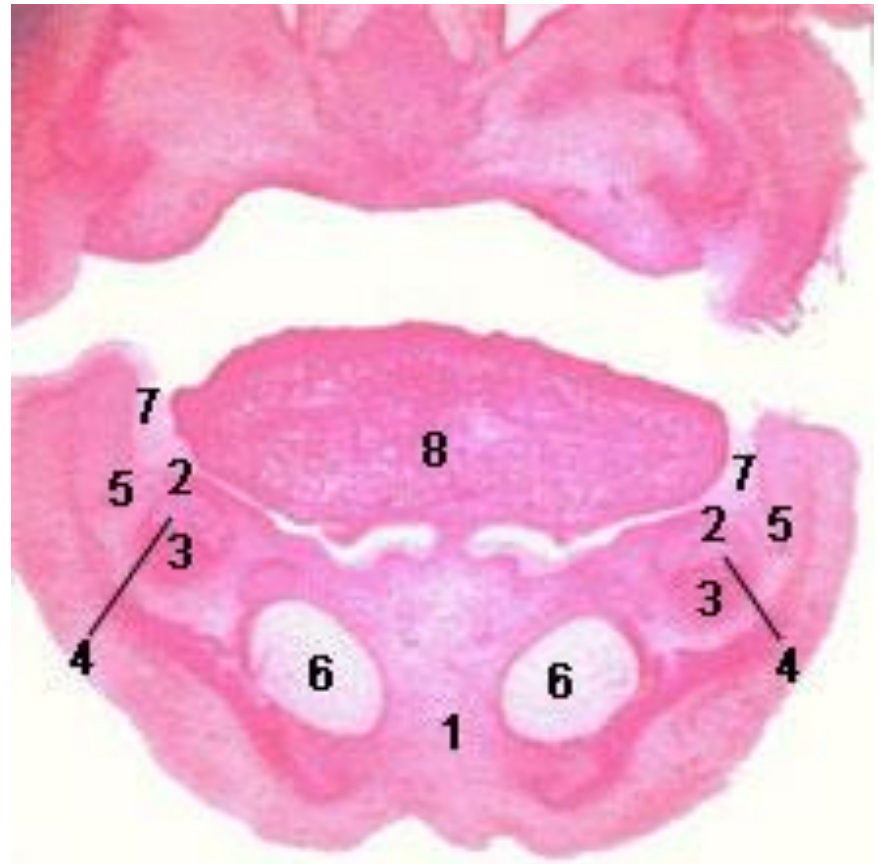


DEVELOPMENT OF VESTIBULUM ORIS

Vestibular lamina

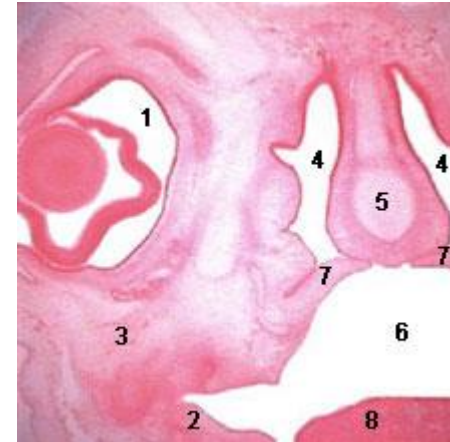
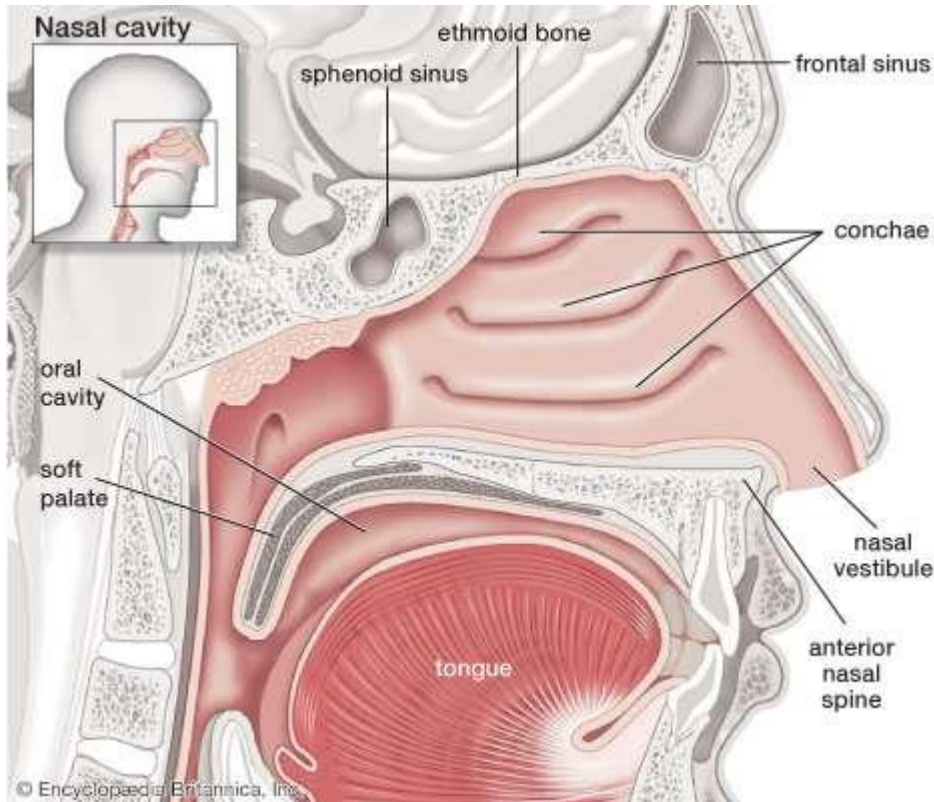
- Dental lamina
- Labiogingival lamina

1. Mandible
2. Dental lamina
3. Dental papilla
4. Enamel organ
5. Labiogingival lamina
6. Meckel's cartilage
7. Oral epithelium
8. Tongue



DEVELOPMENT OF VESTIBULUM NASI

- **Nasal canals** – primitive choans
- **Nasal septum** – from area triangularis – fusing with secondary palate

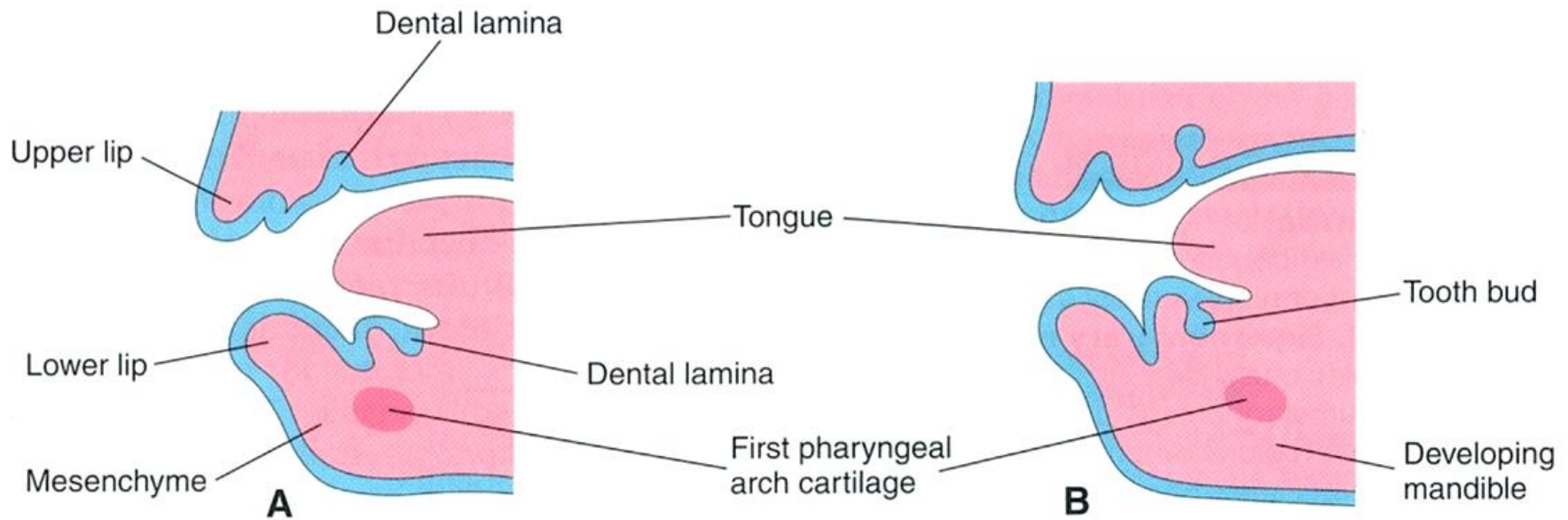


1. Eye
2. Mandibular bone
3. Maxillary bone
4. Nasal cavity
5. Nasal septum
6. Oral cavity
7. Palatine process
8. Tongue

DEVELOPMENT OF TOOTH

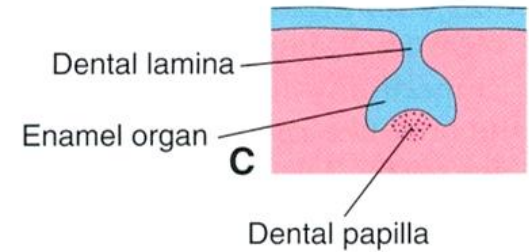
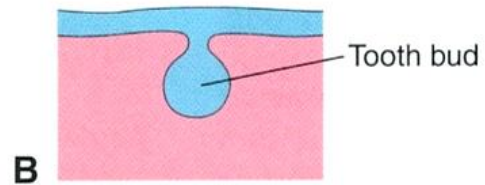
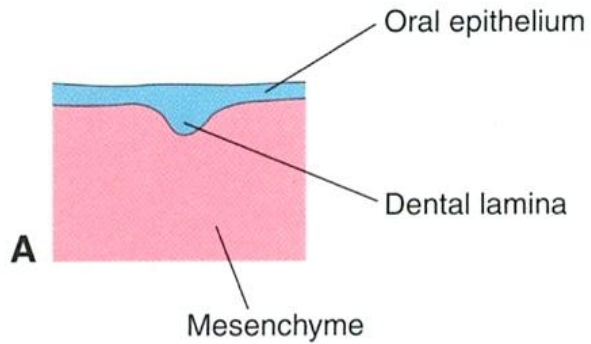
Interactions of ectoderm and mesenchyme

- primary dental lamina – teeth primordia



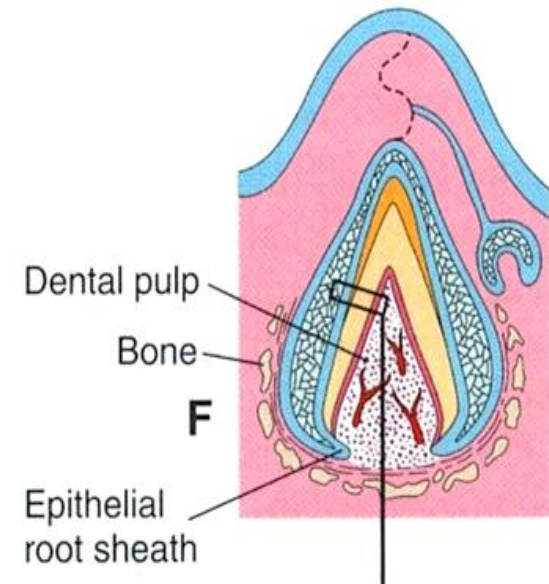
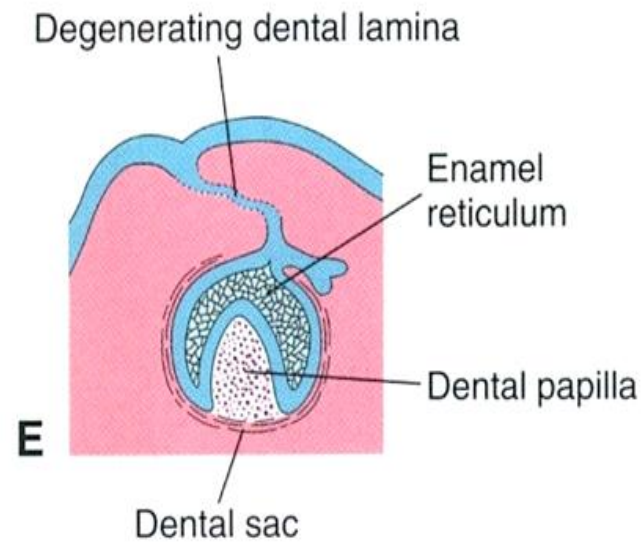
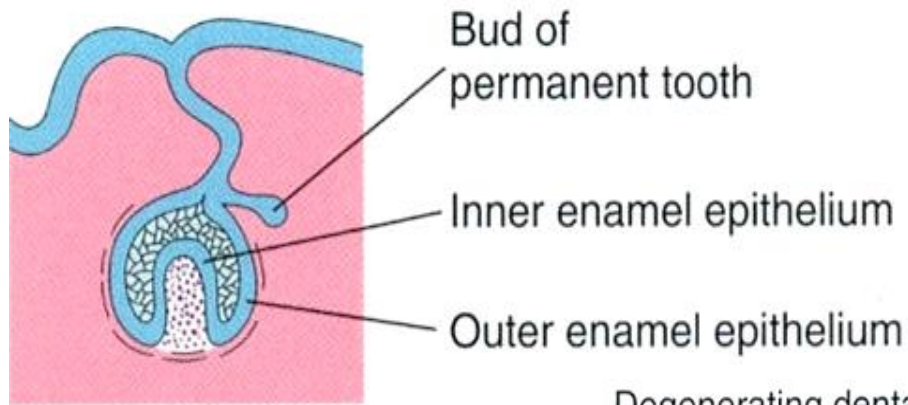
DEVELOPMENT OF TOOTH

- Initiation stage
- tooth bud (primordium)
- cap stage
- bell stage (enamel organ, ectoderm), dental pulp (mesenchyme)

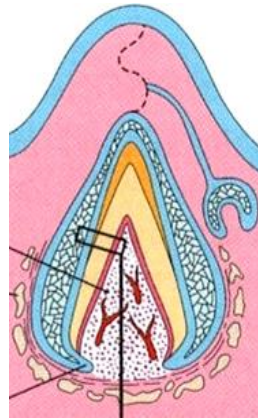
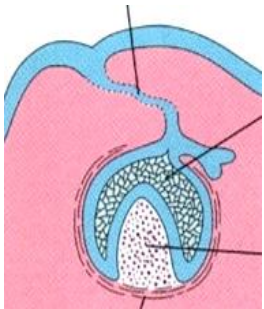


DEVELOPMENT OF TOOTH

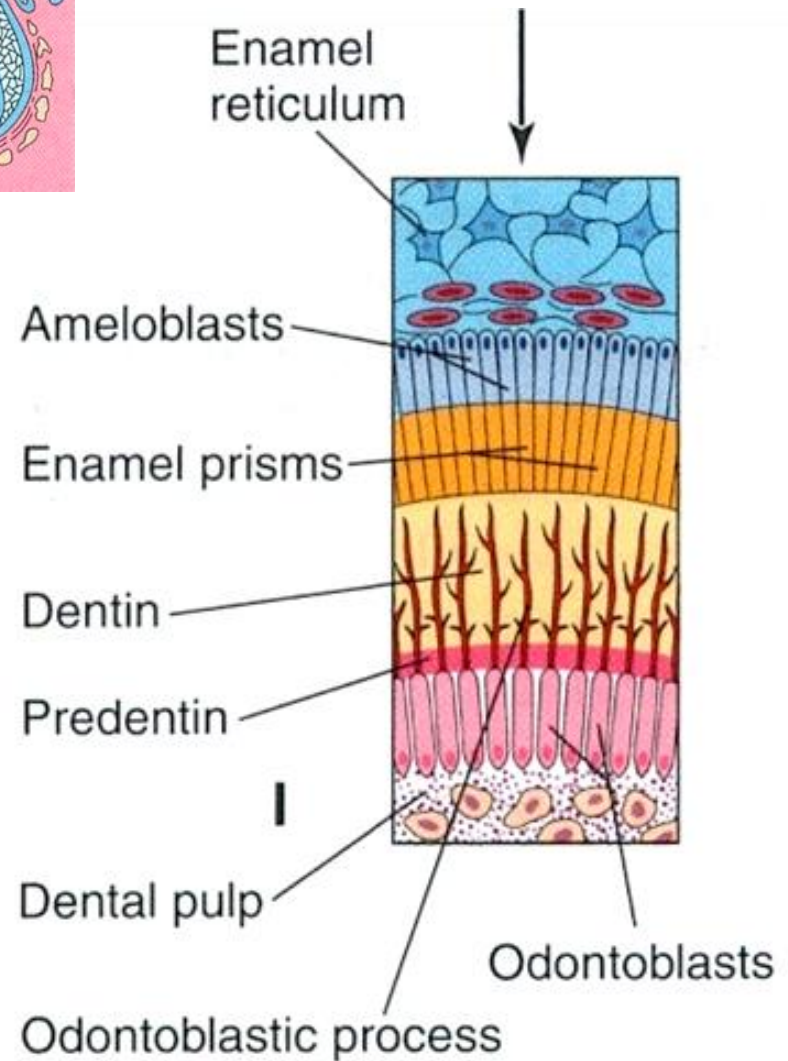
- bell stage – enamel, differentiation of odontoblasts from cells of dental pulp
- enamel prisms and dentin matrix
- dental sac



DEVELOPMENT OF TOOTH



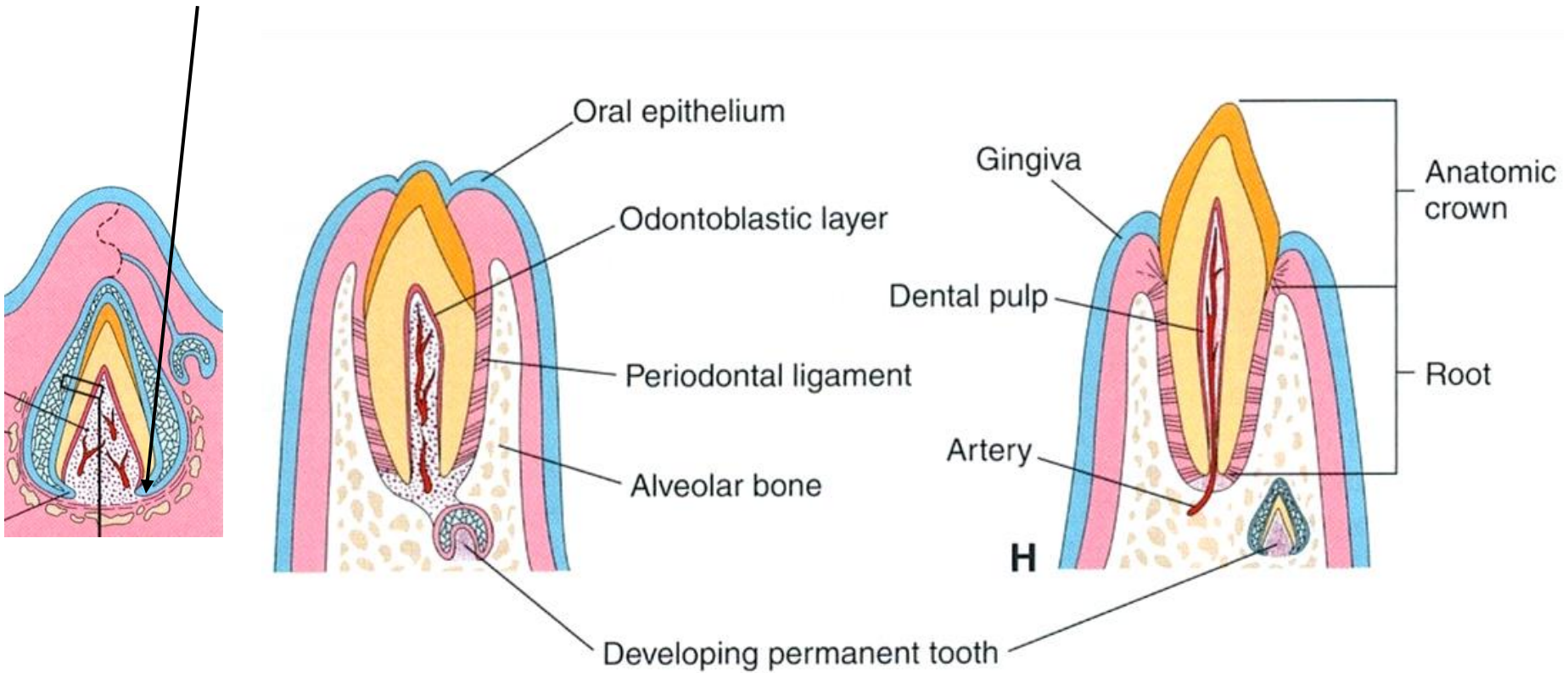
- enamel organ (inner and outer ameloblasts, stratum intermedium stellate reticulum - pulp) – prisms
- odontoblast differentiation - dentin matrix, (processes of odontoblasts = Tomes fibers)



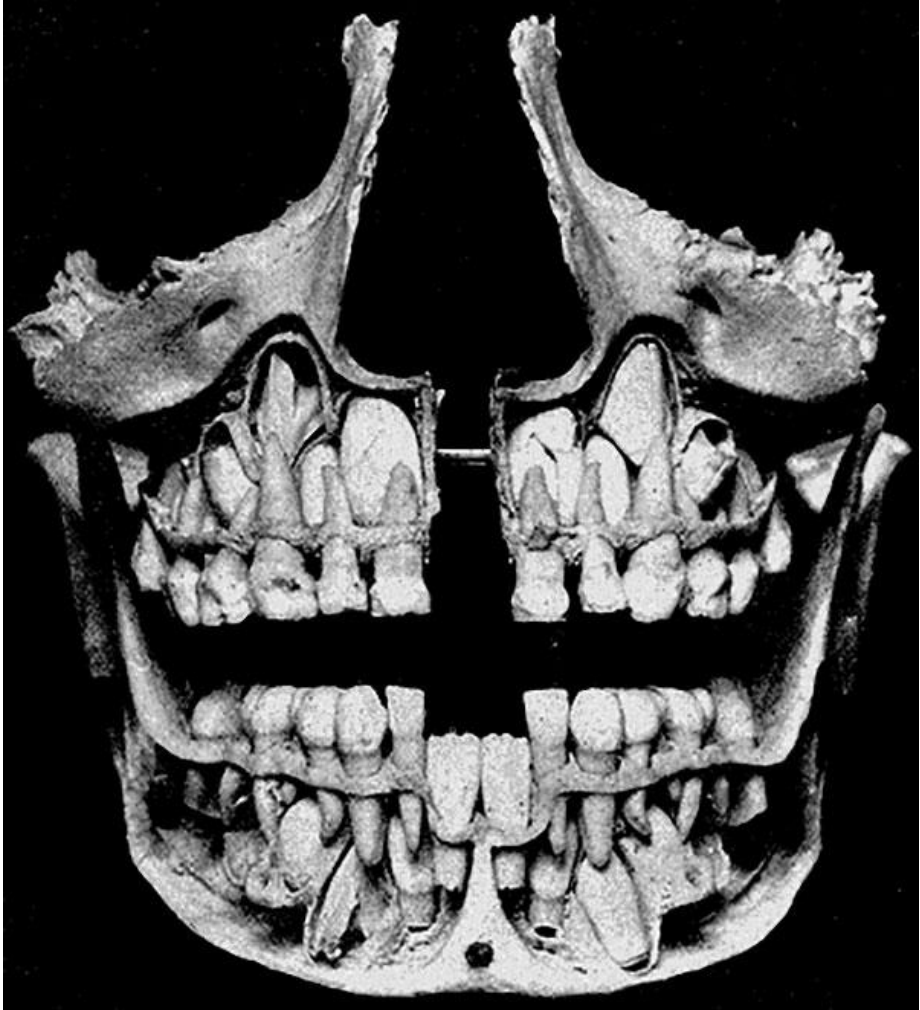
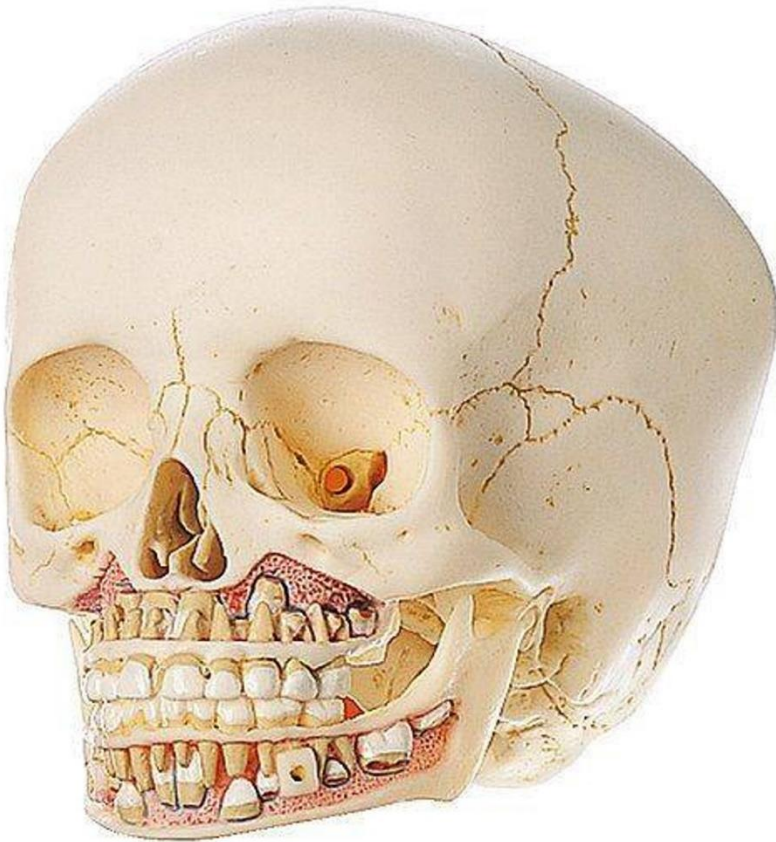
DEVELOPMENT OF TOOTH

root development – tooth eruption

cervical loop → Hertwig epithelial root sheath

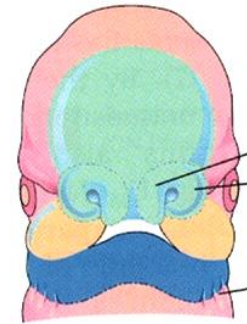


DEVELOPMENT OF TOOTH

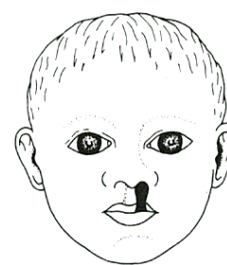


Soft tissue clefts

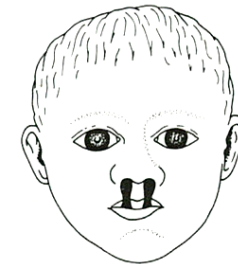
- upper lip (*cheiloschisis*) – lateral (uni, bi), medial
- lower lip – medial, always combined (jaw, tongue) – *gnathoschisis et cheiloschisis inf.*
- oblique cleft (*fissura orbitofacialis*)
- transverse cleft (*fissura transversa*)



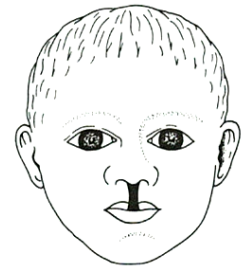
35 days



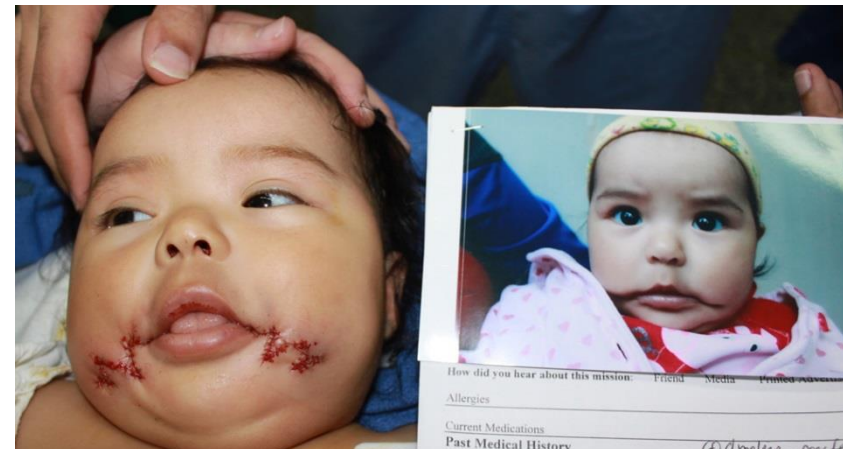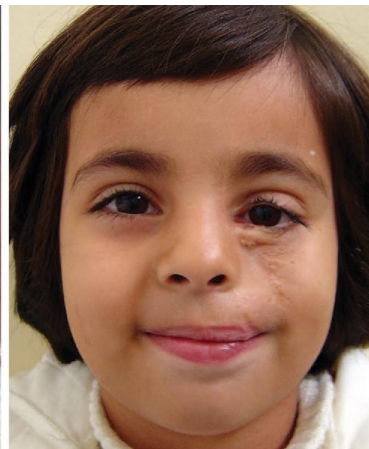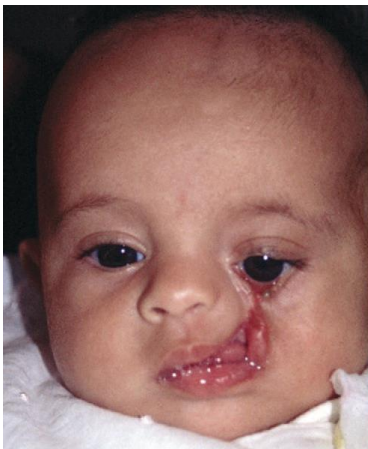A



B



C



ABNORMALITIES OF FACE DEVELOPMENT - CLEFTS

Hard tissue clefts

- upper jaw
 - between 2nd incisor and canine
 - unilateral or bilateral
 - always combined with palate cleft (cheilognathoschisis)
- palate (palatoschisis)
 - primary (before foramen incisivum)
 - secondary (behind foramen incisivum)
- combined: cheilognathopalatoschisis

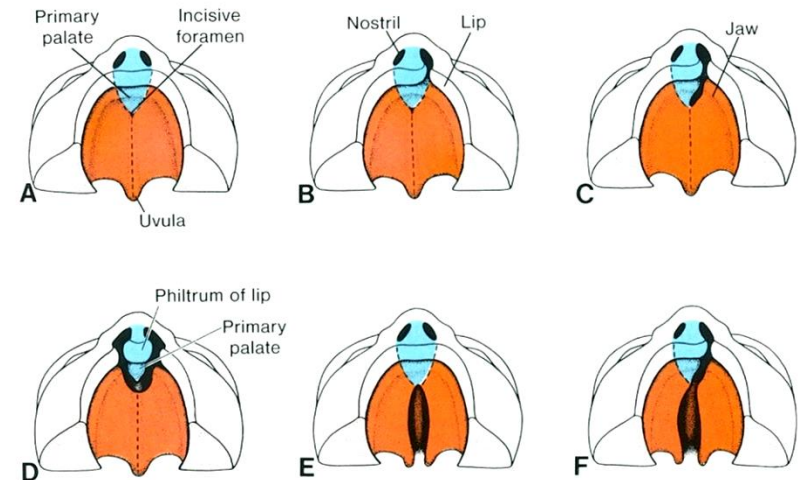
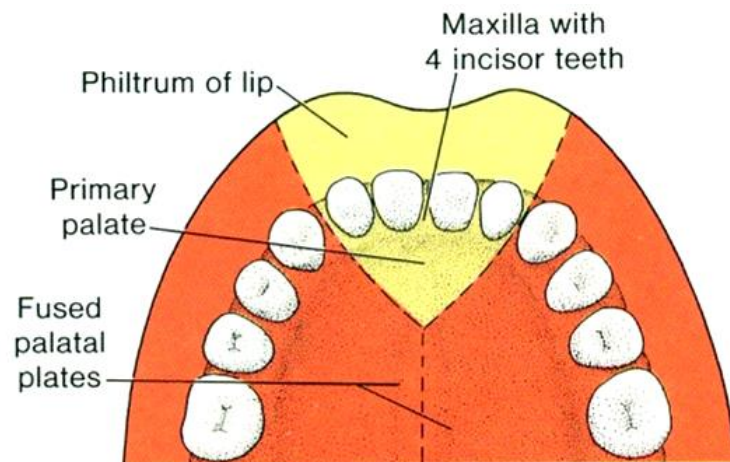
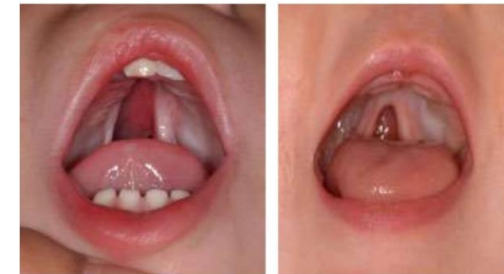
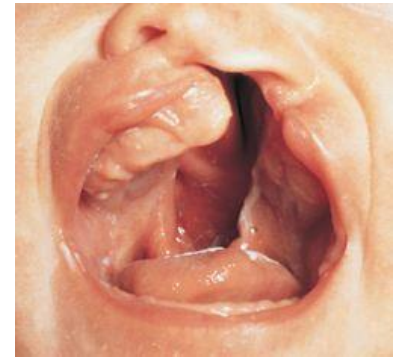
Figure 16-25. Ventral view of the palate, gum, lip, and nose. **A**, Normal. **B**, Unilateral cleft lip extending into the nose. **C**, Unilateral cleft involving lip and jaw, and extending to incisive foramen. **D**, Bilateral cleft involving lip and jaw. **E**, Isolated cleft palate. **F**, Cleft palate combined with unilateral anterior cleft.

ABNORMALITIES OF FACE DEVELOPMENT - CLEFTS

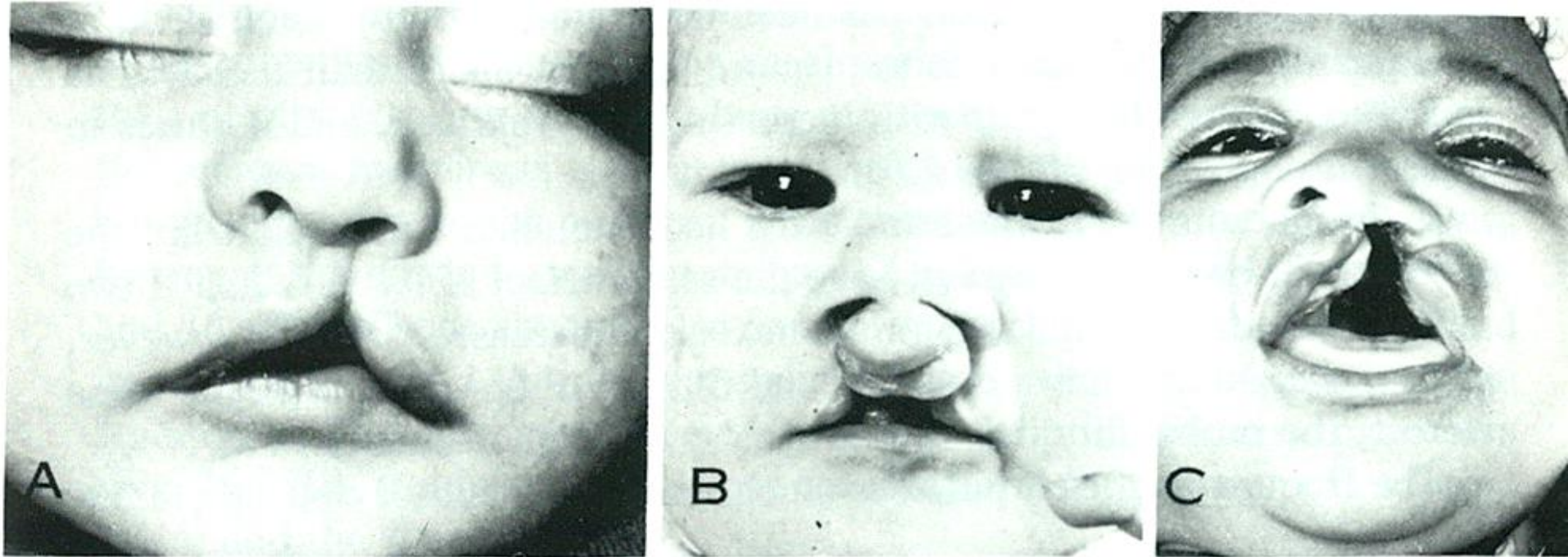
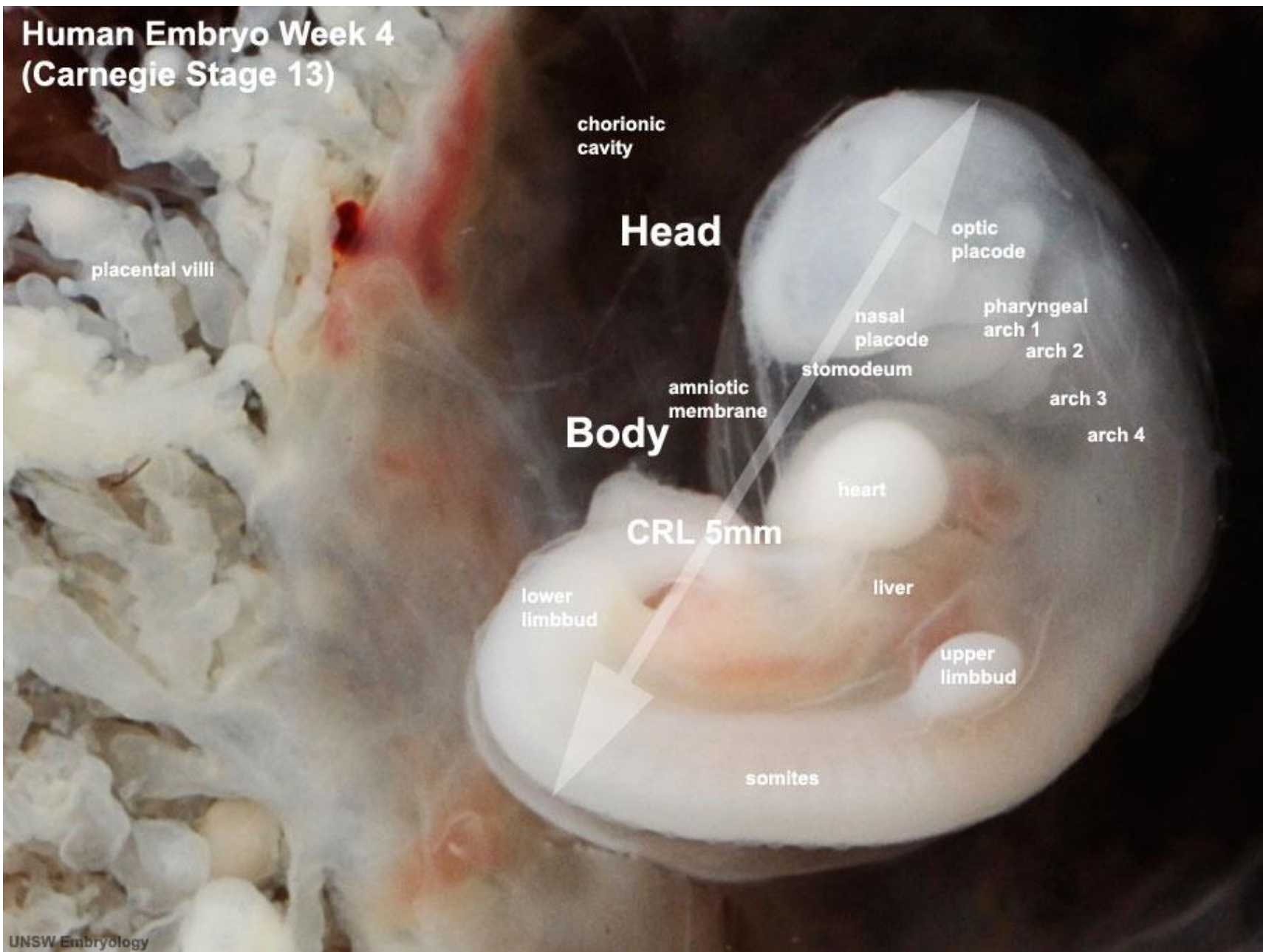


Figure 16-26. Photographs of incomplete cleft lip (A), bilateral cleft lip (B), and cleft lip, cleft jaw, and cleft palate (C). (Courtesy Dr. M. Edgerton, Department of Plastic Surgery, University of Virginia.)

http://www.youtube.com/watch?v=agmSH8_mLz0

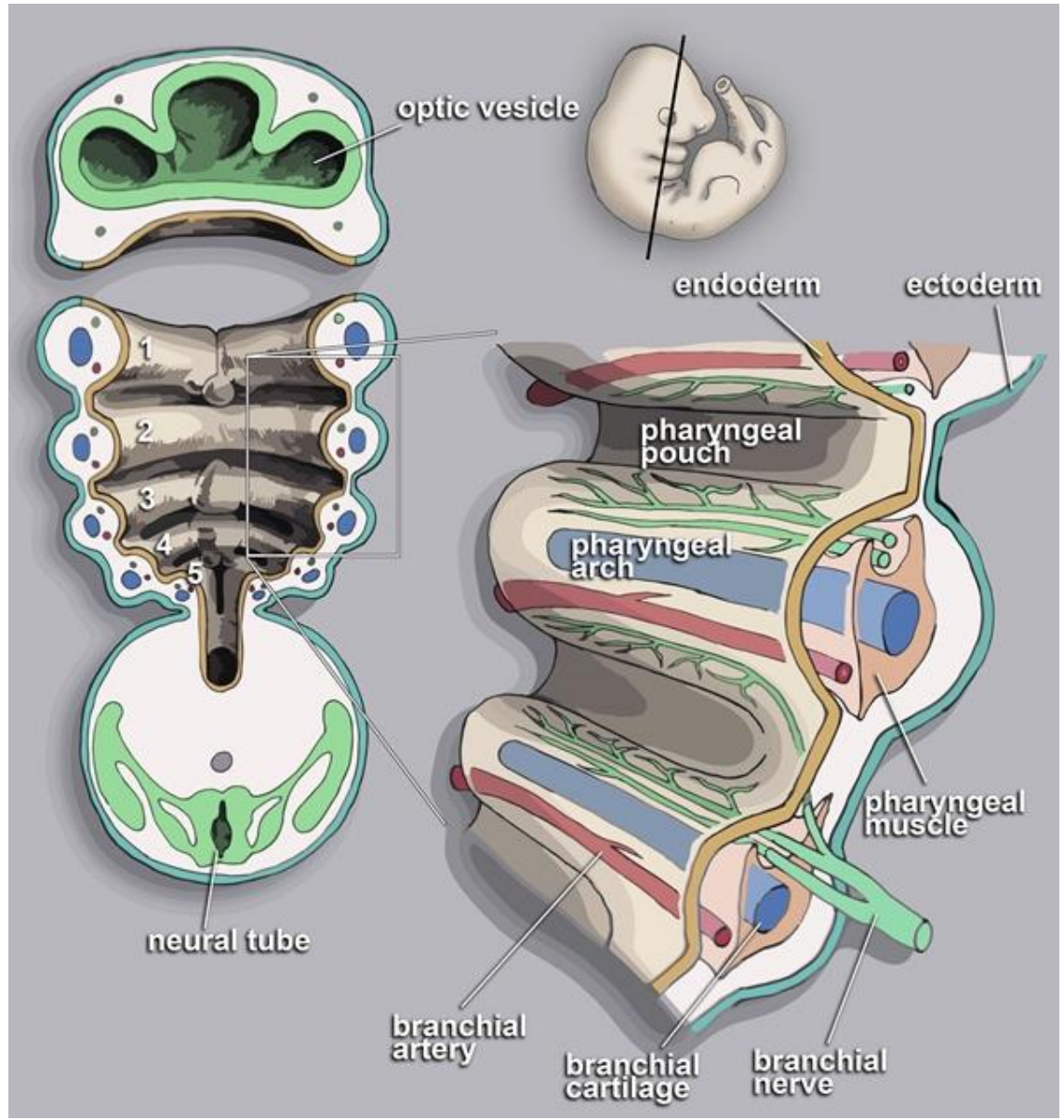
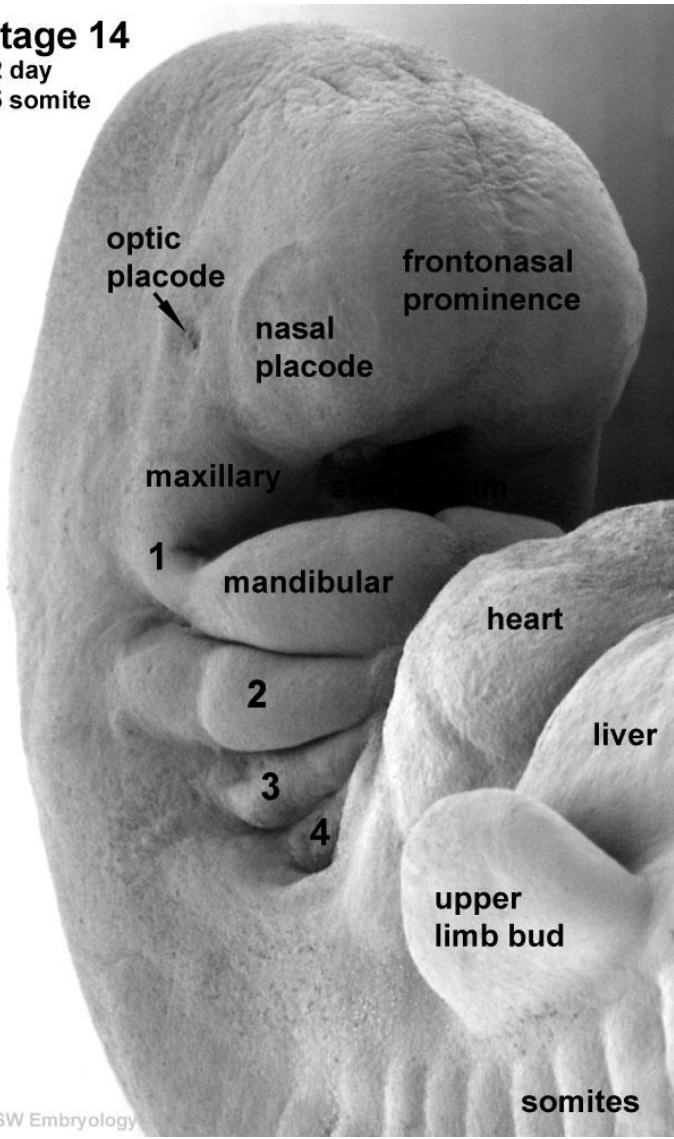
PHARYNGEAL APPARATUS



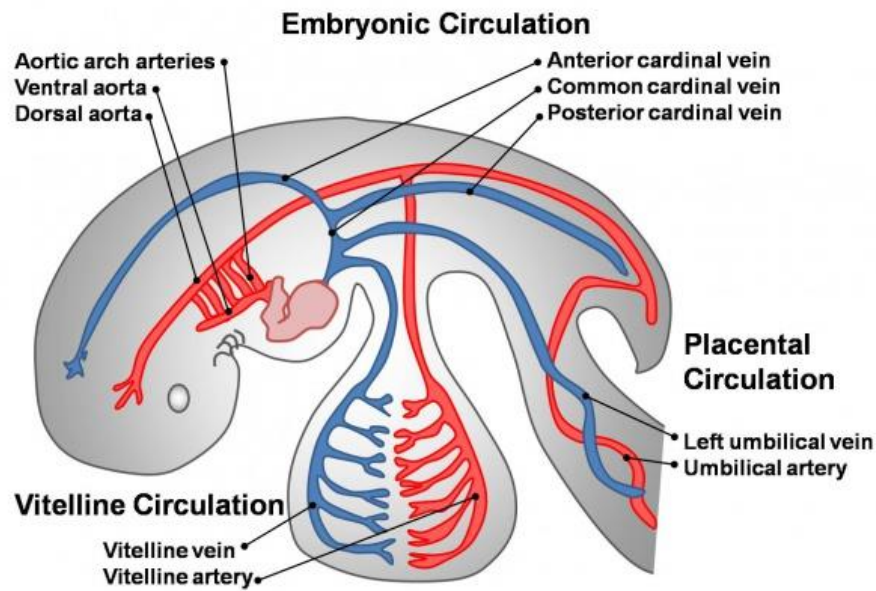
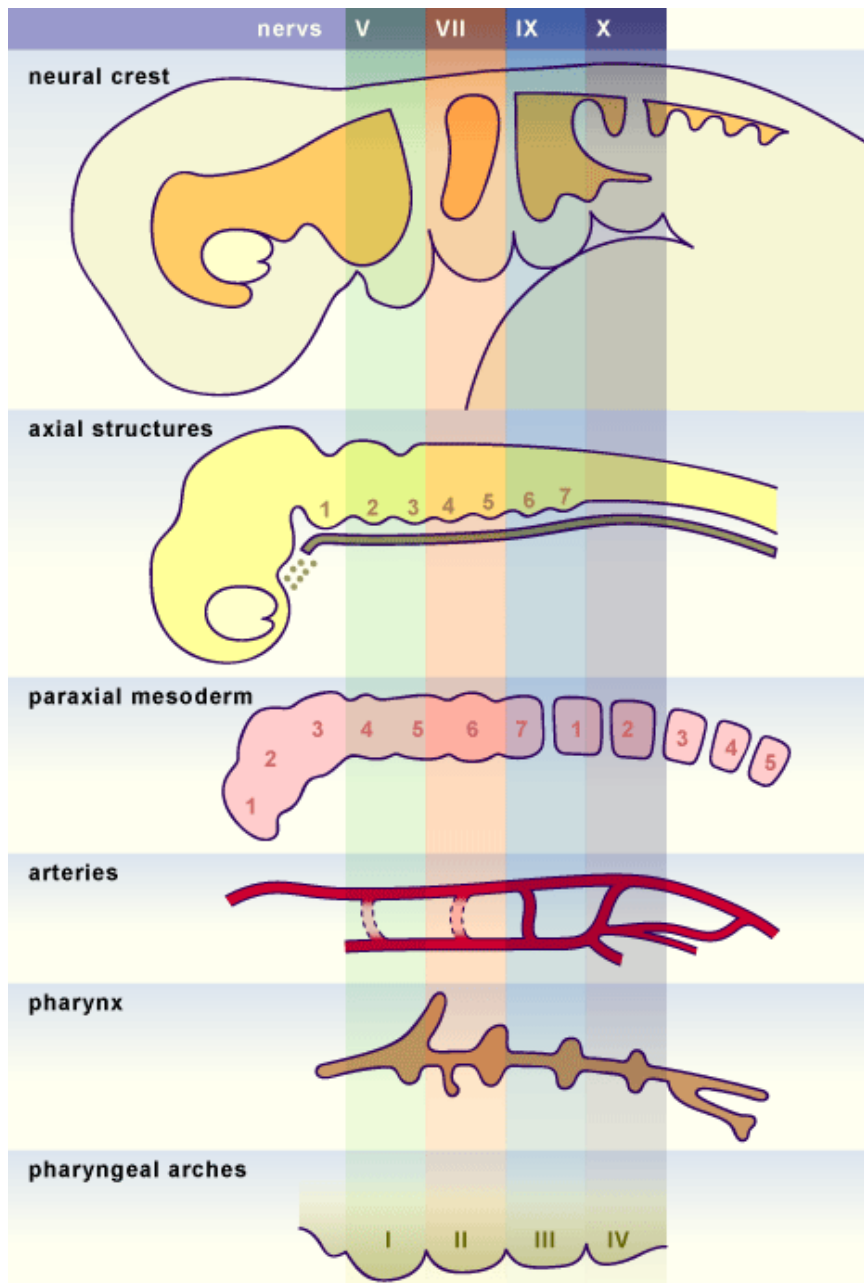
PHARYNGEAL APPARATUS

Stage 14

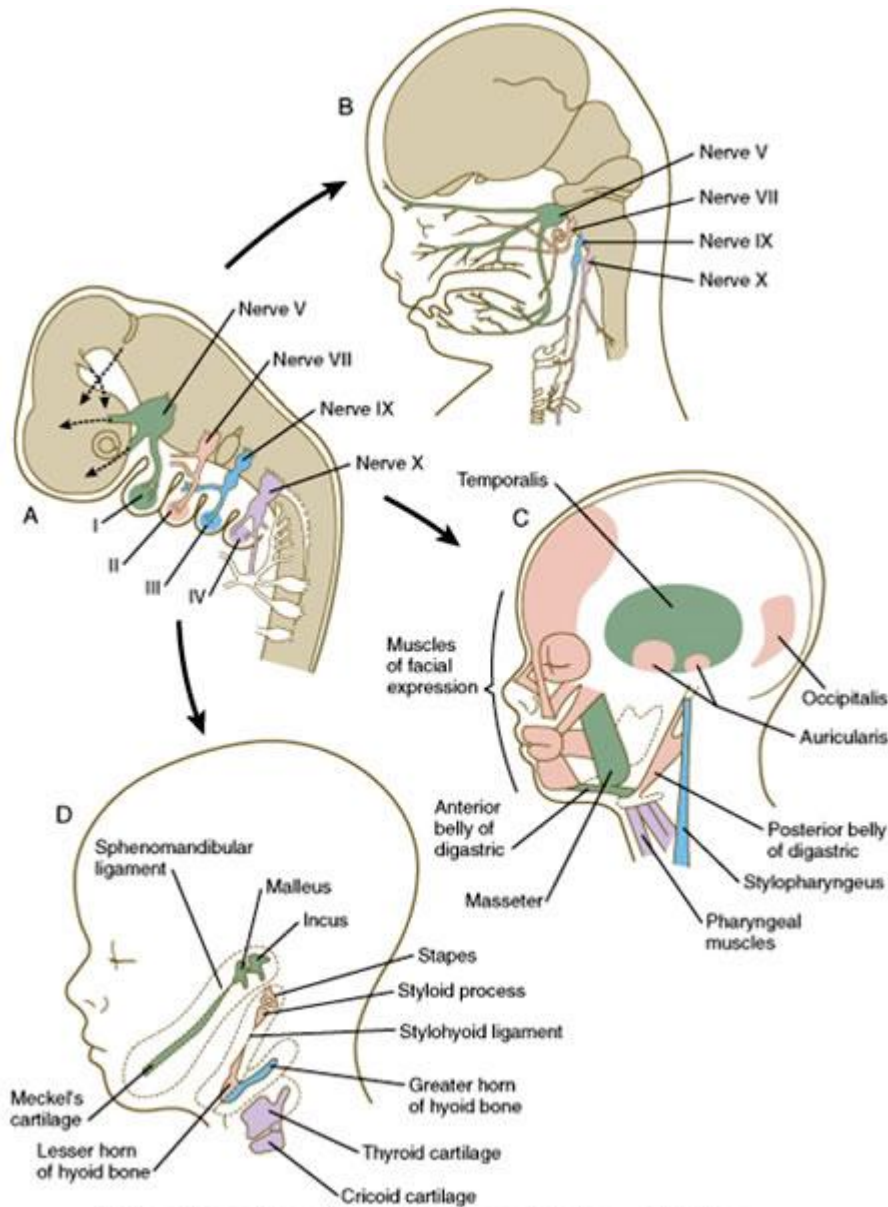
32 day
35 somite



PHARYNGEAL APPARATUS



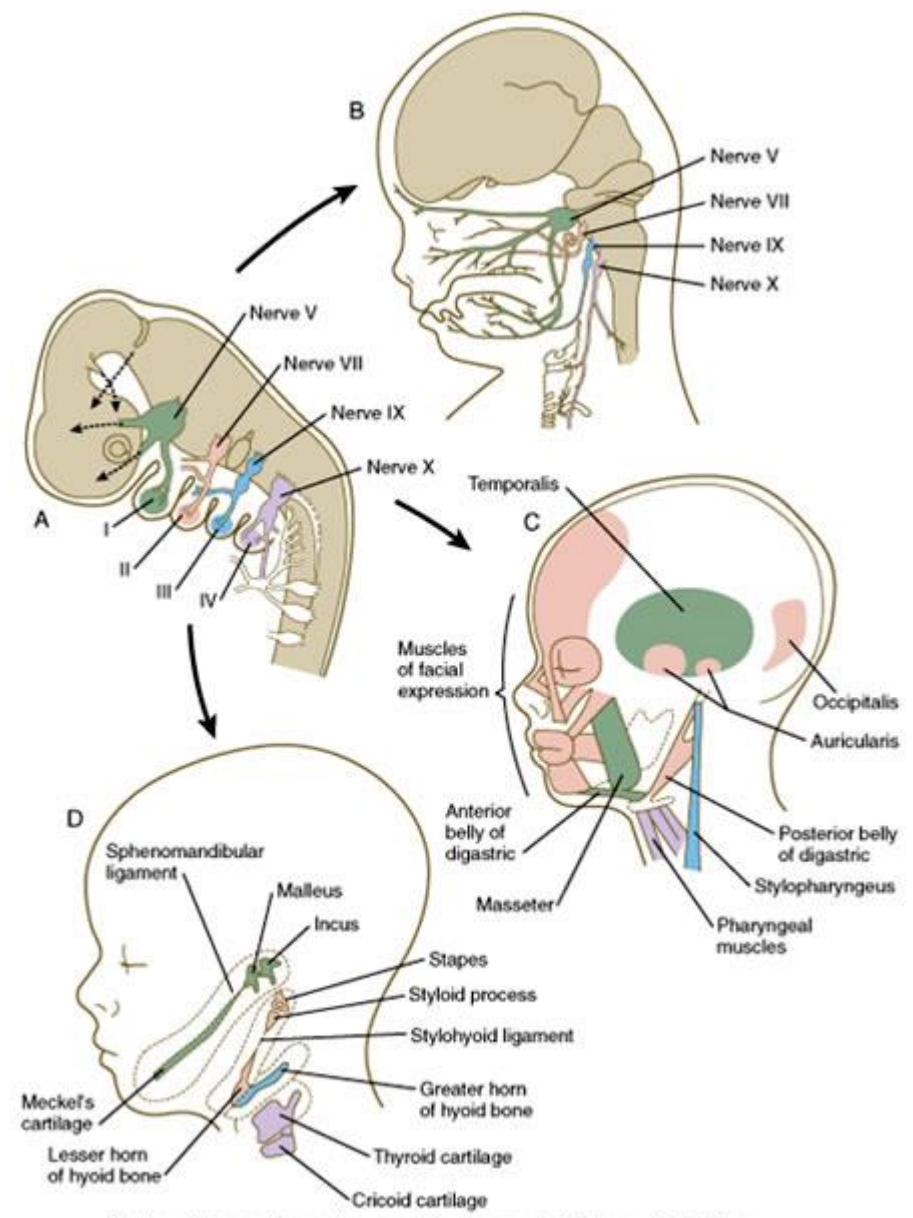
PHARYNGEAL APPARATUS



Derivatives

- Face including soft tissues
- Mimic and mastication muscles
- Tongue
- Outer and middle ear
- Hyoid bone
- Laryngeal cartilages
- Thymus
- Parathyroid glands
- Fossa tonsillaris (→ t. palatina)
- Large arteries (for details see the lesson on cardiovascular system development)

PHARYNGEAL APPARATUS



PHARYNGEAL APPARATUS

Derivative of ectodermal ridge	Pharyngeal arch	Aortic arch	Cranial nerve	Example of branchiomic muscles	Skeletal derivatives	Derivative of endodermal pouch
1. external acoustic meatus	1 mandibular	a. maxillaris	V. trigeminus	masticatory	incus, malleus lig. sphenomandib. Meckel cartilage	middle ear cavity, tuba auditiva
2-4. disappear	2 hyoid	a. stapedia a. hyoidea	VII. facialis	mimic	stapes proc. styloideus, hyoid cartilage.	fossa tonsillaris
	3	a. carotis interna	IX. glosso-pharyngeus	m. stylopharyngeus	hyoid cartilage	thymus, parathyroid bodies (inf.)
	4	a. subclavia dx. a. arcus aortae	X. vagus	svaly faryngu a laryngu	laryngeal cartilages	parathyroid bodies (sup.)

THANK YOU FOR
ATTENTION

pvanhara@med.muni.cz

<http://www.histology.med.muni.cz>