



# Mužský pohlavní systém

gonády – *testes*

vývodní cesty

- *epididymis*
- *ductus deferens*
- *ductus ejaculatorius*
- mužská urethra

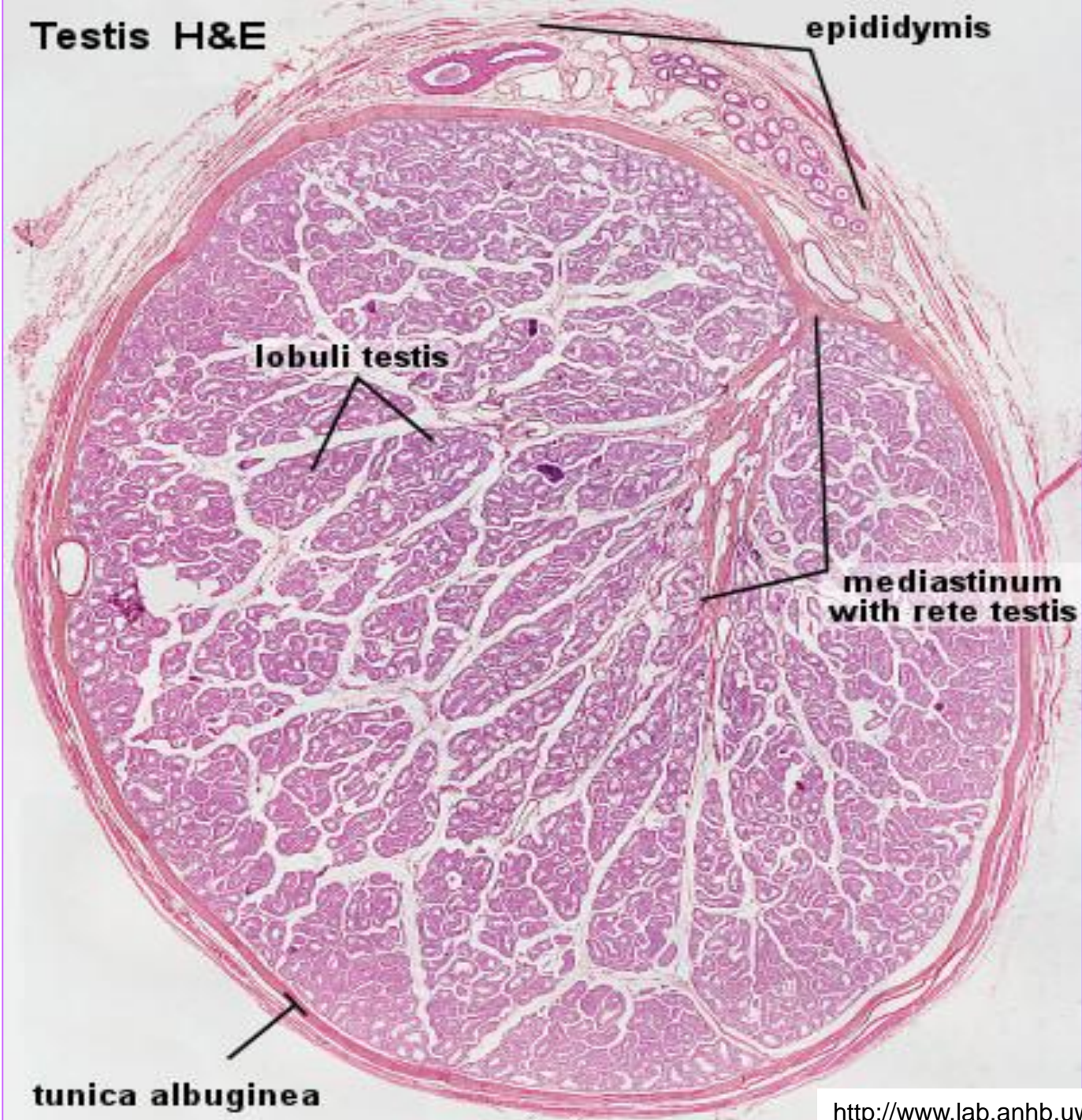
akcesorní žlázy

- *prostata*
- *vesiculae seminales (gll. vesiculosae)*
- *gll. bulbourethrales*

zevní pohl. orgány

- *penis*

**Testis H&E**



**epididymis**

**lobuli testis**

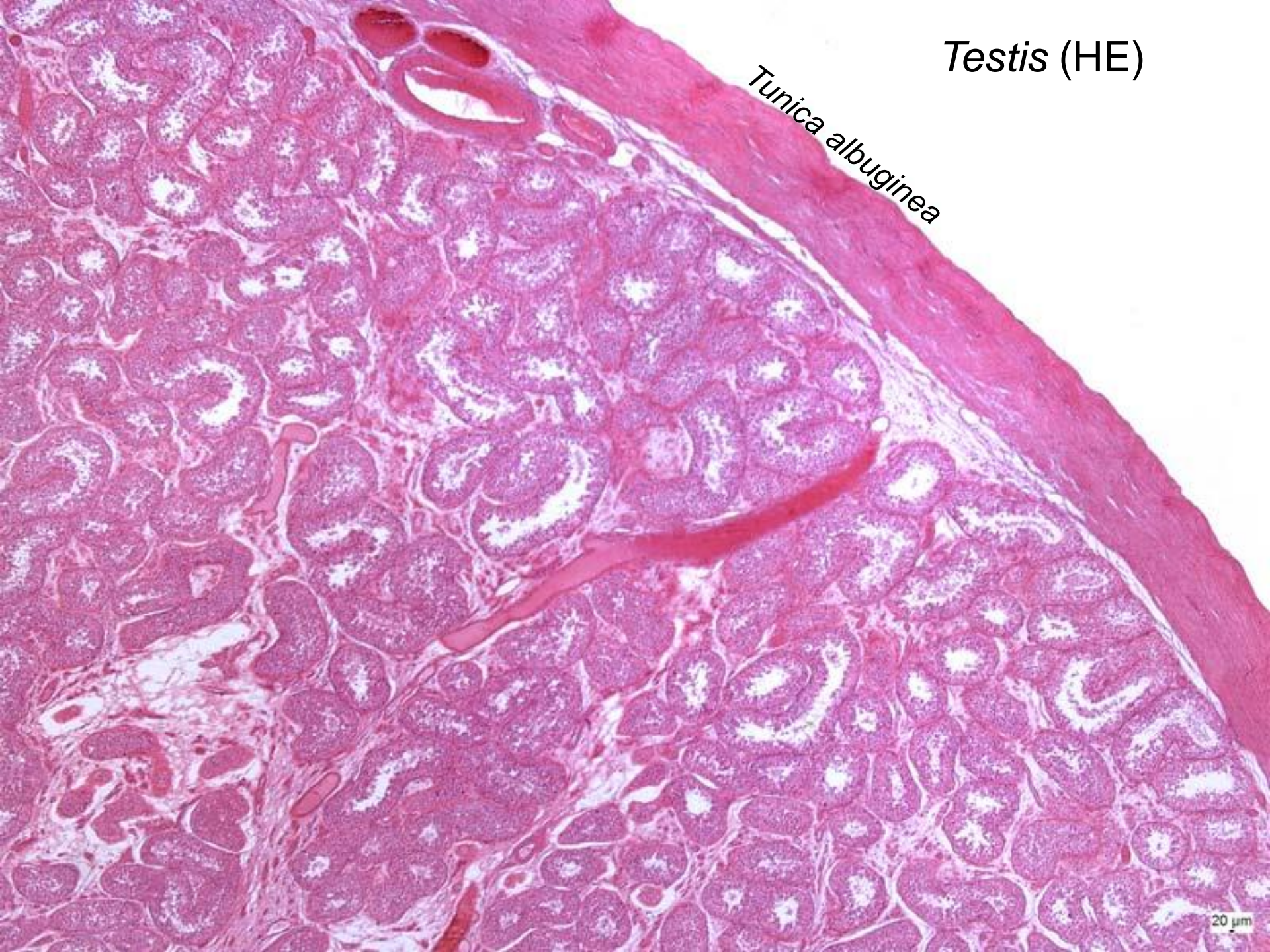**mediastinum  
with rete testis**

**tunica albuginea**



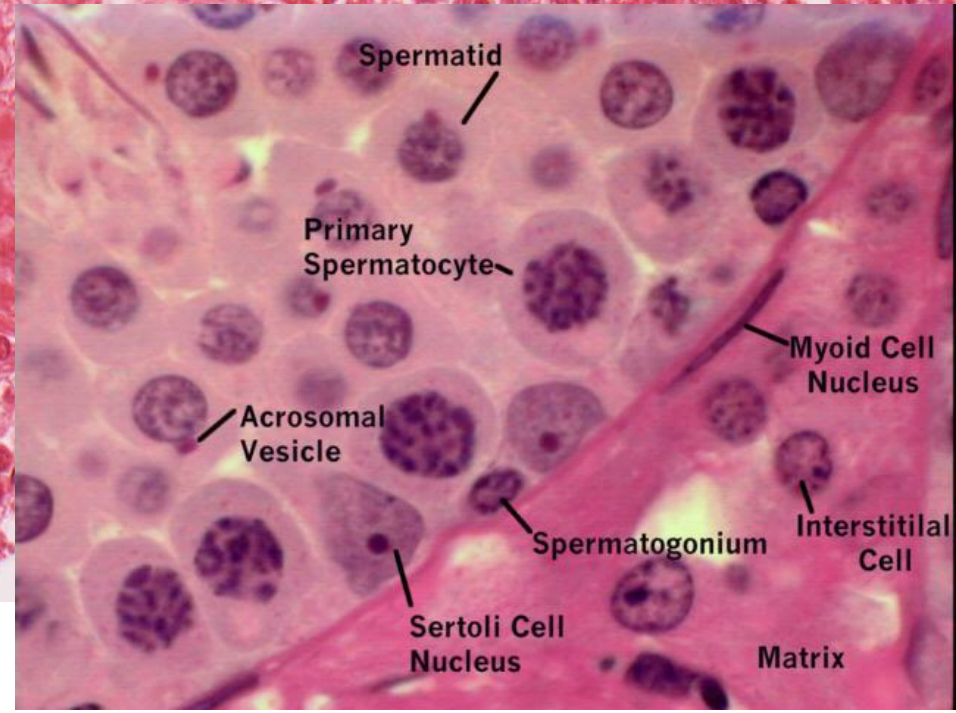
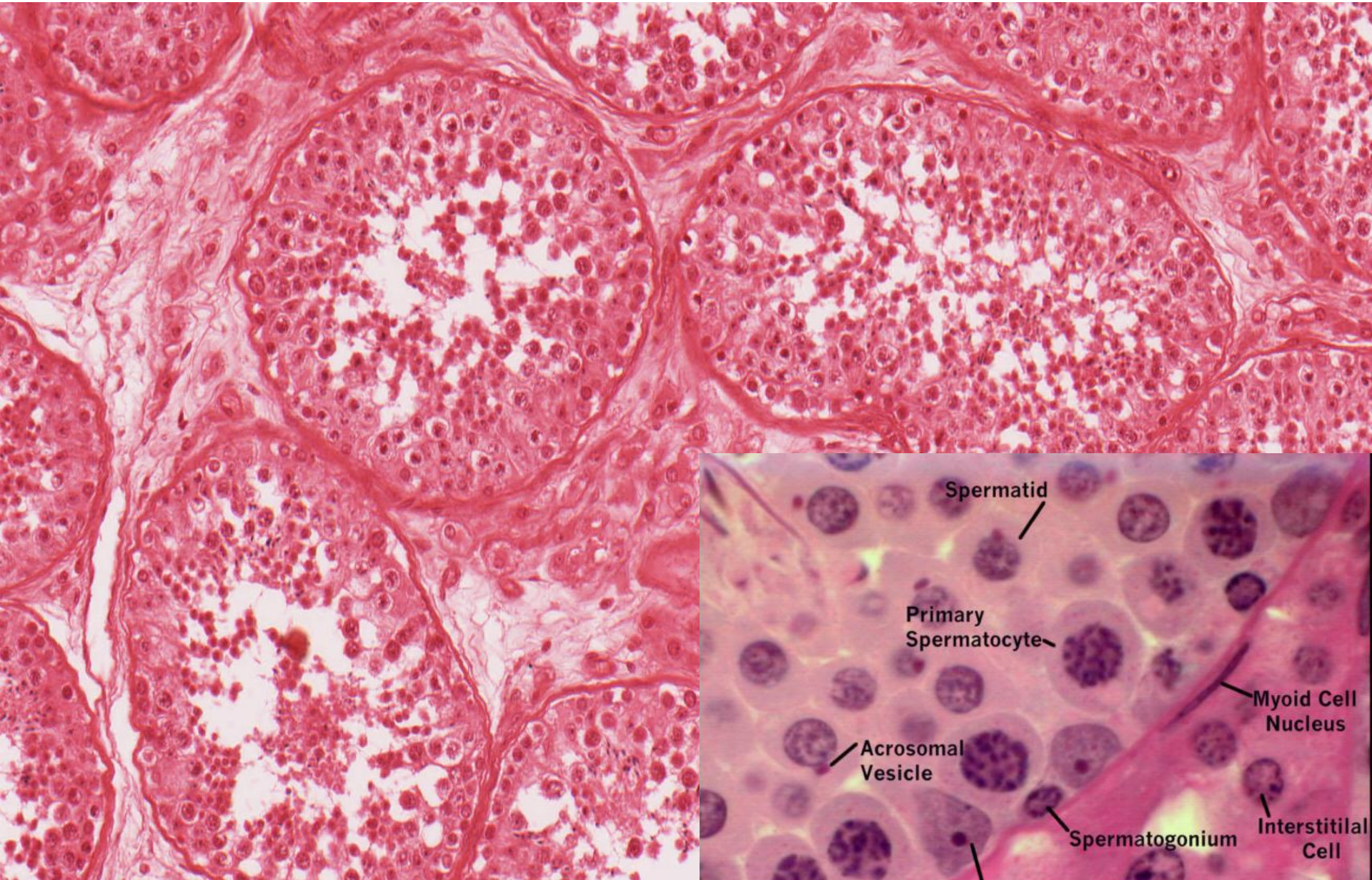
Testis (HE)

*Tunica albuginea*

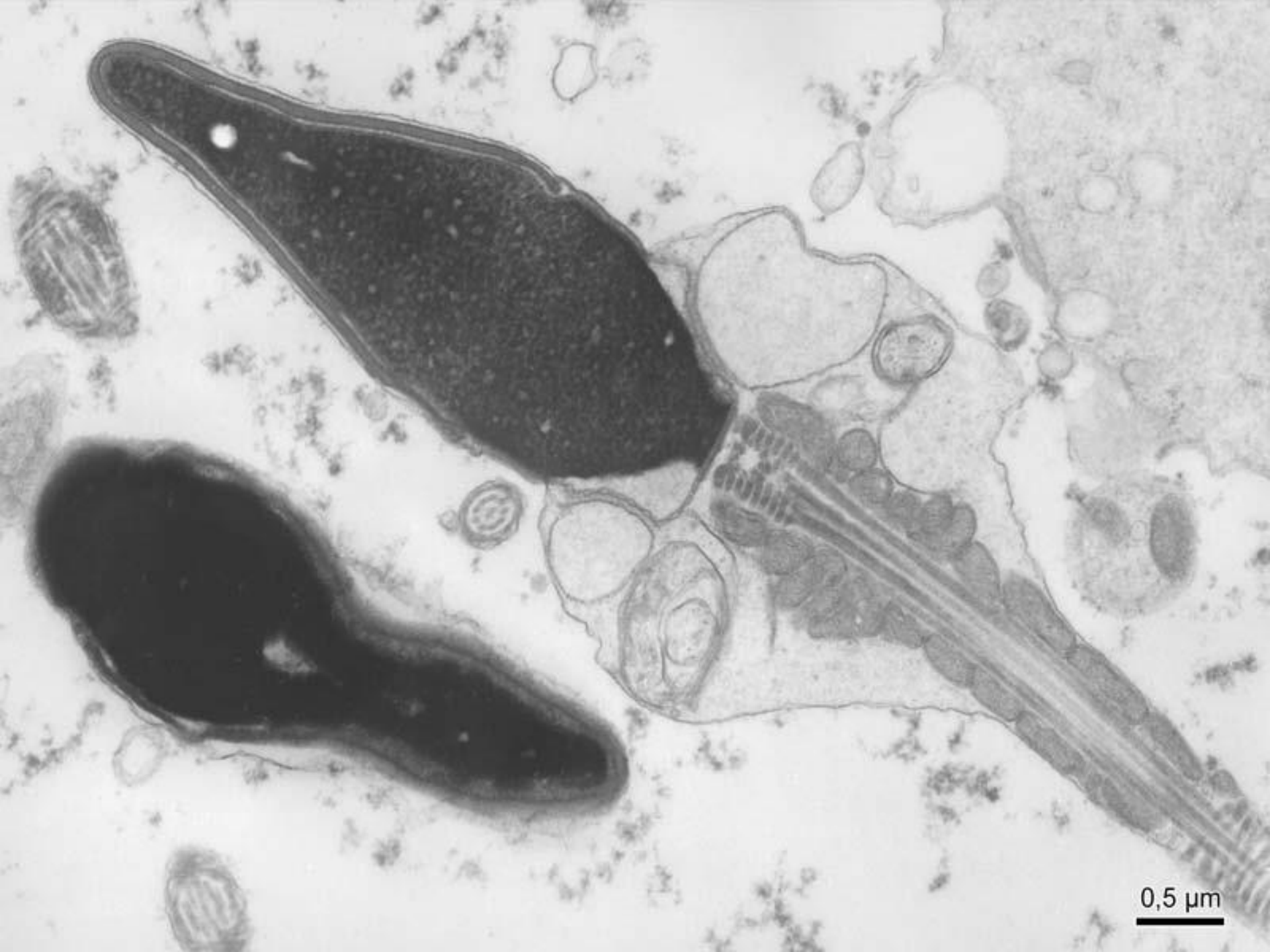




# *Tubuli seminiferi contorti* - spermatogeneze

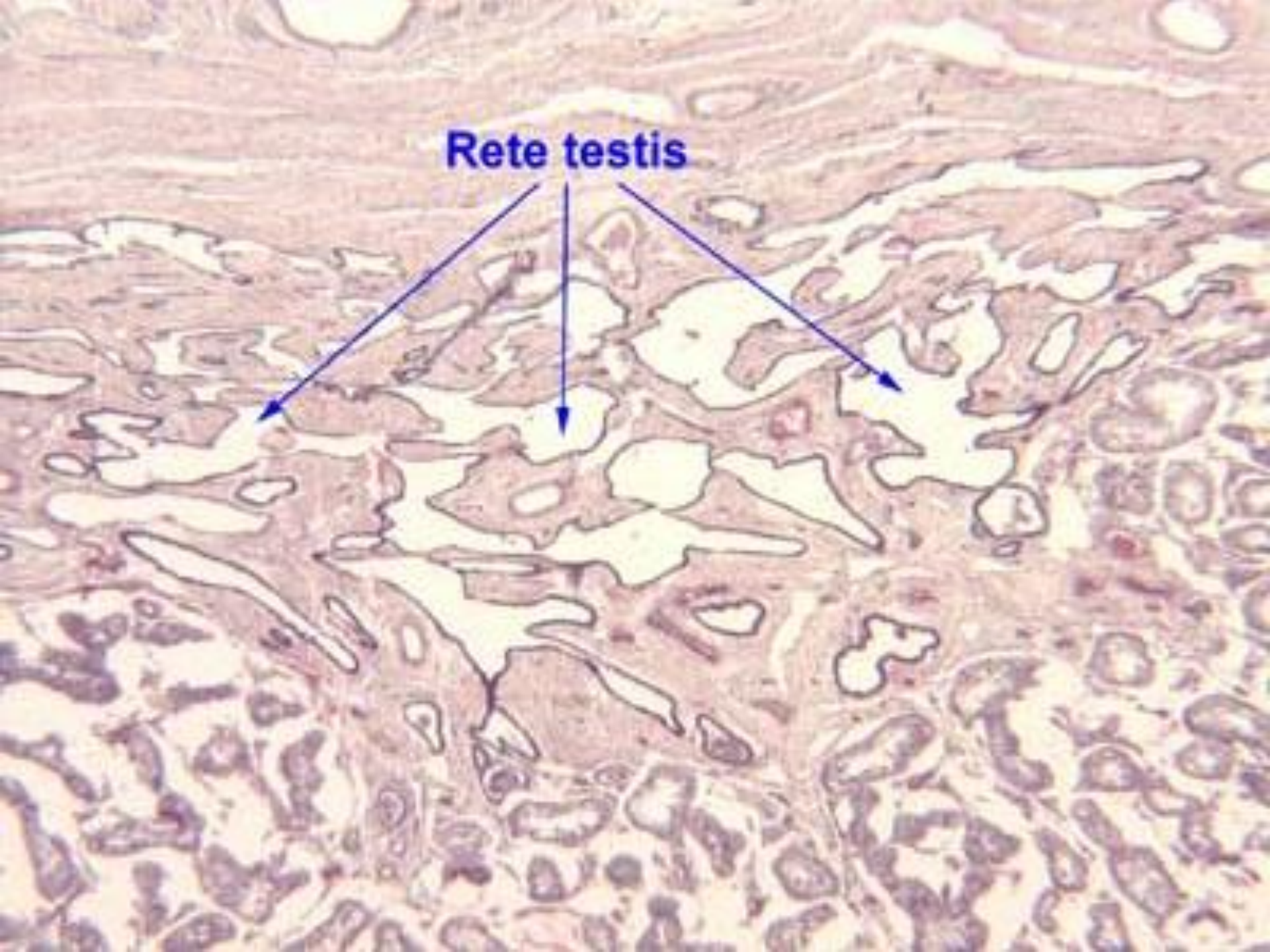





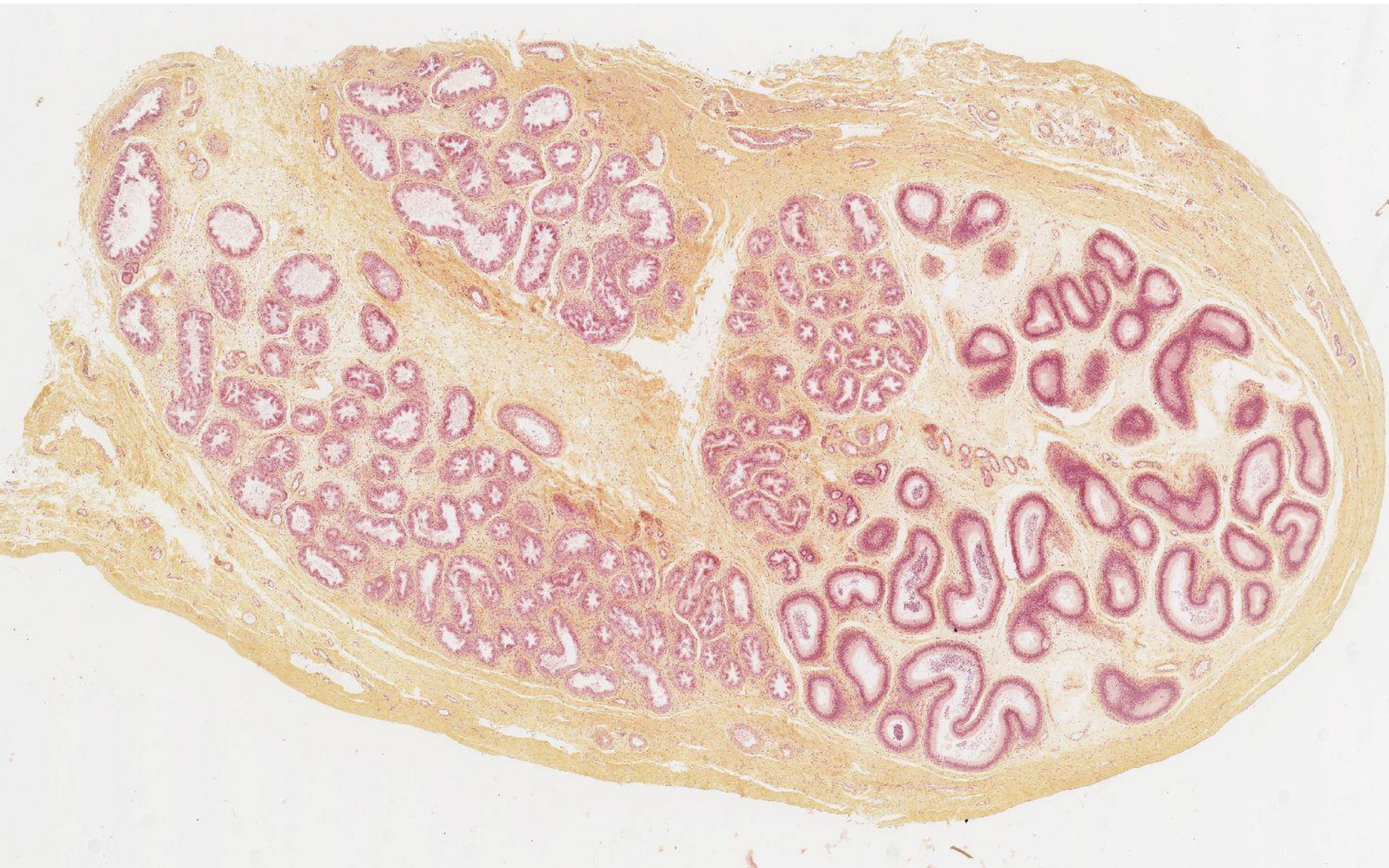0,5 μm

**Rete testis**





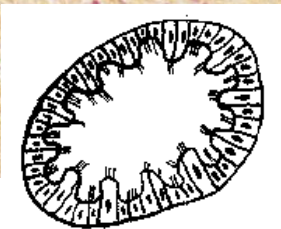
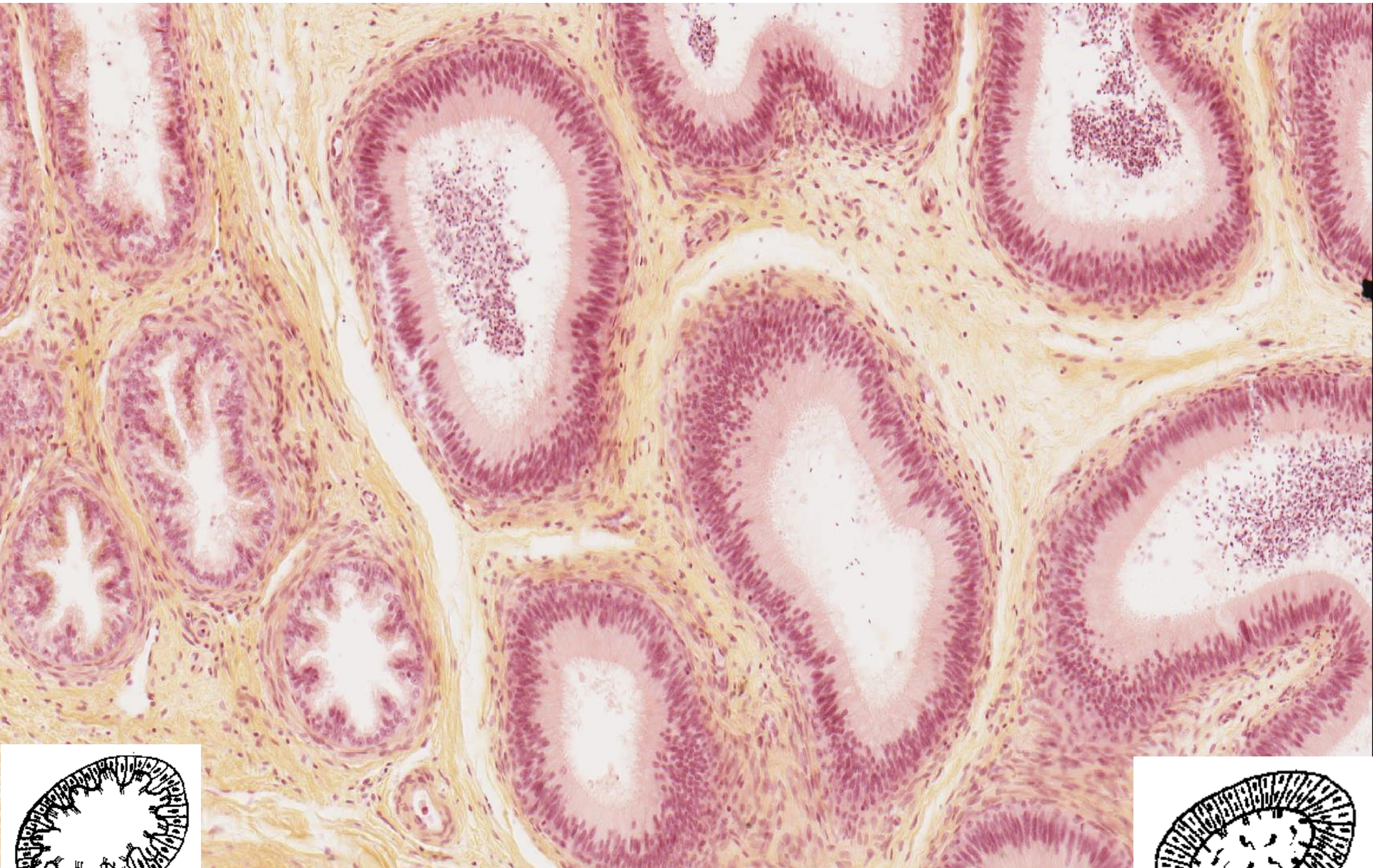
*Epididymis* (HEŠ)





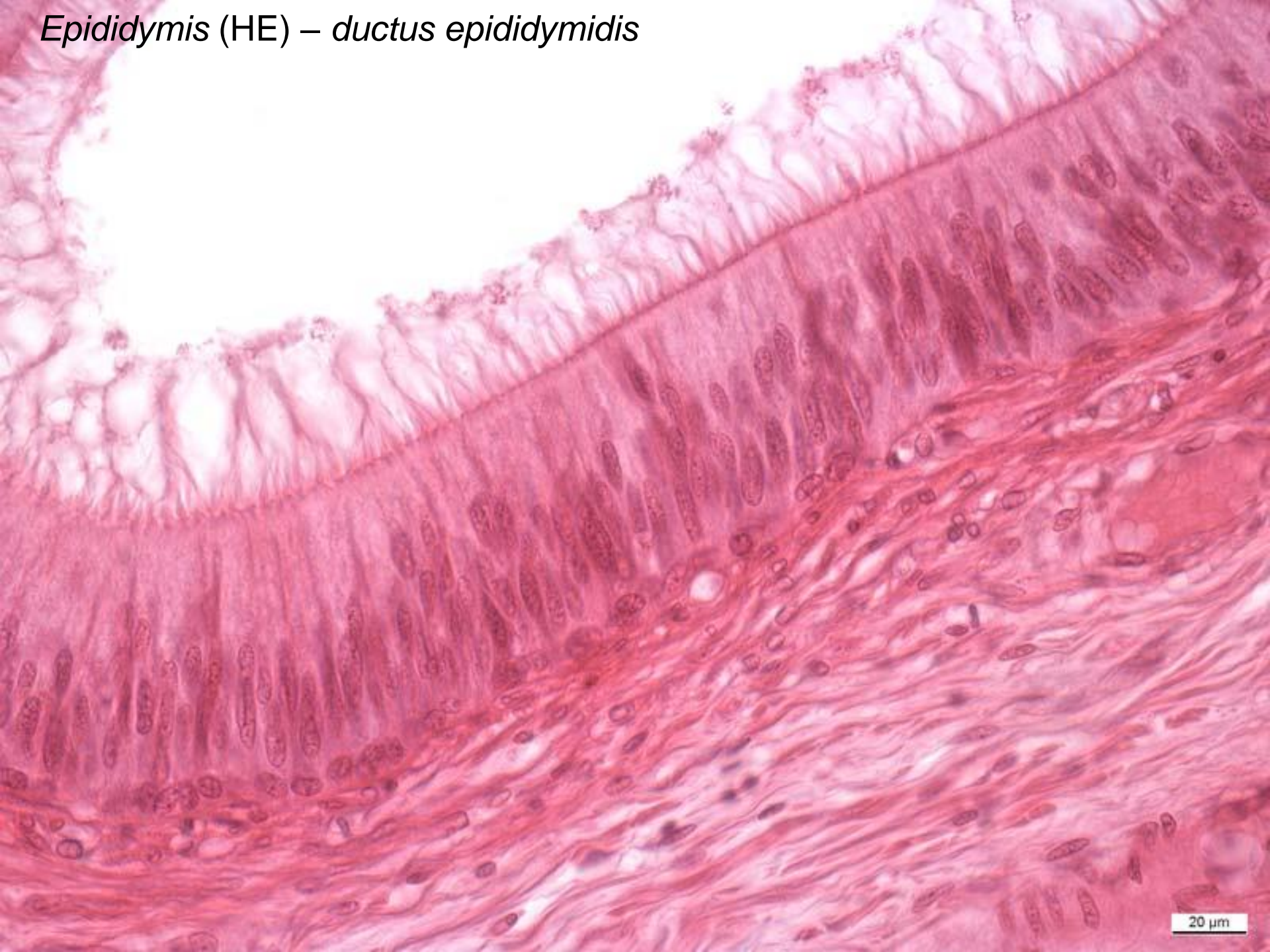*Ductuli efferentes*

*Ductus epididymidis*





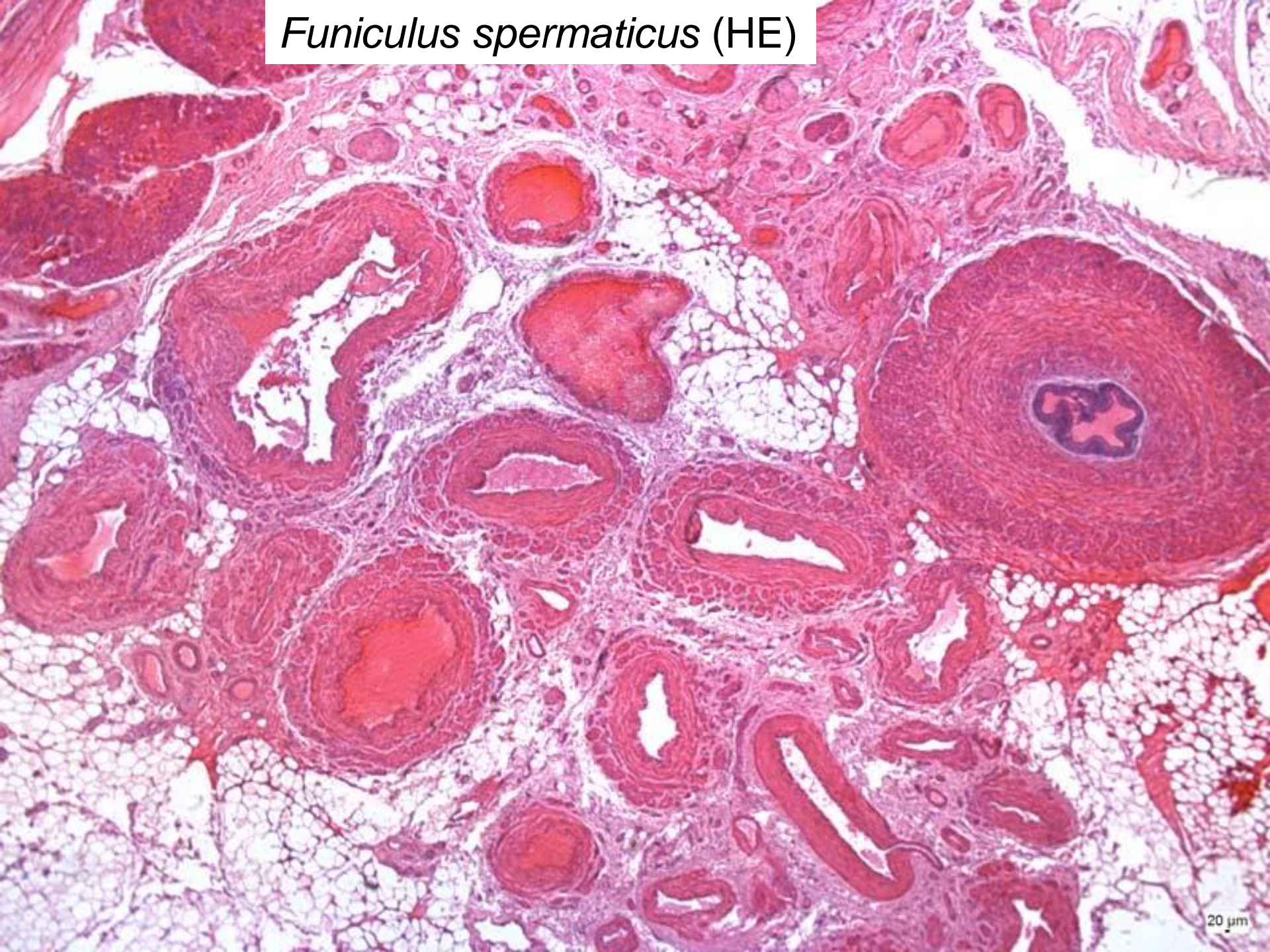
*Epididymis (HE) – ductus epididymidis*



20  $\mu$ m

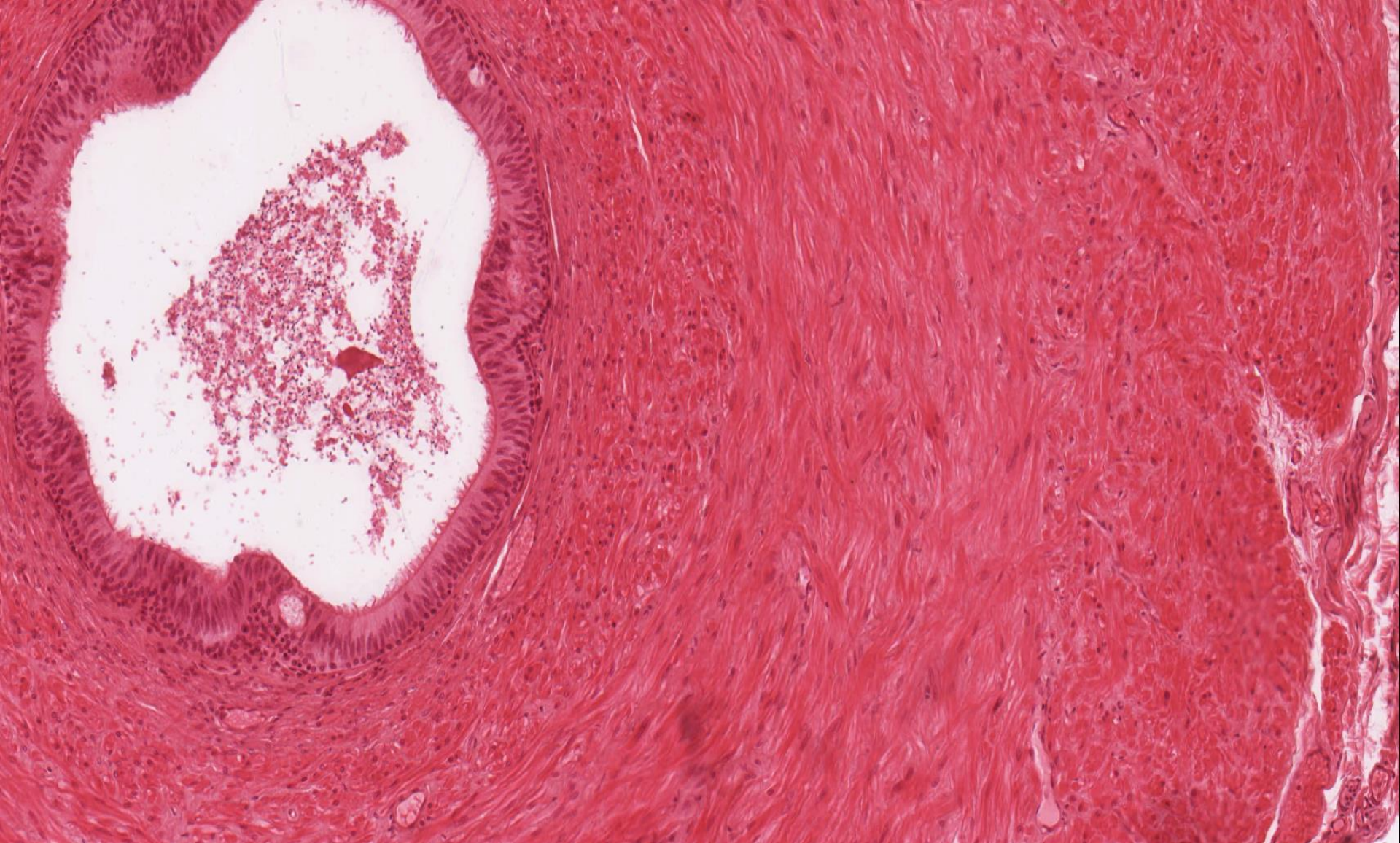


*Funiculus spermaticus* (HE)



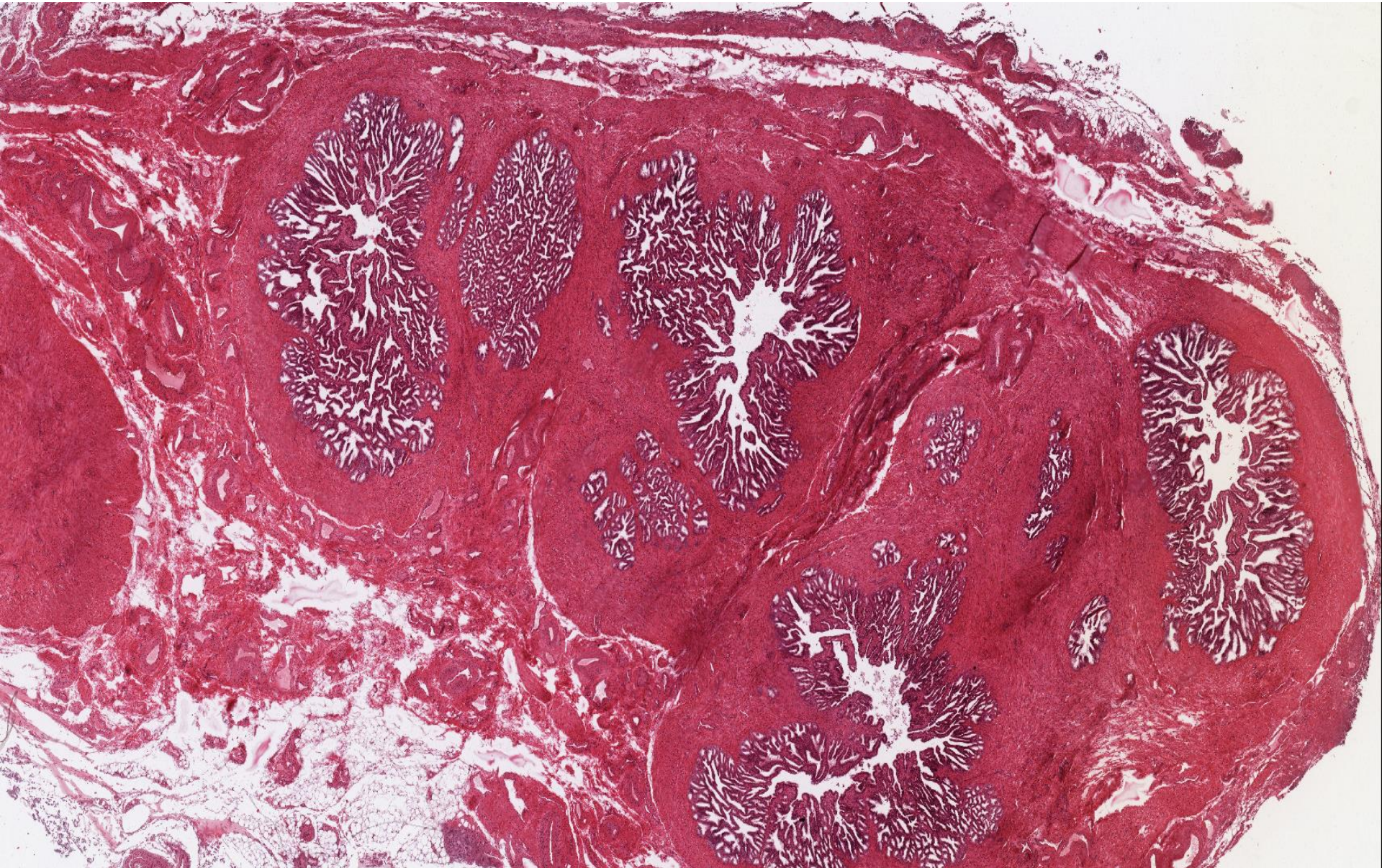


*Funiculus spermaticus (HE) – ductus deferens*



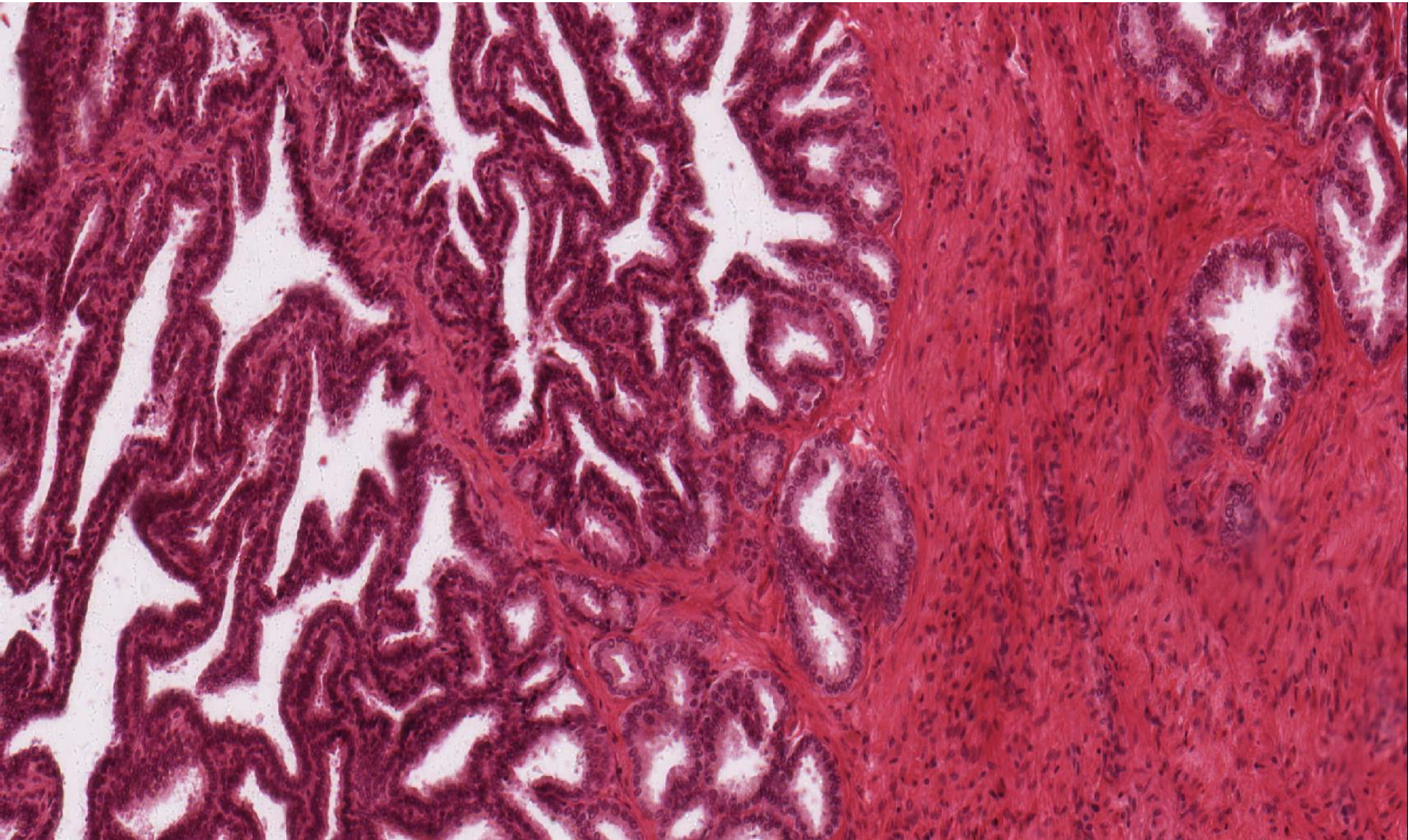


*Glandula vesiculosa* (HE)



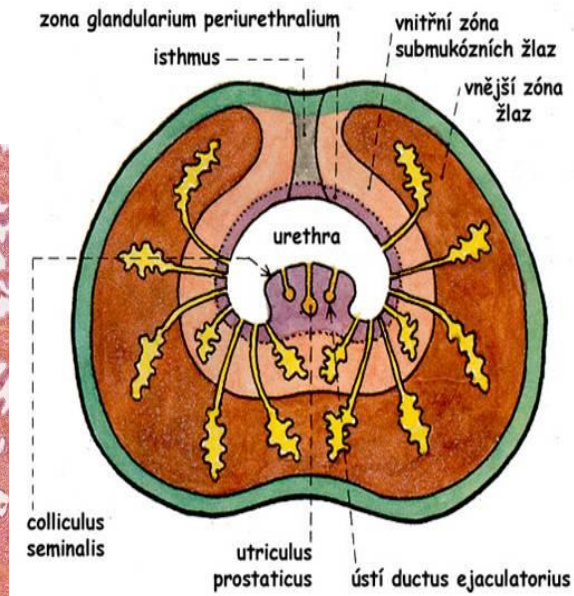
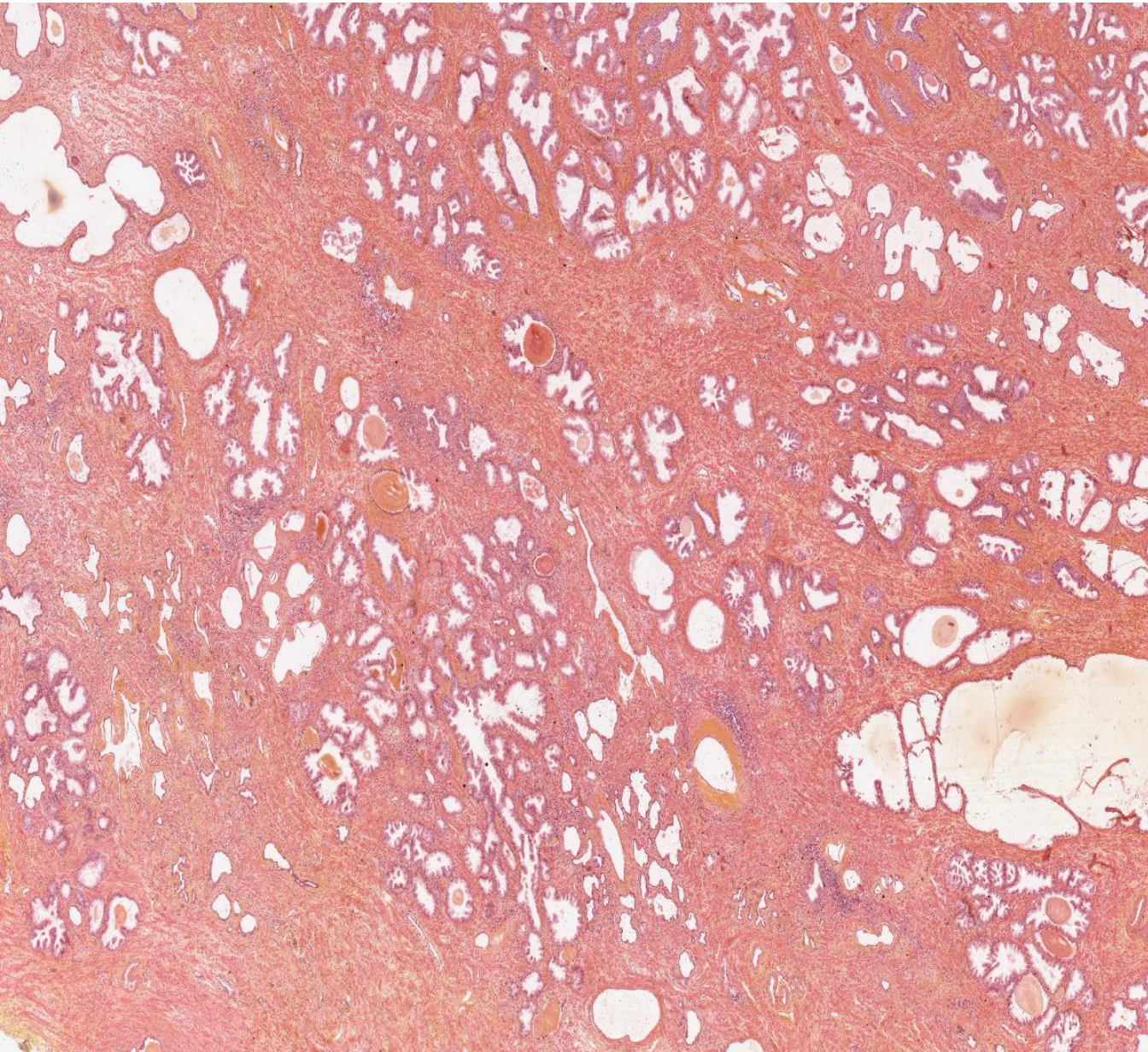


# Glandula vesiculosa (HE)



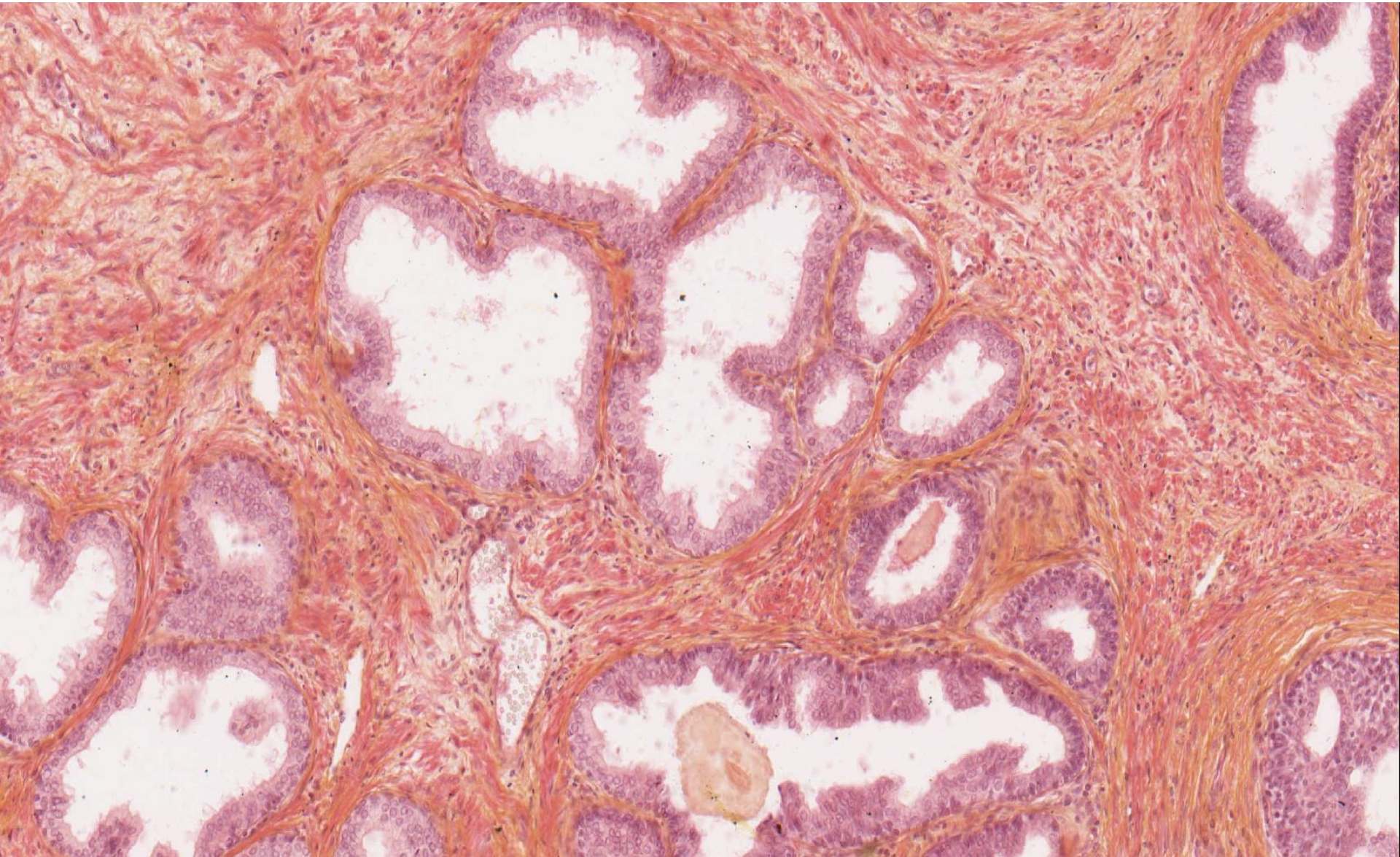


# Prostata (HEŠ)

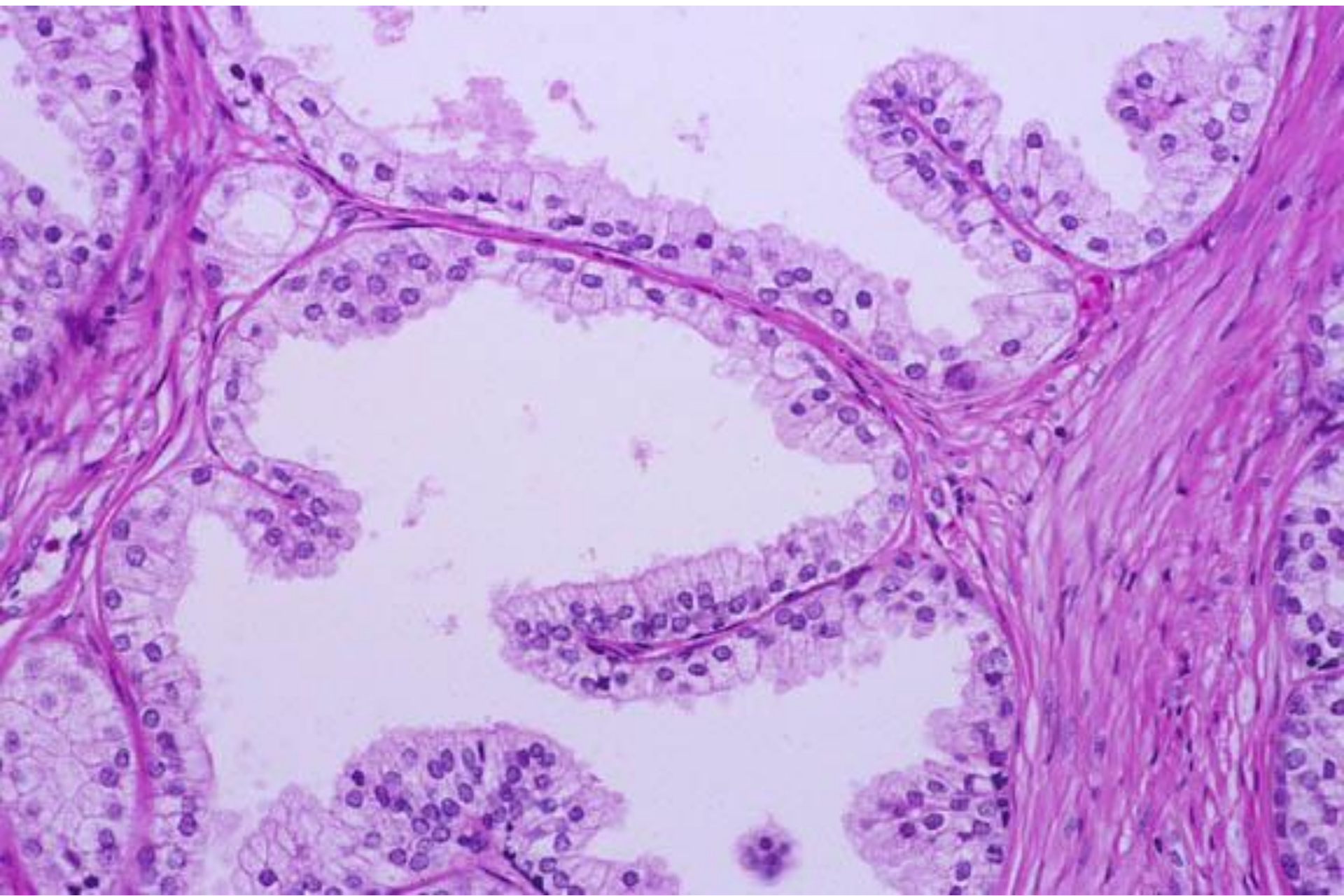




# Prostata (HEŠ)

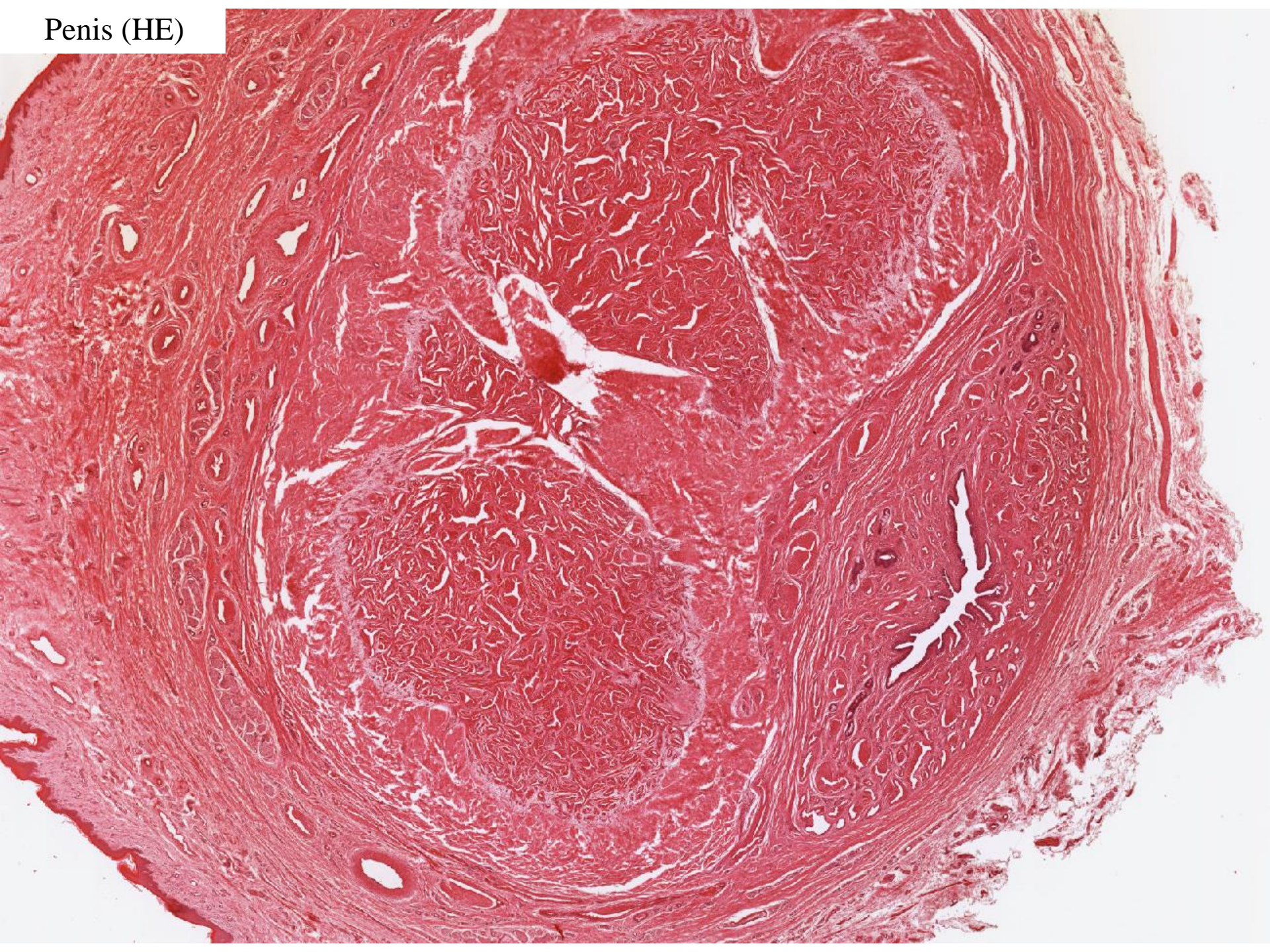






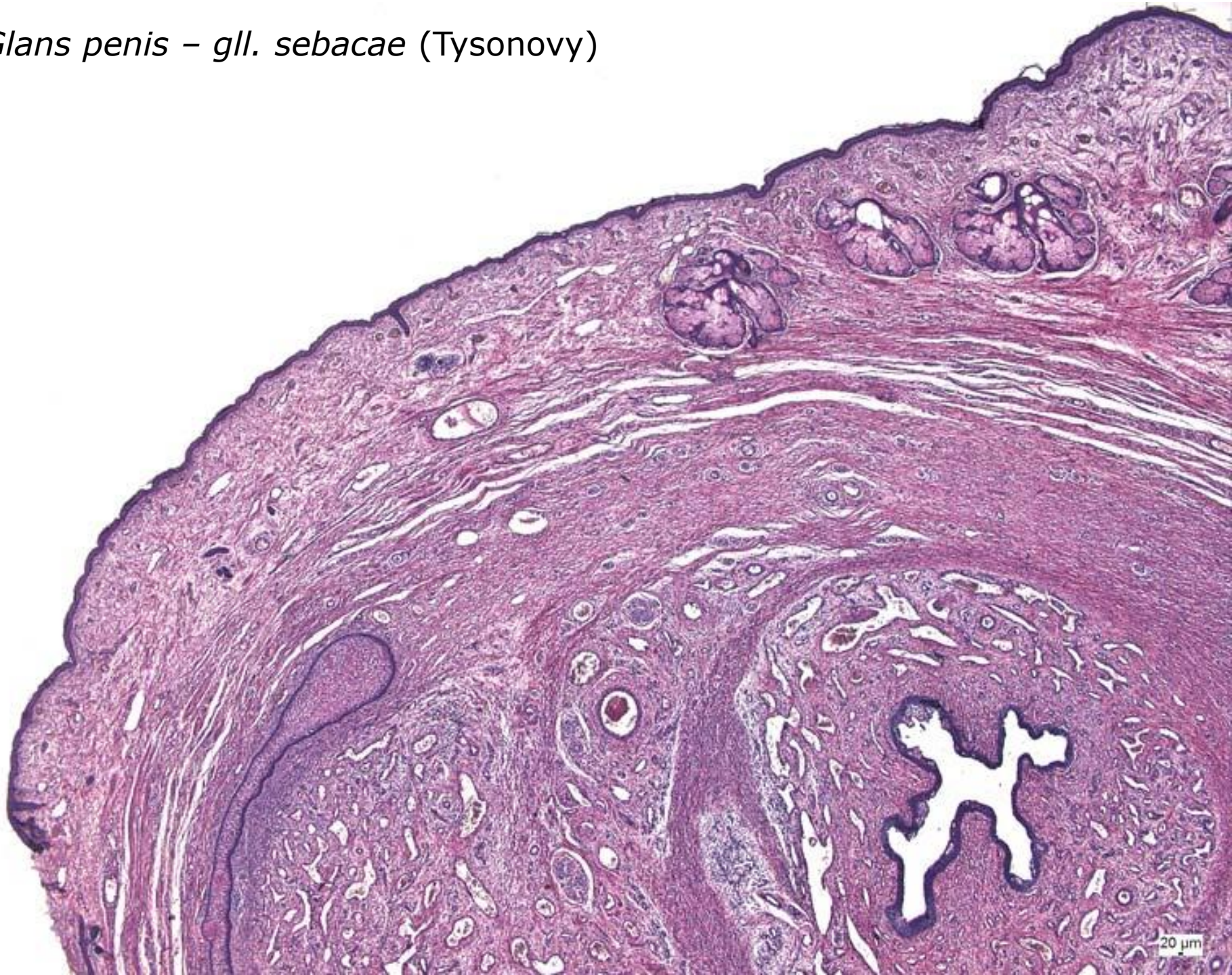

Penis (HE)



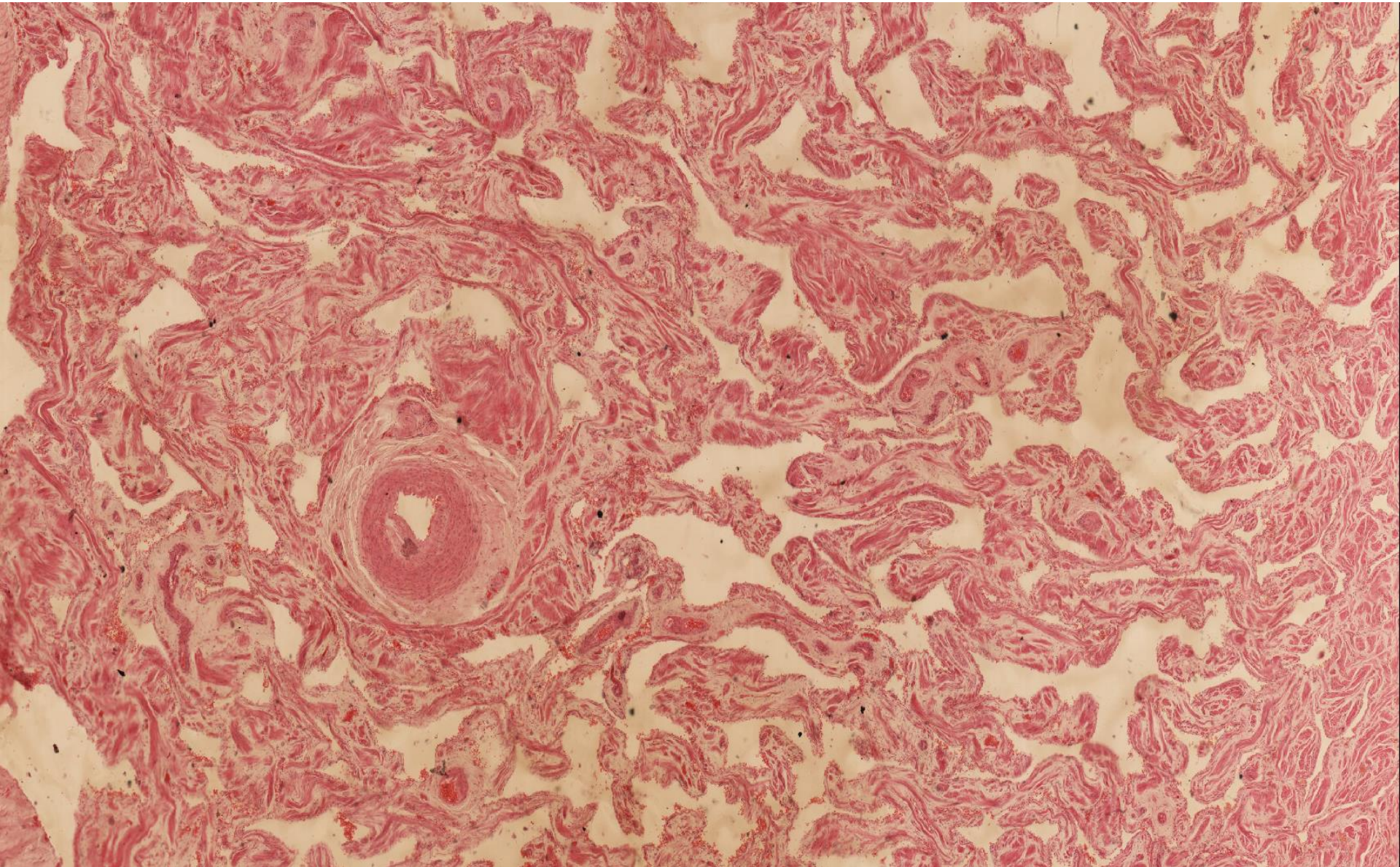


*Glans penis – gl. sebaciae (Tysonovy)*





*Penis – corpus cavernosum*





# Mužský pohlavní systém

## Preparáty:

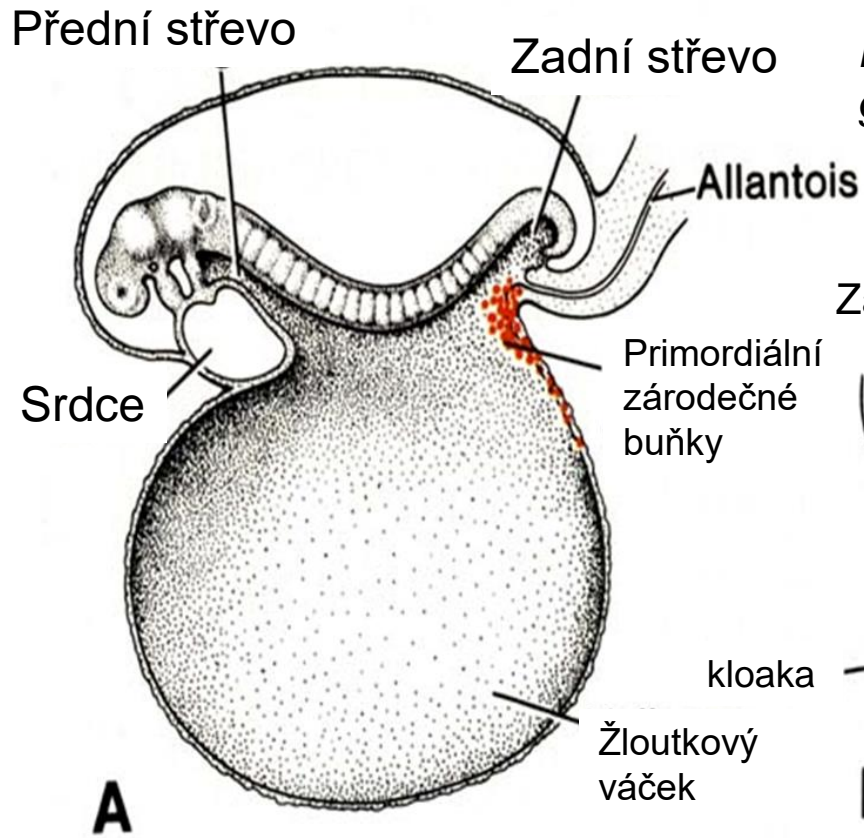
- 36. *Testis* (HE)
- 37. *Epididymis* (HE, HEŠ)
- 38. *Funiculus spermaticus* (HE)
- 39. *Glandula vesiculosa* (HE)
- 40. Prostata (HE)
- 41. Penis (HE)

## Atlas EM:

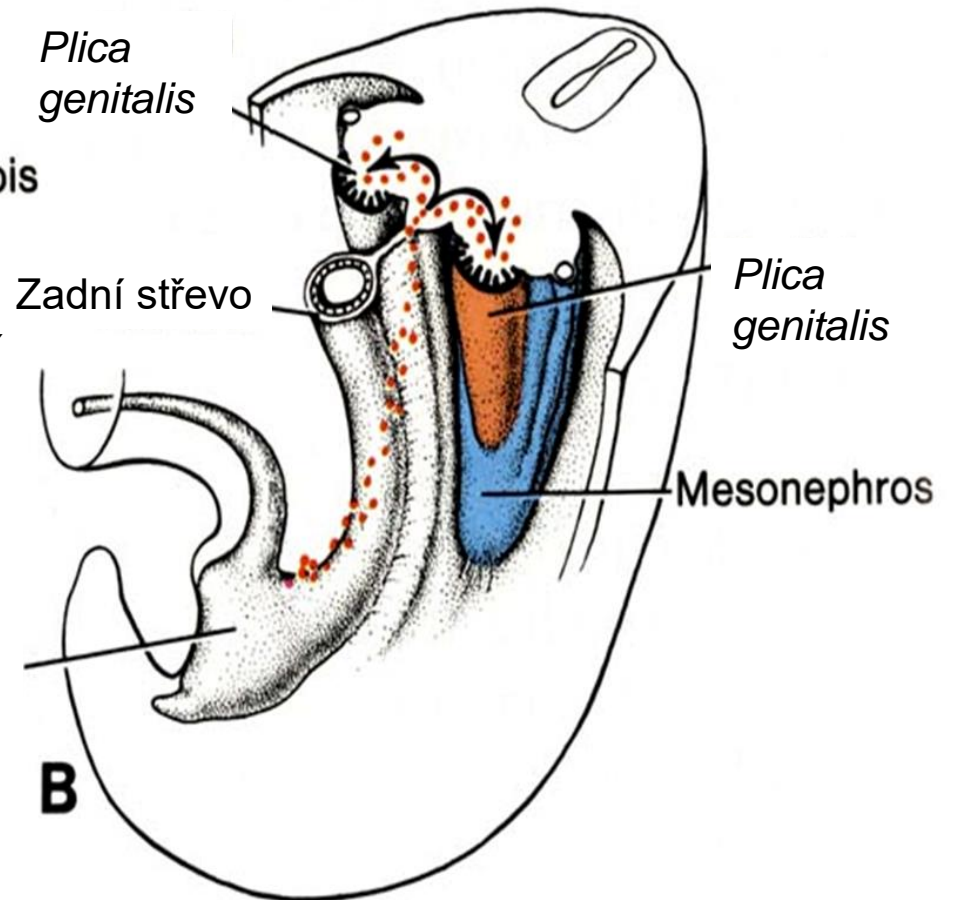
- Lidská spermie (71)
- Vývoj gonád (95)
- Vývoj vývodních pohlavních cest a zevních genitálií (96)



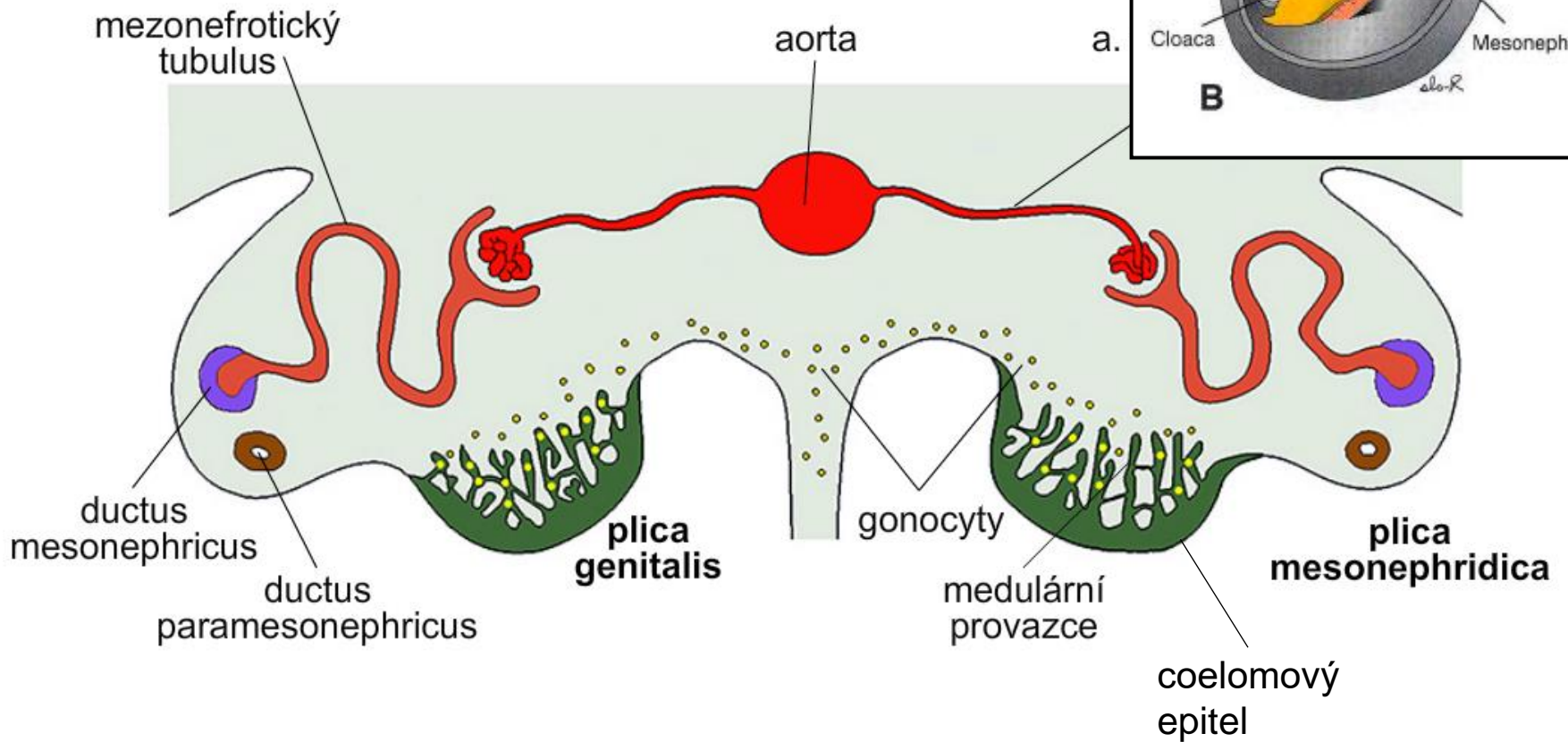
## 4. týden



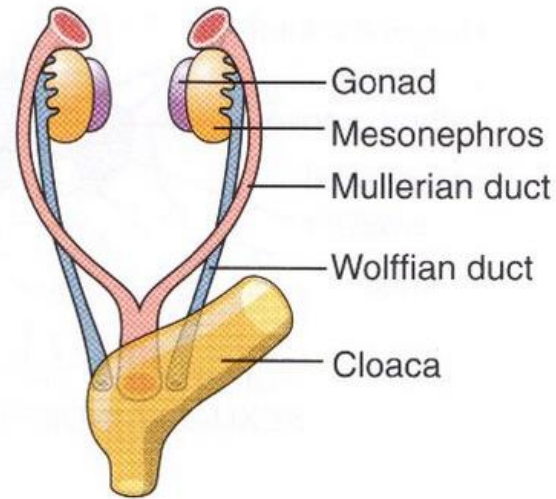
## 5. - 6. týden



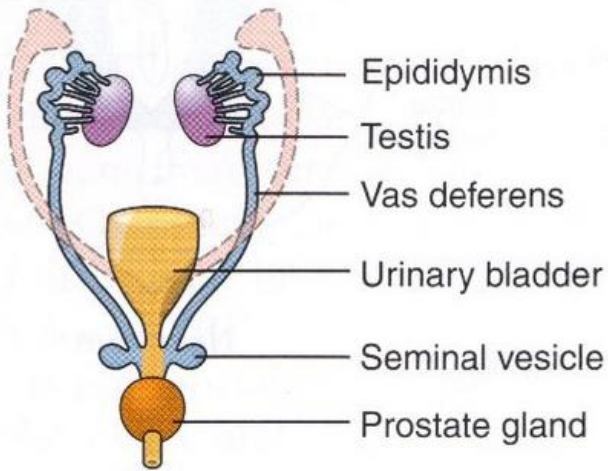




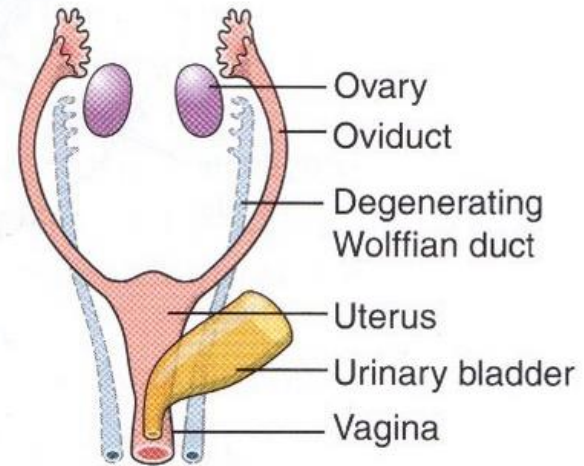




INDIFFERENT STAGE

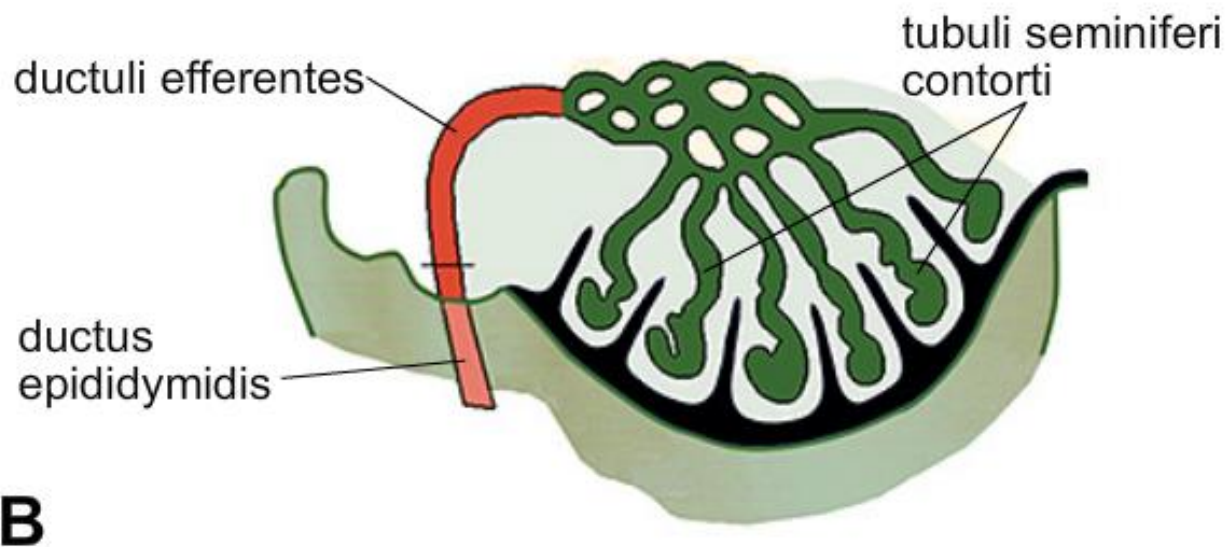
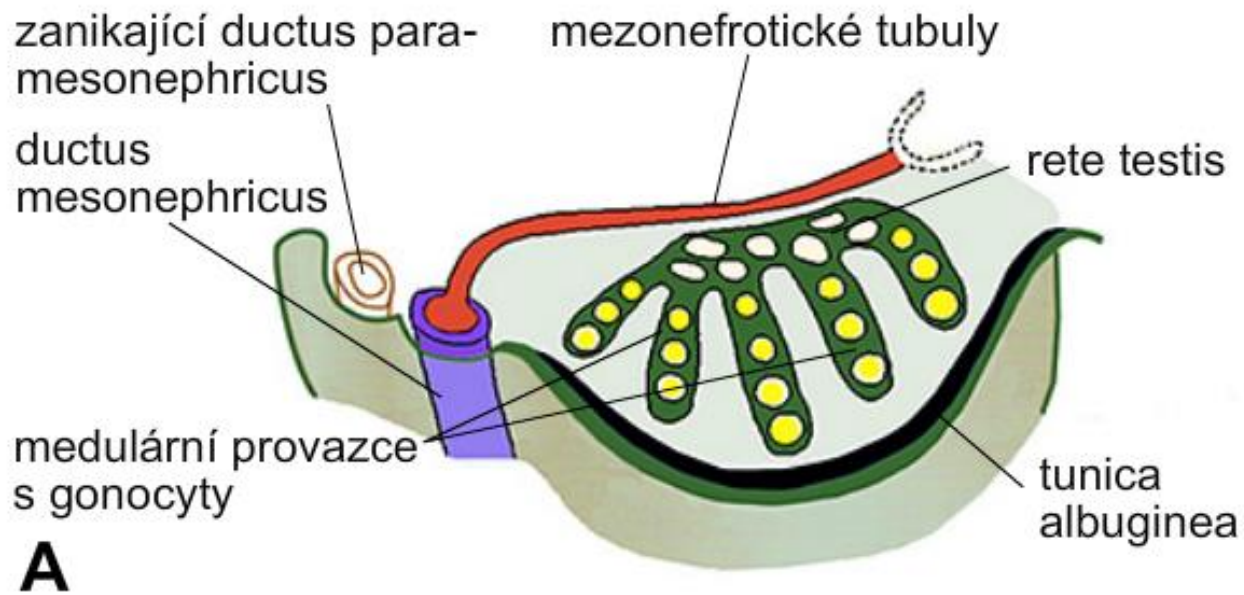


MALE



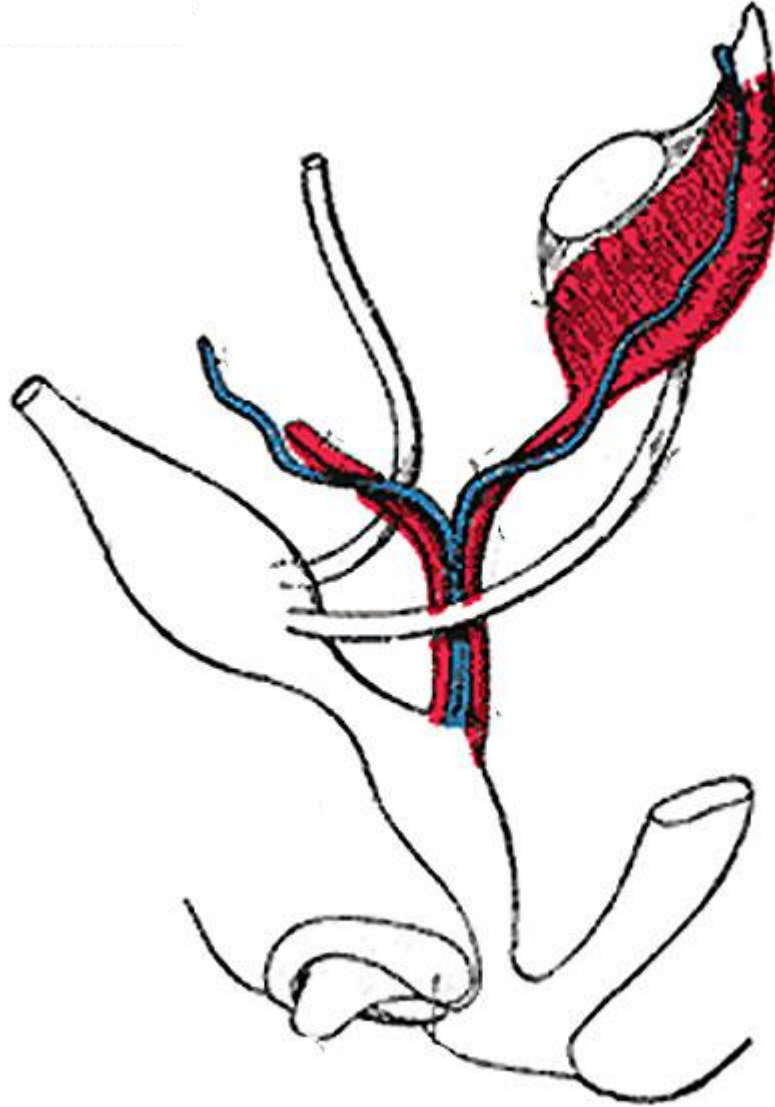
FEMALE



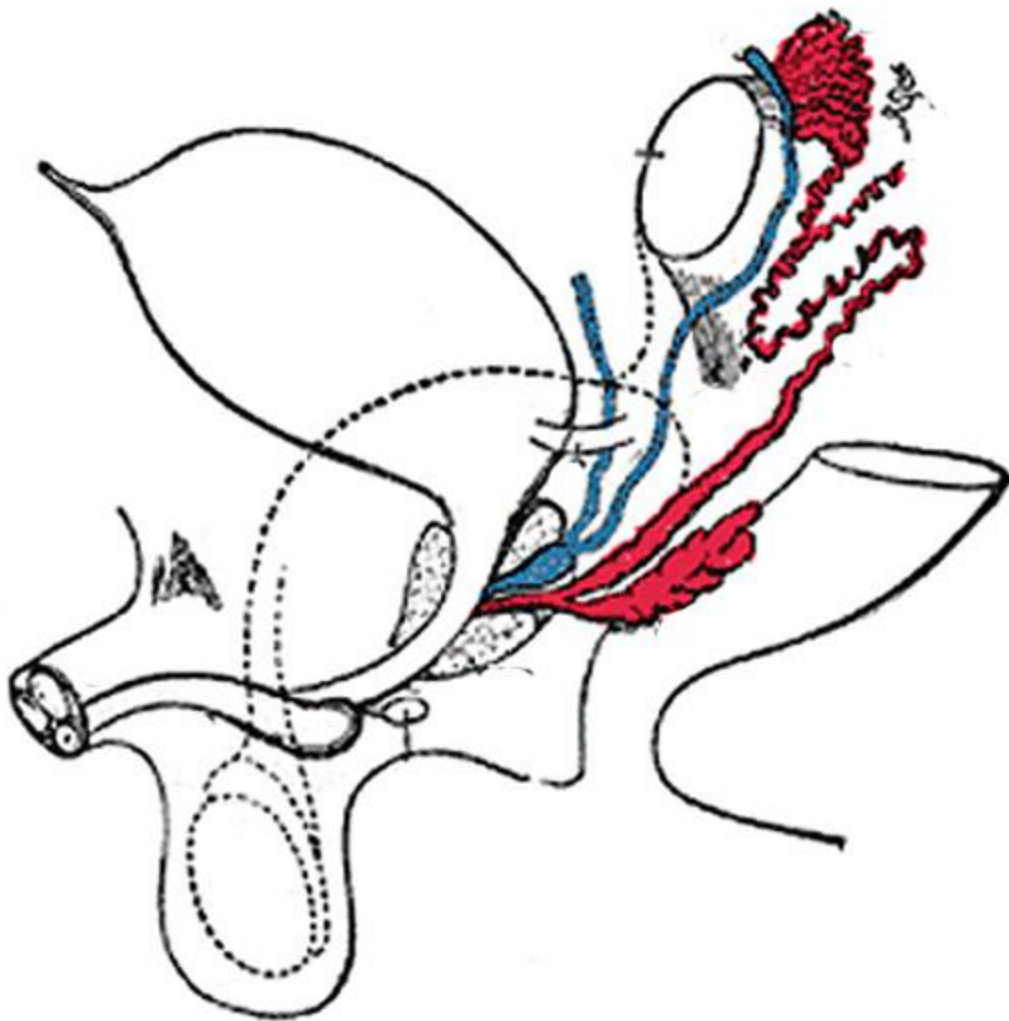




## Indiferentní stádium







Gray, Henry. Anatomy of the Human Body. Philadelphia: Lea & Febiger, 1918.



