

# Anatomy\_practice 2024

Lower extremity

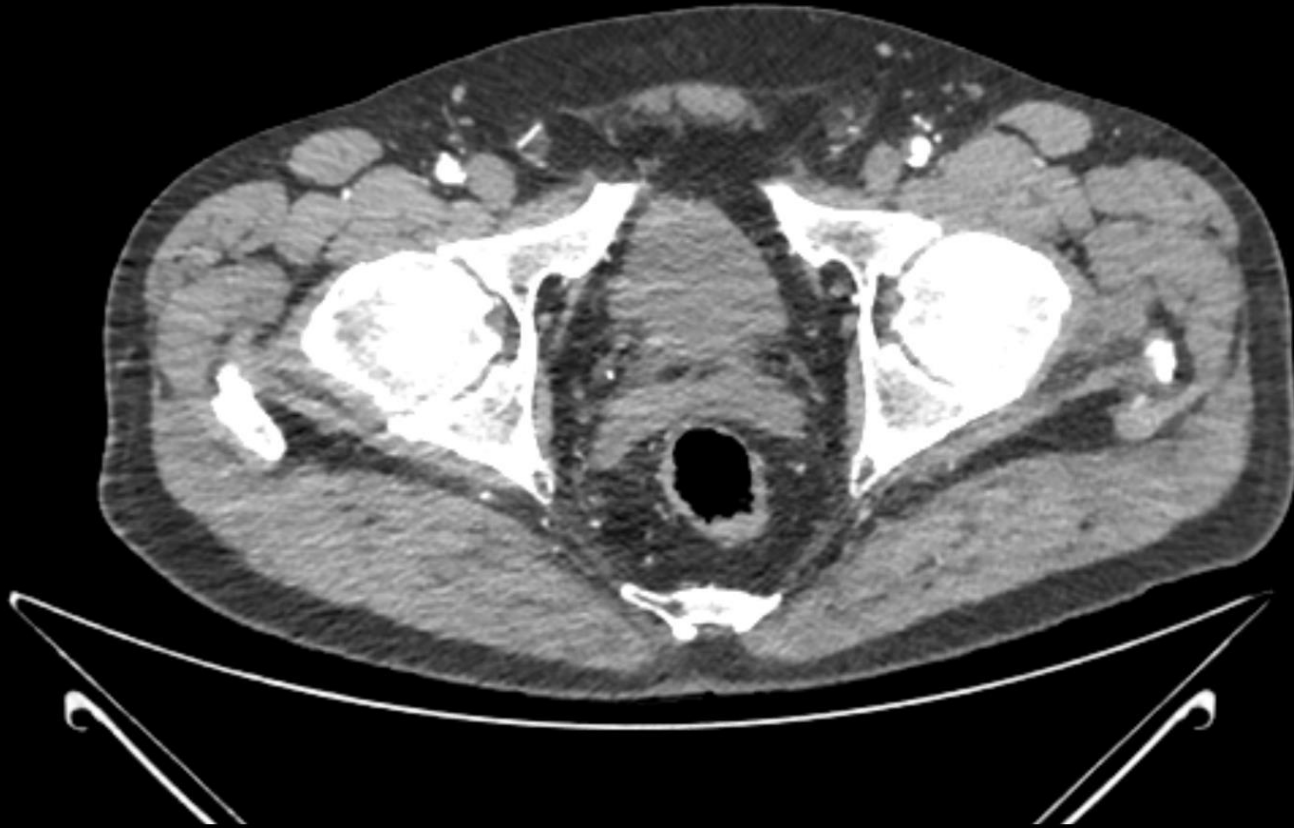## **Protocol**

1st part – presets\_CT/MRI

2nd part – table\_plastinates

1st part of the protocol \_ Anatomage table

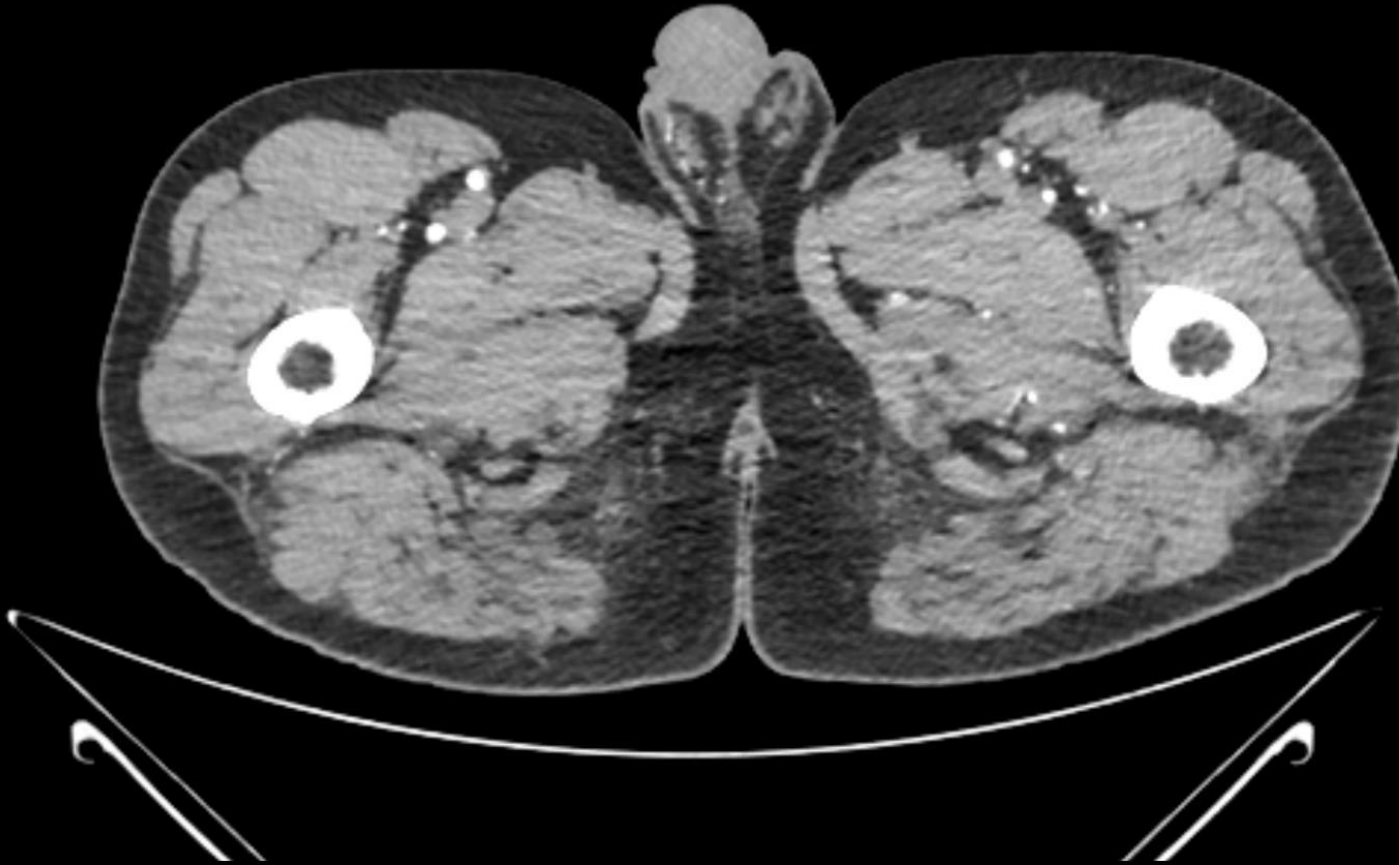Find the six listed structures on the selected CT/MRI images/presets and mark them with its number from the list.



1. Pelvitrochanteric muscles dx.
2. M. gluteus medius dx.
3. M. rectus femoris dx.
4. M. iliopsoas dx.
5. M. pectineus dx.
6. V. femoralis dx.

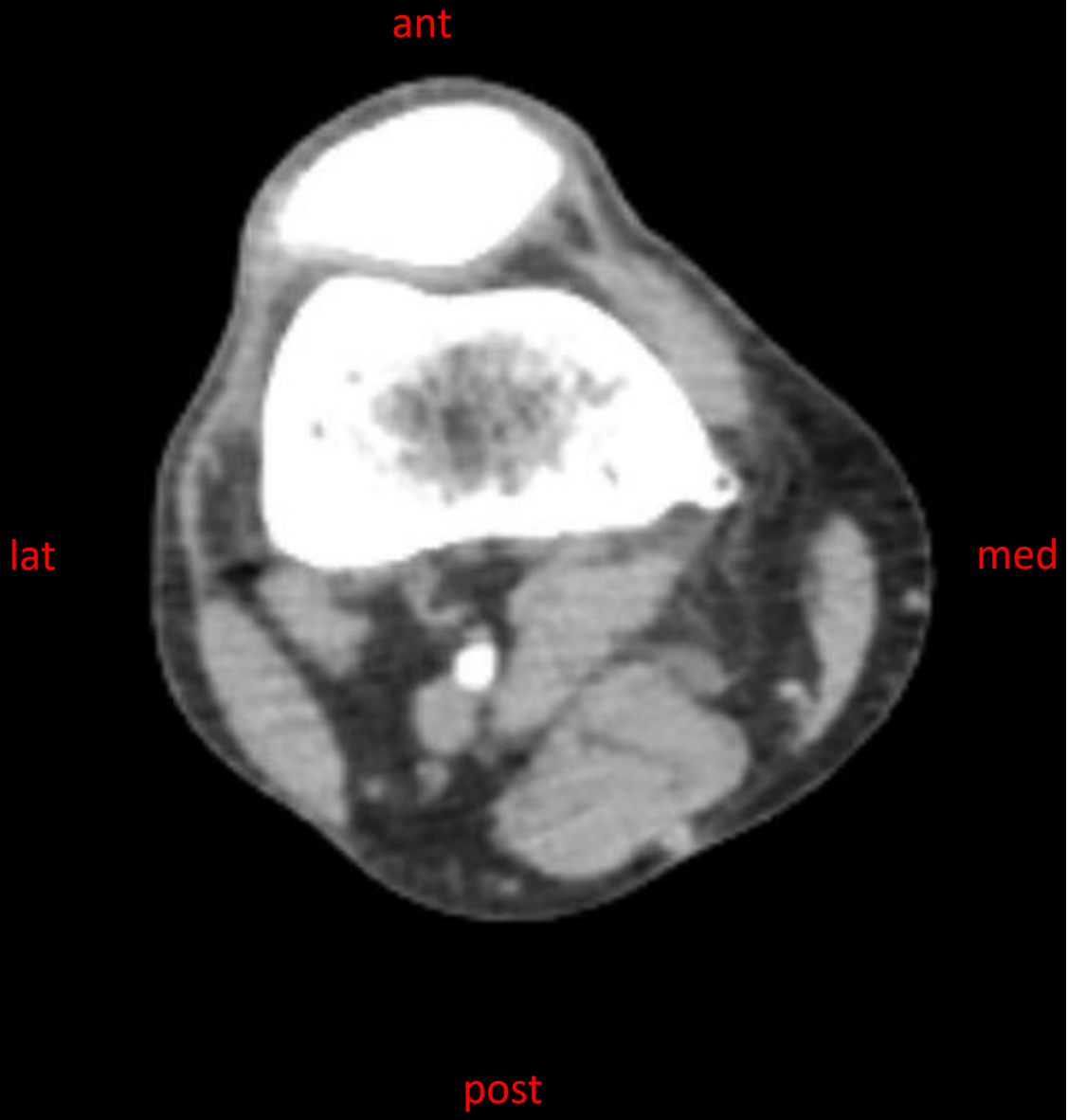## CTAG – preset 401

R



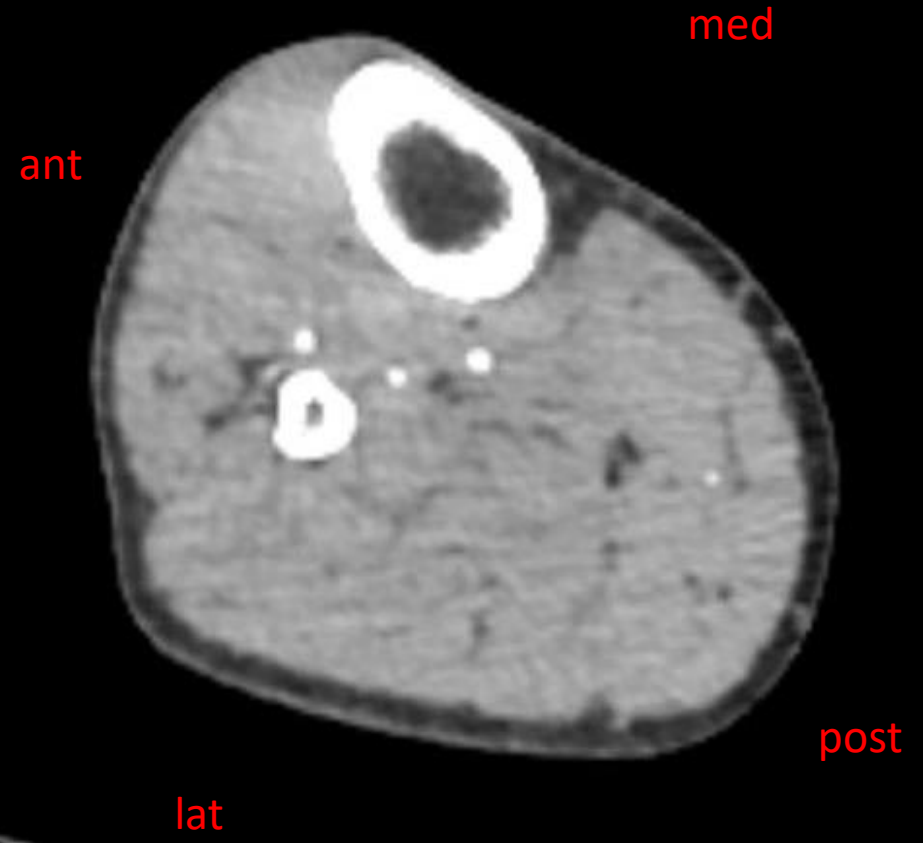1. A. profunda femoris dx.
2. M. tensor fasciae latae dx.
3. M. sartorius dx.
4. M. vastus medialis dx.
5. M. gracilis dx.
6. Mm. femoris posteriores dx.

CTAG – preset 402



- 1. M. biceps femoris
- 2. N. tibialis
- 3. M. semimembranosus
- 4. M. semitendinosus
- 5. M. gracilis
- 6. V. spahena magna

CTAG – preset 405



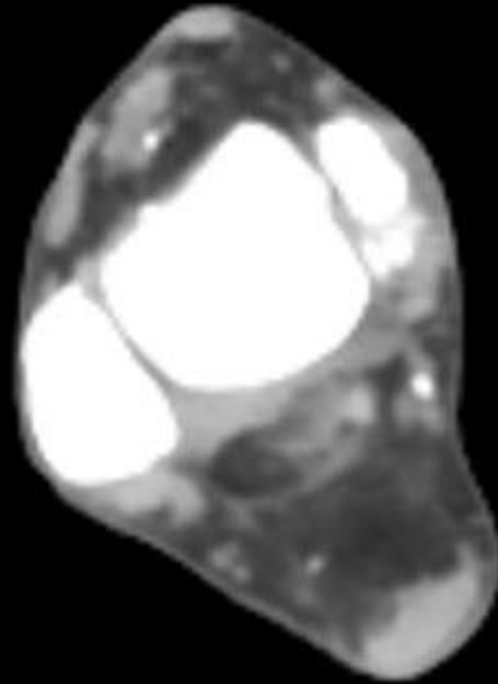
- 1. M. tibialis anterior
- 2. A. tibialis anterior
- 3. M. fibularis longus
- 4. A. tibialis posterior
- 5. A. fibularis
- 6. M. soleus

ant

med

lat

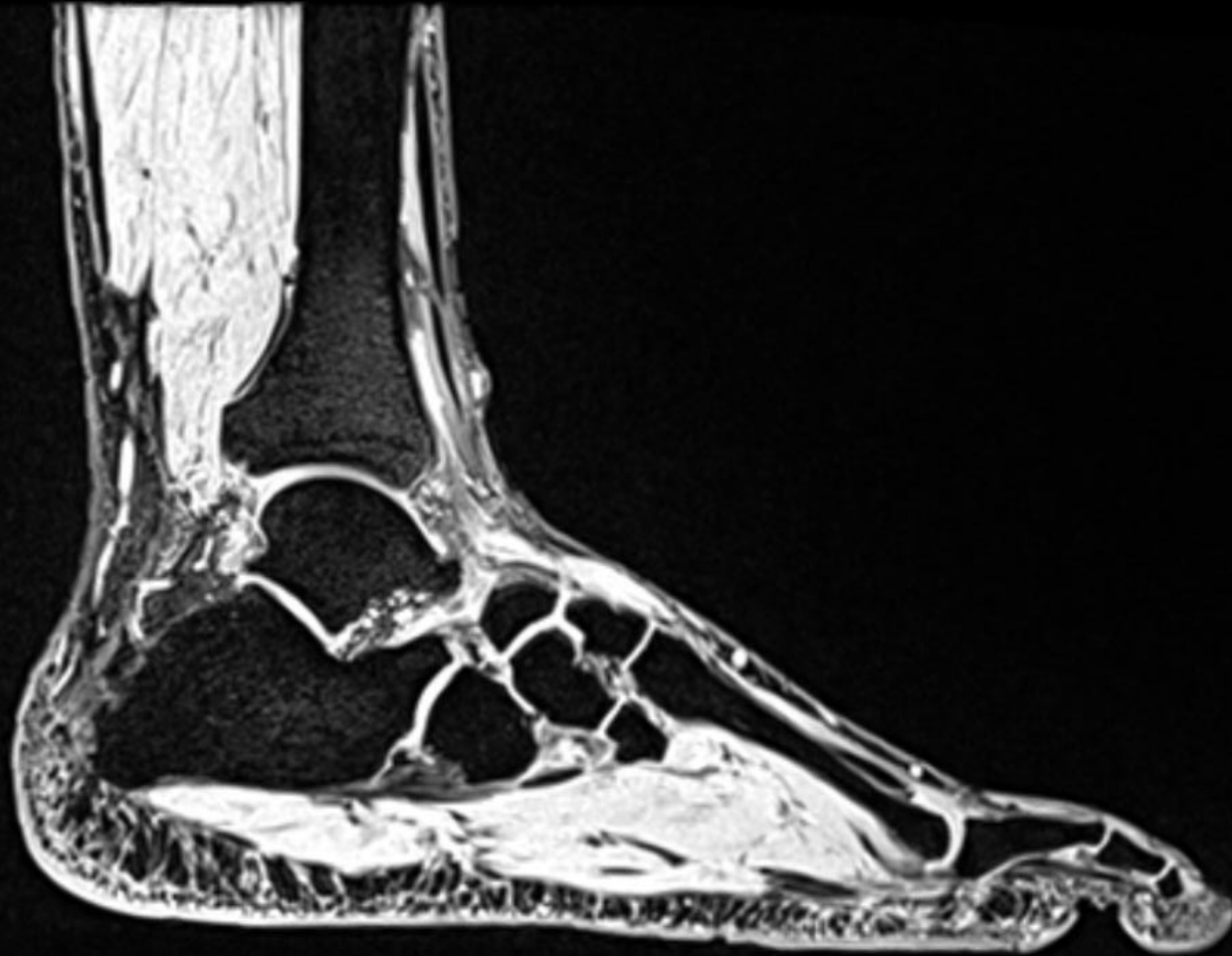
post



1. A. dorsalis pedis
2. M. extensor digitorum longus
3. Mm. fibulares
4. Maleollus medialis
5. M. flexor hallucis longus
6. A. tibialis posterior

## MRI - foot

Preset 3



1. M. flexor digitorum brevis
2. M. abductor digiti minimi
3. Lig. plantare longum
4. Os cuboideum
5. A. tarsalis lateralis
6. M. flexor hallucis longus



2nd part of the protocol\_plastinates of the lower extremity:

Fill the structures according to the numbers in selected plastinates of transversal sections:

- |     |     |
|-----|-----|
| 1.  | 19. |
| 2.  | 20. |
| 3.  | 21. |
| 4.  | 22. |
| 5.  | 23. |
| 6.  | 24. |
| 7.  | 25. |
| 8.  | 26. |
| 9.  | 27. |
| 10. | 28. |
| 11. | 29. |
| 12. | 30. |
| 13. | 31. |
| 14. | 32. |
| 15. | 33. |
| 16. | 34. |
| 17. | 35. |
| 18. | 36. |