

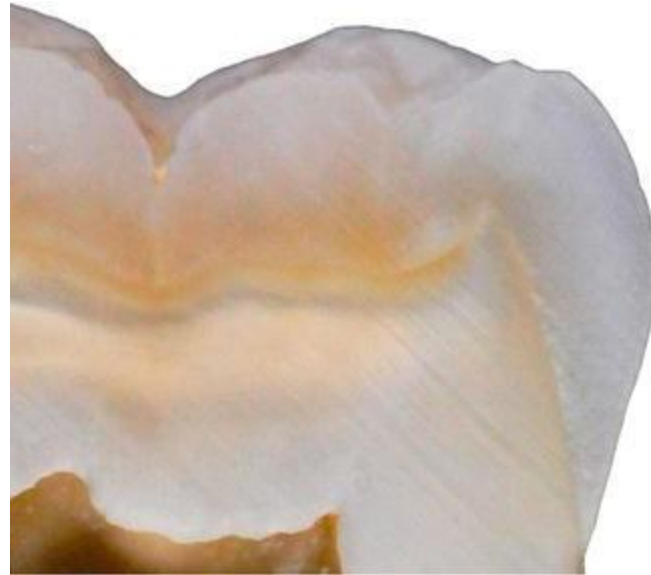
Evolutionary Medicine

Miriam Nývltová Fišáková

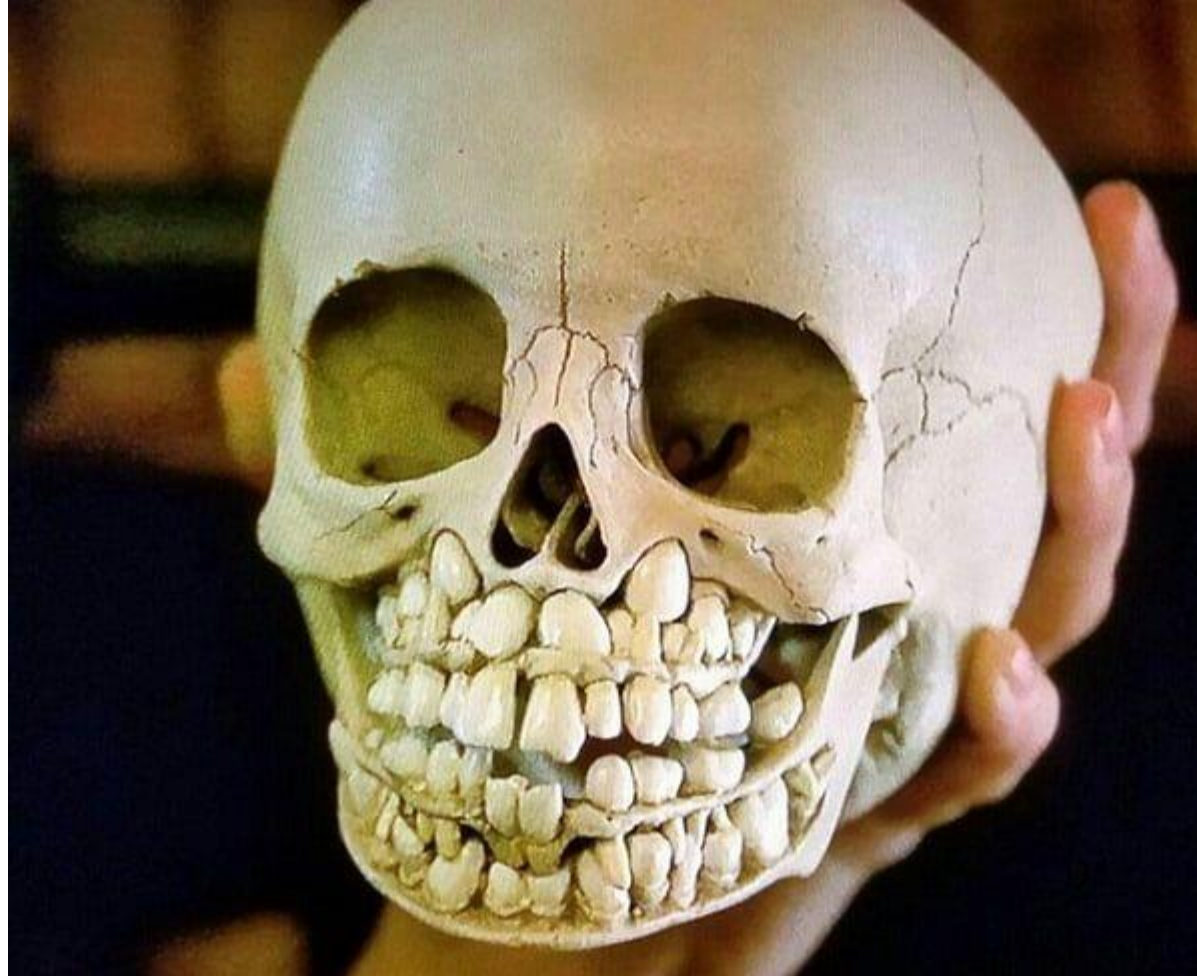
Department of Physiology



Developmental, evolutionary and behavioural perspectives on oral health



Childhood



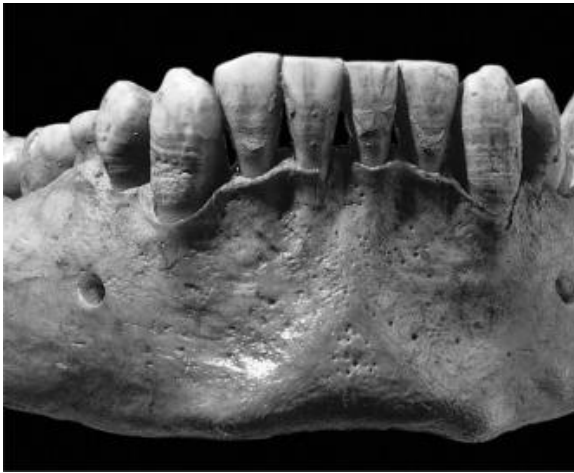Childhood

- The eruption and subsequent loss of baby teeth are important milestones in childhood. In traditional societies, complementary foods are introduced to children between 4 and 6 months of age, when the first teeth appear (see Sellen and Smay, 2001)
- During this period, the child begins to taste everything and puts everything in his mouth. During this period, the child's immunity begins to build up massively. The immunity obtained from breast milk protects him from pathogens
- The problem arises when a child does not have access to good quality, clean, drinkable water.

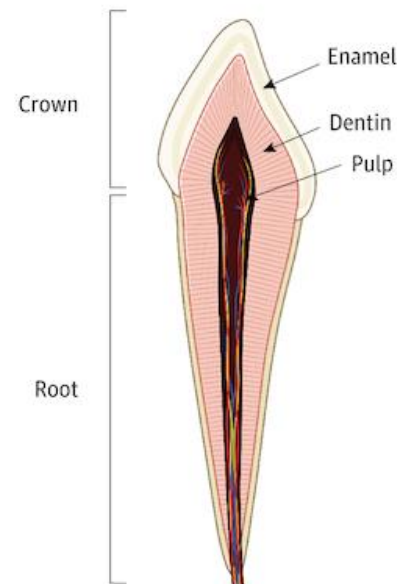


Developmental disruption begin at birth

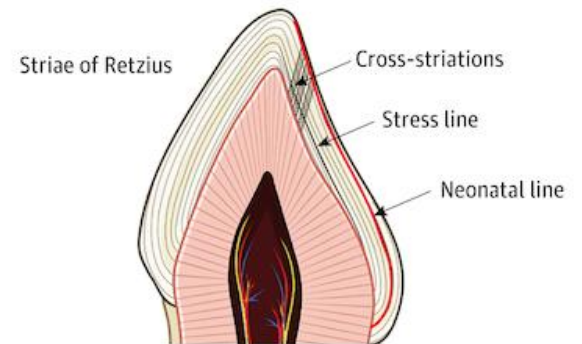
- Permanent teeth begin to calcify in utero, such as the first molar (see Massler et al., 1941). This allows these teeth to demonstrate the precise position of dentin and enamel at birth—the neonatal line. This distinct line separates the anterior and posterior periods, and allows us to track the daily increments of dentin and to monitor problems during the development of the child's teeth.
- From the neonatal line, it can be determined whether the child was born at term or prematurely.
- Since enamel is mainly mineralized between birth and 6 years of age, we can monitor its development in early childhood. If there is any disturbance, it will manifest itself with the formation of hypoplasia.



A Main tissues



B Growth lines

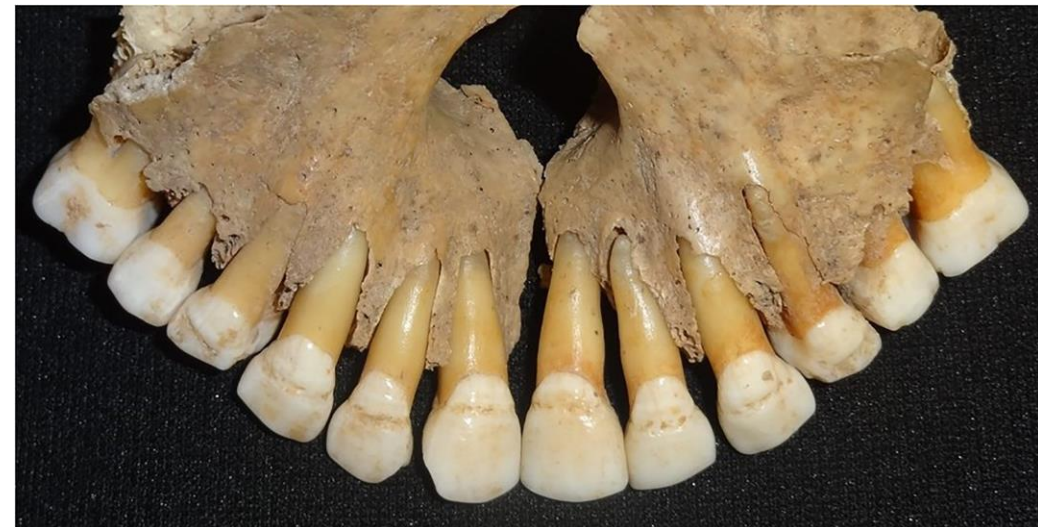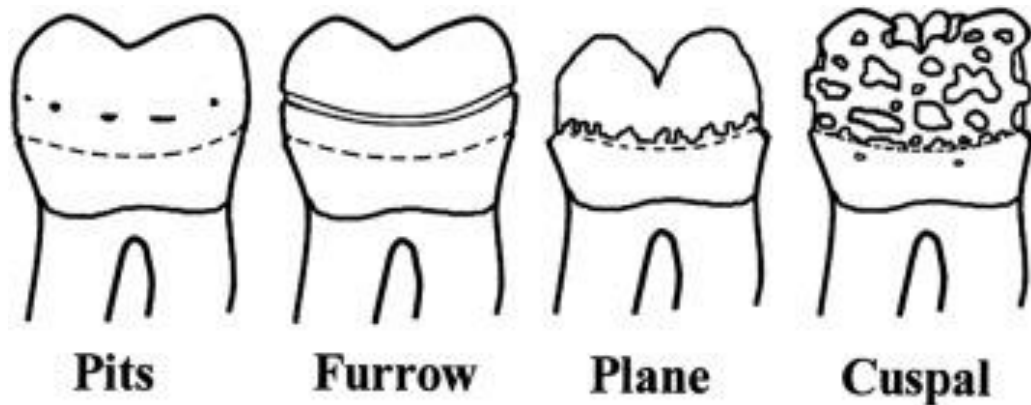


C Neonatal line



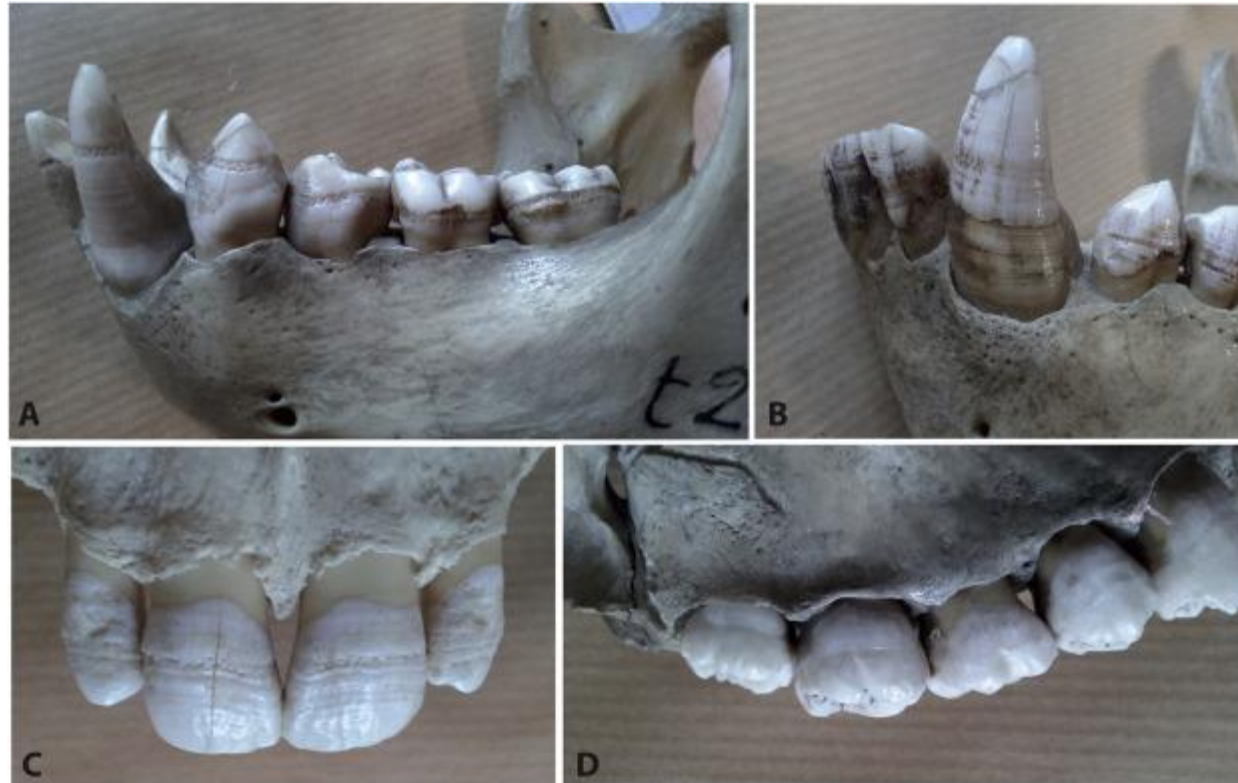Hypoplasia

Enamel hypoplasia is a defect of the teeth in which the enamel is deficient in quantity, caused by defective enamel matrix formation during enamel development, as a result of inherited and acquired systemic condition(s). It can be identified as missing tooth structure and may manifest as pits or grooves in the crown of the affected teeth, and in extreme cases, some portions of the crown of the tooth may have no enamel, exposing the dentin. It may be generalized across the dentition or localized to a few teeth. Defects are categorized by shape or location. Common categories are pit-form, plane-form, linear-form, and localised enamel hypoplasia. Hypoplastic lesions are found in areas of the teeth where the enamel was being actively formed during a systemic or local disturbance. Since the formation of enamel extends over a long period of time, defects may be confined to one well-defined area of the affected teeth. Knowledge of chronological development of deciduous and permanent teeth makes it possible to determine the approximate time at which the developmental disturbance occurred



Hypoplasia

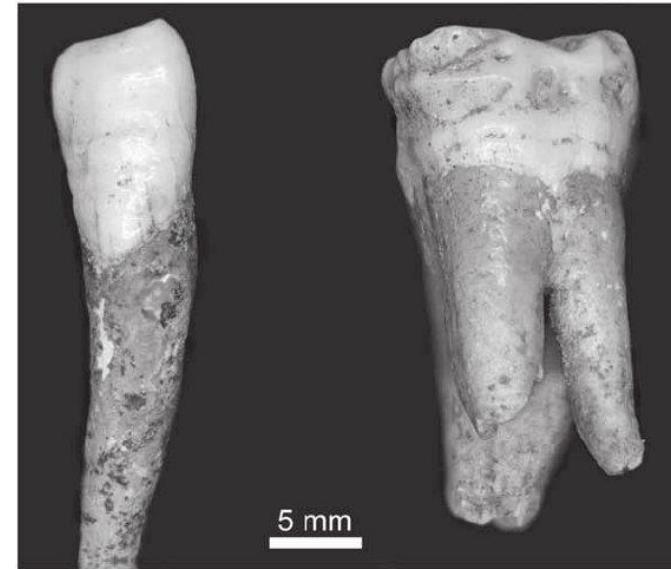Hypoplasia was more common in the past in pre-industrial times, and it also occurs in animals and apes.



Fossil *Pongo* sp.

Hypoplasia

- Hypoplasia refers to the following causes: specific diseases or syndromes, nutritional deficiencies, and physical or psychological stress.
- We have information about this from laboratory animals or primates with quality veterinary care.
- Hypoplasia has been reported in apes when gorillas were captured in the wild and brought into captivity.
- A similar case was recorded in a non-human primates in the case of tail loss.
- It was previously thought that stressful conditions in childhood limited later life in adulthood, but this has turned out to be not entirely true. It turns out that we do not fully understand all the conditions and etiology associated with this.




Hypoplasia

- another reason for hypoplasia is a lack of vitamin D, especially at higher altitudes and during the industrial revolution in the 19th century, when there was poor access to sunlight mainly in cities due to smog
- lack of vitamin D led to a lack of fluoride and to the invasion of the organism by parasites, thus causing hypoplasia
- hypoplasia was common in children born with syphilis
- it is also thought that hypoplasia occurs during weaning and transition to solid foods. This has not been proven, but in primates this correlates



Hypoplasia

The greatest increase in hypoplasia was recorded in the Neolithic period during the transition from a hunter-gatherer lifestyle to agriculture, when cereals and other plants became more common. There was also a significant increase in the population and the concentration of people in one place together with animals, and this led to the spread of diseases.



Hypoplasia

Hypoplasia also occurs when there is social contact between two different populations, e.g. between Europeans and Aborigines.



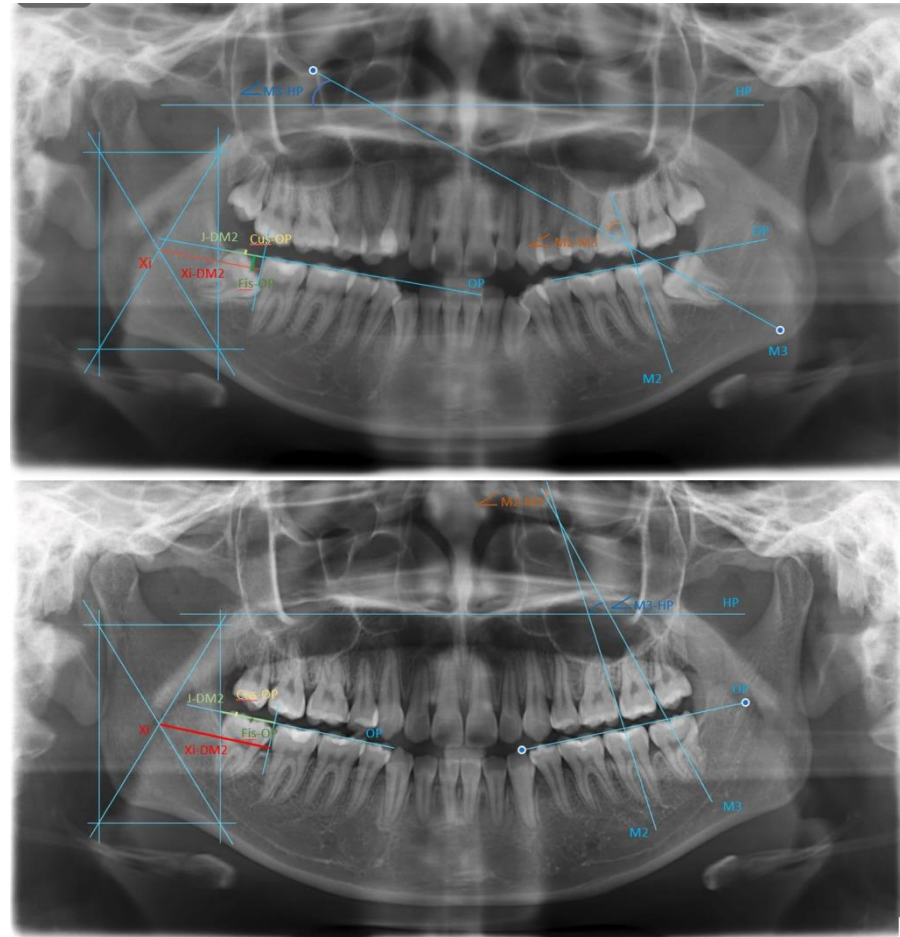
Hypoplasia

Hypoplasia is not necessarily caused by malnutrition, but rather by a weaker immune system due to malnutrition and the subsequent development of hypoplasia.



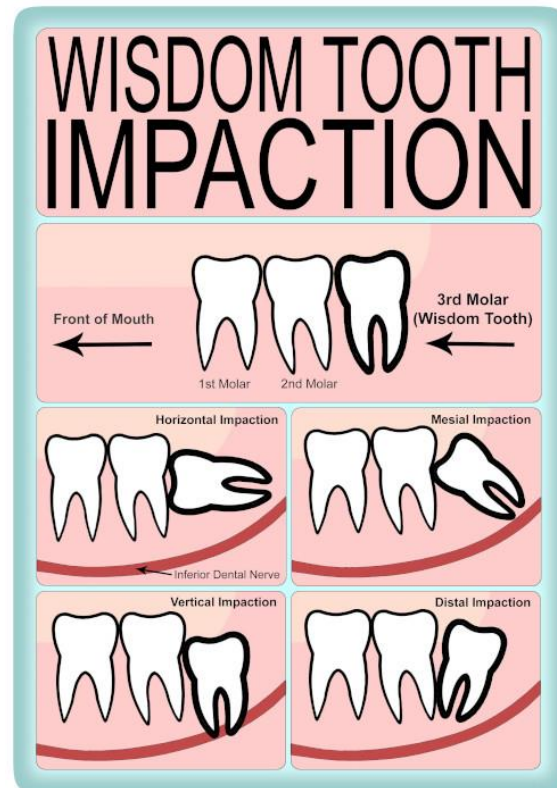
Those pesky wisdom teeth

There are two problems with wisdom teeth in the current population. One is complete absence or a problem with decay, and the other is poor growth.



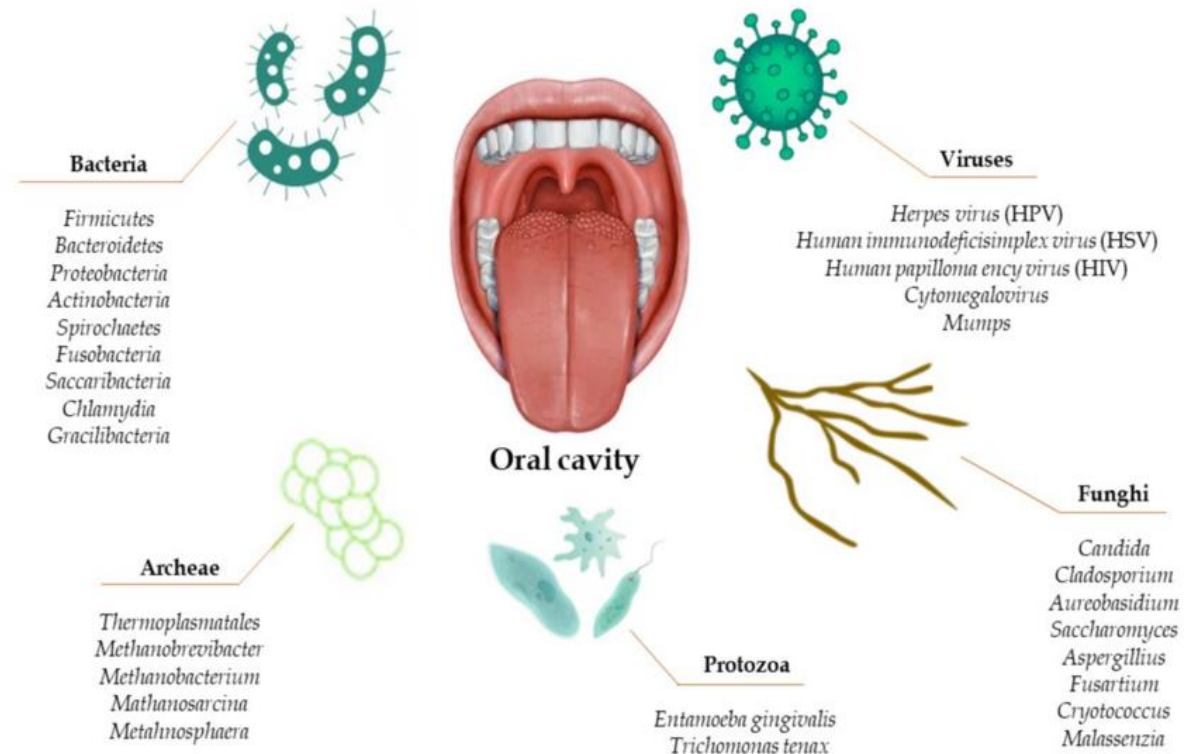
Those pesky wisdom teeth

- The absence of third molars, or their poor growth, is explained by the fact that during evolution, humans' jaws became smaller because they no longer needed to chew solid food, and therefore we have weaker chewing muscles and no longer need the last molars
- An alternative hypothesis is that the absence of wisdom teeth is an evolutionary advantage, as these teeth are often subject to decay and infection. These infections are very dangerous, being close to the head, heart and brain, and are also more likely to result in death.

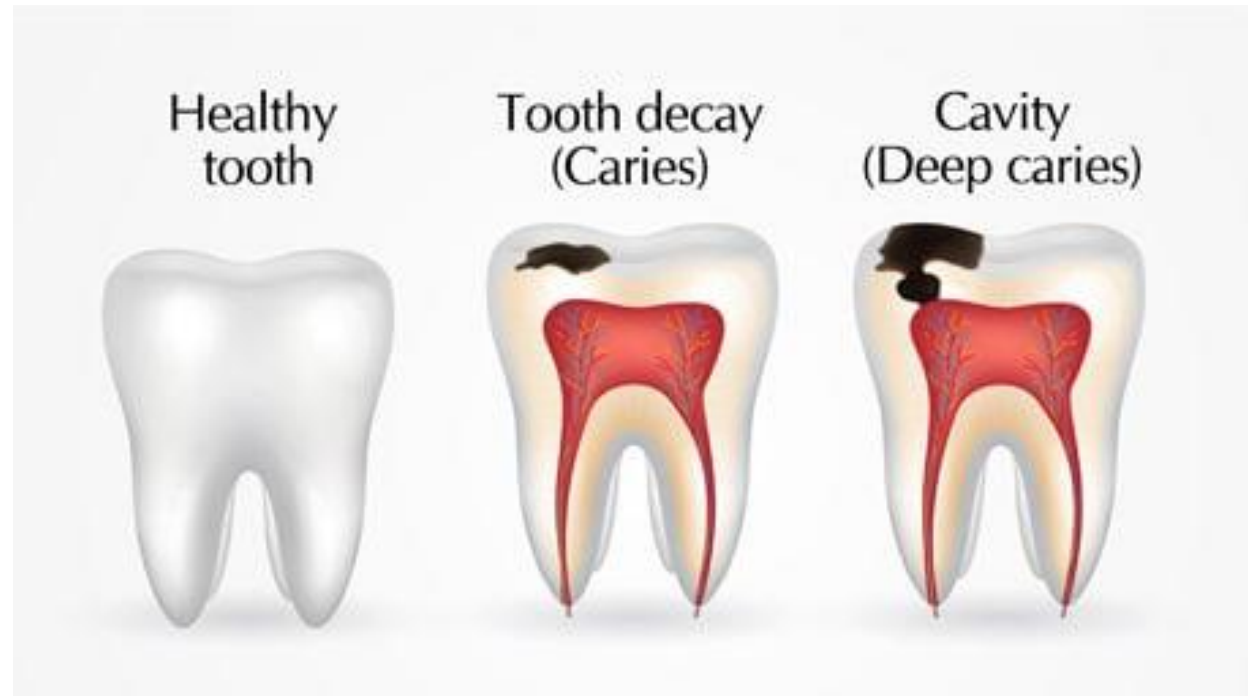

Oral microbiome

- The oral microbiome is important for dental health. Its composition depends on age, geographic origin, socioeconomic status, and genetics
- With intensive oral hygiene, we harm the microbiome, destroy friendly bacteria and allow unfriendly bacteria to grow.

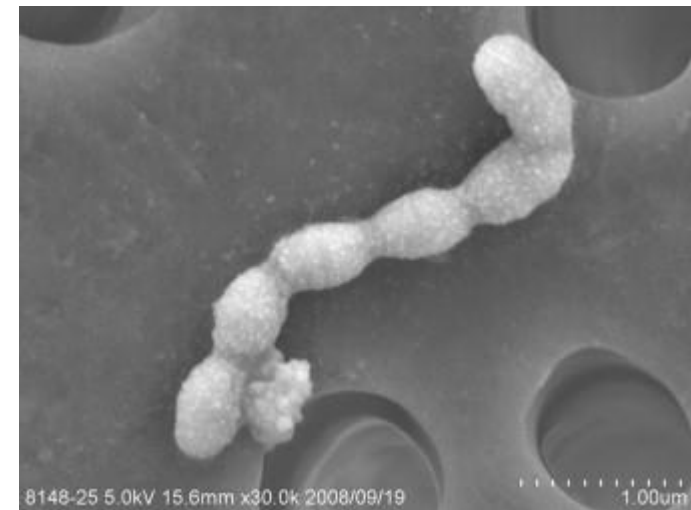
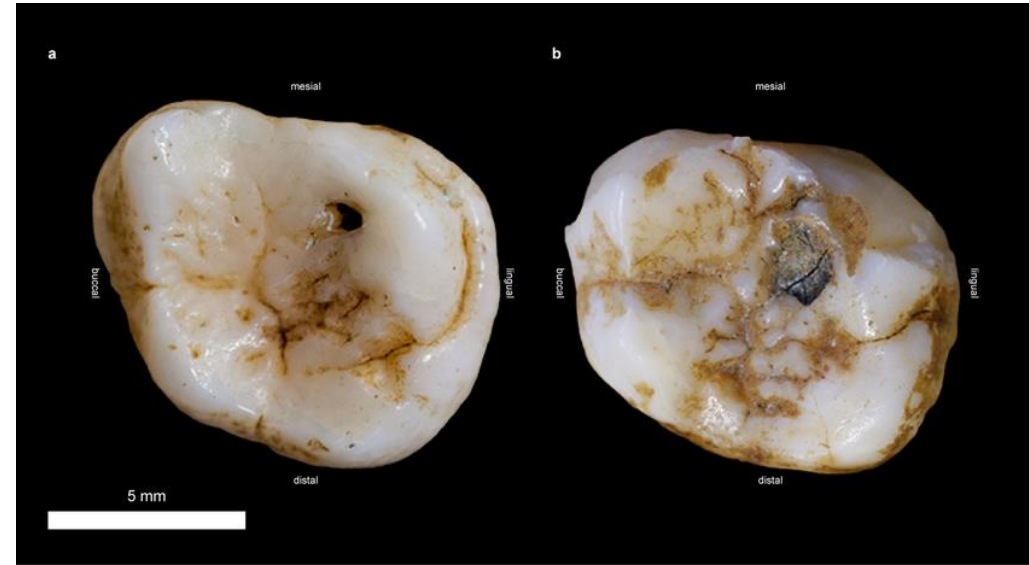


Caries

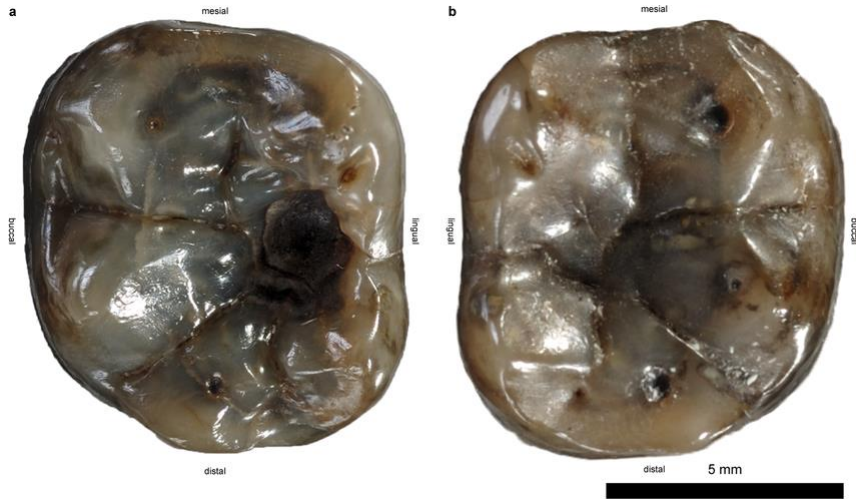


Caries

- Tooth decay is considered the scourge of modern civilization, but tooth decay also appeared earlier in our ancestors and even in modern apes, who are frugivorous
- Tooth decay is considered the scourge of modern civilization, but tooth decay also appeared earlier in our ancestors and even in modern apes, who are frugivorous
- Dental caries in humans is caused by the bacteria *Streptococcus mutans*
- DNA analysis of this bacterium revealed that it originated 14,000 years ago, which corresponds to the emergence of agriculture
- This bacterium produces a stronger acid than others

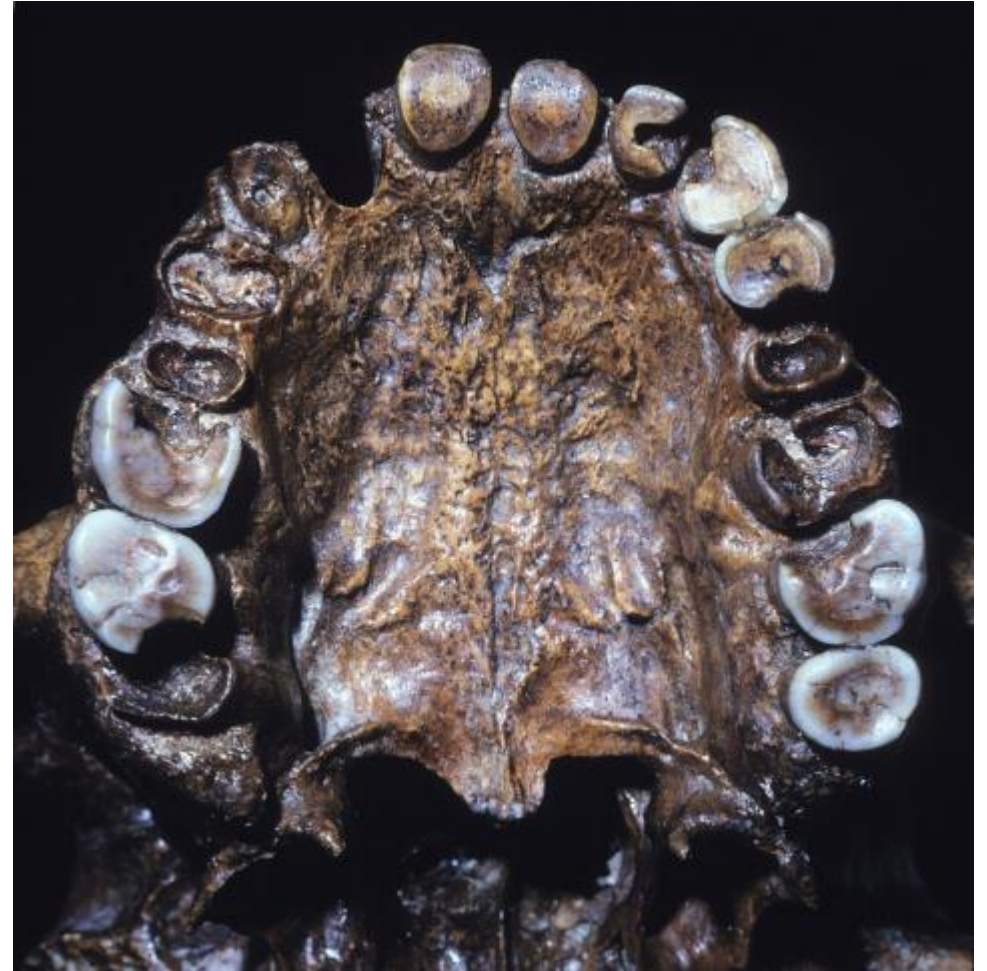

Carries



***Dryopithecus cariathicus*-miocene (Cenozoic)**

With fossils this old, we don't know if they were caused by *S. mutans* or another species. Further research is needed.



Man from Broken Hill-300 000 years ago

SCIENTIFIC REPORTS

OPEN

Earliest evidence of dental caries manipulation in the Late Upper Palaeolithic

Received: 10 March 2015

Accepted: 17 June 2015

Published: 16 July 2015

Gregorio Oxilia^{1,2,3}, Marco Peresani³, Matteo Romandini³, Chiara Matteucci², Cynthianne Debono Spiteri^{4,5}, Amanda G. Henry^{4,6}, Dieter Schulz⁷, Will Archer⁶, Jacopo Crezzini^{8,9}, Francesco Boschini^{8,9}, Paolo Boscato⁹, Klervia Jaouen⁶, Tamara Dogandžić⁶, Alberto Broglio³, Jacopo Moggi-Cecchi³, Luca Fiorenza^{10,11}, Jean-Jacques Hublin⁶, Ottmar Kullmer¹² & Stefano Benazzi^{2,6}

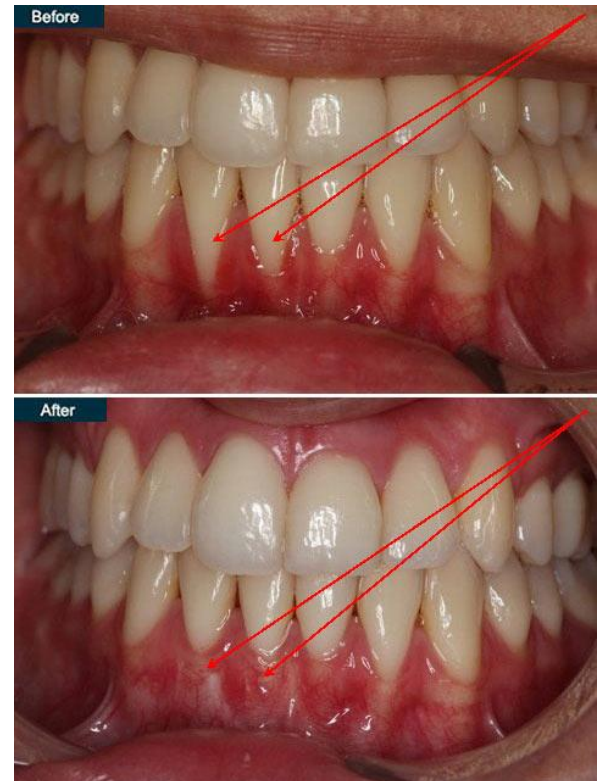
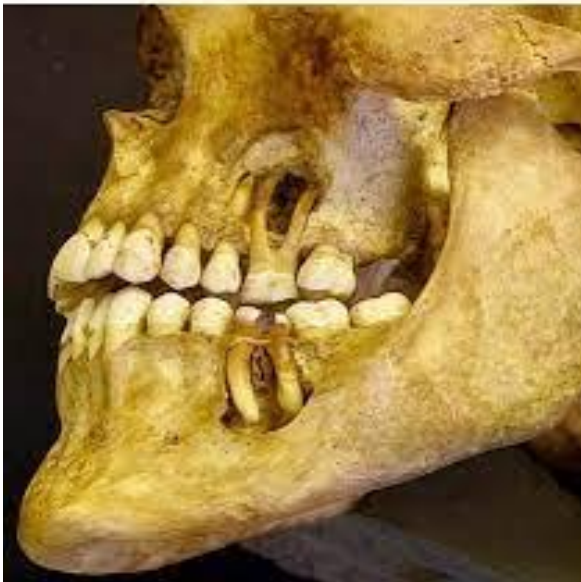Prehistoric dental treatments were extremely rare, and the few documented cases are known from the Neolithic, when the adoption of early farming culture caused an increase of carious lesions. Here we report the earliest evidence of dental caries intervention on a Late Upper Palaeolithic modern human specimen (Villabruna) from a burial in Northern Italy. Using Scanning Electron Microscopy we show the presence of striations deriving from the manipulation of a large occlusal carious cavity of the lower right third molar. The striations have a "V"-shaped transverse section and several parallel micro-scratches at their base, as typically displayed by cutmarks on teeth. Based on *in vitro* experimental replication and a complete functional reconstruction of the Villabruna dental arches, we confirm that the identified striations and the associated extensive enamel chipping on the mesial wall of the cavity were produced ante-mortem by pointed flint tools during scratching and levering activities. The Villabruna specimen is therefore the oldest known evidence of dental caries intervention, suggesting at least some knowledge of disease treatment well before the Neolithic. This study suggests that primitive forms of carious treatment in human evolution entail an adaptation of the well-known toothpicking for levering and scratching rather than drilling practices.

Gum disease

This disease appears more frequently in humans with the transition to agriculture and then during the Industrial Revolution. In earlier species, this disease is not as common.

The cause is still unclear and more research in oral health is needed.

An ancient Egyptian (3000 BC) with severe abscesses. Ouch!



Thank you for your attention!

