

# **XXVII. Examination of reflexes in man**

Physiology - practices

# Reflexes

- **Reflex:** is an involuntary response of an organism triggered by stimulation of receptors – the main functional unit of the nervous system based on negative feedback
- **Reflex arch:** consists of 1. receptor, 2. afferent pathway, 3. centre (brain or spinal cord), 4. efferent pathway and 5. effectors organ.
- Particular reflexes have anatomically **strictly defined reflex arches**, e.g. pathway and centre.
- According to the character of a reflex response to a certain stimulus, we can topically diagnose and point out the place of nervous system disablement.
- **Function:** correction of changes or protection against damage.

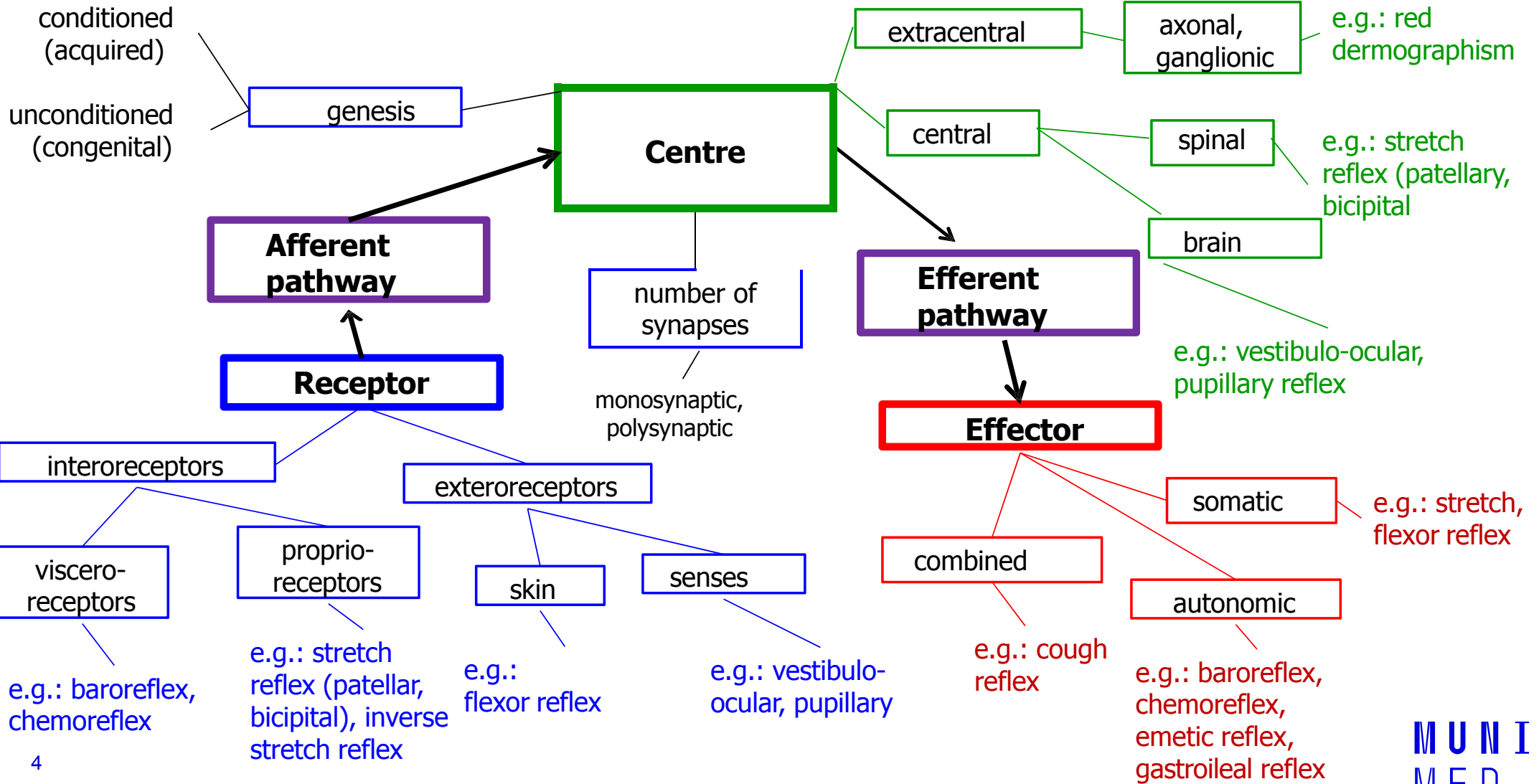
# Examination of Reflexes

- When examining reflexes the following items are considered:
  - **Elicitability of a reflex** – if we can elicit the reflex
  - **Quantitative changes** in the response – the strength or symmetry of the response
  - **Qualitative changes** – if the response is as expected or different
- **Proprioceptor reflexes** (stretch reflexes)
  - Most reflexes are elicited by fast, springy tapping of the corresponding receptor area with a percussion hammer.
  - The tapping of the hammer should be adequately strong, fast, and precise, but not painful.
  - Muscles involved in the muscle response must be sufficiently relaxed.

Facilitating manoeuvre consisting of a voluntary contraction of antagonistic muscles should be used if the reflex can not be elicited even in a correct procedure, e.g. Jendrassik's manoeuvre (the patient flexes both sets of fingers into a hook-like form and tries to put them apart)

Sometimes it is necessary to distract the subject's attention by asking him to perform a simple calculation (repeated subtraction of a number).

# Classification of reflexes

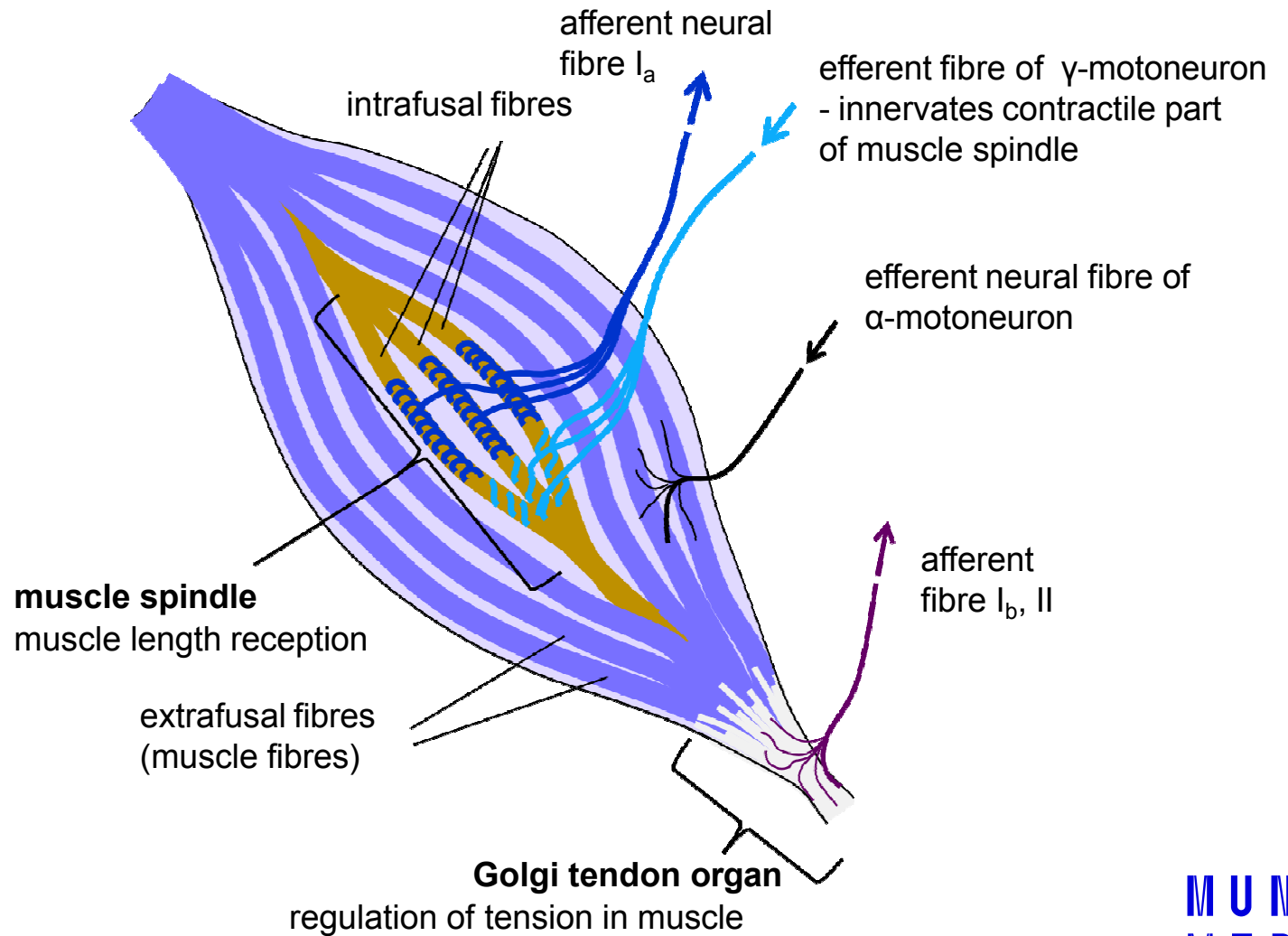


# Reflexes in practicals

- Proprioceptive reflexes (myotatic, stretch):
  - jaw thrust reflex (masseter), nasopalpebral
  - biceps, stylo-radial, triceps
  - patellar (knee jerk), ankle jerk (Achilles' tendon reflex), medioplantar
- Exteroceptive reflexes (cutaneous and mucous):
  - corneal and conjunctival, palatal
  - epigastric, mesogastric, hypogastric
  - plantar
- Sensory reflexes:
  - pupillary response to light (direct or indirect), to convergence, to pain
  - twinkle reflex

# Proprioceptors in the muscle

Apart from muscle spindles and Golgi tendon organs, **proprioceptors in joints** registering the position of a joint also exist

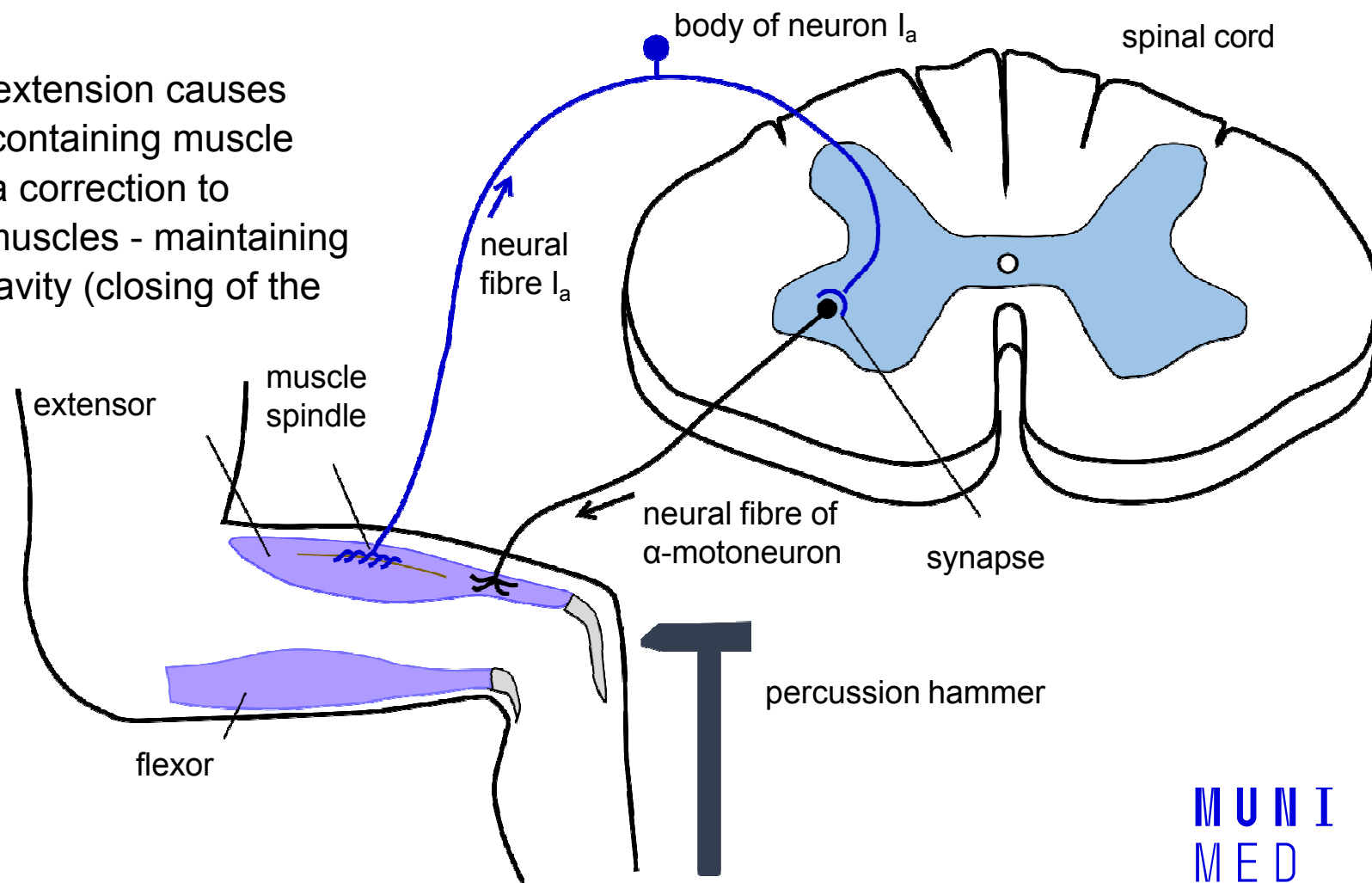


# Stretch reflex – reflex arch (myotatic reflex: monosynaptic, proprioceptive)

**Receptor:** Muscle spindle

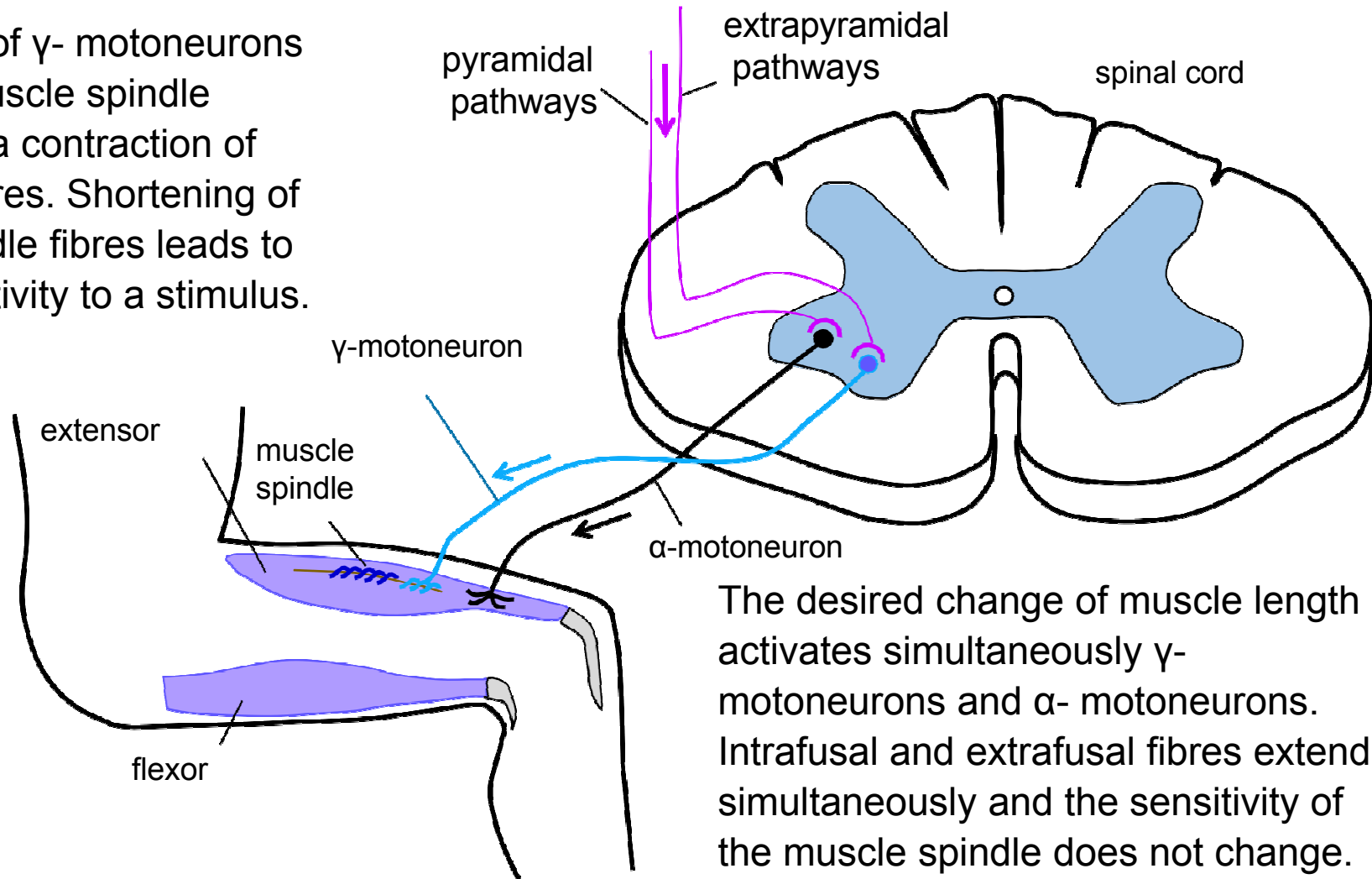
**Main function:** Unwanted extension causes contraction of the muscle (containing muscle spindle). Reflex serves as a correction to unwanted prolongation of muscles - maintaining of erect posture, defying gravity (closing of the mouth)

**Elicitation:** By percussion of the tendon of a muscle with a reflex hammer, passive and involuntary prolongation of the muscle occurs. The muscle spindle is triggered and a reflexive muscle contraction is started.



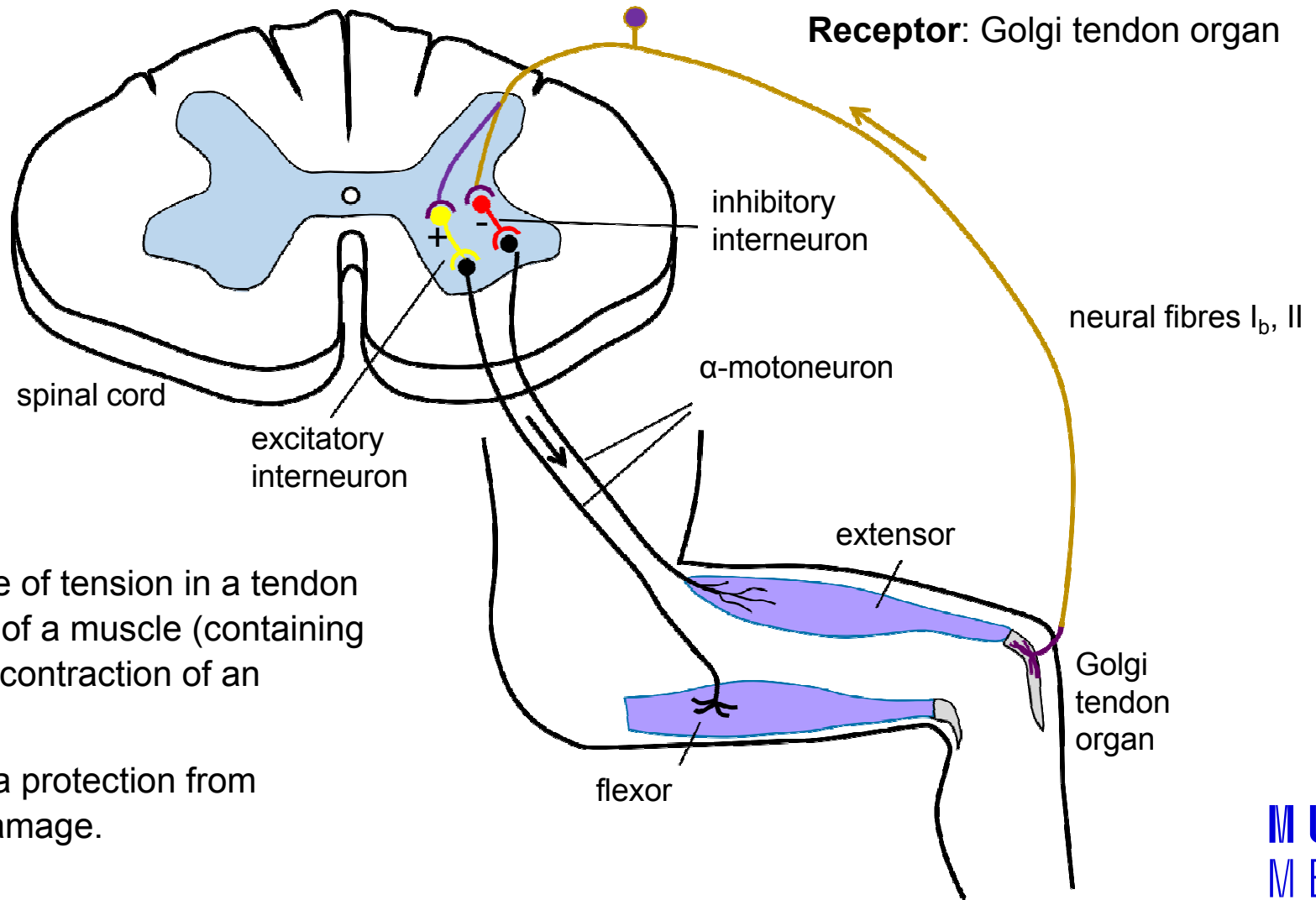
# Stretch reflex – correction of muscle spindle sensitivity

The activity of  $\gamma$ - motoneurons regulates muscle spindle sensitivity via contraction of intrafusal fibres. Shortening of muscle spindle fibres leads to higher sensitivity to a stimulus.





# Golgi tendon reflex, inverse stretch reflex (bisyndaptic, proprioceptive)

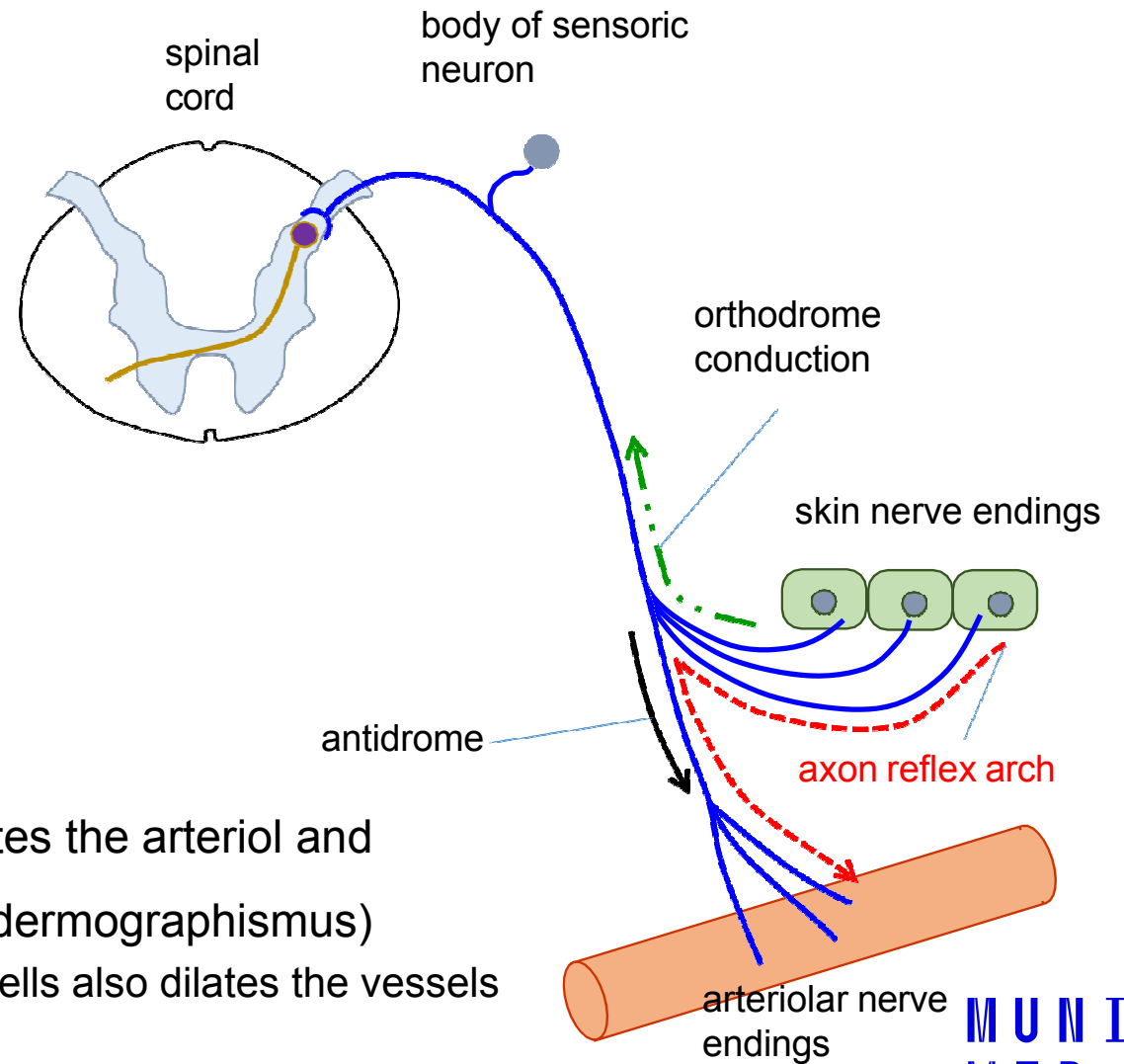


**Function:** An increase of tension in a tendon causes the relaxation of a muscle (containing a Golgi receptor) and contraction of an antagonist muscle.

This reflex serves as a protection from muscle and tendon damage.

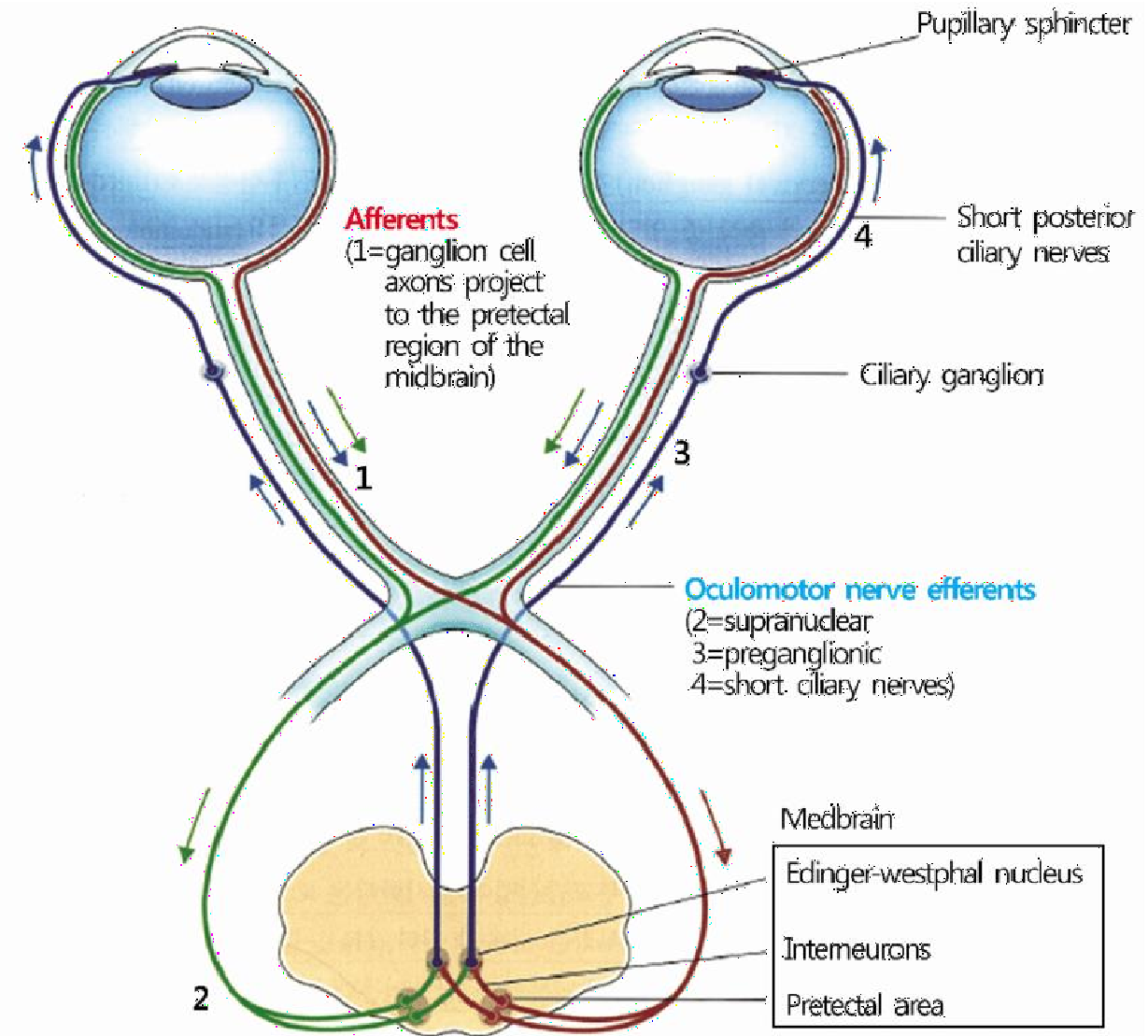
# Axon reflex (extracentral)

- The impulses generated in the sensory nerve are transmitted anti-directionally (upstream) to other branches of the sensory fibre
- When irritating the skin receptors, the pulse is converted to nearby arterioles innervated by the same fibre
- Substance P from the nerve endings dilates the arteriolar and increases the vascular permeability (red dermographismus)
  - In addition, histamine released from mast cells also dilates the vessels and increases their permeability



# Pupillary response

- Constriction of pupils in reaction to light
  - symmetrical constriction of both pupils
  - miosis – constriction of pupils, parasympathetic activity
  - mydriasis – dilatation of pupils, sympathetic activity
  - centre of reflex: brainstem (diencephalon)



# XXVIII. Recording of Achilles' tendon reflex

Physiology - practices

# Recording of Achilles' tendon reflex

## Aim:

- To learn how to register electrical and mechanical responses of Achilles' tendon reflex.
- After measuring particular values get an idea about the time sequence of electrophysiological processes of reflex response, which start with stimulation of appropriate receptors and ends up in muscle relaxation.
- Achilles' tendon reflex – monosynaptic, proprioceptive, somatic, stretch, unconditioned, spinal, monosegmental

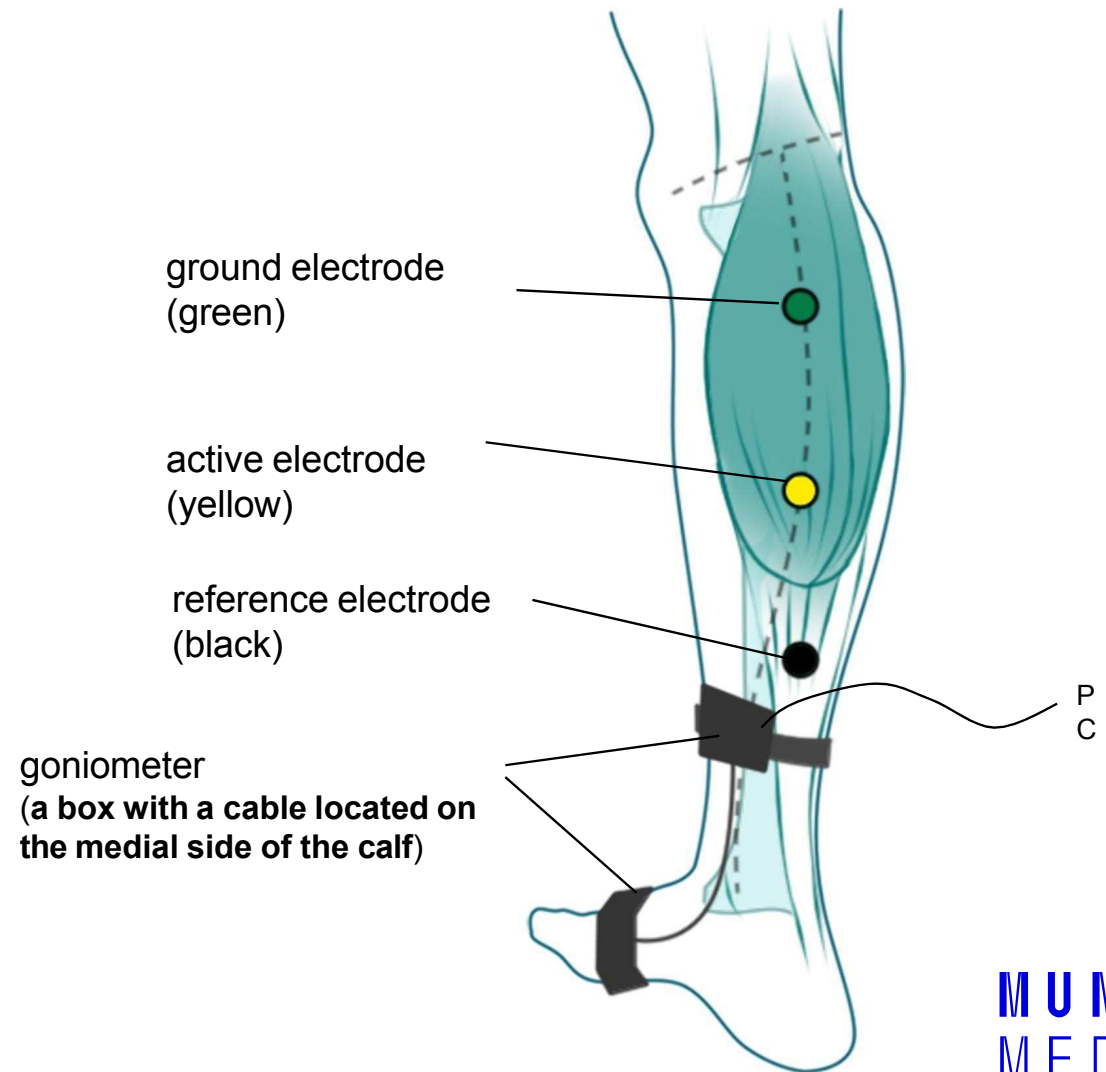
- Achilles tendon reflex (or ankle jerk) as a proprioceptive reflex is elicited by tapping the tendon of the soleus muscle with a reflex hammer. The rapid stretch of muscle activates the muscle spindles and evokes an increased discharge of action potentials from the spindles.
- The volley of action potentials in the primary sensors **Ia** fibres monosynaptically excites the alpha motoneurons (mainly in the S1 segment) which in turn activate the soleus muscle, where the reflex begins.
- Contraction of muscle is preceded by membrane depolarisation of activated muscle fibres which generate the so called **compound muscle action potential (CMAP)**. This potential may be recorded using surface electrodes (electromyographically). Two parameters of electromyogram (EMG) are of interest: the duration of the signal and the interval of its delay, the latency period.

# Methods

- The mechanical response of the muscle, contraction and relaxation, may be recorded with a joint goniometer fixed on the calf and the foot. The muscle contraction changes the angle formed by the attached boxes, thereby the deflexion of the fibres and eventually the amount of light converted to an electric signal. The first derivative of the signal yields the velocity of contraction and relaxation.
- Electrodes are placed on the calf and an electromyographic curve is obtained.
- The measurement of Achilles tendon reflex was formerly used to assess indirectly the thyroid function. Prolongation of the mechanical response (specifically the time when the velocity of muscle relaxation reaches its maximal value) is symptomatic of thyroid hypofunction, whereas it is shortened in hyperthyroidism

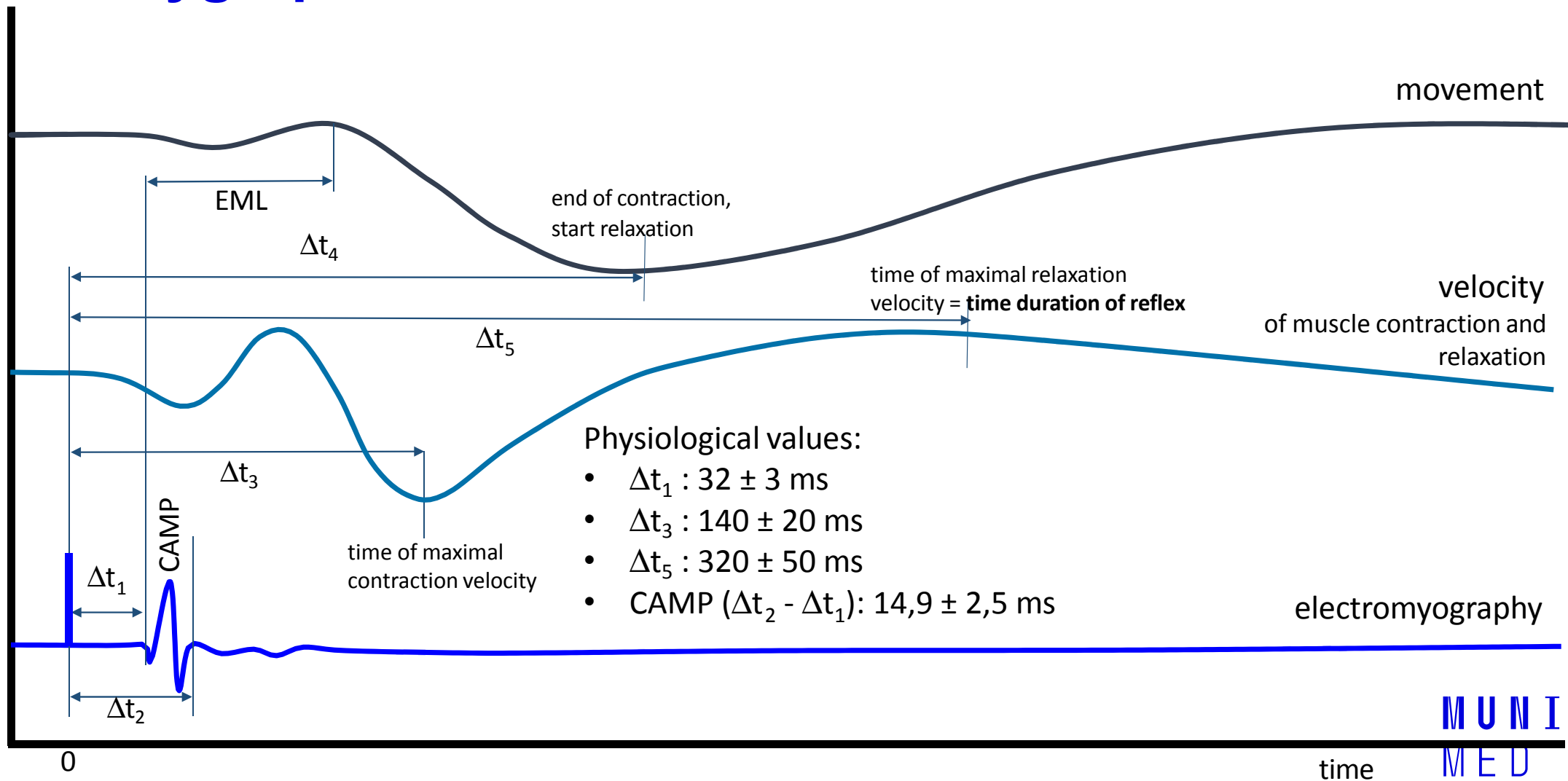
# Position of goniometer and electrodes

## on the right leg





# Polygraphic record of the Achilles tendon reflex



## Example of how to process the protocol:

- Write results from 5 records in the table

record	1	2	3	4	5	mean	phys. values (ms)
$\Delta t_1$							$32 \pm 3$
$\Delta t_2$							
$\Delta t_3$							$120 \pm 20$
$\Delta t_4$							
$\Delta t_5$							$320 \pm 50$
CAMP							$14,9 \pm 2,5$

## In conclusion:

- Compare acquired values to physiological values
- High  $\Delta t_5$  values may point to reduced thyroid function and vice versa

# Interesting links

- Stretch reflexes
  - <https://www.youtube.com/watch?v=0sqClzuotWo>
- Babinski and plantar reflex:
  - <https://www.youtube.com/watch?v=HnX4bH1WRHQ>
  - [https://www.youtube.com/watch?v=iV\\_a2WSbdM8](https://www.youtube.com/watch?v=iV_a2WSbdM8)
- Reflexes used in brain dead examination:
  - <https://www.youtube.com/watch?v=Nty6bICZlyA>
- From 8:40 min
  - <https://www.youtube.com/watch?v=qiZBGFwv4E&t=524s>
- Vestibuloocular reflex
  - [https://www.youtube.com/watch?v=j\\_R0LcPnZ\\_w](https://www.youtube.com/watch?v=j_R0LcPnZ_w)
- Pupillary reflex
  - <https://www.youtube.com/watch?v=aM0ipmW3ikc>