

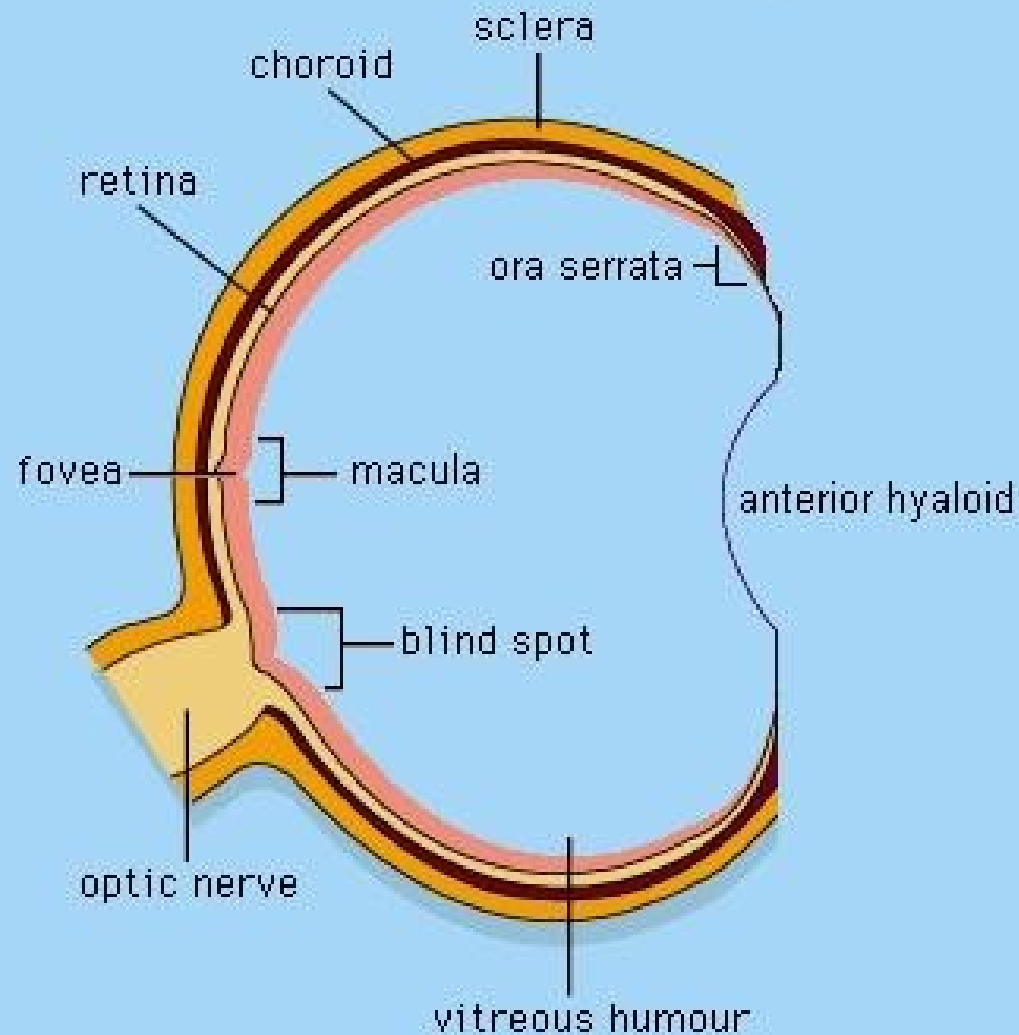


Posterior segment surgery

MUDr. Veronika Matušková
Oční klinika FN Brno

Přednosta prof. MUDr. Eva Vlková, CSc.

The Posterior Segment



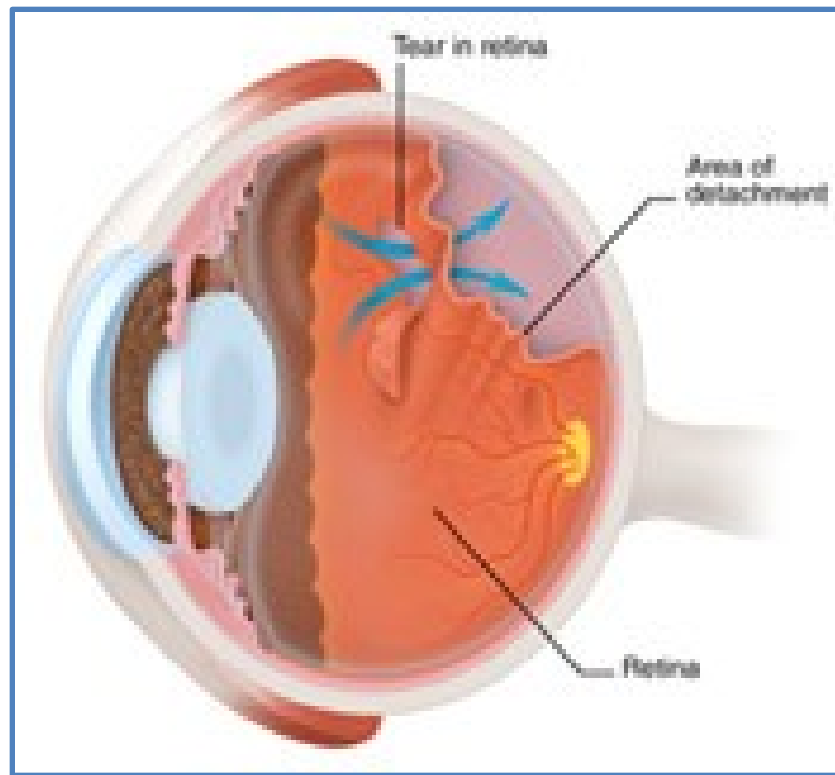
Retinal detachment

Rhegmatogenous - tear

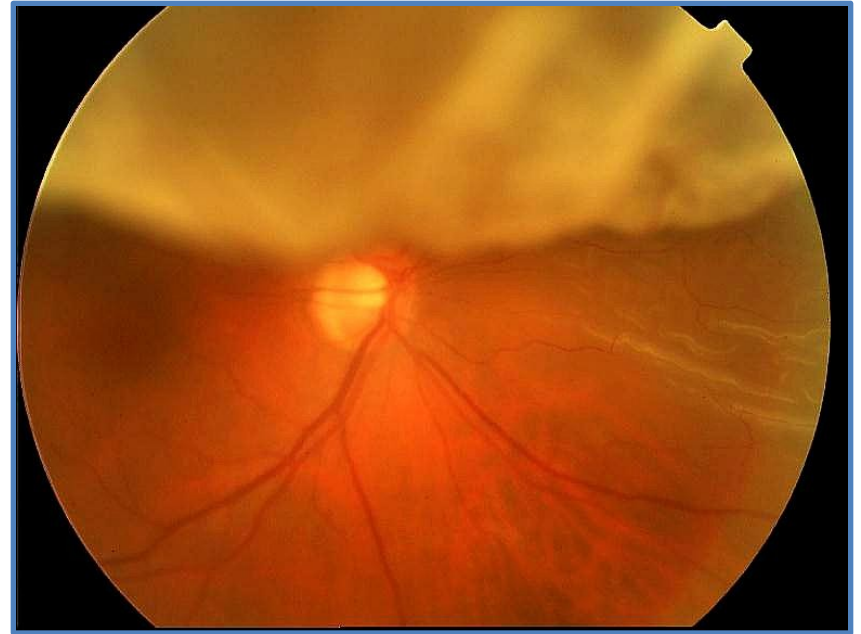
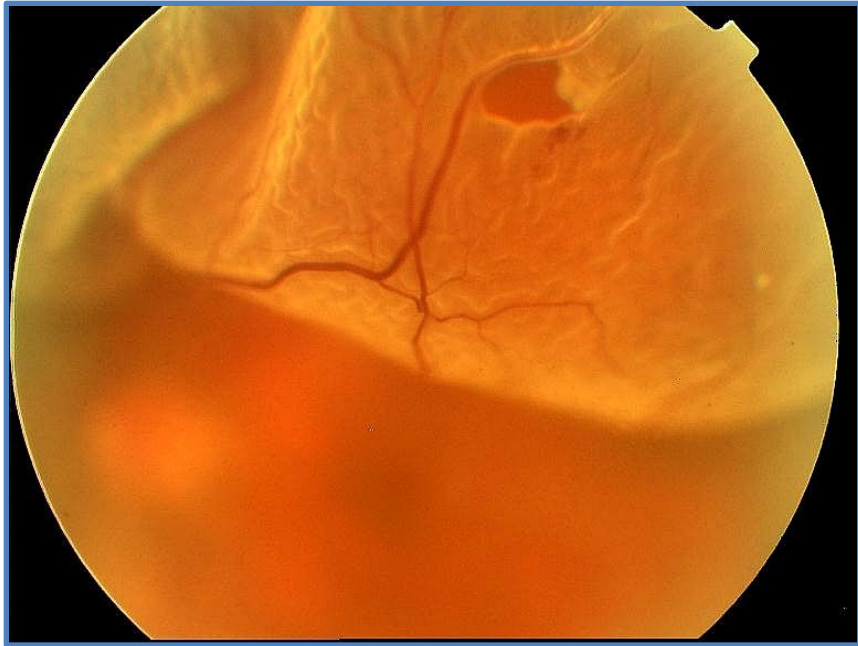
Tractional - traction of corpus vitreum

Serose – production of fluid

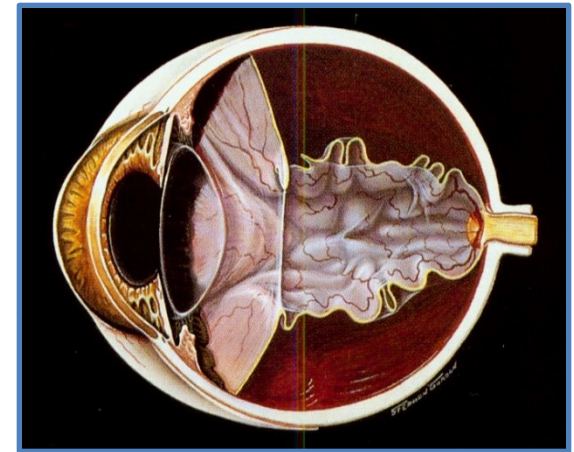
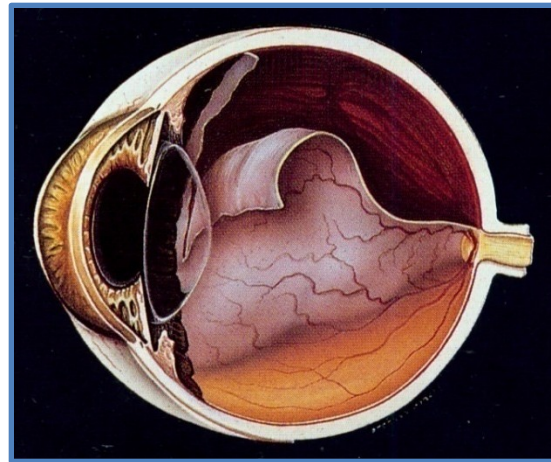
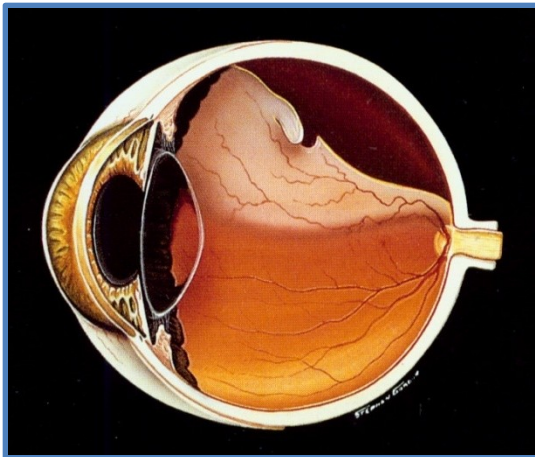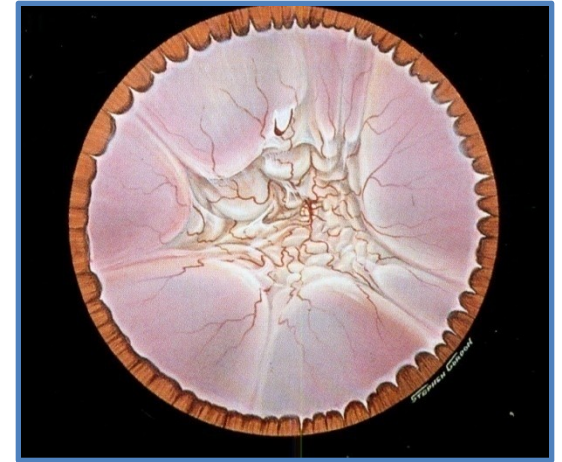
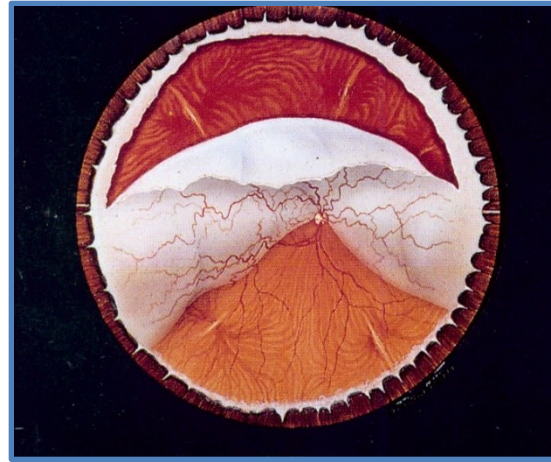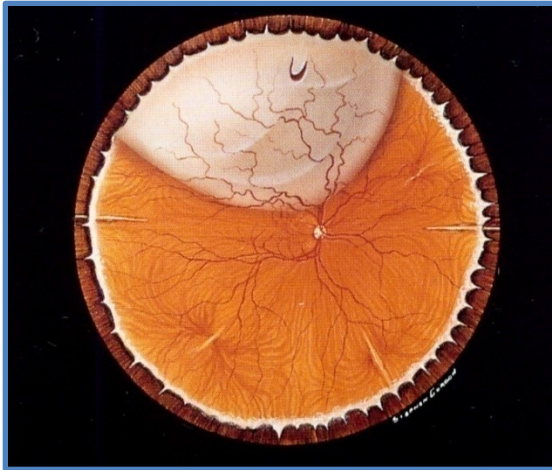
Retinal detachment



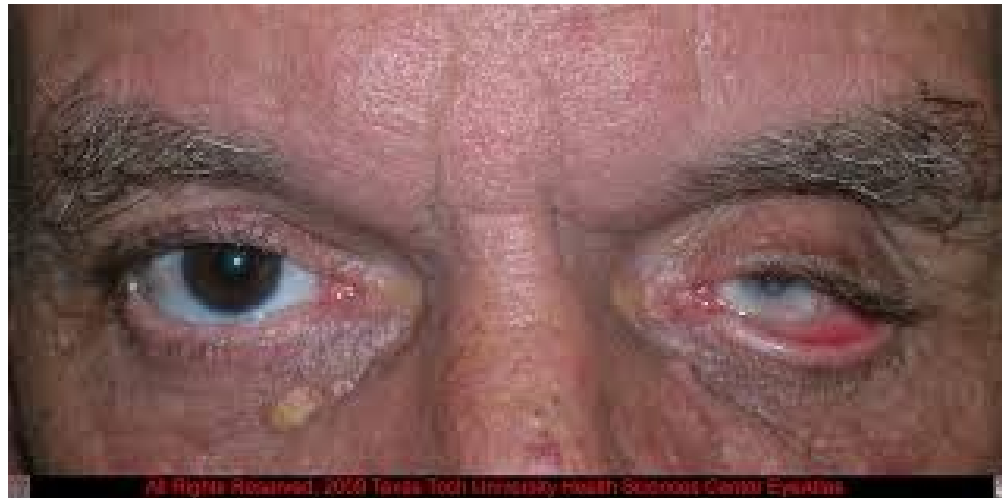Retinal detachment



Retinal detachment



Phtisis bulbi



All Rights Reserved, 2000 Texas Tech University Health Sciences Center Eye Clinic

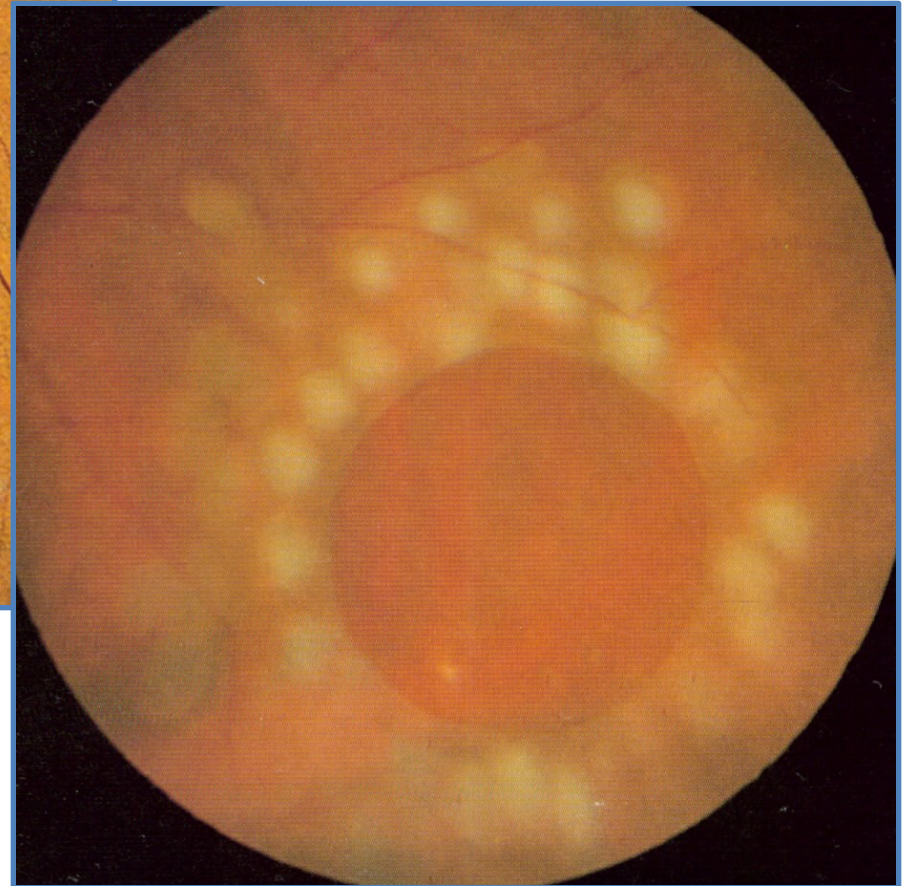
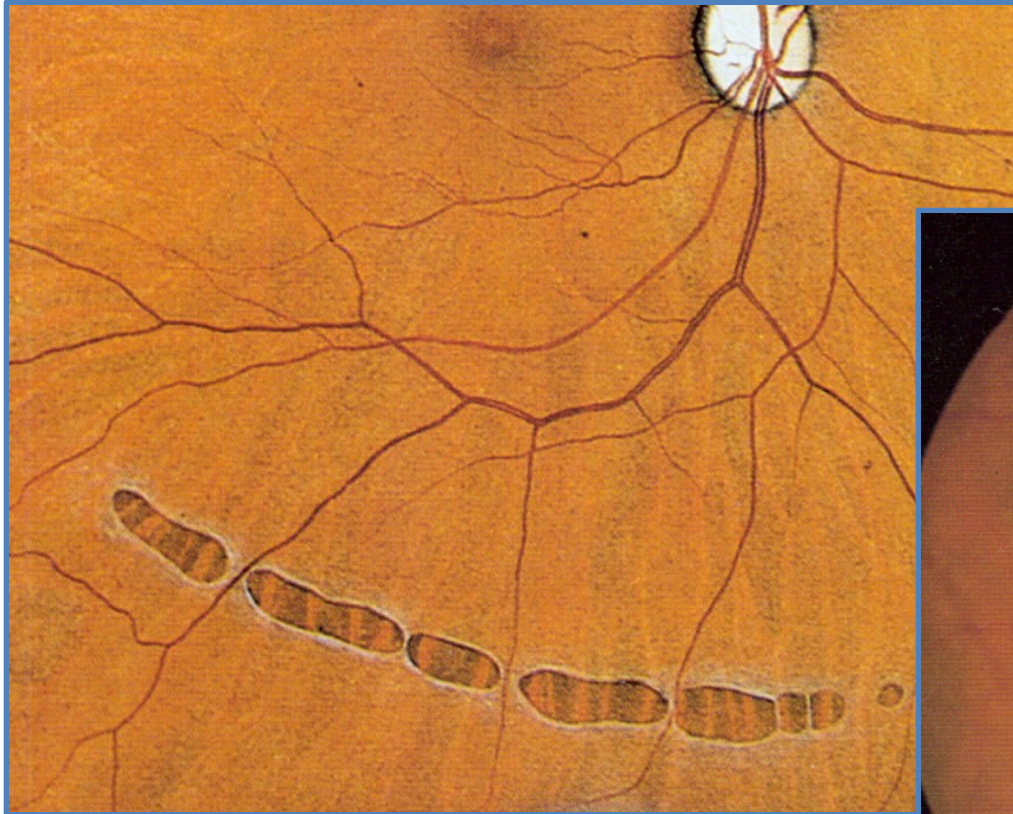Retinal detachment - symptoms

- Fotopsia (flashes)
- Black spots (black snow)
- **Scotoma** (black spot in peripheral visual field)
- Decrease of visual acuity
- Metamorfopsia

Surgery:

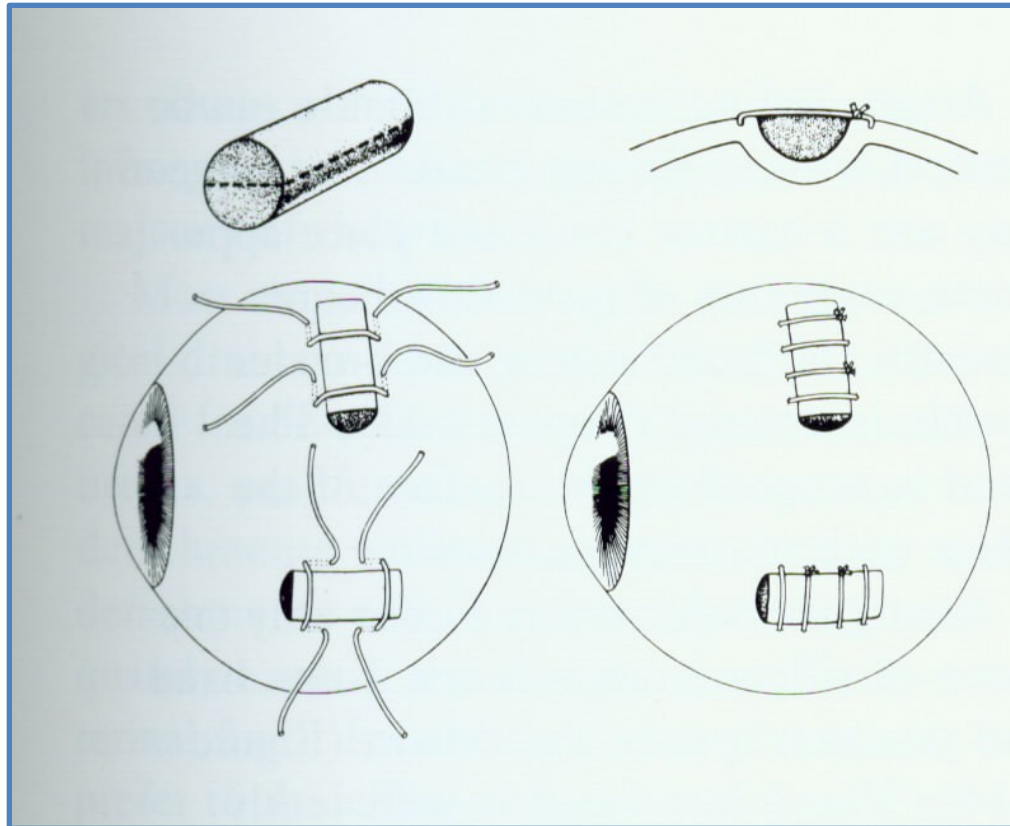
Close the tear

Laser photocoagulation

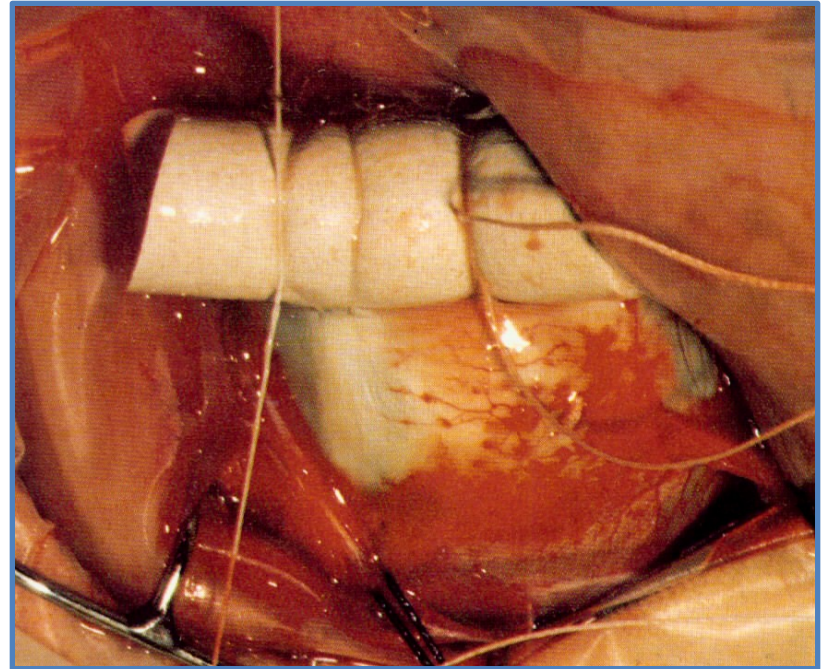
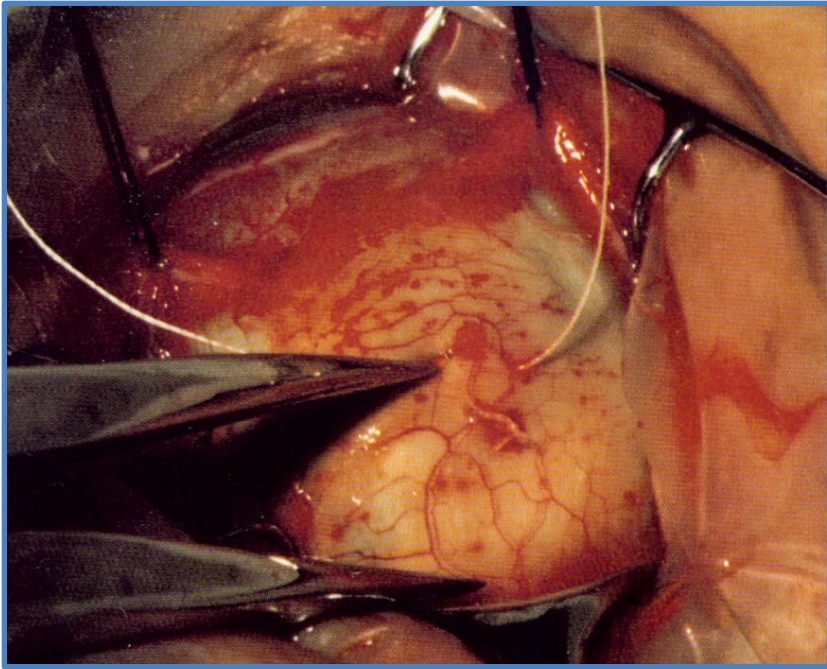


Extrabulbar operations

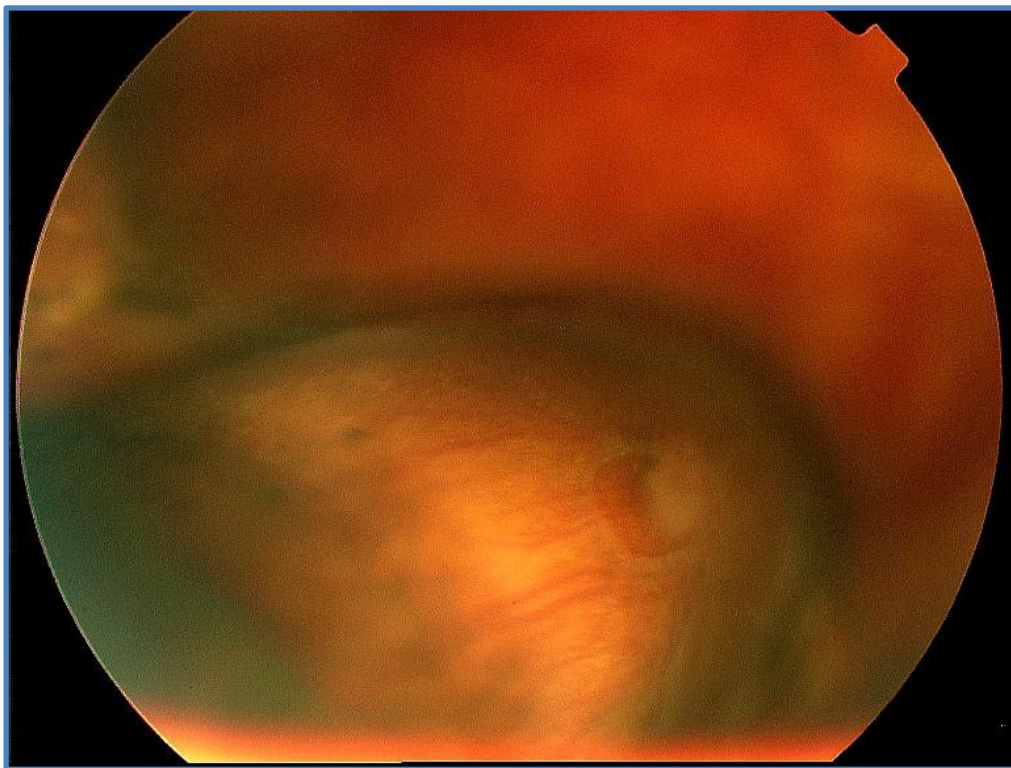Cryotherapy and plombage



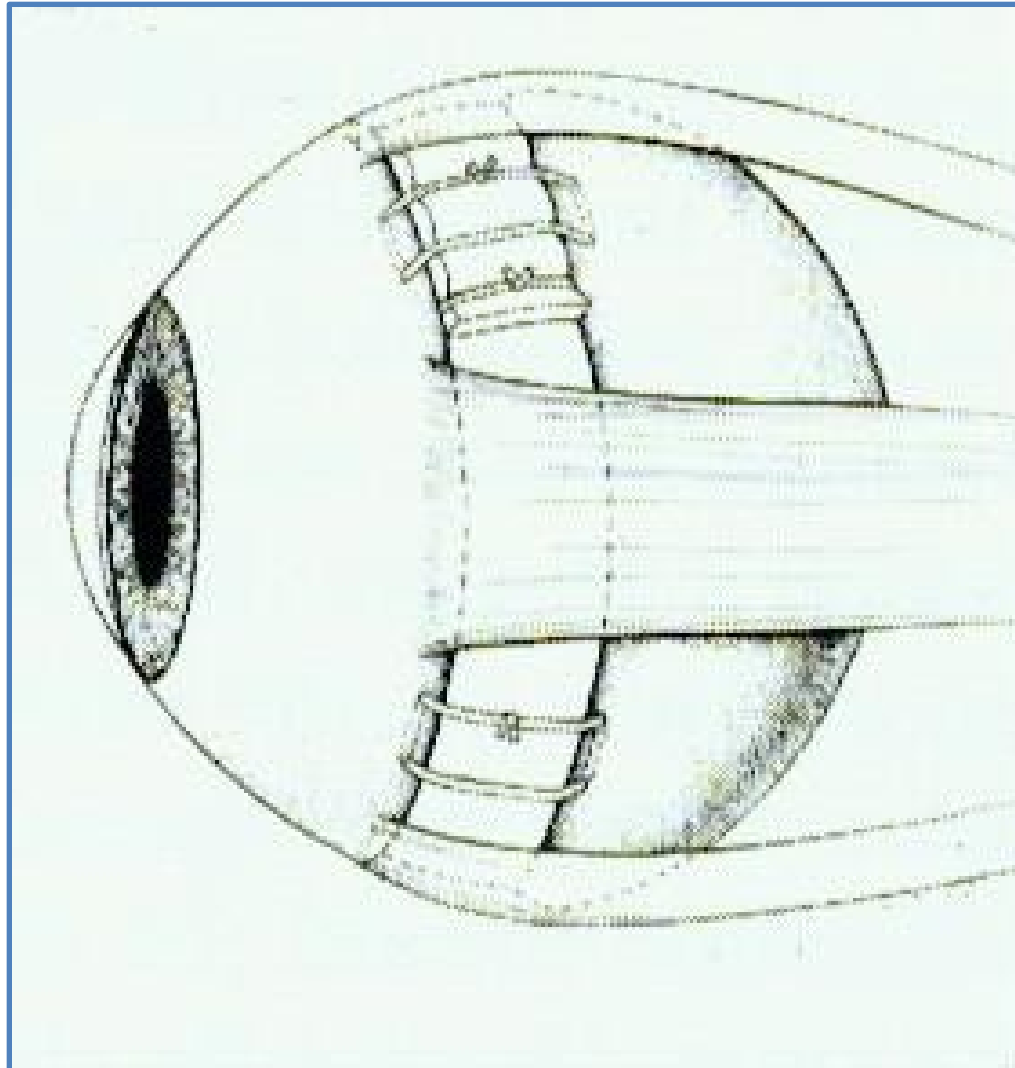
Plombage



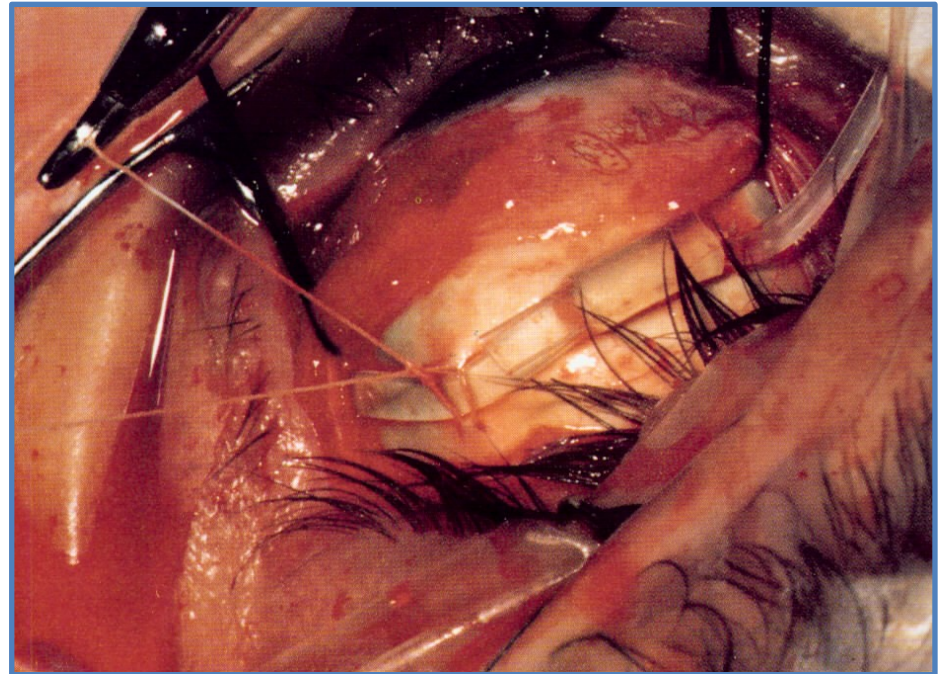
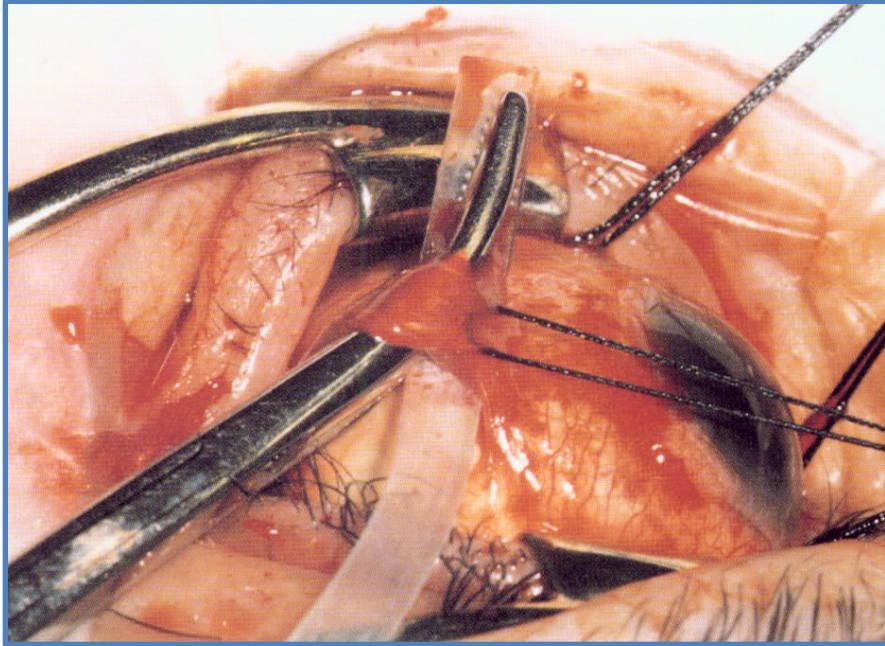
Plombage



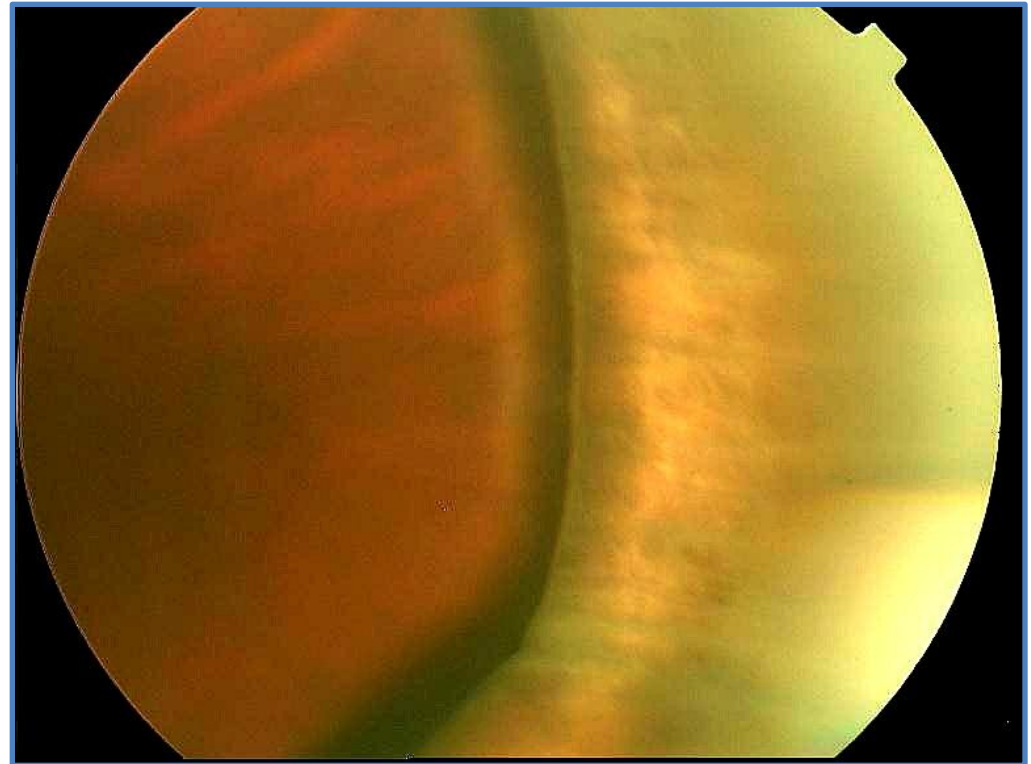
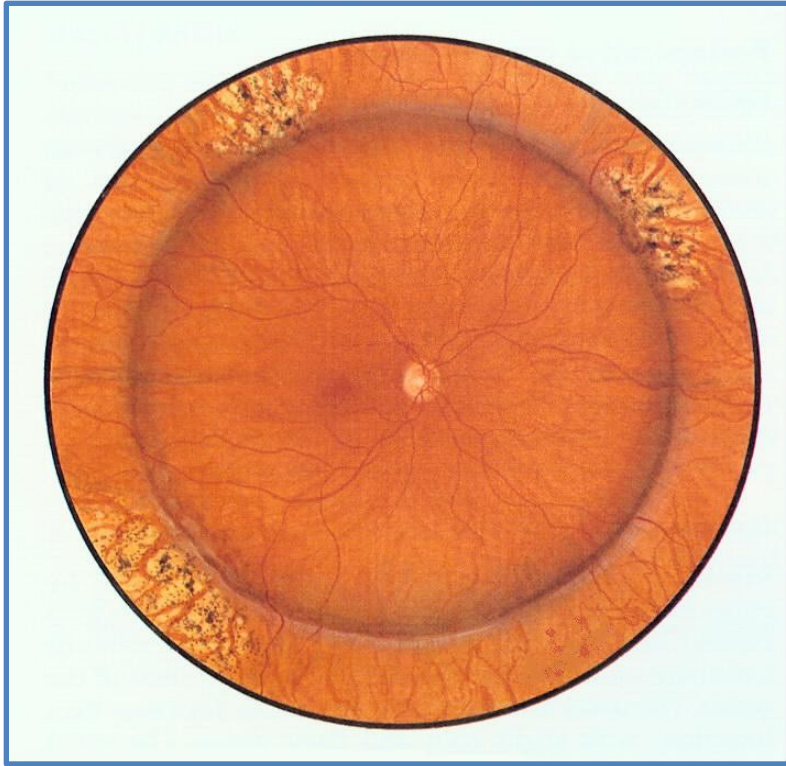
Cerclage



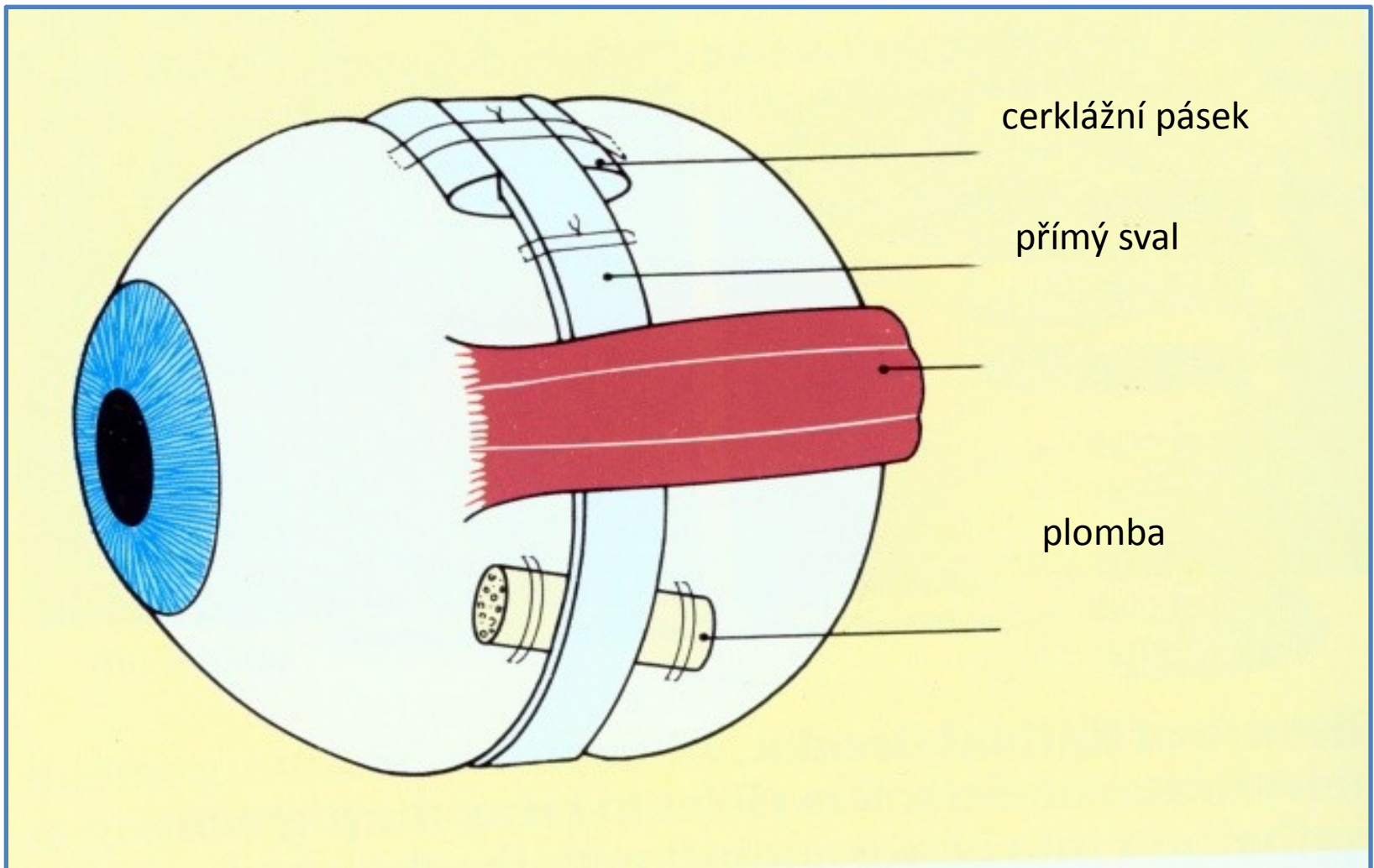
Cerclage



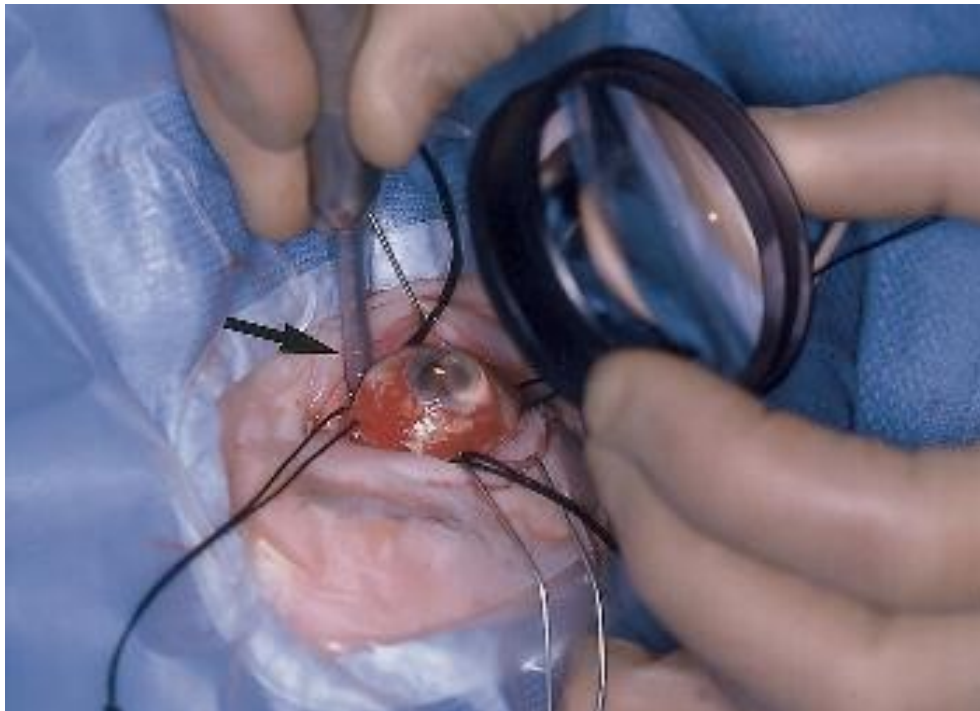
Cerclage



Extrabulbar surgery



Cryotherapy - development of chorioretinal adhesion (scar)

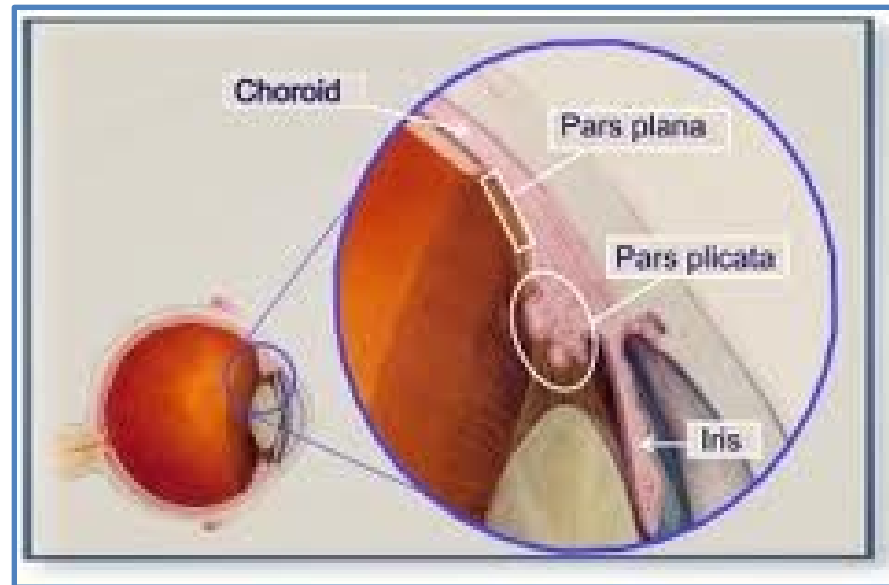


Complications

- Fenestra is not closed
- PVR - proliferative vitreoretinopathy

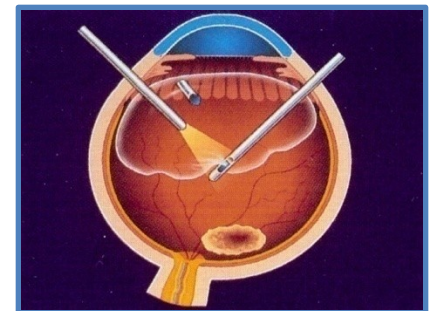
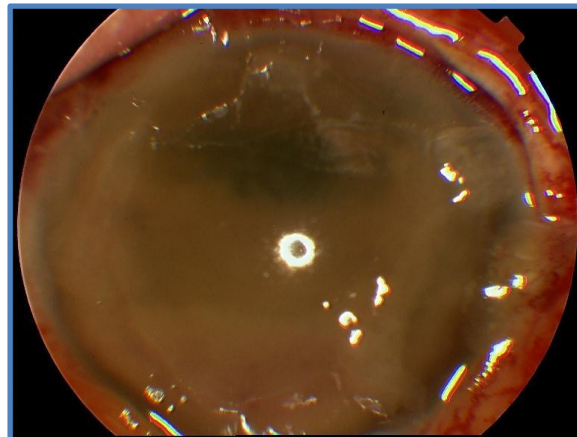
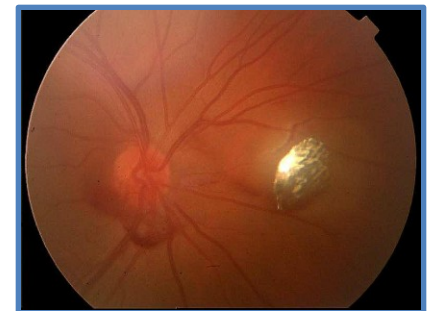
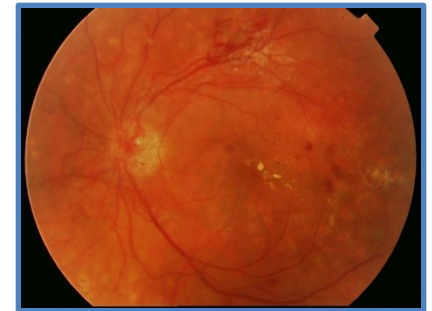
PPV

- Pars plana vitrektomie

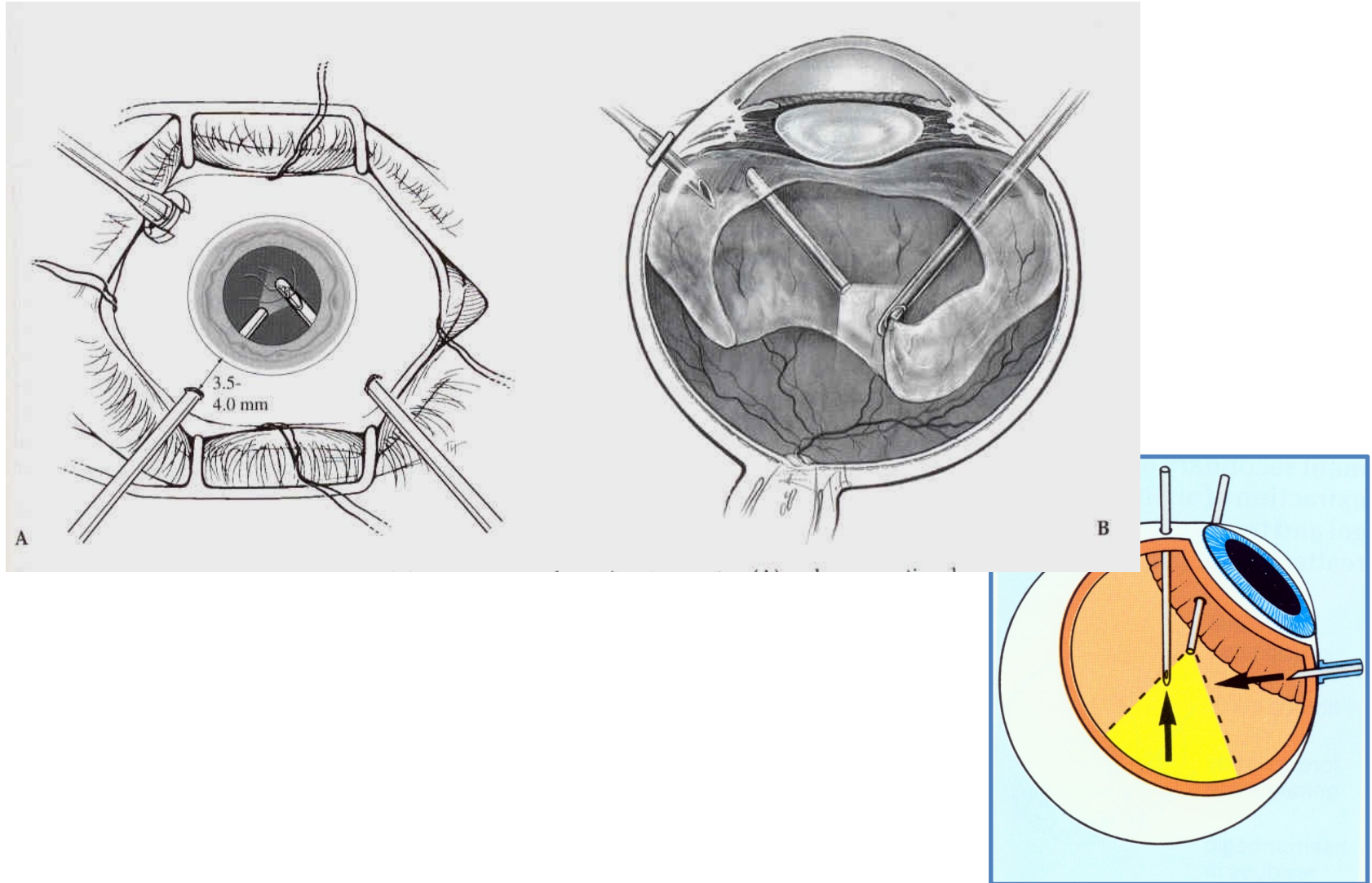


Pars plana vitrectomy

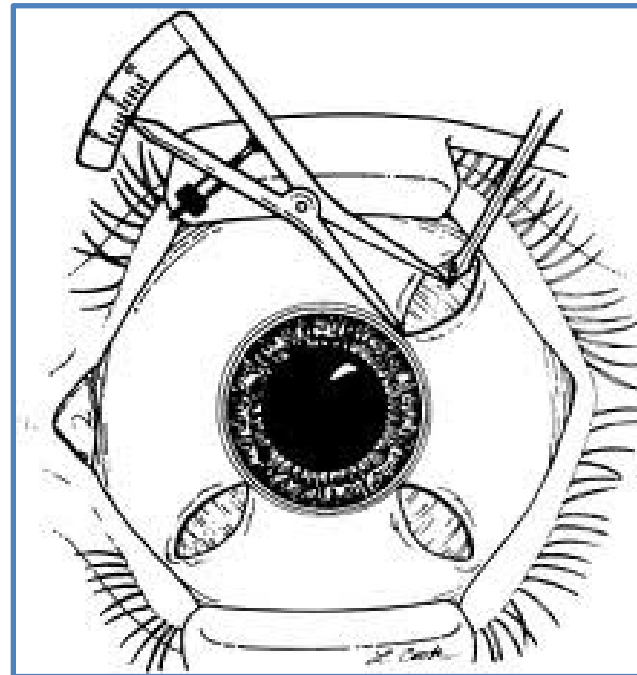
- Haemophthalmus
- PDR
- Retinal detachment
- Complications of cataract surgery
- Posterior luxation of lens
- Foreign intraocular body
- Endophthalmitis



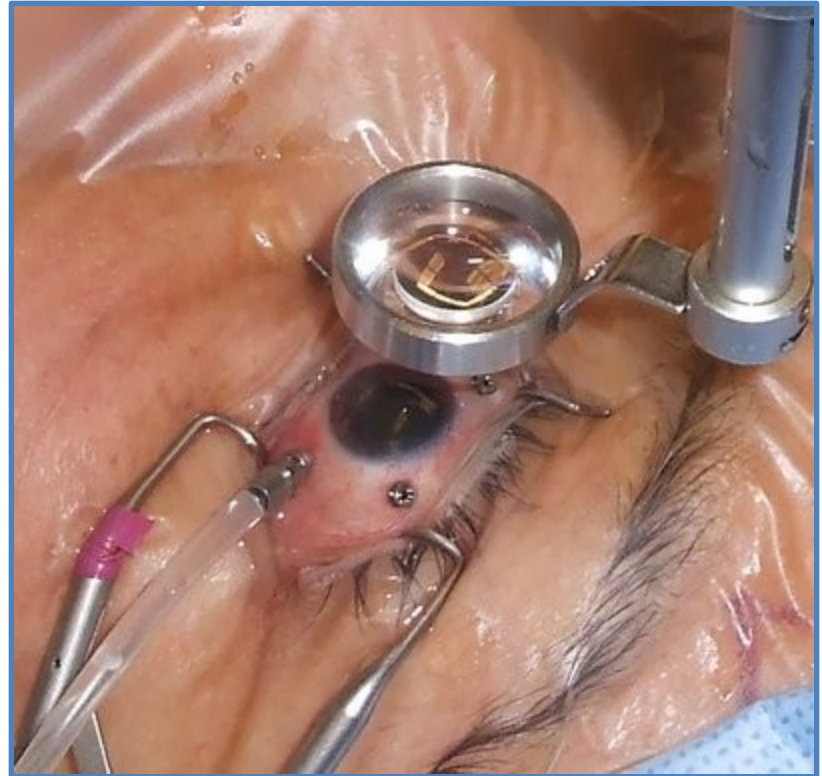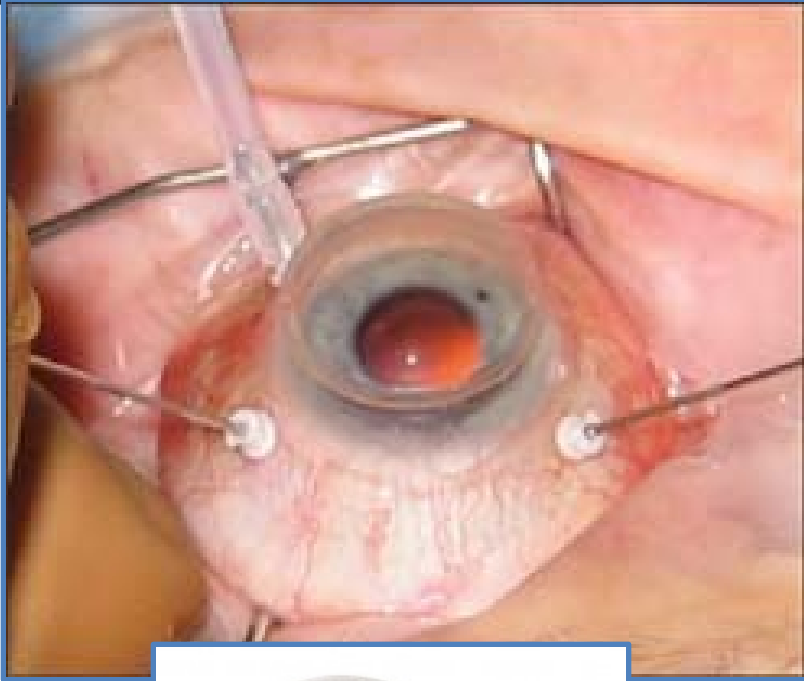
Pars plana vitrectomy -PPV



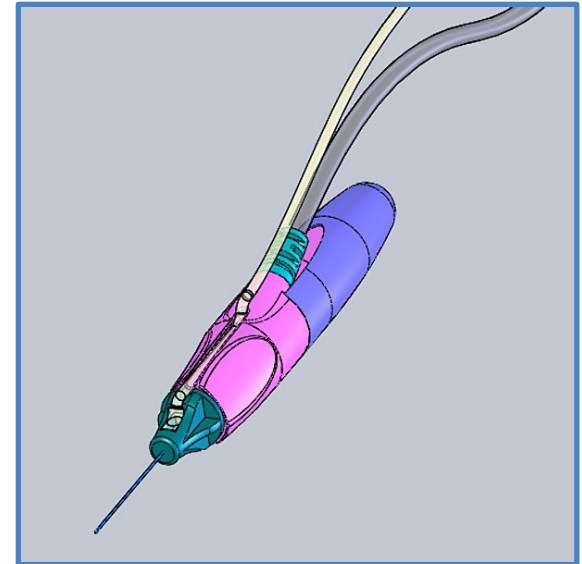
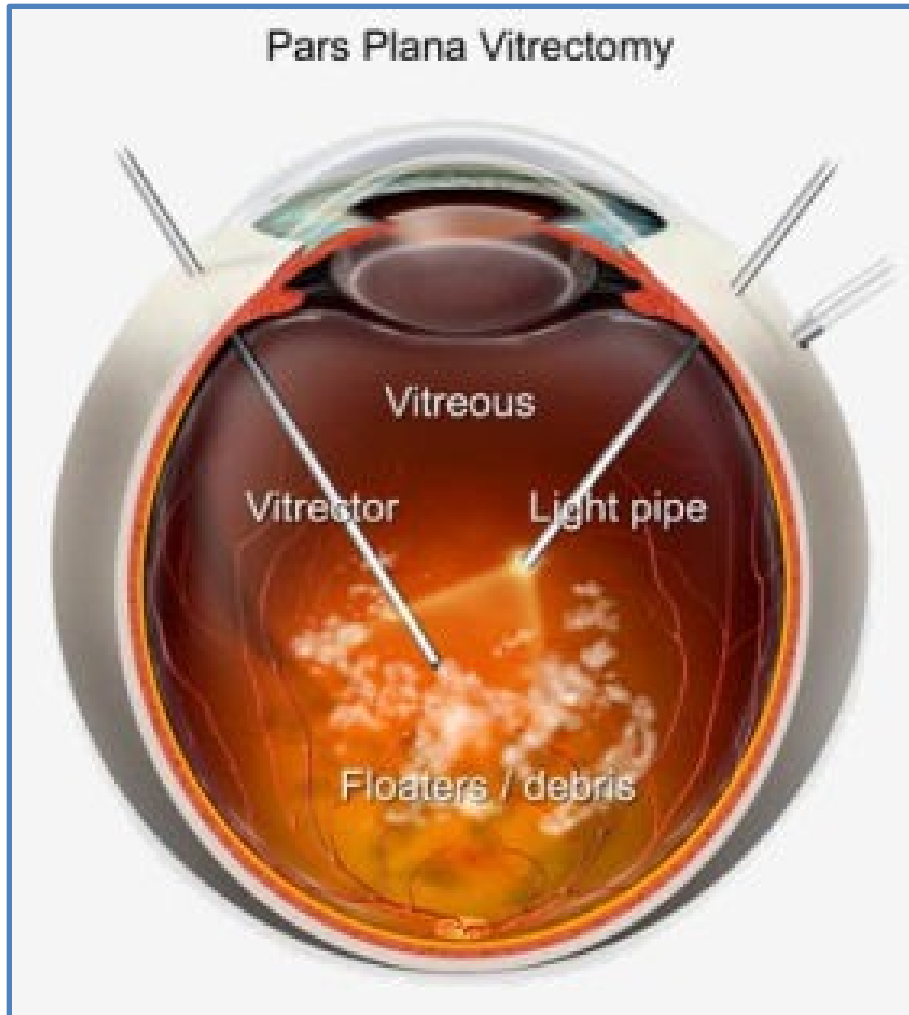
PPV – pars plana



PPV

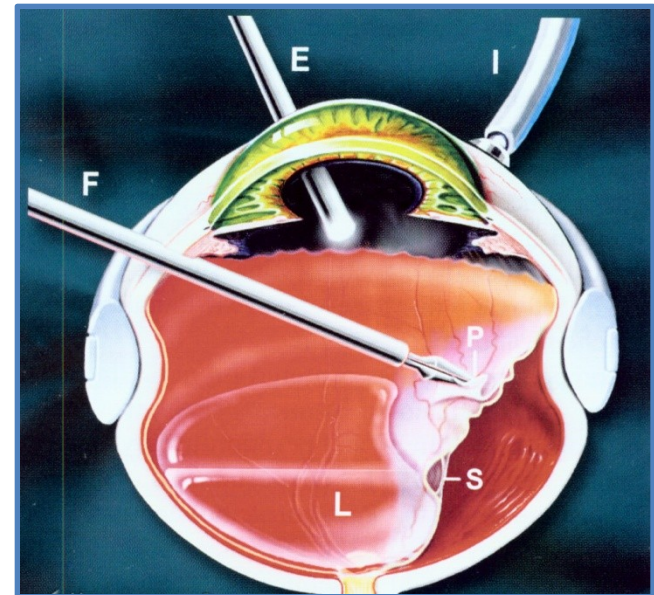
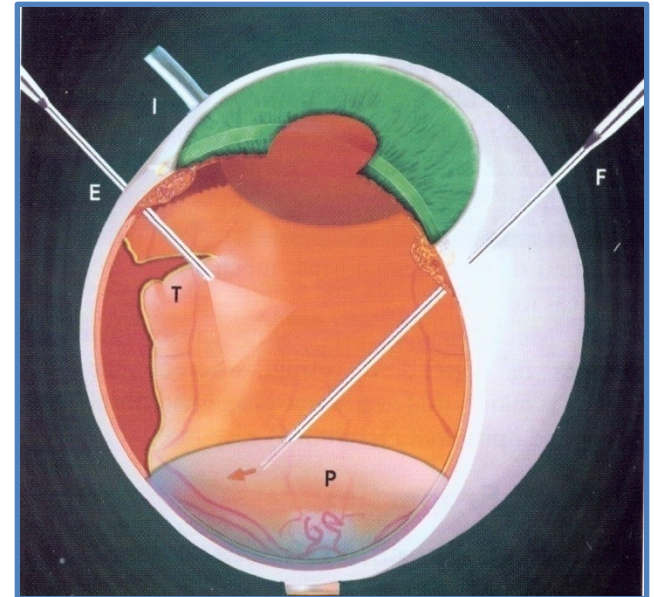


PPV

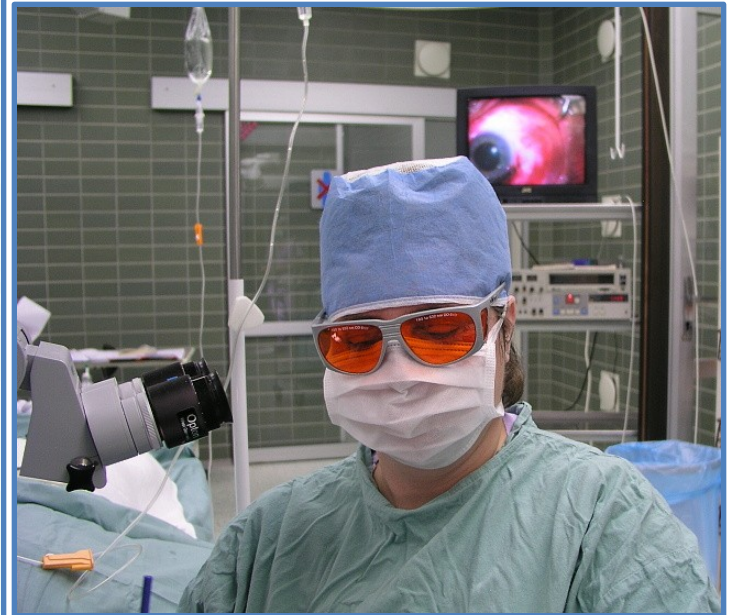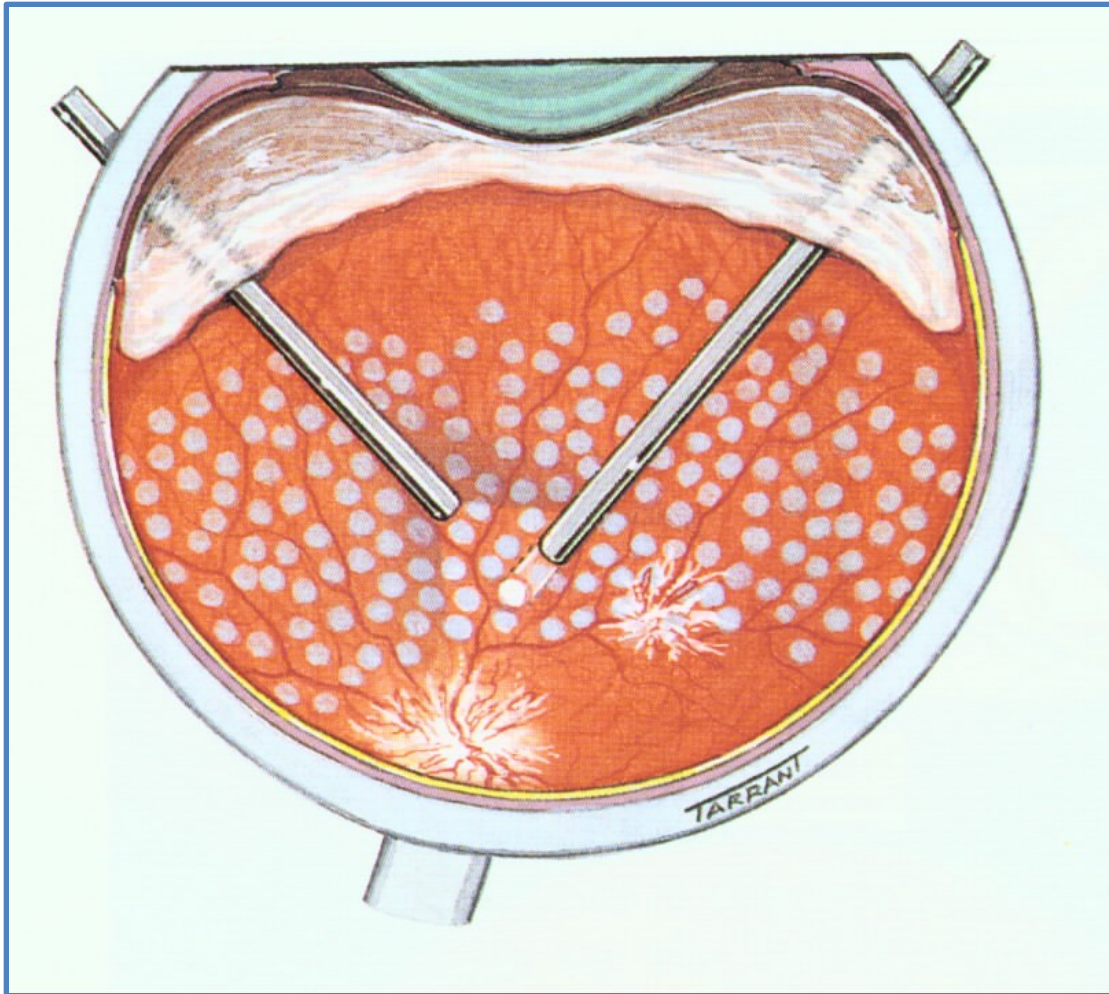


Internal tamponade

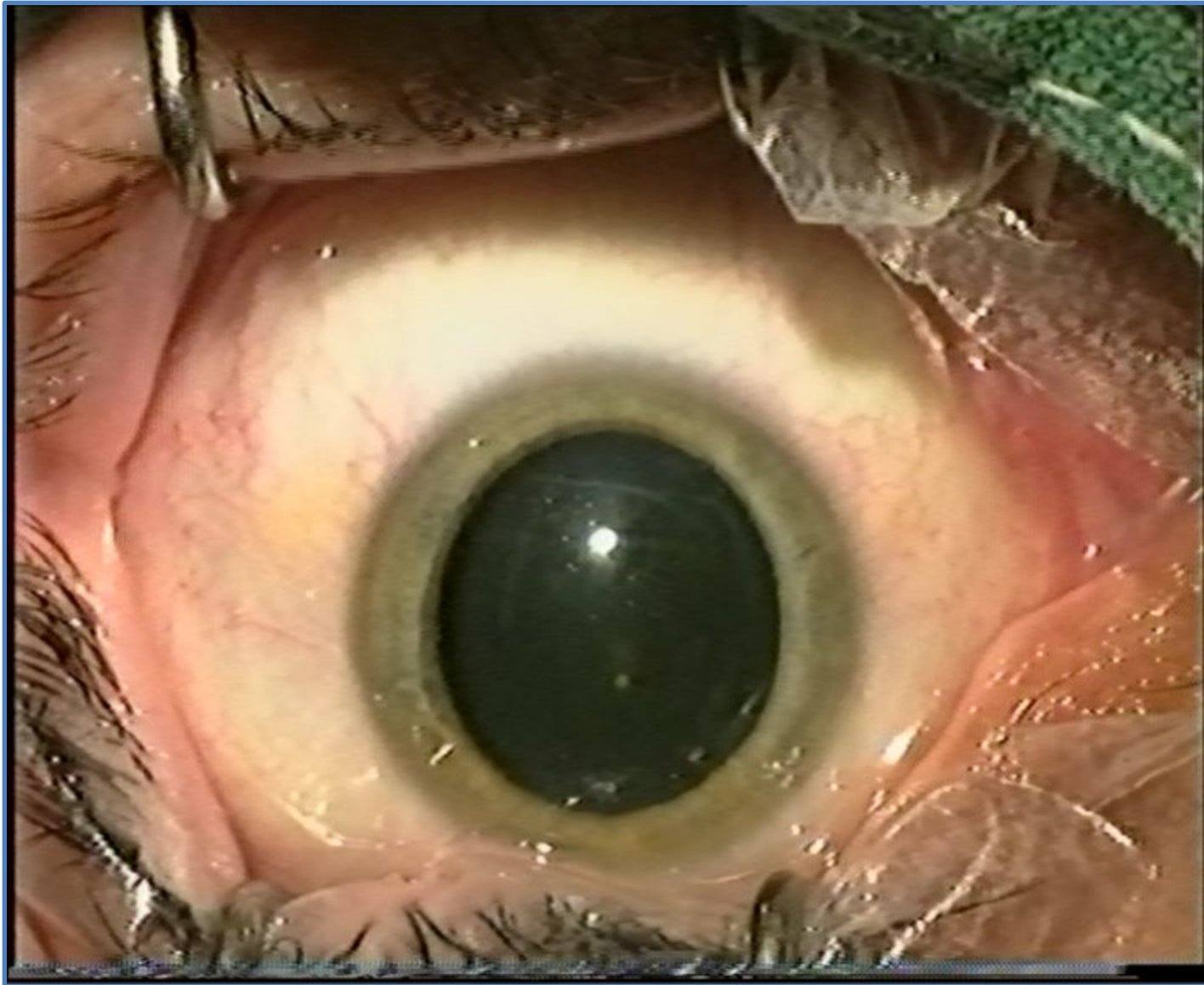
- a) Infusion solution
- b) Silicone oil
- c) Gas (C3F8, SF6)



Endolaser

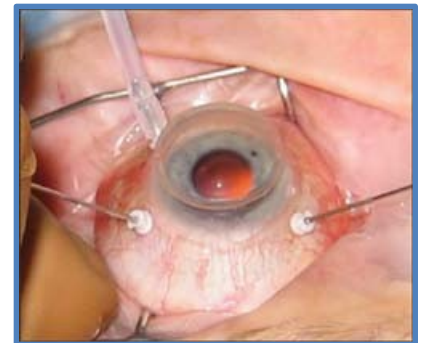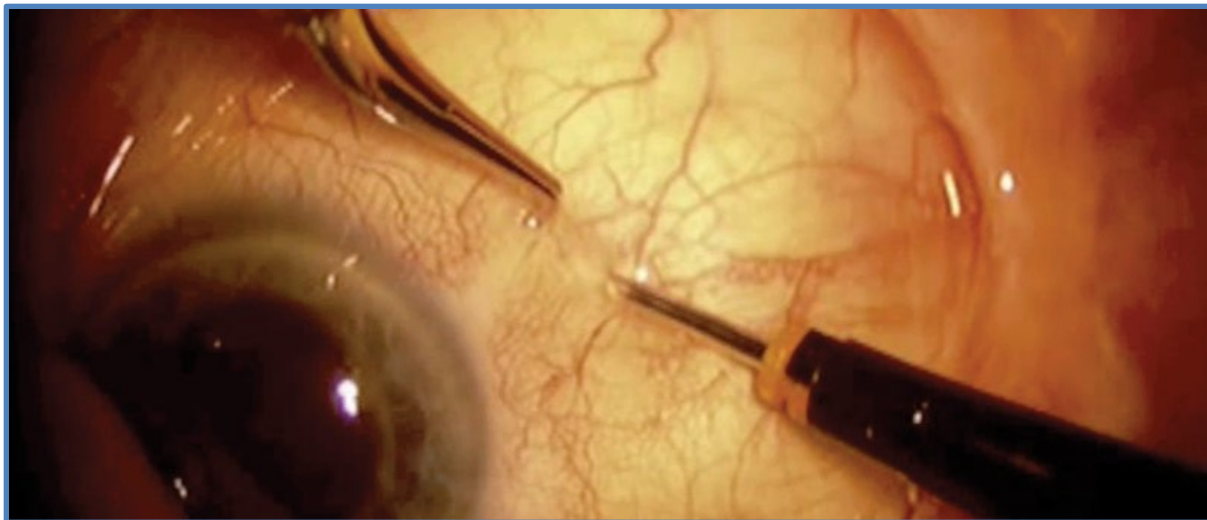
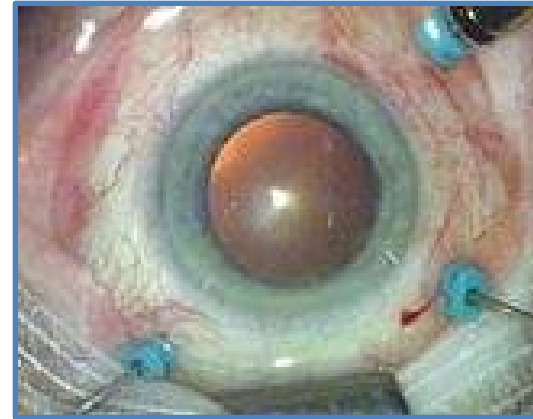


PPV-video

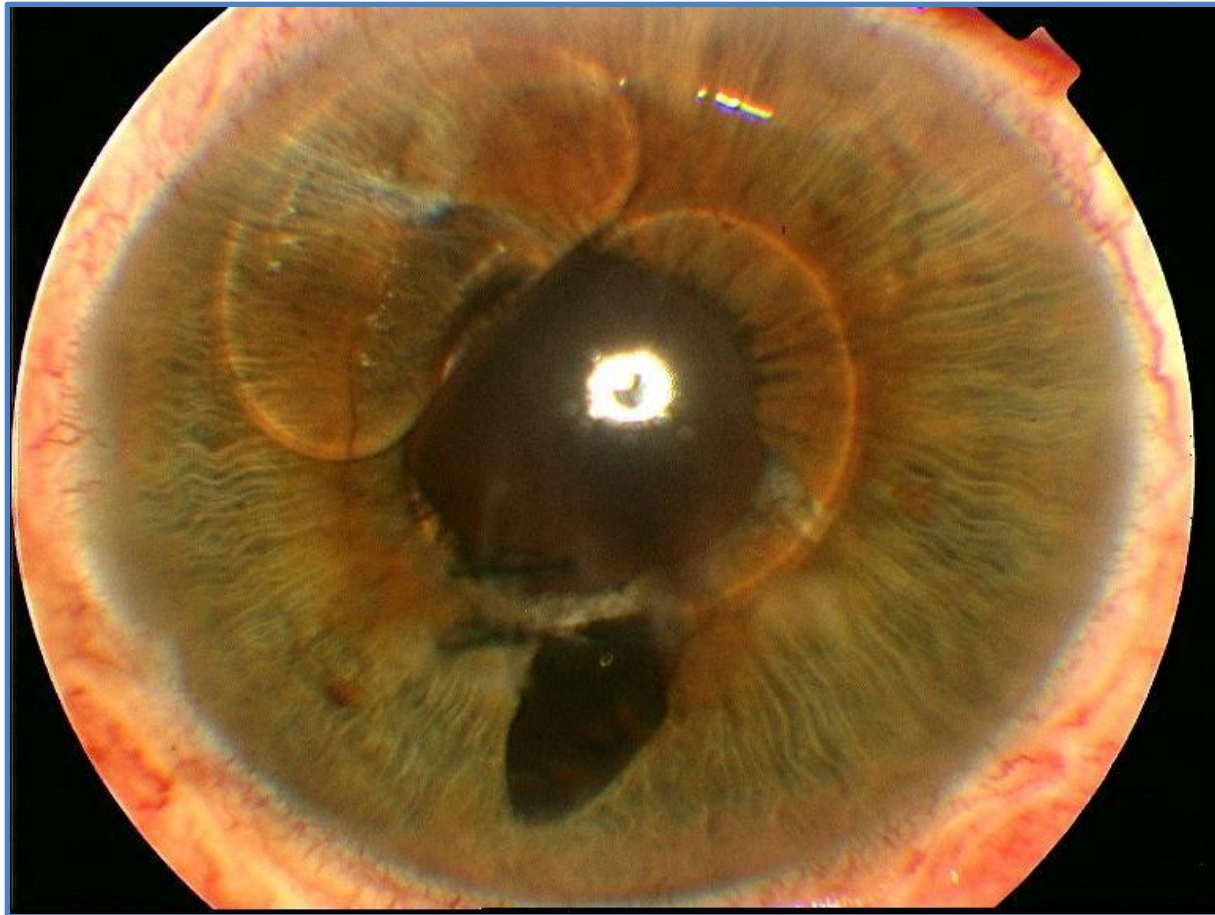


PPV -23 or 25 G

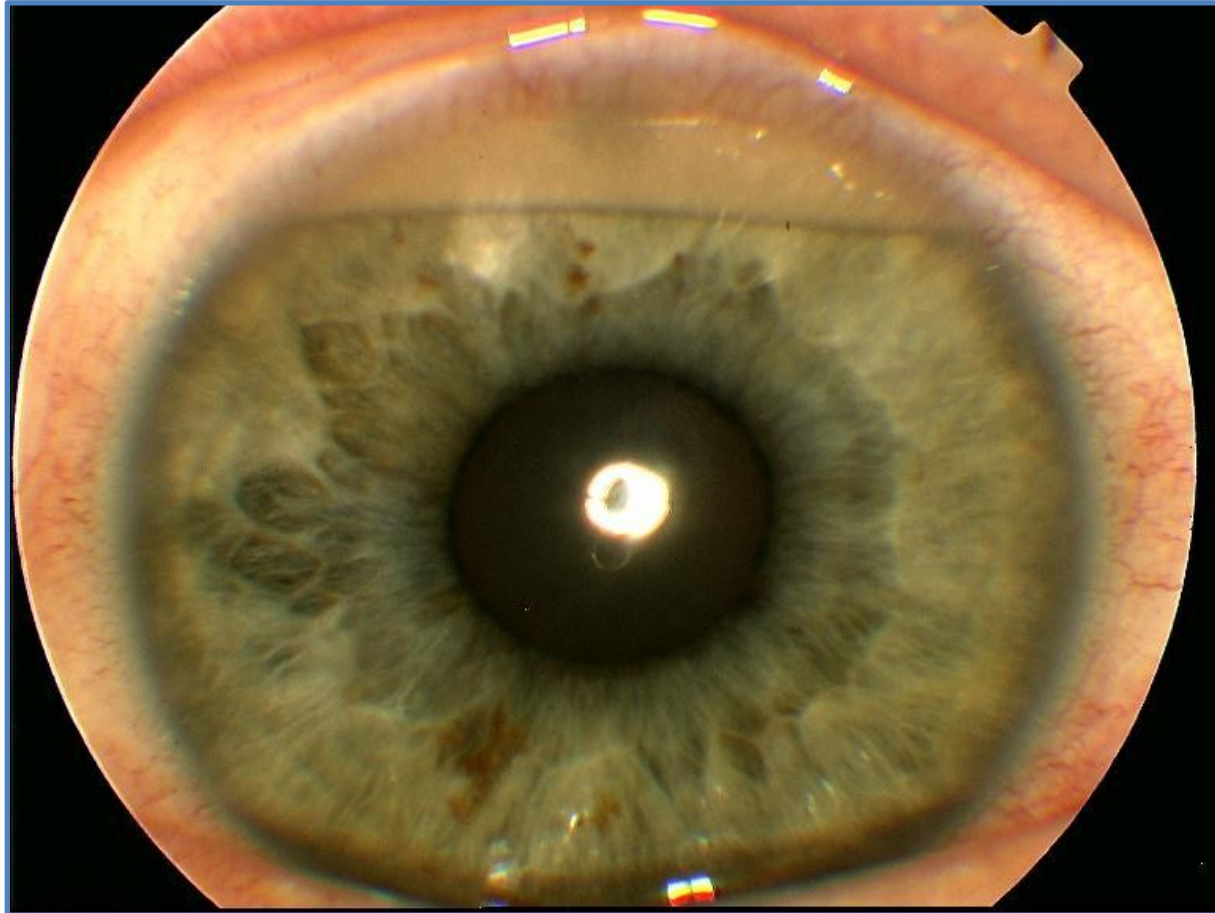
- Sutureless surgery
- 23 G (0,57 mm)
- 20 G (0,45 mm)



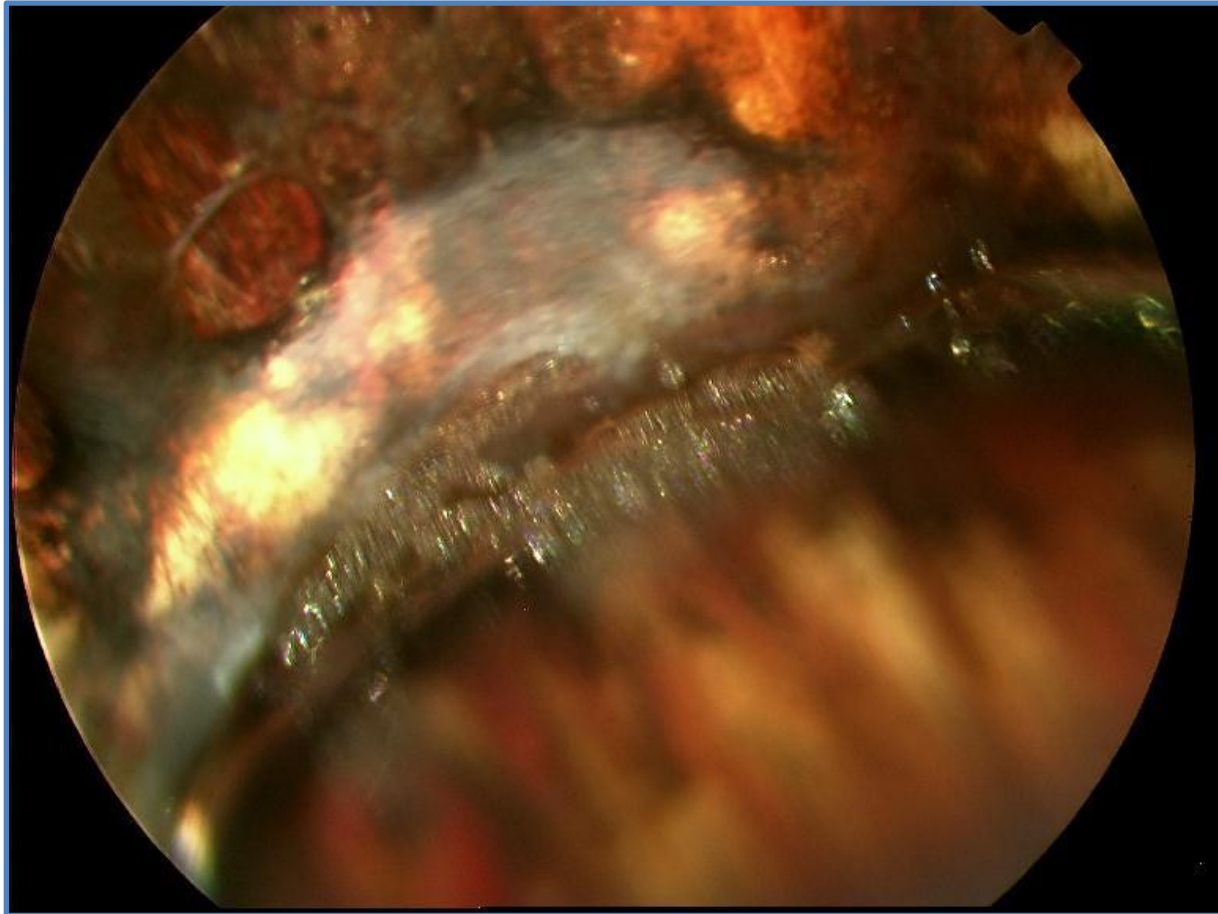
Complications



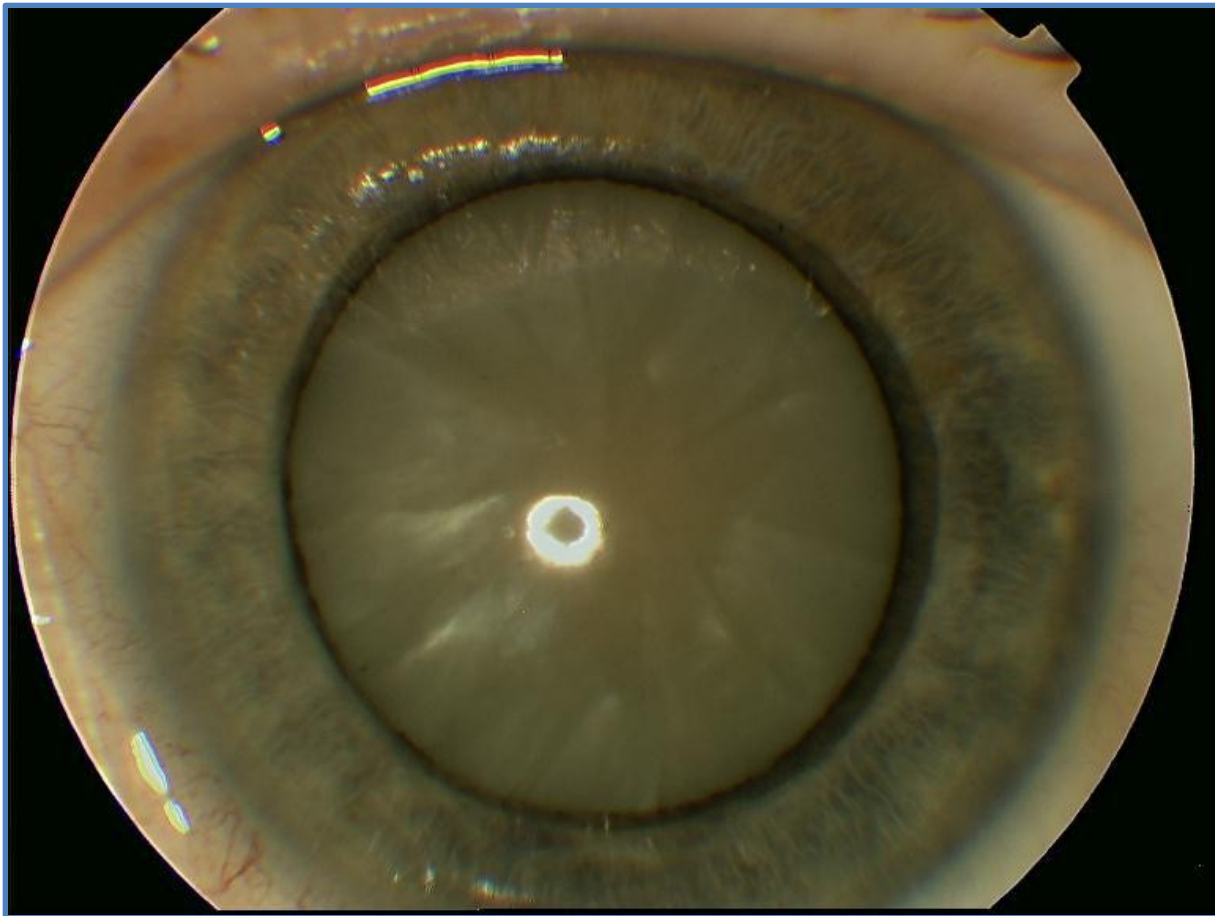
Complications



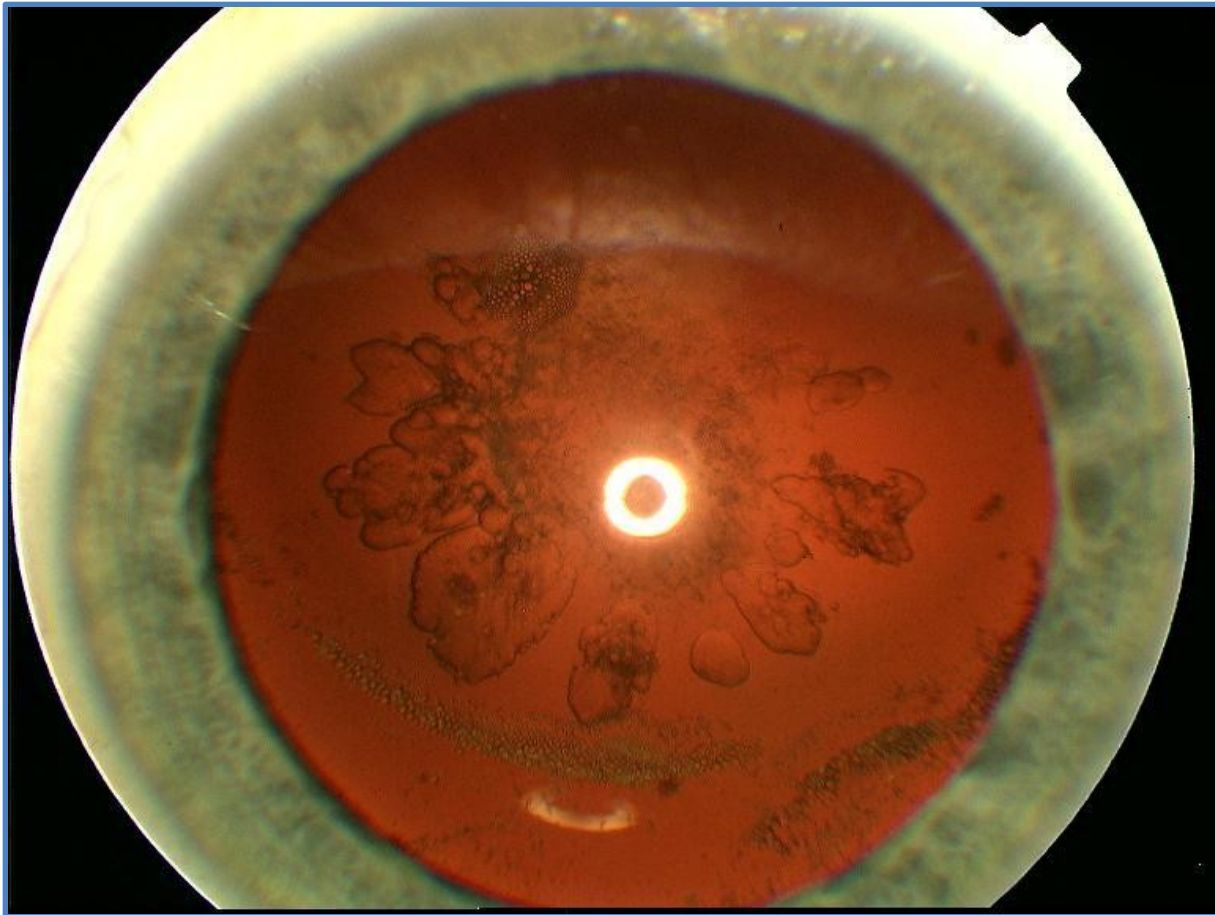
Complications - emulsification



Complications

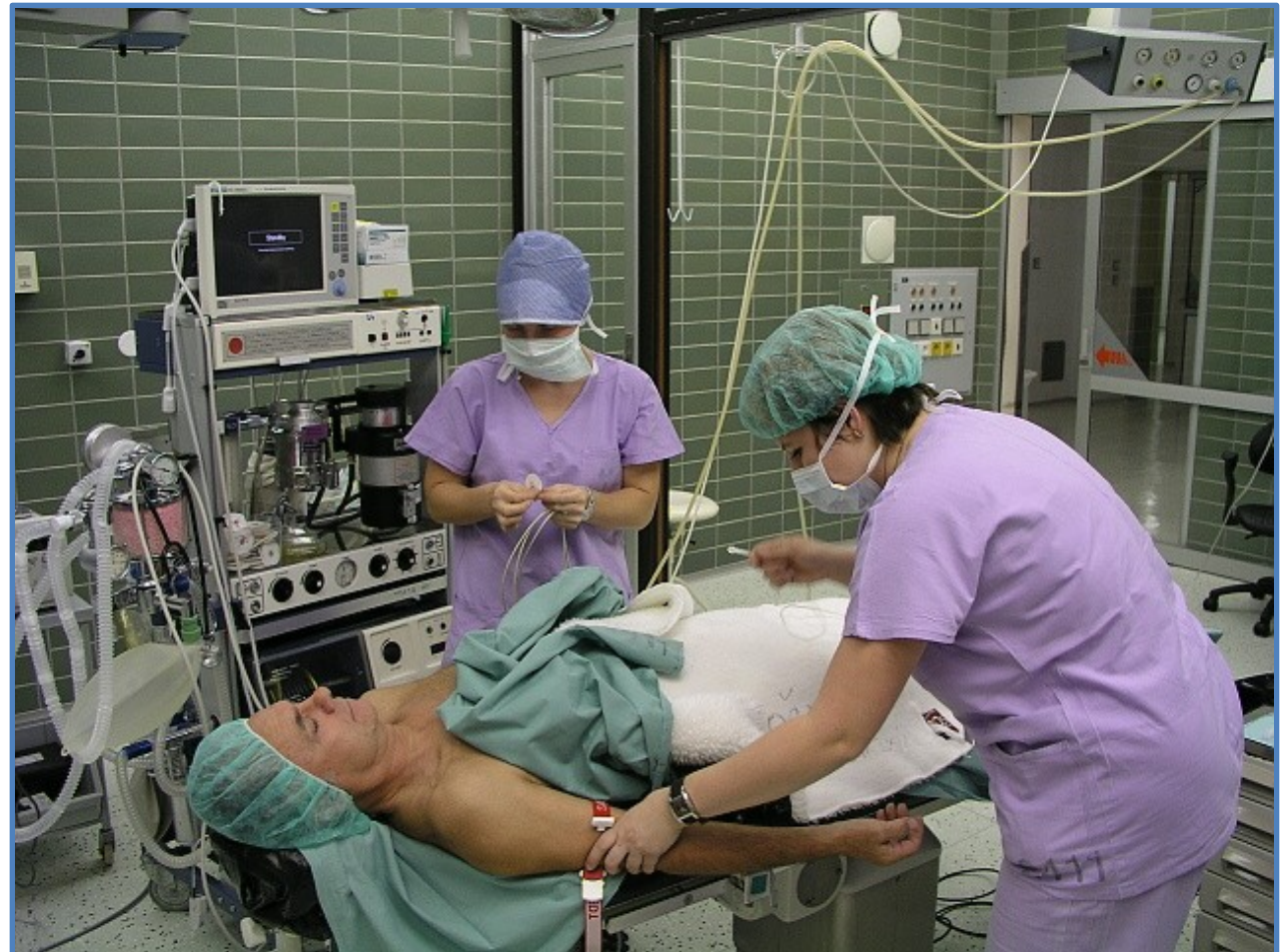

Complications

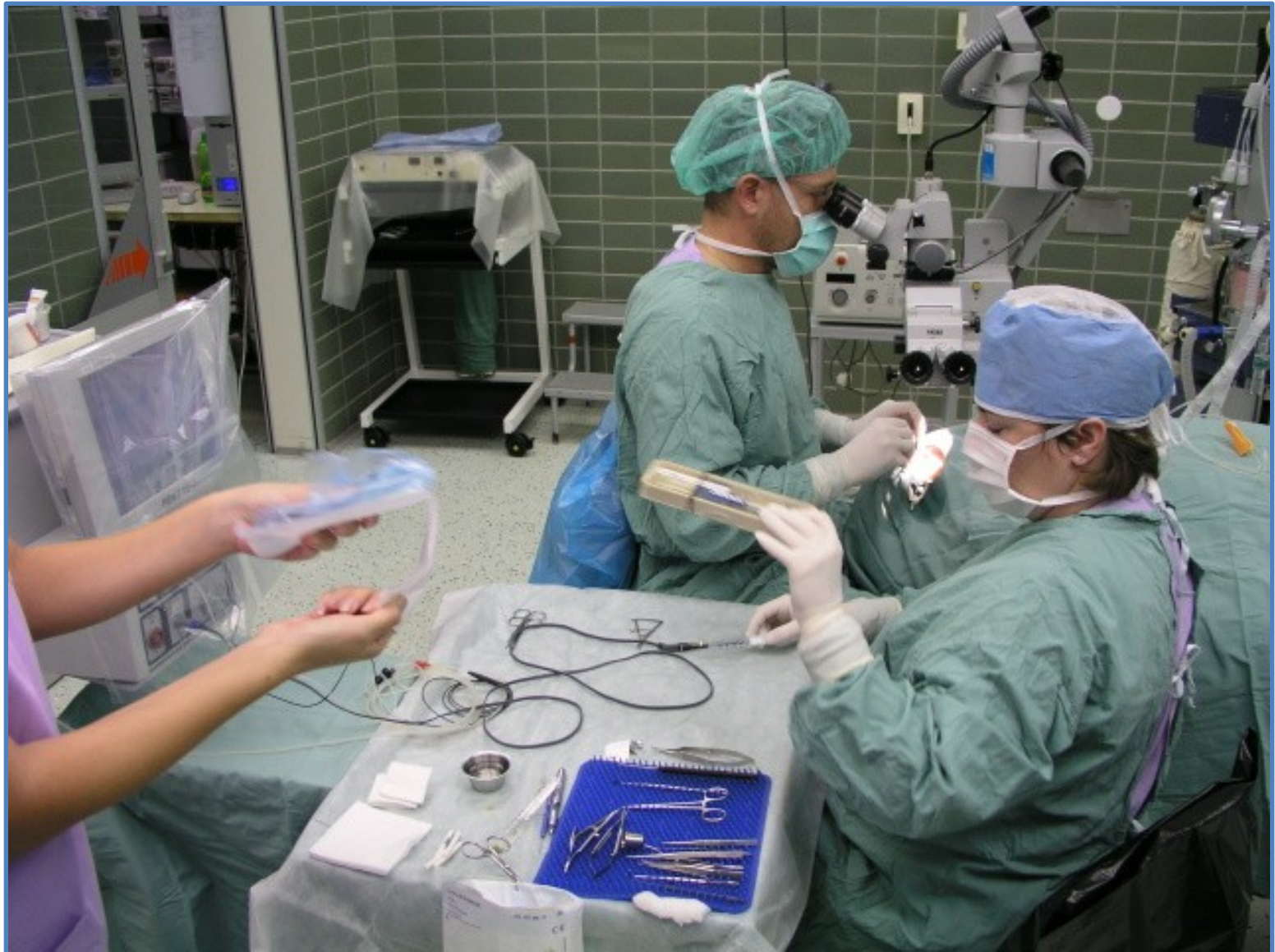

Anesthesia

- GA
- ANS
- LA



Surgery



Surgery

