

Hypertensive retinopathy

- ◆ Acute systemic hypertension causes constriction of the retinal arterioles and clinically focal narrowing.
- ◆ Prolonged acute systemic hypertension may cause disruption of the blood-retinal barrier.
- ◆ Clinically, flame or splinter hemorrhages, macular exudate (star) and cotton-wool spots are observed.
- ◆ Malignant hypertension may result in swelling of the optic nerve head.

Hypertensive retinopathy

- ◆ Prolonged systemic hypertension results in thickening of the walls of the retinal arterioles and the ophthalmoscopic signs of retinal arteriolar sclerosis.
- ◆ Clinically, the thickened arterioles have a broader and brighter light reflex, in the place where arteries cross veins thickening of the artery causes compression of the vein.

Diabetic retinopathy

- ◆ Diabetic retinopathy is one of the most frequent causes of new blindness in Europe and USA.
- ◆ 25% of the diabetic population has some form of diabetic retinopathy.
- ◆ The prevalence of all types of retinopathy in the diabetic population increases with the duration of diabetes and patient age.

Diabetic retinopathy

- ◆ Diabetic retinopathy is microangiopathy.
- ◆ Early in the course of diabetic retinopathy certain physiologic abnormalities have been identified- impaired autoregulation of the retinal vasculature, alterations in retinal blood flow, and breakdown of the blood- retinal barrier,

Diabetic retinopathy

- ◆ Later in the course of diabetic retinopathy we observe capillary closure.
- ◆ Capillary closure is believed to result in retinal ischemia.
- ◆ Retinal ischemia causes the release of a vasoproliferative factor stimulating neovascularization.

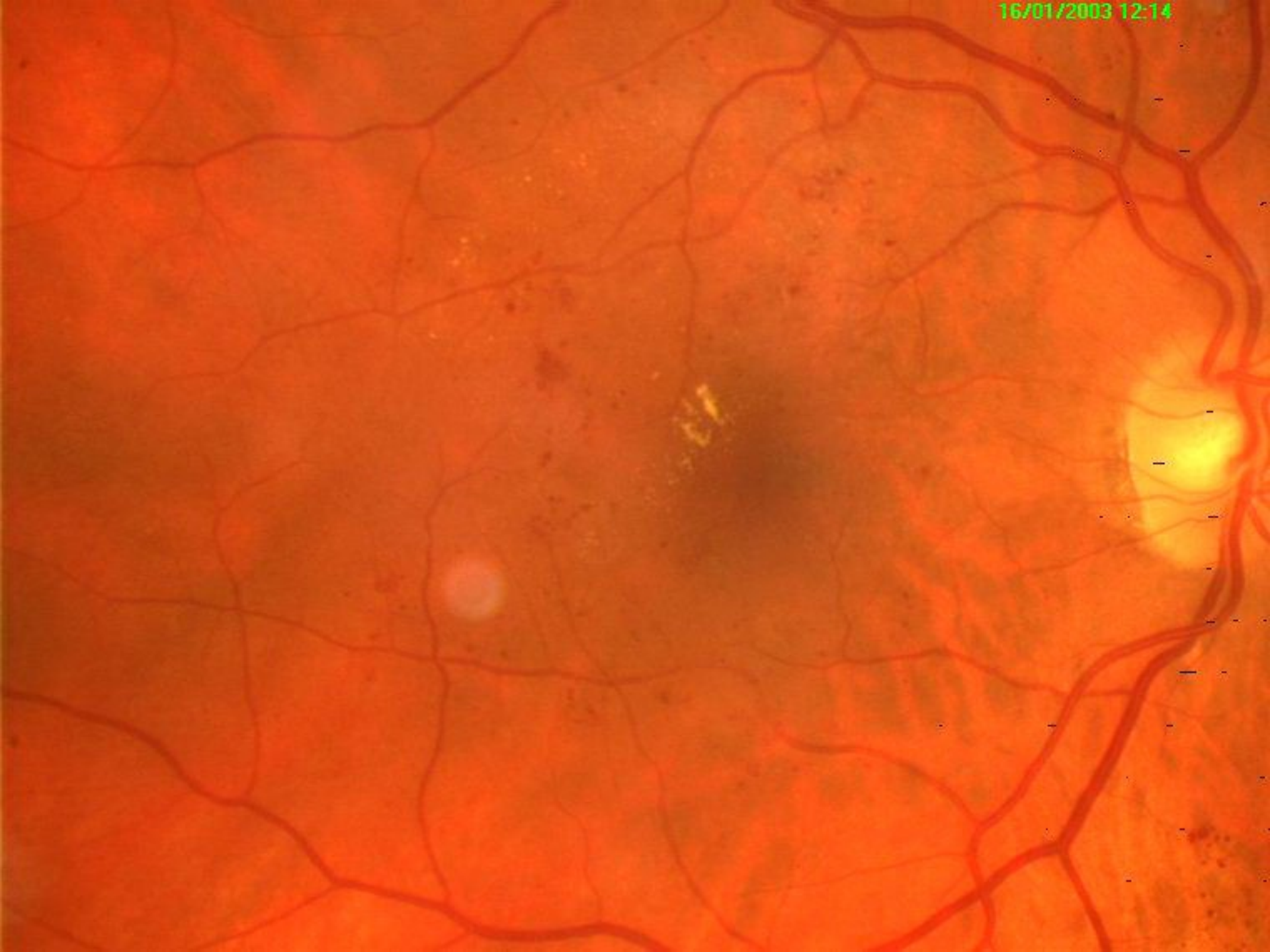Diabetic retinopathy

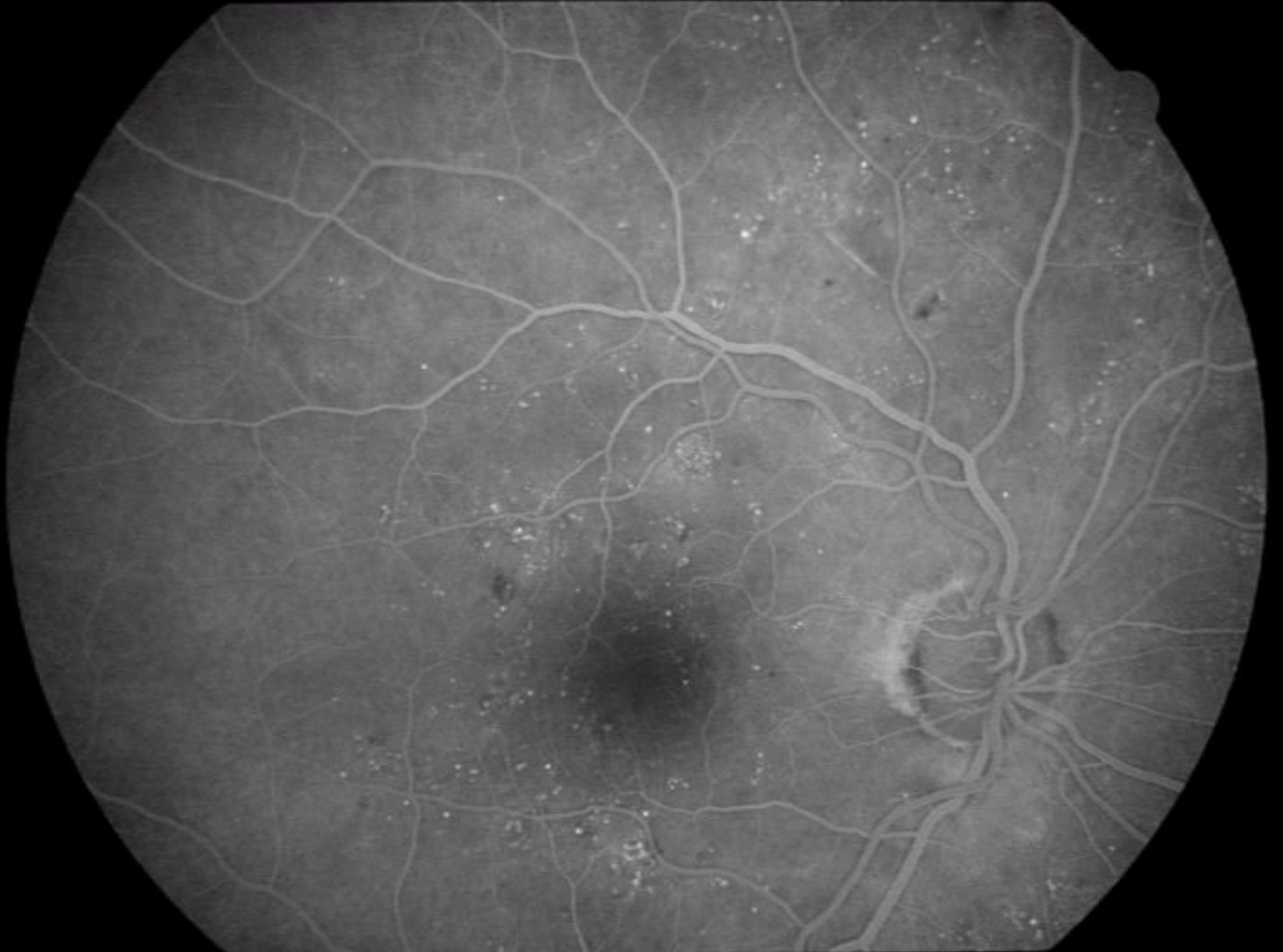- ◆ For clinical use diabetic retinopathy may be classified into two stages:
 1. Nonproliferative retinopathy
 2. Proliferative retinopathy

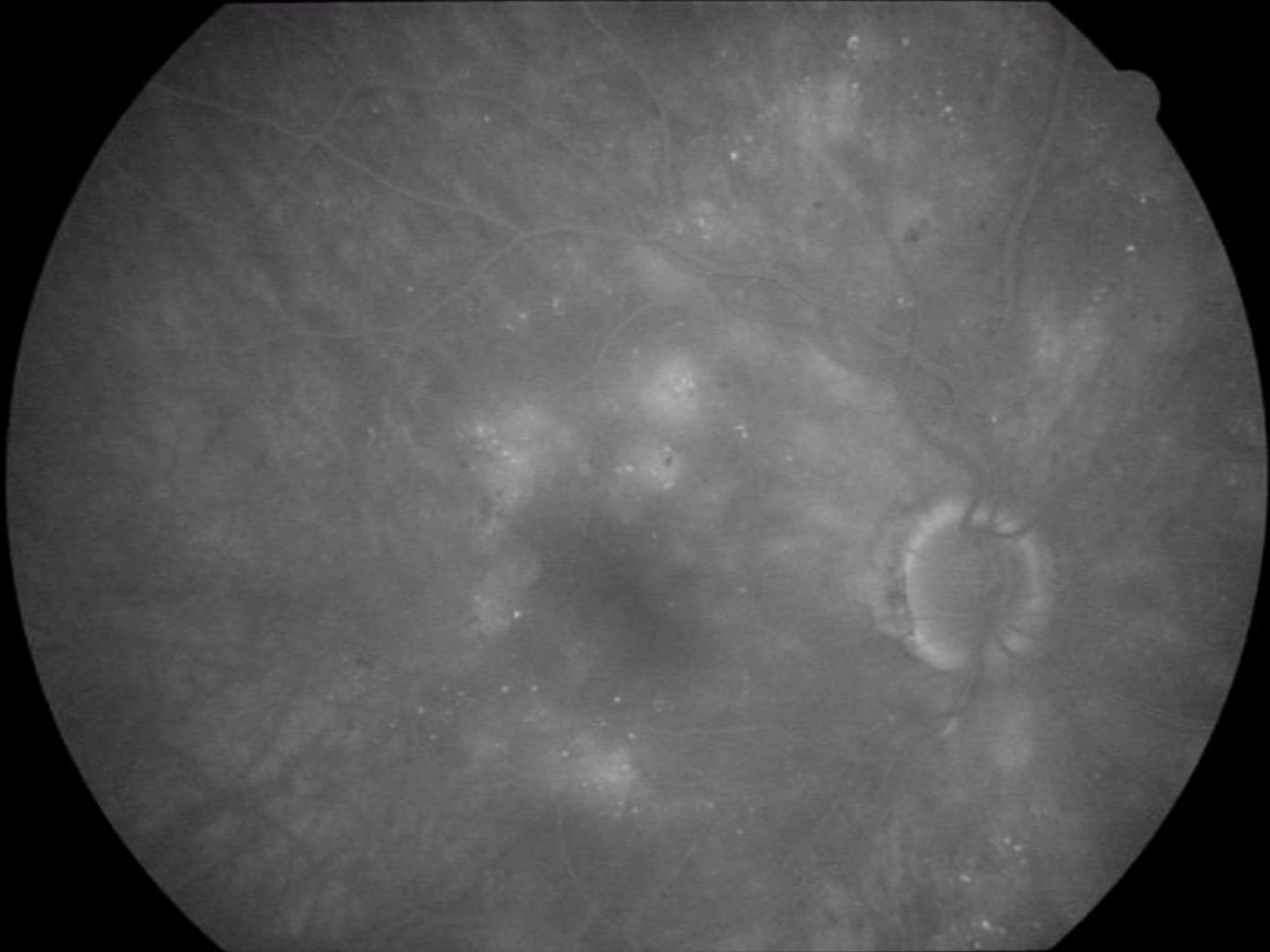
Nonproliferative diabetic retinopathy

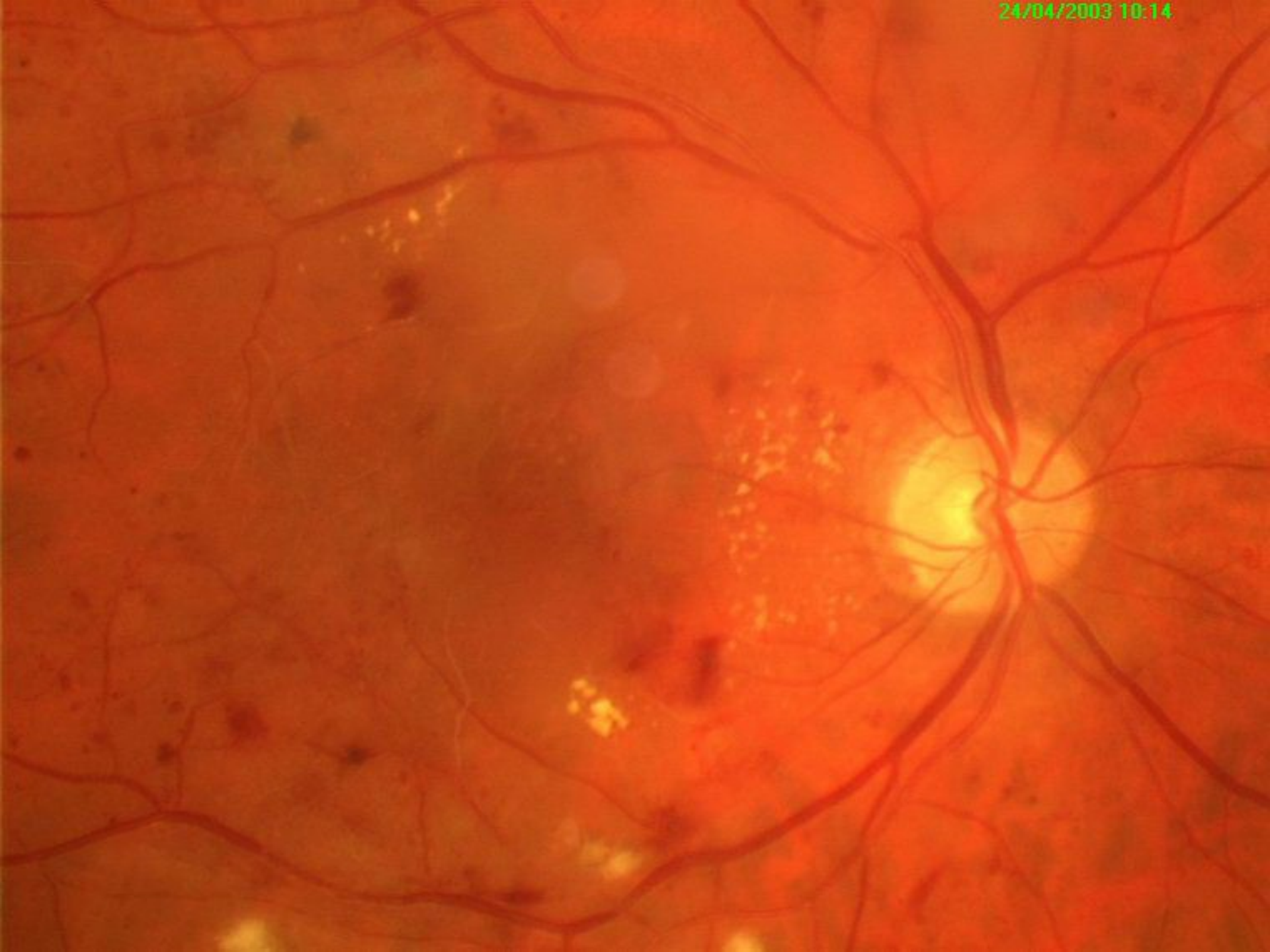- ◆ Microaneurysms
- ◆ Intraretinal hemorrhages
- ◆ Focal and diffuse edema
- ◆ Hard exsudates
- ◆ Cotton-wool spots

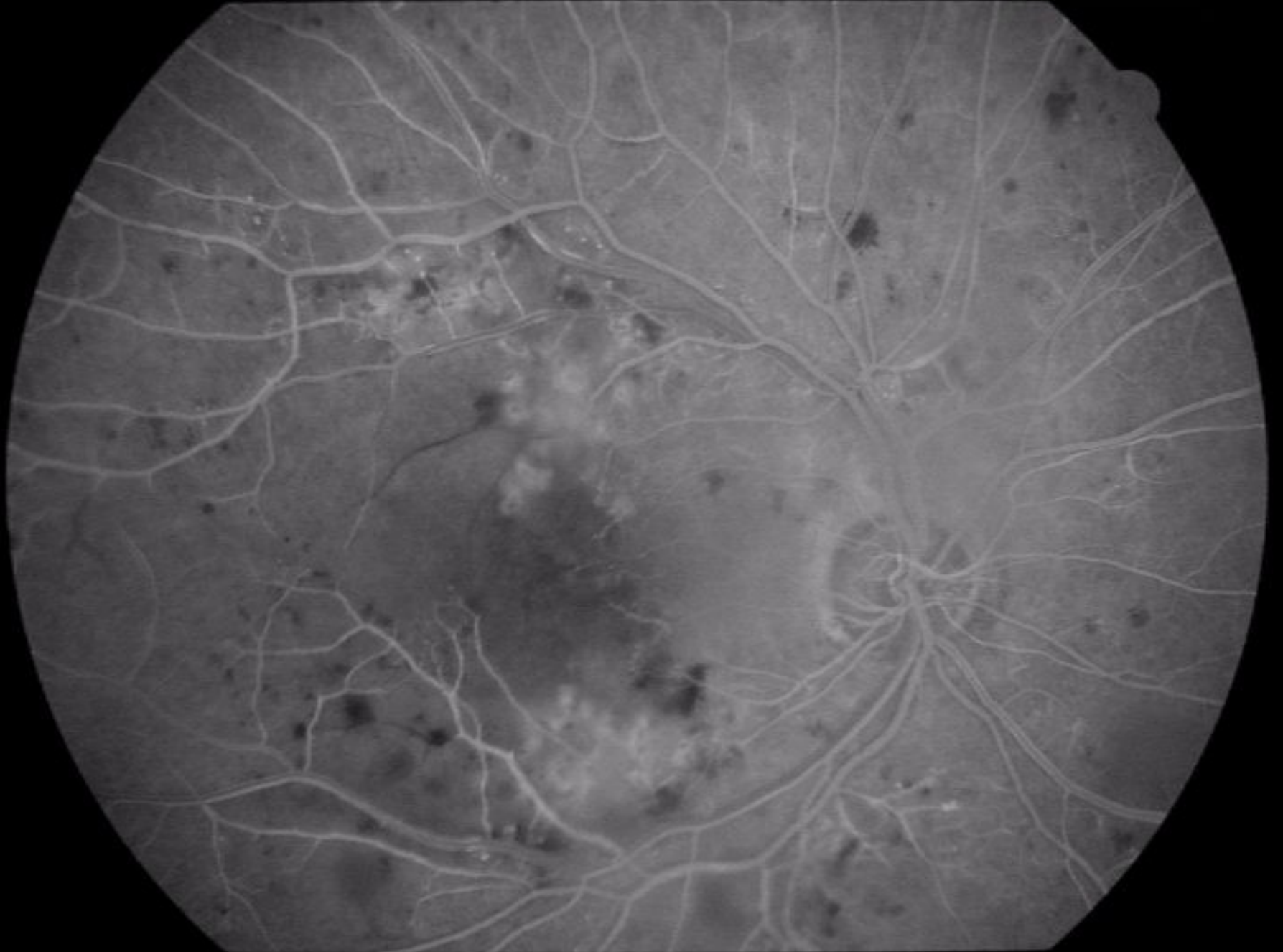16/01/2003 12:14

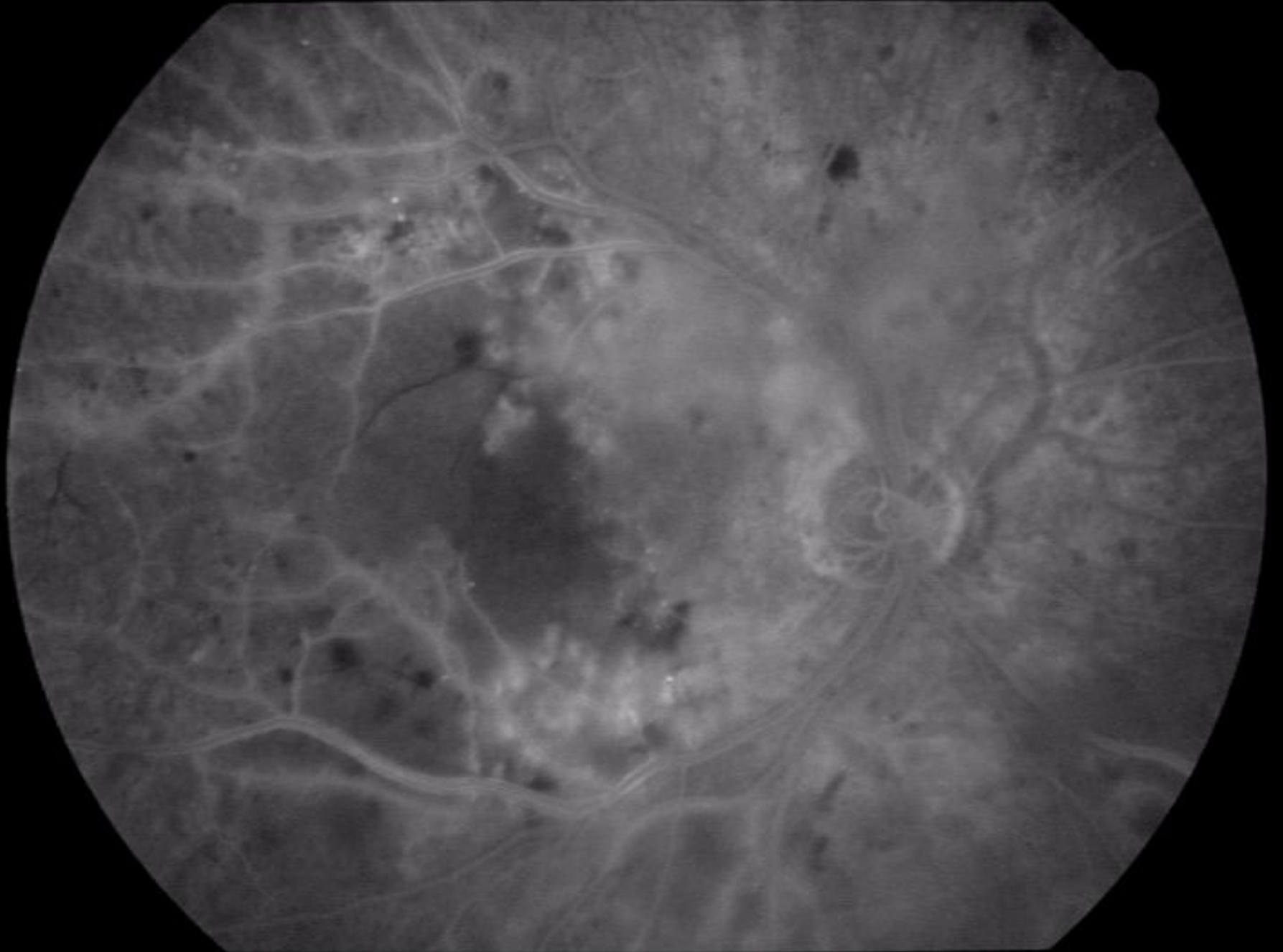








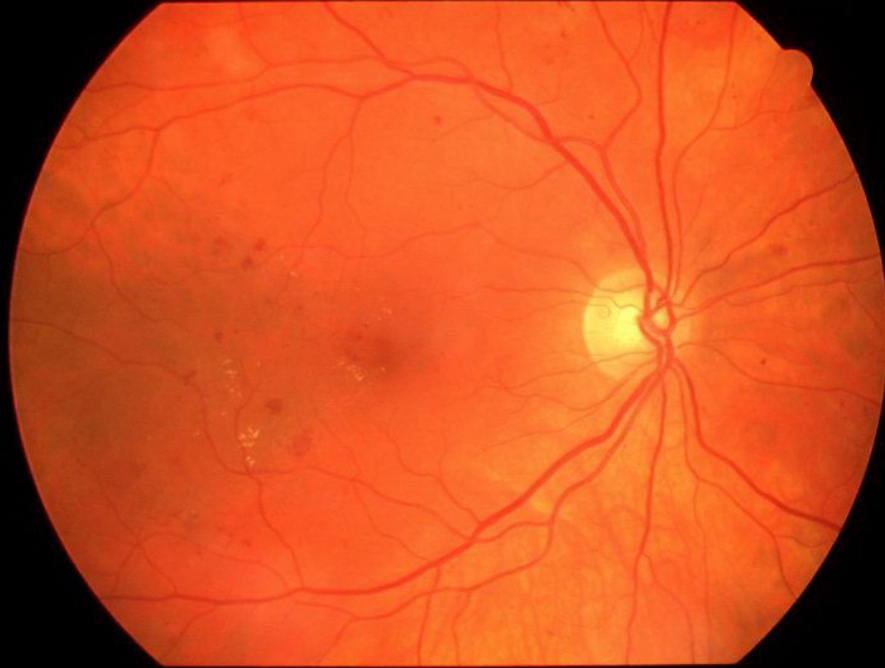




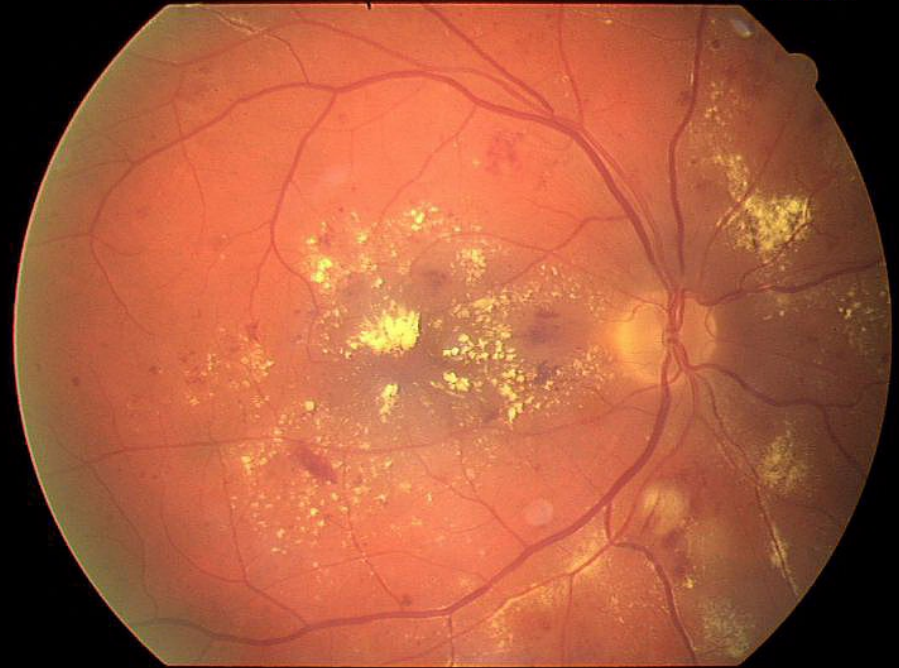
Nonproliferative diabetic retinopathy

- ◆ **Diabetic maculopathy** may present as focal or diffuse retinal thickening with or without deposits of intraretinal lipid-protein exudates.
- ◆ The visual prognosis is poorer for the diffuse edema pattern than for the focal pattern.

10/10/2002 09:21

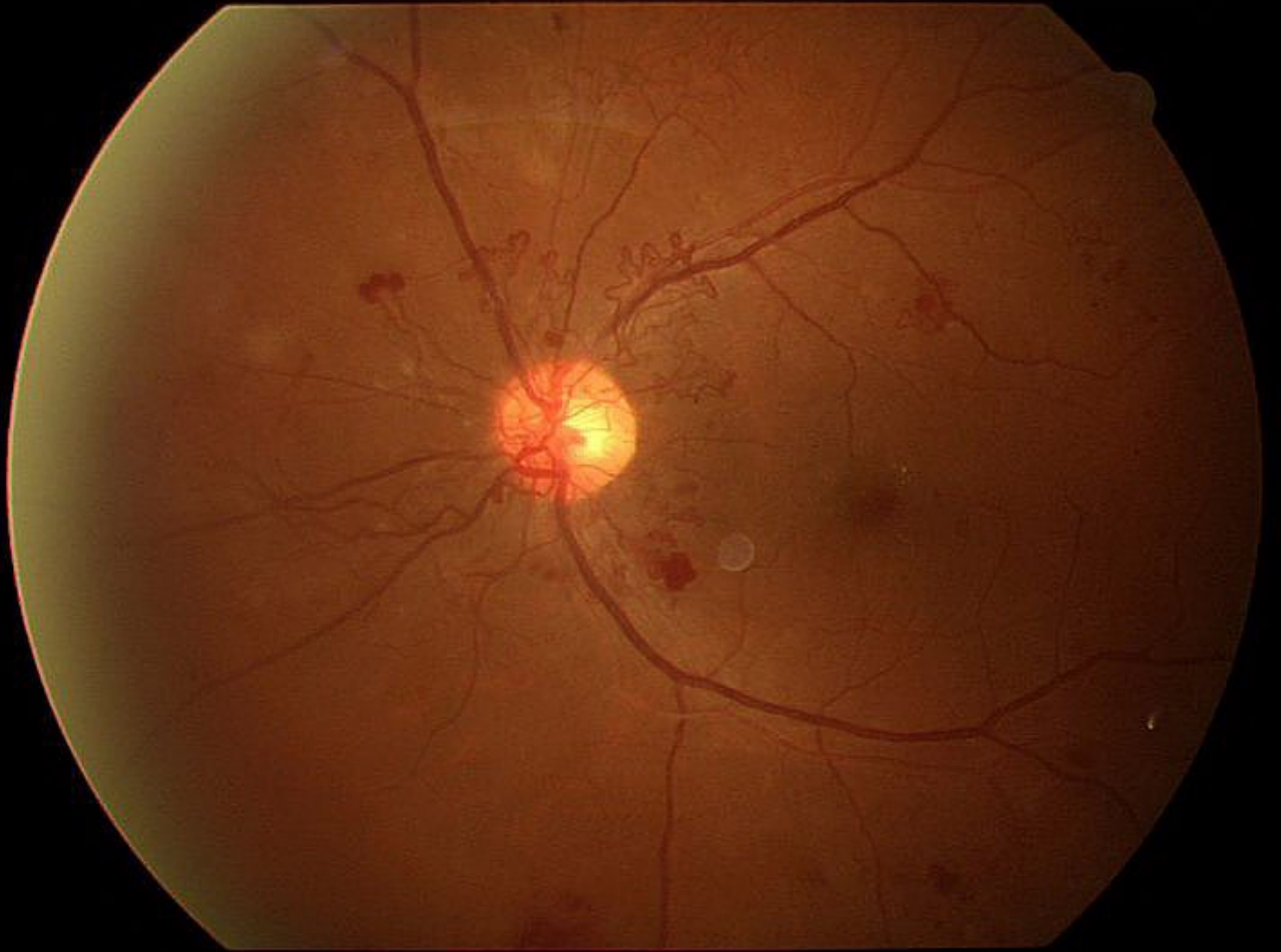


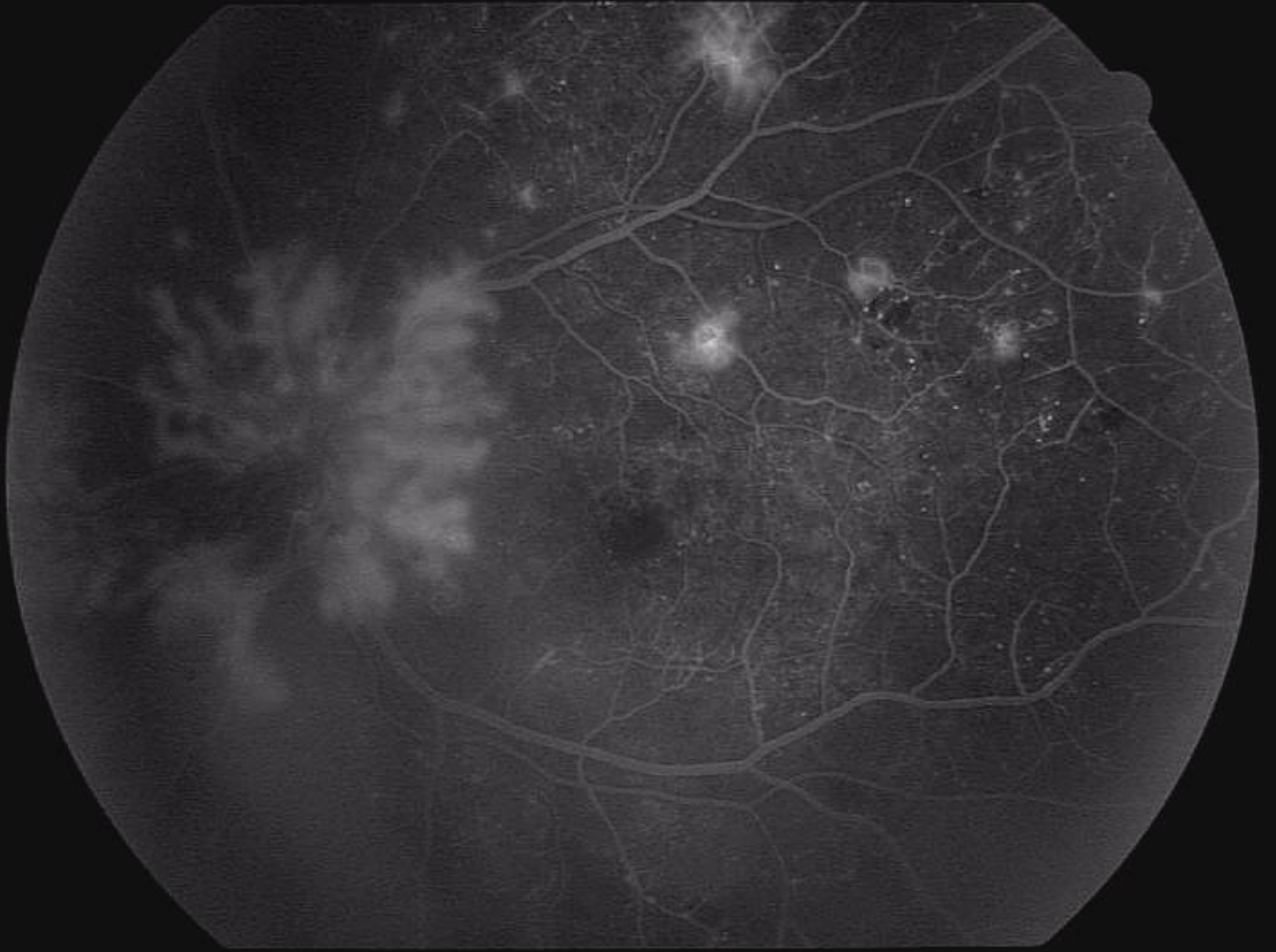
26.01.2000 10:02



Proliferative diabetic retinopathy

- ◆ The extraretinal fibrovascular proliferation is viewed as a response to widespread intraretinal capillary obliteration and ischemia.
- ◆ The neovascularization can cause haemophthalmus, traction retinal detachment, secondary glaucoma.





Diabetic retinopathy

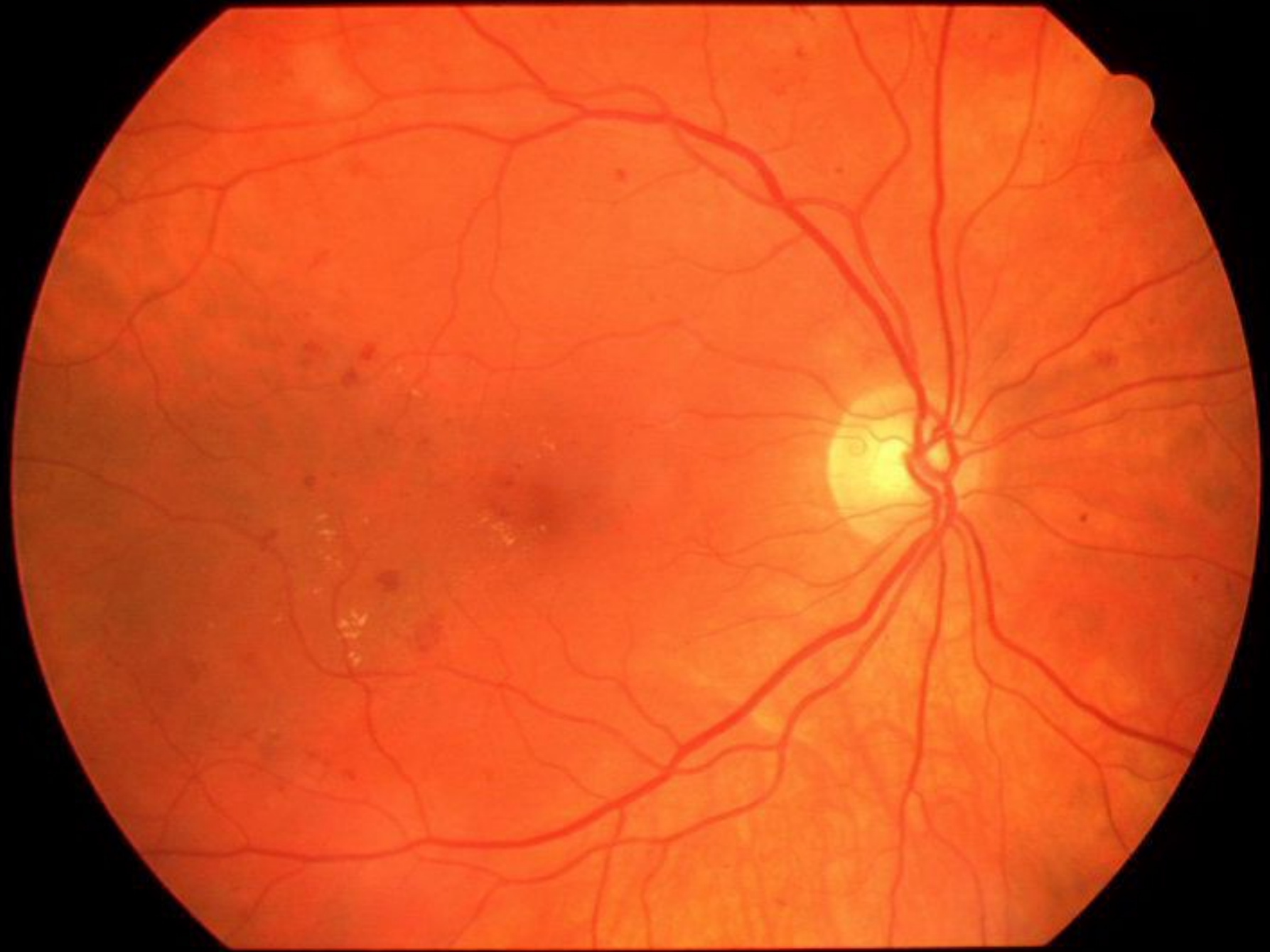- ◆ Photocoagulation is currently used to treat eyes with non-proliferative retinopathy with macular edema, and eyes with proliferative disease.

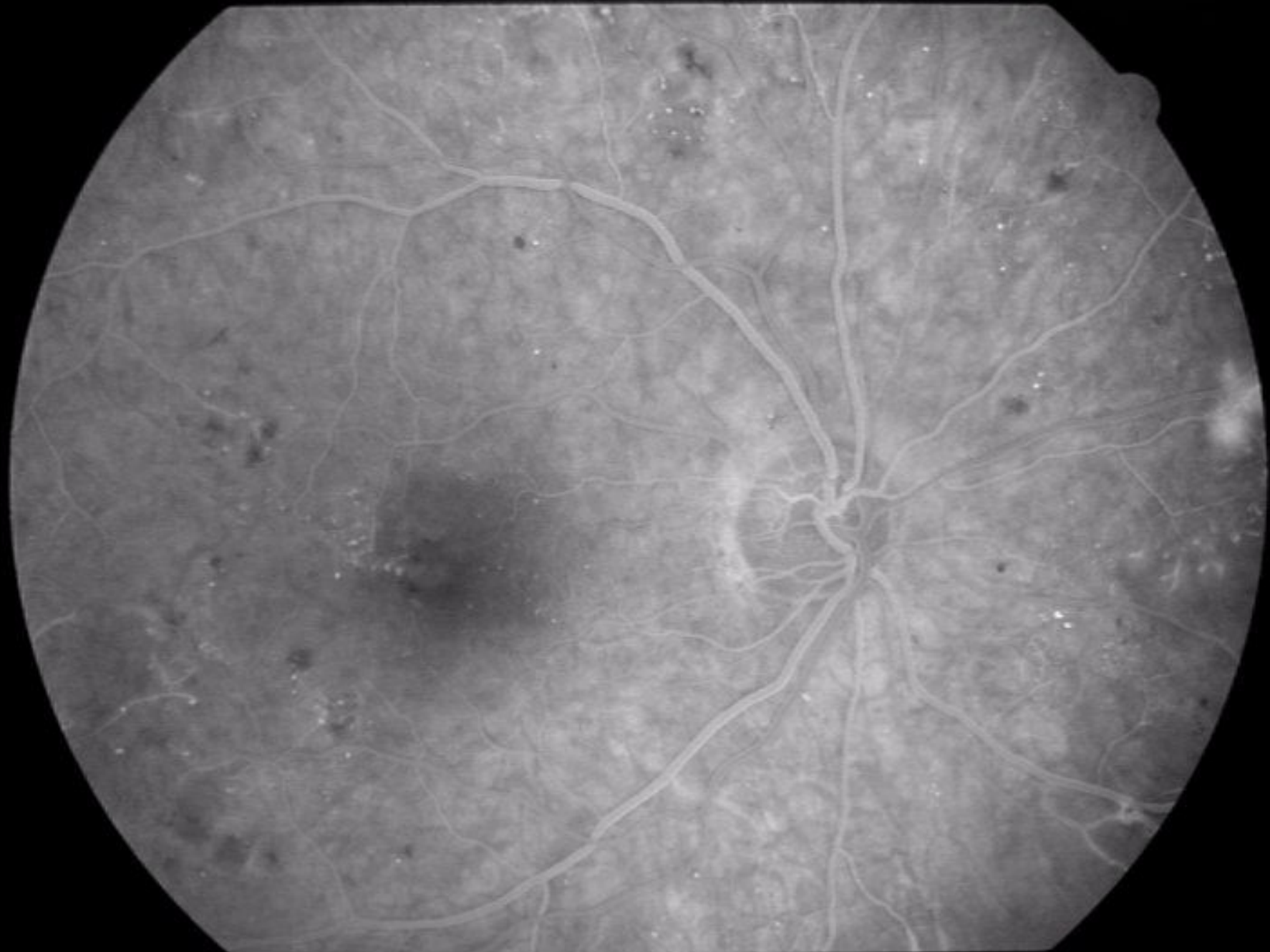
Clinically significant macular edema

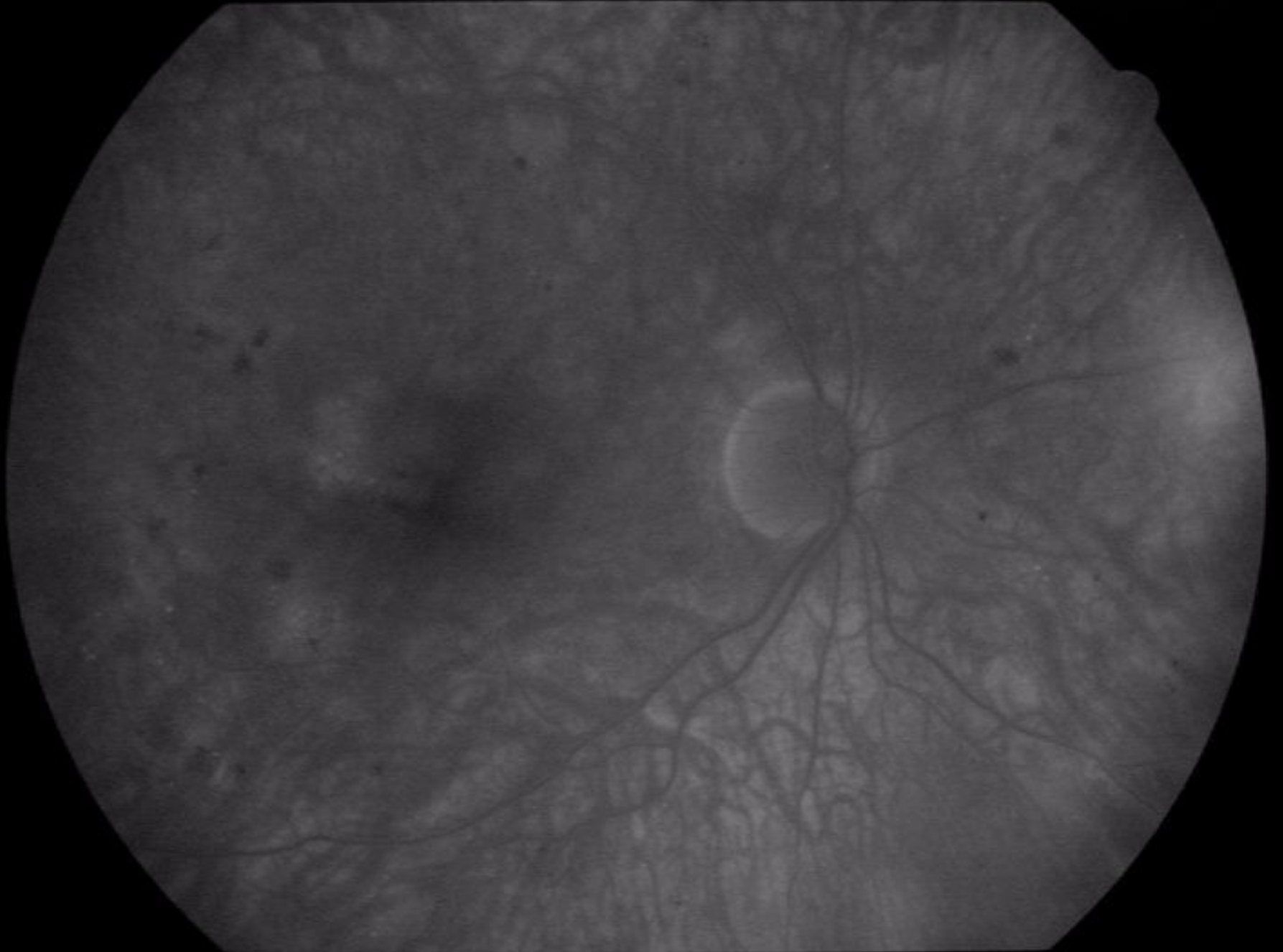
- ◆ Thickening of the retina at or within 500 microns of the center of the macula
- ◆ Hard exsudate at or within 500 microns of the center of the macula associated with thickening of adjacent retina
- ◆ A zone(s) of retinal thickening one disc area or larger any part of which is within one disc diameter of the center of the macula.

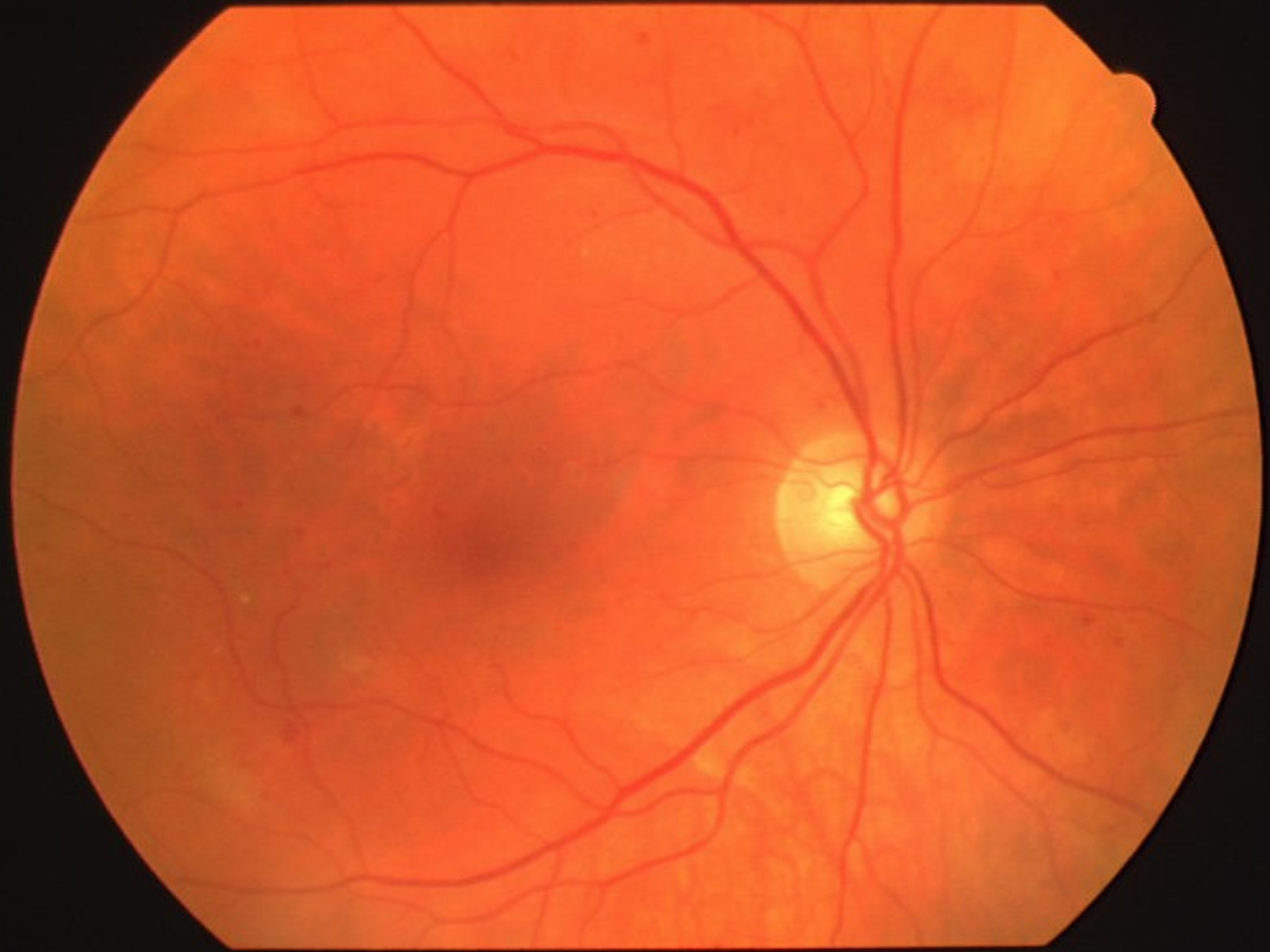Diabetic retinopathy

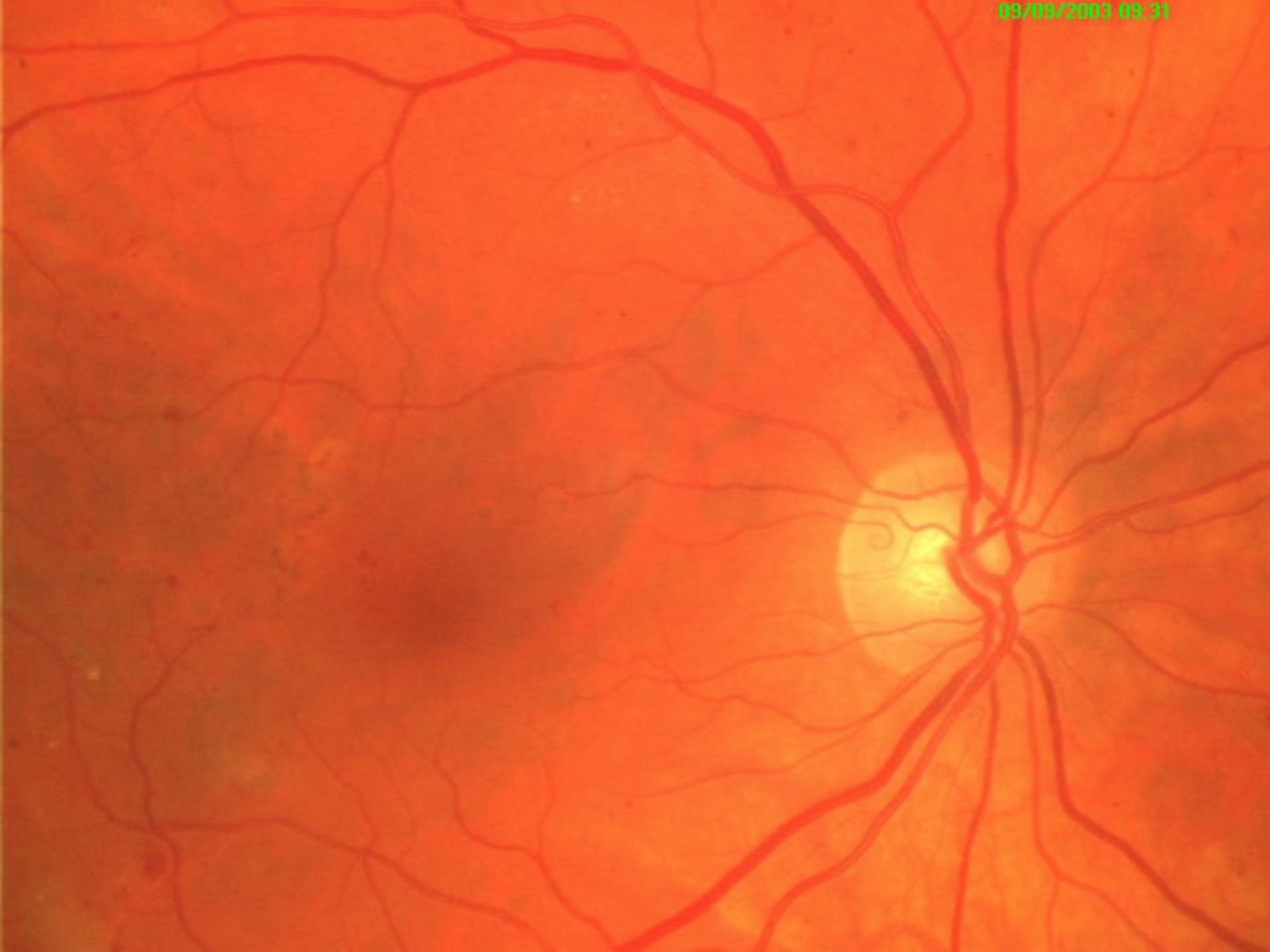- ◆ The technique of photocoagulation for **clinically significant macular edema** includes **focal therapy** directed to the leaking mikroaneurysms in the posterior retina or **grid photocoagulation** for diffuse leakage of all capillaries of the posterior retina.

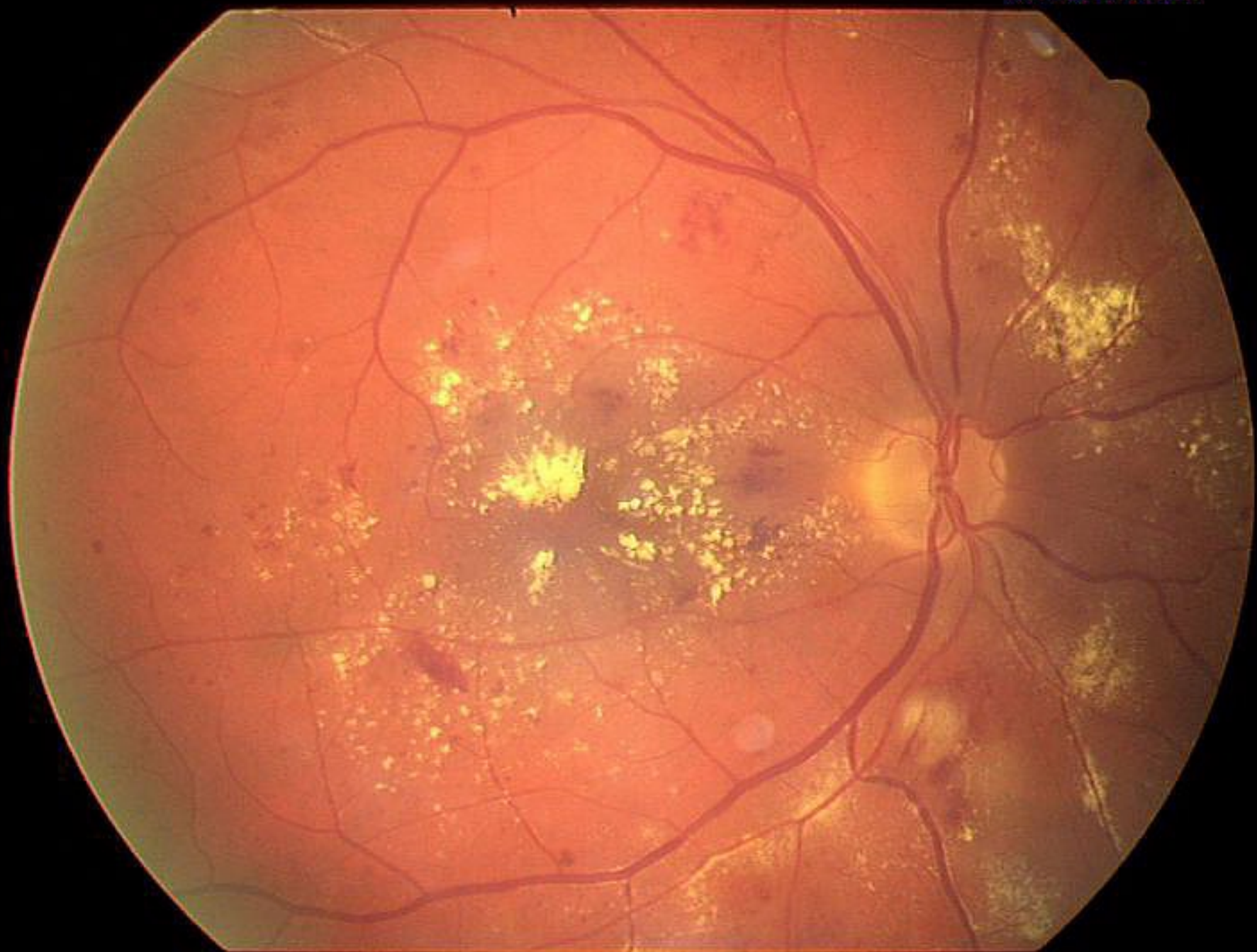


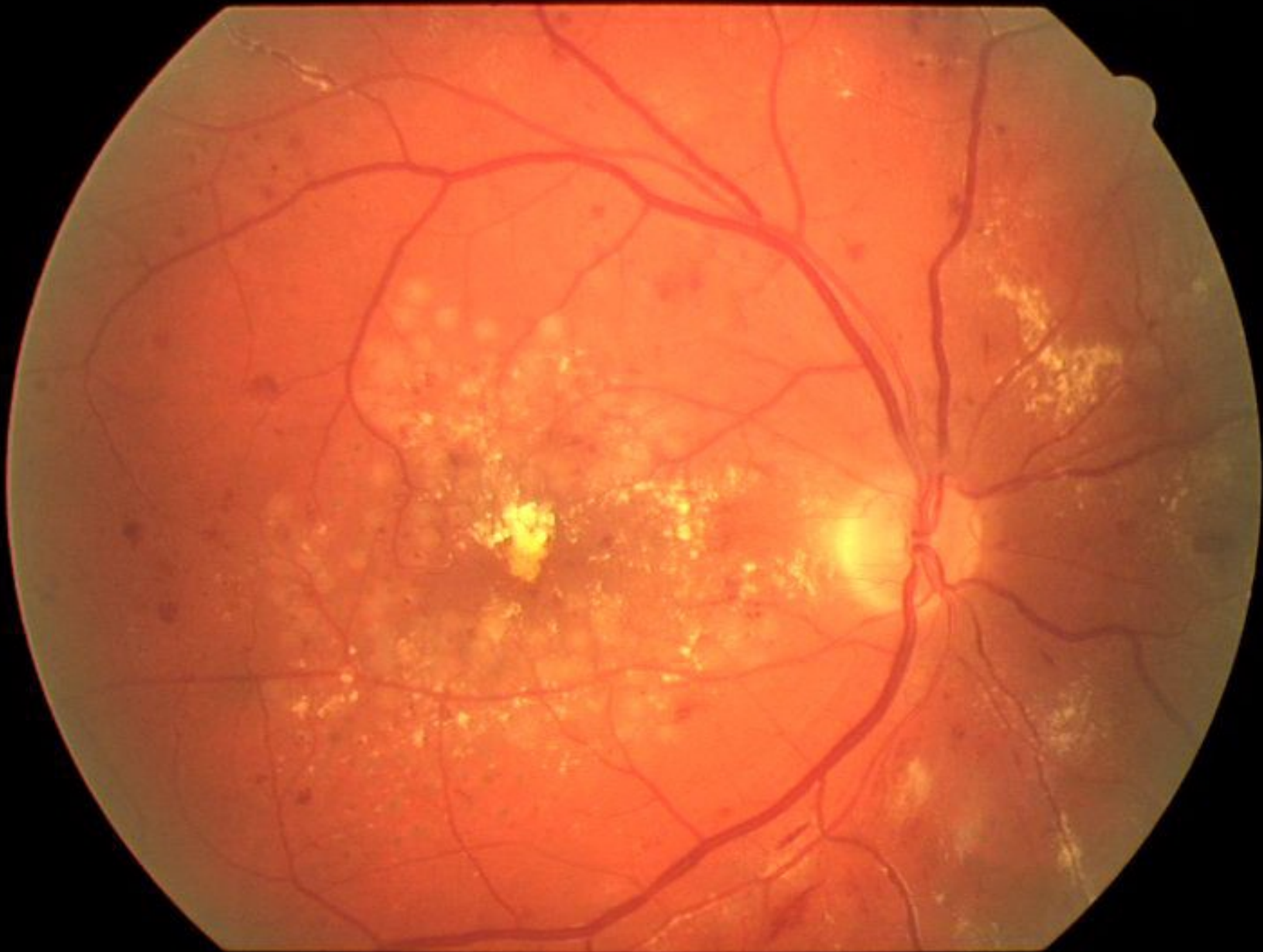
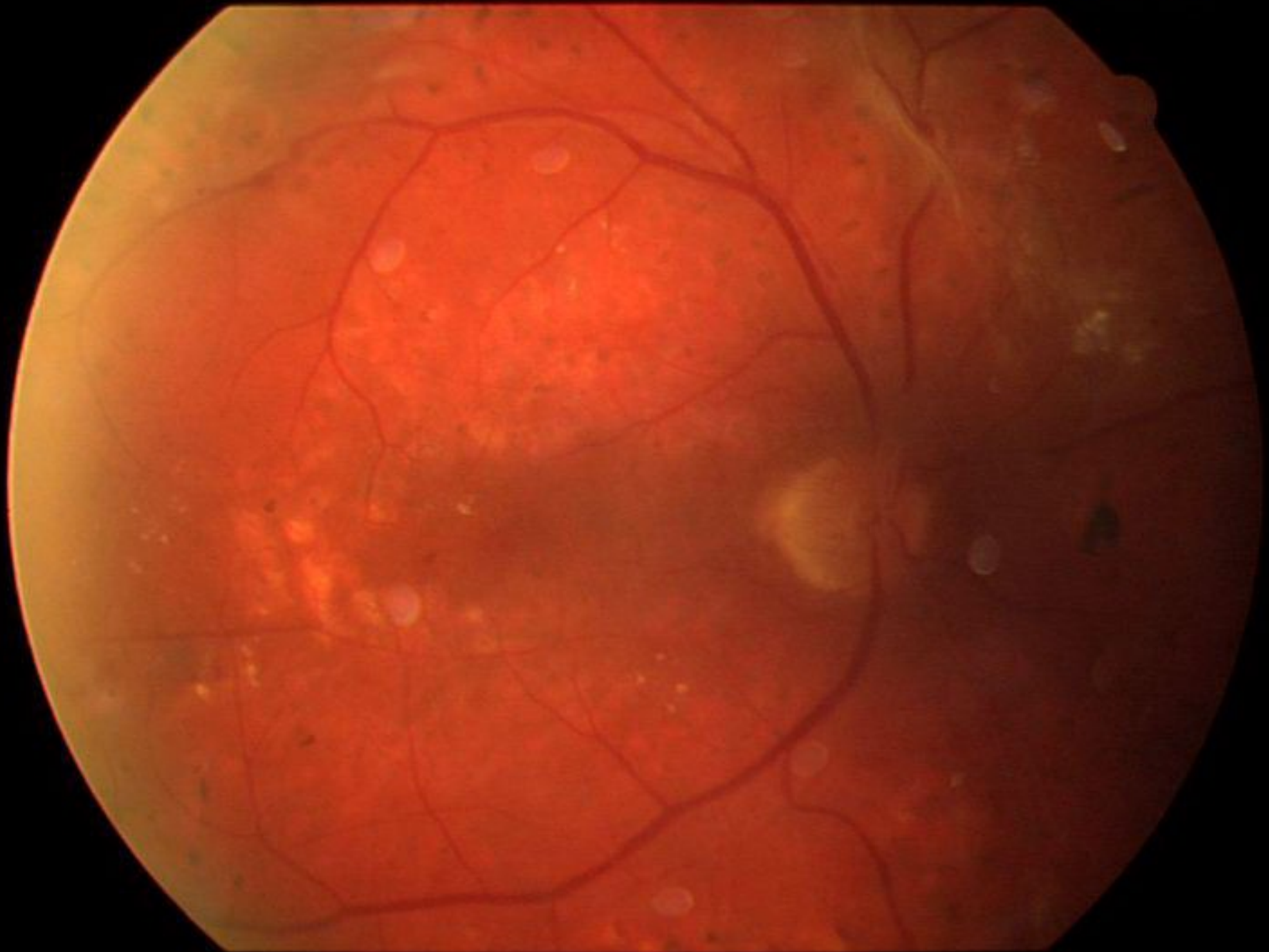










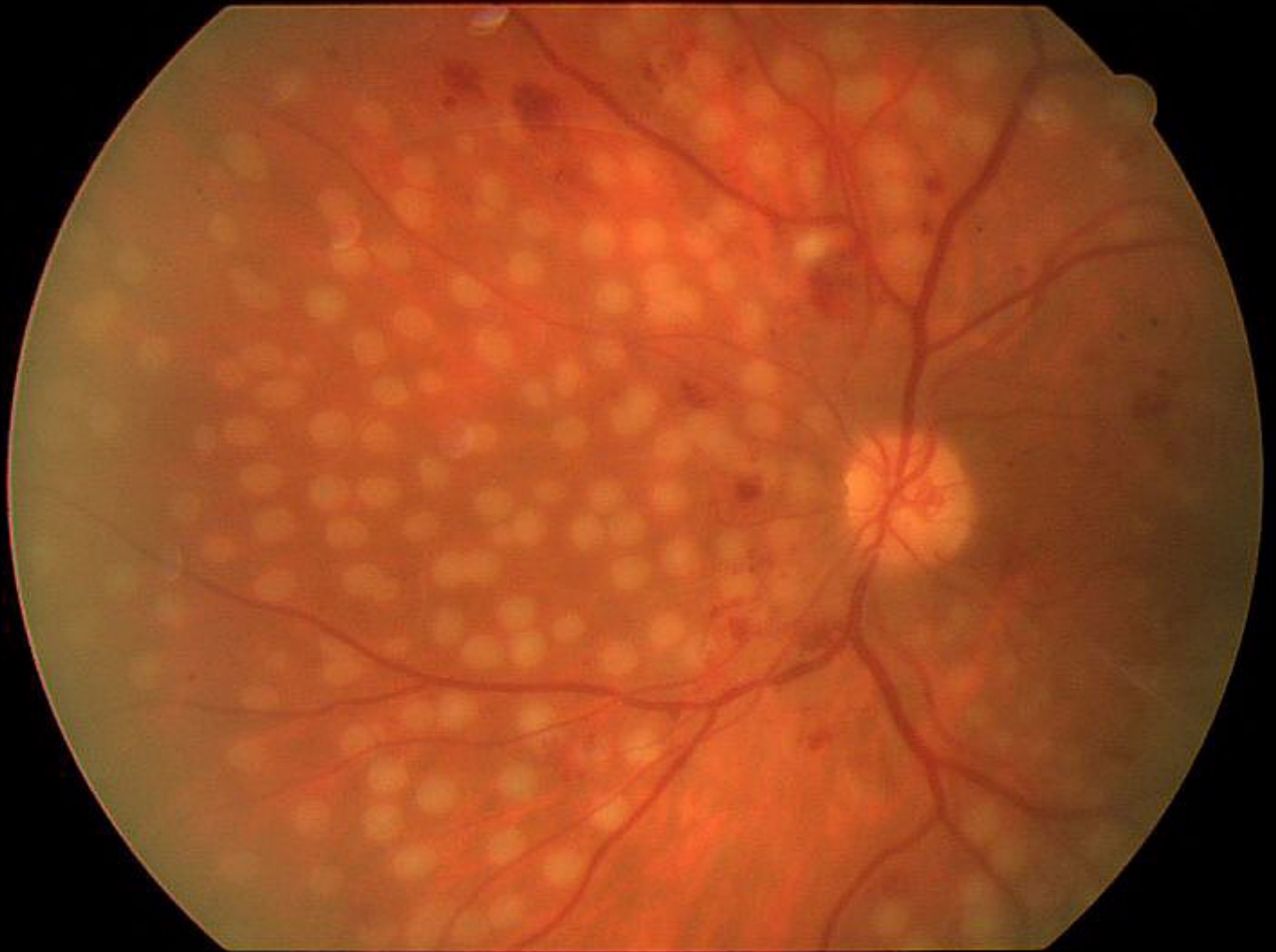


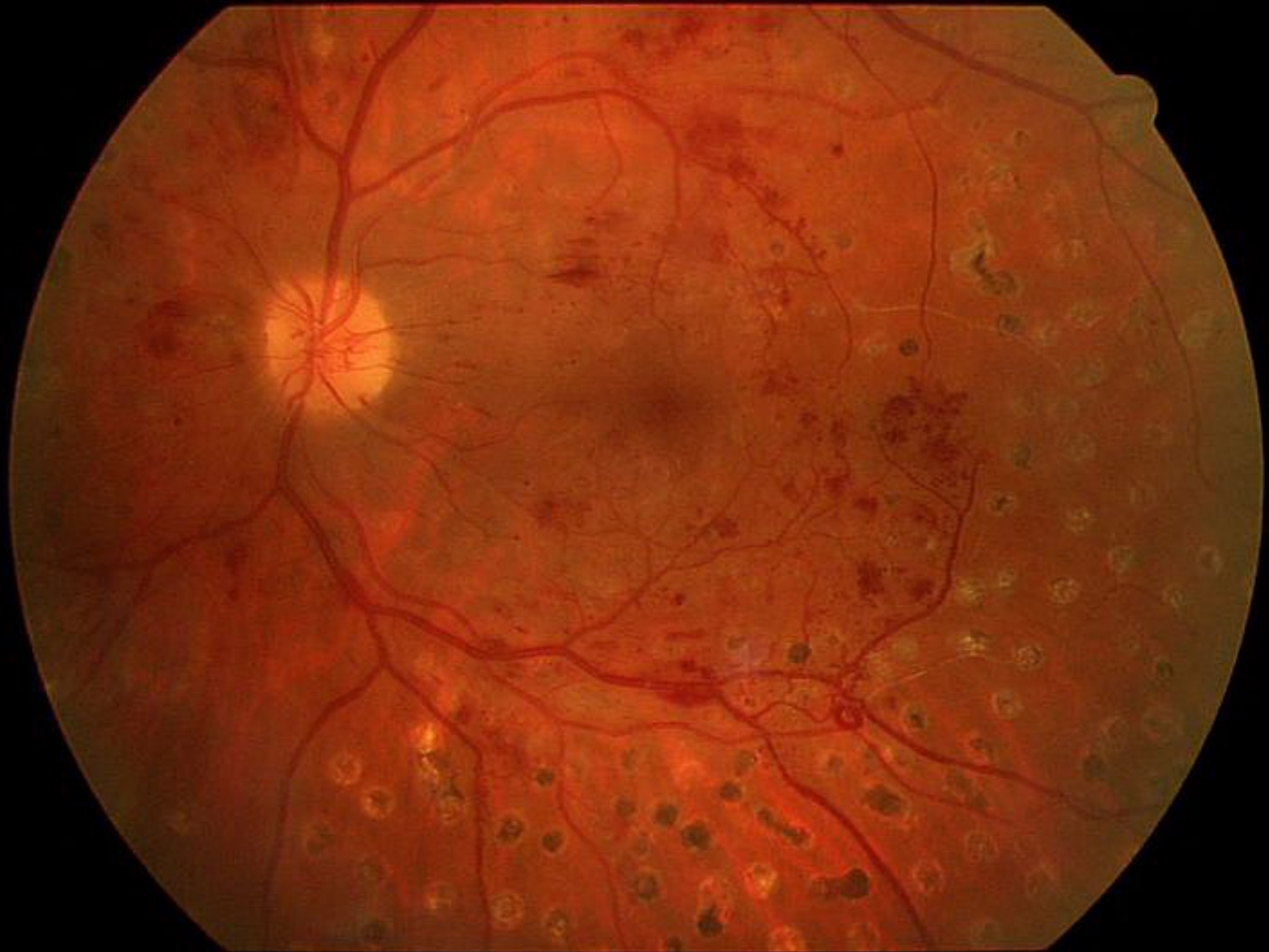Diabetic retinopathy

- ◆ For proliferative retinopathy we perform **panretinal photocoagulation**
- ◆ The goal of panretinal photocoagulation is to cause regression of neovascularizations and to prevent new vessel formation in the future.







Retinopathy of prematurity

- ◆ Retinopathy of prematurity is a proliferative retinopathy of premature and low birth weight infants.
- ◆ It is recommended to perform examination of all high-risk infants = less than 36 weeks gestation or birth weight less than 2000 grams.

Retinopathy of prematurity

- ◆ Normal retinal vascularization proceeds from the optic disc to the periphery and is complete in the nasal quadrants at approximately 36 weeks of gestation and on the temporal side at 40 weeks.

Retinopathy of prematurity

Pathogenesis:

- ◆ By the premature children, exposure to oxygen and possibly radical oxygen inhibits further vascularization, leaving a variable amount of anterior neurosensory retina without inner blood supply.
- ◆ Other factors such as low birth weight, intercurrent illness, short gestational period and pCO₂ may contribute to the development of retinopathy.

Retinopathy of prematurity

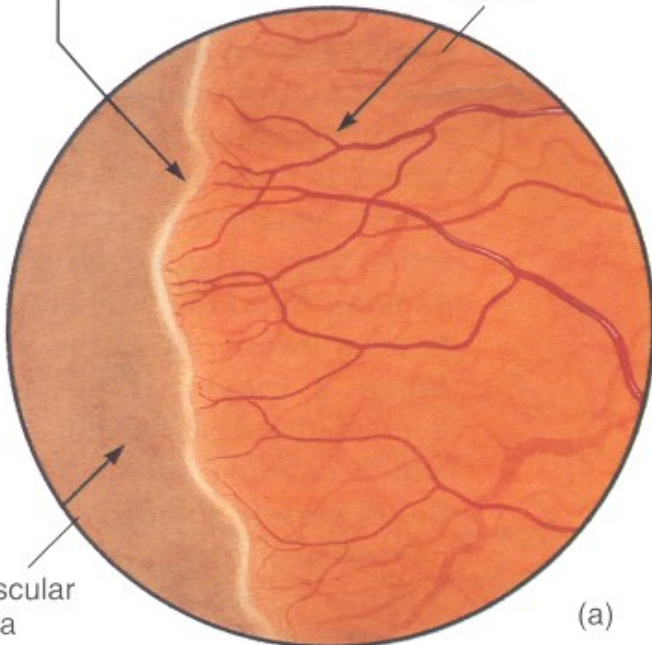
- ◆ Clinically we can see the border between vascularized and nonvascularized retina.
- ◆ Stage 1: presence of a demarcation line between vascularized and nonvascularized retina.
- ◆ Stage 2: at the border zone is a mesenchymal arteriovenous shunt developed.

Retinopathy of prematurity

- ◆ Stage 3: a demarcation ridge with extraretinal fibrovascular proliferation
- ◆ Stage 4: subtotal retinal detachment
- ◆ Stage 5: total retinal detachment

Demarcation line

Vascularized retina

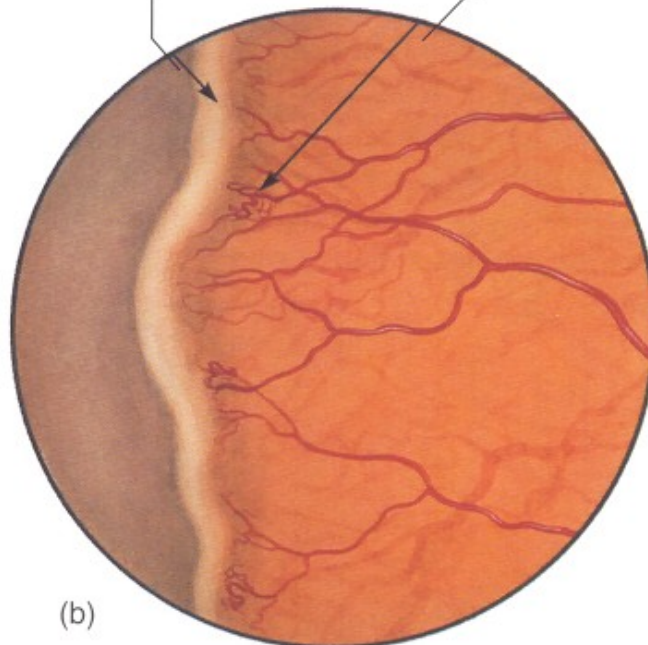


Avascular retina

(a)

Ridge

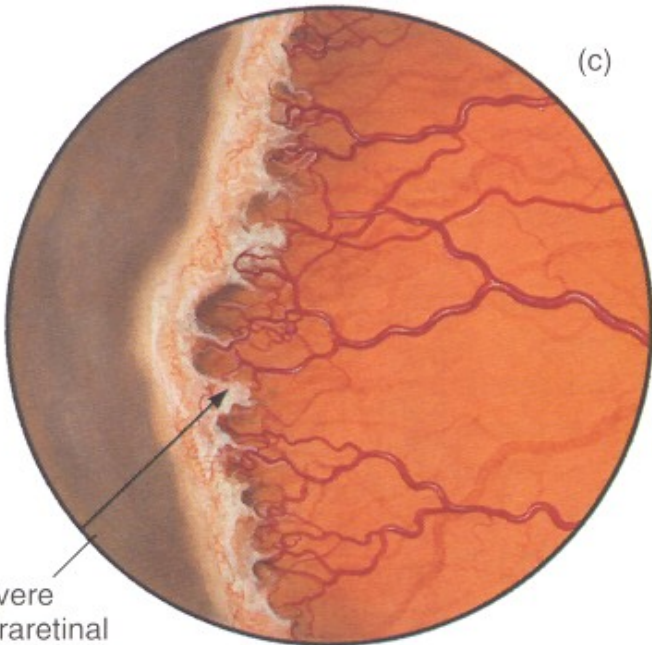
Isolated neovascular tufts



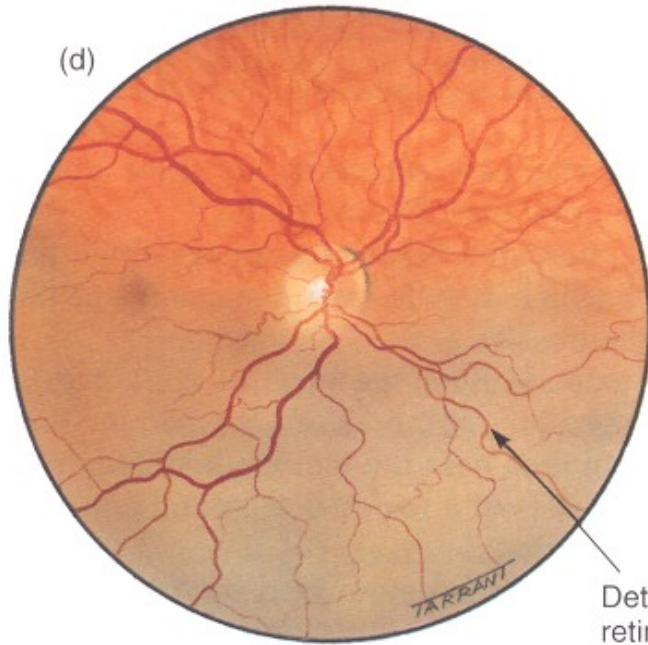
(b)

(c)

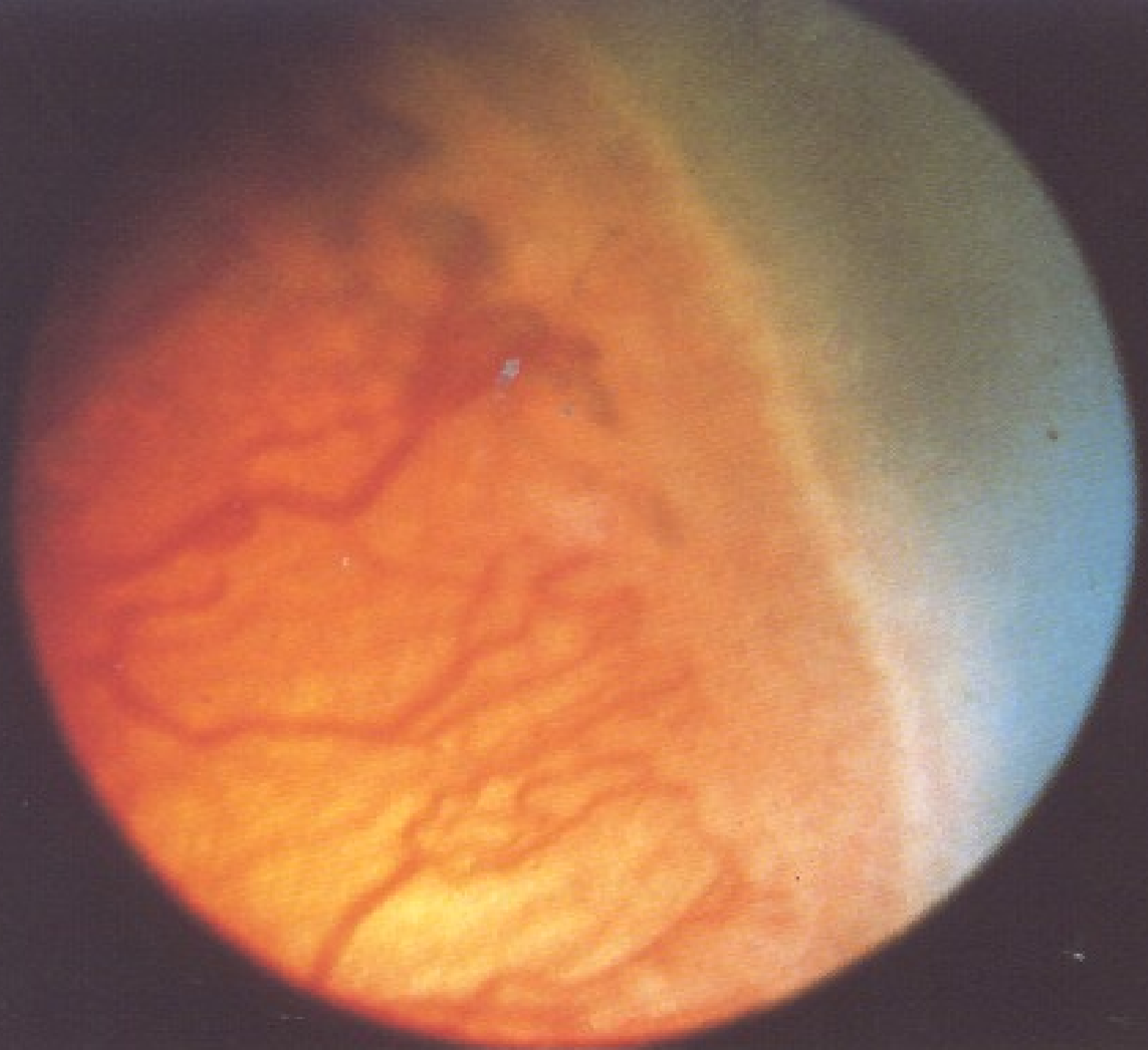(d)

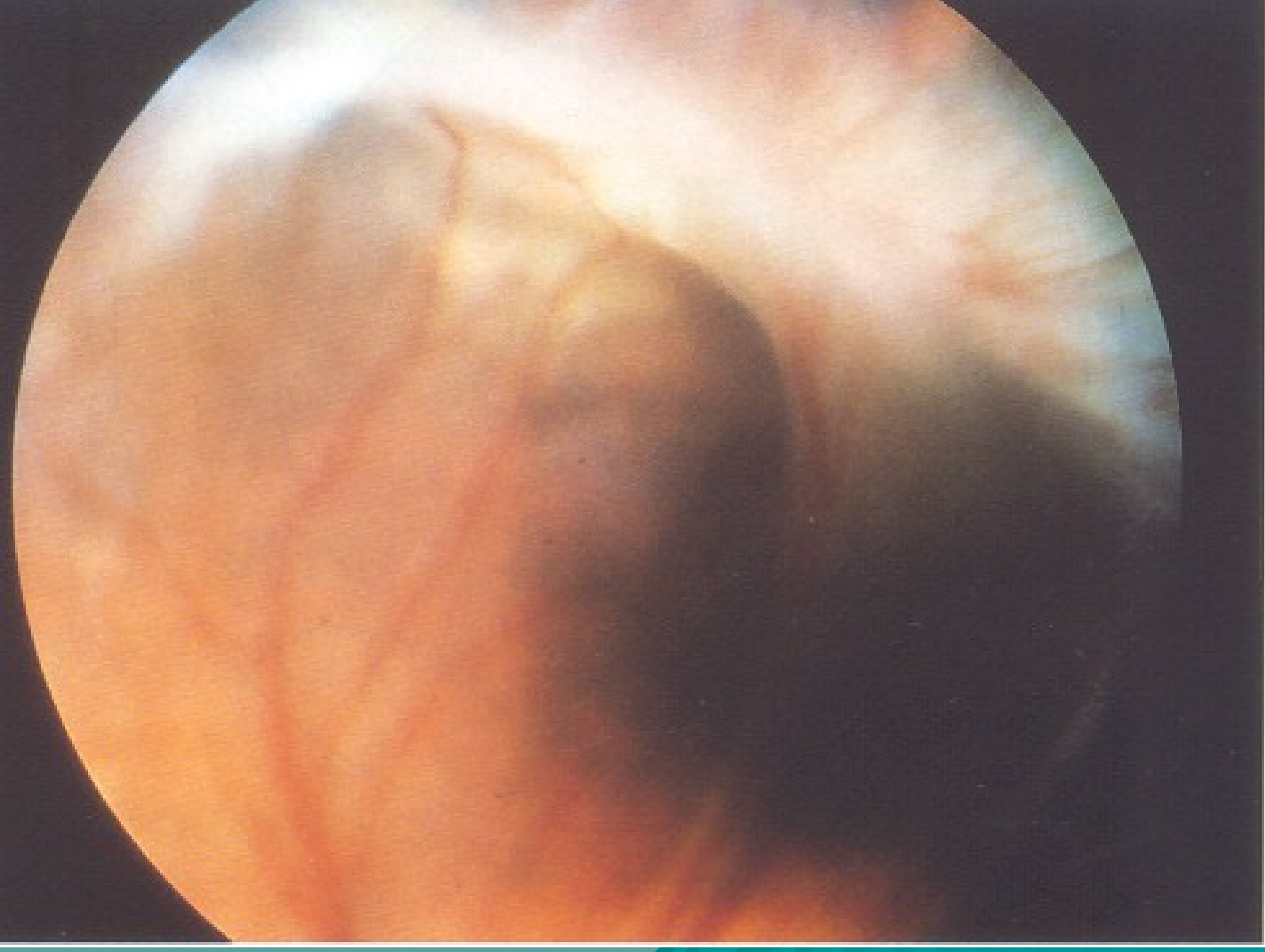


Severe extraretinal fibrovascular proliferation



Detached retina





Retinopathy of prematurity

- ◆ Treatment:
- ◆ Stage 3= cryotherapy
- ◆ Stage 4= scleral buckle
- ◆ Stage 5= pars plana vitrectomy.

Branch retinal vein occlusion

- ◆ The site of occlusion is almost invariably at an **arteriovenous crossing point**.
- ◆ The superotemporal quadrant is most commonly affected (63%), and nasal occlusions are rarely detected clinically.

Branch retinal vein occlusion

Pathogenesis:

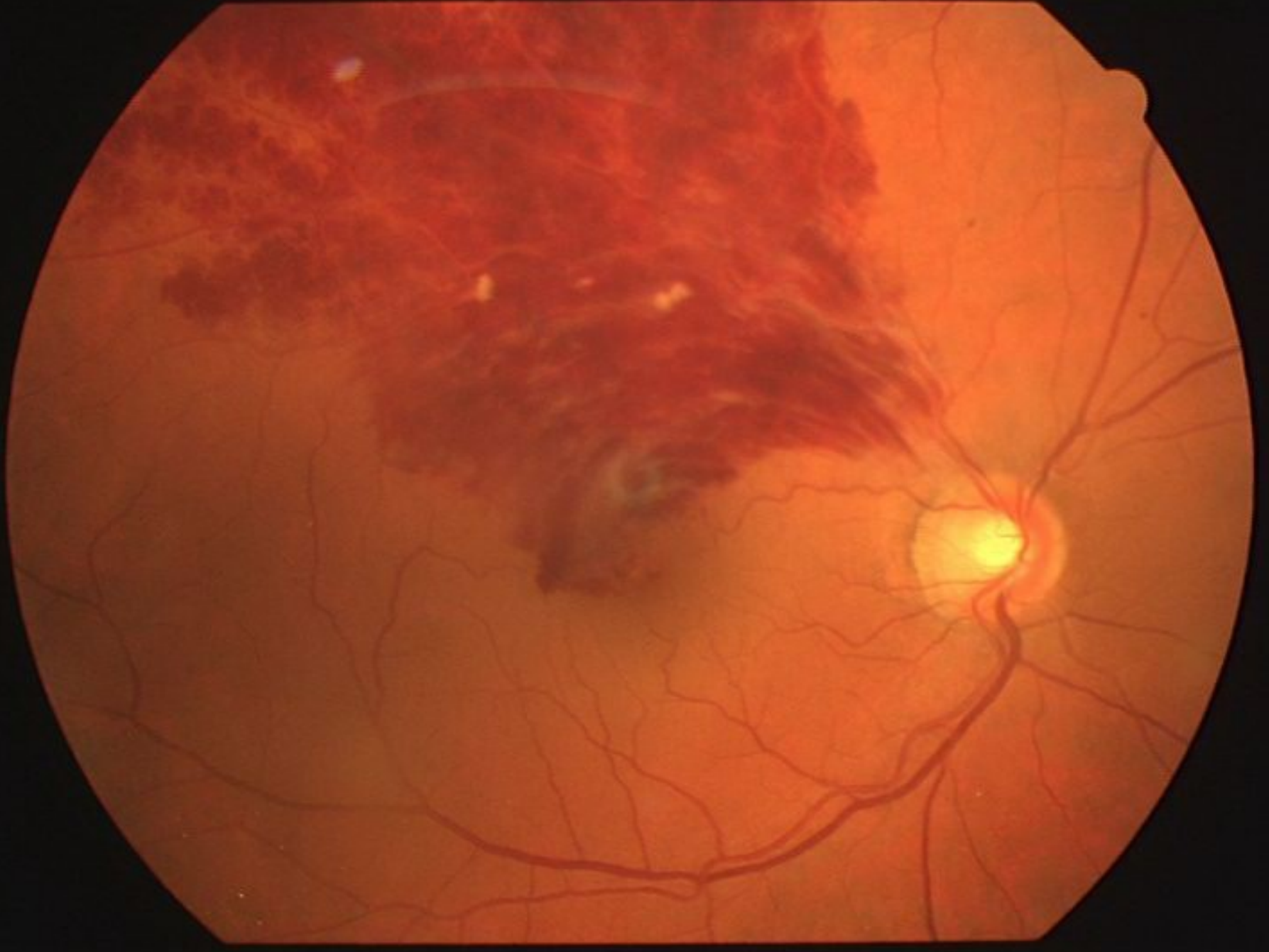
- ◆ Histologic studies suggest that the common adventitia at these points binds the artery and vein together and that thickening of the arterial wall compresses the vein resulting in turbulence of flow, endothelial cell damage, and thrombotic occlusion.

Branch retinal vein occlusion

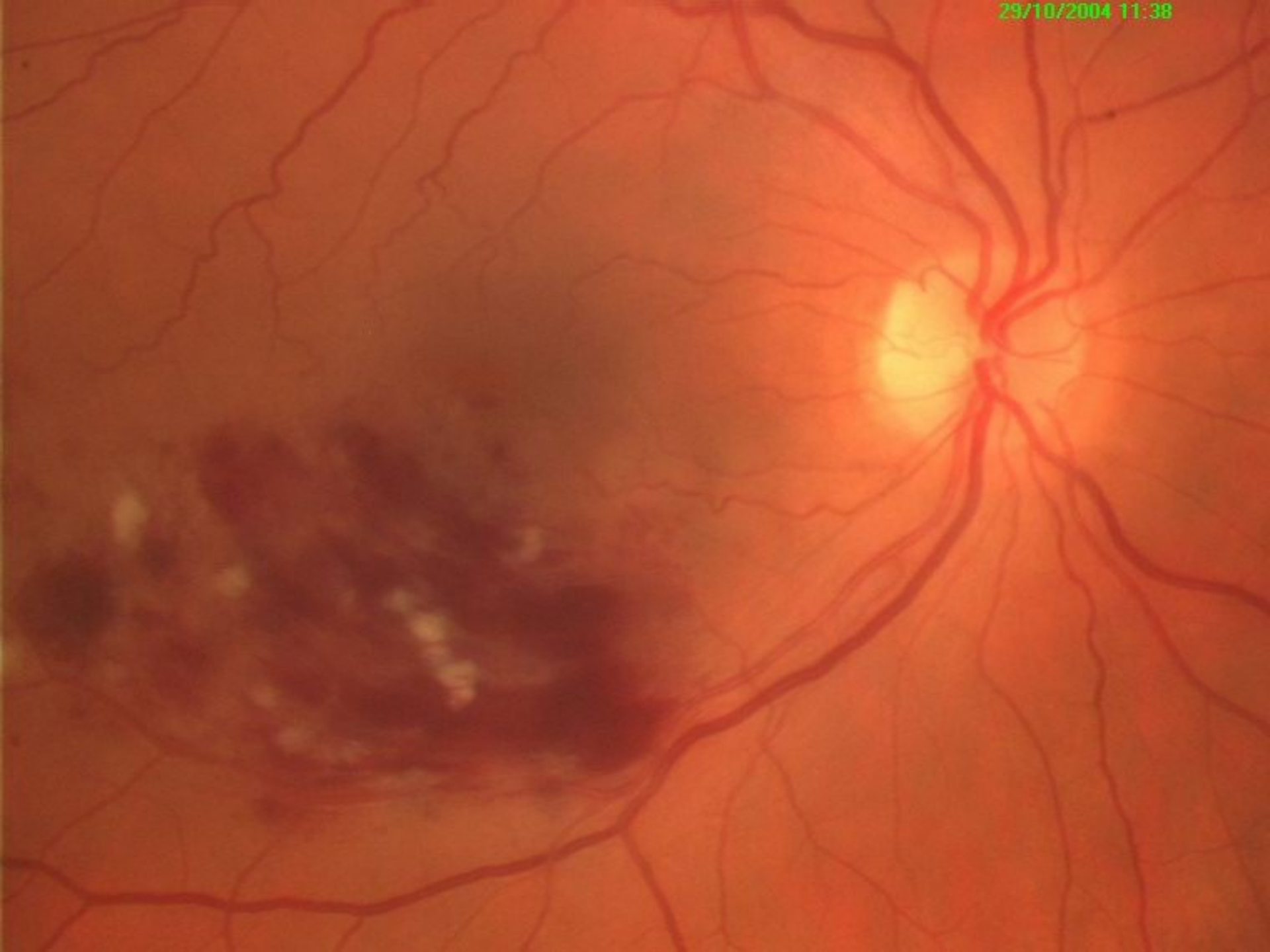
- ◆ Predispose to BRVO:
 - Systemic hypertension
 - Diabetes
 - Arteriosclerosis
 - Hyperopia

Branch retinal vein occlusion

- ◆ **The oftalmoscopic findings** include:
 - superficial hemorrhages
 - retinal edema
 - cotton-wool spots
 - the obstructed vein is dilated and tortuous
 - the corresponding artery may become narrowed
- ◆ The area and location of involved retina depend on the site of the venous obstruction



29/10/2004 11:38



Branch retinal vein occlusion

- ◆ The visual prognosis is related to the extent of capillary damage and retinal ischemia.
- ◆ Sometimes capillary compensation and collateral formation may permit restitution of flow with resolution of the edema and improvement in visual function.

Branch retinal vein occlusion

- ◆ The visual prognosis is related to the extent of capillary damage and retinal ischemia.
- ◆ Extensive retinal ischemia frequently results in cystoid macular edema, pigmentary macular disturbance, macular edema with hard lipid exudates, subretinal fibrosis, epiretinal membrane formation, and neovascularization

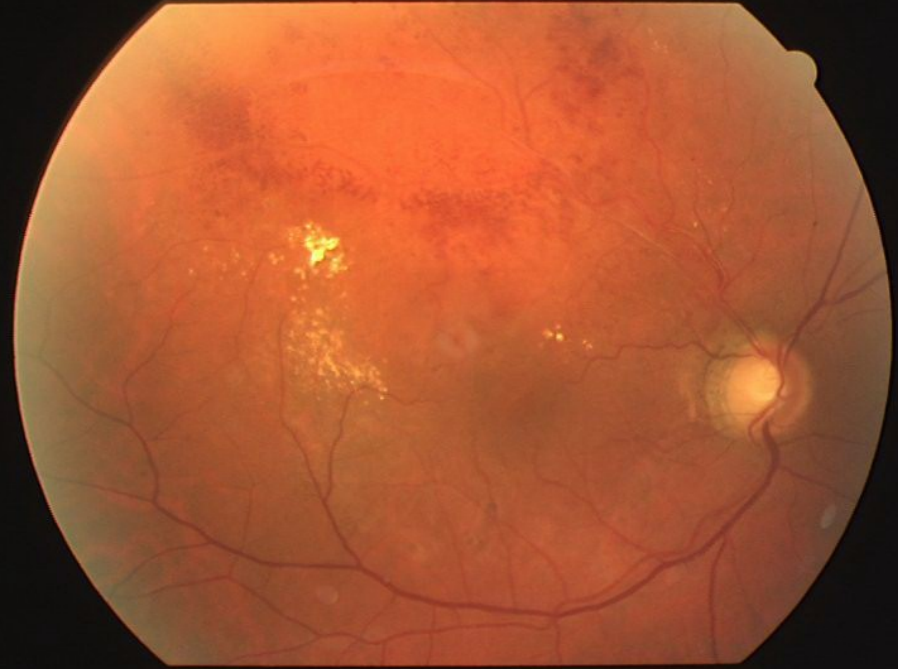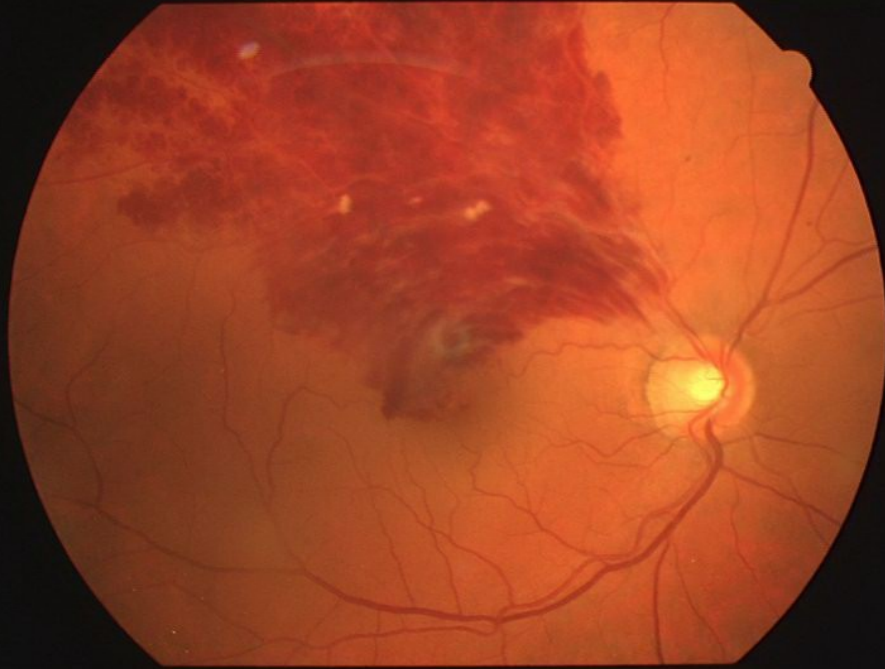
Branch retinal vein occlusion

- ◆ Photocoagulation therapy in BRVO is considered for two major complications:
 - Chronic macular edema
 - Neovascularization

Branch retinal vein occlusion

- ◆ Photocoagulation therapy:
- ◆ For persistent macular edema, photocoagulation lesions are placed in the paramacular retina drained by the obstructed vein. The leaking microvascular abnormalities and areas of capillary nonperfusion are treated directly.

27/04/2004 11:54



Branch retinal vein occlusion

- ◆ Photocoagulation therapy:
- ◆ For eyes with neovascularization, panretinal photocoagulation is effective in causing regression of the new vessels.

Branch retinal vein occlusion

Drugs:

- ◆ Medications that reduce platelet adhesiveness (Aspirin)
- ◆ Peripheral vasodilators (Agapurin)
- ◆ Vasoprotectives, capillary stabilizing agents (Ascorutin)

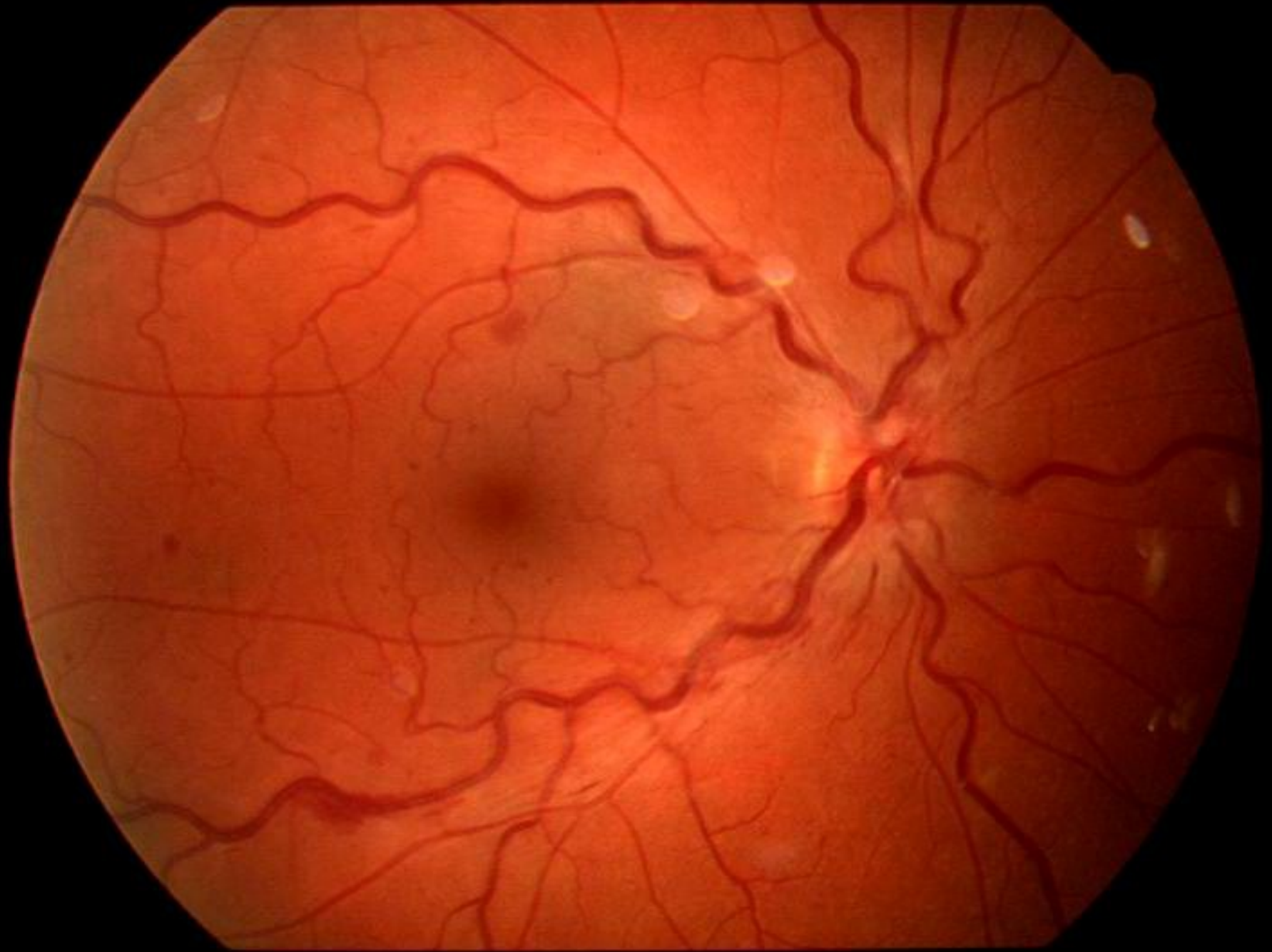
Central retinal vein occlusion

- ◆ Histologic studies suggest that all forms of CRVO have a common mechanism, which is thrombosis of the central retinal vein at the level of the lamina cribrosa.
- ◆ Two forms of the disease are recognized:
 - ◆ A milder form called non-ischemic
 - ◆ A severe form called ischemic

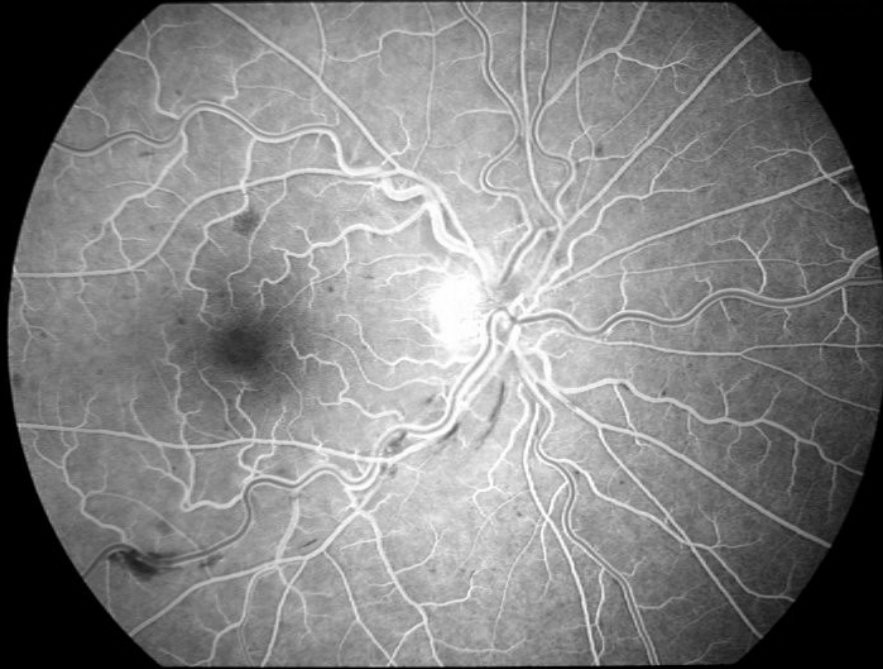
Central retinal vein occlusion

◆ Non-ischemic CRVO

- Mild optic disc swelling
- Mild dilatation and tortuosity of all branches of the central retinal vein
- Dot and flame hemorrhages in all quadrants of the retina
- Macular edema may or may not be present
- Capillary leakage, minimal areas of nonperfusion

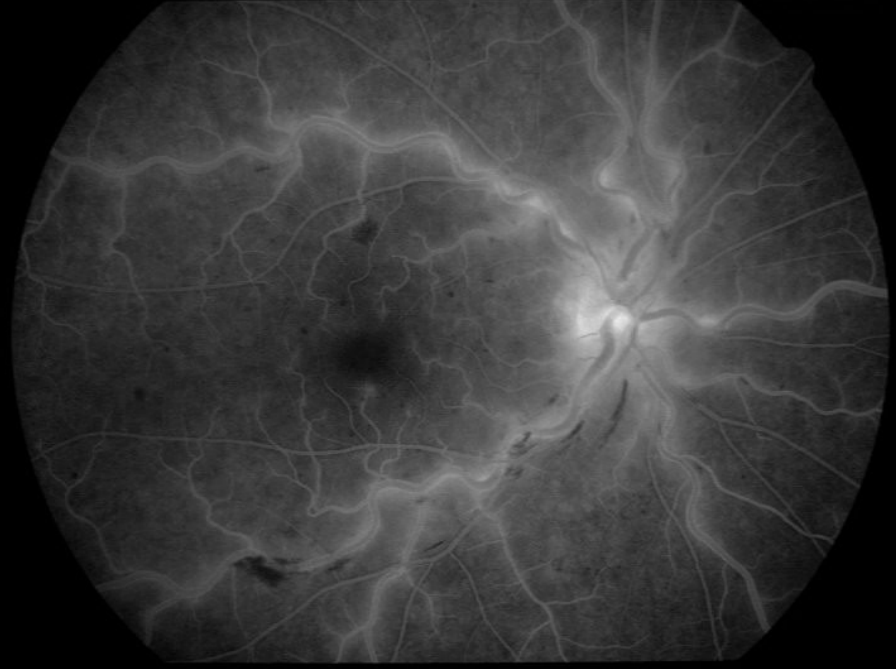


11/09/2002 10:28



Timer 1 - 00:00:15

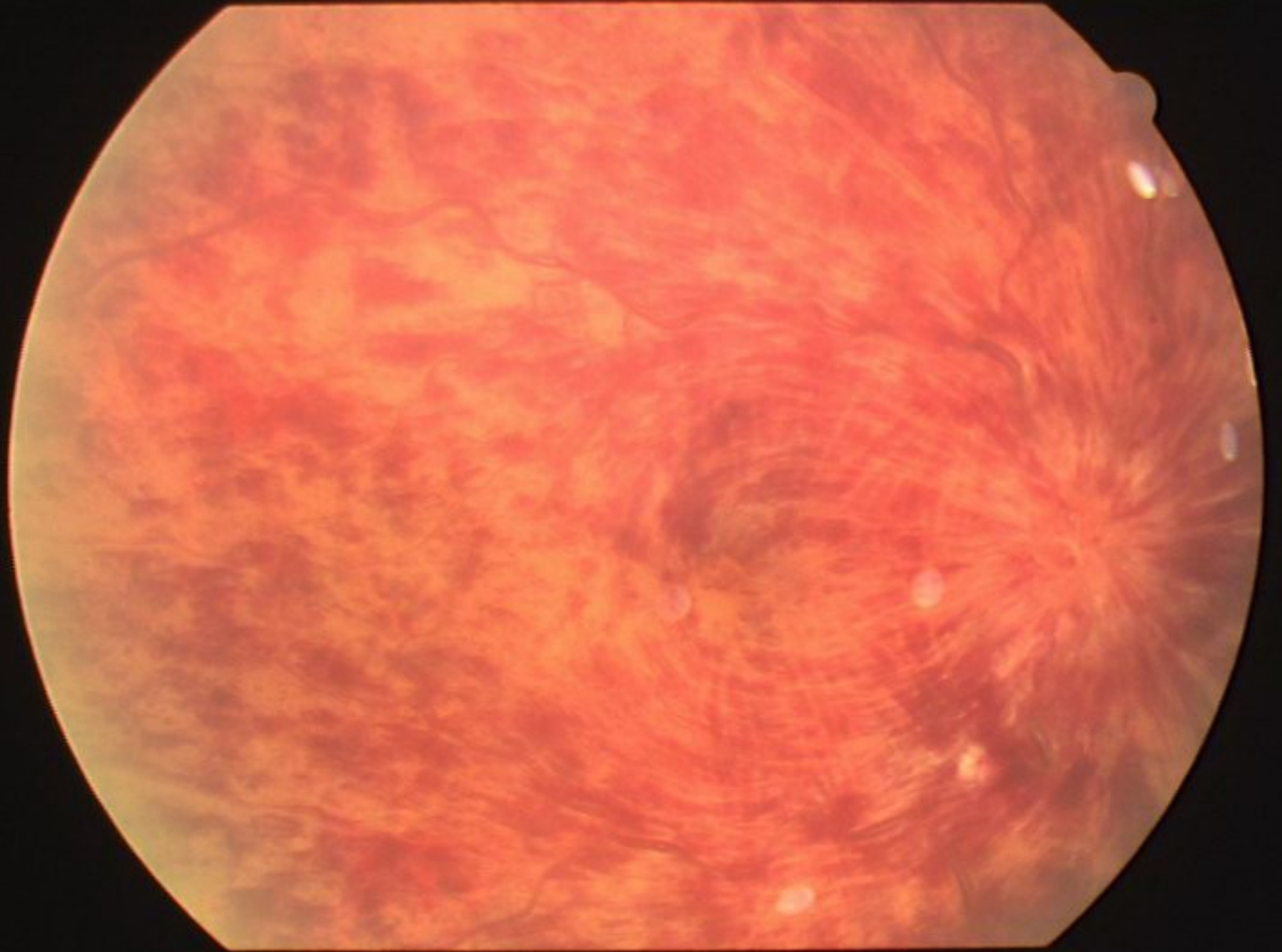
11/09/2002 10:32



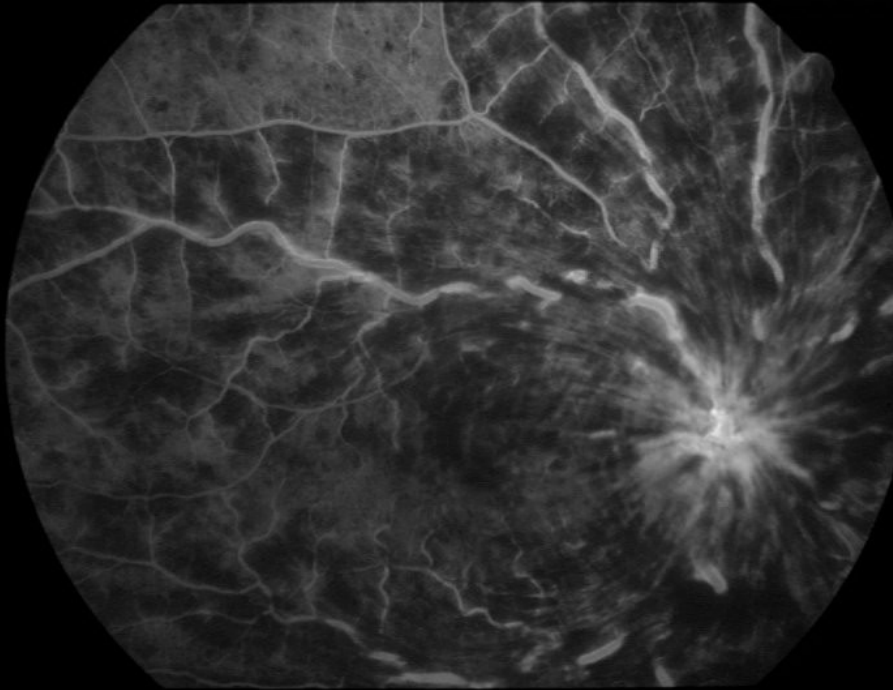
Timer 1 - 00:04:23

Central retinal vein occlusion

- ◆ Ischemic CRVO
 - Extensive four quadrant retinal edema and hemorrhage
 - Marked venous dilatation
 - Cotton-wool spots
 - Fluorescein angiography demonstrates widespread capillary nonperfusion
 - Later we observe neovascularization

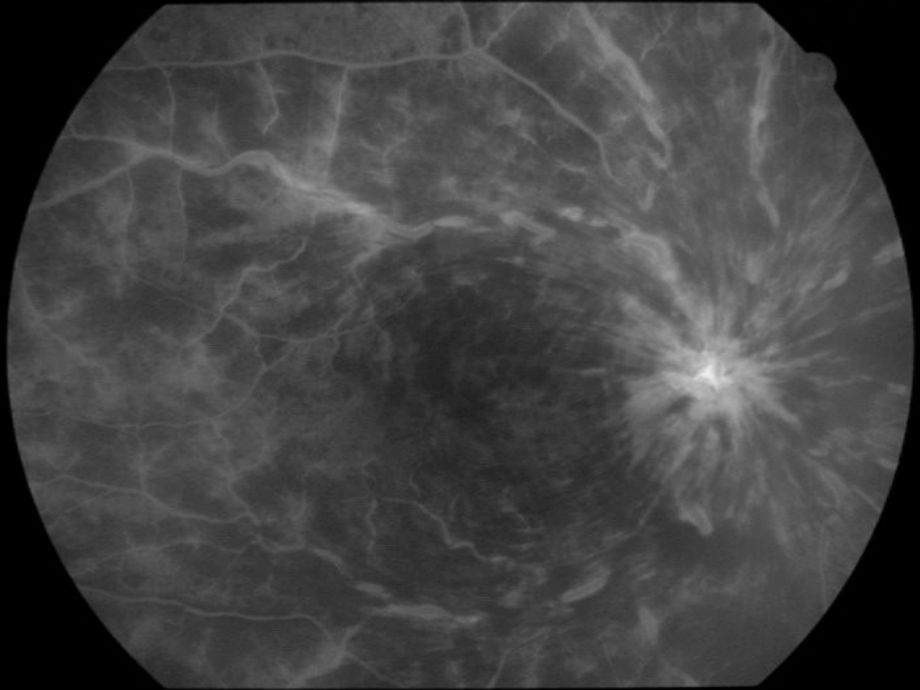

05/08/2003 10:06



Timer 1 - 00:01:07

05/08/2003 10:10



Timer 1 - 00:05:22



Central retinal vein occlusion

Therapy:

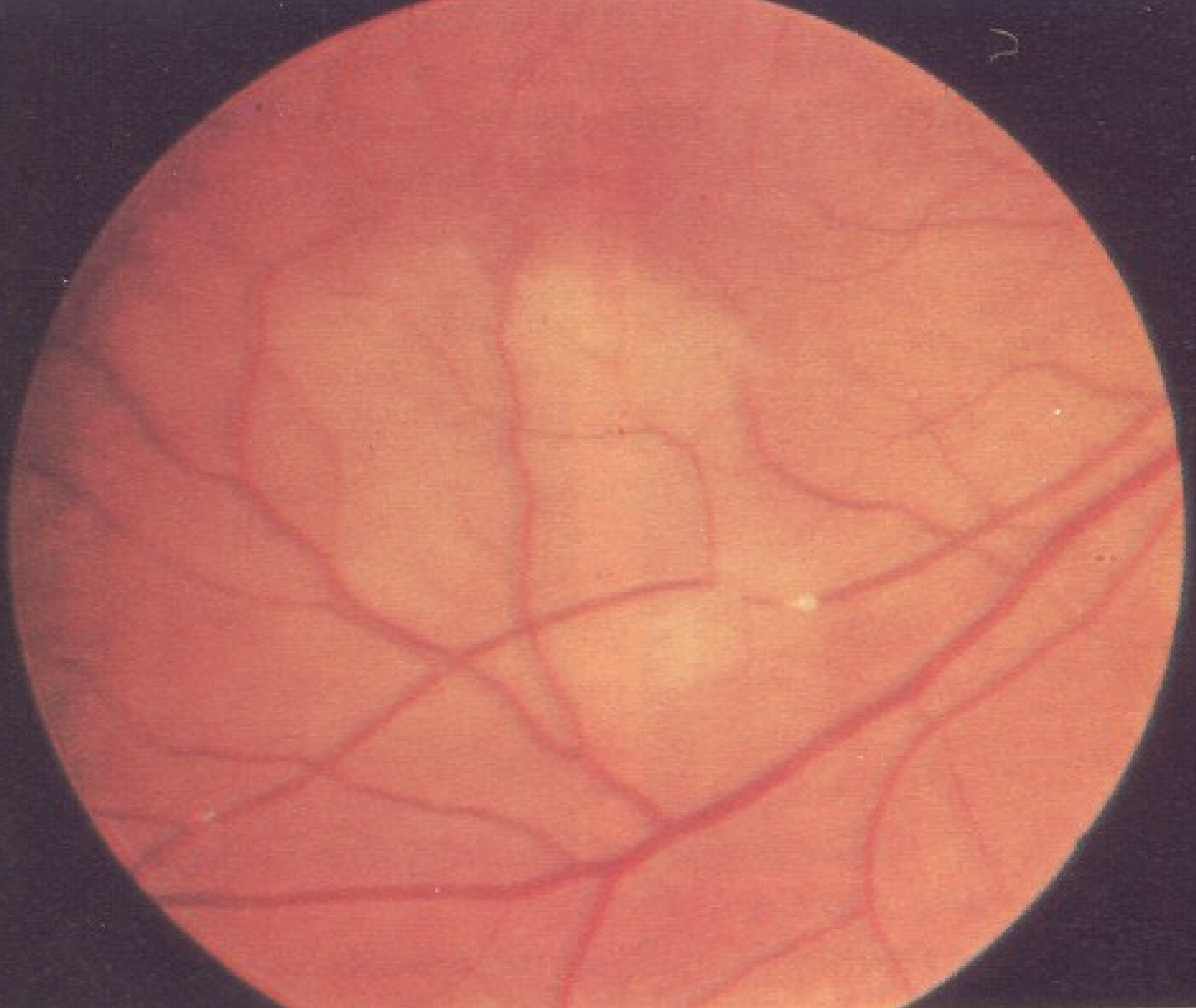
- We use anti-thrombotic agents (Warfarin)
- Panretinal photocoagulation is effective therapy for neovascularization

Branch retinal artery occlusion

- ◆ Occlusion is due to embolization or thrombosis of the affected vessel.
- ◆ Three types of emboli are recognized:
 - Cholesterol emboli arising in the carotid arteries
 - Platelet-fibrin emboli associated with large vessel arteriosclerosis
 - Calcific emboli arising from diseased cardiac valves

Branch retinal artery occlusion

- ◆ Acute BRAO causes an edematous, white retina in the distribution of the affected vessel.



Branch retinal artery occlusion

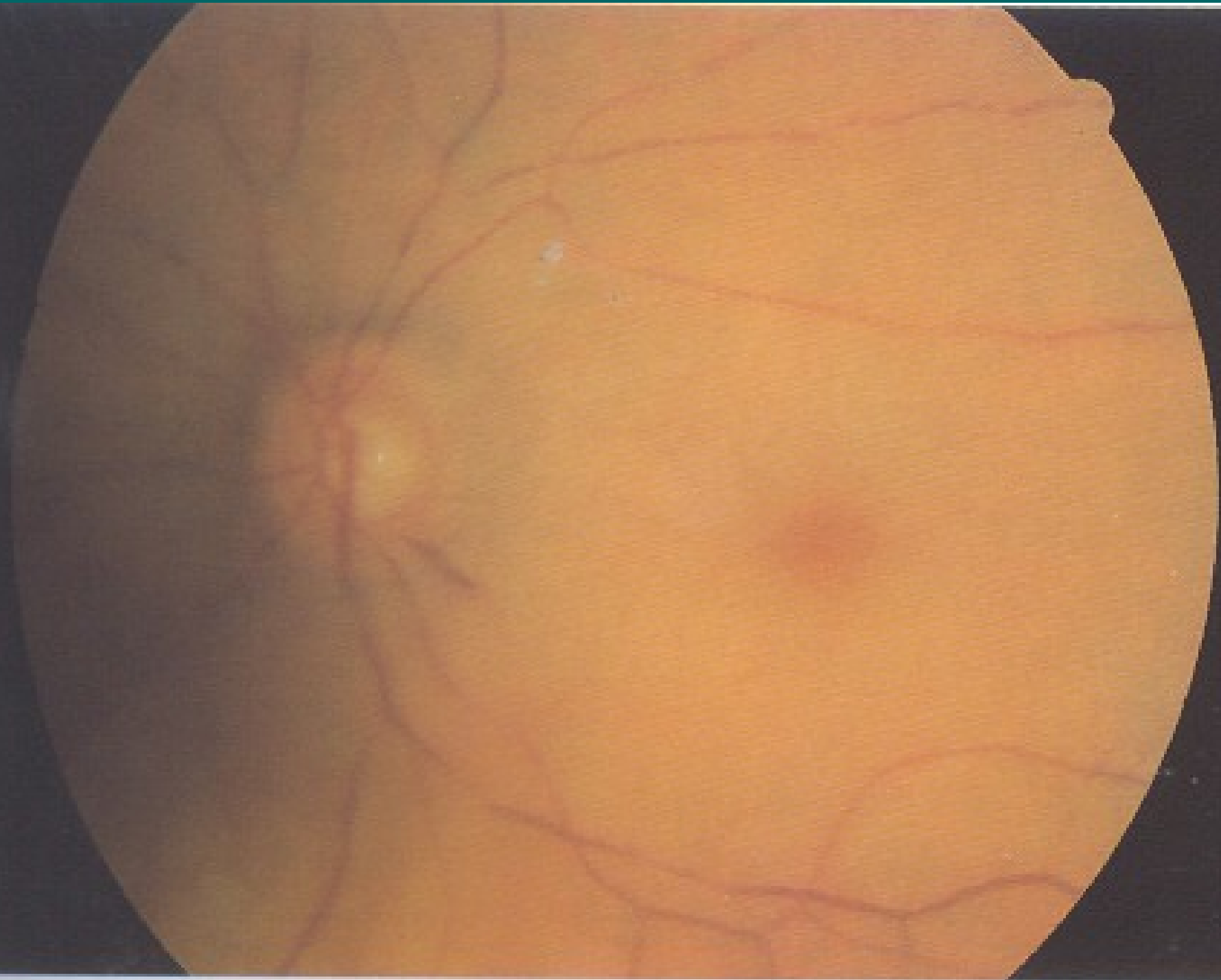
- ◆ Therapy:
Pressure on the globe may dislodge the embolus from a central large vessel and result in obstruction of a smaller more peripheral vessel.

Central retinal artery occlusion

- ◆ CRAO is usually due to arteriosclerosis-related thrombosis, occurring at the level of the lamina cribrosa
- ◆ Embolization may be important in some cases.

Central retinal artery occlusion

- ◆ Sudden, severe, and painless loss of vision.
- ◆ The retina becomes opaque and edematous.
- ◆ This permits an orange reflex, from the intact choroidal vasculature beneath the intact foveola, to stand out in contrast to the surrounding opaque retina, producing the „cherry red spot“.

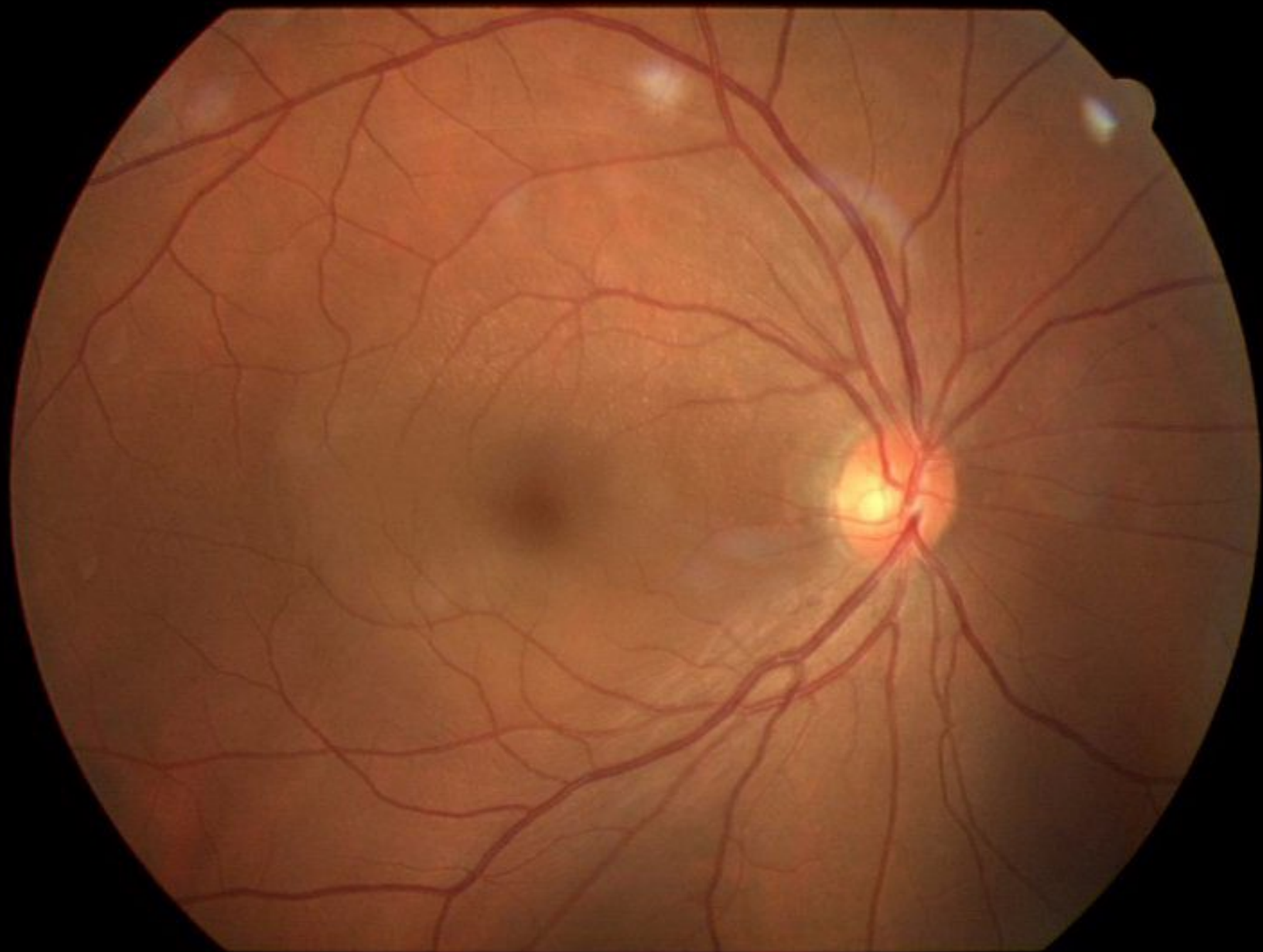


Central retinal artery occlusion

- ◆ The reduction in intraocular pressure by paracentesis, ocular massage and drugs.

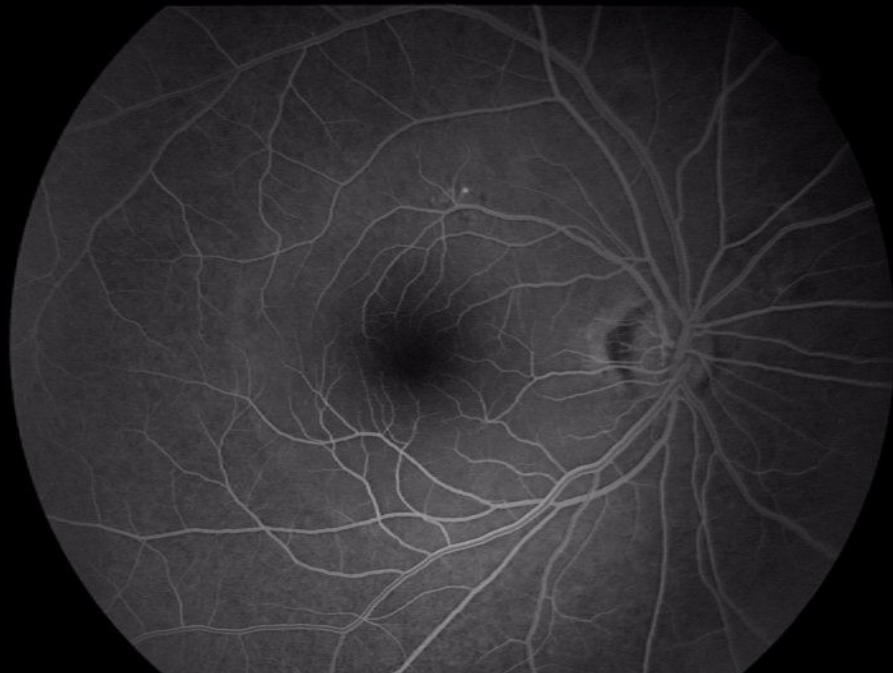
Central serous retinopathy

- ◆ Is characterized by the development of a serous detachment of the sensory retina.
 - Sudden onset of blurred and dim vision
 - Micropsia
 - Metamorphopsia
 - Decreased color vision

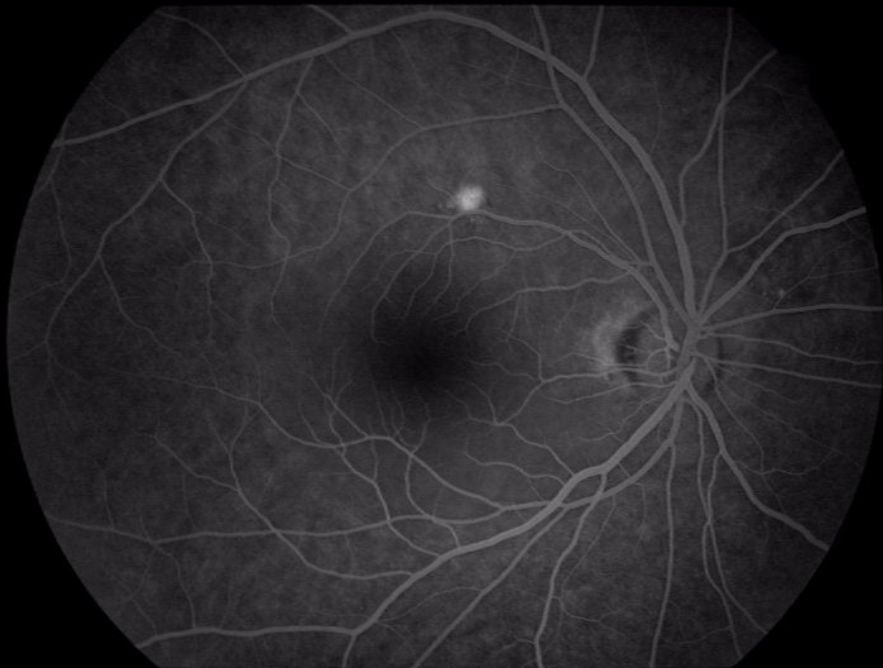


Central serous retinopathy

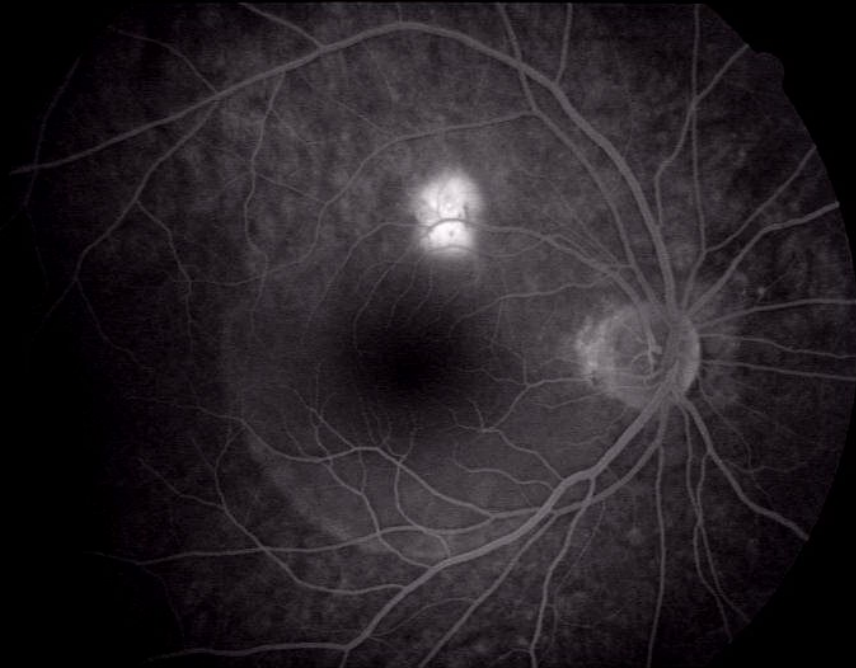
- ◆ The most common fluorescein angiographic presentation is a small focal hyperfluorescent leak from the RPE that appears early in the angiogram and increases in size and intensity with time.



Timer 1 - 00:00:13



Timer 1 - 00:00:50

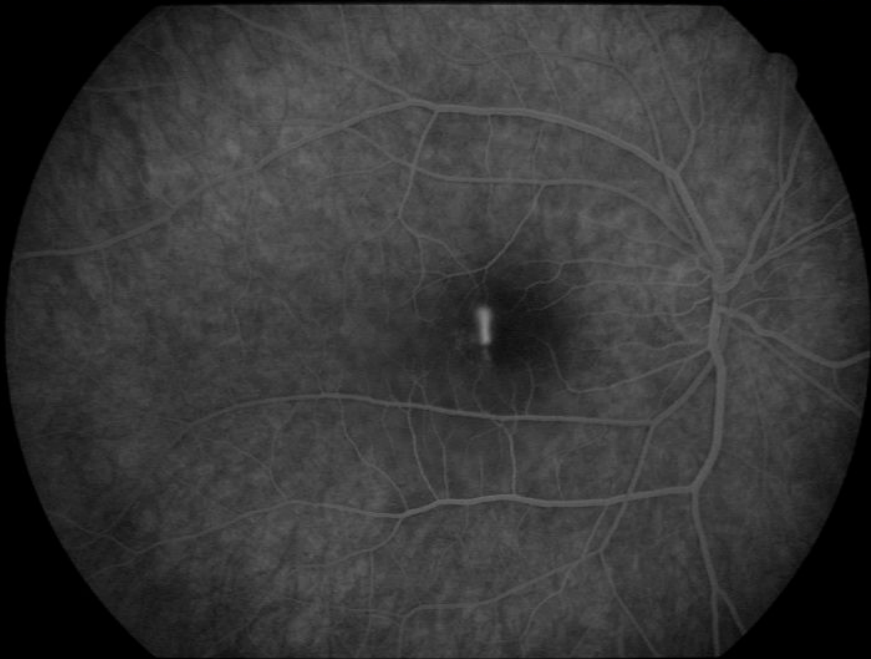

Timer 1 - 00:10:48

Central serous retinopathy

- ◆ Occasionally, rapid leakage of fluorescein produces a pattern of subretinal pooling of dye referred to as a „smokestack“.

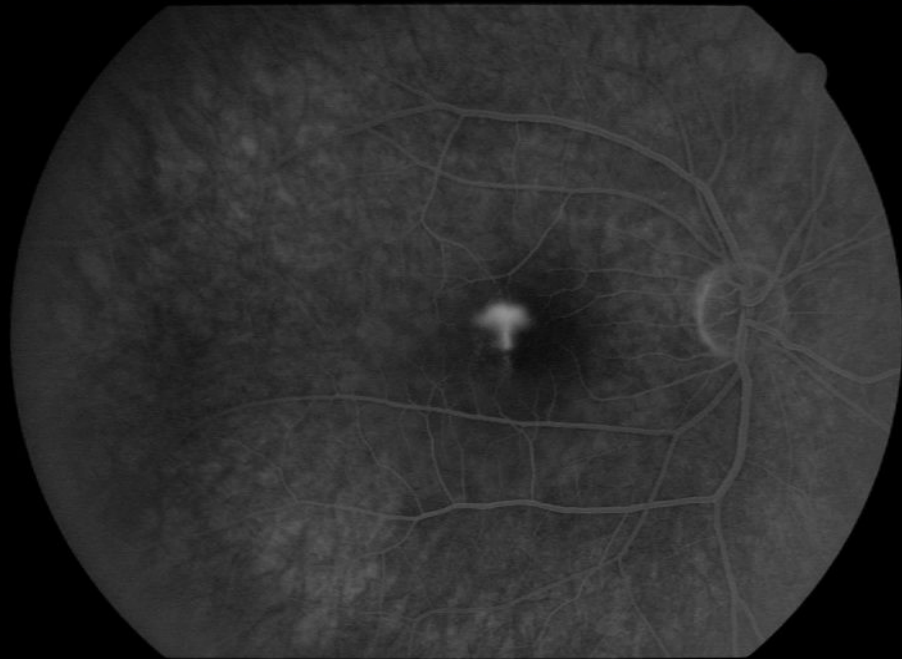
24/08/2001 12:42



Timer 1 - 00:01:23

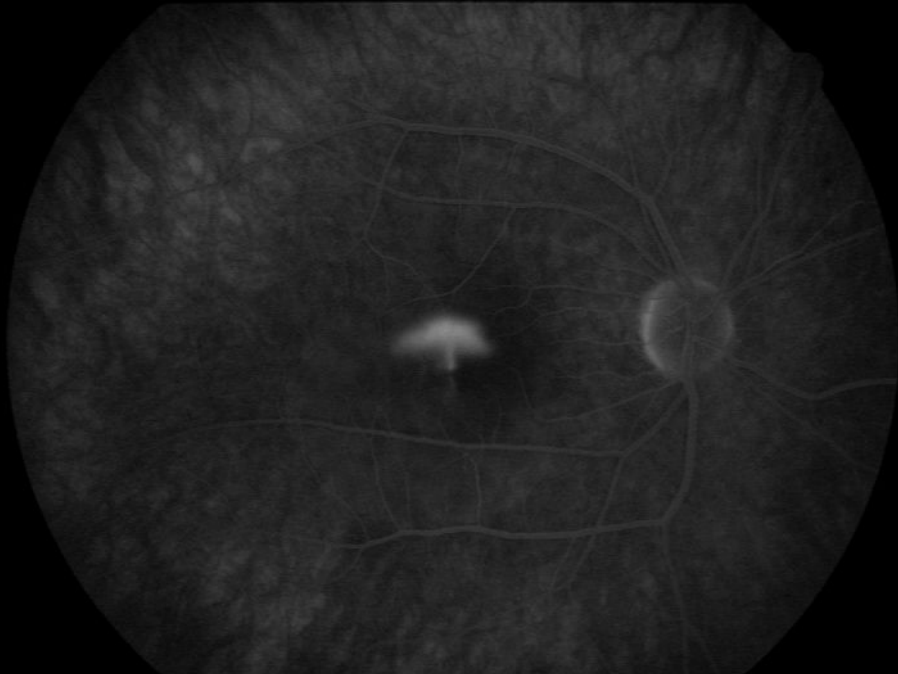24/08/2001 12:47

24/08/2001 12:44

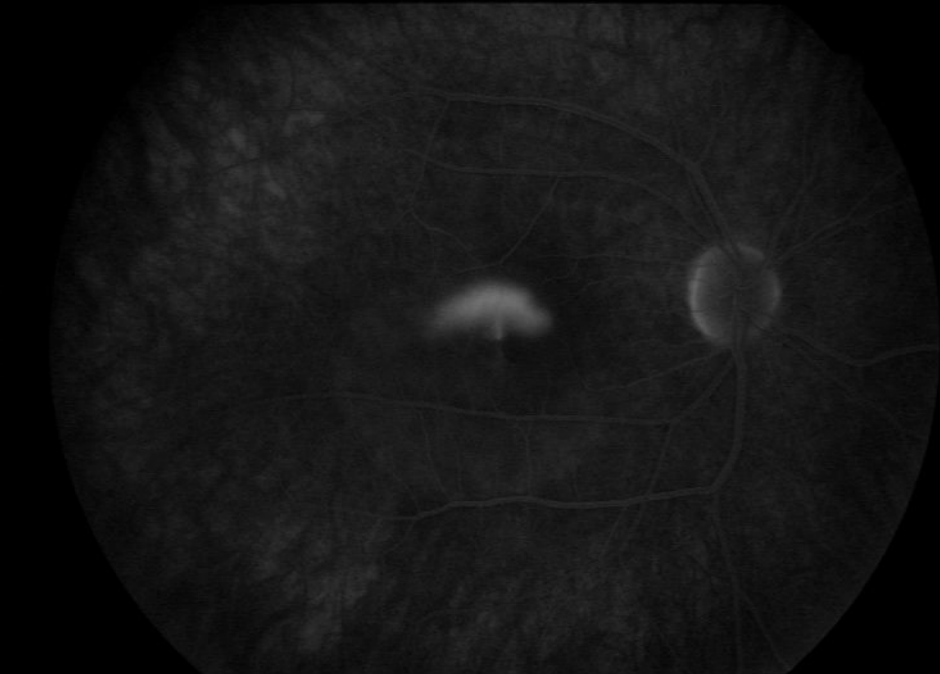


Timer 1 - 00:03:03

24/08/2001 12:51



Timer 1 - 00:06:29



Timer 1 - 00:10:01

Central serous retinopathy

- ◆ Most eyes with central serous choroidopathy undergo spontaneous resorption of subretinal fluid within one to six months of the onset of symptoms.

Central serous retinopathy

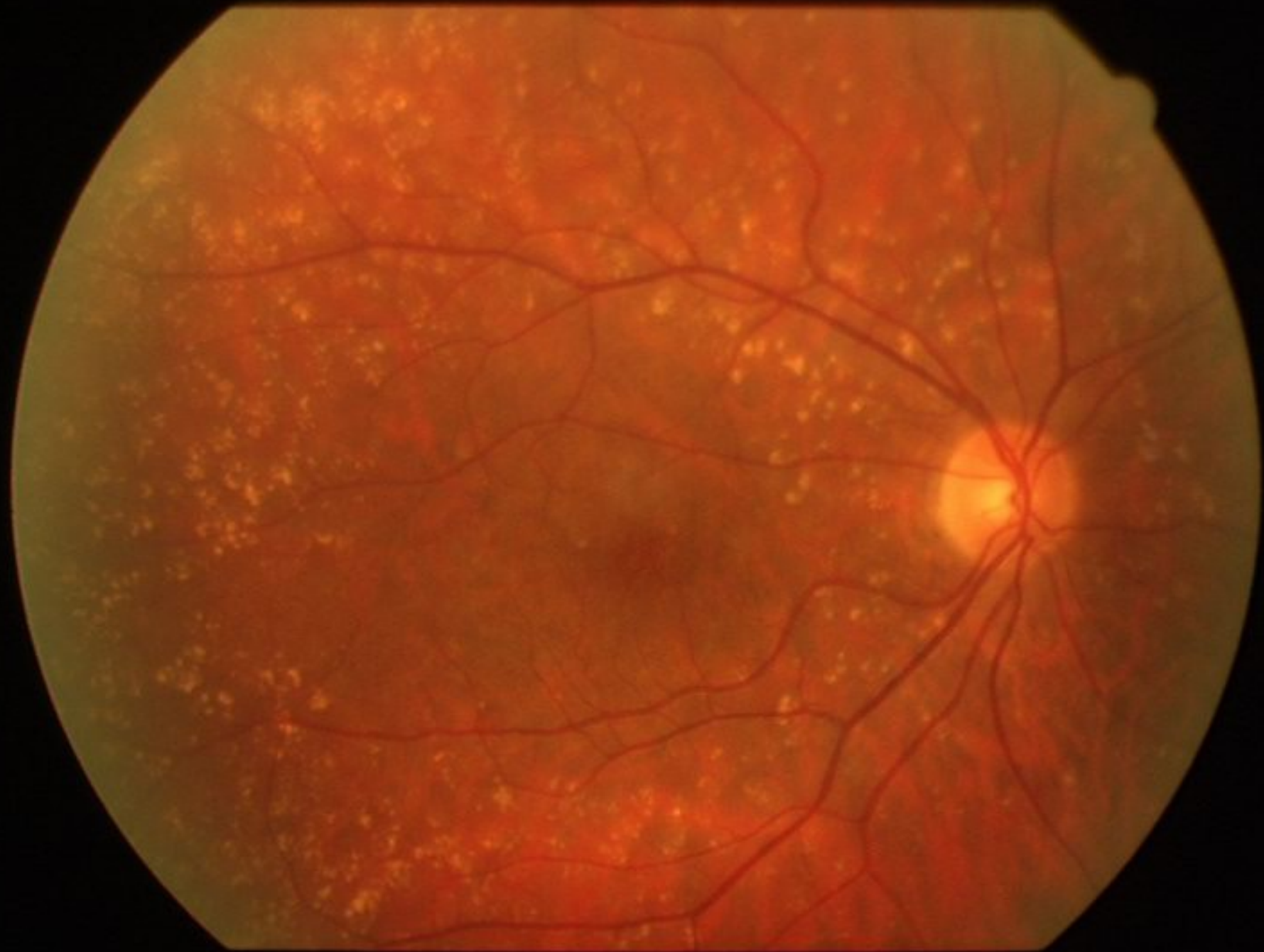- ◆ Consider laser photocoagulation in the following instances:
 - Persistence of serous detachment beyond four months.
 - Recurrences in eyes with visual deficit from previous episodes.
 - Permanent visual deficit from previous episodes in opposite eye.
 - Occupational or other patient needs requiring prompt restoration of vision.

Age-related macular degeneration

- ◆ ARMD is the leading cause of new blindness in the Europe and USA.
- ◆ Dry form of ARMD
- ◆ Wet form of ARMD

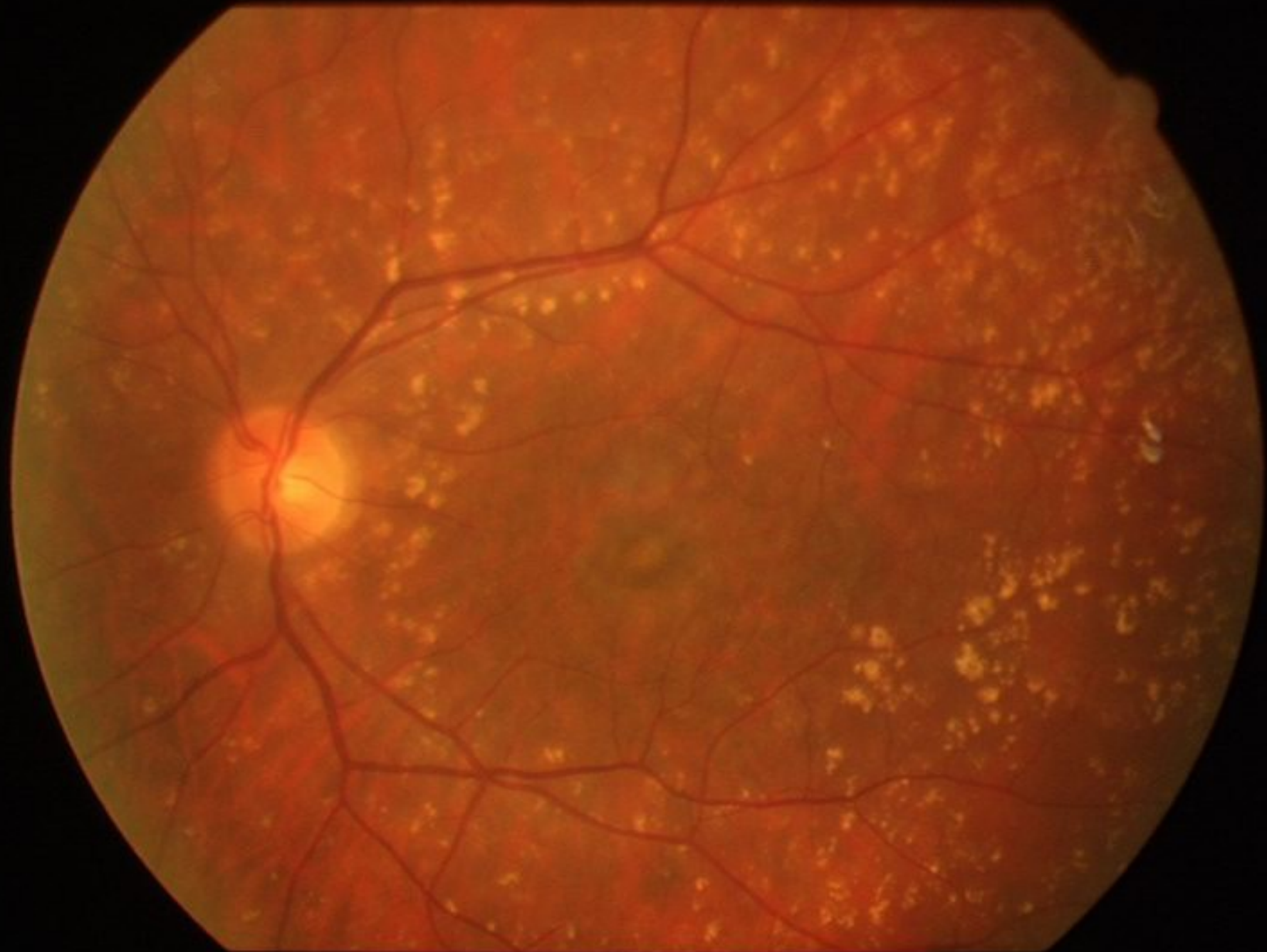Age-related macular degeneration

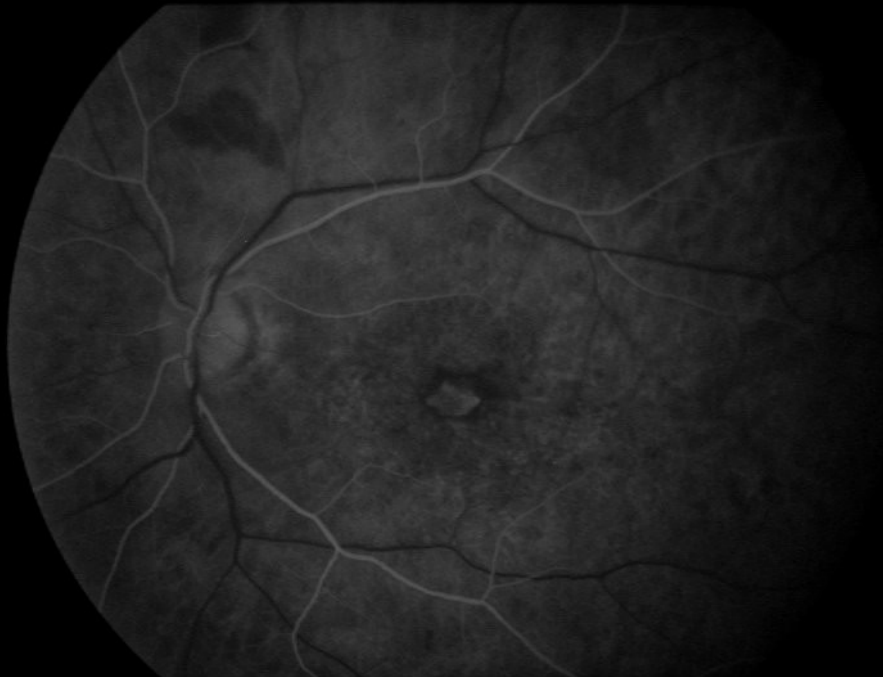- ◆ Dry form of ARMD:
- ◆ Changes in the macula, affecting the outer retinal layer:
 - Retinal pigment epithelium (loss of pigment granules)
 - Bruch's membrane (drusen)
 - Choriocapillaris (atrophy of capillaries)



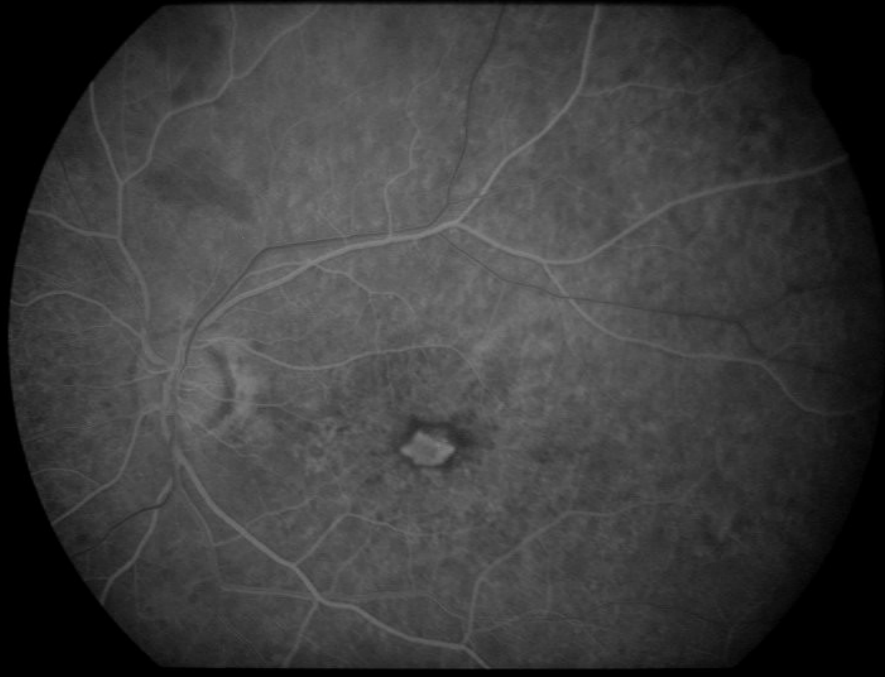Age-related macular degeneration

- ◆ Wet form of ARMD

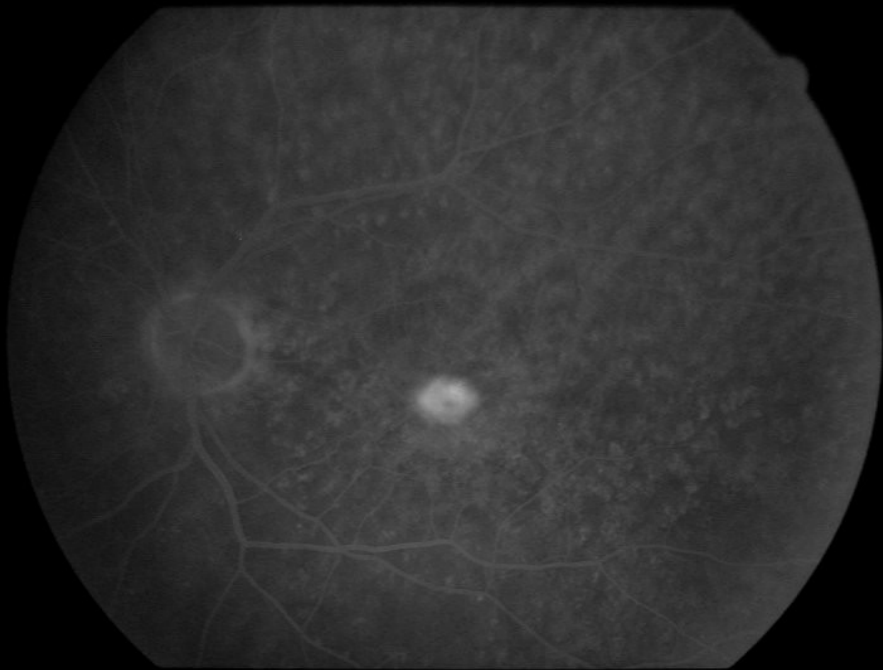




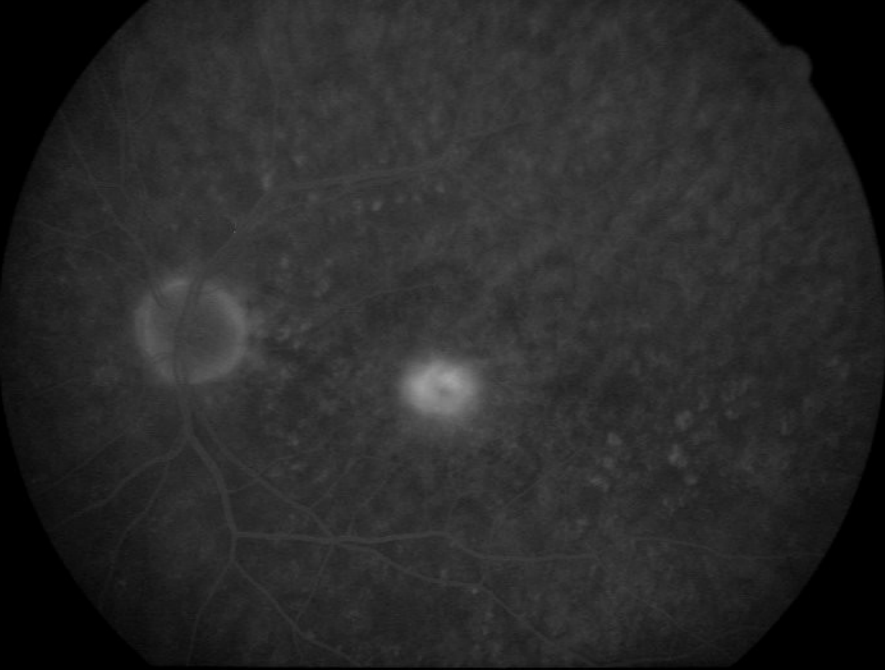
Timer 1 - 00:00:10



Timer 1 - 00:00:13



Timer 1 - 00:01:39

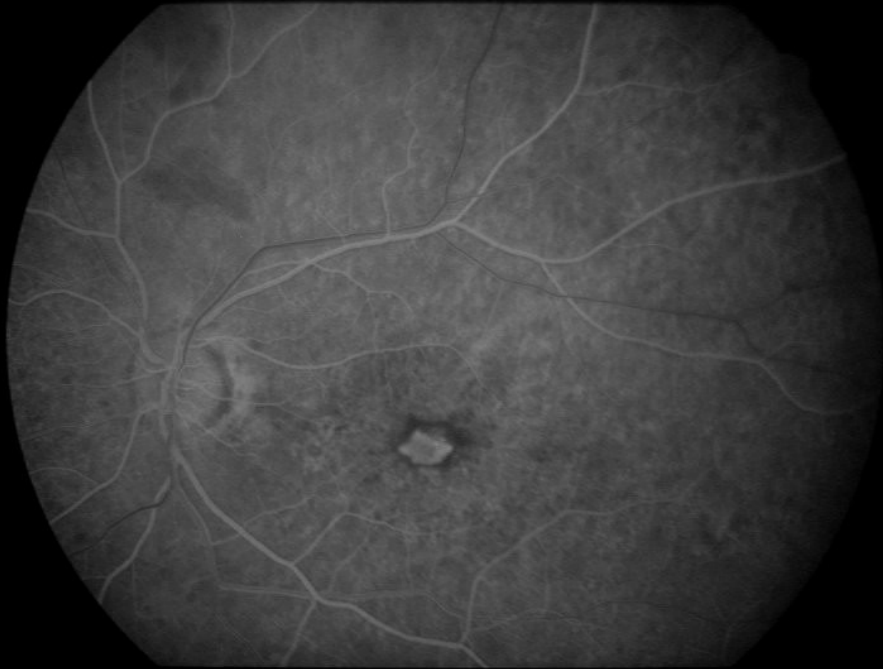

Timer 1 - 00:05:35

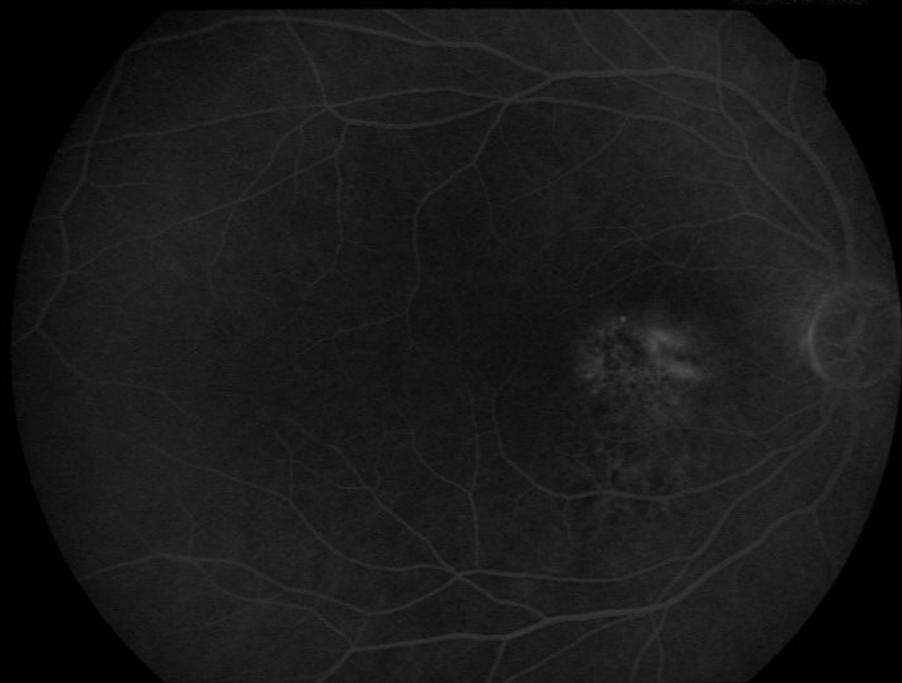Age-related macular degeneration

◆ Choroidal neovascularization (CNV)

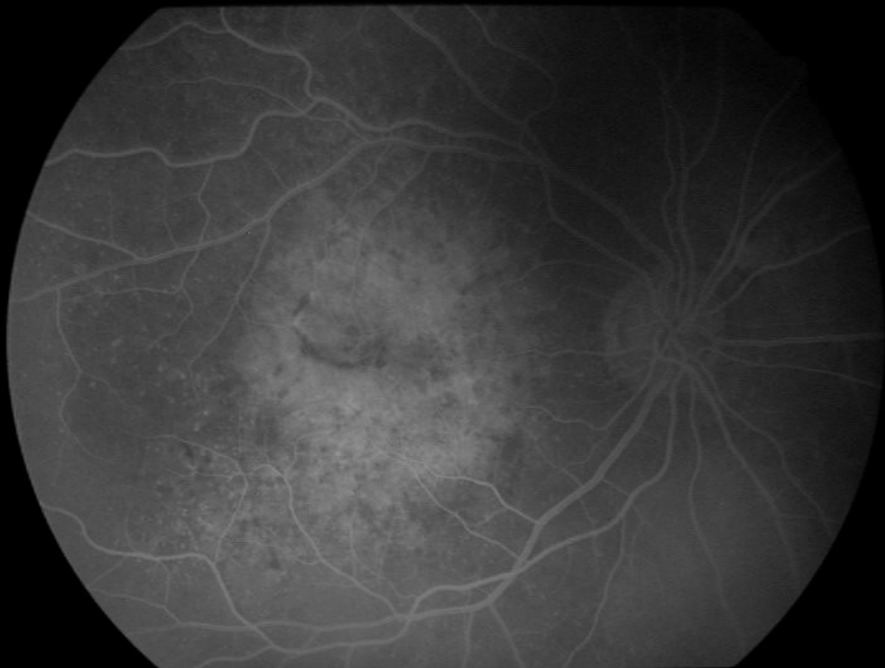- Extrafoveal
- Juxtafoveal
- Subfoveal



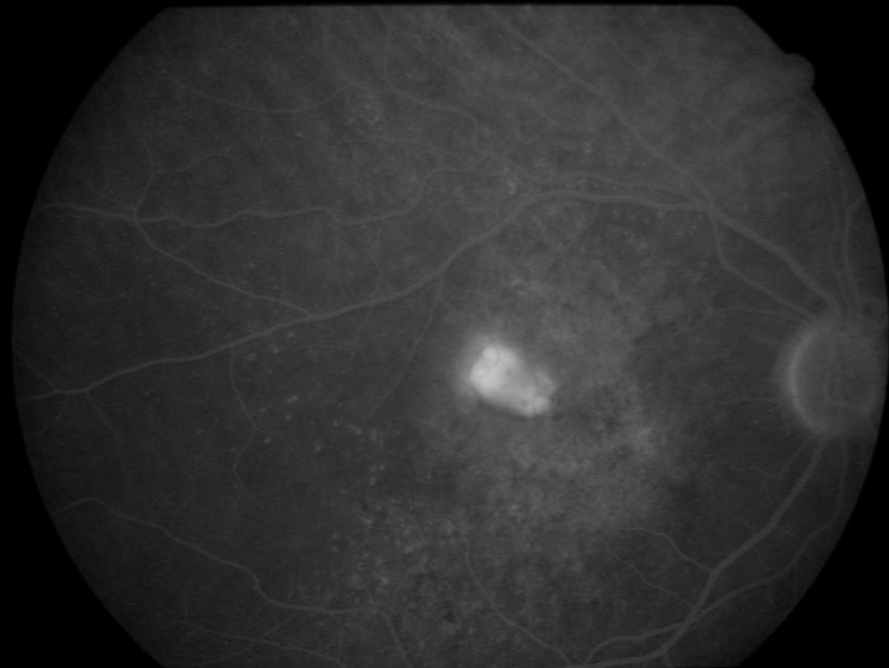
Timer 1 - 00:00:13



Timer 1 - 00:03:07



Timer 1 - 00:00:12

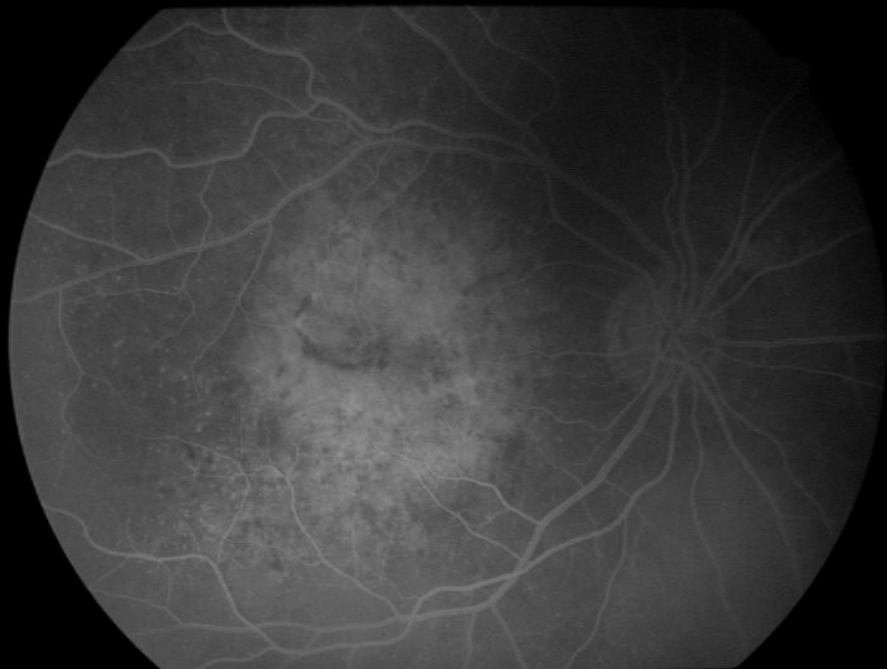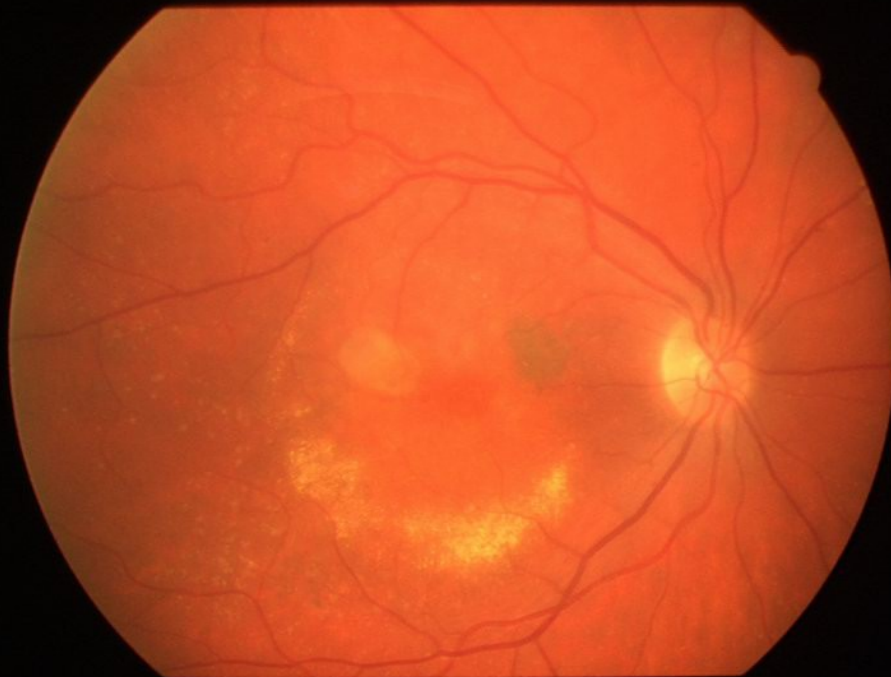


Timer 1 - 00:05:46

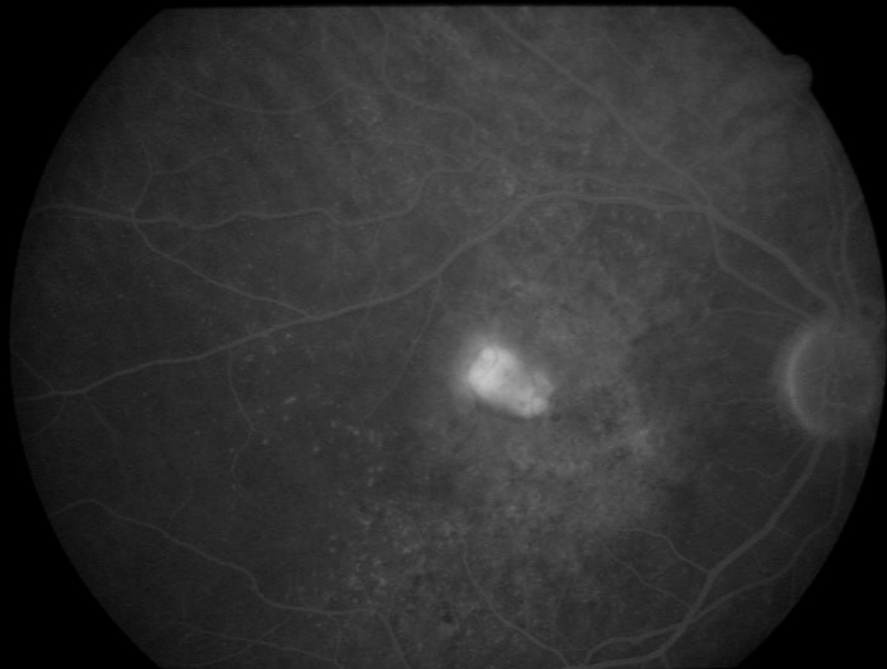
Age-related macular degeneration

- ◆ Therapy:
- ◆ There is no known effective medical treatment for the dry form of ARMD.

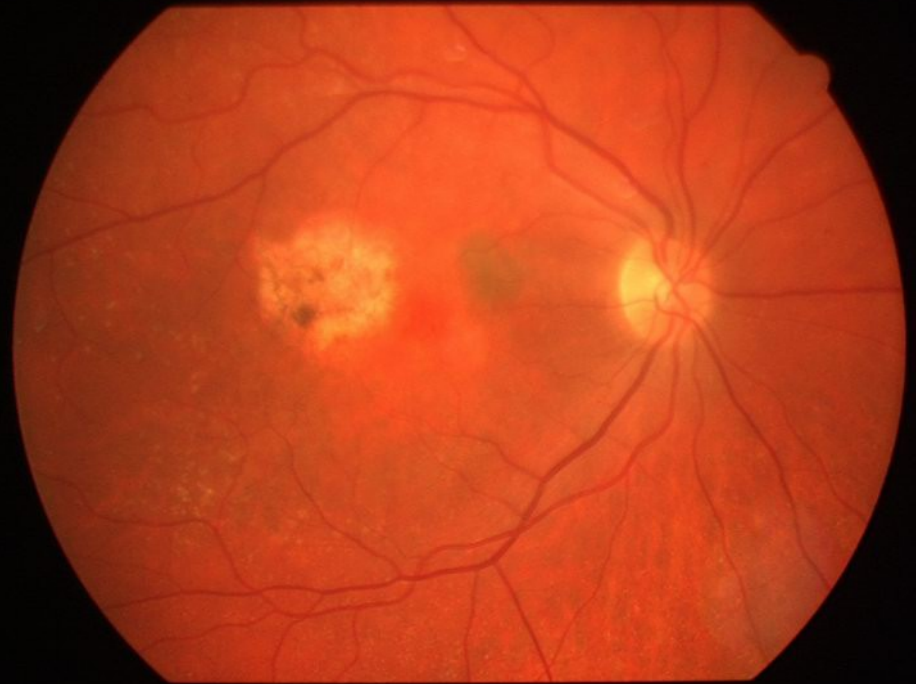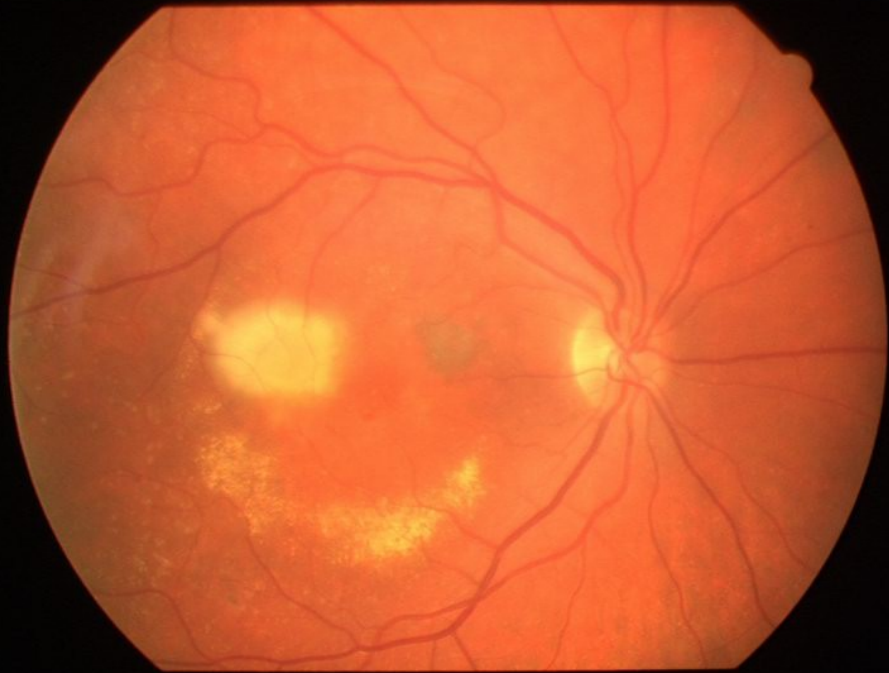
- ◆ Wet form of ARMD:
 - Argon laser
 - Photodynamic therapy
 - Anti-VEGF drugs



Timer 1 - 00:00:12



Timer 1 - 00:05:46





Retinal detachment

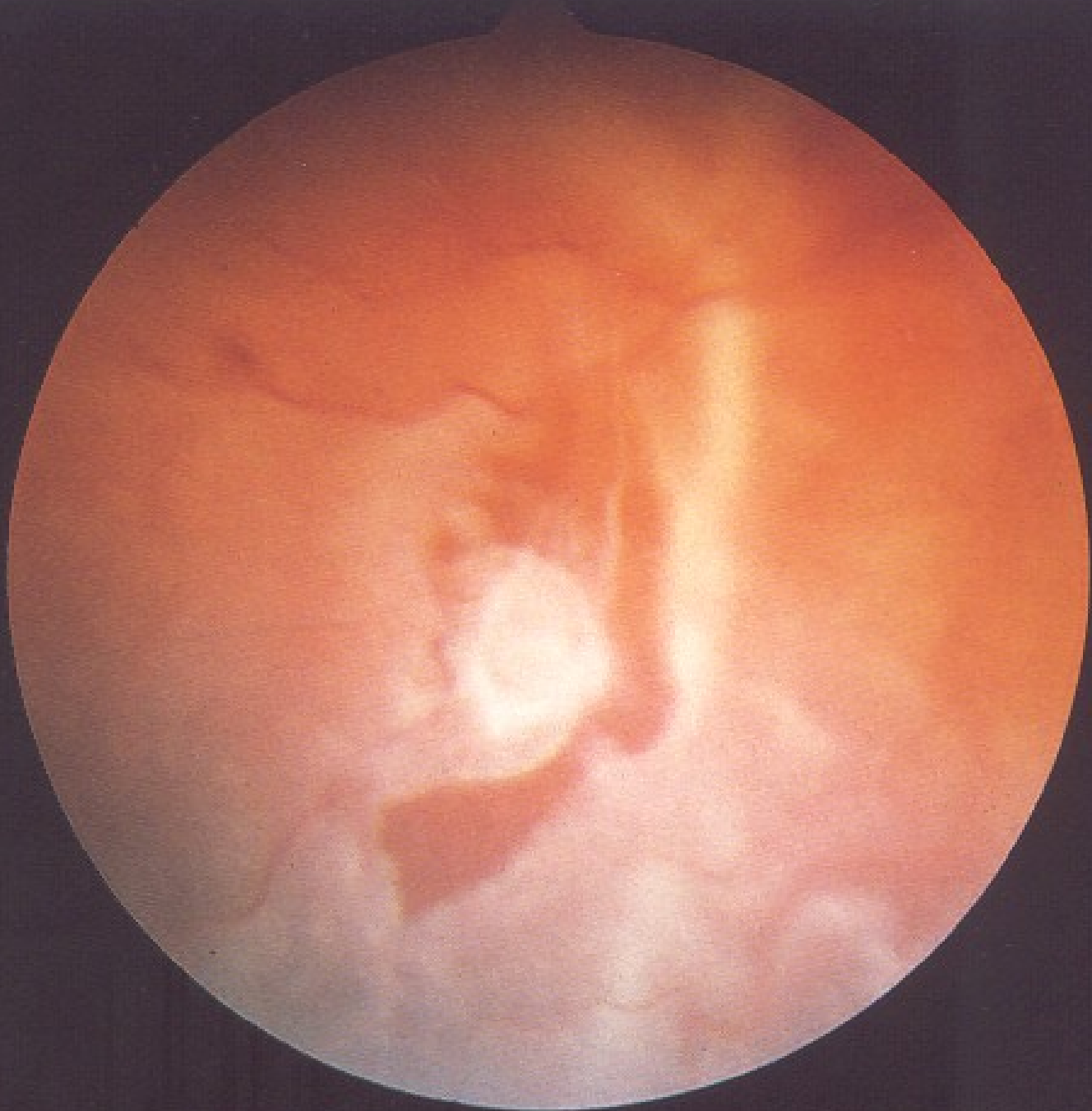
- ◆ Retinal detachment is a separation of the neuroepithelium from the retinal pigment epithelium.

Retinal detachment

- ◆ Rhegmatogenous retinal detachment
(Greek *rhegma*, meaning break)
- ◆ Nonrhegmatogenous retinal detachment
 - Exudative retinal detachment
 - Traction retinal detachment

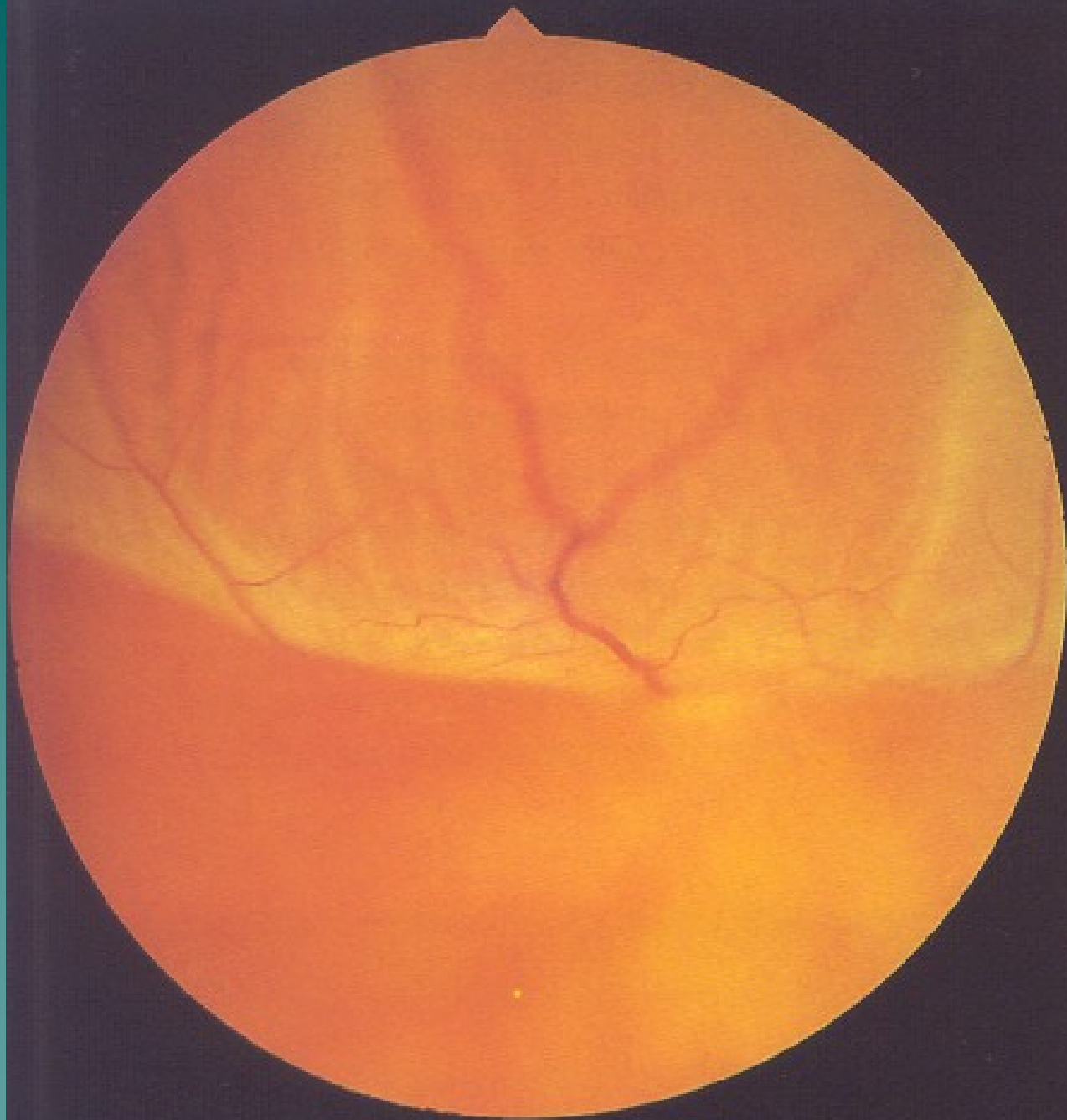
Rhegmatogenous retinal detachment

- ◆ A retinal break can be found
- ◆ 50% of patient have photopsias or entopsias (floaters).
- ◆ The intraocular pressure is usually lower in the affected eye than in the fellow eye.



Rhegmatogenous retinal detachment

- ◆ Small clumps of pigmented cells in the vitreous.
- ◆ The detachment is convex toward the front of the eye.
- ◆ The detached retina has a corrugated appearance and undulates with eye movements.



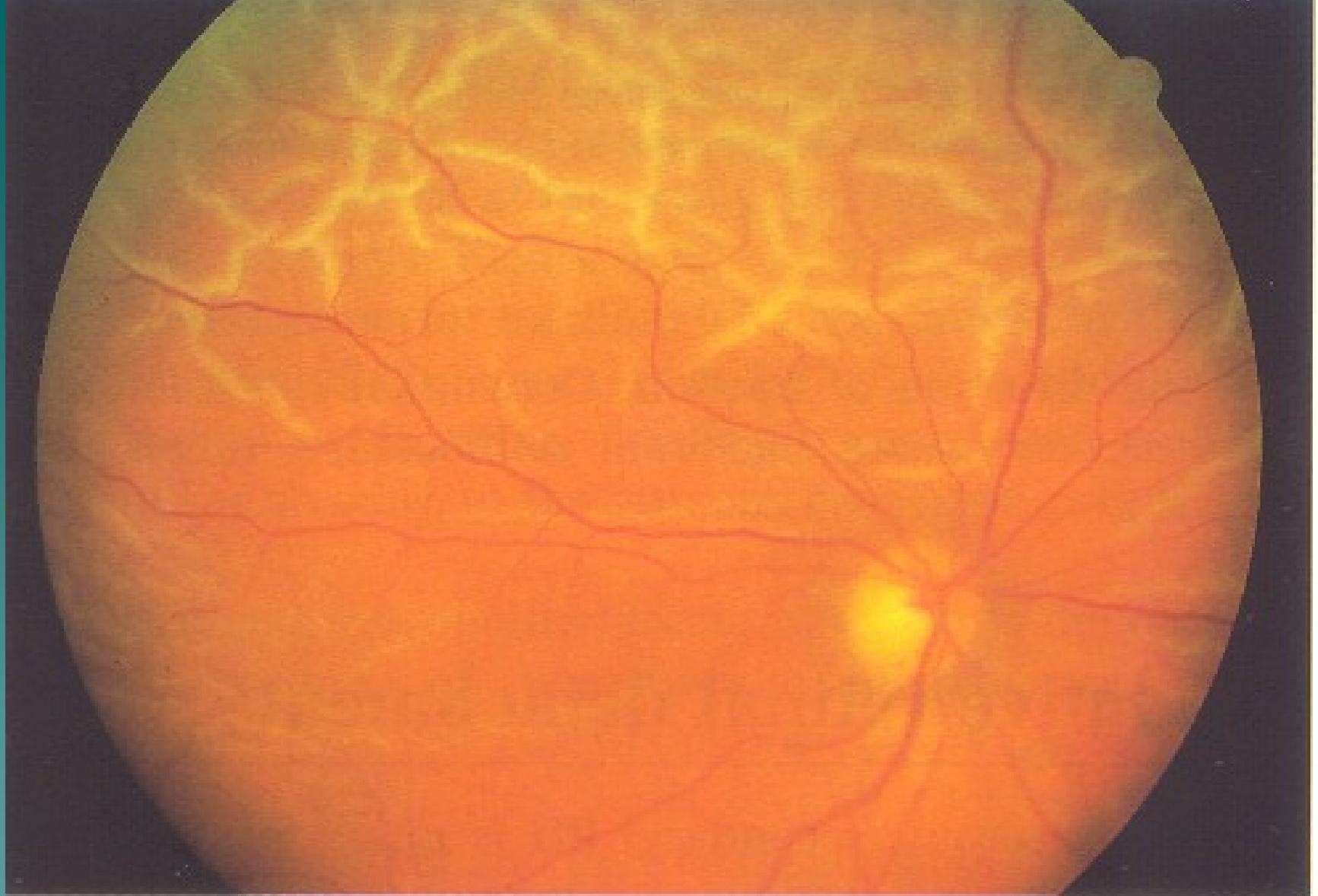
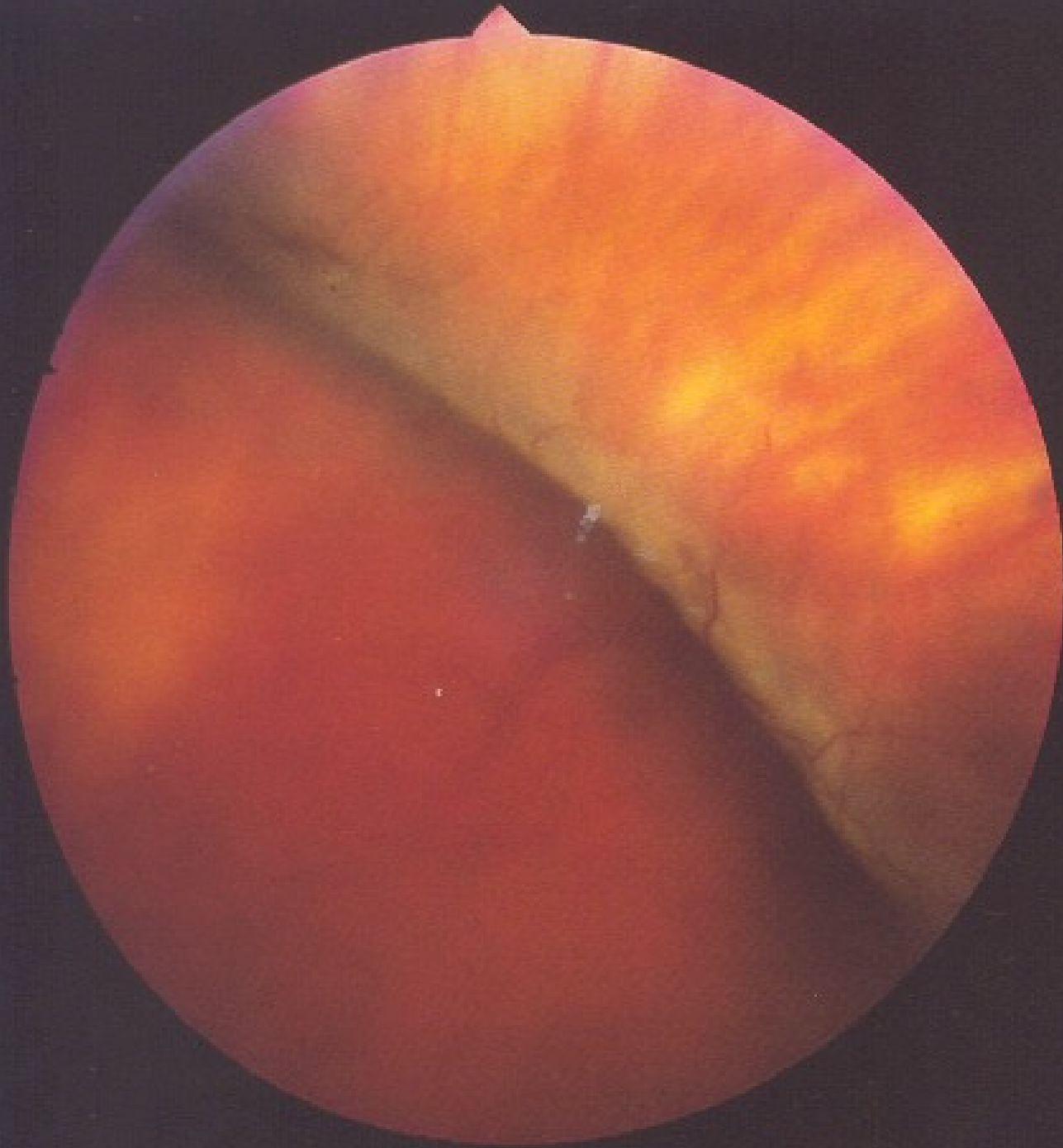
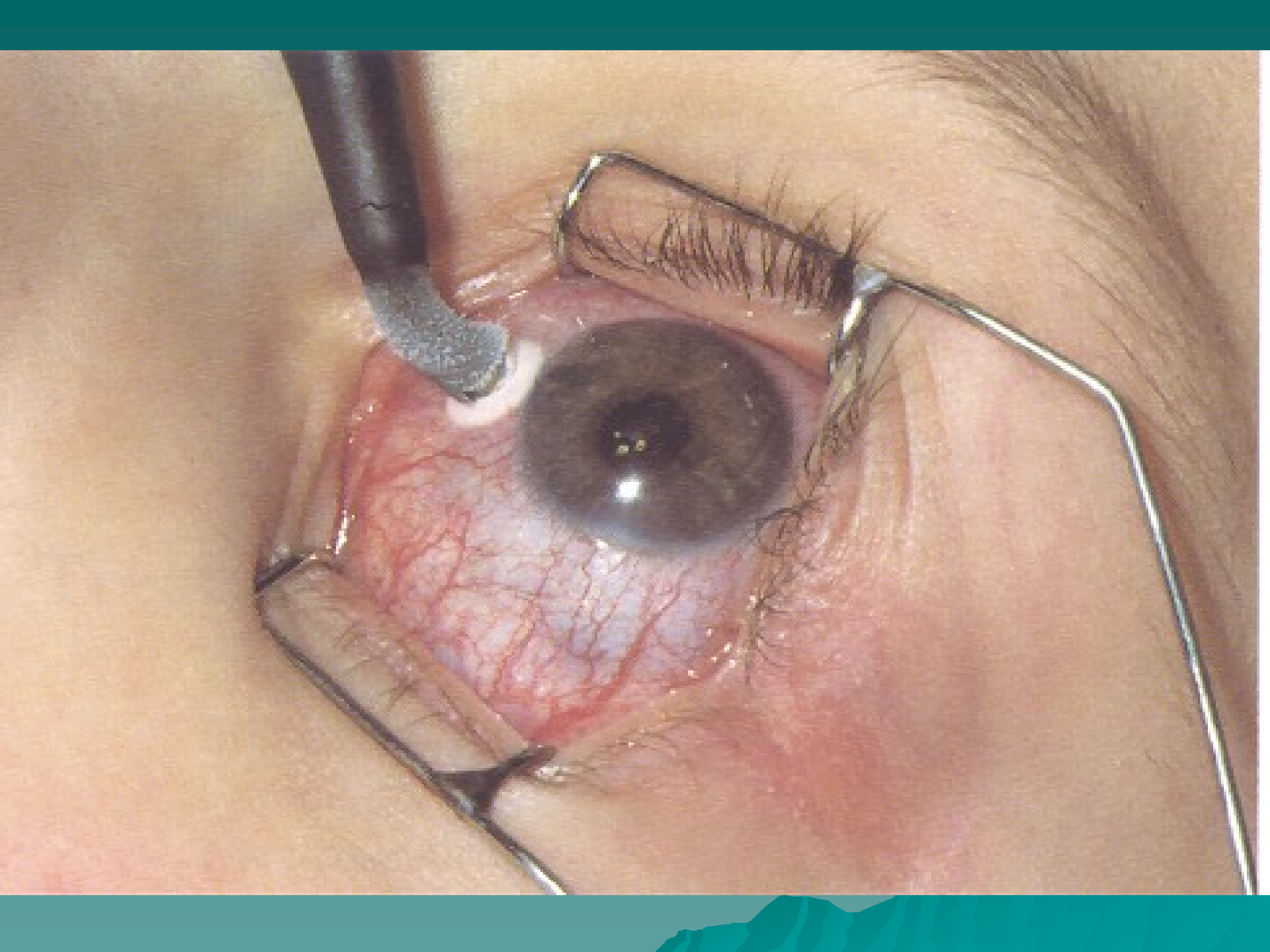


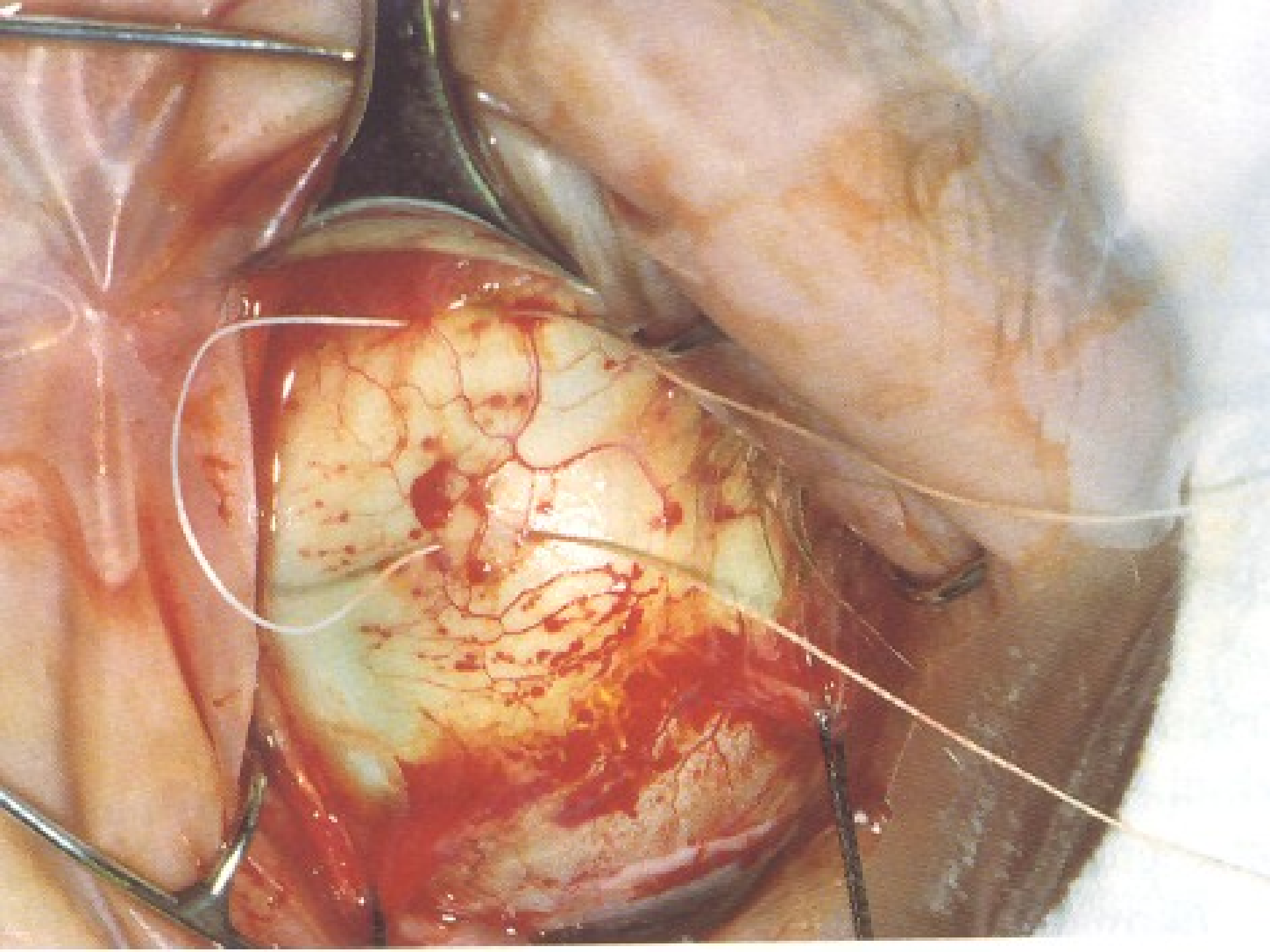
Figure 9.39 Fresh superior retinal detachment with the characteristic corrugated appearance caused by intraretinal oedema

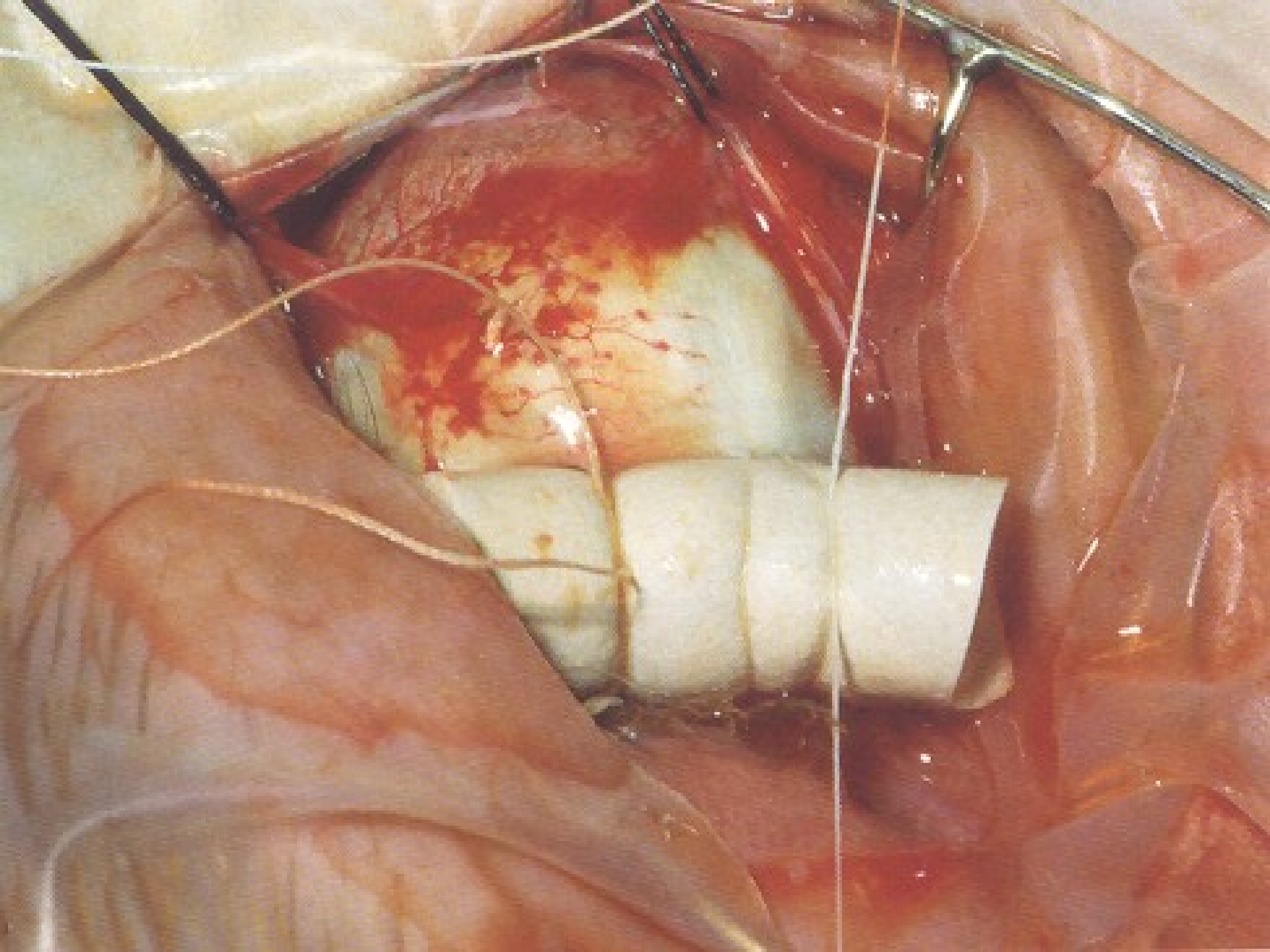
Rhegmatogenous retinal detachment

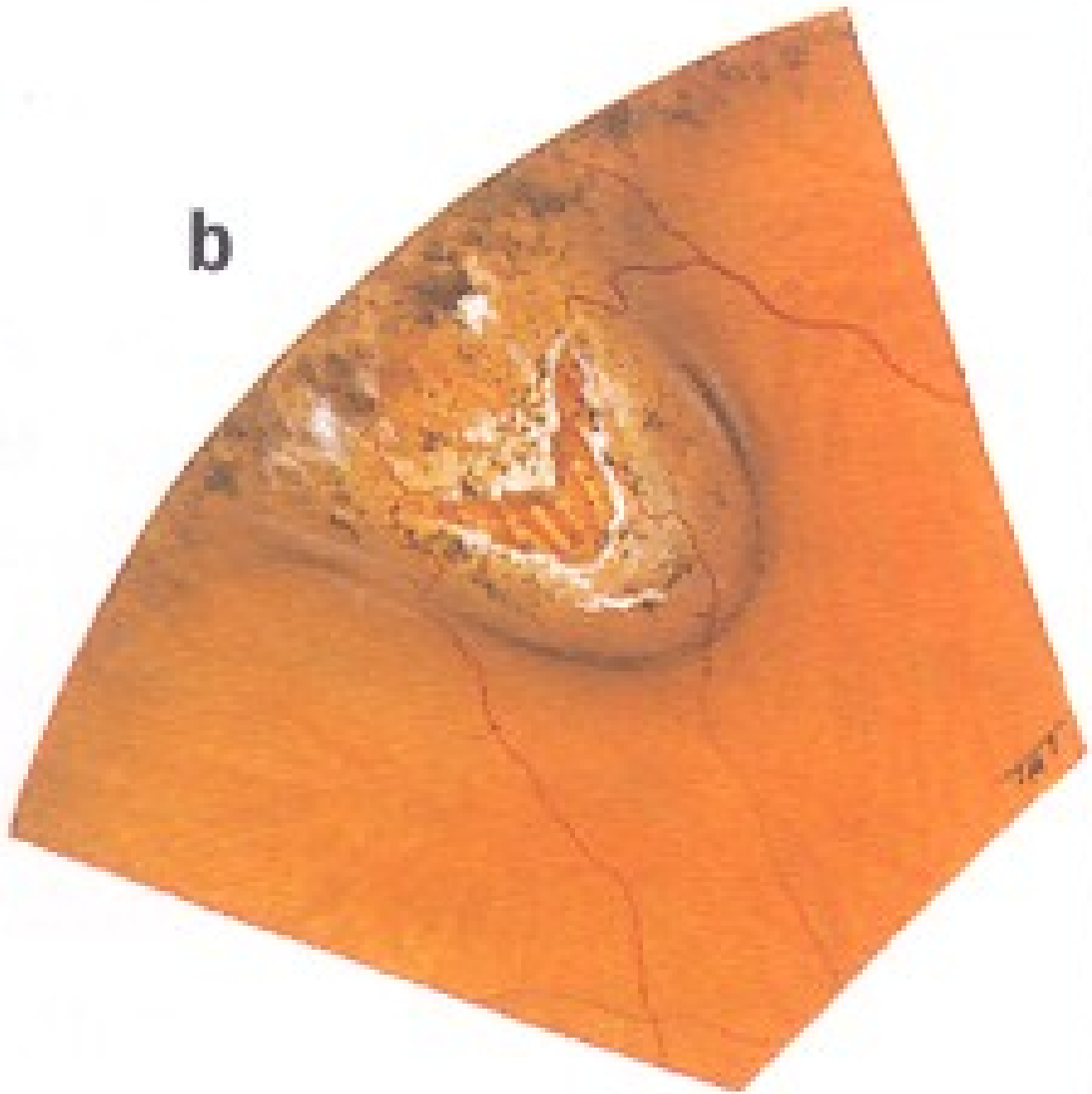
- ◆ The principles of retinal detachment surgery are first to find all breaks, and second to close all breaks.
 - A careful preoperative examination
 - A scleral buckling procedure
 - Pars plana vitrectomy
- ◆ If all breaks are closed, the subretinal fluid will be absorbed.

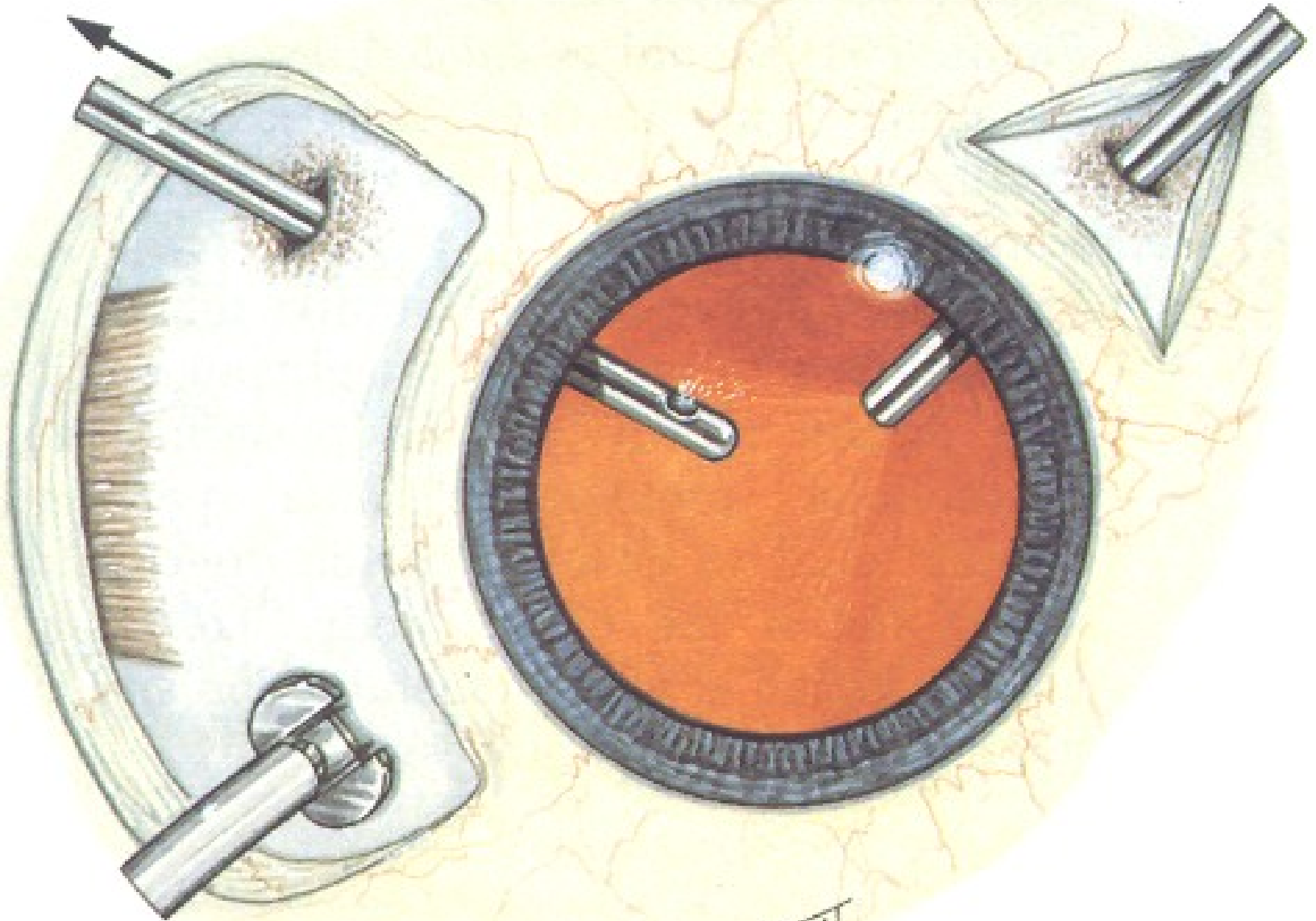




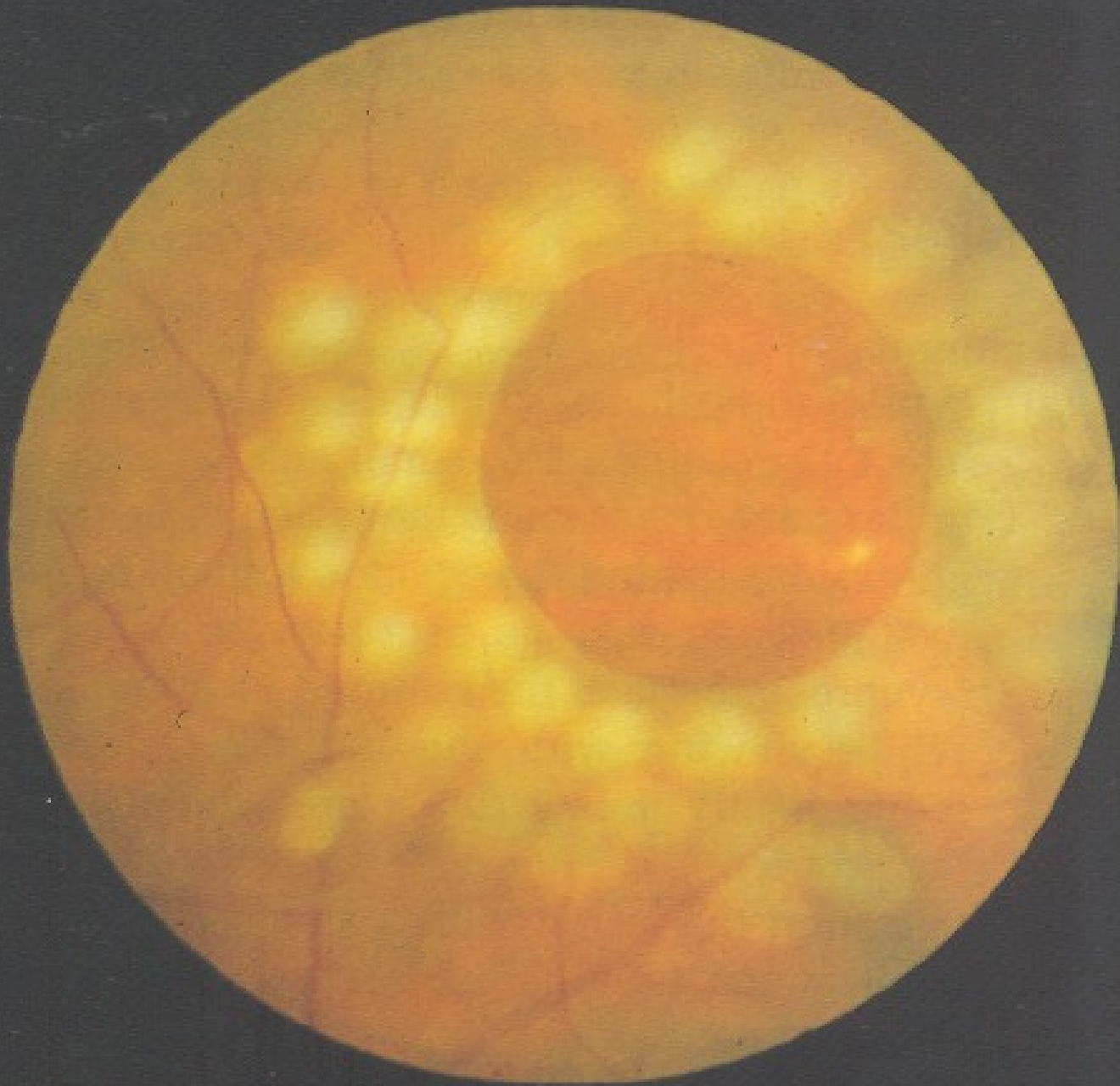








TARRANT

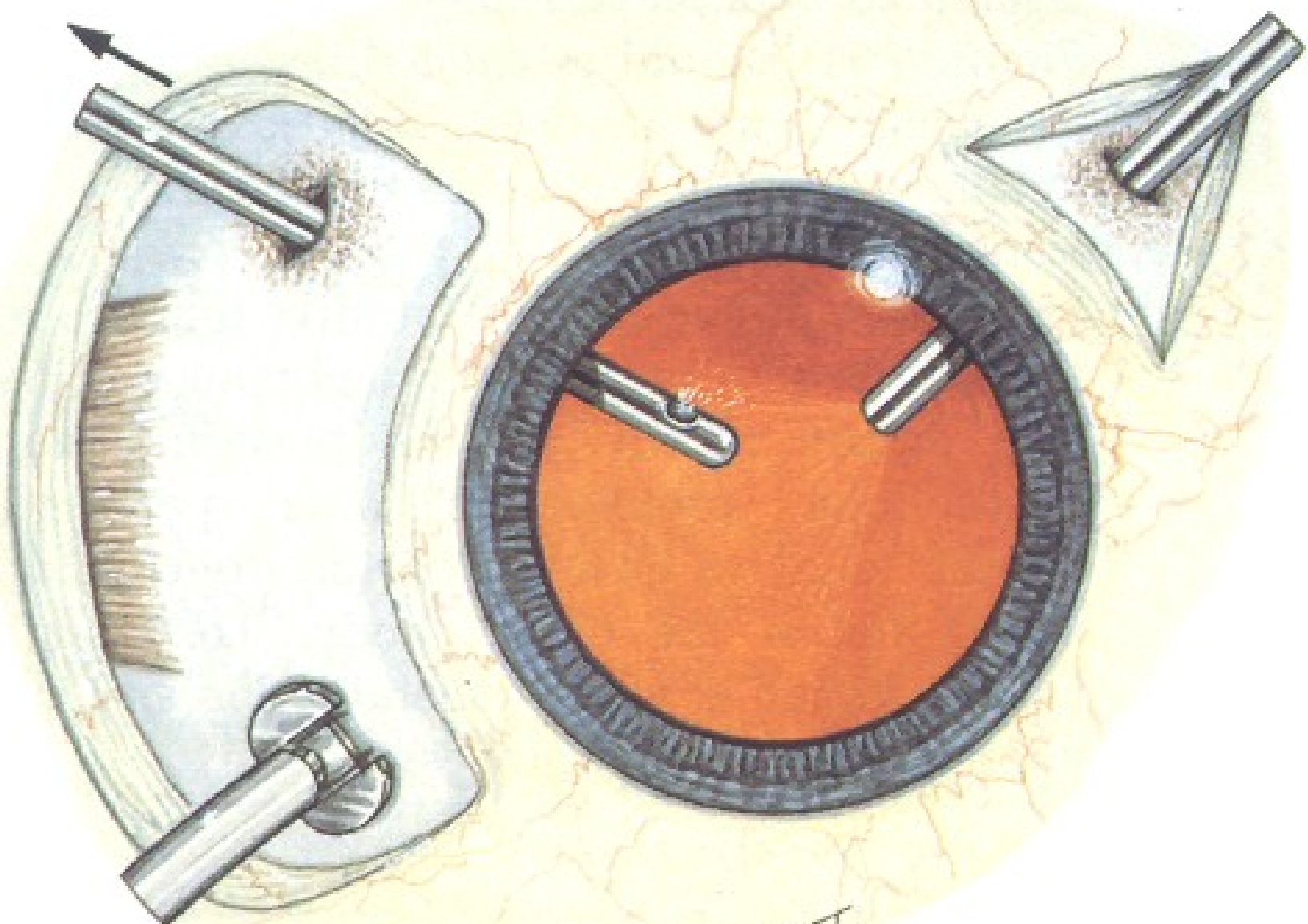


Exudative retinal detachment

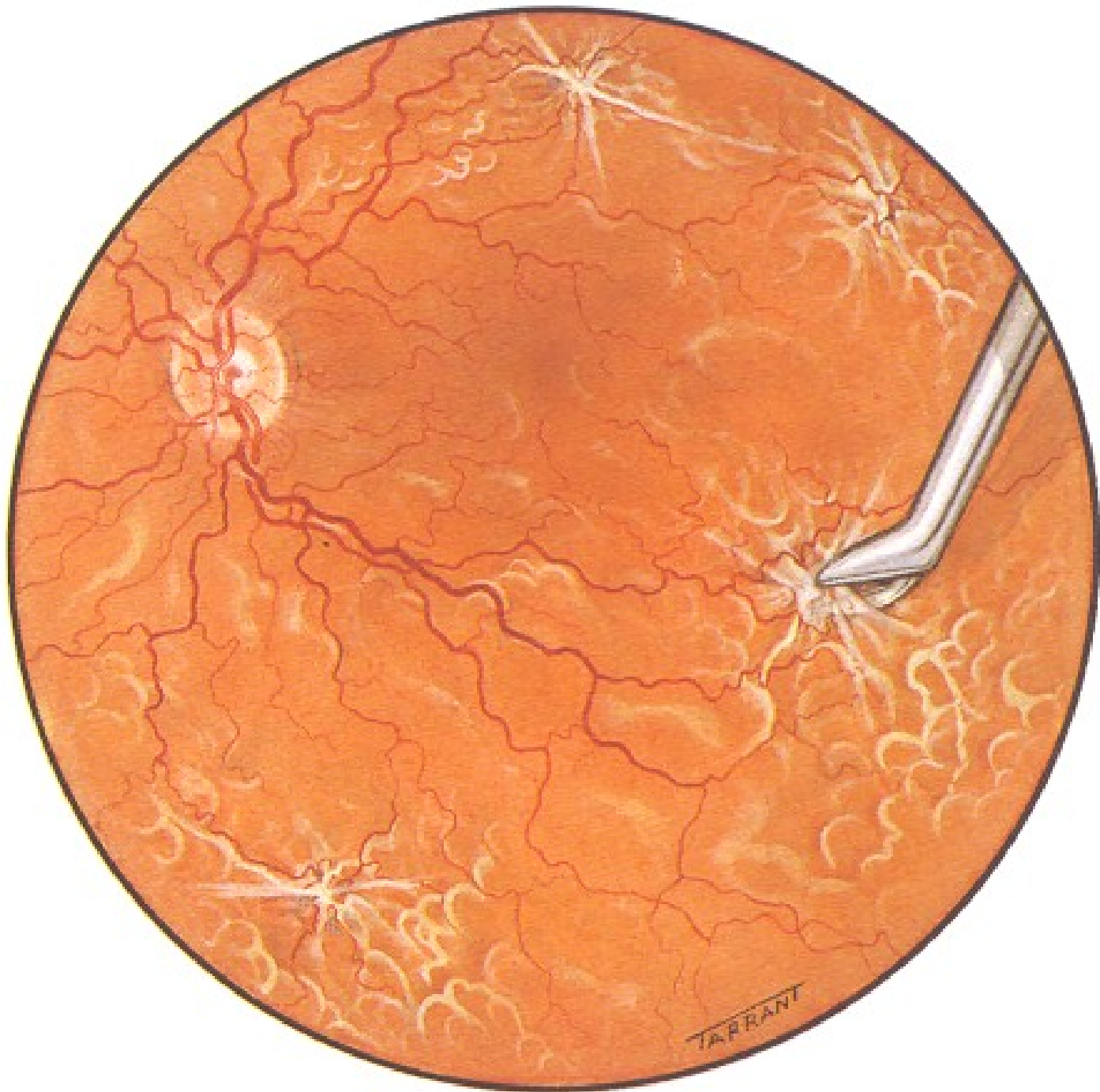- ◆ ERD occurs when either retinal blood vessels or the RPE are damaged, allowing fluid to pass into the subretinal space.
- ◆ Neoplasia and inflammatory diseases are the leading causes of such detachments.
- ◆ We have to treat the reason (neoplasia and inflammatory diseases).

Traction retinal detachment

- ◆ Vitreous membranes pull the sensory retina away from the RPE, causing a traction retinal detachment.
- ◆ The retina has a smooth surface and is immobile.
- ◆ The detachment is concave toward the front of the eye.
- ◆ Treatment=PPV



TARRANT



Angiomatosis retinae (von Hippel's disease)

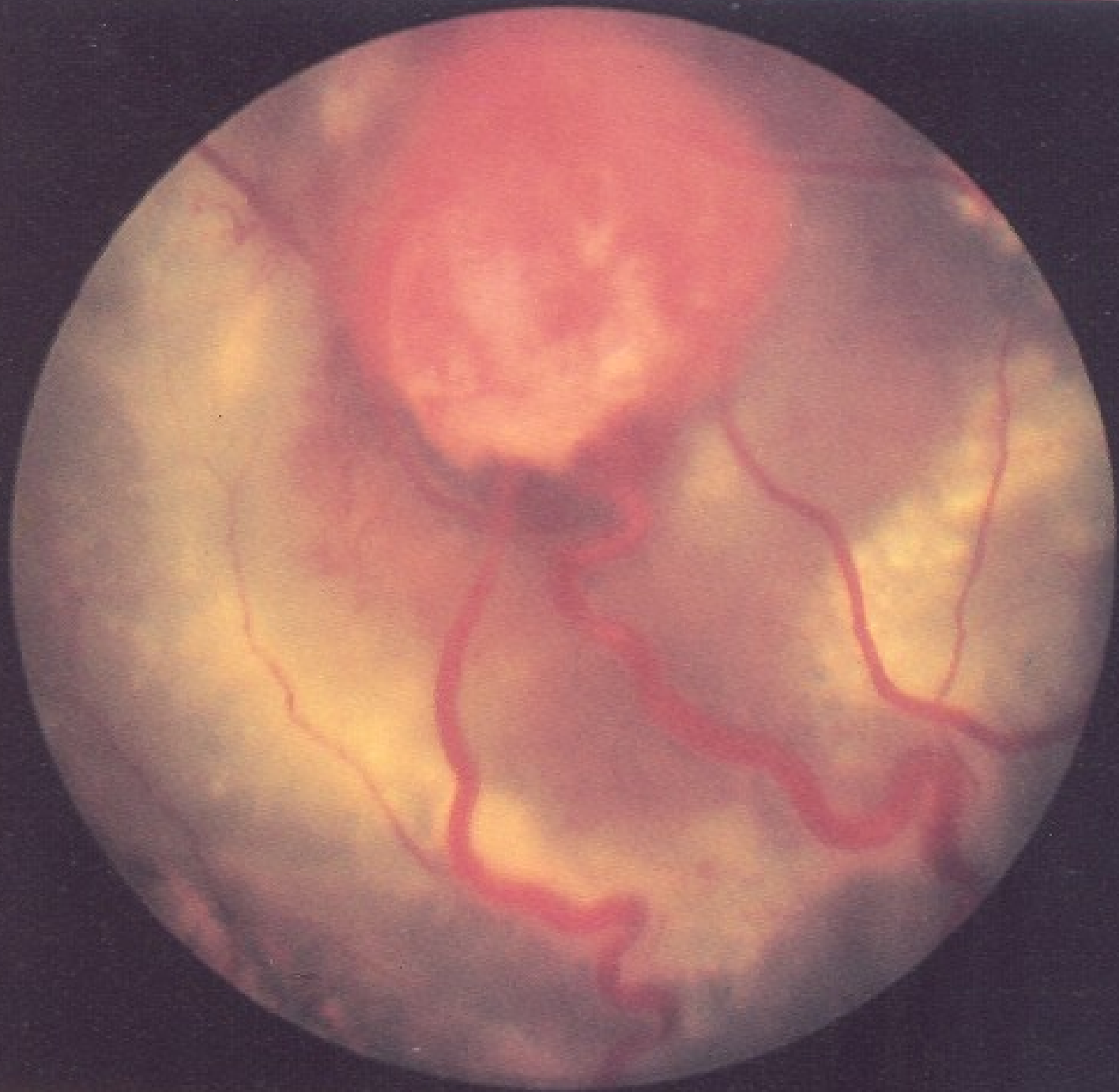
- ◆ In angiomatosis retinae, capillary hemangiomas develop in the retina or optic nerve head.
- ◆ Capillary hemangioma is a spherical orange-red tumor fed by a dilated tortuous retinal artery and drained by an engorged vein.

Angiomatosis retinae (von Hippel's disease)

- ◆ Multiple angiomas may be found in the same eye.
- ◆ Bilateral involvement occurs in 50% of patients.

Angiomatosis retinae (von Hippel's disease)

- ◆ Leakage of plasma constituents from an angioma may result in serous detachment of the retina and/or accumulation of exudate in the macula resulting in reduction in visual acuity.
- ◆ Occasionally vitreous hemorrhage may occur.



Angiomatosis retinae (von Hippel's disease)

- ◆ Angiomatosis retinae has both a hereditary and sporadic form.
- ◆ The type of transmission is autosomal dominant, often with incomplete penetrance and delayed expression.
- ◆ The retinal angiomas may be associated with cerebral (hemangioblastomas of the cerebellum, medulla, pons, and spinal cord) and visceral lesions (cysts of the kidney, pancreas, liver, epididymis, ovary).

Angiomatosis retinae (von Hippel's disease)

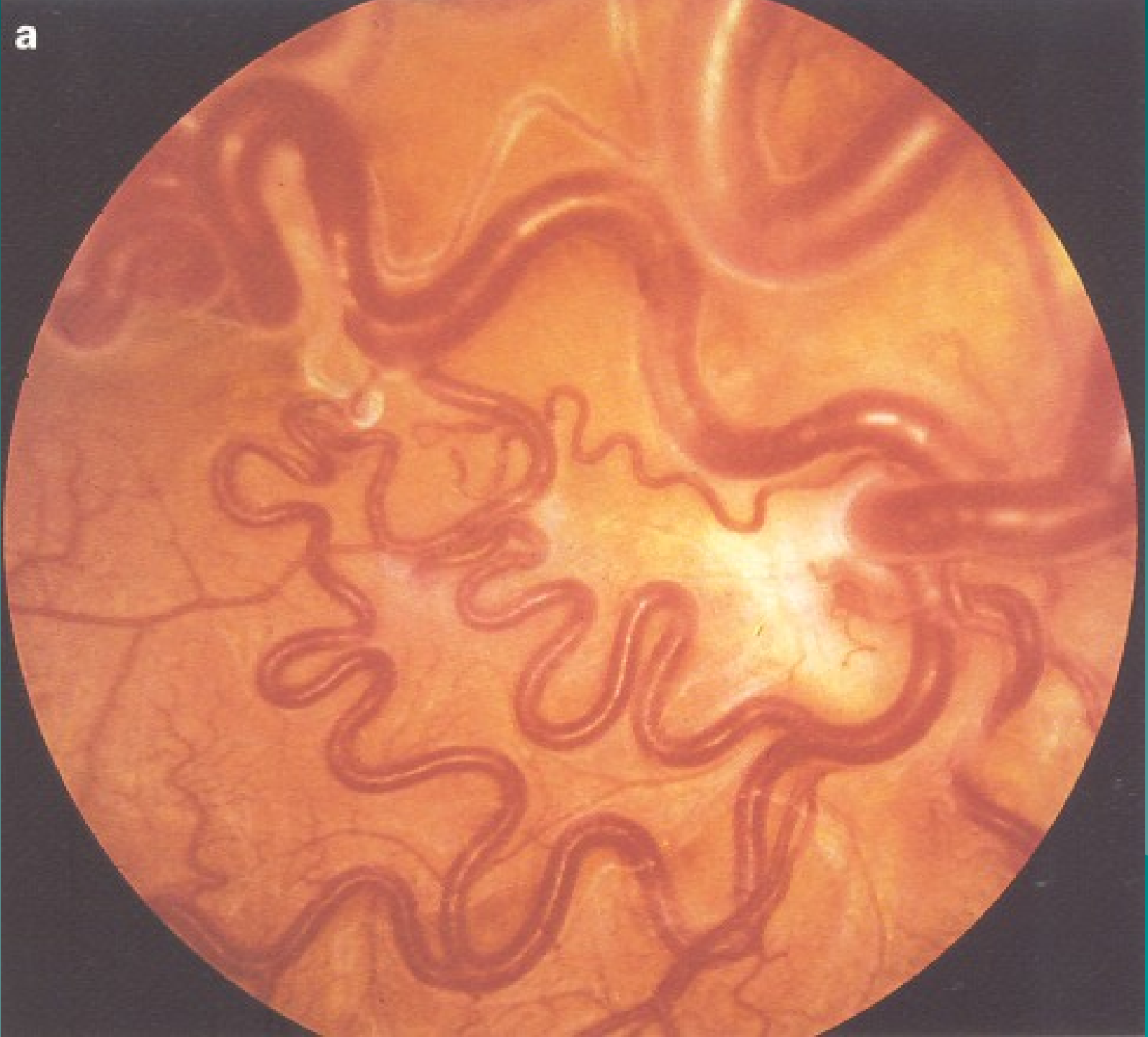
- ◆ When angiomatosis retinae is associated with central nervous system and visual involvement, the name von Hippel-Lindau disease is used.
- ◆ Management includes treatment of identified angiomas if associated with leakage (photocoagulation, cryotherapy).

Racemose hemangioma

Wyburn-Mason syndrome

- ◆ Congenital retinal arteriovenous communications are rare developmental anomalies.
- ◆ The abnormalities may range from a single arteriovenous communication to a complex anastomotic system.
- ◆ In many cases the lesions are unilateral, non-hereditary.

a



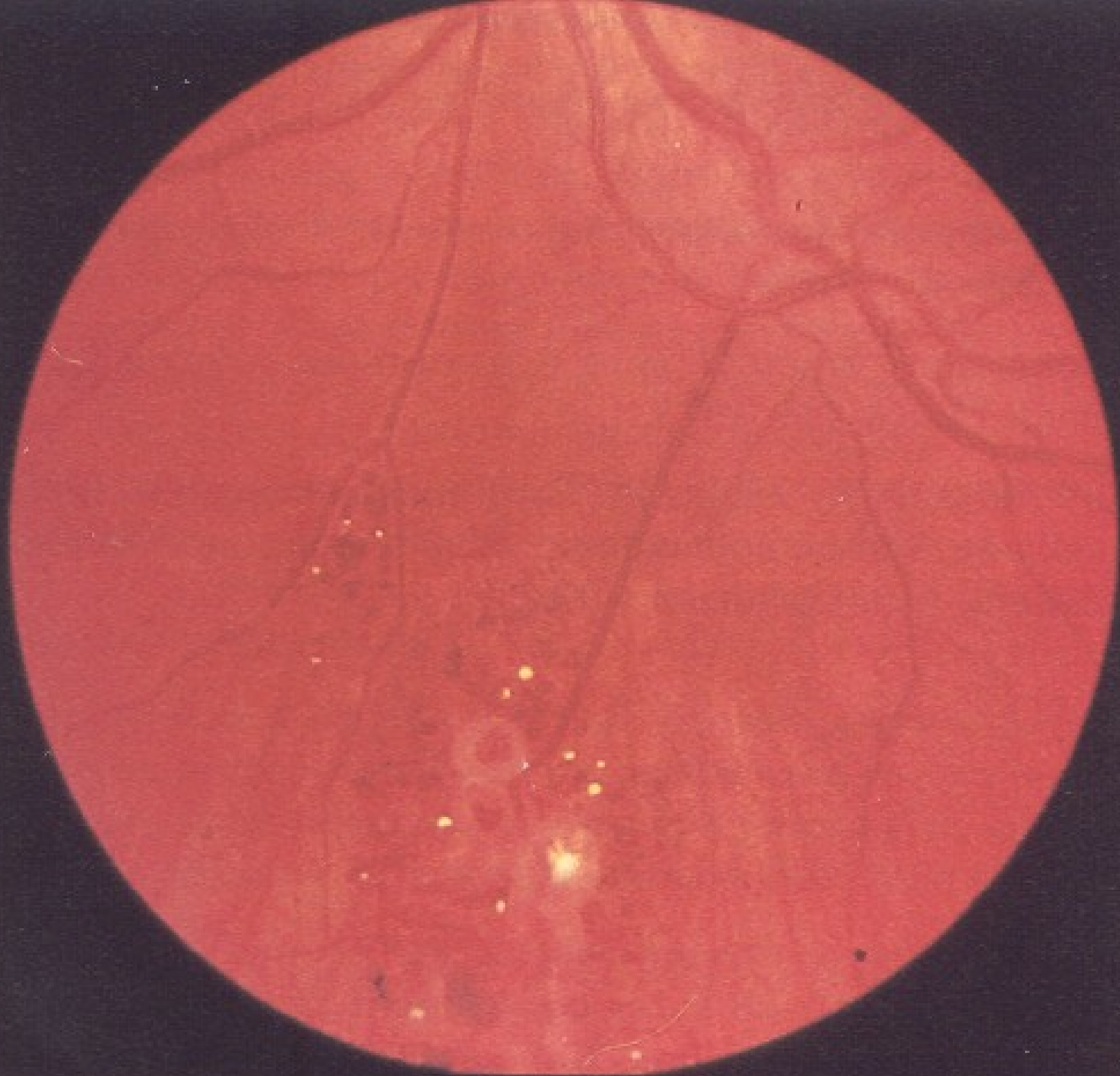
Racemose hemangioma

Wyburn-Mason syndrome

- ◆ The retinal lesions may be associated with similar ipsilateral vascular malformations in the brain, face, and orbit = Wyburn-Mason syndrome.
- ◆ If the lesions are large, however, they may have subretinal fluid and exudate.

Retinal cavernous hemangioma

- ◆ Retinal cavernous hemangioma is characterized by the formation of grape-like- clusters of thin-walled, angiomatous lesions in the inner retina or on the optic nerve head.
- ◆ Leakage is characteristically absent.
- ◆ Occasionally the angiomas may bleed into the vitreous but they usually remain asymptomatic.
- ◆ Treatment (photocoagulation, cryotherapy) is usually not necessary.



Retinoblastoma

- ◆ Retinoblastoma is the most common intraocular malignancy of childhood.
- ◆ The tumor occurs bilaterally in 30% to 35% of cases.
- ◆ About 90% of cases are diagnosed prior to age 3 years.

Retinoblastoma

- ◆ 6% of retinoblastoma patients will have a family history of retinoblastoma. The condition is generally inherited through an autosomal dominant gene with high but incomplete penetrance.
- ◆ When retinoblastoma is bilateral, it is caused by a germinal mutation.

Retinoblastoma

- ◆ The most common presenting signs of retinoblastoma appear to be leukocoria and strabismus.
- ◆ Other features, such as visual difficulties, red eye, discoloration of the iris, and spontaneous hyphema are uncommon.

Retinoblastoma

- ◆ Small retinoblastoma lesions generally appear as white, vascular intraretinal tumors fed and drained by dilated, tortuous retinal vessels.
- ◆ Far- advanced retinoblastoma commonly extends outside the eye and invades the optic nerve and orbit.

Retinoblastoma

- ◆ Retinoblastoma undergoes spontaneous regression in approximately 1% of tumors.
- ◆ Management options that are currently used in children with retinoblastoma include enucleation, radiation therapy, photocoagulation, cryotherapy, and chemotherapy.

