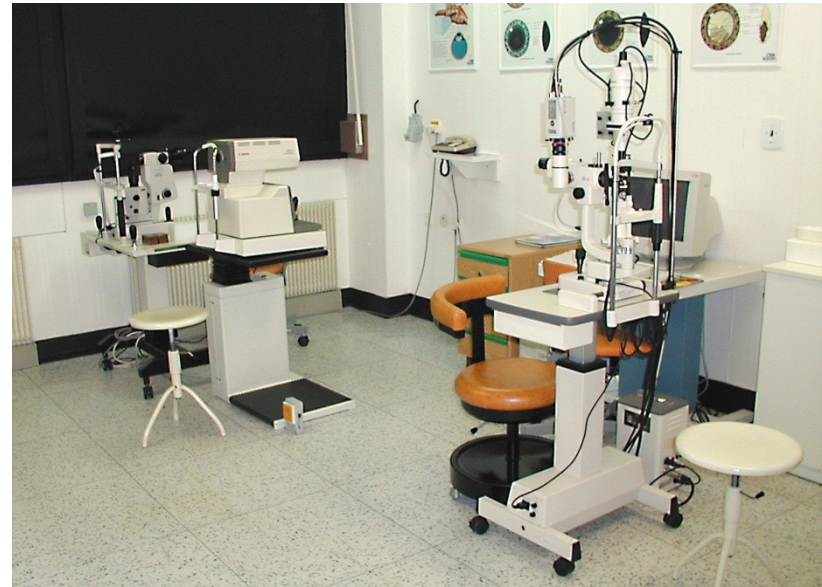

Examination techniques in ophthalmology

V. Matušková

Basic examination techniques

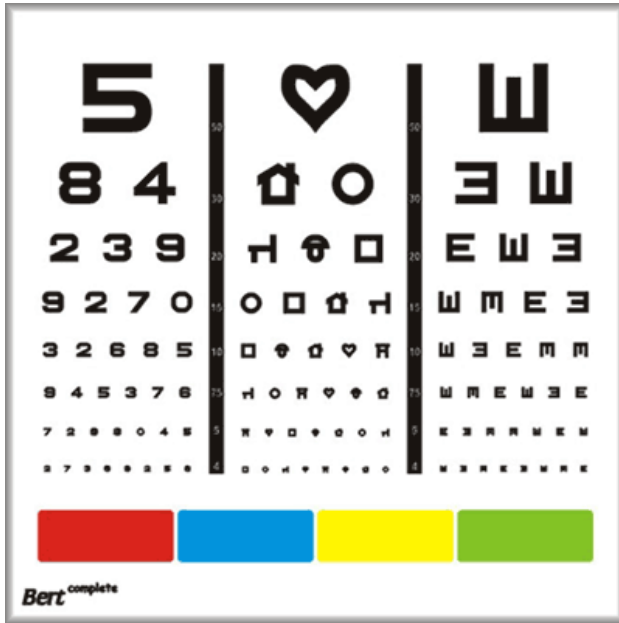
- Visual acuity (natural, best corrected)
- Measurement of intraocular pressure
- Slit lamp examination
- Fundus examination



Visual acuity

- Visual acuity (natural, best corrected)
- Distance vision
- Near vision
- **Charts**
 - Snellen
 - Landolt ring
 - Pictures
 - ETDRS
- **Jaeger**

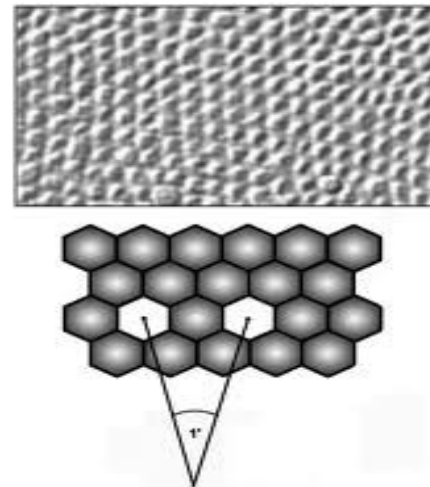

Charts



VISUAL ACUITY CHARTS	
Standard Snellen chart	Bailey-Lovie chart
<p>E 1</p> <p>F P 2</p> <p>T O Z 3</p> <p>L P E D 4</p> <p>P P C F D 5</p> <p>K H F C E F 6</p> <p>VELOPED 7</p> <p>DEVELOPED 8</p> <p>DEVELOPED 9</p> <p>DEVELOPED 10</p>	<p>D S R K N</p> <p>C K Z O H</p> <p>O N R K D</p> <p>K Z V D C</p> <p>V S H Z O</p> <p>H D K C R</p> <p>O S N H N</p> <p>S Y Z D K</p> <p>S Y Z D K</p> <p>S Y Z D K</p> <p>S Y Z D K</p>

Visual Acuity

- 5/50 (metres, feet 20/200)
- 0,1
- Minimum separabile – minimum angle of resolution



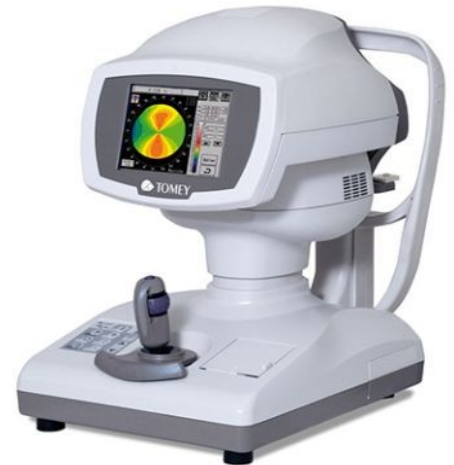Visual acuity

- Counting finger (metres)
- Hand movement
- Light perception
- Amaurosis
- Practical blindness

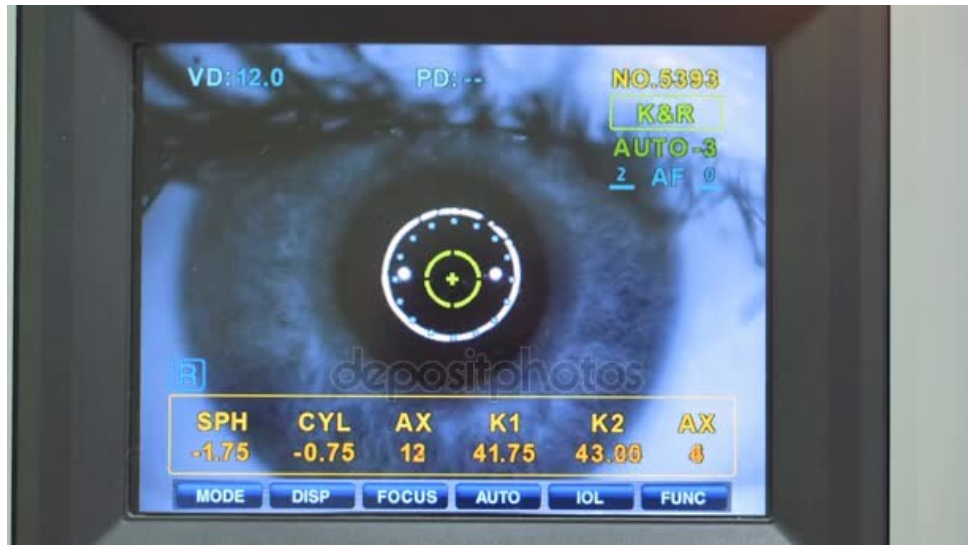
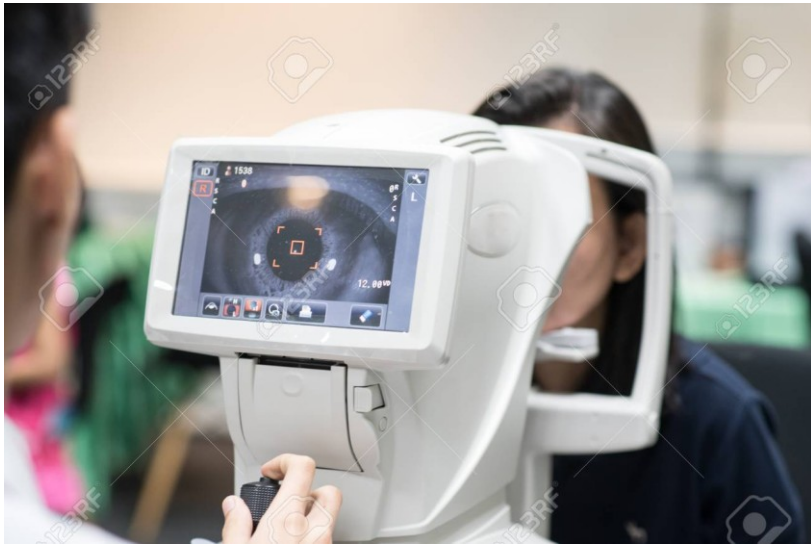
Refraction

- Refractive error is an optical abnormality in which the shape of the eye fails to bring light into sharp focus on the retina, resulting in blurred or distorted vision.
- In optometry, a "refraction" procedure is the measurement of refractive error
- **Autorefractor**



Autorefractor



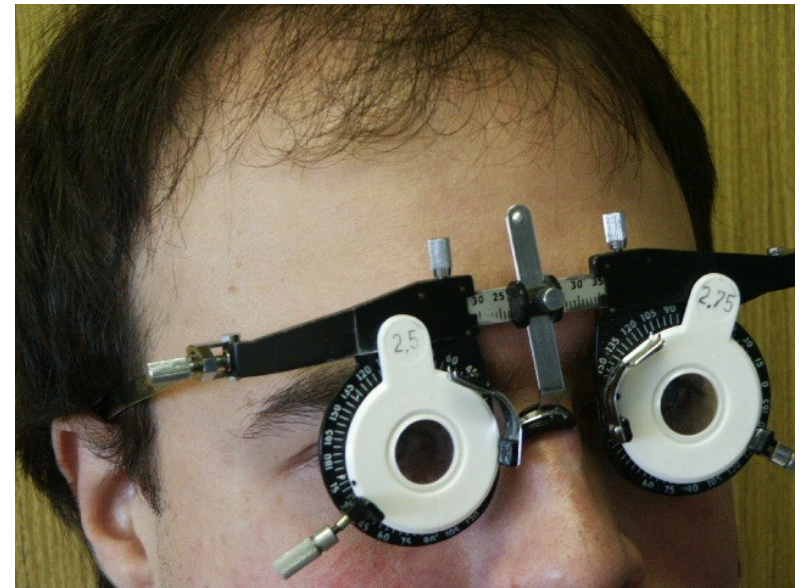
Visual acuity

- VOD: 5/50, s – 2,0 Dsf a -1,0 Dcyl ax 90 5/5
- VOS: 5/30, s – 2,5 Dsf a -1,5 Dcyl ax 100 5/7,5,

-
- VOD: visus oculi dextri
 - VOS: visus oculi sinistri
 - Dsf: dioptry sferic
 - Dcyl: dioptry cylindric
 - Ax: axis

Visual acuity

- Frame
- Lenses
- Axis



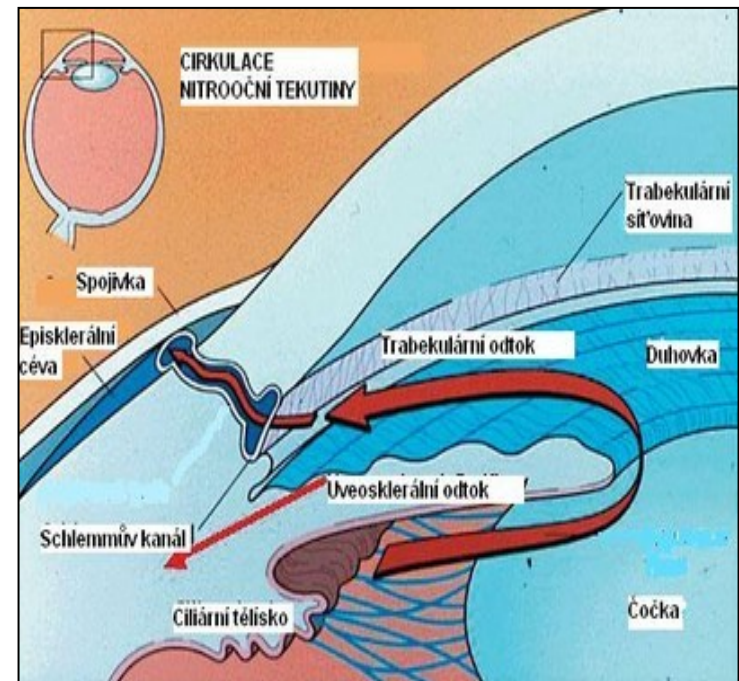
Tonometry

Contact techniques

- Schiötz tonometry
- Goldmann applanation tonometry


Non contact techniques

- Jet air (air puff)

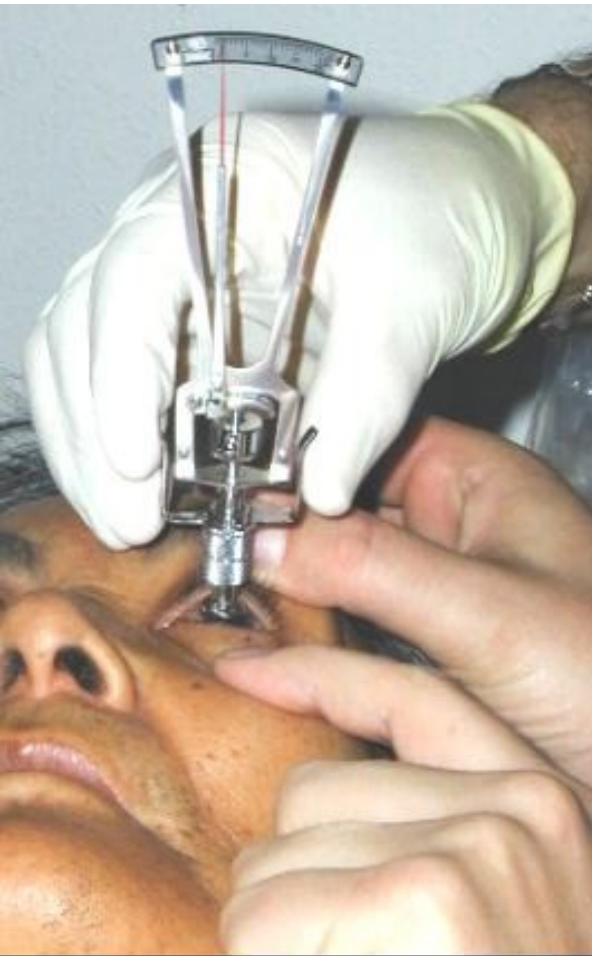

Schiötz tonometry

- 7/7,5
- Topical aneesthesia



Schiötz tonometry






Goldmann tonometry

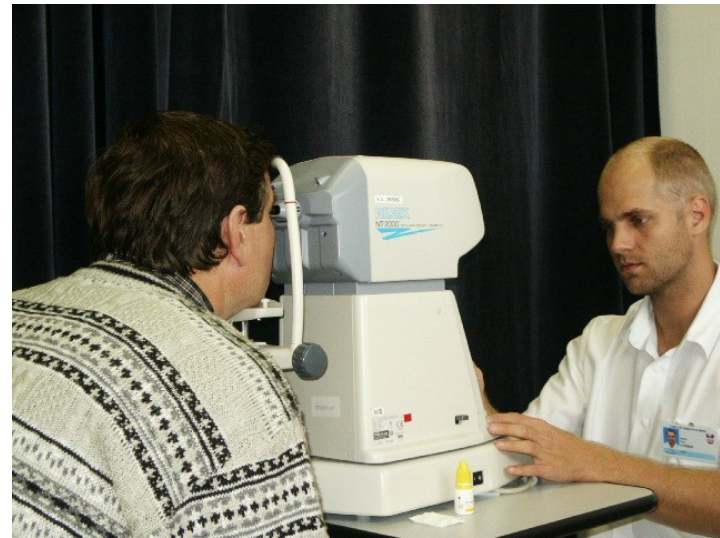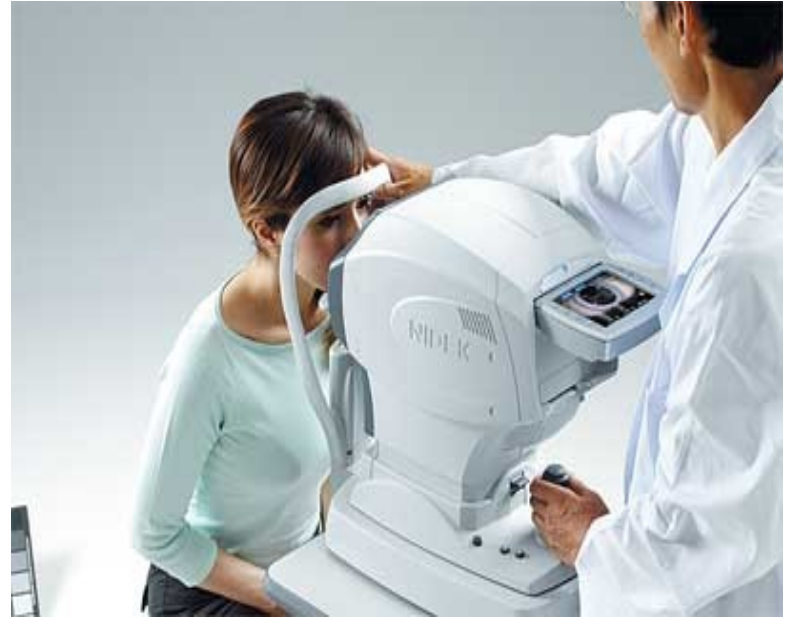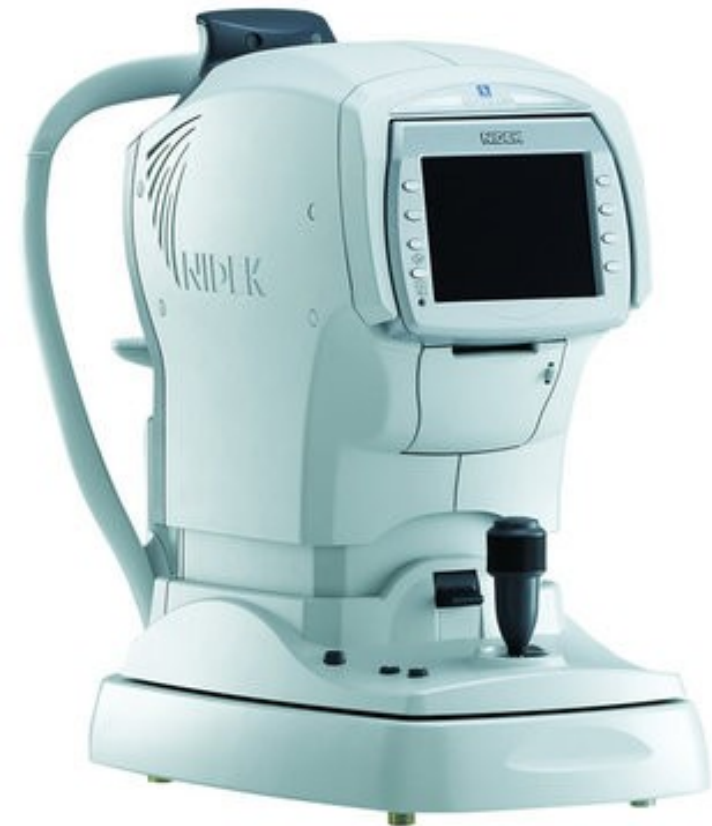- The normal range is 10-21 mmHg
- Topical anesthesia, fluorescein
- Force required to flatten the cornea



Goldmann tonometry

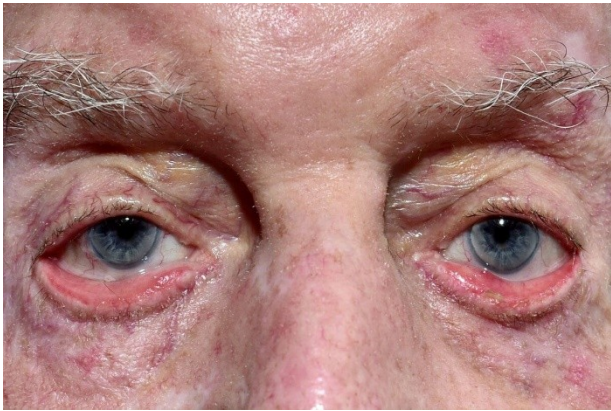

Non contact tonometry

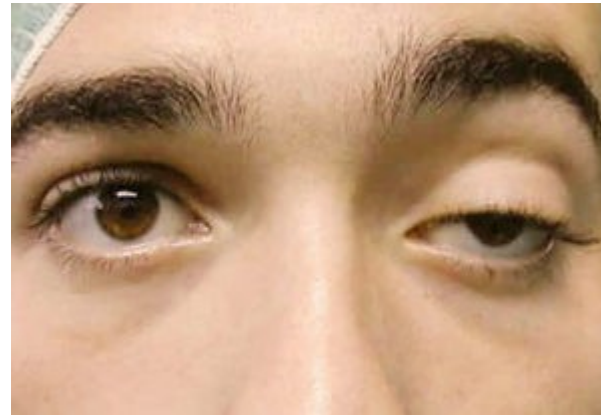

Examination of anterior segment

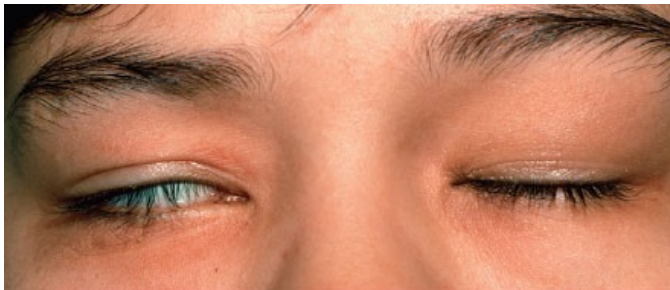Aspection



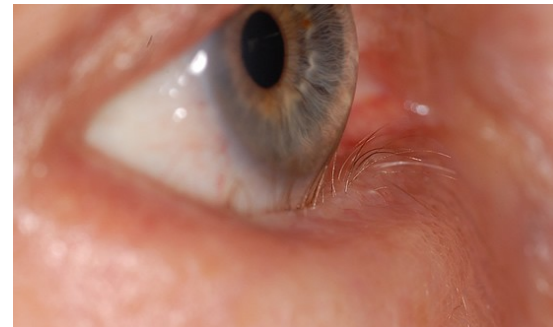Ectropium



Ptosis



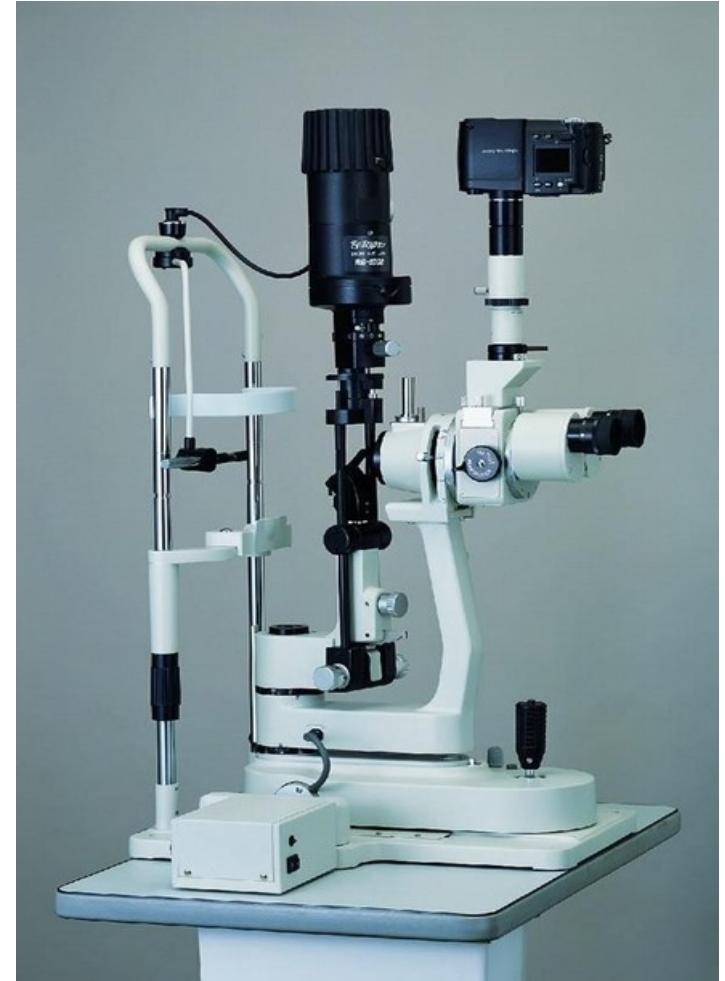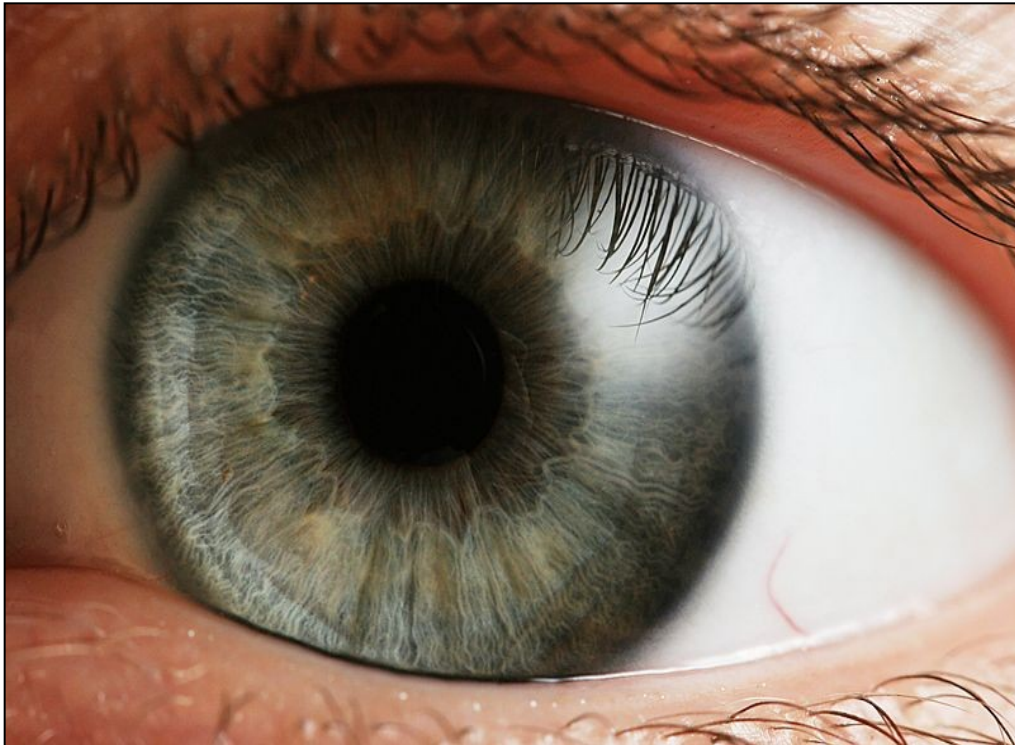
Lagophtalmus



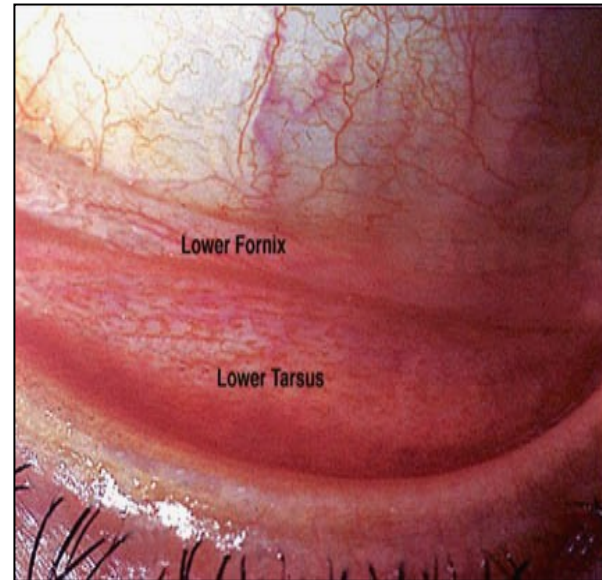
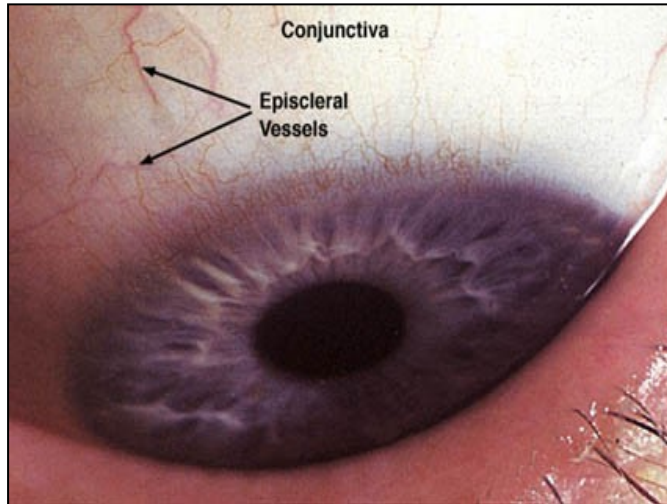
Entropium

Slit lamp biomicroscopy

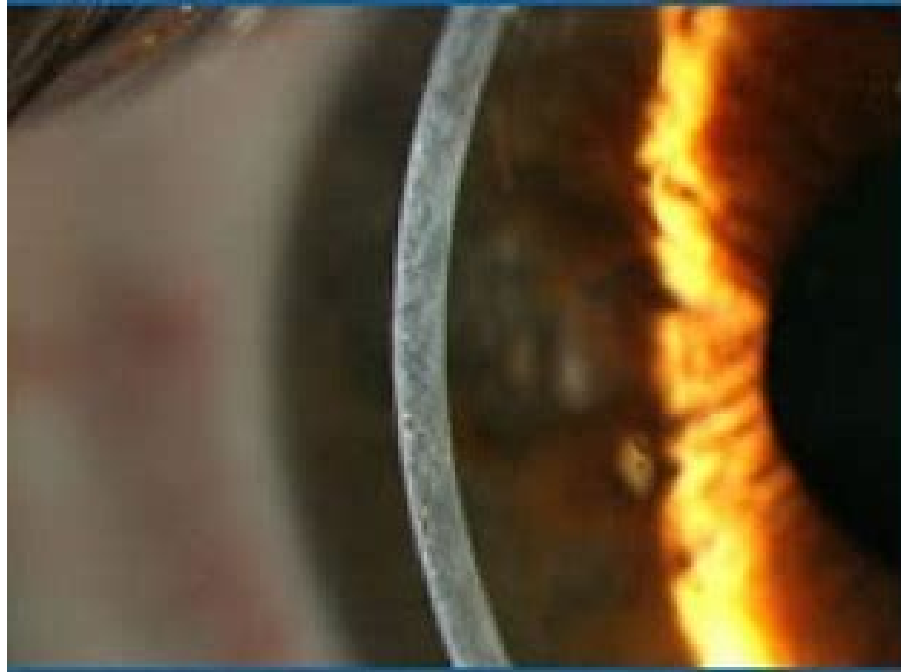- table mounted microscope with a special adjustable illumination source attached



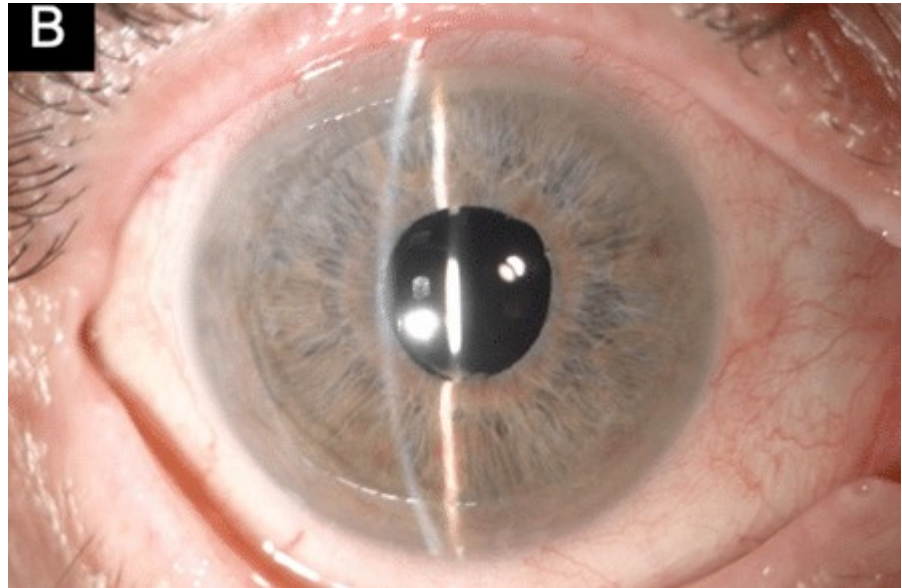
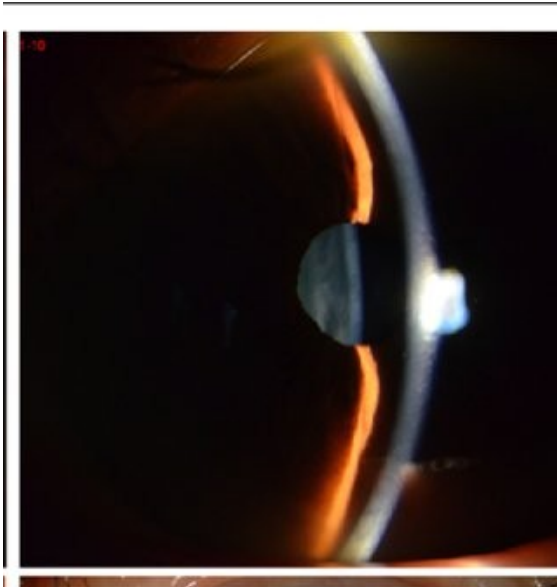
Slit lamp biomicroscopy



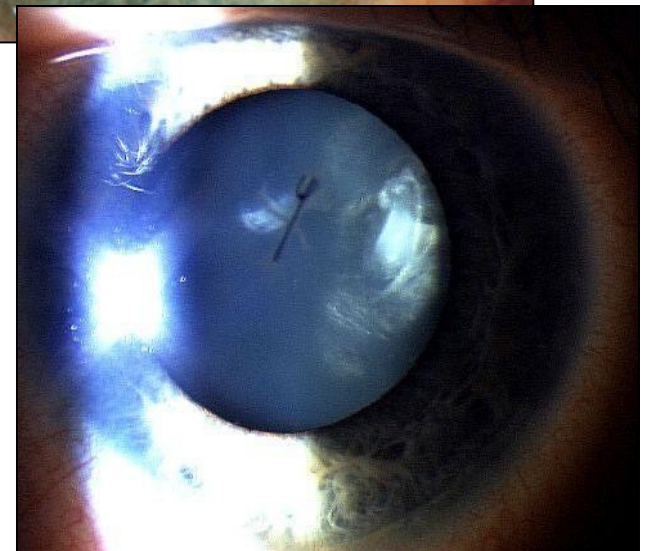
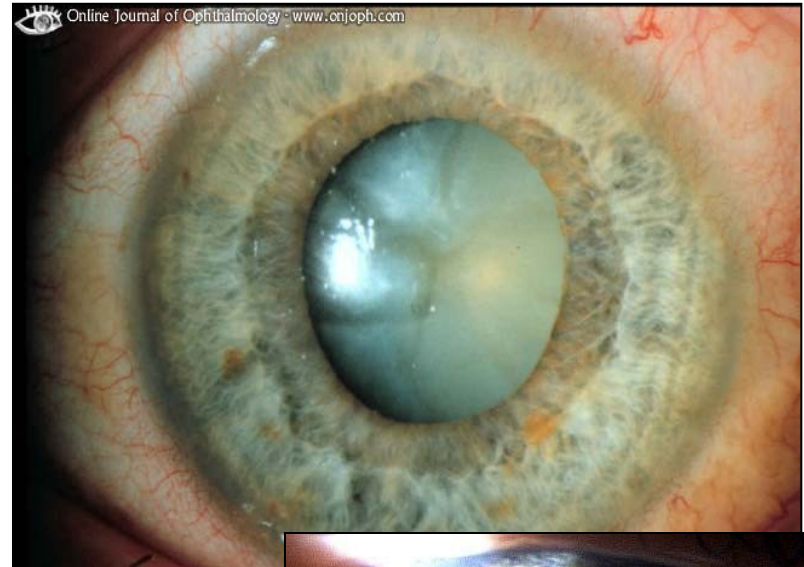
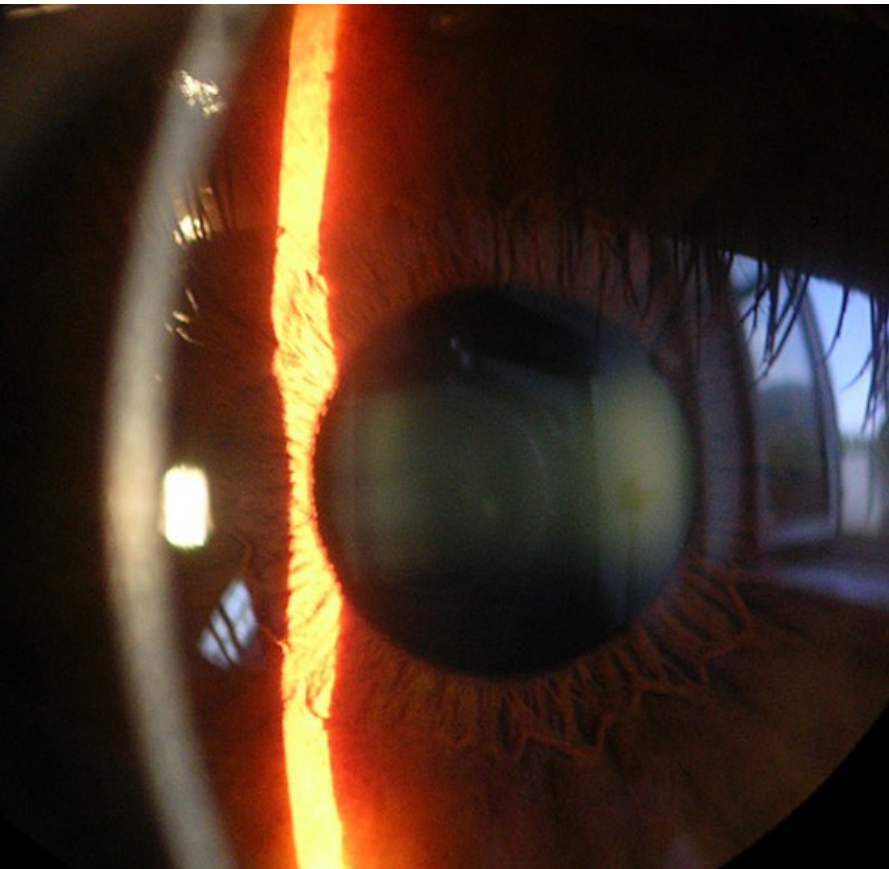
Slit lamp biomicroscopy



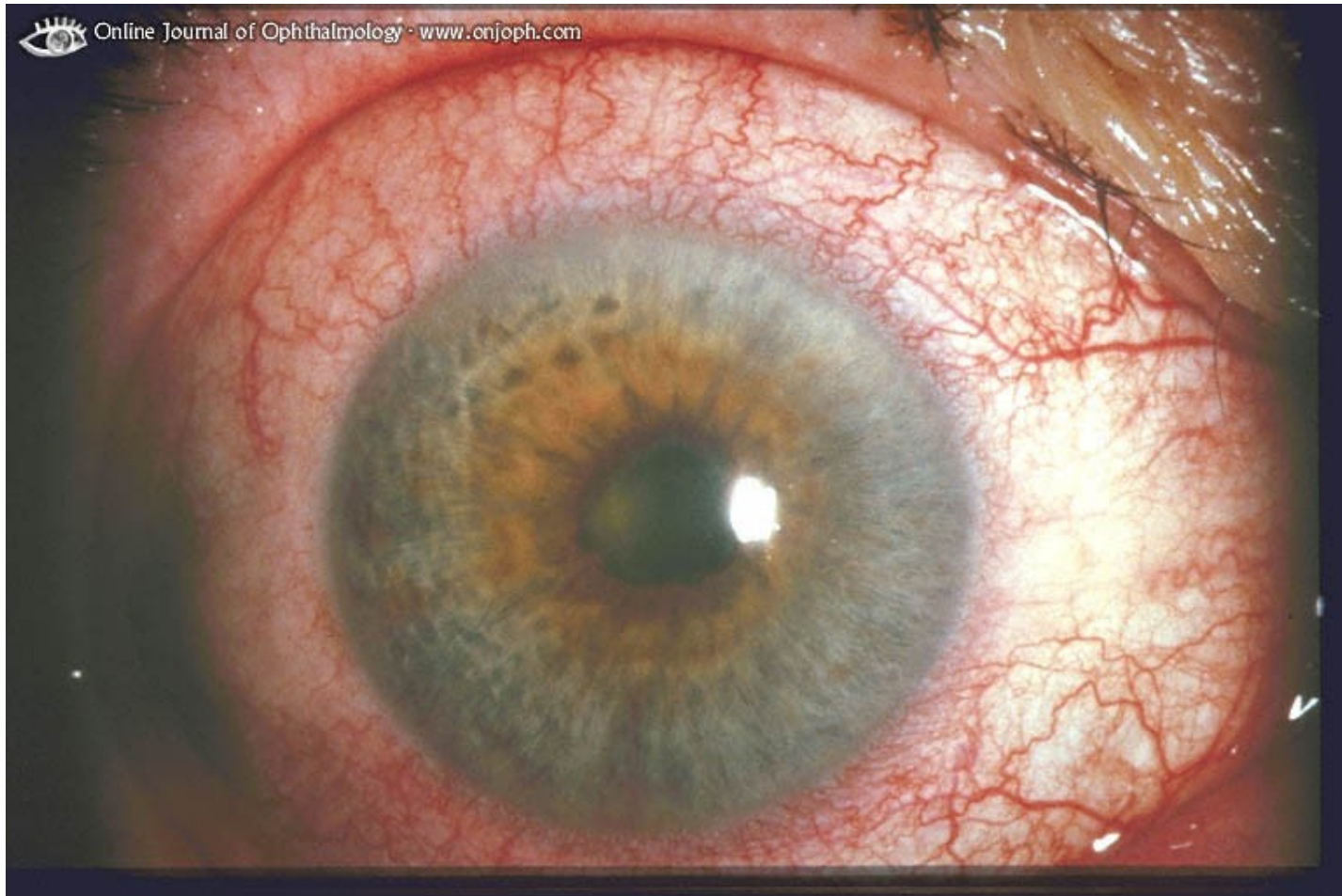Slit lamp biomicroscopy



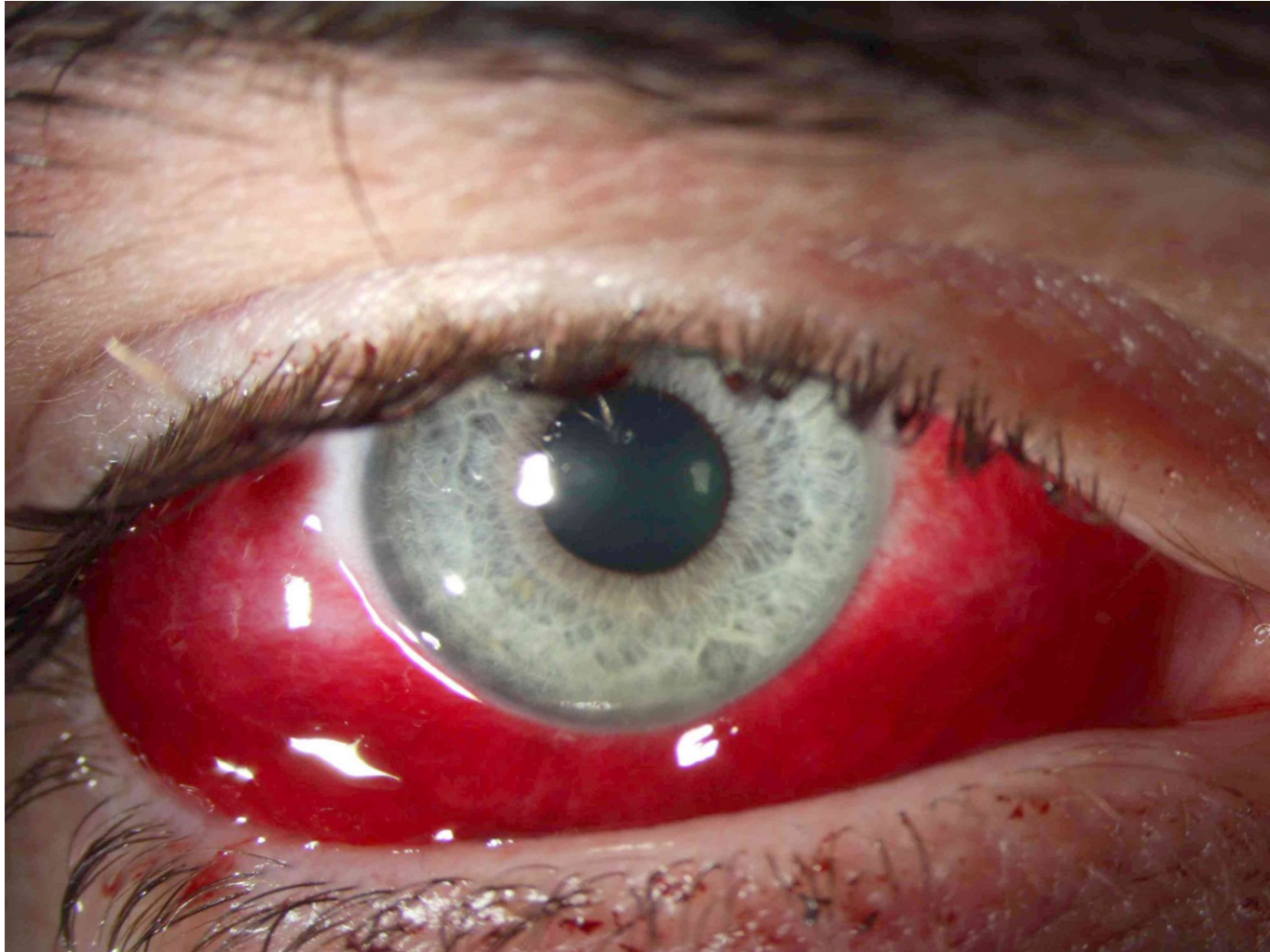
Slit lamp biomicroscopy



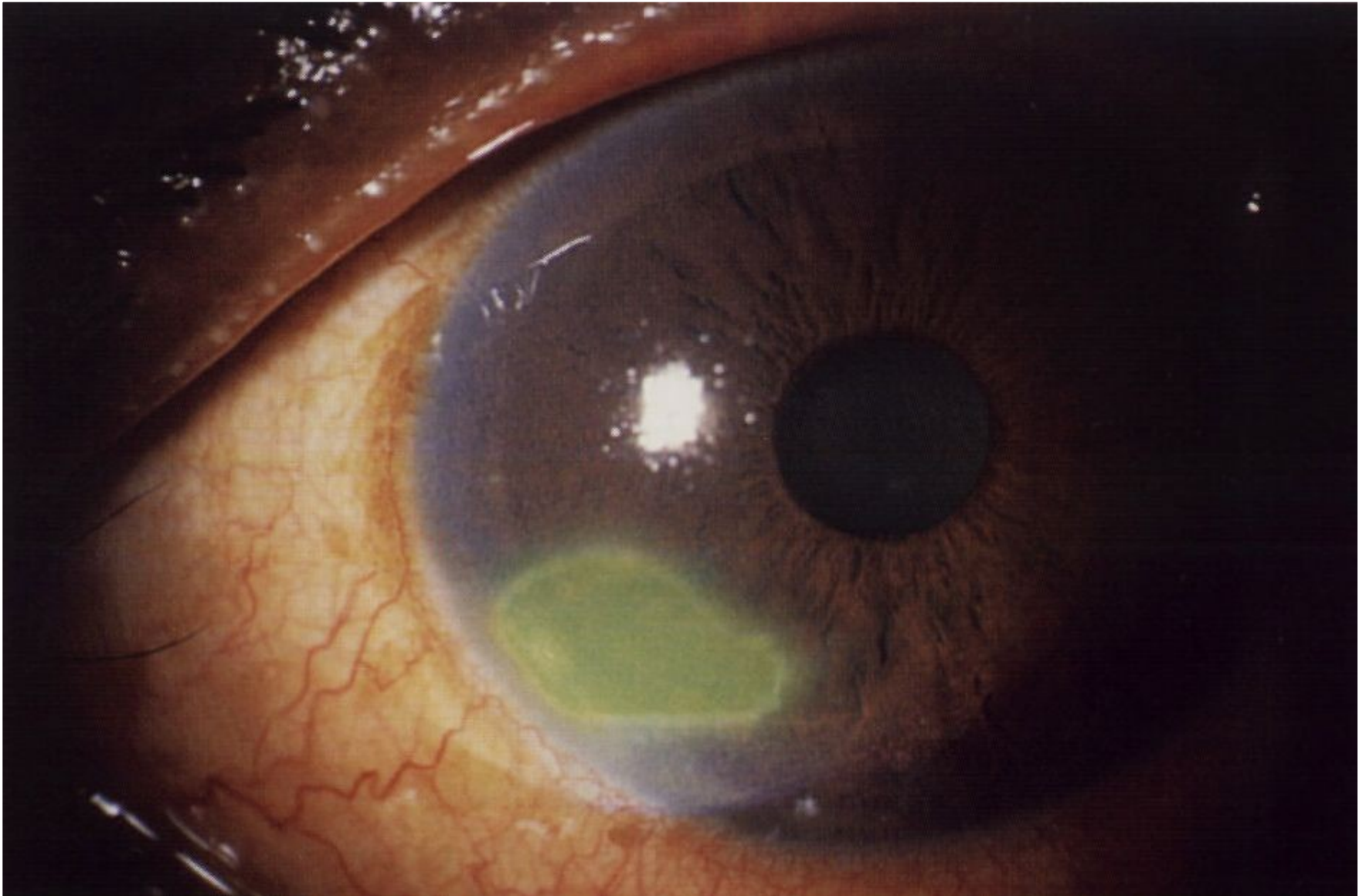
Synechia posterior



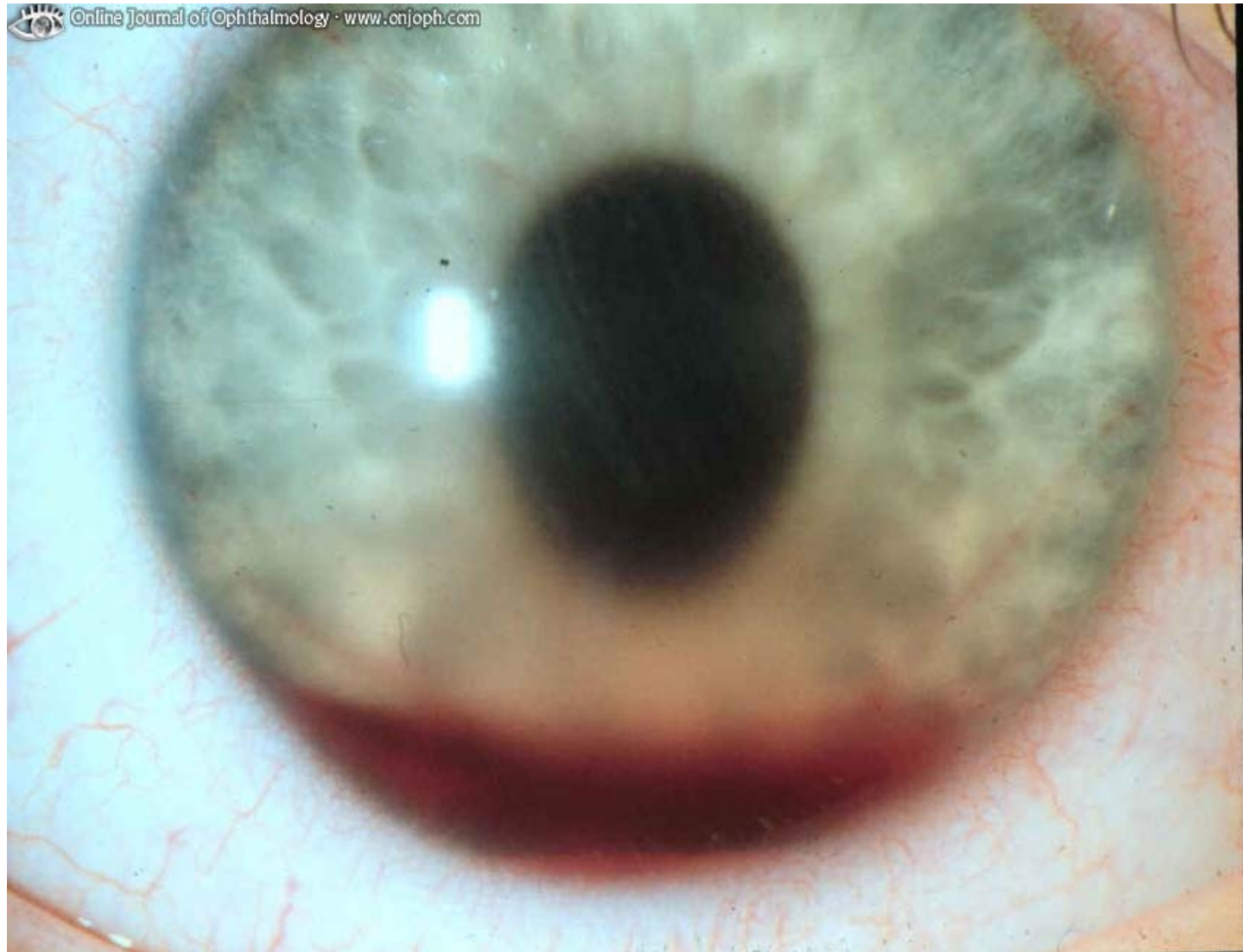
Sunconjunctival haemorrhage



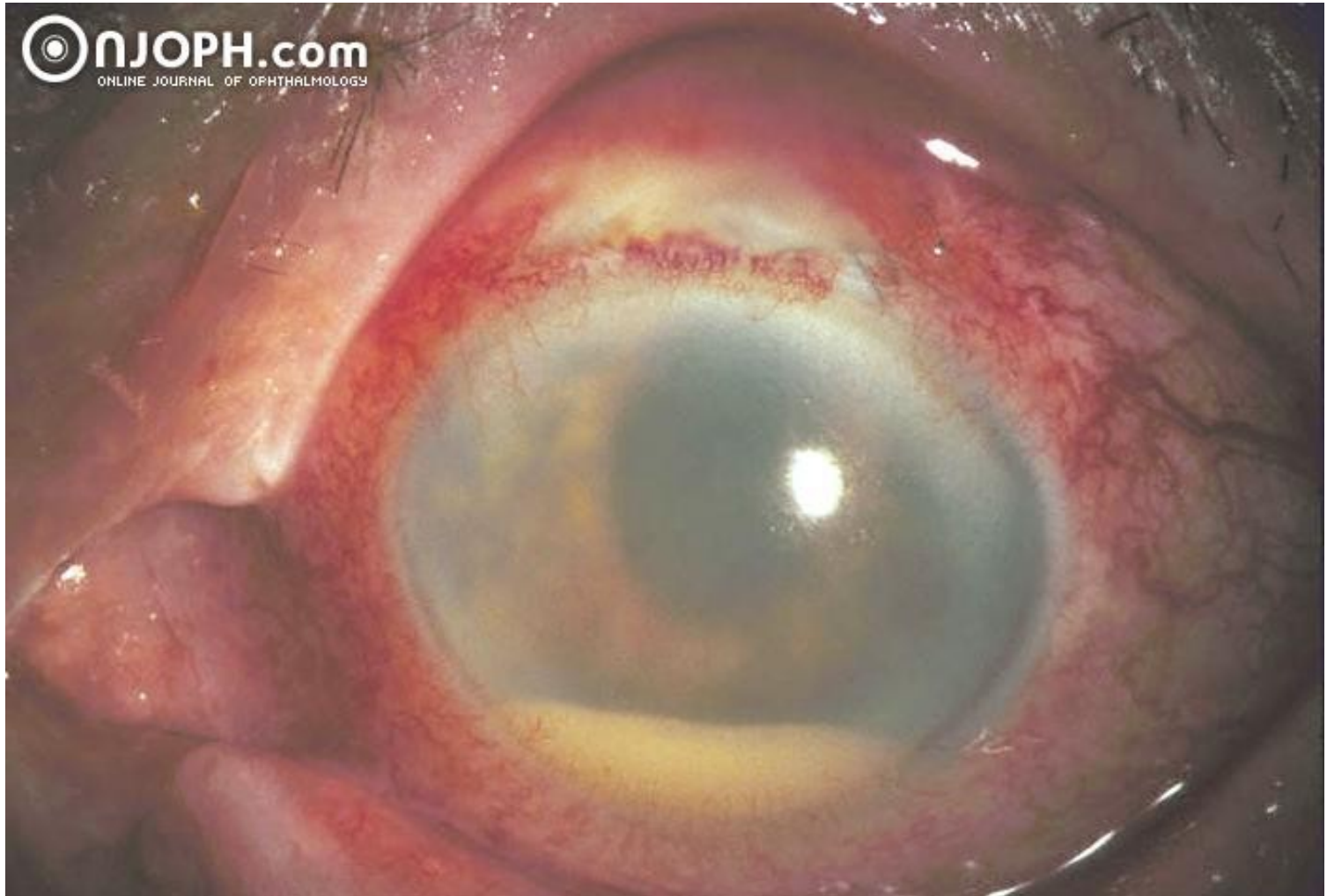Corneal abrasion



Hyphema

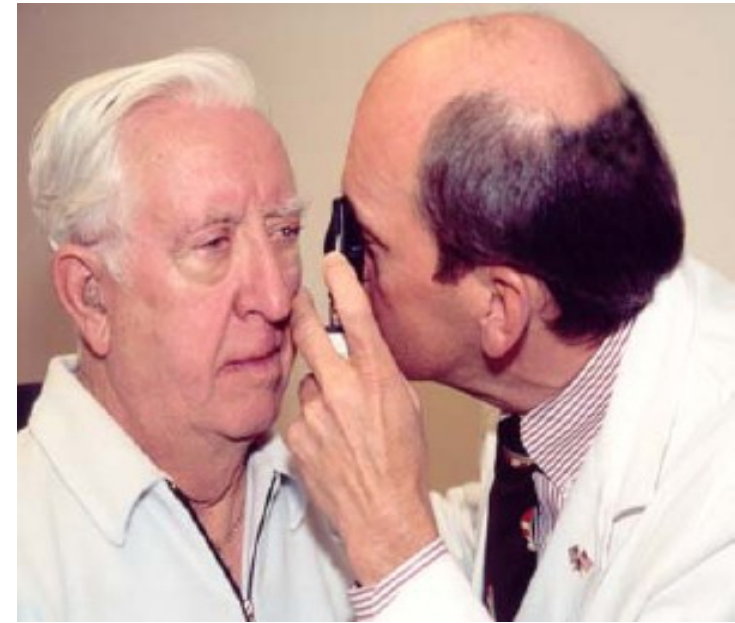


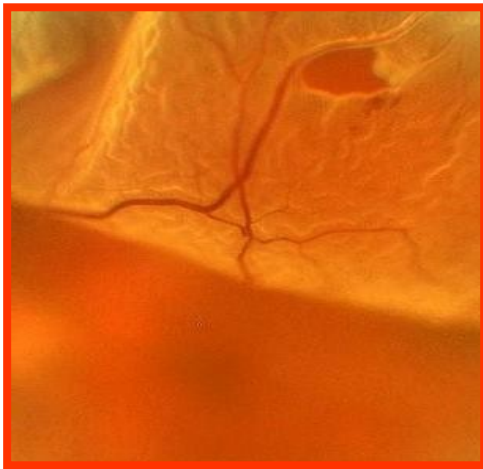
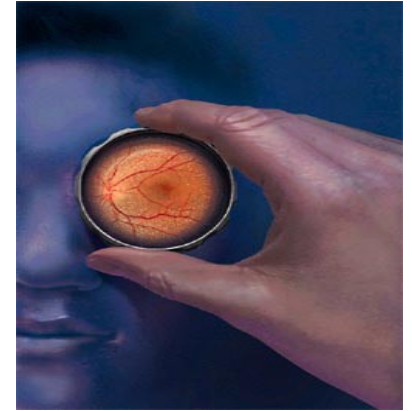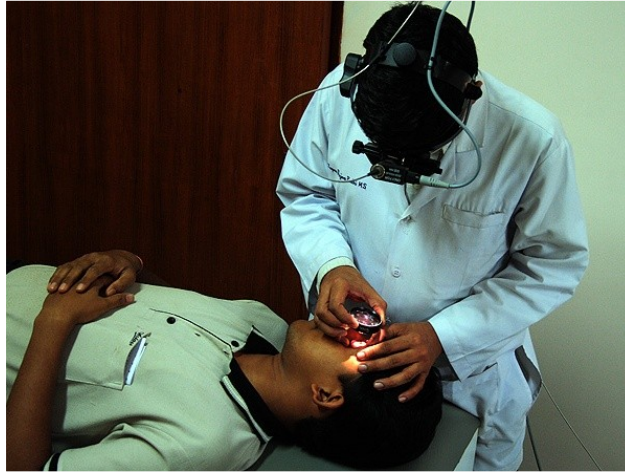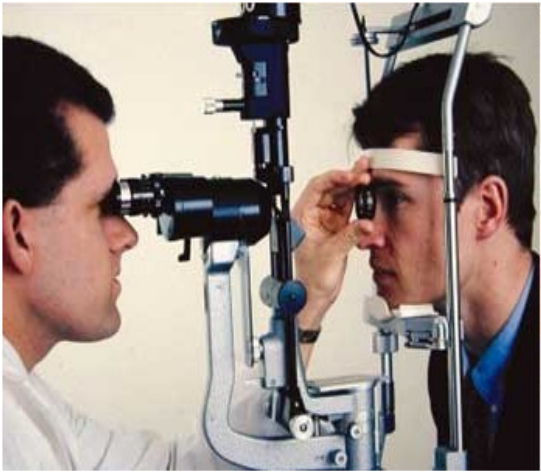Hypopyon



Examination of fundus

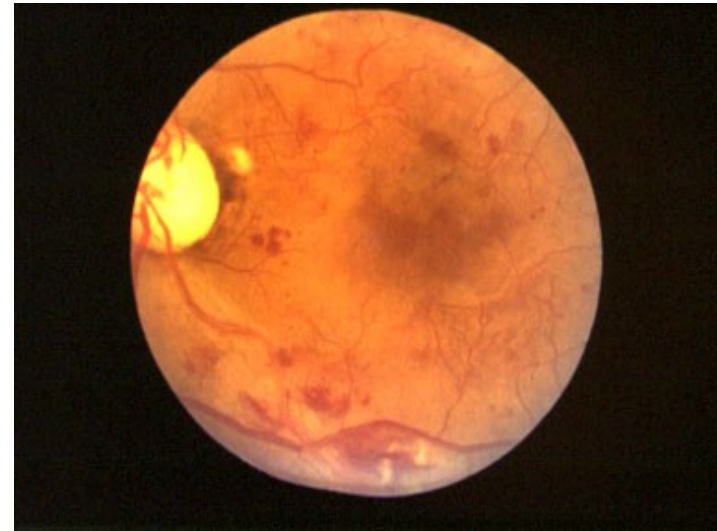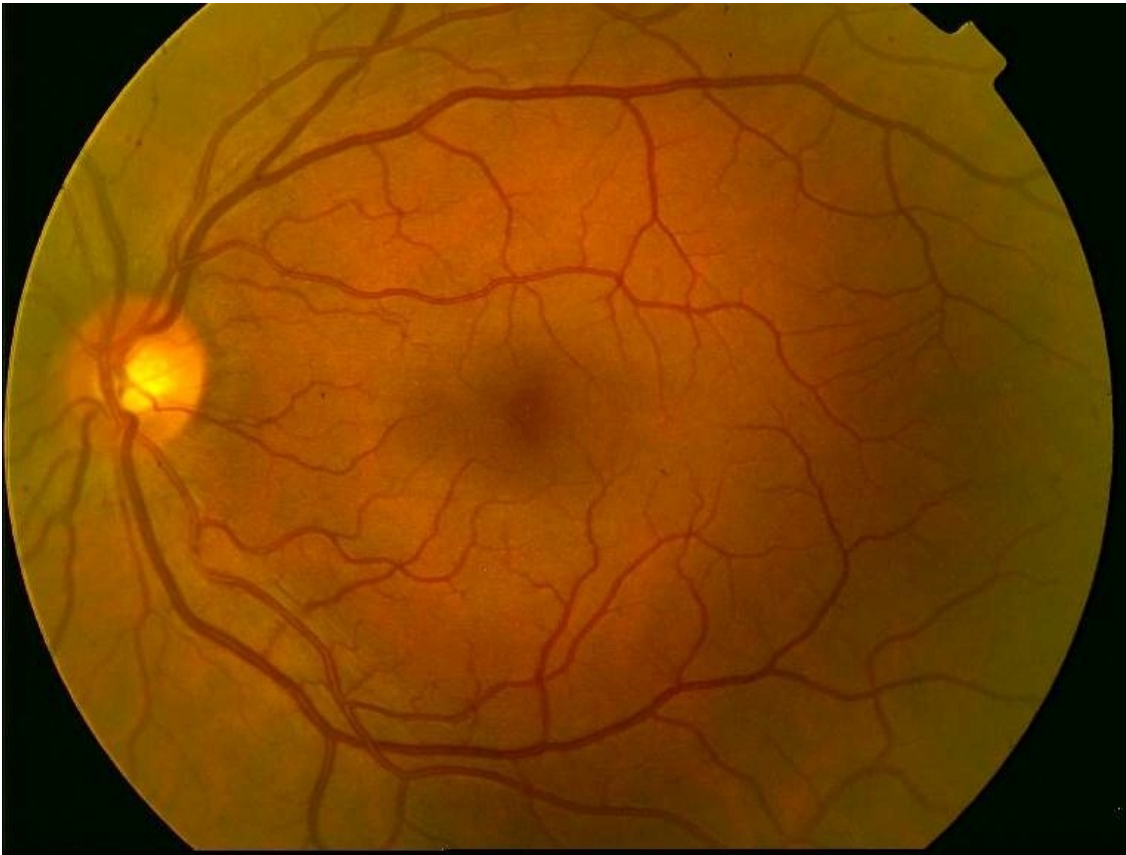
- **Ophthalmoscopy** - direct (no stereopsis, worse for periphery)
- indirect
- **Slit lamp biomicroscopy**
(high power convex lens, the image is vertically inverted and laterally reversed)
- **Mydriasis is necessary !**





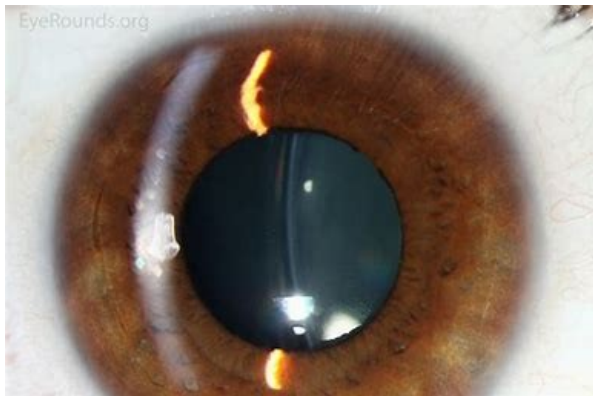Features	Direct Ophthalmoscopy	Inverted Ophthalmoscopy (45°)	Field Ophthalmoscopy
Field	18 degrees	180 degrees	18 degrees
Examiner's distance from patient	10 cm and patient's eye retinal focus	same length	same length
Form of the fundus image	Real	Real	Real
Side of the fundus	Inferior	Optical	Superior

Ocular fundus



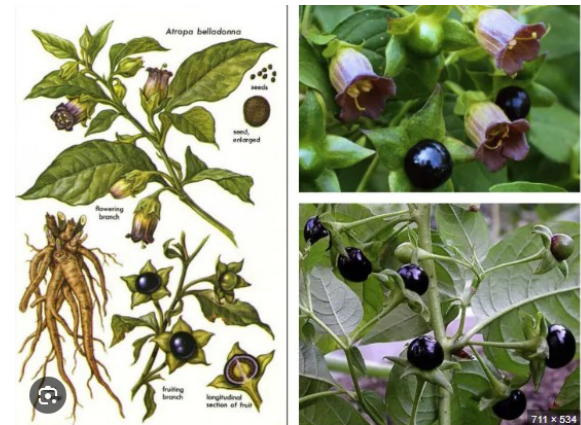
Status of the lens

- Phakic eye (own lens)
- Pseudophakic eye (arteficial intraocular lens)
- Aphakic eye (without any lens)



Farmacology

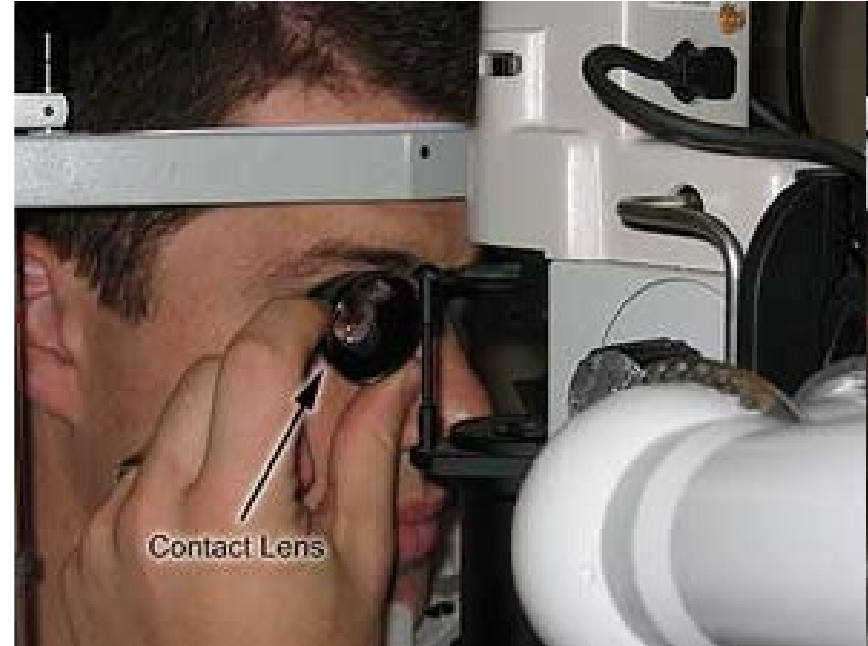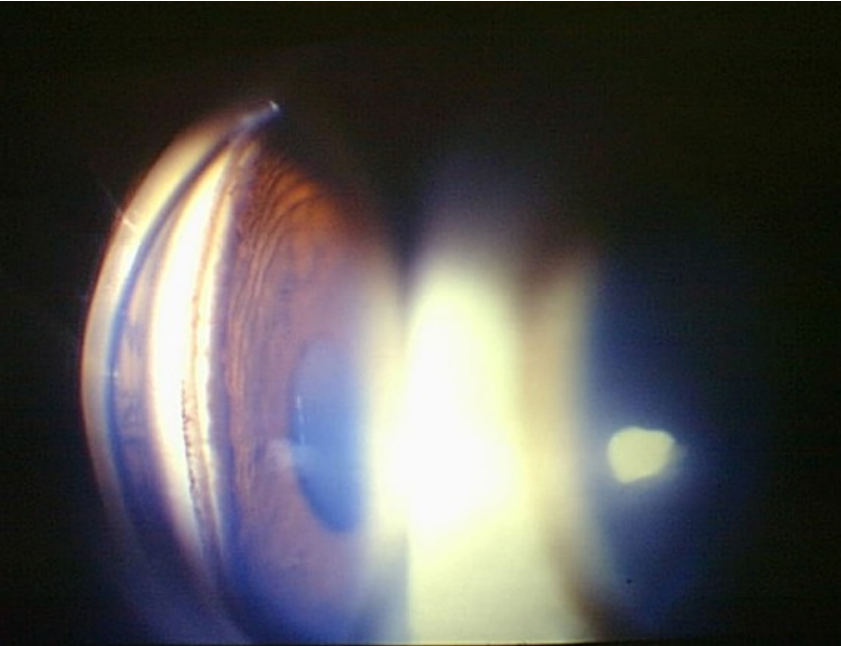
- Pilocarpin - parasympatomimetics
- Atropin – parasympatolyticum (anticholinergicum)
- Scopolamin, tropikamid



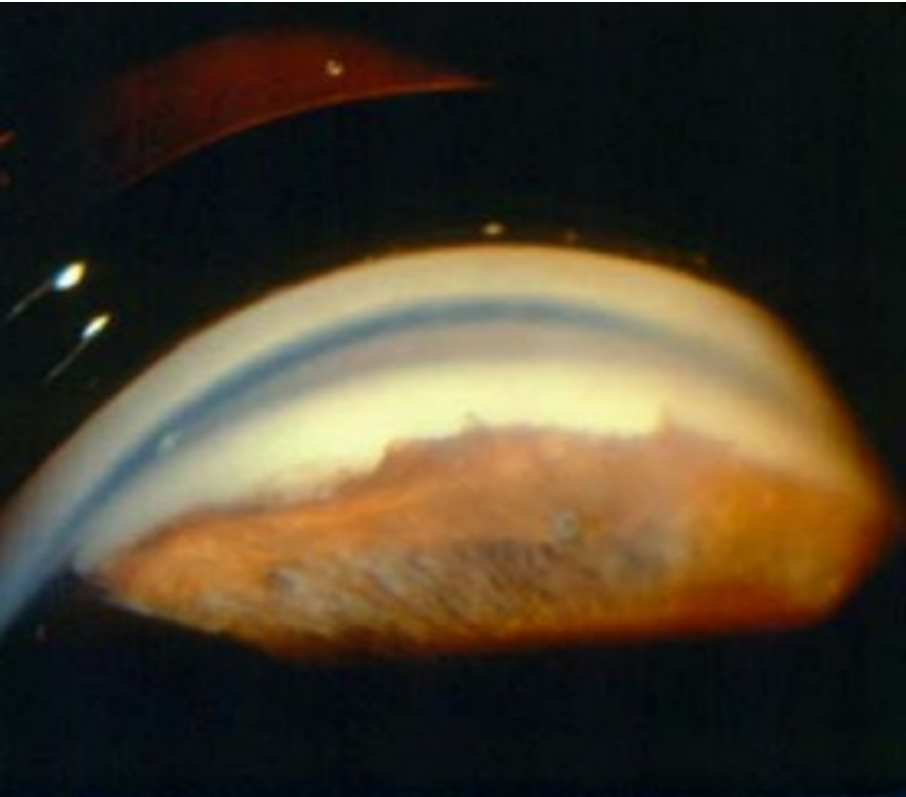Atropa belladonna - Deadly Nightshade, Atropa Belladonna - Quinta dos Ouriques

Special examination techniques

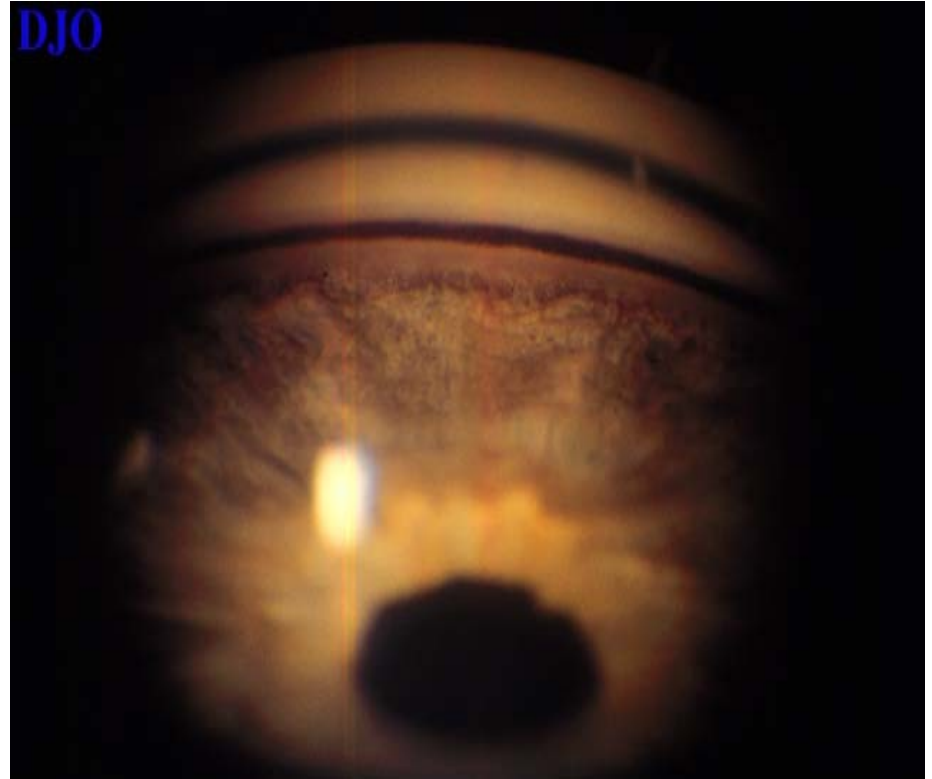
Gonioscopy

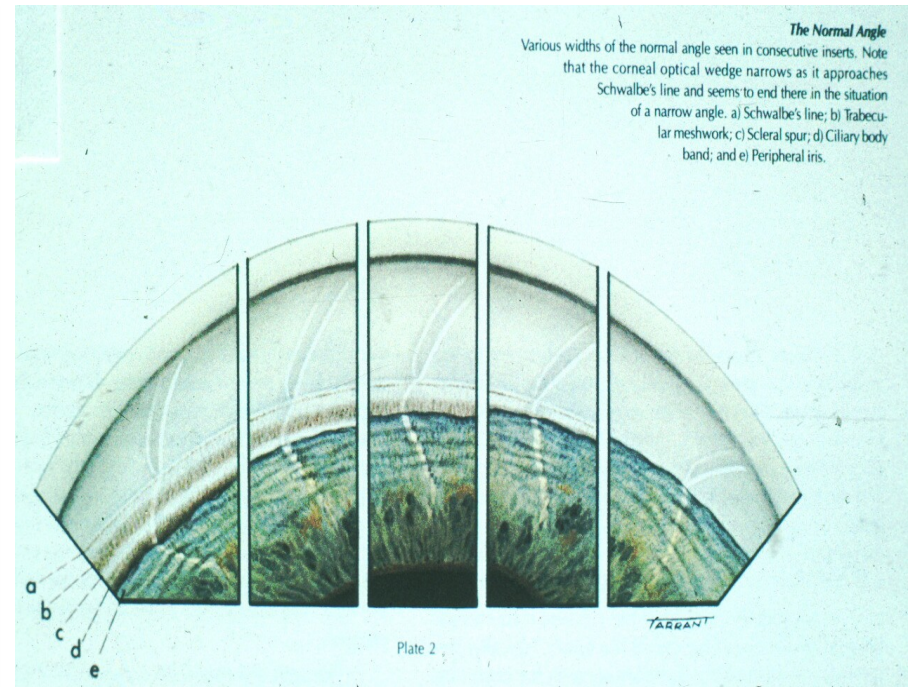
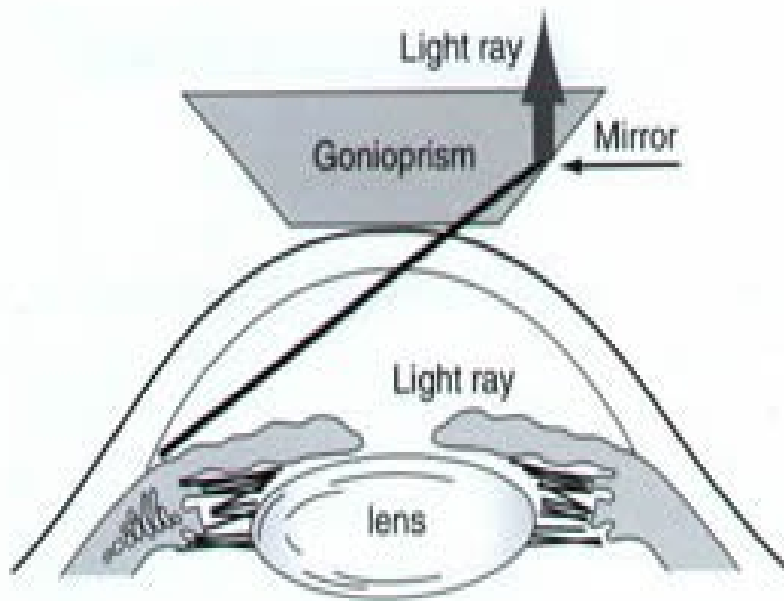


- Gonio lens (mirrors)
- Angle structures
- Fundus examination



DJO



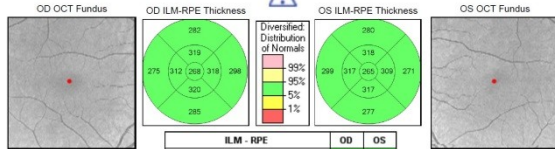
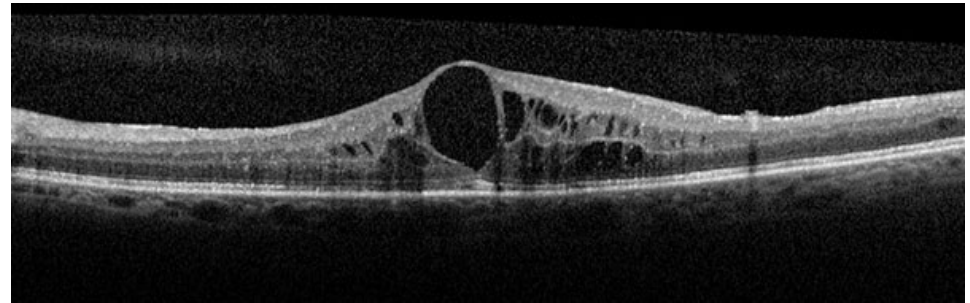
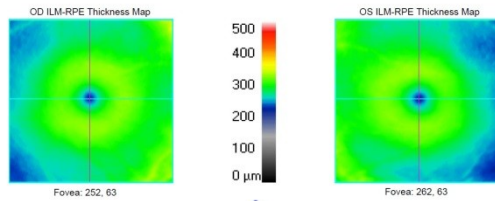


Optical coherence tomography

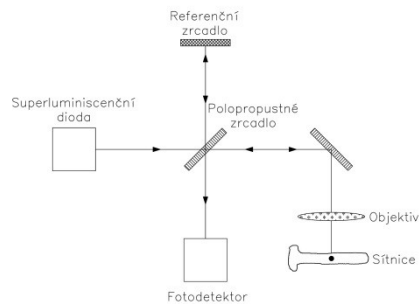
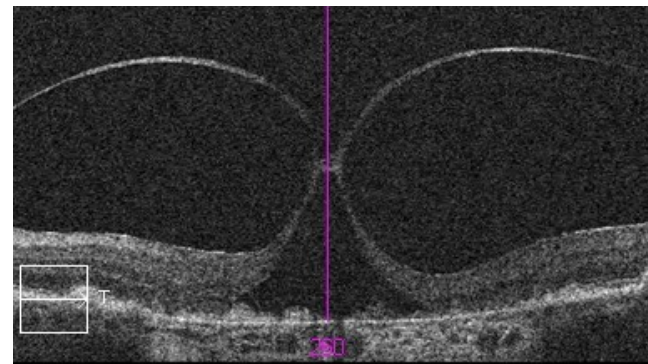
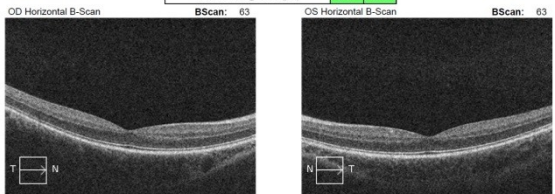
Name: **XXXXXXXXXX** OD OS
 ID: **XXXXXXXXXX** Exam Date: **XXXXXXXXXX** **XXXXXXXXXX** CZMI
 DOB: **XXXXXXXXXX** Exam Time: **XXXXXXXXXX**
 Gender: Unknown Serial Number: 4000-11302 4000-11302
 Technician: Operator, Cirrus Signal Strength: 9/10 9/10



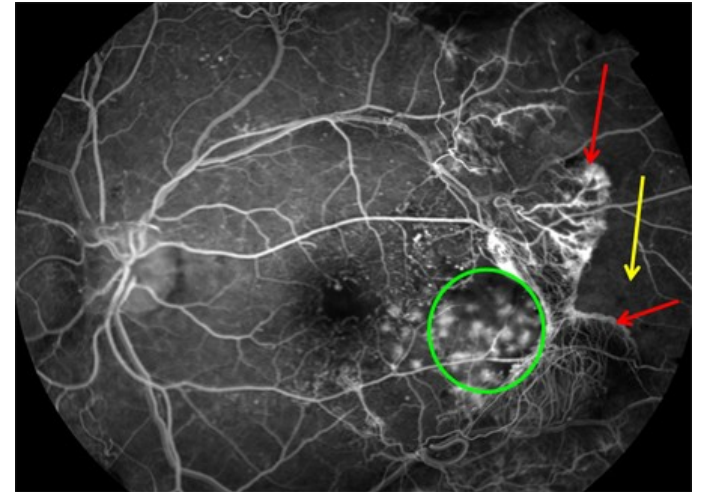
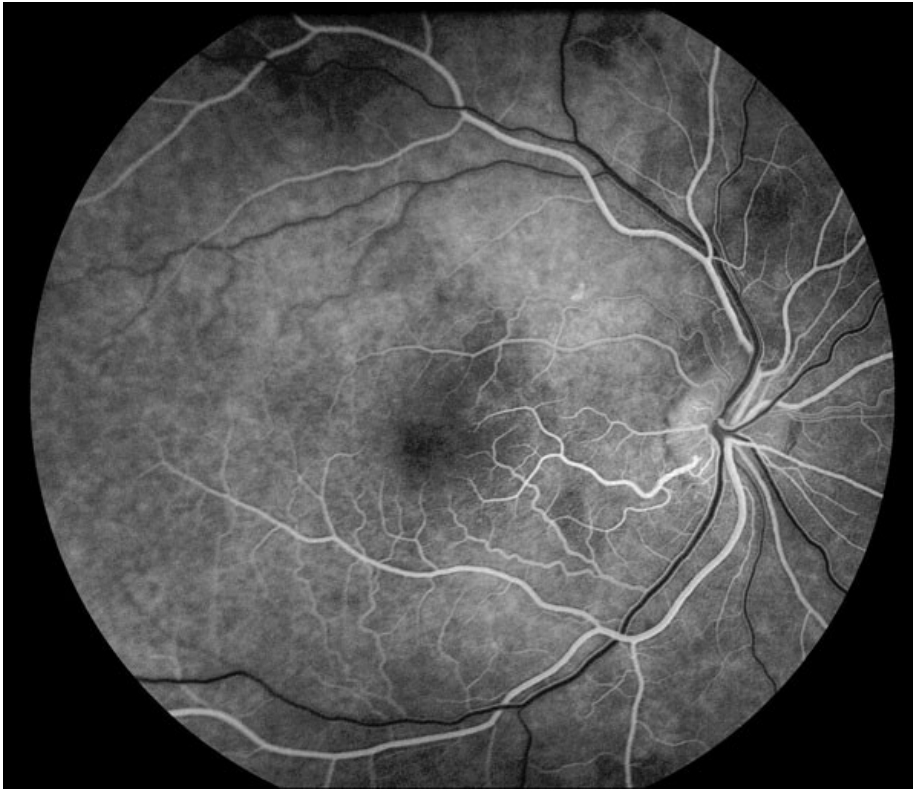
Macula Thickness OU: Macular Cube 512x128 OD OS



ILM - RPE		OD	OS
Thickness Central Subfield (µm)		258	265
Volume Cube (mm³)		10.4	10.3
Thickness Avg Cube (µm)		283	296



Fluorescein angiography

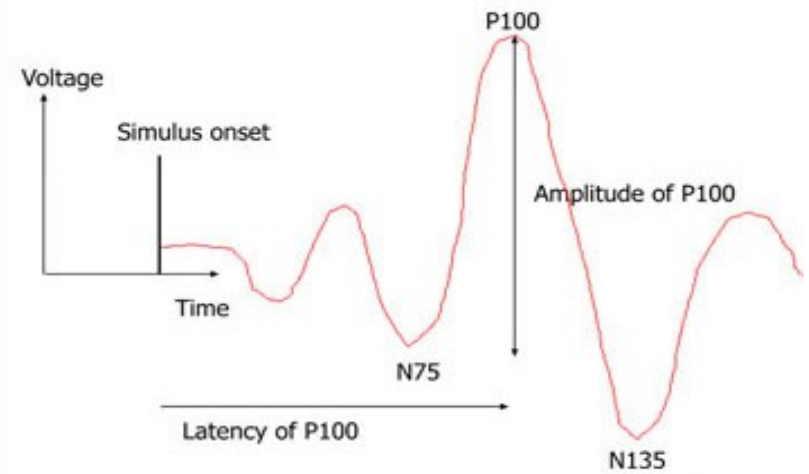
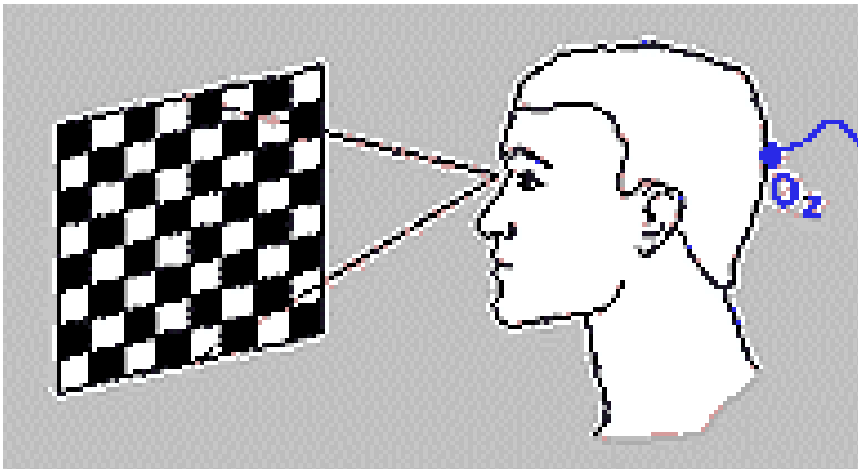


Electrophysical tests

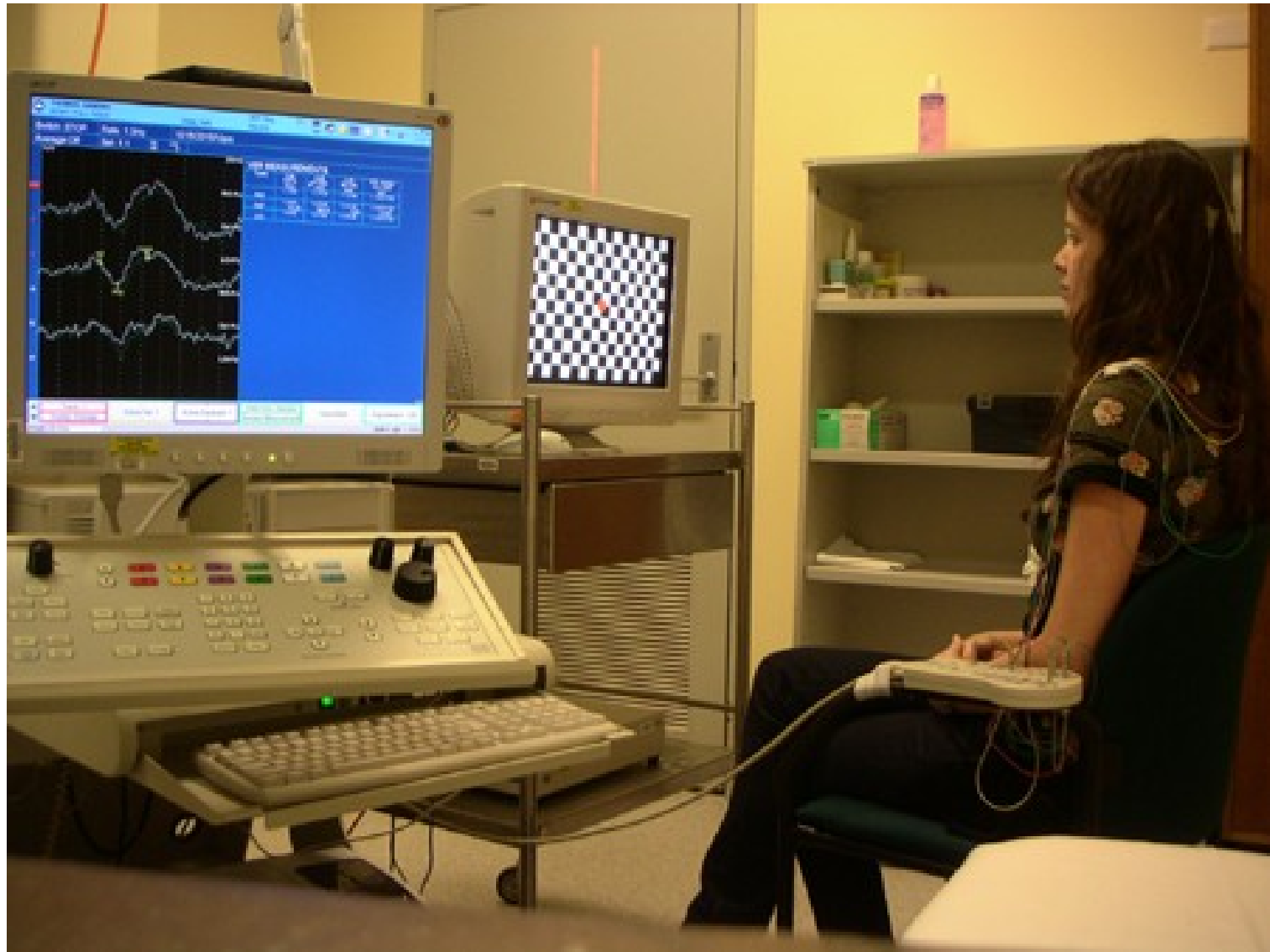- **ERG (electroretinography)**
diagnosis of functional defects of retina
- Record of an action potential produced by the retina when it is stimulated by light

- **VEP (visual evoked potential)**
-diagnosis of functional defects of visual pathways
- Record of electrical activity of the visual cortex created by stimulation of the retina

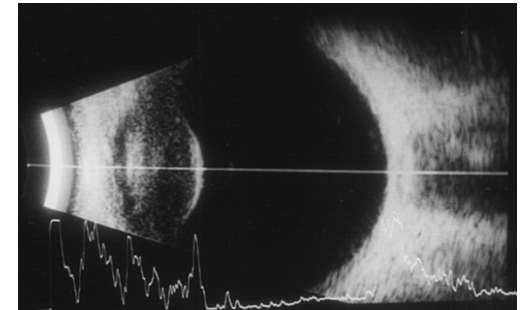
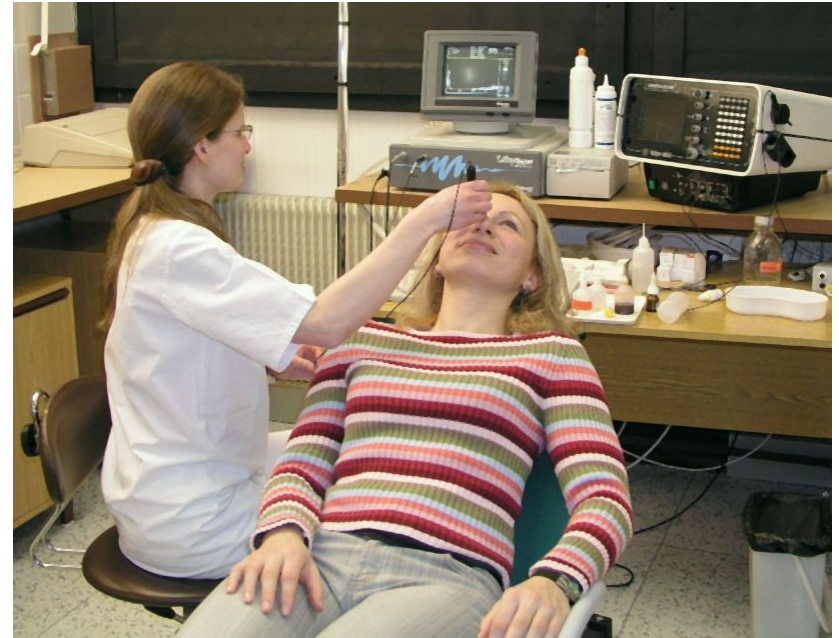Electrophysical tests



Electrophysical tests

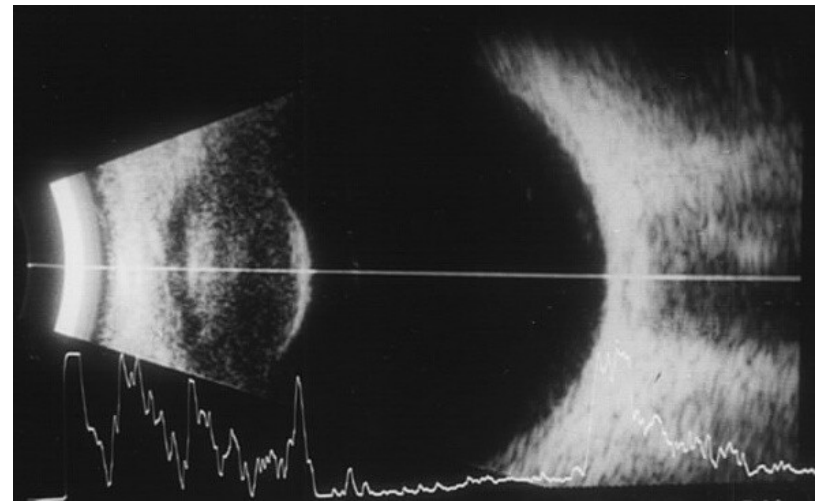
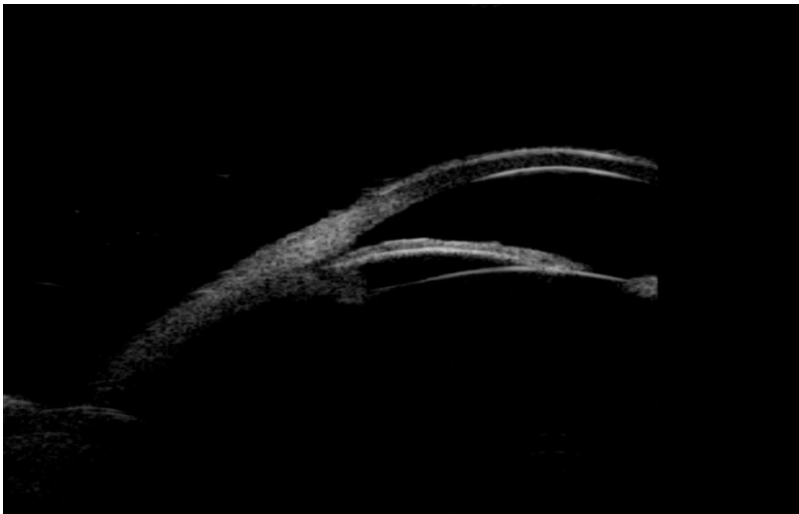


Ultrasound



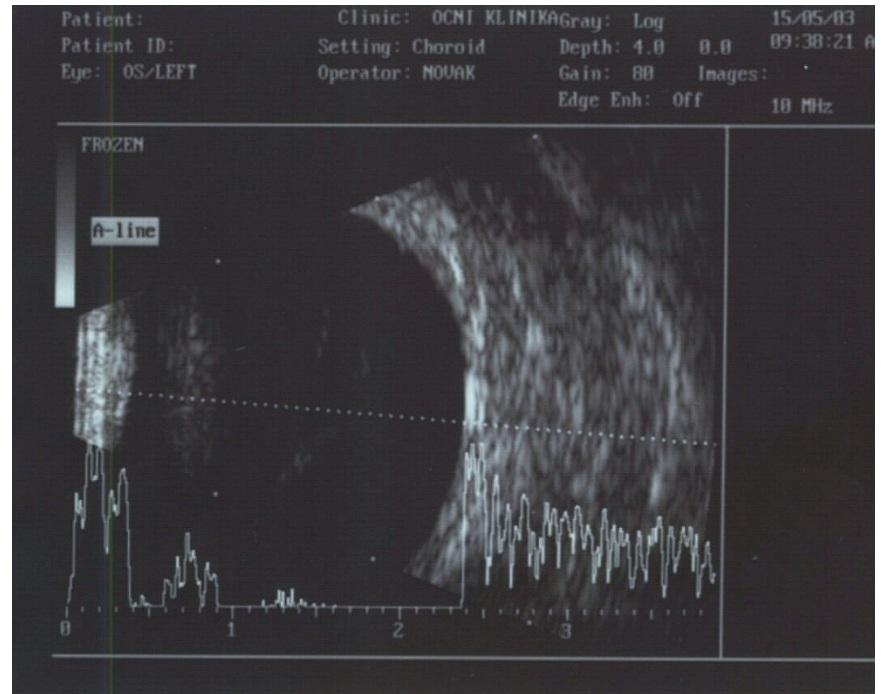
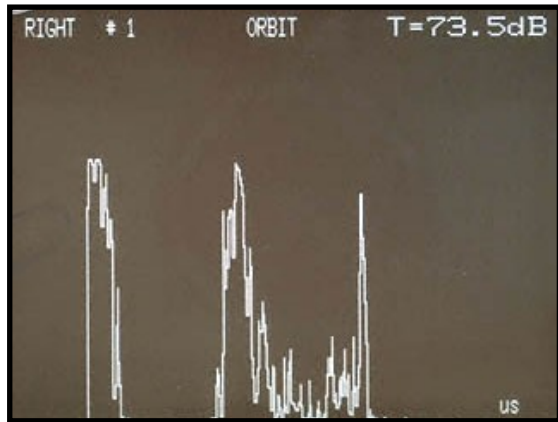
Ultrasound

- Non transparent optical media
- UBM- high frequency ultrasound – imaging of anterior segment



Ultrasound

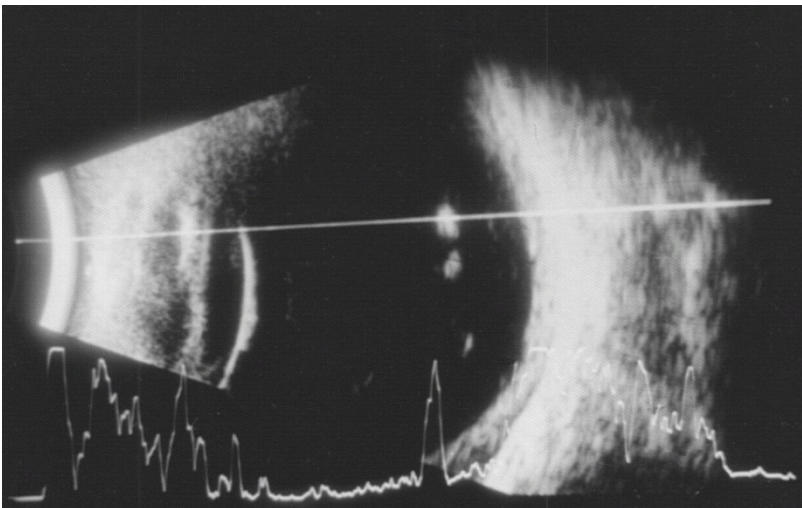
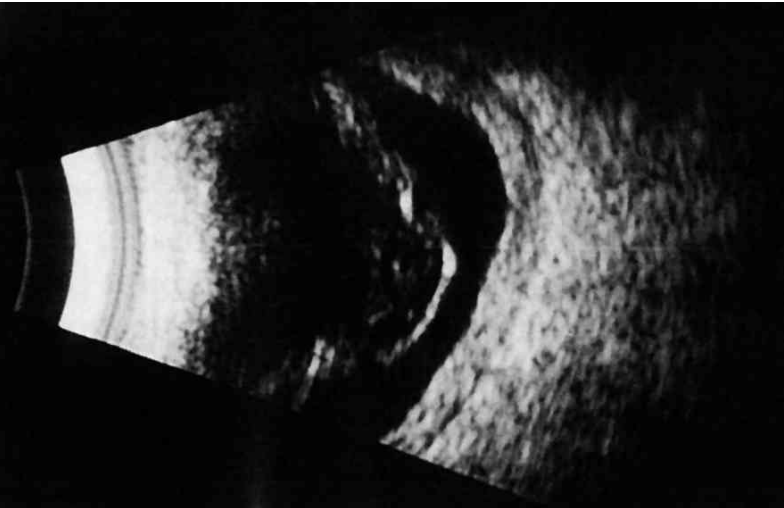
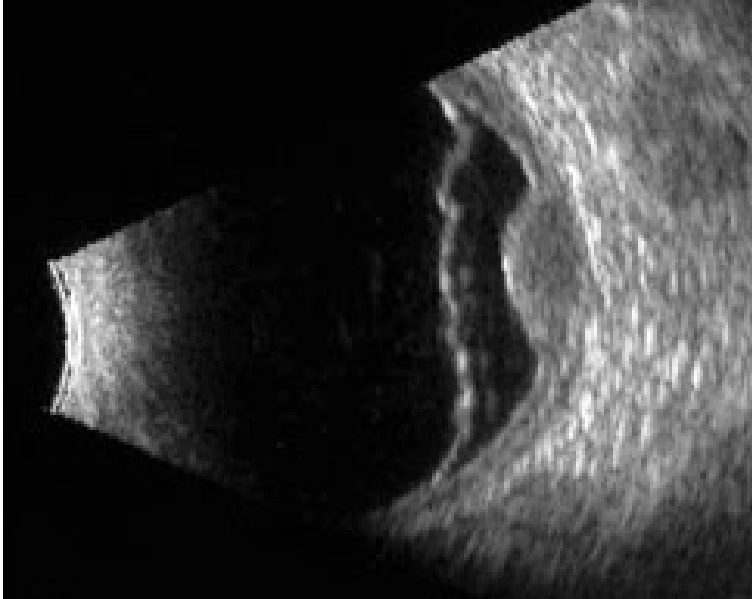
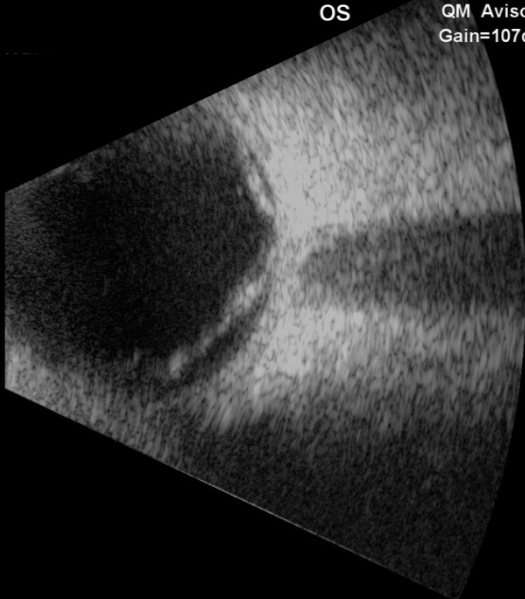- **A scan (biometry)**
- **B scan**




Ultrasound

OS

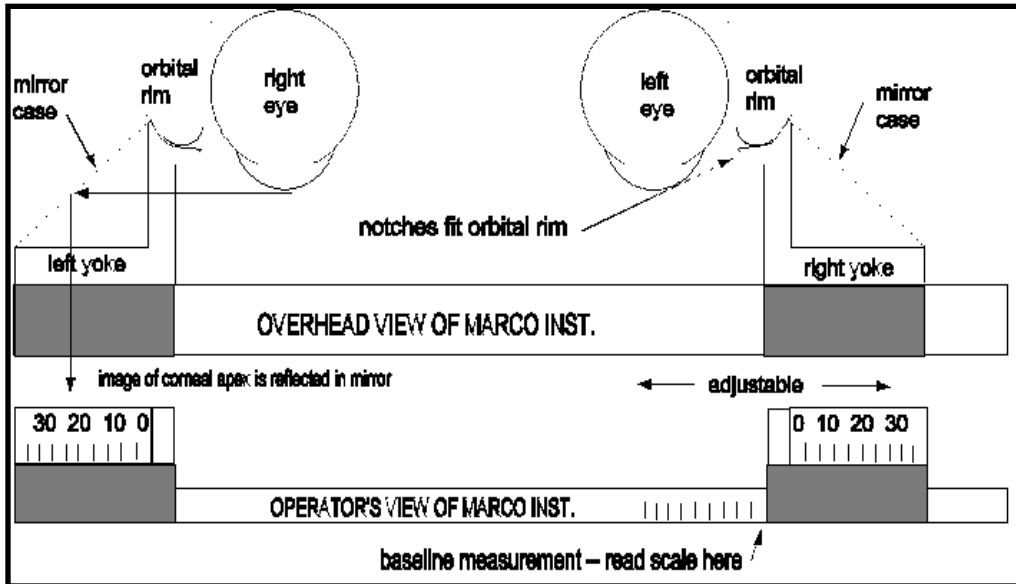


QM Aviso S V:3.0.0
Gain=107dB Dyn=60dB Tgc=20dB



Color vision – HUE test



Hertl exoftalmometry



Děkuji za pozornost!

