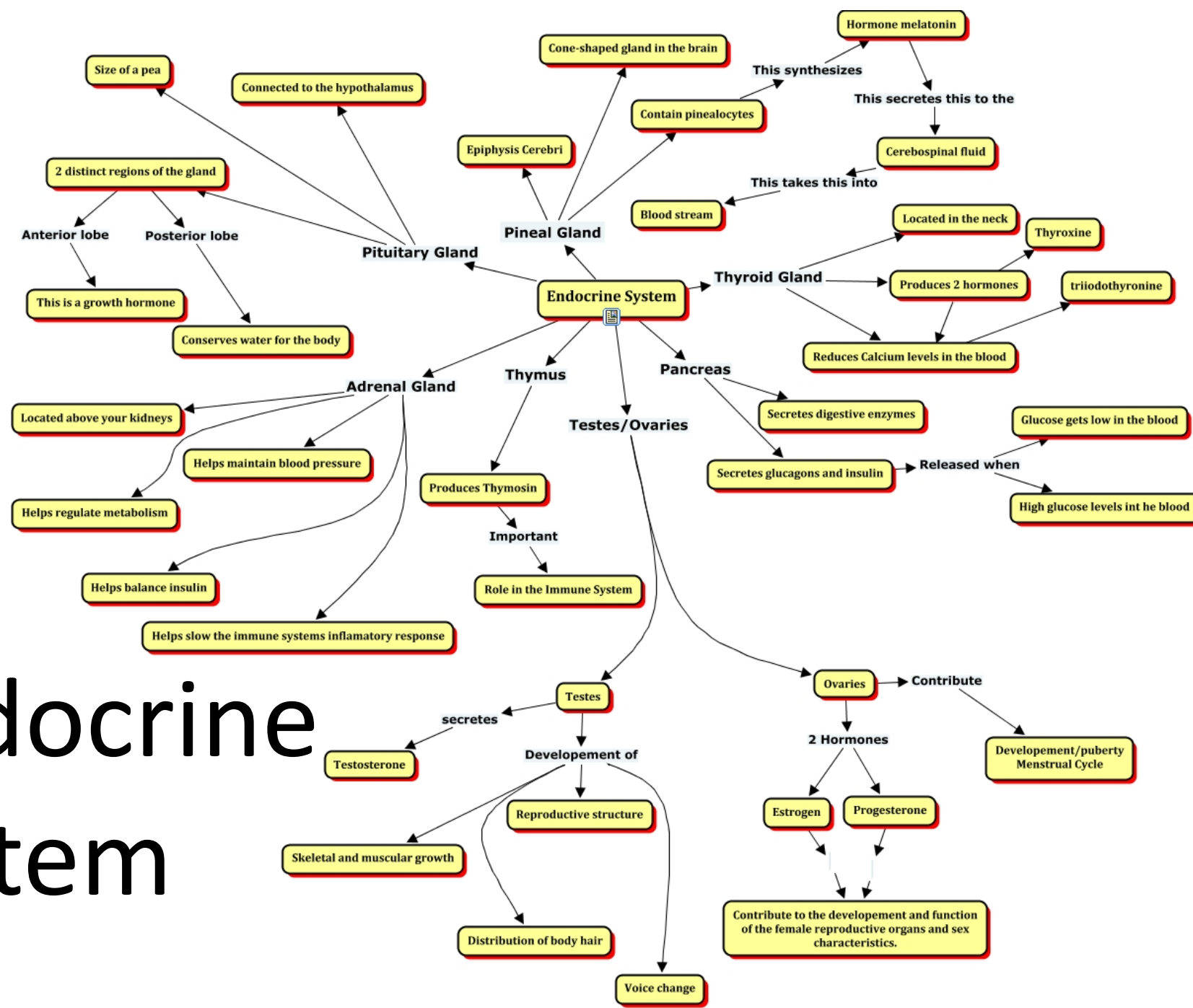
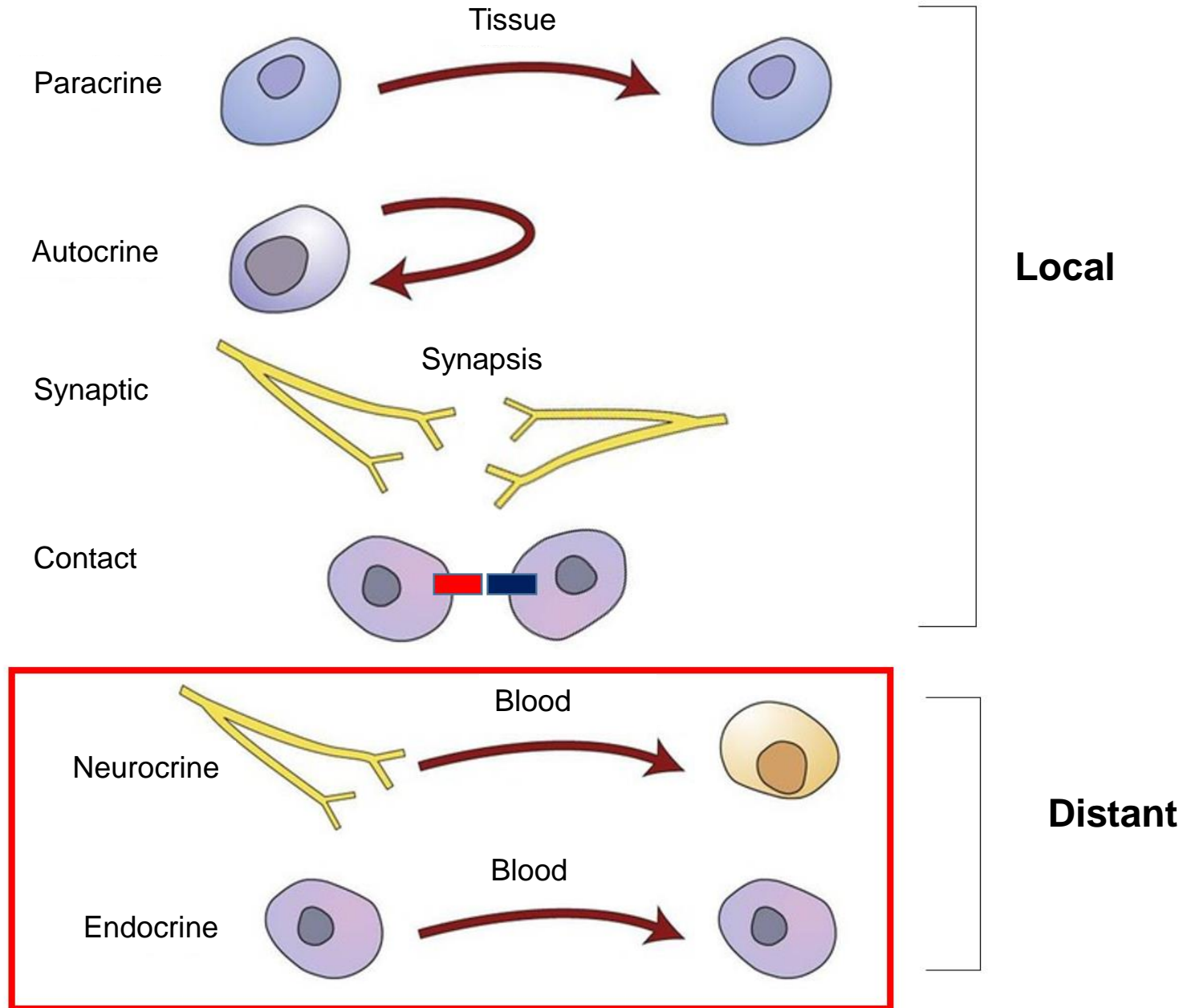


Endocrine system

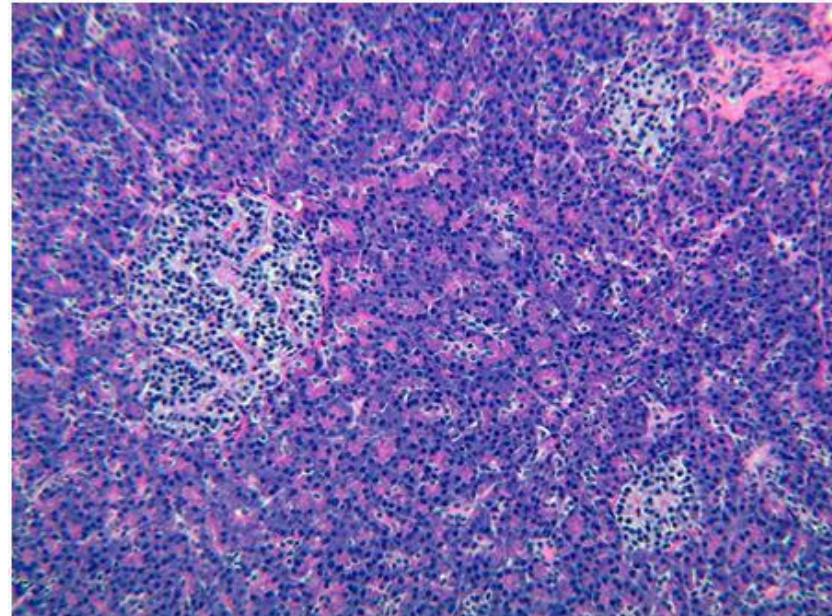
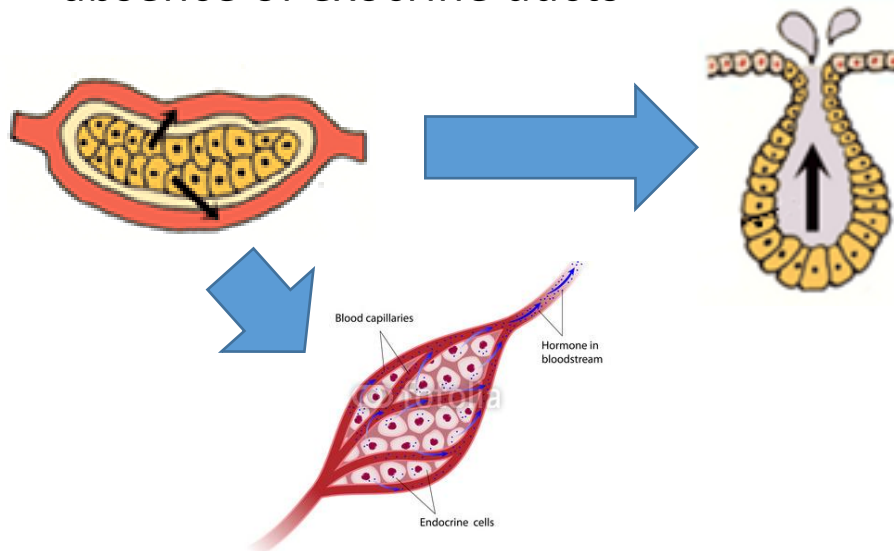


INTERCELLULAR COMMUNICATIONS



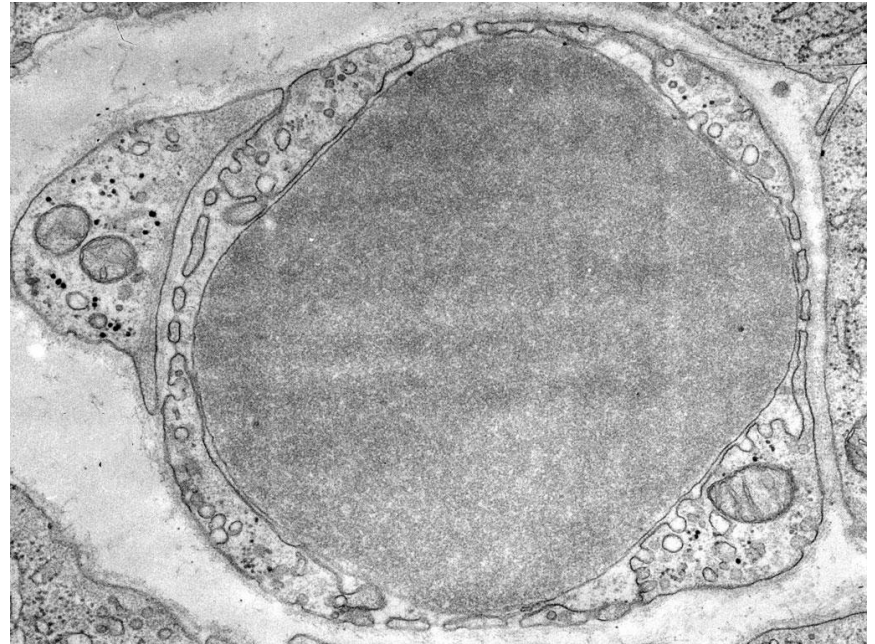
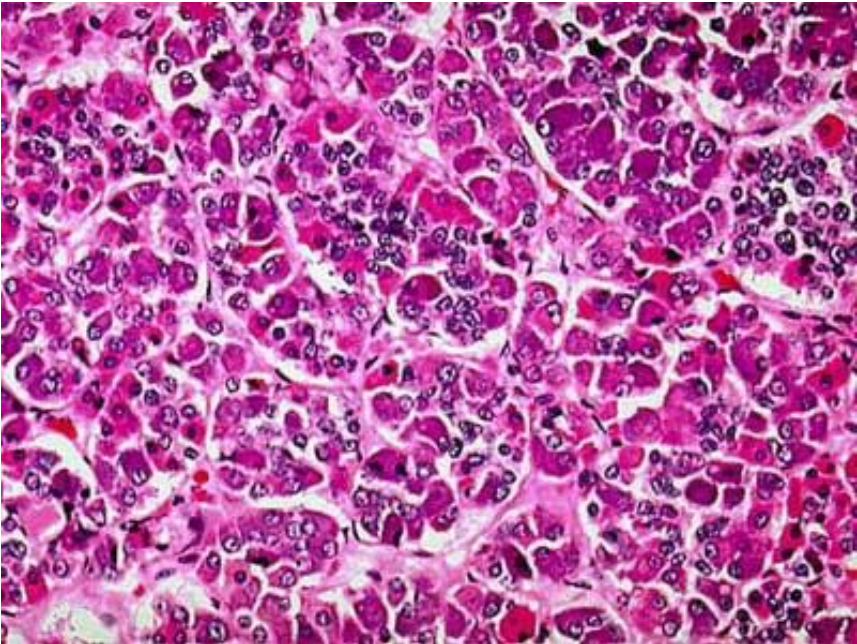
GENERAL PROPERTIES OF ENDOCRINE ORGANS

- **Endocrine organs** (e.g. pituitary, thyroid, parathyroid, adrenal)
- **Endocrine tissue within other organs**
(pancreas, gonads, kidneys, placenta)
- **Isolated endocrine cells** (DNES, APUD)
- **Neuroendocrine cells**
- **Common developmental scheme**
 - invagination of epithelial layer
 - contact with original tissue lost during development
 - absence of exocrine ducts



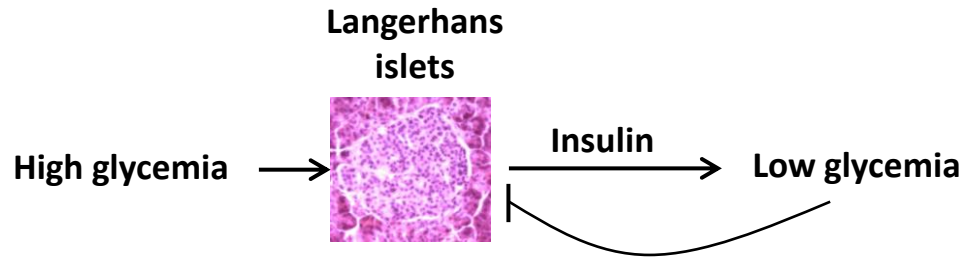
GENERAL PROPERTIES OF ENDOCRINE ORGANS

- C.t. capsule + septs
- **Trabecules** of glandular epithelium or **follicles** or **clusters** of glandular cells
- **Capillary network**
 - Fenestrated capillaries
 - Sinusoids

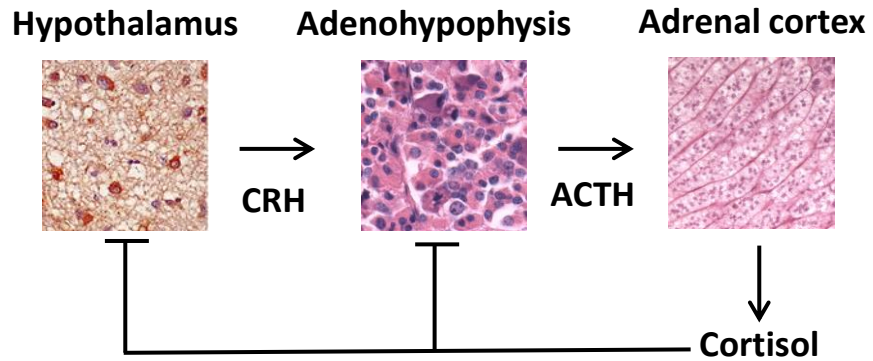


REGULATION OF HORMONE SECRETION

1. Negative feedback by change of metabolic state



2. Negative feedback by increased concentration of secreted hormone

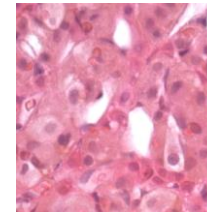


3. Nerve system – direct innervation

CNS (sympathicus)



Adrenal medulla

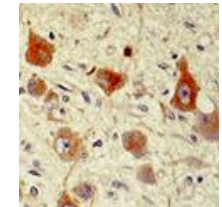


Adrenalin

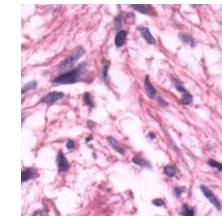
CNS



Hypothalamus



Neurohypophysis



ADH

GENERAL PROPERTIES OF HORMONES

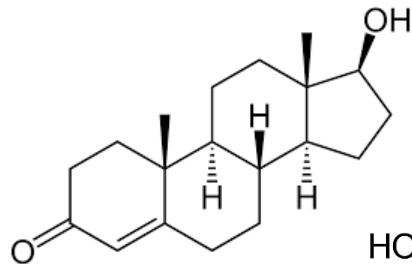
- hormones are chemical messengers delivered by bloodstream to target cells and tissues
- chemical nature of hormone determines its function

- classification
 - **water soluble**
 - **water insoluble**

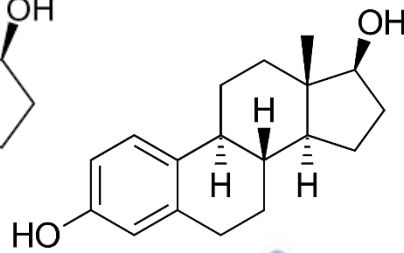
 - **surface receptors**
 - **nuclear receptors**

GENERAL PROPERTIES OF HORMONES

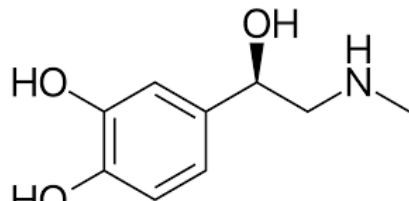
- **steroids** – hydrophobic, intracytoplasmic or nuclear receptors (sex hormones, corticosteroids)
- **proteins and polypeptides** – hydrophilic, plasma membrane receptors (insulin, pituitary hormones, PTH, ...)
- **aminoacids** and their amine derivatives (adrenalin, noradrenalin, thyroxin)



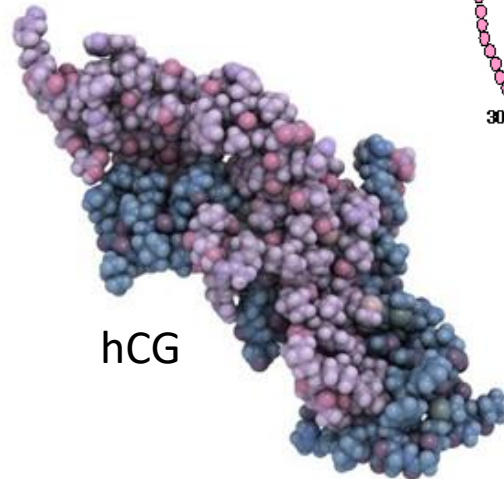
Testosterone



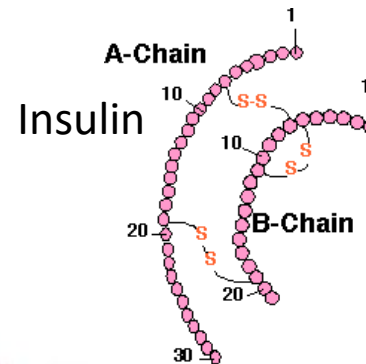
Estradiol



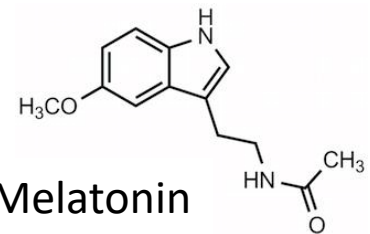Adrenalin



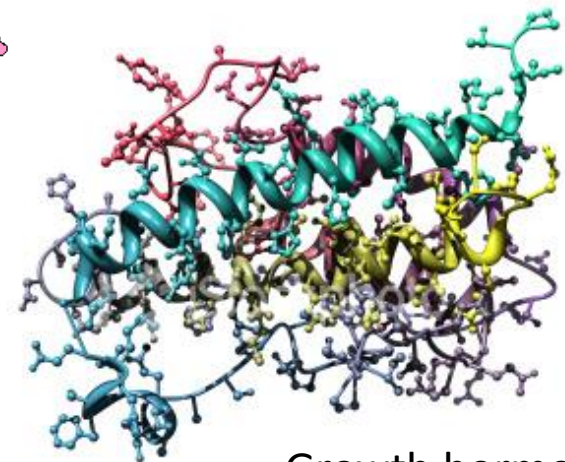
hCG



Insulin

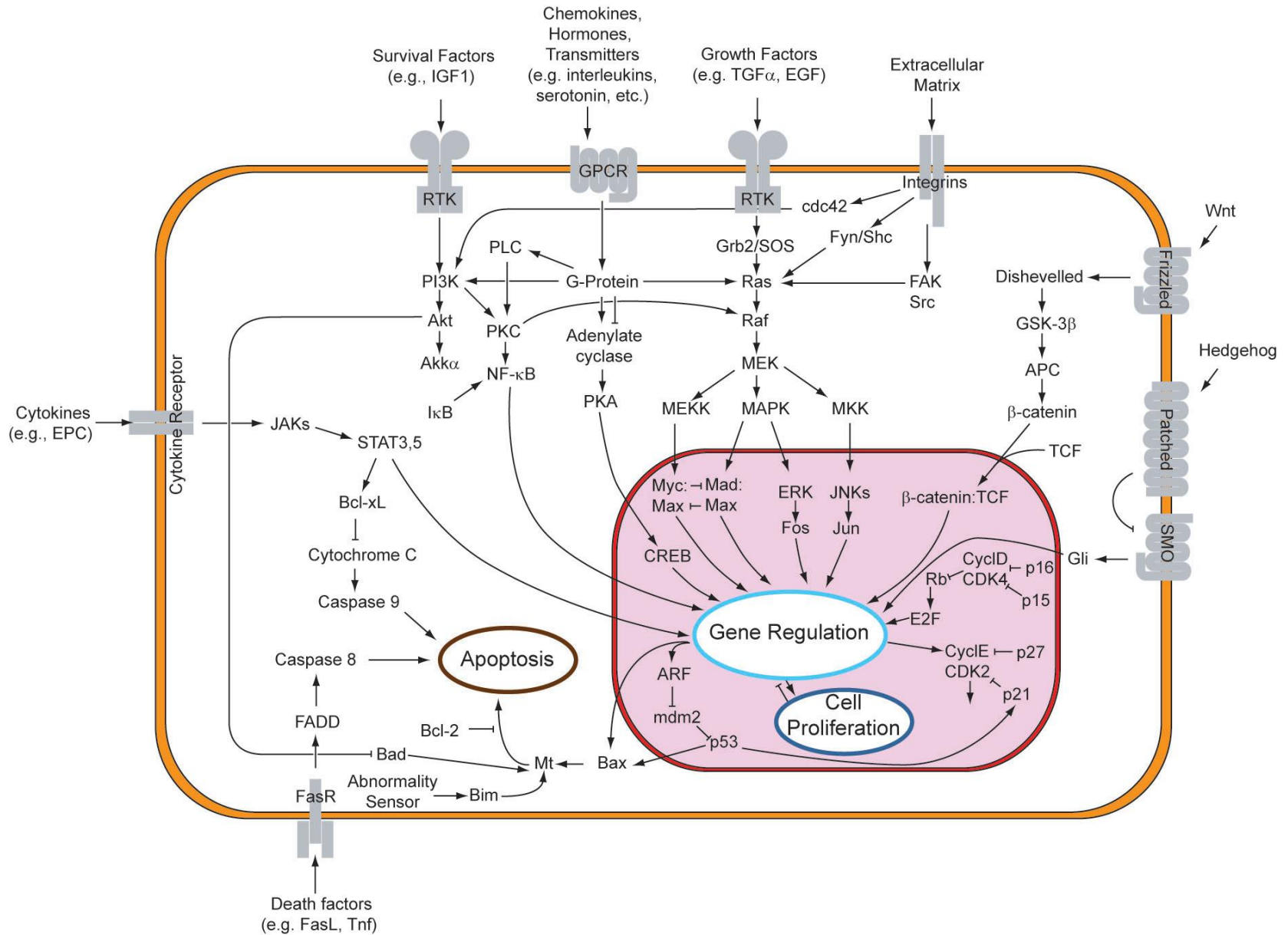


Melatonin

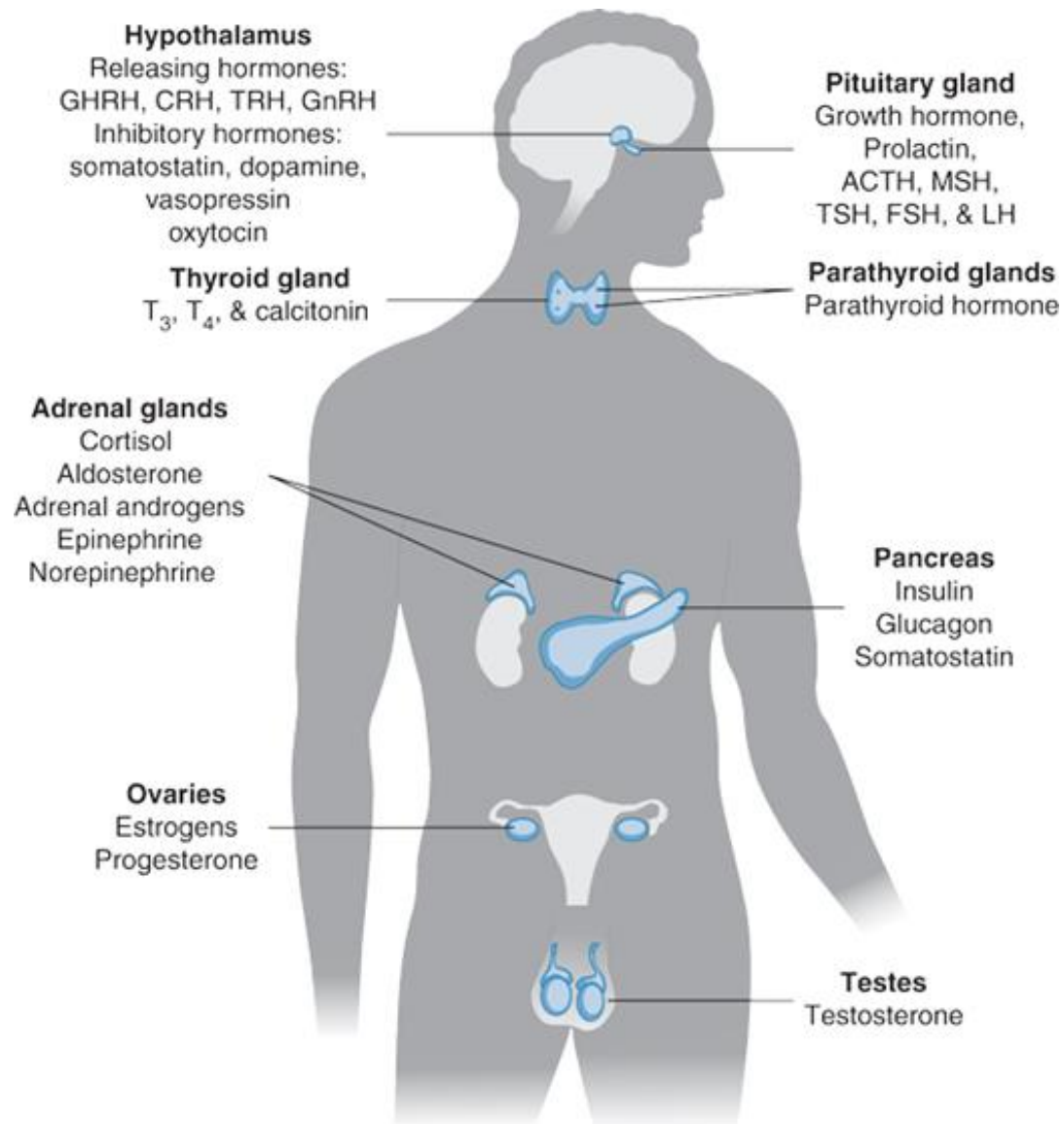


Growth hormone

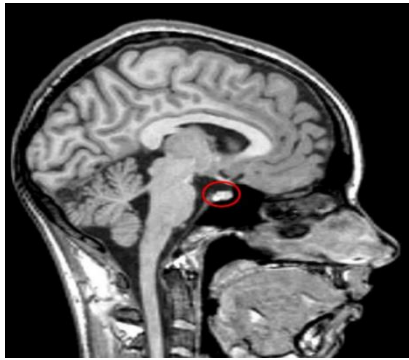GENERAL PROPERTIES OF HORMONES



ENDOCRINE GLANDS



PITUITARY GLAND (GL. PITUITARIA)



Corpus callosum

Hypothalamus

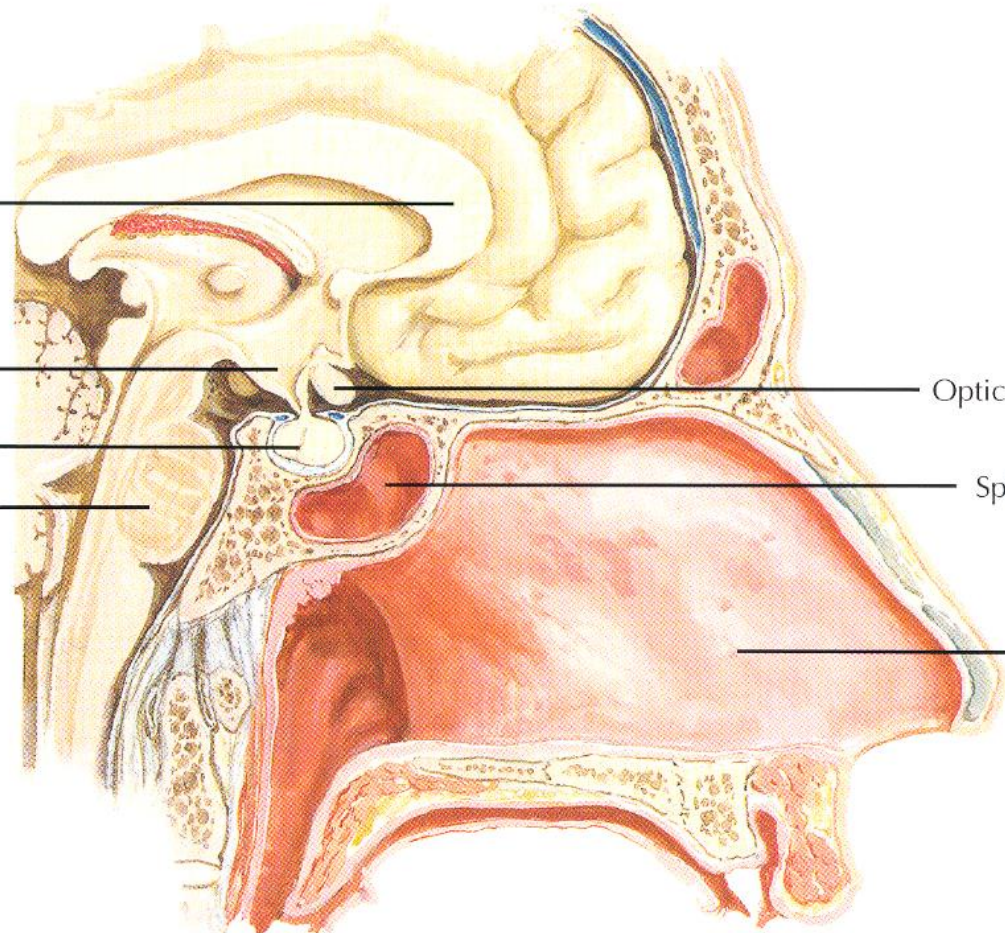
Pituitary gland

Brainstem (pons)

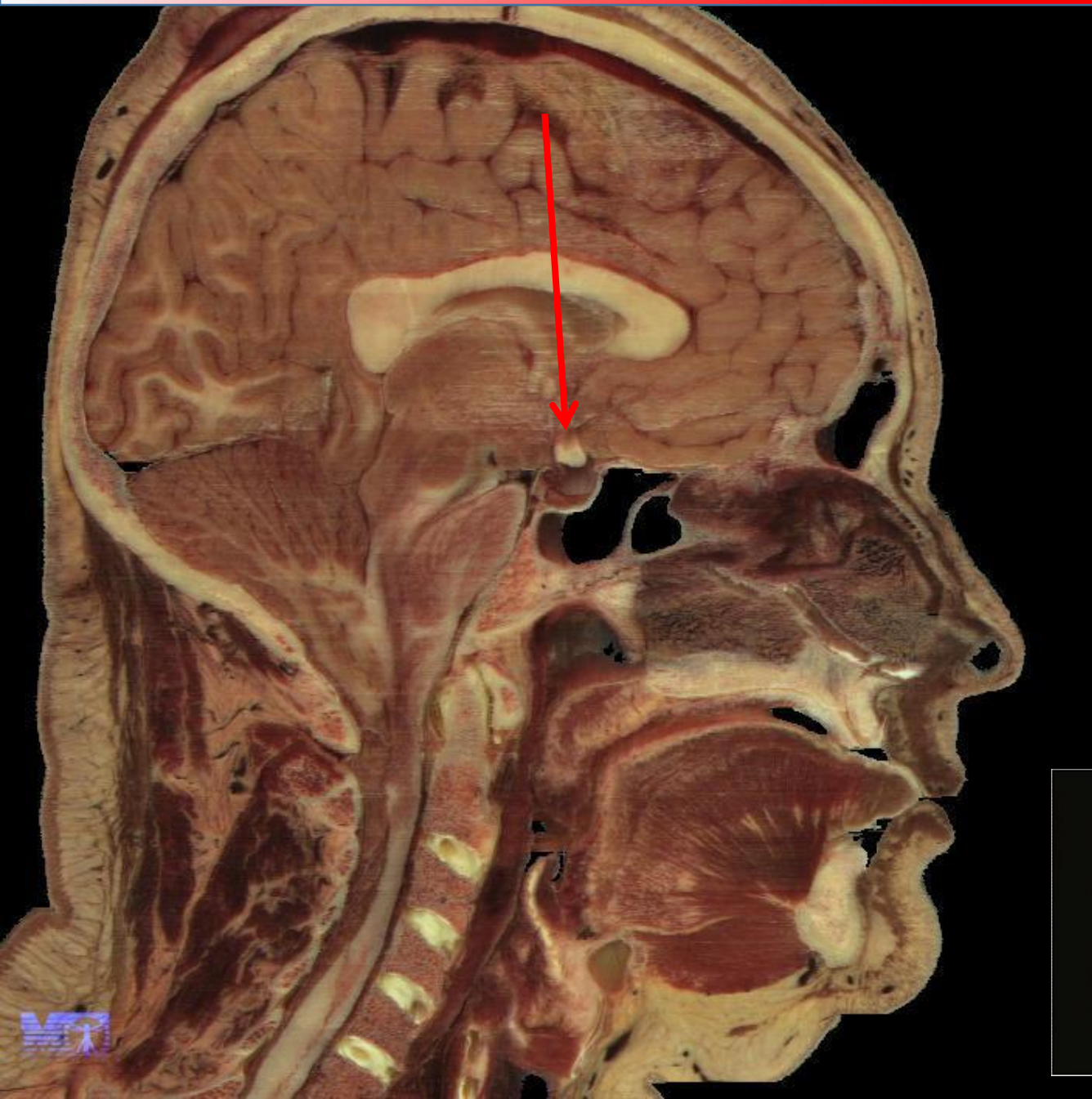
Optic chiasm

Sphenoid sinus

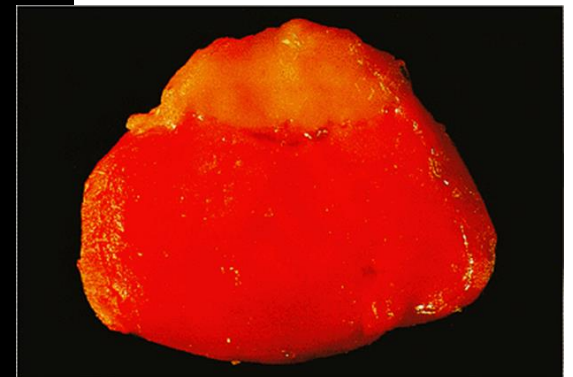
Nasal septum



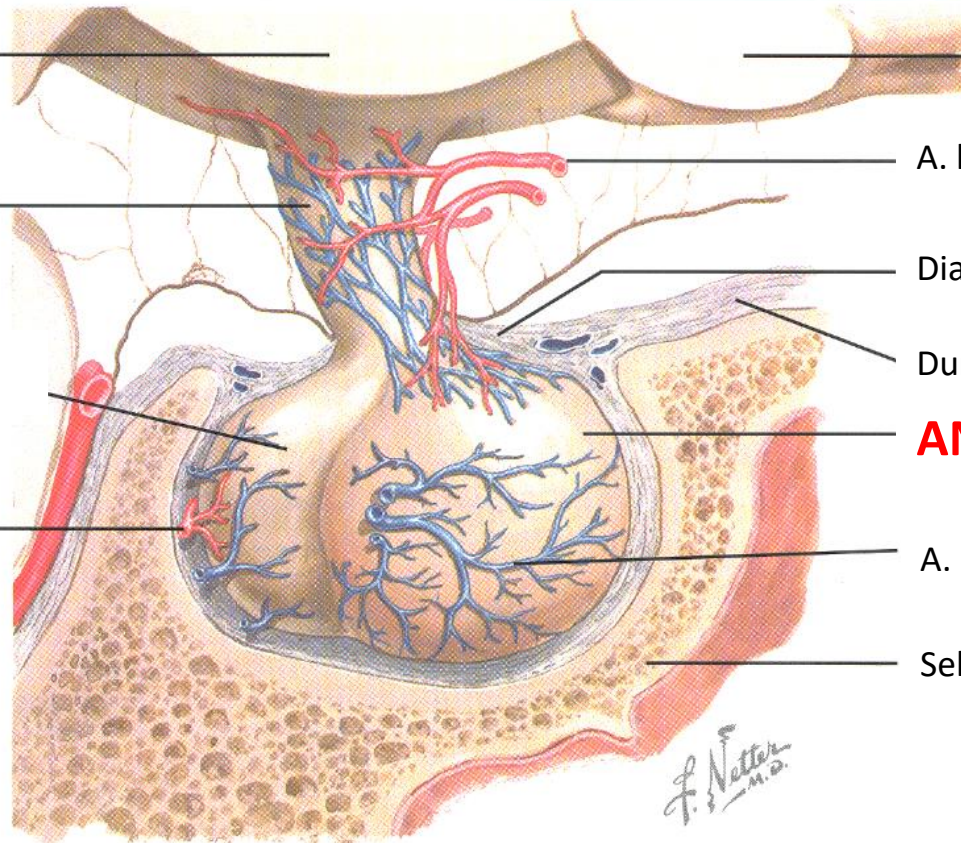
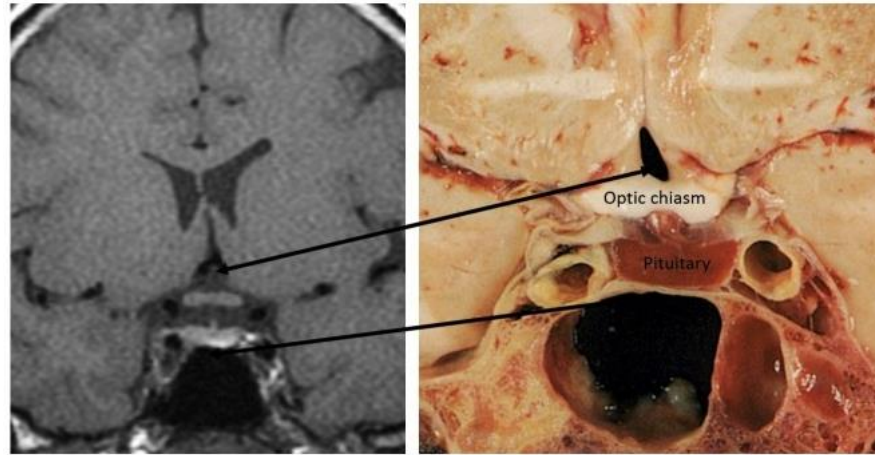
PITUITARY GLAND (GL. PITUITARIA)



- hypothalamus
- sella turcica
- fossa hypophysialis
- optic chiasm



PITUITARY (GL. PITUITARIA)



HYPOTHALAMUS

INFUNDIBULUM

POSTERIOR LOBE

A. hypophysialis inf.

Chiasma opticum

A. hypophysialis sup.

Diaphragma sellae

Dura mater

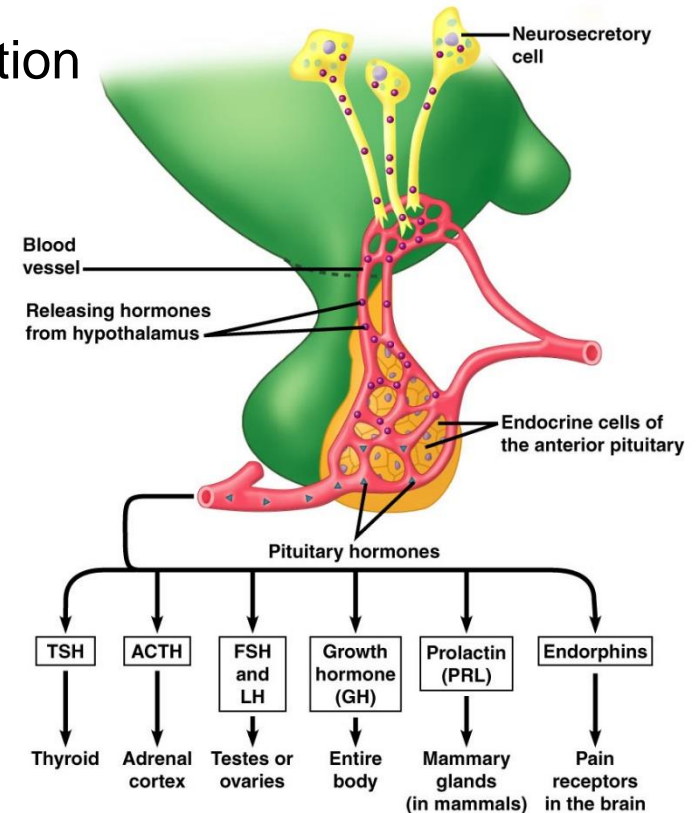
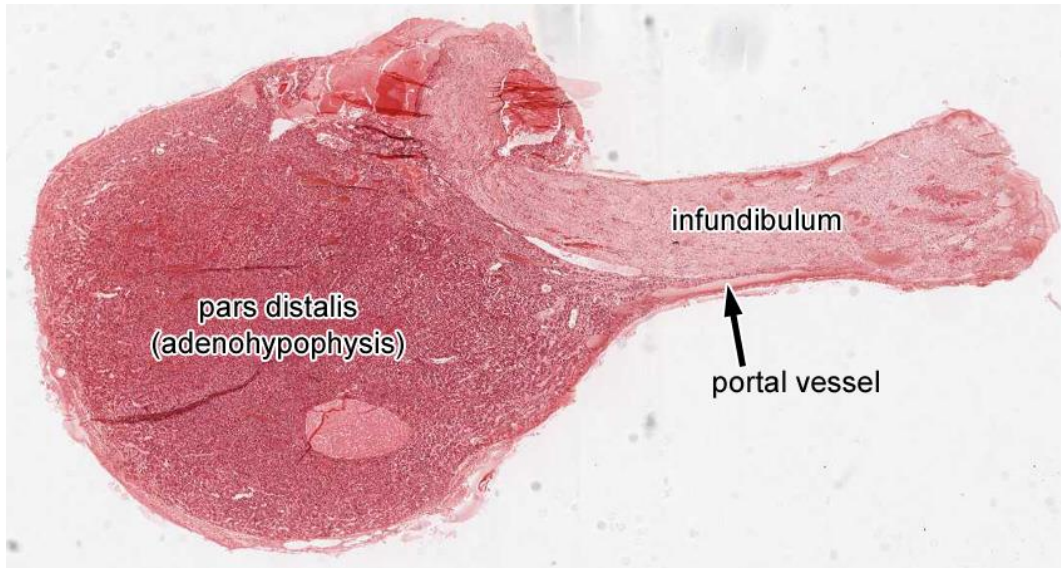
ANTERIOR LOBE

A. hypophysialis inf.

Sella turcica of sphenoid bone

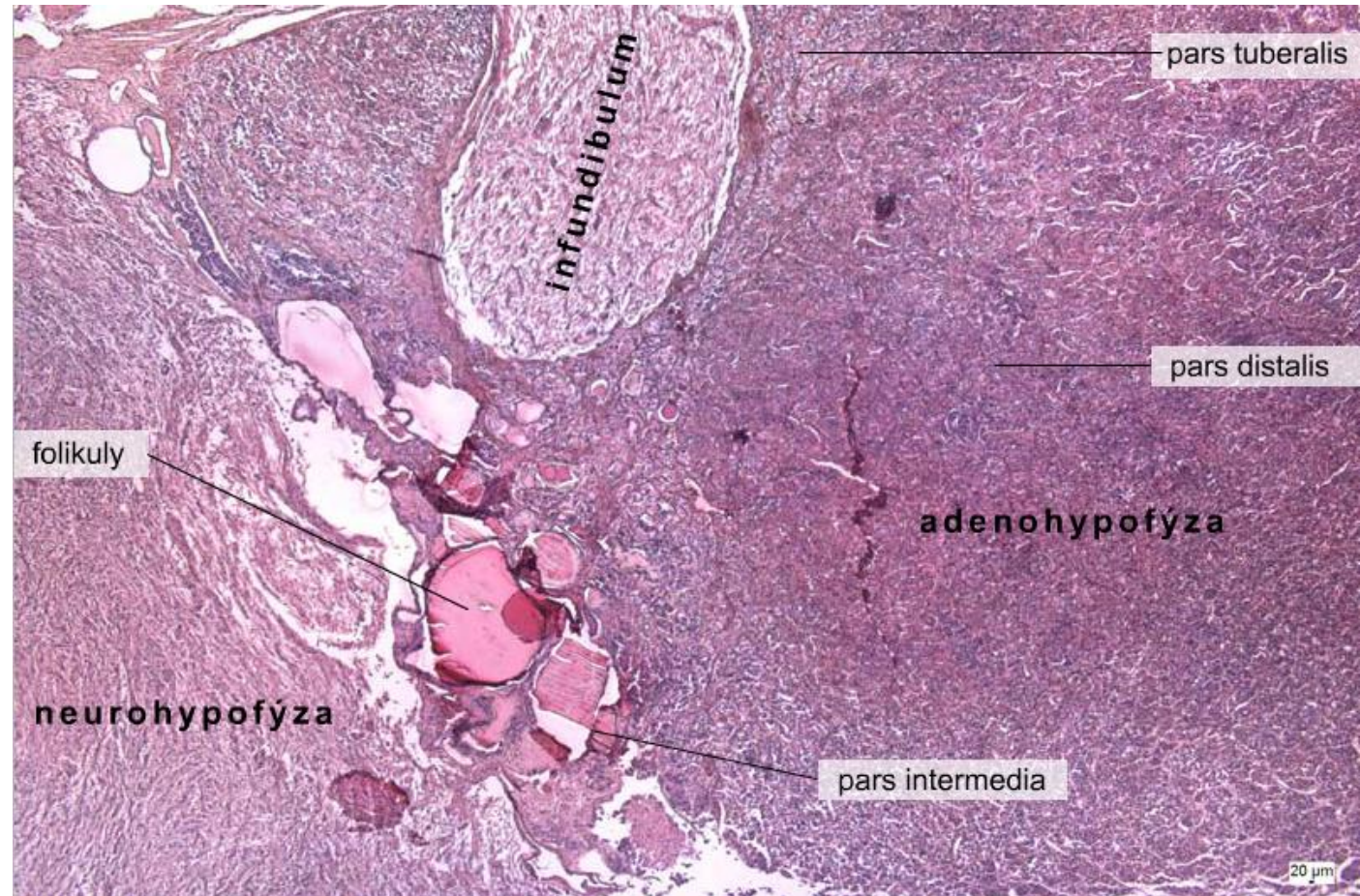
PITUITARY GLAND (GL. PITUITARIA)

- adenohypophysis - glandotropic hormones, prolactin, GH
- neurohypophysis - hypothalamic hormones - ADH, oxytocin
- anatomical and functional association with hypothalamus
- capillary systems and neuroendocrine secretion

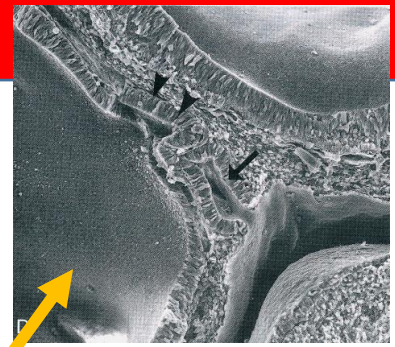


PITUITARY GLAND (GL. PITUITARIA)

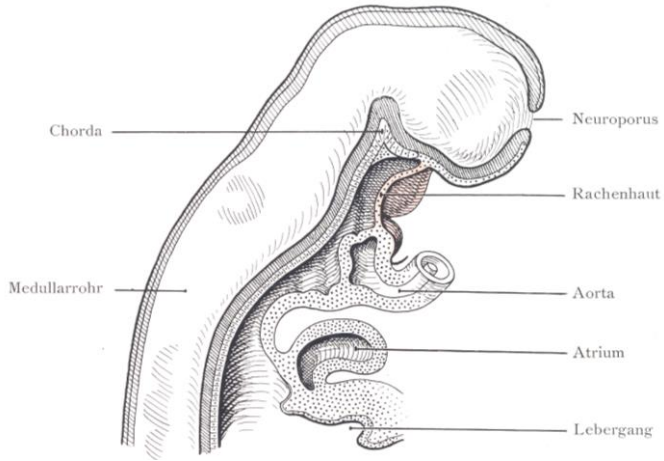
- adenohypophysis (*pars distalis*, *pars tuberalis*, *pars intermedia*)
- neurohypophysis (*pars nervosa*)
- *infundibulum*, *eminentia mediana*



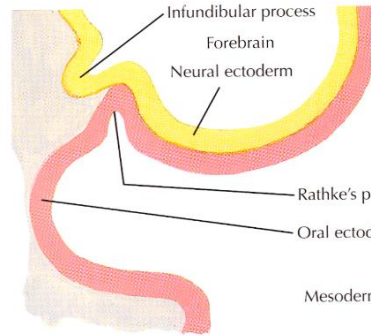
EMBRYONIC DEVELOPMENT OF PITUITARY GLAND



- Ectoderm of stomodeum (Rathke's pouch)
- Neuroectoderm of ventral wall of diencephalon

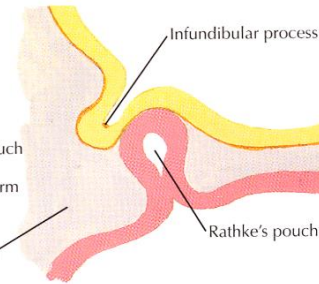


~ week 3



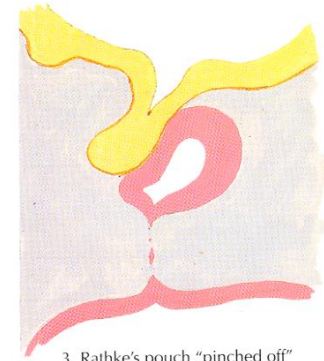
1. Beginning formation of Rathke's pouch and infundibular process

~ week 6

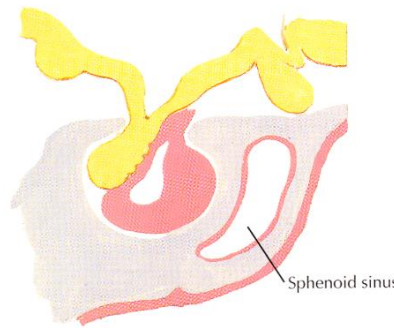
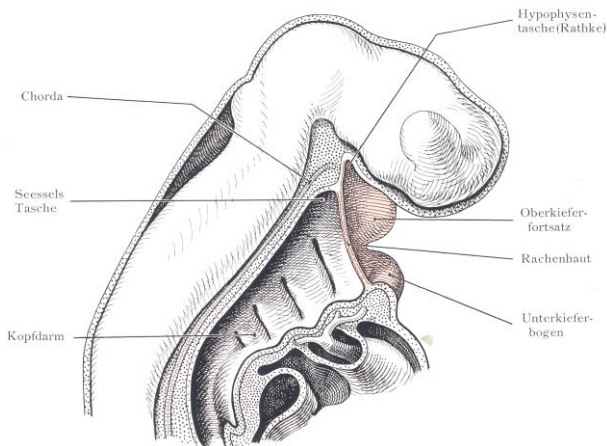


2. Neck of Rathke's pouch constricted by growth of mesoderm

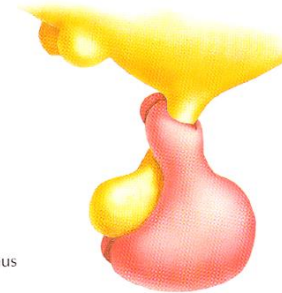
~ week 8



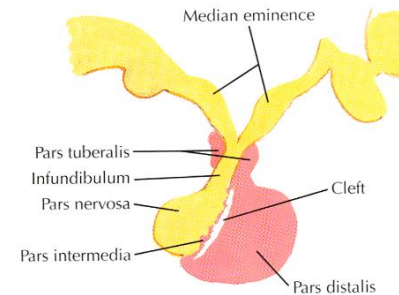
3. Rathke's pouch "pinched off"



4. "Pinched off" segment conforms to neural process, forming pars distalis, pars intermedia and pars tuberalis



5. Pars tuberalis encircles infundibular stalk (lateral surface view)



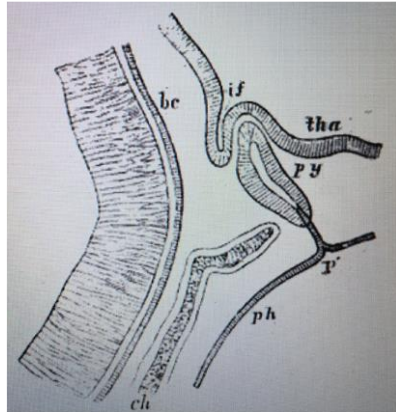
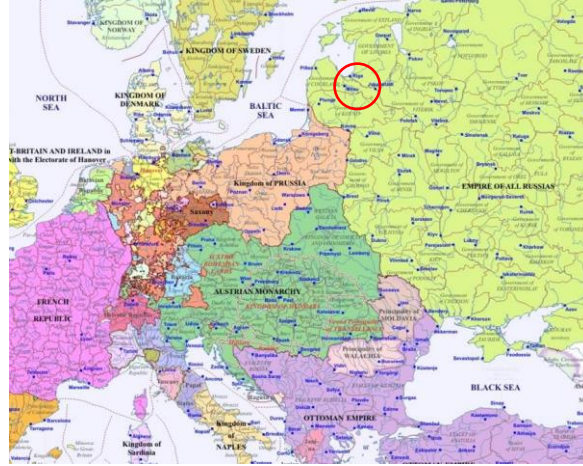6. Mature form

~ week 11

~ week 16

F. Netter M.D.

MARTIN HEINRICH RATHKE (1793 – 1860)



Ueber die Entstehung der Glandula pituitaria.

Von
HEINRICH RATHKE.

Schon längst bemerkte ich bei mehreren Thieren in einer sehr frühen Zeit des Fruchtlebens, bei Säugethieren namentlich geraume Zeit früher, als sich der Gaumen bildet, ganz hinten in der Mundhöhle, unterhalb der Grundfläche des Schädels eine kleine unregelmässig rundliche Vertiefung, die der Schleimhaut des Mundes angehörte und offenbar eine dünnwandige Aussackung derselben war. Lange aber wusste ich sie nicht zu deuten, zumal da ich sie bei älteren Embryonen, wenn ich die Mundhöhle untersuchte, nicht mehr wiederfand. Endlich ward ich gewahrt, dass diese Vertiefung den ersten Schritt zur Bildung des Hirnanhanges (Gland. pituitaria) bezeichnet.

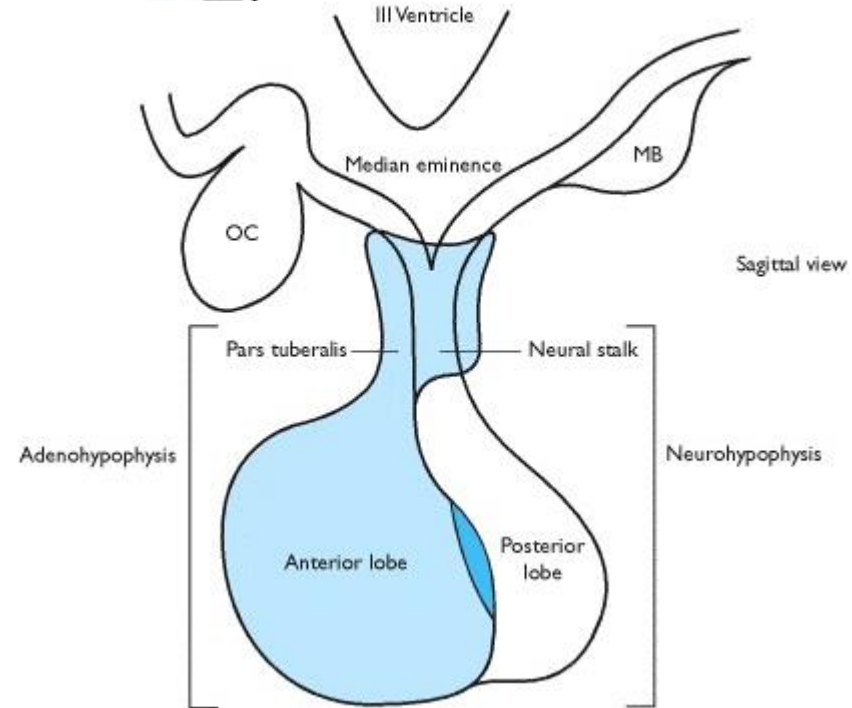
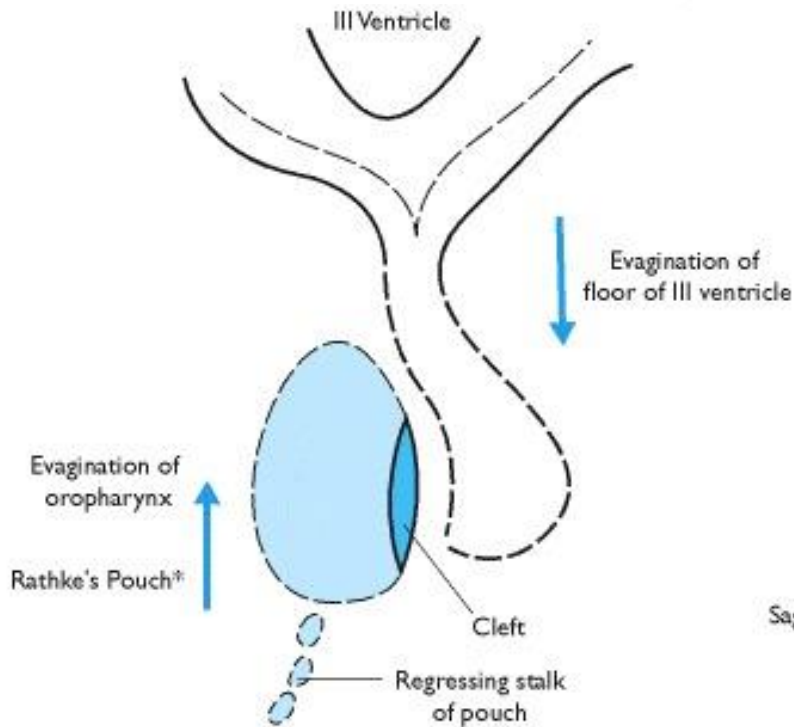
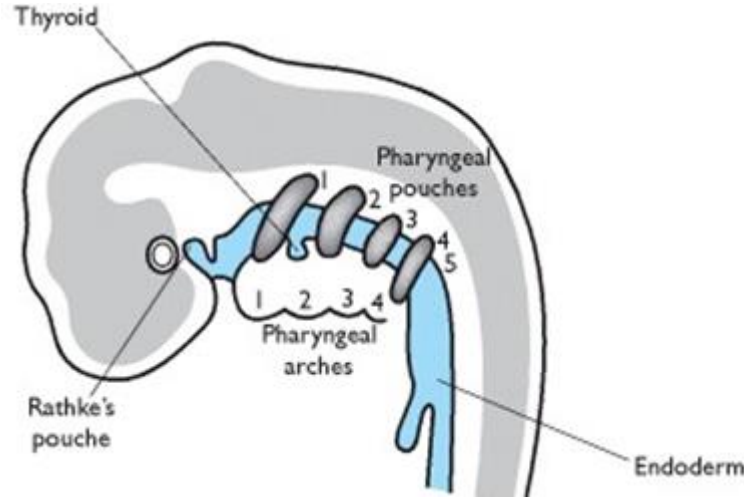
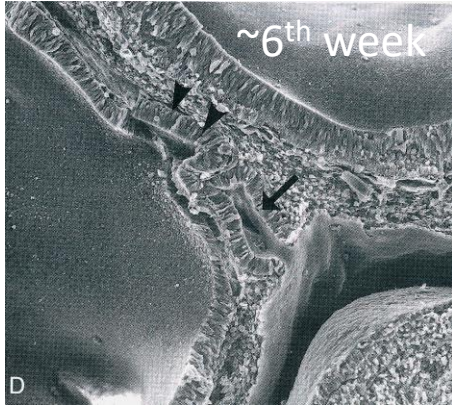Bevor ich nun aber das weitere Verhalten derselben schildere, sehe ich mich genöthigt ein Paar Worte über den Schädel vorzuschicken. Der Stern von der Chorda dorsalis reicht, wie es allen Anschein hat, vielleicht bei allen Wirbelthieren nur bis zwischen die beiden Knorpelkapseln, welche bei den mit einem Knochenskelett versehenen Thieren zu den

- Physician, anatomist, embryologist, zoologist
- One of founding fathers of modern embryology

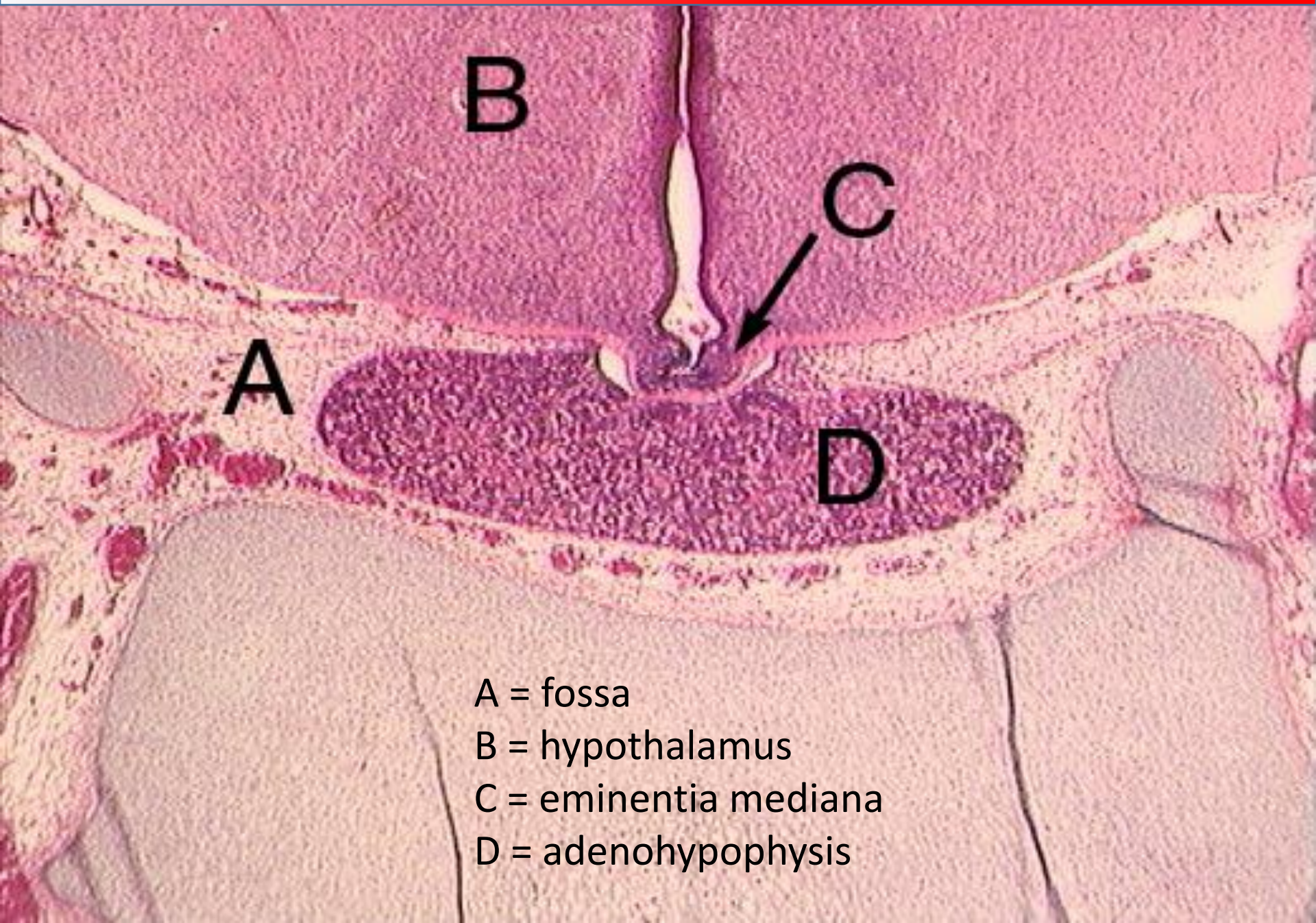
"For a long time I have observed in several animals ... a small irregularly rounded depression which belongs to the mucous membrane of the mouth, of which it is clearly a thin-walled outpocketing. ... Finally I saw that this depression represents the first step in the formation of the pituitary gland" (p. 482).

Rathke, H. : *Ueber die Entstehung der glandula pituitaria*. Arch, f. Anat., Phys. und wiss. Med. S. 482-85. **1838**

EMBRYONIC DEVELOPMENT OF PITUITARY GLAND



EMBRYONIC DEVELOPMENT OF PITUITARY GLAND



A = fossa

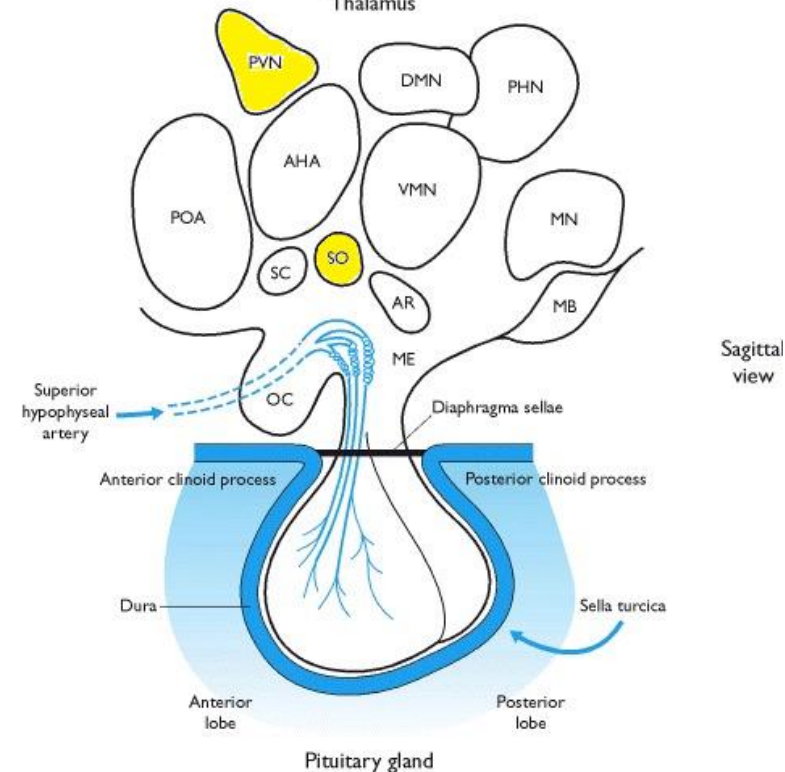
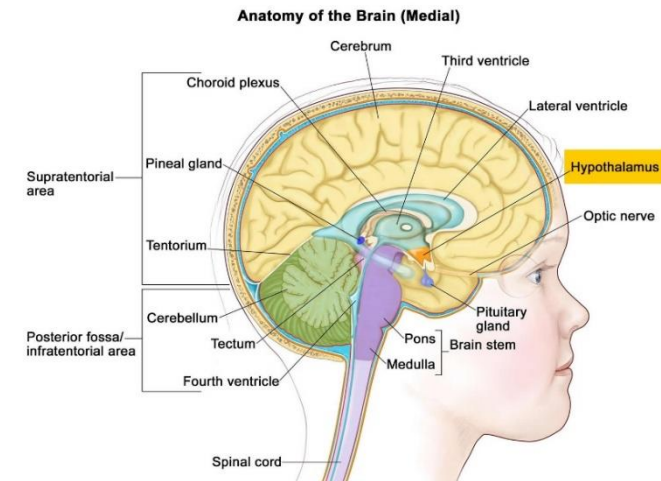
B = hypothalamus

C = eminentia mediana

D = adenohypophysis

HYPOTHALAMUS

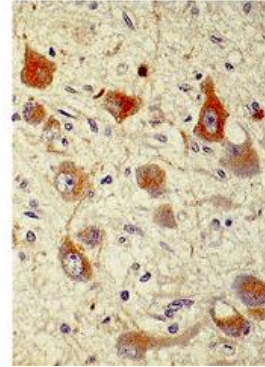
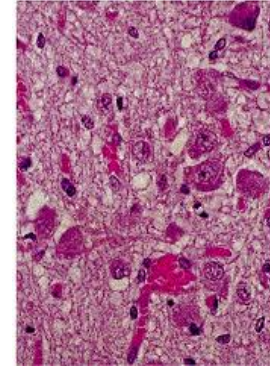
- small region of diencephalon
- complex neuroarchitecture
- core of the limbic system
- complex functions
- regulation of temperature, emotions, eating behavior, circadian rhythms
- hormonal regulation controlled by various stimuli (osmoreception, concentration of nutrients, electrolytes, systemic functions - pain)
- **neurosecretion from hypothalamic nuclei**
 - *n. supraopticus, n. paraventricularis*
 - magnocellular neurons - **tractus hypothalamo-hypophysialis** - **oxytocin and ADH through neurohypophysis**
 - parvocellular neurons - capillaries in *eminentia mediana* - **statins and liberins regulating secretion from adenohypophysis through hypothalamo-hypophyseal portal system**



MECHANISM OF NEUROSECRETION

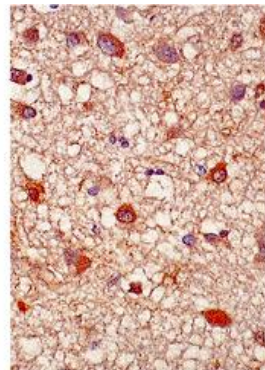
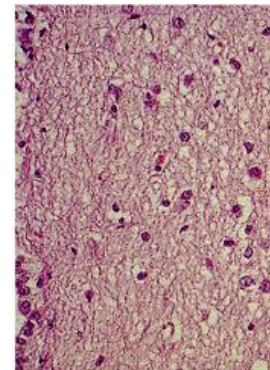
Tractus hypothalamo-hypophysialis

- axons of magnocellular neurons in *nucleus supraopticus* and *paraventricularis*
- terminating on fenestrated capillaries in neurohypophysis
- synthesis of prohormones → maturation during axonal transport
- capillary plexus from *arteria hypophysialis inferior* (branch of *a. carotis interna* → *sinus cavernosus*)



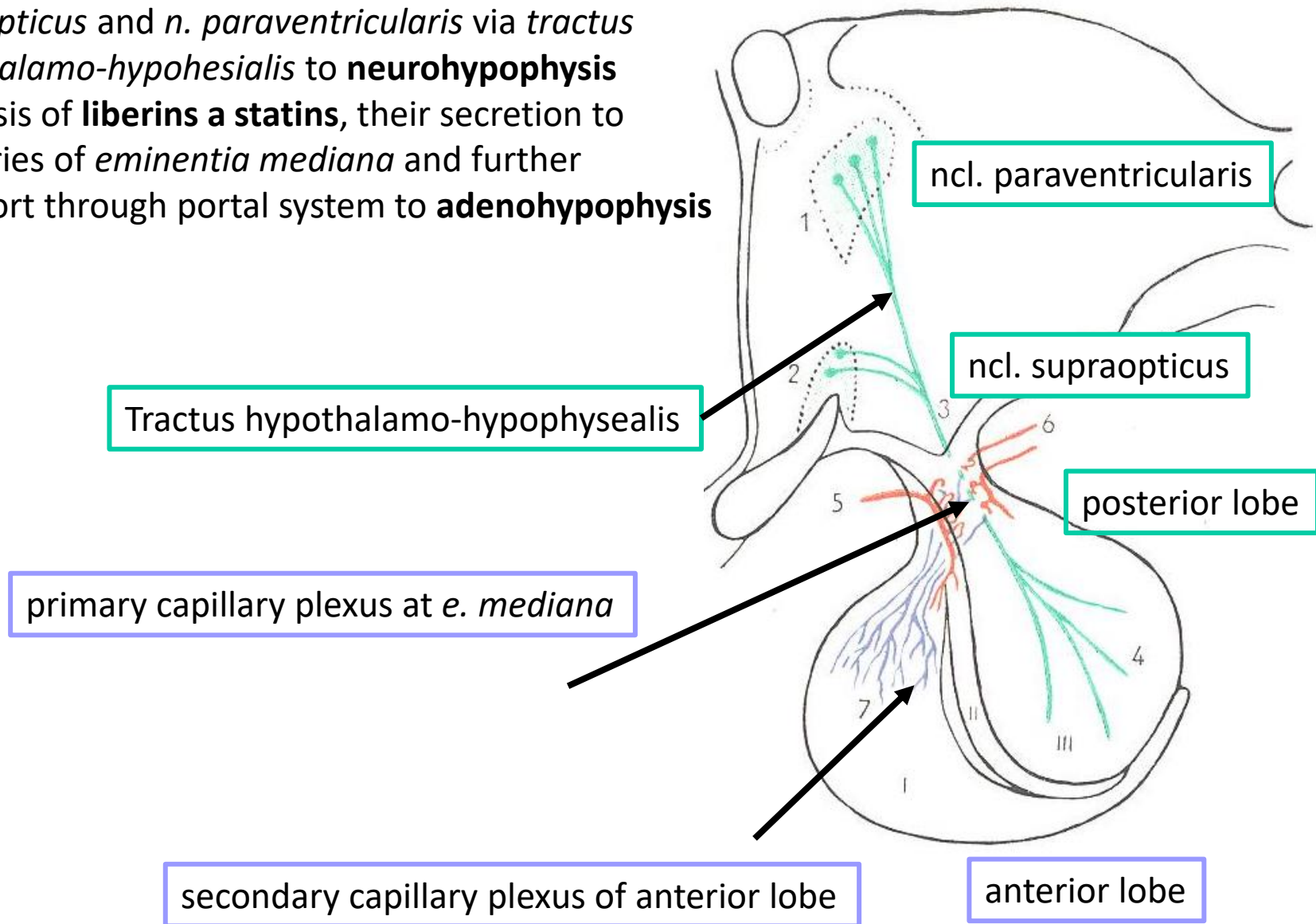
Hypophyseal portal system

- parvocellular neurons e.g. in *nucleus arcuatus*, *preopticus*, *paraventricularis* and *nuclei tuberales*
- axonal transport onto primary capillary plexus in ***eminentia mediana*** (from anterior and posterior superior hypophyseal arteries) → hypophyseal portal veins → secondary capillary plexus in adenohypophysis → inferior hypophyseal portal veins → *vv. jugulares internae*

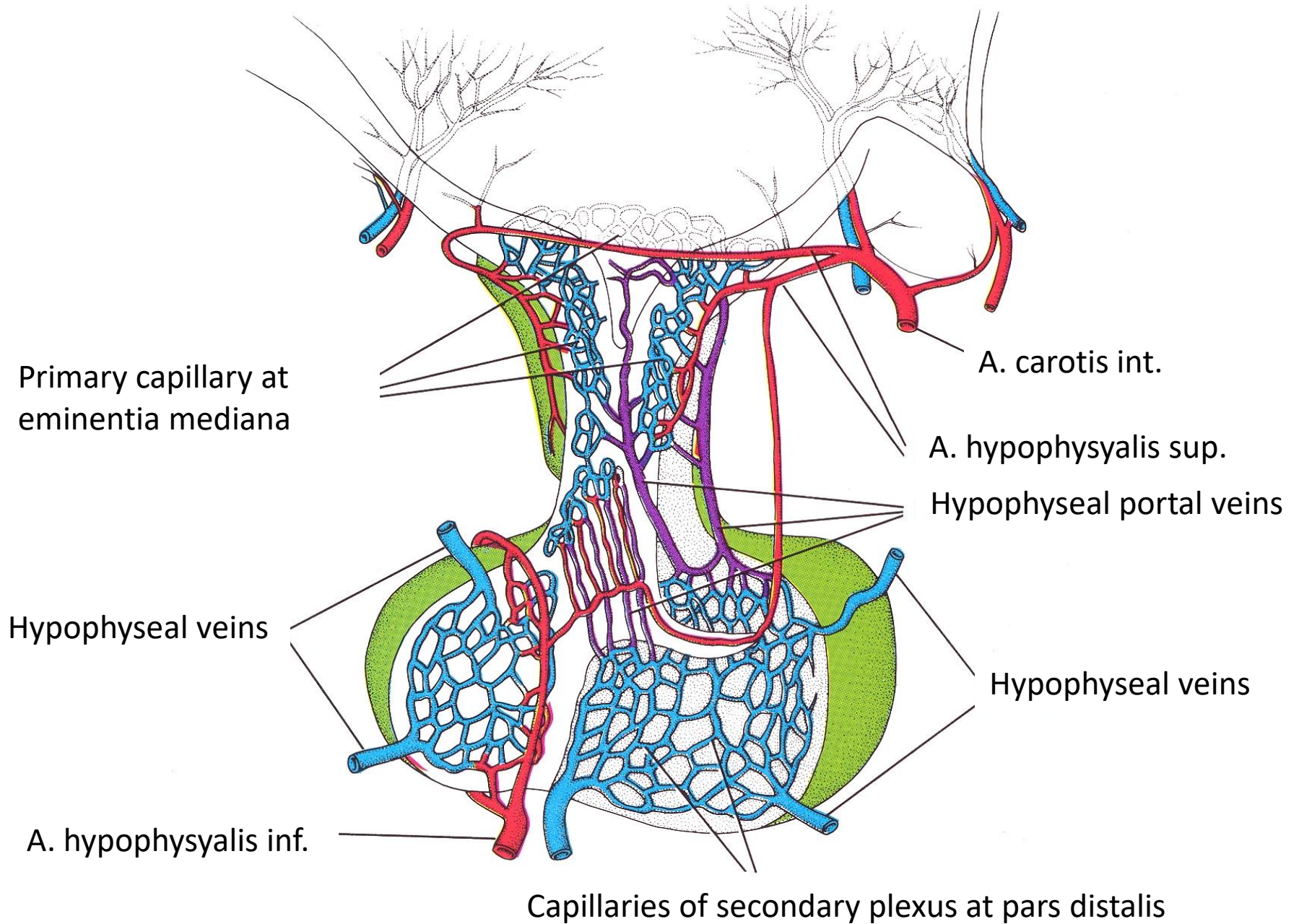


MECHANISM OF NEUROSECRETION

- synthesis and transport of **effector hormones** from *n. supraopticus* and *n. paraventricularis* via *tractus hypothalamo-hypohesialis* to **neurohypophysis**
- synthesis of **liberins a statins**, their secretion to capillaries of *eminentia mediana* and further transport through portal system to **adenohypophysis**

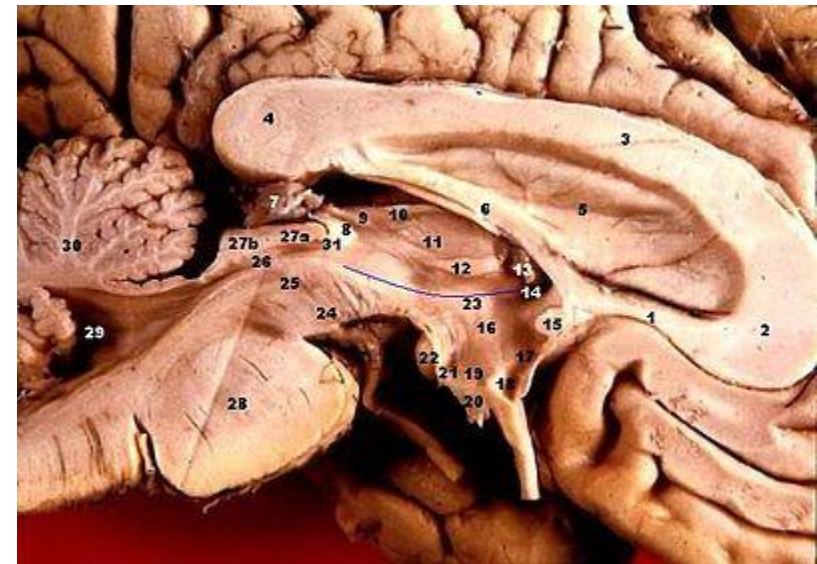
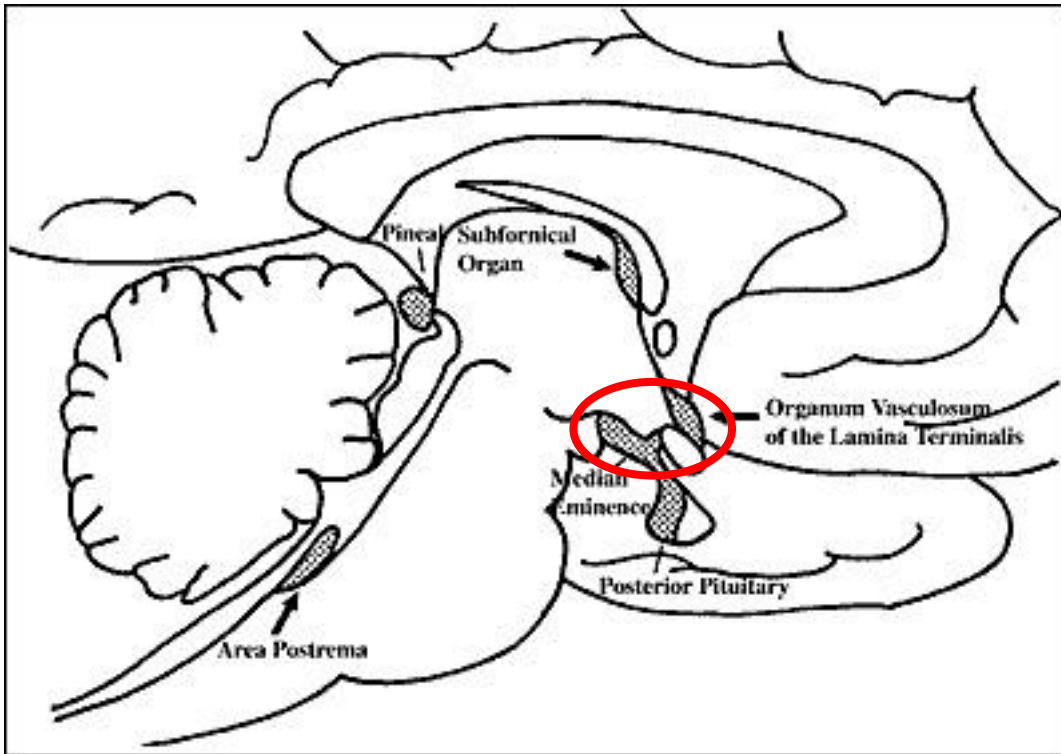


CAPILLARY SYSTEMS OF HYPOPHYSIS



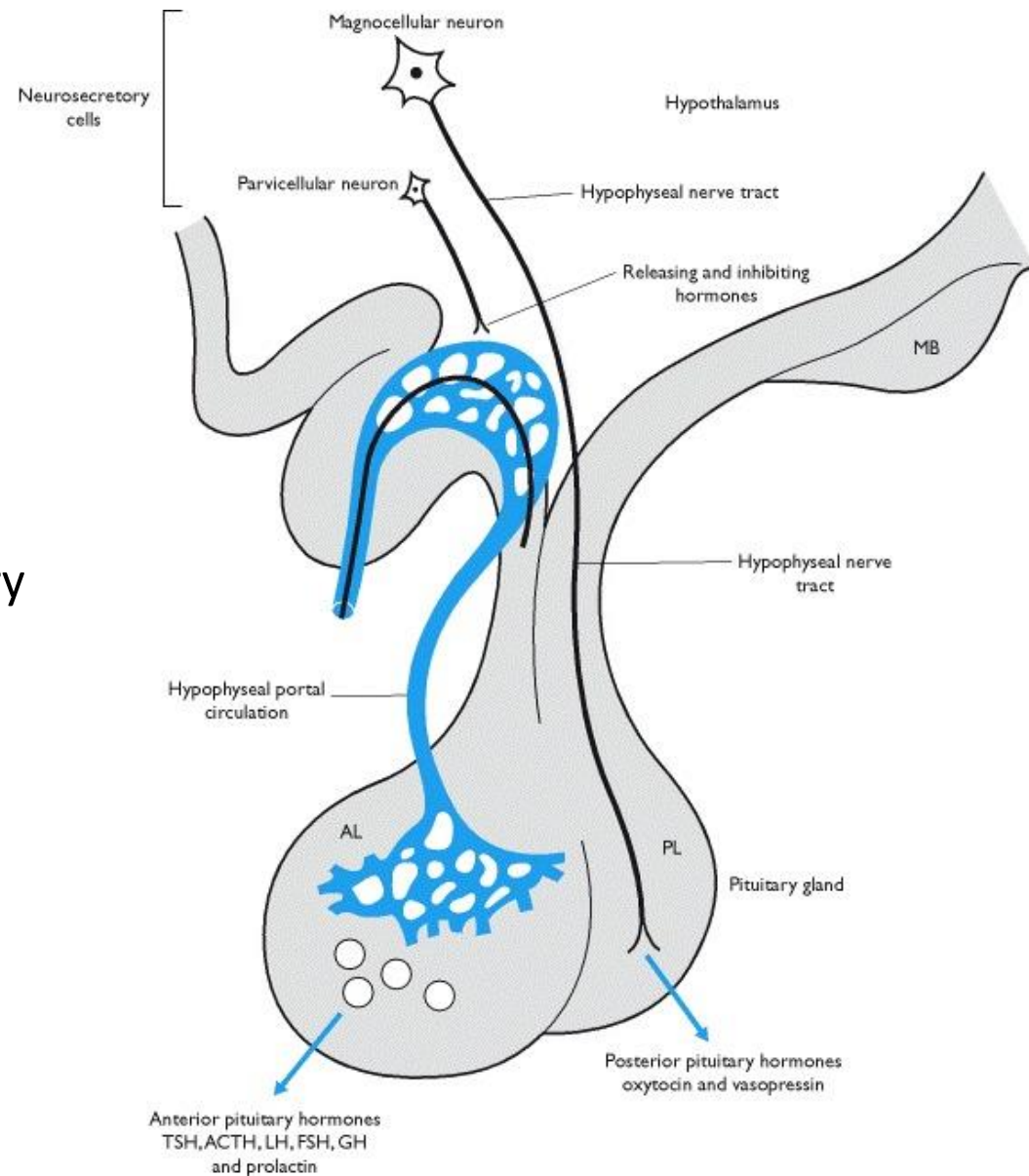
EMINENTIA MEDIANA

- elevated part of *tuber cinereum* (detachment of infundibulum *p. nervosa*)
- neurohemal area - hematoencephalic barrier is open here
- fenestrated capillaries with large perivascular spaces

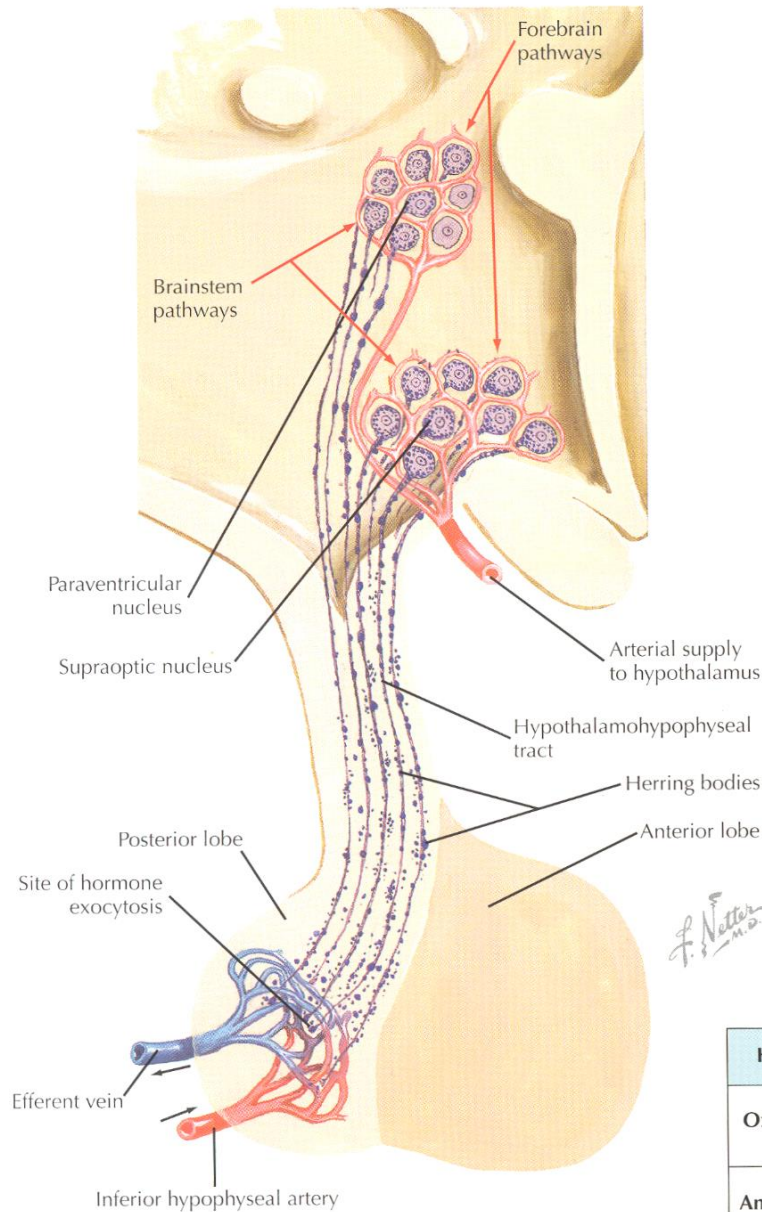


NEUROHYPOPHYSIS (POSTERIOR LOBE)

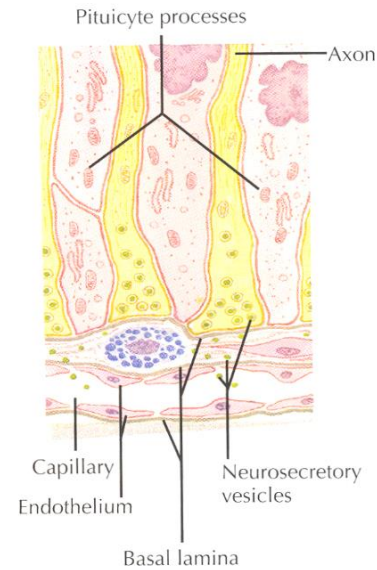
- **Nonmyelinated nerve fibers**
 - axons of neurosecretory cells (c.a. 100 000) of hypothalamic nuclei (n. supraopticus and paraventricularis)
- **Pituicytes** (neuroglia)
 - astrocyte-like (intermediate filaments, GFAP)
 - local control of secretion from neurosecretory termini
 - Herring bodies – neurosecretory endings – dilatation close to capillaries
- **Hormones**
 - oxytocin (OT)
 - antidiuretic hormone (ADH, vasopressin)



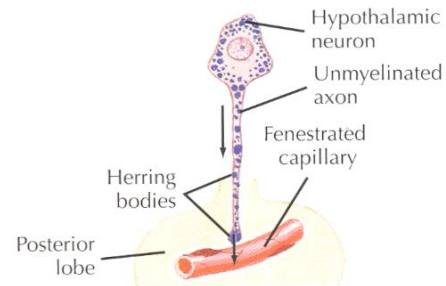
NEUROHYPOPHYSIS (POSTERIOR LOBE)



▼ Neurosecretory Ending (posterior pituitary).

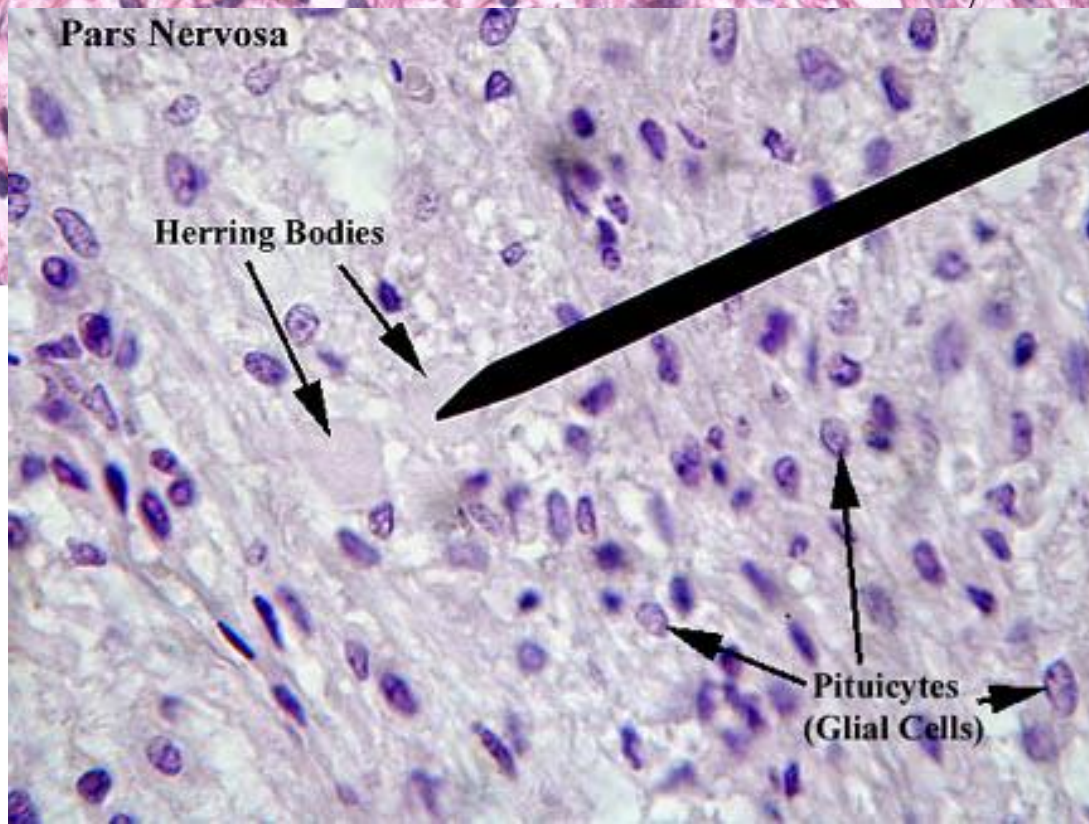
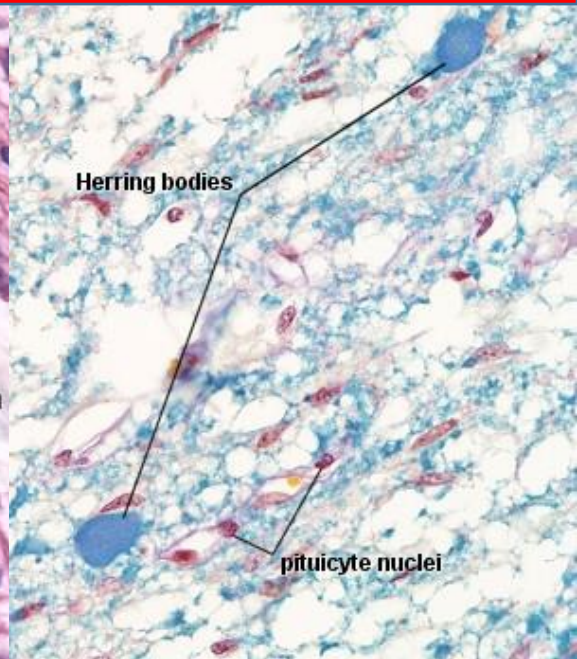
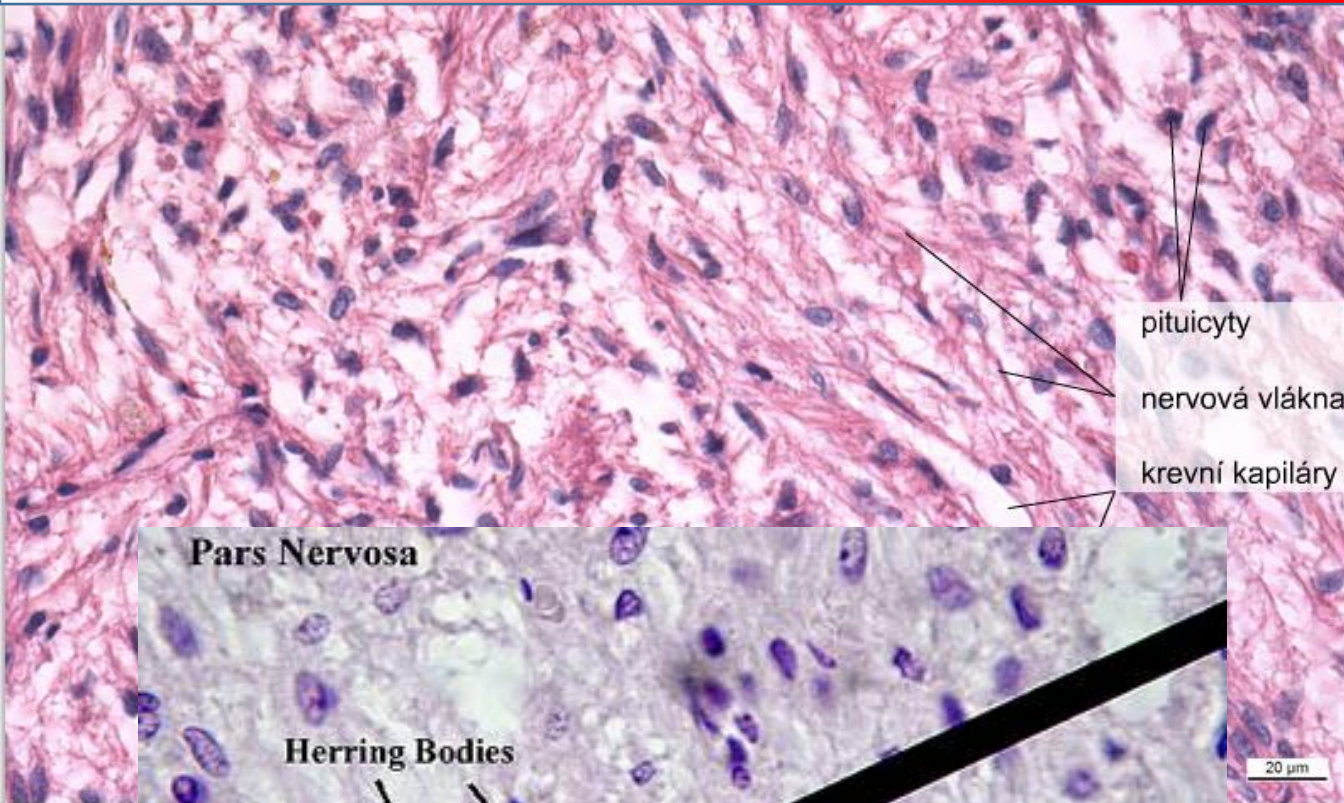


▼ Origin of ADH.



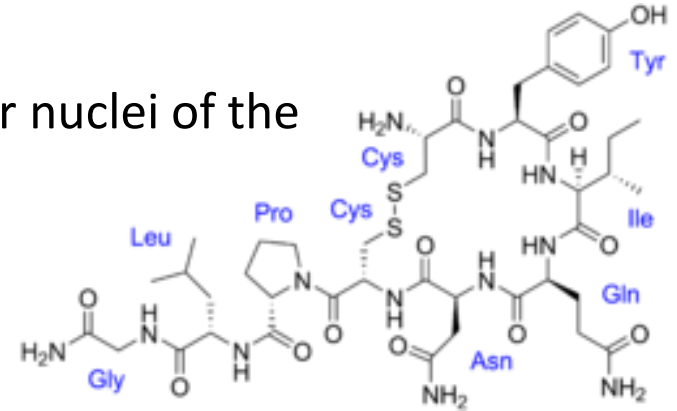
Hormone	Principal Action	Principal Nucleus of Origin
Oxytocin (OXY)	Uterine contraction, milk ejection	Paraventricular
Anti-diuretic hormone (ADH)	Water excretion in kidney, arteriolar constriction	Supraoptic

NEUROHYPOPHYSIS (POSTERIOR LOBE)



Oxytocin

- nonapeptide
- magno-cellular supraoptic and paraventricular nuclei of the hypothalamus
- OR - G-coupled receptor
- lactation reflex
- uterine contraction
- social behavior



Vasopressin

- nonapeptide
- retention of water
- effective in collecting duct and distal convoluted tubule (aquaporin translocations)
- blood pressure regulation by affecting t. media
- diabetes insipidus, hypernatremia, polyuremia



ADENOHYPHYSIS (ANTERIOR LOBE)

Chromophilic cells

Acidophils

Nonglandotropic

- direct effect on target tissues

Basophils

Glandotropic

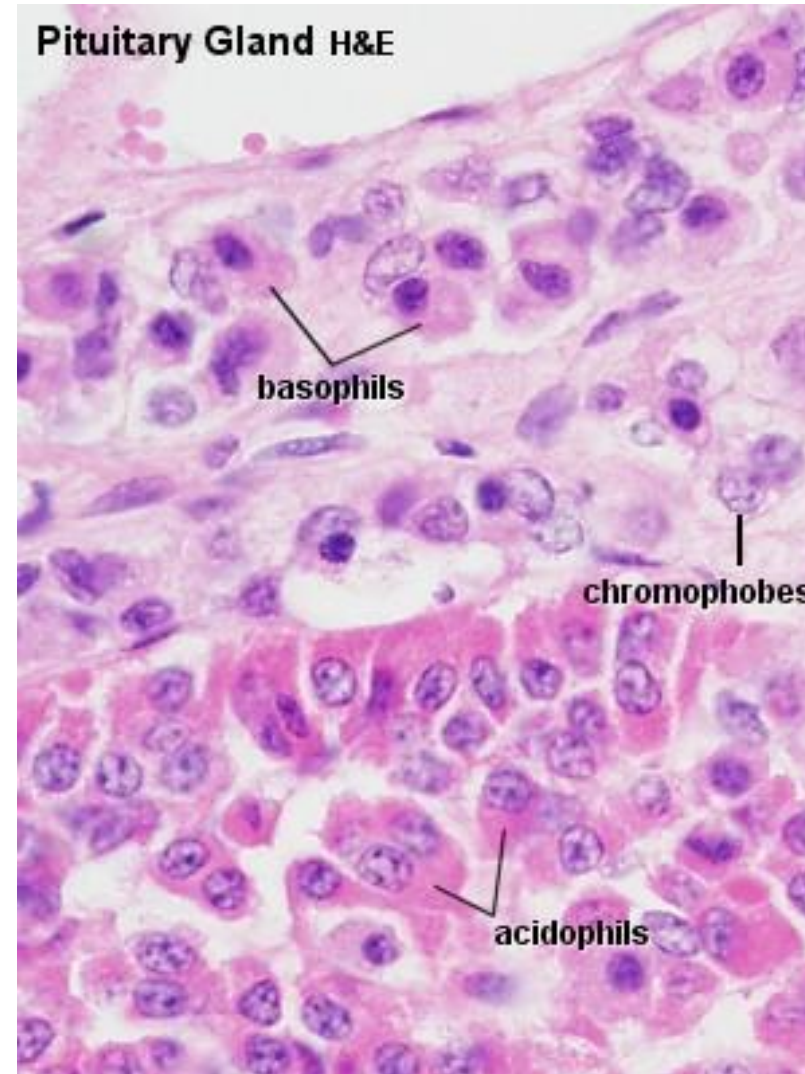
- regulation of other endocrine glands

Chromophobic cells

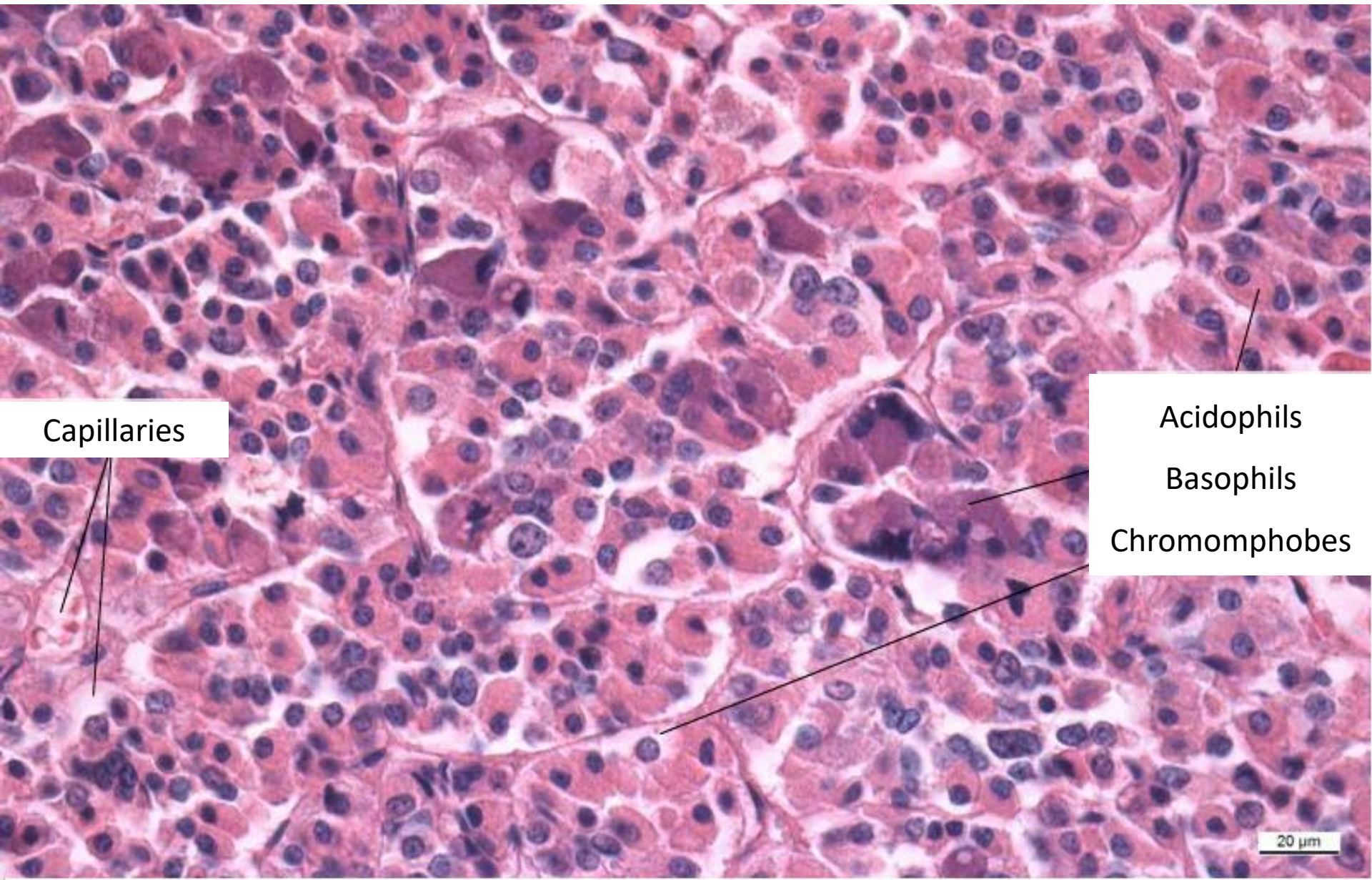
- undifferentiated cells
- degranulated ("empty") chromophils
- stromal cells

Folliculo-stellate cells (FS-cells)

- unclear function, putative stem cells
- cytokine production



ADENOHYPHYSIS (ANTERIOR LOBE)



Capillaries

Acidophils

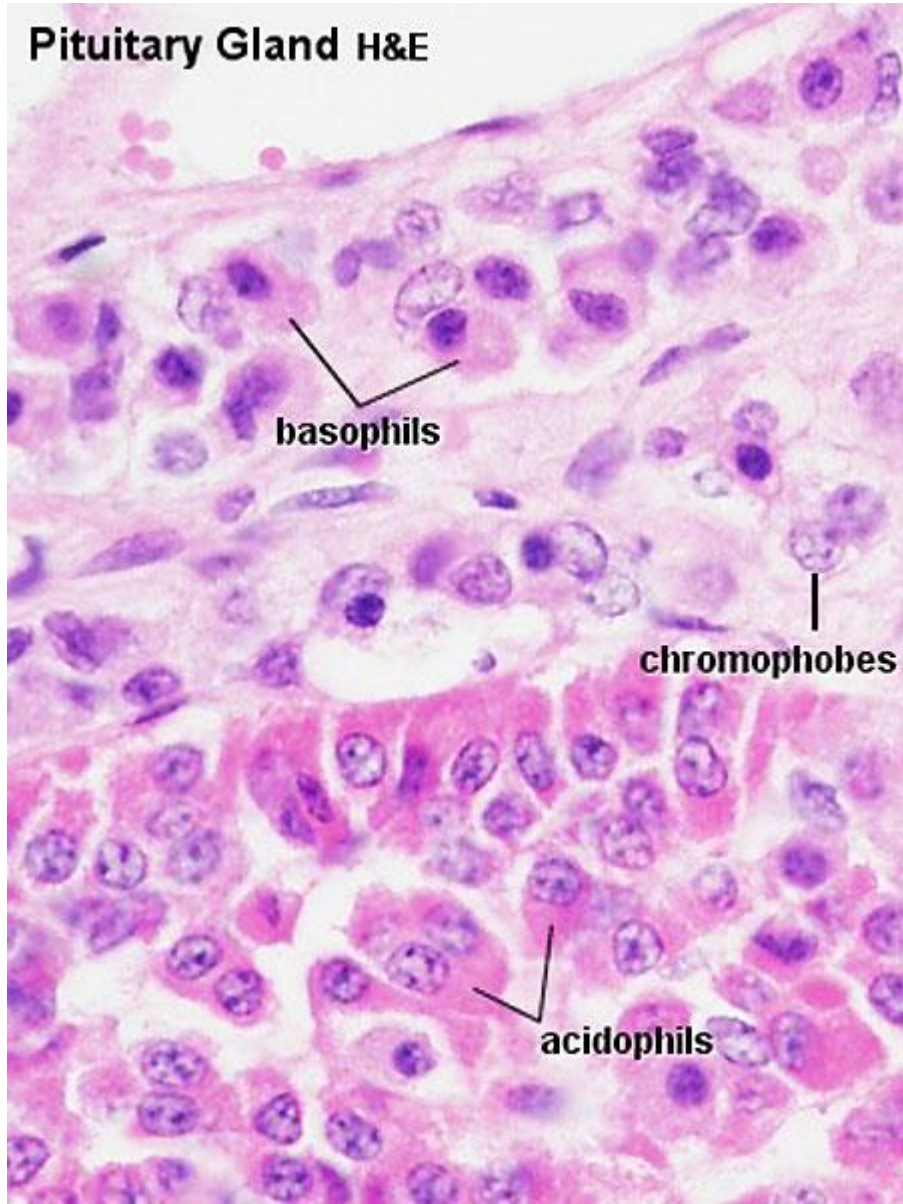
Basophils

Chromomphobes

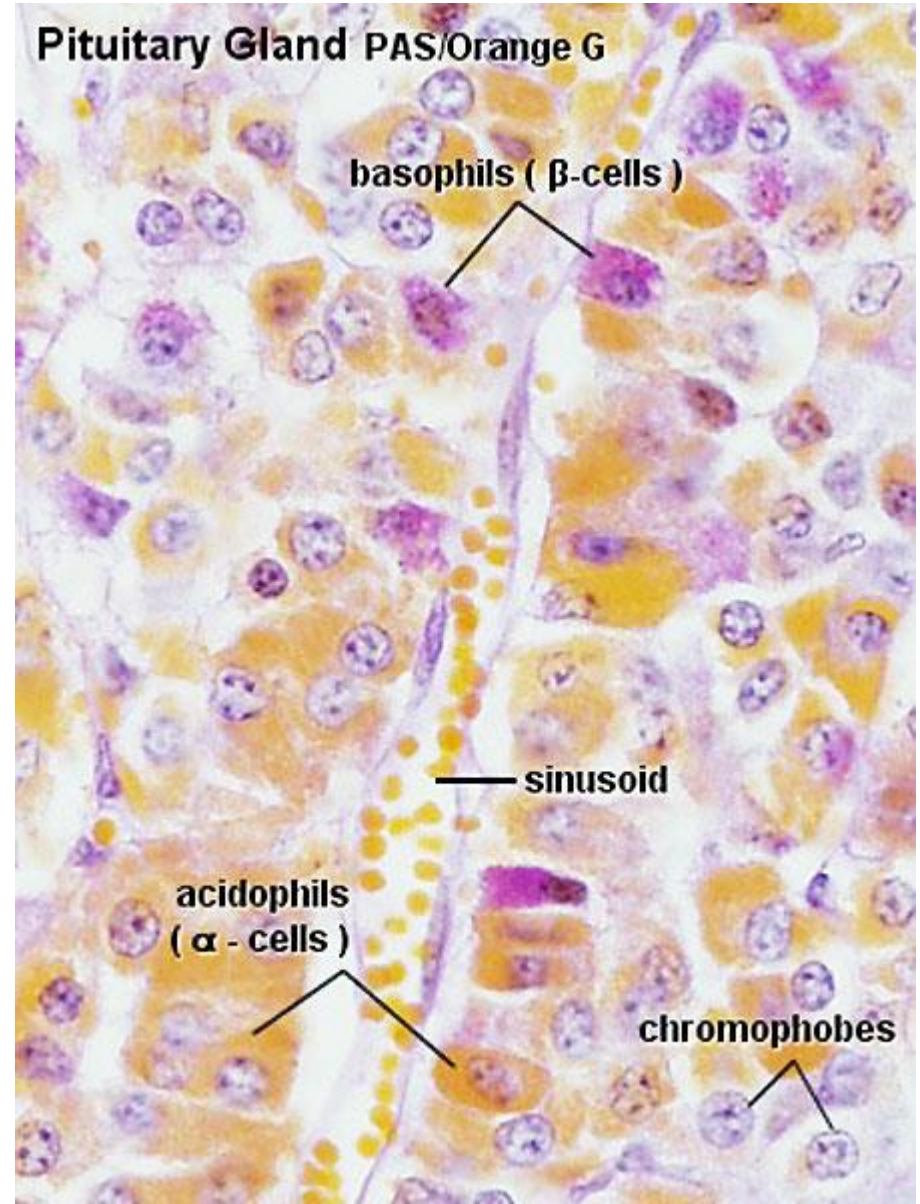
20 μ m

ADENOHYPHYSIS (ANTERIOR LOBE)

Pituitary Gland H&E

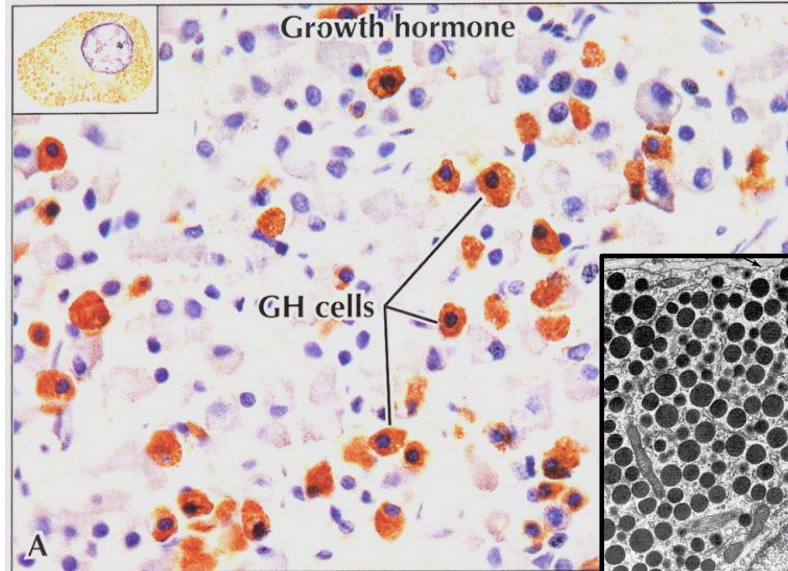


Pituitary Gland PAS/Orange G

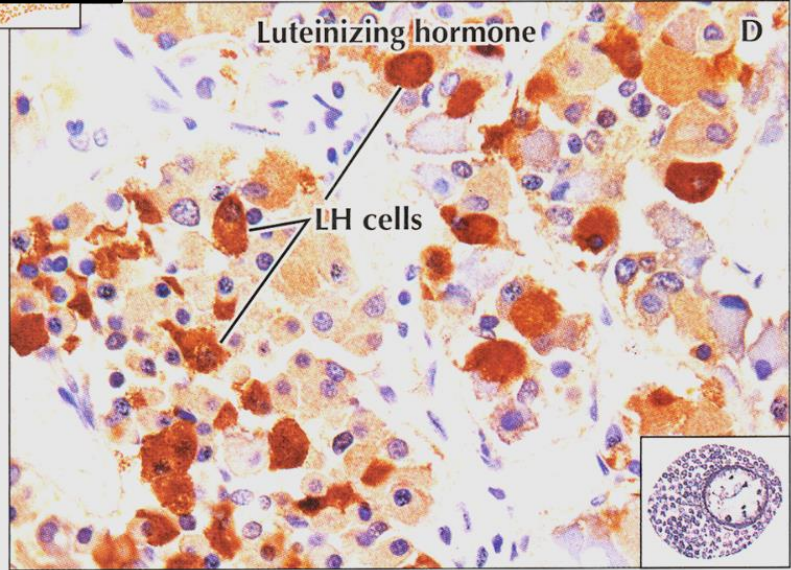
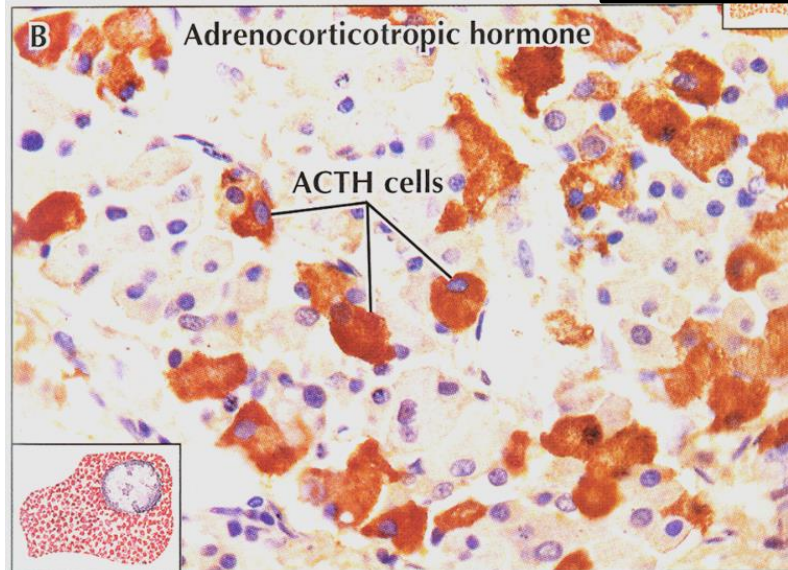
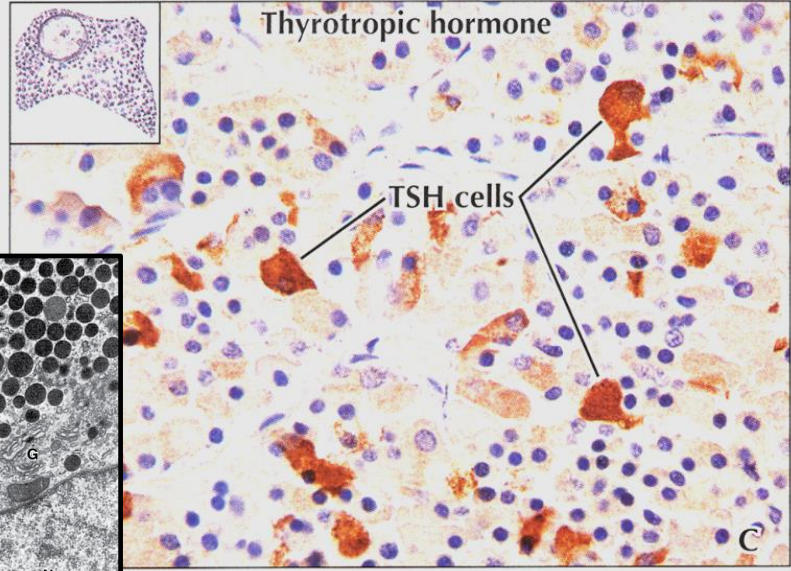


ADENOHYPHYSIS (ANTERIOR LOBE)

Acidophils producing GH



Basophils producing glandotropic hormones



REGULATION BY HYPOTHALAMIC HORMONES

- gonadoliberin → FSH a LH
- corticoliberin → cortikotropin
- thyreoliberin → thyreotropin
- *prolactin releasing hormone (?)* → *prolactin*
- somatoliberin → somatotropin
- follistatin — FSH a LH
- somatostatin — somatotropin, TSH
- dopamin — prolactin

”FLAT PEG”

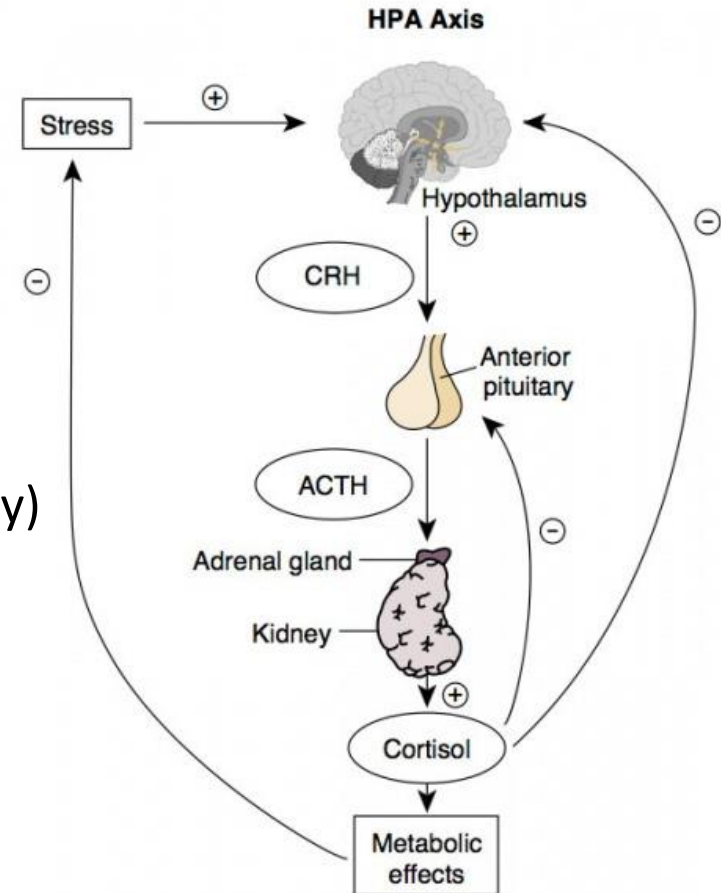
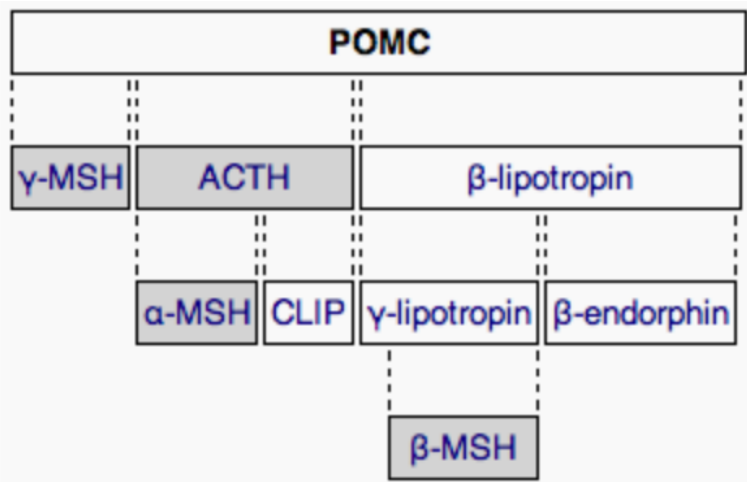
- FSH
- LH
- ACTH
- TSH
- Prolactin
- Endorphins
- Growth hormone

Pro-opio-melanocortin (POMC)

rough ER → pre-prohormon
produced by various tissues

cleavage to

- ACTH (target: adrenal cortex → cortisol)
- MSH (target: melanocytes - mostly in paracrine way)
- lipotropin (lipolysis, steroidogenesis)
- endorphins



FSH (folitropin), LH (lutropin)

- gonadotropic cells of adenohypophysis stimulated by GnRH
- glycoproteins, 30kDa
- heterodimer, two noncovalent bound subunits (**a/α** - common for - LH, FSH, TSH, hCG, **b/β** - specific)
- FSH receptor (testes, ovarium, uterus) G-protein coupled receptor
 - glycosylated extracellular domain of 11 leucine rich repeats specific to FSH
 - after ligand binding, activation of G-protein and cAMP signaling
 - alternative activation of MAPK cascade (ERK)
 - complex signaling response (prostaglandins, PLPc, NO)

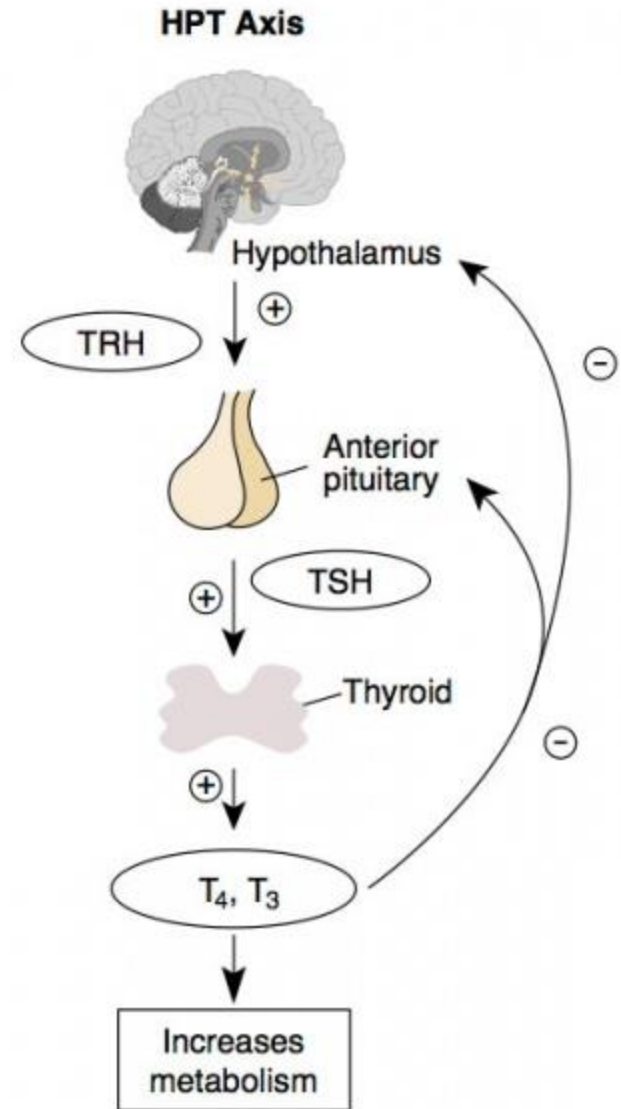
FSH

LH

ovarium	follicle development (FSHR in m. <i>granulosa cells</i>)	ovulation, development of corpus luteum, production of androgens in thecal cells
testes	spermatogenesis, FSHR in Sertoli cells	production of testosterone in Leydig cells (expression of LHR)
extragonadal	FSHR in secretory endometrium of luteal phase uterus (endometrial functions, embryo-endometrial interactions)	uterus, seminal vesicles, prostate, skin... unknown function

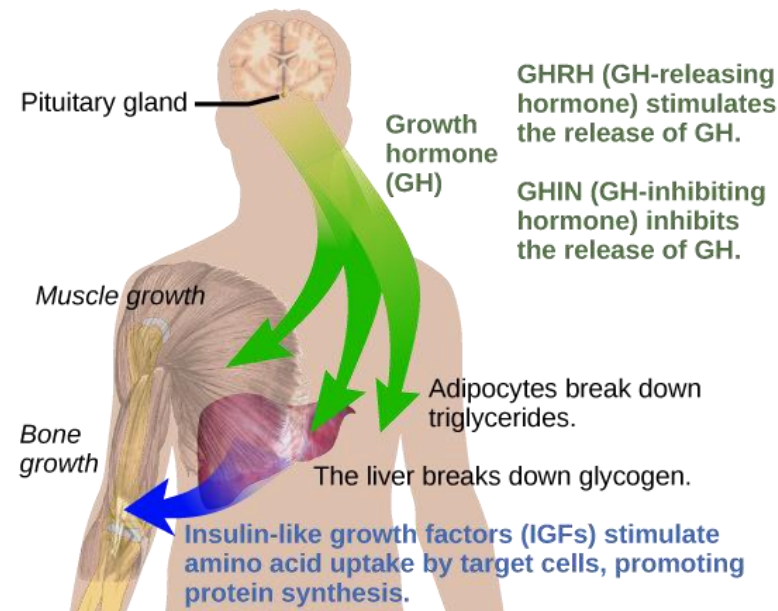
TSH, thyrotropin

- thyrotropic cells of adenohypophysis stimulated by TRH
- production of T₄ (thyroxin) a T₃ (triiodothyronin) by thyroid gland
- glycoprotein, 28,5 kDa, heterodimer, two noncovalent bound subunits (α, β)
- TSH receptor on thyroid follicular cells
- G-protein signaling → adenylylcyklase → cAMP
- cAMP → iodide channels (pendrin), transcription of thyreoglobulin, endo- and exocytic pathway
- cross-reactivity with hCG → in pregnancy - alterations in synthesis of thyroid hormones (**gestational hyperthyroidism**)



GH, somatotropin, growth hormone

- somatotropic cells of adenohypophysis stimulated by GHRH (somatocrinin)
- several molecular isoforms (alternative splicing), ~20-24 kDa
- broad spectrum of target cell types and physiological circuits
 - transcription of DNA, translation of RNA, proteosynthesis
 - lipid use (fatty acid mobilization, conversion to acetyl-CoA)
 - inhibition of direct use of glucose, stimulation of glukoneogenesis
 - transmembrane transport of aminoacids
 - proteosynthesis in chondrocytes and osteoblasts, proliferation, osteogenesis
- GHR in various tissues
 - RTK, JAK-STAT
- somatomedins
 - small proteins (MW 7,5 kDa), IGF-like
 - produced by liver
- various pathologies associated with GH



ADENOHYPHYPHYSIS – HORMONES

Table 2. Nonclassical Anterior Pituitary Substances and Cell(s) of Origin

<i>Substances</i>	<i>Cell Types</i>
PEPTIDES	
ACTIVIN B, INHIBIN, FOLLISTATIN	F,G
ALDOSTERONE STIMULATING FACTOR	UN
ANGIOTENSIN II (ANGIOTENSINOGEN, ANGIOTENSIN I CONVERTING ENZYME, CATHEPSIN B, RENIN)	C,G,L,S
ATRIAL NATURETIC PEPTIDE	G
CORTICOTROPIN-RELEASING HORMONE-BINDING PROTEIN	C
DYNORPHIN	G
GALANIN	L,S,T
GAWK (CHROMOGRANIN B)	G
GROWTH HORMONE RELEASING HORMONE	UN
HISTIDYL PROLINE DIKETOPIPERAZINE	UN
MOTILIN	S
NEUROMEDIN B	T
NEUROMEDIN U	C
NEUROPEPTIDE Y	T
NEUROTENSIN	UN
PROTEIN 7B2	G,T
SOMATOSTATIN 28	UN
SUBSTANCE P (SUBSTANCE K)	G,L,T
THYROTROPIN RELEASING HORMONE	G,L,S,T
VASOACTIVE INTESTINAL POLTPEPTIDE	G,L,T
GROWTH FACTORS	
BASIC FIBROBLAST GROWTH FACTOR	C,F
CHONDROCYTE GROWTH FACTOR	UN
EPIDERMAL GROWTH FACTOR	G,T
INSULIN-LIKE GROWTH FACTOR I	S,F
NERVE GROWTH FACTOR	UN
PITUITARY CYTOTROPIC FACTOR	UN
TRANSFORMING GROWTH FACTOR ALPHA	L,S,G
VASCULAR ENDOTHELIAL GROWTH FACTOR	F
CYTOKINES	
INTERLEUKIN-1 BETA	T
INTERLEUKIN-6	F
LEUKEMIA INHIBITORY FACTOR	C,F
NEUROTRANSMITTERS	
ACETYLCHOLINE	C,L
NITRIC OXIDE	F


C = corticotroph, F = folliculostellate cell, G = gonadotroph, L = lactotroph, S = somatotroph, T = thyrotroph, UN = unknown

Hypophyseal tumors

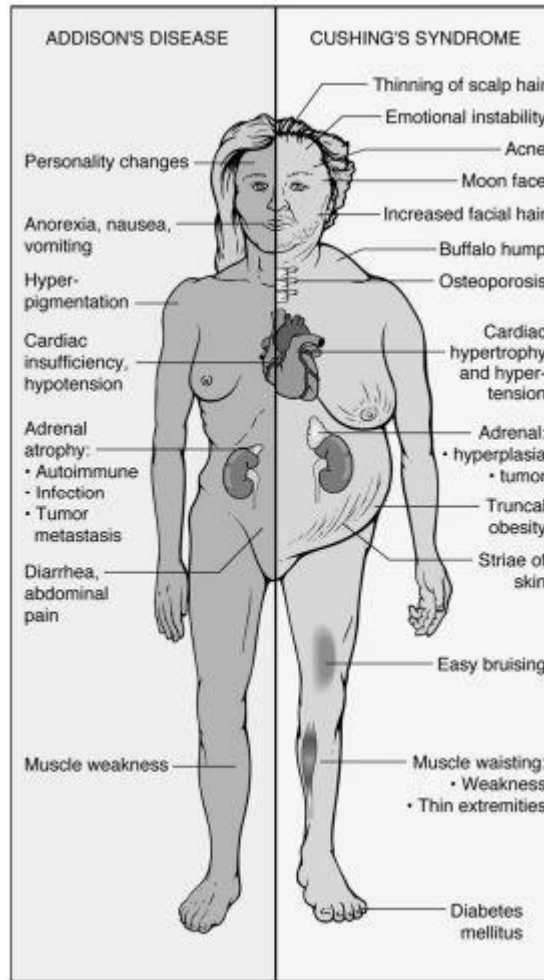
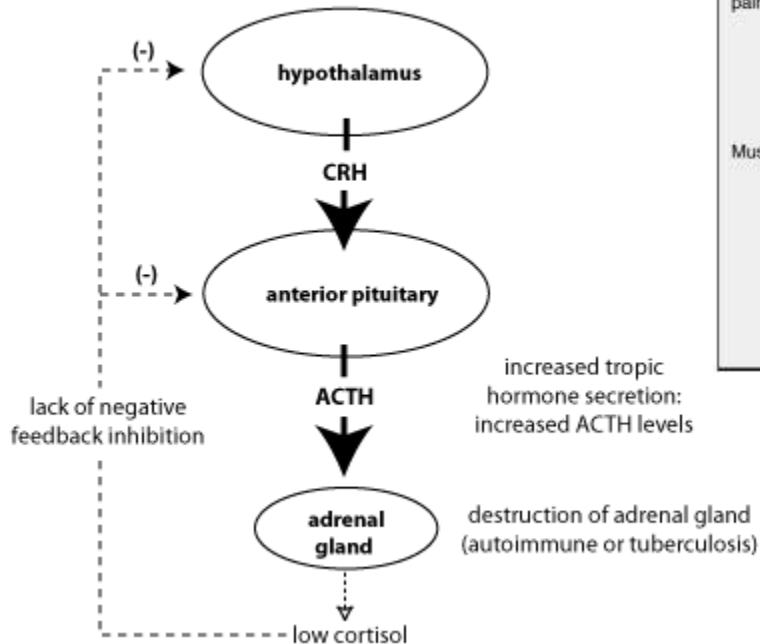
- compression of surrounding structures (e.g. optic chiasma)
- hyperfunction of endocrine component
 - prolactinoma - galactorrhea
 - hypogonadism (alterations of GnRH)
 - gigantism - acromegaly
 - nanism



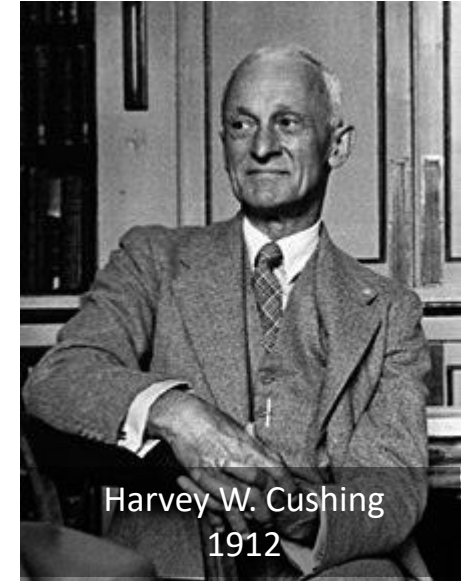
Corticotrophs hypofunction



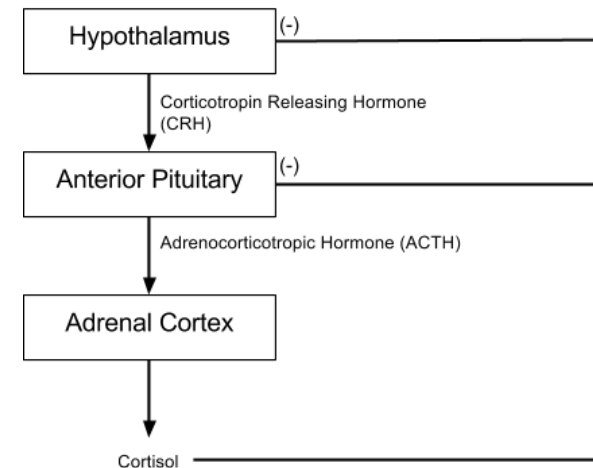
Addison's Disease



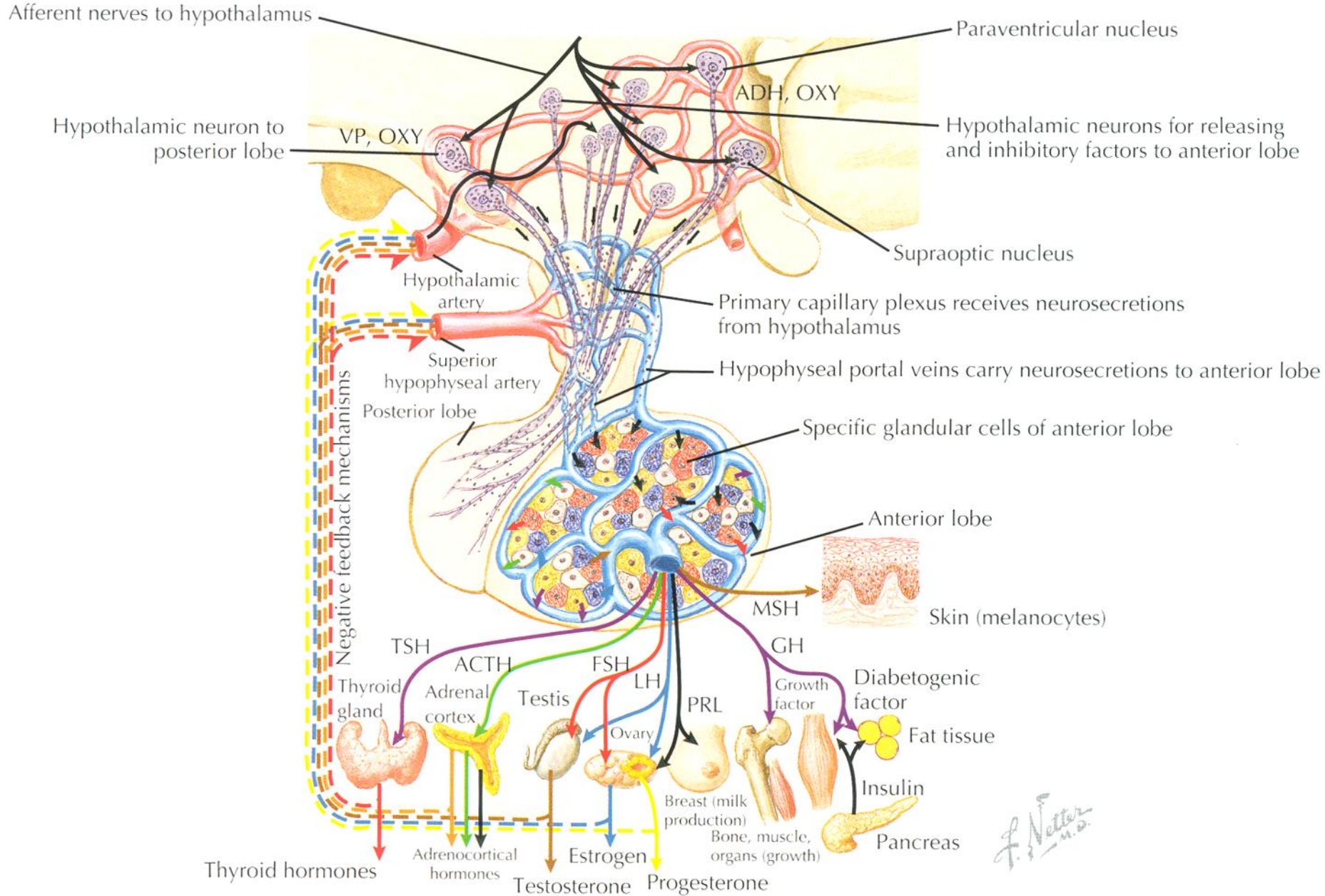
Corticotrophs hyperfunction



Cushing's syndrome



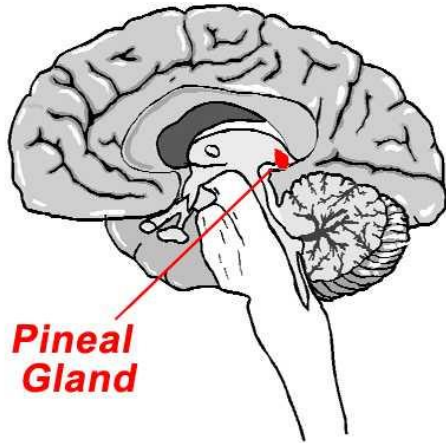
PITUITARY GLAND SUMMARY



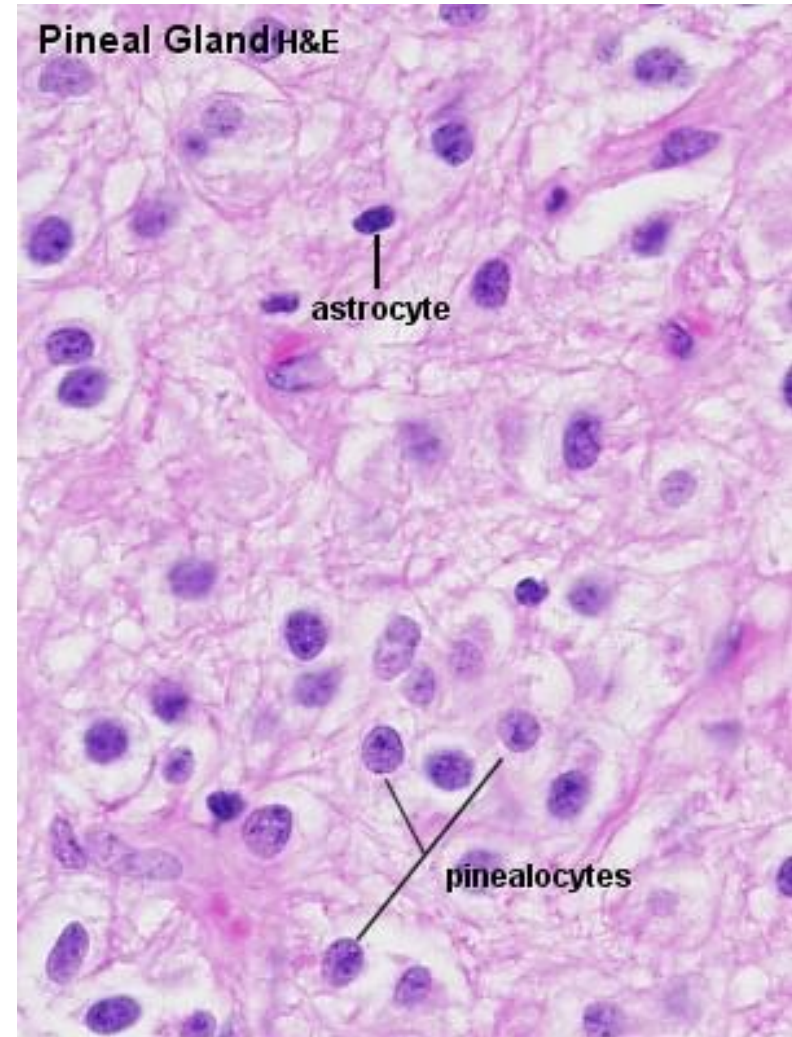
F. Netter M.D.

Anatomy		Microscopic anatomy		Hormones and target tissues				
Anterior lobe (adenohypophysis)	pars distalis	superior hypophyseal arteries → primary capillary plexus at eminentia mediana → hypophyseal portal veins → secondary capillary plexus in adenohypophysis	trabecular epithelium in cords and clusters, reticular fibers; agranular folliculo-stellate cells with so far unclear function		lack hormonal activity			
			chromophobes	undifferentiated cells degranulated chromophilic cells stromal cells				
	pars tuberalis	Rathke's cysts	chromophils	acidophilic nonglandotropic	mammotrophic cells	small polypeptides	dopamin (PIH) ⊥ PRF (?) → prolactin	mammary gland in gravidity and lactations
					somatotropic cells		somatostatin (GHIH) ⊥ GHRH → somatotropin (STH)	directly liver and growth plates other tissues via somatomedins
				basophilic glandotropic	corticotropic cells	glycoproteins	CRH → ACTH, MSH	adrenal cortex → cortisol melanocytes
	thyrotropic cells	TRH → TSH	thyroid → thyroxin, T3					
	gonadotropic cells	GnRH → FSH (ICSH), LH	gonads → androgens, estrogens, progesterone					
Posterior lobe (neurohypophysis)	eminentia mediana → infundibulum	inferior hypophyseal arteries → capillary plexus in neurohypophysis	nonmyelinated axons of hypothalamic neurons n. supraopticus, n. paraventricularis (tractus hypothalamohypophysialis), pituicytes			small peptides	ADH	tubulus reuniens, ductus colligens t.media of vessels
pars nervosa	oxytocin						myometrium of uterus during gravidity myoepithelium of lactating mammary gland	

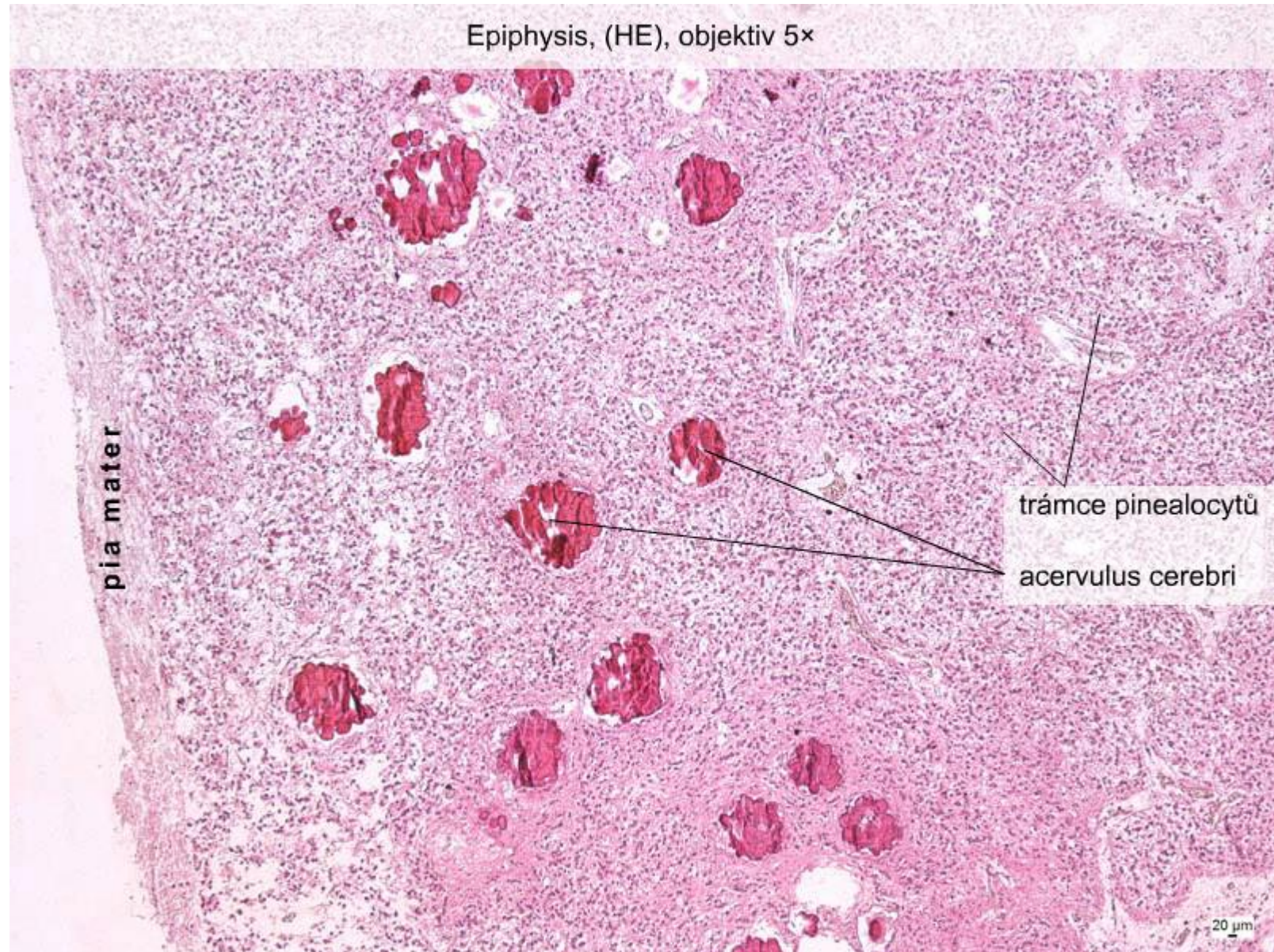
EPIPHYSIS (C. PINEALE)





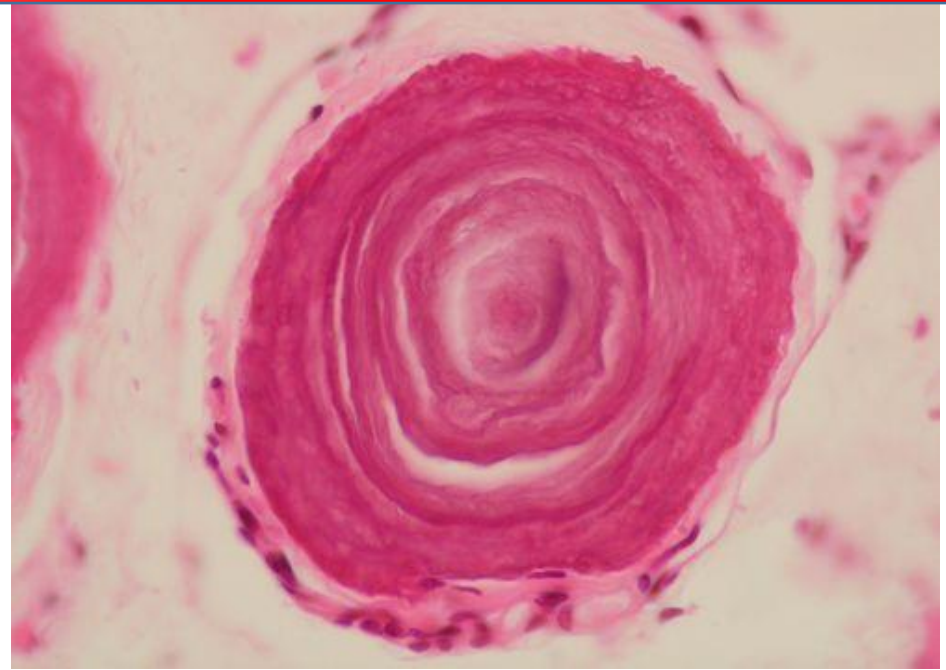
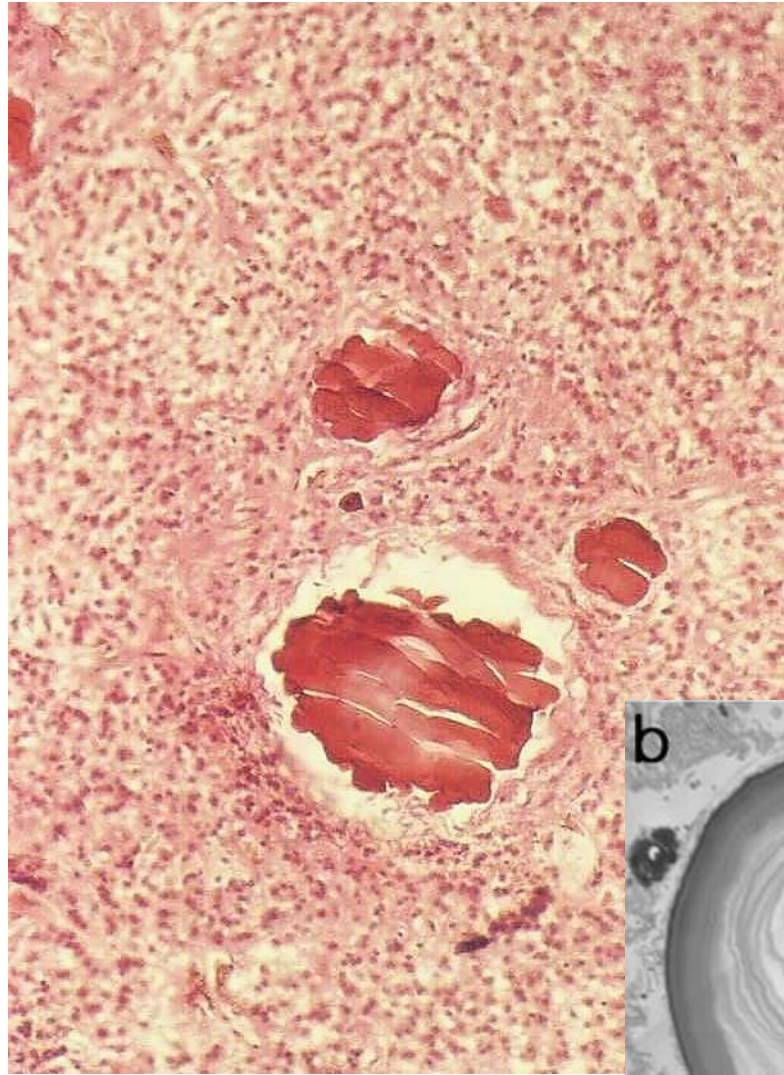
- epithalamus
- c.t. capsule continuous to pia mater
- thin c.t. septa
- non-myelinated nerve fibers
- **pinealocytes** (95%, large, pale, round nuclei)
- interstitial neuroglia (astrocytes, dark, elongated nuclei)
- *acervulus cerebri*
- melatonin



EPIPHYSIS (C. PINEALE)

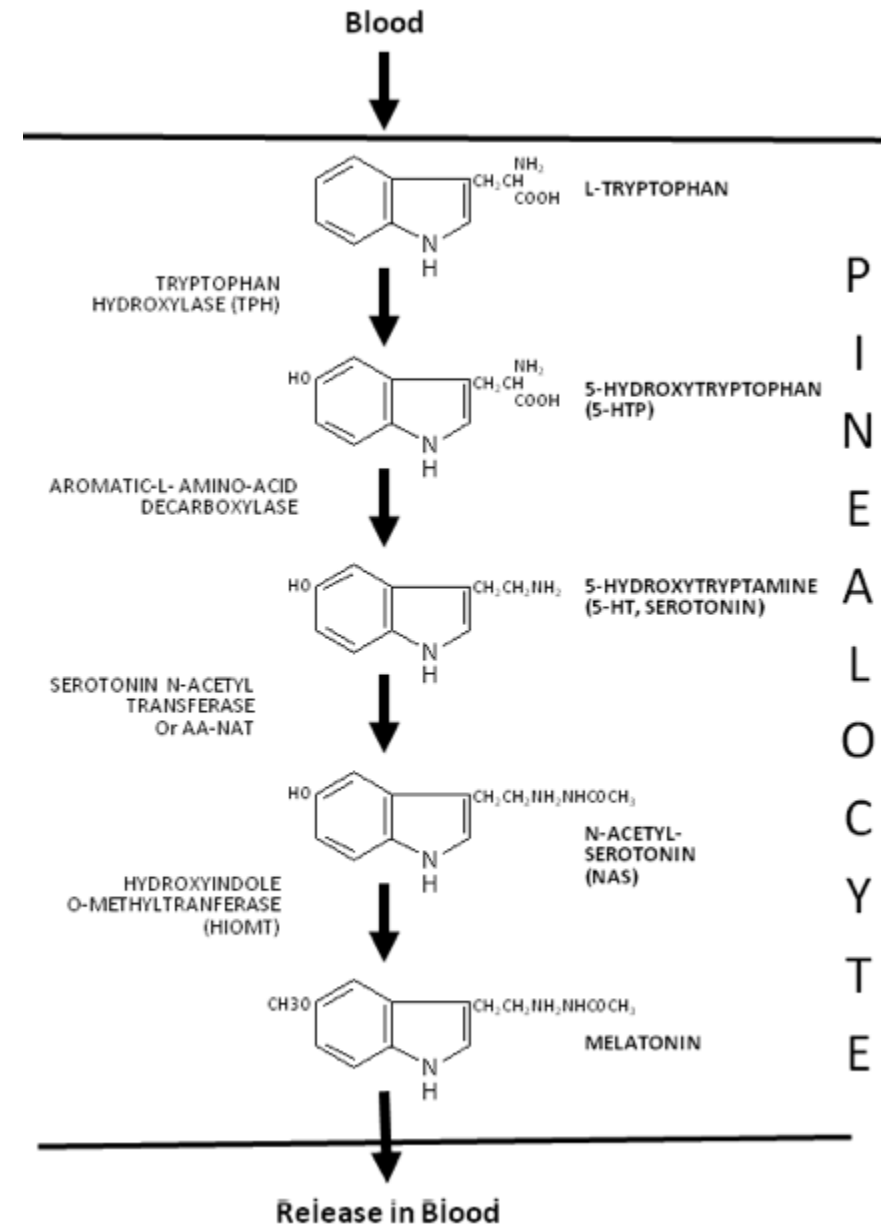


EPIPHYSIS - ACERVULUS CEREBRI



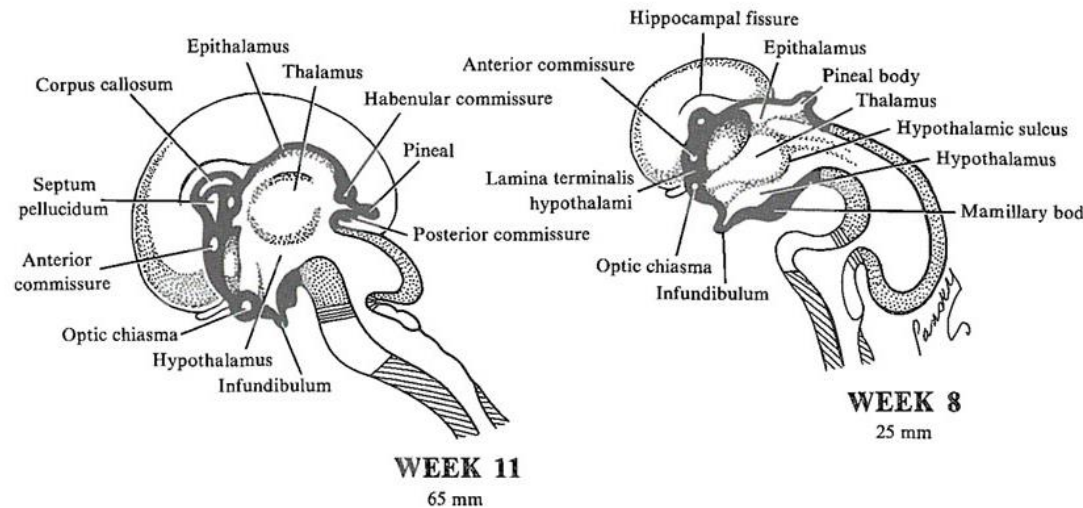
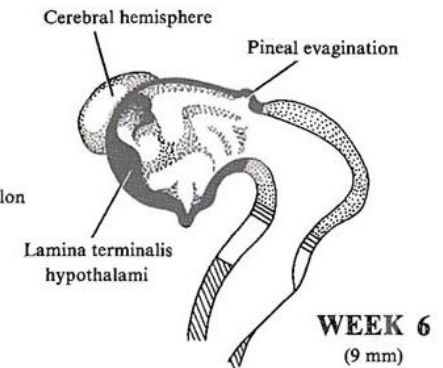
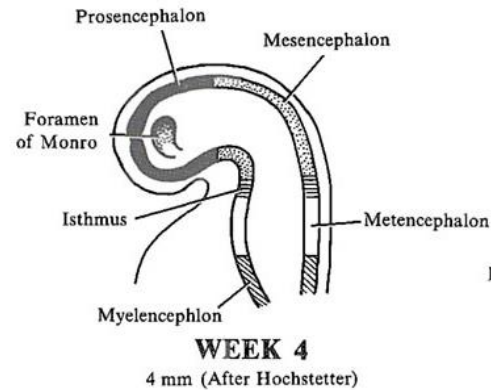
EPIPHYSIS (*C. PINEALE*)

- pinealocytes
- star-like, modified neurons in trabecules
- association with fenestrated capillaries
- neurosecretory dilatations
- nonvisual photoreception



EMBRYONIC DEVELOPMENT OF EPIPHYSIS

- thickening of caudal part of ependyma that does not contribute to development of choroid plexus at the roof of diencephalon
- neuroectoderm



WEEK 8
25 mm

Anolis



Parietal eye



Sphenodon



THYROID GLAND (GL. THYROIDEA)

- Follicular cells → thyroid hormones (T3, T4)
- **C cells** → calcitonin

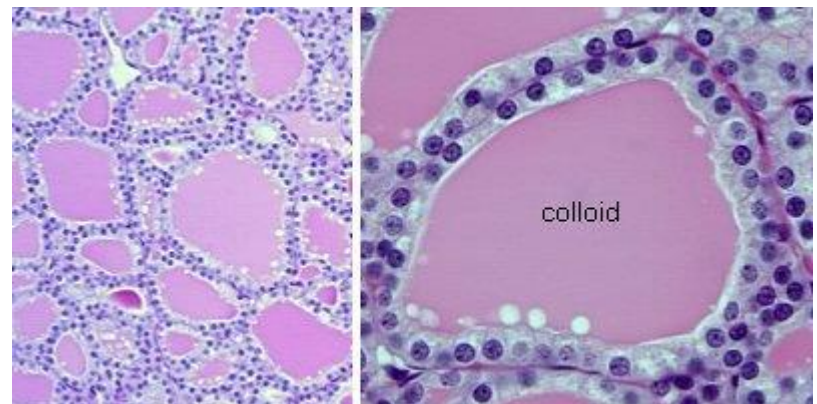
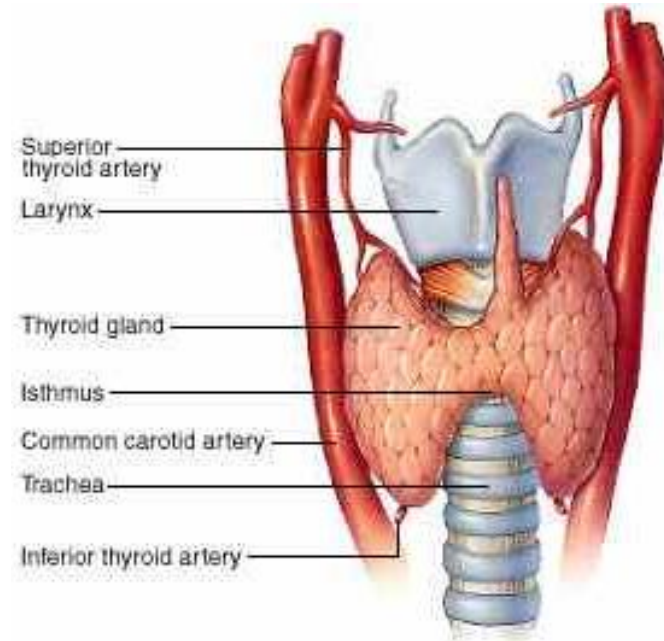
C.t. capsule, septa

Lobes → lobuli - follicles

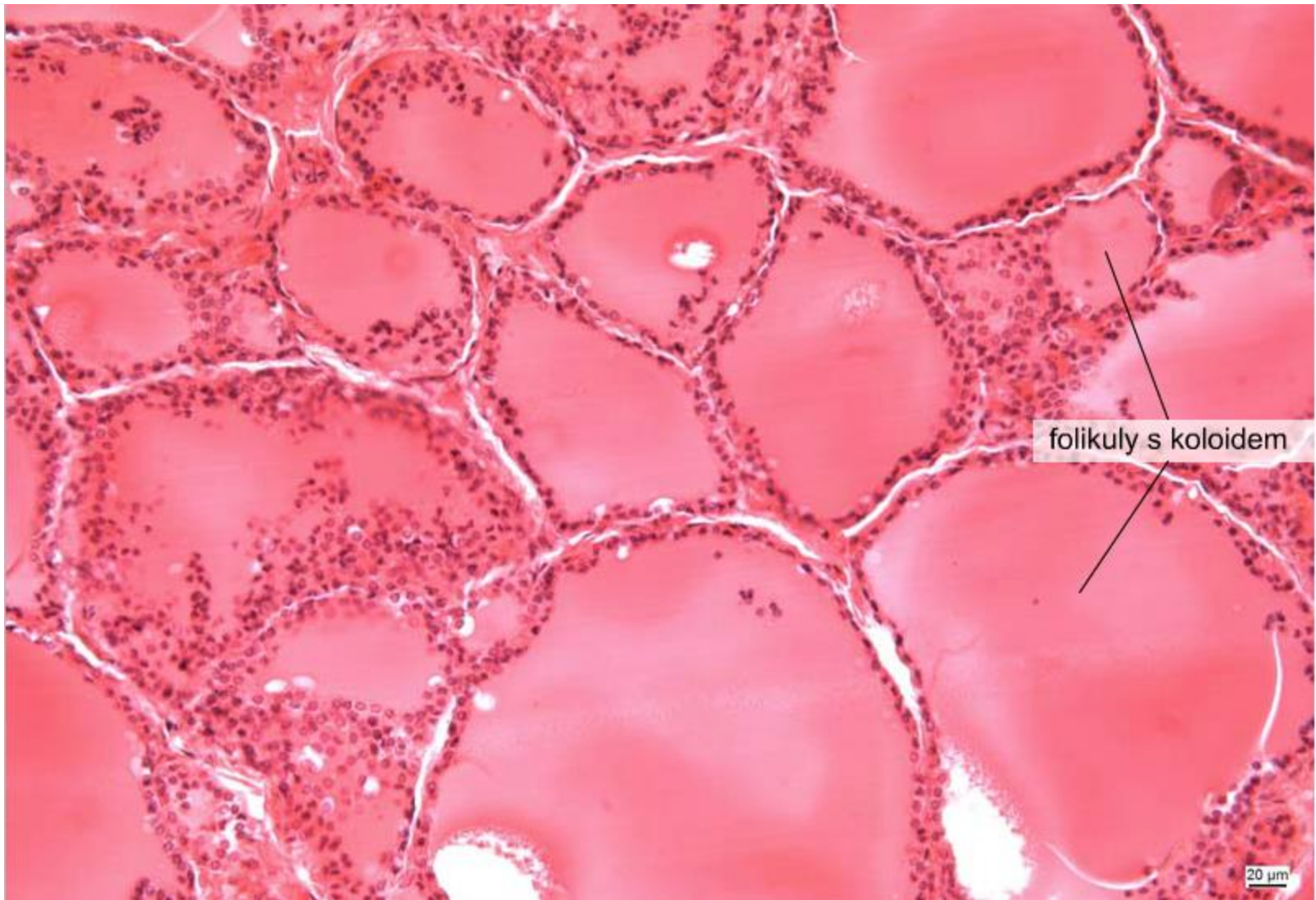
Follicles (50 μm - 1 mm)

- separated by interstitial loose collagen c.t.
- simple epithelium (flat to cubic, according to their secretory activity)
- colloid

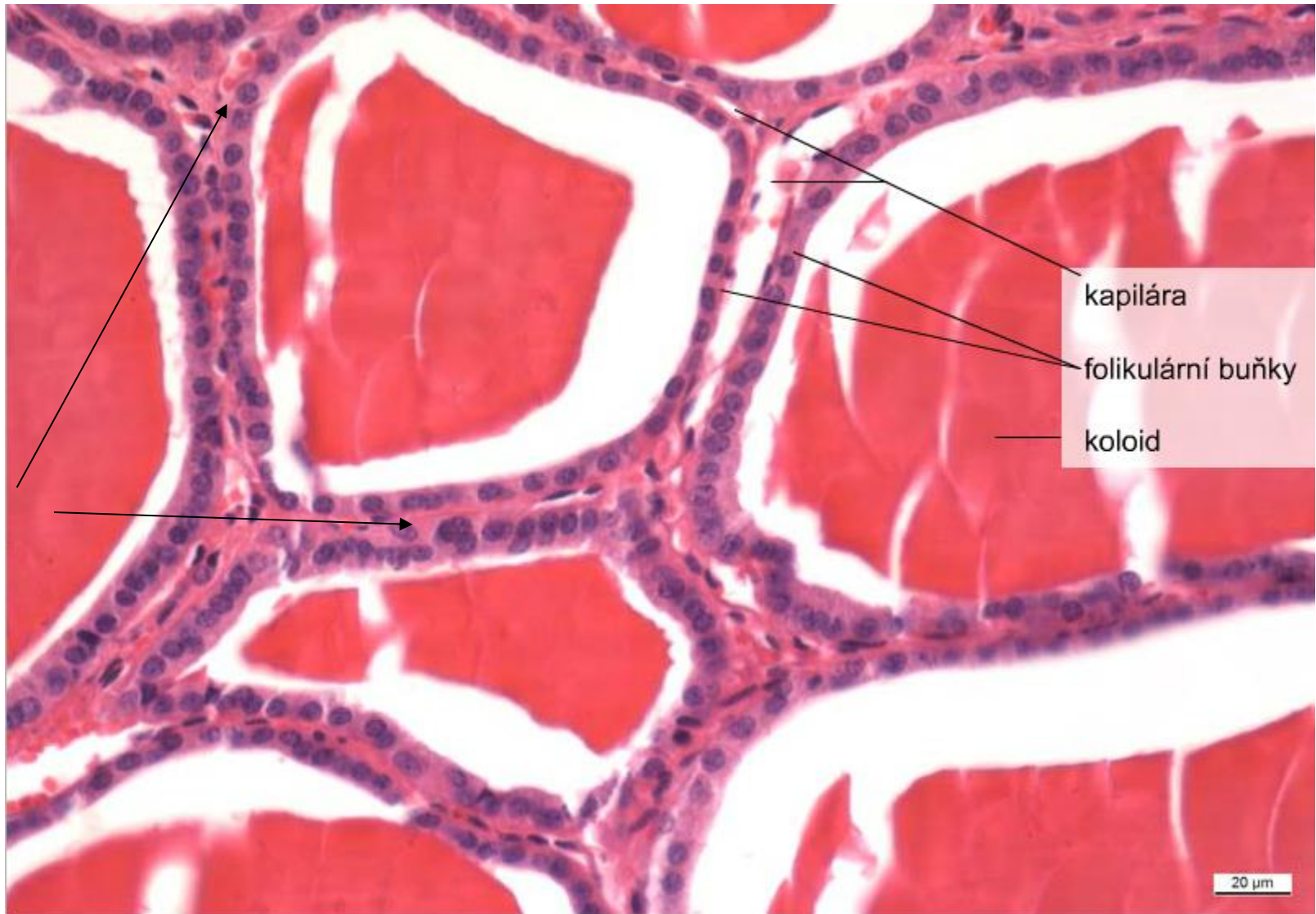
Capillary network from thyroid arteries



THYROID GLAND - FOLLICLES



THYROID GLAND - FOLLICLES



C-cells

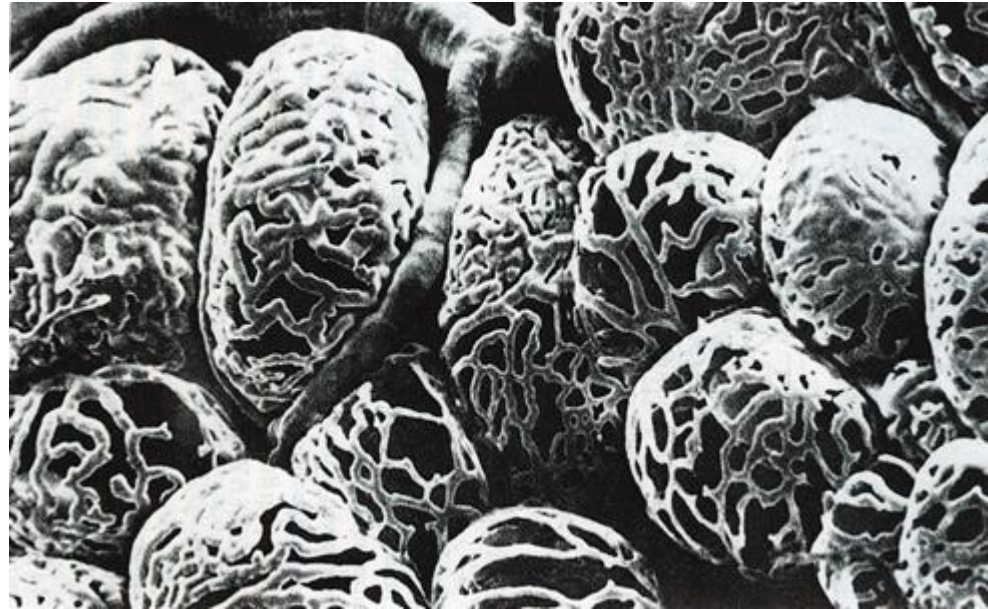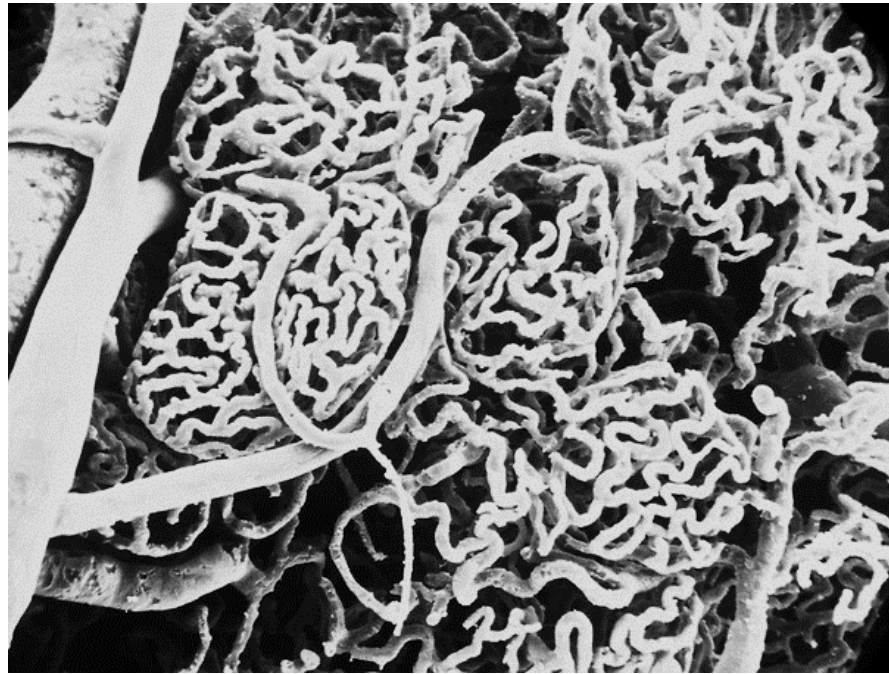kapilára
folikulární buňky
koloid

20 µm

Follicular cells and C-cells (parafollicular)

FOLLICLES OF THYROID GLAND

Capillaries around thyroid follicles



T3 and T4

T4 synthesis in thyroid

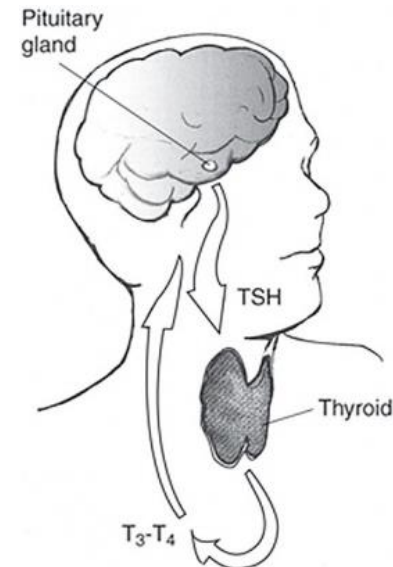
- sodium-iodide symporter transports two Na^+ and one I^- across the basement
- I^- is moved across the apical membrane into the colloid of the follicle.
- thyroperoxidase oxidises $2 \text{I}^- \rightarrow \text{I}_2$.
- thyroperoxidase iodinates the tyrosyl residues of thyroglobulin
- (TSH) stimulates the endocytosis of the colloidal content
- endocytic vesicles + lysosomes, lysosomal enzymes cleave T_4 from the iodinated thyroglobulin
- exocytosis

T3 synthesis from T4

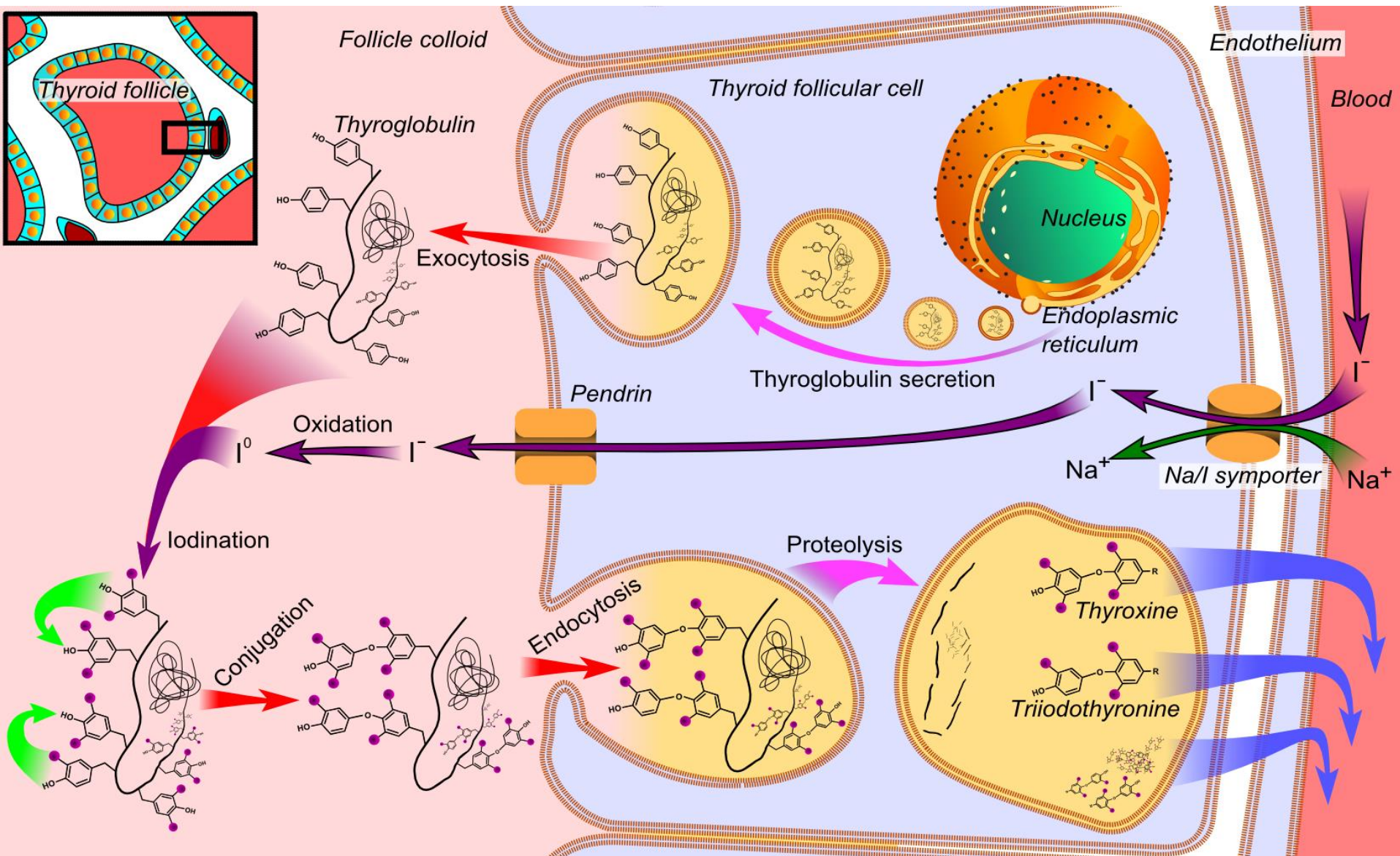
- T4 half-life in blood 6.5 days, T3 2.5 (T4 is a reservoir for T3)
- deiodination by tissue specific deiodinase enzymes generates T3

Critical for brain development

Metabolism (nitrogen balance, proteosynthesis, lipolysis)



THYROID GLAND – T3 AND T4 HORMONES



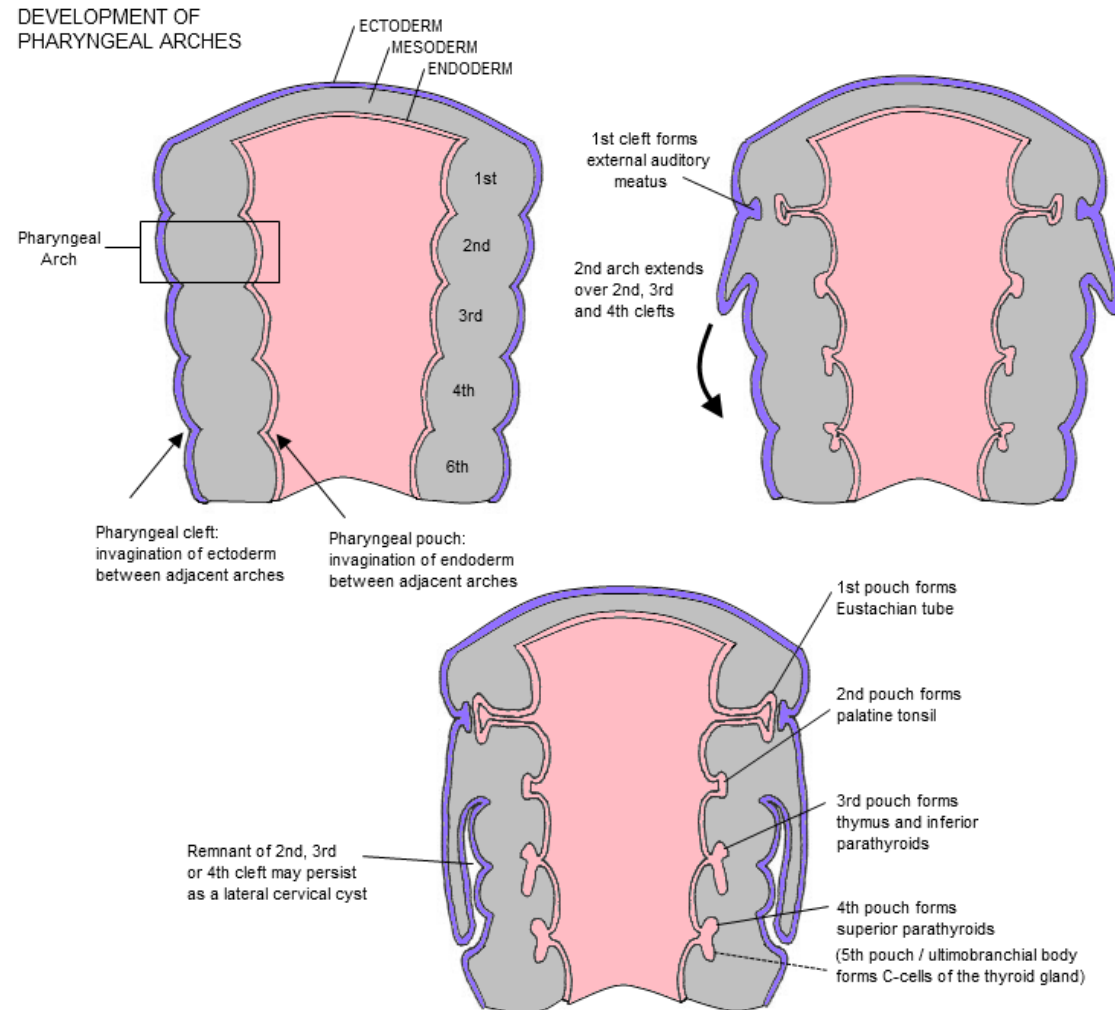
C cells of thyroid

Neuroendocrine cells

- pale staining
- epithelial basis, under basal lamina no contact with colloid
- derived from neural crest
- associate with ultimobranchial body, (derivative of the 4th pharyngeal pouch)

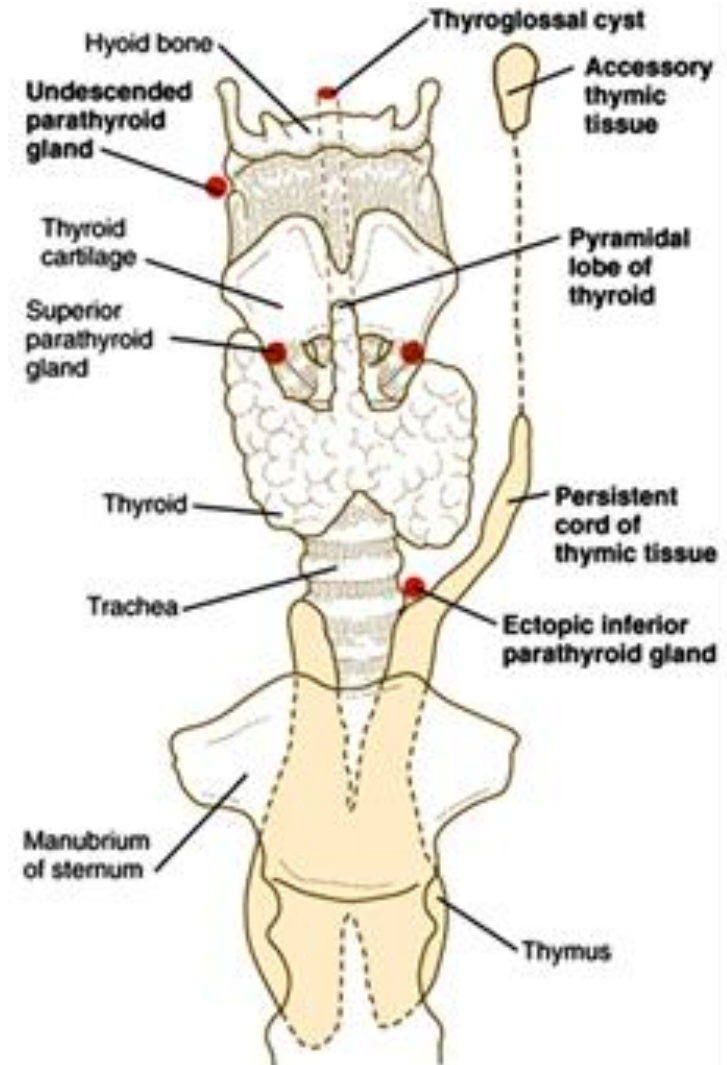
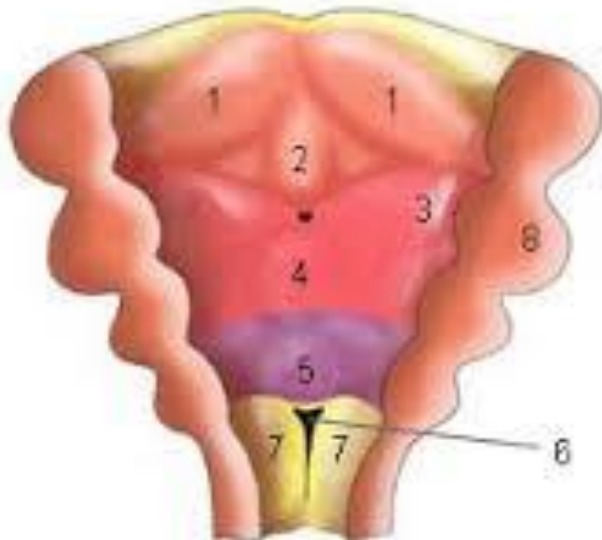
Calcitonin

- inhibition of osteoclasts



EMBRYONIC DEVELOPMENT OF THYROID GLAND

- endodermal proliferation of pharyngeal floor
- ductus thyreoglossus originates between tuberculum impar and copula
- bilobed civerticulum, lobus pyramidalis
- obliterated d. thyreoglossus – foramen caecum
- ectopic thyroid tissue



PARATHYROID GLAND (GL. PARATHYREOIDEA)

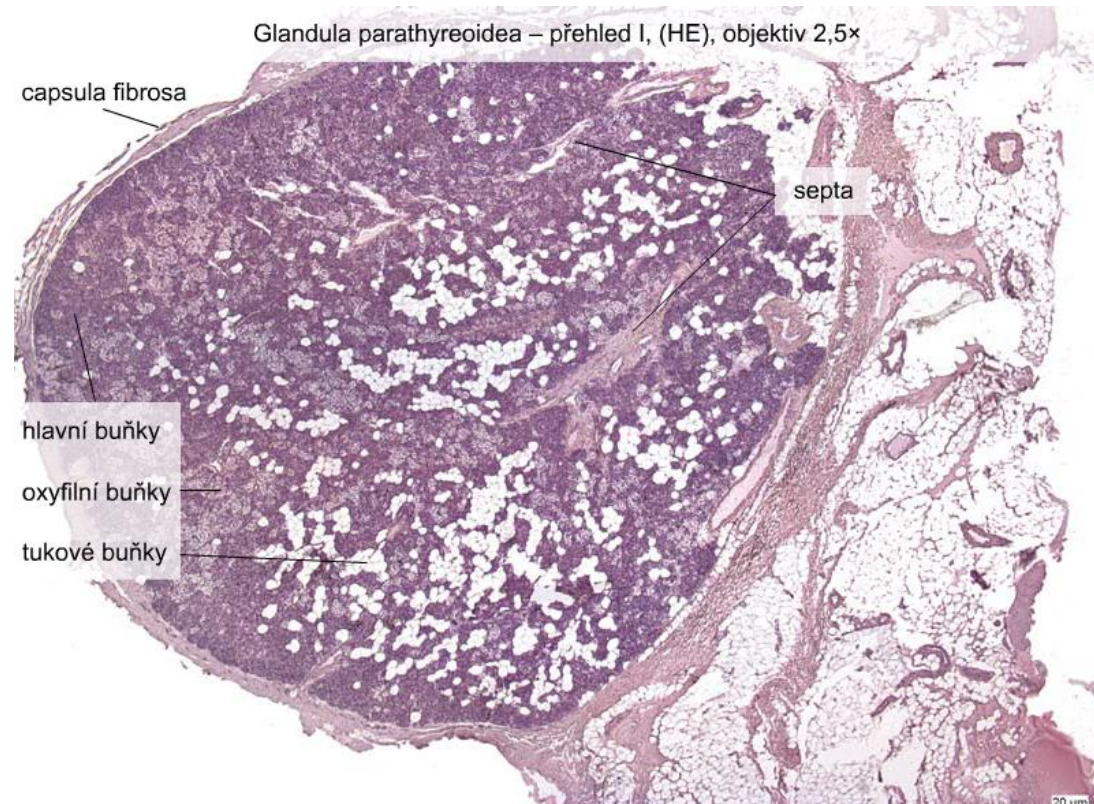
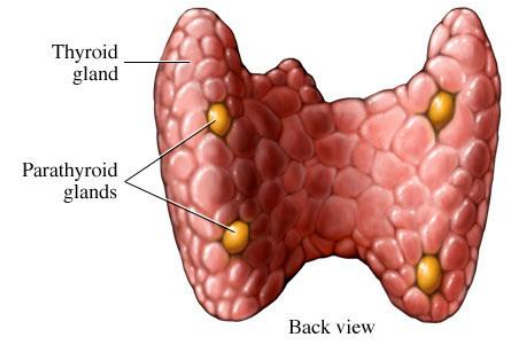
6 mm, 130 mg

c.t. capsule and septa

Capillary network

Cords and clusters of glandular cells

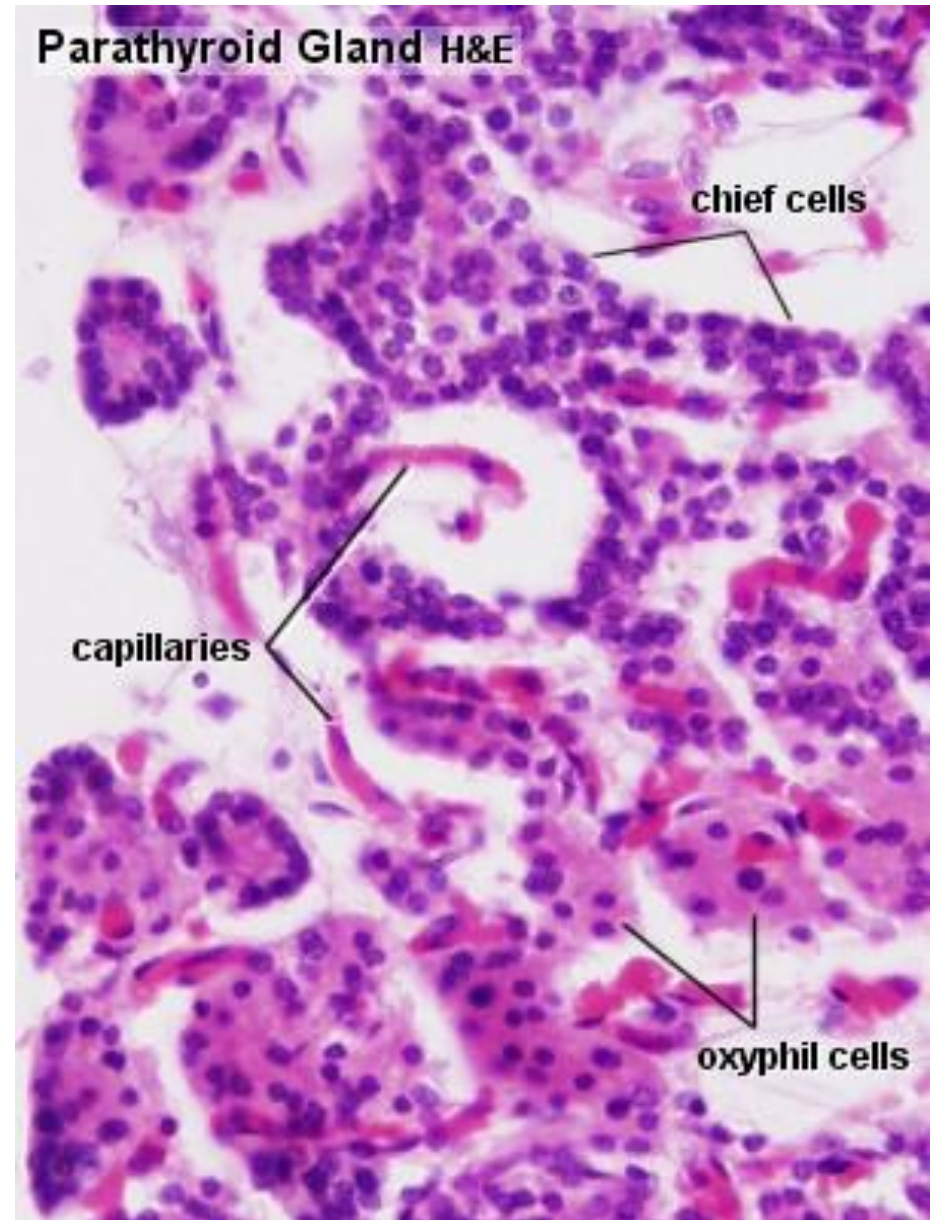
- Chief
- Oxyphilic
- Adipose



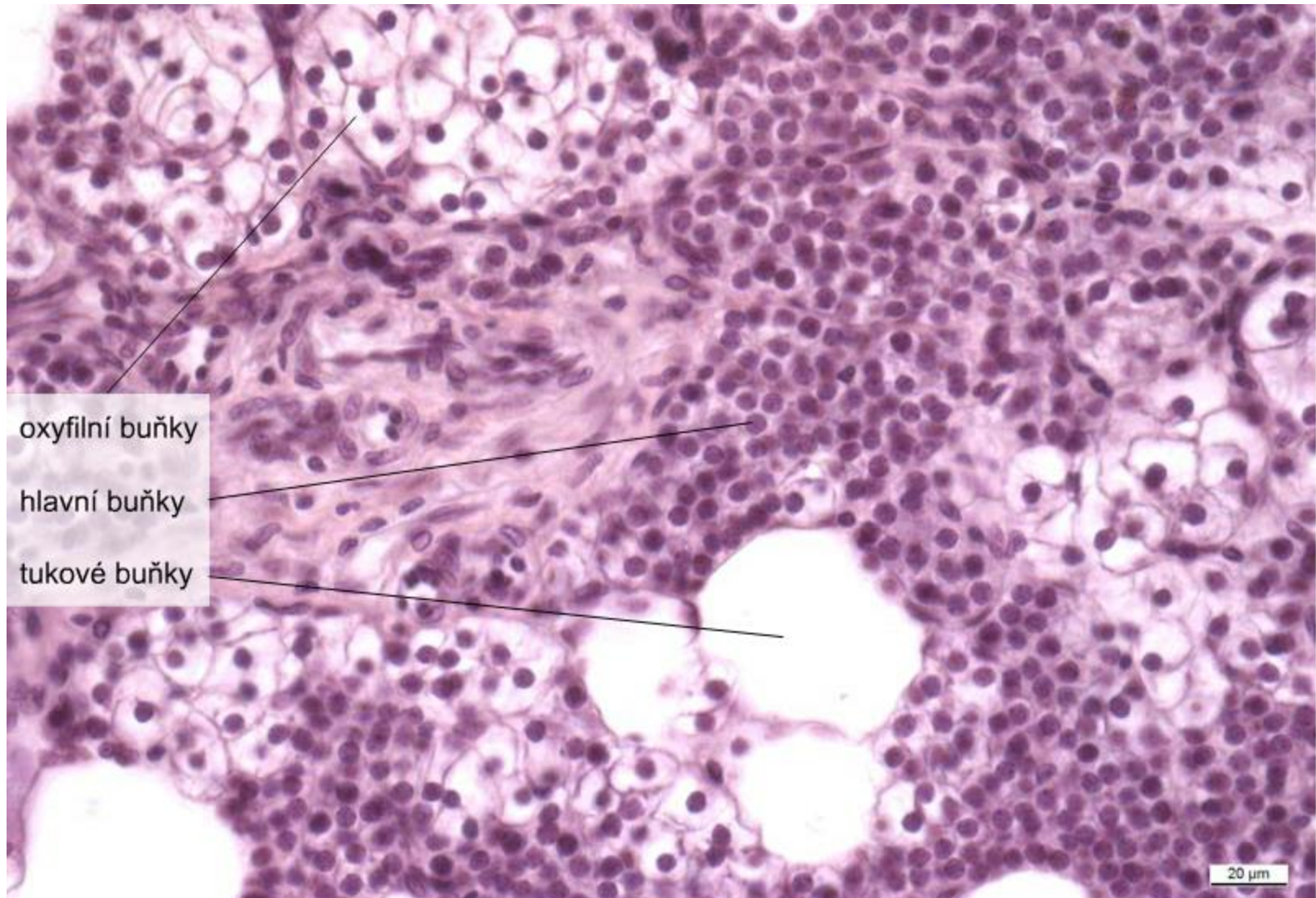
PARATHYROID GLAND (GL. PARATHYREOIDEA)

- **Chief**
 - most abundant
 - small cells (7-10 μ m, big nucleus
 - mildly acidophilic
 - PTH – calcium metabolism

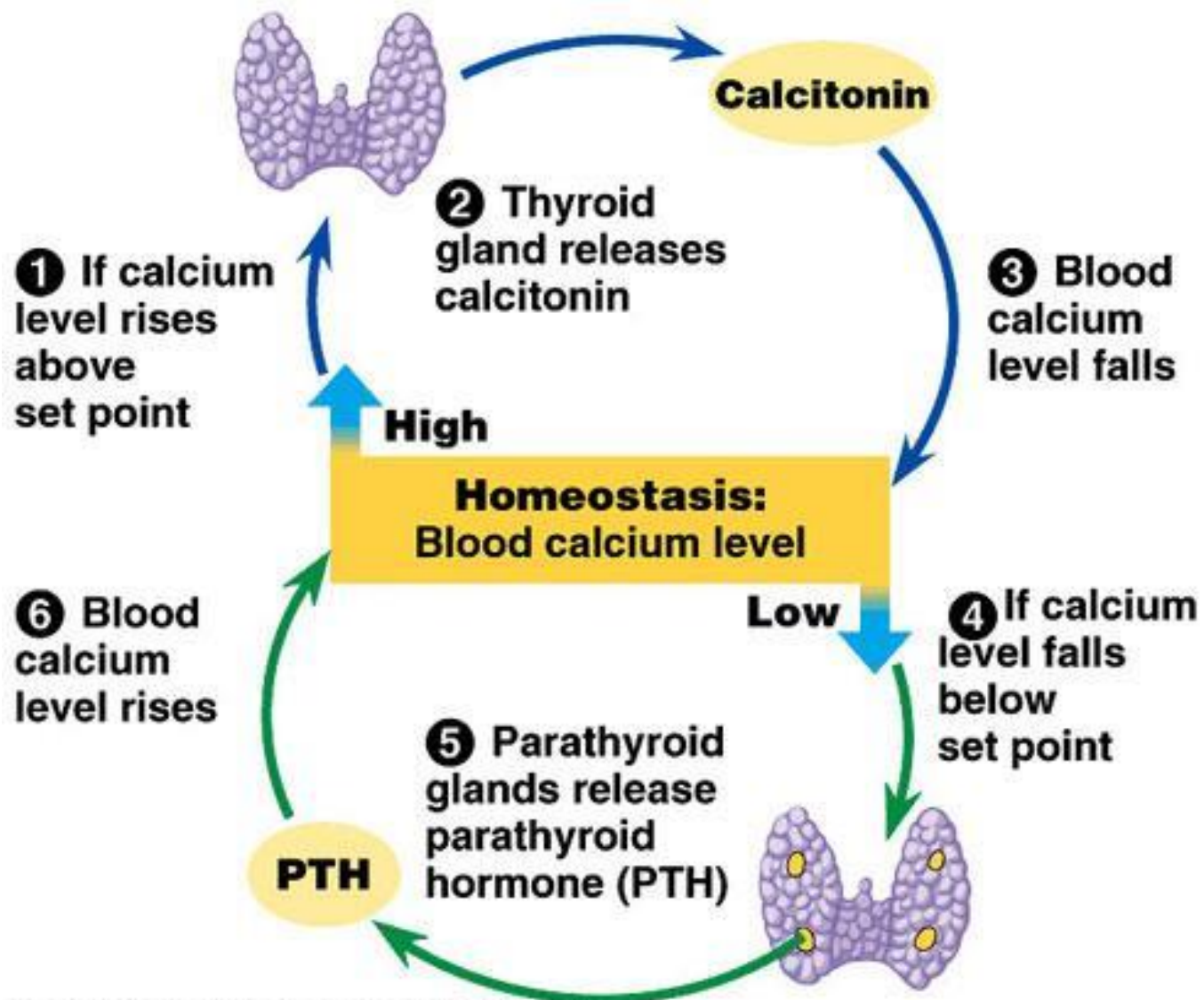
- **Oxyphylic**
 - large, polyhedral,
 - strongly acidophilic
 - round nucleus
 - glycogen



PARATHYROID GLAND (GL. PARATHYREOIDEA)

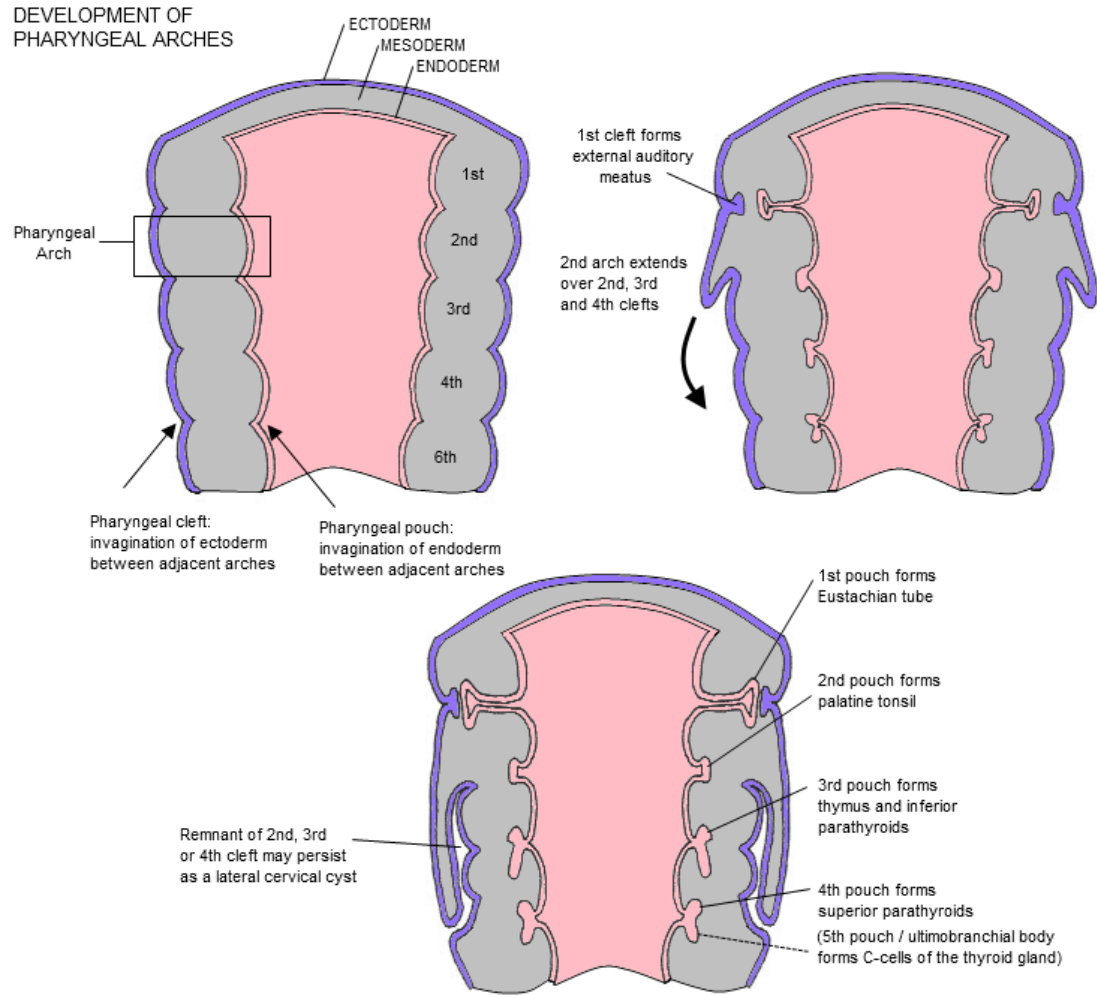


PTH vs. CALCITONIN

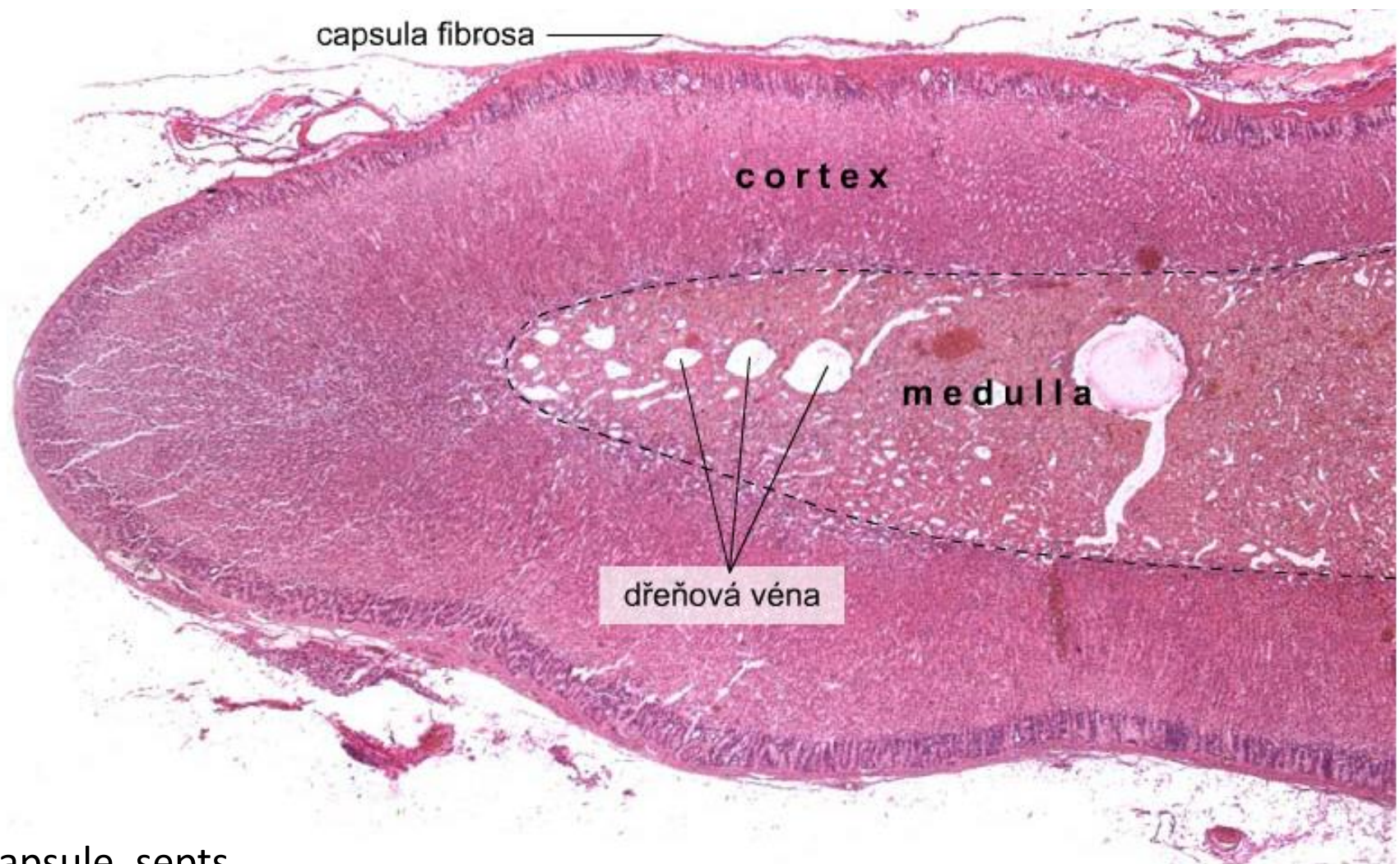


EMBRYONIC DEVELOPMENT OF PARATHYROID GLAND

- *glandulae parathyroideae superiores* from endoderm of **4th pharyngeal pouch**
- *glandulae parathyroideae inferiores* from dorsal process of **3rd pharyngeal pouch**
- together with thymus descend to lower poles of thyroid
- ectopic PTH gland in thymus or mediastinum



ADRENAL GLAND (*CORPUS SUPRARENALE*)



c.t. capsule, septs
capillary plexus

ADRENAL GLAND DEVELOPMENT

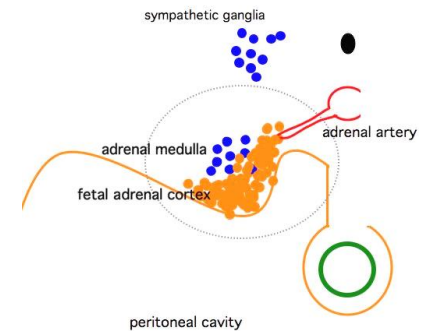
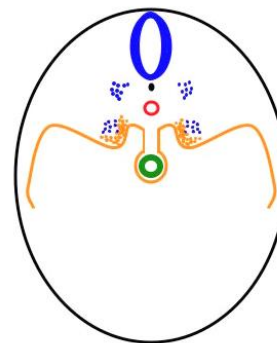
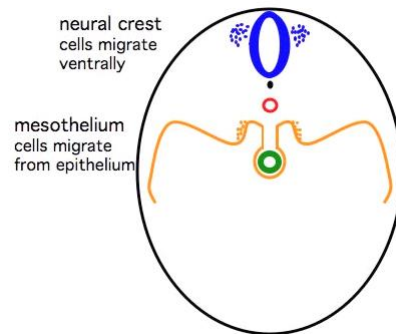
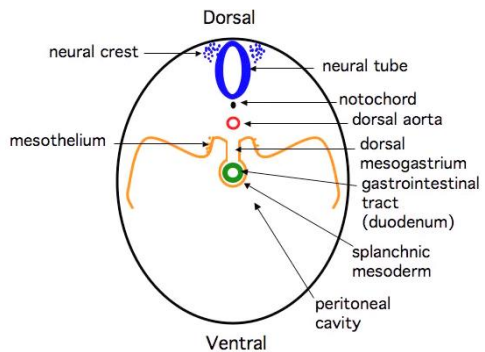
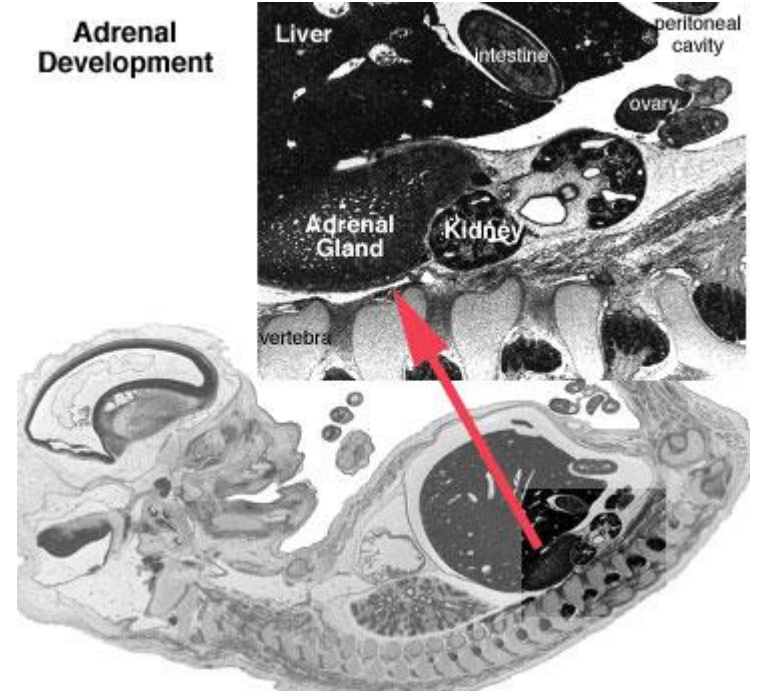
cortex

- mesoderm
- mesothelium, coelomic epithelium

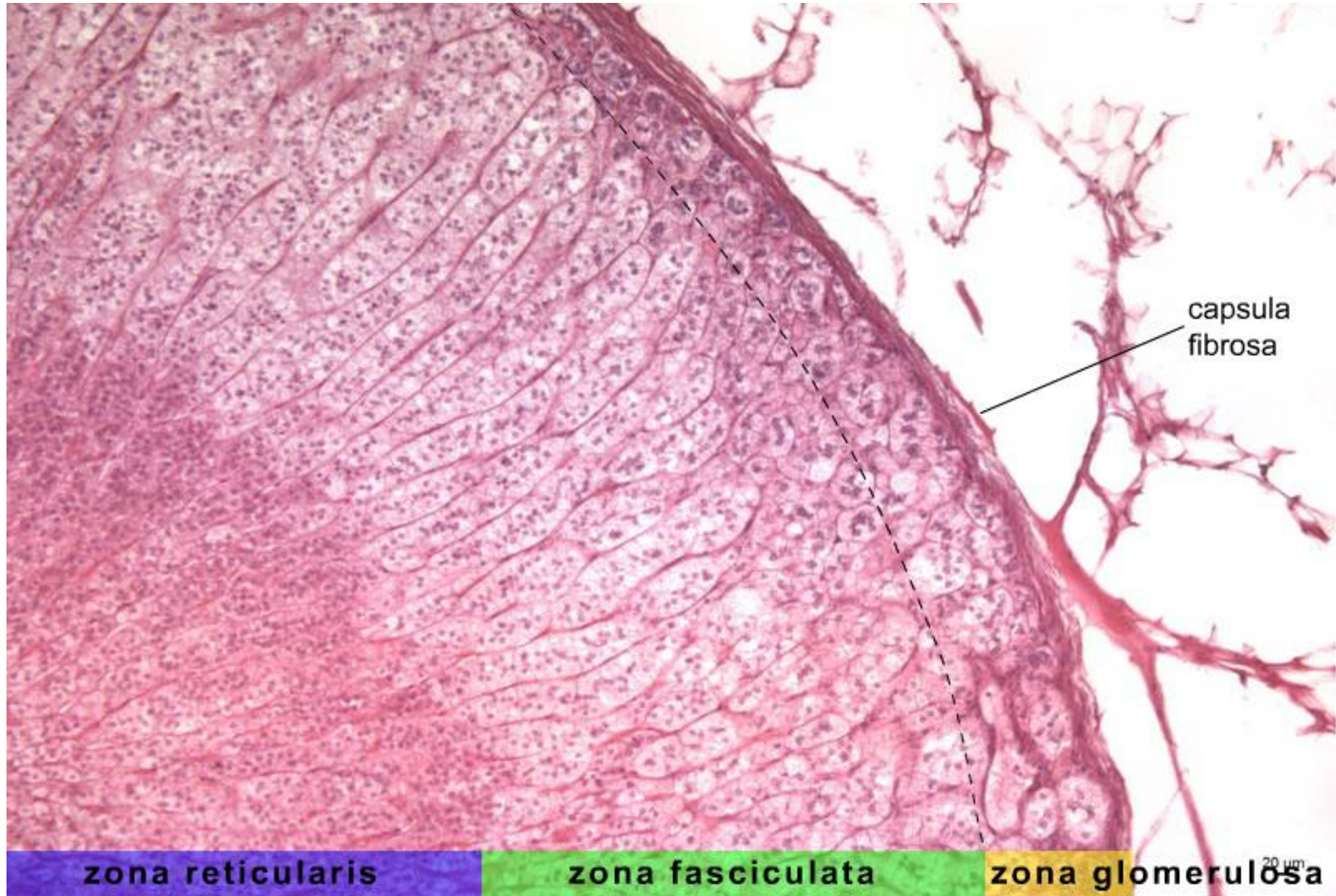
medulla

- neural crest

Adrenal Development

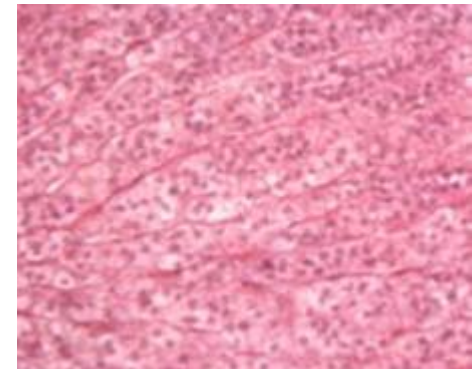
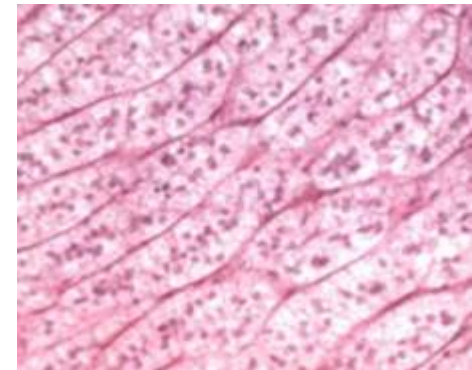
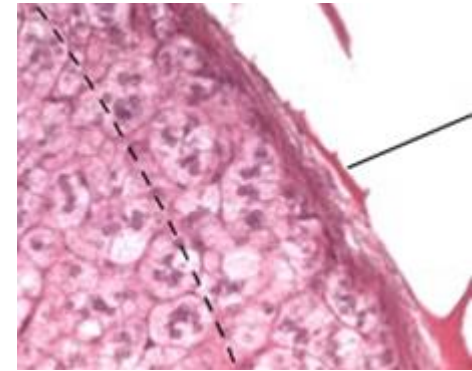


ADRENAL CORTEX



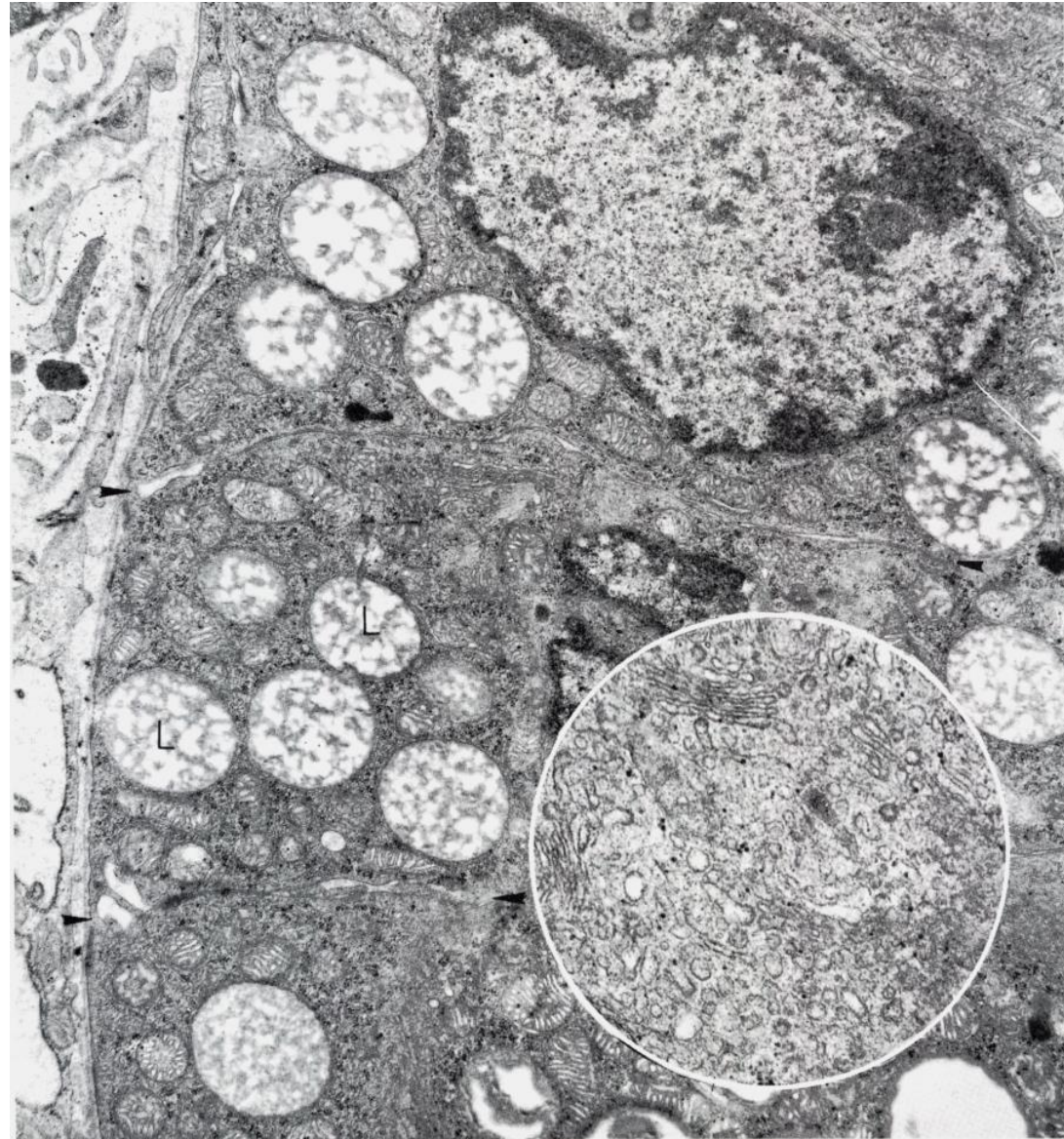ADRENAL CORTEX

- **Zona glomerulosa (1/10)**
 - thin layer under c.t. capsule
 - relatively small cells in coiled glomeruli
 - not so abundant lipid droplets
 - **mineralocorticoids**
- **Zona fasciculata (6/10)**
 - radially arranged trabeculae
 - lipid droplets in cytoplasm
 - **glucocorticoids**
- **Zona reticularis (3/10)**
 - branched trabeculae
 - small, acidophilic cells
 - lipofuscin
 - **androgen precursors**

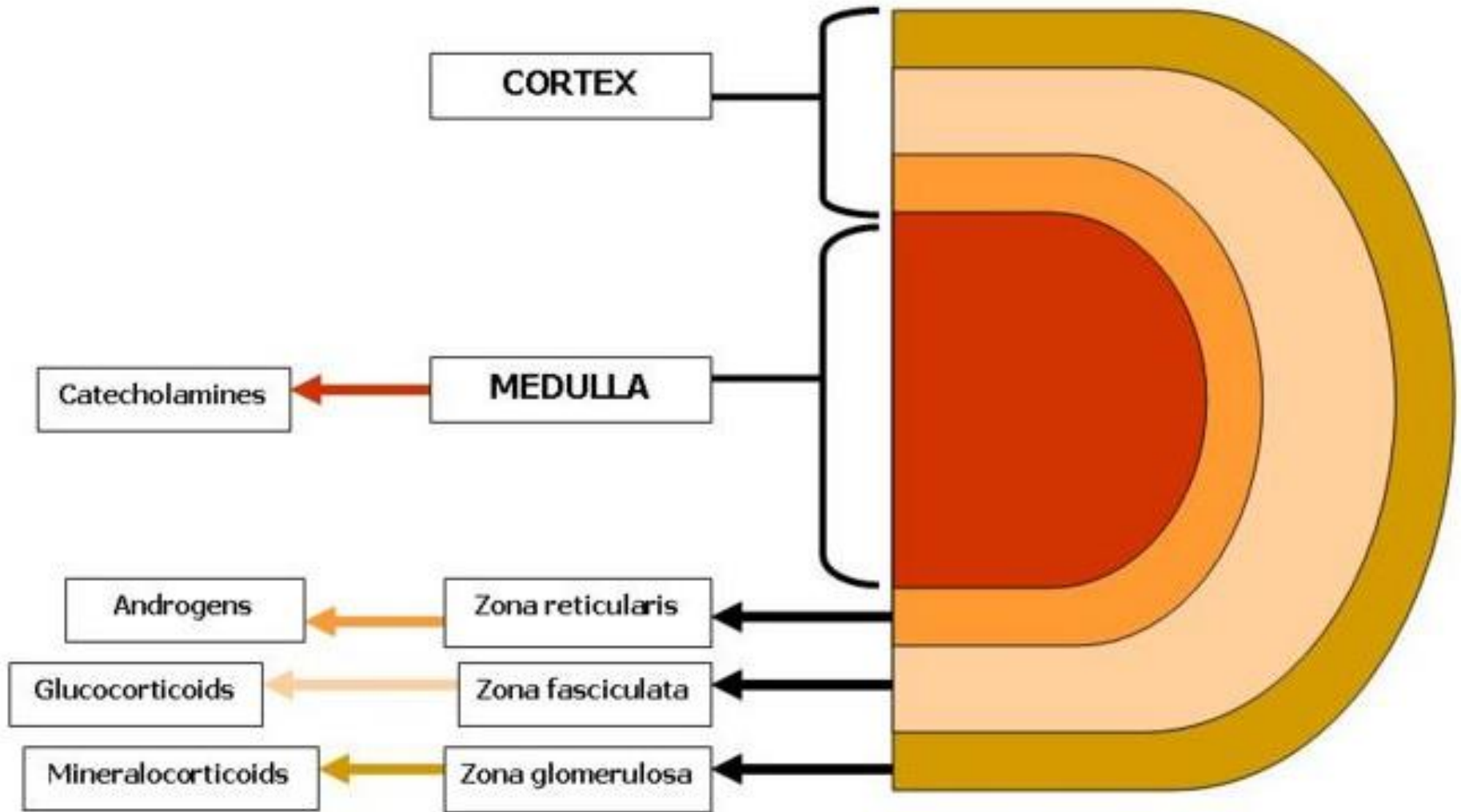


ADRENAL CORTEX HORMONE

- Steroids produced in cortex = CORTICOSTEROIDS
- Steroidogenic cells
 - SER, lipid droplets, mitochondria
 - *mineralocorticoids*
 - *glucocorticoids*
- **Aldosteron** – *zona glomerulosa*
- **Cortisol** – *zona fasciculata*
- **Androgens, estrogens, progesteron** – *zona reticularis*



ADRENAL HORMONES

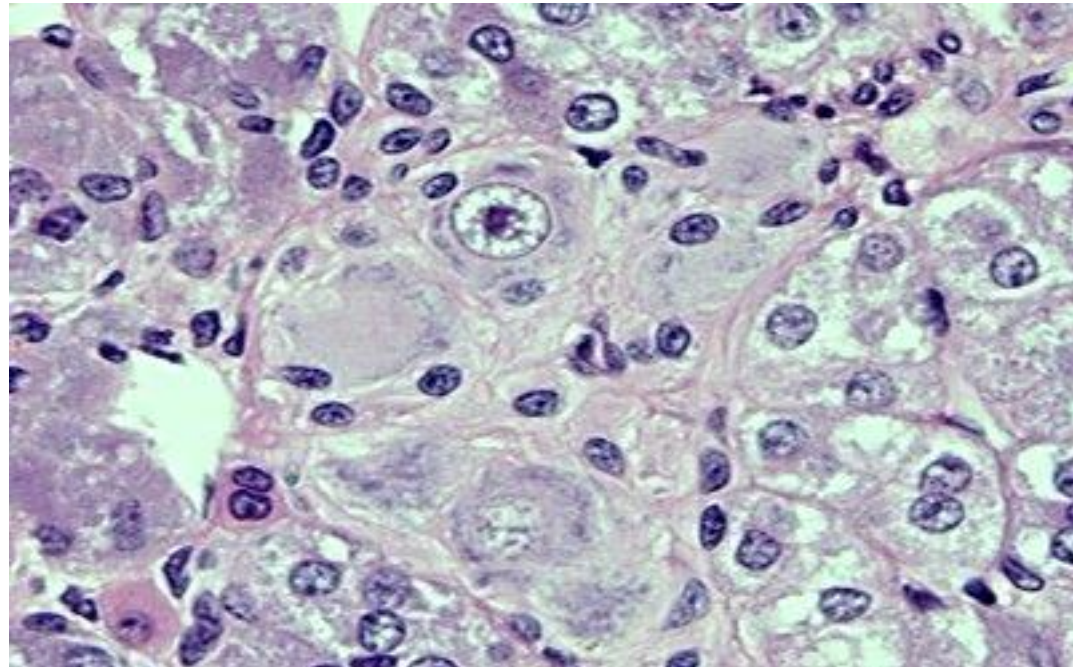


ADRENAL MEDULLA

Clusters of glandular cells in reticular c.t.

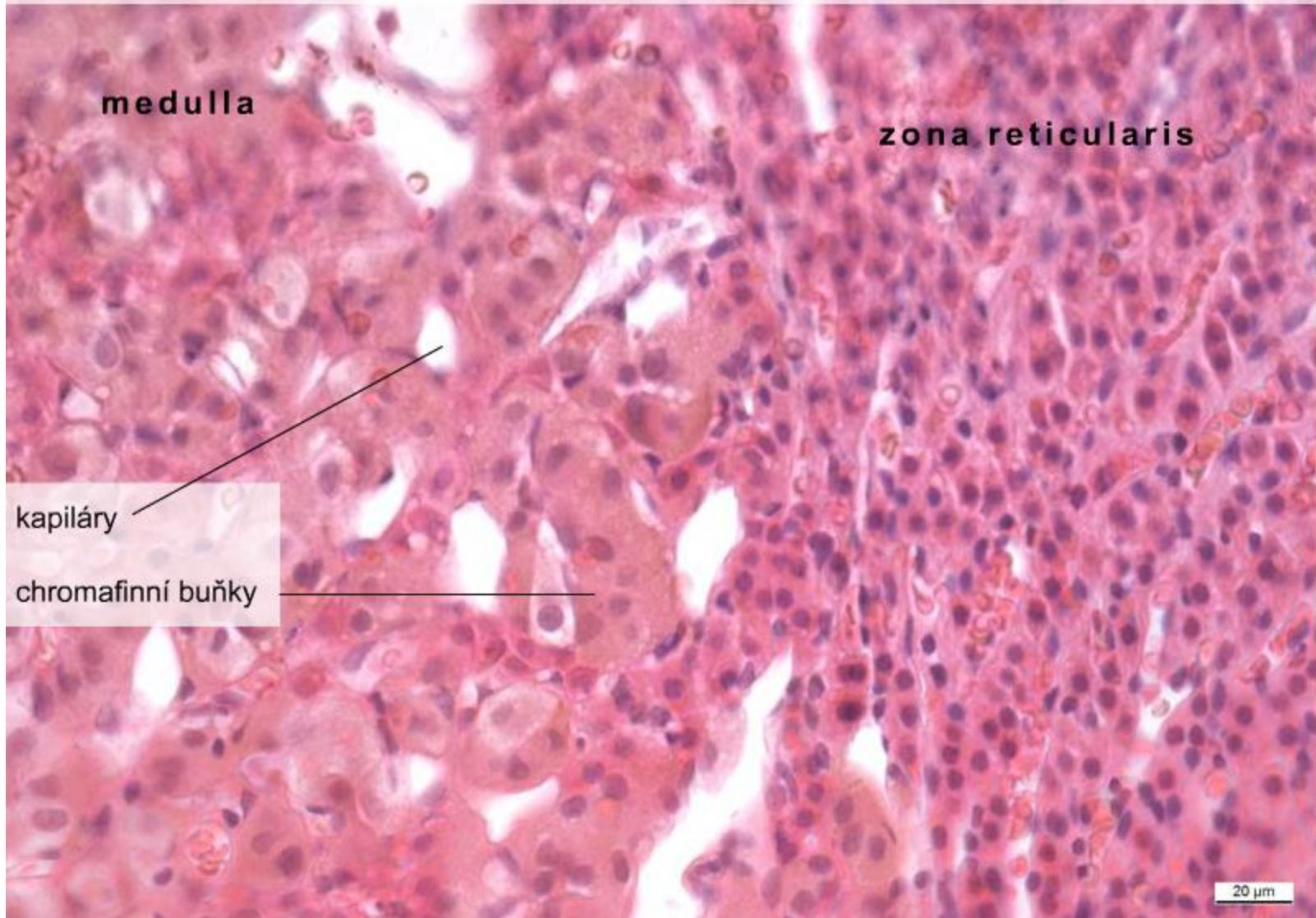
- chromaffin cells – modified postganglionic neurons
- ganglionic cells
- capillaries, venules, nerve fibers
- **adrenaline and noradrenaline**

Neural crest origin



ADRENAL MEDULLA

Corpus suprarenale – medulla, (HE), objektiv 40×



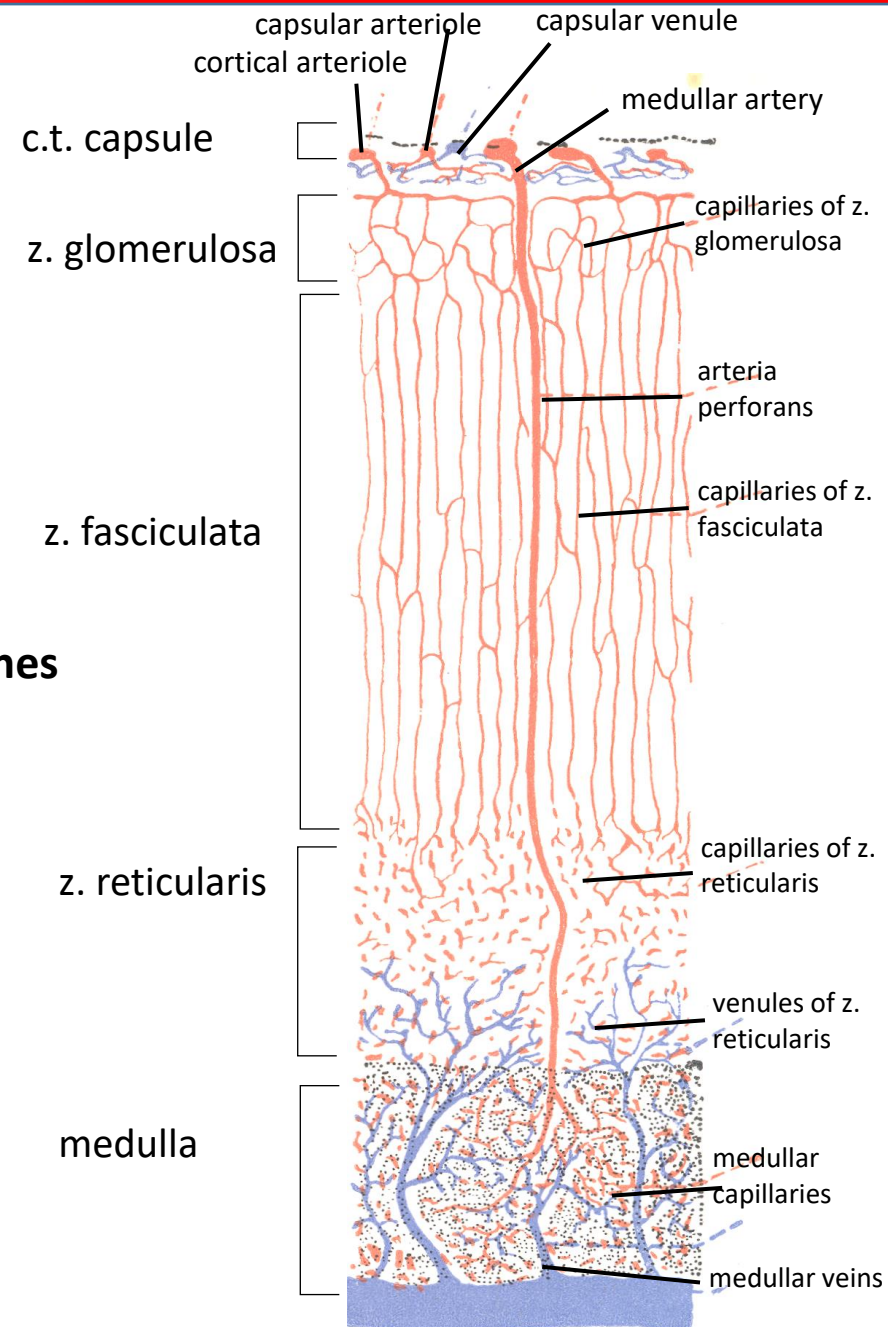
ADRENAL VASCULARISATION

arteriae suprarenales (3) → arterial plexus in cortex under c.t. capsule → radially oriented fenestrated sinusoid capillaries continuous with medullar capillaries → medullar veins → *v. suprarenalis*

→ Medullary cells influenced by cortical hormones

three arterial regions

- 1) c.t. capsule and superior parts of cortex
- 2) radial capillaries of cortex continuing to medulla
- 3) medullar capillaries from *aa. perforantes*



Adrenal hormones

Region (zone)		Hormone	Target tissue	Hormonal effect	Control
Cortex	Zona glomerulosa	Mineralocorticoids (aldosteron)	Kidney	Increased renal reabsorption of Na ⁺ and water Synergic to ADH Excretion of K ⁺	renin-angiotensin system, high level of K ⁺ low level of Na ⁺
	Zona fasciculata	Glucocorticoids (hydrocortison)	Most cells	Release of aminoacids from muscles and lipids from fat tissue, peripheral utilization of lipids, antiinflammatory effects	Stimulation by ACTH
	Zona reticularis	Androgens (dehydroepiandrosterone)	Most cells	In adult males not significant Children and women growth of bones, muscles, hematopoiesis	Stimulation by ACTH
Medulla		Epinefrine, norepinefrine	Most cells	Increased heart activity, centralization of circulation, bronchodilatation, glycogenolysis, regulation of glycemia	Sympaticus

STRESS

Hypothalamus

CNS
(sympathicus)

Pituitary gland

ACTH

Adrenal medulla

Adrenal cortex

Adrenaline

- blood pressure,
vasoconstriction, heart rate...

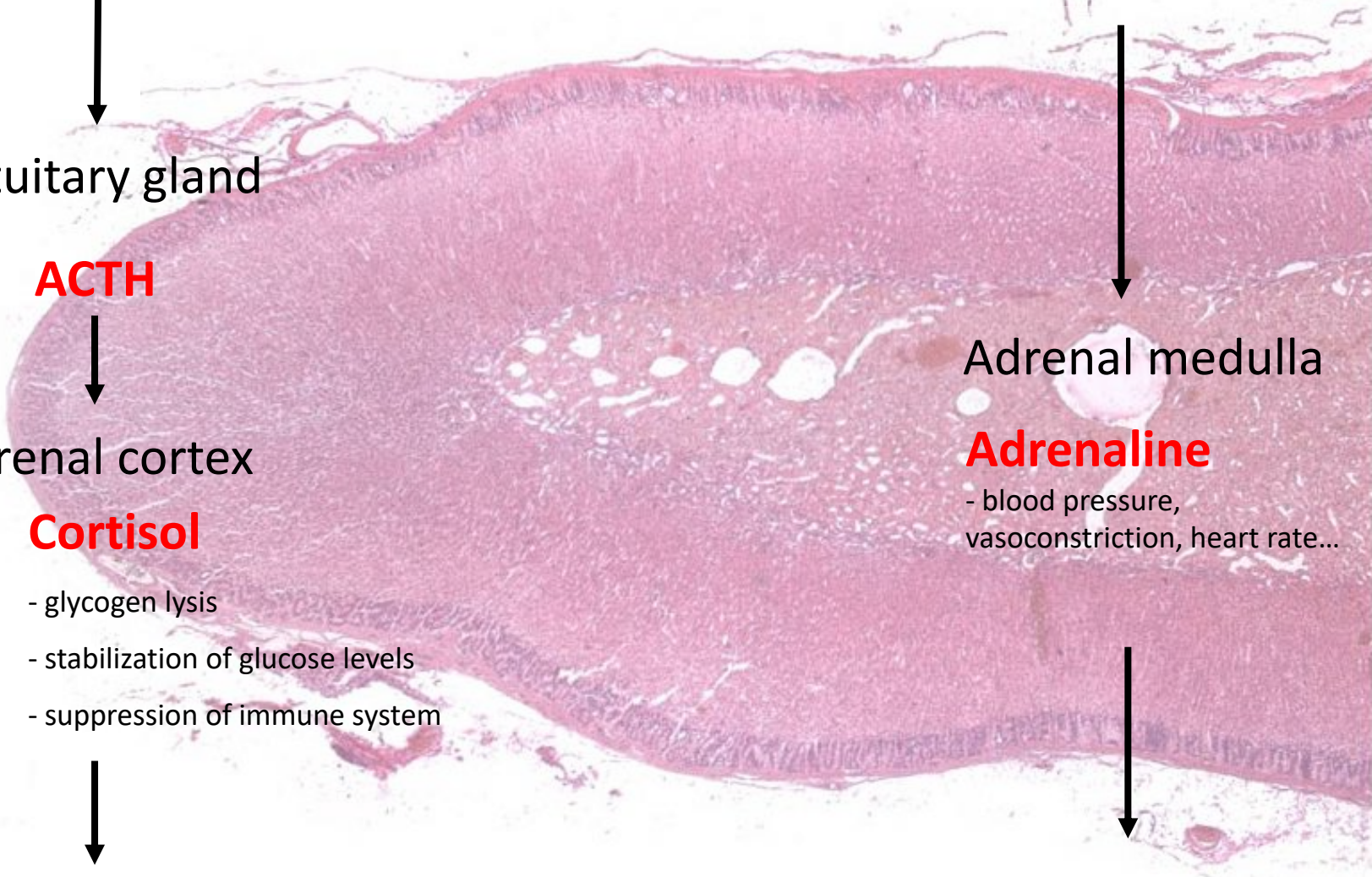Cortisol

- glycogen lysis
- stabilization of glucose levels
- suppression of immune system

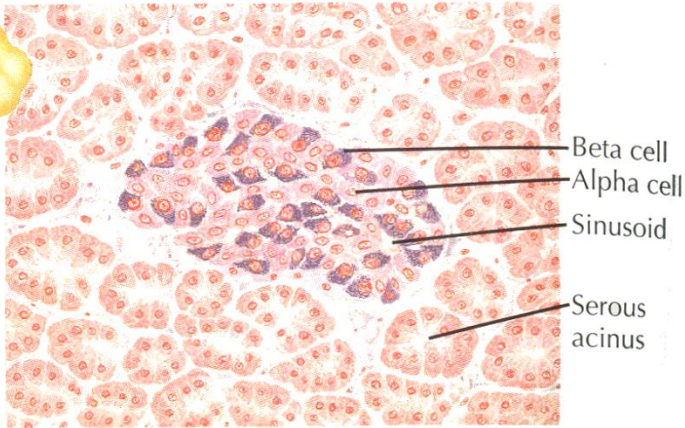
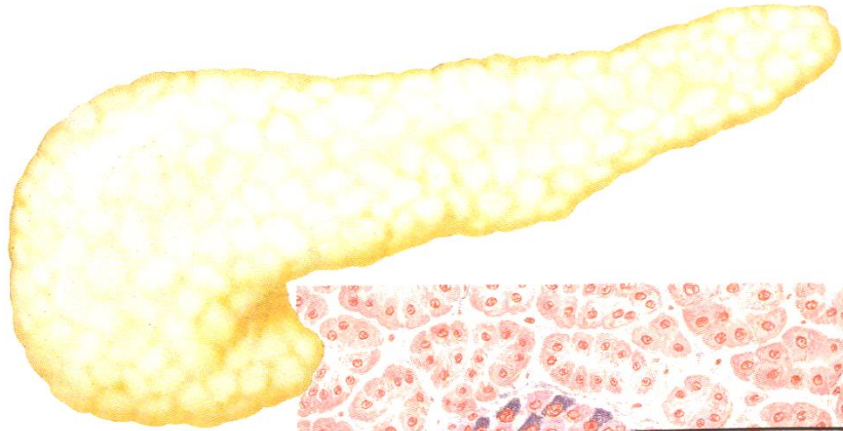
Chronic stress

Fight or Flight

20 µm



ISLETS OF LANGERHANS



Paul Langerhans
1847 – 1888)

Beiträge
zur mikroskopischen Anatomie der
Bauchspeicheldrüse.

INAUGURAL-DISSERTATION,

zur
ERLANGUNG DER DOCTORWÜRDE

IN DER

MEDICIN UND CHIRURGIE

VORGELEGT DER

MEDICINISCHEN FACULTÄT

DER FRIEDRICH-WILHELMS-UNIVERSITÄT

ZU BERLIN

UND ÖFFENTLICH SO VORZULESEN

am 18. Februar 1869

VON

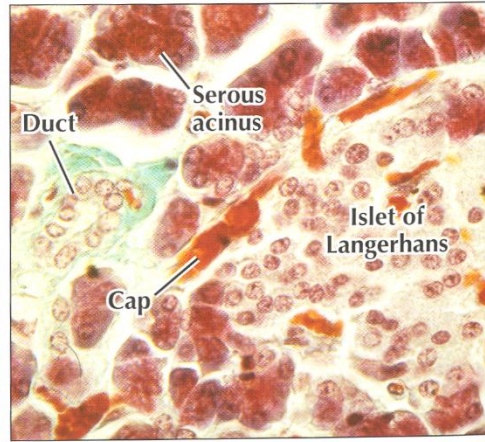
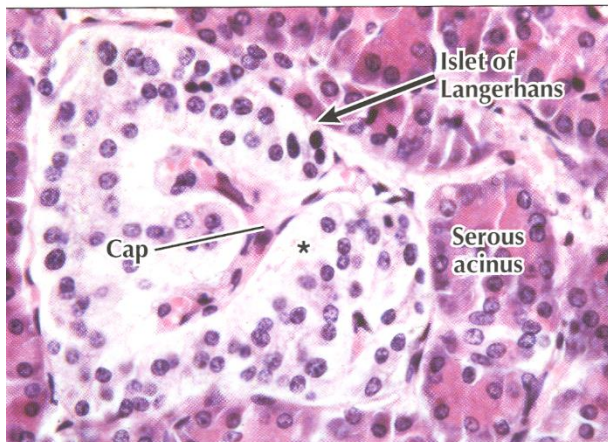
Paul Langerhans
aus Berlin.

OPPONENTEN:

O. Locillet de Mars, Dd. med.
O. Soltmann, Dd. med.
Paul Ruge, Stud. med.

BERLIN.

BLUMBERGERSTRASSE VON GUSTAV LANGBE.



ISLETS OF LANGERHANS



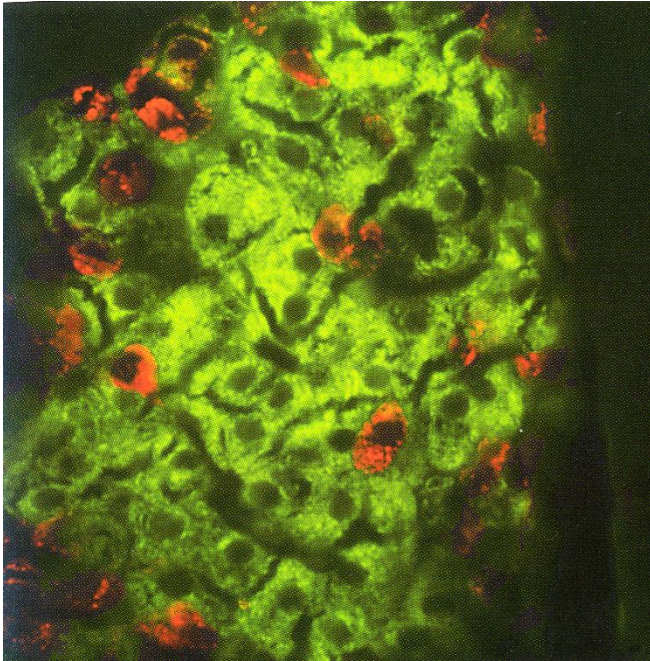
Laguesse E. Sur la formation des ilots de Langerhans dans le pancreas. Comptes Rend SocBiol **1893**;5 (Series 9k.819-20



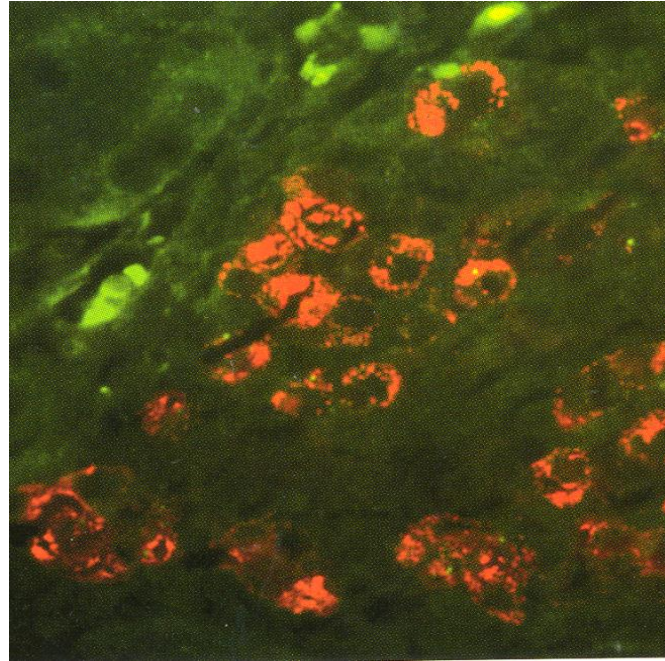
On July 27, **1921**, Sir Frederick Banting and Charles Best succeeded in isolating insulin from canine pancreases and thereby discovered the first effective treatment for diabetes mellitus.

ISLETS OF LANGERHANS

HEALTHY



DIABETES TYPE I



B-cells producing insulin




Ab-anti insulin –Alexa Fluor

A-cells producing glucagon



Ab-anti glukagon –Texas Red



Thank you for
attention

Comments and questions:

pvanhara@med.muni.cz