

# Microscopic structure of the sense organs

Aleš Hampl

November 2024

# Sense system

It serves to convey stimuli that influence organism from inside and outside

## **Sensitive nerve endings**

(with simple structure)

- Simple sensory endings
- Intraepithelial sensory endings
- Sensory bodies

## **Complex organs**

- Photosensitive organ - Eye
- Organ of hearing and equilibrium - Ear

# Photoreceptor organ - Eye

Analyzes the form, light intensity and colour reflected from objects

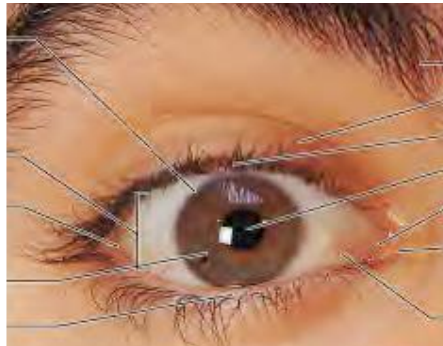
## Eye ball

(three-layered structure)

- tunica externa = fibrosa
- tunica media = vasculosa
- tunica interna = nervosa

## Accessory structures

- eye lids
- conjunctiva
- lacrimal apparatus
- muscles



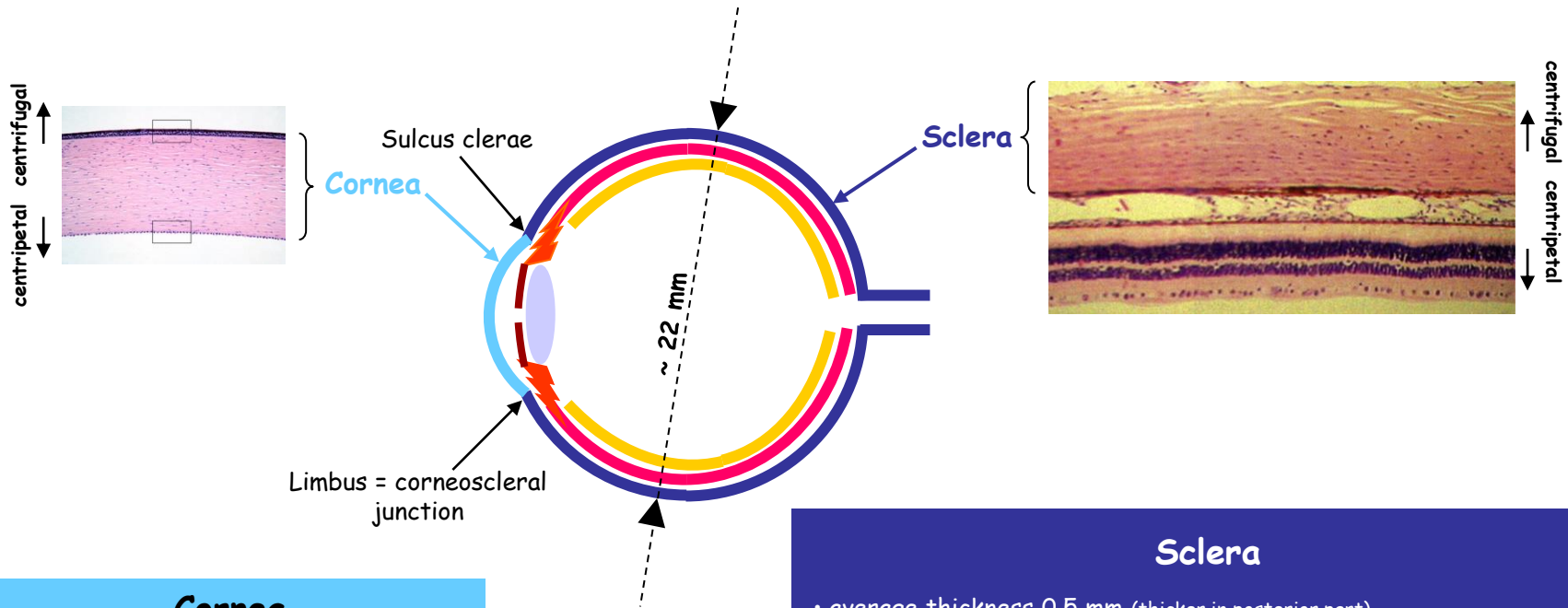
# What do we expect from the eye ?

- Ability to sense signals and transfer them to CNS
- Ability to focus on objects
- Enough strength
- Ability to regenerate
- Ability to move with a minimal friction

# Enough strength

Eyes sit in the protective environment of the skull, in orbits, surrounded by the fat cushions..

<b>Cornea</b>	+	<b>Sclera</b>	=	<b>Tunica externa oculi</b>
1/6	+	5/6	=	6/6 of the surface



## Cornea

- average thickness 0.9-1.0 mm
- colorless
- transparent
- thoroughly avascular
- 5 distinct layers

continues on the next slide

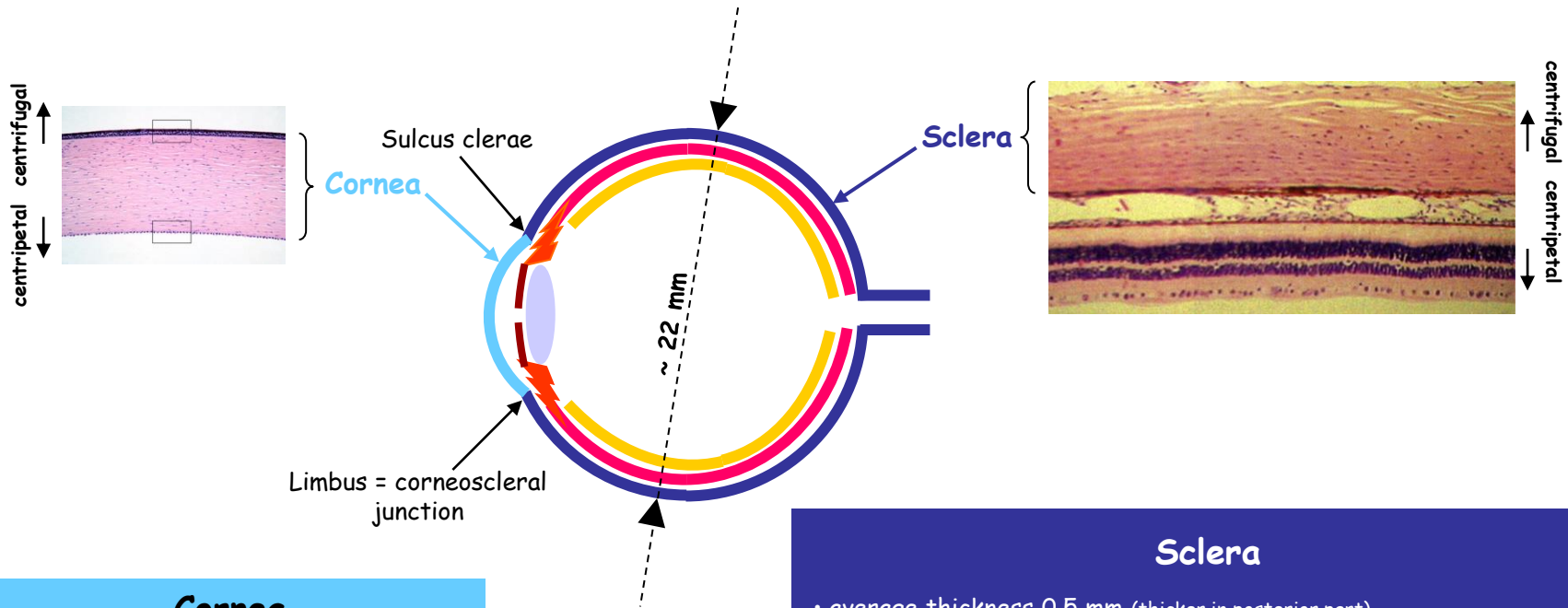
## Sclera

- average thickness 0.5 mm (thicker in posterior part)
  - bundles of flat collagen I fibers (intertwining in all directions)
  - few fibroblasts, minimum ground substance
  - relatively avascular
  - connected by loose system of collagen fibers with **Tenon's capsule** - **Tenon's space** - allows for free movement of the eye
  - **lamina suprachoroidea** - connection to choroid
- (loose connective tissue with melanocytes, fibroblasts and elastic fibers)

# Enough strength

Eyes sit in the protective environment of the skull, in orbits, surrounded by the fat cushions..

<b>Cornea</b>	+	<b>Sclera</b>	=	<b>Tunica externa oculi</b>
1/6	+	5/6	=	6/6 of the surface



## Cornea

- average thickness 0.9-1.0 mm
- colorless
- transparent
- thoroughly avascular
- 5 distinct layers

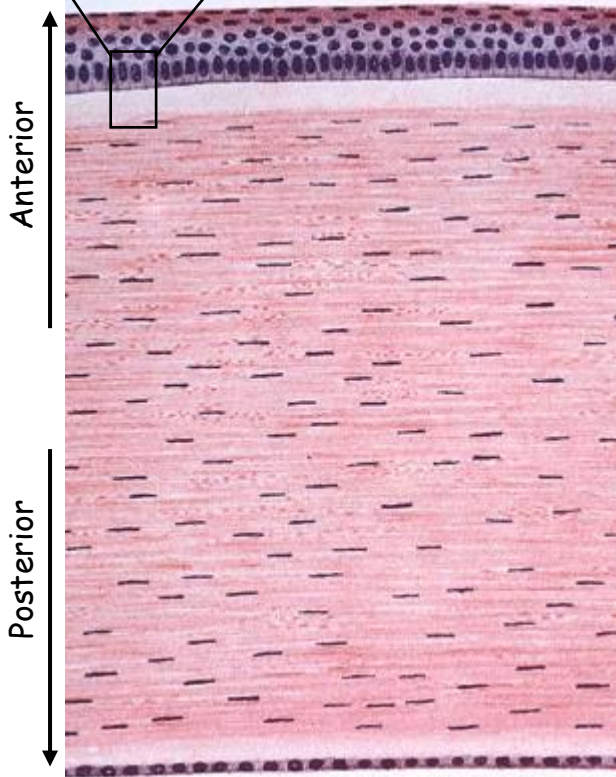
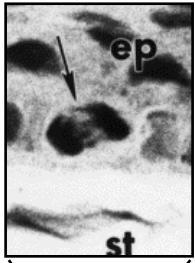
continues on the next slide

## Sclera

- average thickness 0.5 mm (thicker in posterior part)
- bundles of flat collagen I fibers (intertwining in all directions)
- few fibroblasts, minimum ground substance
- relatively avascular
- connected by loose system of collagen fibers with **Tenon's capsule** - **Tenon's space** - allows for free movement of the eye
- **lamina suprachoroidea** - connection to choroid  
(loose connective tissue with melanocytes, fibroblasts and elastic fibers)

# Cornea

(transversal section)



Anterior

Posterior

- stratified + squamous (5-6 layers)
- nonkeratizing
- rich in nerve endings
- surface cells equipped with microvilli (protrude into the space with the film of tears)

Corneal epithelium  
Bowman's membrane

- = **Lamina limitans anterior**
- thickness about 7 - 12  $\mu\text{m}$
- fine collagen fibers (intersecting in all directions)
- no cells
- provides strength

Substantia propria corneae = STROMA

- many layers of collagen fibers (in right angles)
  - flat keratocytes in between the collagen lamellae (fibroblast-like cells)
  - contains mucoïd substance rich in chondroitinsulphate
  - properly hydrated
- KEY to the TRANSPARENCY**

- = **Lamina limitans posterior**
- fine collagen fibers
- fibers are organized to 3D network

Descemet's membrane  
Corneal endothelium

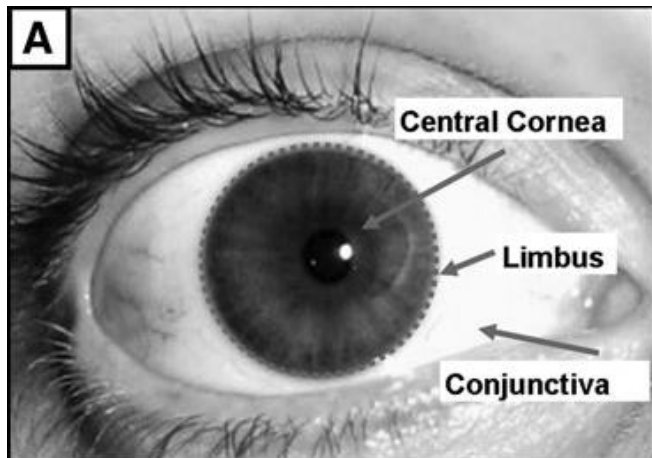
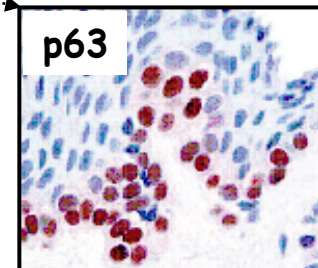
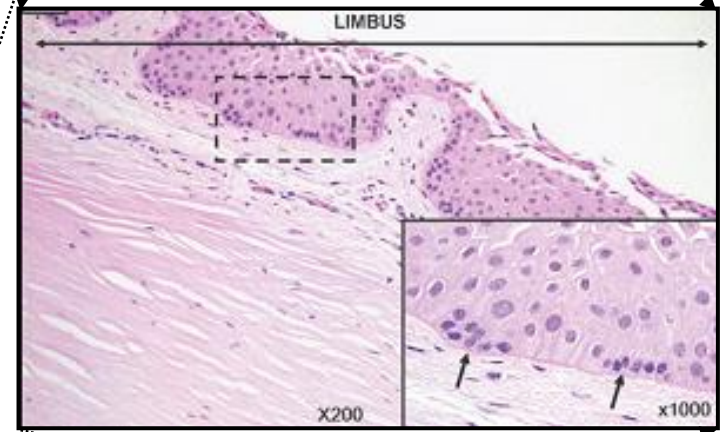
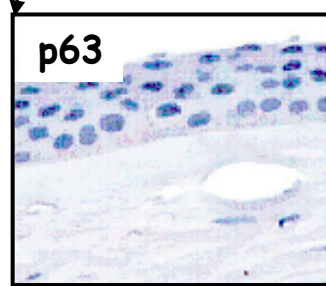
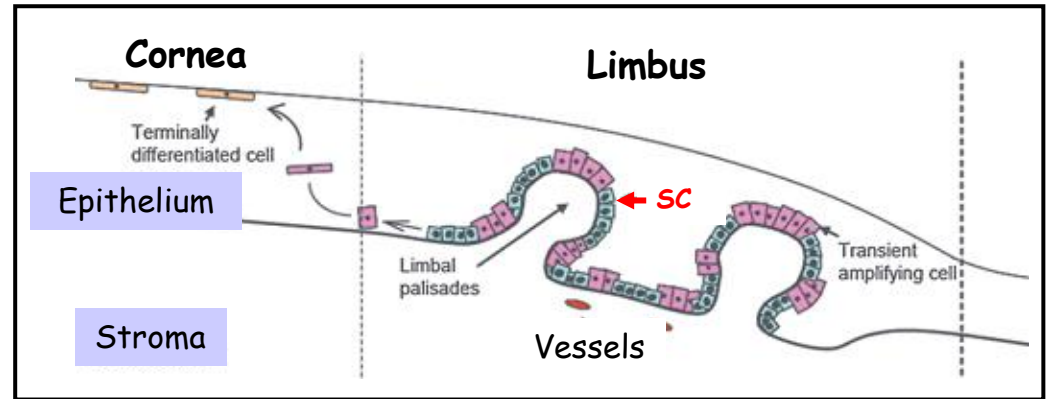
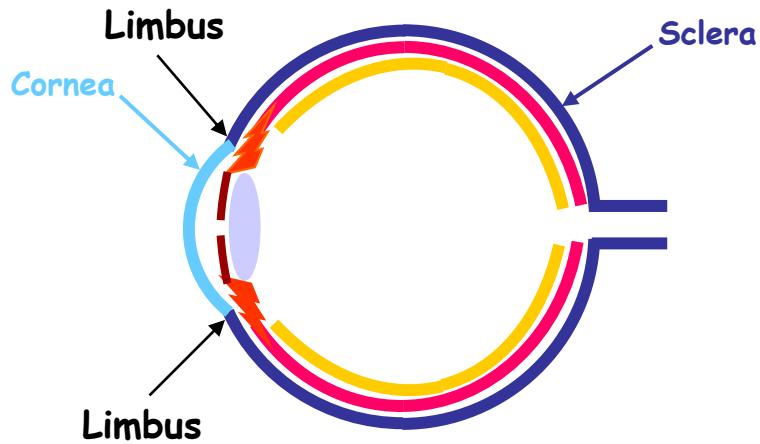
- simple + squamous
- active in transport to maintain cornea in a proper state
- continues on the frontal part of iris (via spongium anguli iridocornealis)

# Ability to regenerate

## Limbus - corneoscleral junction

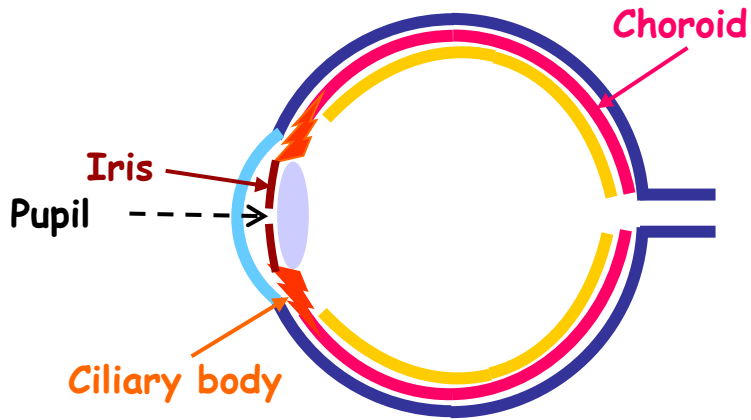
The area of transition of the transparent collagen bundles of cornea into the opaque collagen bundles of sclera.

Highly vascularized - feeds avascular cornea





# Enough supply of resources



<b>Choroid</b>	+	<b>Ciliary body</b>	+	<b>Iris</b>	=	<b>Tunica media</b>
Choroidea		Corpus ciliare		Iris		T. vasculosa

## Choroid = 4-layered structure

### Lamina suprachoroidea

- loose connective tissue
- rich for pigment cells - melanocytes

### Lamina vasculosa

- loose connective tissue
- rich for pigment cells - melanocytes
- contains larger vessels and nerves

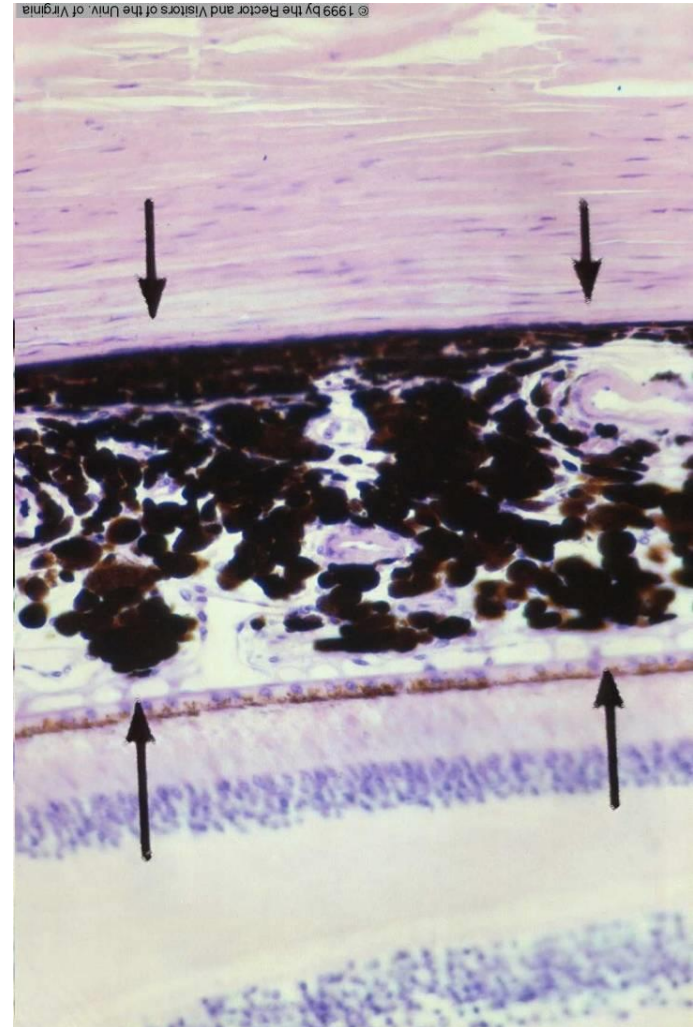
### Lamina choriocapillaris

- loose connective tissue
- network of small vessels

### Lamina vitrea = L. basalis = Bruch's membrane

- fibers of collagen and elastin
- overall thickness about 3-4 μm
- links together basal laminae of Lamina choriocapillaris of choroid and pigmented epithelium of retina

Choroid



Sclera

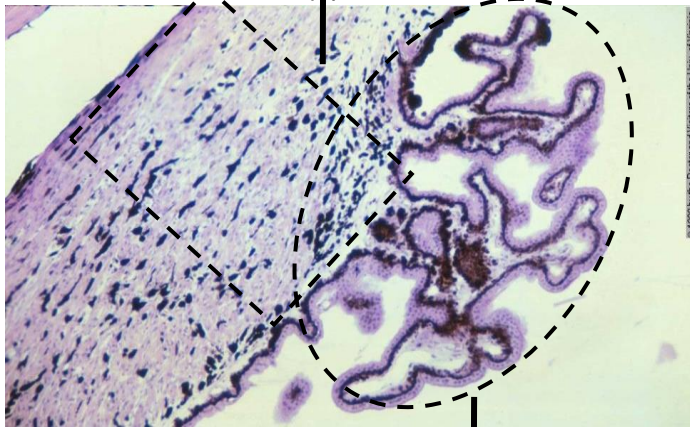
Retina

# Ability to focus on objects

## Ciliary body - anterior extension of the choroid

### Stroma of ciliary body

- loose connective tissue
- contains elastic fibers, vessels and melanocytes
- rich for capillaries (chamber fluid)
- bundles of smooth muscle fibers (anchored to sclera and protrude to the processes of ciliary body - *m. ciliaris*)



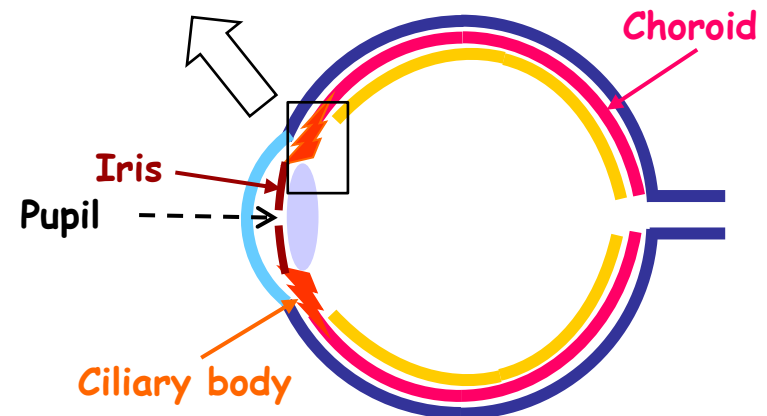
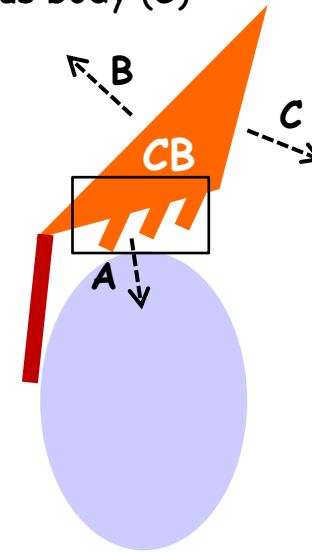
### Processes of CB (Processus ciliares)

- protrude into posterior chamber
- total number of about 70-80
- rich for capillaries (chamber fluid)
- covered by two-layered epithelium (from the retina - *pars ciliaris retinae*)
- linked to the lens capsula *fibrae suspensoriae lentis* (zonulae)

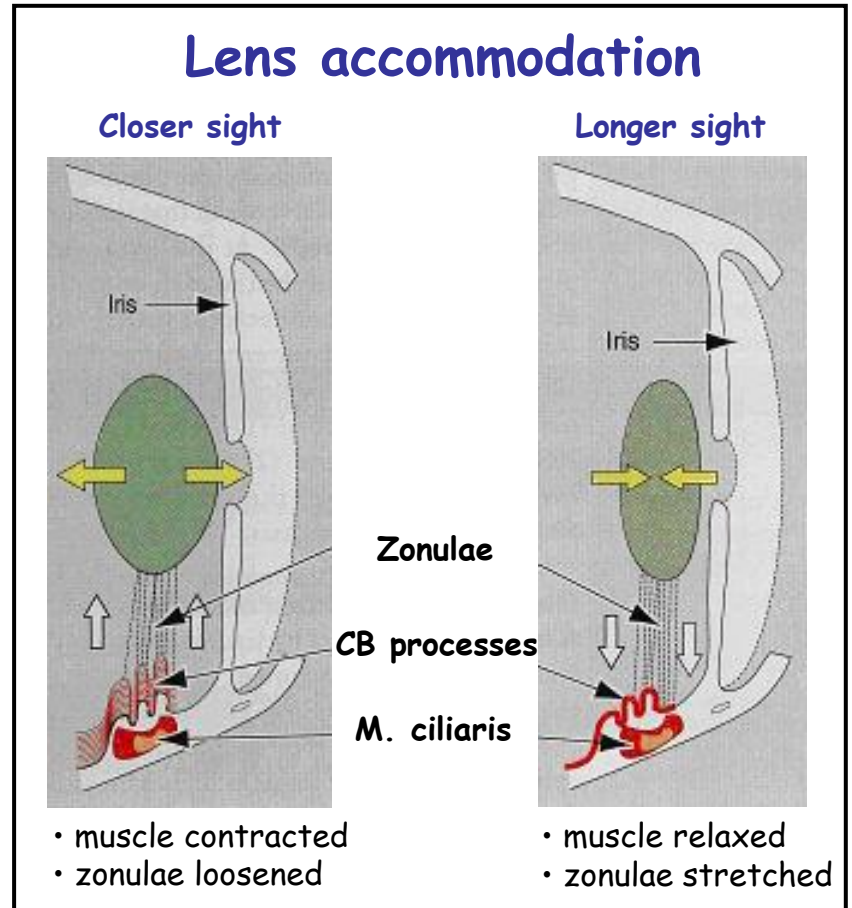
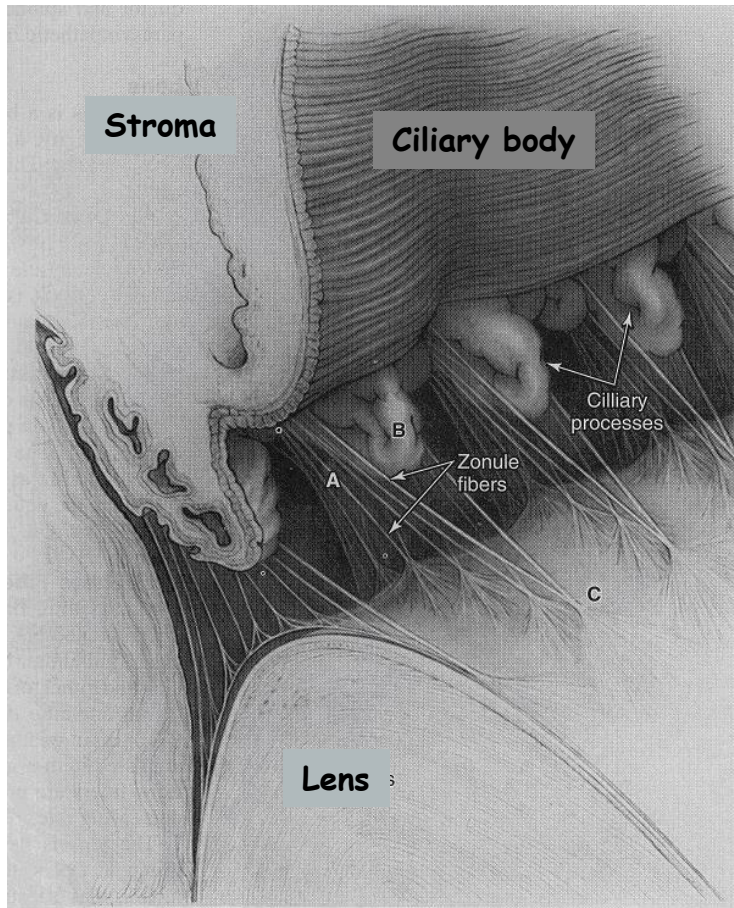
### Triangular on crosssection

Connects to:

- lens + posterior chamber (A)
- sclera (B)
- vitreous body (C)

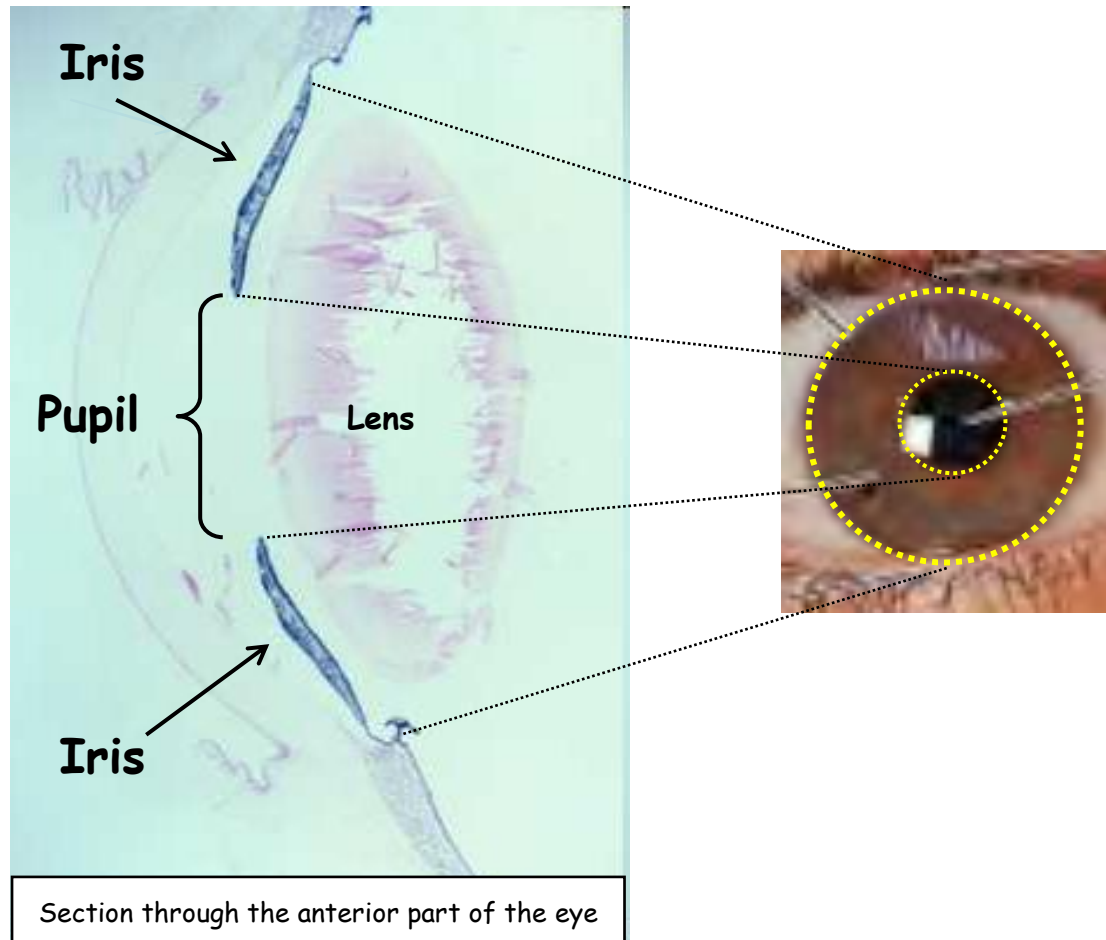


# Ciliary body

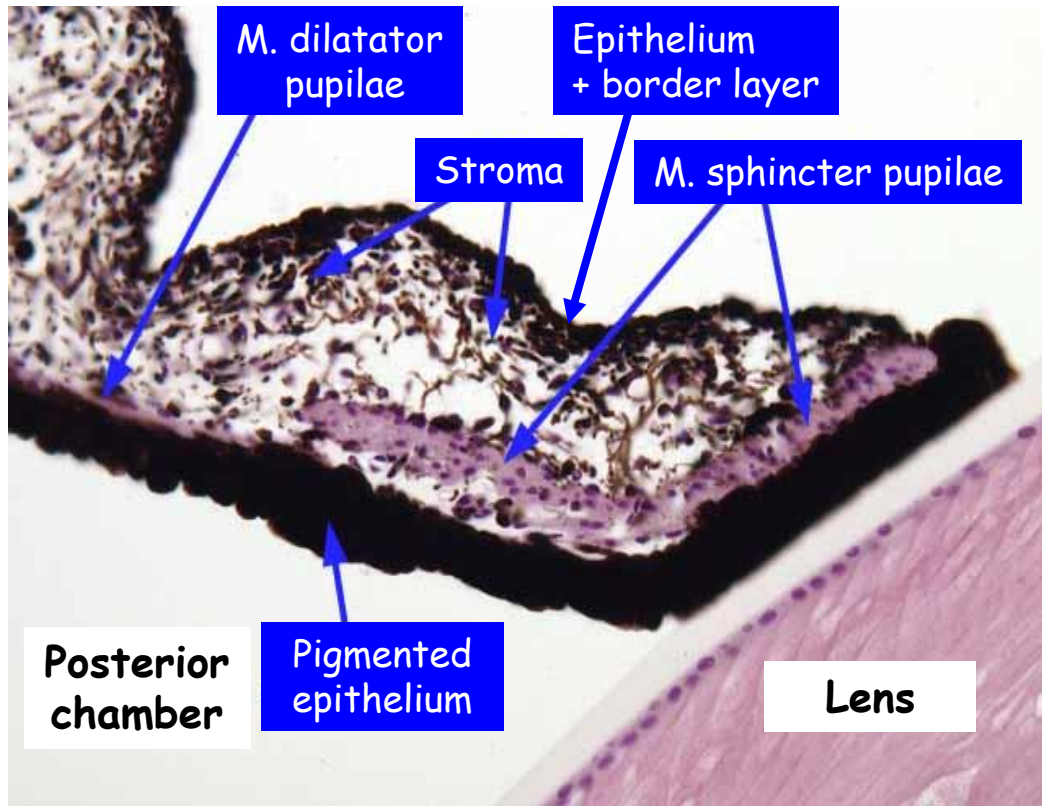


# Iris - 1

Anterior continuation of the choroid.  
Partially covers the lens.



# Iris - 2



## Iris = 4-layered structure

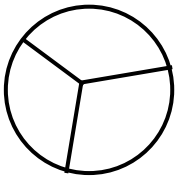
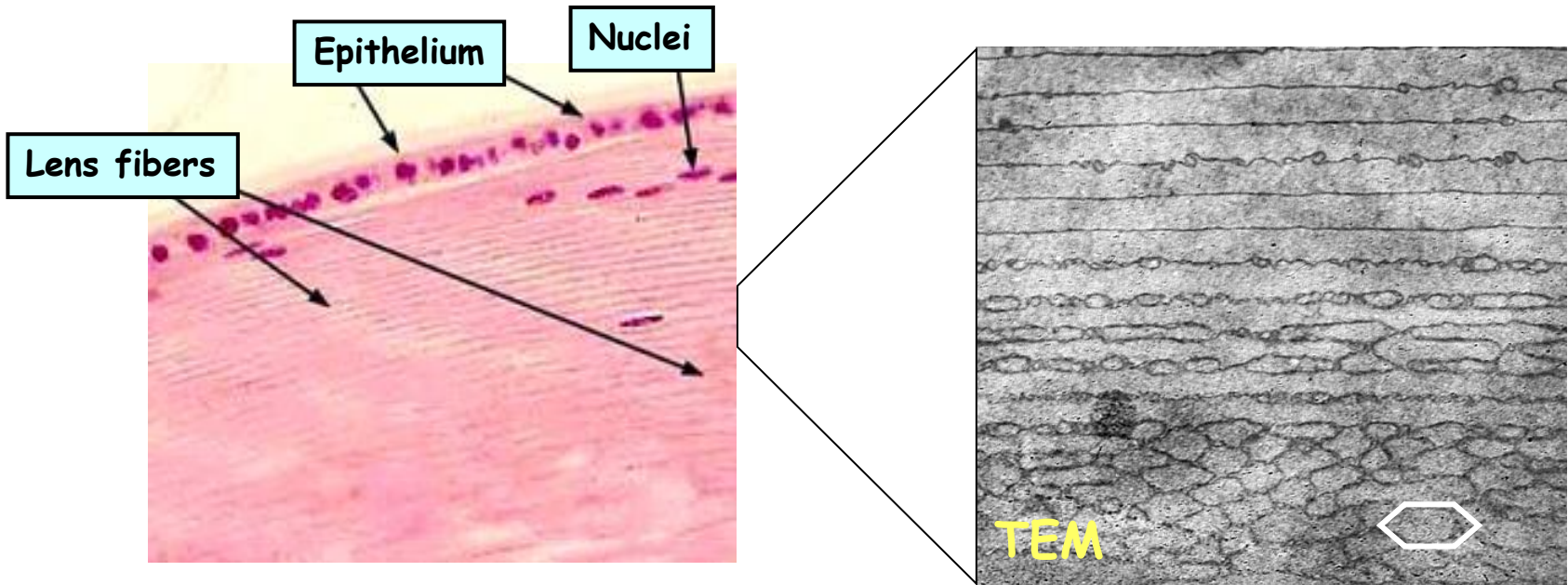
Layers from outside:

- 1. Anterior epithelium**
  - continuation of the posterior ep. of the cornea
  - discontinuous layer of flat epithelial cells, fibroblasts a melanocytes
- 2. Anterior border layer**
  - thin layer of connective tissue
  - rich for pigmented cells - melanocytes
  - **decides about eye colour**
- 3. Stroma**
  - loose connective tissue
  - large number of radially running vessels
  - concentrically ordered smooth muscle fibers (=musculus sphincter pupillae)
- 4. Pars iridica retinae**
  - 2-layered
  - continues form ciliar body
  - layer facing the stroma contains smooth muscle fibers (=musculus dilatator pupillae)

# Lens

## Capsule + Epithelium + Fibers

- 10-20  $\mu\text{m}$
- Collagen IV



Epithelium (cuboidal + low cylindrical) only on the anterior surface.

Fibrae suspensorie lentis are anchored to the equator of the lens.

# Ability to sense signals and transfer them to CNS for processing

Retina = Tunica aculi interna - Tunica nervosa

## Posterior part

- photosensitive
- multilayered

## Anterior part

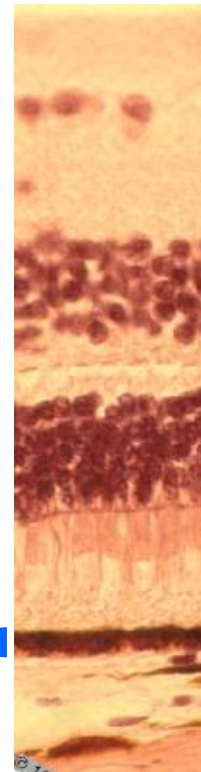
- non-photosensitive
- two-layered
- covers ciliary body and posterior part of the iris

Invagination of prosencephalon creates two-layered **optic cup**.

## Outer layer

### Stratum pigmenti retinae

- columnar cells
- basally located nucleus
- firm connection with lamina vitrea/basalis of choroid
- zonulae occludentes and adherentes
- rich for smooth ER (esterification of vit A)
- rich for melanin granula
- apical extensions (microvili and sheets)
- vesicles in apical parts



~ 0.2 mm

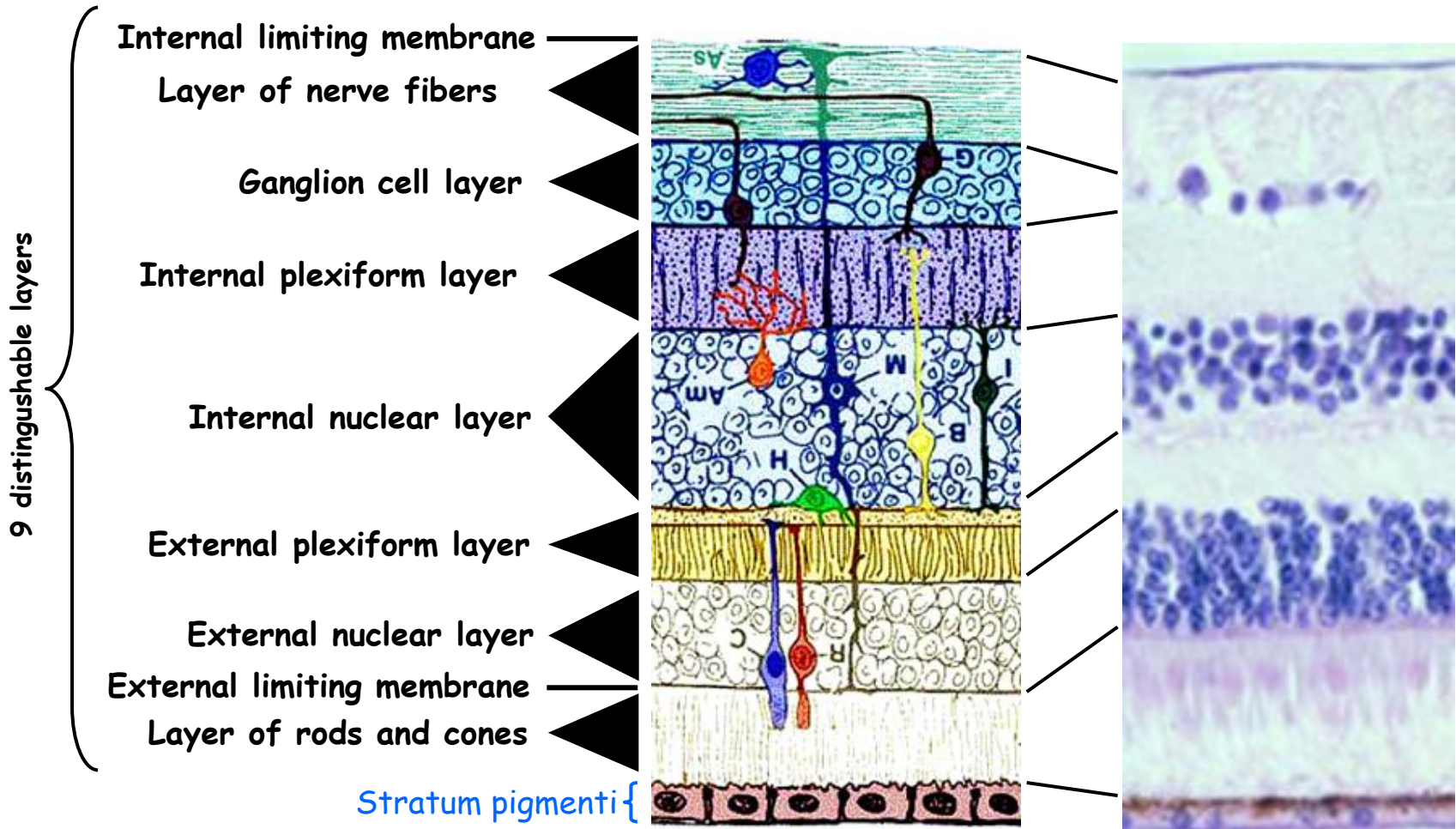
} Choroid

## Inner layer

### Neural retina

# Neural (optical) retina

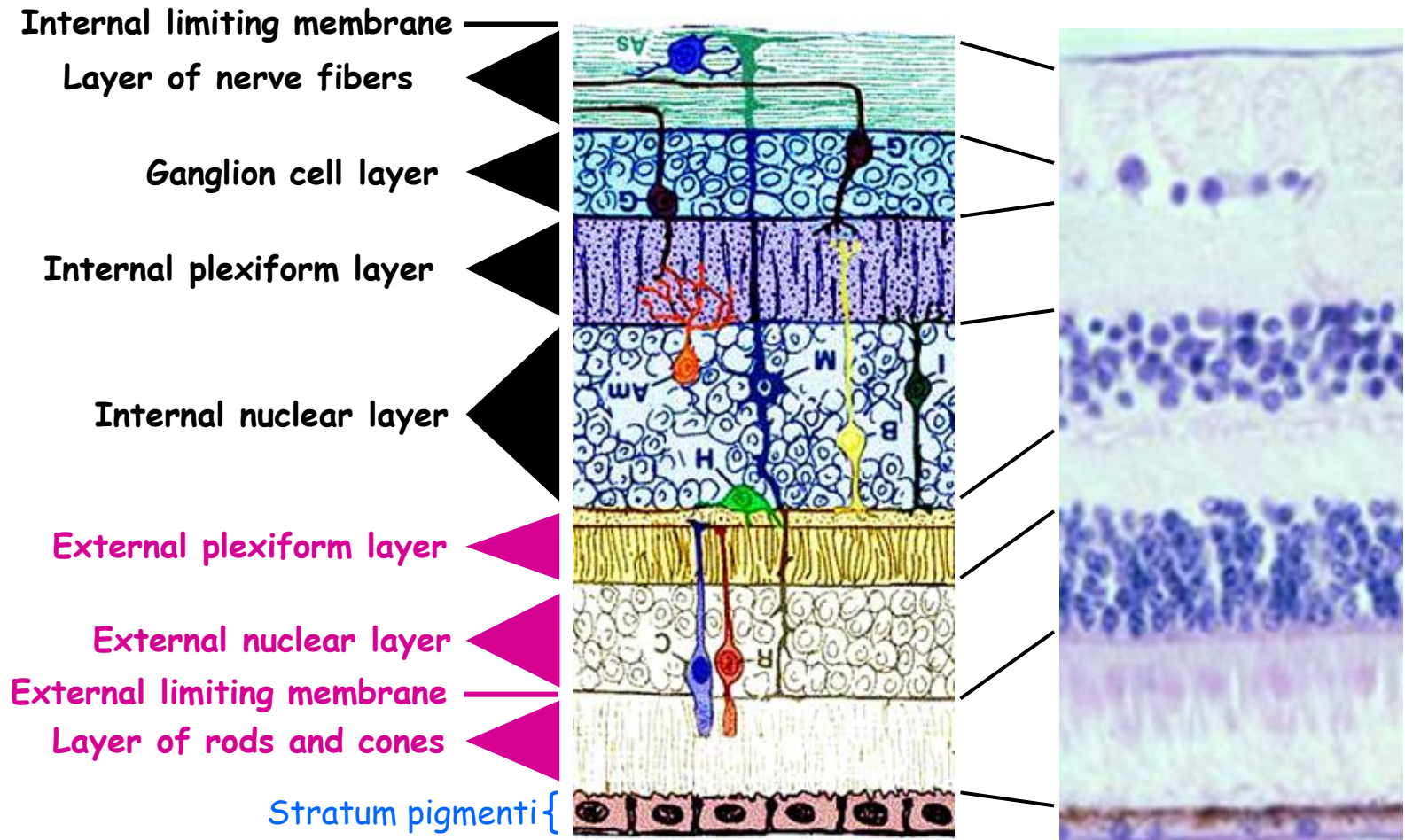
minimum 15 different types of neurons with tens of interactions (synapses)





# Photoreceptors = Rod and cone cells 1

## I. Neurones of the optical path



# Photoreceptors = Rod and cone cells 2

## I. Neurones of the optical path

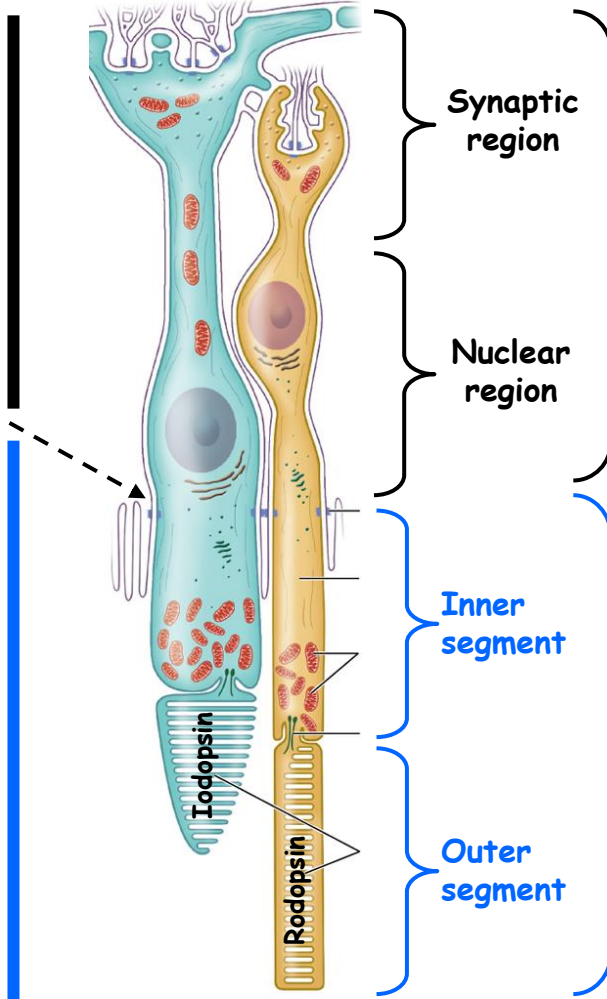


**External plexiform layer**

**External nuclear layer**

**Membrana limitans externa**  
(series of junctional complexes between photoreceptors and glial Muller cells)

**Layer of rods and cones**

**SEM**



**Synaptic region**

**Nuclear region**

**Inner segment**

**Outer segment**


**Central part**

**Peripheral part**

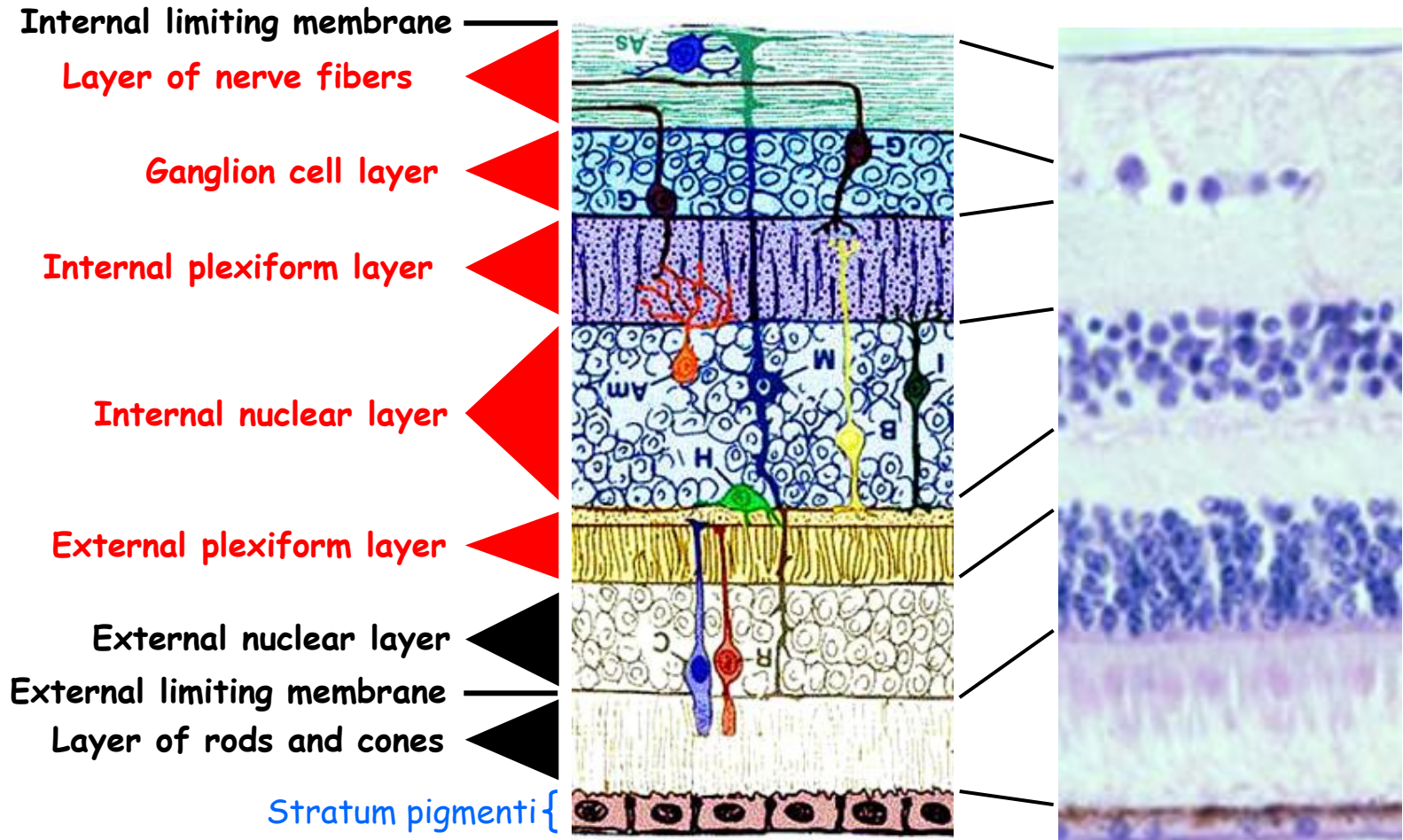
**Rhodopsin**

**Rhodopsin**

Rod cells: 100-150 mil.  
Cone cells: 7 mil. (méně citlivé)



# Other neurons of the optical path 1



# Other neurons of the optical path 2

## II. neuron Bipolar cells

### Diffuse

- Synapses with two or more receptors

### Monosynaptic

- Synapses with only one receptor
- Direct transfer of impulses from some rods

## III. neuron Ganglion cells (multipolar)

- Large cells
- Nuclei mainly in one layer
- Dendrites connect to neurites of bipolar and amakrine cells
- Neurites run in 9. layer of the retina and come together to form optic nerve

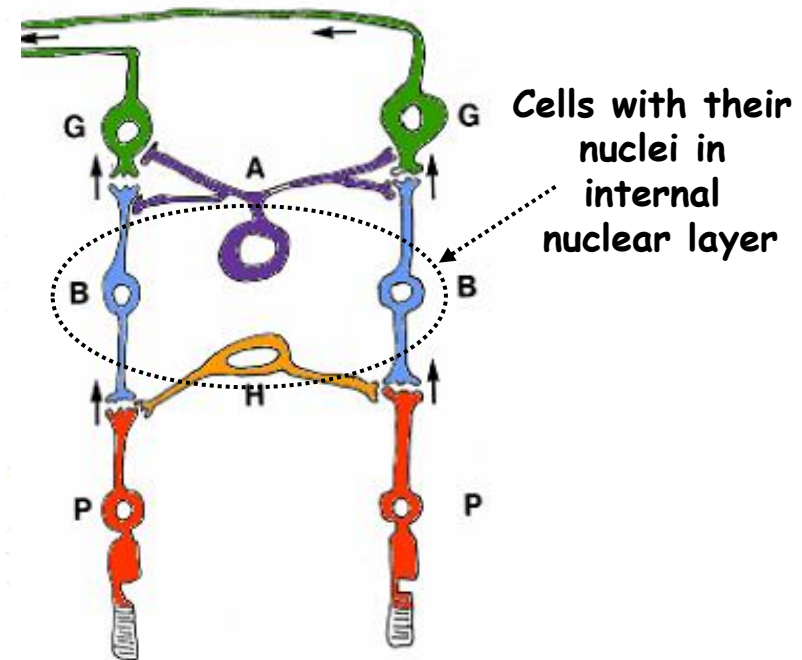
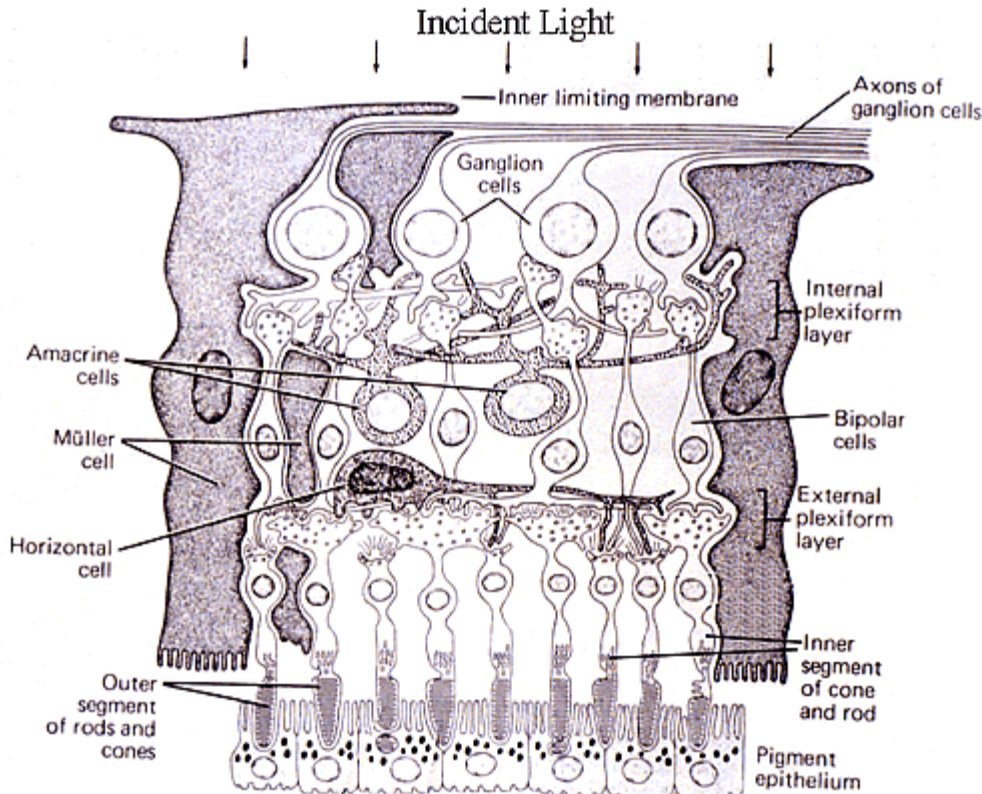
## Asociating + integrating neurons

### Horizontal cells

- Small
- Multipolar

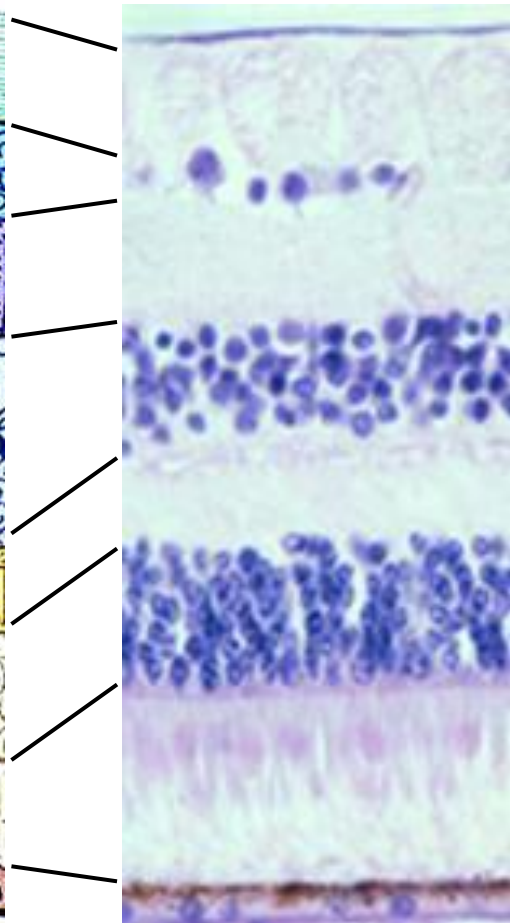

### Amacrine cells

- They don't have neurite



# Supporting cells of the retina 1

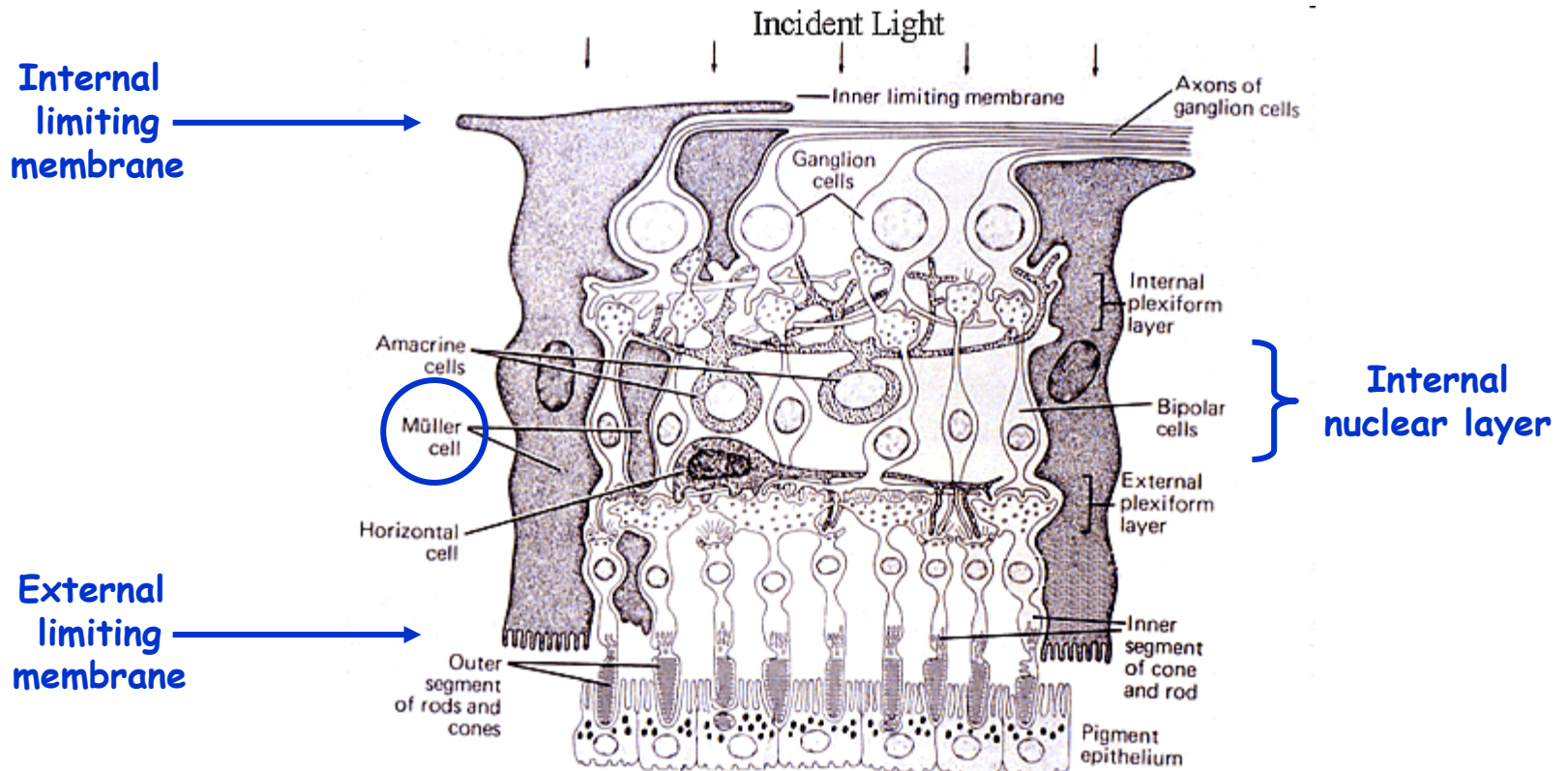
- Internal limiting membrane
- Layer of nerve fibers
- Ganglion cell layer
- Internal plexiform layer
- Internal nuclear layer
- External plexiform layer
- External nuclear layer
- External limiting membrane
- Layer of rods and cones
- Stratum pigmenti {



# Supporting cells of the retina 1

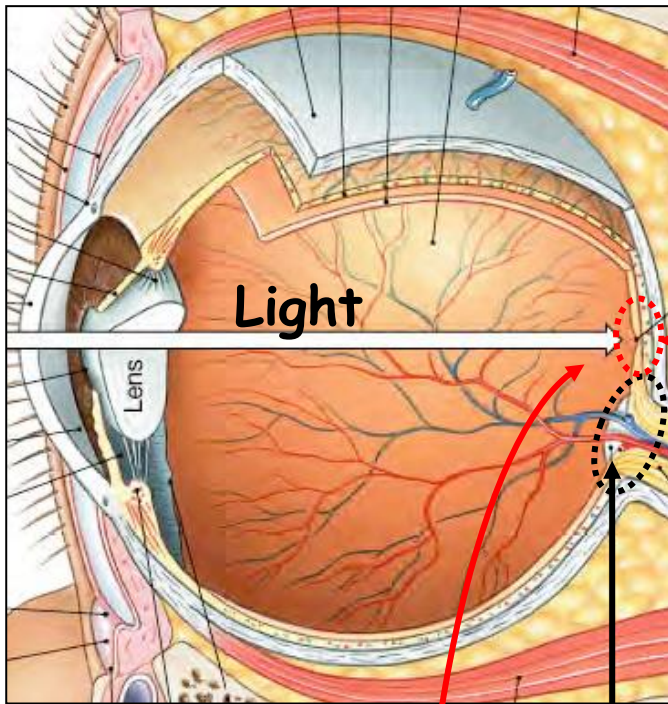
## Müller cells

= modified glial cells of the CNS



„Does the retina see the same in all its areas“

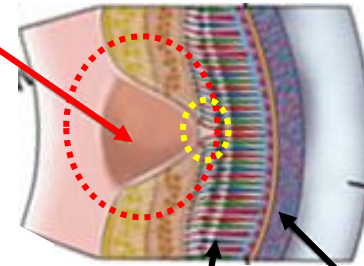
Central x Peripheral vision



Light

Lens

Macula lutea

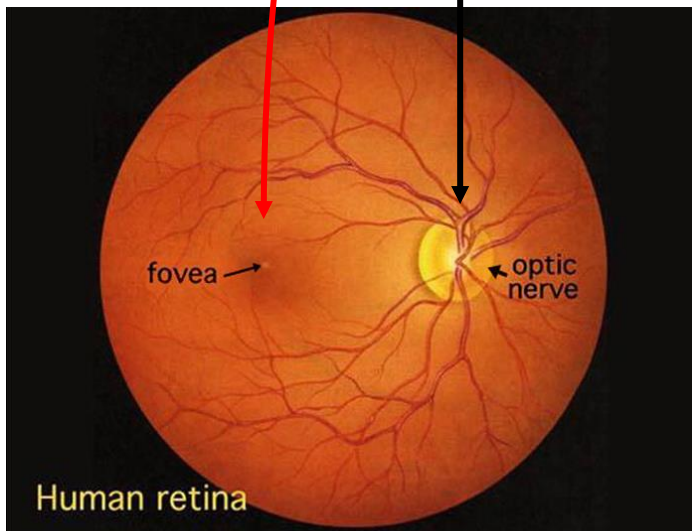


Retina

Choroid

Papilla of the optic nerve

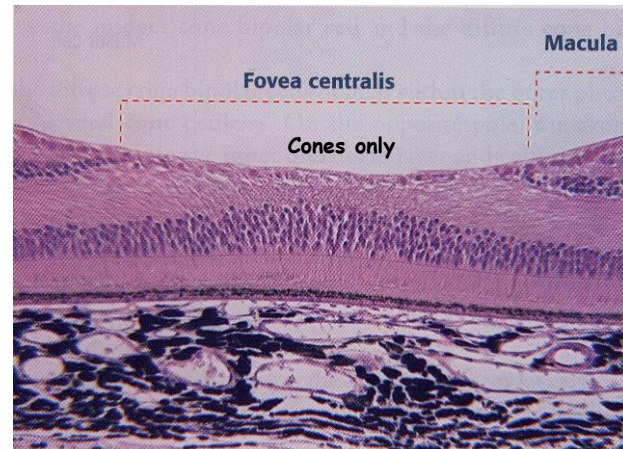
Fovea centralis of the macula lutea = the sharpest vision



fovea

optic nerve

Human retina

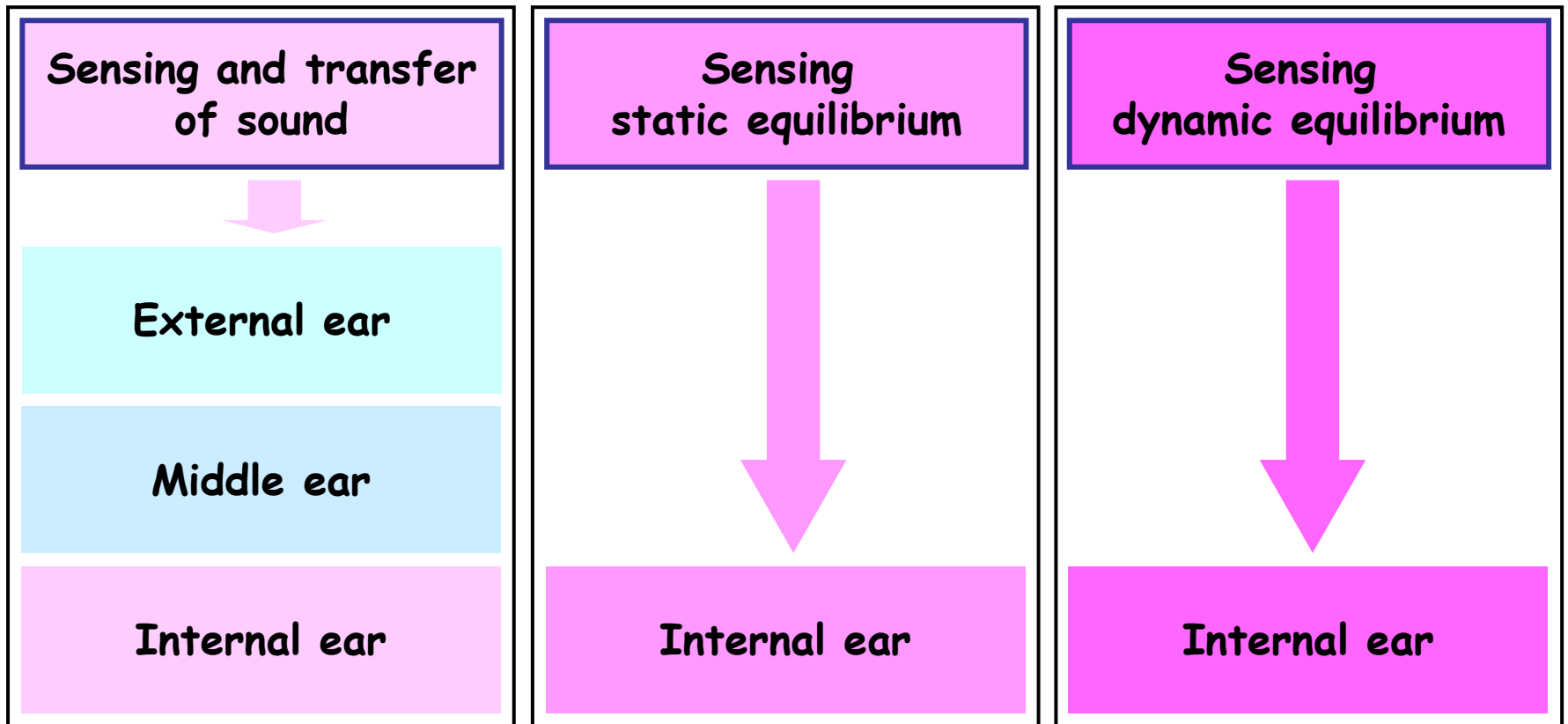


Macula

Fovea centralis

Cones only

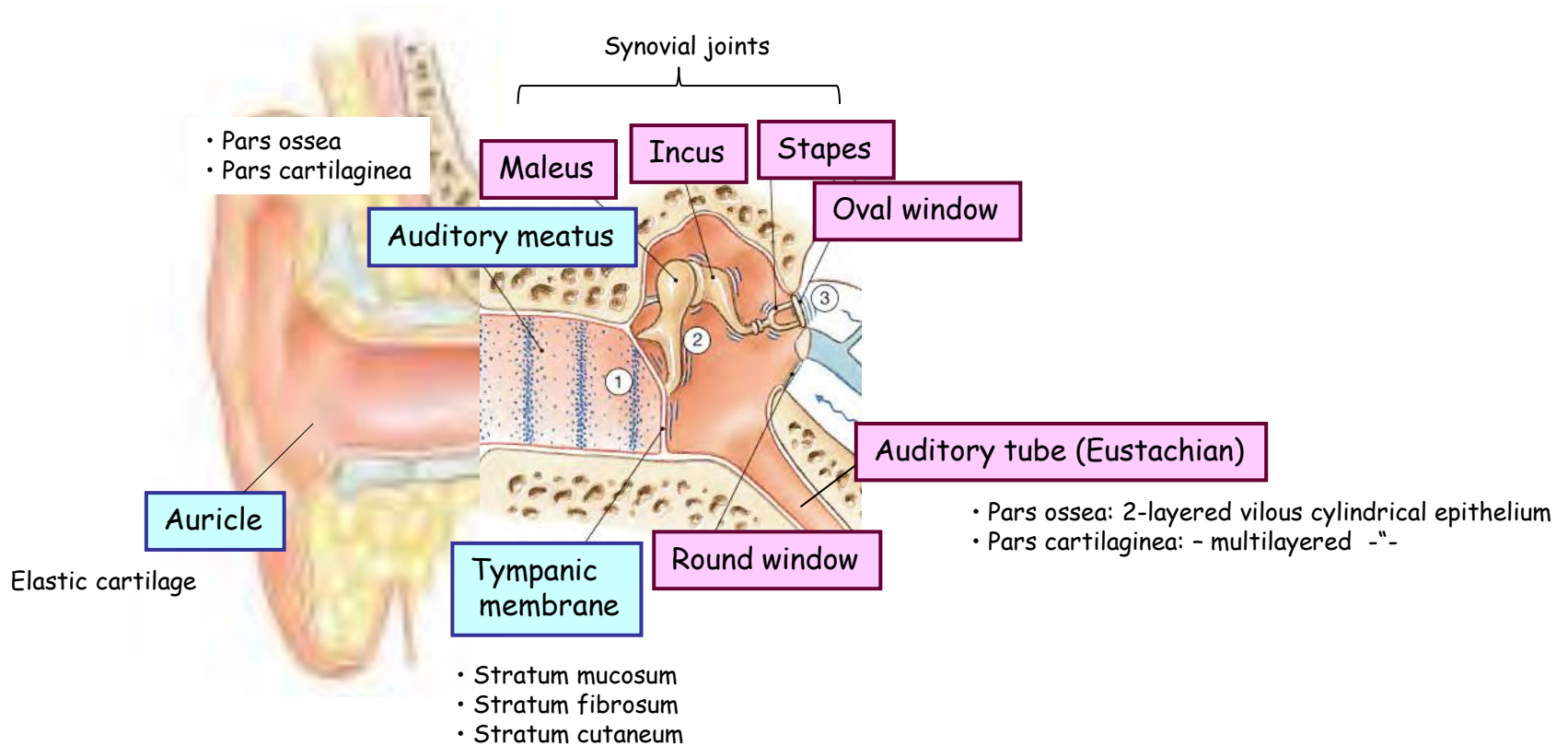
# Audioreceptor system = Vestibulocochlear apparatus



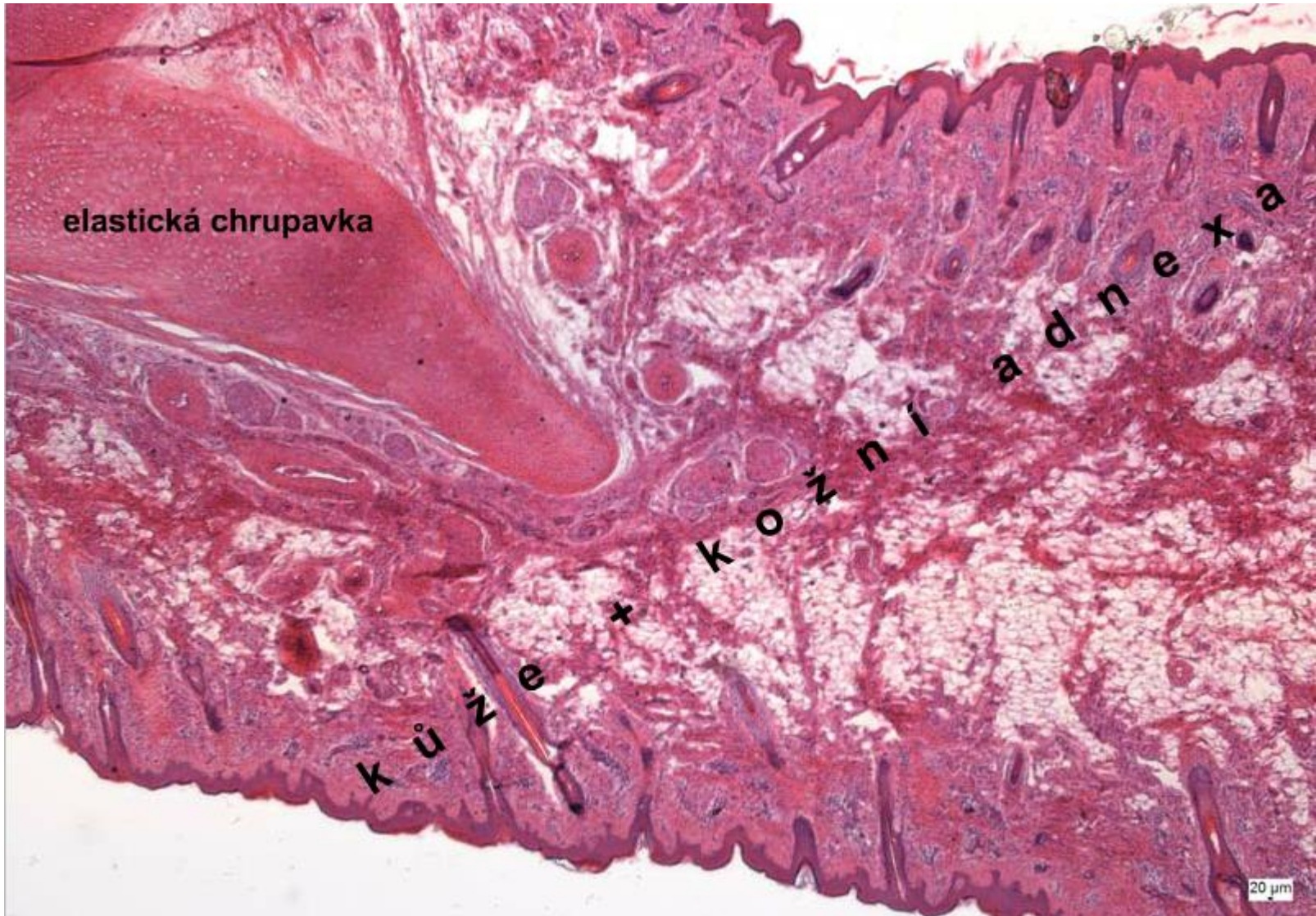


# External + Middle ear - Organ of hearing

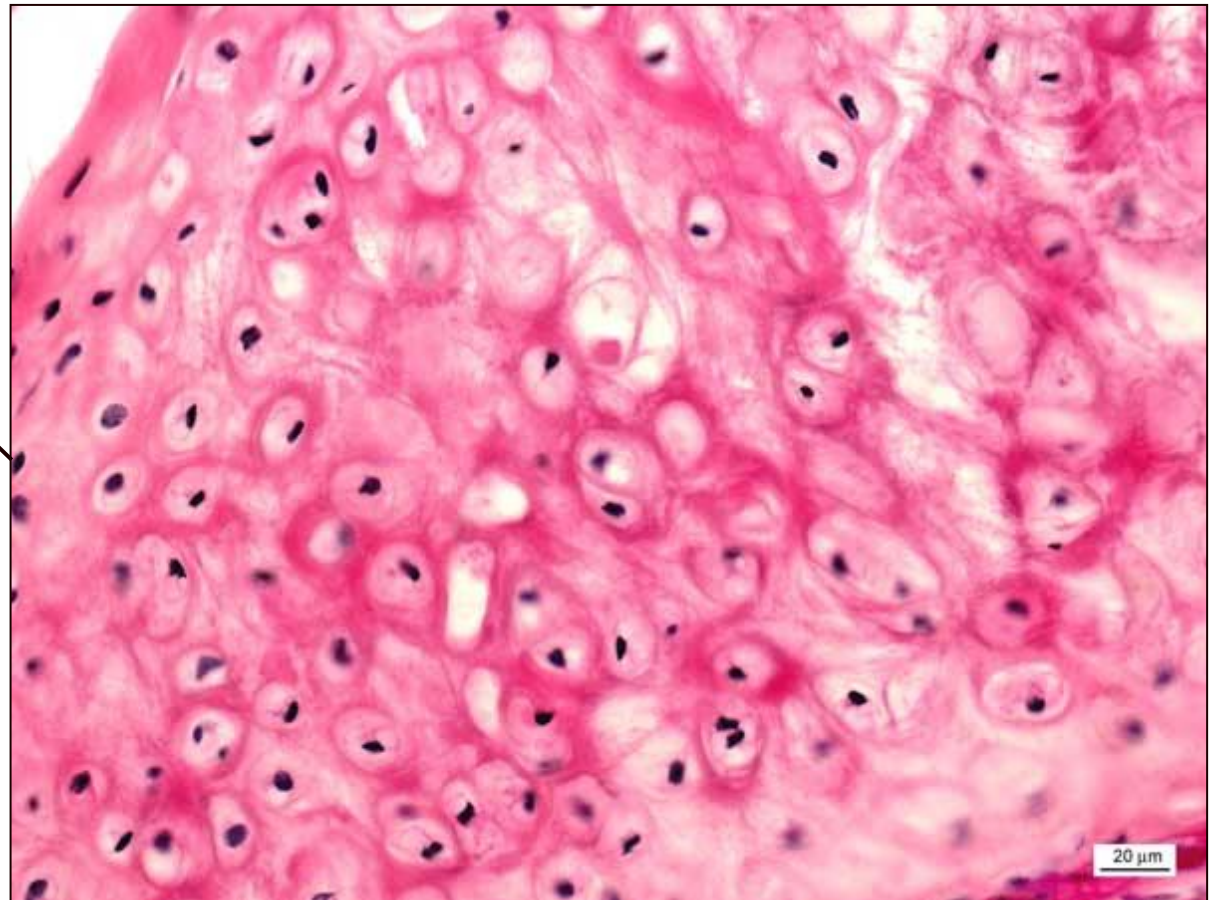
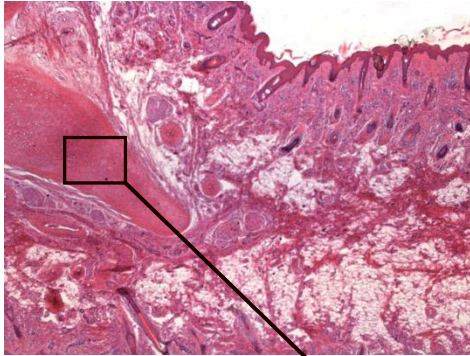
Middle ear - fitted in the cavities of **temporal bone** along with internal ear - osseous labyrinth.



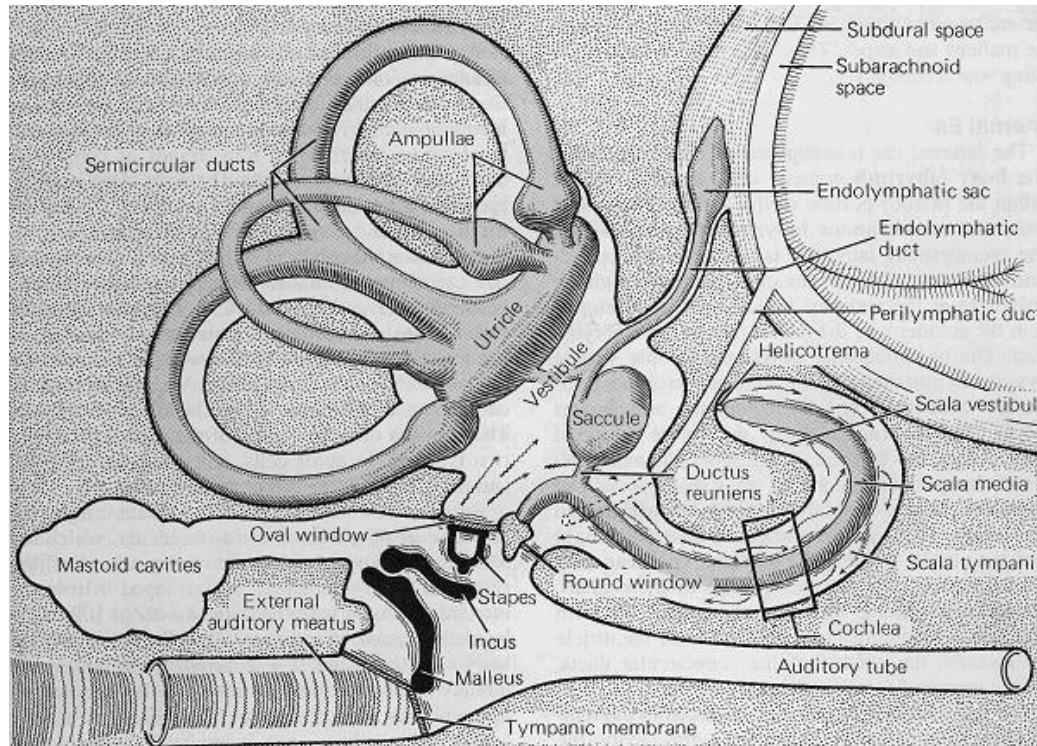
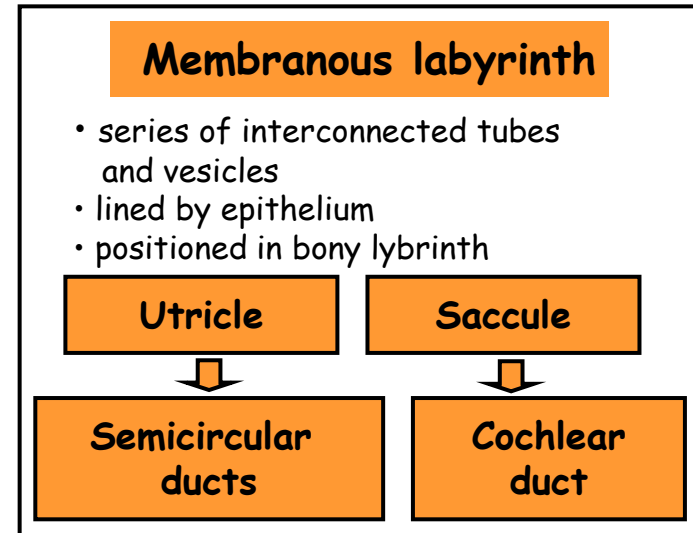

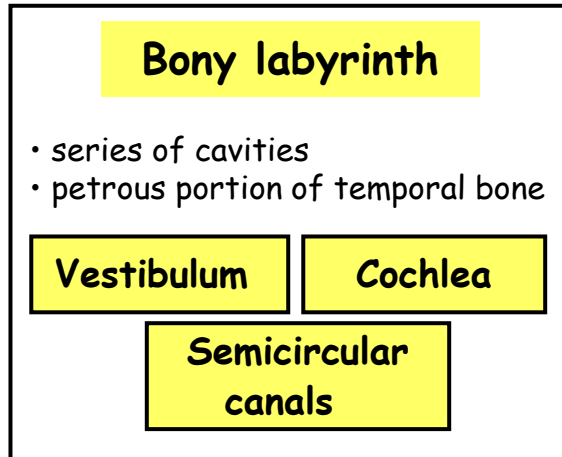
# Extrenal ear - Auricle



# External ear - Auricle - Elastic cartilage



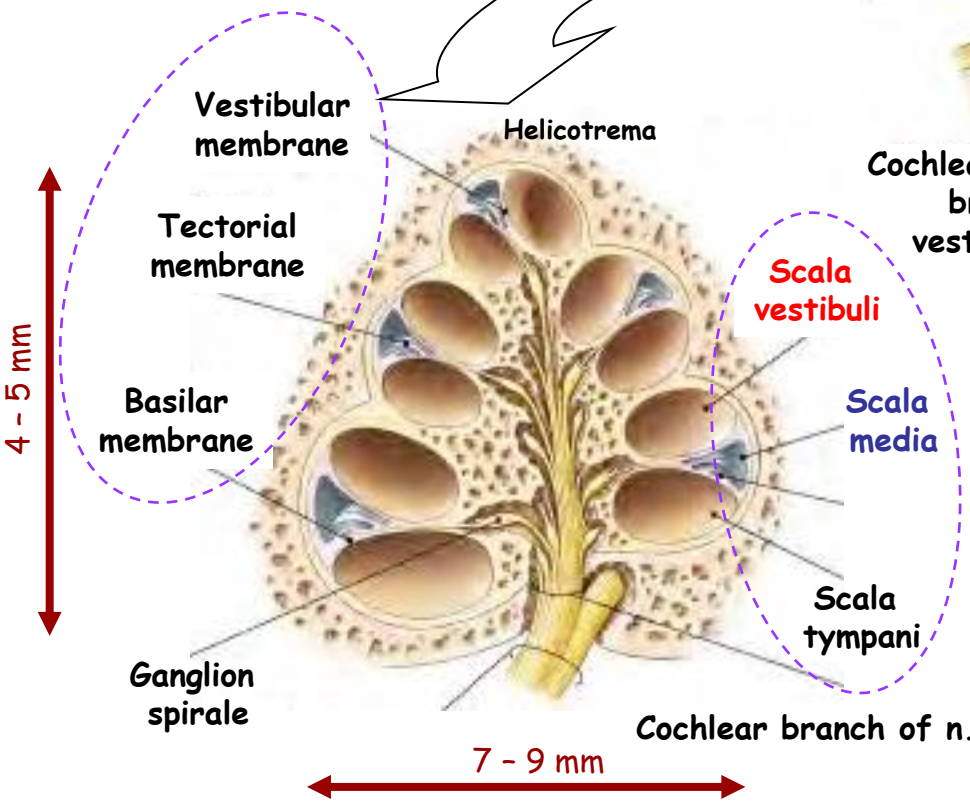
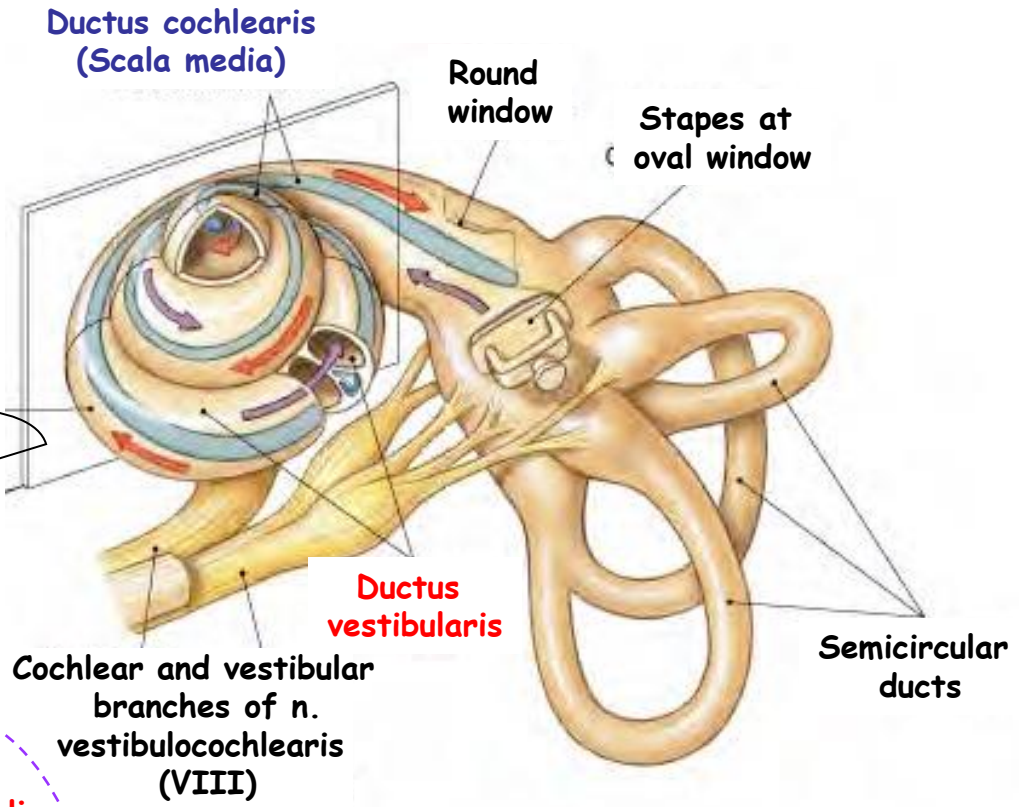
# Internal ear



# Internal ear - Organ of hearing

**Cochlea**

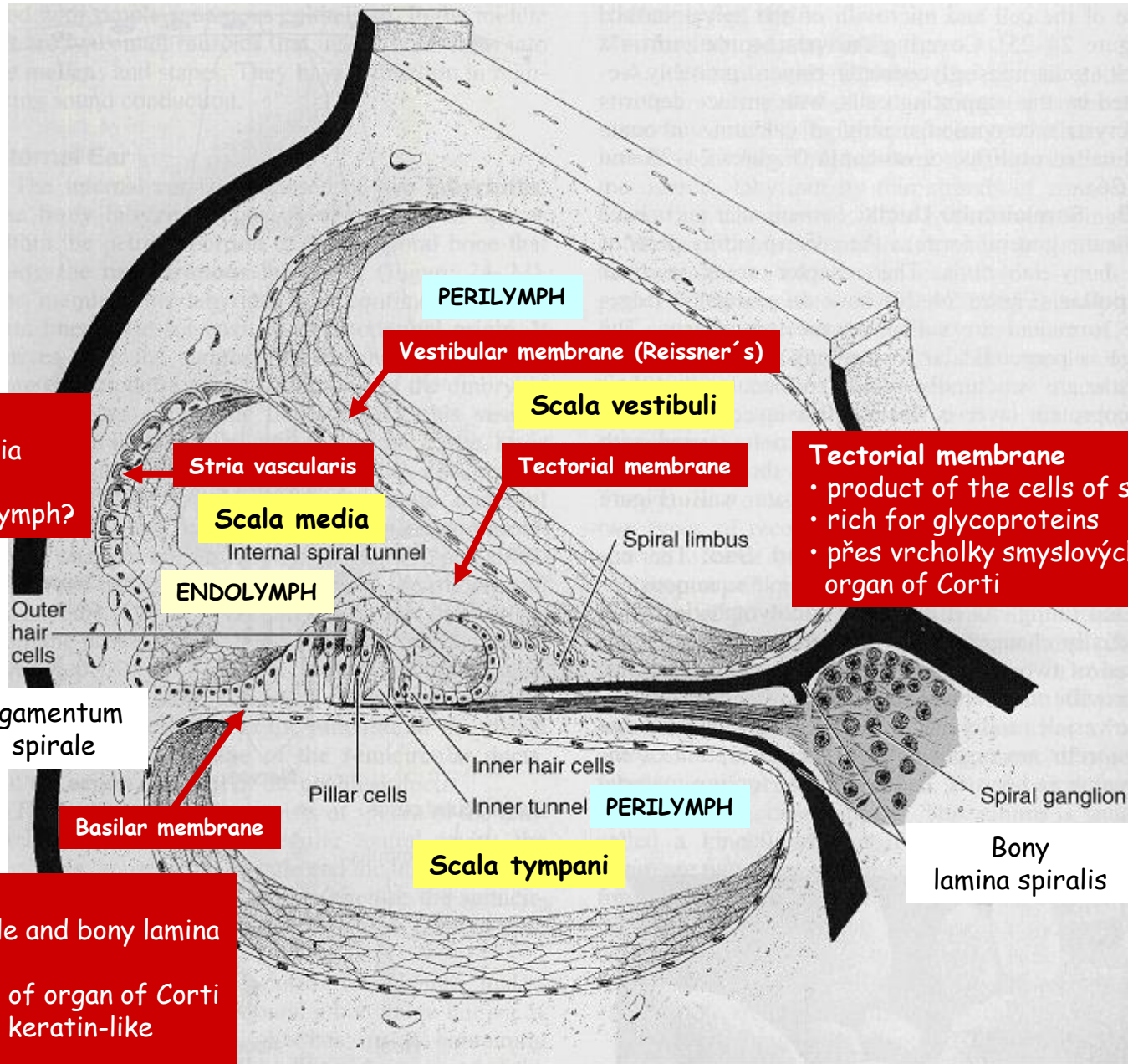
- 2,5 turns around modiolus
- total length about 35 mm



**Modiolus (bony core)**

- central axis of cochlear duct
- contains ganglion spirale cochleae, nervus cochlearis and vessels

# Internal ear - Detail of cochlear duct



**Stria vascularis**

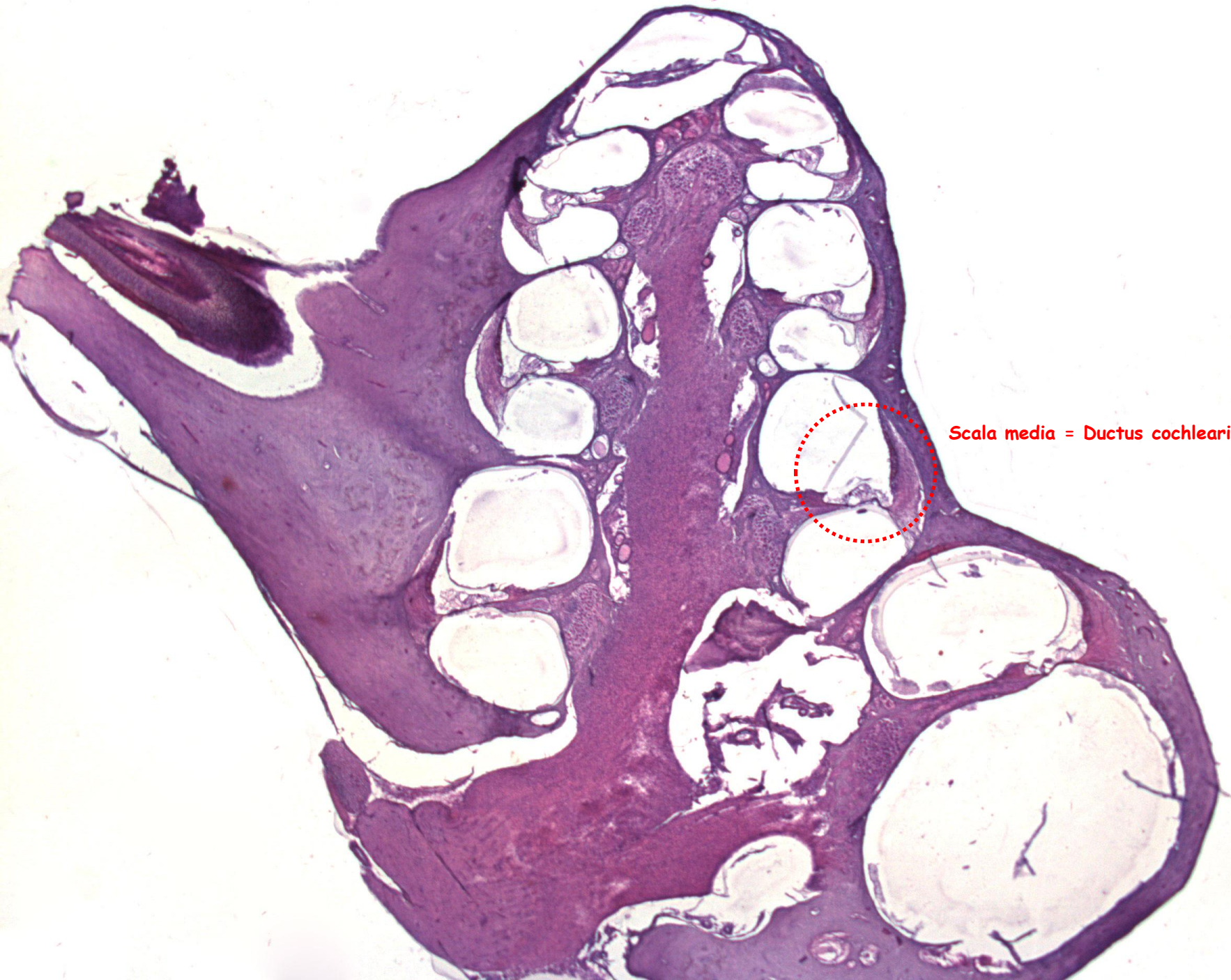- vascularized epithelia
- responsible for the composition of endolymph?

**Tectorial membrane**

- product of the cells of spiral limbus
- rich for glycoproteins
- přes vrcholky smyslových buněk organ of Corti

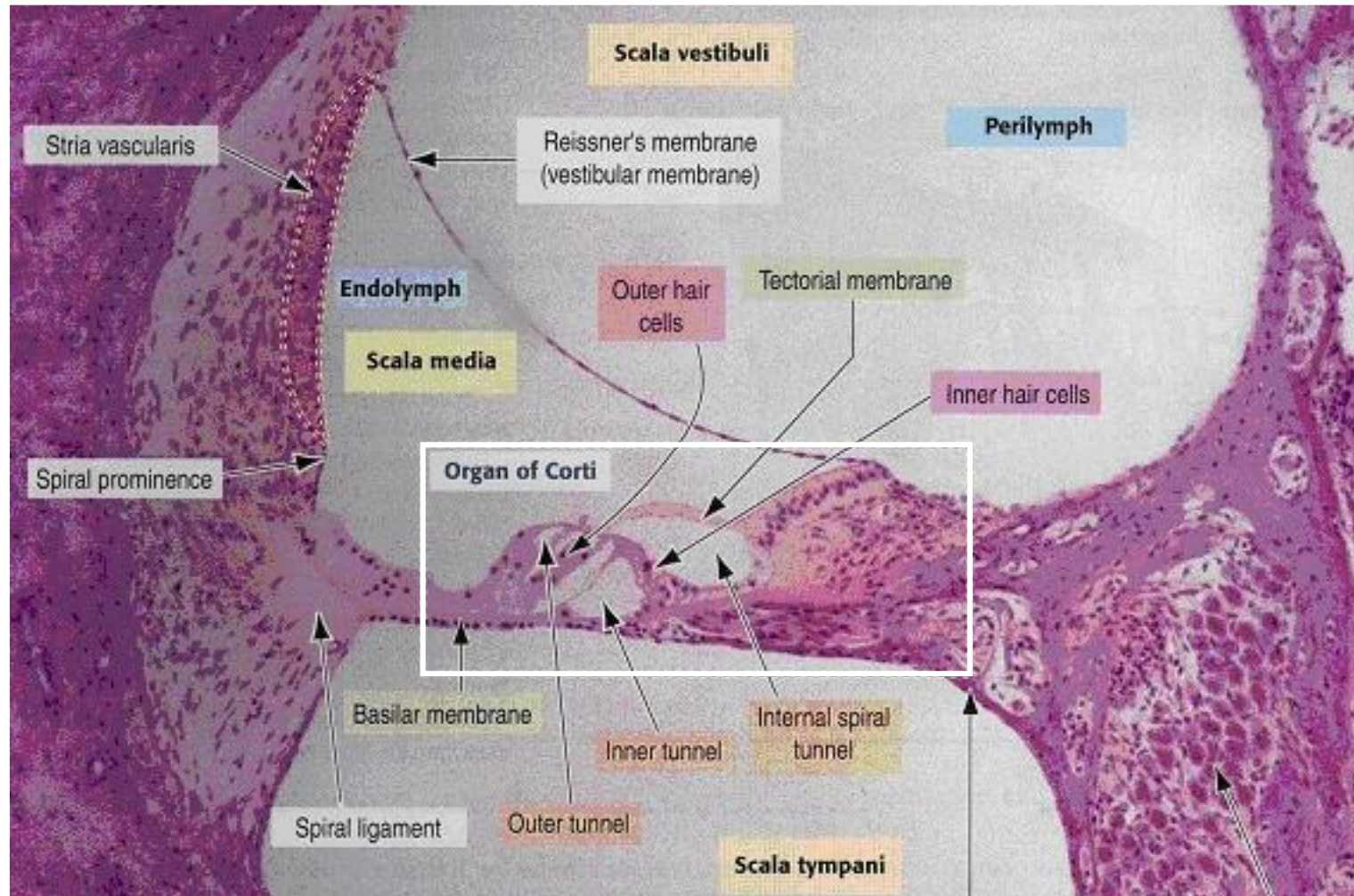
**Basilar membrane**

- between lig. spirale and bony lamina spiralis
- supports the cells of organ of Corti
- made of fibrils of keratin-like proteins



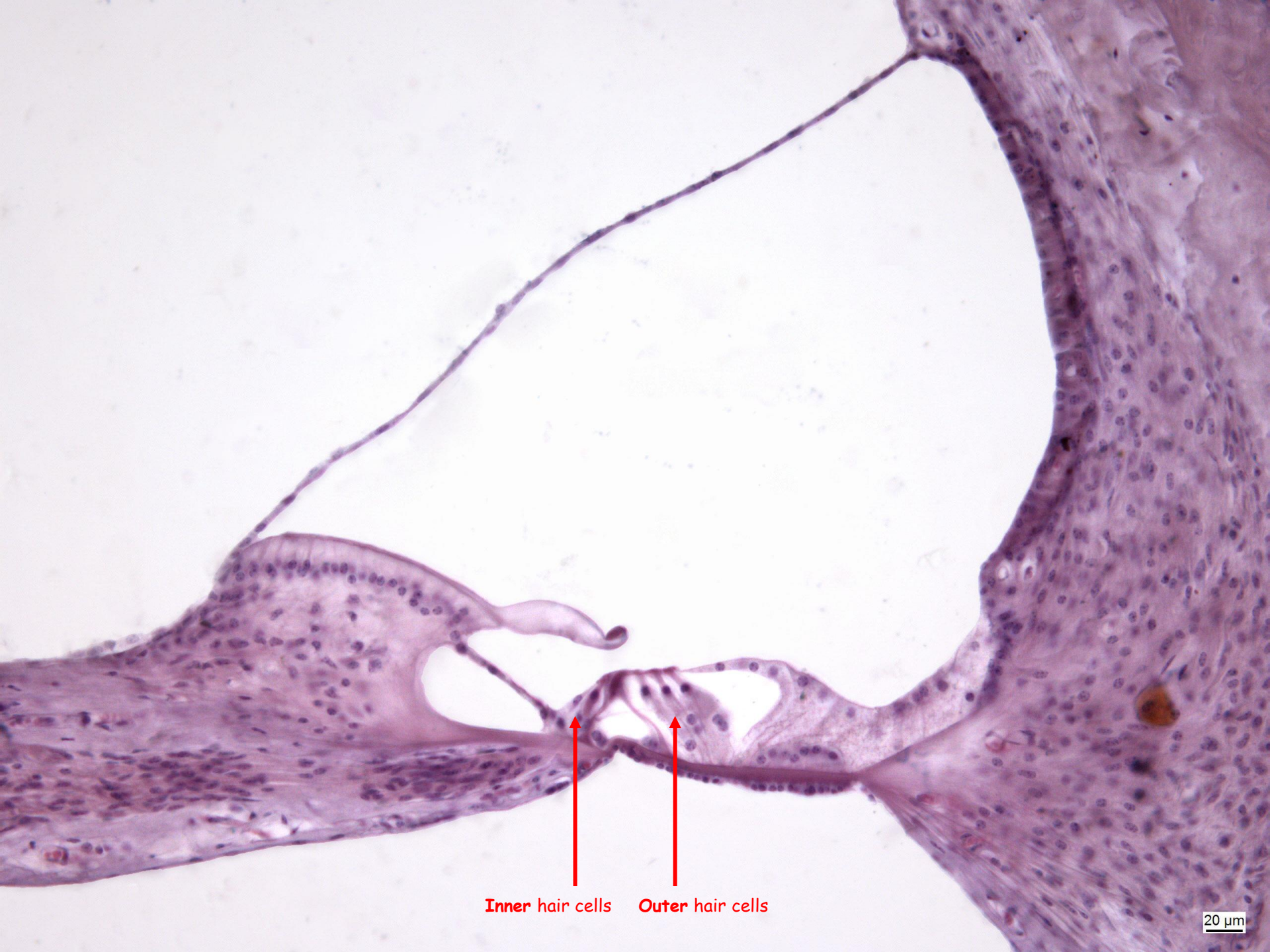
Scala media = Ductus cochlearis

# Internal ear - Organ of Corti - 1



Ganglion spirale



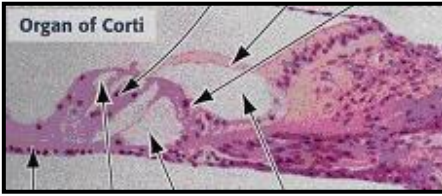


Inner hair cells

Outer hair cells

20  $\mu$ m

# Internal ear - Organ of Corti - 2



**Secondary receptor cells**

- hearing hairs - stereocilia
- in contact with tectorial membrane
- bases wrapped by dendrites of bipolar cells of ganglion spirale

**Outer hair cells**

- 3-5 rows, ~12 000, no axonema

**Inner hair cells**

- 1 row, ~3 500, no axon.

**Supporting cells**

**Hensen's cells**

**Outer phalangeal cells**

- support to hair cells, which run through the spaces between ph.

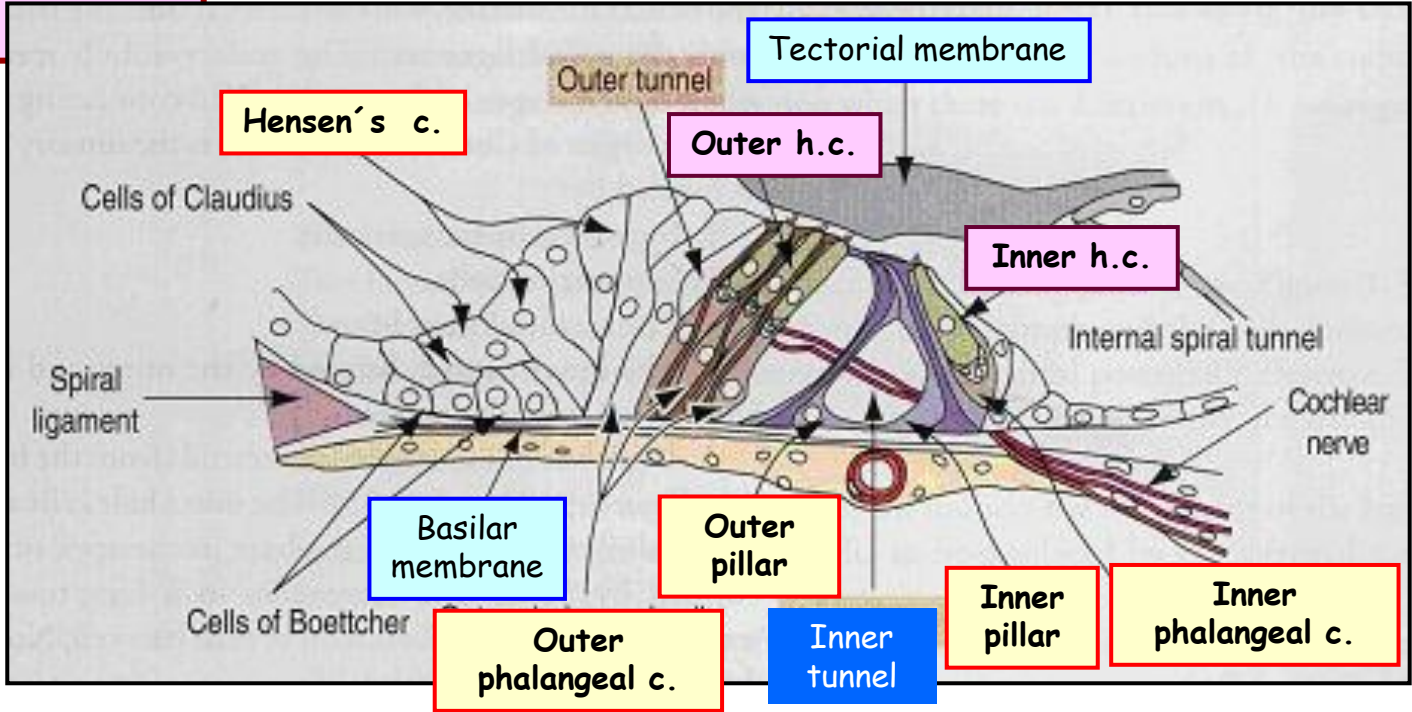
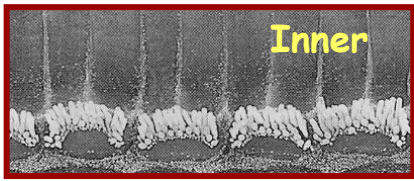
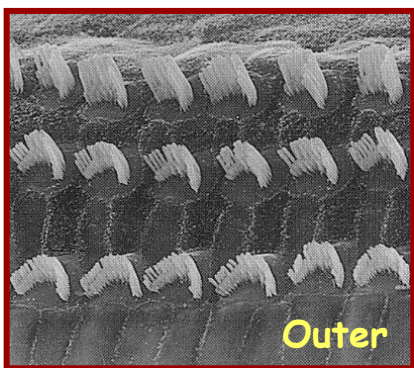
**Outer pillar of Corti**

**Outer pillar of Corti**


**Inner phalangeal cells**

- same as inner ph. cells

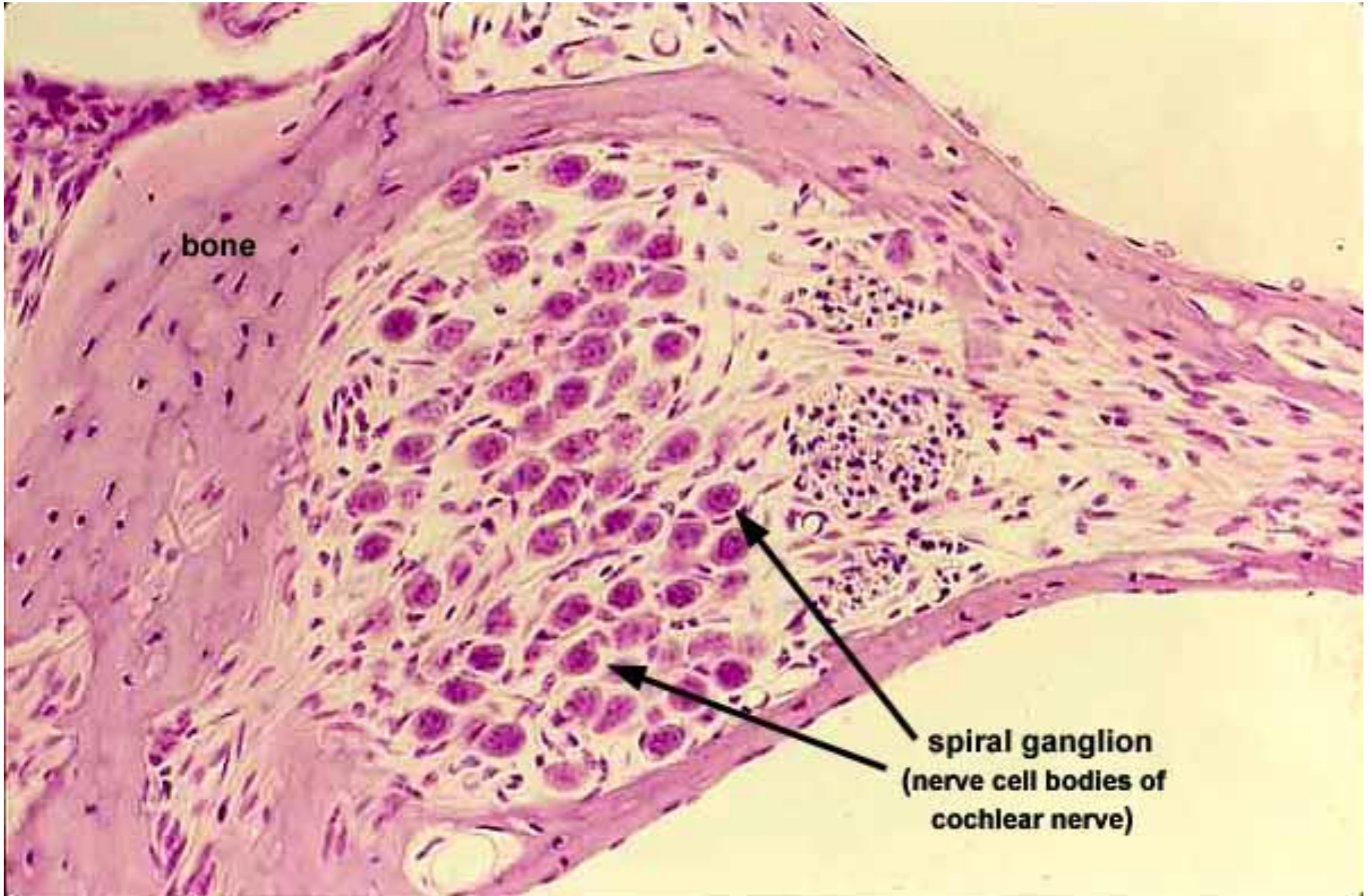
**Border cells**



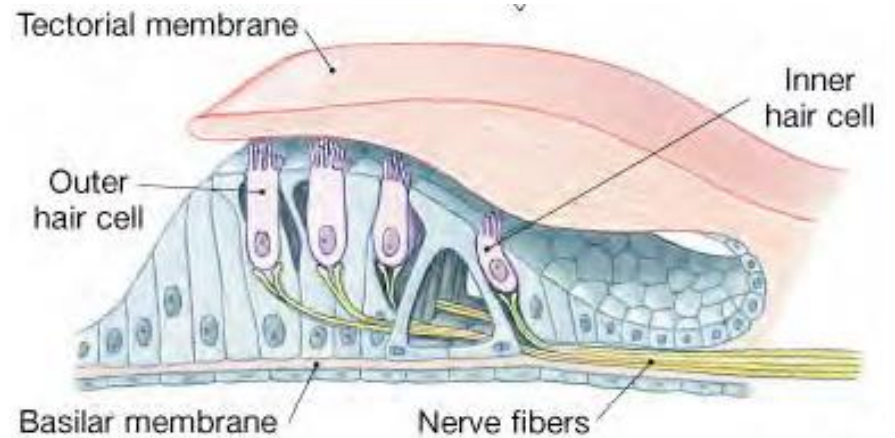
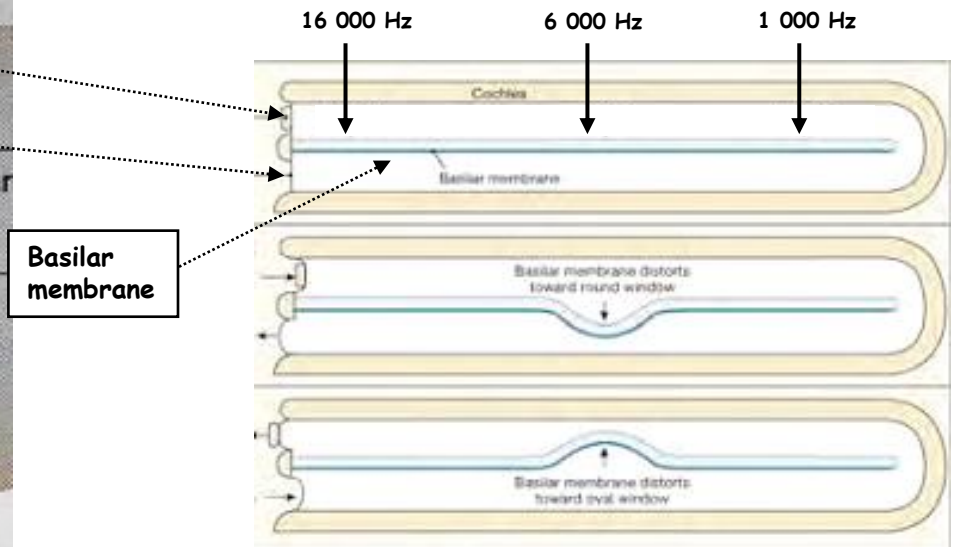
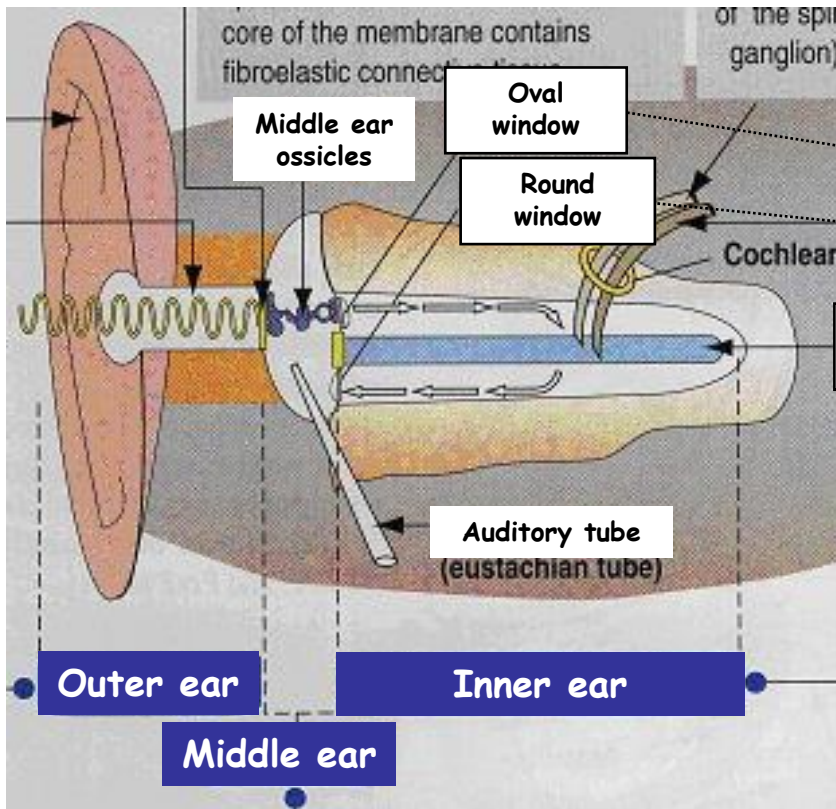
# Hair and phalangeal cells



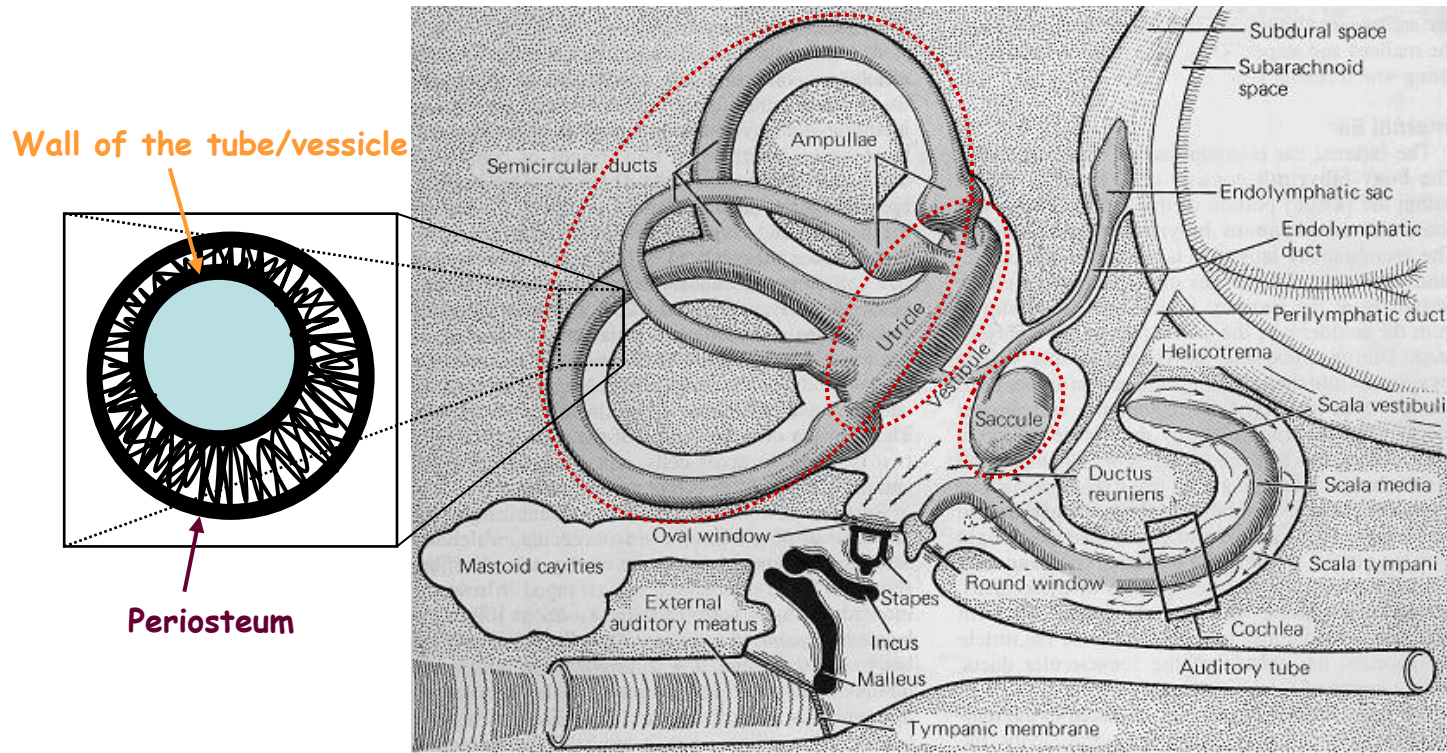
# Spiral ganglion



# Inner ear - Principle of hearing



# Inner ear - Statokinetic / Vestibular organ - 1



**Uniform composition of the wall (vessicles and tubes)**  
Thin layer of connective tissue + single-layer squamous/cuboidal epithelium.

**Unifying concept of the composition of sensing elements**  
(vessicles - **maculae**; tubes - **cristae ampullares**)  
Thickening of the wall with neuroepithelial cells innervated by branches of n. vestibularis.

# Inner ear - Statokinetic / Vestibular organ - 2

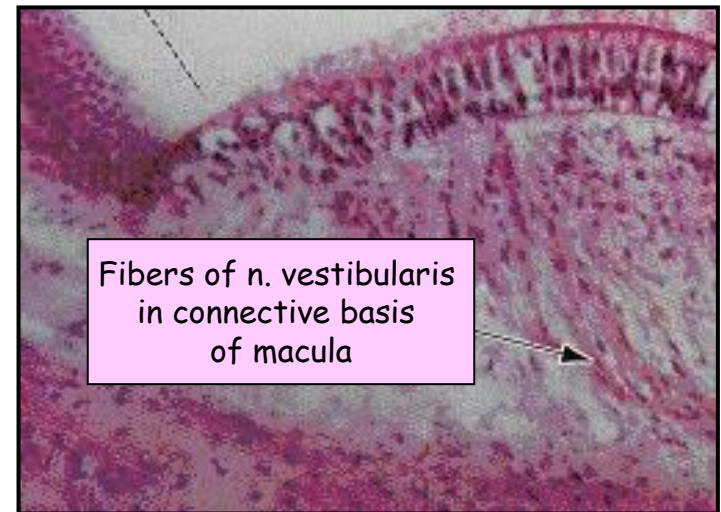
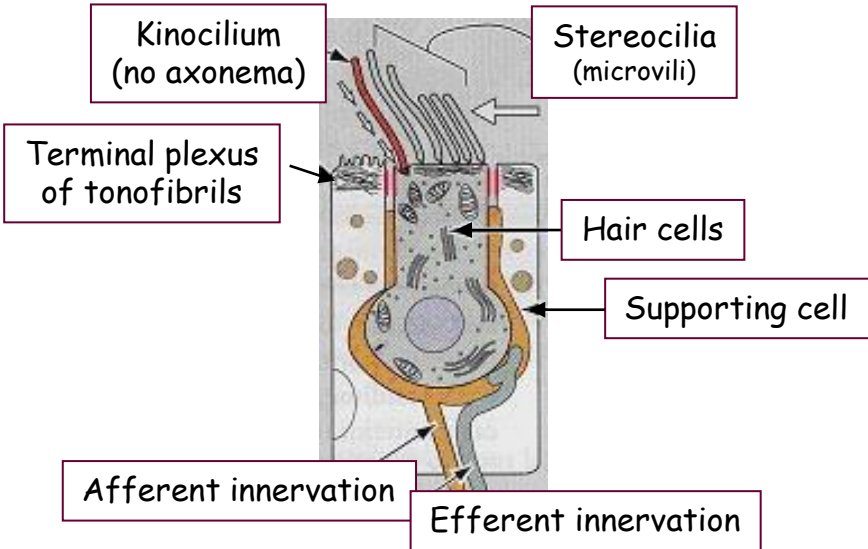
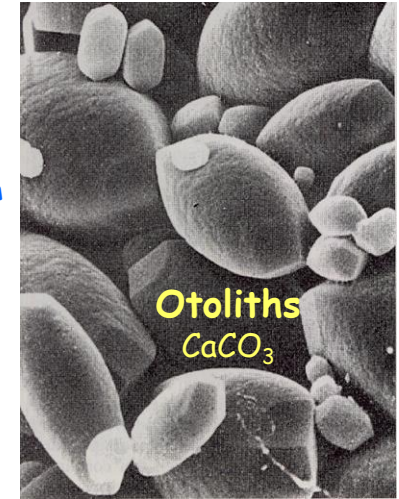
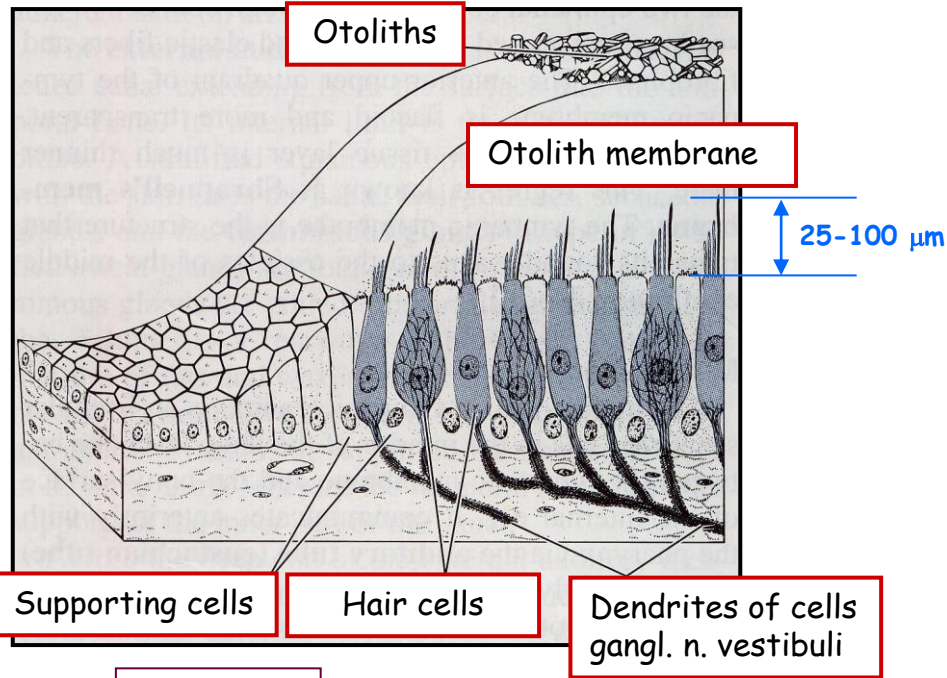
## Sensing of static equilibrium (maculae = static spots)

Deviation from the gravity force  
(gravity force of otoliths)  
max. pressure - max. pull

**Position of maculae**

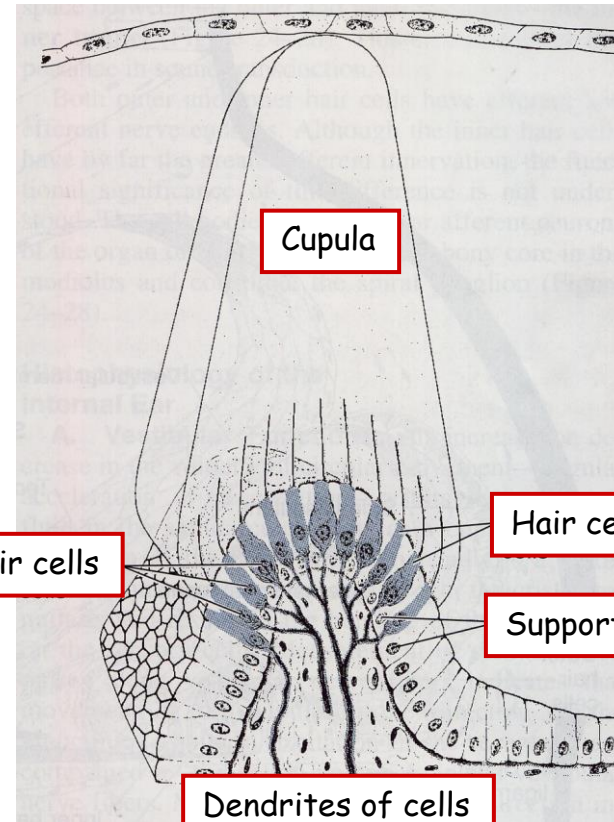
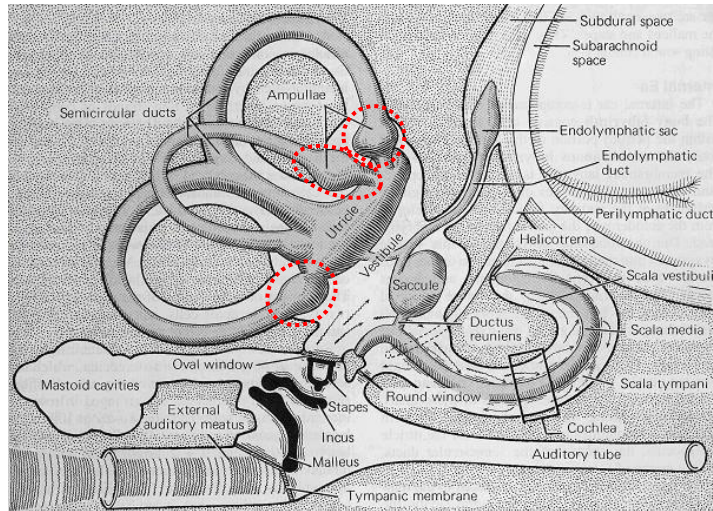
**Saccul**  
bottom

**Utricl**  
lateral wall

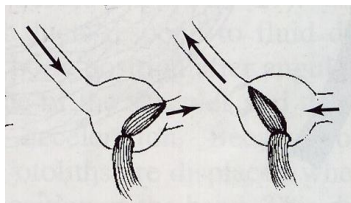


# Inner ear - Statokinetic / Vestibular organ - 3

## Sensing of dynamic equilibrium (cristae ampulares)



Reaction on acceleration/deceleration  
(movement of endolymph)



**Position of cristae ampullares**

- in ampules of semicircular ducts
- ridges perpendicular to axis of SDs

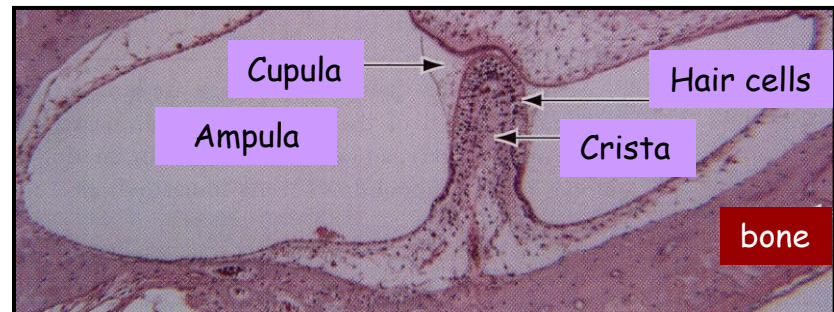
Hair cells

Cupula

Hair cells

Supporting cells

Dendrites of cells  
gangl. n. vestibuli



Cupula

Ampulla

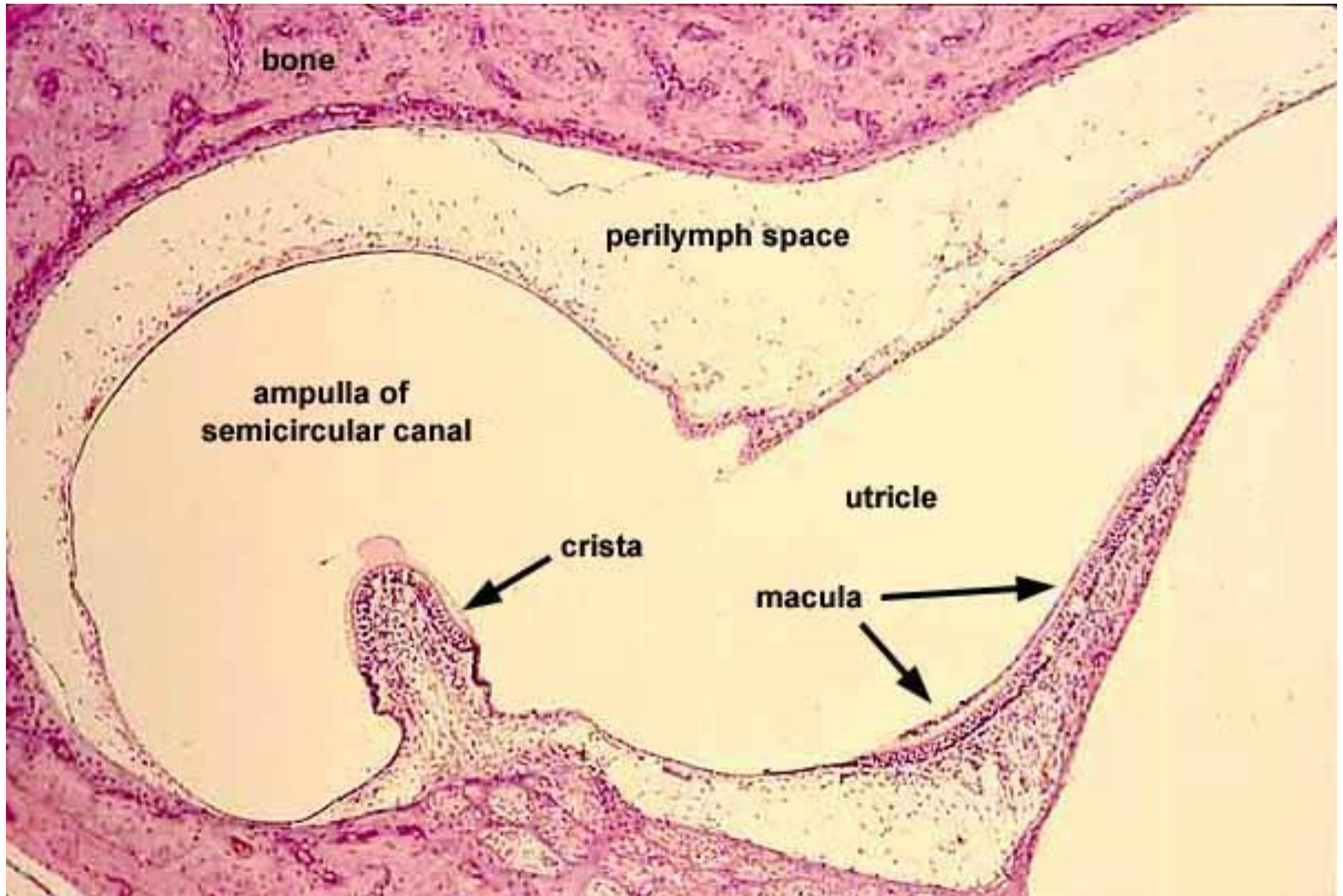
Hair cells

Crista

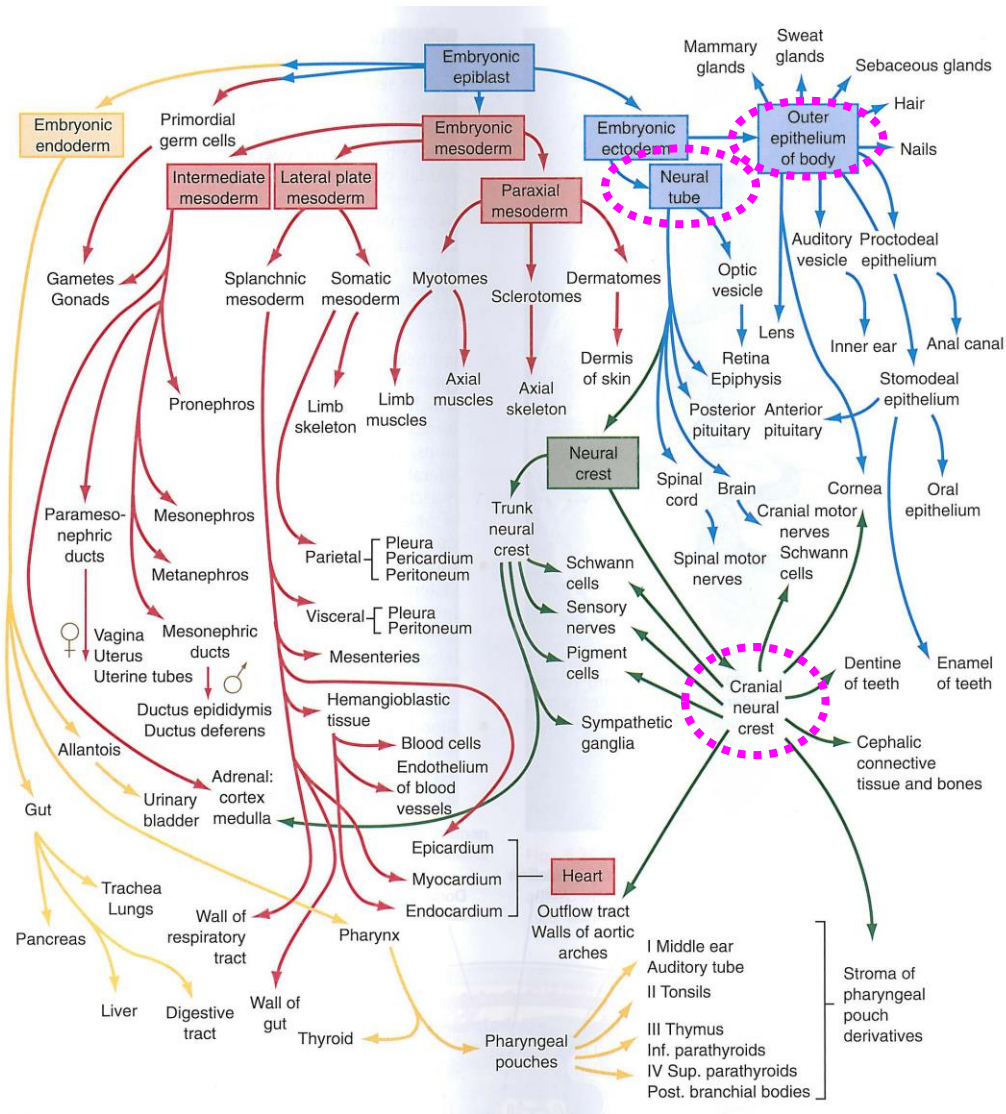
bone



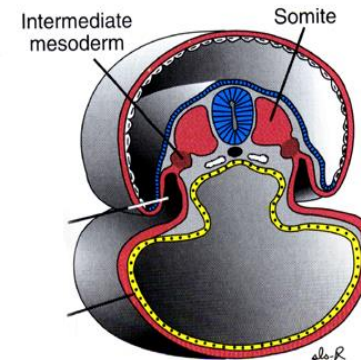
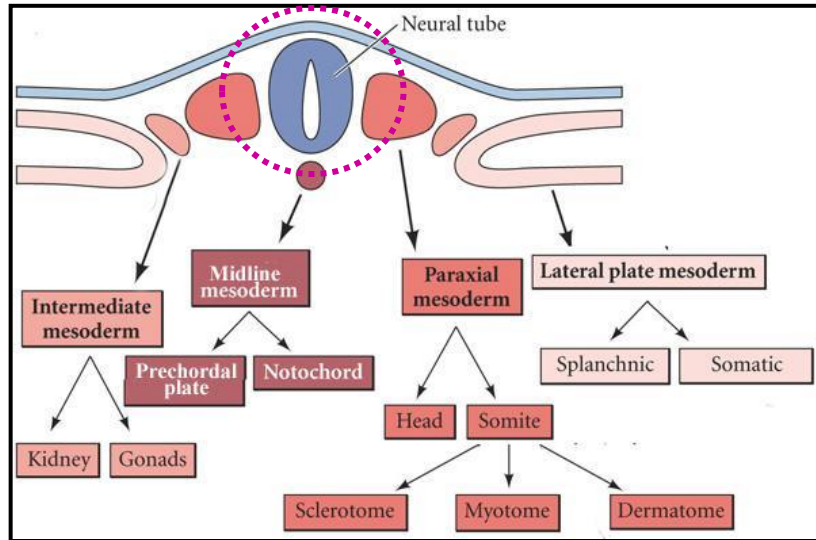
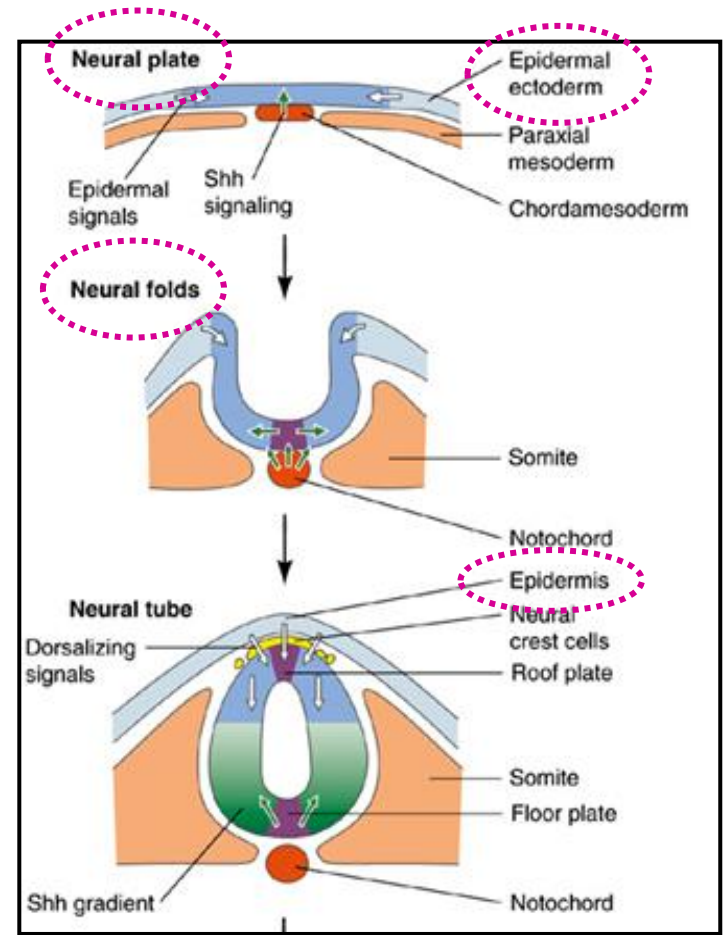
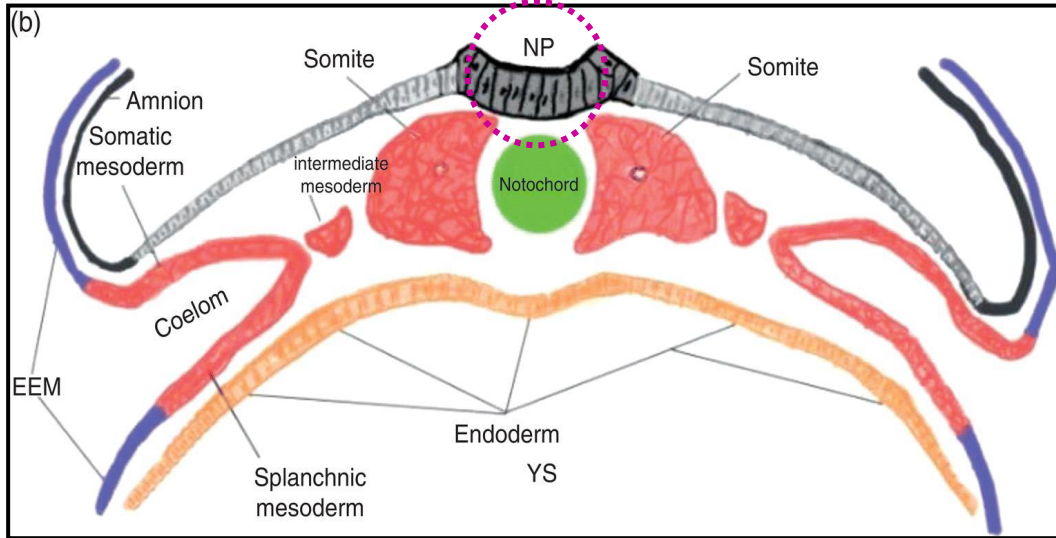
# Membranous labyrinth



# Development of sense organs - Overall picture

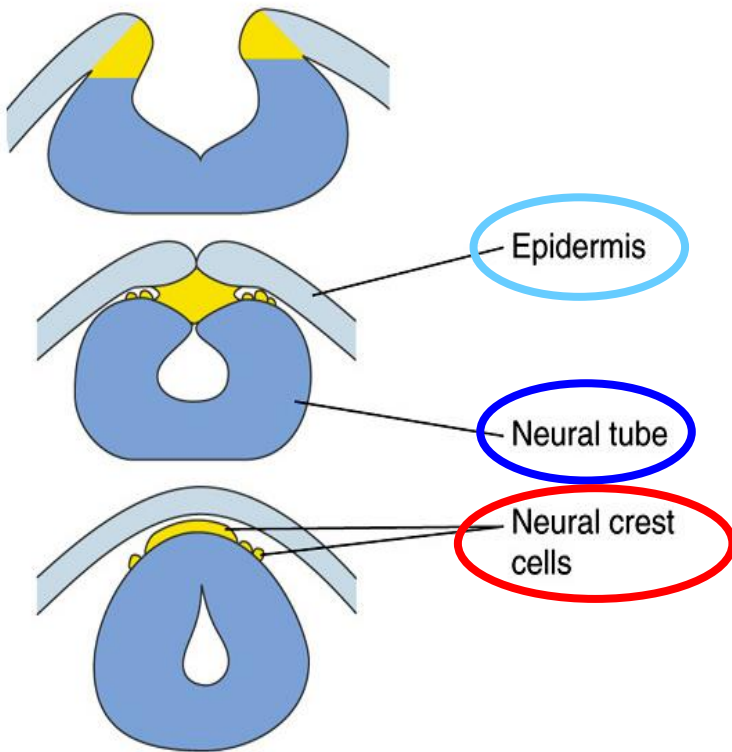


# Sense organs - Reminder - Neural tube

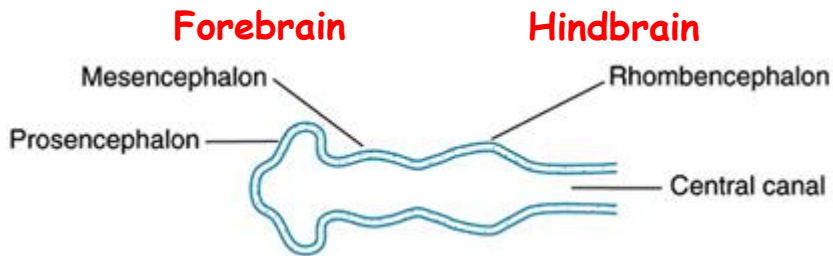


# Sense organs - Reminder - Neural crest

Arise from both  
dorsal epidermis and neural plate



# Sense organs - Cranial neural tube + Placodes

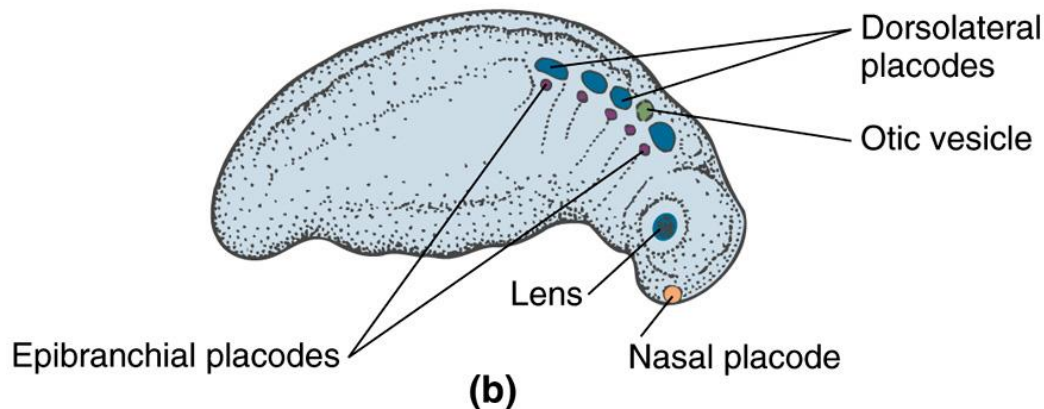


Brain after 4 weeks of development

**Placodes:** patches of dense columnar epithelium in the epidermis covering the head - their formation is induced by underlying brain and mesenchymal tissue - **develop in week 4**



Placode  
(a)



(b)

## Dorsolateral placodes

Contribute to:

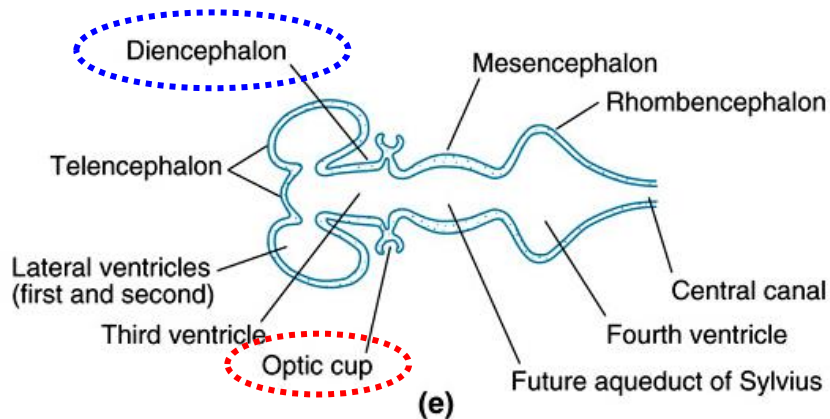
- eye - lens placode
- ear - otic placode
- nose - nasal placode
- sensory ganglia

## Epibranchial placodes

Develop into:

- sensory ganglia of cranial nerves (V, VII, IX, X)

# Sense organs - Eye development 1



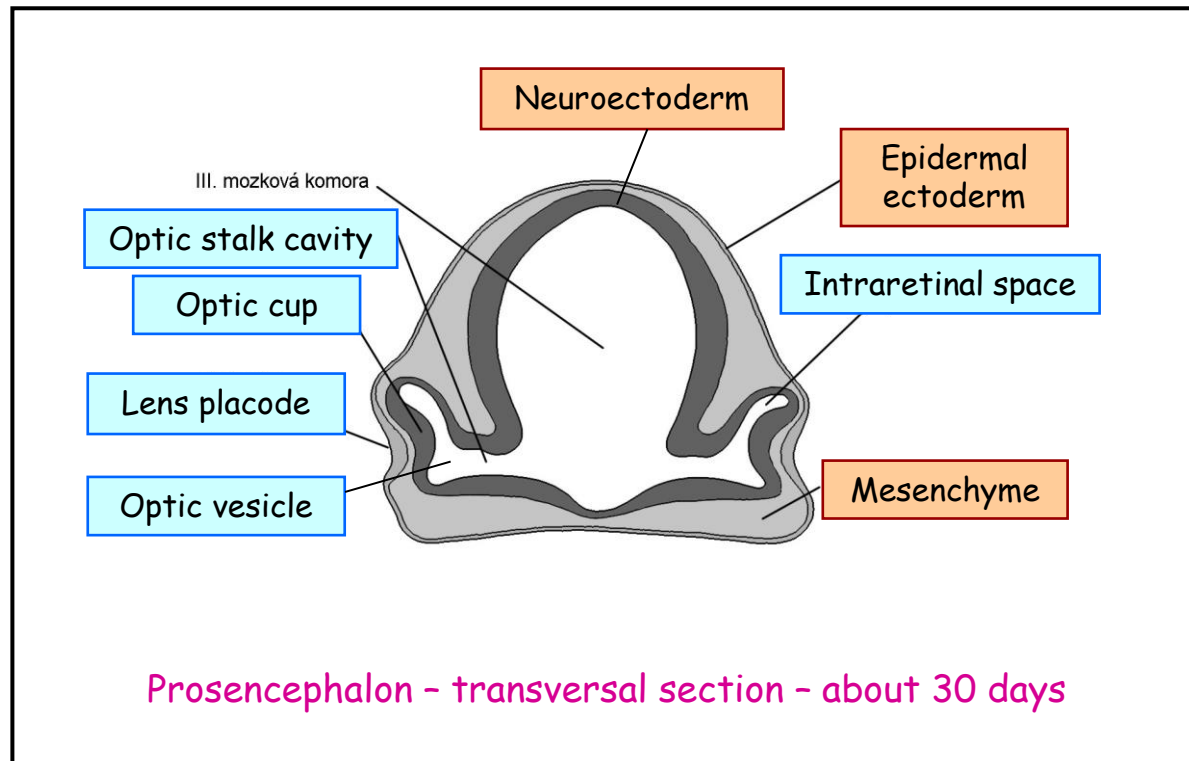
Brain after 5 weeks of development

Neural plate ectoderm → prosencephalon (forebrain) **eye fields** →

→ neural plate growth carries eye field region forward →

→ eye field invaginates forming **optic grooves (sulci)**

## Sense organs - Eye development 2



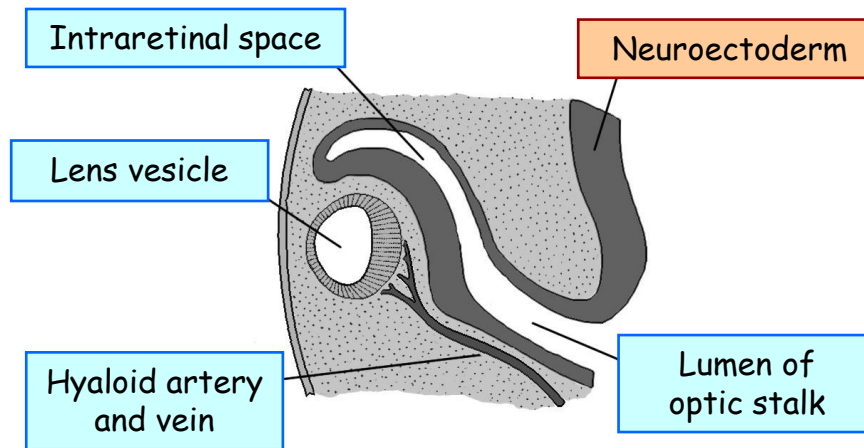
**Lens placode:** the ectoderm invaginates in response to signals from the optic cup underneath. It then pinches off as a lens vesicle. Cells elongate to fill the vesicle and start to synthesize crystallins.

**Optic cup:** forms from the neural tube by invagination. The opening (choroid fissure) closes forming a round optic cup, an extension of the brain.

**Optic stalk:** connection to the brain that is filled with neurons to form the optic nerve.

**Reciprocal interaction:** the lens induces the formation of the optic cup and the cup regulates formation of the lens.

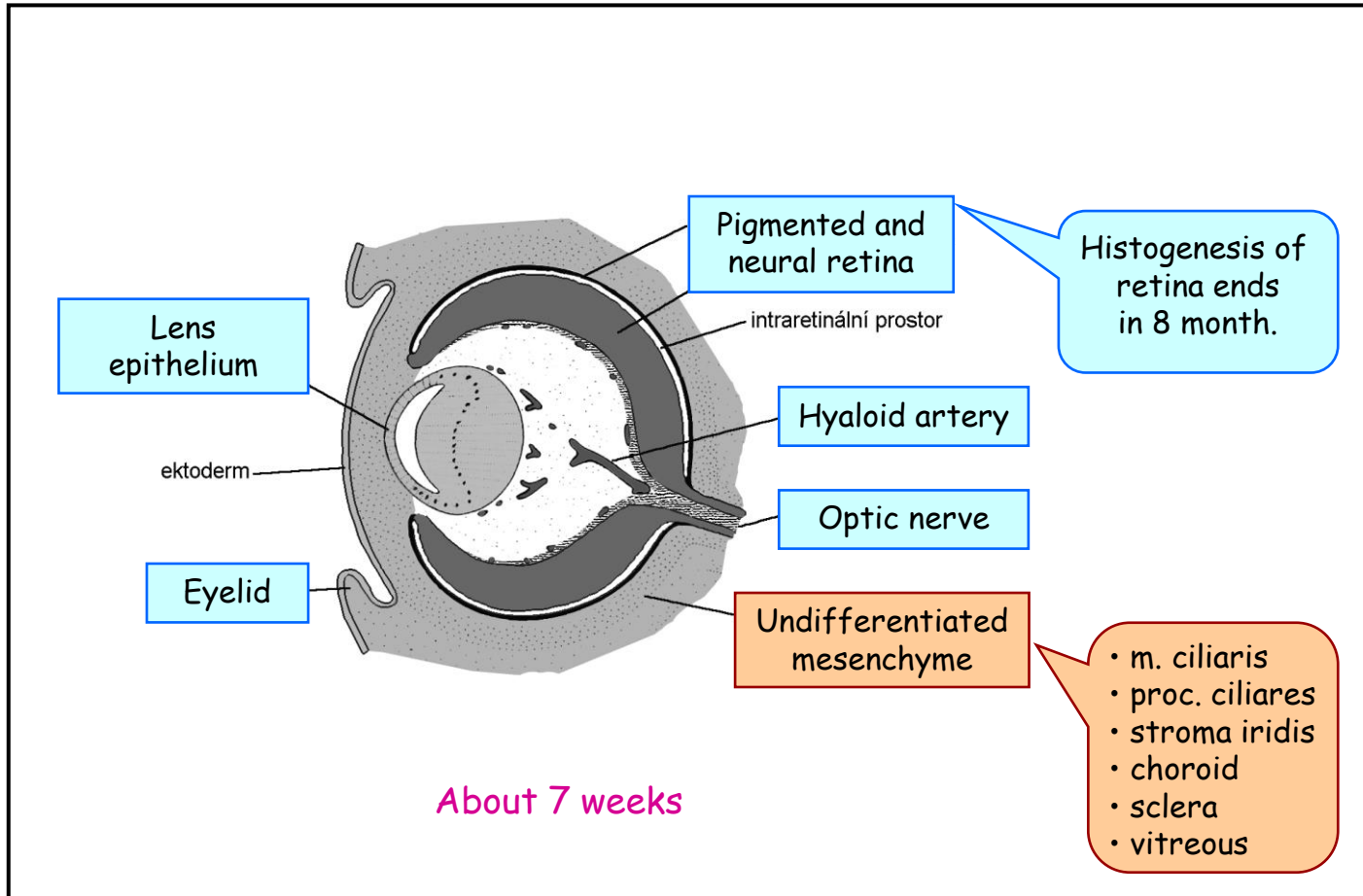
# Sense organs - Eye development 3



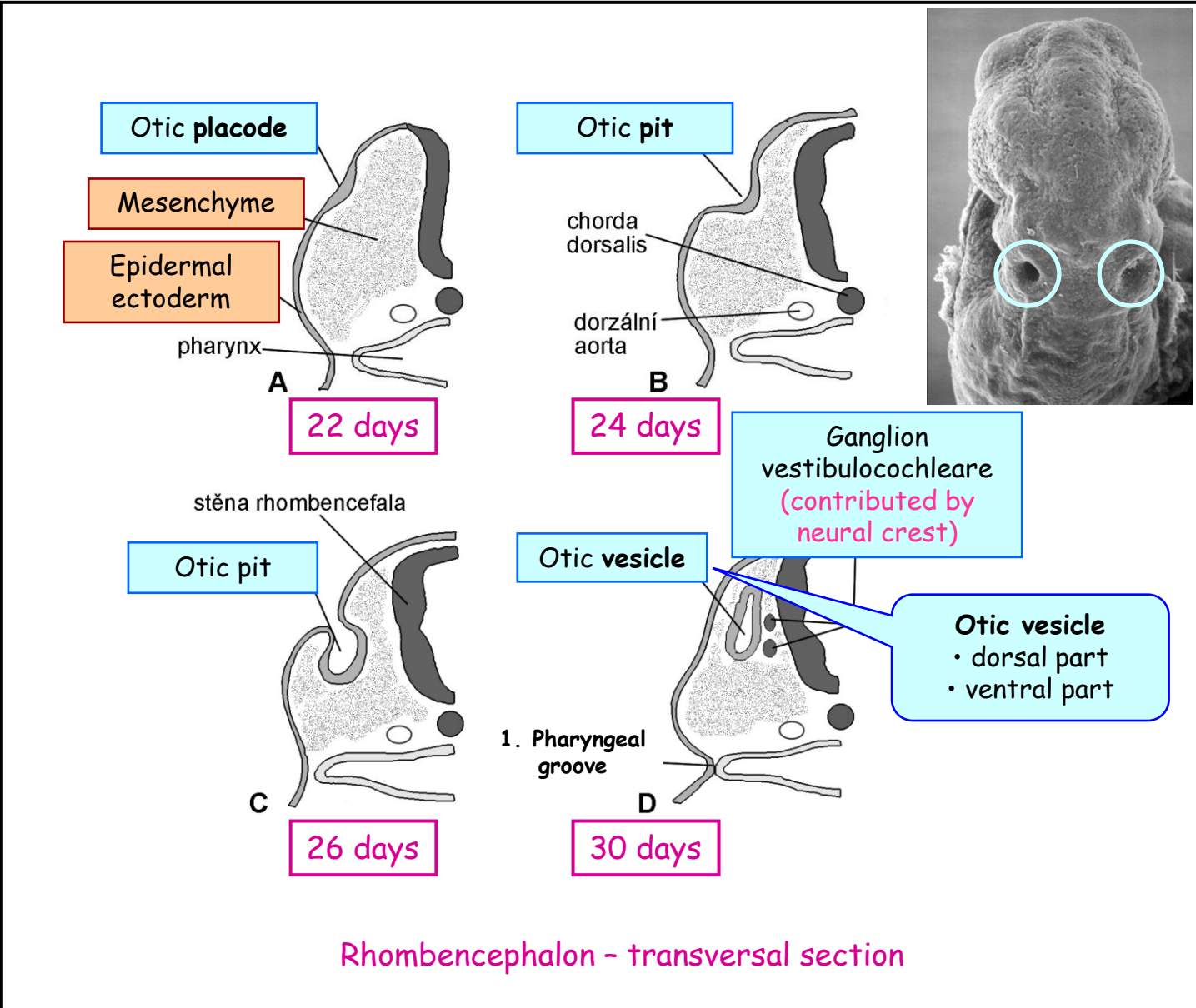
Diencephalon - transversal section - 6 weeks



# Sense organs - Eye development 4

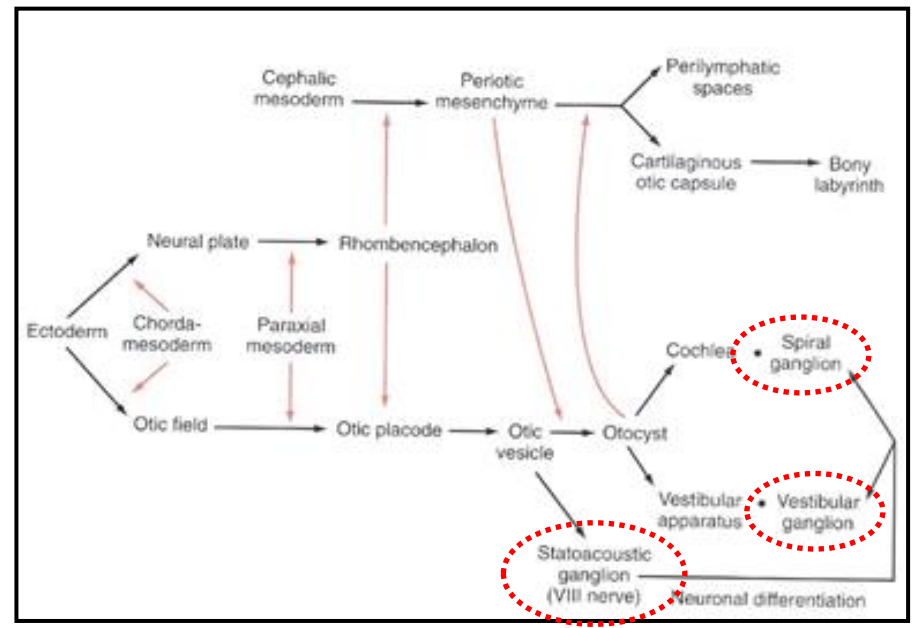
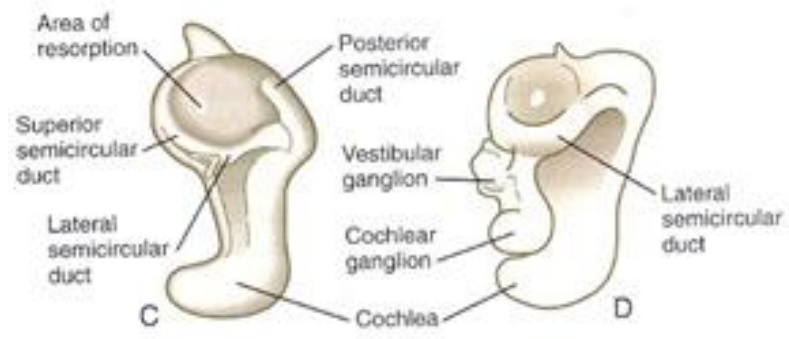


# Ear development - Inner ear 1

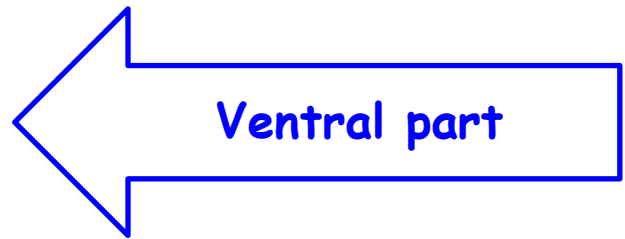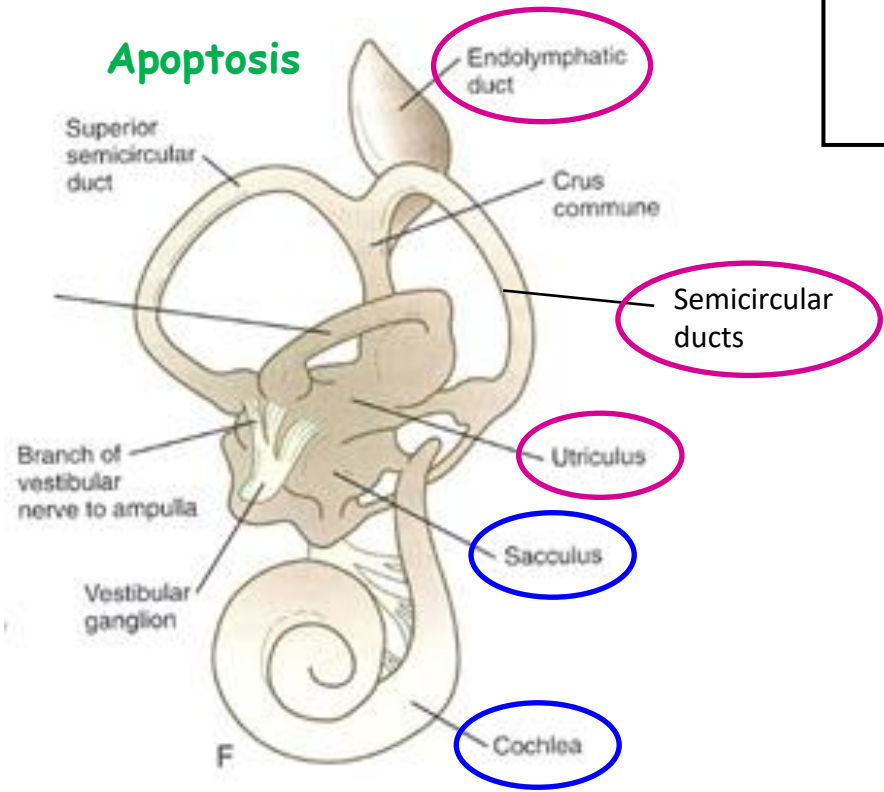


# Ear development - Inner ear 2

## Elongation

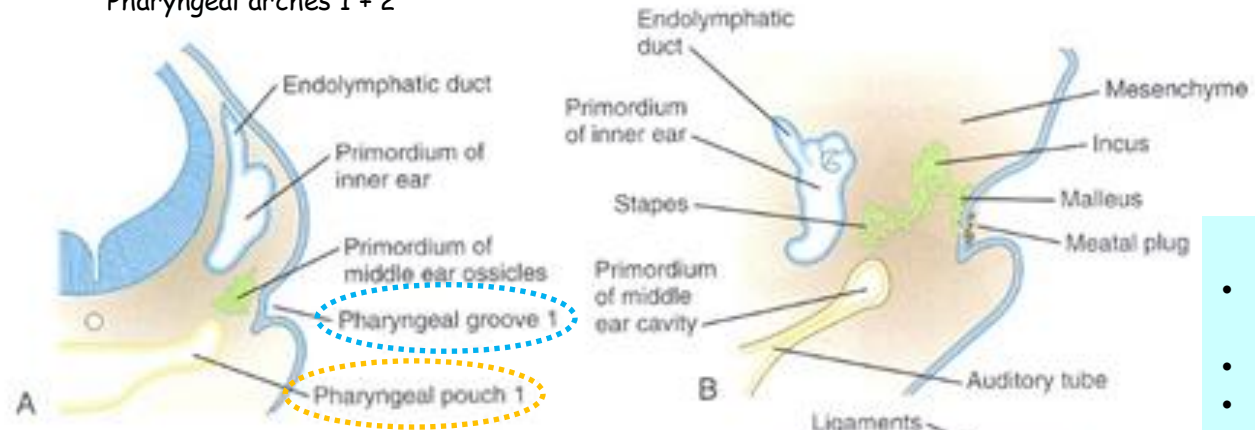


## Apoptosis



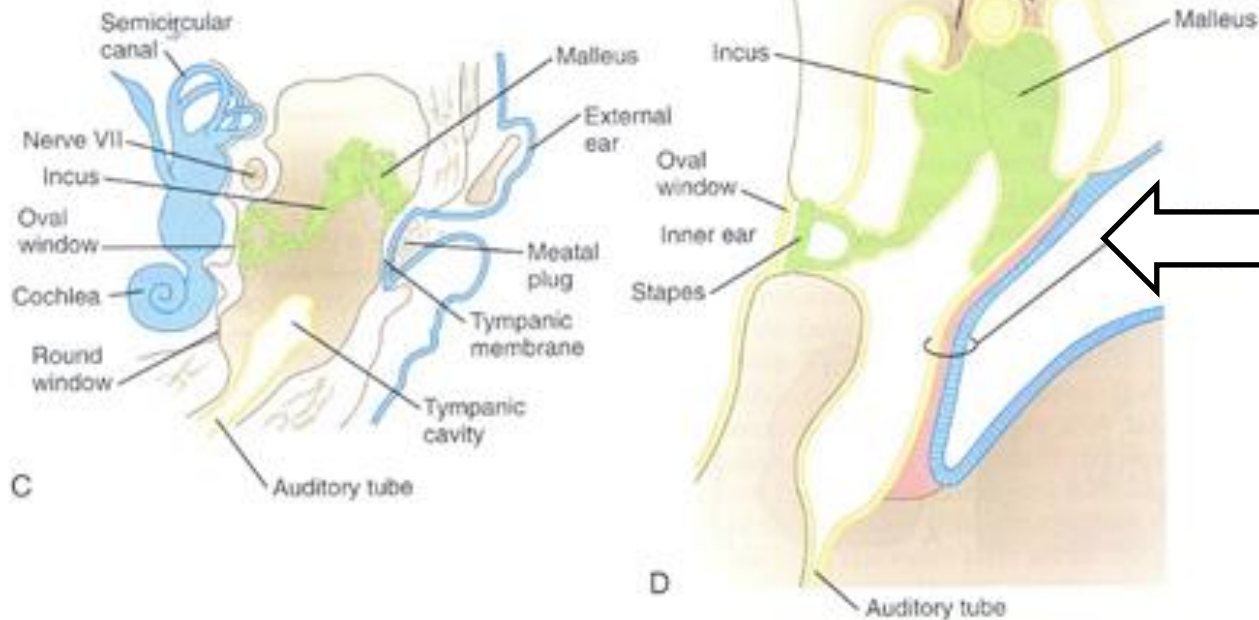
# Ear development - Middle ear

Pharyngeal arches 1 + 2



## Ossicles

- Mesenchyme of neural crest origin (phar. arches 1+2)
- Embedded in mesenchyme
- Apoptosis late in pregnancy

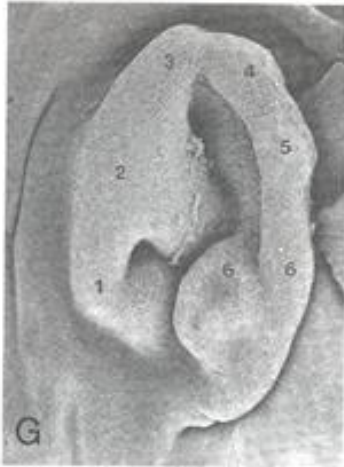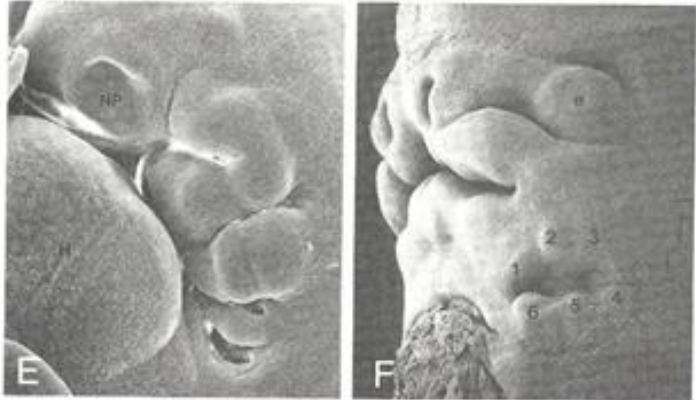
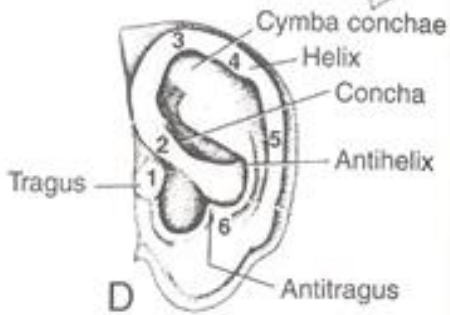
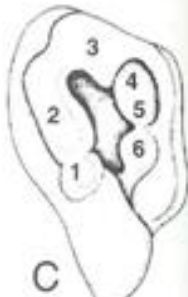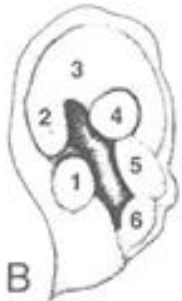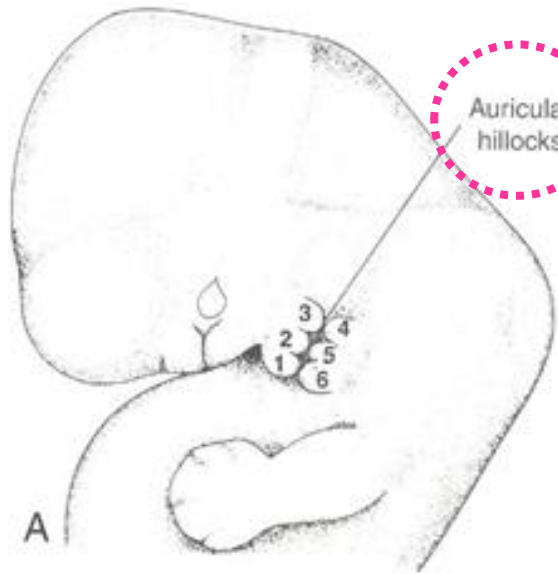


## Tympanic membrane

Endoderm  
Mesoderm  
Ectoderm

# Ear development - External ear

Mesenchyme



External auditory meatus - ectoderm

Thank you for your attention !