

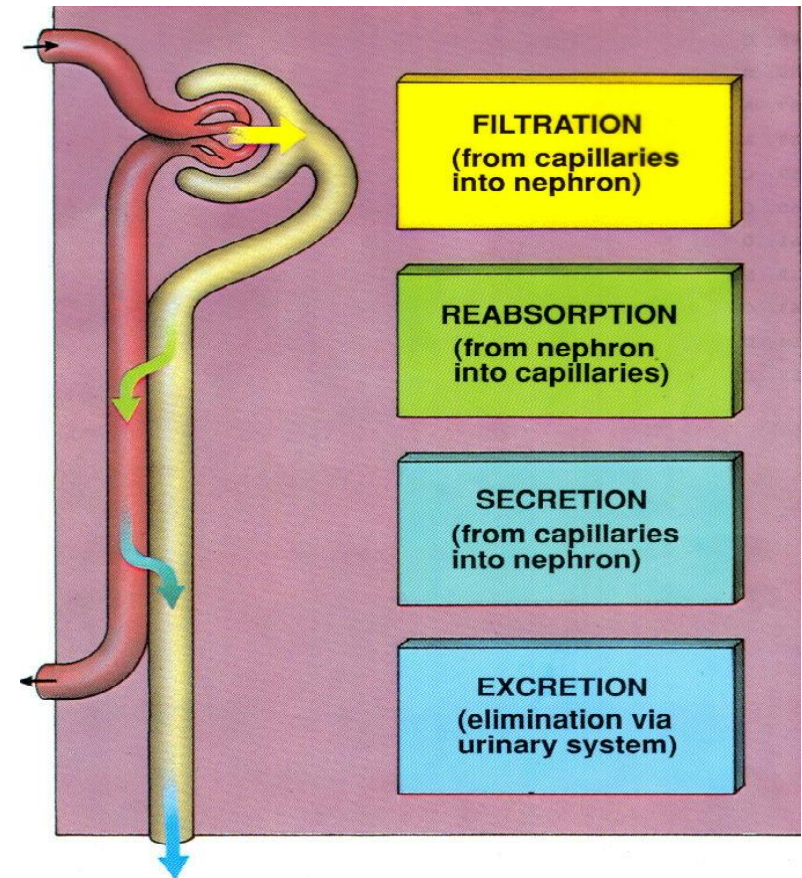
Urinary system

Aleš Hampl

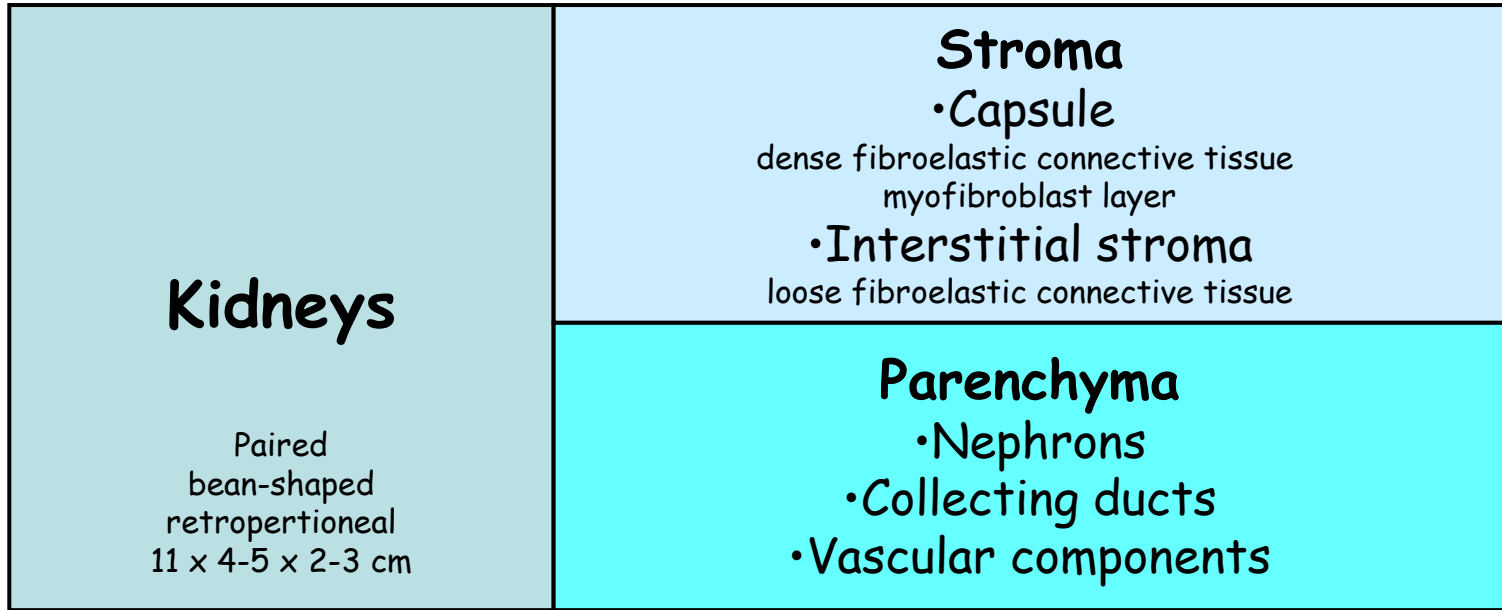
October 2024

Functions of urinary system

- 1. Regulating blood volume and pressure
- 2. Regulating plasma concentrations of sodium, potassium, chloride and other ions
- 3. Stabilising blood pH
- 4. Conserving nutrients
- 5. Detoxifying poisons (with the liver)



Components of urinary system



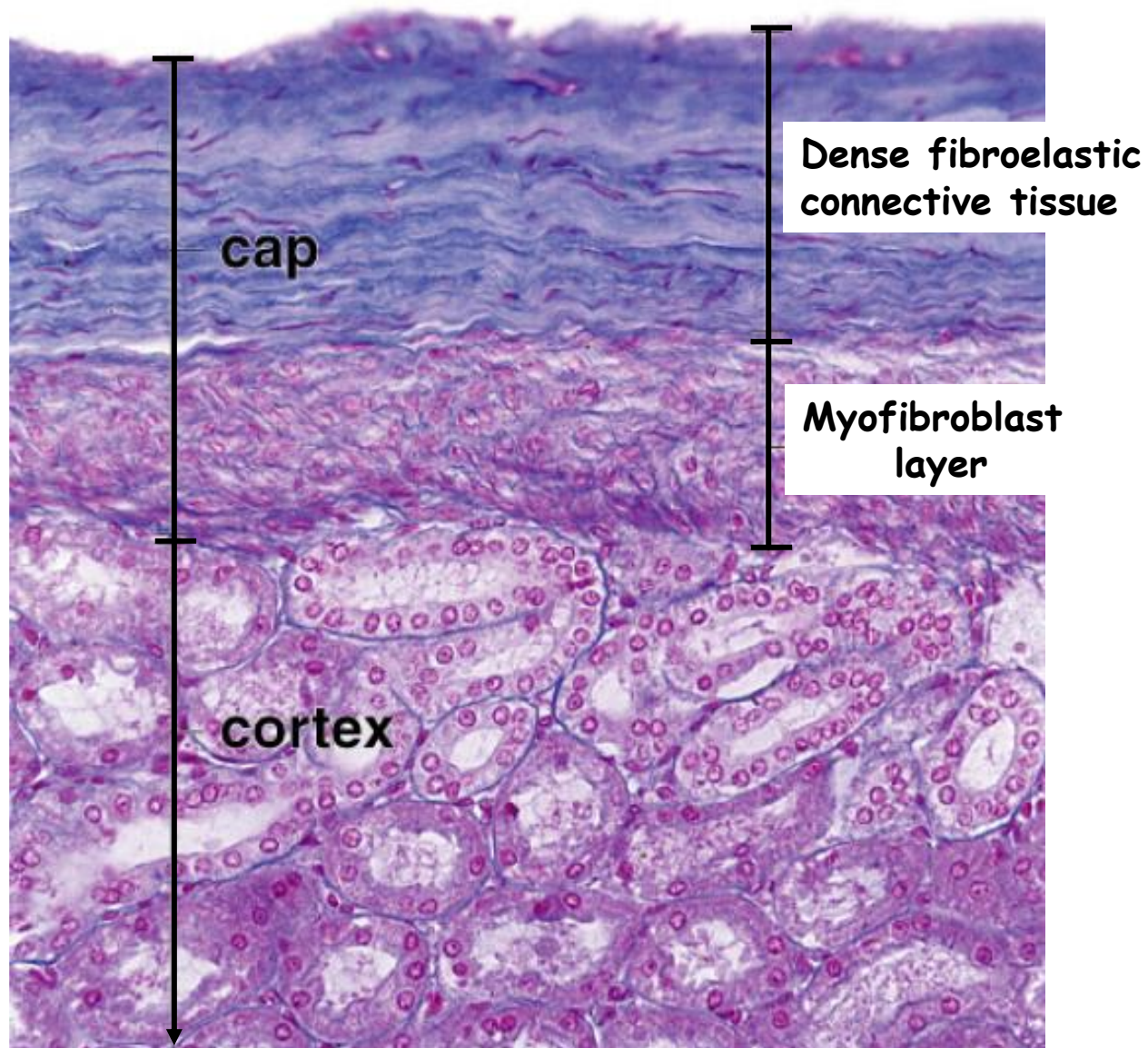
Urethers

Urinary bladder

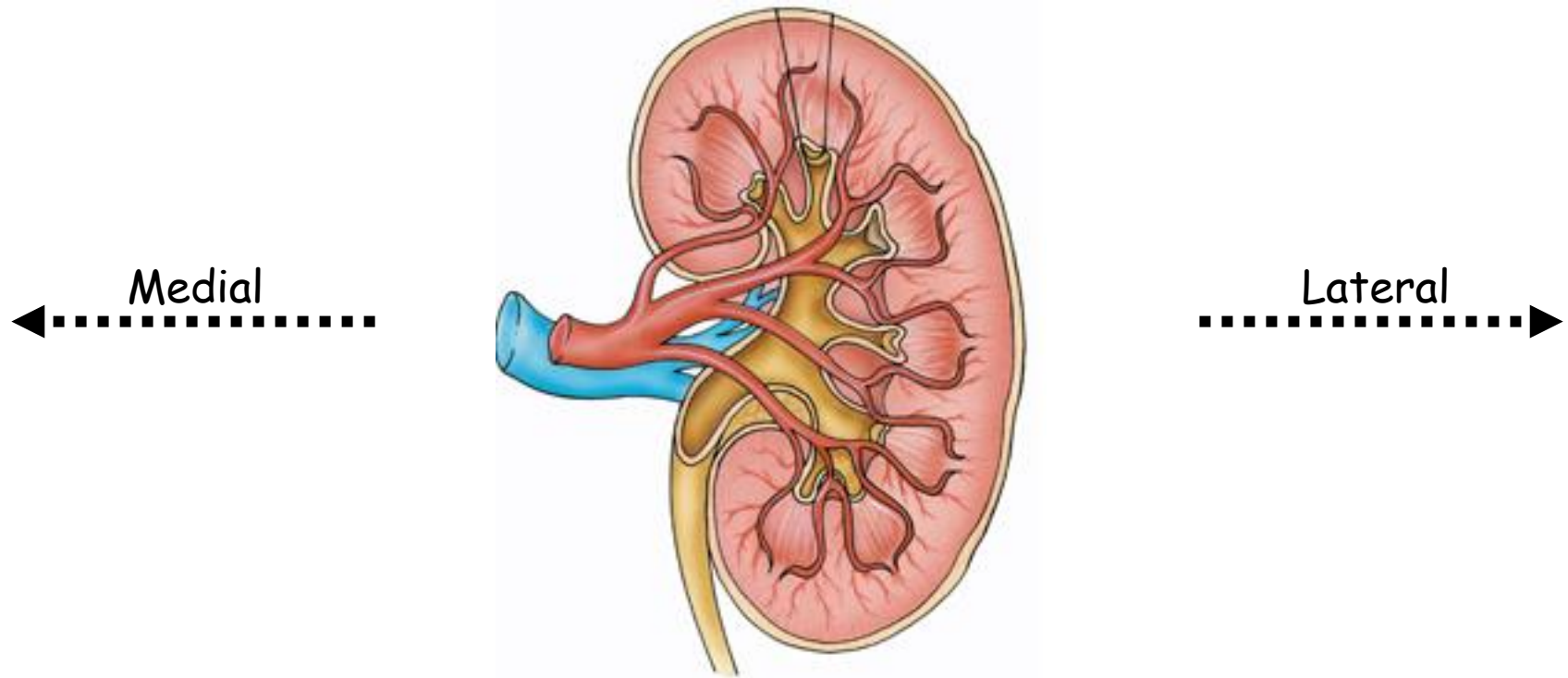
Urethra

Urinary tract

Kidneys capsule



Overall organization of kidney



Hilum - portal for renal vessels, nerves and urether

Renal sinus - cavity deep to hilum occupied by renal pelvis and vessels

Renal pelvis - expansion of ureter, extension to **major and minor calyces**

Renal parenchyma - medulla + cortex

- Cortex
- Medulla

Lobe

Cortical arch

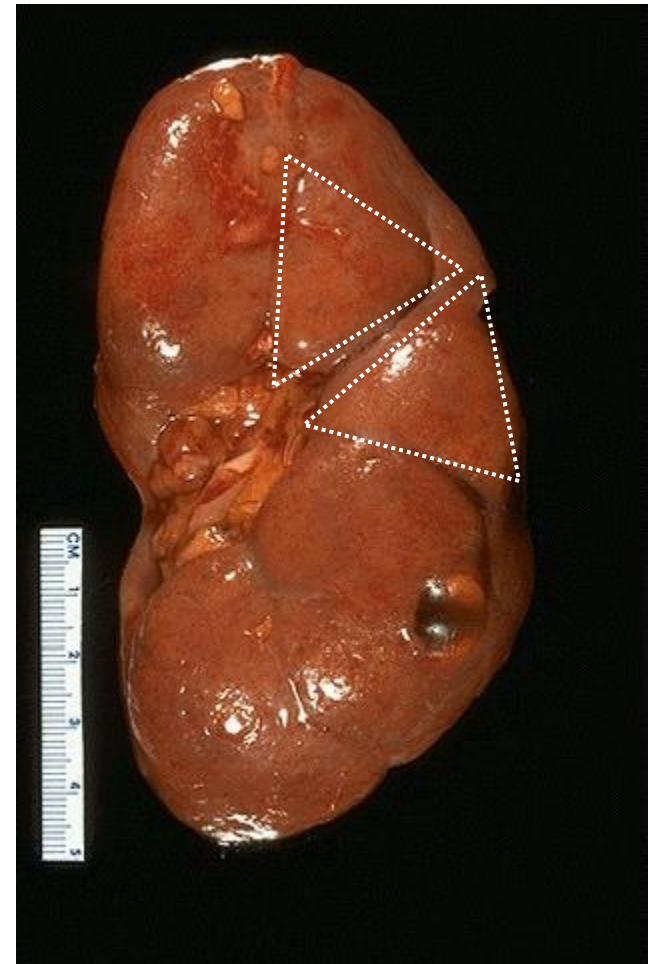
Renal column

Extension of cortex into medulla

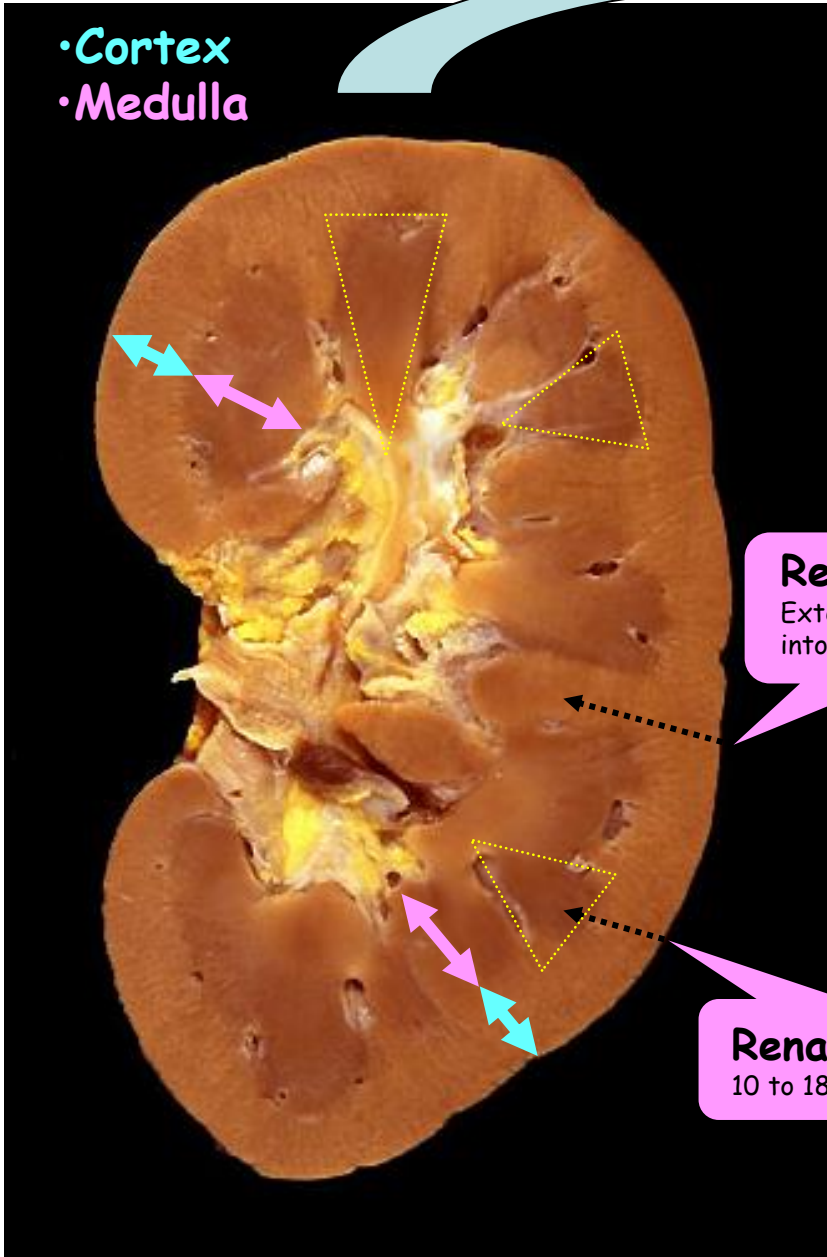
Renal pyramid

10 to 18 per kidney

Lobular structure of the kidney



•Cortex
•Medulla

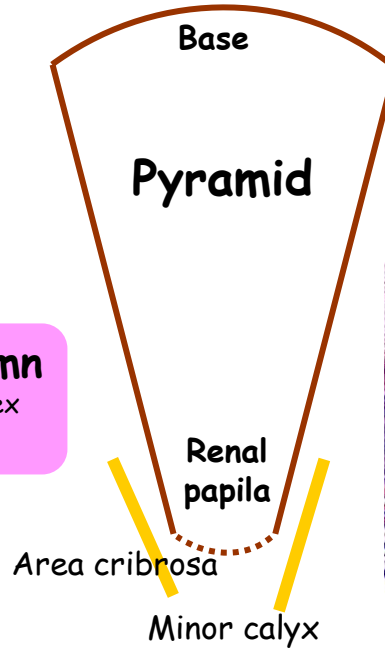


Renal collumn

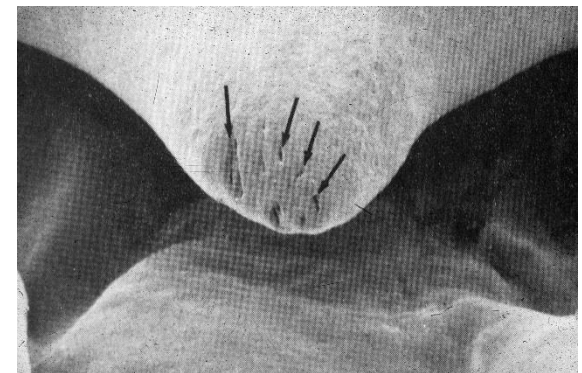
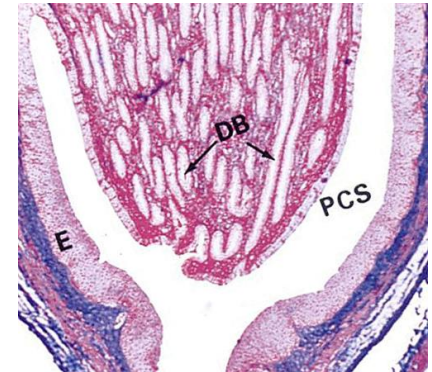
Extension of cortex into medulla

Renal pyramid

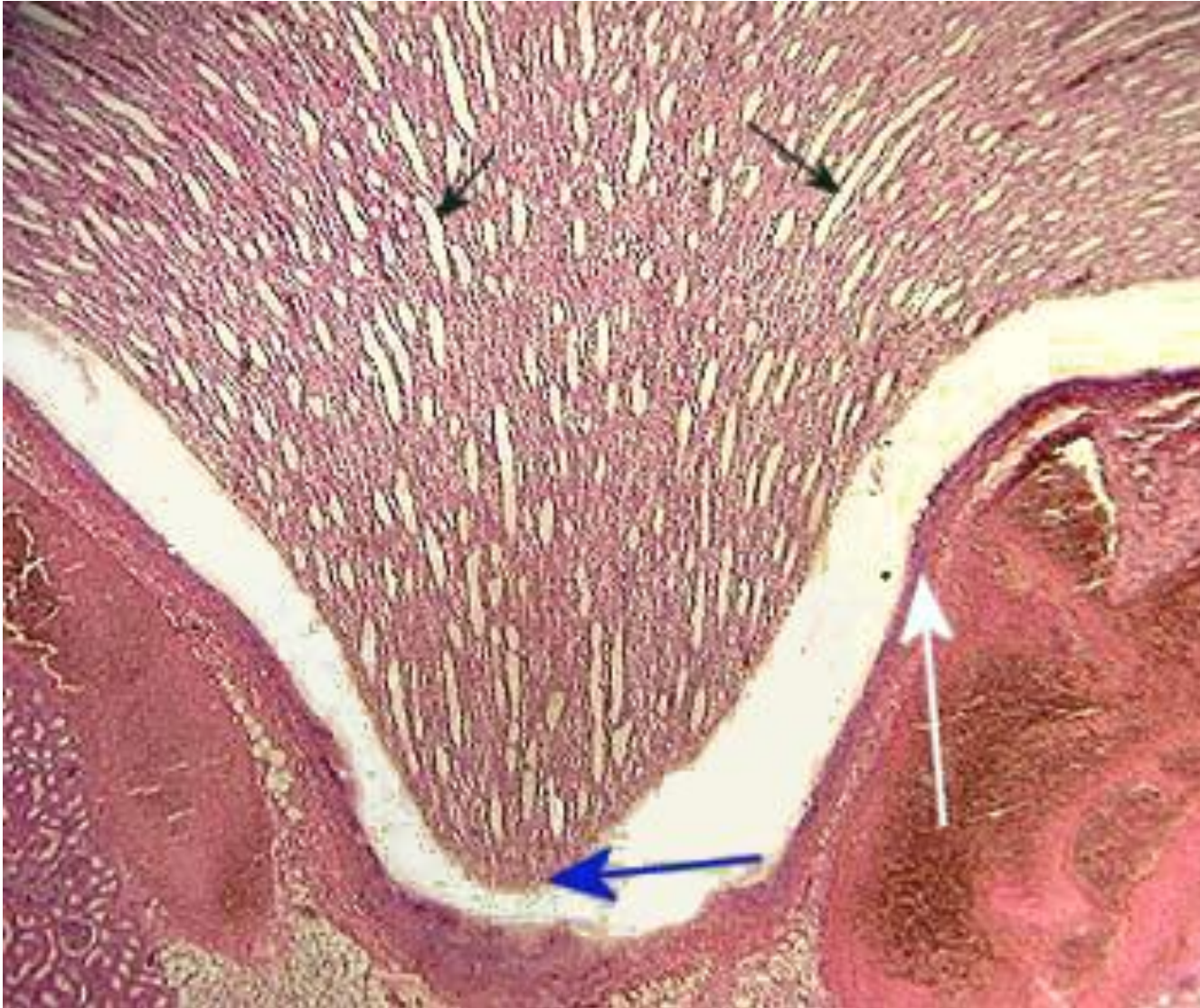
10 to 18 per kidney



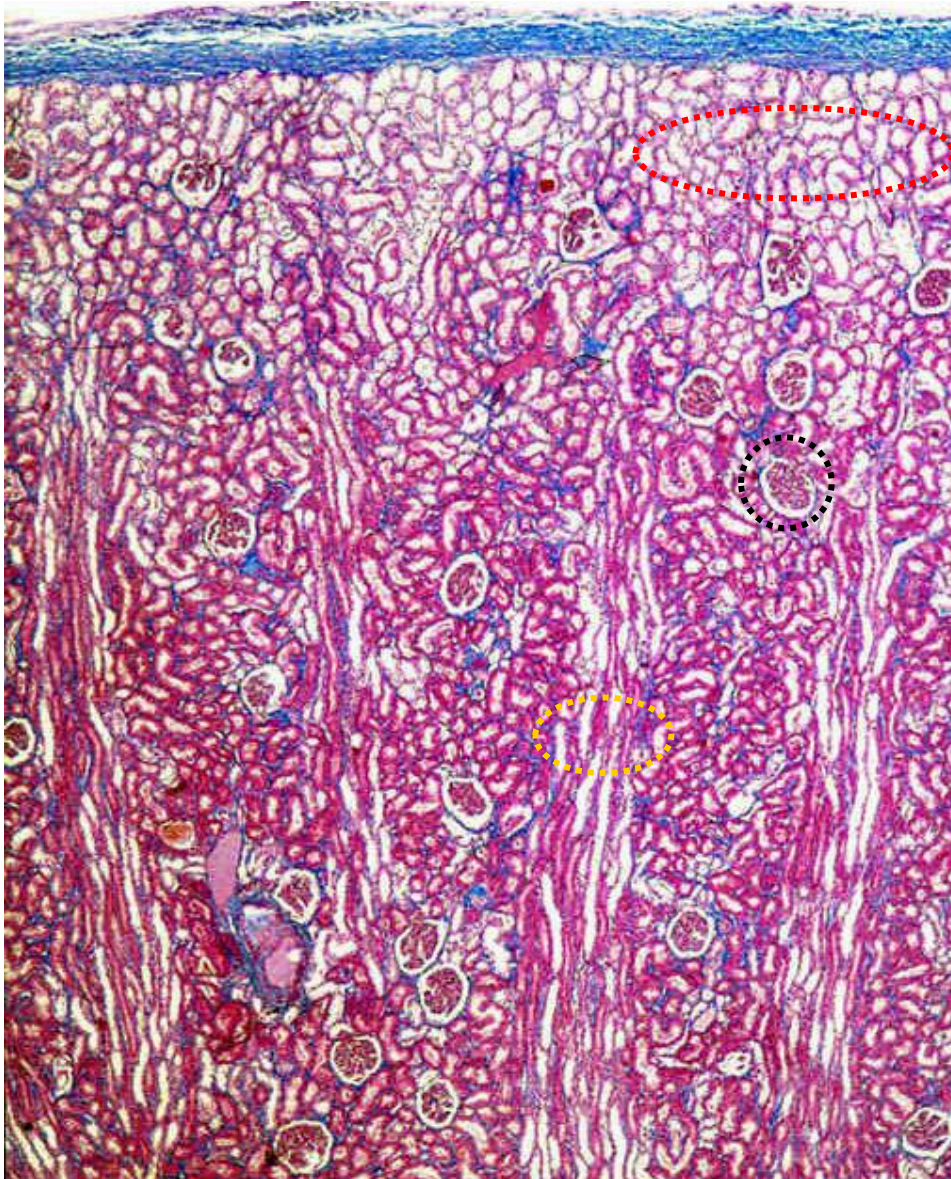
DB-ducts of Bellini



Kidney medulla



Kidney cortex

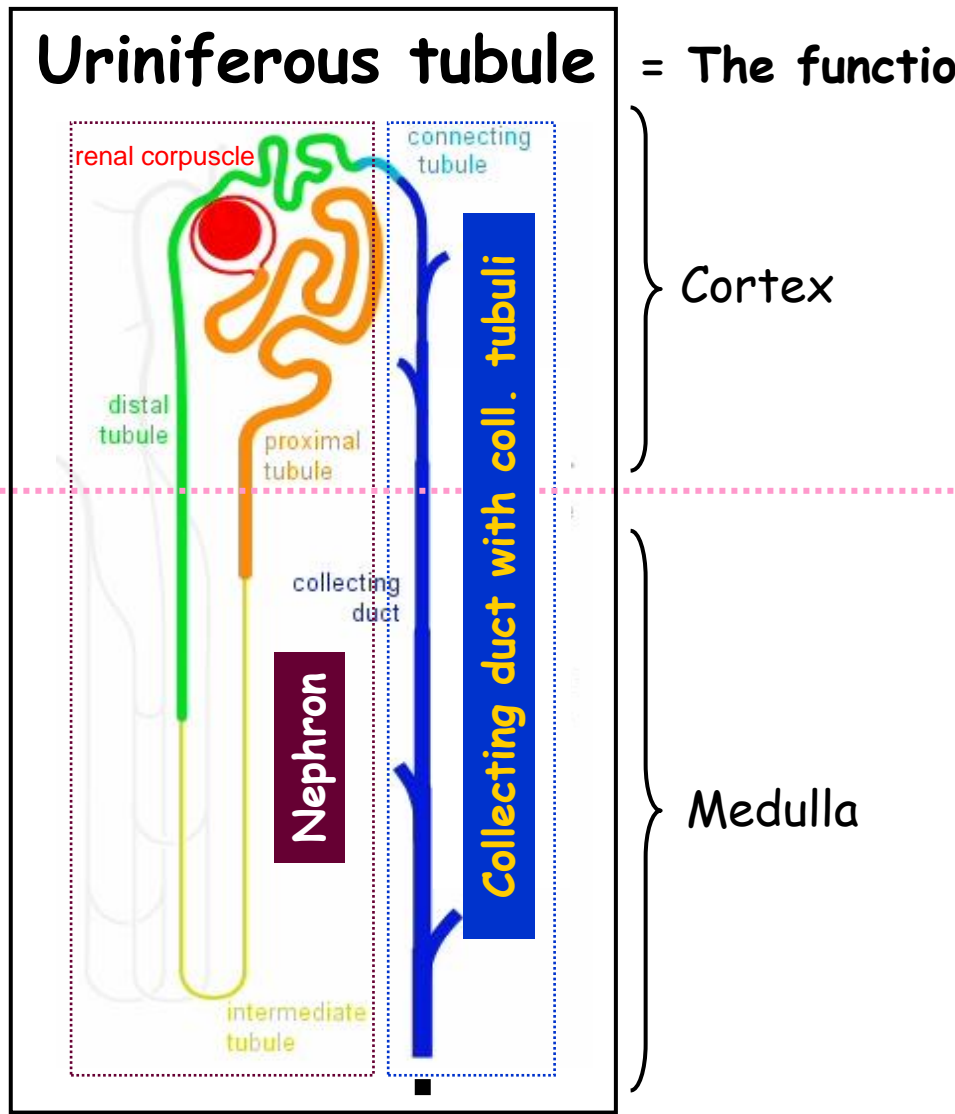


Cortical labyrinth
(convoluted tubules)

Renal corpuscles

Cortical rays
(continuation of collecting
ducts from renal pyramids)

Urineriferous tubule = The functional unit of the kidney



Cortex

Medulla

Ducts of Bellini

1 to 1.4 millions
of nephrons
in one kidney

Area cribrosa
Minor calyx

Nephrons X Collecting ducts
Different embryological origin

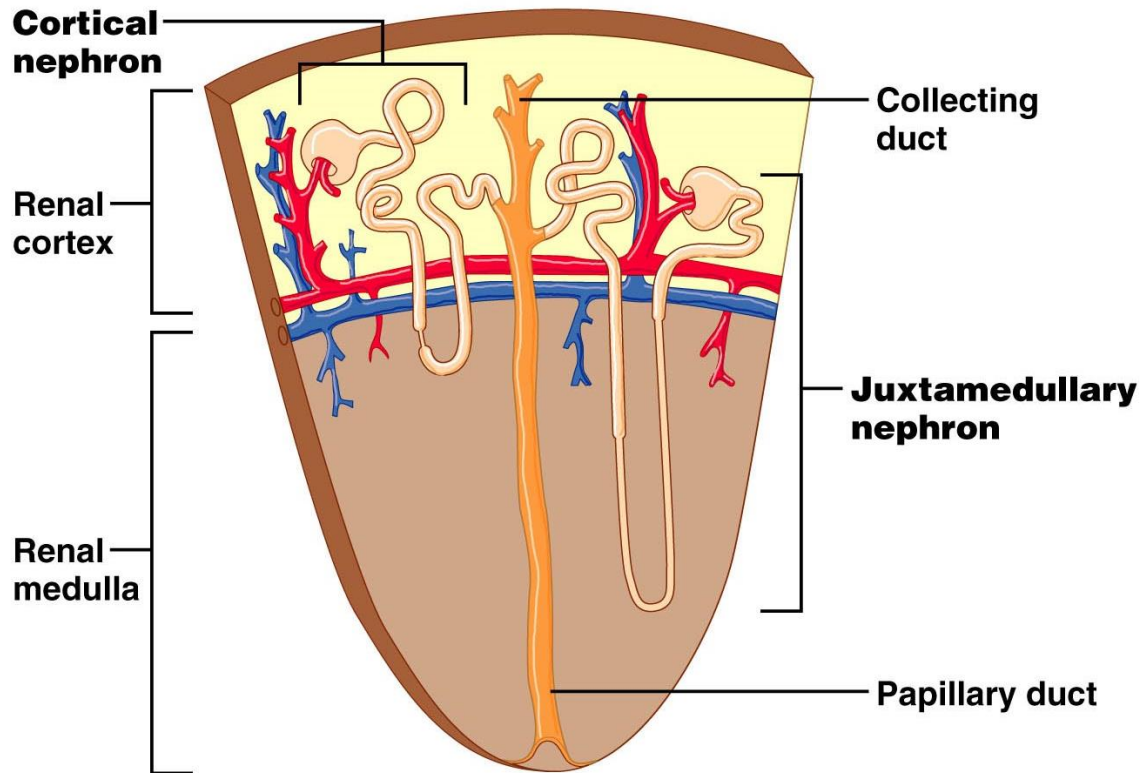
Nephron

Cortical nephrons

85% of nephrons

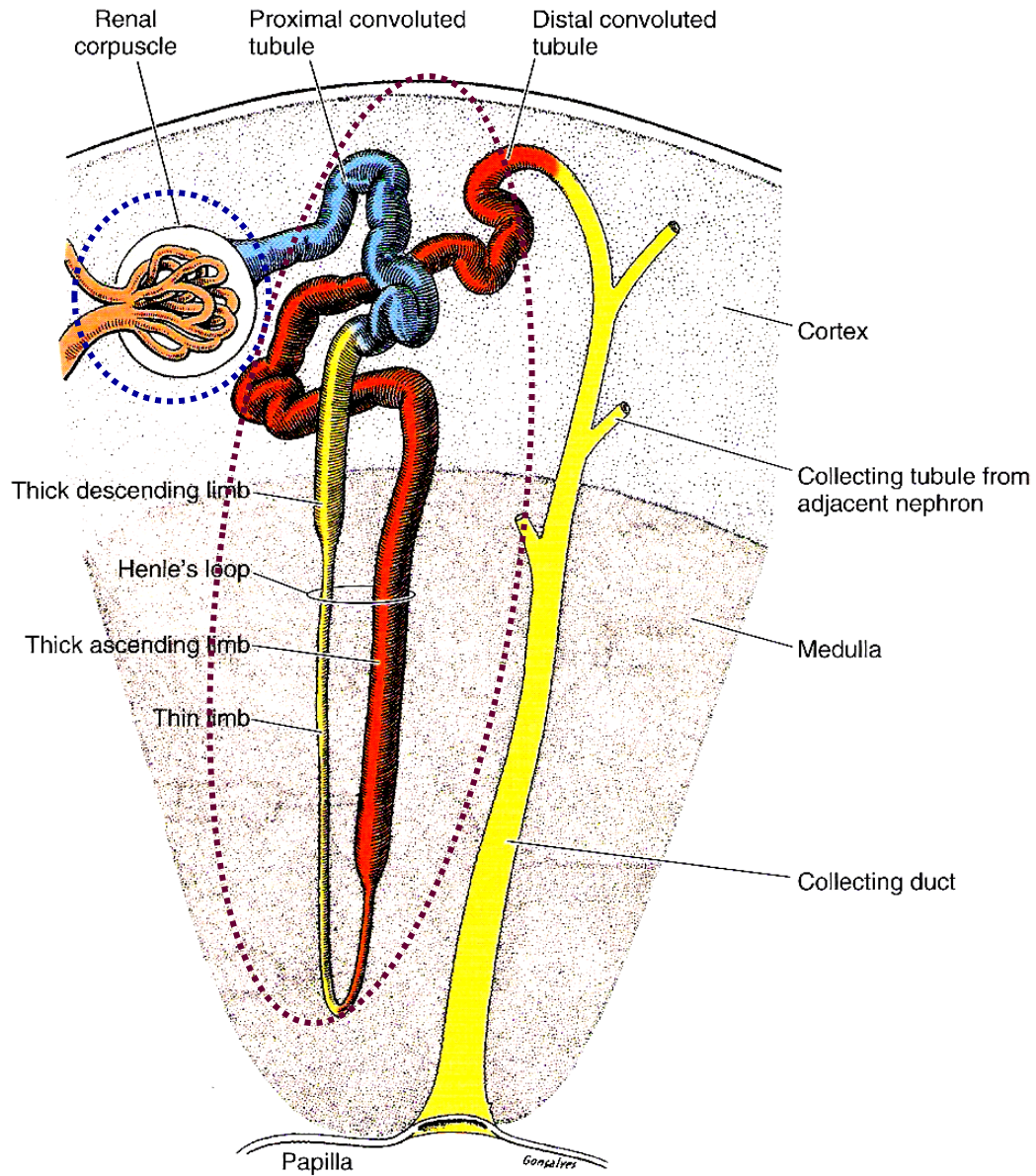
Juxtamedullary nephrons

15% of nephrons



About 40 mm long

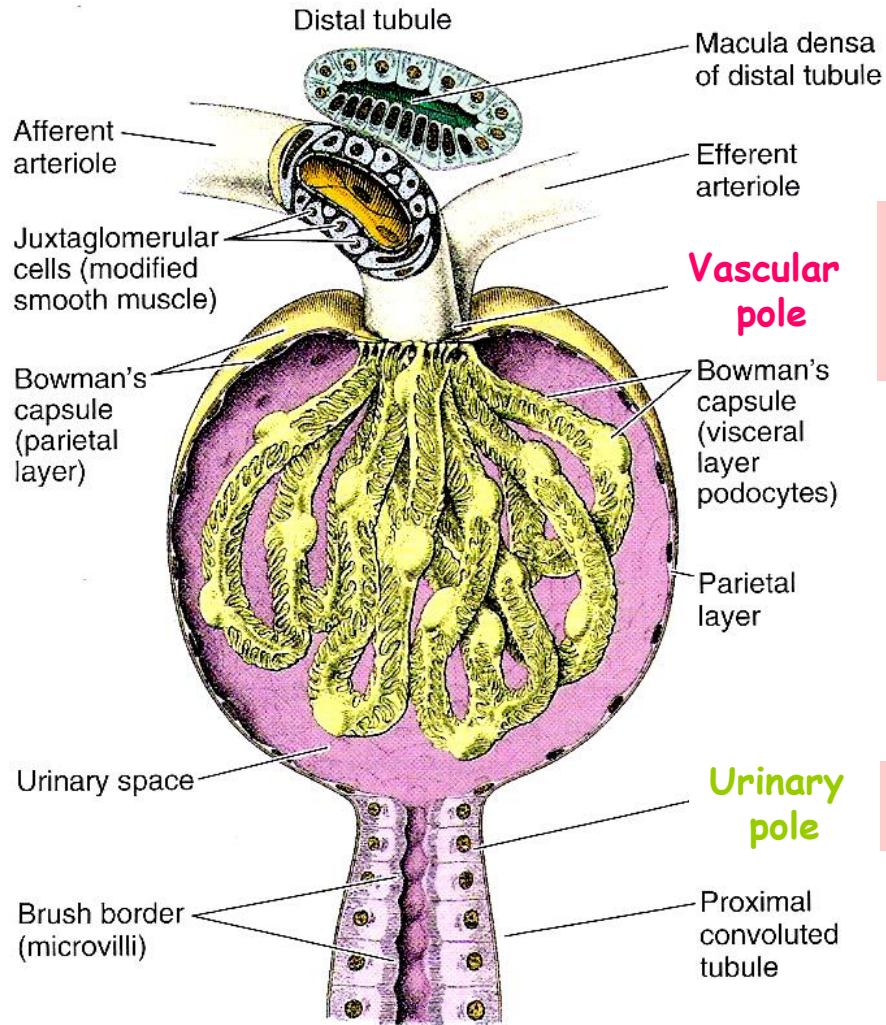
Nephron



Nephron - Renal corpuscle 1

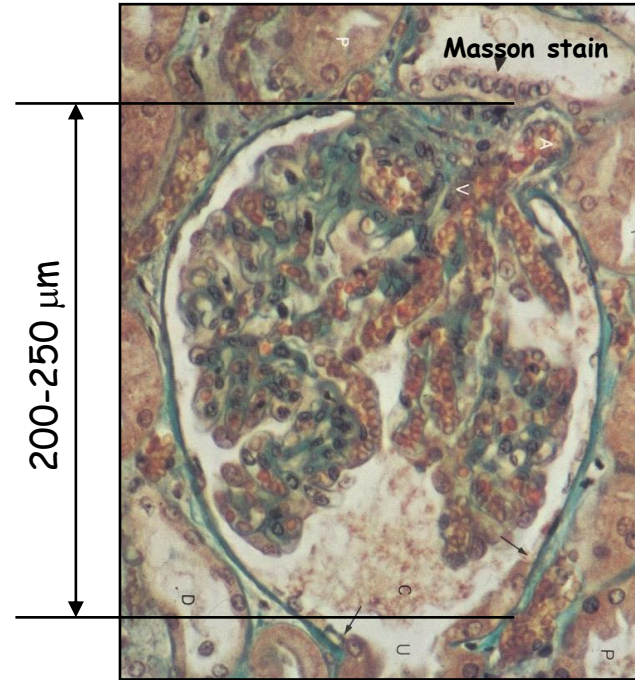
Glomerulus - tuft of capillaries

Bowman`s capsule - invaginated dilatation of proximal tubule

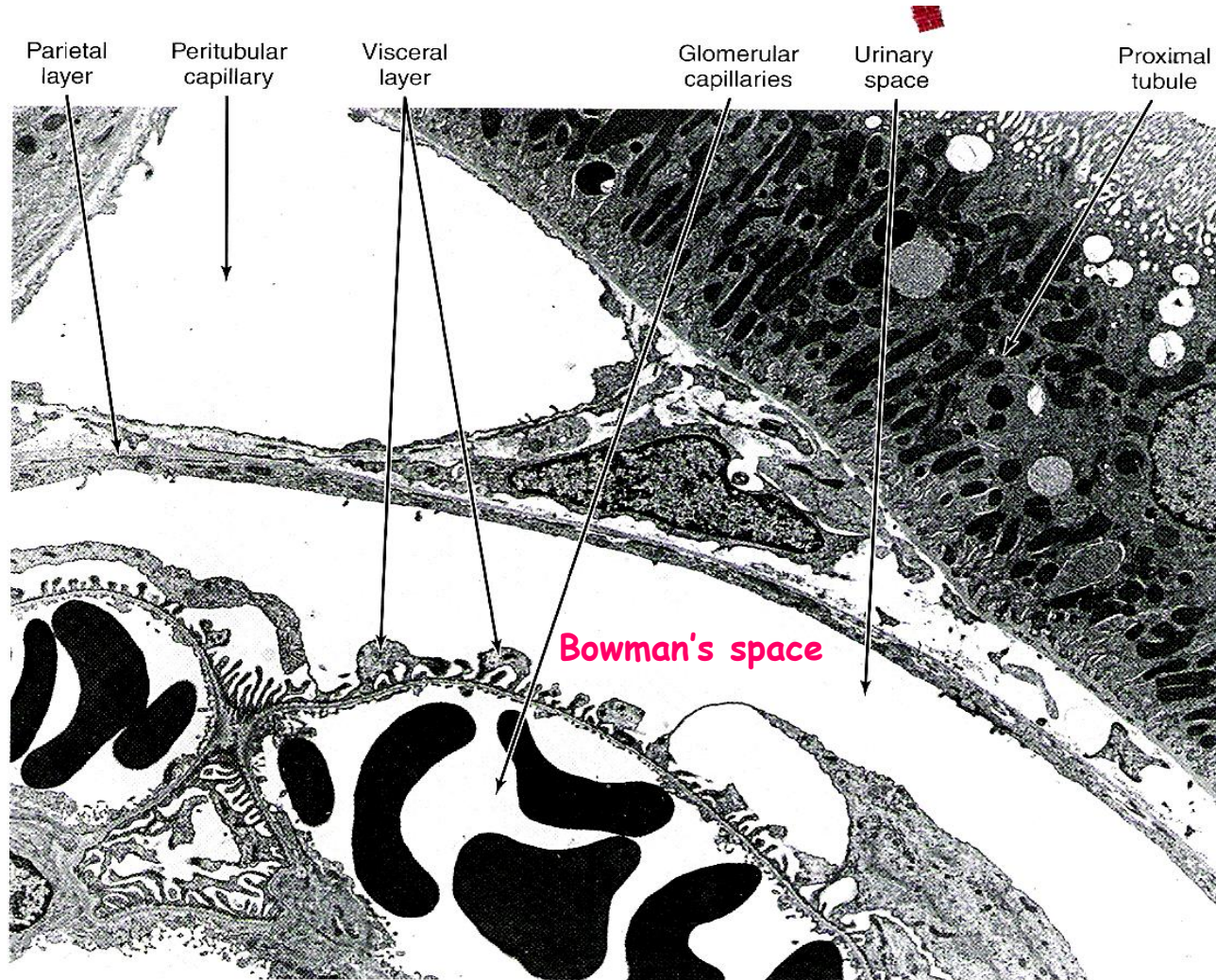


side of the corpuscle where the afferent arterioles and efferent arterioles enter and exit, respectively

side of the corpuscle where the PCT exits.

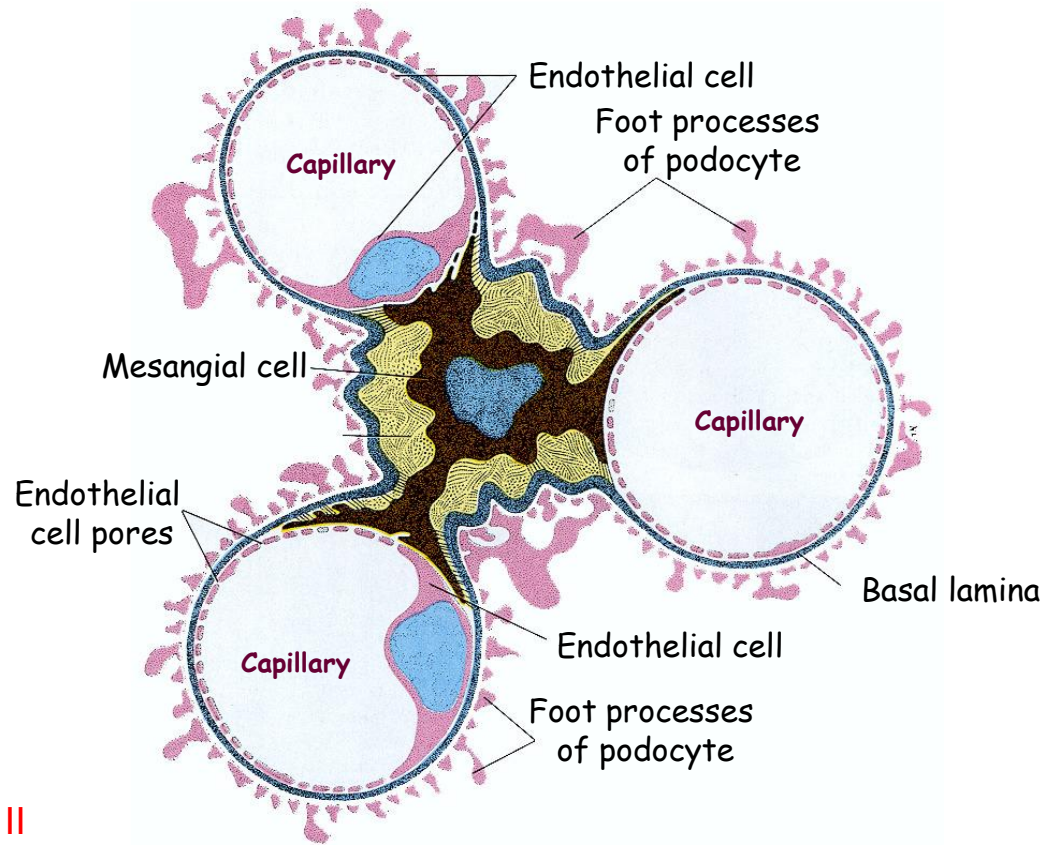
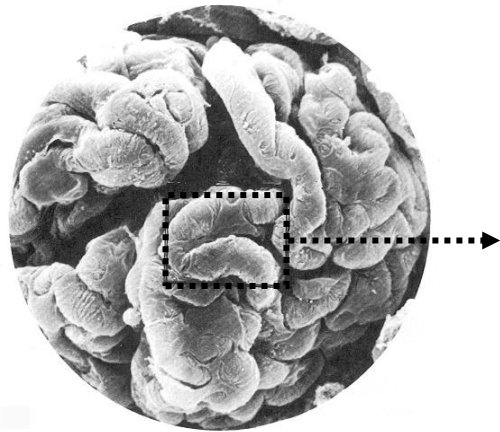
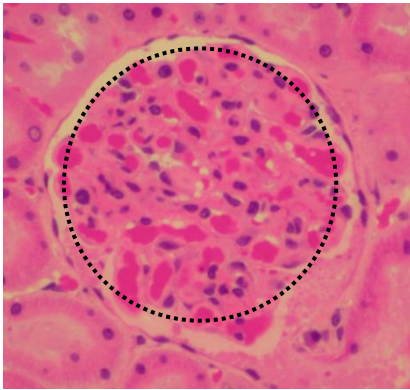


Nephron - Renal corpuscle 2



Nephron - Glomerulus 1

Endothelial cell + Basal lamina + Podocytes + Mesangial cells

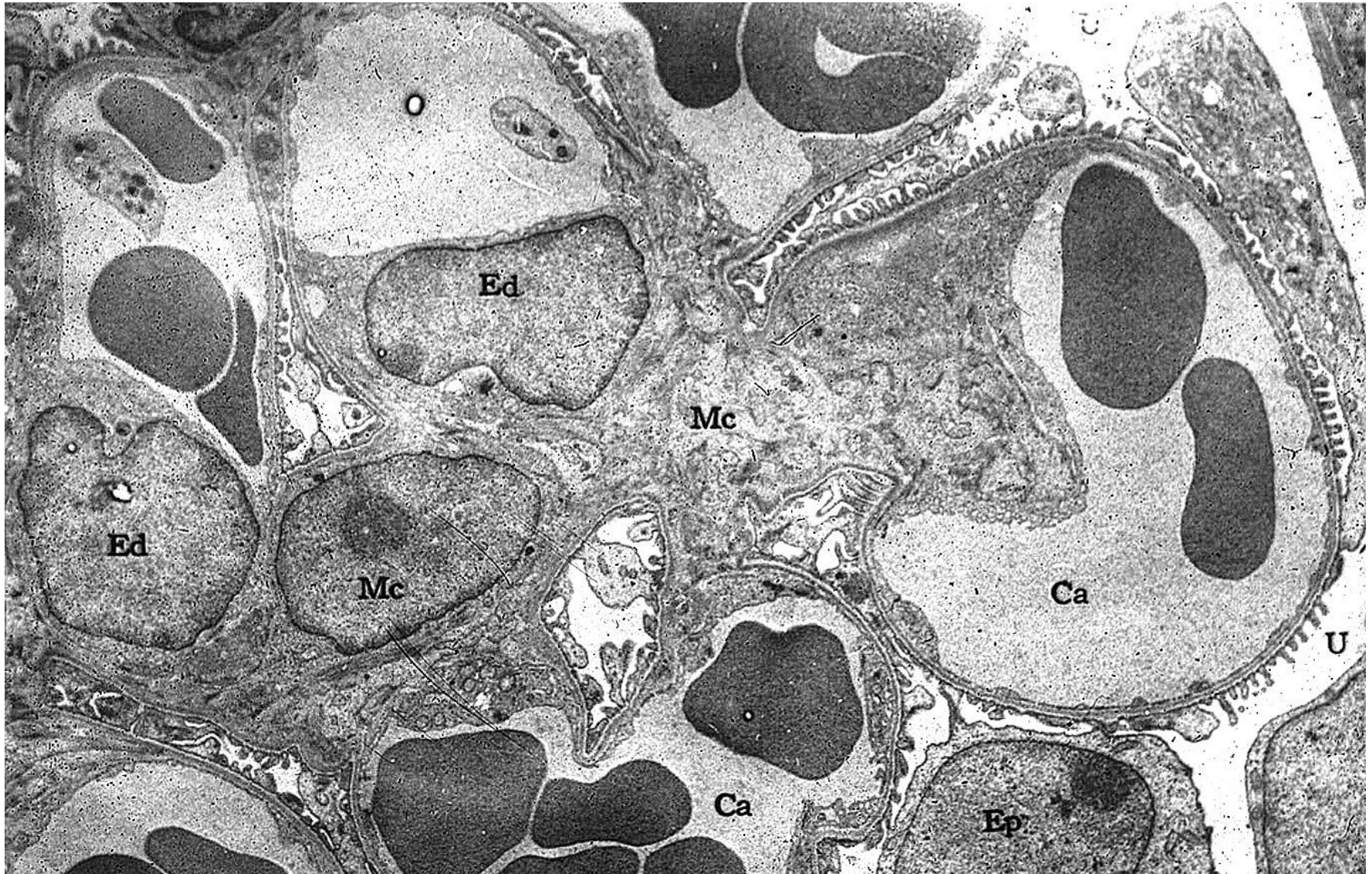


Mesangial cells

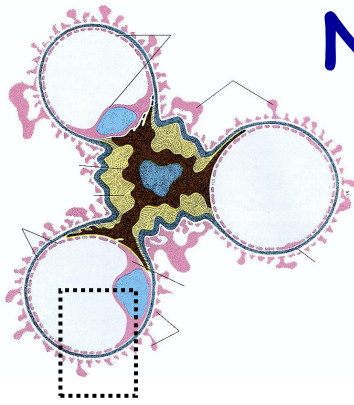
- **Contractile** - receptors for angiotensin II
- Give structural support to the glomerulus, synthesize ECM
- Endocytose and dispose of normal and pathologic molecules trapped by the glomerular basement membrane
- Produce chemical mediators such as cytokines and prostaglandins

Lamina Rara - contain fibronectin (bind them to cells) - **physical barrier**
Lamina Densa - meshwork of Type IV collagen and laminin in a matrix contg (-) charged heparan sulfate that restricts passage of cationic molecules - **charge barrier**

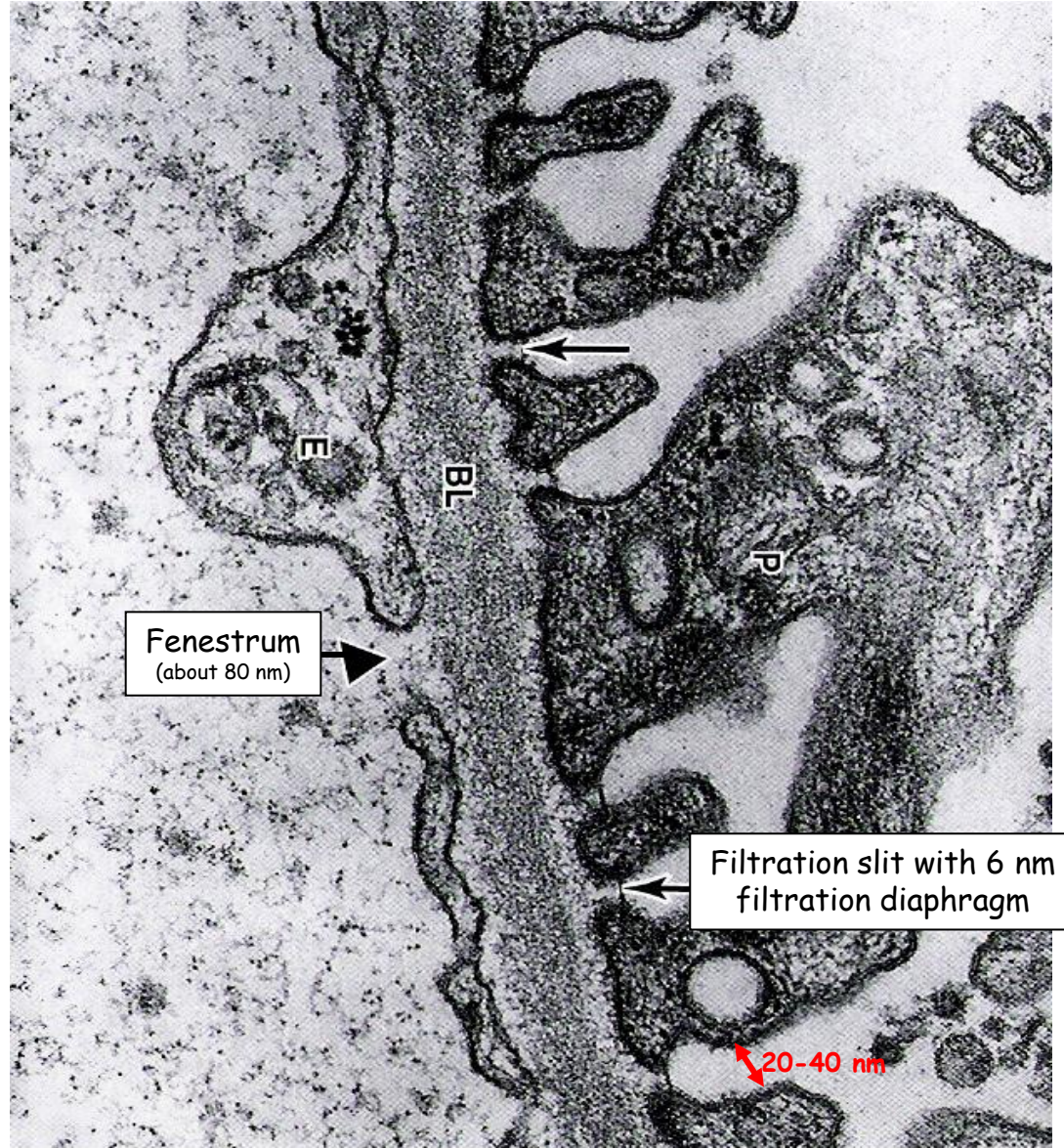
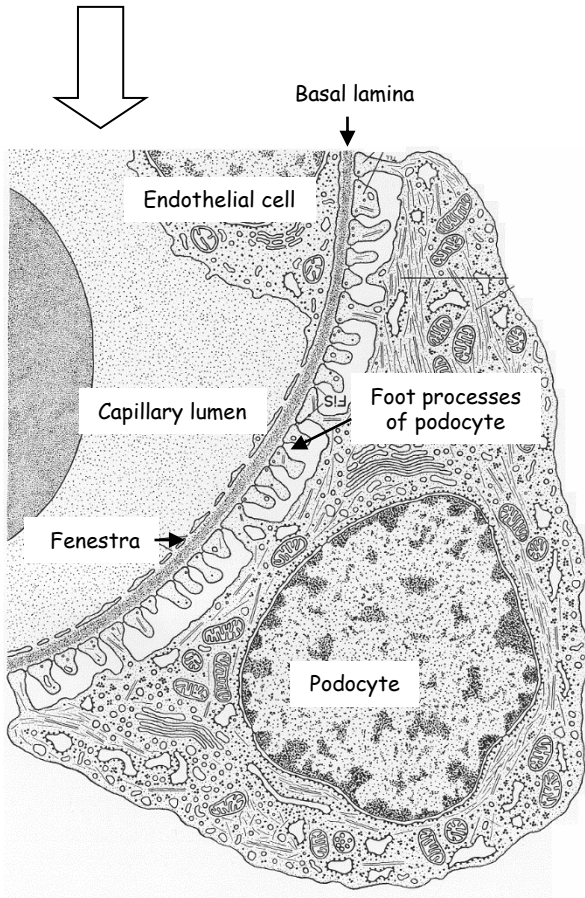
Nephron - Glomerulus 2



Nephron - Glomerulus 3




Lamina rara externa
Lamina densa
Lamina rara interna

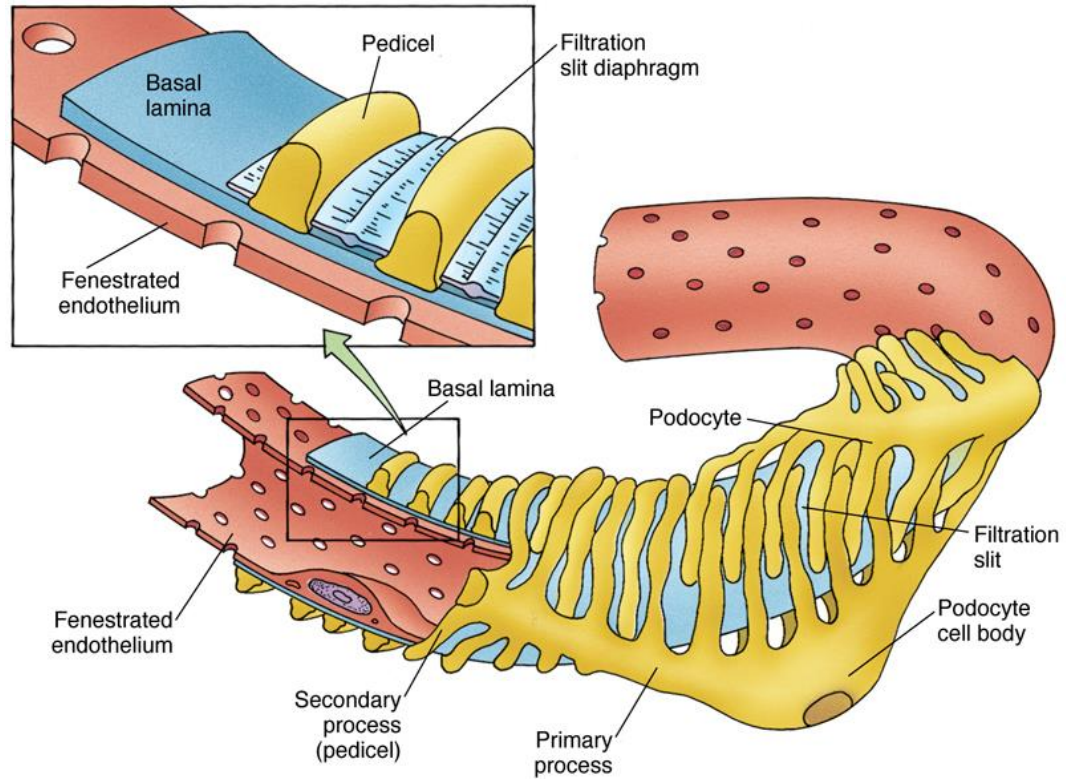
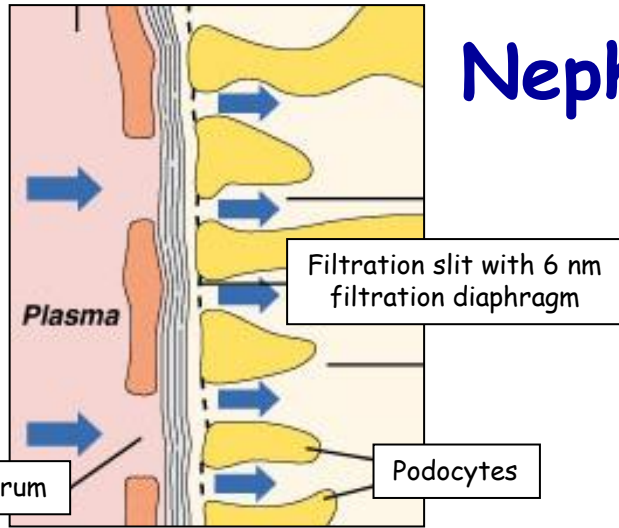


Fenestra: 70 - 90 nm

Nephron - Glomerulus - Podocyte 1

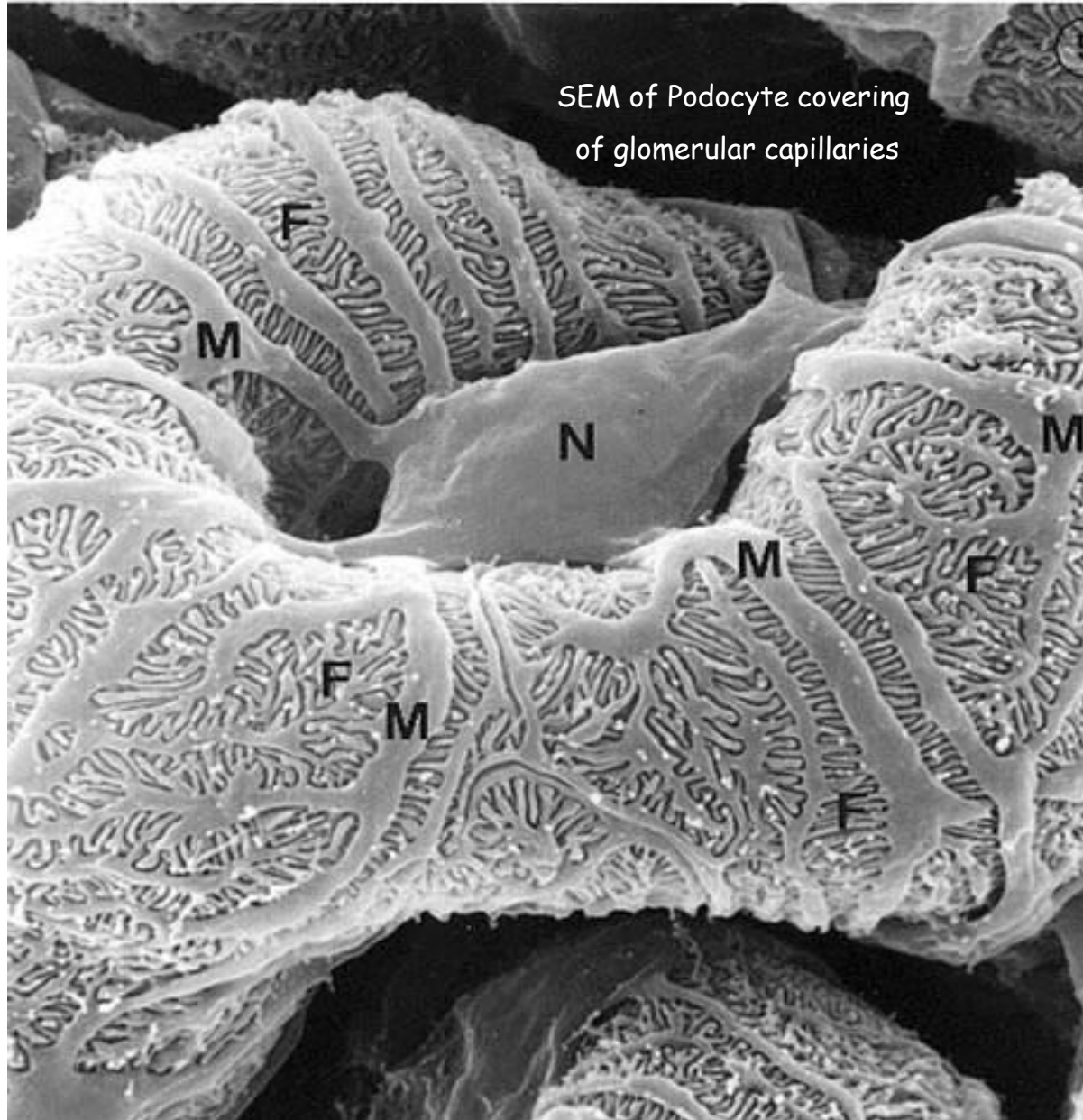


Nephron - Glomerulus - Podocyte 2



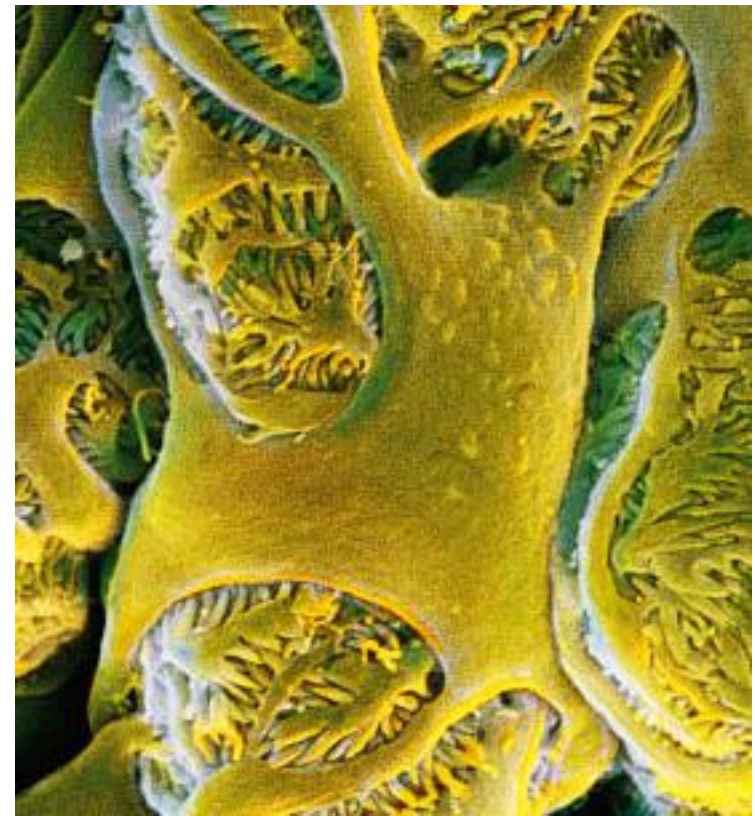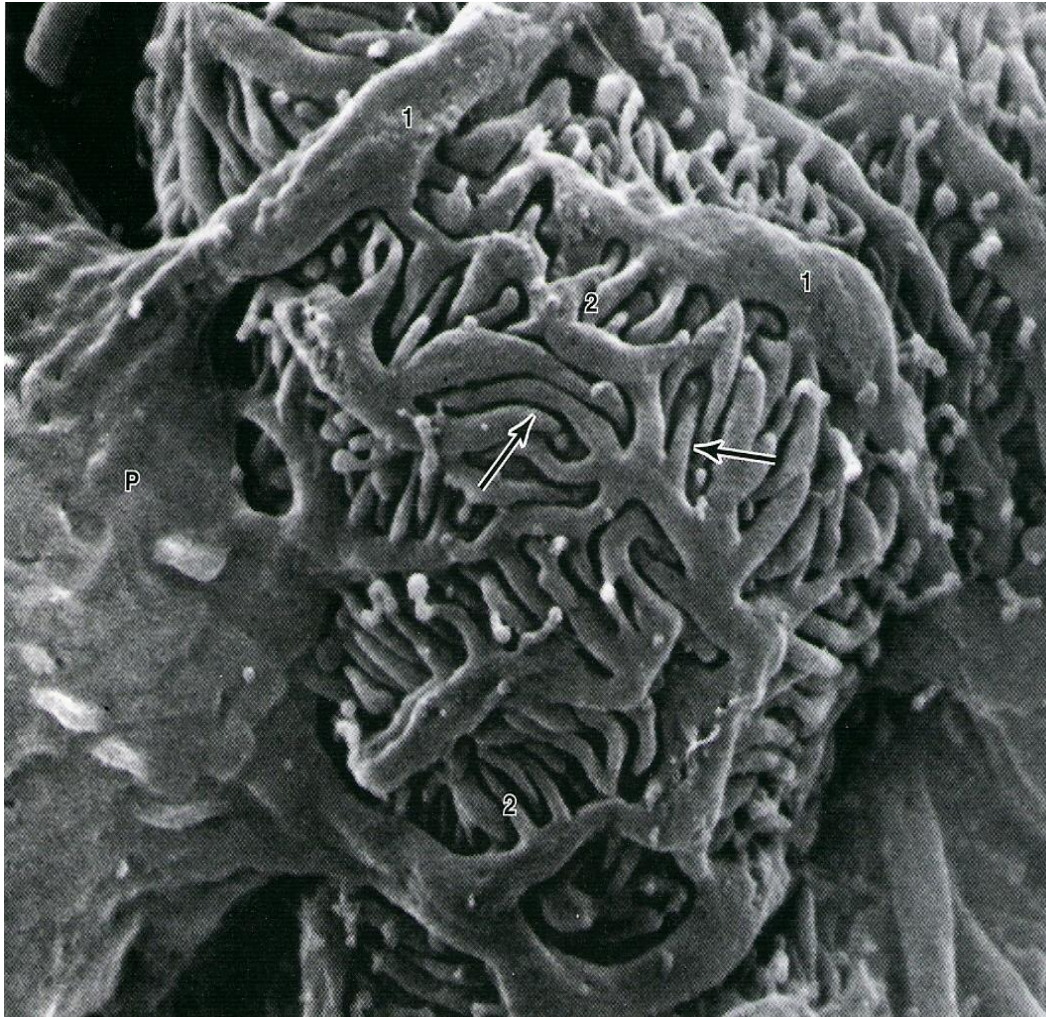Primary processes
X
Secondary processes

Nephron - Glomerulus - Podocyte 3

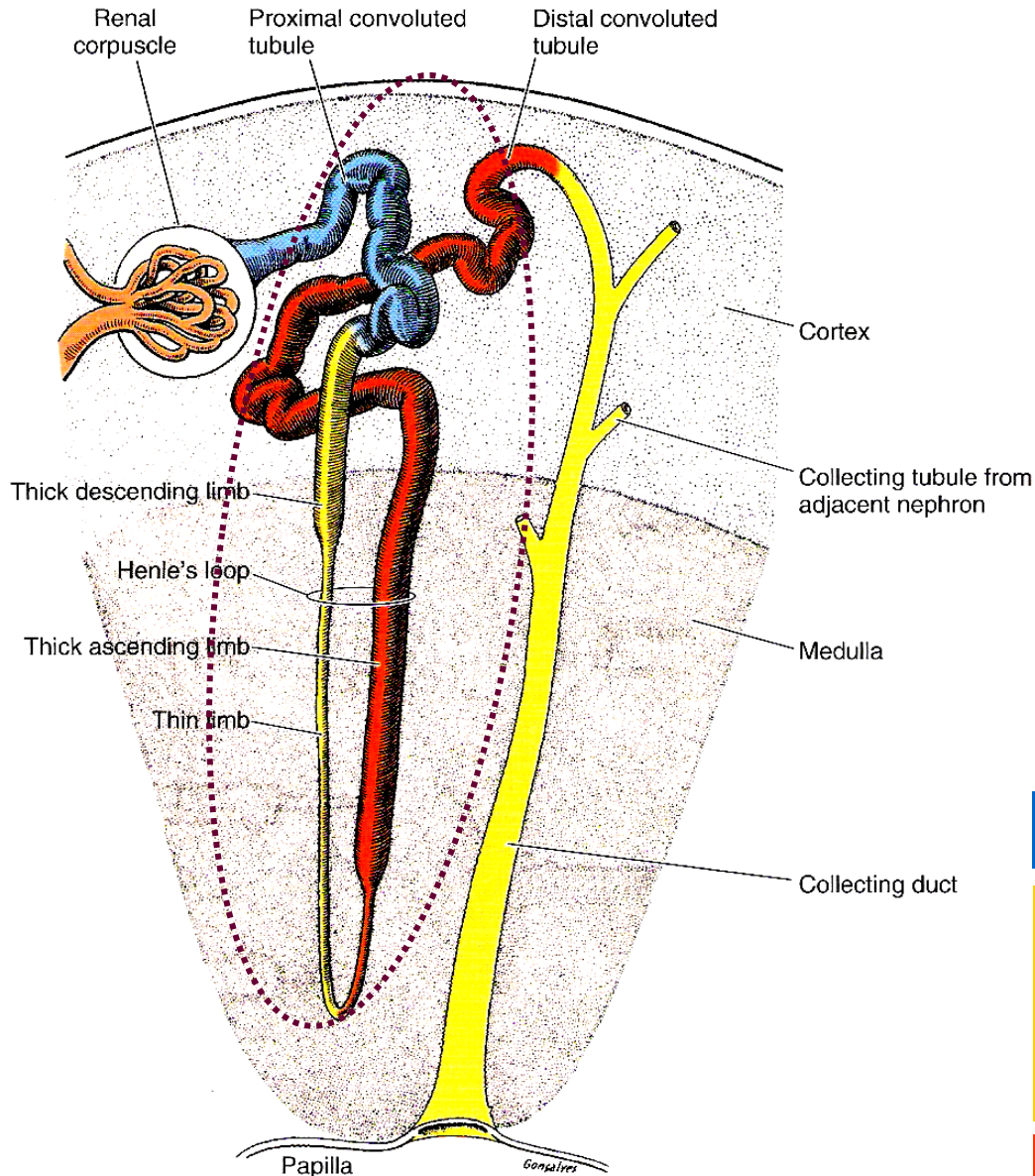


Nephron - Glomerulus - Podocyte

„Octopus-like cell“



Nephron - Tubular section 1



Proximal convoluted tubulus

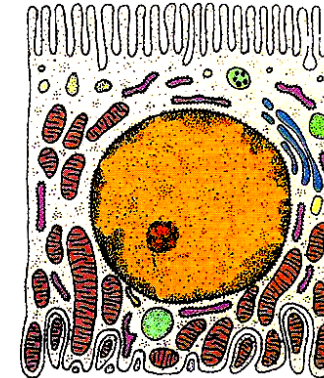
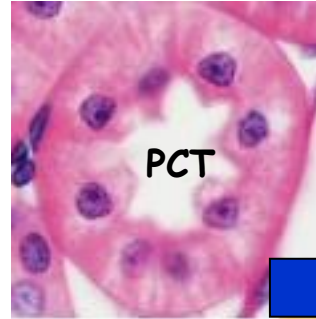
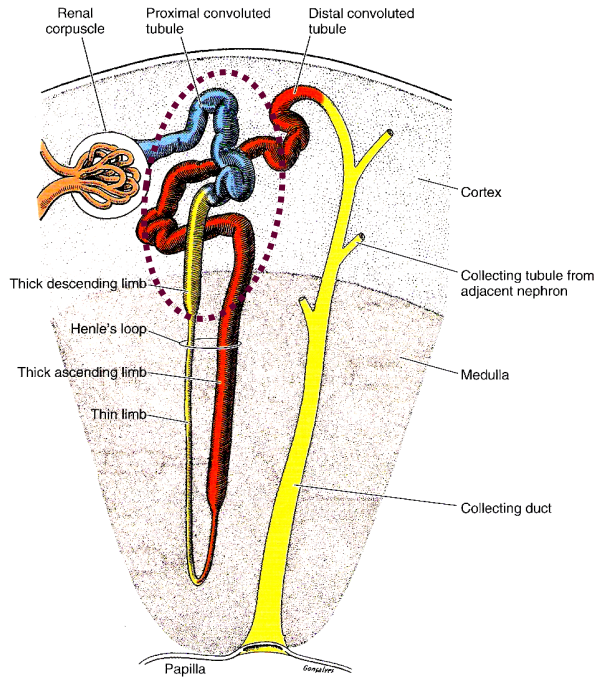
Henle's loop

- Thick descending limb
- Thin limb
- Thick ascending limb

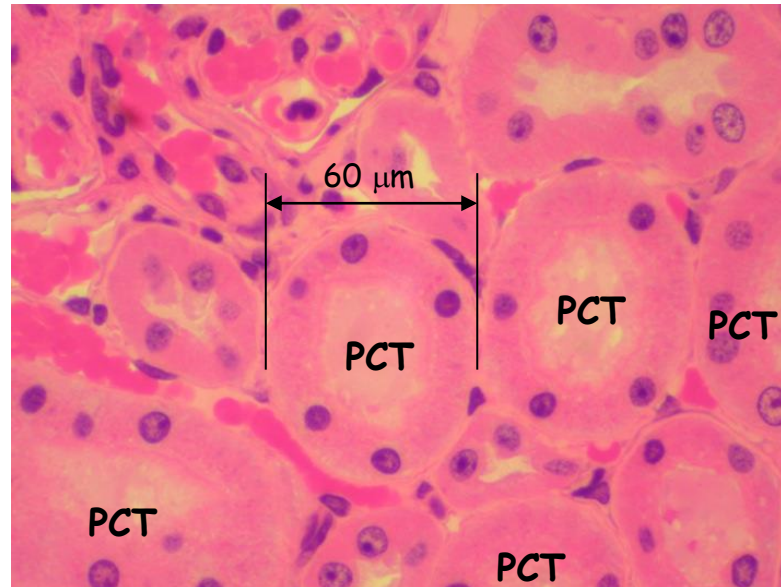
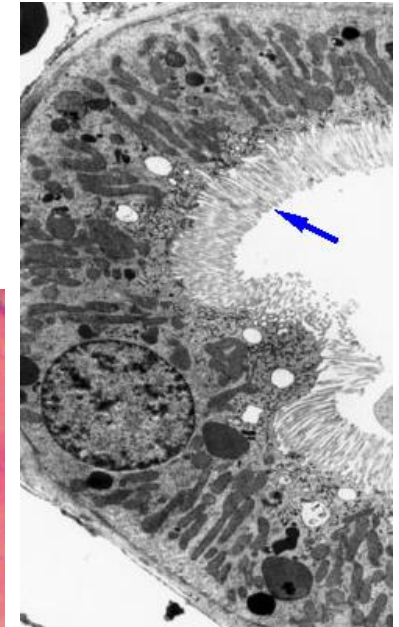
Distal convoluted tubulus

Nephron - Tubular section 2

Proximal convoluted tubulus + Thick descending limb of HL
= 14 mm in length



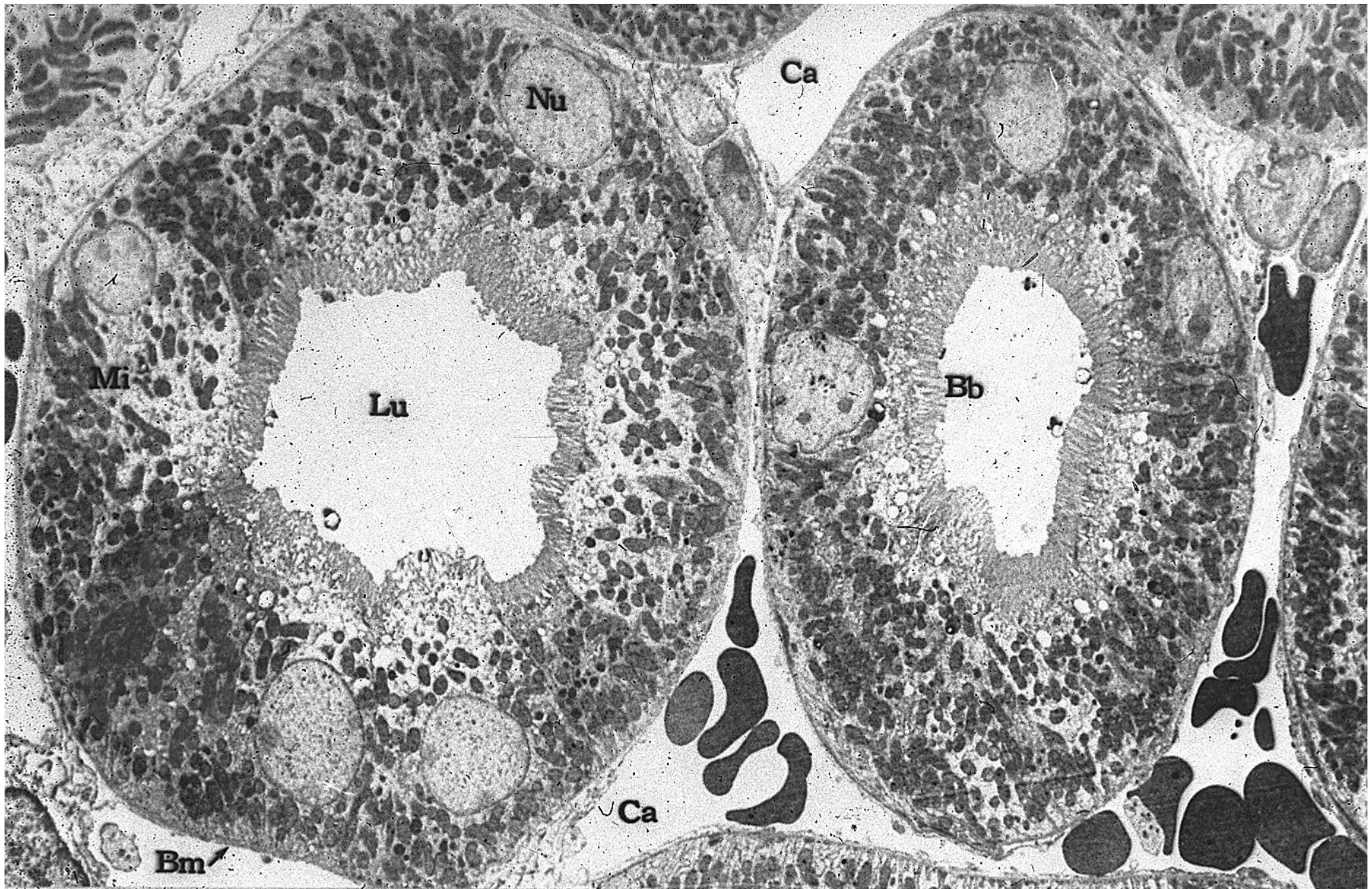
Microvili = Brush border



Reabsorption

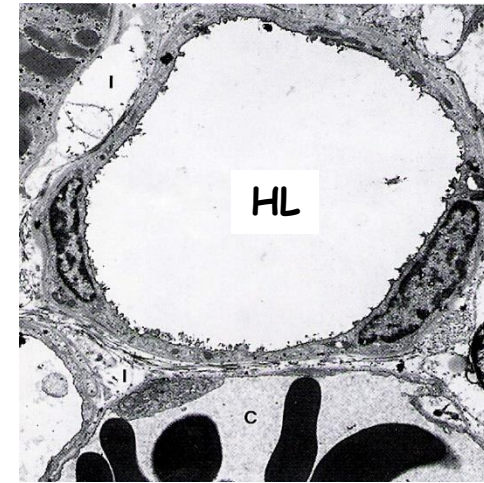
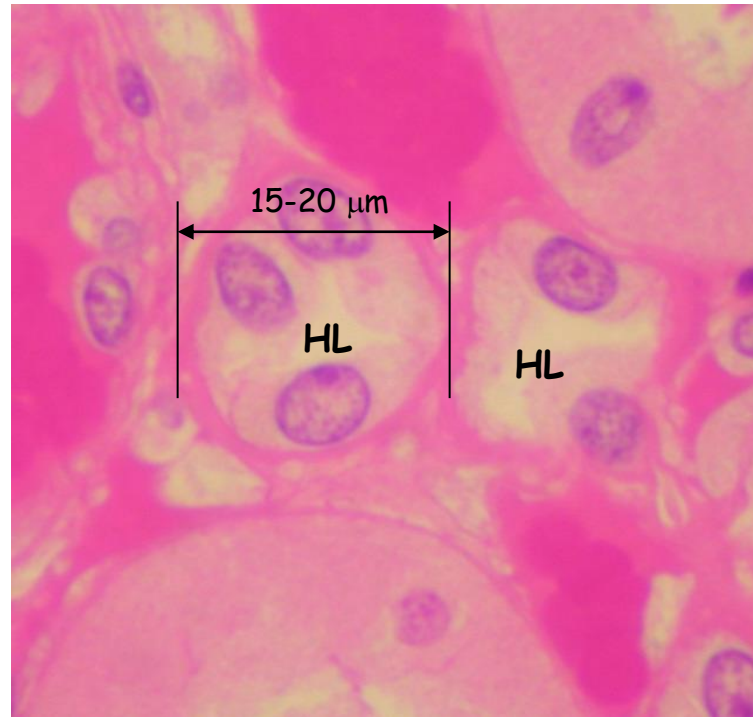
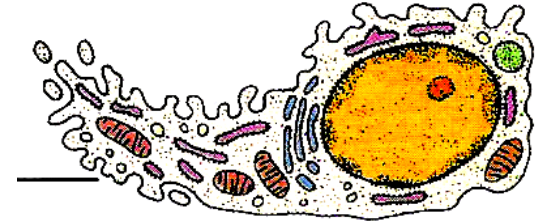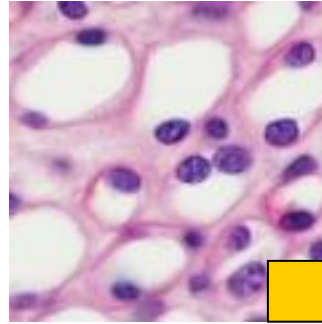
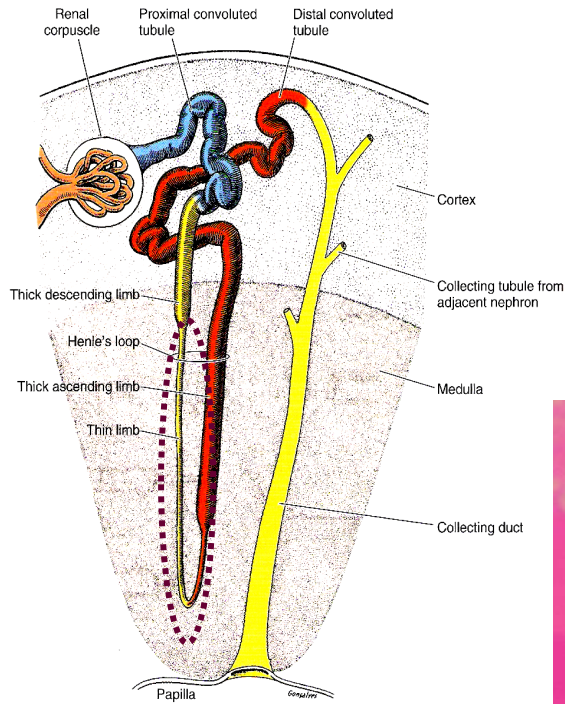
$\frac{3}{4}$ of sodium, Cl, K, H₂O,
amino acids, proteins

Proximal convoluted tubuli



Nephron - Tubular section 3

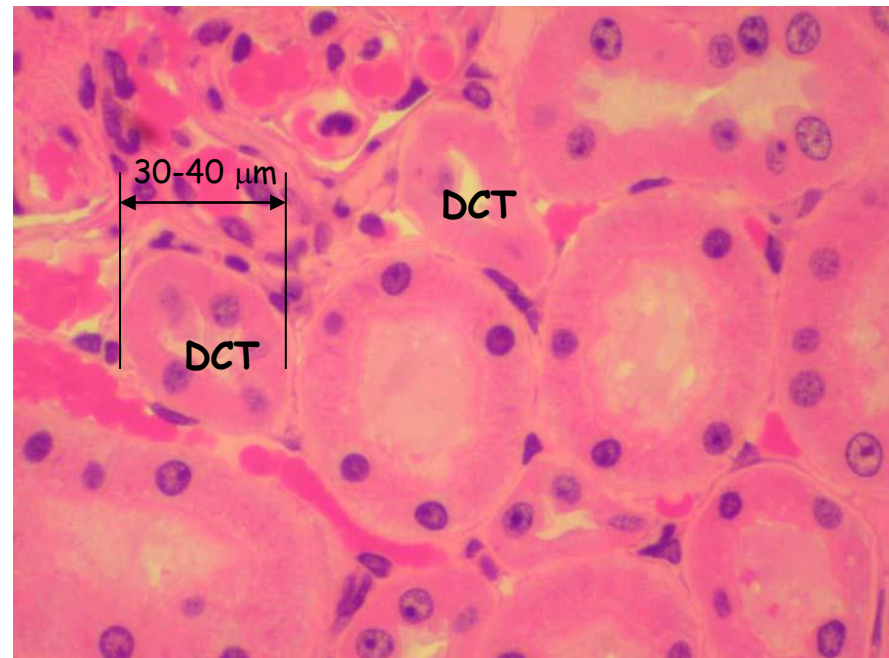
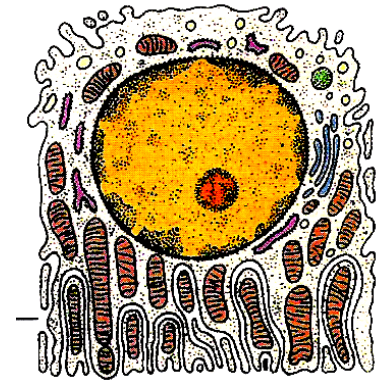
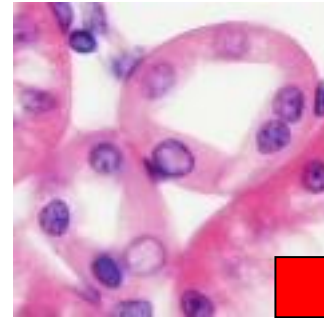
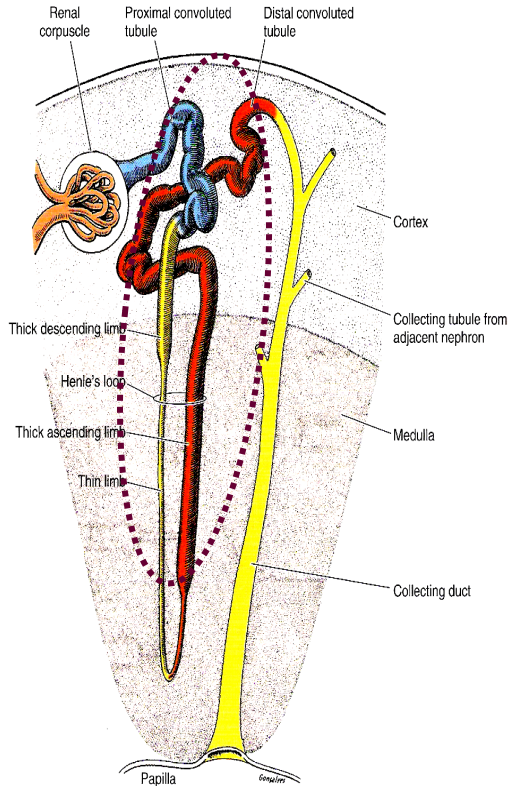
Thin descending limb of HL + Thin ascending limb of HL
= 9-10 mm in length



Reabsorption
 H_2O

Nephron - Tubular section 4

Thick ascending limb of HL + Distal convoluted tubulus
9-10 mm in length + 4-5 mm in length

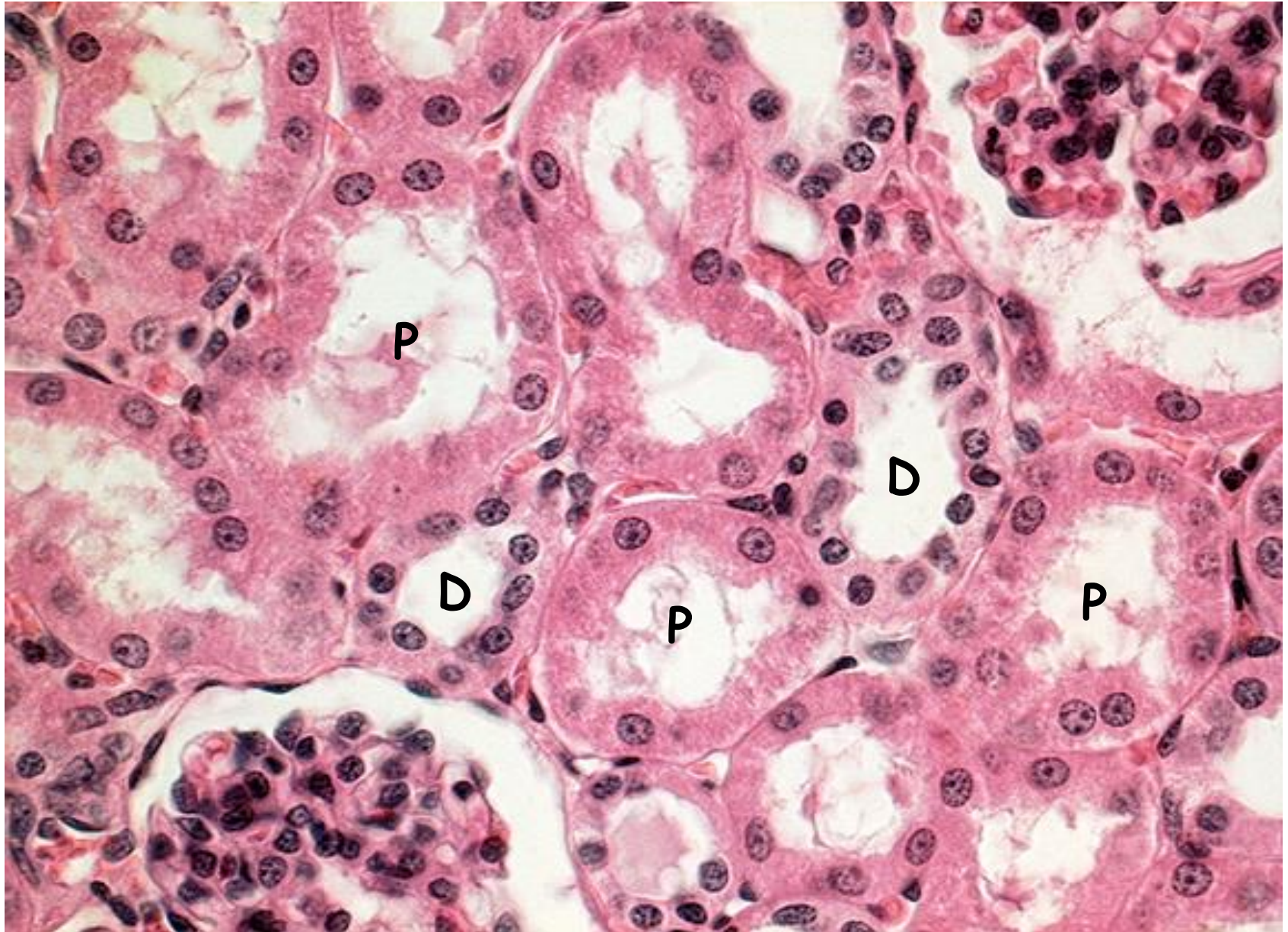


Reabsorption

Na, K, Cl

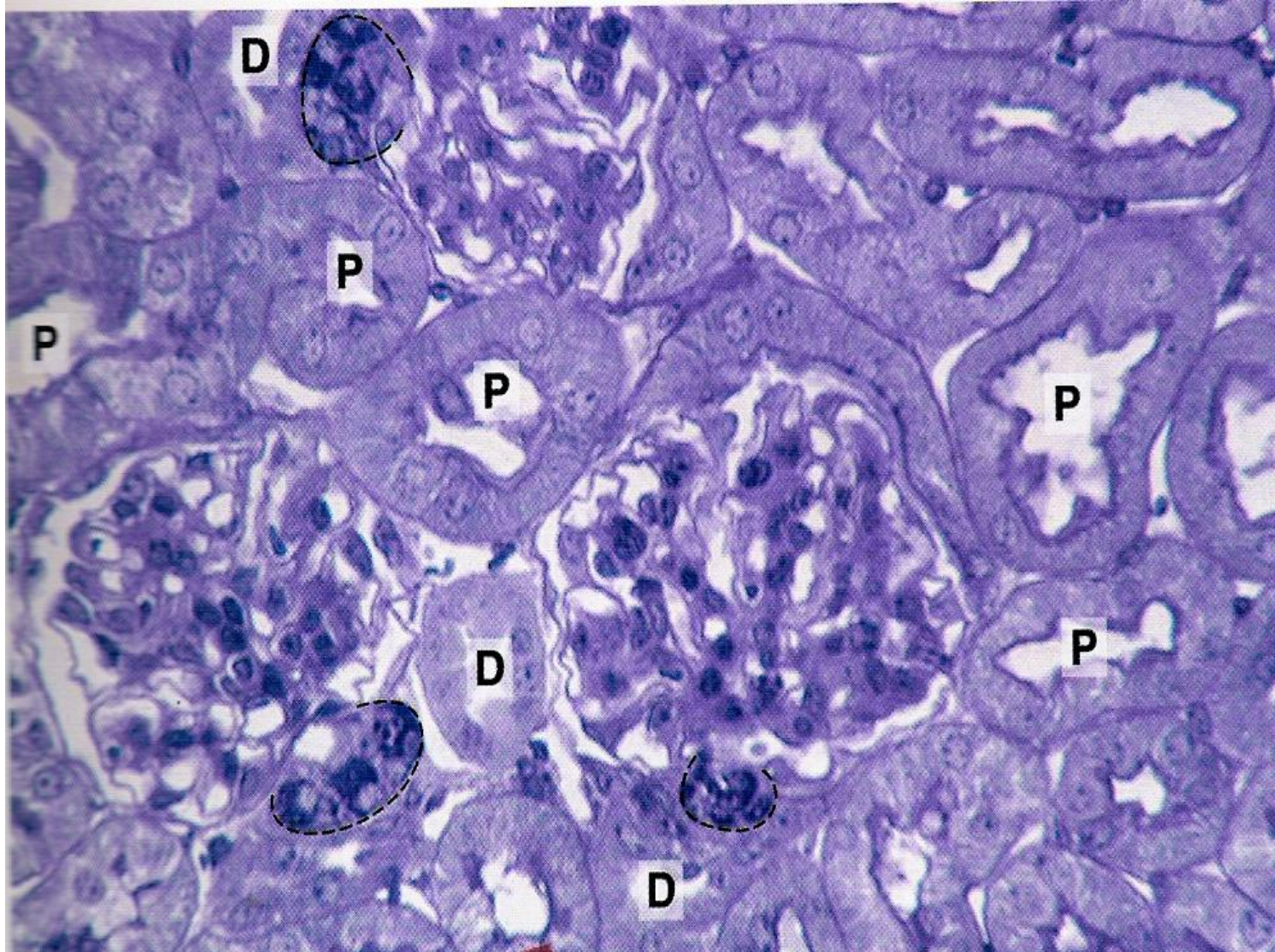
Impermeable for water

Proximal and distal convoluted tubuli

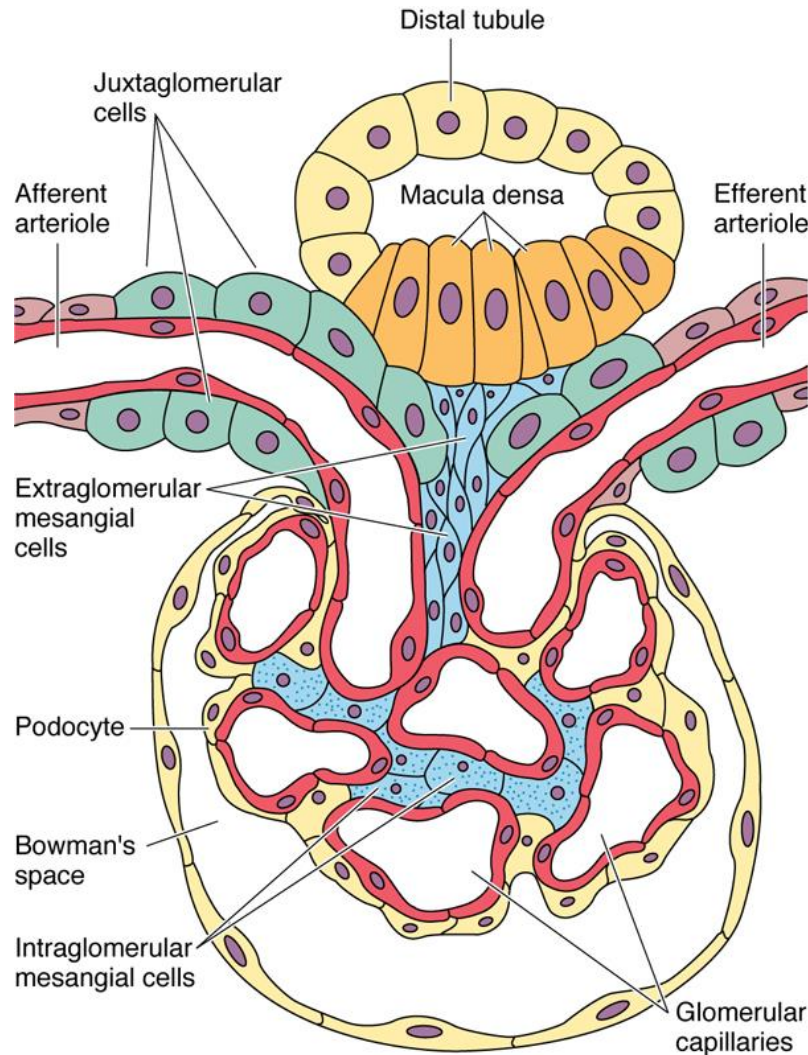


Cortex

Proximal X Distal convoluted tubuli (7:1)



Nephron - Tubular section - Juxtaglomerular apparatus 1



Macula densa

Monitors osmotic concentration in the fluid in the nephron and secretes local hormones that alter JG cell secretion.

Juxtaglomerular cells

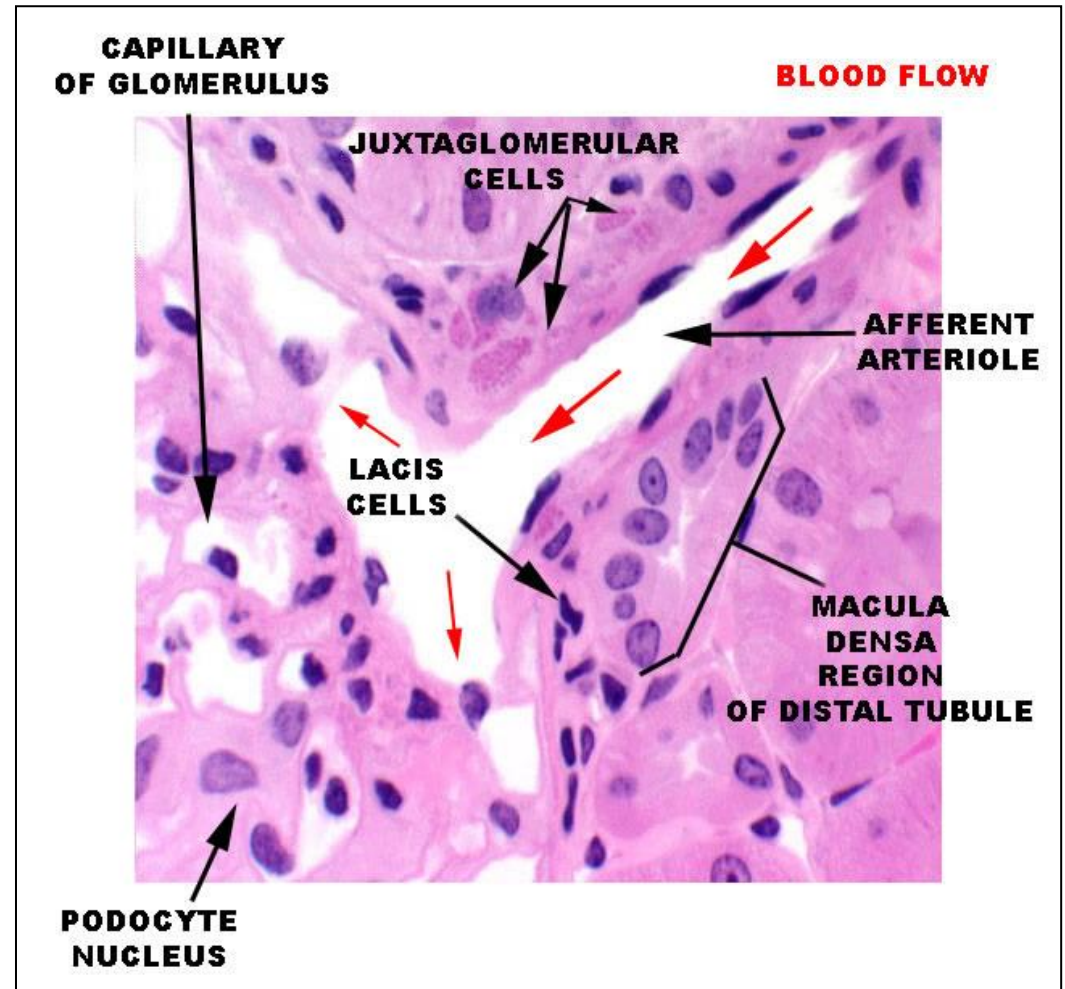
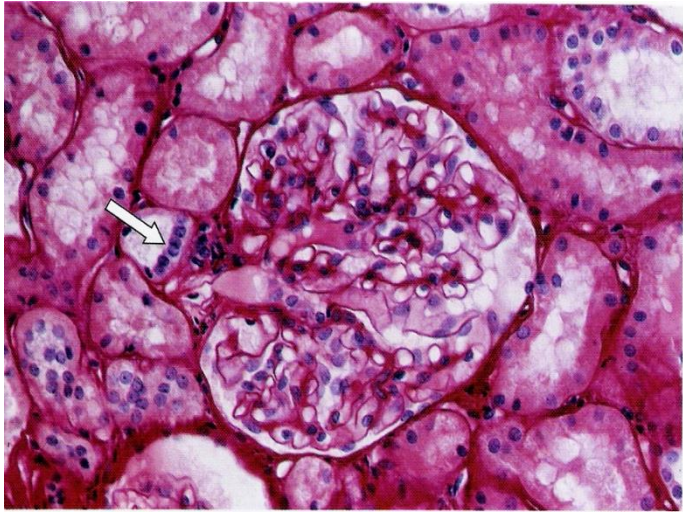
Monitor blood pressure in the afferent arteriole and secrete renin. **Renin** converts angiotensinogen in blood plasma to angiotensin I which is converted to angiotensin II in the lungs. **Angiotensin II** causes arteriole constriction throughout the body, raising blood pressure.

Extraglomerular mesangial cells (Lacis cells)

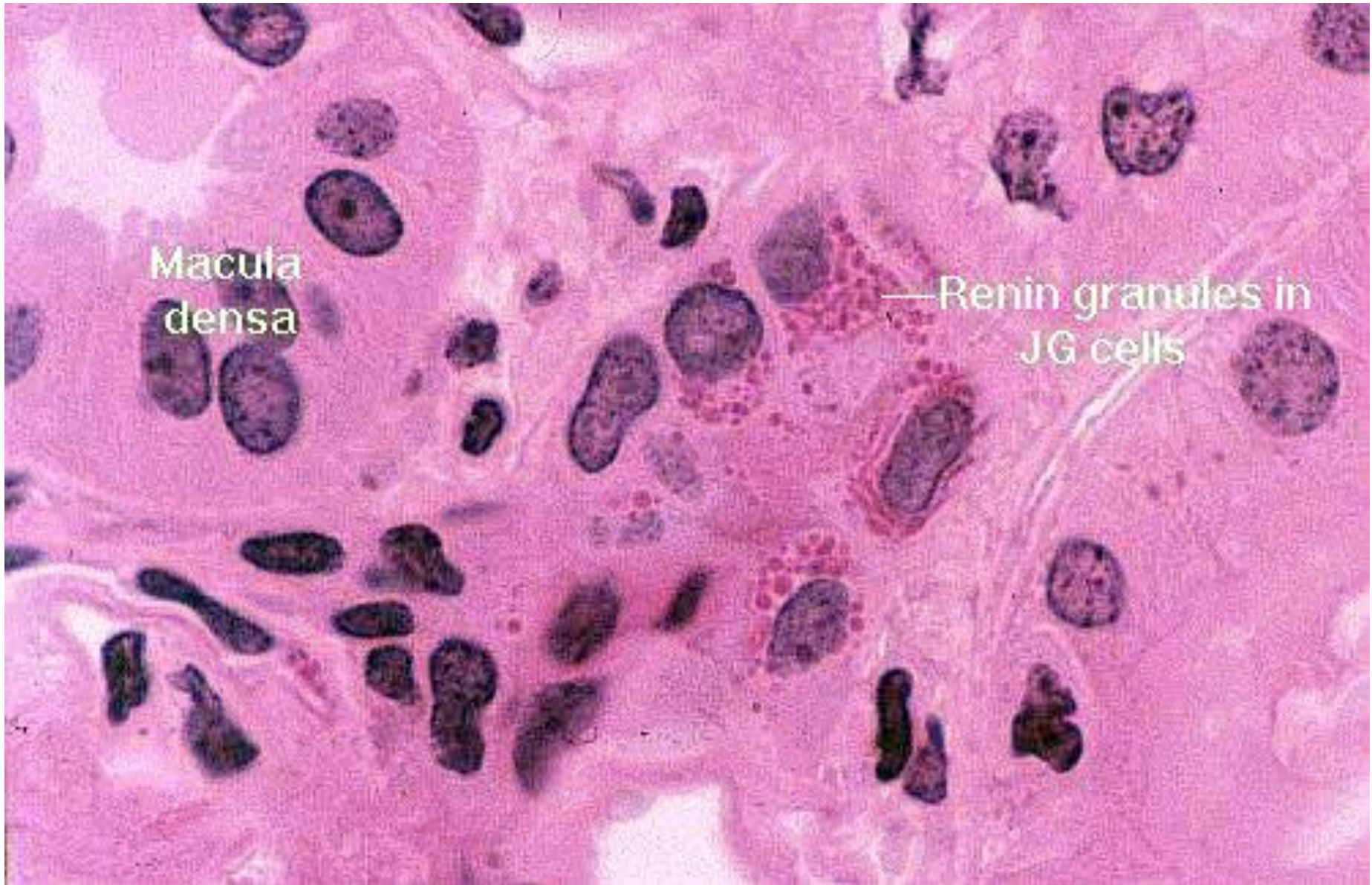
Nephron - Tubular section - Juxtaglomerular apparatus 2

Macula densa

Modified DCT in proximity of vascular pole of renal corpuscle



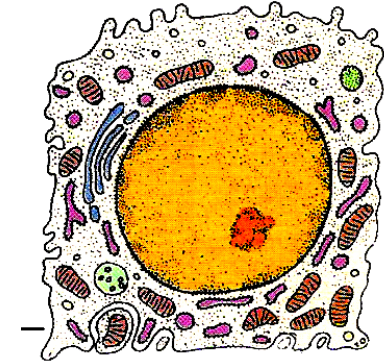
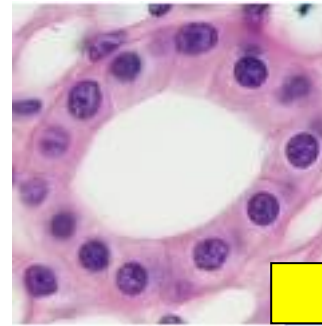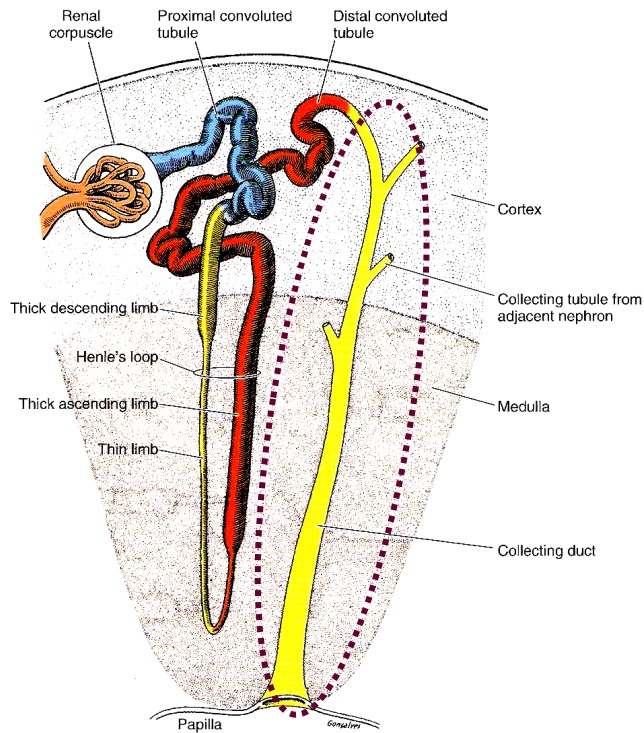
Juxtaglomerular cells



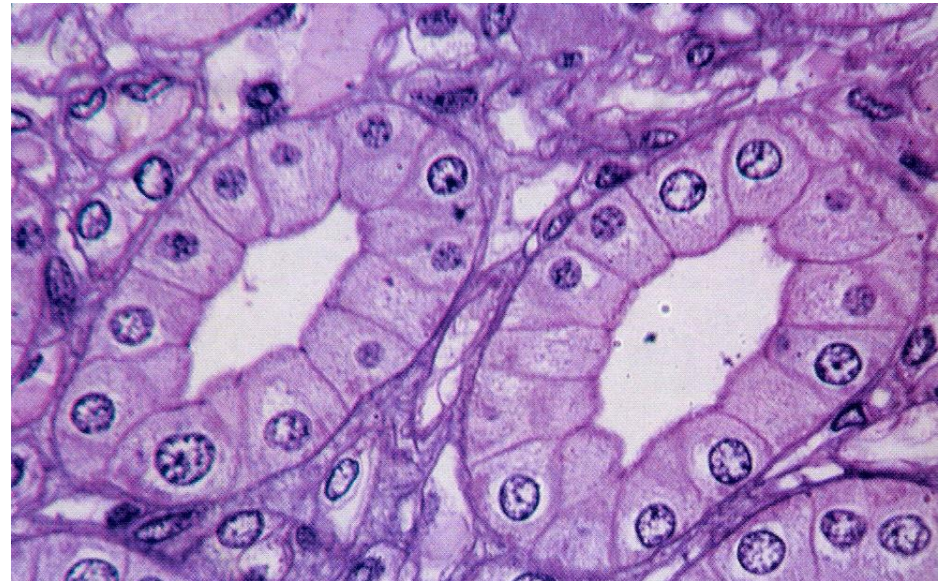
Collecting ducts

Cortical + Medullary + Papillary = 20 mm in length

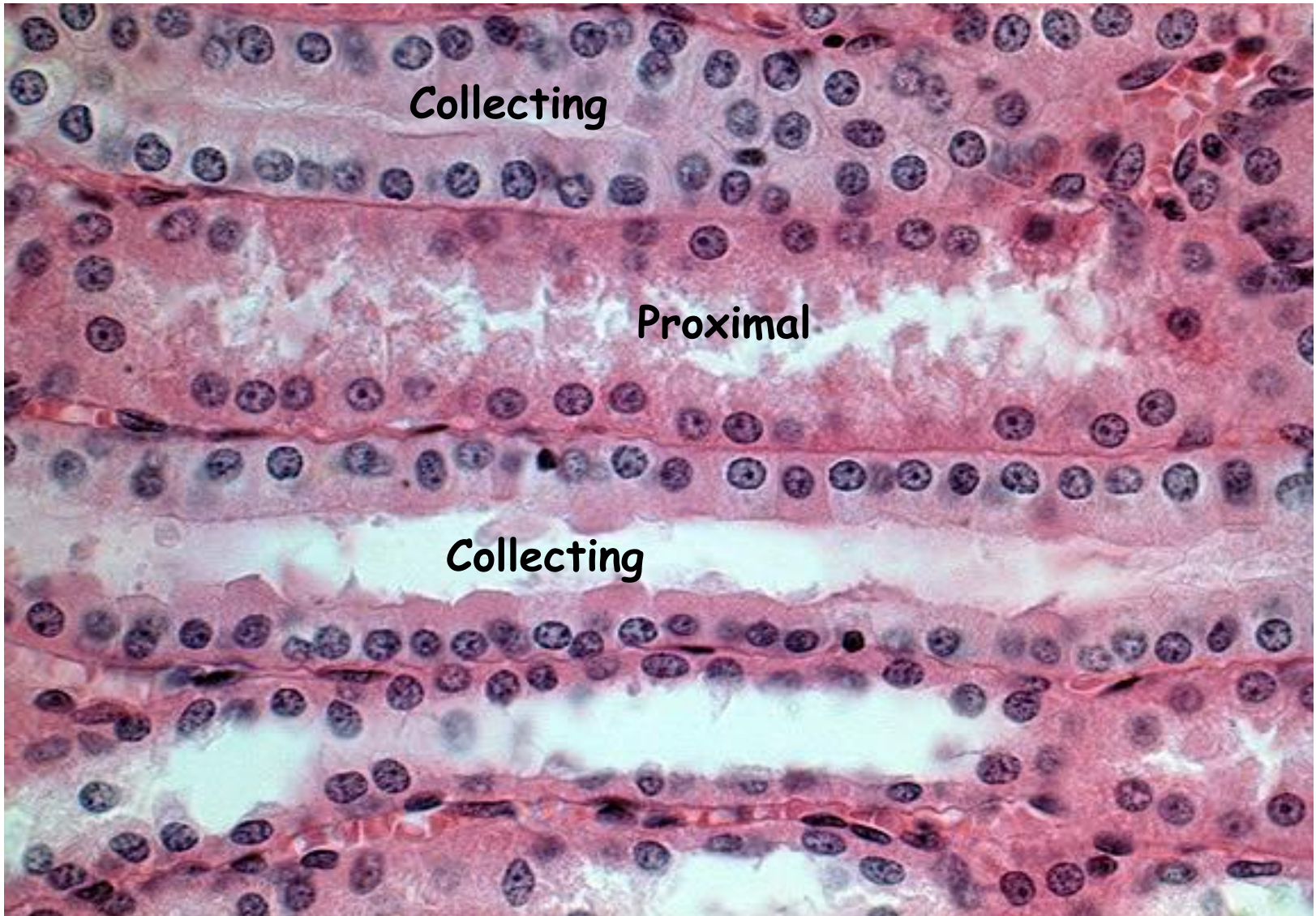
↓
200 - 300 μm



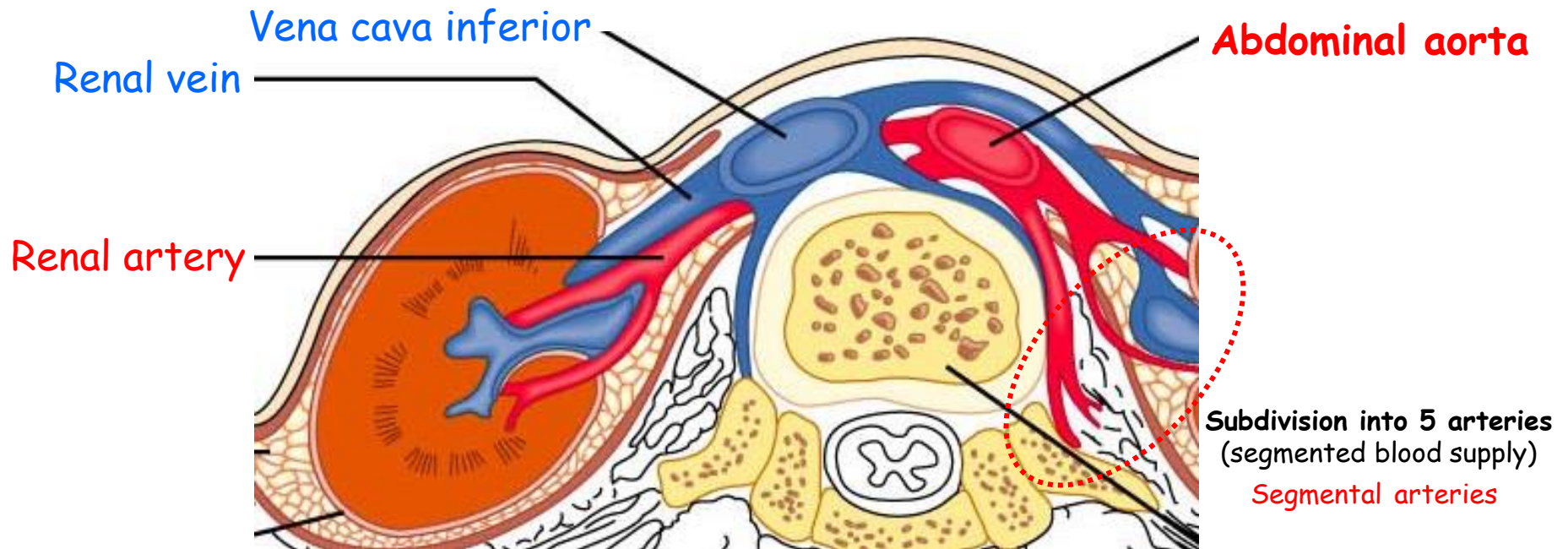
- Conserve body fluids
- Reacts to **ADH** (antidiuretic hormone) of the posterior pituitary gland
- ADH increases the permeability of the collecting tubules and distal tubules to water so more is reabsorbed
- This decreases the total volume of urine
- Alcohol inhibits the release of ADH, so less water is reabsorbed producing copious amounts of dilute urine (can cause dehydration)



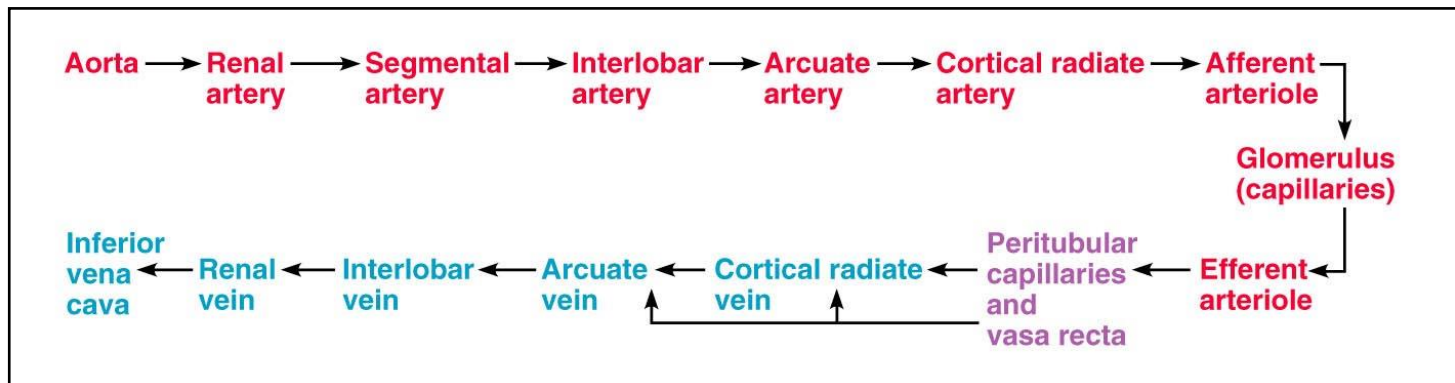
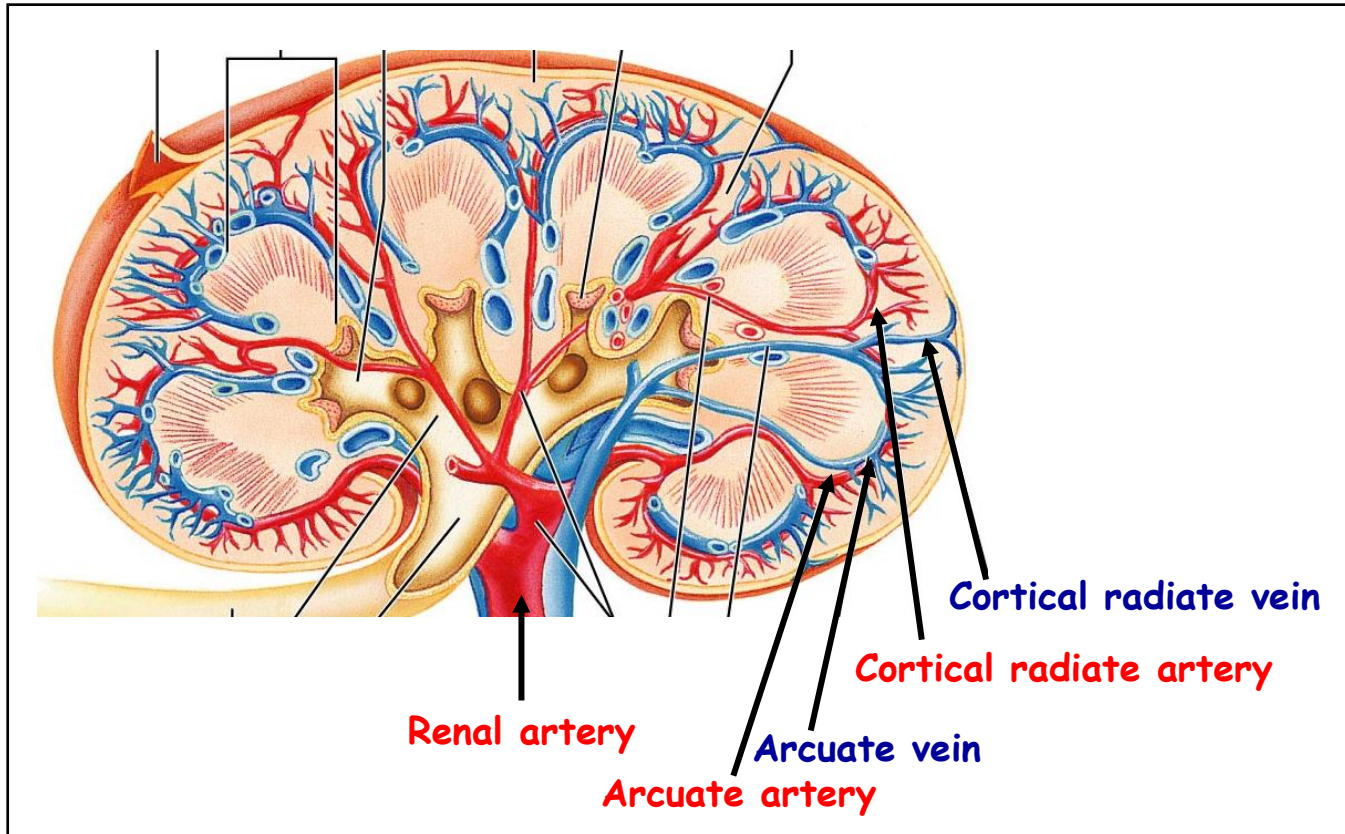
Long section of Collecting and proximal tubuli



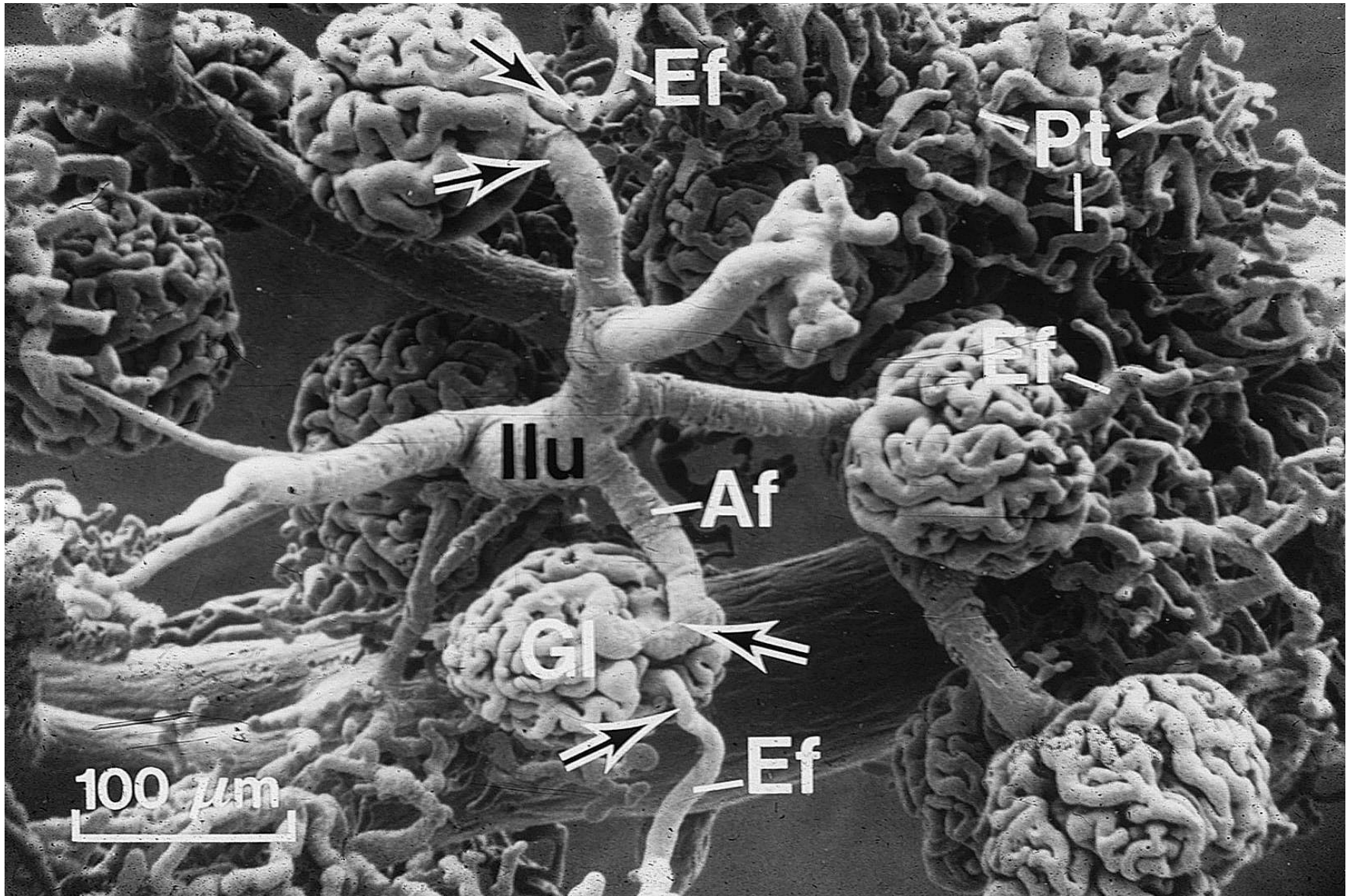
Blood circulation



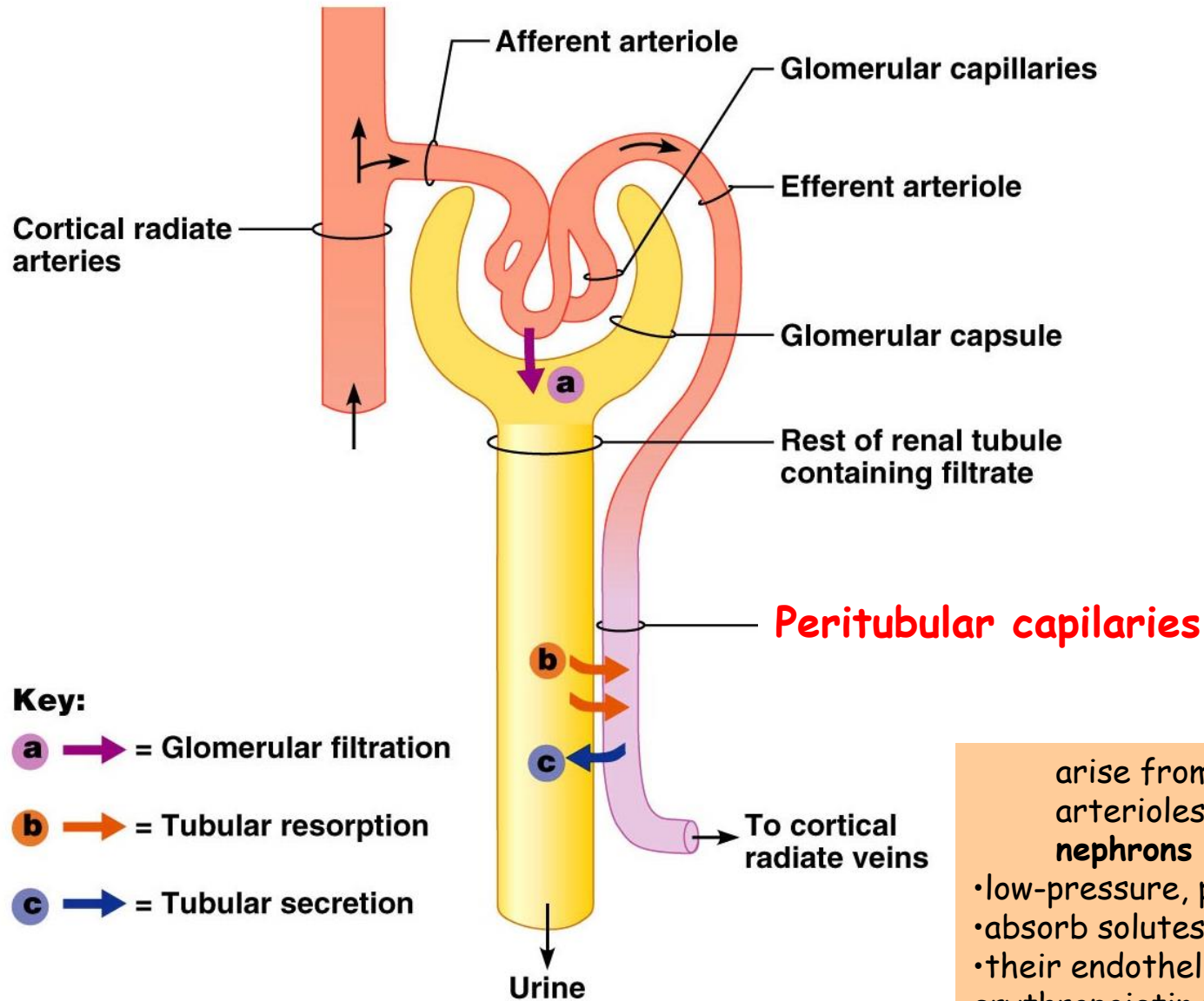
Blood circulation



Blood circulation - Afferent + Efferent arterioles



Blood circulation - Peritubular capillaries

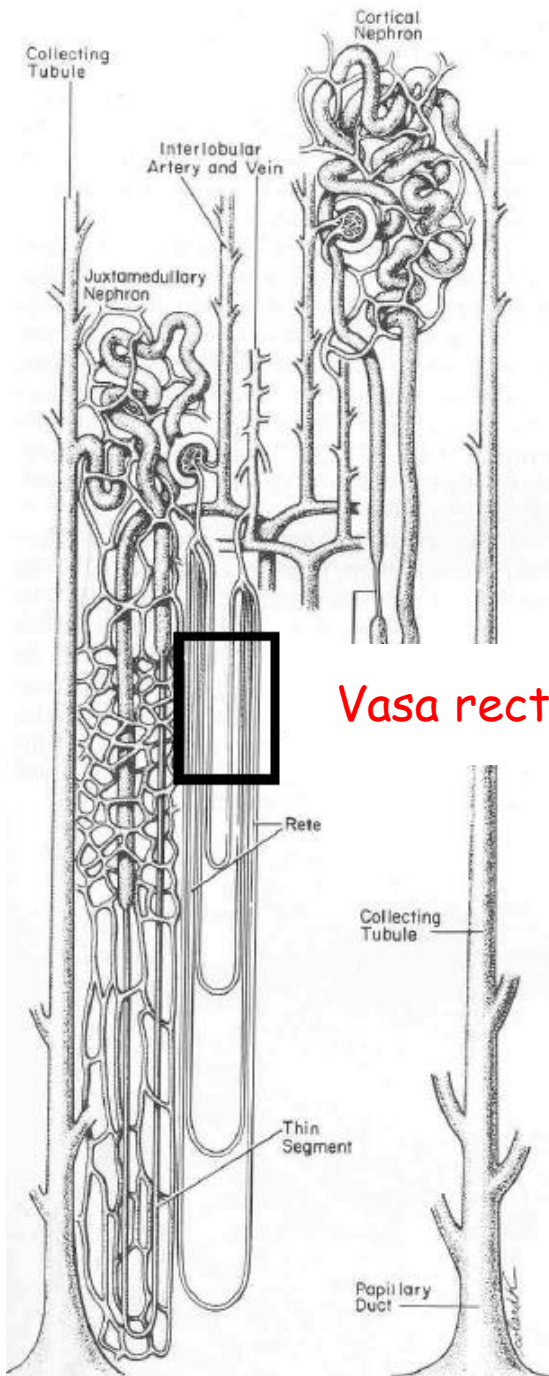


arise from efferent arterioles of **cortical nephrons**

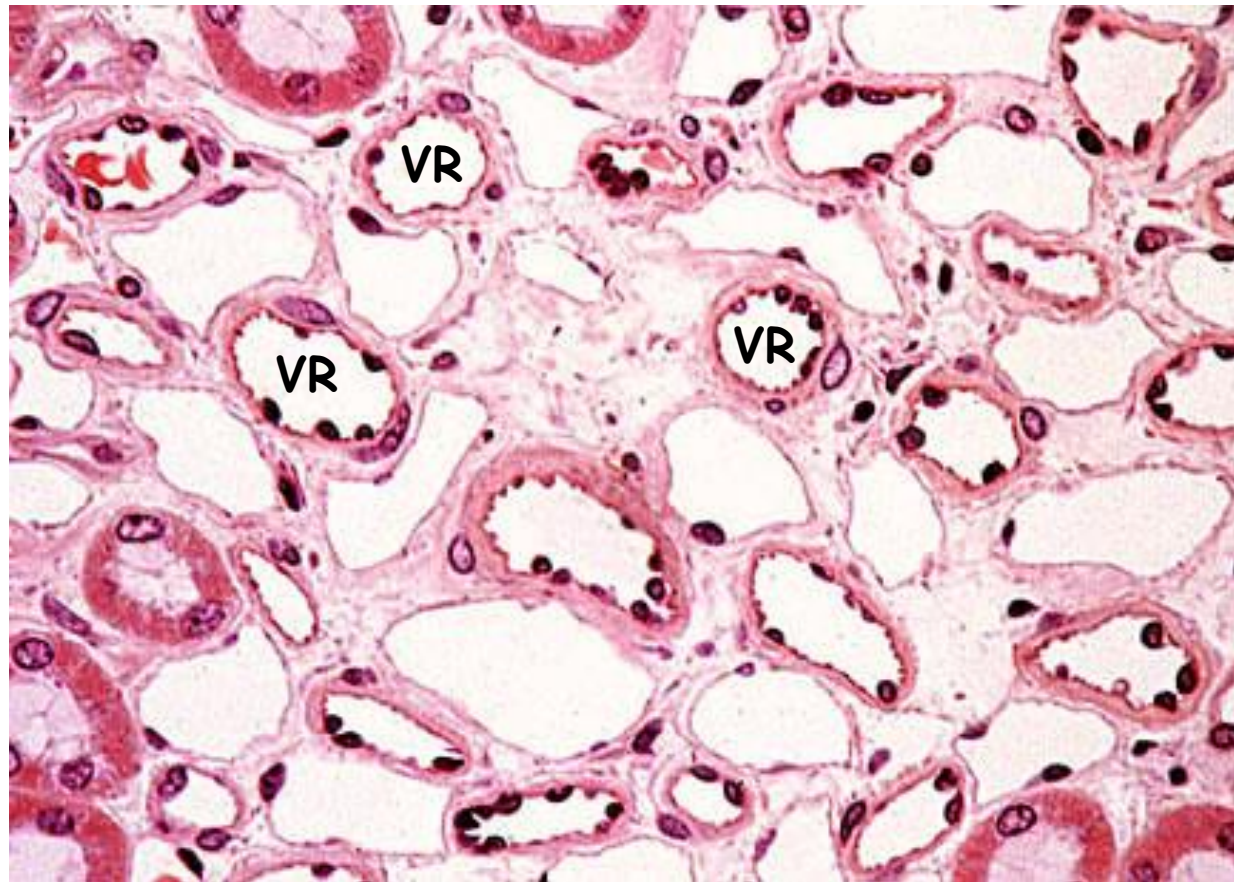
- low-pressure, porous capillaries
- absorb solutes
- their endothelia manufacture erythropoietin (?)

Blood circulation - *Vasa recta*

- arose from efferent arterioles of **juxtamedullary nephron**
- thin walled looping vessels
- 10-25 mm long
- part of the kidney's urine-concentrating mechanism



Vasa recta



Excretory passages

- Calyces (minor + major)
- Pelvis
- Ureters
- Urinary bladder
- Urethra

General organizational pattern

(calyces, pelvis, ureters, bladder)

• Mucosa

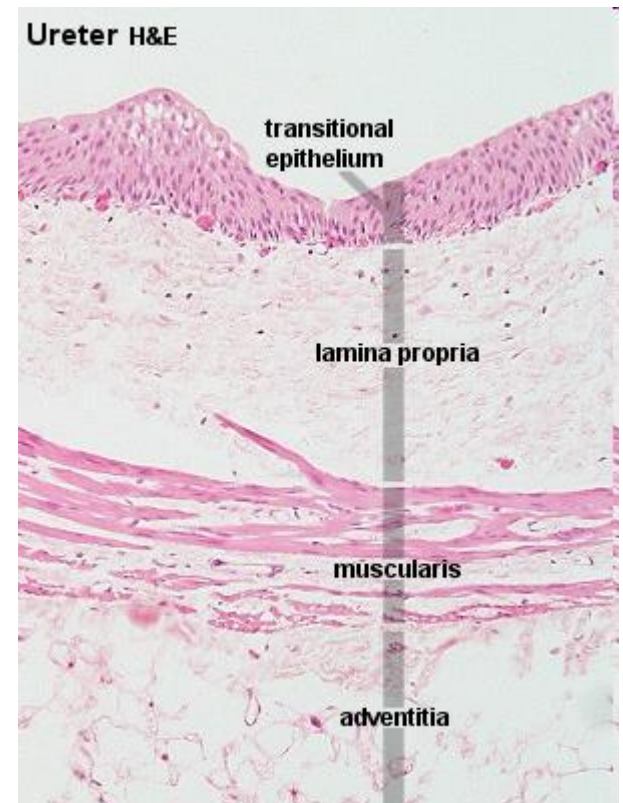
Luminal sheet epithelium (transitional)

Basal lamina

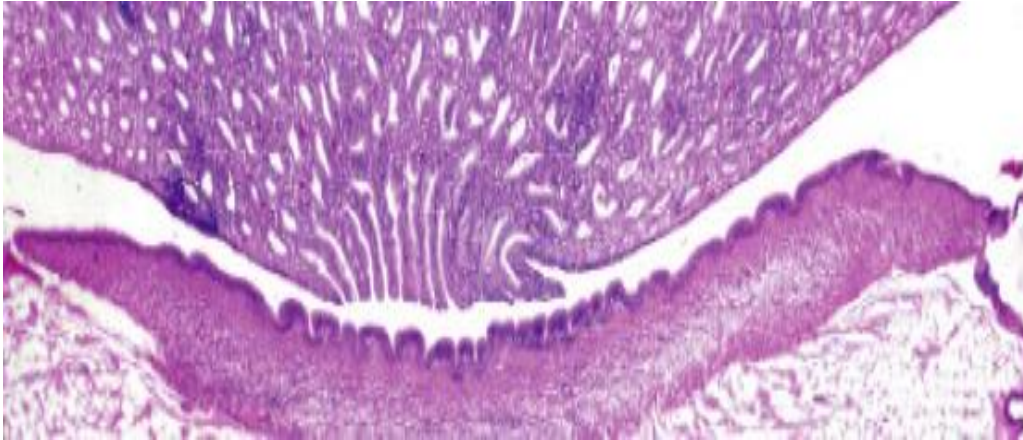
Lamina propria/submucosa (connective tissue)

• Lamina muscularis (smooth muscle)

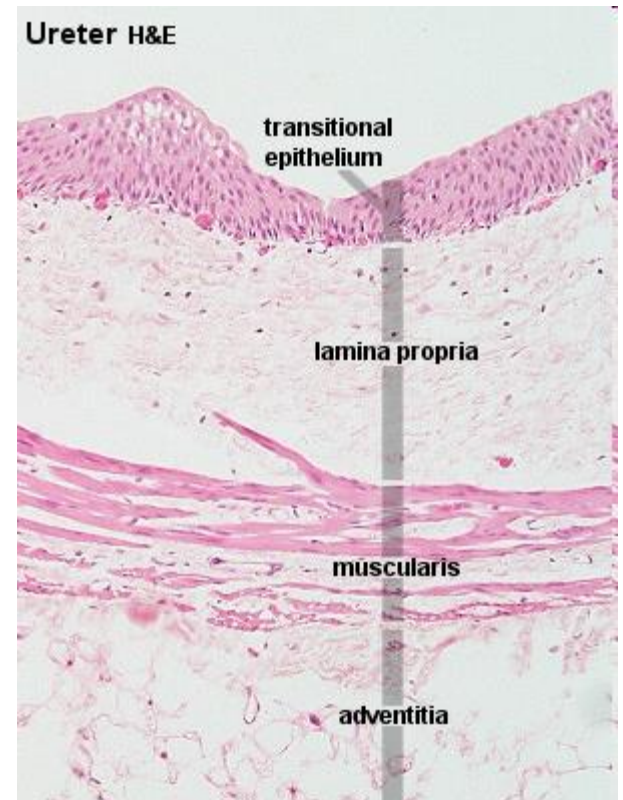
• Lamina adventitia or serosa



Renal calyces + pelvis

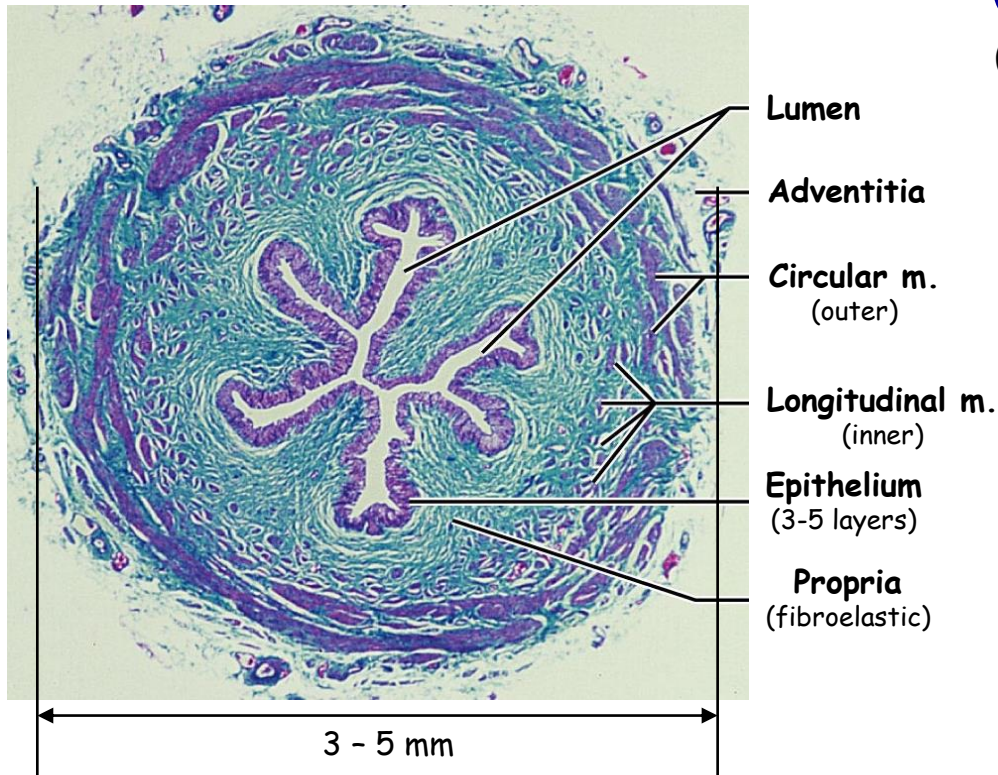


- Minimal lamina propria and submucosa
- Thin tunica muscularis
- Tunica adventitia - blends with adipose tissue in the renal sinus

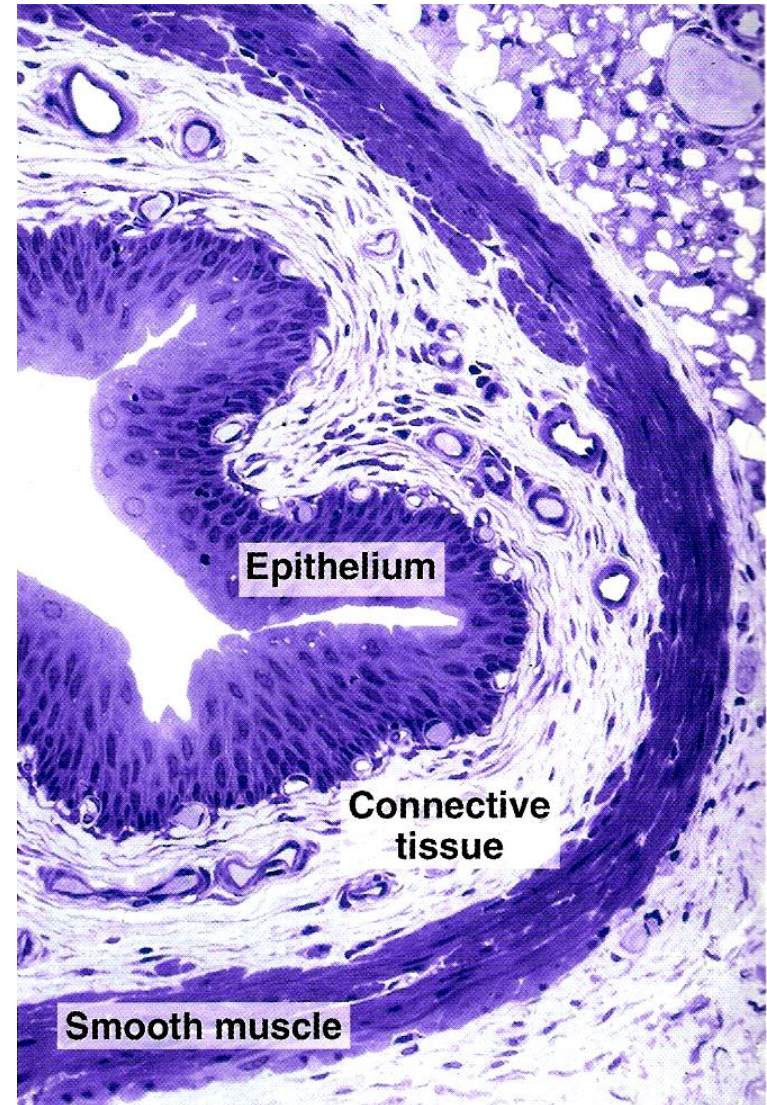


Ureters

(25-30 cm long)

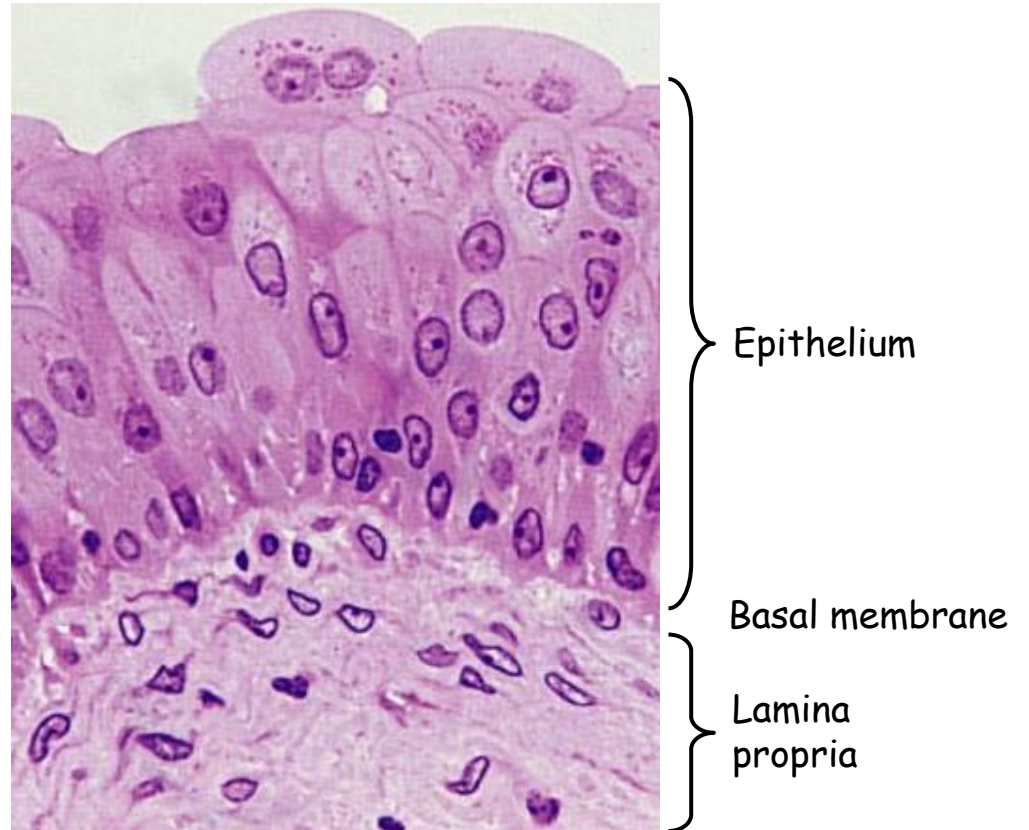
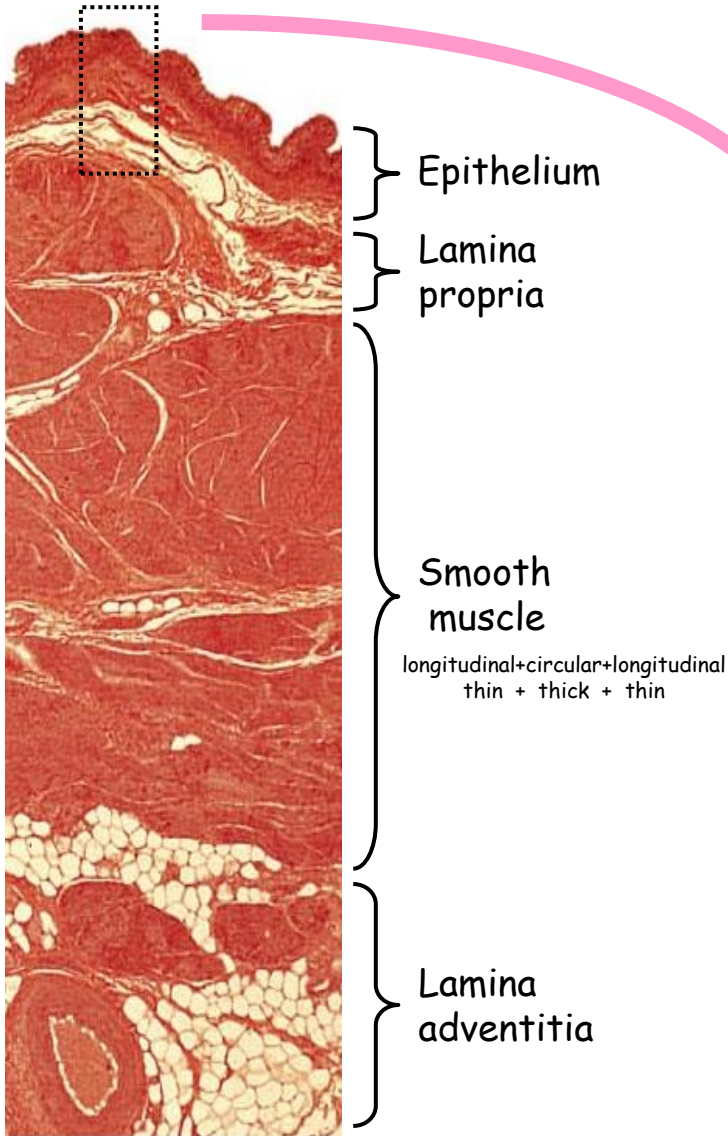


- Carry urine from renal pelvis to the urinary bladder
- Same wall layers as pelvis
- Ureter wall thickens and the muscle cells change from a helical to longitudinal array near the bladder
- Urine moves by active peristaltic motion

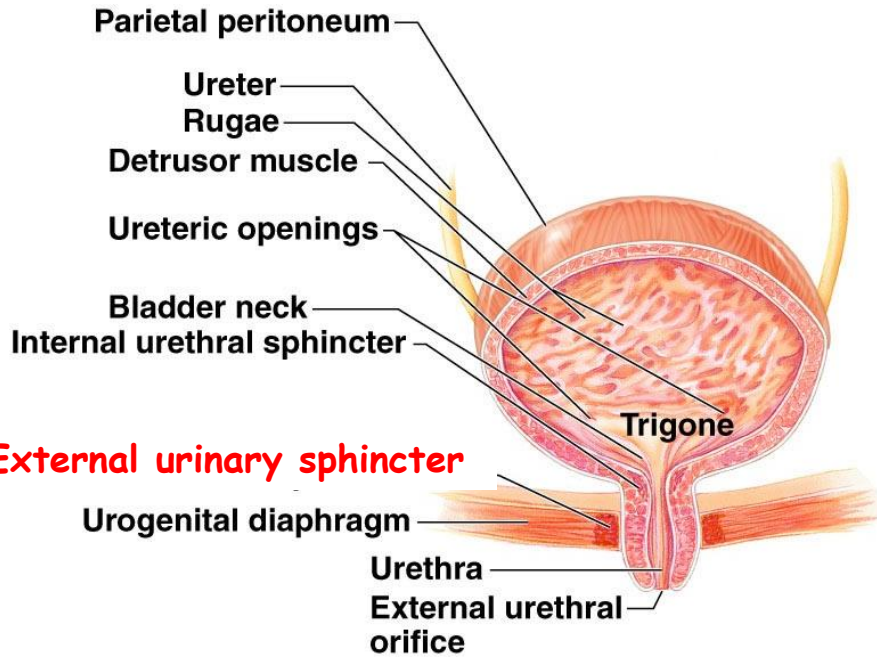


Urinary bladder

Thick muscularis - near the opening into the urethra → they form an involuntary **internal sphincter**.

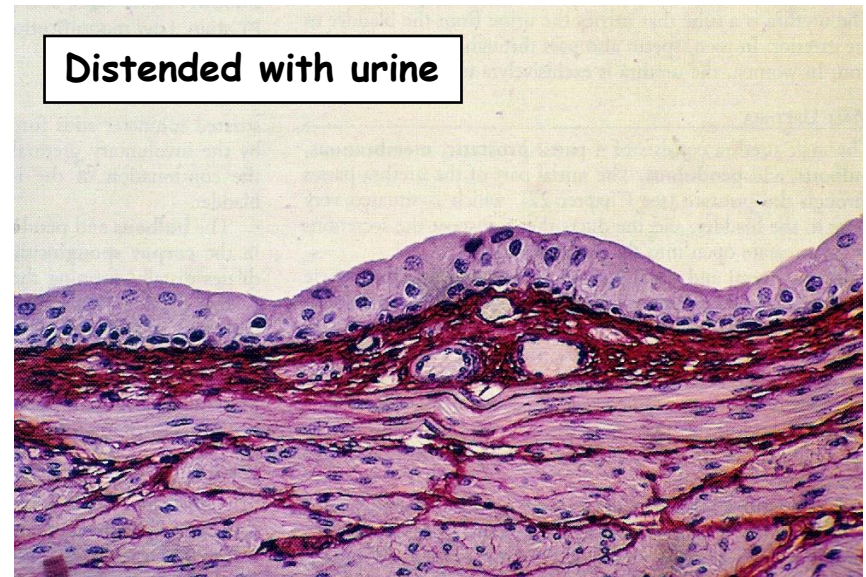
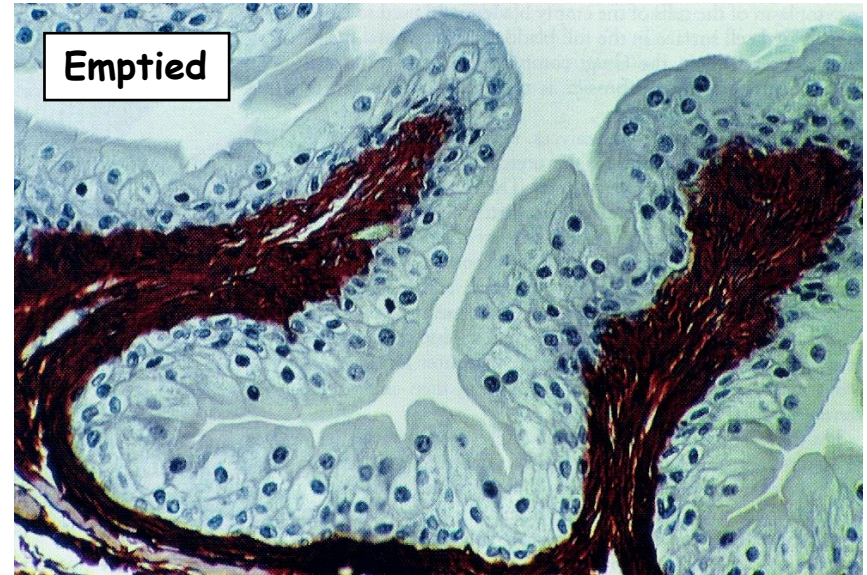

Urinary bladder



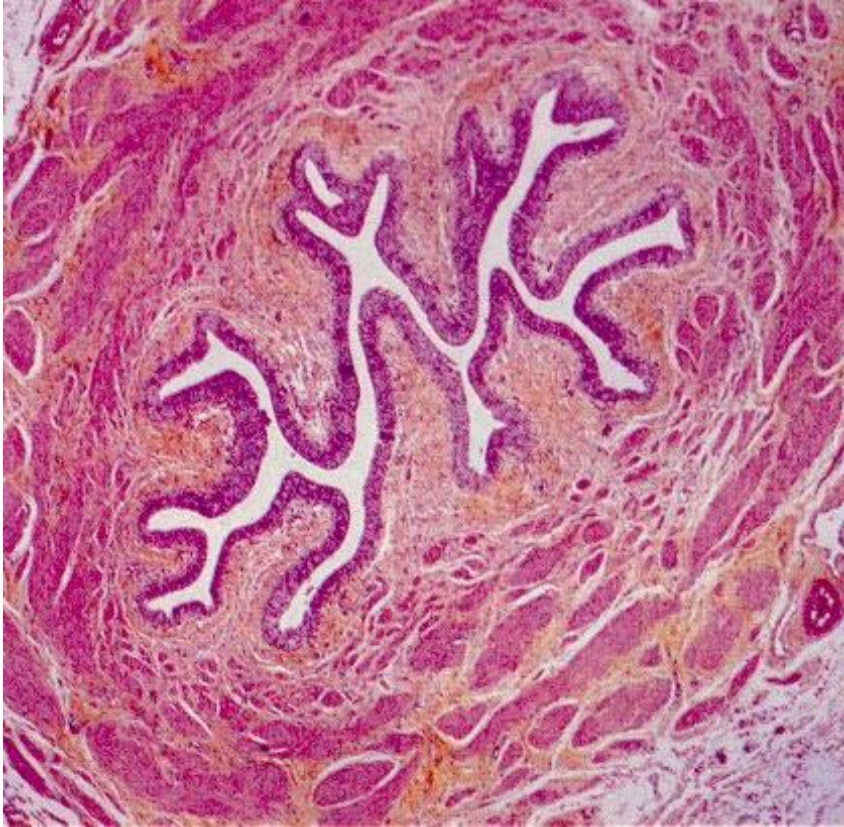
External urinary sphincter

(b)



Female urethra

(4-5 cm in length)



Transitional epithelium

- **Transitional + stratified squamous nonkeratinizing ep.**
- **Folded mucosa** (due to fibroelastic propria)
- **Two-layered muscularis**
- **Glands of Littre**

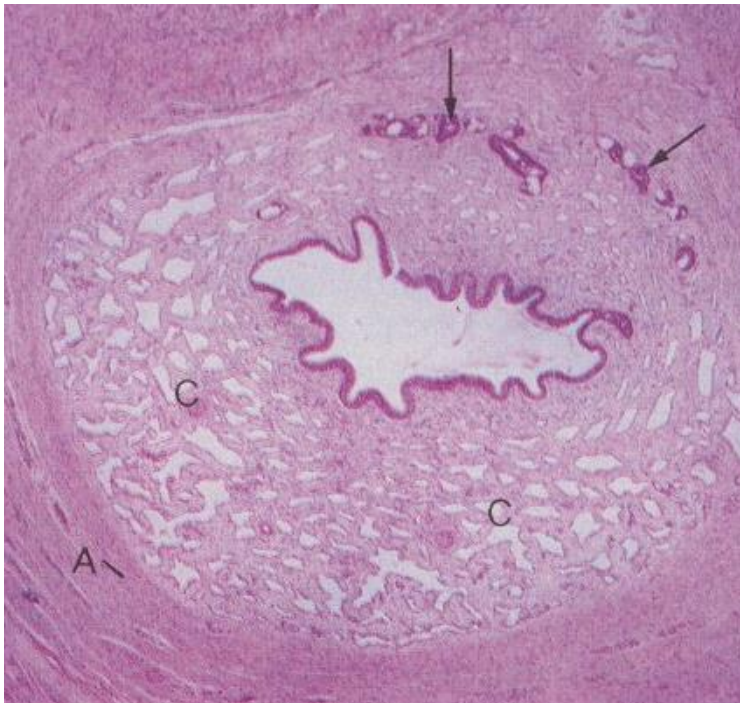
Male urethra

(15-20 cm in length)

Prostatic urethra - transitional ep., openings of prostate gland

Membranous urethra - stratified columnar ep., through the urogenital diaphragm

Spongy (penile) urethra - stratified columnar + squamous ep.

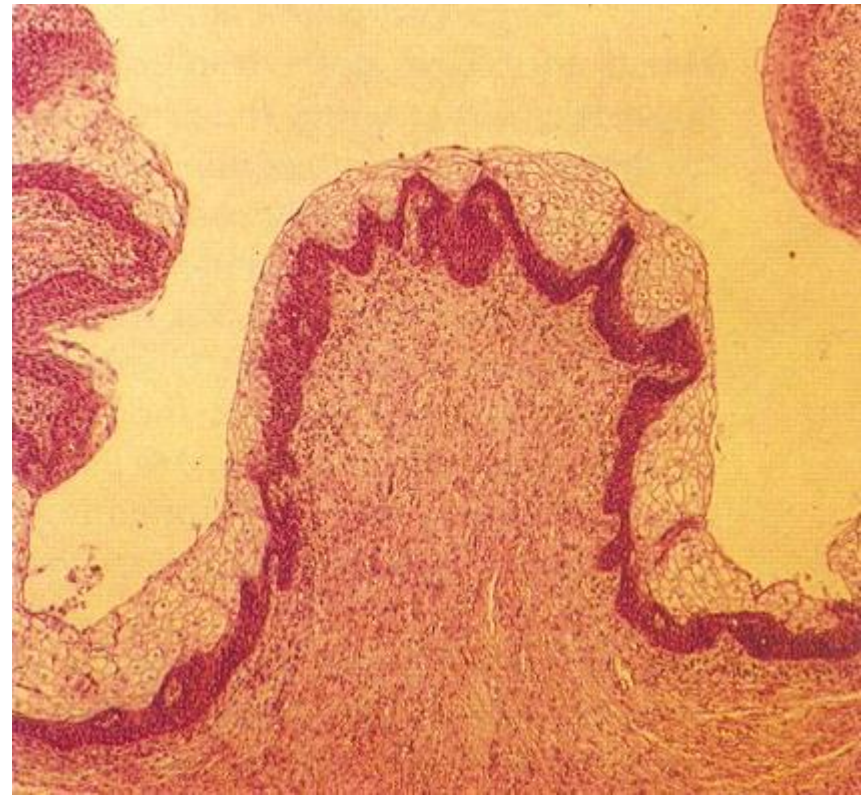


Spongy - penile

A) Tunica albuginea

C) Corpus spongiosum (erectile)

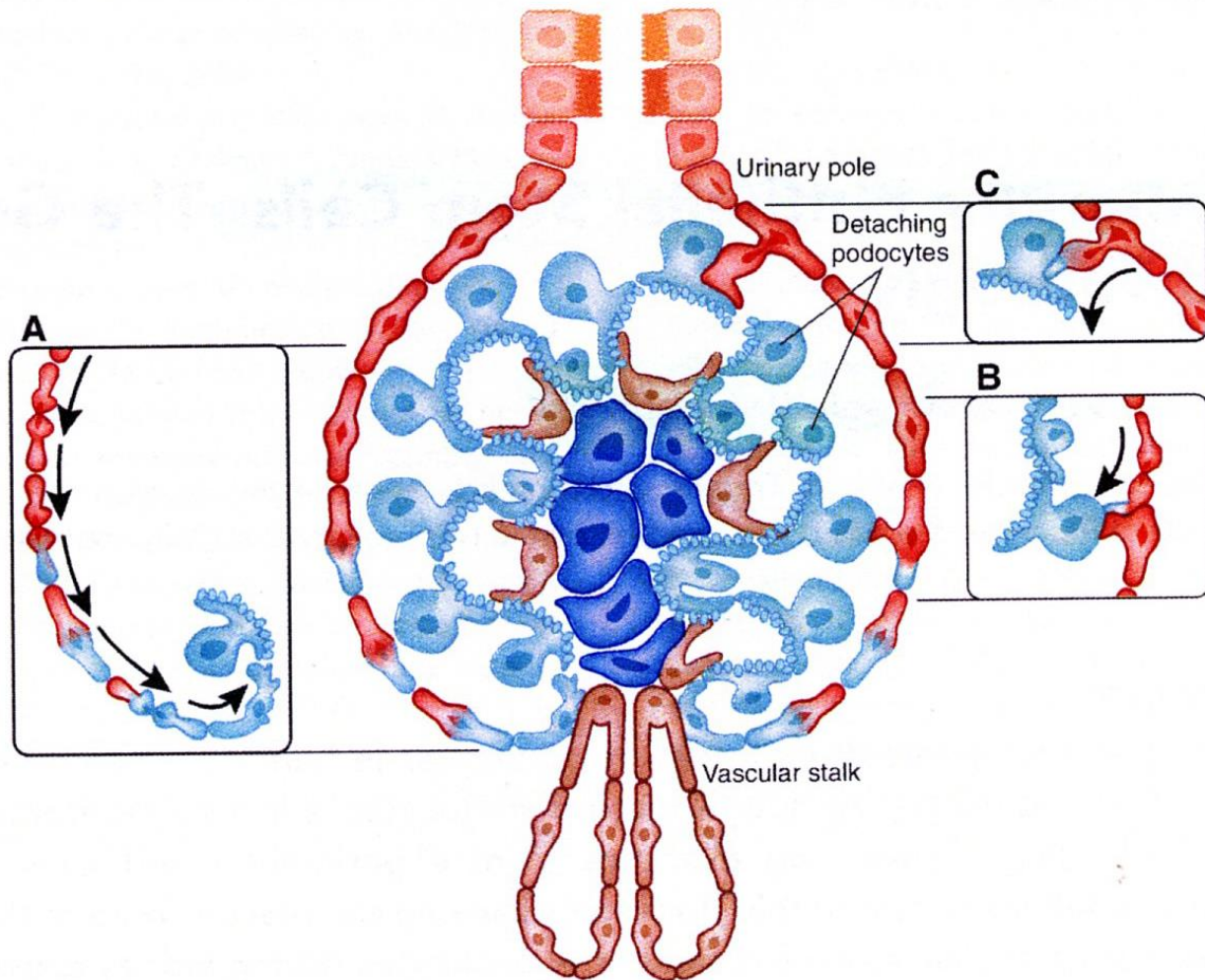
Arrows) Glands of Littre



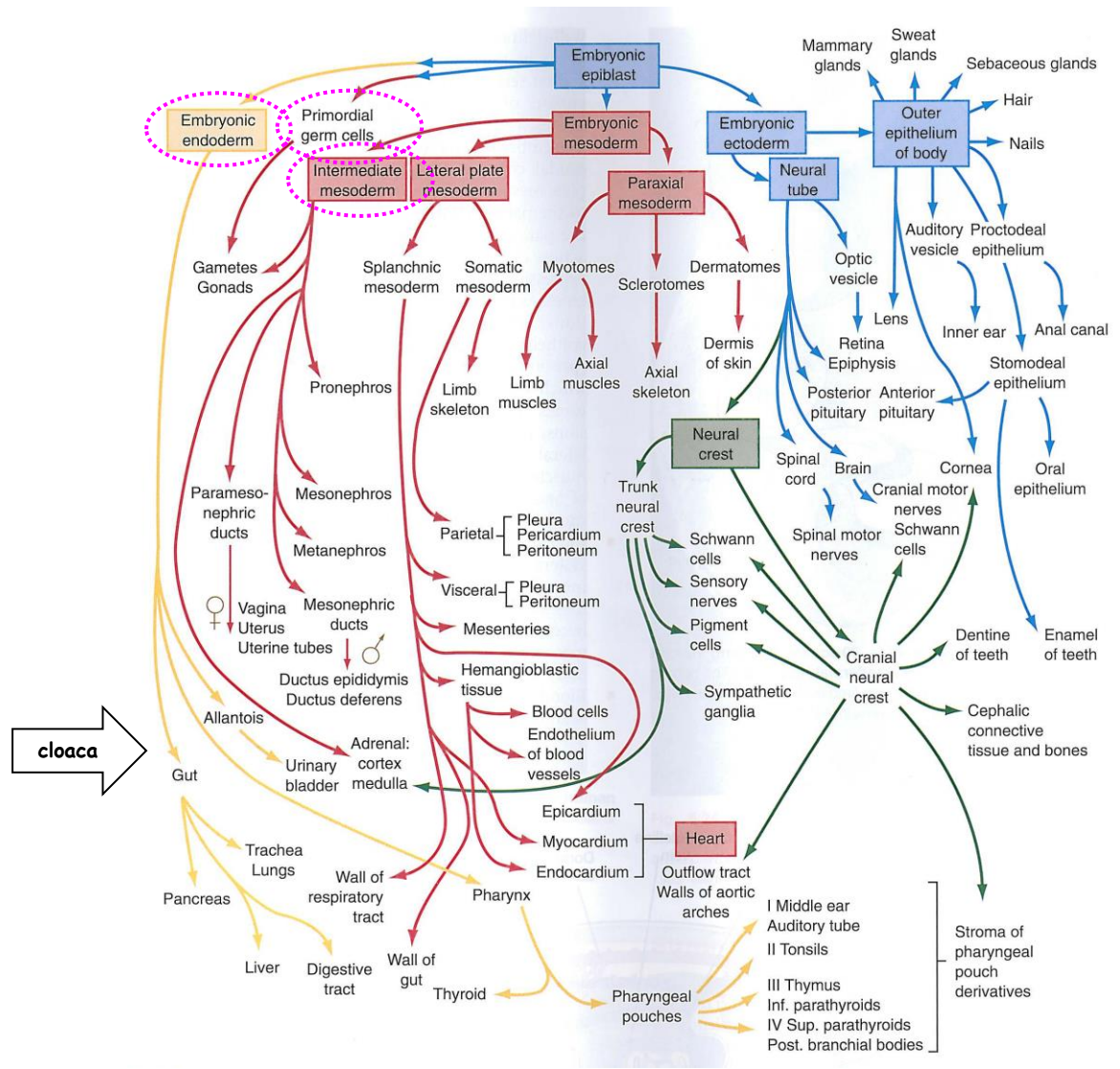
Near the tip of penis - fossa navicularis

Stratified squamous epithelium (nonkeratinizing)

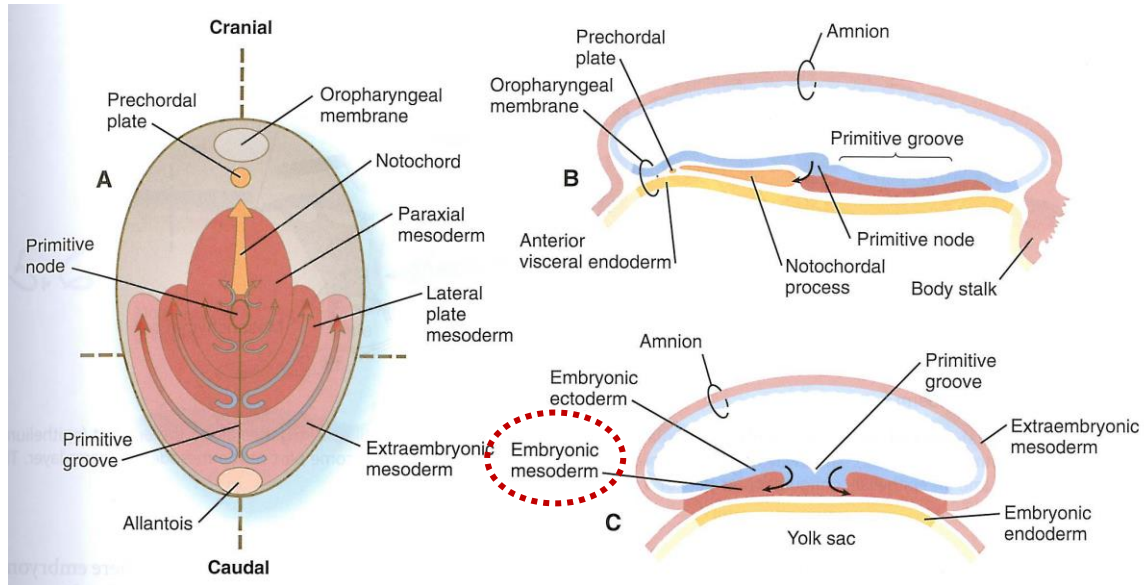
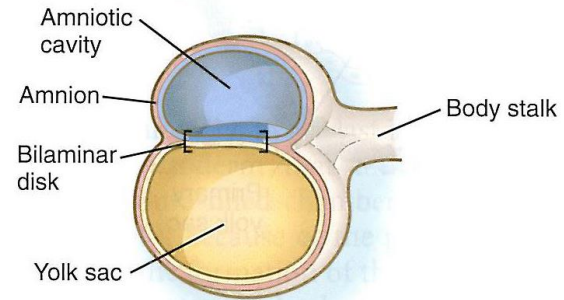
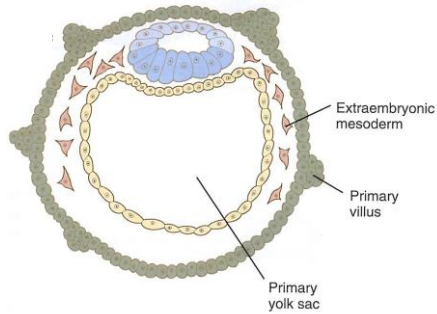
Dialysis x Kidney transplant x Kidney regeneration ?



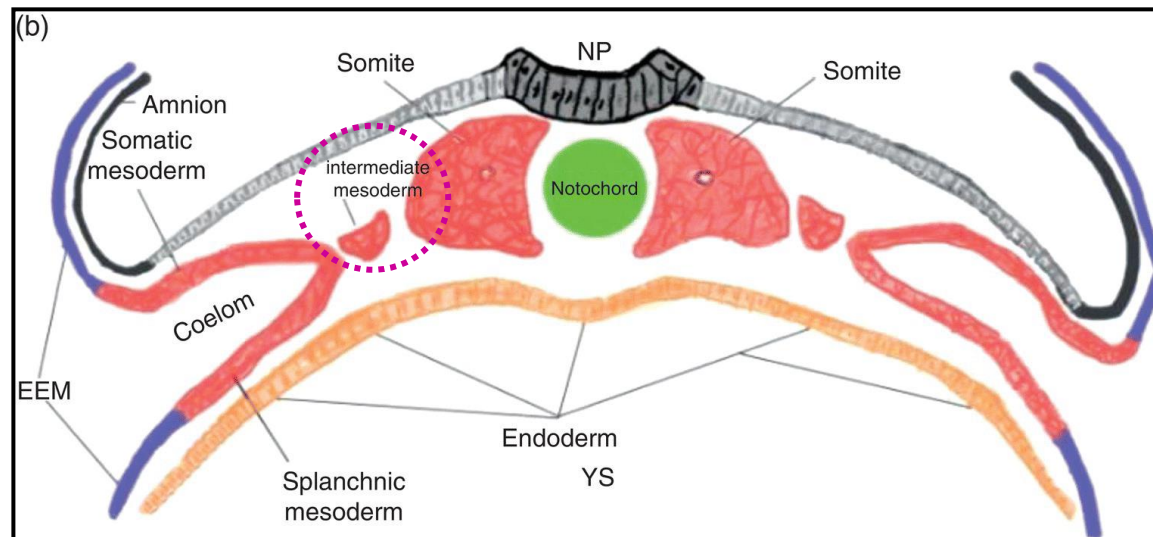
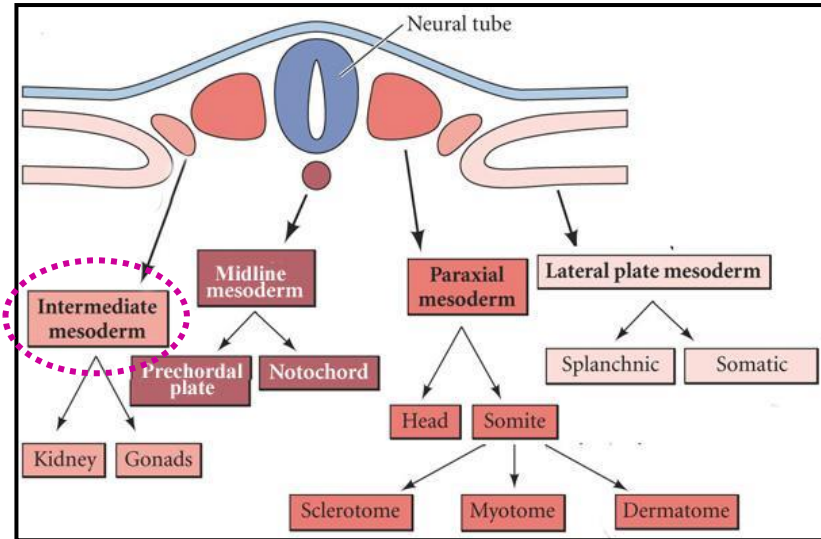
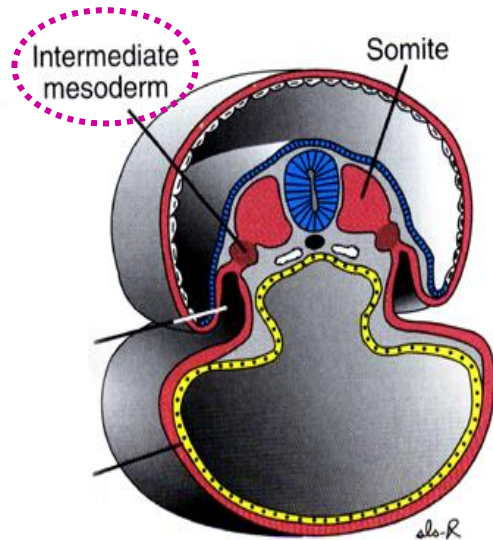
Urogenital system - Overall picture



Urogenital system - Reminder



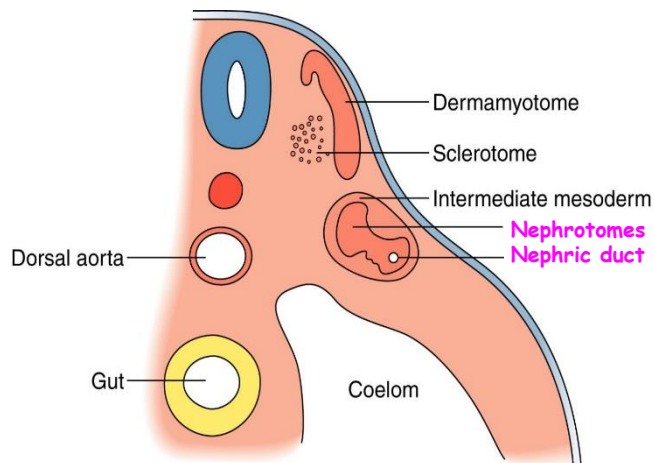
Urogenital system - Intermediate mesoderm



Urogenital system - Early forms of kidneys - Pronephros

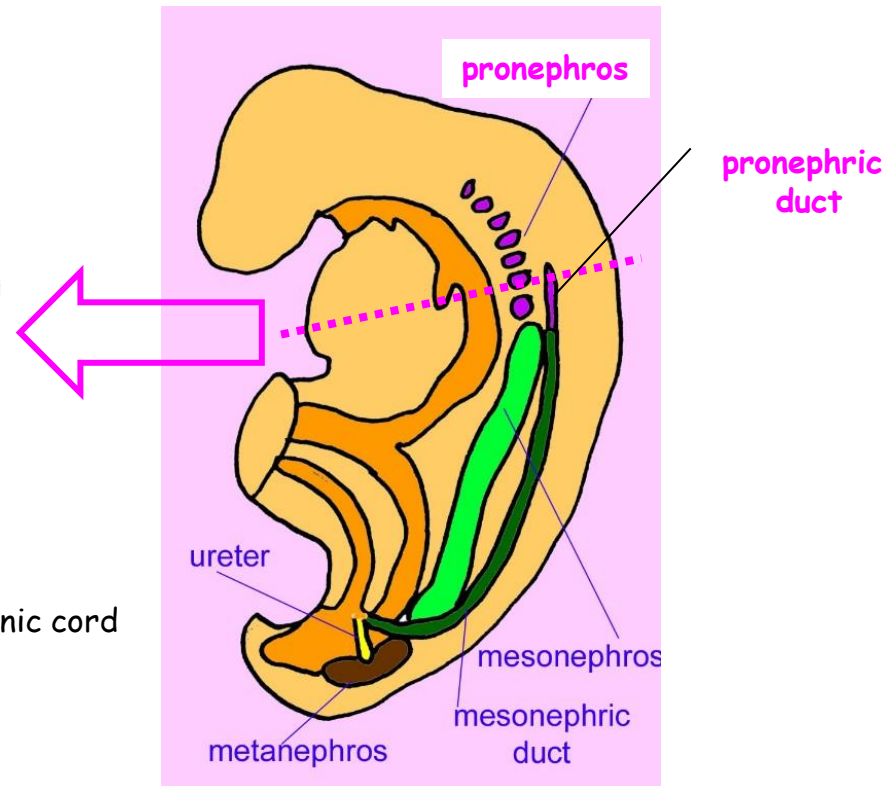
Recapitulation of three stages of evolution of kidneys in a cranial to caudal sequence:

- pronephros
- mesonephros
- metanephros



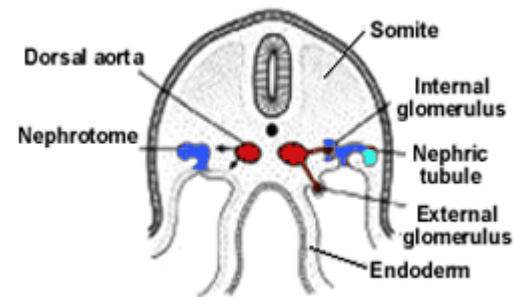
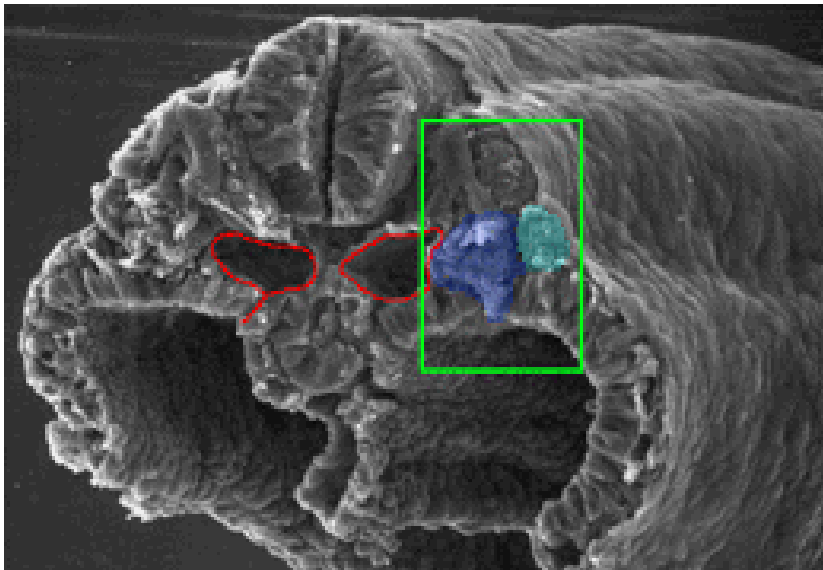
Nephrotomes

- at about day 22 in cervical part of nephrogenic cord
- 7 to 10 groups of epithelial cells
- connect to pronephric duct
- non-functional
- disappear by day 28



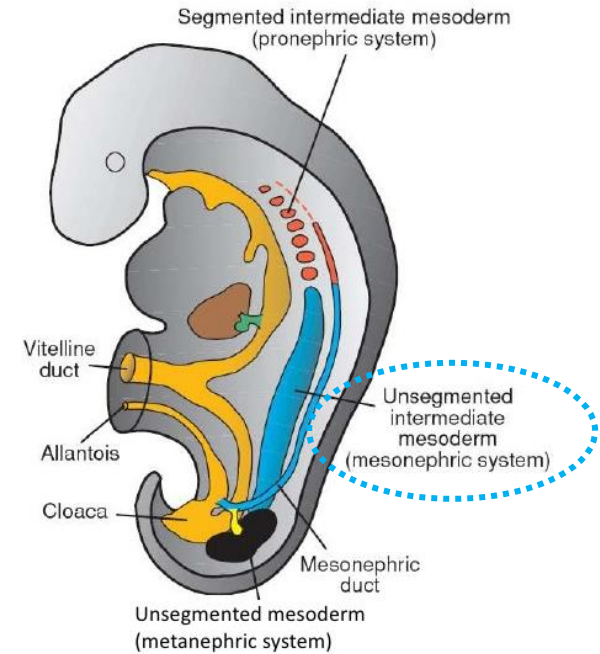
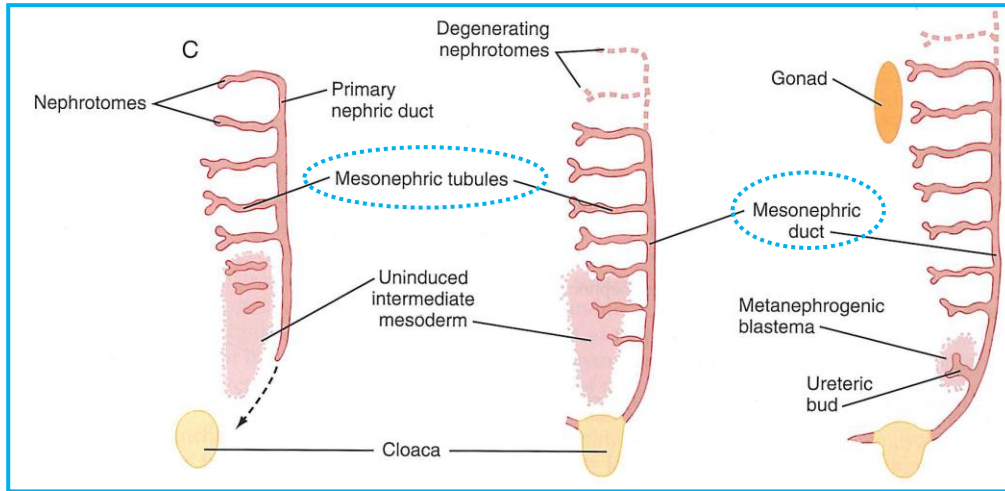
Urogenital system - Early forms of kidneys - Pronephros

Mouse D9 - equivalent to human D27



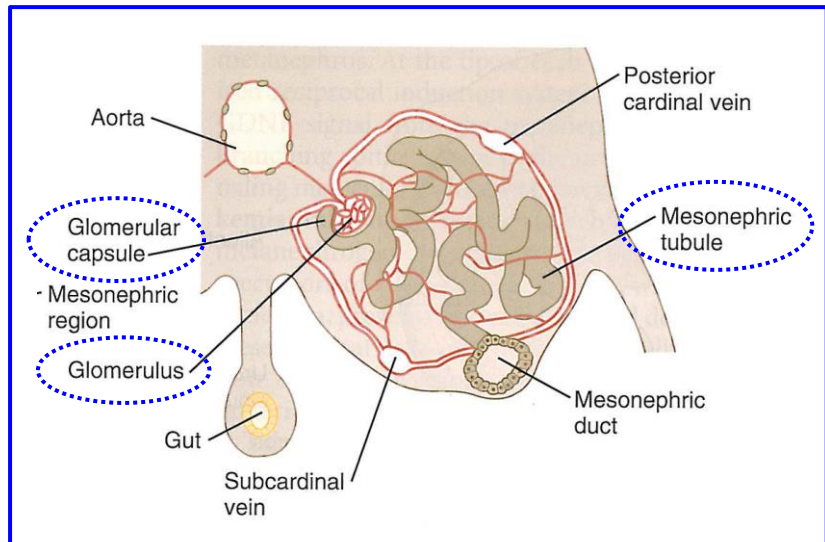
The lumen of each **nephrotome** opens into the **primary nephric duct** as well as into the body cavity. Glomeruli form as small vessels extend from the **dorsal aortae**.

Urogenital system - Early forms of kidneys - Mesonephros

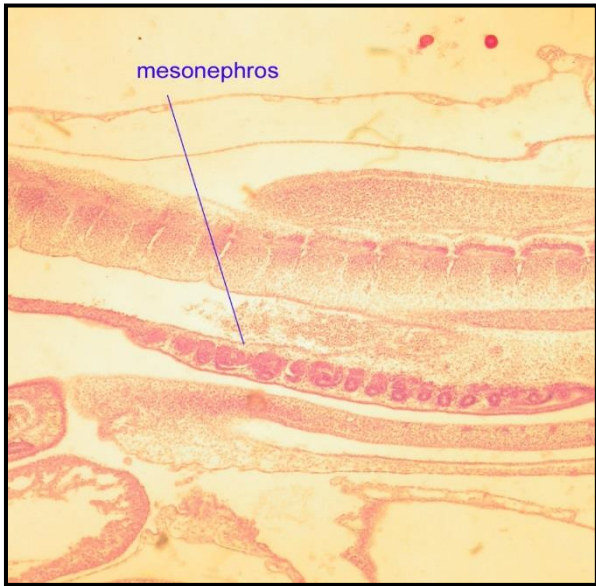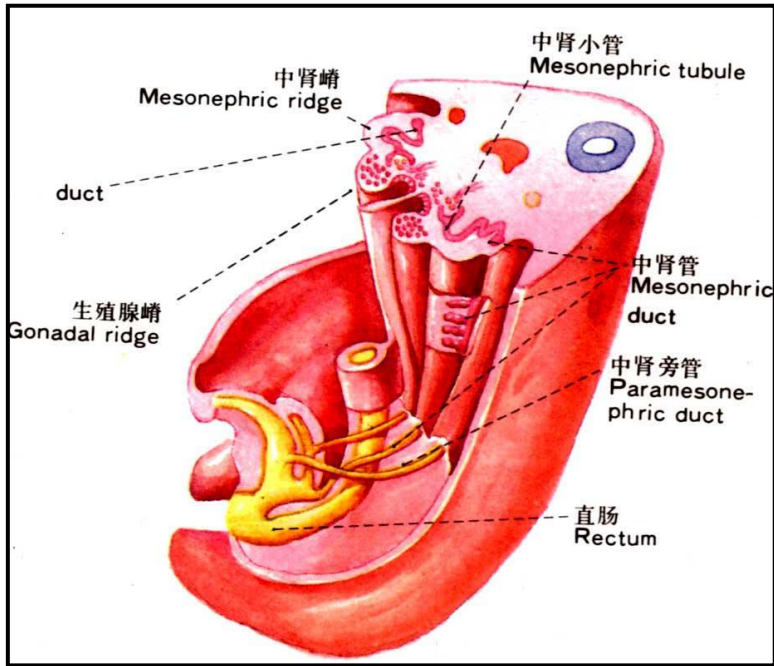
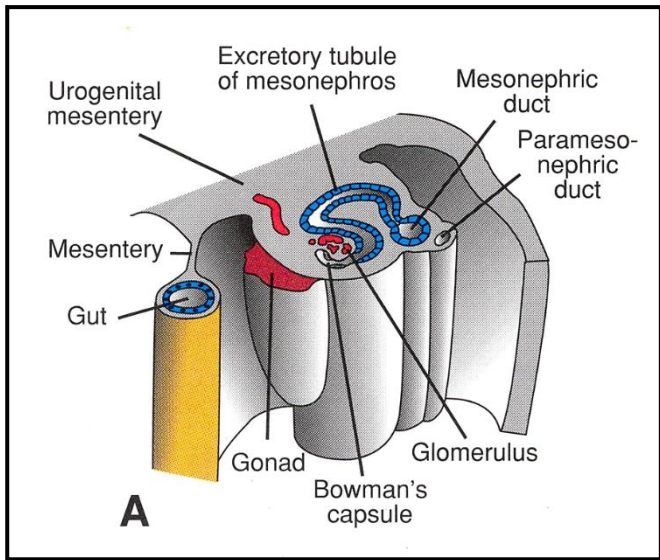


Mesonephros

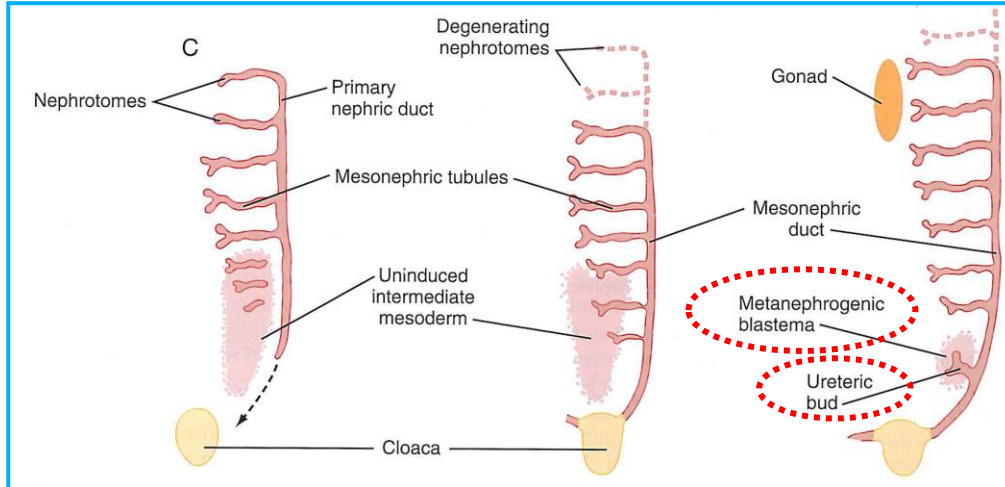
- caudal continuation of nephrogenic cord
- thoracolumbar region
- unsegmented intermediate mesoderm
- mesonephric ducts (paired) - Wolffian ducts
- mesonephric tubuli - open individually into m. duct
- 36 to 40 m. tubuli in total (on one side)
- some filtration - **mesonephric unit** →
- mesonephros is most prominent when metanephros start to shape - **active since week 6 til week 10**
- then they disappear fast
- mesonephric ducts persist in males



Urogenital system - Mesonephros - Another view



Urogenital system - Definitive kidneys - Metanephros



Develop since week 5

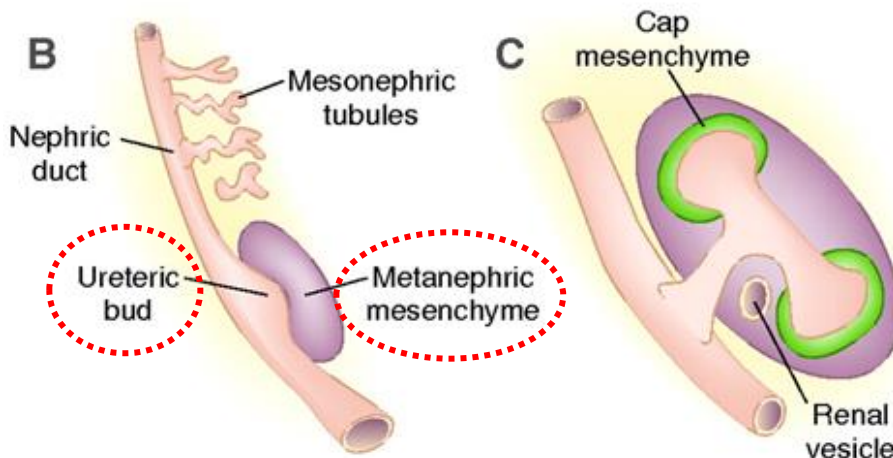
Ureteric bud = metanefric diverticulum

+

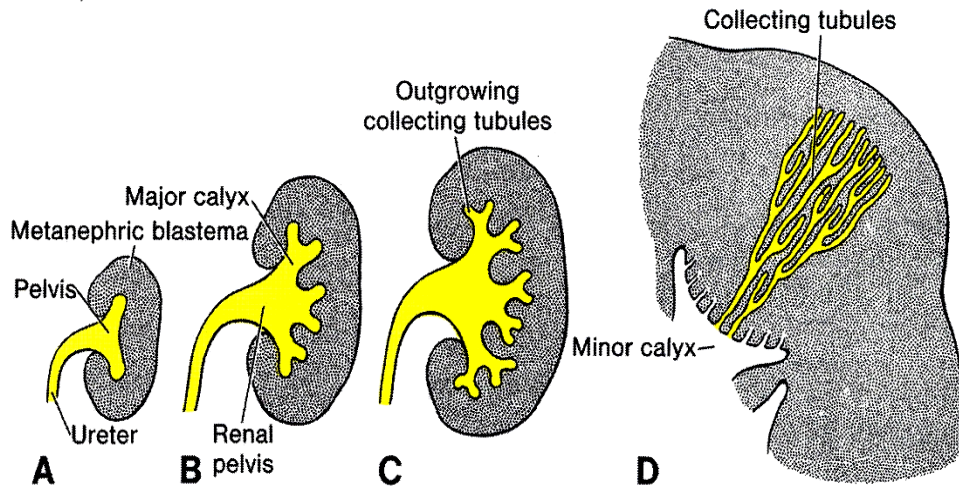
Metanephrogenic blastema
(mesenchyme)

Branching
and
Elongation

14 to 15 x



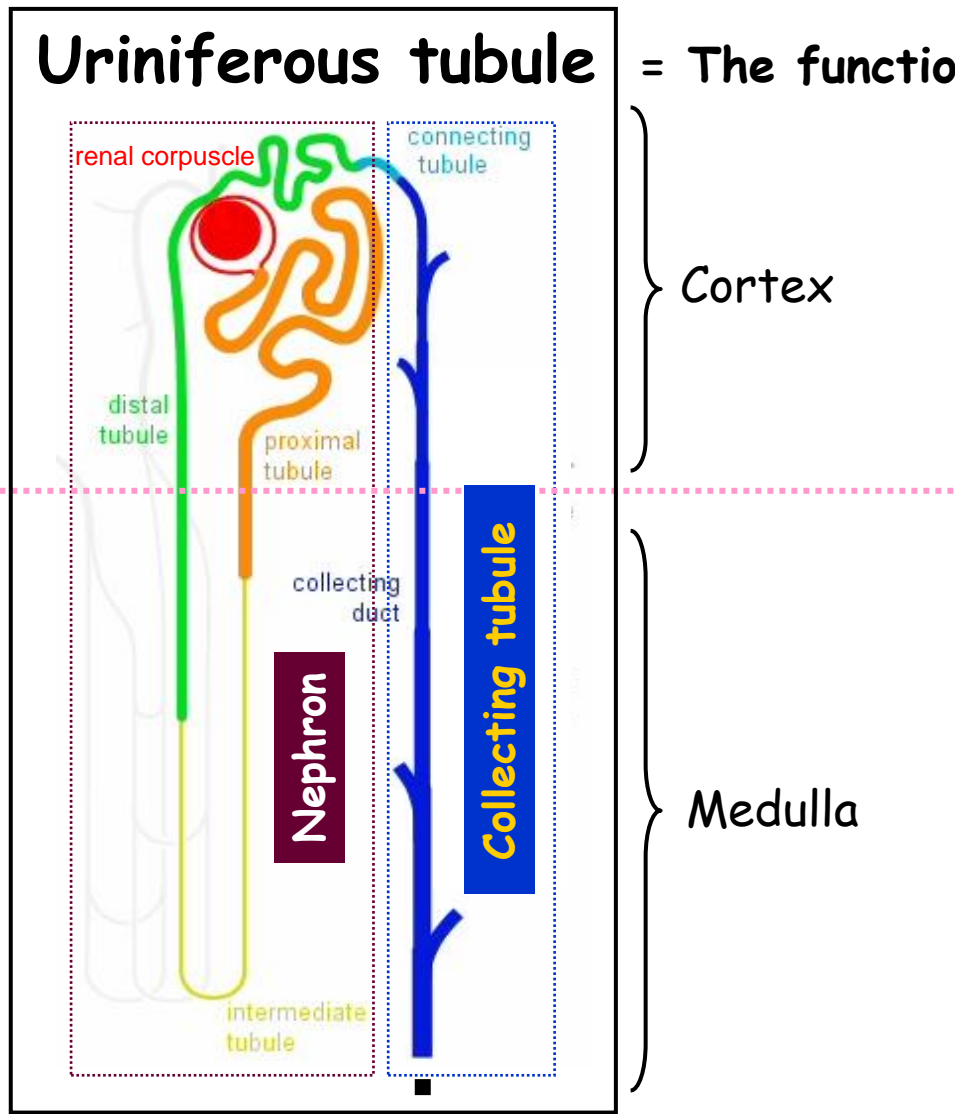
Urogenital system - Definitive kidneys - Metanephros



Repeated branching of ureteric bud produces:

- ureter
- pelvis
- calyces (major + minor)
- collecting tubuli (1 to 3 millions)

Urineriferous tubule = The functional unit of the kidney



Cortex

Medulla

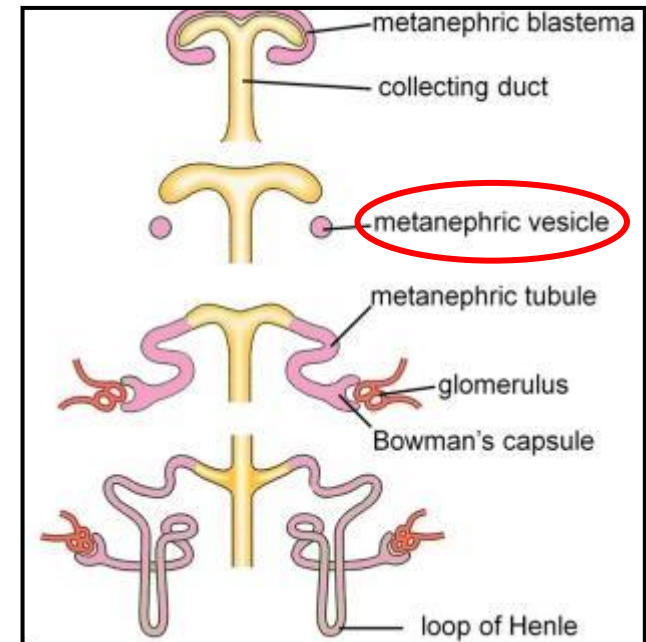
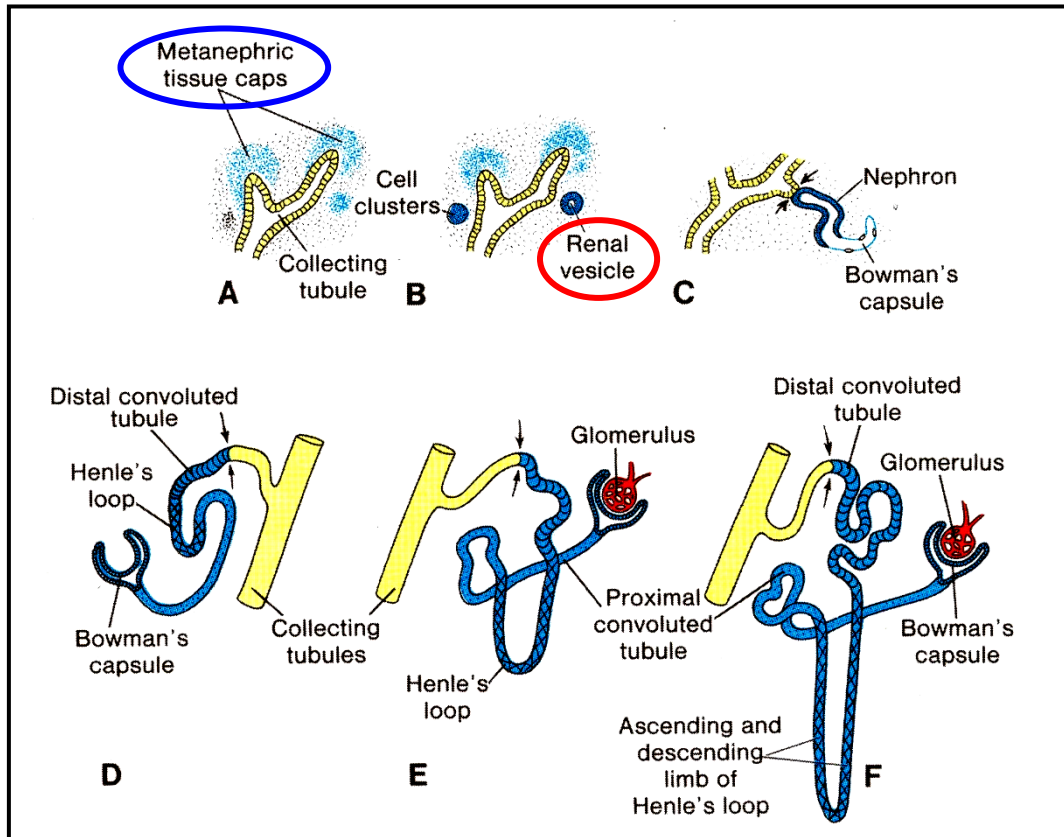
Ducts of Bellini

1 to 1.4 millions
of nephrons
in one kidney

Area cribrosa
Minor calyx

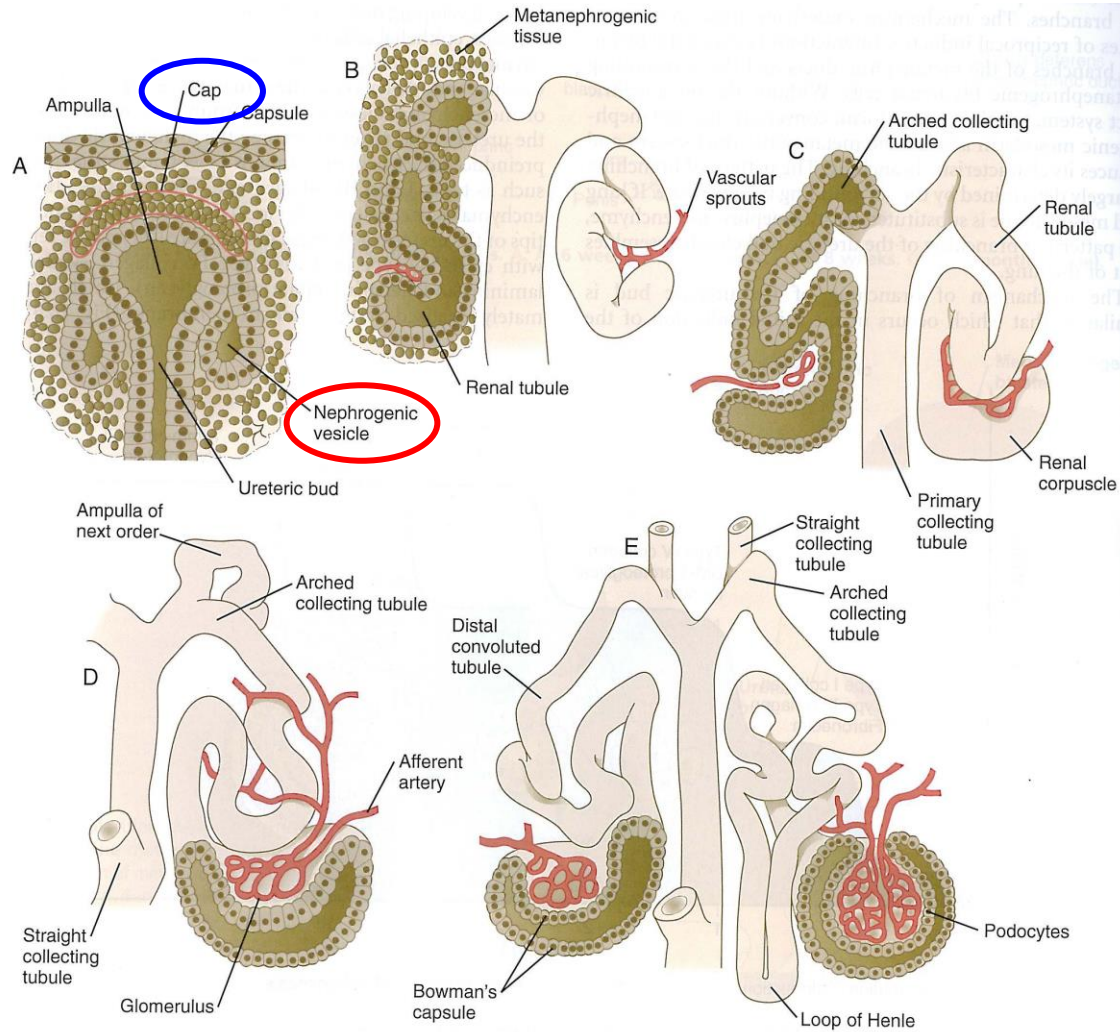
Nephrons X Collecting tubules
Different embryological origin

Urogenital system - Metanephros - Nephrons

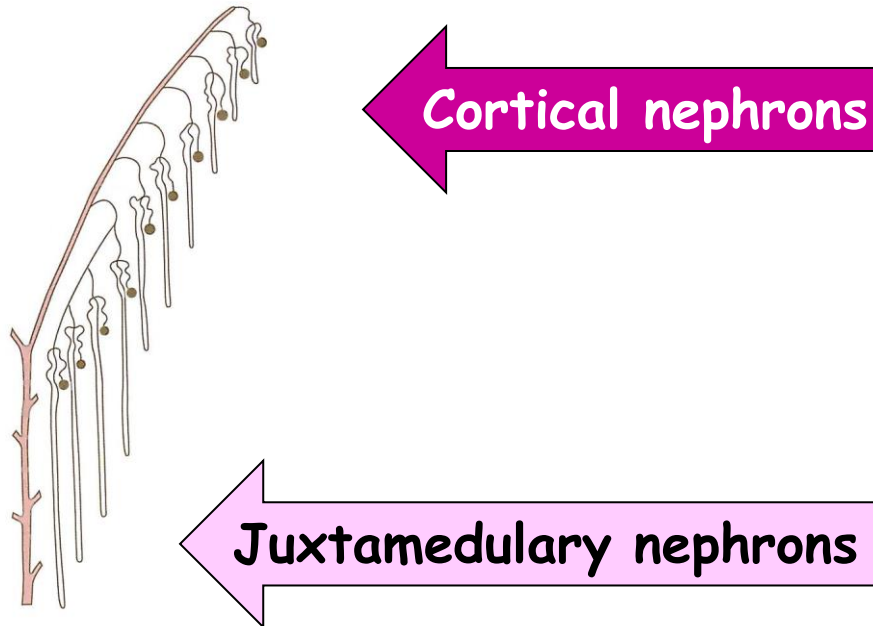


- arched ampulous endings of ureteric ducts (collecting tubuli) - **capping** by condensed mesenchyme
- part of the cap cells differentiate into **nephrogenic vesicle**
- vesicles elongate
- vesicles open to the collecting tubulus on one end
- distal from the ducts, the cells of elongating vesicles polarize and form **lumen and basal lamina**
- precursors of endothelia grow into this area - **glomerulus**
- endothelia connect to branches of dorsal aorta - **glomerular circulation**
- production of urine since week 10

Urogenital system - Metanephros - Nephrons

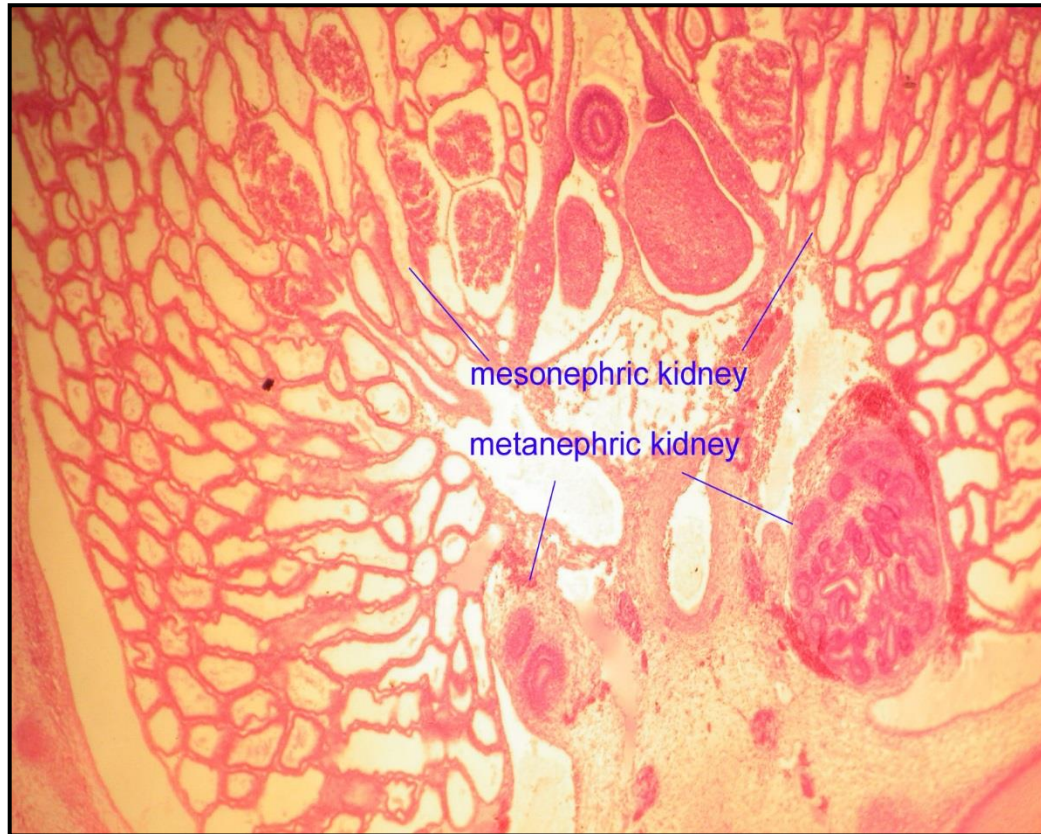

Urogenital system - Metanephros - Nephrons



- about 15 successive generations of nephrons in peripheral zone of kidney
- outermost nephrons are **less mature**

Urogenital system - Definitive kidneys - Metanephros

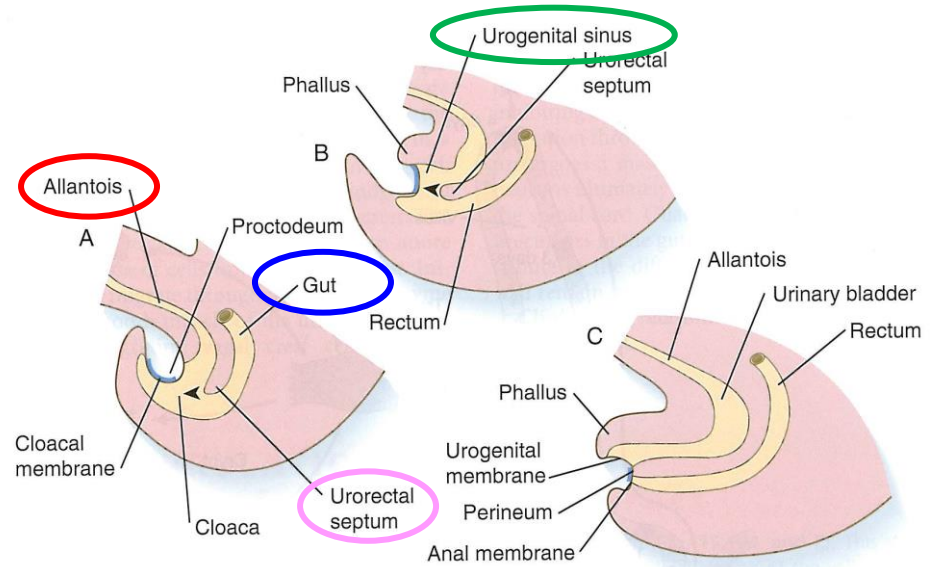


Urinary system - Bladder

Cloaca

=

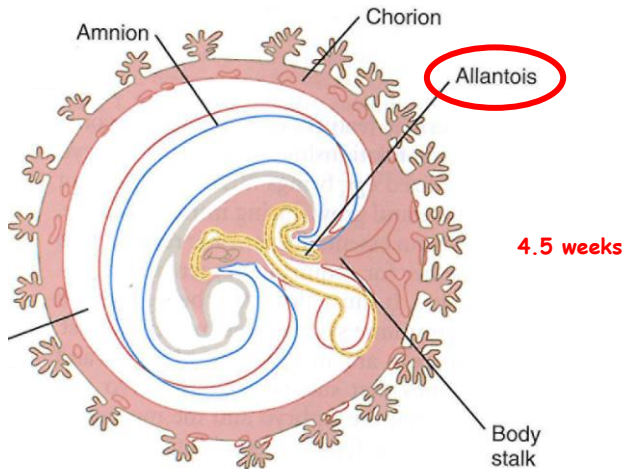
terminal part of the hindgut + allantois



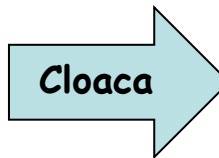
5 weeks

6 weeks

8 weeks



4.5 weeks

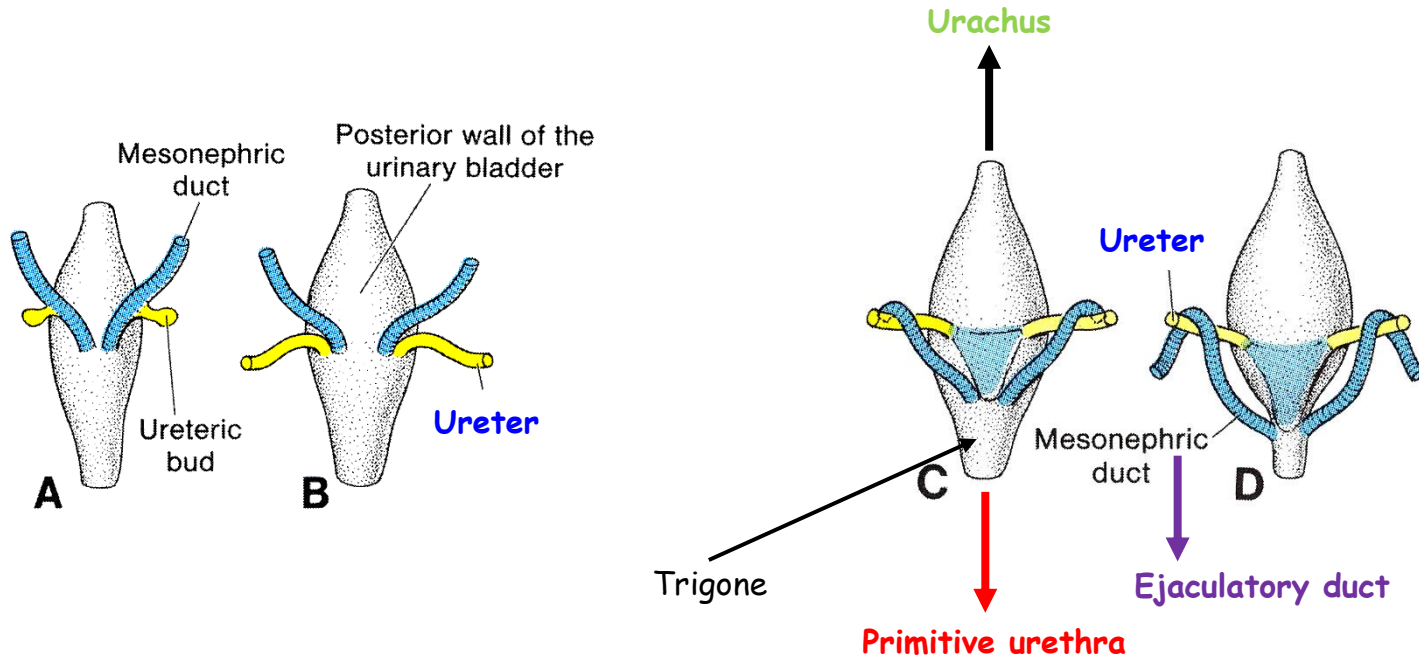


Urogenital sinus	Urogenital membrane
Urogenital septum	Perineum
Primitive rectum	Anal membrane

- ventral outpocketing of the hindgut
- sac-like structure (respiration)
- in umbilical cord
- proximal part - URACHUS - continuous with bladder
- URACHUS - transforme to Median umbilical ligament

Urinary system - Bladder + Ureters + Urethra

Posterior view

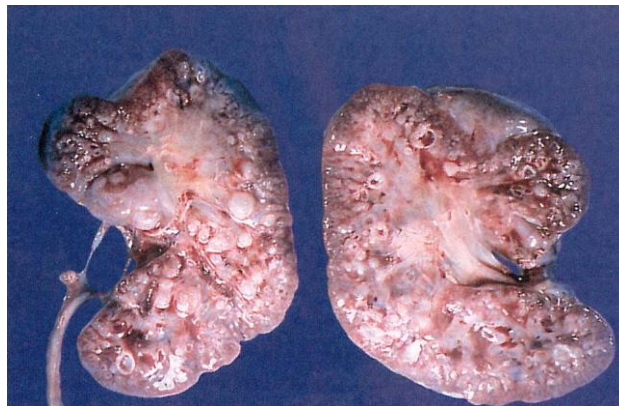
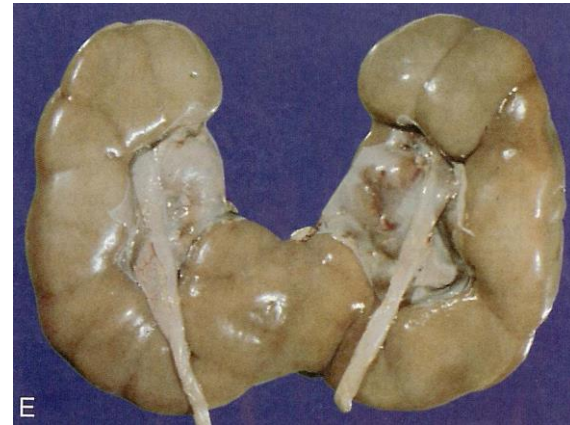
- alantoids expands - urinary bladder
- initially bladder is continuous with alantoids - then obliteration - **urachus** - **median umbilical ligament**
- caudal portions of mesonephric ducts become absorbed by the bladder wall - separation - **ureters** + **ejaculatory ducts**

Urinary system - Congenital anomalies

1. Agenesis
2. Duplication
3. Anomalies of shape
4. Abnormal of position
5. Congenital polycystic kidney

Horseshoe kidney



Thank you for your attention !

Questions and comments at:
ahampl@med.muni.cz