

Management of deep caries

Caries pulpae proxima

- Dental caries next to dental pulp
- Dentin between the lesion and the pulp (can be decalcified)

Caries pulpaе proxima

– Indirect pulp capping

Caries next to dental pulp (caries pulpaе proxima). Carious dentin is possible to remove almost completely. Decay is deep in small region. Appr 1 mm² carious dentin can be left.

Kalciumhydroxide cement, permanent filling

Alternativs: MTA, Biodentine

Formation of tertiary dentine.

Caries ad pulpam penetrans or large car pulpae proxima

Large caries pulpaе proxima or caries ad pulpam penetrans

– Intermittent excavation

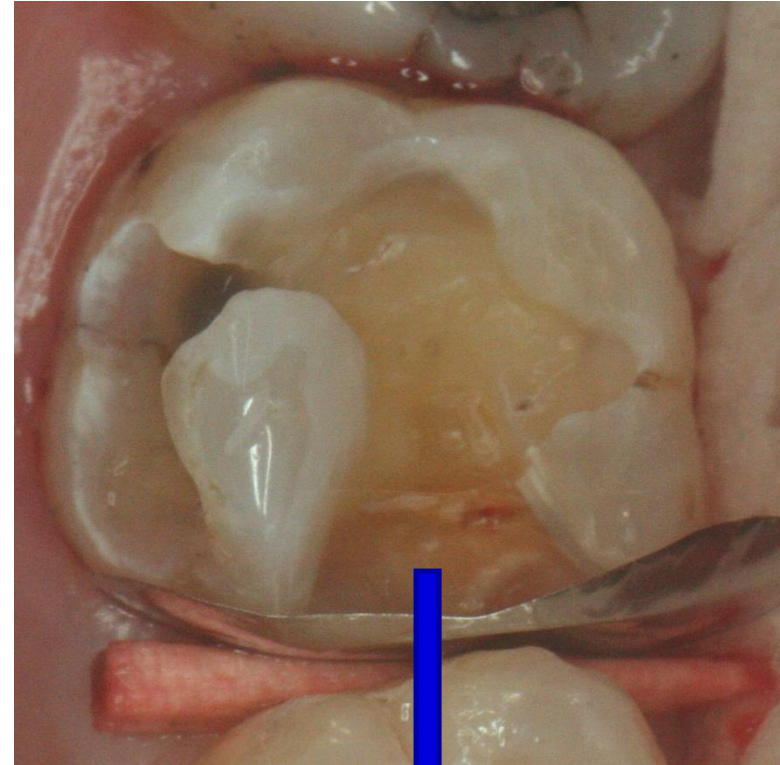
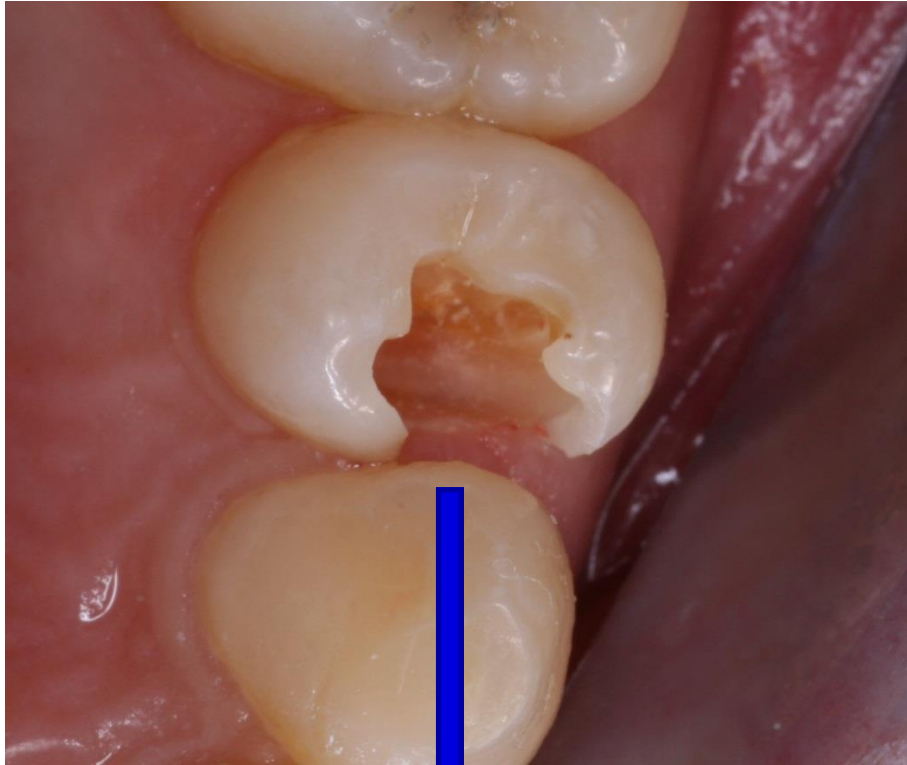
Large dental caries spreading towards dental pulp. Big amount of carious dentine.

High risk of perforation

Suspension of calcium hydroxide, temporary filling for 6 weeks.

Dessication of soft dentine, formation of tertiary dentine.

Permanent filling follows



Intermittent excavation
Pulpotomy



