

Cysts of jaws and oral soft tissues, including developmental cysts.

Markéta Hermanová

Definition of a cyst

- A pathological cavity, lined wholly or in part by epithelium, having fluid or semifluid contents
- Broader definition: a pathological cavity, having fluid or semifluid contents, which has not been created by the accumulation of pus

Classification of cysts of the jaws

■ Odontogenic cysts

- developmental
- inflammatory

■ Non-odontogenic cysts

■ Non-epithelialized primary bone cysts

■ Cysts of the soft tissues

Odontogenic cysts

■ Developmental

- Odontogenic keratocysts
- Dentigerous (follicular) cyst
- Eruption cyst
- Lateral periodontal cysts
- Gingival cyst
- Glandular odontogenic cyst

■ Inflammatory

- Radicular cyst
 - (a) apical
 - (b) lateral
 - (c) residual periapical
- Paradental cyst

Non-odontogenic cysts

- Nasopalatine duct (incisive canal) cyst
- Nasolabial (nasopalveolar) cyst
- Median cysts
- Palatal cyst of the newborn (Epstein pearls; Bohn's nodules)

Non-epithelialized primary bone cysts

- Solitary bone cyst (simple, traumatic, haemorrhagic bone cyst)
- Aneurysmal bone cyst
- Stafne's idiopathic bone cavity

Incidence of cyst of the jaws

Odontogenic cysts (90 %)		Non-odontogenic c.(10%)	
Radicular cysts	60-75 %	Nasopalatine cyst	5-10 %
Dentigerous cyst	10-15 %	Other non-odontogenic and primary bone cysts	<1 %
Keratocyst	5-10 %		
Paradental cyst	3-5 %		
Gingival cyst	<1 %		
Lateral periodontal c.	<1 %		

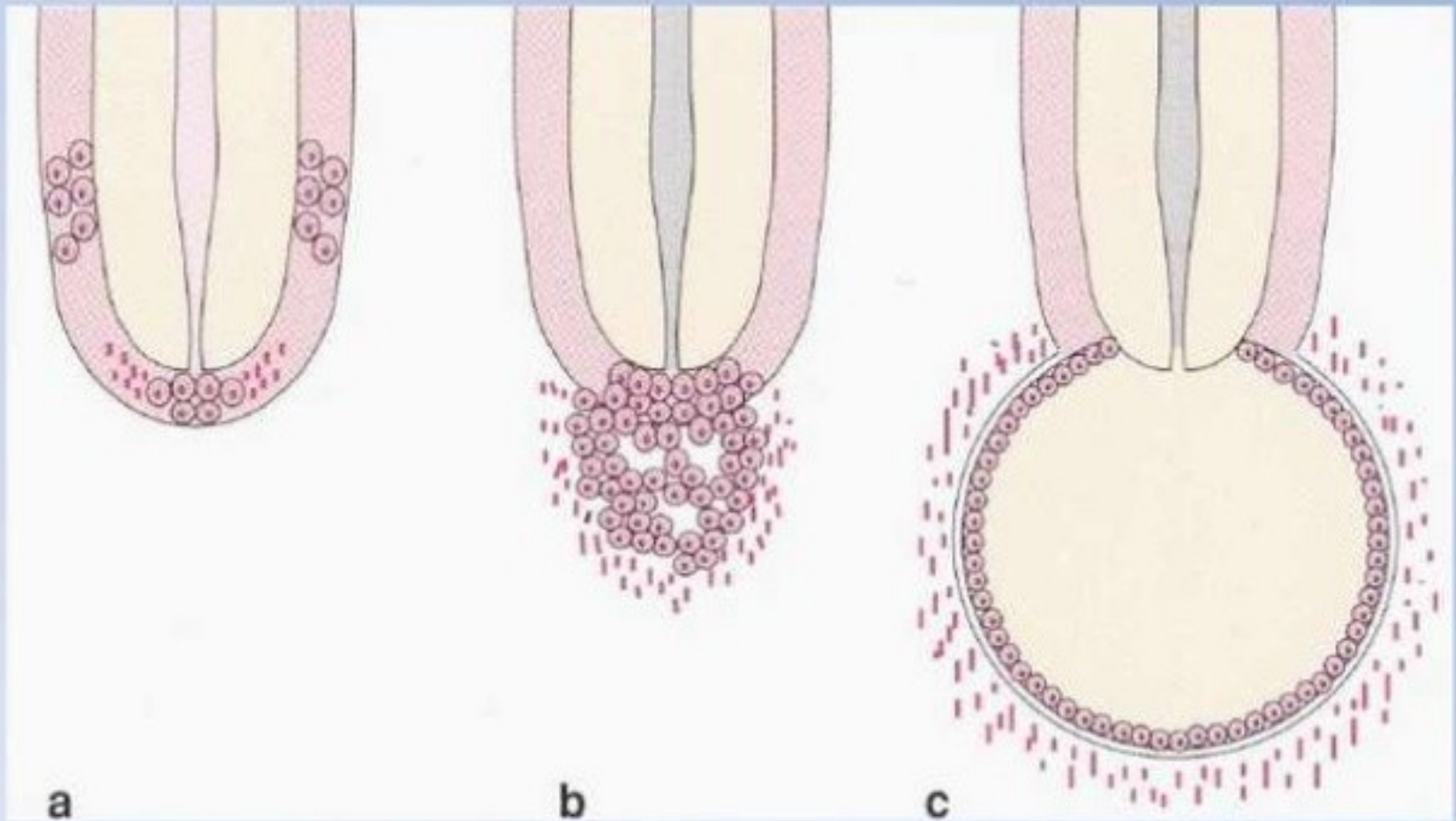
Origins of odontogenic cysts

- **Derived from epithelial residues of the tooth-forming organ**
- **The main cyst types derived from each residue are:**
 - **Dental lamina rests/gland of Serres**
 - (a) odontogenic keratocysts
 - (b) some lateral periodontal and gingival cysts
 - **Reduced enamel epithelium**
 - (a) dentigerous cysts
 - (b) paradental cysts
 - **Rests of Malassez**
 - (a) radicular cysts

Radicular cysts

- Apical, residual periapical, or lateral sub-types
- Apical most common
- Associated with non-vital tooth
- Apical radiolucency indistinguishable from a periapical granuloma
- May be symptomless
- Enlargement of cyst leads to bone resorption

Radicular cyst / pathogenesis

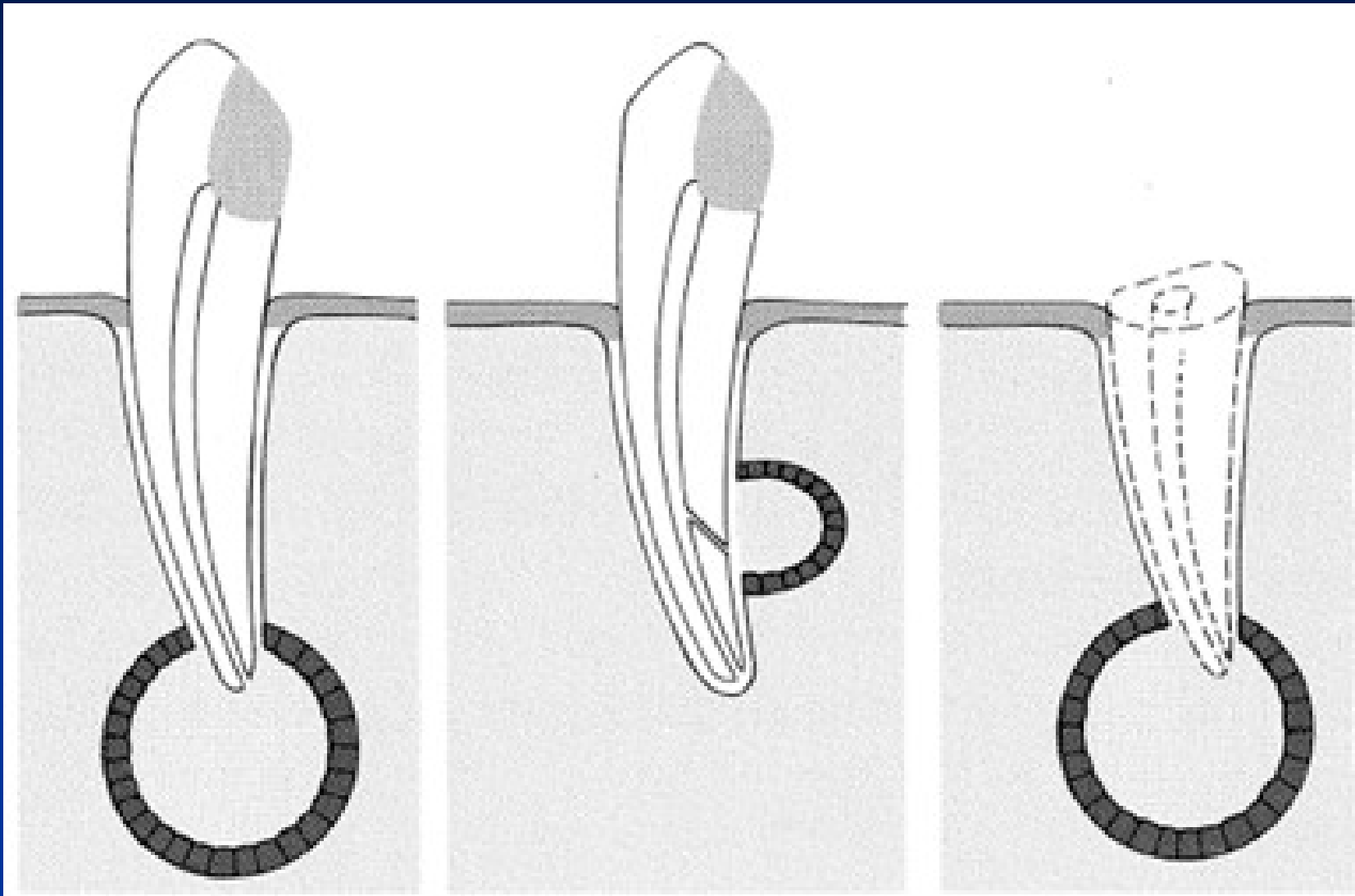


a Initiation

b Cyst formation

c Cyst enlargement

Radicular cyst

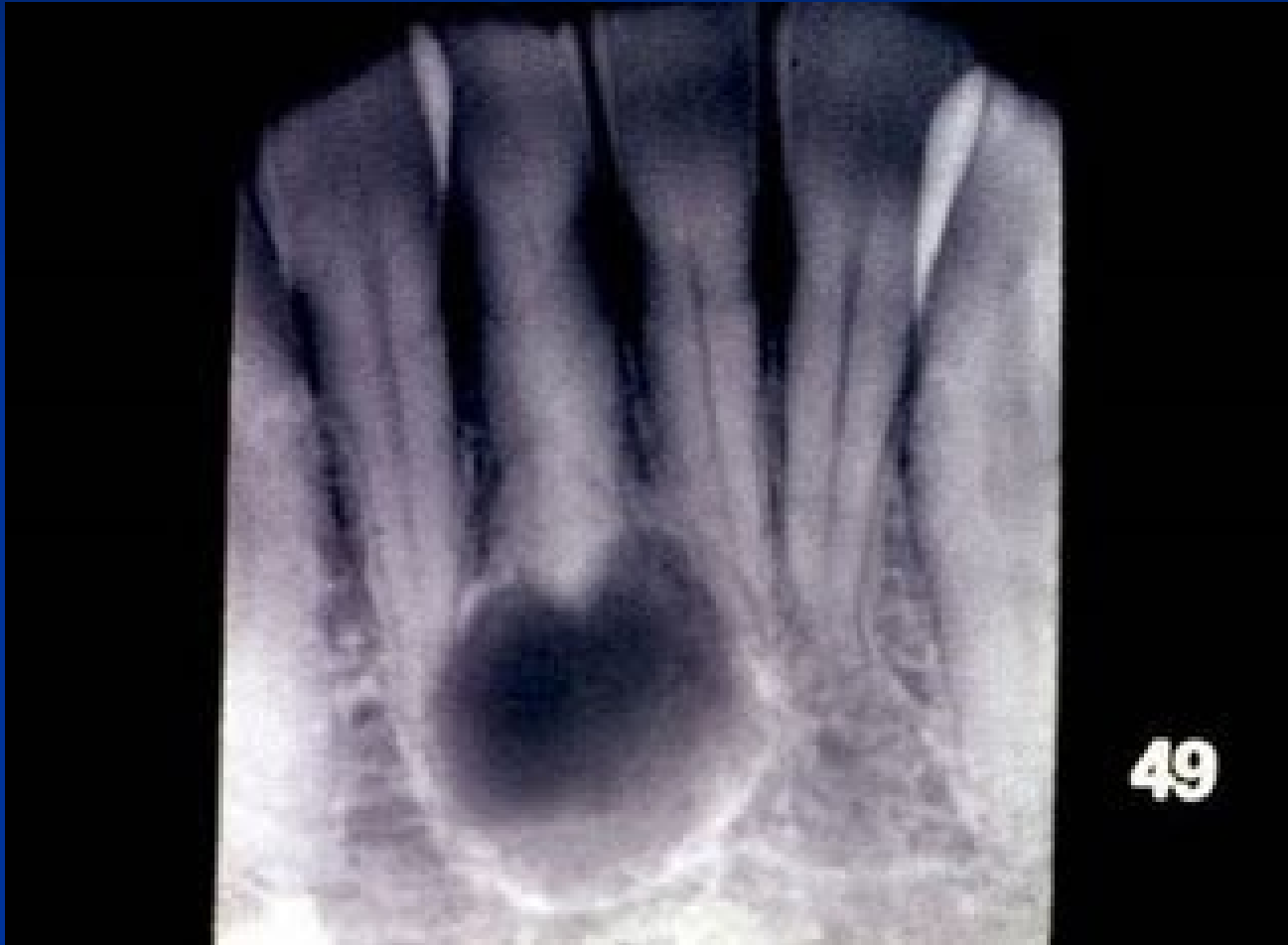

apikální

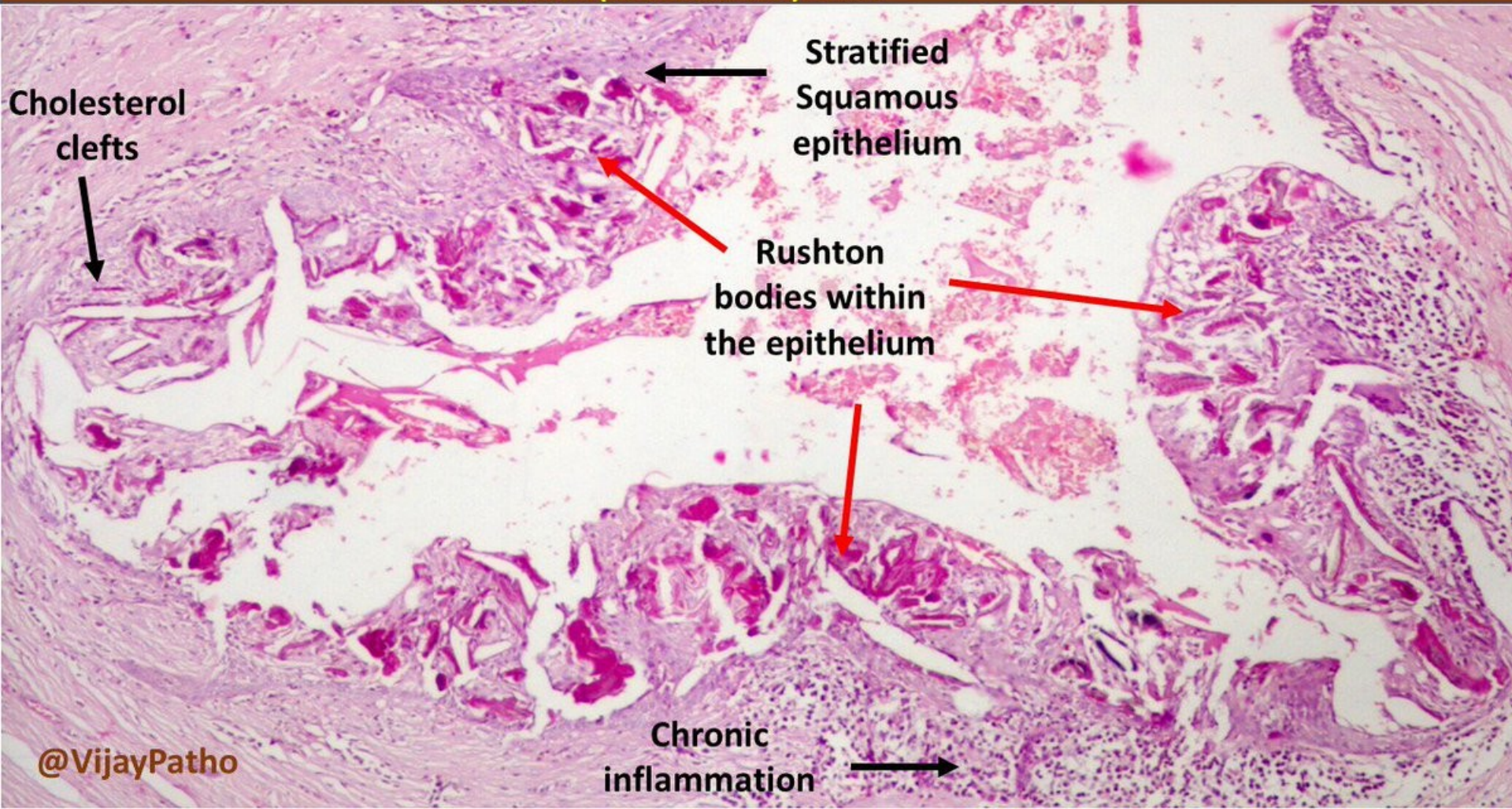
laterální

reziduální

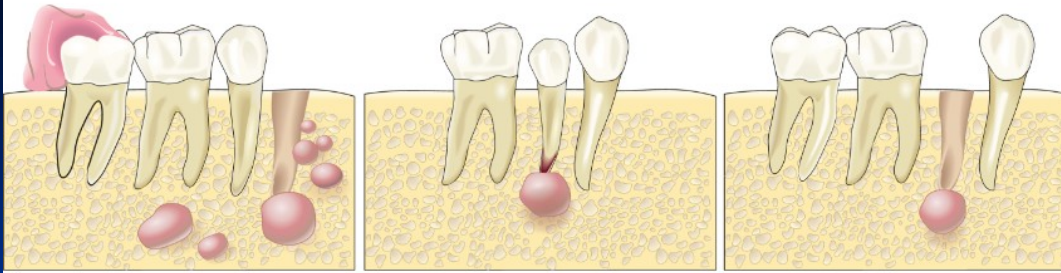
Radicular cyst



PERIAPICAL (RADICULAR) CYST



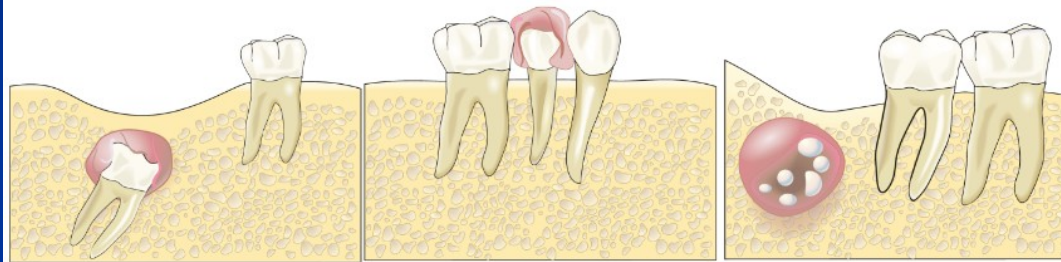Odontogenic Cysts



Odontogenic Keratocyst

Radicular Cyst

Residual Cyst

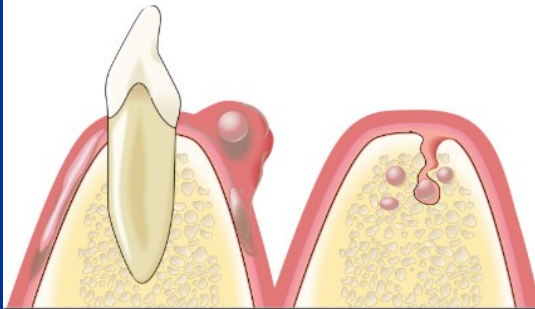


Dentigerous Cyst

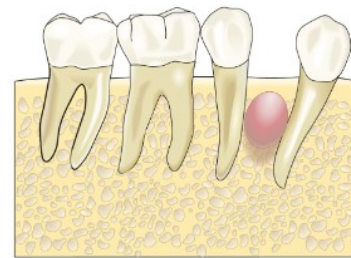Eruption Cyst

Calcifying Odontogenic Cyst

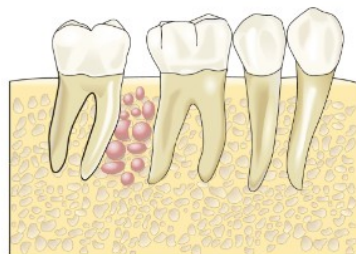
=Calcifying odontogenic tumour



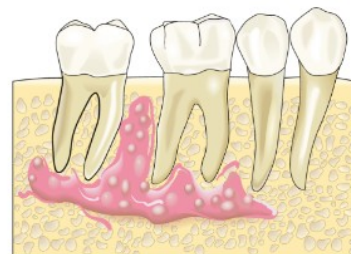"Adult" Gingival Cyst



Lateral Periodontal Cyst



Botryoid Odontogenic Cyst



Sialodontogenic Cyst

Radicular cyst-histology

- Arise from proliferation of the rests of Malassez within chronic periapical granulomas
- Lined by non-keratinizing squamous epithelium
- Supported by a chronically inflammed capsule
- Capsule may contain collections of cholesterols
- Hypertonic content: breakdown products, serum proteins, water and electrolytes, cholesterol crystals

Expansion of radicular cyst

- Hydrostatic pressure of the cyst fluid increased due to hypertonic content
- Water drawn into the cyst cavity along this osmotic gradient
- Cyst expansion
- Bone resorption

Dentigerous (follicular) and eruption cyst

- Most frequently involve impacted/late-erupting teeth
- Develop between reduced enamel epithelium and crown
- Surround part or all of the involved crown
- Cysts attached to amelocemental junction
- Lined by thin, non-keratinizing squamous epithelium; often shows mucous cell metaplasia
- Non-inflamed capsule; may contain odontogenic epithelial rests
- Eruption cyst = extraalveolar dentigerous cyst

Odontogenic keratocysts

- Bimodal age distribution – 2nd-3rd decades and 5th decade
- Few symptoms; cause little expansion; may reach large size
- Unilocular/multilocular radiolucency; may mimic dentigerous cyst
- More common in mandibula than in maxilla
- Tendency to recur
- May be multiple; associated with nevoid basal cell carcinoma syndrome

Naevoid basal cell carcinoma syndrome (Gorlin syndrome)

- AD
- Multiple naevoid BCC + multiple odontogenic keratocysts + skeletal abnormalities (rib abnormalities, vertebral deformities, polydactyly, cleft lip/palate) + calcified falx cerebri + brain tumours
- Mutation in tumor suppressor gene PTCH (9q)
- Mutations of PTCH affect the normal function of *Hedgehog* signalling pathway
- *Hedgehog* signalling pathway controls transcription of the genes involved in the development, patterning, and growth of numerous tissues and organs

Odontogenic keratocysts

- **Thin, easily torn wall**
- **Lined by an even layer of parakeratinized squamous epithelium**
- **Palisaded basal cell layer**
- **Satellite cysts in capsule**
- **Tendency to recur due to difficulty of surgical removal**
 - thin, easily ruptured wall
 - Projection into cancellous spaces easily torn
 - Satellite cysts in capsule
- **Cyst enlargement involves**
 - Focal areas of active growth of the cyst wall
 - Extension of proliferating areas along cancellous spaces
 - Production of bone resorbing factors

■ **Gingival cyst**

- in neonates, arise from remnants of the dental lamina, disappear spontaneously

■ **Developmental lateral periodontal cyst**

- Canine and premolar region of the mandibula, vital teeth
- Non-keratinizing or cuboidal

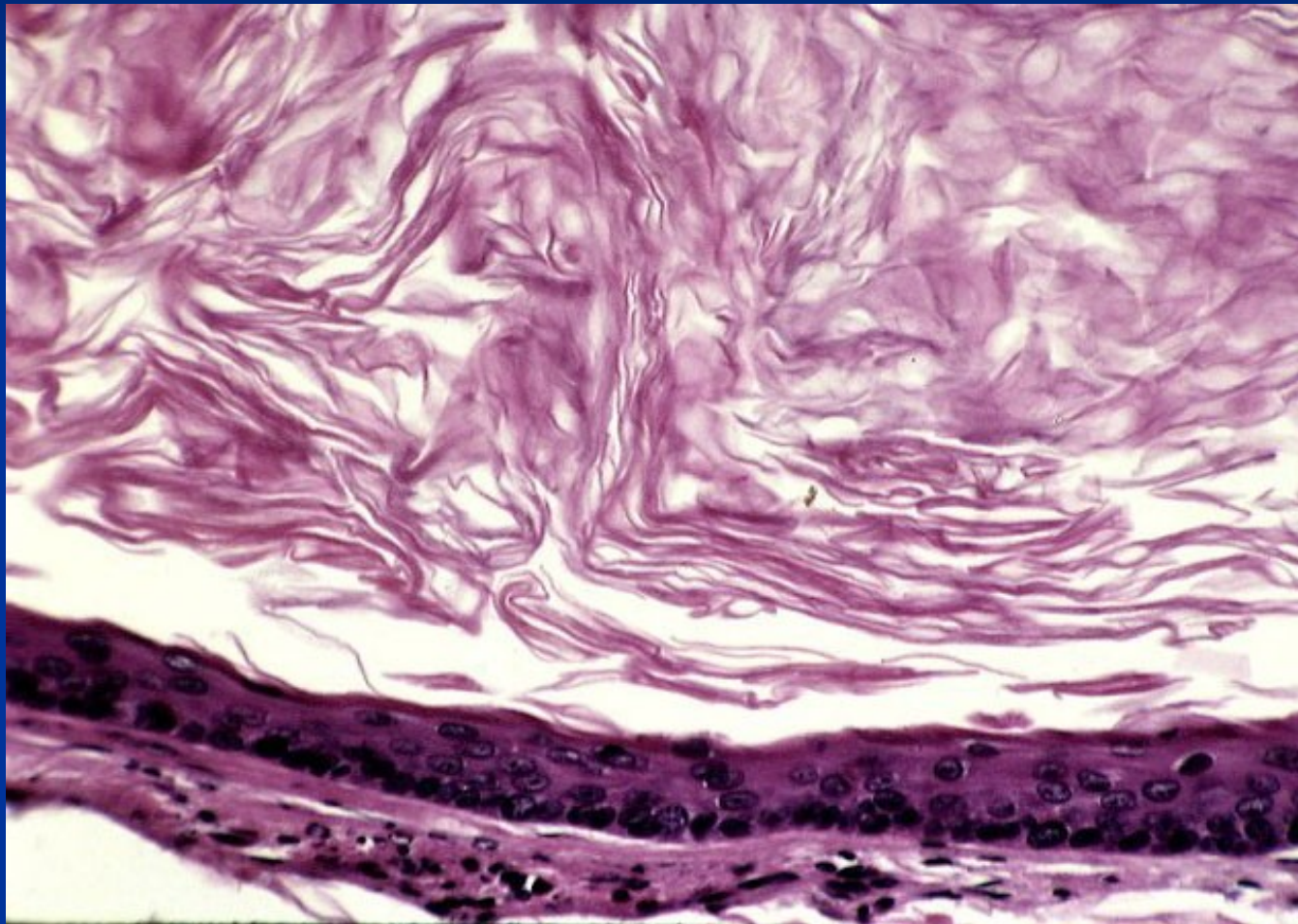
■ **Glandular odontogenic cyst**

- Anterior part of mandibula, potentially aggressive
- Lining by cuboidal, columnar and mucous cells

■ **Paradental cyst**

- Alongside partly eruptive 3rd molar involved by pericoronitits
- Histologically resemble radicular cysts-inflammatory

Odontogenic keratocyst



Non-odontogenic cysts

■ **Nasopalatine duct (incisive canal) cyst**

- Commonest of the non-odontogenic cysts
- Derived from nasopalatine duct residues; midline anterior palate
- Lining: stratified squamous epithelium, pseudostratified ciliated columnar epithelium, mucous cells, columnar or cuboidal epithelium

■ **Nasolabial cyst**

- In soft tissue of the upper lip; also bilateral
- Lining: pseudostratified columnar epithelium, stratified squamous epithelium, mucous cell, ciliated cells
- Derived from remnants of the lower part of the embryonic nasolacrimal duct

■ **Palatal cyst of the newborn (Epstein pearls; Bohn's nodules)**

- 1-3 mm papules, midline near the junction of soft and hard palate
- Keratin filled, lined by stratified squamous epithelium

■ **Median cyst**

- Palate, mandibula
- Displaced nasopalatine duct cyst???
- In mandibula odontogenic???

Non-epithelialized primary bone cysts

■ Solitary bone cyst

- Mainly molar region mandible; second decade
- Empty cavity, no epithelial lining; loose fibrous tissue covering the bone
- Pathogenesis: haemodynamic disturbance in medullary bone (trauma, haemorrhage)

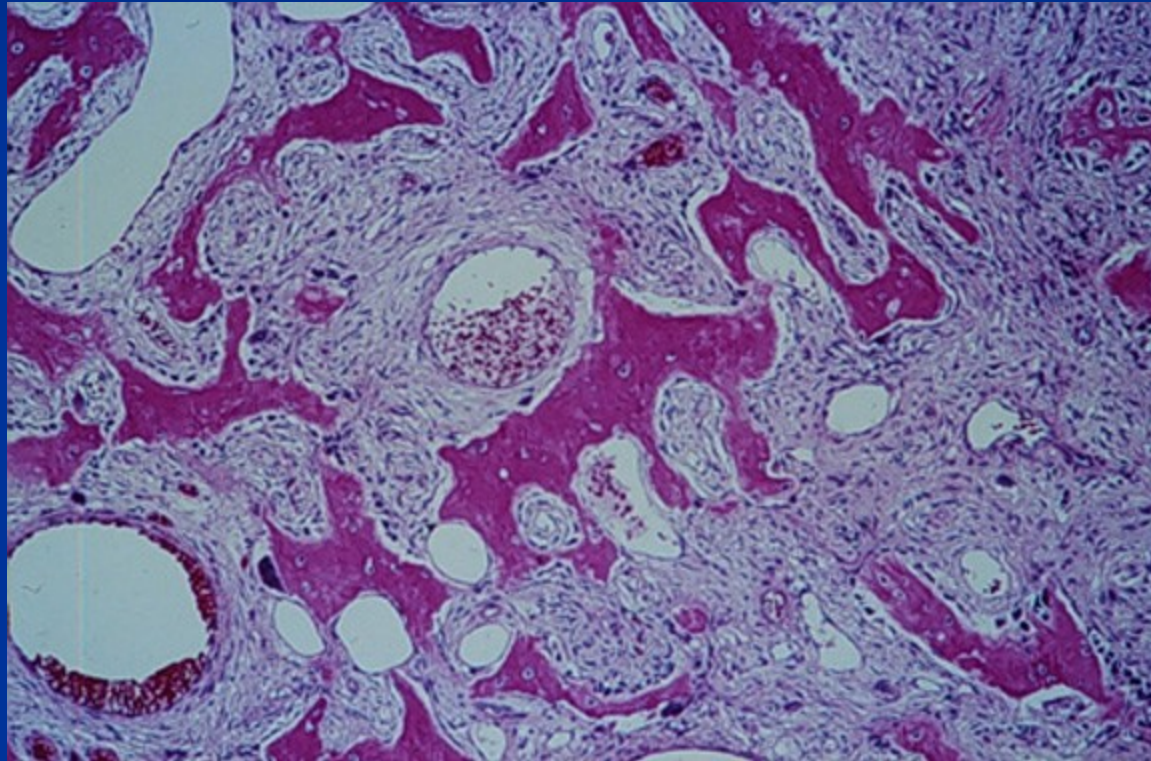
■ Aneurysmal bone cyst

- Primary or secondary; uni- or multilocular
- Blood filled spaces separated by cellular fibrous tissue
- Pathogenesis: haemodynamic disturbance in medullary bone

■ Stafne's idiopathic bone cavity

- Developmental anomaly of the mandible
- Usually contains ectopic salivary tissue in continuity to submandibular salivary gland

Aneurysmal bone cyst



Cysts of the soft tissues

■ Salivary mucoceles

- Mucous extravasation cyst

(lower lip, cheek, floor of the mouth; mucin-filled cystic cavity lined by inflamed granulation tissue, mucophages; **ranula** – clinical term, swelling of the floor of the mouth; usually mucous extravasation cyst)

- Mucous retention cyst

(no in lower lip; cystic dilatation of the duct)

■ Dermoid and epidermoid cysts

- Dermoid cysts: Developmental lesions; lined by orthokeratinized stratified squamous epithelium, with skin appendages in the wall

- Epidermoid cysts: usually acquired, traumatic implantation of epithelium, cystic change and expansion

■ Lymphoepithelial cyst

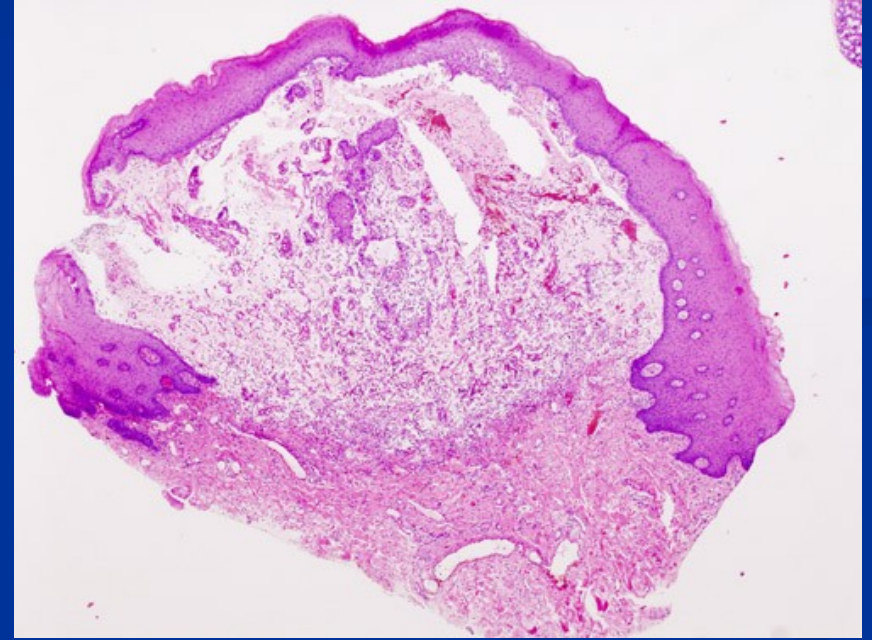
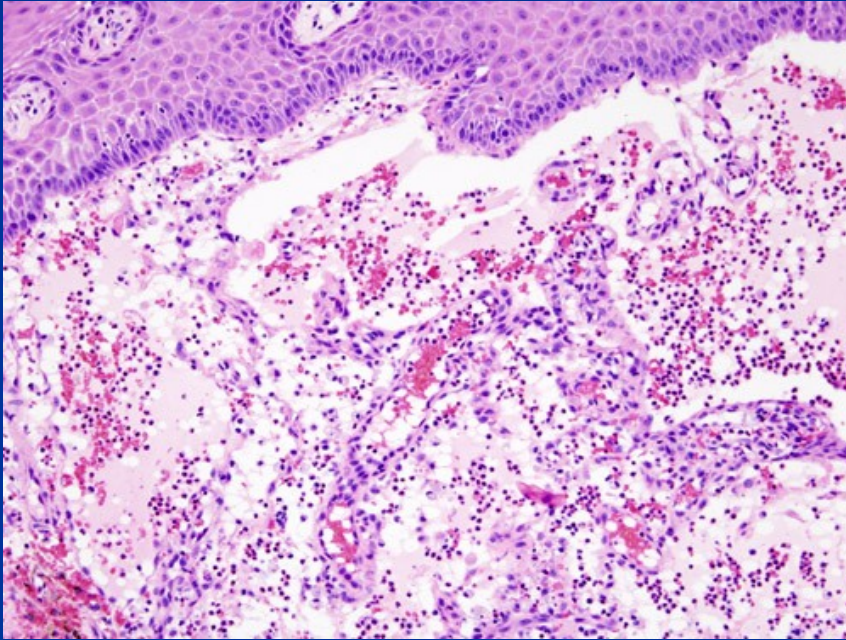
- Also classified as branchial cyst

- Lined by stratified squamous epithelium with well-organized lymphoid tissue in the wall

■ Thyroglossal cyst

- developmental, from the embryonic thyroglossal duct, localised in the midline of the tongue

Mucocele



Thyreoglossal cyst

