

Nose and paranasal sinuses II.

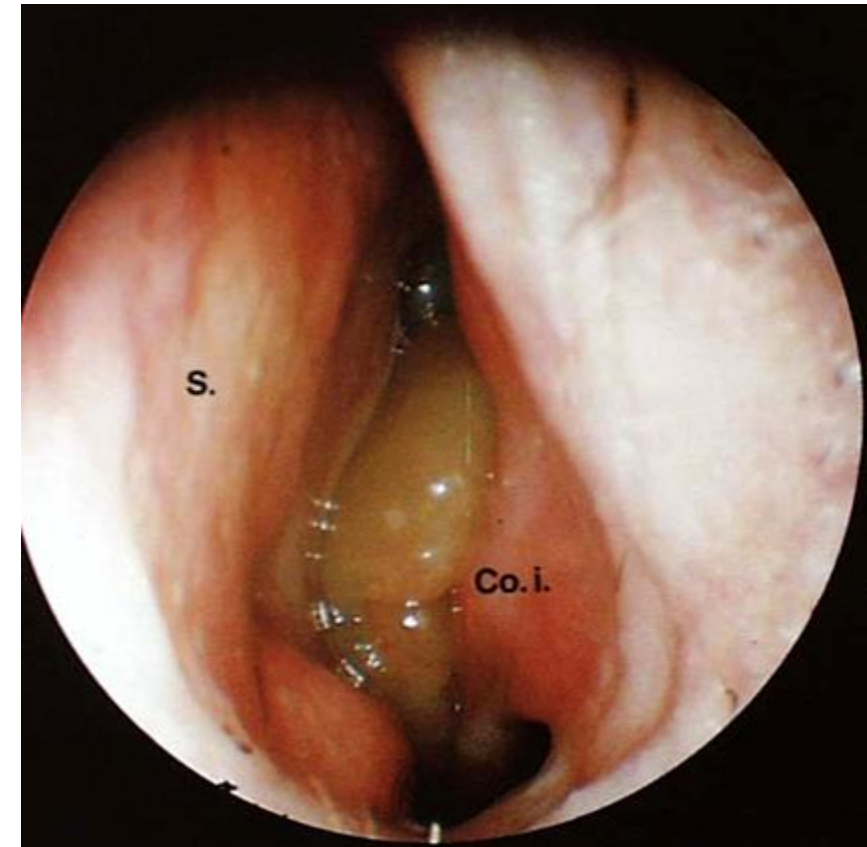


Ass.prof. Pavel Smilek, MD, Ph.D.

**ENT Clinic of Masaryk university, Brno
Faculty St. Ann Hospital**

Head: Ass.prof. Gál Břetislav, MD, Ph.D.

Pekařská 53, Brno , 656 91





Olfactory organ – applied physiology

- **Gustatory olfaction** – sensory impressions caused by food (aroma, bouquet) search and food intake. Perception of impulses from external environment are mediated with **smell, trigeminal nerve and taste - chemosenzoric perception**
- Protective function – warning against poisonous foods and toxic substance
- Social communication (psychology, occupation...)
- Symptom of some psychiatric disorders

Applied anatomy of olfactory sense



peripheral and central part

1) peripheral part: *olfactory mucosa (regio olfactoria)*

fila olfactoria

localised: c. nasi superior, cranial part of c. nasi media and septum

olfactory mucosa: smell, supporting and basal cells

fila olfactoria: fibres of the olfactory nerv connected with axons of olfactory cells, go through lamina cribriformis into bulbus olfactorius

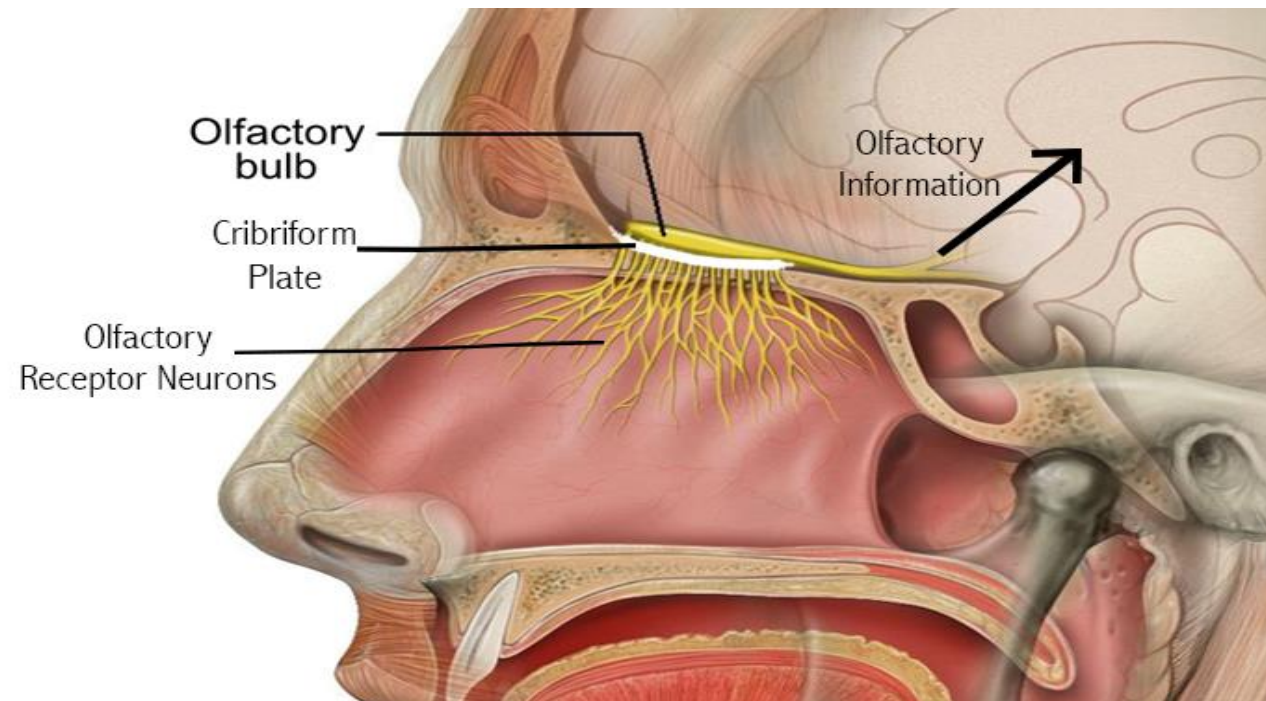
Applied anatomy of olfactory sense

2) central part:

bulbus olfaktorius - connection and smell stimulus processing ***olfactory cortex*** -

primary olfactory cortex (piriformní kortex, amygdala)

- ***secondary olfactory cortex*** (parahippocampus and limbic systém)

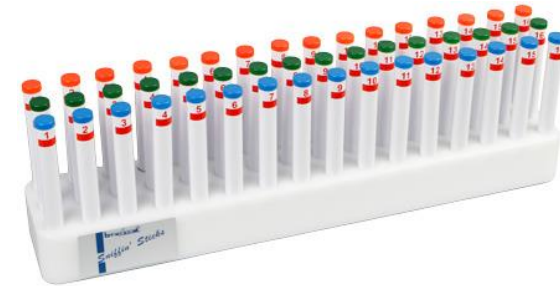



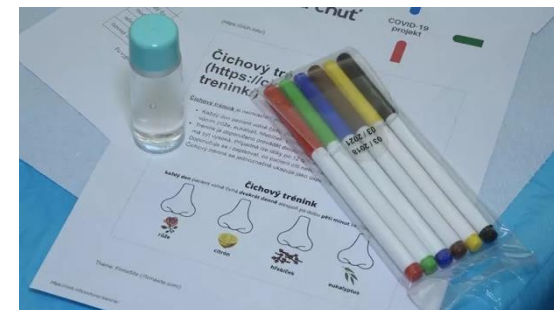
Diagnosis of olfactory disorder

- **History of disease** injuries, surgery of nose and paranasal sinuses, surgery of brain, inflammations, toxic influences, medication, neurodegenerativ, psychiatric and metabolic disorder.
- **ENT investigatios** rhinoscopy, rhinoendoscopy
- **Subjective methods of evaluation of smell**
- **Objective methods of evaluation of smell** - EEG with olfactory evoked potentials, elektroolfactogram and functional magnetic resonance (research)
- **Imagination evaluations** CT, MR

- **Sniffin' stick test** – threshold (the lowest concentration) and supra-threshold tests (discrimination of odours)



- ***test of odoured marker (pen)s*** - screening supra-threshold evaluation
 - 1.part – name the odour (points)
 - 2.part – identification of odour





Olfactory disorder

Quantitative disorders: partial loss of smell – *hyposmia* to *anosmia*

Qualitative disorders : change of perception of disorder

- *parosmia* – distorted perception of odour
- *specific anosmia* – inability of perception of some odours
- *fantosmia* - perception of some odours even in their absence
- *kakosmia* – *unpleasant* perception of odours (*graviditas, mb. Parkinson*)



Olfactory disorder

Time viewpoint: *acute, chronic a fluctuate*

Etiopathogenetic viewpoint: **conductive – peripheral** odour cannot influence olfactory epithelium, **sensorineural - central** disorder of olfactory perception

- **conductive disorder** – one-, or both sided

1. *mechanical obstruction of nasal cavity* (septal deviation, rhinitis, nasal polyposis, tumors of nose and paranasal sinuses)

2. *pathologic changes outside nasal cavity* (choanal atresia, adenoids , tumors of epipharynx, pts after total laryngectomy)

- **sensorineural disorders**

1. disorders in **olfactory epithelium** (viral damage, inhalation of toxic odours, rhinitis atrophica, A avitaminosis)

2. disorders in central parts – **in olfactory pathway, olfactory cortex** (congenital diseases, injury, diabetes mellitus, tumors etc.)



Olfactory disorder

Congenital diseases	congenital	Choanal atresia Cystic fibrosis Primary ciliary dyskinesia ASA syndrome Meningocele, meningoencephalocele
	other	Septal deformities
Inflammatory diseases	Infectious	Viral Bacterial Mycotic
	Non-infectious	Allergy Non-allergic – nasal polyposis, medicamentous rhinitis
Tumors	Benign	Papilloma, inverted papilloma Juvenil angiofibroma, hamartoma
	Malignant	Epithelial – spinocellular cancer, adeno-cancer, melanoma
		Mezenchymal – plazmocyoma, chondroma, chondrosacoma Neuroectodermal – olfactory neuroblastoma
Injuries	Injuries of face skeleton	Injuries of middle etage Injuries of superior etage
		Injuries of base of the skull



conductive disorder

- ***Conservative treatment:*** corticosteroids systemically and locally, olfactory training and improving nasal ventilation
- ***Surgery:*** chronic rhinosinusitis with nasal polyposis not reacting on conservative treatment– FESS, removal of nasal obstruction in tumors and anatomical deformities

sensorineural disorders cannot be treated, diagnosis could reveal life threatening diseases which could be treated



Epistaxis (symptom!)

Local causes

- vascular, microtrauma of plexus Kiesselbachi
- rhinitis ant. Sicca
- environmental influences
- trauma of the nose
- foreign bodies
- bleeding septal polyp (granuloma teleangiectatica or hemangioma)
- tumors of the nose
- tumors of epipharynx and paranasal sinuses § !!!
- idiopathic epistaxis - mild, recurrent epistaxis in young adult

General causes

- Hypertension
- infection (flu, measles, typhus et al.)
- diseases of blood and hemocoagulation
- kidney/hepatic failure
- endocrine causes (pheochromocytoma, menstruation)
- hereditary hemorrhagic telangiectasia (morbus Rendu-Osler)

Blood supply

Upper third nasal cavity blood supply from **a. carotis interna** - *a. ophthalmica* - *a. ethmoidalis anterior a posterior*.

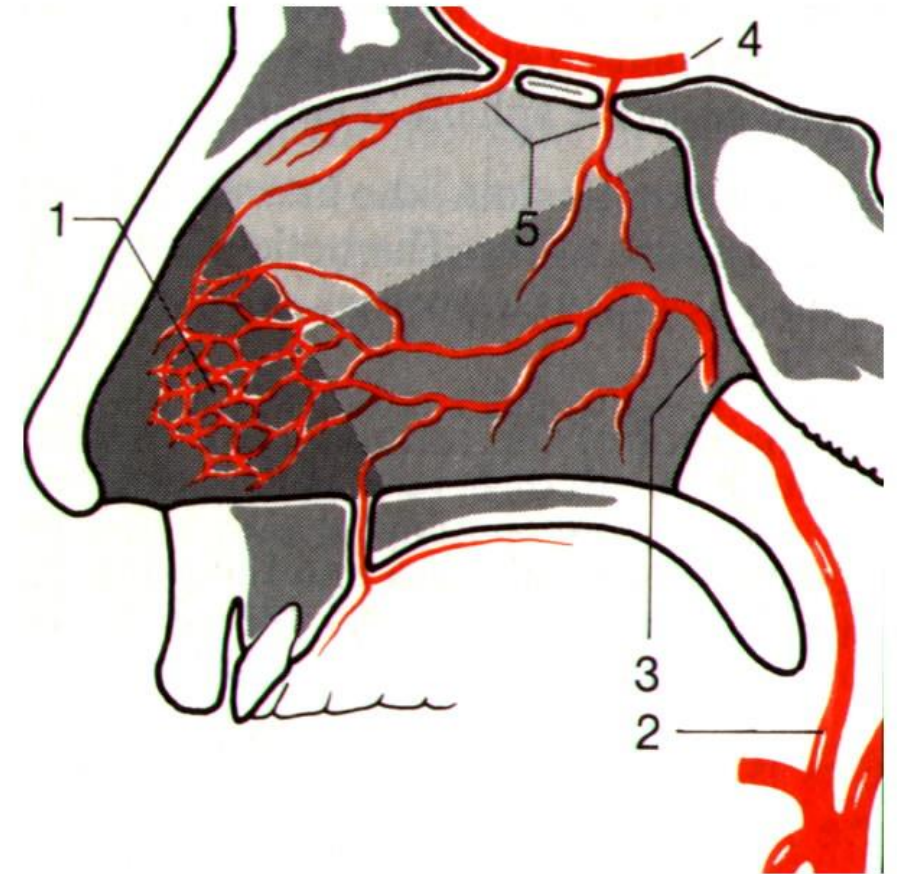
Posterior and inferior nasal cavity **a. carotis externa** via *a. maxillaris* and *a. sphenopalatina* - *a.a. nasales posteriores lat. et septi*.

A. carotis externa - *a. maxillaris* - *a. palatina descendens* - *a. palatina maior* - *a. nasopalatina*.

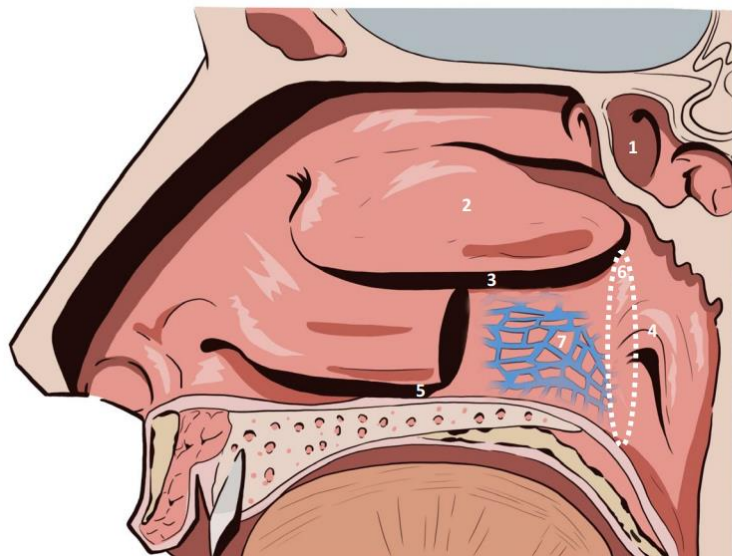
Locus Kiesselbachi (plexus)

Nasopharyngeal Woodruff's plexus (plexus a. sphenopalatina)

- 1-Locus Kiesselbachi
- 2-a.maxillaris
- 3-a.sphenopalatina
- 4-a.opthalmica
- 5-a.ethmoidalis ant. et post.



Woodruf's plexus („posterior epistaxis“)

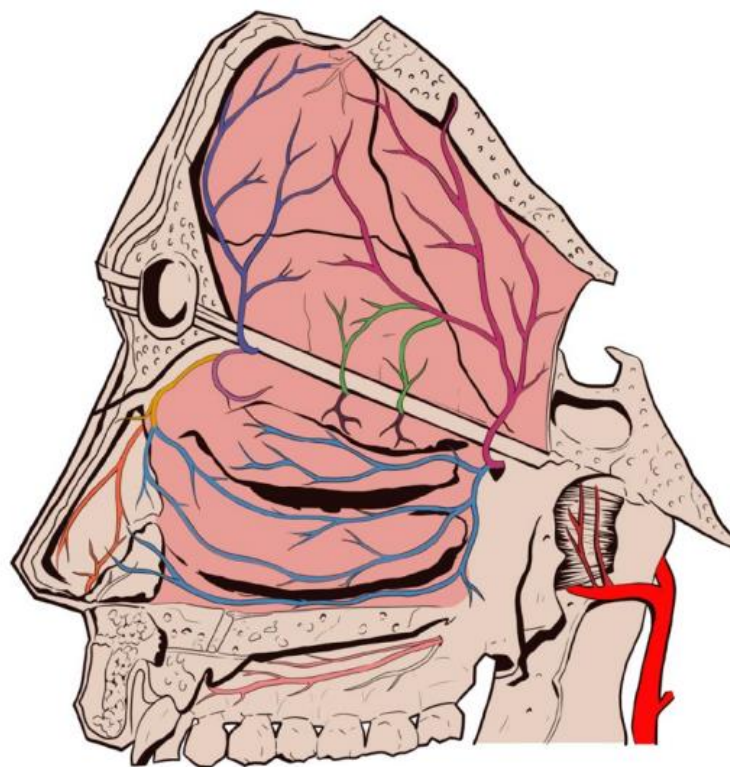


- 1 = Sphenoid air sinus
- 2 = Middle concha
- 3 = Middle meatus
- 4 = Torus tubarius
- 5 = Inferior meatus
- 6 = Choana
- 7 = Woodruff's plexus

Woodruf's plexus is a vascular network located on the posterior lateral wall of the inferior meatus of the nasal cavity and it is responsible for **posterior epistaxis**.

Vascular supply of the nasal cavity. Arteries described as contributors to Woodruf's plexus exemplified on the grid on the side of the figure, mainly **sphenopalatine artery**.

Woodruf's plexus – venous vascular network as described by anatomical dissection studies



- Posterior septal branch of the sphenopalatine artery
- Septal branches of the posterior ethmoidal artery
- Lateral branches of the posterior ethmoidal artery
- Septal branch of the anterior ethmoidal artery
- Lateral branch of the anterior ethmoidal artery
- Posterior lateral nasal branches of the sphenopalatine artery
- External nasal branch of anterior ethmoidal artery
- Anterior lateral nasal branch of anterior ethmoidal artery
- Greater palatine artery
- External carotid artery - maxillary artery



Epistaxis – first diagnostic steps

- take accurate history of disease
- try to find the origin of bleeding
- examine blood pressure
- evaluate hemo-coagulation

Another possibilities:

- X-ray examination
- general internal examination

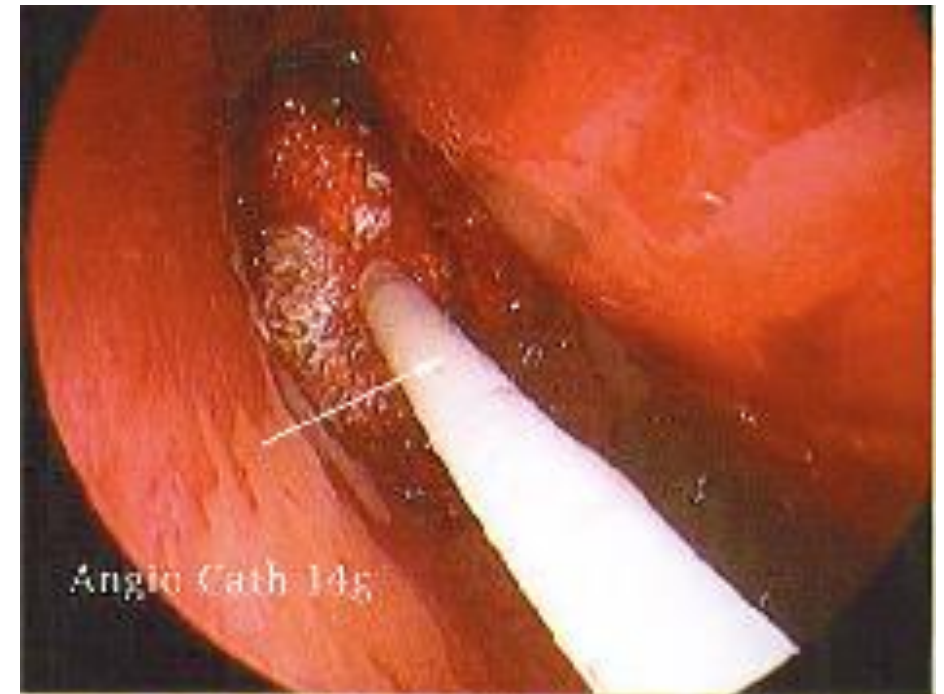

Epistaxis – local treatment

- preserve a calm atmosphere
- the patient should sit with the upper part of the body tilted forward
- cold compresses to the nape of the neck and dorsum of the nose
- mild pressure is applied to both nasal alae for several minutes
- cautery: chromic acid, electrocautery, laser
- **nasal packing**
- **Vascular ligation** maxillary artery in the pterygopalatine fossa, the anterior and posterior ethmoidal arteries
- Selective arterial **embolisation**

Absorbable materials for nasal packing/tamponade

- Gelatin (Gelaspon, Gelfoam)
- Gelatin with thrombin (FloSeal)
- Hyaluronic acid (Merogel)
- Carboxymethylcellulose (Sinu-knit)
- Polyurethane (Nasopore)
- Fibrin glue (Evicel)

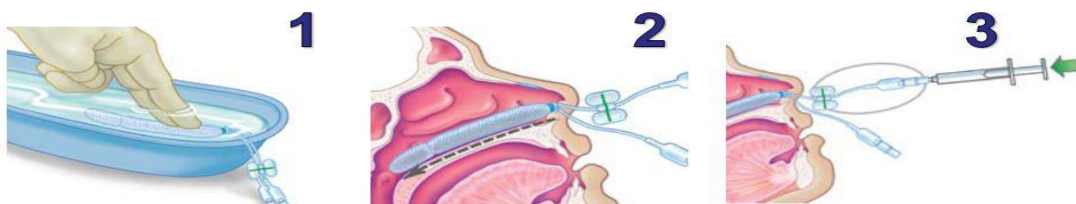



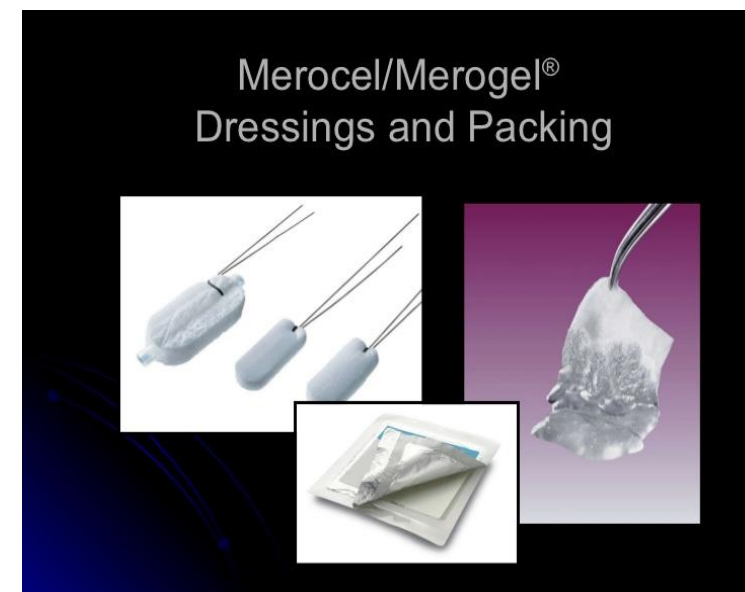Non-absorbable materials for nasal tamponade

- Gauze with Vaseline
- Balloon tamponades
- Polyvinyl alcohol (PVA) - Merocel, Rhinocell)Viscose and cellulose (Rapid Rhino)
- Pork belly (Ian Humprey - October 2014 -Nobel Prize; 4 year old girl with Glanzman's thrombasthenia)

Rapid Rhino® 900 for Posterior Epistaxis



1. Thoroughly soak in sterile water for 30 seconds.
2. Insert Rapid Rhino into the patient's nostril parallel to the septal floor, or following along the superior aspect of the hard palate, until the blue indicator ring is inside the opening of the nostril.
3. Using a 20 cc syringe, slowly inflate the posterior (**green stripe**) balloon **first** with air only inside the patient's nose.

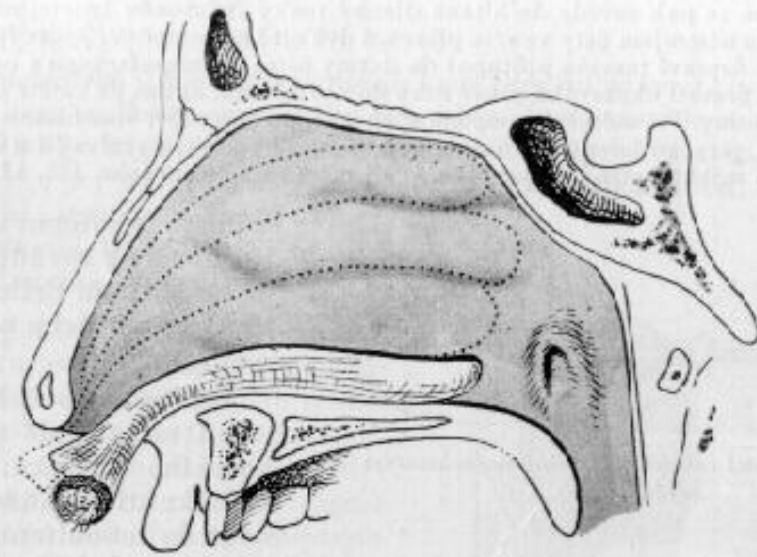


Anterior nasal packing

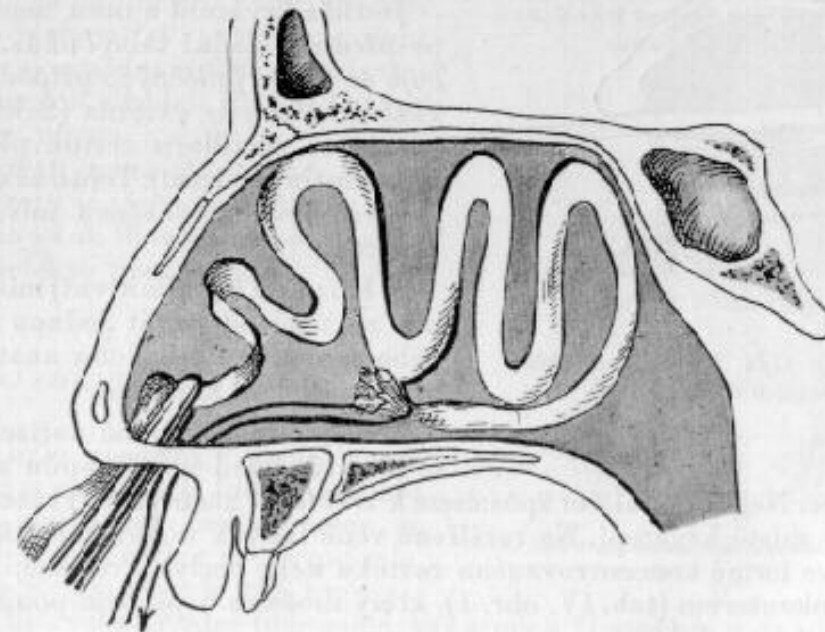
topical anesthesia, strips of ointment-saturated gauze are introduced in layers from above downward into the nasal cavity.

floor (etage)

continuing



Vrstvená (etážová) tamponáda nosní dutiny



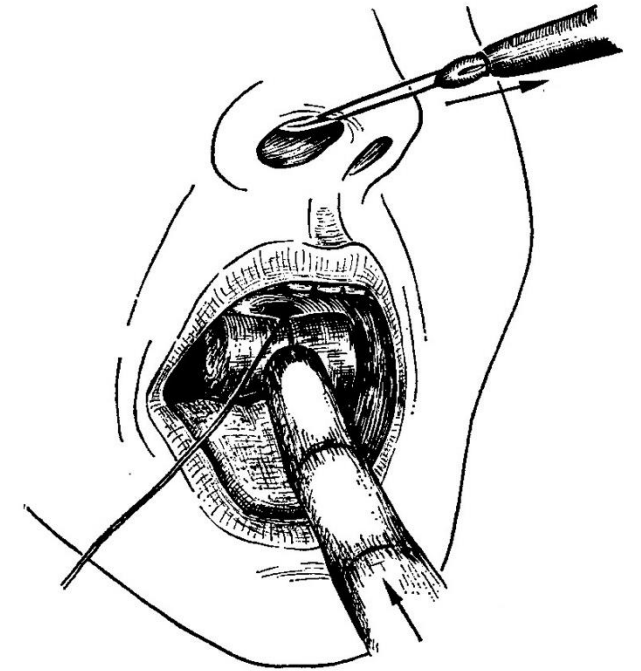
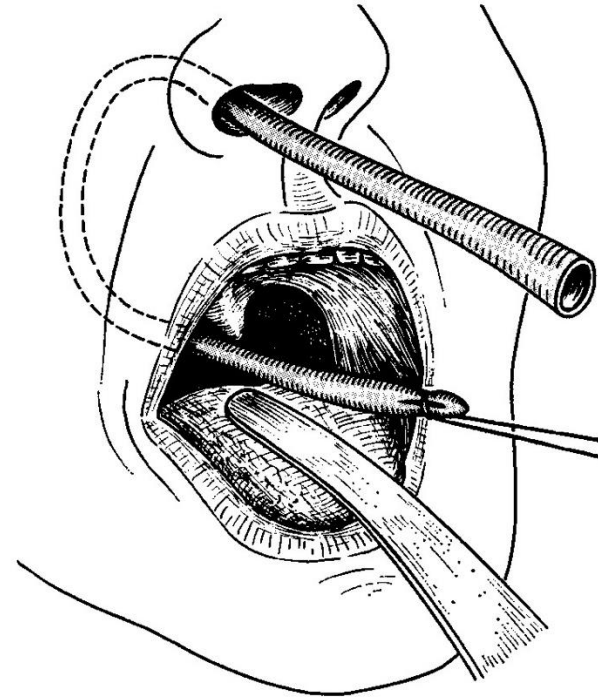
Tamponáda nosní dutiny dlouhým mulem

Pneumatic nasal packing

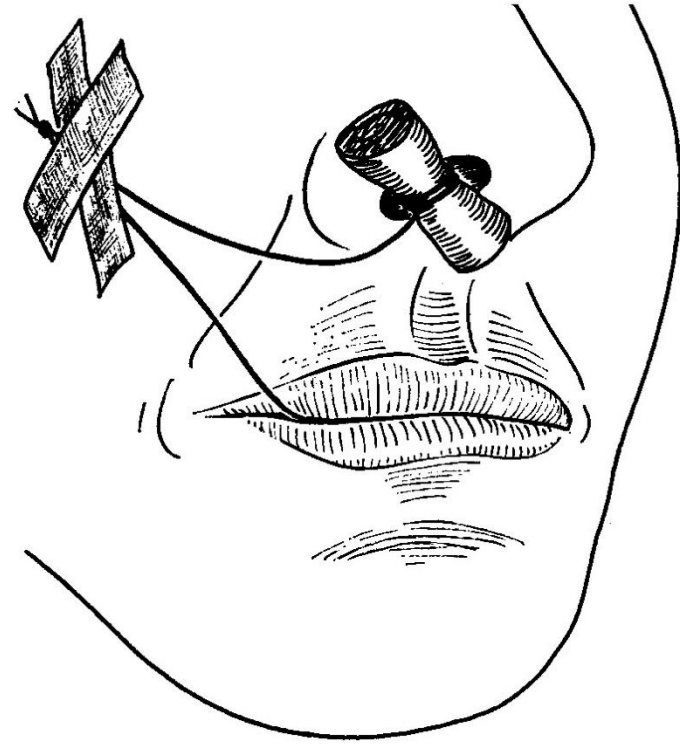
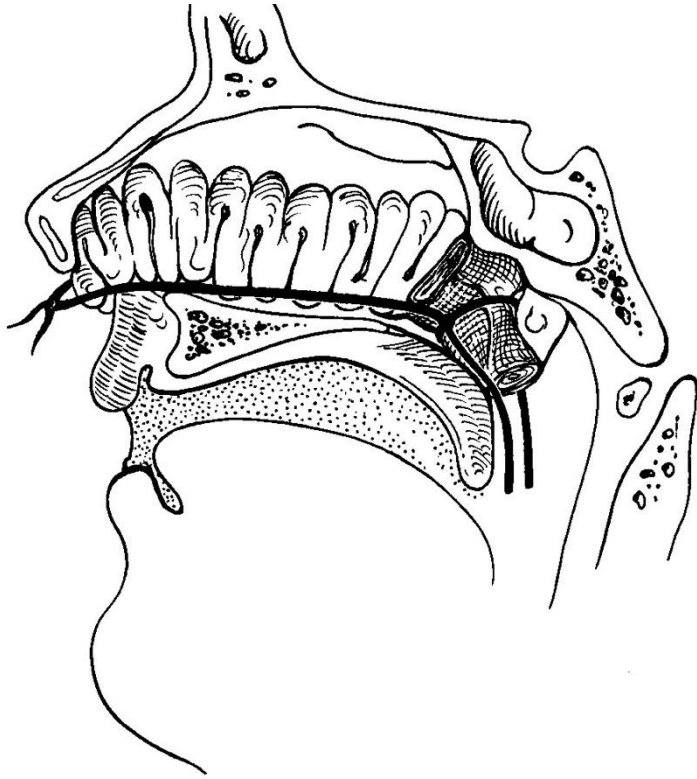


Posterior nasal packing

a gauze pack with a stay suture is used to close off the choana and is fixed in the nasopharynx to prevent the escape of blood from the nose into the nasopharynx, anterior packing is then performed. Technique - a Foley catheter is passed into the nasopharynx down the side of the nose....



Posterior nasal packing cont.



Vascular ligation

a.

1. Ligation a. maxillaris.

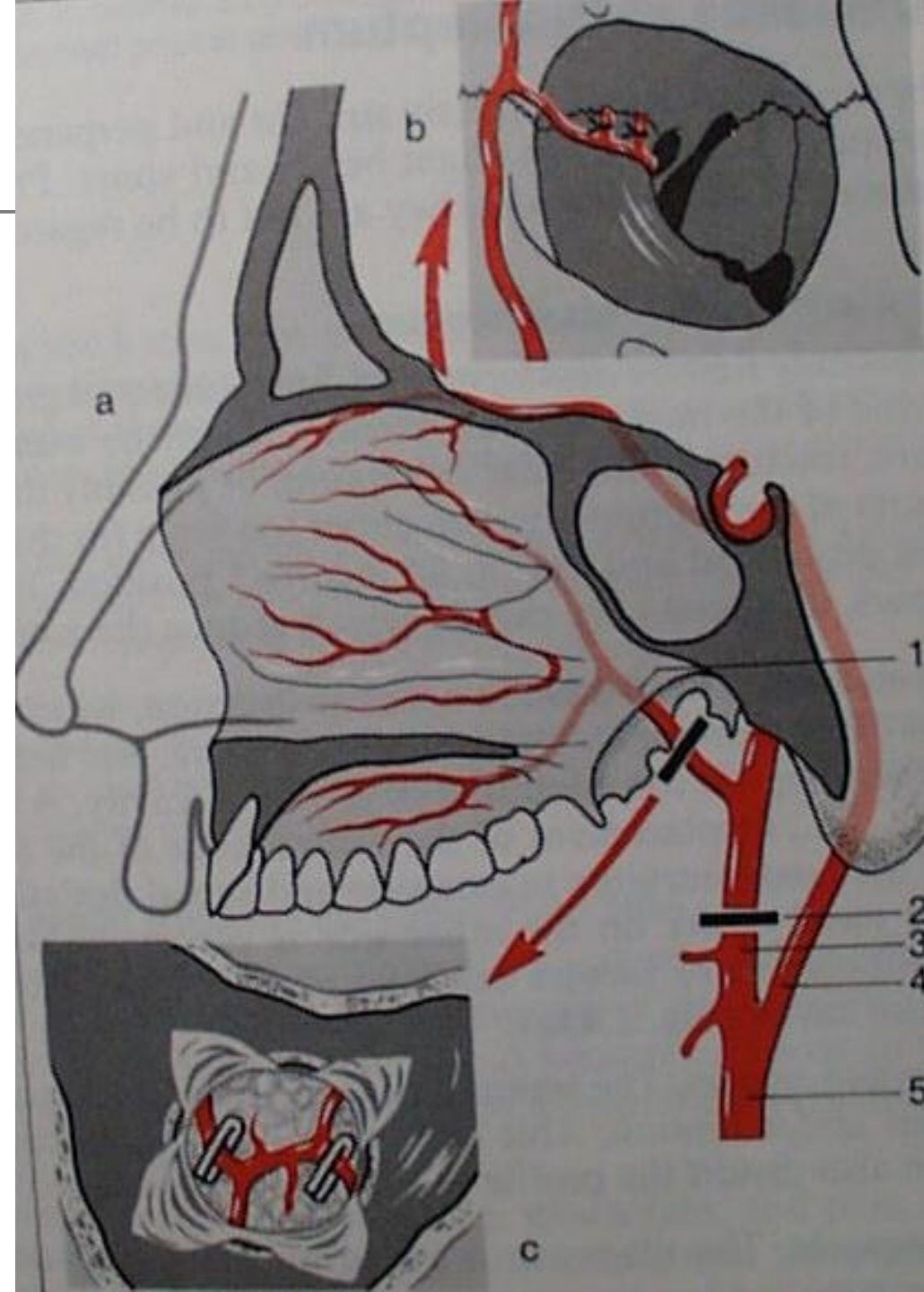
2. Ligation a. car. ext.

b.

Ligation a. ethmoidalis post.

c.

Ligation a. maxillaris ve fossa pterygopalatina





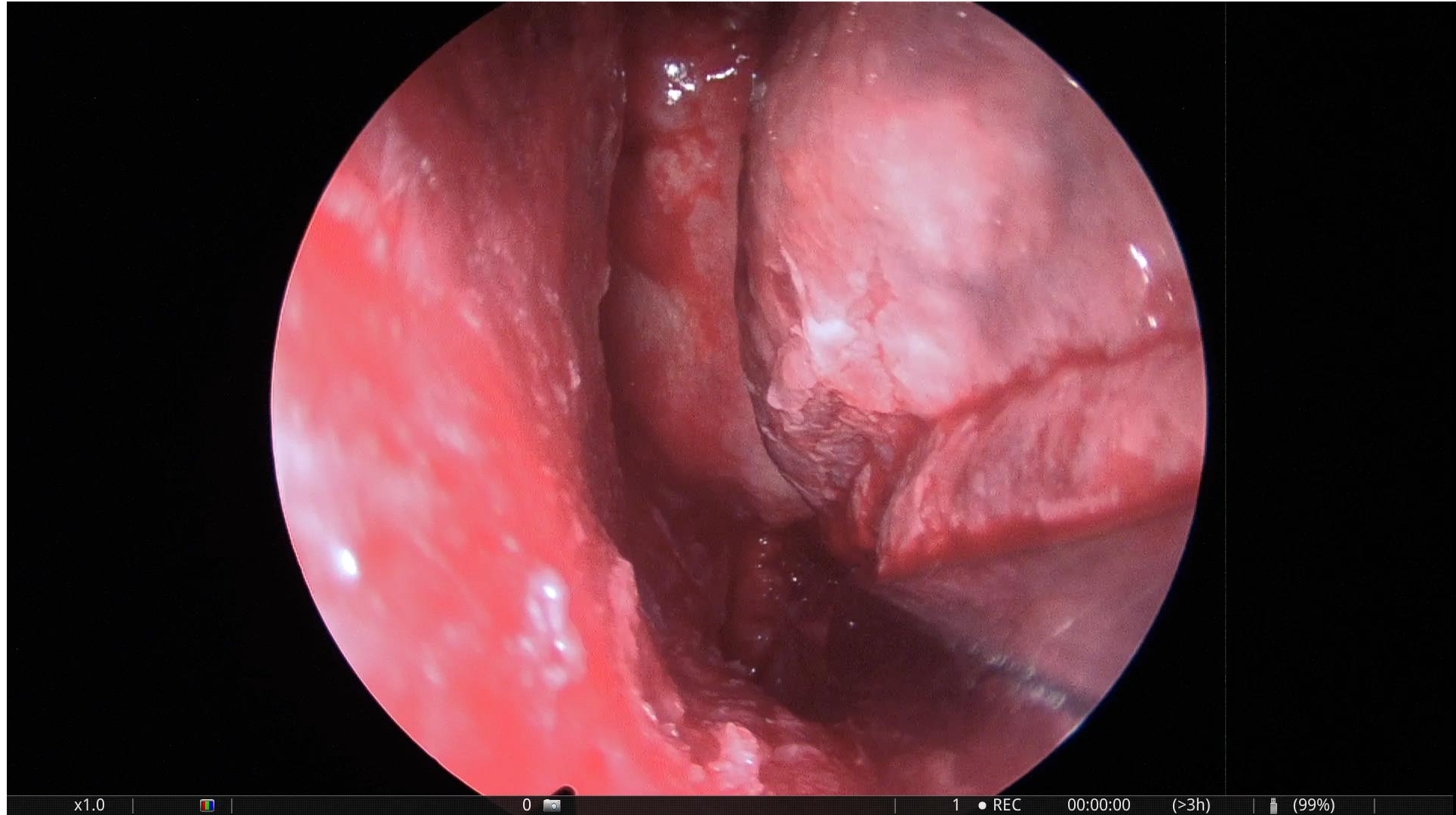
Epistaxis - general therapeutic management

according to causes

- supply of the blood, frozen plasma
- hemostyptics (Dicynone, ...)
- treatment of hypertension
- substitution of missing hemo-coagulation factors



Endoscopic electrocautery sphenopalatine artery





Classification of splanchnocranial fractures

1.) **upper face** (frontal sinuses, frontobasal fractures)

2.) **middle facial stage**

a.) lateral fractures - injuries of the zygomatico-maxillary complex

b.) central fractures - fractures of the nasal bones, naso-maxillary complex, maxilla, blow-out fracture of the orbit, breakage of the alveolar processes and LeFort type fractures:

LeFort I (subzygomatic inferior)

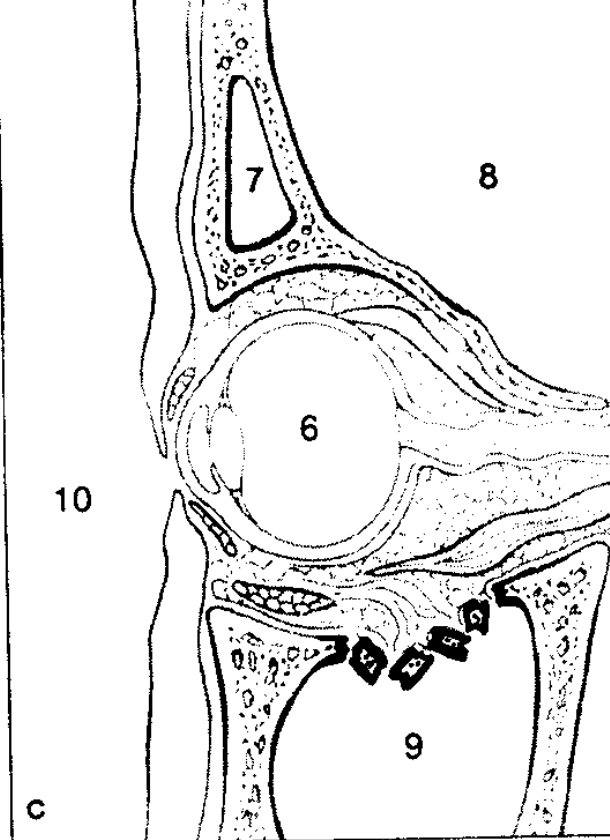
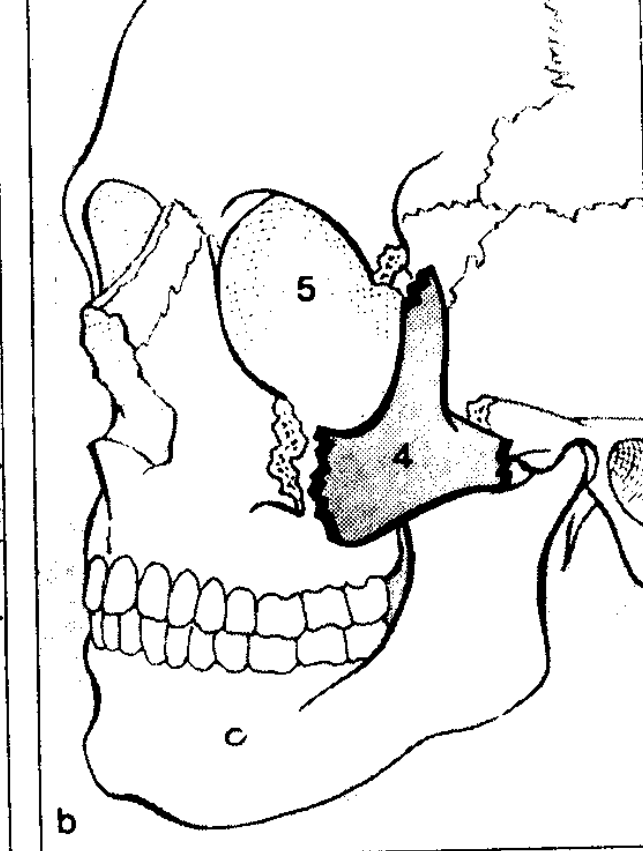
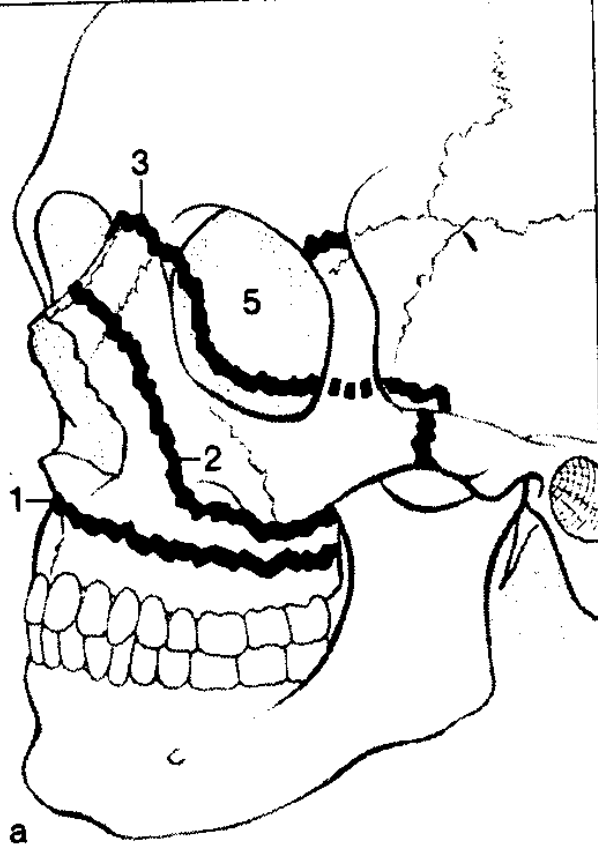
LeFort II (subzygomatic superior)

LeFort III (suprazygomatic)

3.) **lower facial region**

a.) Fractures of the mandible

b.) luxation of the temporomandibular joint



Trauma of the Face - middle facial stage

- central
- lateral

- a) fractures of the Middle third of the Face, horizontal
- 1) LeFort I inferior subzygomatic
 - 2) LeFort II superior subzygomatic
 - 3) LeFort III suprazygomatic fracture
- b) lateral fractures of the Zygoma and the Bony Orbit
- c) blow out fracture



Injury of nose

cause - accident, industrial and sports injuries

incidence - growing

serious **consequences** – blocked nose, lesion of voice, smell,
appearance

Injury of anterior **skull base**

Nose injuries

Open

Combined

Closed

Soft tissue injuries

Bone injuries

Soft tissue injuries

Bone injuries



Symptoms

- Visible **deformity**
- **Oedema, hematoma,**
- **Crepitation** of the fragments on lateral pressure on the nose
- **Sub skin emphysema** injury of mucosa membrane
- **Bleeding**
- **Liquorhea** – intracranial communication
- **Blocked nose**, rhinolalia clausa a anosmia
- **Shock**



Diagnosis

depends on the severity of the course

- History
- **Inspection, palpation and documentation** (legal reasons !)
- **Rhinoendoscopy**
- Radiography, **CT**
- Evaluation of **smell**



Treatment

- **Shock prevention**
- securing the **airway** (oro- or nasotracheal intubation - especially during the subsequent surgery in the oral cavity), if intubation is not possible, coniotomy with later transfer to tracheostomy is indicated (for anaesthesia during the subsequent surgery, especially in polytraumatised patients where long-term ventilatory support can be assumed)
- to stop **bleeding** (compression, ligature)
- **open wounds** must be treated according to the principles of plastic surgery (disinfection of the wound area, removal of foreign bodies, excision of necrotic masses, wound adaptation in layers, suture with single (removed after 3-4 days) or continuous suture (removed after 7 days), in wounds with loss of soft tissue, skin grafts)
- **Tetanus prevention**
- **Transport**
- **Antibiotic treatment**

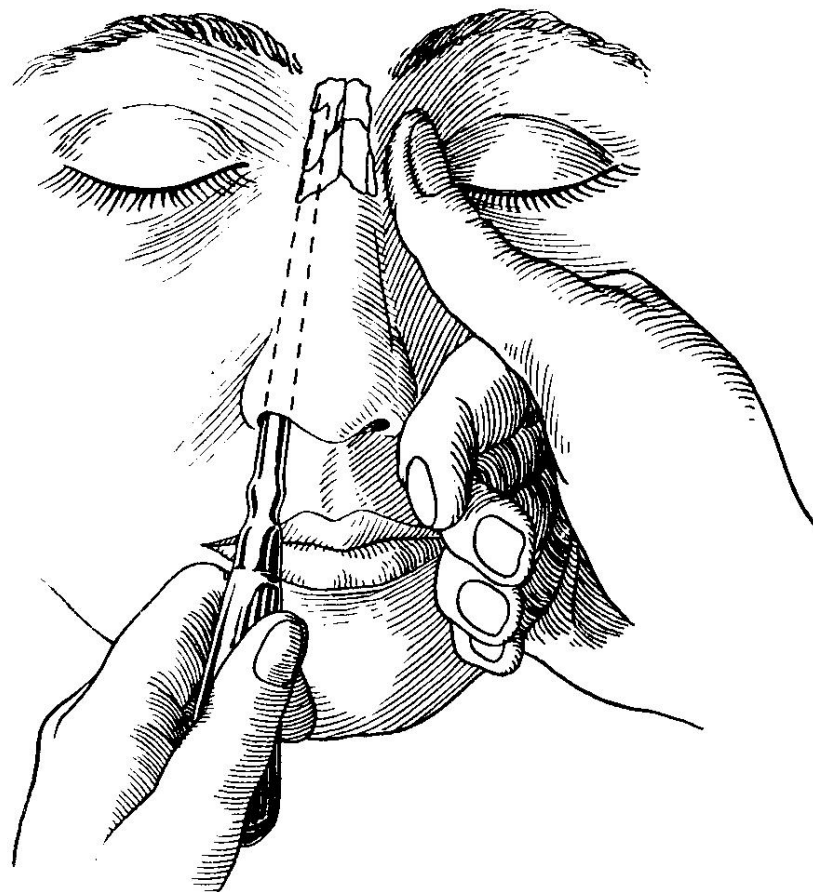


Treatment cont.

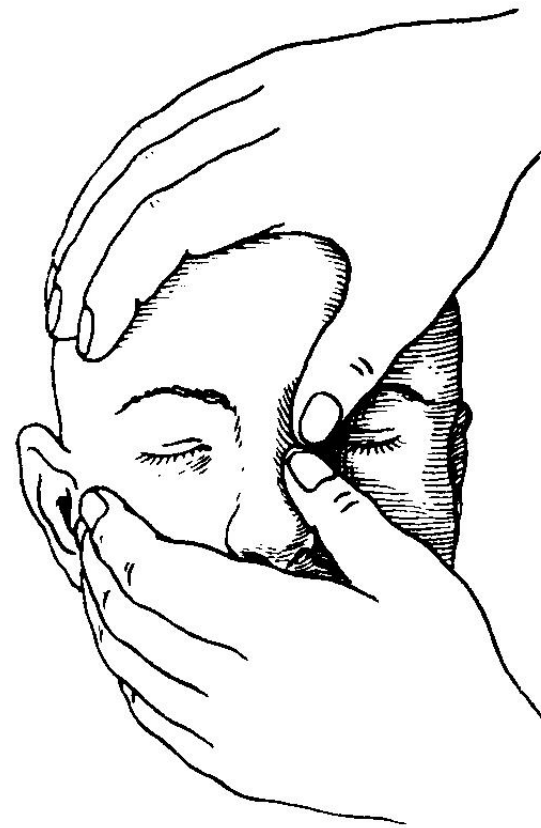
for **fractures**, procedures under local or general anaesthesia:

- non-bloody or bloody **repositioning**
- **fixation** of the fracture, if necessary (sling dressing, cast, Sauer splints, intermaxillary fixation)
- most maxillofacial trauma requires **delayed** surgery (3-10 days, resolution of swelling and hematomas)

Reposition of the nasal bones

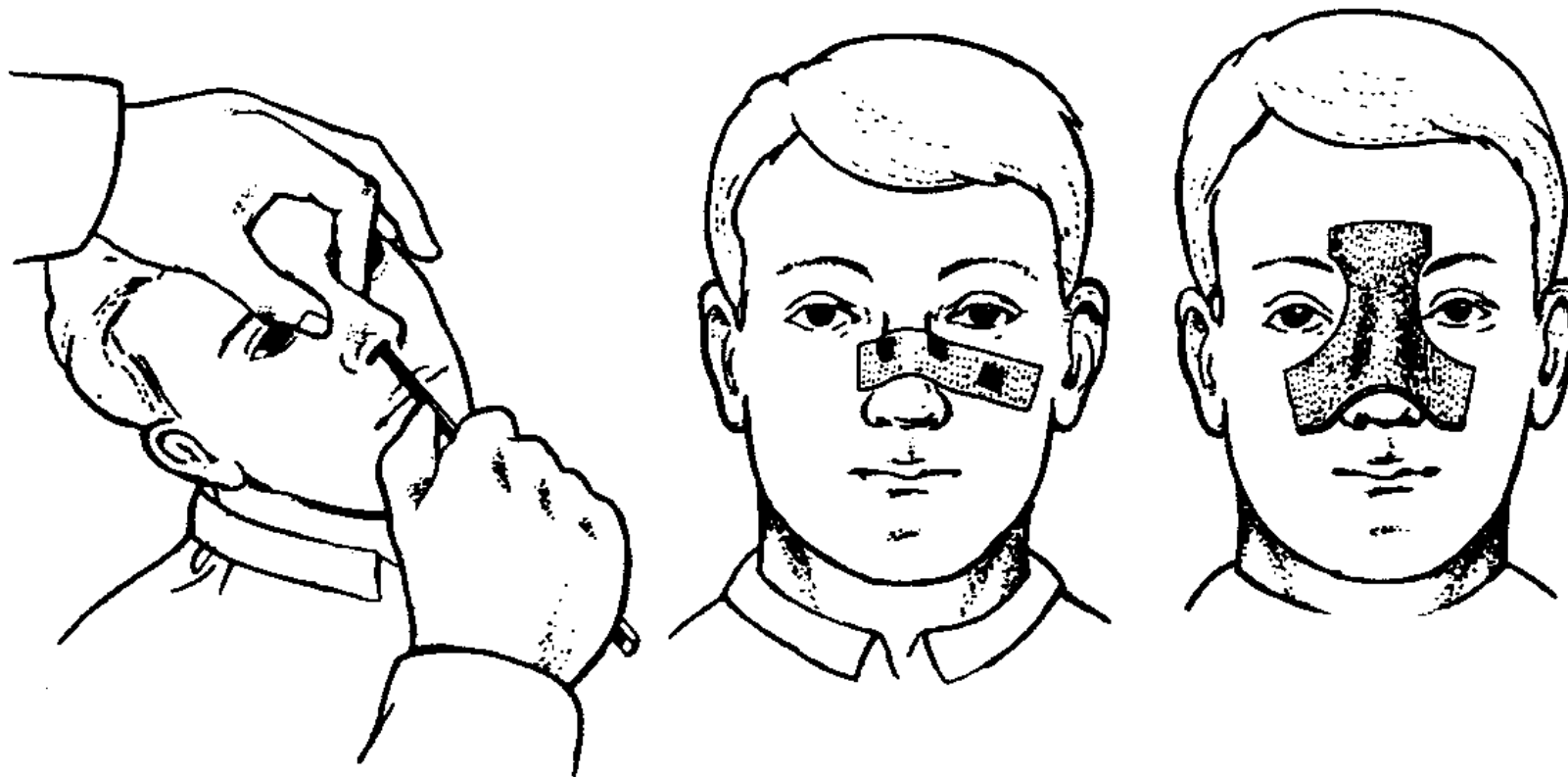


Uvedení zlomených nosních kůstek do původní polohy s pomocí elevatoria


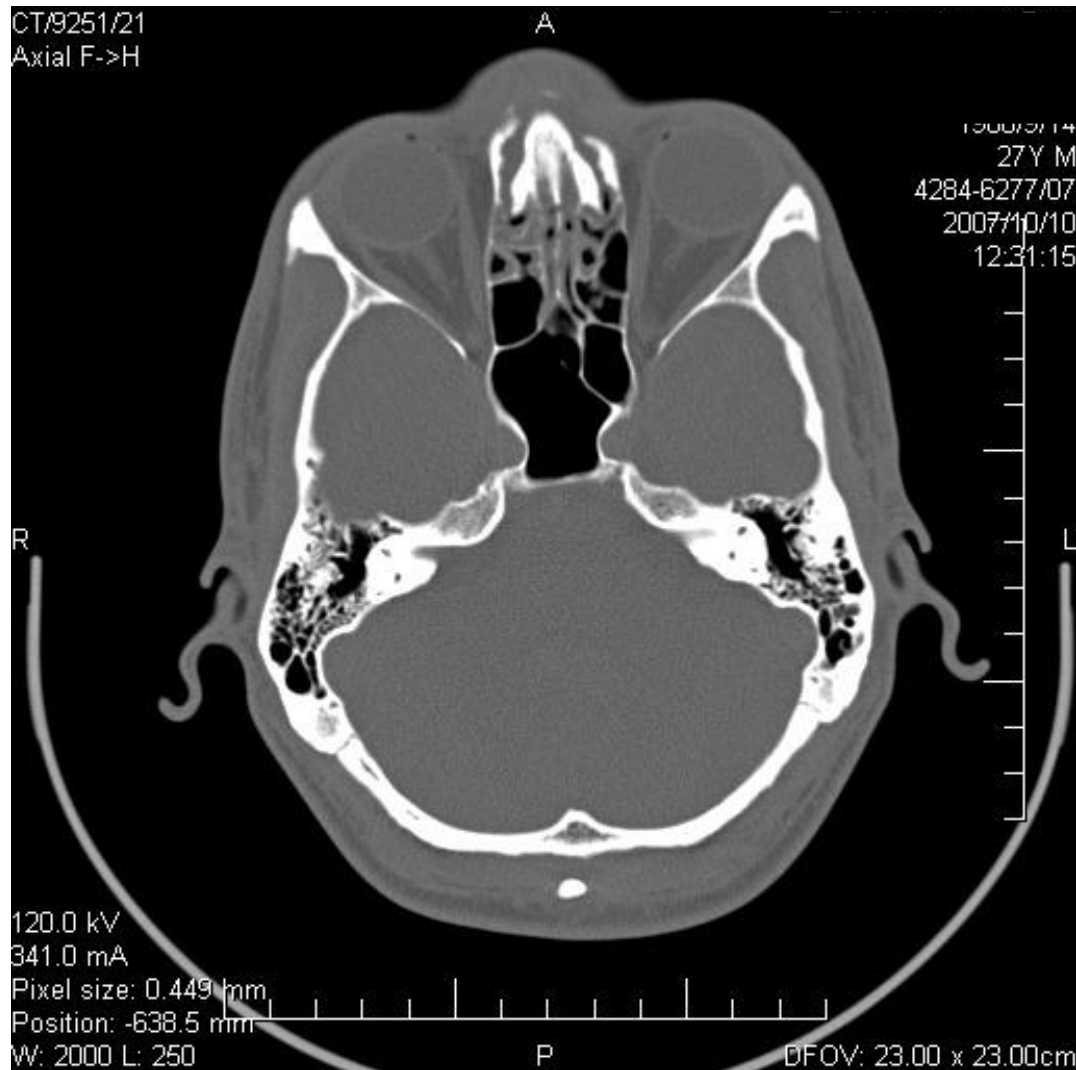


Reposice nosních kůstek palci ze zevnějška (redressement)

Reposition and fixation of fractured nasal bones



Frontobasal fracture – young man, injury from cracked tyre



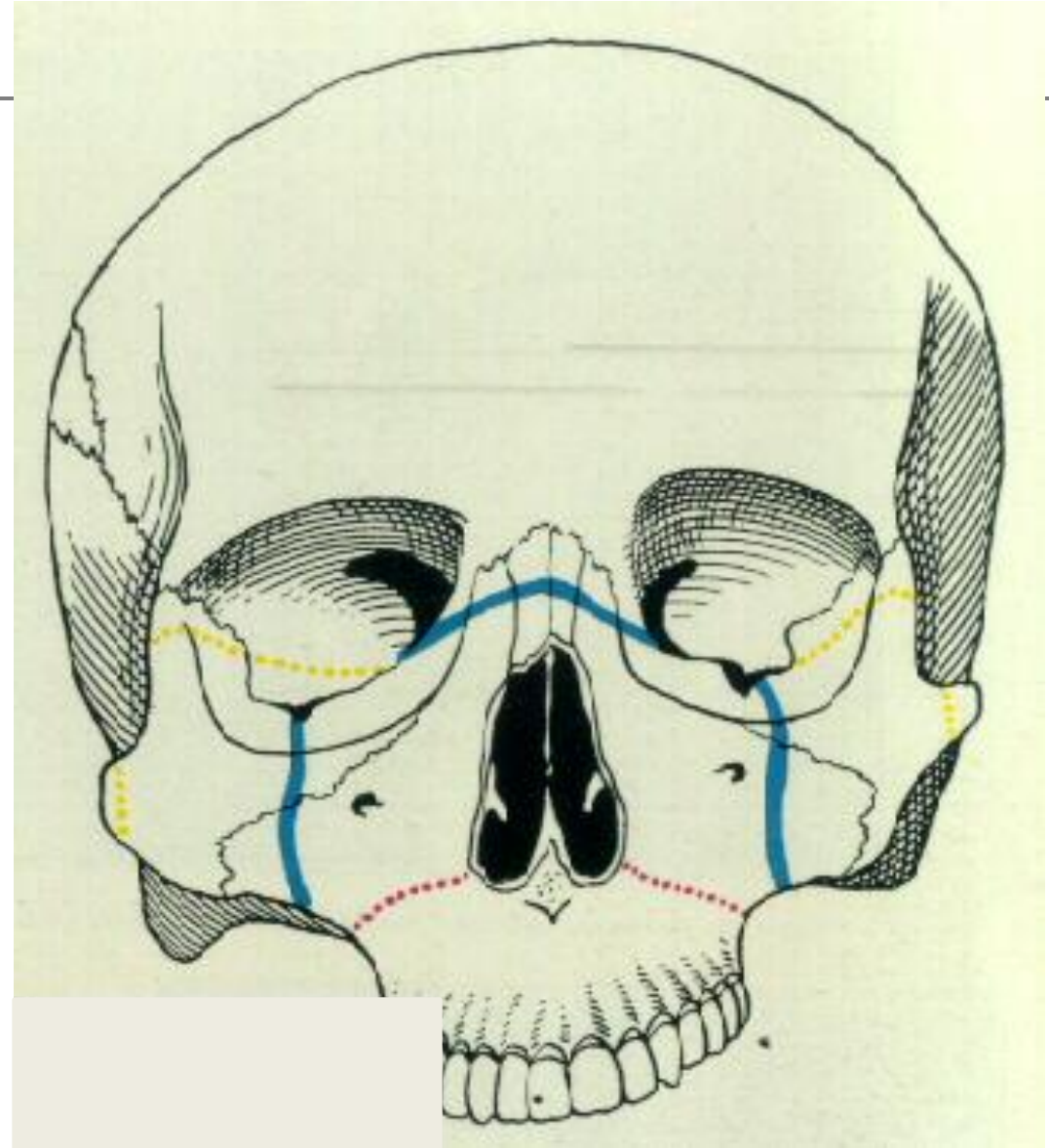
1) **LeFort I**

inferior subzygomatic fracture

2) **LeFort II**

superior subzygomatic fracture

3) **LeFort III** suprazygomatic fracture





Injuries of paranasal sinuses

Surgery is necessary if:

- 1) liquorhea
- 2) injured sinus is inflamed
- 3) inflammation after injury
- 4) foreign body in wound
- 5) complicated fractures with displaced fragments
- 6) endocranial complications



Tumors of nose and paranasal sinuses

see „Oncology day 8“



Diseases of the orbit

- a) inflammations, tumours, injuries
- b) surgical procedures





Inflammation of the orbit

85% of infections of sinogenic origin, mostly from ethmoid sinuses

Diagnostics

- Clinical examination: eyelid, eyeball (mobility, visus), rhinoendoscopic examination to exclude pathology in the area of the ostiomeatal unit.
- Imaging methods: CT of the orbits and paranasal sinuses with contrast or MRI with contrast to better visualize the inflammatory seepage and possible abscess.

Therapy

Medical - (preseptal cellulitis, incipient orbito-cellulitis) - beta-lactam PNCs, cephalosporins IIIrd generation. Anemisation of the nasal cavity and anti-edema therapy (corticosteroids contraindicated).

Surgical - if symptoms worsen despite 24-hour ATB therapy or if condition does not visibly improve within 48 hours. In abscess drainage from external or endoscopic approach. This includes treatment of the primary inflammatory focus in the paranasal sinuses.

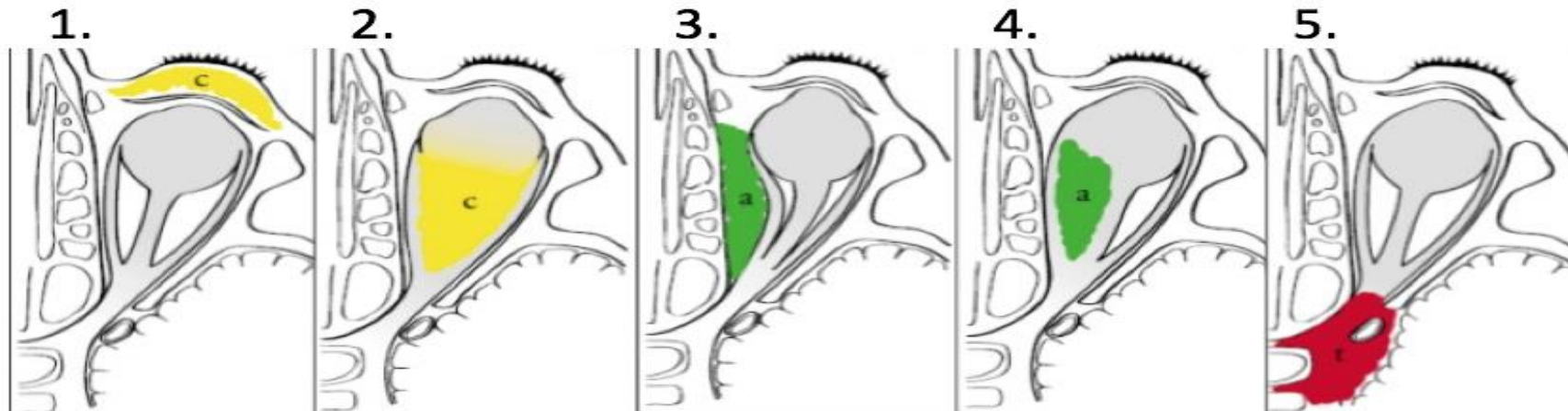


Inflammations of the orbit - division

	Swelling and redness of the eyelids	Position and mobility of eyeball	Conjunctival chemosis	Vision	Meningism, fotofoby, sepsis
Preseptal cellulitis	yes	normal	no	normal	no
Orbital cellulitis	yes	exophthalmos, impaired mobility	yes	normal	no
Subperiosteal abscess	yes	dislocation laterocaudal, mobility normal	yes	normal	no
Orbital abscess	yes	exophthalmus, impaired mobility	yes	impaired	no
Thrombosis of the cavernous sinus	yes	exophthalmus (also both sided), impaired mobility	yes	impaired	yes

Orbital Complications of Sinusitis

1. Periorbital (Pre-Septal) cellulitis (c)
2. Orbital (Post-septal) cellulitis (c)
3. Subperiosteal Abscess (a)
4. Orbital Abscess (a)
5. Cavernous Sinus Thrombophlebitis (t)

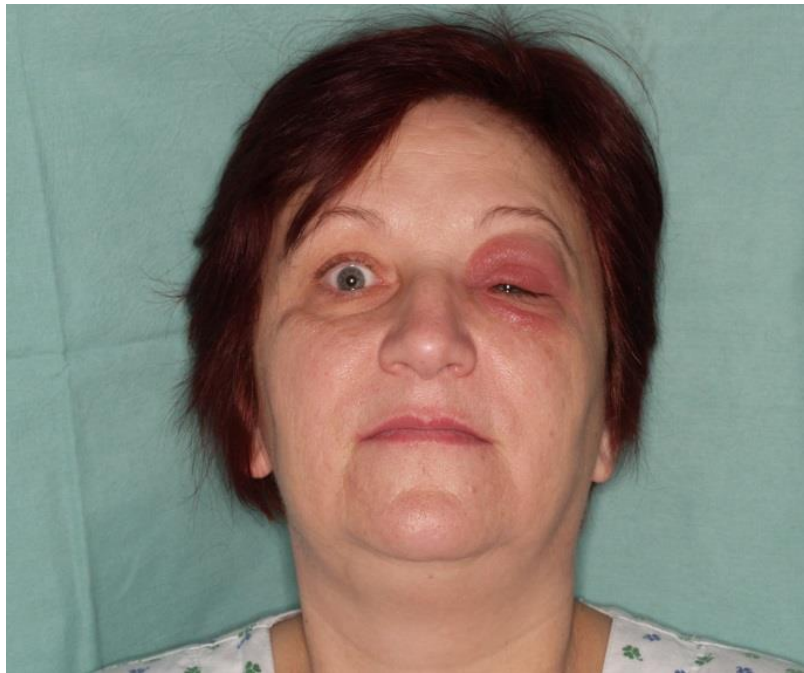


Zdroj: převzato z www.slideshare.net

Inflammations of the orbit, examples

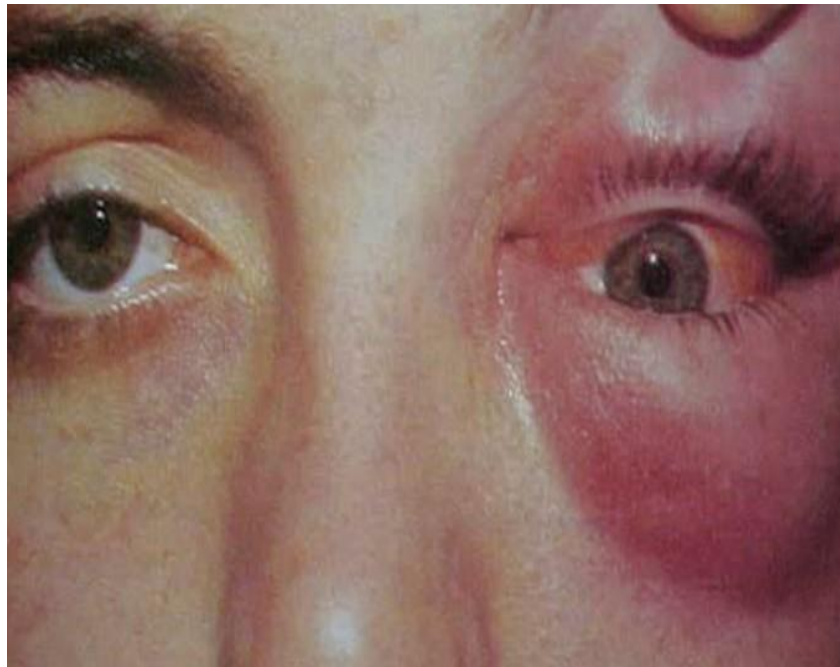Preseptal orbitocelulitis

Adapted from Archiv
KOCHHK,
FN u sv.Anny v Brně



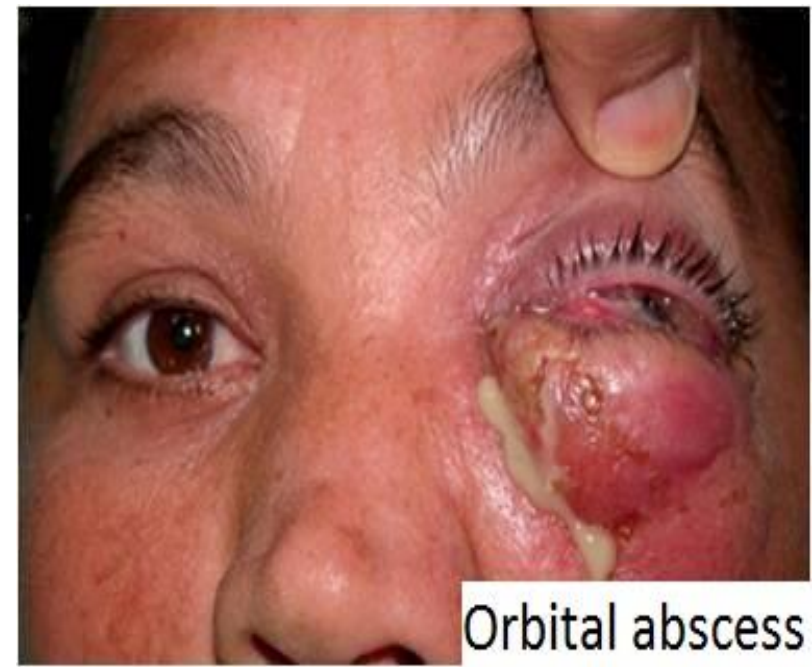Orbital cellulitis

Adapted from
www.thegeniusprof.com



Orbital abscess

Adapted from
www.drmmkotb.com





Tumors of the orbit

Primary - arising from orbital tissues - lymphangioma, capillary and cavernous haemangioma, glioma, meningioma, schwannoma, rhabdomyosarcoma

Secondary - overgrowth into the orbit from surrounding tissues - orbital promotion of eyelid tumours (basalioma, spinalioma), paranasal sinuses and intracranial tumours, retinoblastoma from the globe

Metastasis - neuroblastoma in children, often bilaterally. In adults, most often metastases from breast and lung, also affected in haemoblastoses.



Pseudotumors of the orbit

non-infectious inflammation that can act like a tumor

Histology: signs of chronic inflammation.

Clinical picture: heterogeneous - pain on eyeball movement, diplopia, inflammatory changes, conjunctival chemosis, "tumor-like" resistance at the orbital entrance in a completely quiet eye, without elevated inflammatory markers in KO.

Diagnosis: MRI of the orbit with contrast (possibly CT orbit with contrast), histological verification.

Treatment: corticosteroids, some types respond well to radiation. After repeated recurrences, transition to malignant lymphoma may occur.



Injuries (fractures) of the orbit

stand-alone unit /or part of extensive facial trauma and intracranial injuries

Direct - indirect (hydraulic)

Frontobasal - nasomaxillary (nasoorbital) - zygomaticoorbital - hydraulic

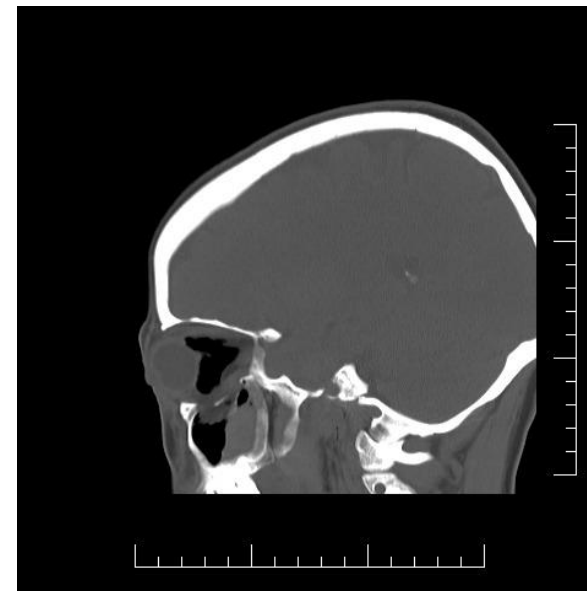
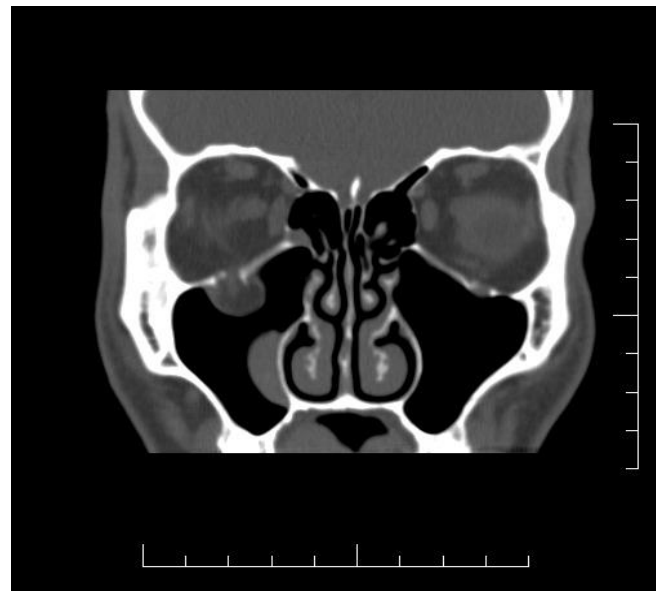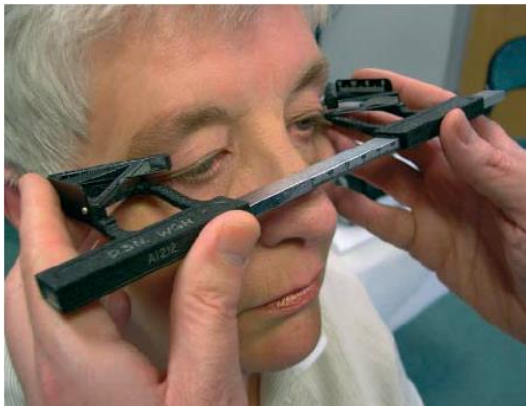Clinical picture: swelling, hematoma and emphysema of the eyelids and periorbital landscape, narrowing of the optic fissure, enophthalmus or exophthalmus, dropping of the eyeball, diplopia, sensory disturbance in the innervation area of the infraorbital nerve (2nd branch of the n.V), epistaxis

Injuries (fractures) of the orbit

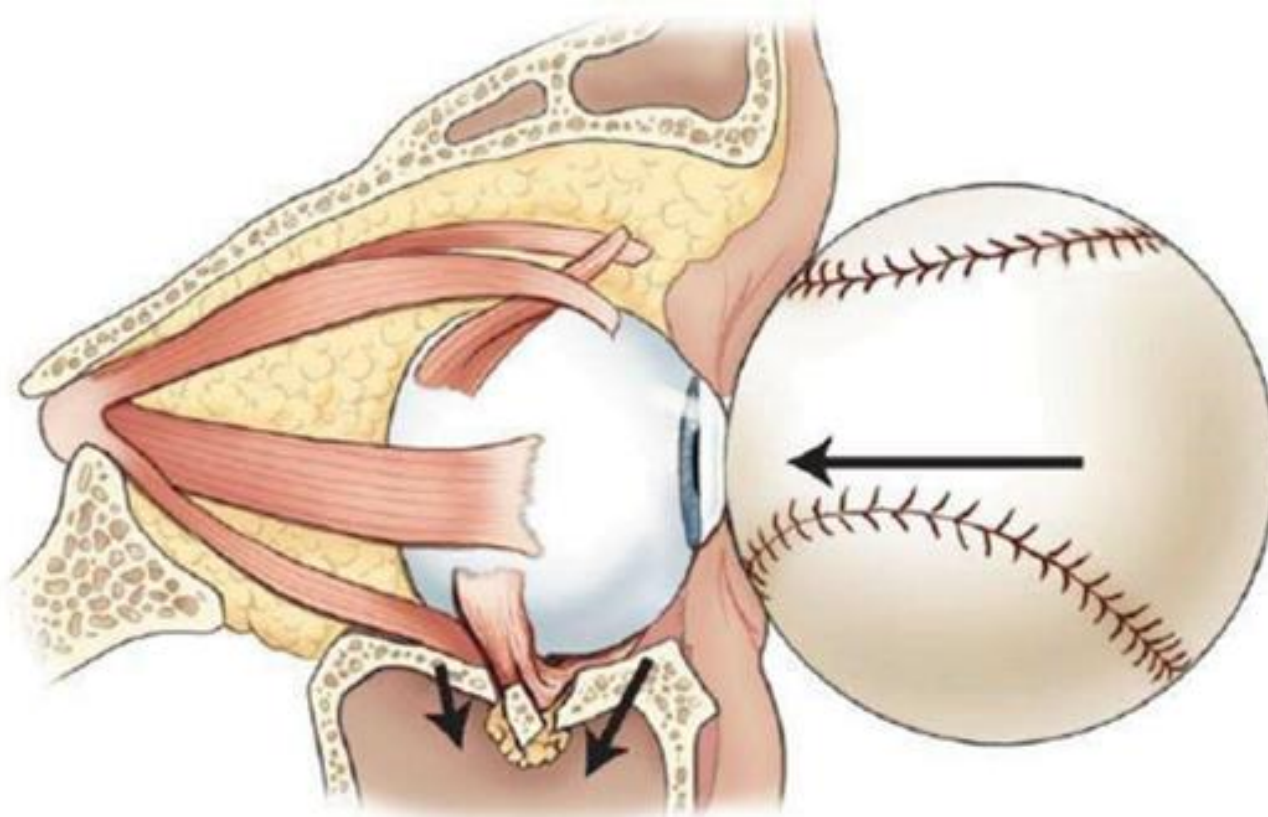
Functional eye examination: passive duction test, exophthalmometry (Hertel test), diplopia analysis (Hess screen)

Imaging method: CT of paranasal sinuses and orbits in sagittal, axial and coronal projections

Treatment: conservative X surgical (ocular and radiographic indications), always ATB

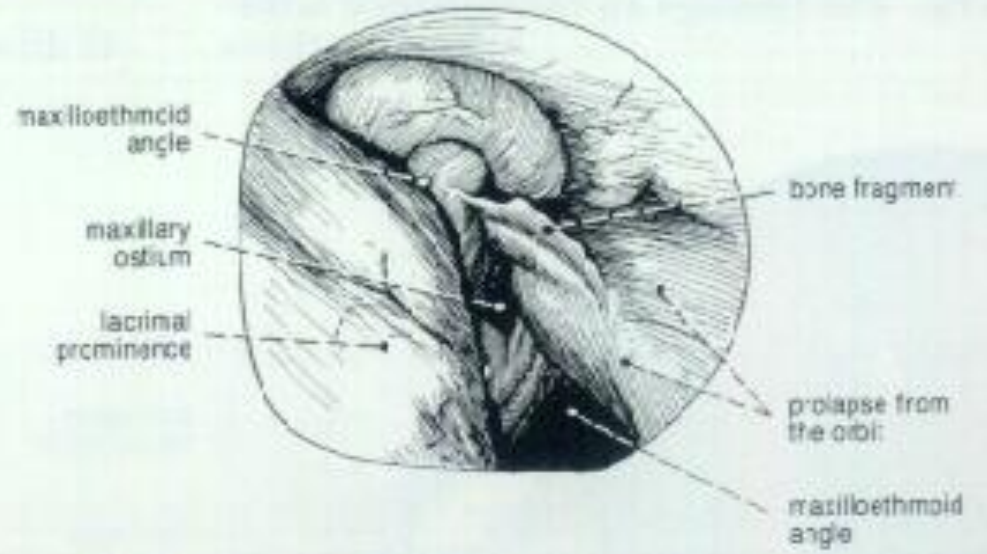
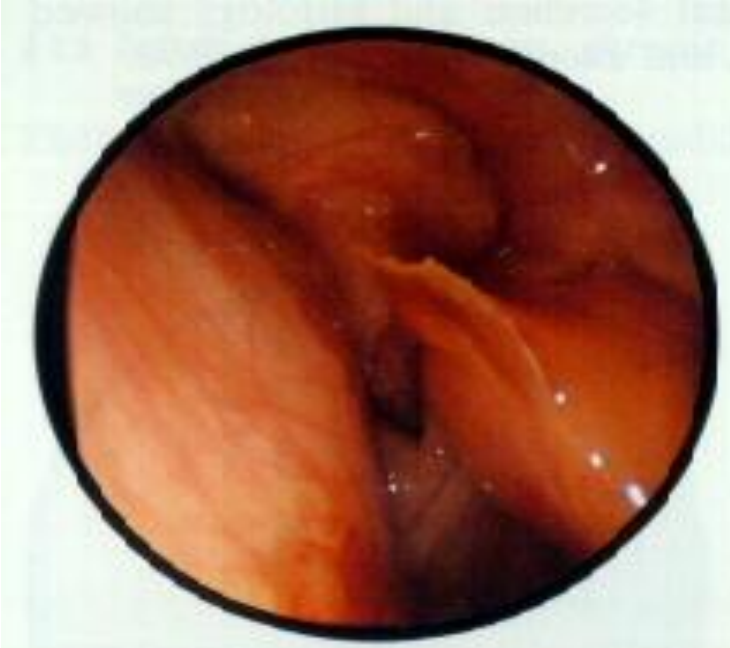
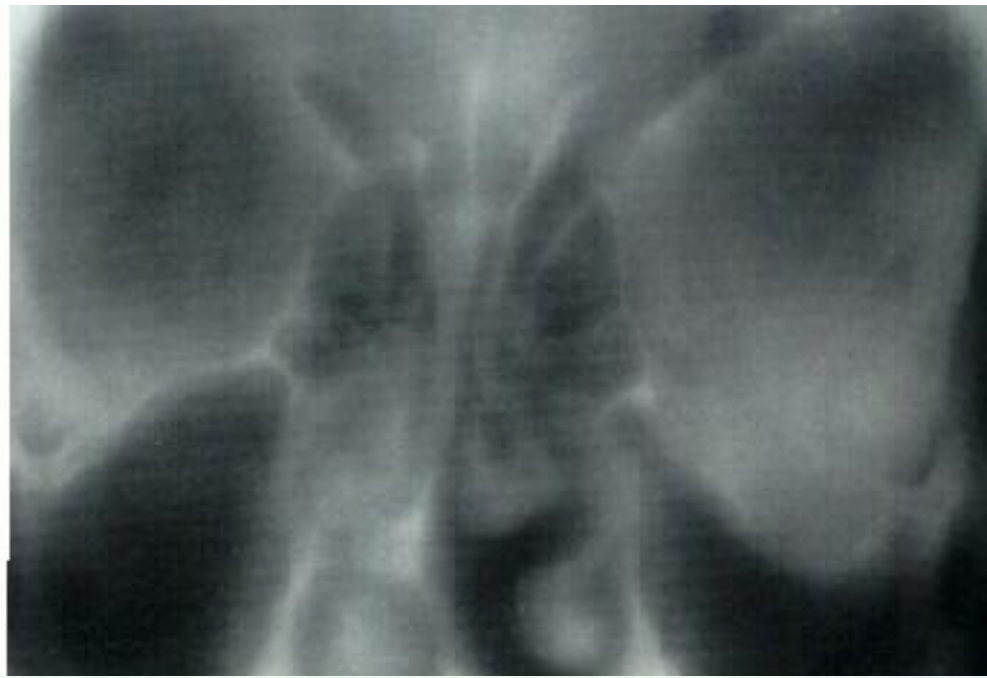
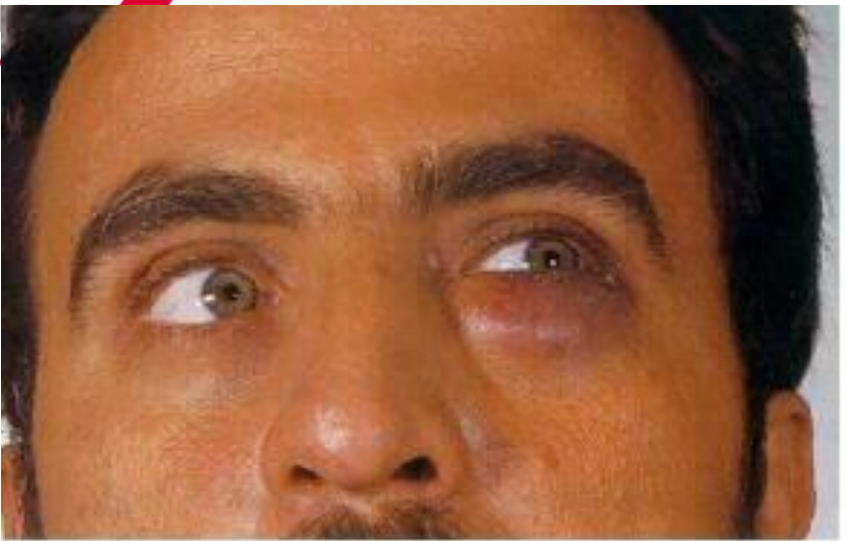Mechanism of the blow-out fracture

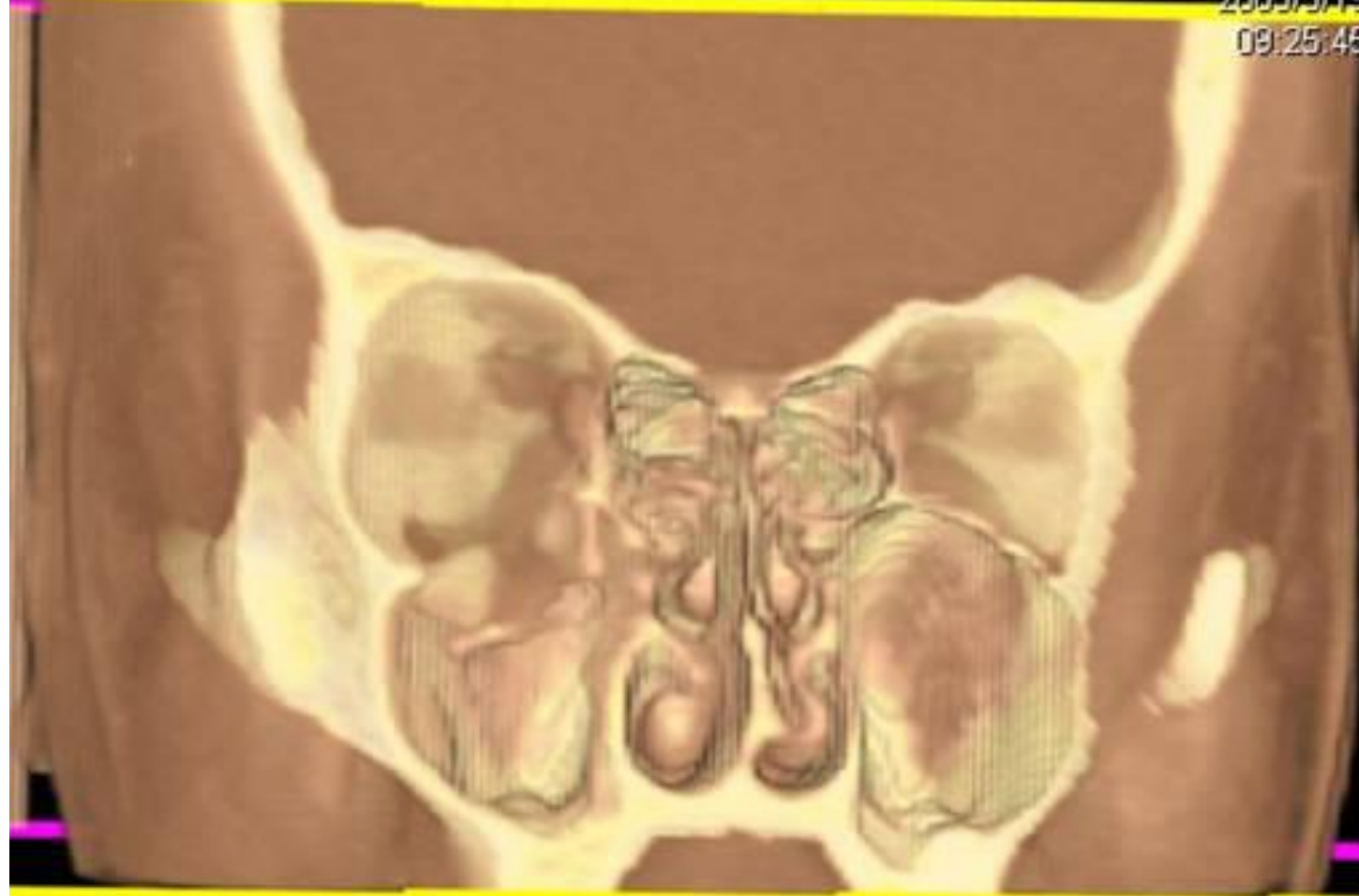

Blow-out fracture

FAKULTNÍ
NEMOCNICE
U SV. ANNY
V BRNĚ



warping of the lower rectus
eye muscle (musculus rectus
inferior) – consequence –
diplopia (double vision)





Surgical approaches to the orbit

Orbitotomy transorbital X extraorbital (transcranial)

Transorbital:

- **Anterior:** transpalpebral or transconjunctival incision for lesions in the orbital entrance, anterior parts of the orbit and peribulbar. Osteotomy is not necessary
- **Lateral:** access through the lateral wall of the orbit - removal of more or less of the lateral part of the orbit, nowadays without lateral canthotomy for tumours retrobulbar and in the lateral half of the orbit both intra- and extraconally (Krönlein, 1874)
- **Medial:** incision in the inner corner of the eye, periorbita and lamina papyracea of ethmoids. In orbital decompression for retrobulbar hematoma and in tumor retrobulbarly and in the medial part of the orbit.

Transcranial frontotemporal:

- Lowering of the upper orbital wall by transcranial approach, thereby opening the retrobulbar space. There is a possibility of opening the optic canal.



Surgical procedures of the orbit cont.

Enucleation of the bulb

Removal of the eyeball with the adjacent part of the optic nerve for tumour

Exenteration of the orbit

Complete removal of the contents of the orbit with the periorbita, leaving the bony wall of the orbit. For malignant tumors affecting the soft tissues of the orbit or periorbit. The defect is covered with an autologous musculocutaneous flap on a free vascular pedicle or a removable prosthesis (epithesis).

Orbitectomy

The most extensive oncological procedure on the orbit involving removal of both the soft tissues of the orbit and the bony shell. It is used for particularly large tumors growing into and destroying the bony orbit.