

Nuclear medicine I.



KRNM FN BRNO

Nuclear medicine – uses radiopharmaceuticals for:

Diagnostics

Therapy

Scintigraphy

- **Gama emitters**

- ^{99m}Tc , ^{123}I , ^{81m}Kr , ^{111}In
- Detects **1 photon**
- **Planar** scintigraphy (sumation) or **SPECT** (tomographic)
- Static x dynamic
- Possible hybrid imaging SPECT/CT

PET

- **Beta+ emitters**

- ^{18}F , ^{68}Ga , ^{11}C
- Detects **2 photons**
- Tomographic method
- Always hybrid imaging PET/CT or PET/MRI

- **Beta- and alfa emitters**

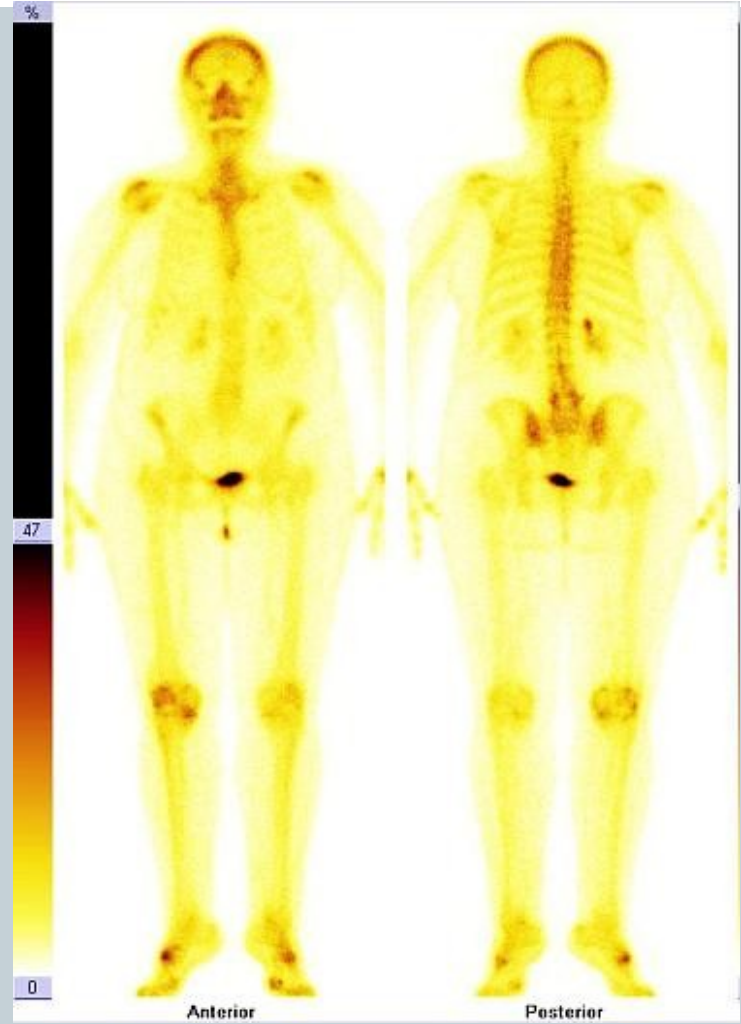
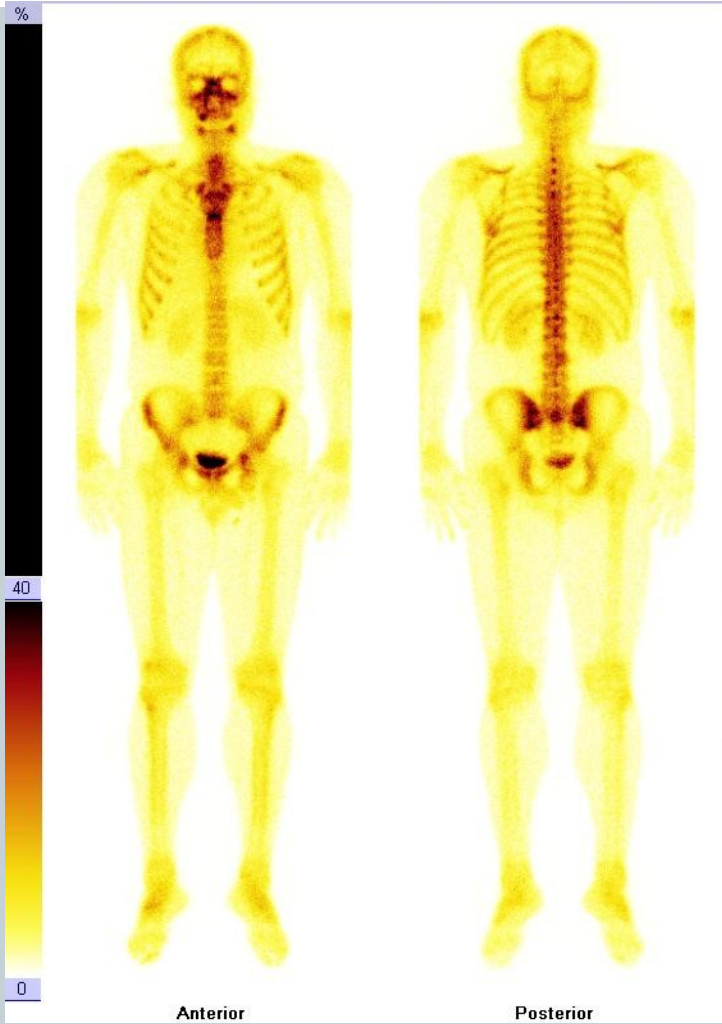
- ^{131}I – thyroid carcinoma, hyperthyreosis
- ^{177}Lu – metastatic prostate cancer, NETs
- ^{90}Y – synovectomy
- ^{223}Ra (alfa) – prostate cancer bone mts

Bone scintigraphy

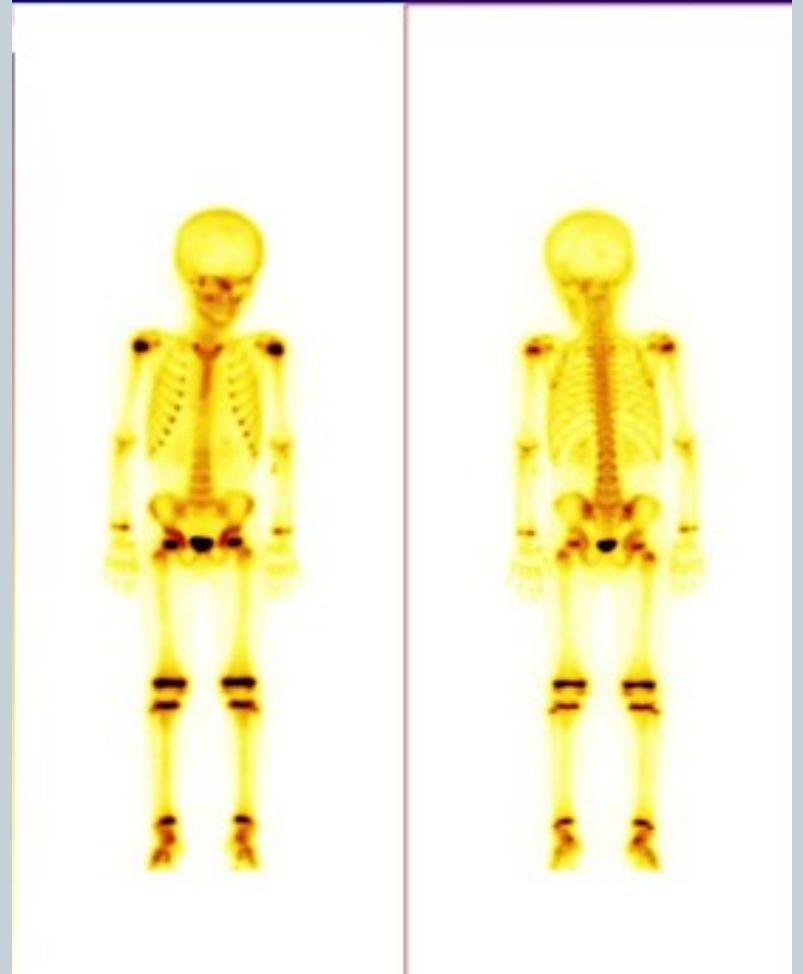
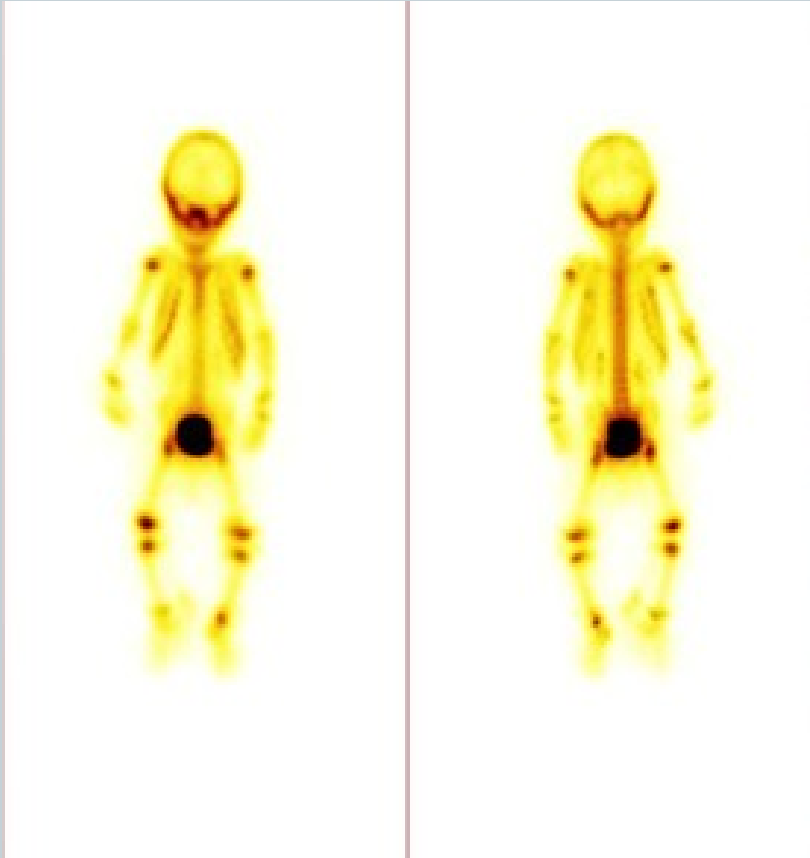
- One of the most commonly used methods
- **Principle:** When tracer is injected intravenously, is taken up by adsorption onto the surface of bone, distribution in the skeleton is based on differences in regional perfusion (vascularity) and **bone turnover** as well as other factors – non specific!!!
- High sensitivity, small specificity (clinical context, patient's history, SPECT, SPECT/CT)
- **RP:** technetium-labeled bisphosphonates (^{99m}Tc -MDP), analogs of some components of the mineral portion of bone
 - (alternatively - ^{18}F -NaF for PET imaging)
- **Imaging technique:** wholebody planar image in anterior and posterior view 2-4h after RP administration, SPECT or SPECT/CT , 3-phase protocol

Bone scan



Bone scan



Bone scintigraphy



- **Indications:**

- **Metastatic** bone disease, primary bone tumors
- Osteomyelitis (mostly periferal bones)
- Evaluation of prosthetic joints for loosening and infection

- Skeletal trauma, stress fructures
- Metabolic bone disease : Morbus Paget, hyperparathyroidism
- Evaluation of bone pain in patients with normal radiographs, evaluation of the significance of an incidental bone finding on radiographs, determination of biopsy site

Bone scintigraphy

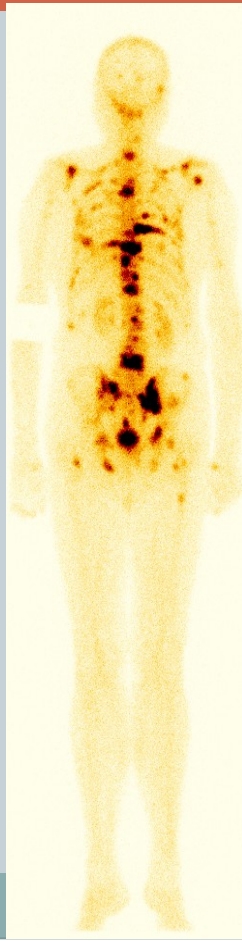
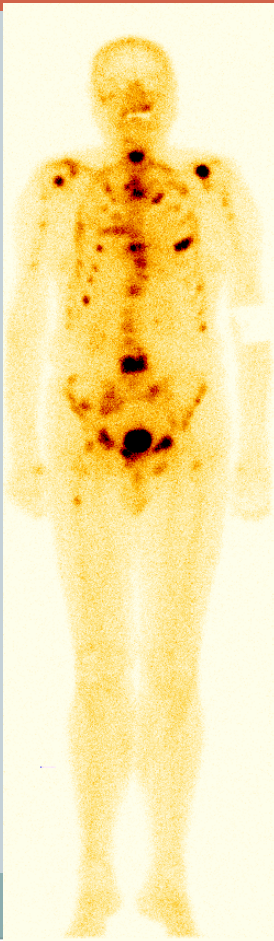


- High sensitivity - predominantly **osteoblastic** sites show **increased activity** (hot spots), whereas mainly osteoclastic or lytic lesions can be difficult to detect (cold lesions) – **tumors that are predominantly lytic have lower sensitivity**
- Highest sensitivity for **prostate cancer**, high sensitivity for **breast** and **lung cancer**, low sensitivity for multiple myeloma, thyroid cancer, renal carcinoma.....
- Bone scan vs FDG PET
 - Higher sensitivity of scintigraphy in osteoplastic metastases
 - Higher sensitivity of PET in osteolytic lesions

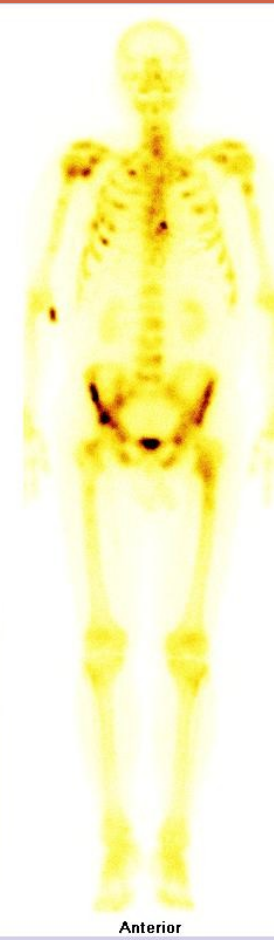
Bone scan



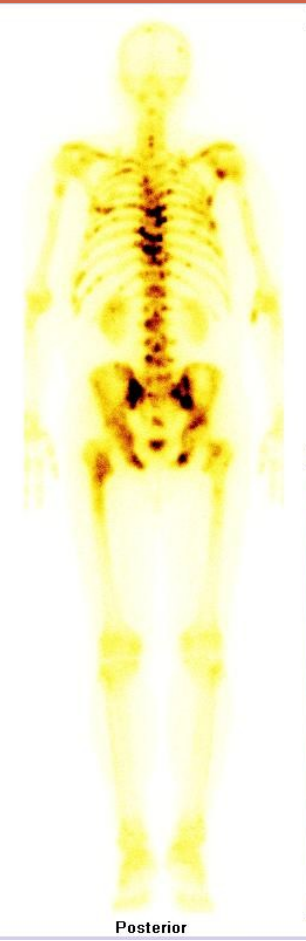
Metastatic breast cancer



Metastatic prostate cancer



Anterior

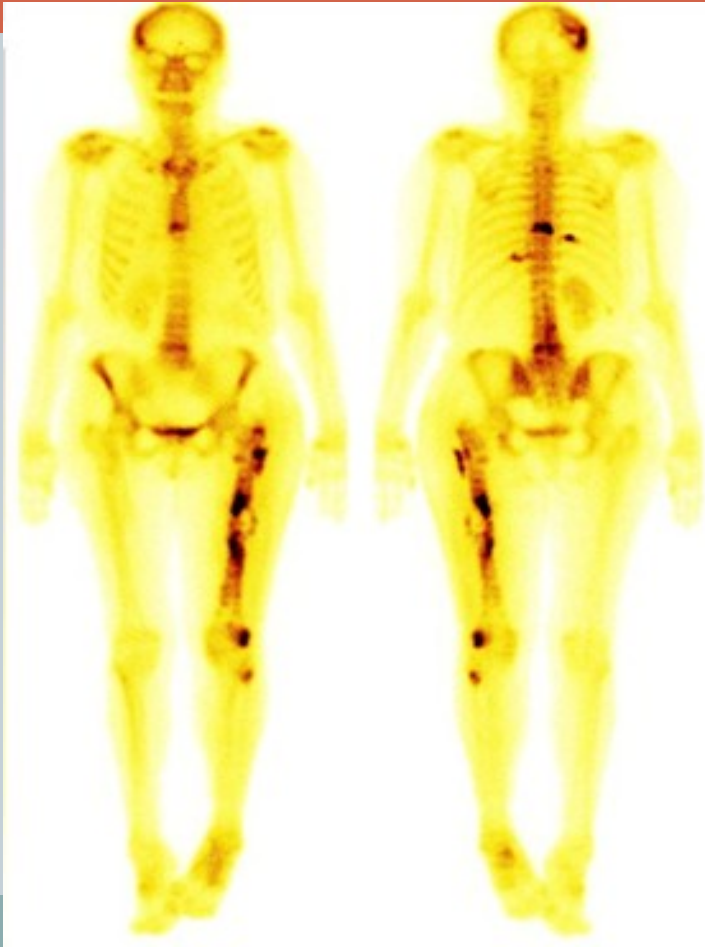


Posterior

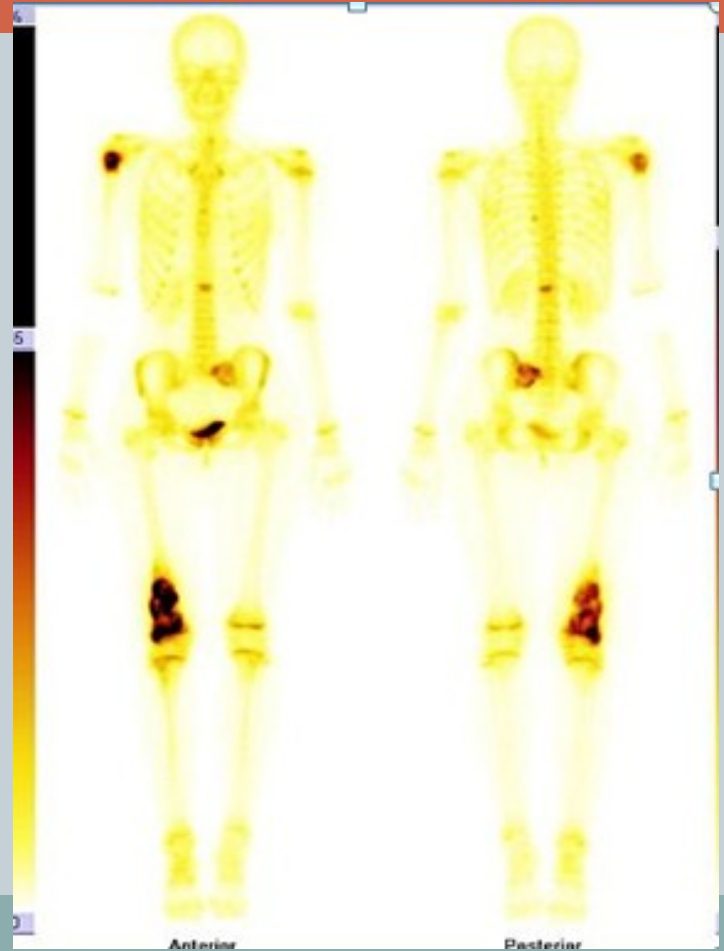
Bone scan



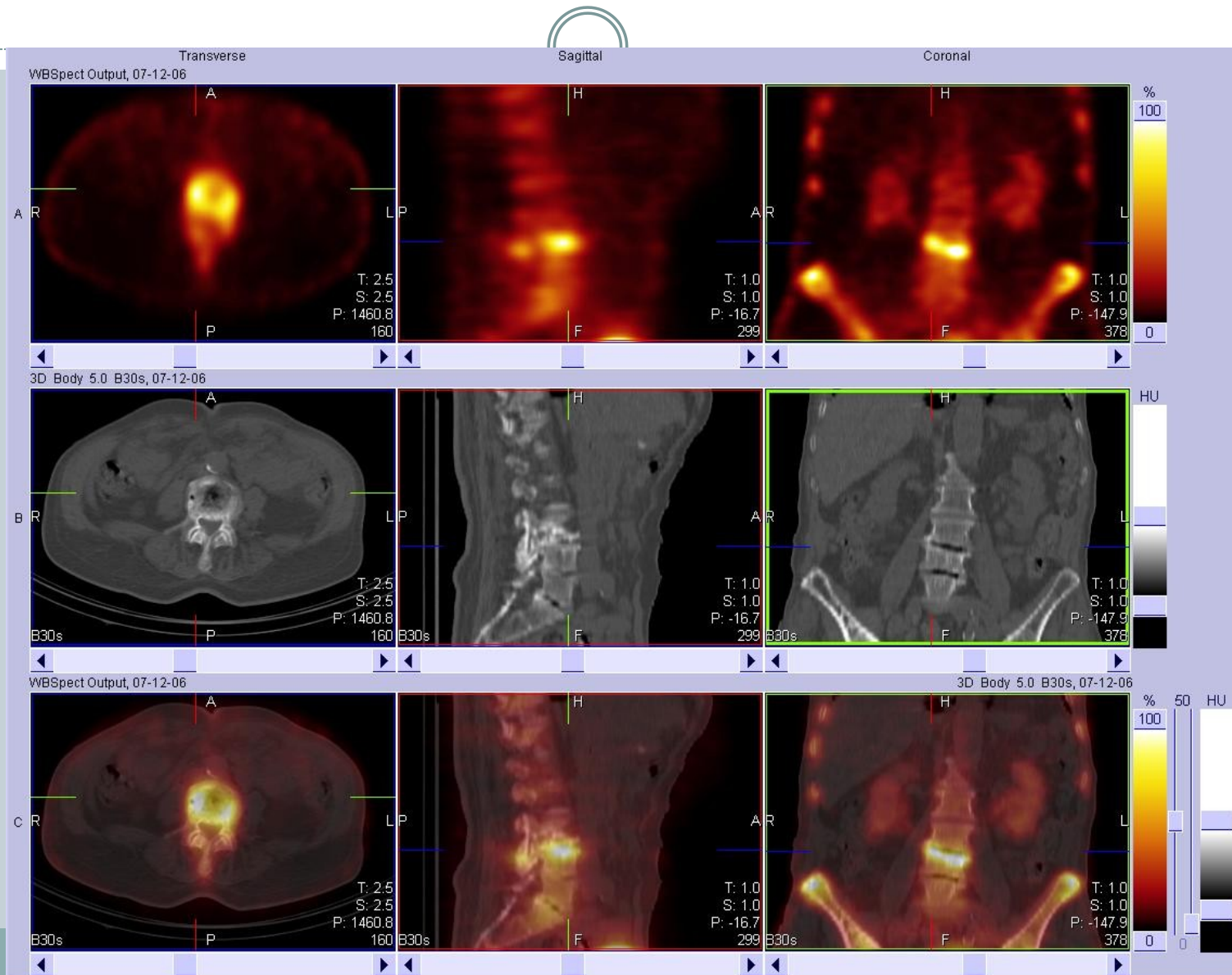
RCC



Osteosarcoma

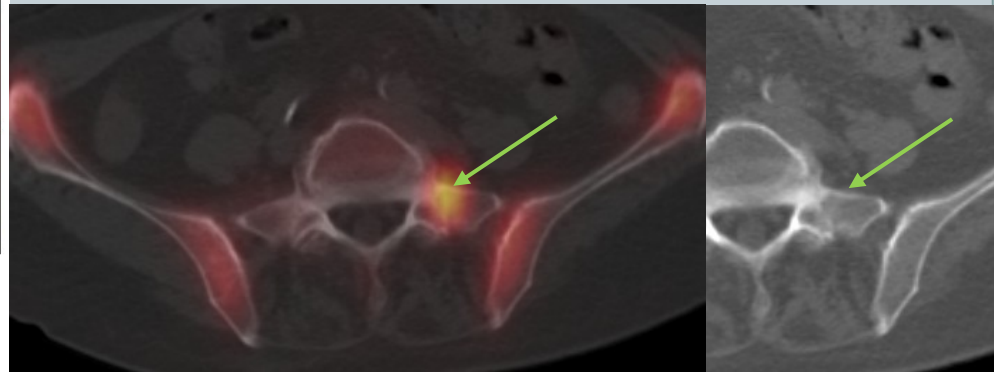
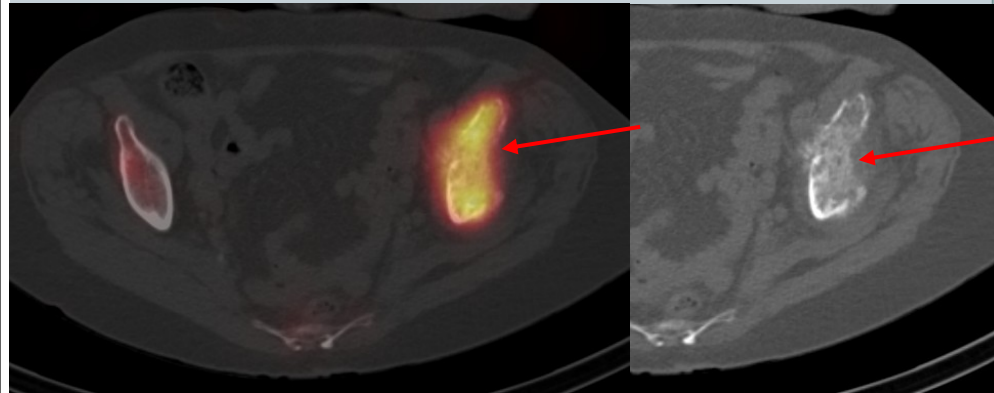
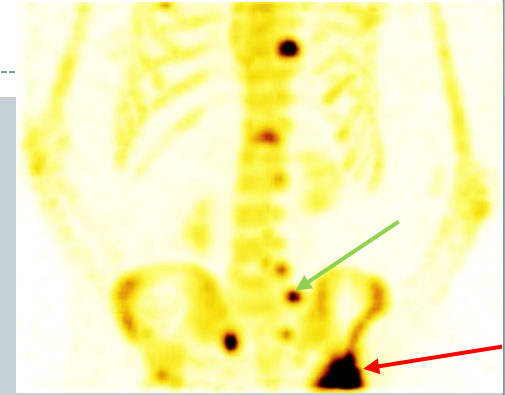
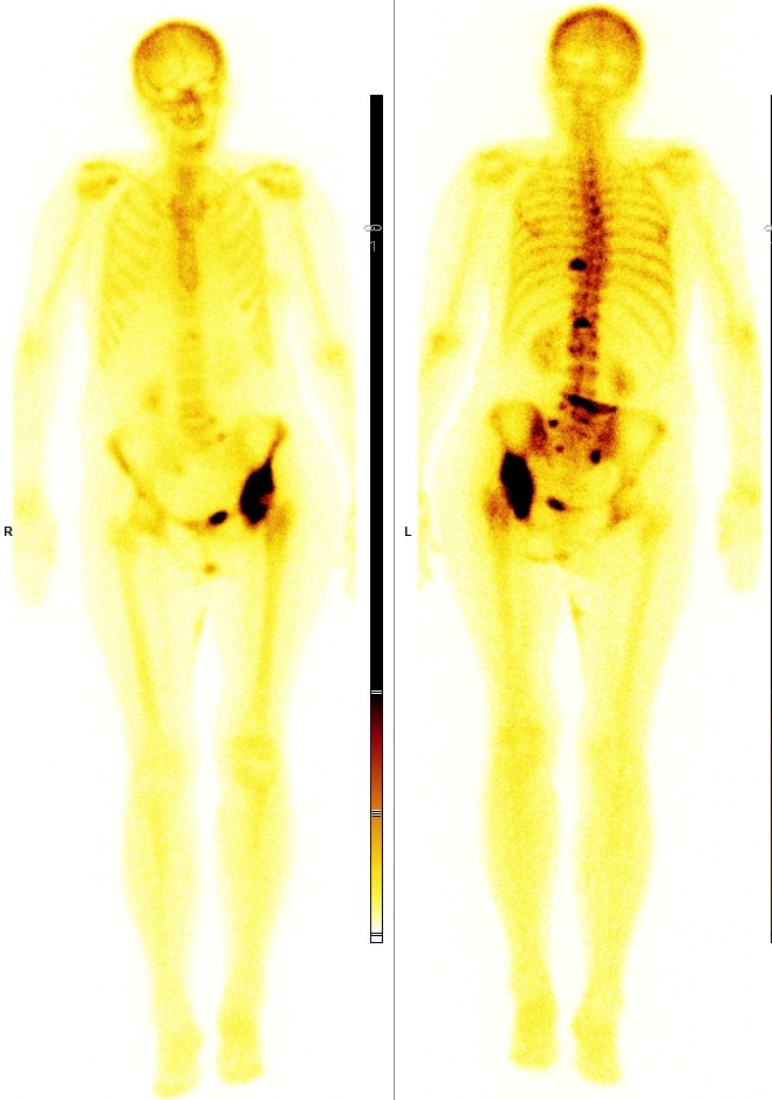


Bone scan – SPECT/CT

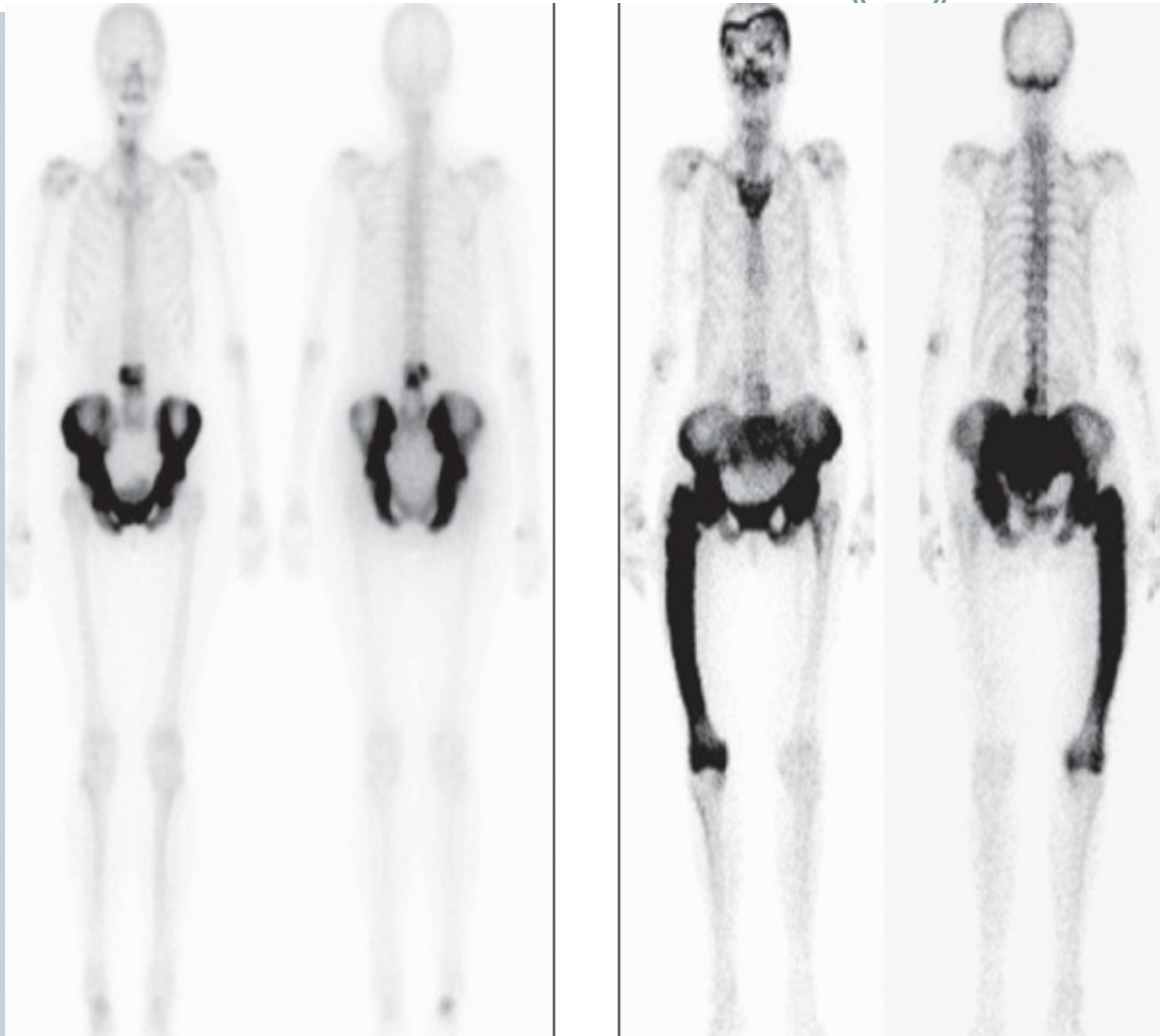


Bone scan – SPECT/CT

Lung cancer



Paget disease



- The pelvis is the most commonly involved site, followed by the spine, skull, femur...

Infection imaging methods



- 3-phase bone scintigraphy – bones only!
- Radiolabeled leukocytes
- Radiolabeled antigranulocyte monoclonal antibodies
- ^{18}F -FDG PET
- Gallium imaging (^{67}Ga galium citrate) – has very limited role today

3-phase bone scintigraphy



Indication: differentiation between osteomyelitis and cellulitis (especially in peripheral skeleton), evaluation of joint replacement complications (aseptic loosening or infection)

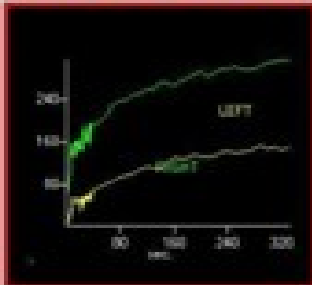
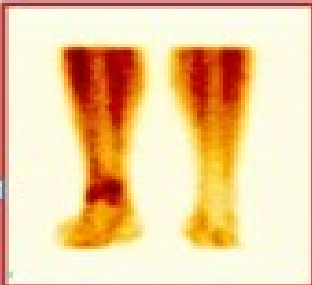

Imaging protocol:

- I. Flow phase: dynamic 2- to 5-second images of the area of interest for 60 seconds after bolus injection
- II. Blood pool and soft tissue phase = immediate static images for time (usually 5 minutes), followed dynamic phase
- III. Skeletal phase : Delayed images at 2-4 hours after injection
- SPECT/CT increases specificity
- Without underlying bone pathology negative study result excludes osteomyelitis with high degree of certainty
- With underlying bone pathology (recent trauma, tumor..) is still sensitivity very high, but specificity only 30-50%

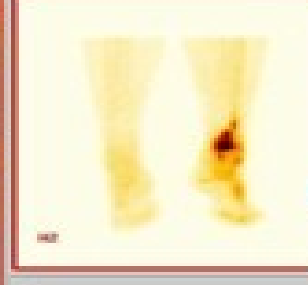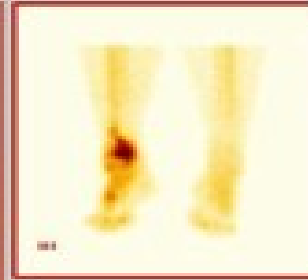
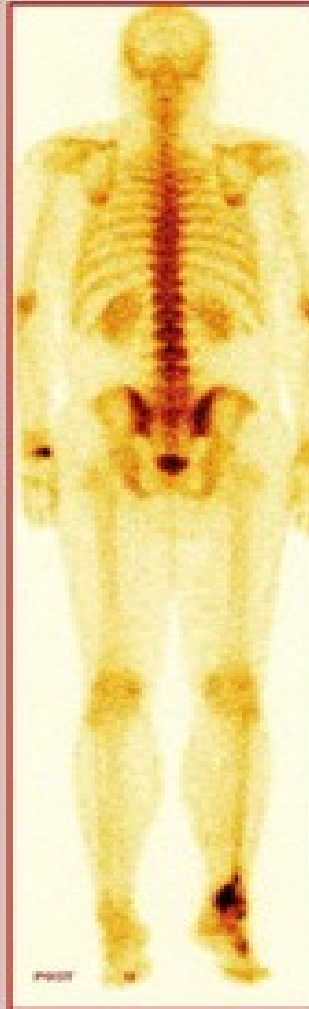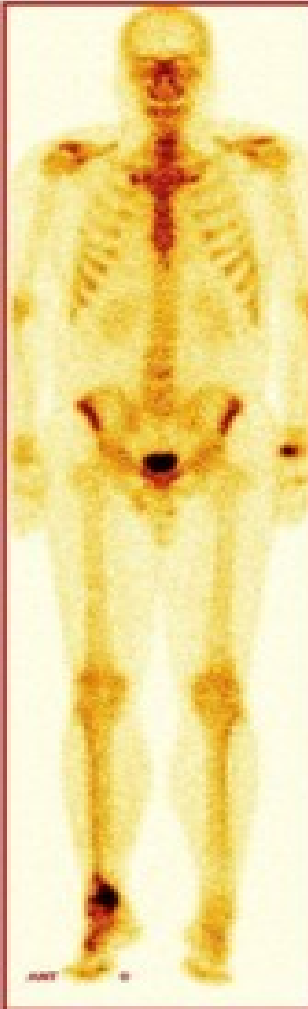3-phase bone scintigraphy



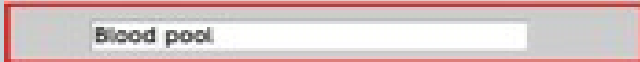
Dynamic flow



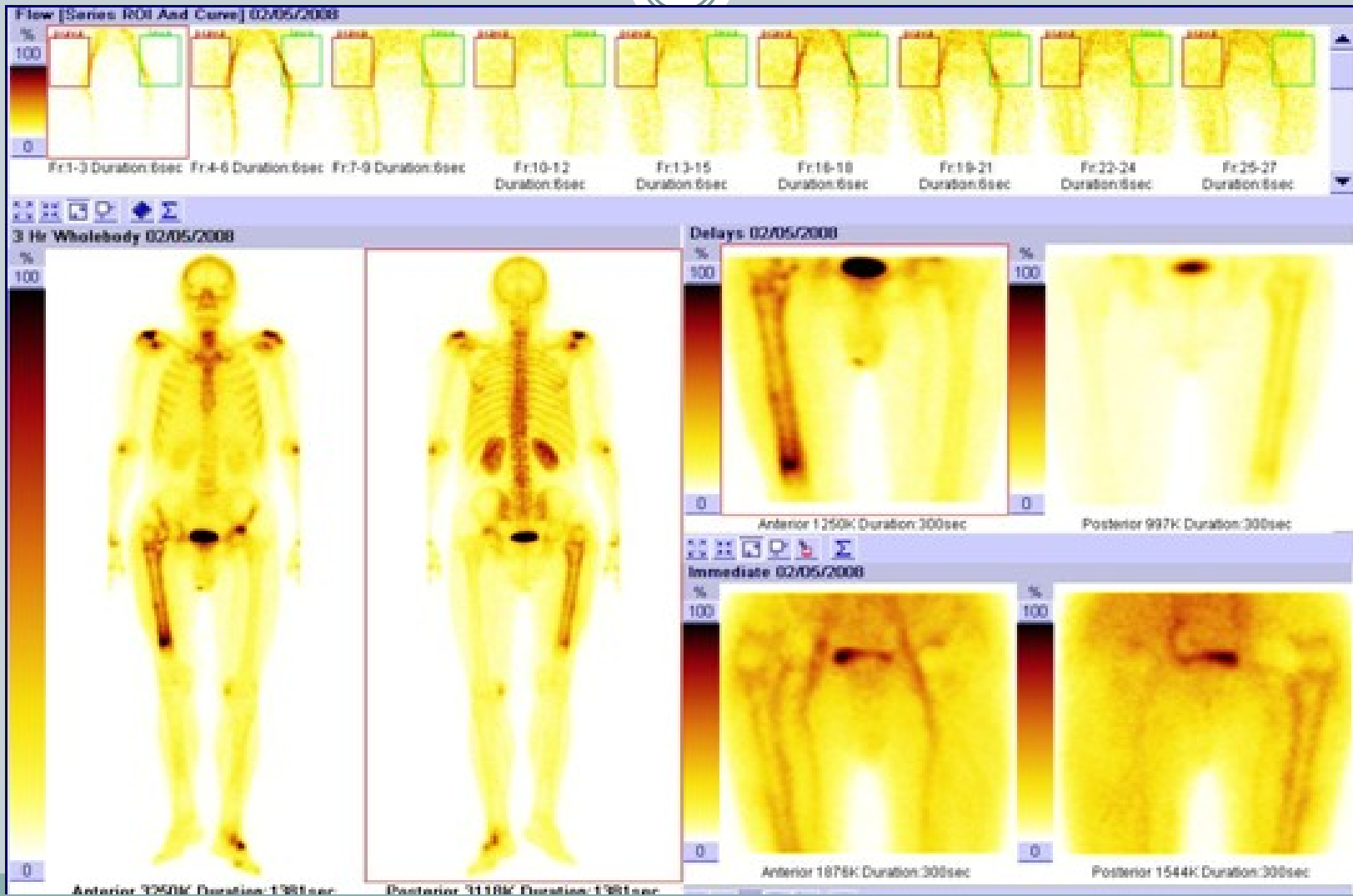
Late images



Blood pool



3-phase bone scintigraphy



Radiolabeled leukocytes

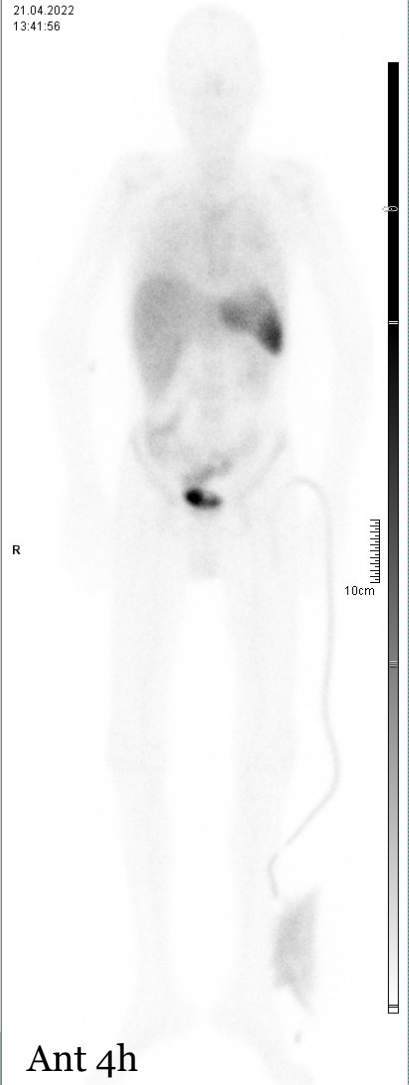

- Leukocyte imaging using in vitro labeling with ^{111}In or $^{99\text{m}}\text{Tc}$ is the nuclear medicine gold standard for diagnosing most infection
- **Principle:** leukocytes are attracted to the site of inflammation – active migration, uptake is not specific for infection, may occur in any inflammatory process that incites the leukocytes response
- Leukocytes are isolated from about 60ml anticoagulated blood, labelled in vitro, effectiveness depends on viability, thus is essential to avoid damage to the cells
- (If not possible to label enough leukocytes, examination with radiolabeled antigranulocyte monoclonal antibodies is possible, needs HAMA test, imaging protocol is same)
- **Imaging protocol:** wholebody image in anterior and posterior view at 4 and 24 hours after injection + SPECT/CT, early imaging of the abdomen at 1- 2 hours after injection is obtain in case of inflammatory bowel disease
- **Indication:** acute pyogenic infection, fever of the unknown origin, osteomyelitis, prosthetic joint infection, vascular grafts infection...
- ! MR is the method of the choice once there is a suspicion for spine osteomyelitis and no other underlying bone pathology

Radiolabeled leukocytes

Anterior_Leukocytv

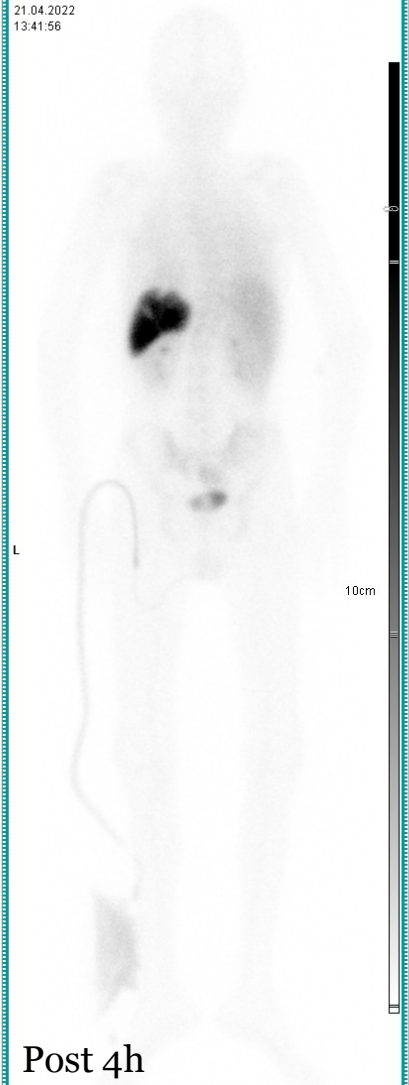21.04.2022
13:41:56



Ant 4h

Posterior_Leukocytv

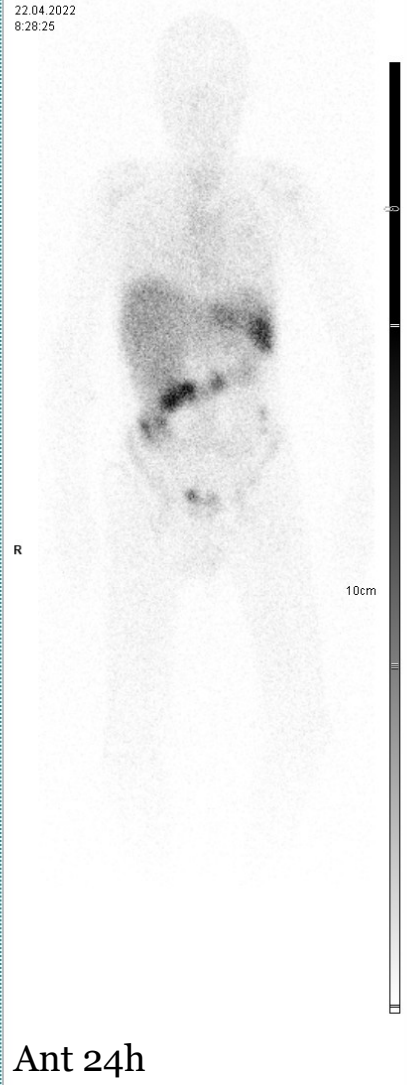21.04.2022
13:41:56



Post 4h

Anterior_Leukocytv_01

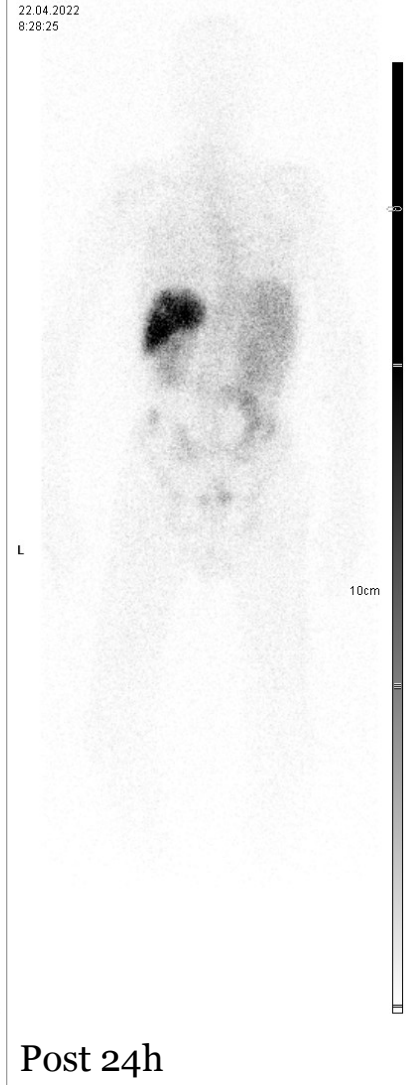
22.04.2022
8:28:25



Ant 24h

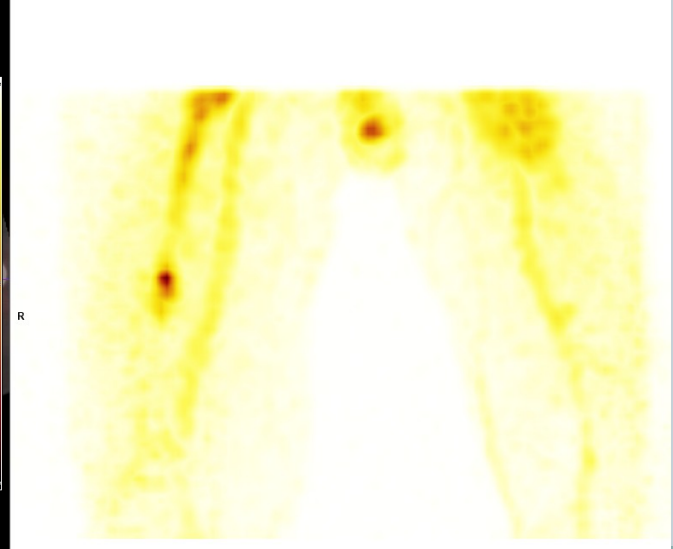
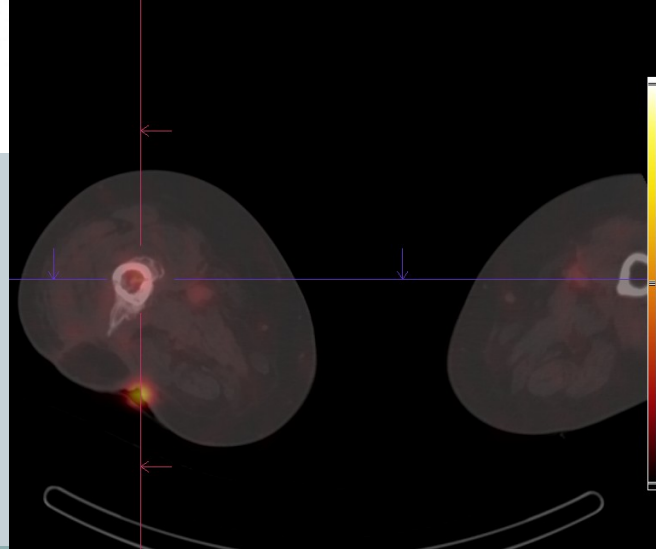
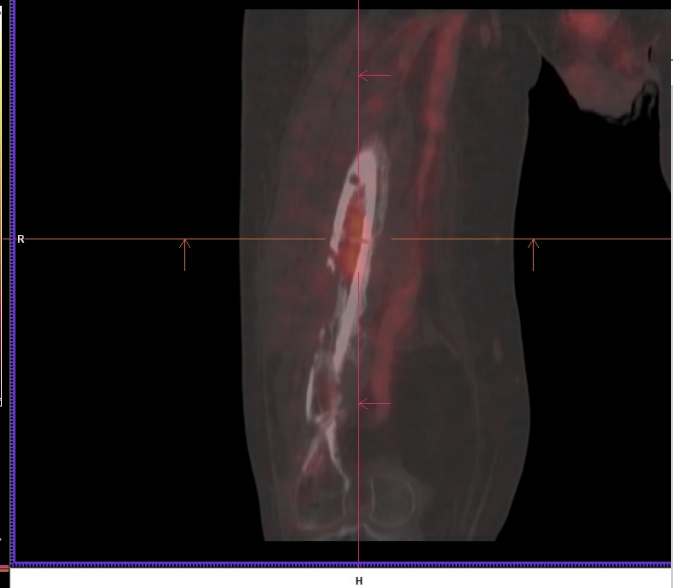
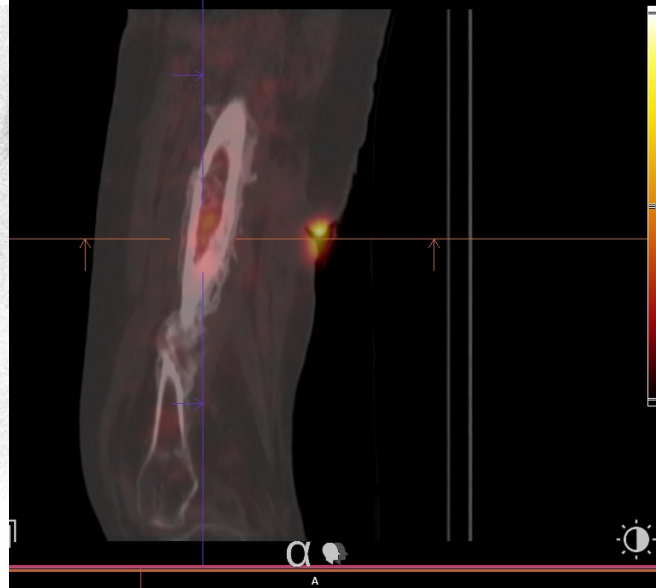
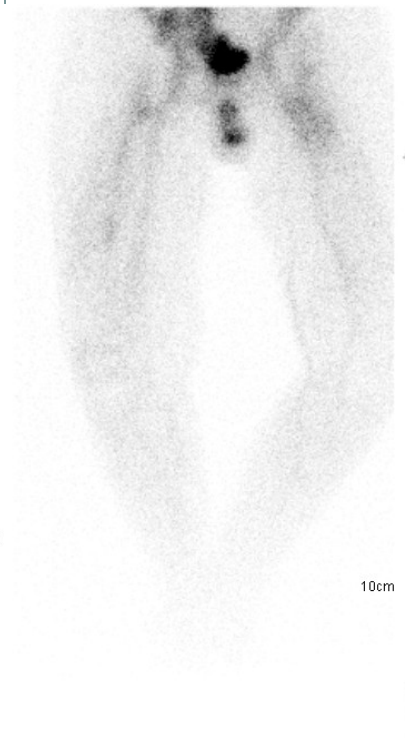Posterior_Leukocytv_01

22.04.2022
8:28:25



Post 24h

Radiolabeled leukocytes



Post removal of OS,
infection in soft tissues
without osteomyelitis

Respiratory system – nuclear imaging methods



- **Perfusion study** : ^{99m}Tc -MAA macroaggregated albumin- displays regional lung perfusion
- **Ventilation study**: radiolabeled aerosols (^{99m}Tc -DTPA), radioactive gases ($^{81m}\text{Krypton}$) - display regional lung ventilation
- **^{18}F -FDG PET/CT, PET/MR** : lung carcinoma, infection

Perfusion a ventilation scintigraphy

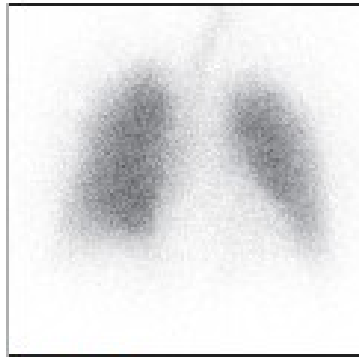


- **Indication**: assess the **probability of pulmonary embolism**, assess regional lung perfusion before lung surgery (semiquantitative evaluation)
- **Imaging**: traditionally perfusion+ventilation (V/Q scan) - V/Q Mismatch
- **SPECT/low-doseCT** perfusion only
 - Ventilation in unclear cases only
- Many centers performed both the perfusion and ventilation studies, clinical experience show that perfusion study by performing SPECT/CT is fully sufficient (depends on clinical context, technical equipment...)
- R-L shunt may be demonstrated at images (activity is seen in the brain, kidneys)

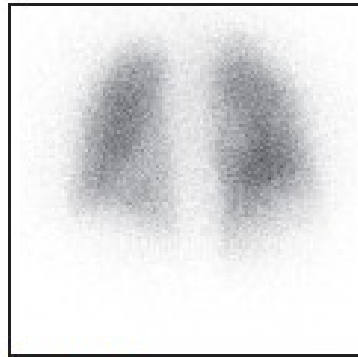
Perfusion ventilation study



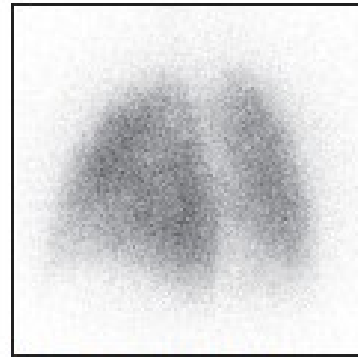
Diagnosis of PTE using ^{81m}Kr and ^{99m}Tc -MAA



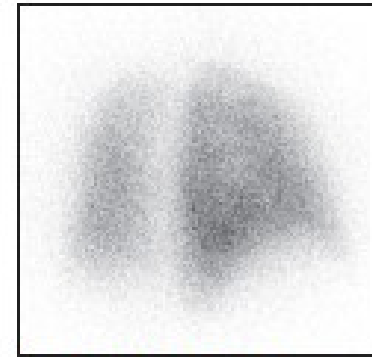
(A) Anterior



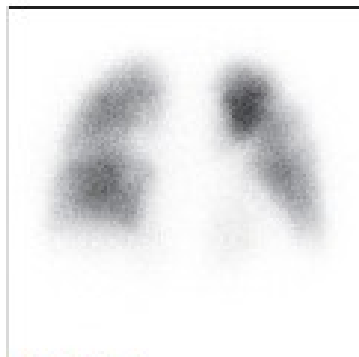(B) Posterior



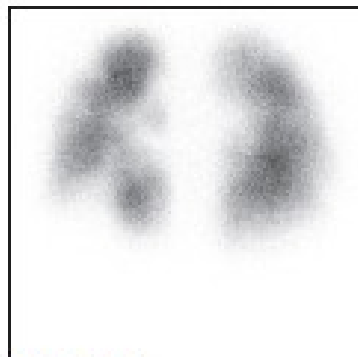
(C) Left posterior oblique



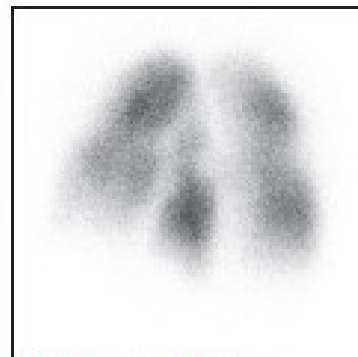(D) Right posterior oblique



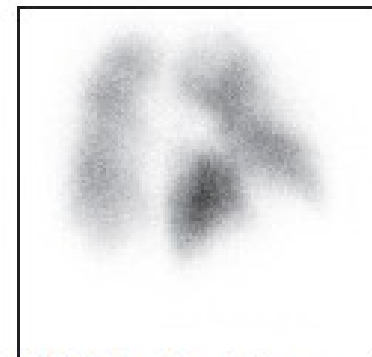(E) Anterior



(F) Posterior

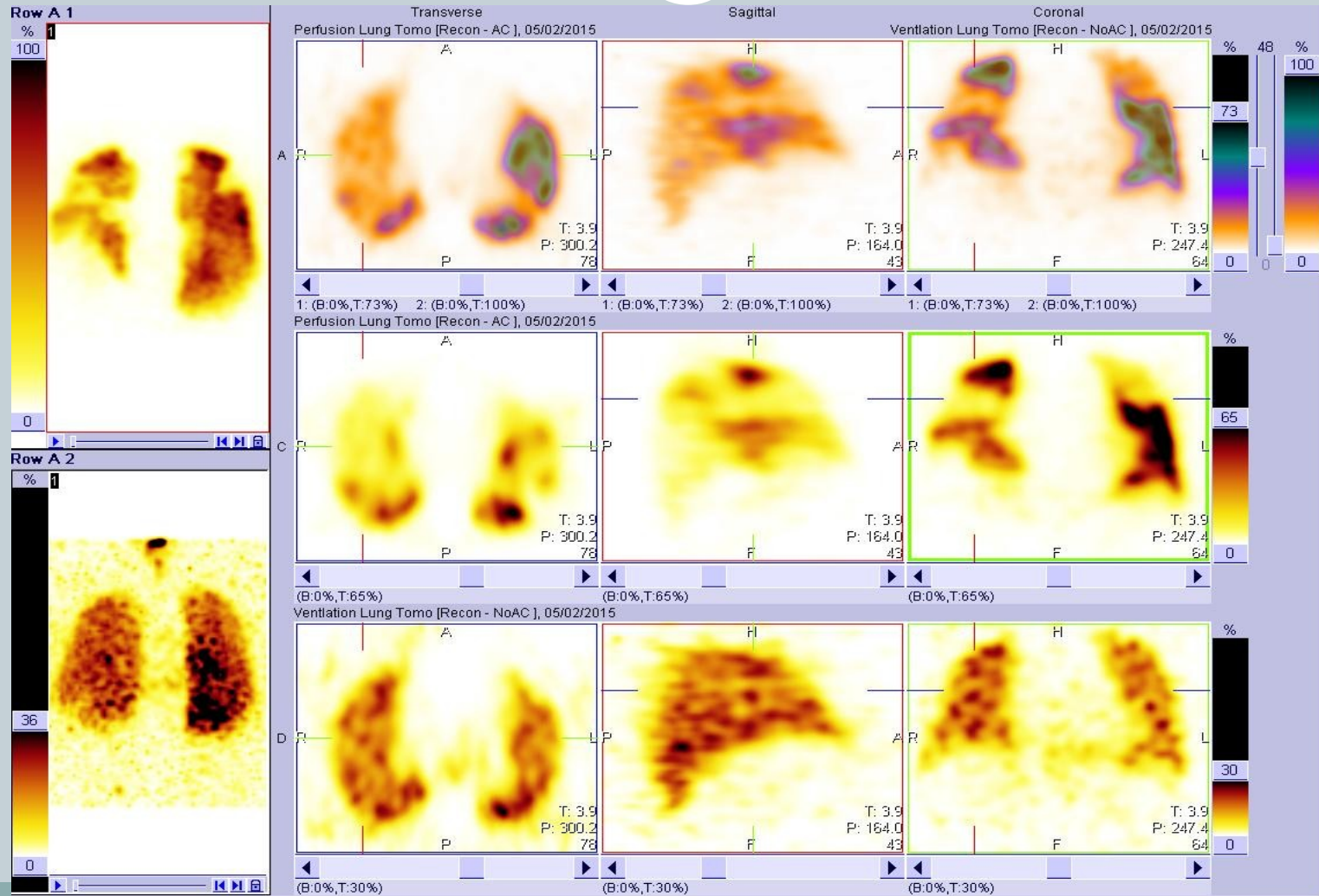


(G) Left posterior oblique

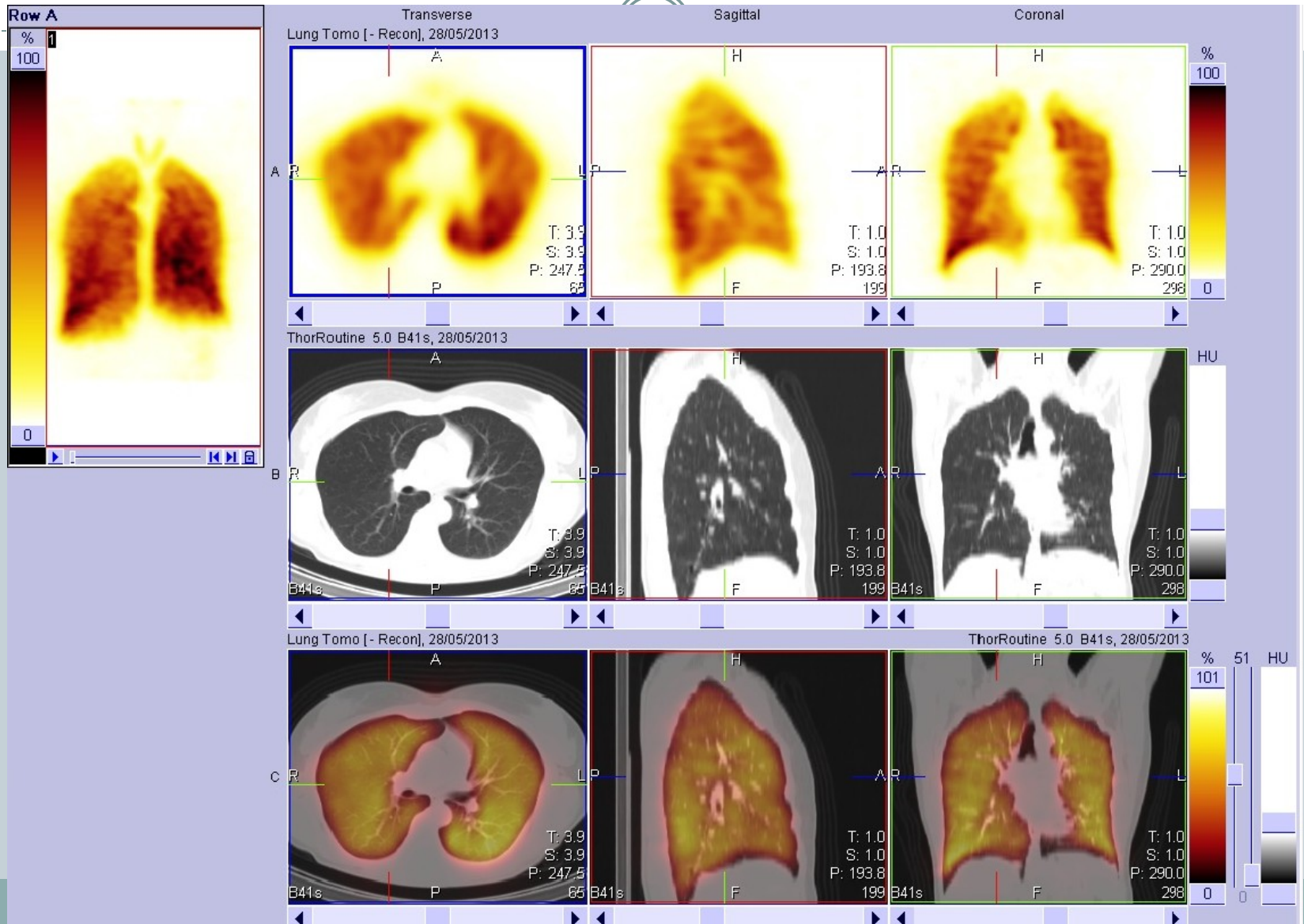


(H) Right posterior oblique

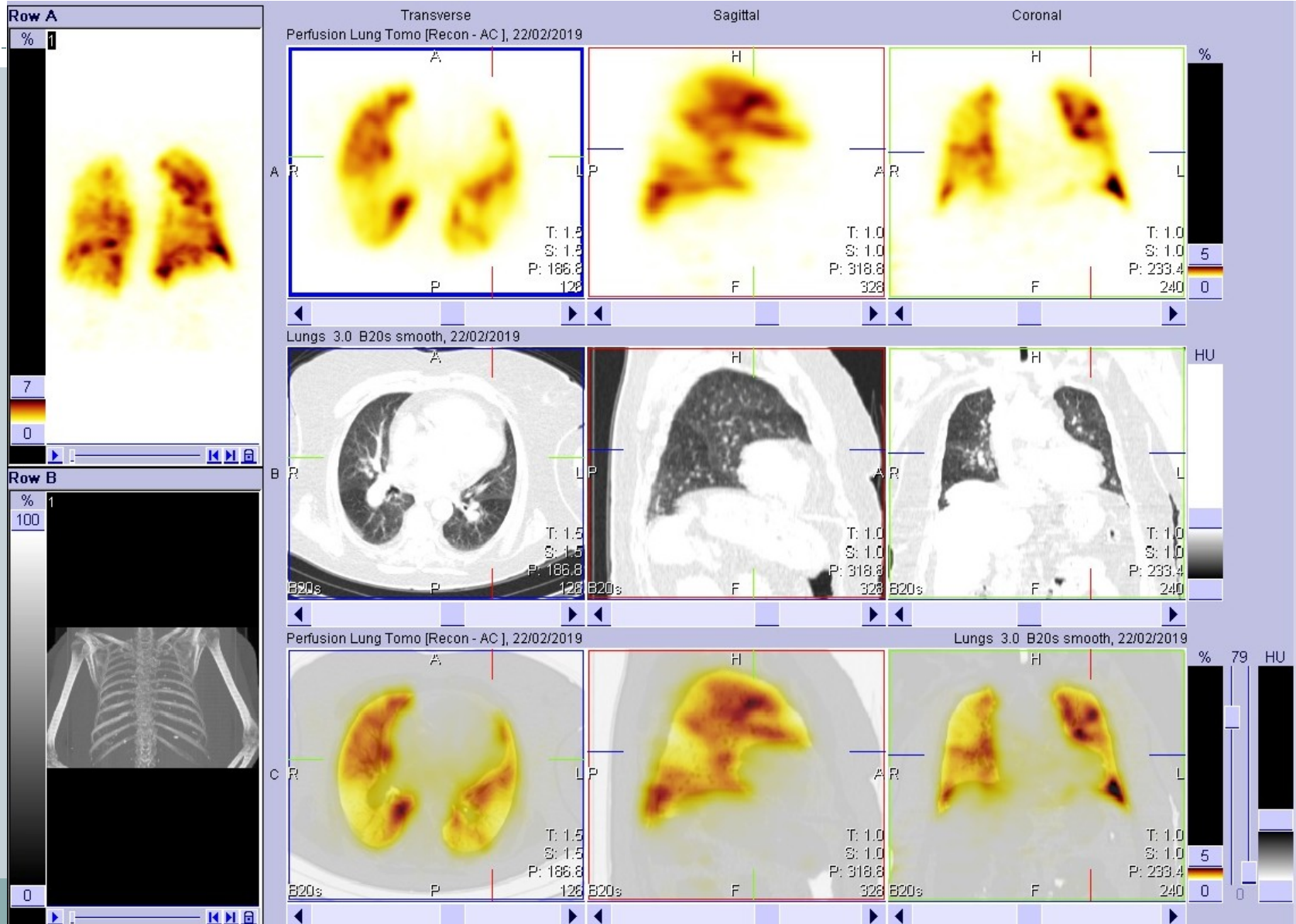
Perfusion ventilation study SPECT



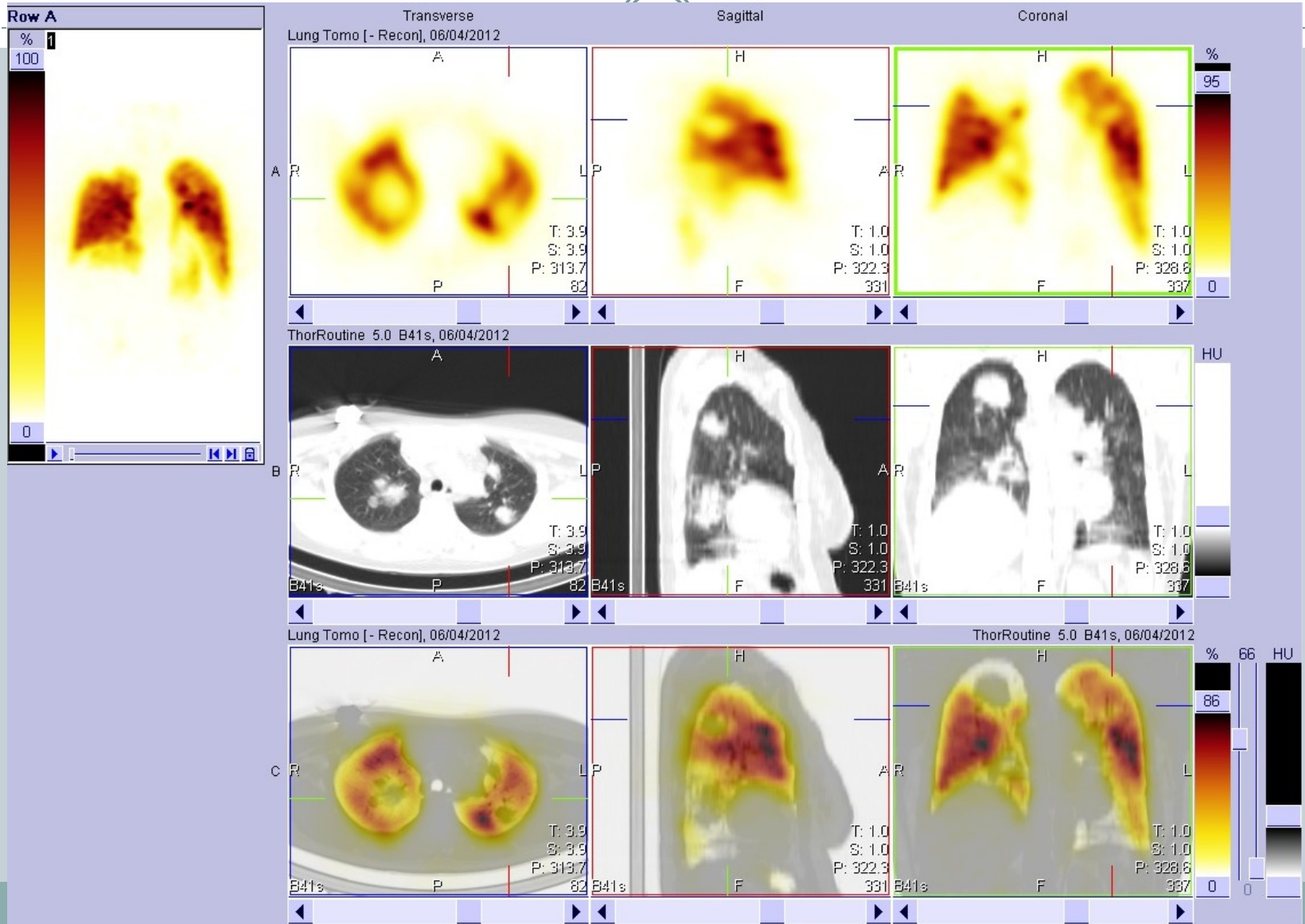
Lung perfusion study, SPECT/CT



Lung perfusion study, SPECT/CT



Lung perfusion study, SPECT/CT



Thyroid imaging



- RP: $^{99\text{m}}\text{TcO}_4$ (technetium pertechnetate), ^{123}I , ^{131}I
- Planar images, SPECT, SPECT/CT

Thyroid scintigraphy - indication




- **Hyperthyroidism** : autonomous/toxic adenoma, Graves disease, subacute thyreoiditis, compensatory low level TSH due to another disease
- **Thyroid nodules** : to determine their functional status
- **Detection of the ectopic thyroid tissue, evaluation of the retrosternal tissue mass (retrosternal goiter, lingual thyroid, struma ovarii)**
- **Thyroid cancer (^{123}I , ^{131}I) staging**

Therapy I 131



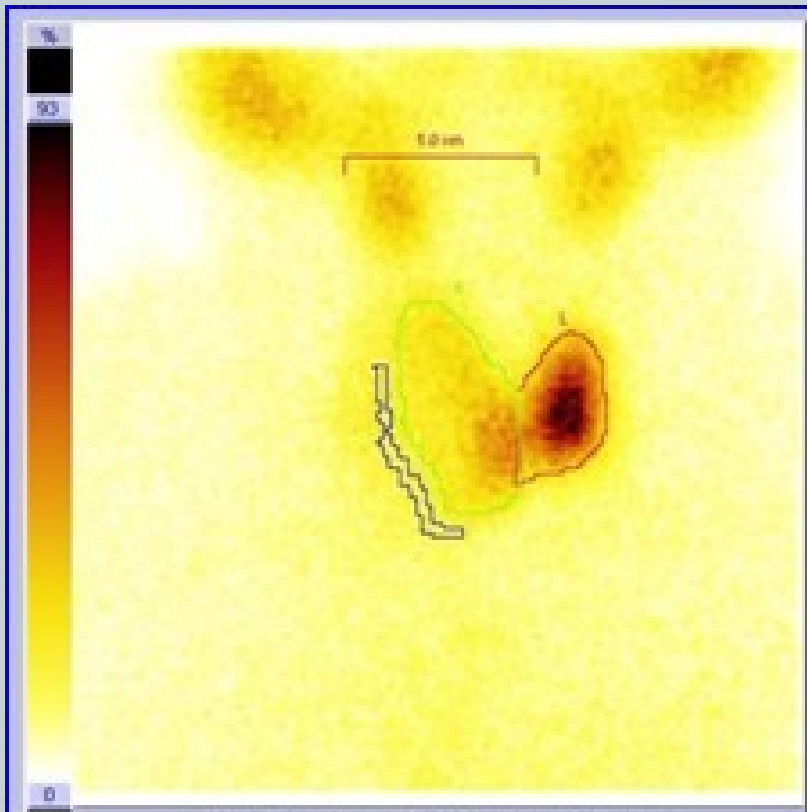
- Hospitalization required
- **Malignant** - patients with **differentiated thyroid cancer**:
- Elimination of residues and micrometastases after TTE
- Therapy of metastases found on follow up dg. scan with I131
- **Benign:**
- Autonomous adenoma
- Relapse of autoimmune hyperthyroidism (Graves-Basedow) without endocrine orbitopathy

Thyroid scintigraphy – normal finding




Thyroid study


Cold nodule



Toxic adenoma



1.54 On the original scan there is a single toxic nodule, with total suppression of the remainder of the gland. On the scan obtained following radiiodine therapy, the nodule is still visualised, although there has been some return of activity to the rest of the gland. This example represents partial resolution of a toxic nodule.

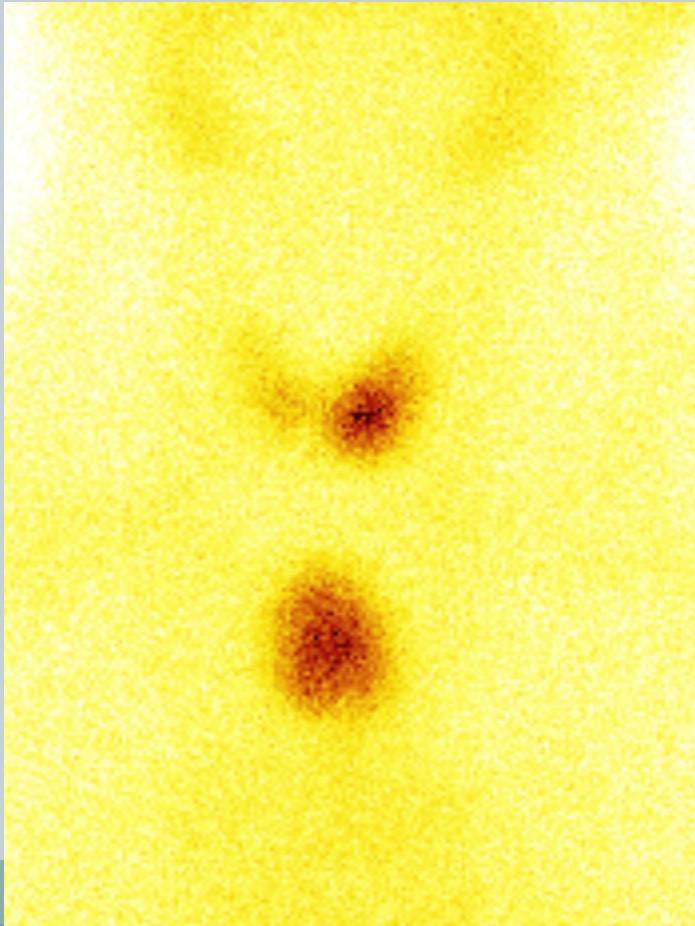


Thyroid scintigraphy

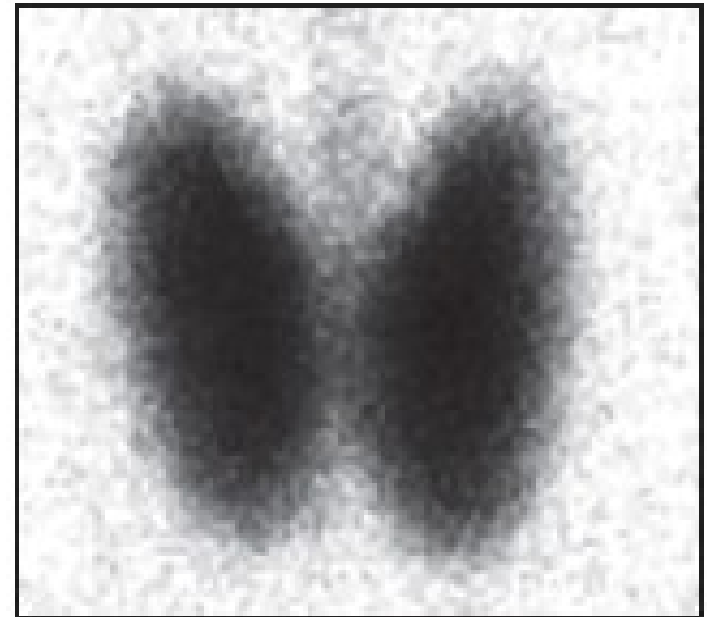

**Ectopic thyroid -
substernal**

Graves-Basedow disease



Diffuse toxicity: Graves' disease



¹²³I-TCO₂ thyroid scan

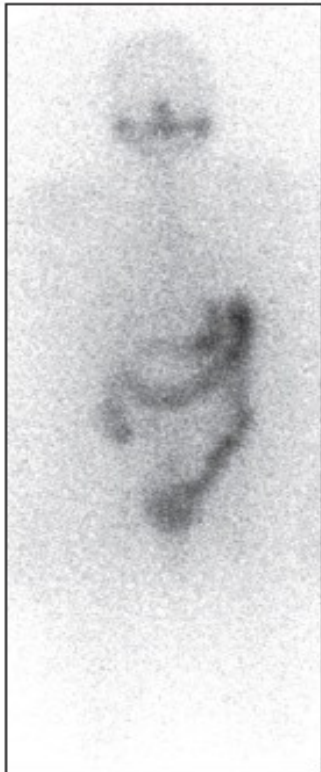Iodine 131



^{131}I – normal finding

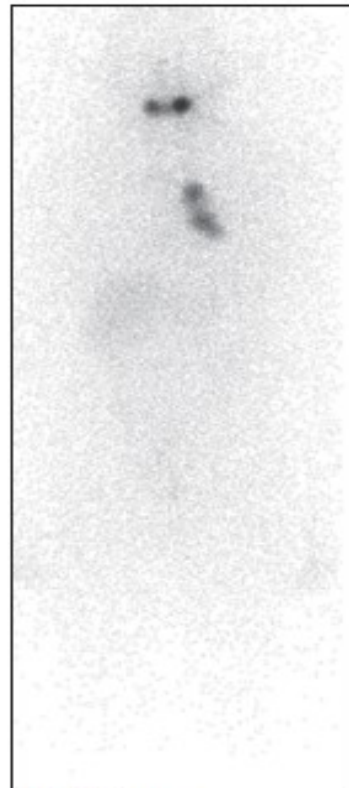^{131}I -dissemination

^{131}I whole-body scan: normal bi

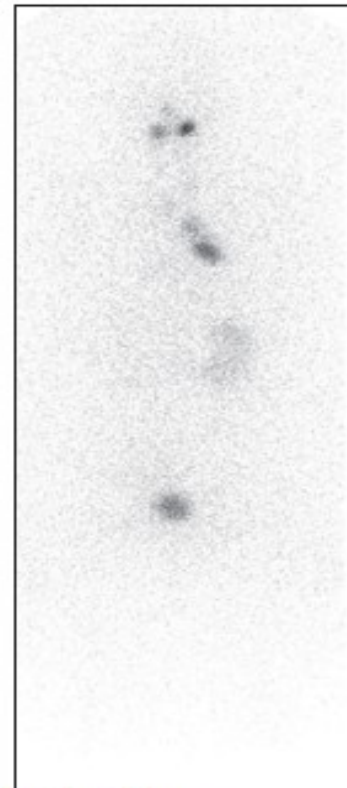


^{131}I whole body

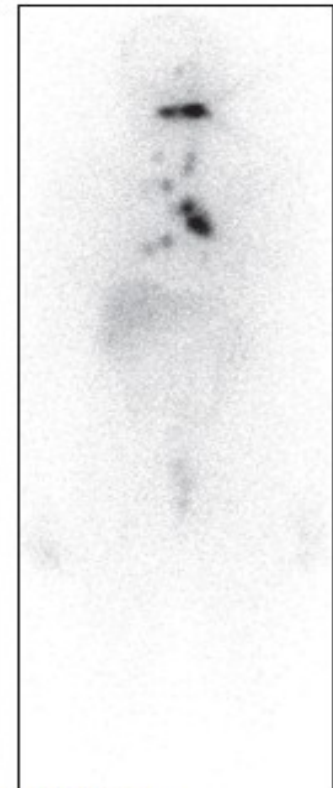
Progressive lung metastases



(A) First ^{131}I scan



(B) Second ^{131}I scan



(C) Third ^{131}I scan

Parathyroid scintigraphy

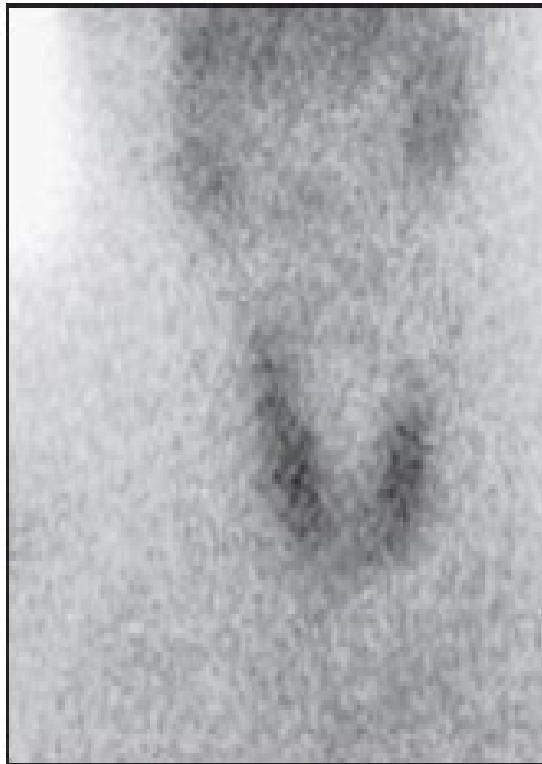

- **Indication:** preoperative localization of hyperfunctioning parathyroid glands making possible minimally invasive surgery
- **RP:** ^{99m}Tc -MIBI – unspecific uptake in paratahyroid and thyroid gland
- **Protocol:**
 - Two-phase scan (^{99m}Tc -MIBI), initial images 10 min after injection, second set of images at 2 hours, there is more rapid washout fromt the thyroid, so delayed images show hyperfunctioning parathyroid gland)
 - Subtraction methodology (compares ^{99m}Tc -pertechnate study and ^{99m}Tc -MIBI study by digital subtraction)
- Planar images, but SPECT, SPECT/CT with better accuracy, localization of the parathyroid gland
- If unclear/negative result – possibility of ^{18}F -choline PET

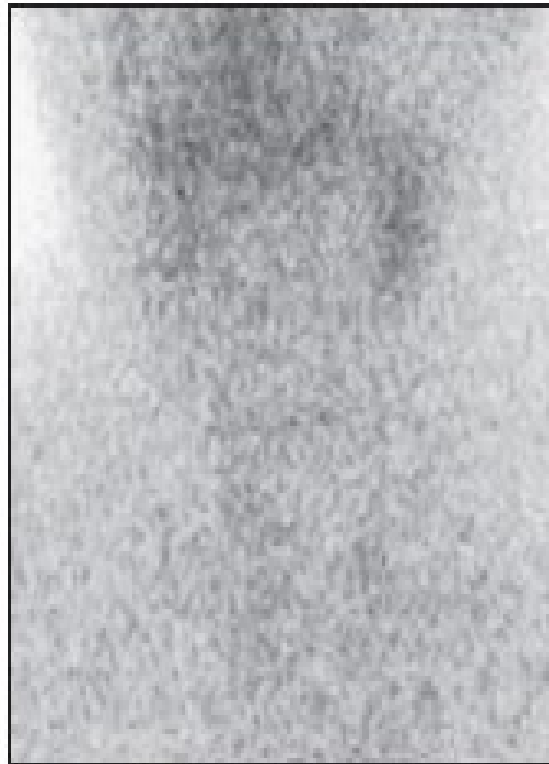MIBI normal finding



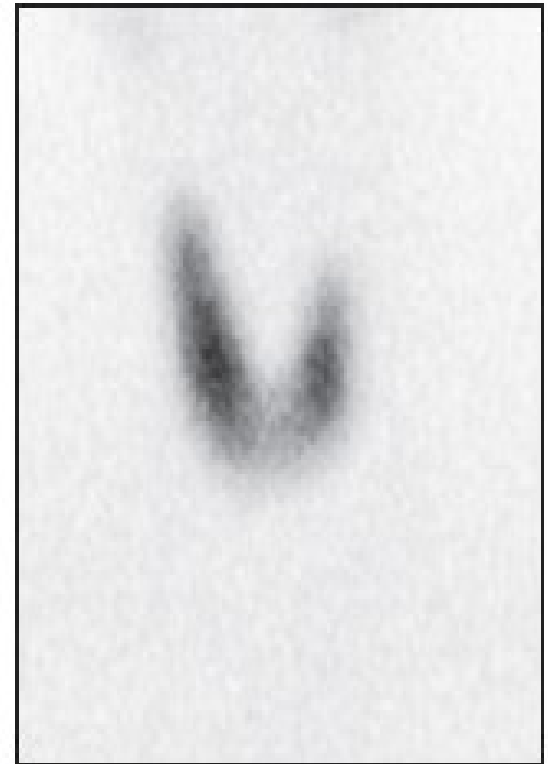
Normal dual-phase ^{99m}Tc -MIBI scan



(A) 15 minutes ^{99m}Tc -MIBI



(B) Delayed 2 hours ^{99m}Tc -MIBI

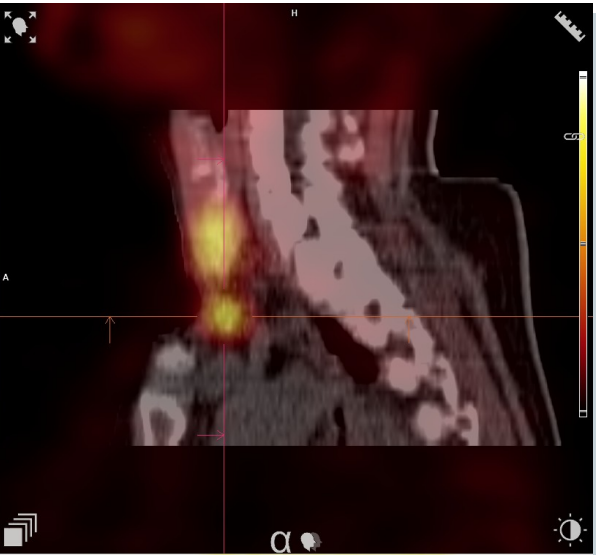
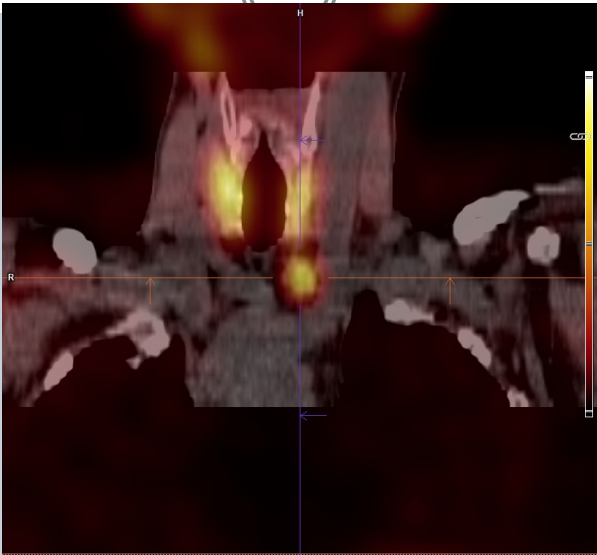
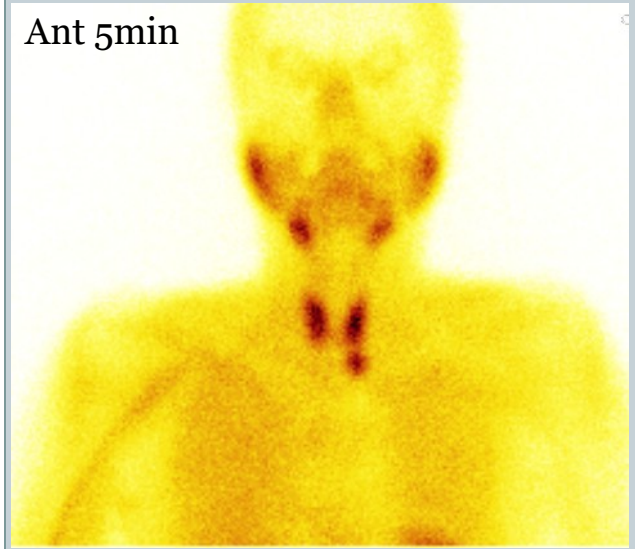

(C) $^{99m}\text{TcO}_4$

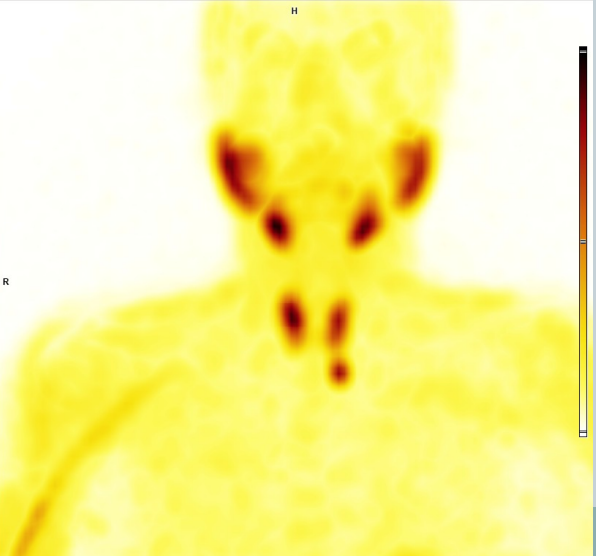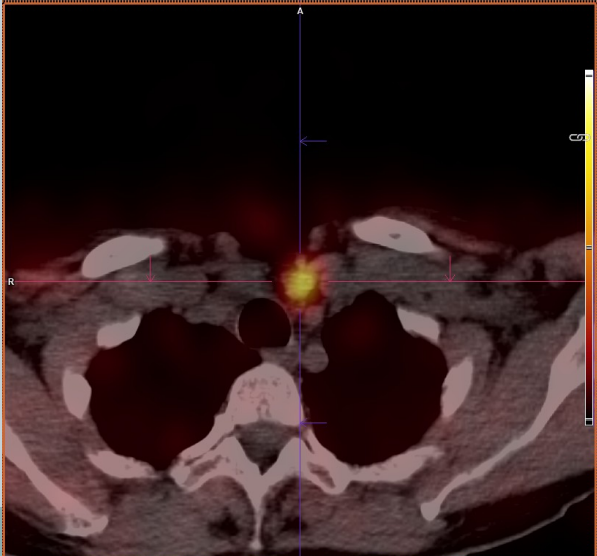
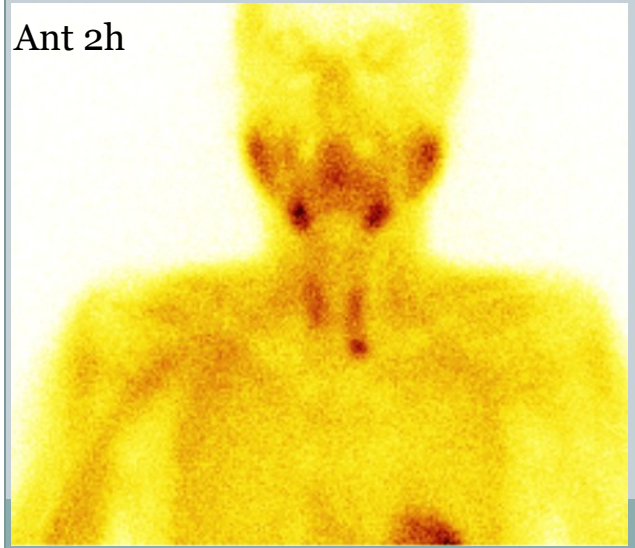
MIBI adenoma



Ant 5min



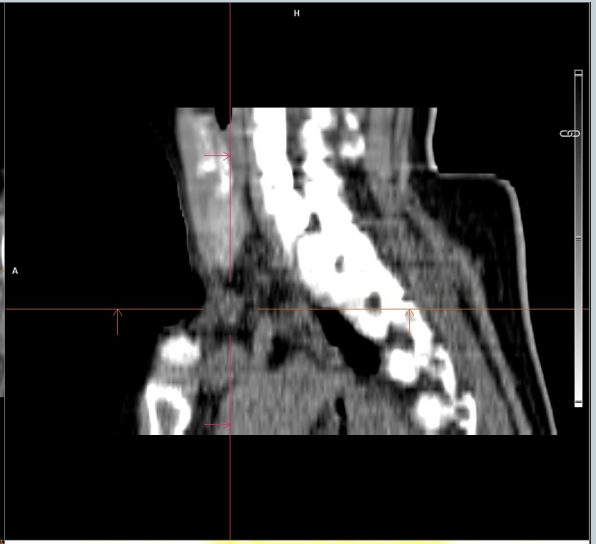
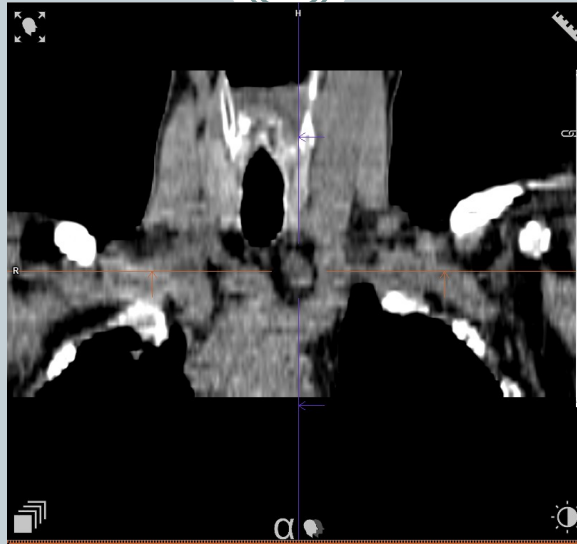
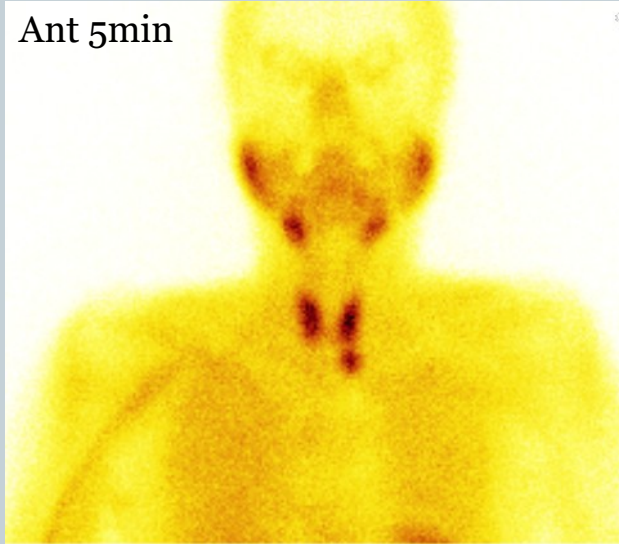
Ant 2h



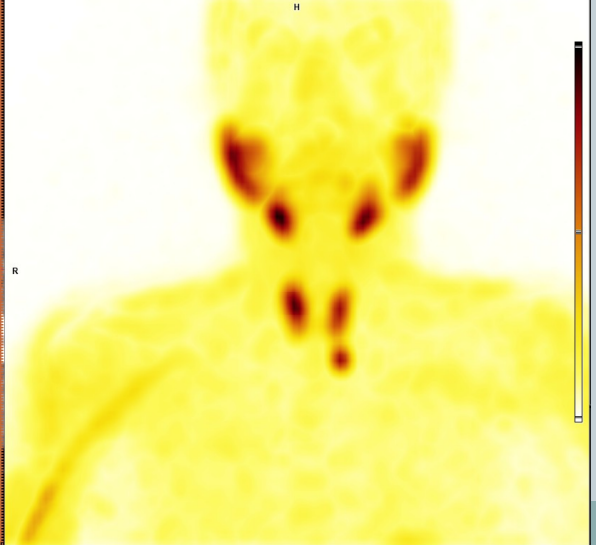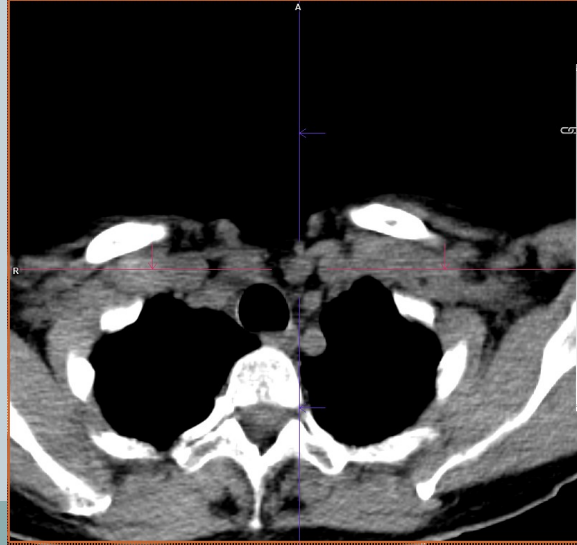
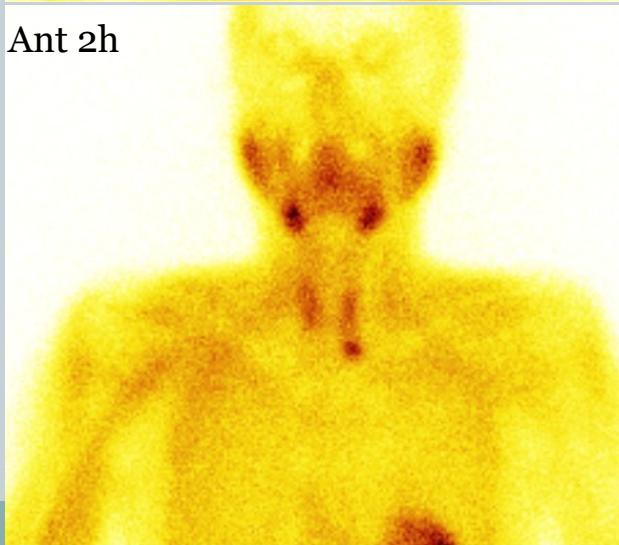
MIBI adenoma



Ant 5min



Ant 2h



Central nervous system

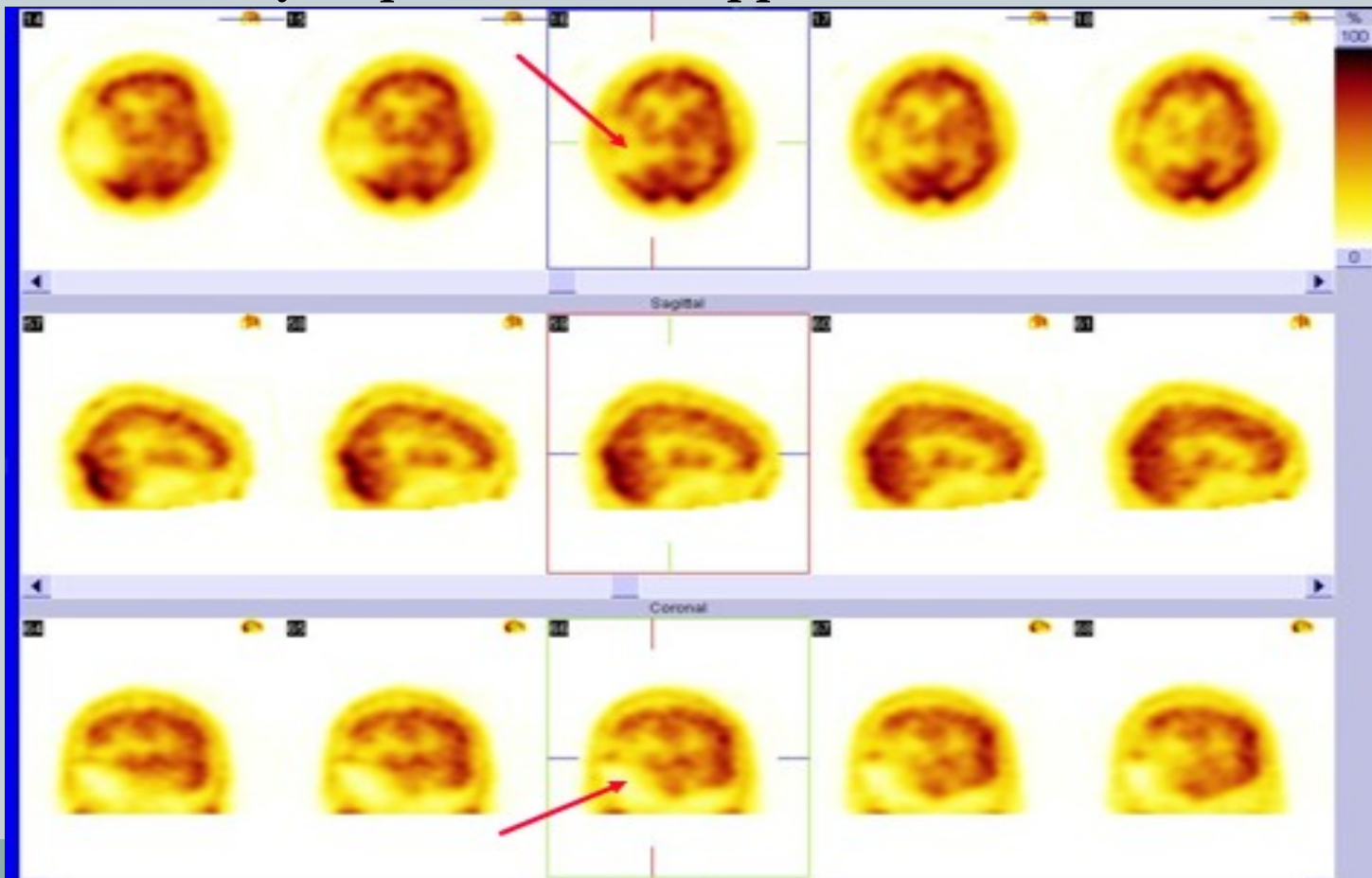


- **Brain perfusion imaging**
 - Epileptogenous focus, Brain death, evaluation of cerebrovascular reserve,, dementia (AD, vascular,...)
- **Neuroreceptor imaging - DaTscan**
 - Parkinson disease and syndromes, essential tremor, Dementia with Lewy Bodies
- **(Cerebrospinal fluid imaging)**
 - Evaluation of suspected CSF leaks, investigation of suspected communicating hydrocephalus (normal-pressure hydrocephalus), verification of CSF shunt patency
- **PET : Amyloid imaging, 18F- FDG, 18-F-FLT....**

Brain perfusion



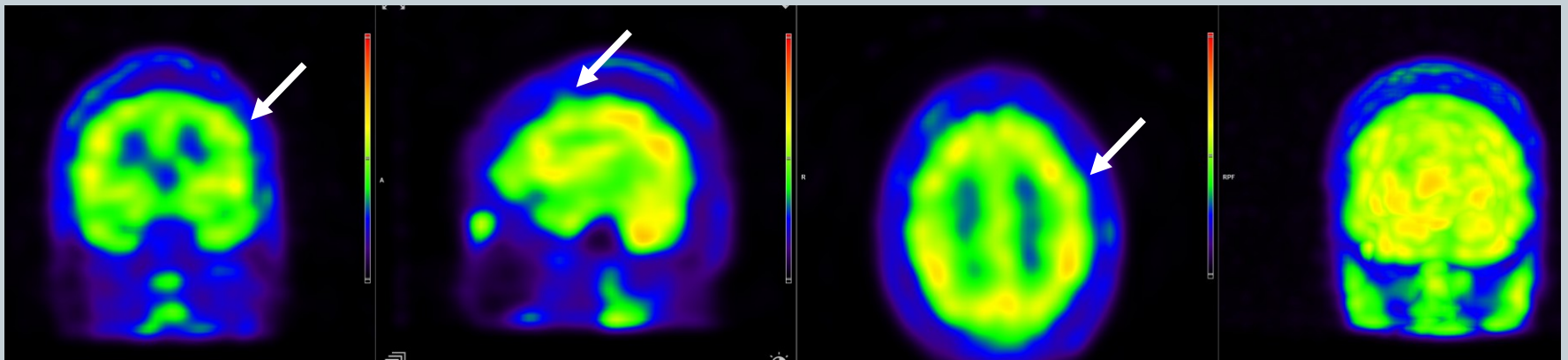
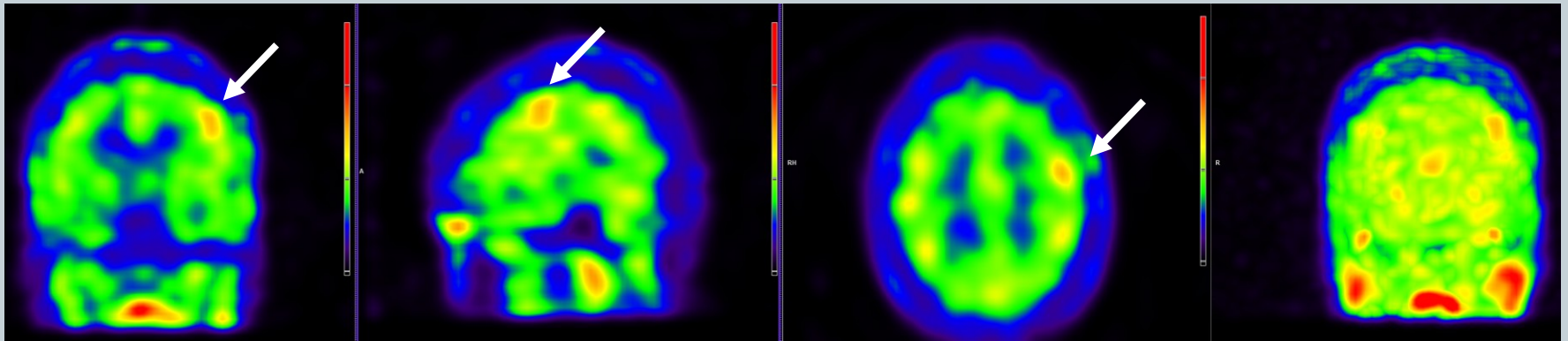
RP: ^{99m}Tc -HMPAO – lipophilic, crosses blood–brain barrier, enter neurons, becomes hydrophilic and is trapped



Brain perfusion – epilepsy



Ictal



Interictal

Brain death



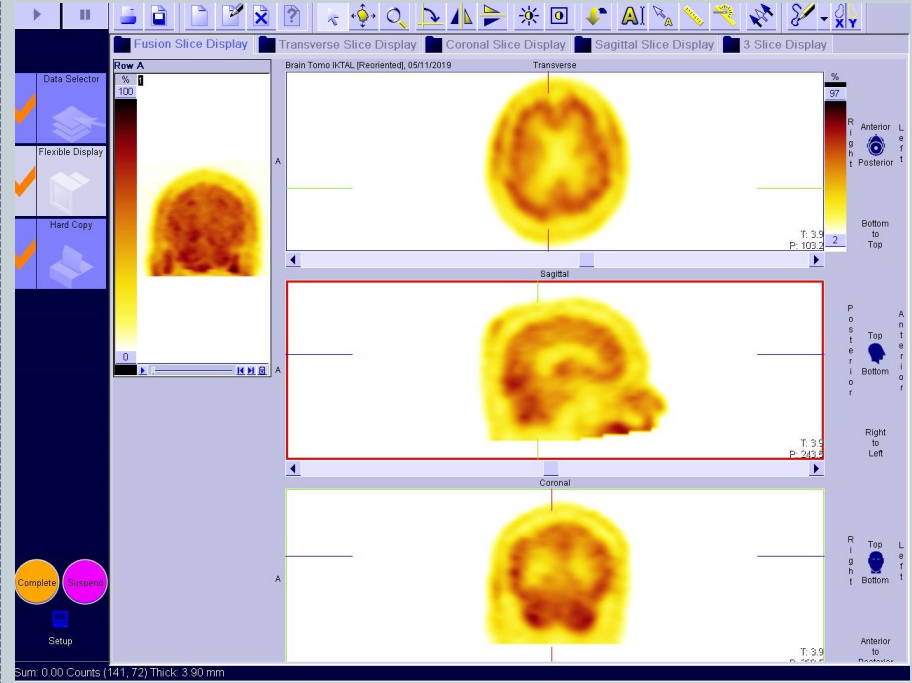
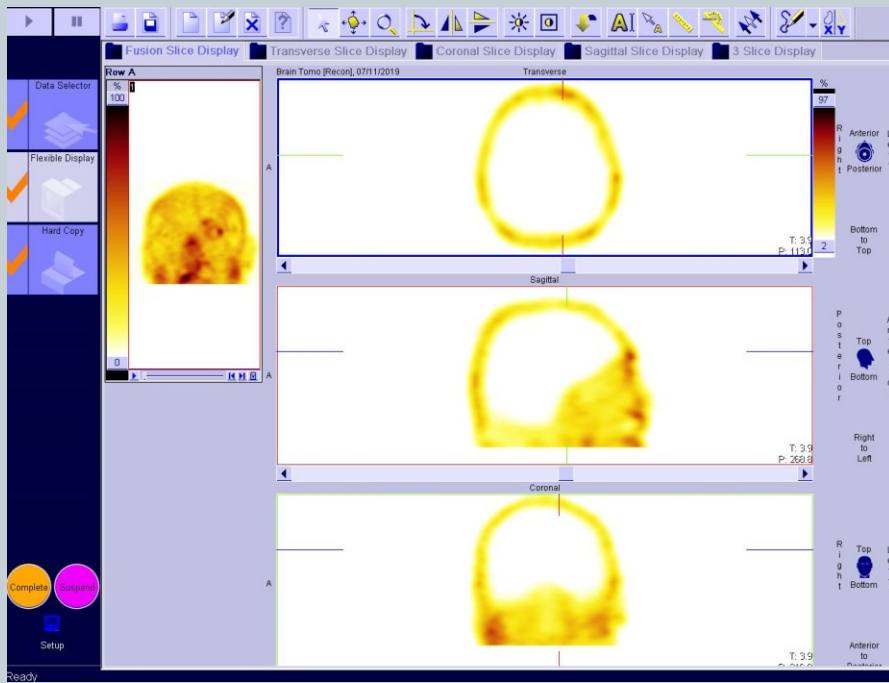
- Imaging methods for diagnosing brain death: Brain perfusion study, angiography, CT angiography, transcranial Doppler ultrasound
- **Criteria for brain death (brain perfusion study):** No intracerebral arterial, capillary or venous blood flow/tracer activity on the dynamic study, no visualisation of the sagittal sinus on immediate post-injected images (99mTc-HMPAO, 99mTc-ECD)
- **Protocol:** dynamic study, immediate post-injected images better in multiple projections, SPECT
- Advantages: No iodine contrast (possible nephrotoxic effect), simple intravenous injection, preferable in patients with lossy head injury or craniectomy (arteriography can be falsely negative)

Brain death



Positive

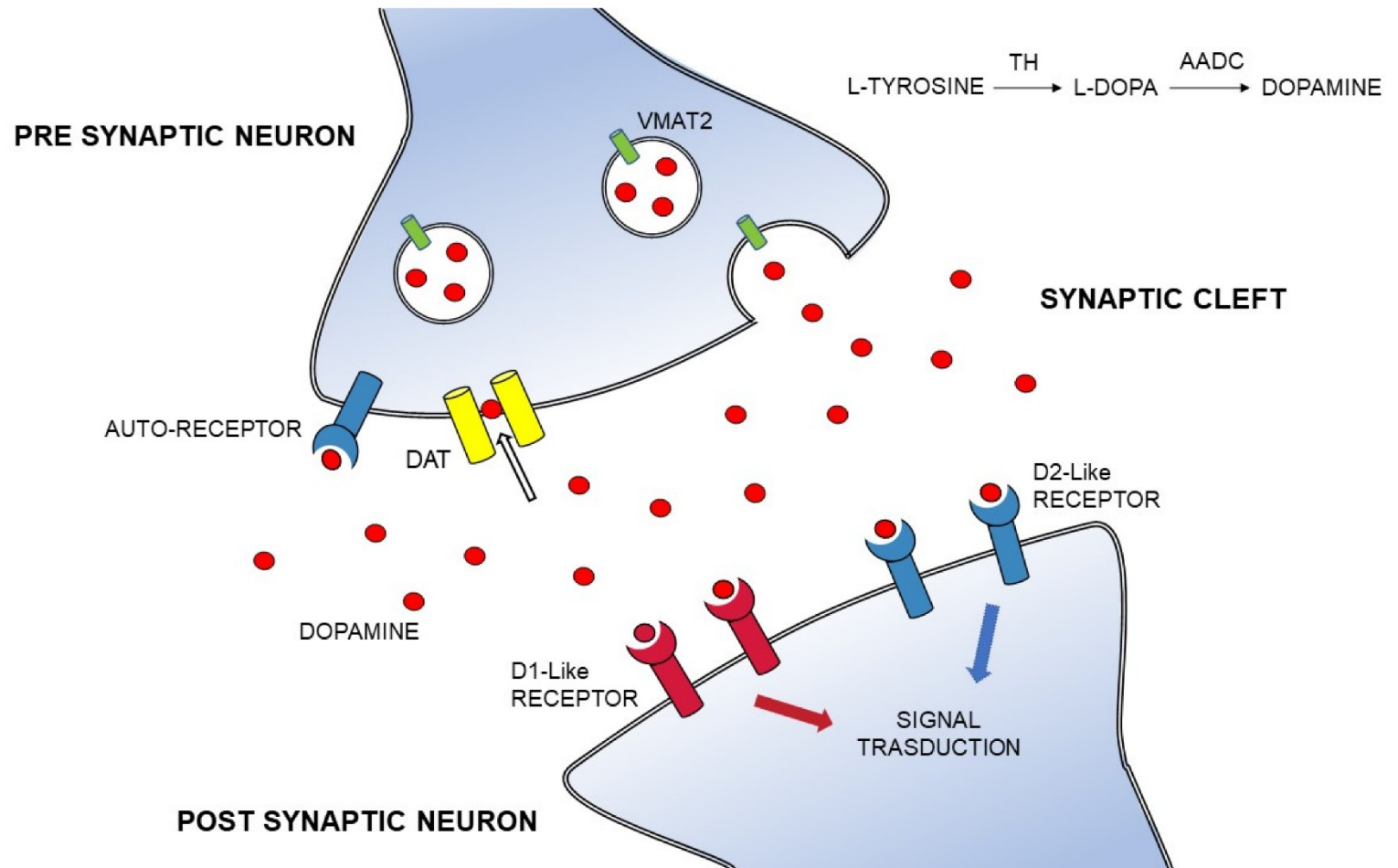
Negative



Datscan – ^{123}I Ioflupan



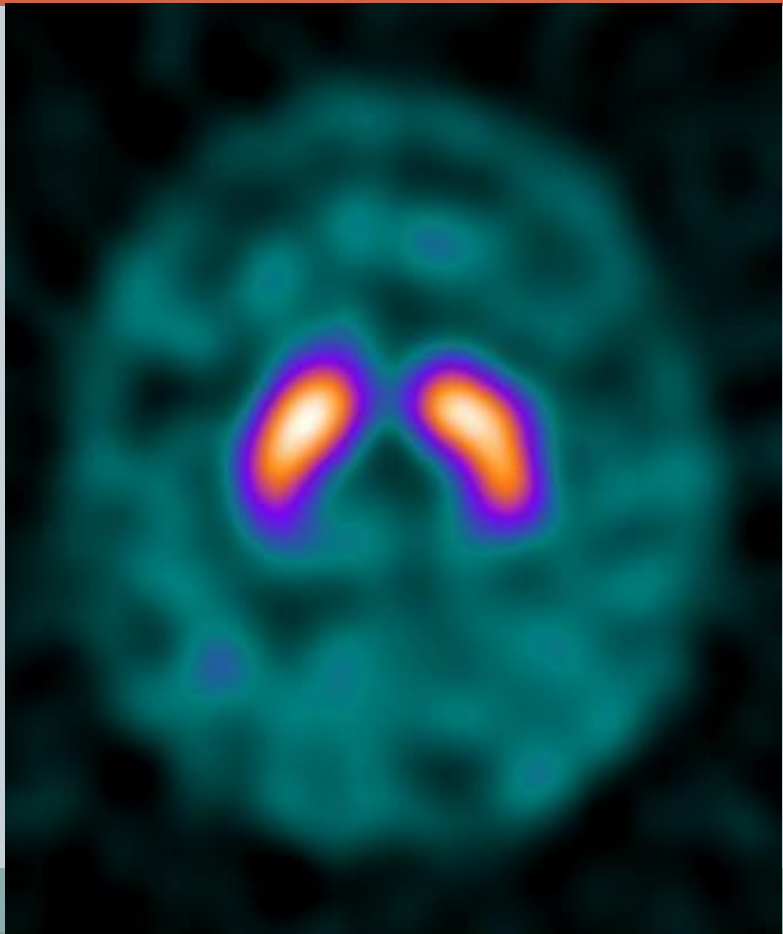
- Idiopathic Parkinson disease – degeneration of nigrostriatal pathways, impairment of afferent pathway from substantia nigra to BG = presynaptic impairment
- Parkinson's disease plus diseases (MSA, PSP...) - directly affected striatum, affected pre- and postsynaptically
- Essential tremor, parkinsonism secondary to medication = no dopamine synapse disorder
- **^{123}I -Ioflupan** : distribution of **presynaptic dopamine transporters**, cocaine analogue, thyroid blockade preparation
- **Indications:** differentiation of Parkinson's disease and Parkinson plus diseases from essential tremor, dg. dementia with Lewy bodies



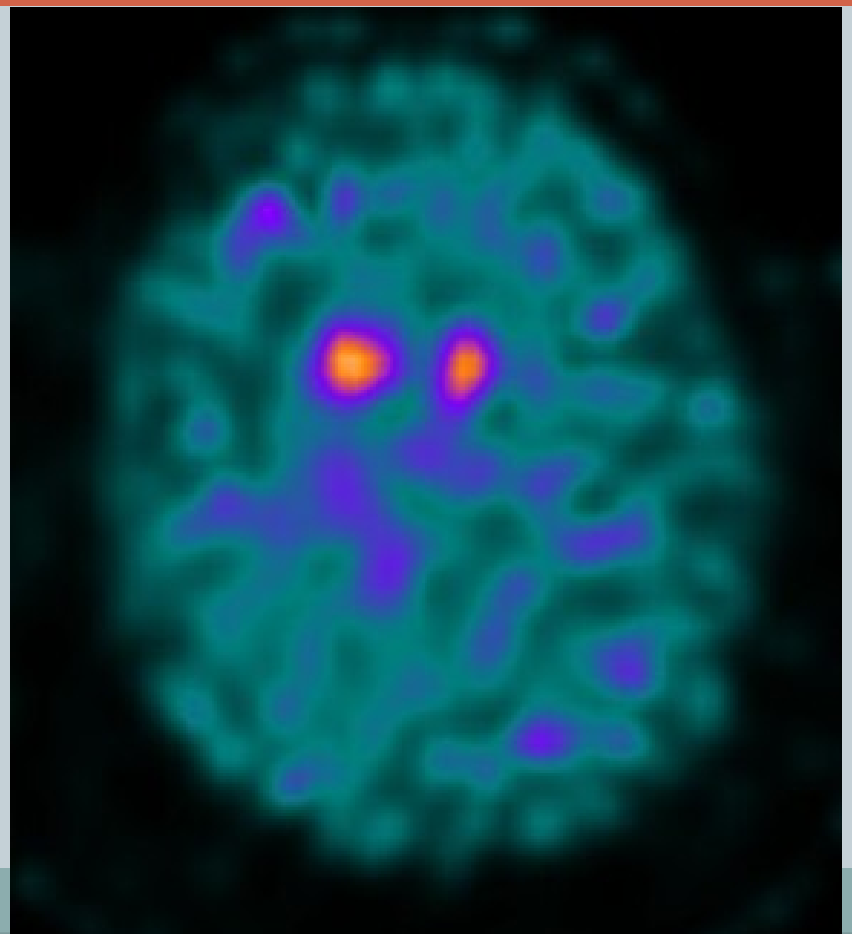
Datscan



Normal



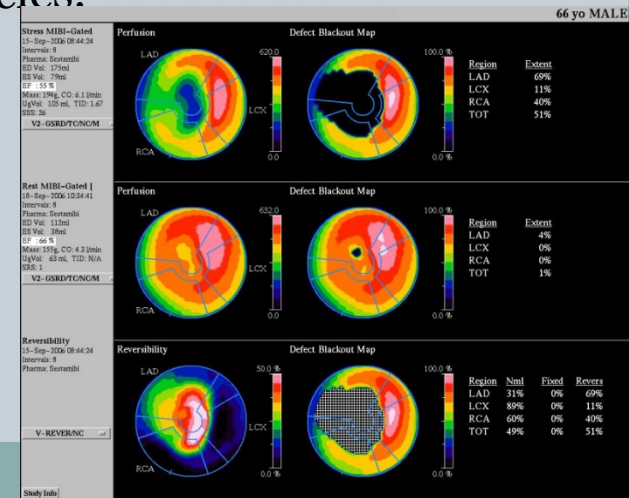
Positive – Parkinson disease



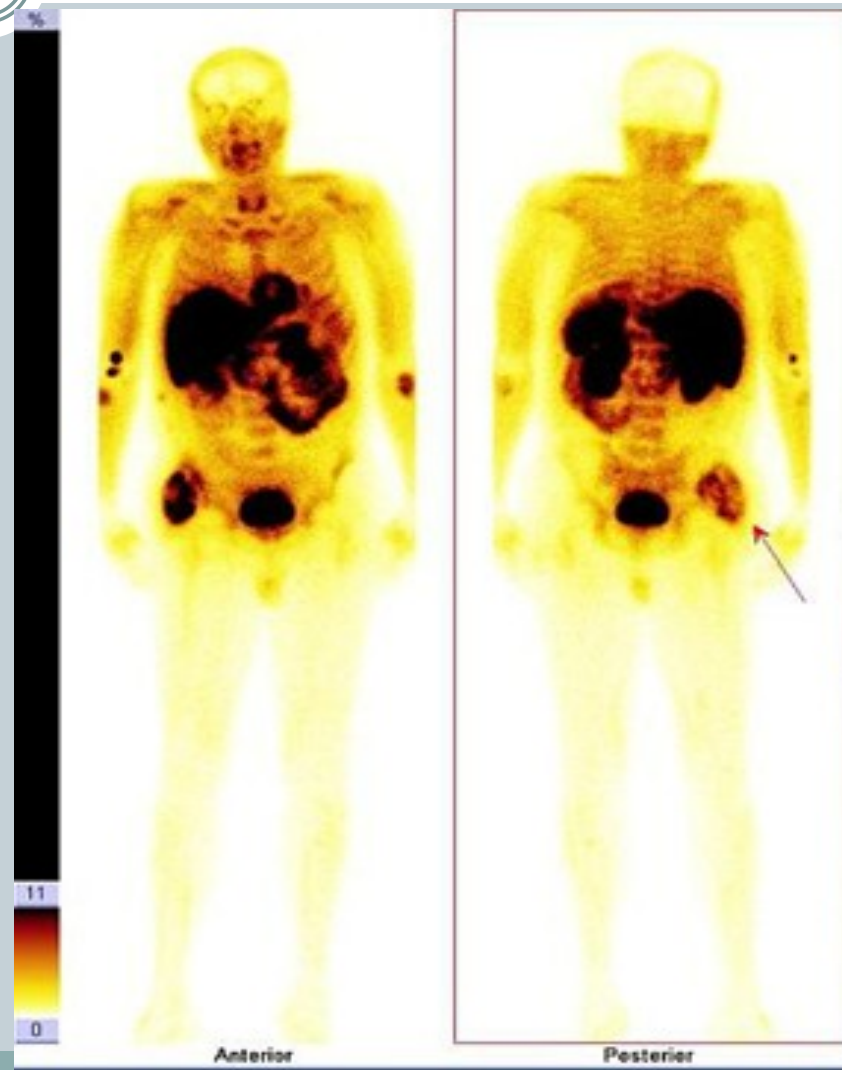
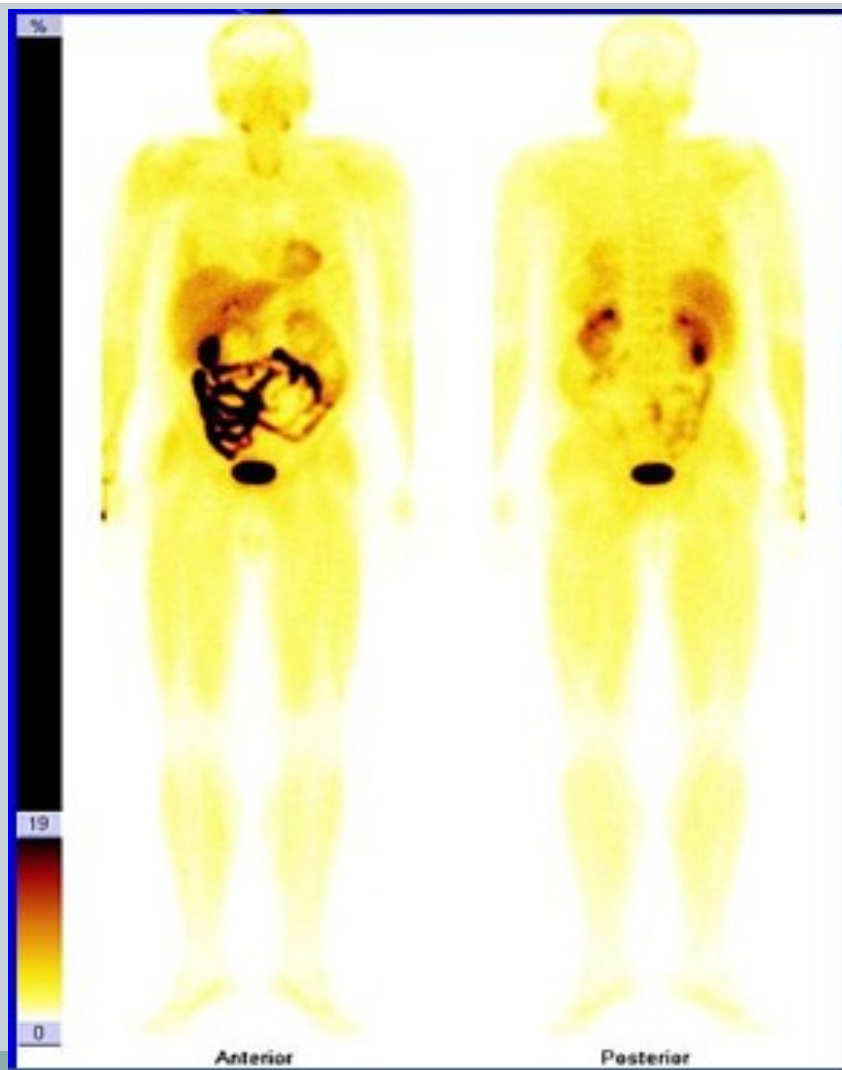
^{99m}Tc -MIBI (sestamibi)



- Nonspecific tumor binding agent, it is concentrated in mitochondria of the viable cells as a result of the passive diffusion
- **Use:**
- **cardiology** (cardiac perfusion studies – dg. ICD)
- **endocrinology** (localisation of hyperparathyroid gland)
- oncology – follow up of patients with differentiated thyroid cancer as an alternative to ^{131}I
 - earlier in pts. with multiple myeloma, breast ca, soft tissue sarcomas
 - accumulation also in other types of malignancies.



MIBI scan

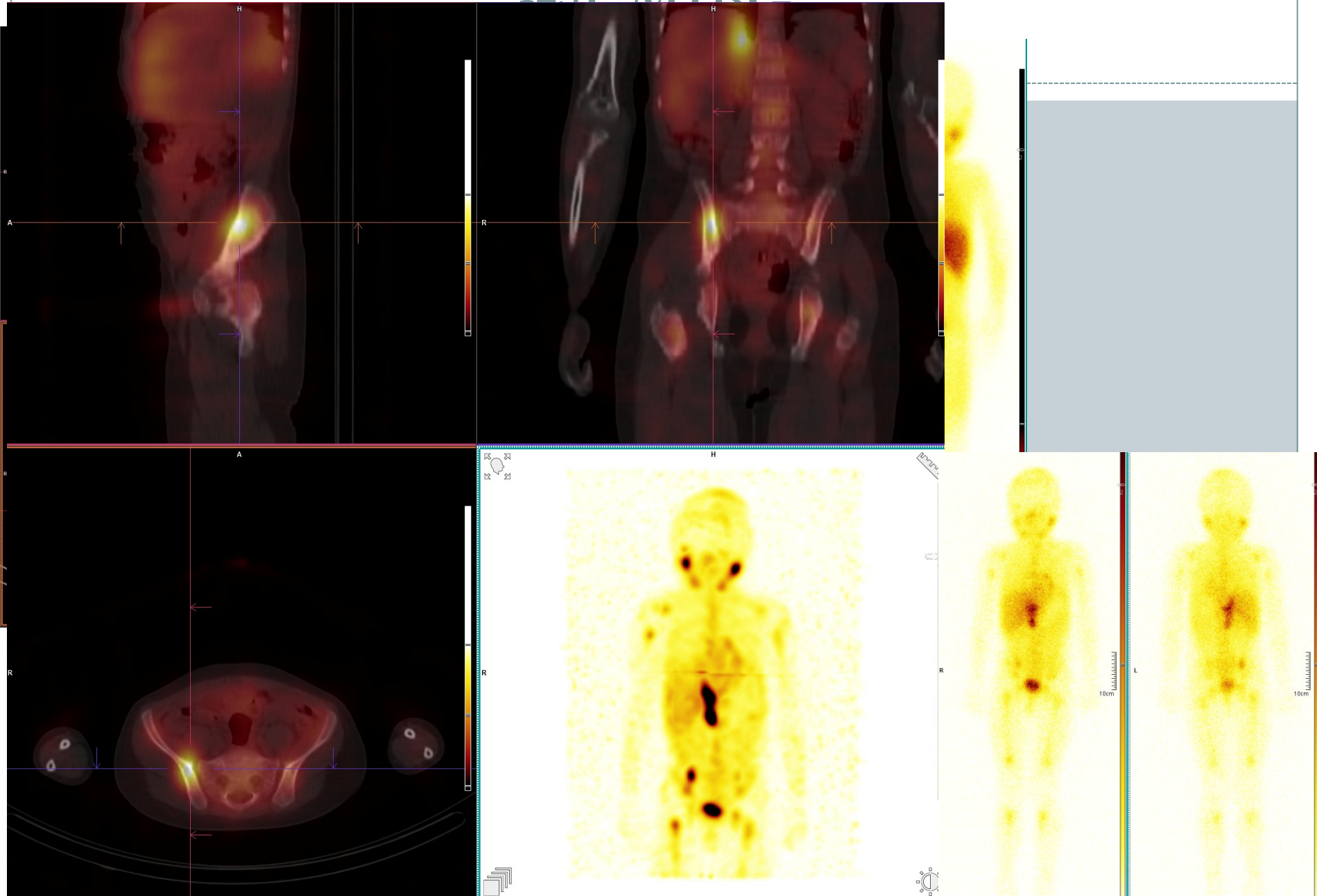


^{123}I -MIBG – adrenal medullary scintigraphy



- Metajodobenzylguanidin = guanethidin analogue (similar to norepinephrin) that accumulates in adrenergic and neuroblastic tumors
- Protocol: Wholebody planar scan + SPECT/CT at 4 and 24 hours after injection, patient preparation before study! (thyroid blockade)
- **Indication** : diagnosis, staging, management of adrenergic neuroectodermal tumors (pheochromocytomas, extraadrenal paragangliomas, neuroblastomas), before planned ^{131}I -MIBG therapy of medullary thyroid cancer
- **Pheochromocytoma/paraganglioma** – catecholamine-secreting tumors (hypertension, arrytmias), 10%bilateral pheochr., 10% extraadrenal paragangliomas, 10% malignant, found from the bladder up to the base of the skull
- **Neuroblastoma** – embryonal malignancy of the sympathetic nervous system, typically in children younger than 4years of age, 70% originate in retroperitoneal area, ^{131}I -MIBG for therapy after the failure of previous conventional therapies

123I MIBG

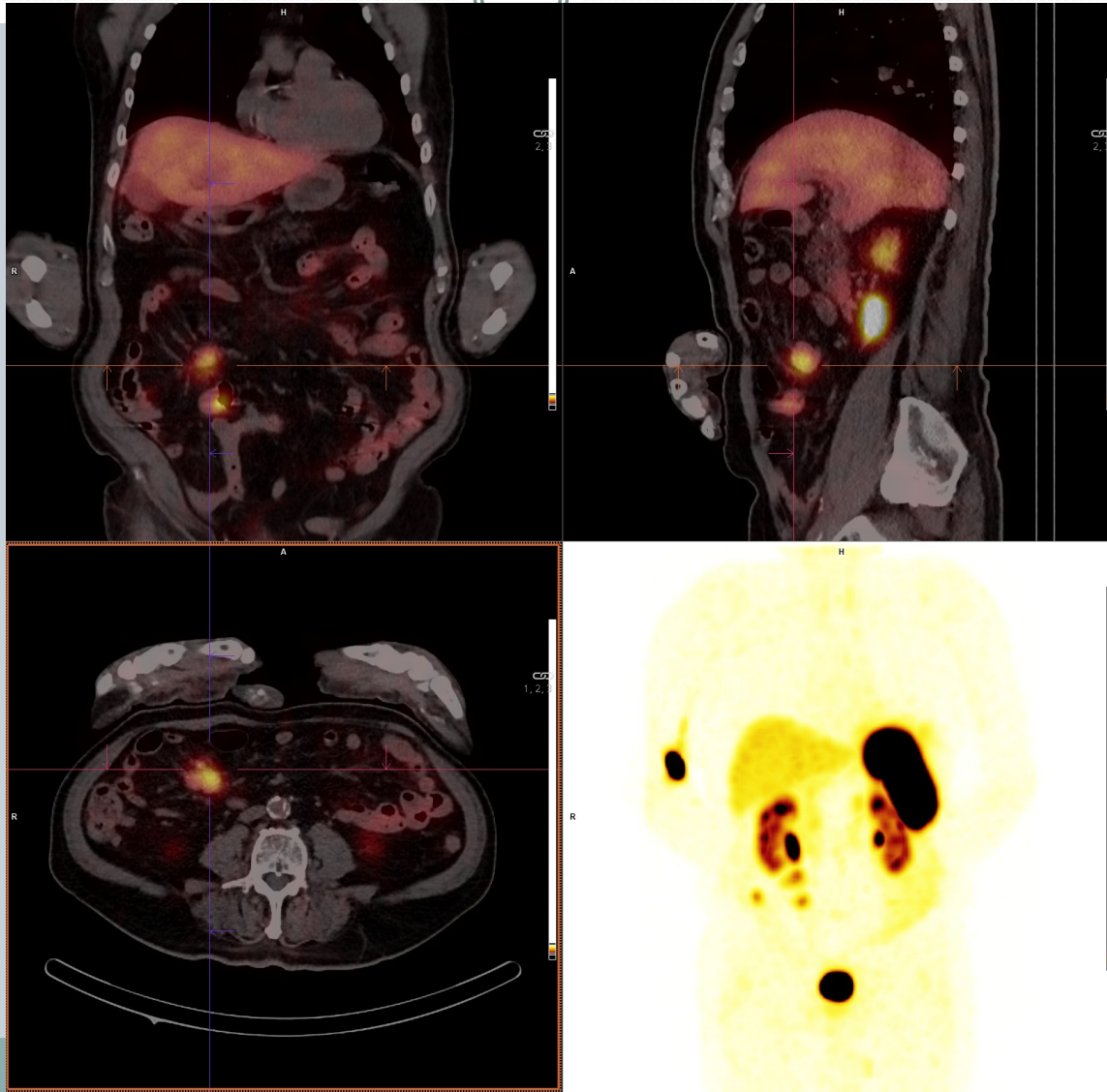


Imaging of somatostatin receptors



- Imaging of the distribution of somatostatin receptors, which are highly expressed in neuroendocrine tumors (especially pulmonary and gastro-enteropancreatic NETs)
- **¹¹¹In-Pentetreotid** (Octreoscan) - synthetic somatostatin analogue with high affinity to SSTR₂, SSTR₅
Protocol : wholebody scan + SPECT/CT at 4h, 24h (sometimes 48h) after injection
Newer alternative:
 - **Tektrotyd** = ^{99m}Tc-EDDA/HYNIC-TOC – at 1h and 4h
 - better image quality than Octreoscan (energy of ^{99m}Tc), 1-day exam, lower radiation dose, lower price
- **Indication:** evaluating neuroendocrine tumors, especially carcinoid, gastroenteropancreatic tumors, small cell lung cancer, meningioma, variable affinity for medullary thyroid cancer, insulinoma
- **Limitation :** false positive uptake in benign inflammatory granulomatous disease (sarcoidosis, TBC, IBD...), in tumors expressing lack of appropriate receptor subtype
- PET alternatives:
 - **⁶⁸Ga-DOTA-TOC** - best sensitivity and image quality, lower availability (⁶⁸Ga), higher price
 - ¹⁸F-FDG PET useful in poorly differentiated neuroendocrine tumors
- **Therapy:** ¹⁷⁷Lu-DOTA-TATE – beta- radiation therapy in patients with progressing GEP NETs

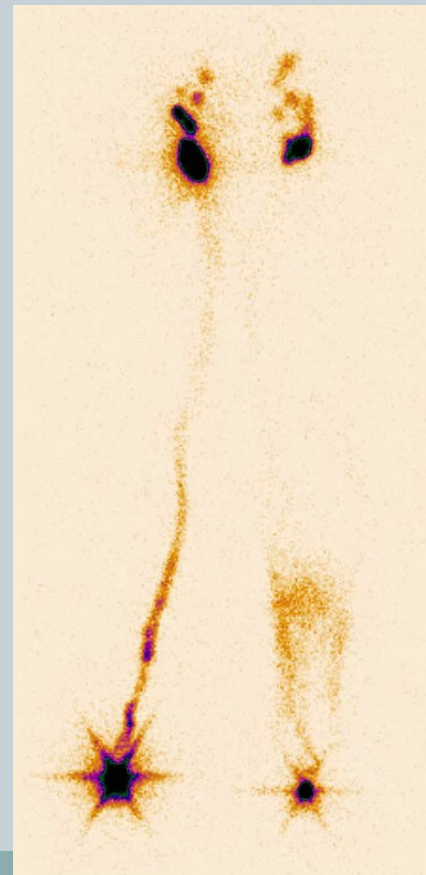
Tektrotyde – NET in ileum + lymph nodes



Lymfoscintigraphy of limbs



- RF: ^{99m}Tc -nanocoloid, subcutaneous
- **Indication:** lymphedema

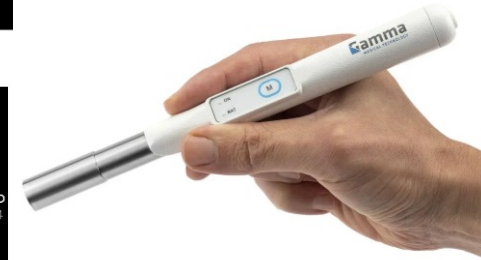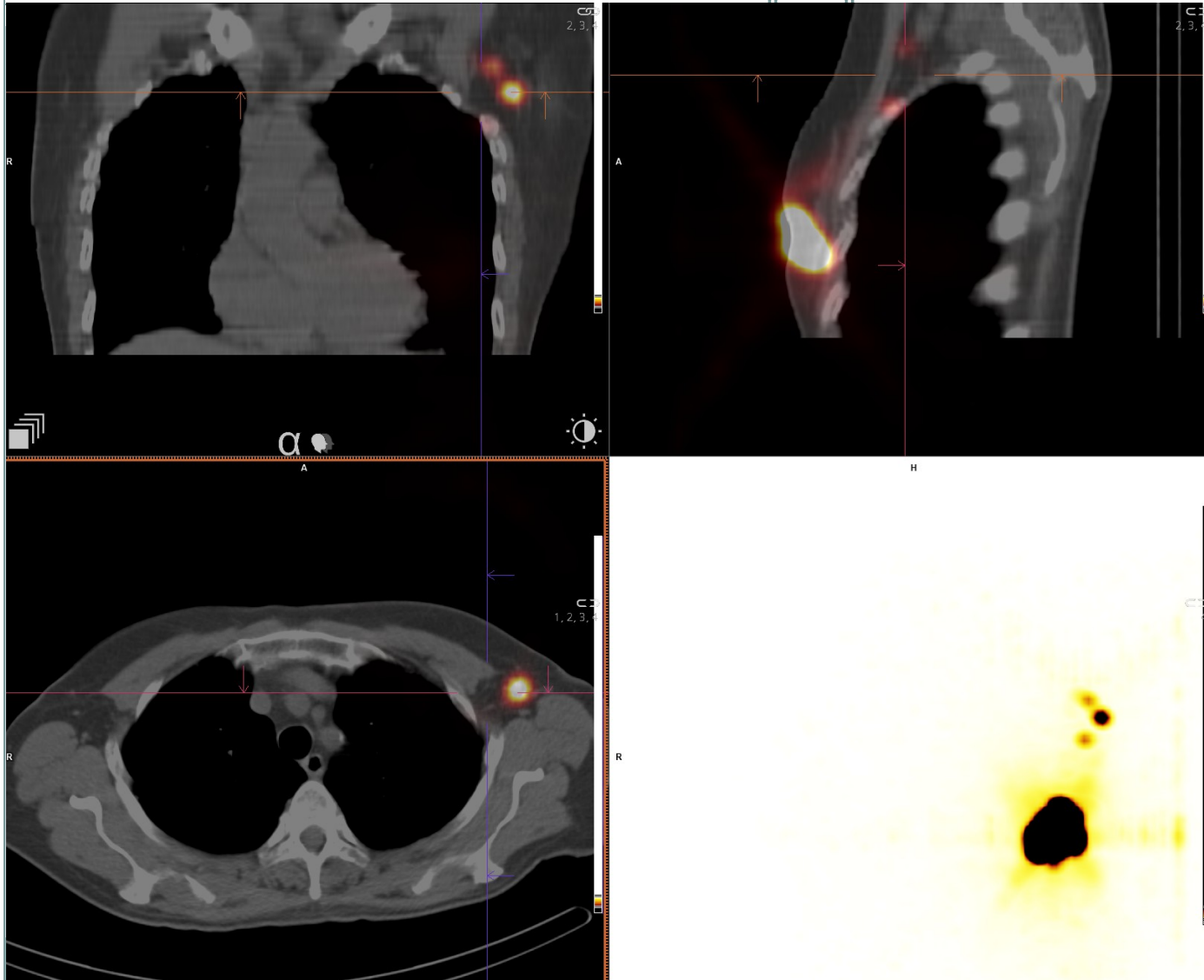


Lymphoscintigraphy – SLN detection

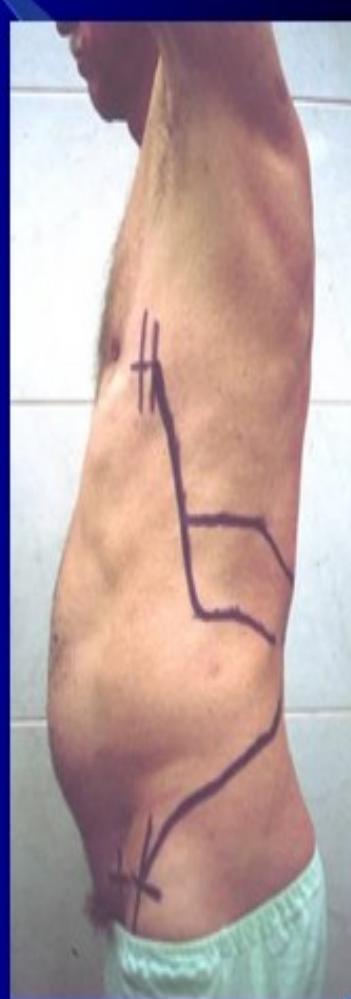


- **Small amount of radioactive active colloidal tracer is injected into the skin in proximity to tumor lesion to determine the SLU receiving drainage and thus possibly metastasizing tumor cells**
- **SLN** (sentinel lymph node) = the first lymph node (nodes) which is first on a direct lymphatic drainage pathway from a primary tumor site, and as such is the most likely the location of metastasis
- Identification and histopathological examination of the SLU (after surgical removal) allow us to predict a regional metastatic potential of that given tumor and thus to choose optimal therapy
- **^{99m}Tc -nanocolloid**
- **Indication** : malignant melanoma, breast cancer, cancer of the tongue, neck, head, vulva
- **Contraindication**: already known metastatic disease indicated for systemic therapy, suspected altered lymphatic drainage due to the previous surgery procedure

Breast cancer – detection of SLN



SLU imaging – patient with melanoma



- Tracer was injected around the lesion on the lower back and drained to 2 lymph nodes. They were marked superficially over the skin