

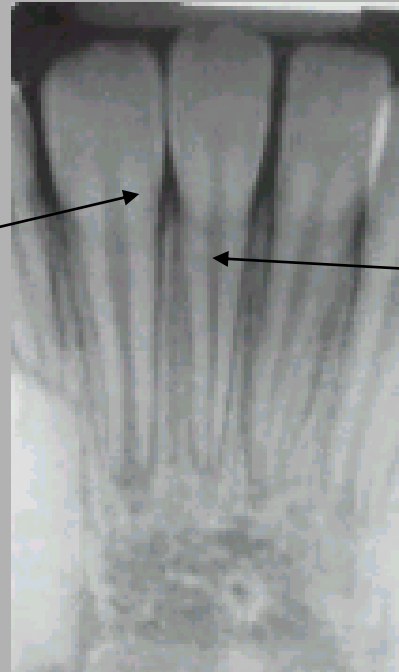
Radiology for stomatologists – plain Xray imaging – principles, pathology



X-ray - attributes

- Electromagnetic radiation of short wavelength produced when high-speed electrons strike a solid target
- Ability to pass through tissues where is partially absorbed

Radio-opacity
(light)



Radiolucency
(dark)

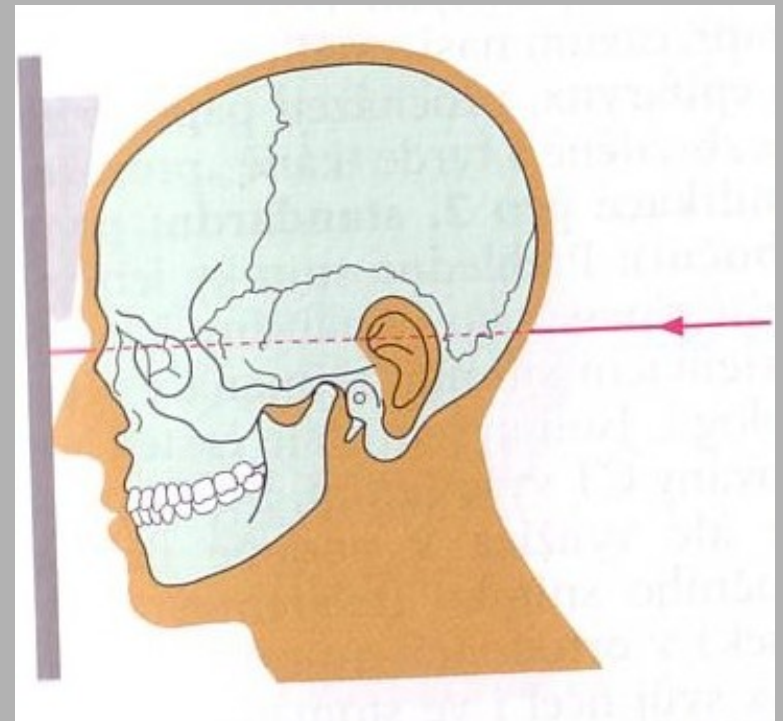
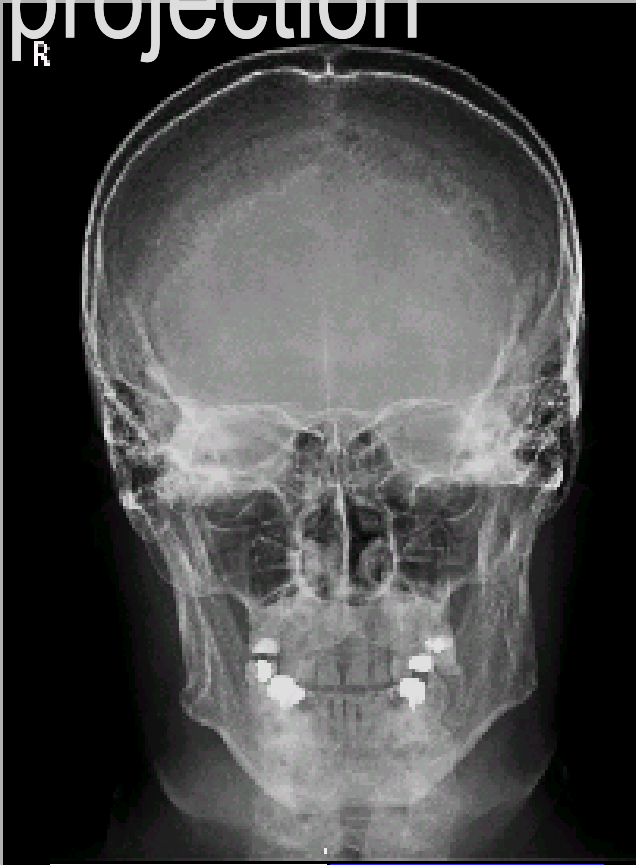Plain X ray imaging

- 1) Imaging of skull – basic projections
- 2) Dental radiographs
 - A) Intraoral imaging
 - B) Extraoral imaging

1) Skull skiagrams - basic projections

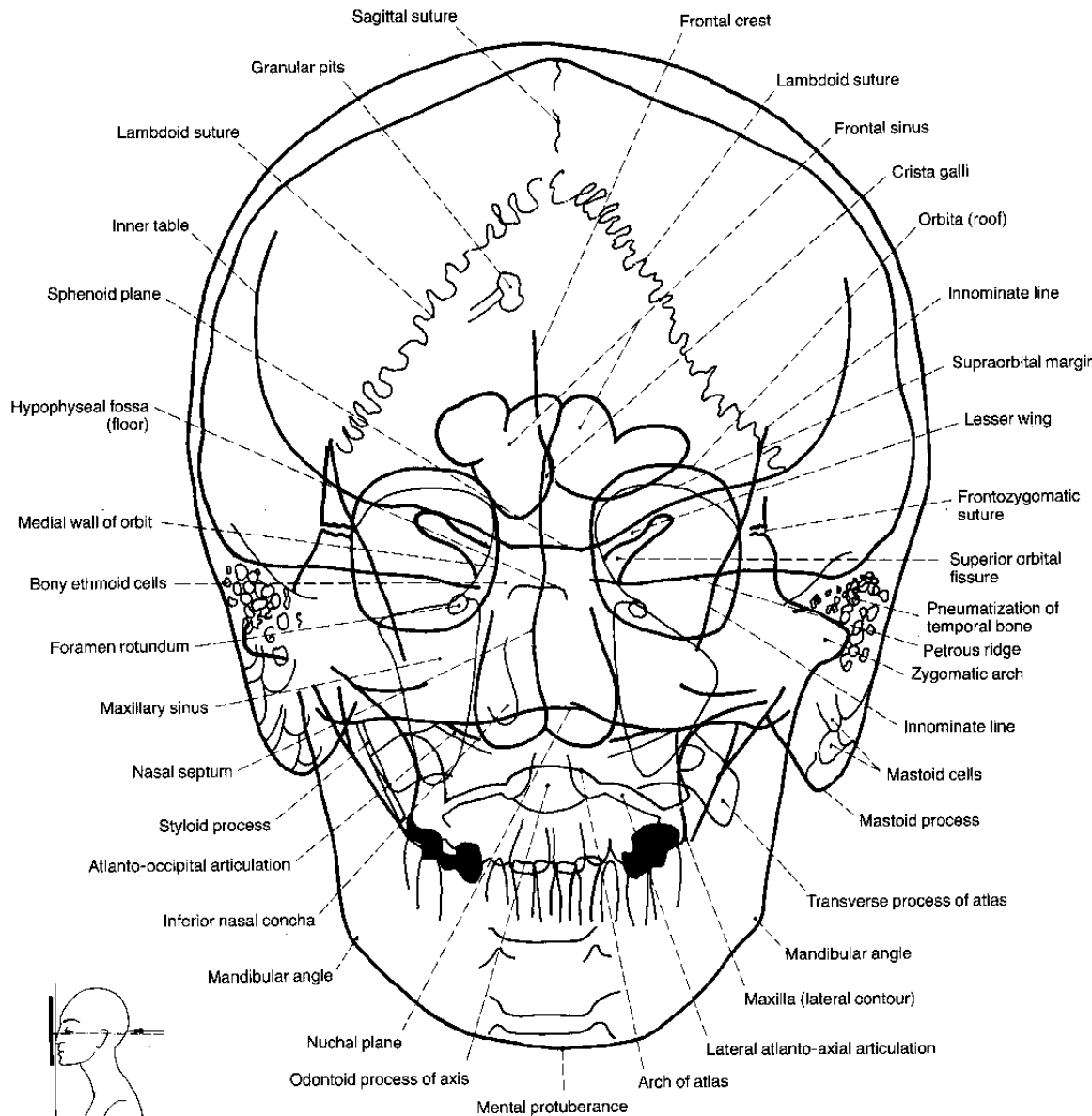
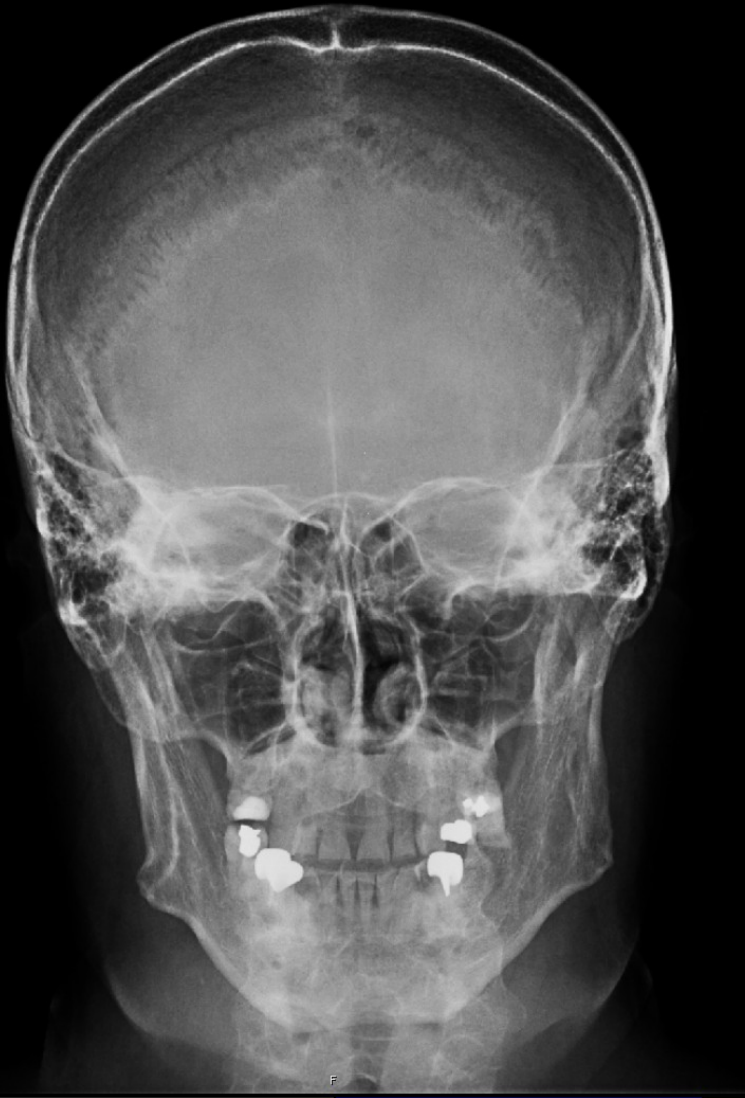- Picture of the cranium – traumatic
- Projection of paranasal sinuses
- Orbits
- Os temporale
- Temporo-Mandibular Joint

Cranium – dorso-ventral and lateral projection

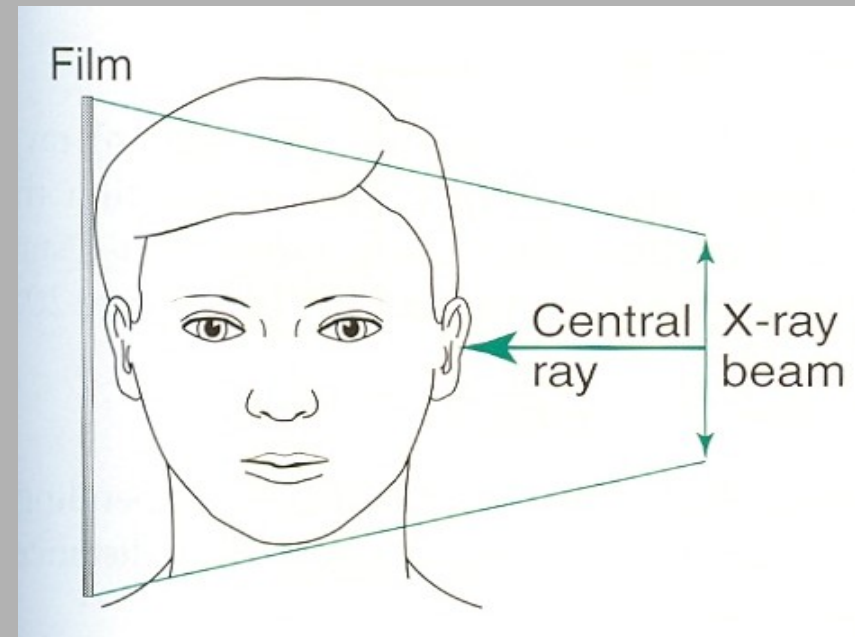
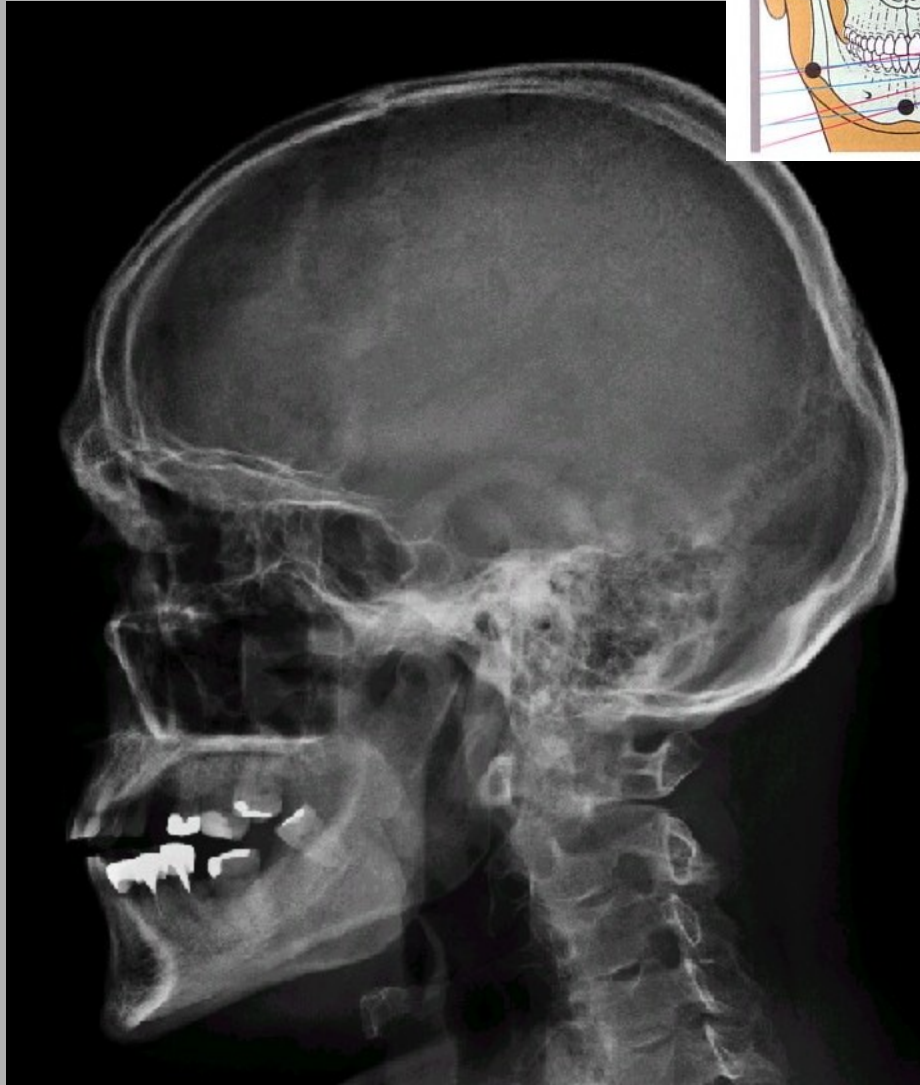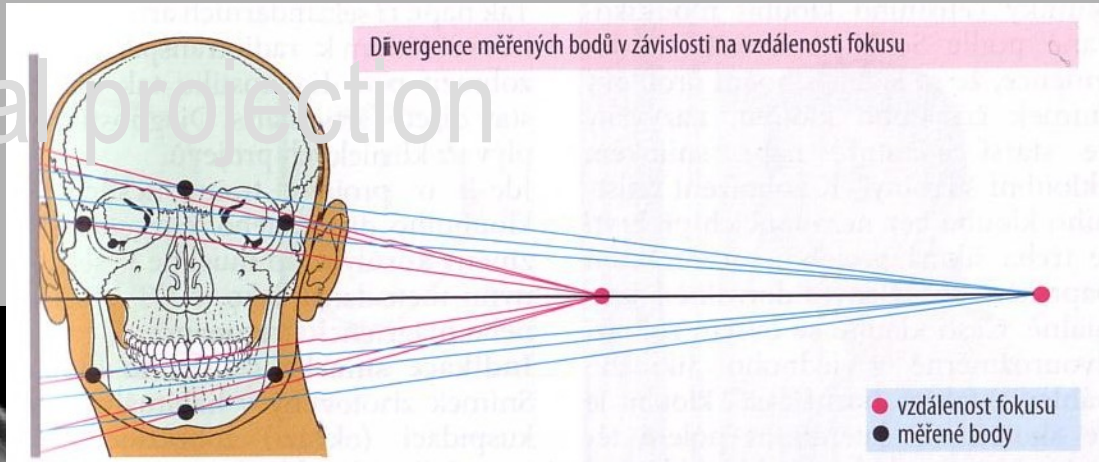


- Nose and forehead touch the cassette
- X-ray pass through the protuber. occipitalis perpendicularly to cassette

Cranium – dorso-ventral and lateral projection

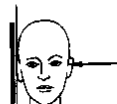
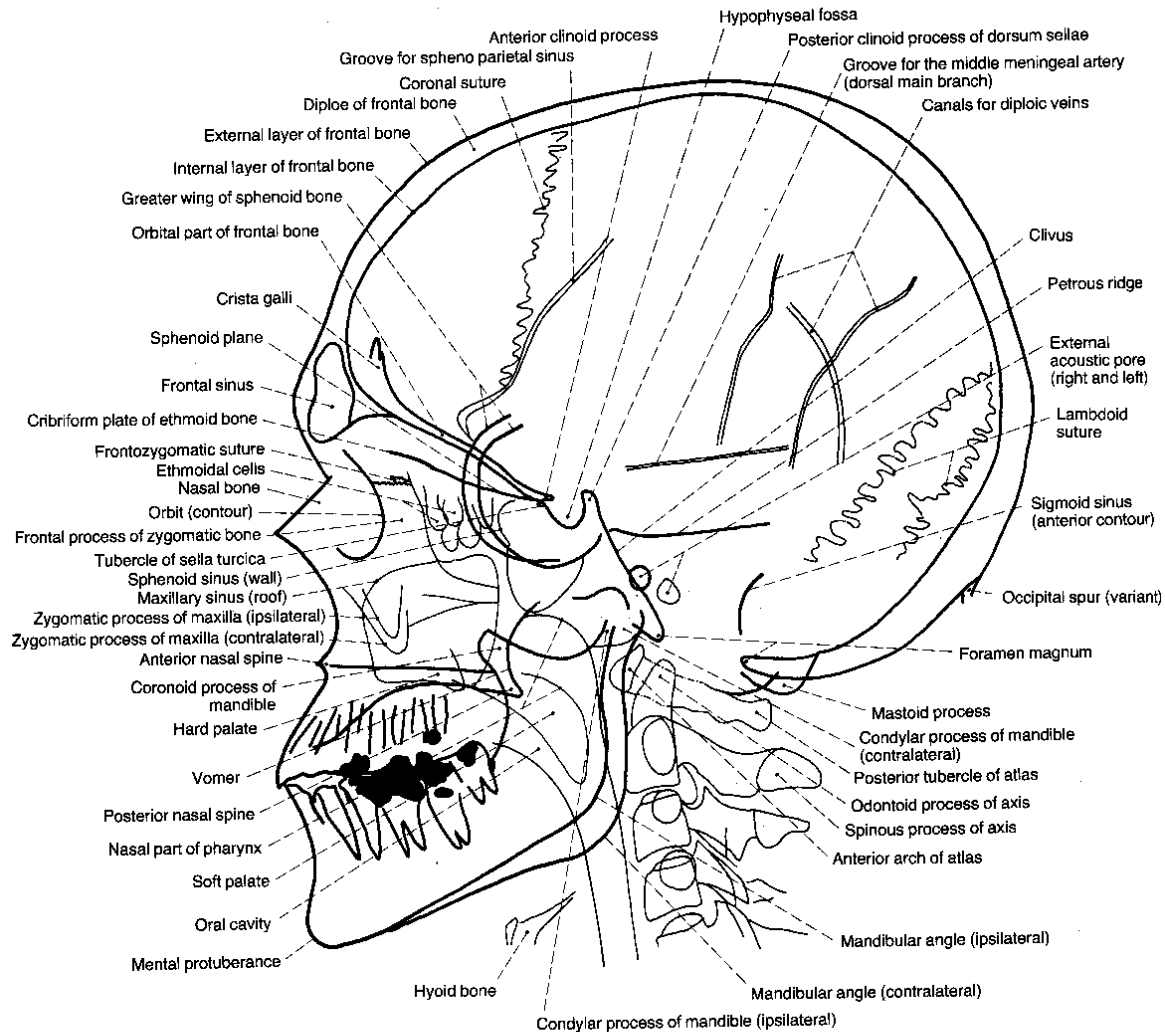
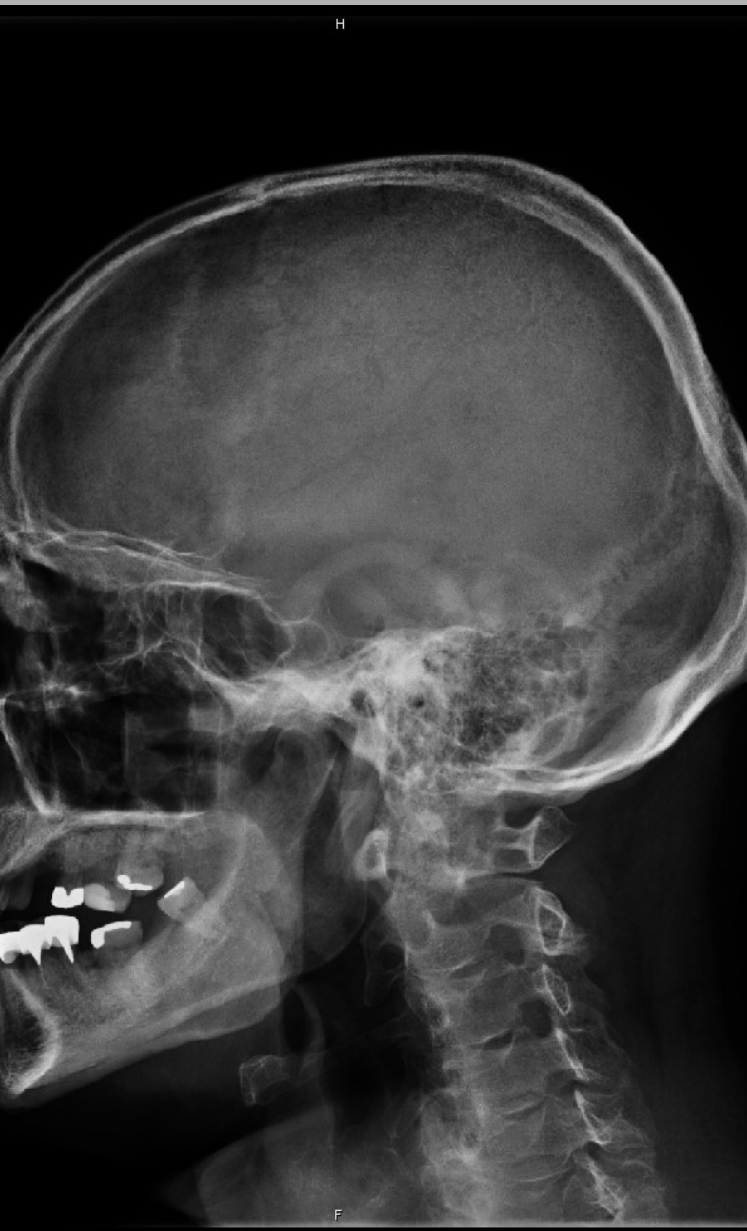

Cranium – lateral projection

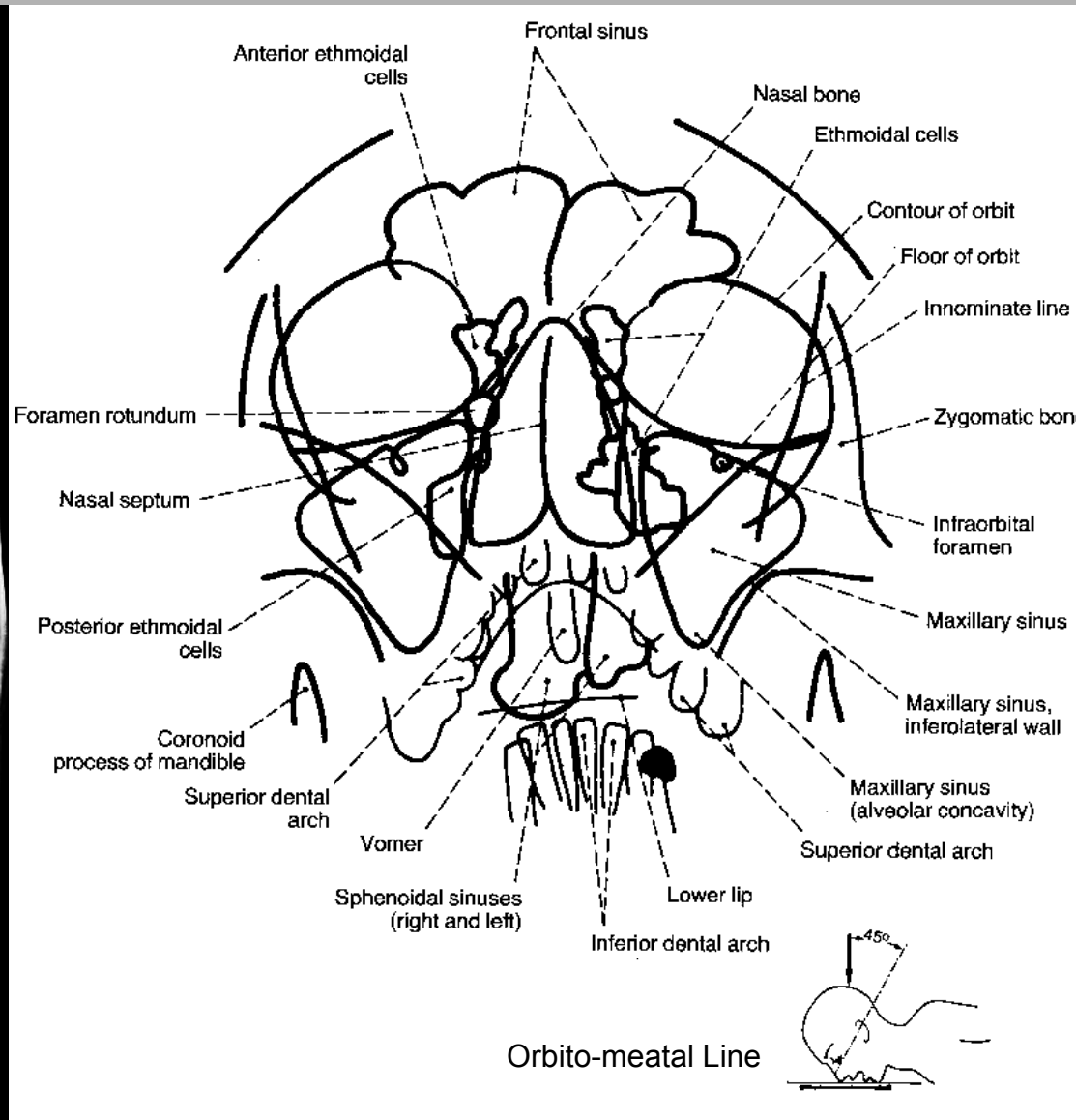
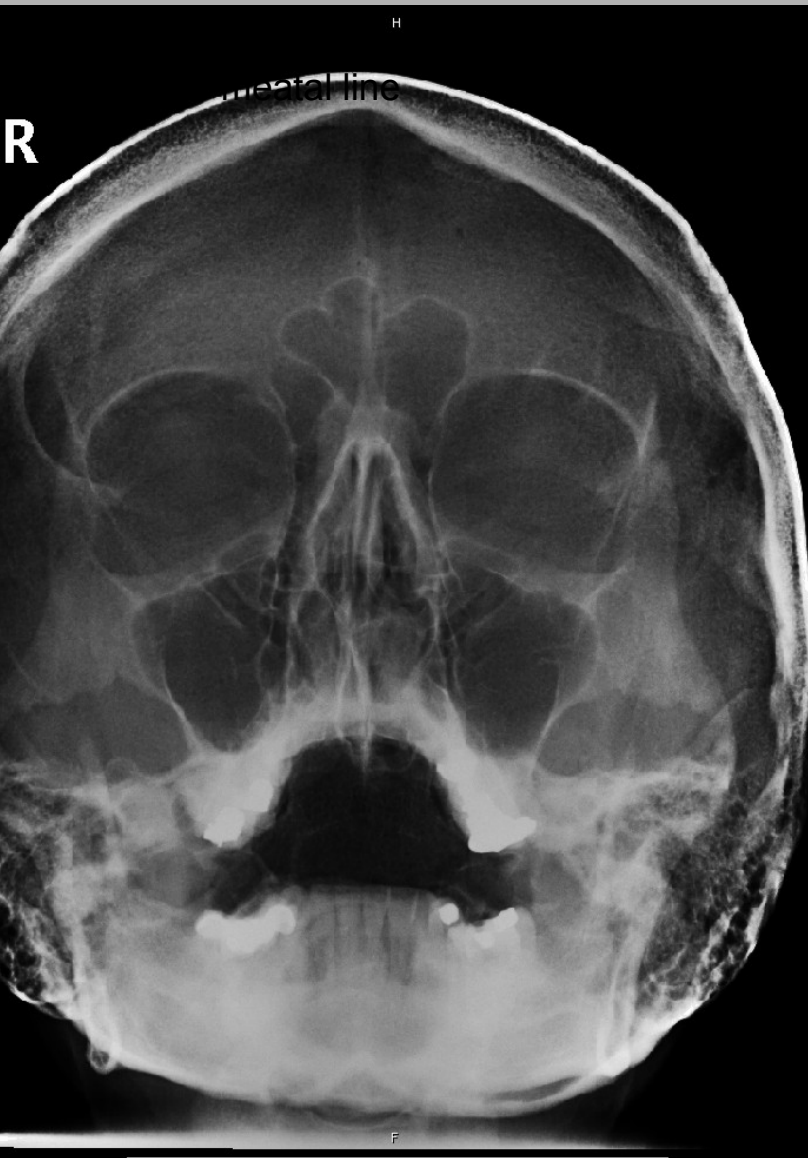

- Central beam goes through the acoustic meatus
- Perpendicular to the cassette

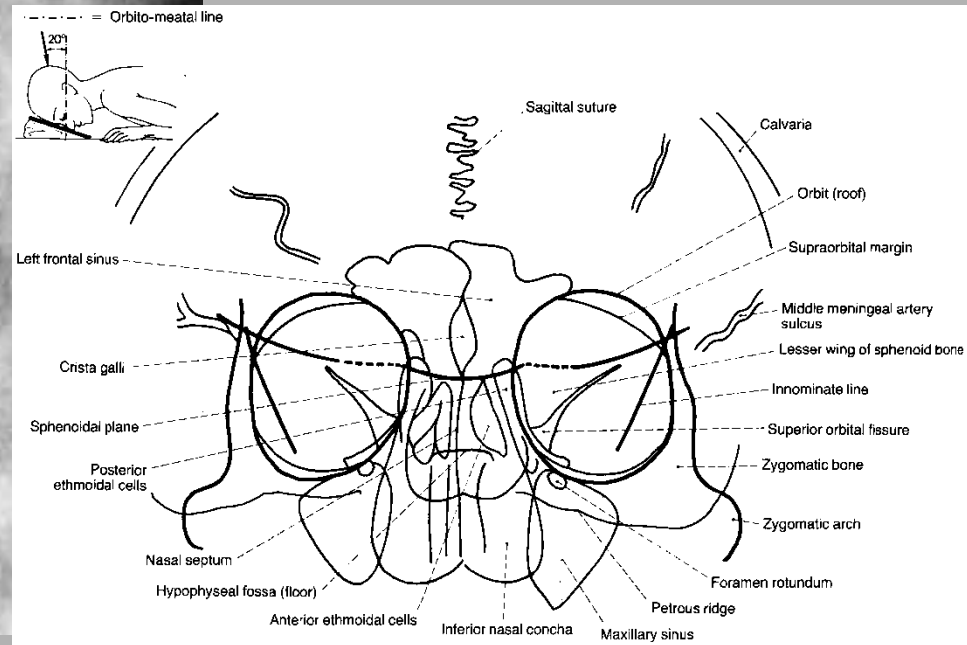
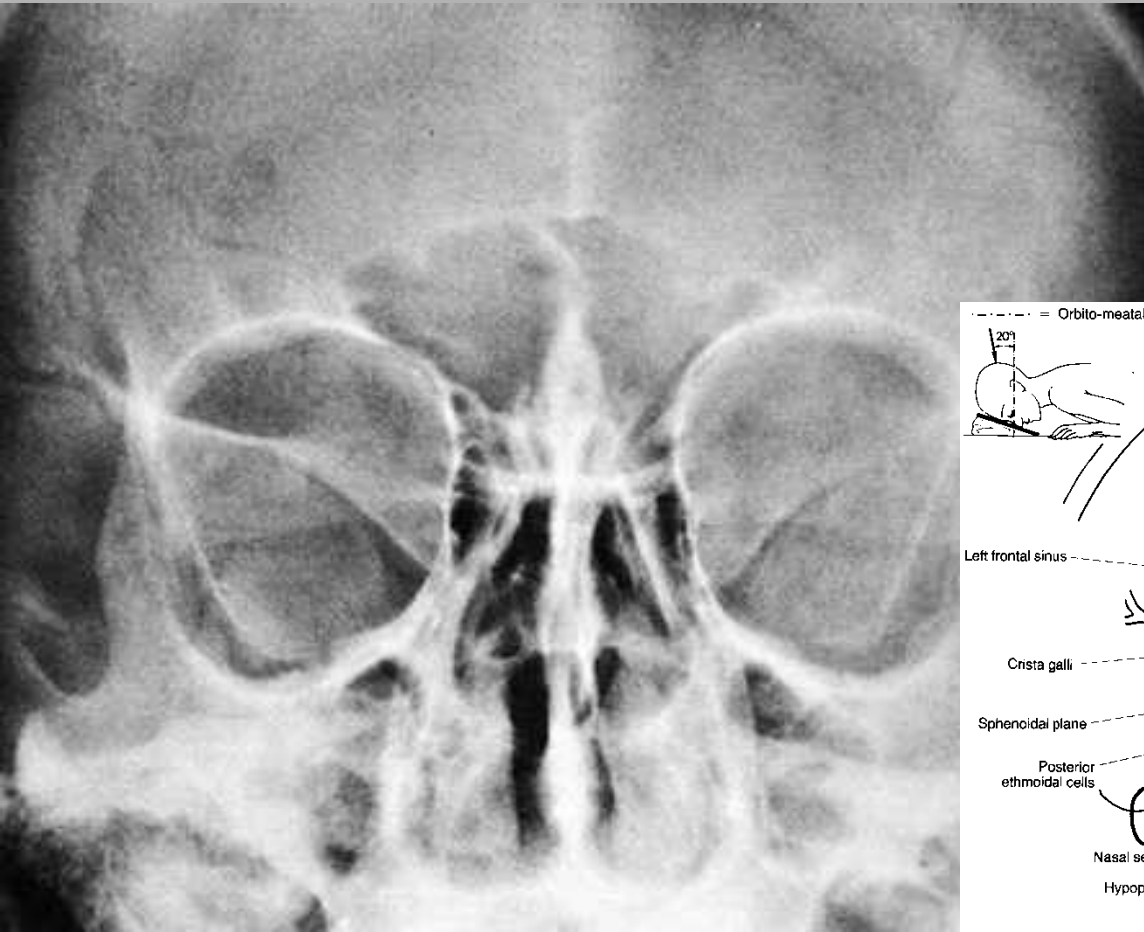
Cranium – lateral projection



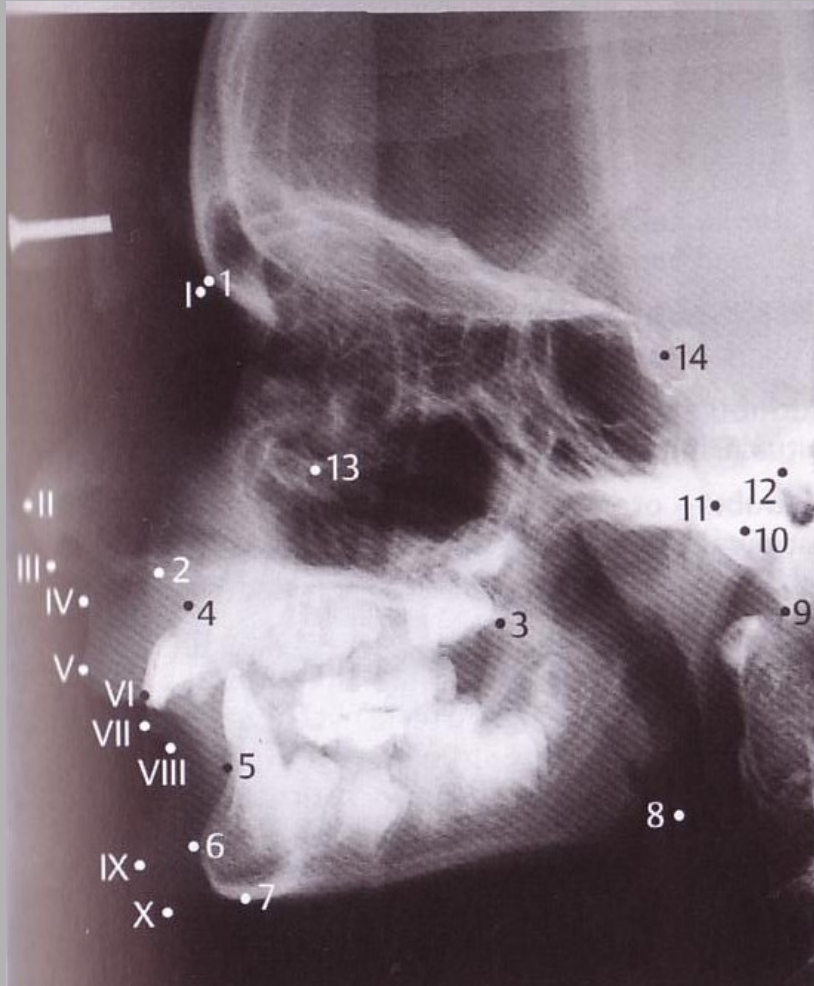
Paranasal sinuses – Water's projection



Orbits – dorso-ventral projection



Orbits – lateral projection



Skeleton Points

- | | |
|----|-------------------------|
| 1 | Nasion |
| 2 | Spina nasalis anterior |
| 3 | Spina nasalis posterior |
| 4 | Bod A |
| 5 | Bod B |
| 6 | Pogonion |
| 7 | Menton |
| 8 | Gonion |
| 9 | Basion |
| 10 | Articulare |
| 11 | Condylion |
| 12 | Porion |
| 13 | Orbitale |

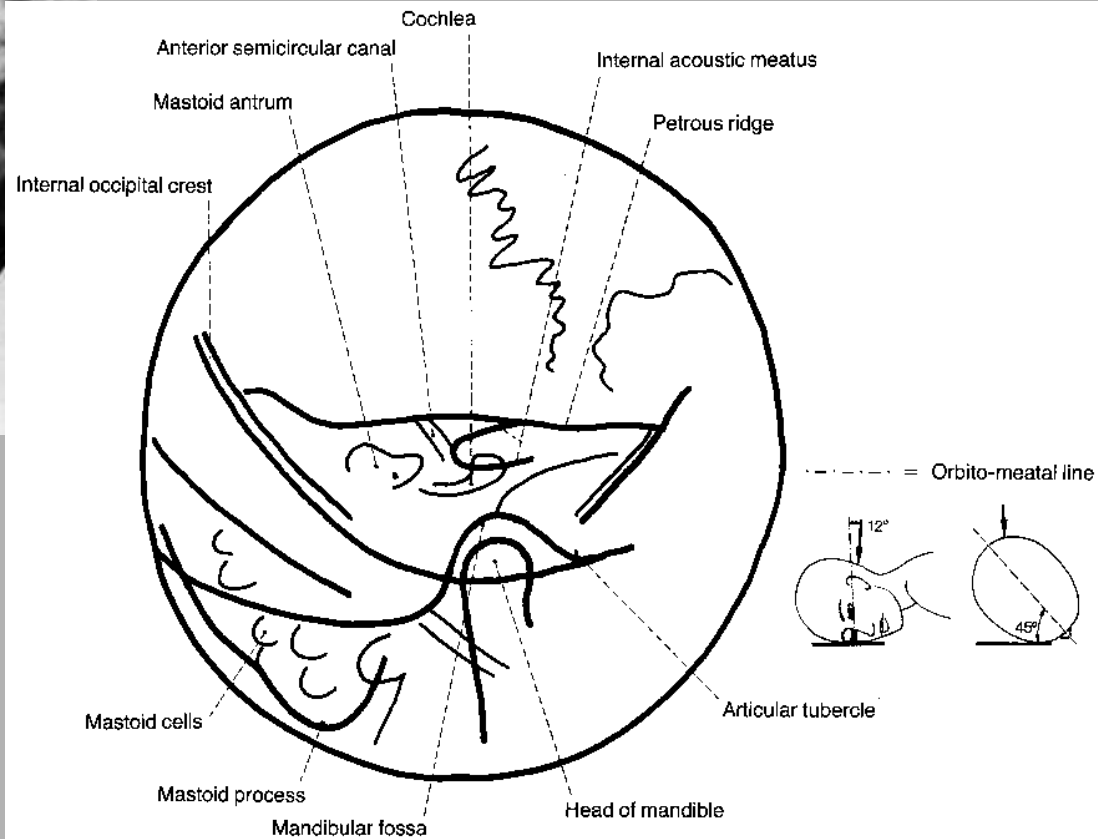
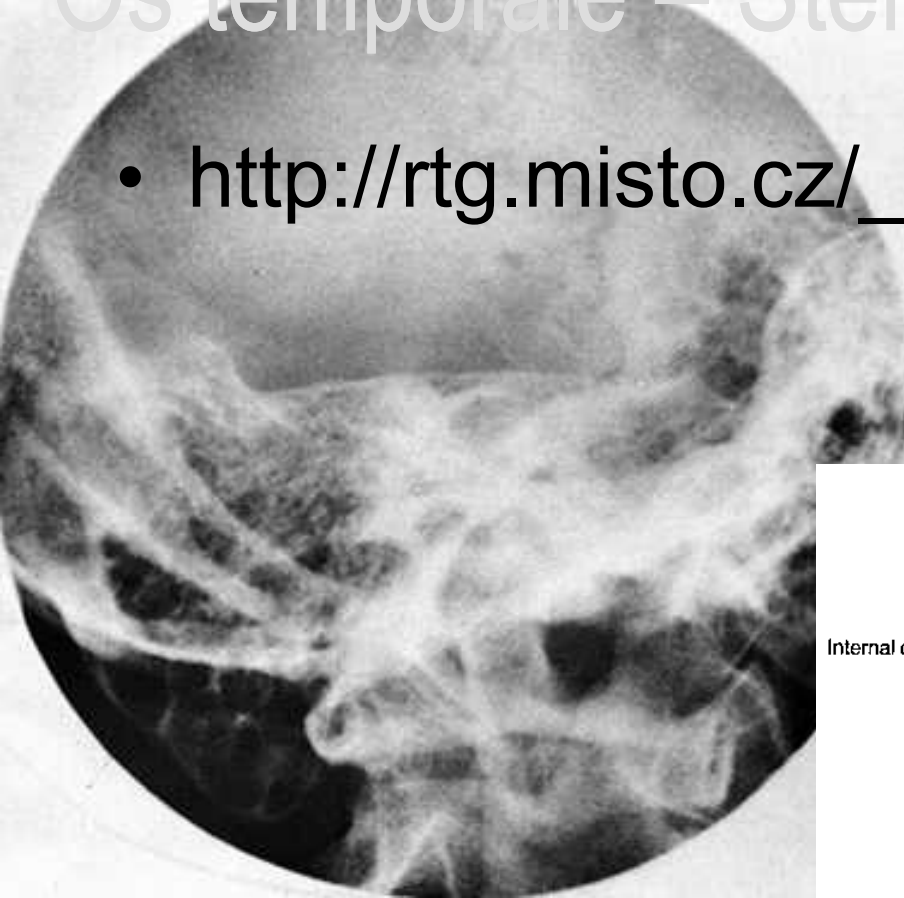14 sella

Soft Tissue Points

- | | |
|------|------------------|
| I | Kožní nasion |
| II | Špička nosu |
| III | Subnasale |
| IV | Subspinale |
| V | Labrale superius |
| VI | Stomion |
| VII | Labrale inferius |
| VIII | Submentale |
| IX | Kožní pogonion |
| X | Kožní gnathion |

Os temporale – Stenver's – semisagittal pr.

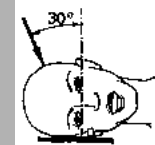
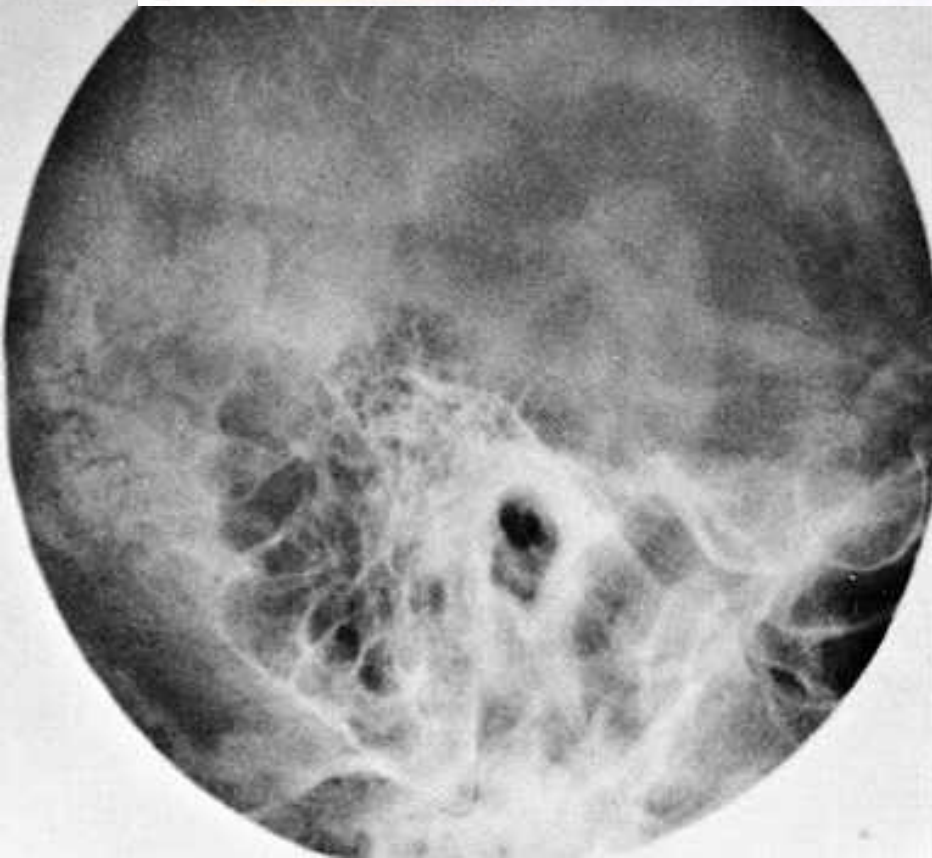
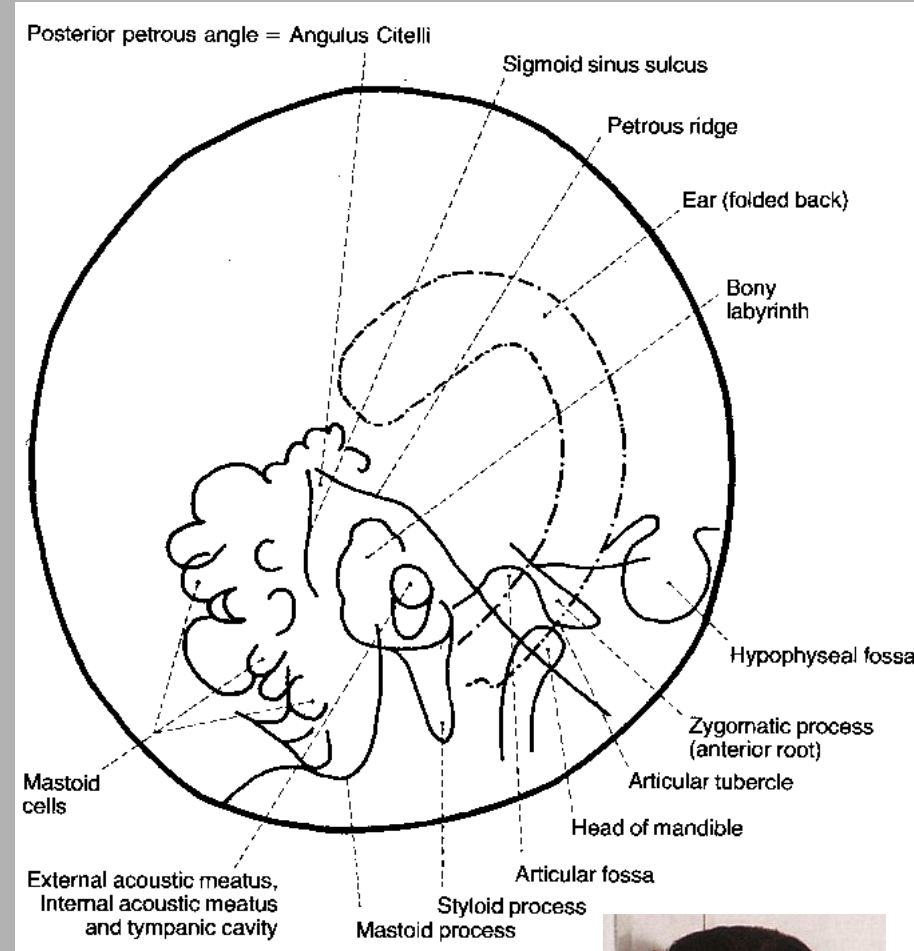
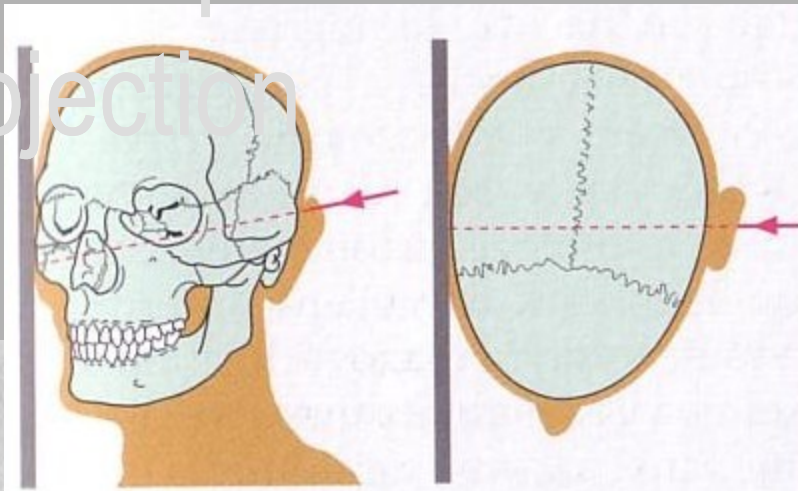
- http://rtg.misto.cz/_MAIL_/hlava/11.jpg



Os temporale – Schüller's – semilateral

projection

http://rtg.misto.cz/_MAIL_/hlava/12.jpg

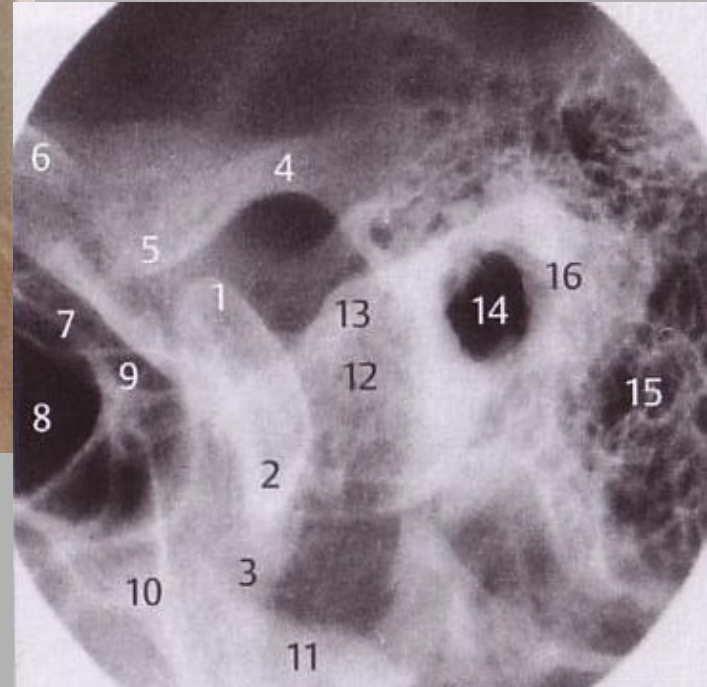
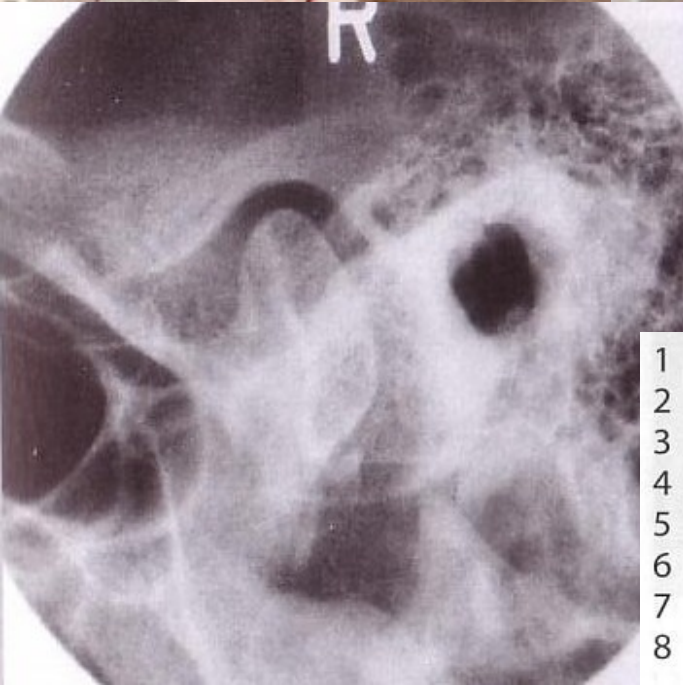

----- = Orbito-meatal line



Os temporale – Schüller's – semilateral

projection

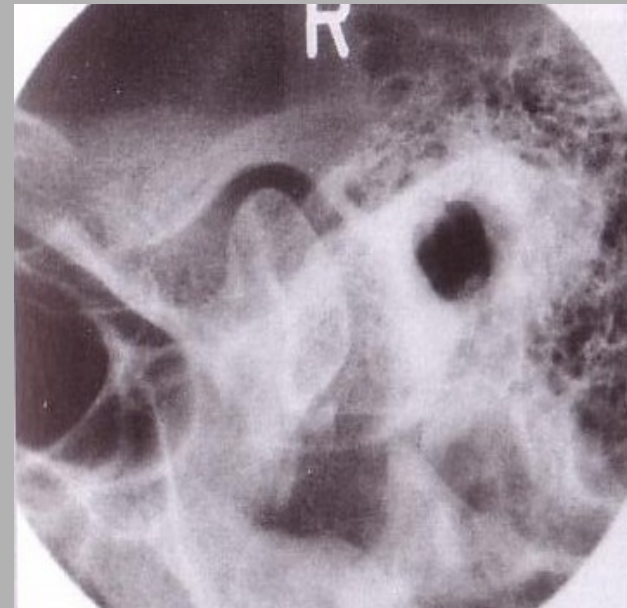
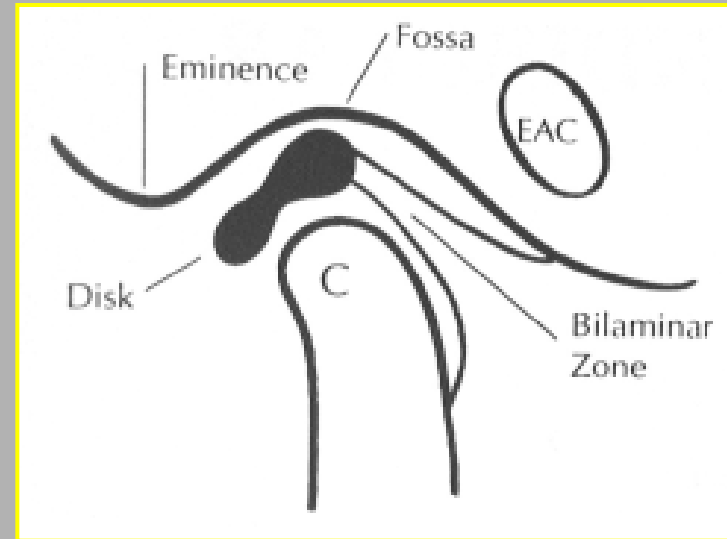


- 1 Kondylus, laterální pól
- 2 Kondylus, mediální pól
- 3 Processus condylaris mandibulae
- 4 Fossa glenoidalis, laterální části
- 5 Eminentia articularis, laterální části
- 6 Arcus zygomaticus
- 7 Sella turcica
- 8 Sinus sphenoidalis

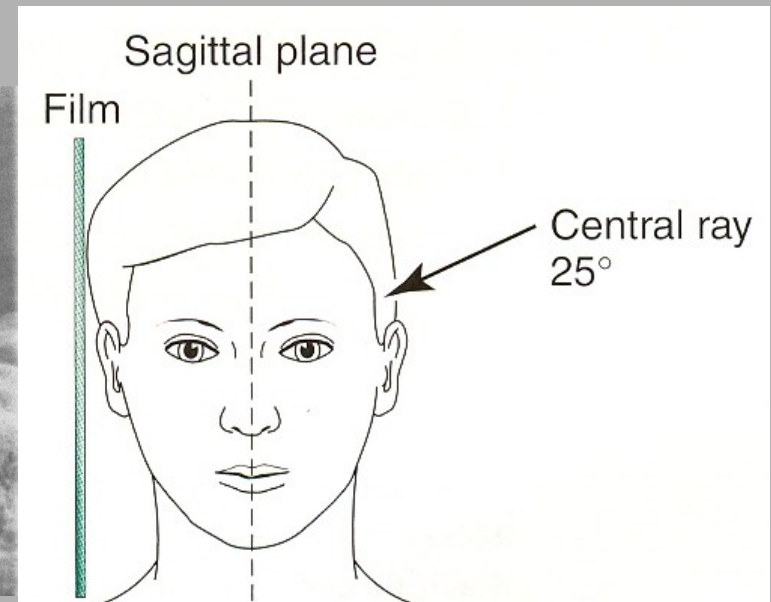
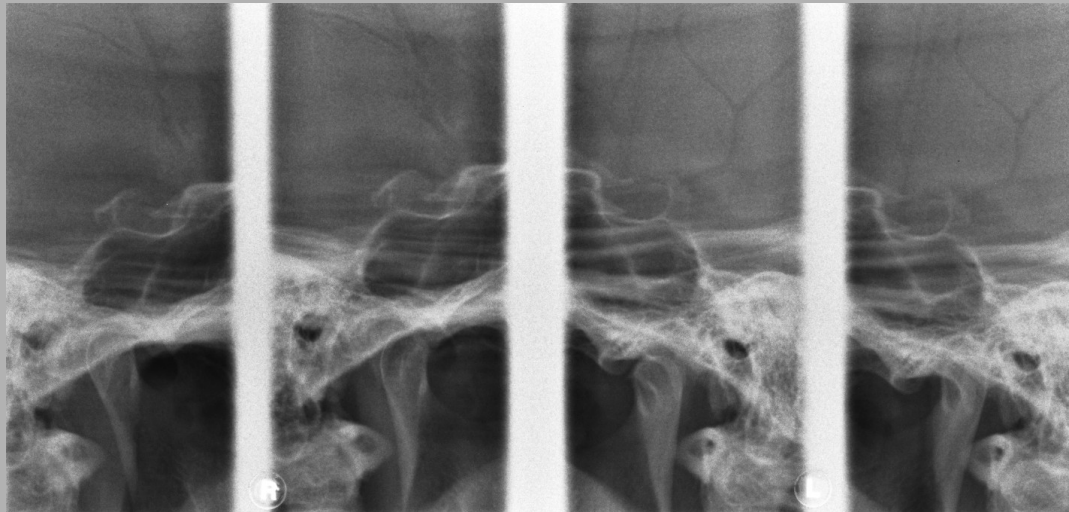
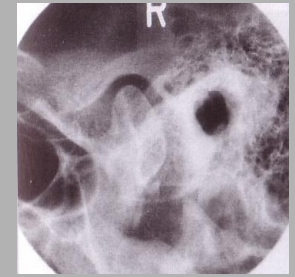
- 9 Processus clinoideus posterior
- 10 Clivus
- 11 Pars petrosa (vzdálenější)
- 12 Pars petrosa (přilehlá)
- 13 Horní hrana pyramid (přilehlá)
- 14 Porus acusticus externus
- 15 Celullae mastoideae
- 16 Pars tympanica ossis temporalis

Temporomandibular joint (TMJ)

- Intracapsul. disease = diskopathy- we can see calcifications
- Correct position of temporo mandible joint (TMJ)



Temporomandibular joint - TMJ



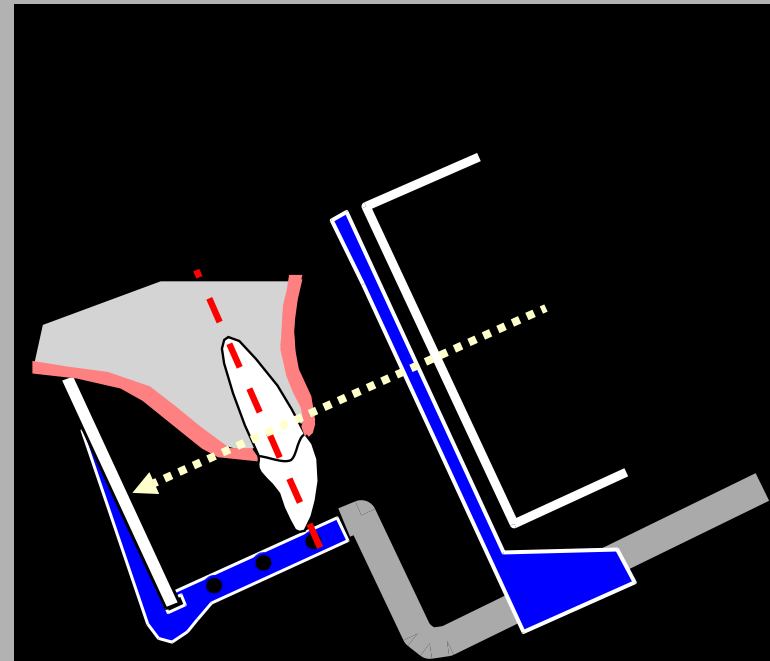
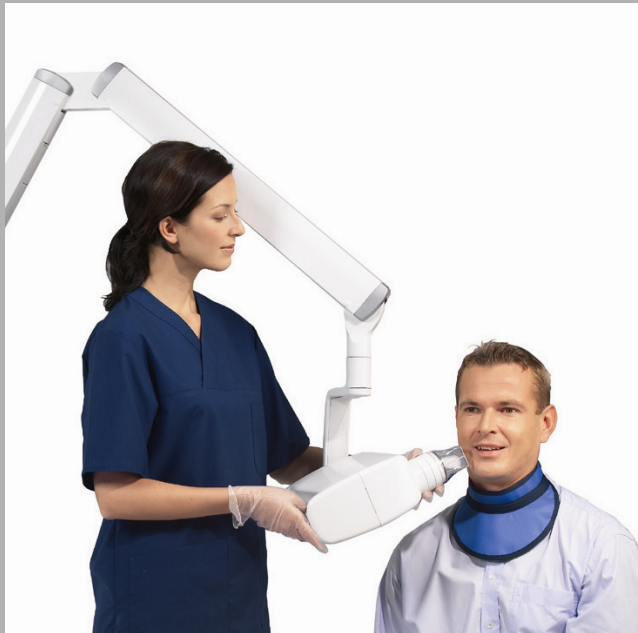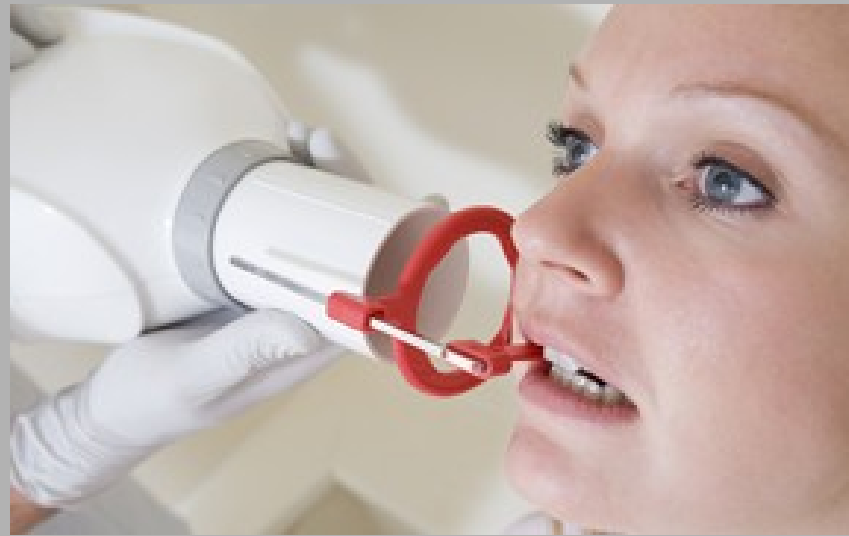serial radiogram TMJ

- x-ray beam pass vertical +25° to center of film
- entering 6-7cm over meatus acusticus.

- condyl head
- fossa glenoidalis
- close mouth
- open mouth

Intraoral X-ray device

- voltage of X-ray tube
 - 50-90 kV
- filtration of primary beam
 - 1,5 mm Al - $U < 70$ kV
 - 2,5 mm Al - $U > 70$ kV
- body tube
 - length of body tube = 10-30 cm



RADIATION PROTECTION

- Use of proper exposure and processing techniques
- Patients should be shielded with lead aprons and thyroid shields.
- These shields should have at least 0.5 mm of lead equivalent.
- Film badges

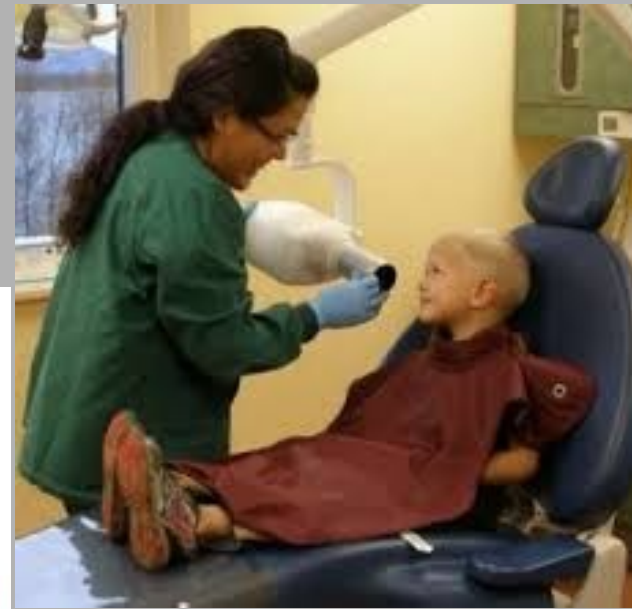
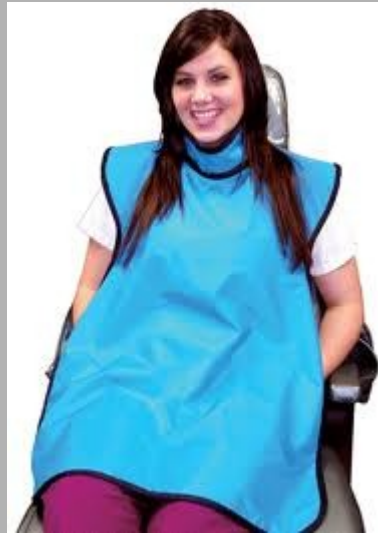


IMAGE RECEPTORS

- **RADIOGRAPHIC FILM**
- **DIGITAL RECEPTORS**
- **indirect digital imaging**



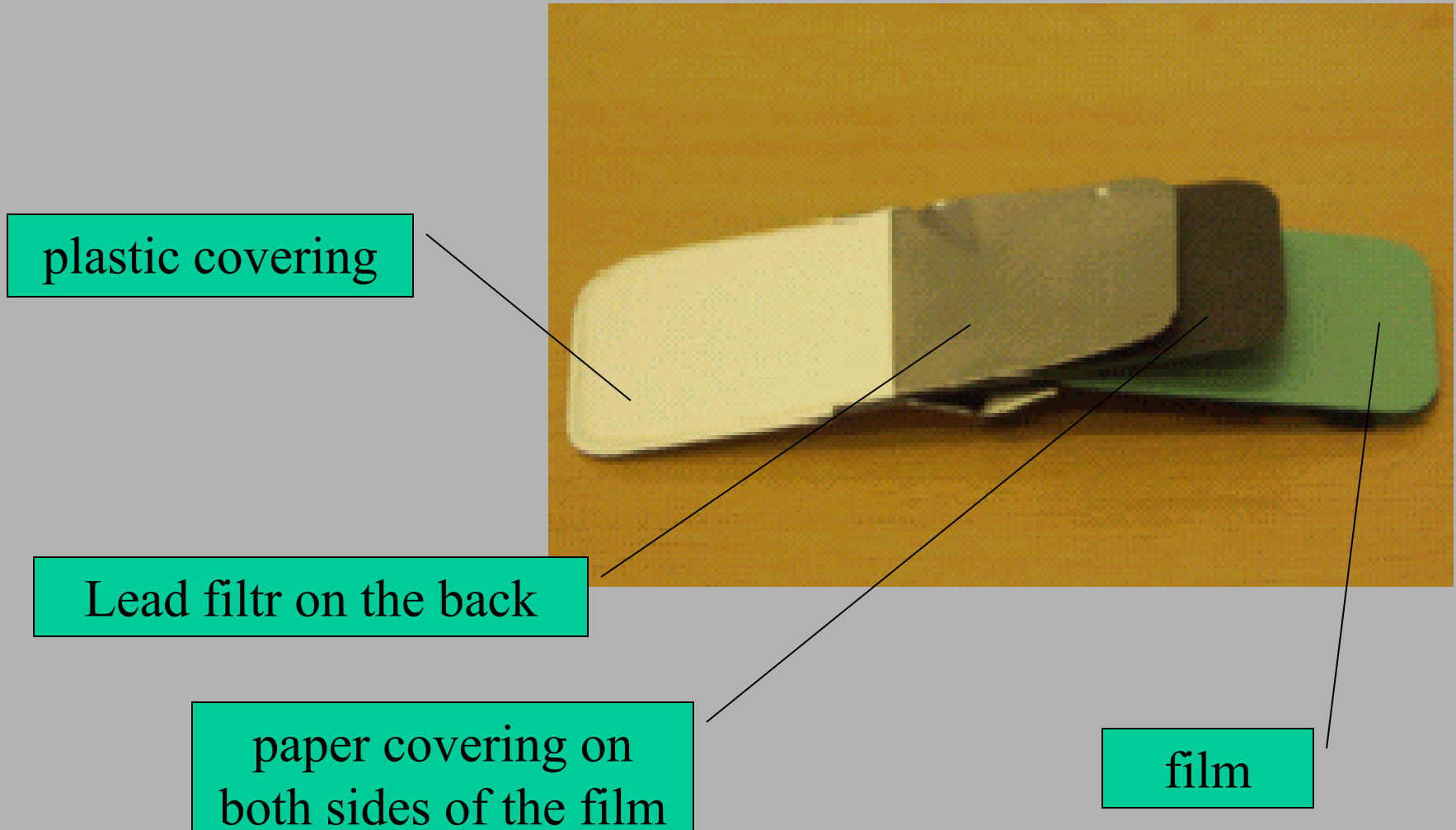
Conventional and digital technique

- Digital:
 - CCD (charged coupled device) as a sensor



Films for intraoral exposure

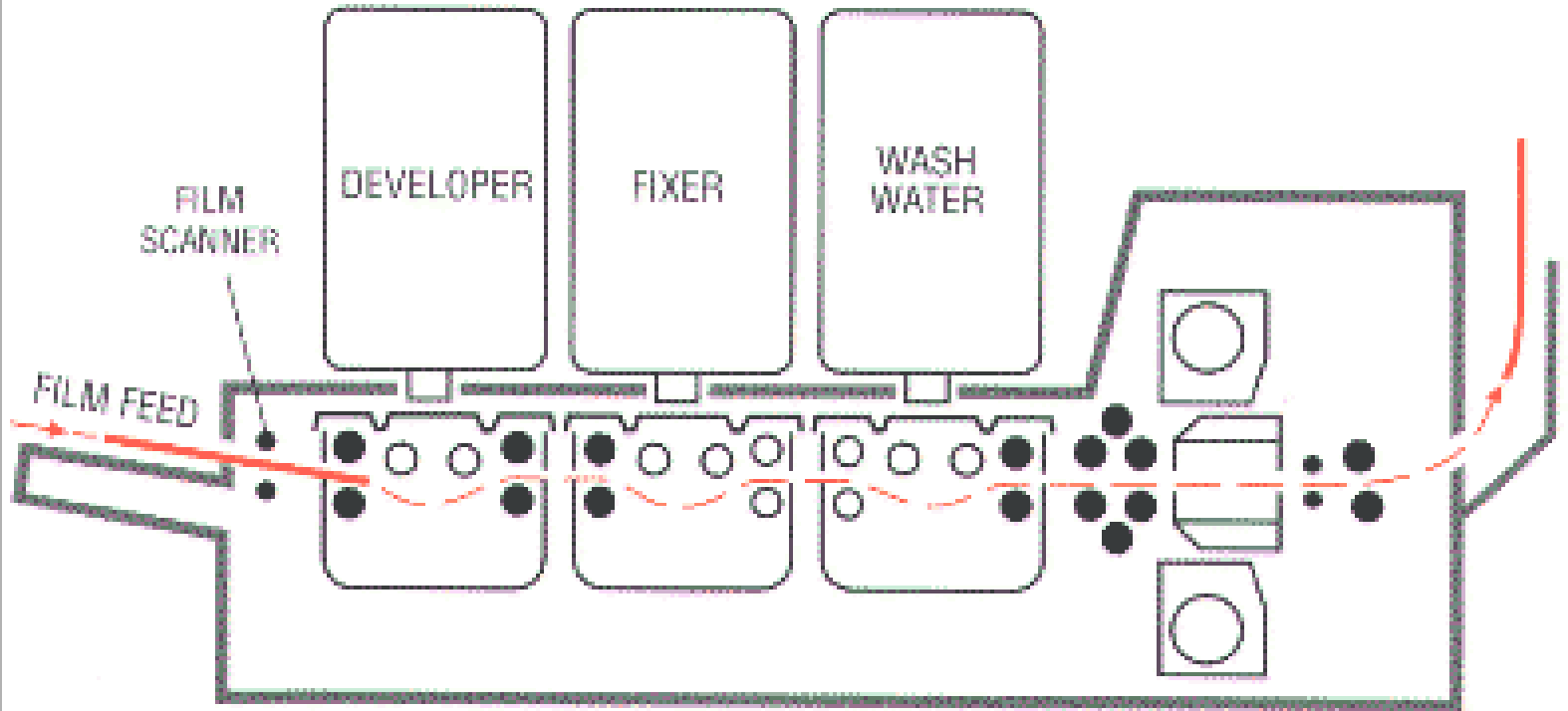
- dental films



SIZES

- Various sizes available, although only three are usually used routinely:
- For periapical & bitewings
 - 31 X 41 mm
 - 22 X 35 mm
- For occlusal
 - 57 X 76 mm

Film processing:



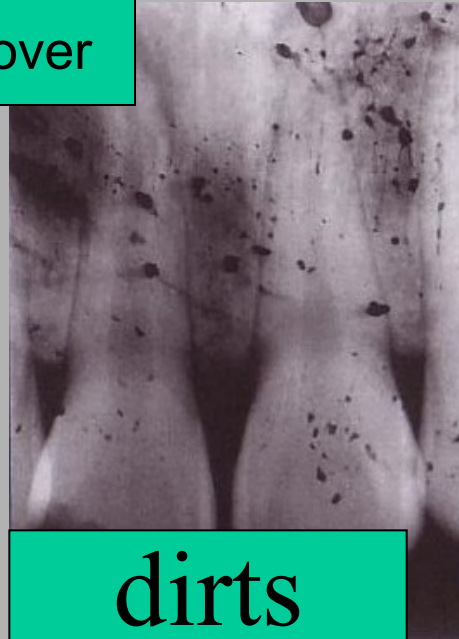
- RUBBER ROLLERS
- PVC ROLLERS

Automatic processing machine

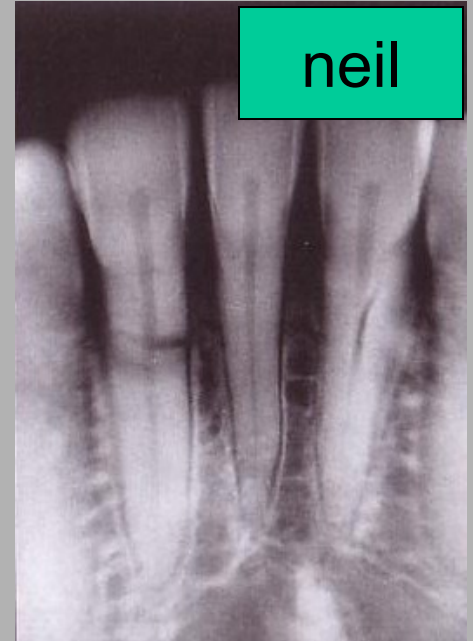


Conventional film processing - artifacts

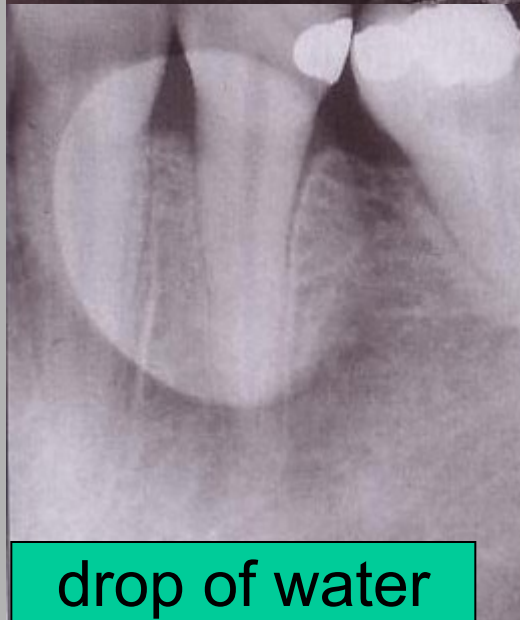
too fast taking film out of the cover



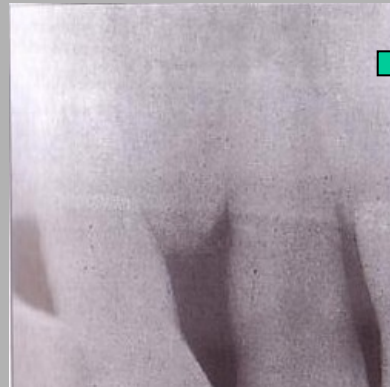
dirts



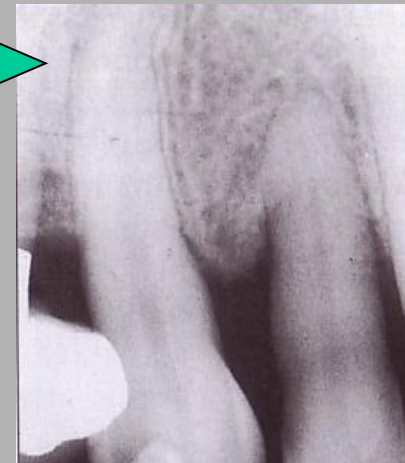

nail



drop of water

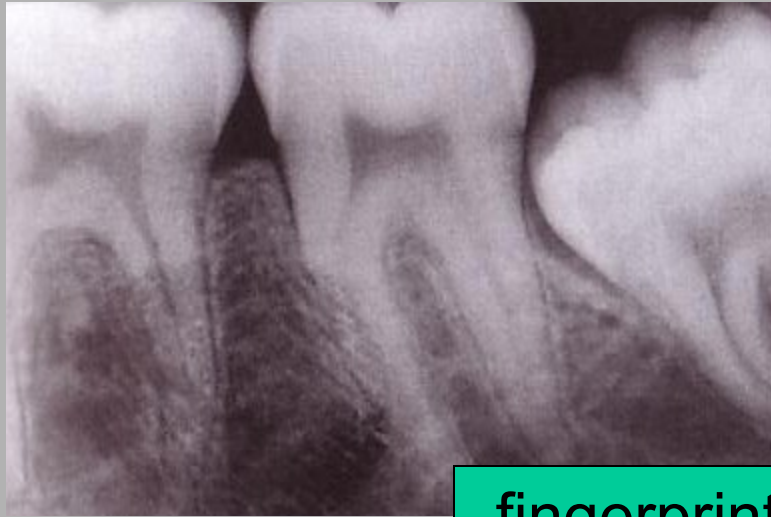

cold chemicals
film is grainy

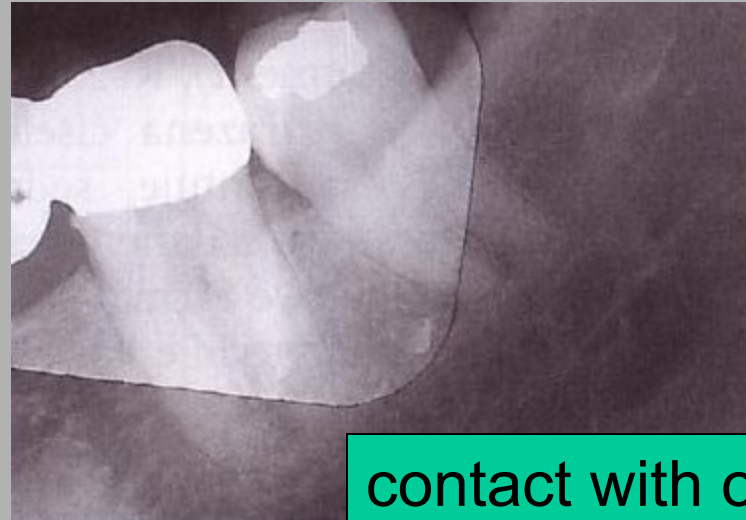


correct temperature

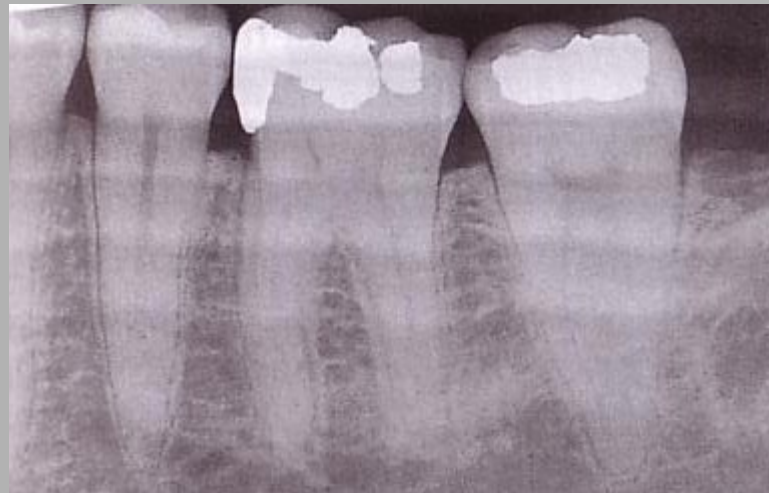Conventional film processing - artefacts



fingerprint

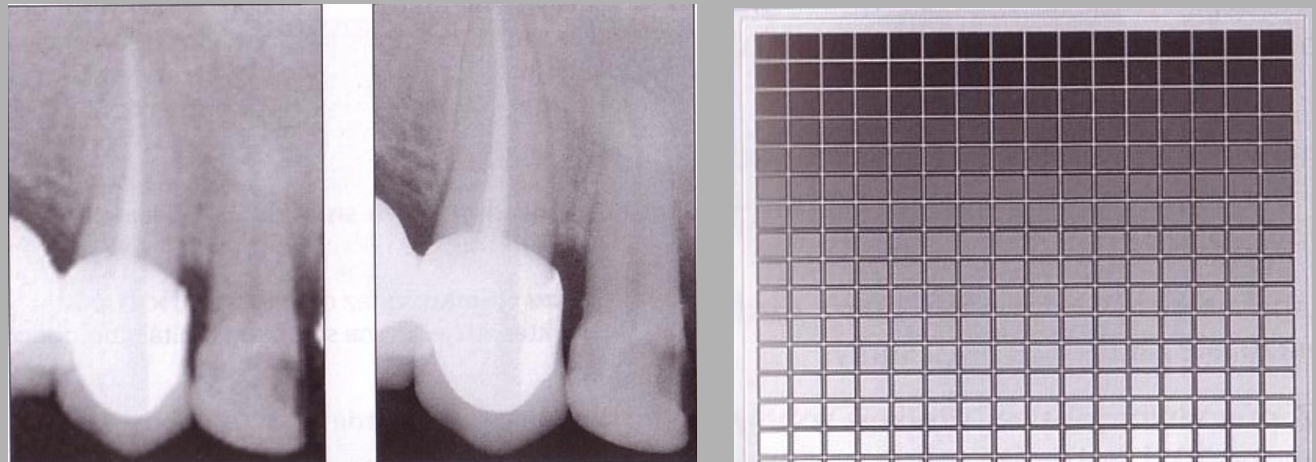
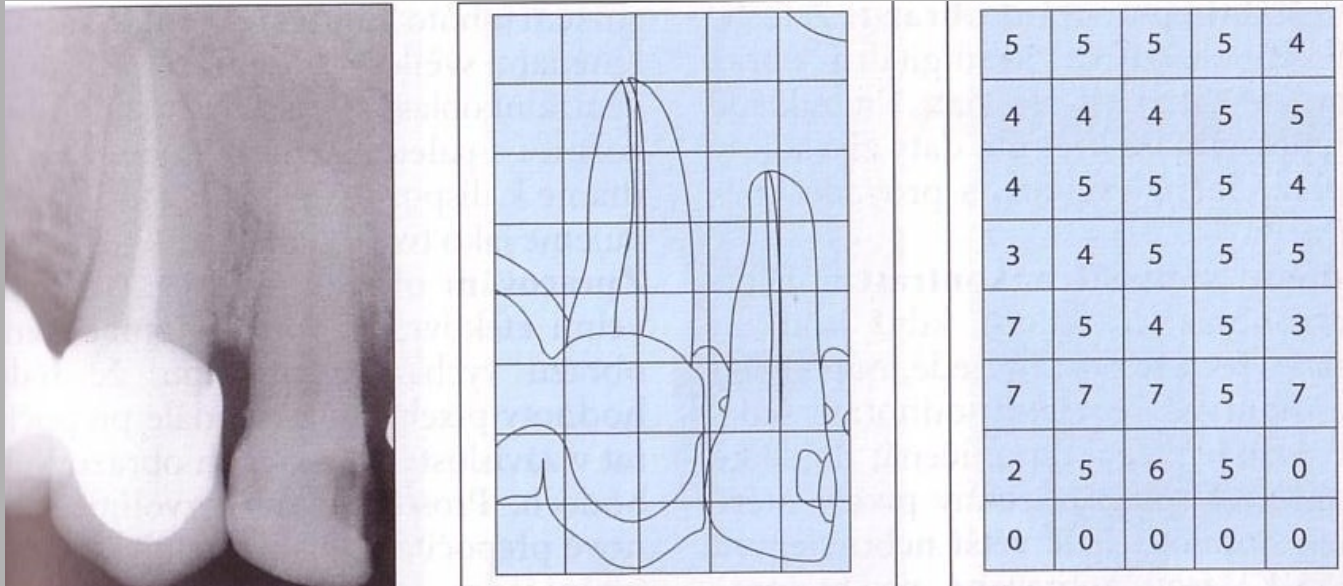


contact with other film



too high temperature during developing

Digital technique




amount of radiation incident on the detector at any spot is coded by gray shade – with 256 different gray shades

Digital technique - advantages

- filmless performance
- friendly inspecting and storage of pictures
- repeated exposure without medium changing

Indirect digital imaging



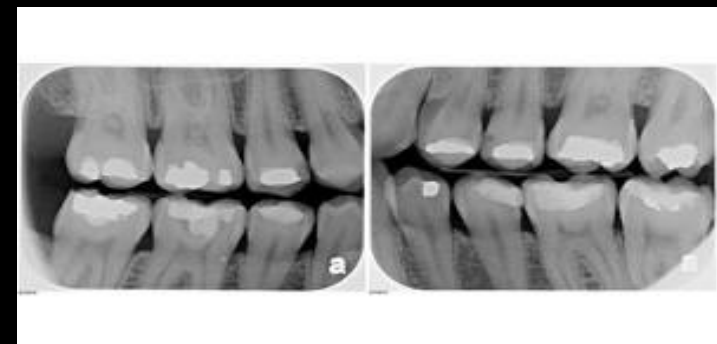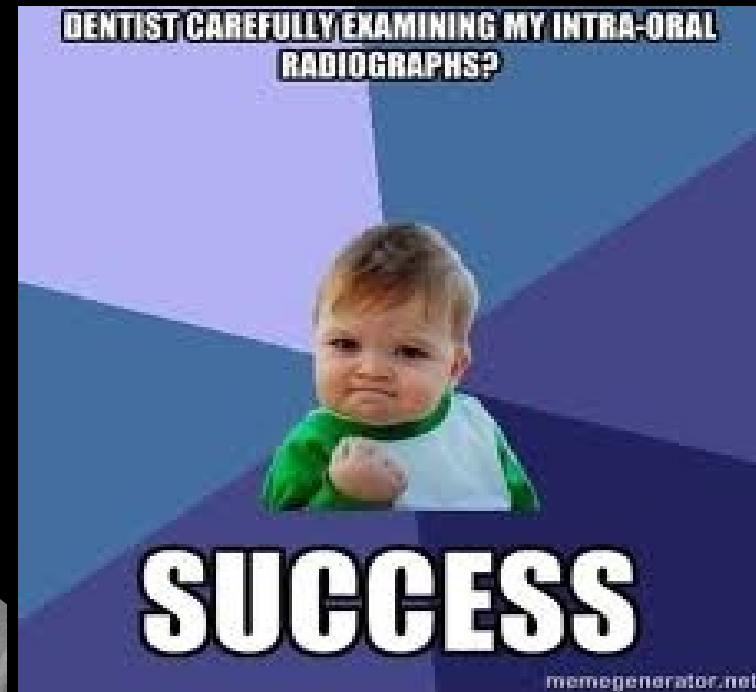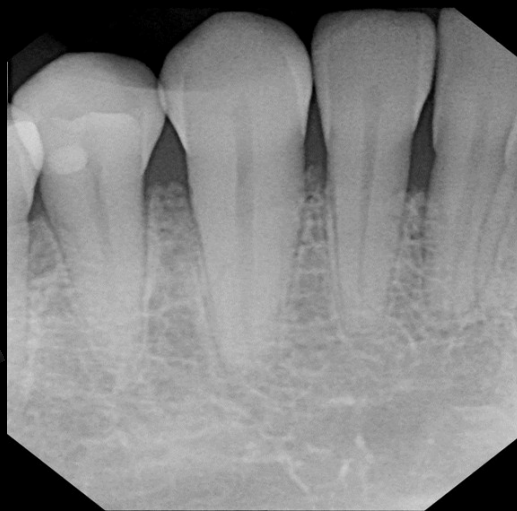
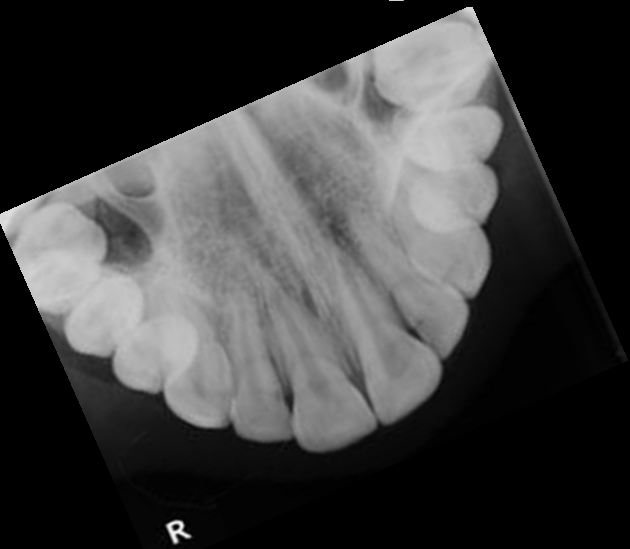Existing X-ray film digitized using CCD camera

Scans the image

Digitizes displays on computer monitor

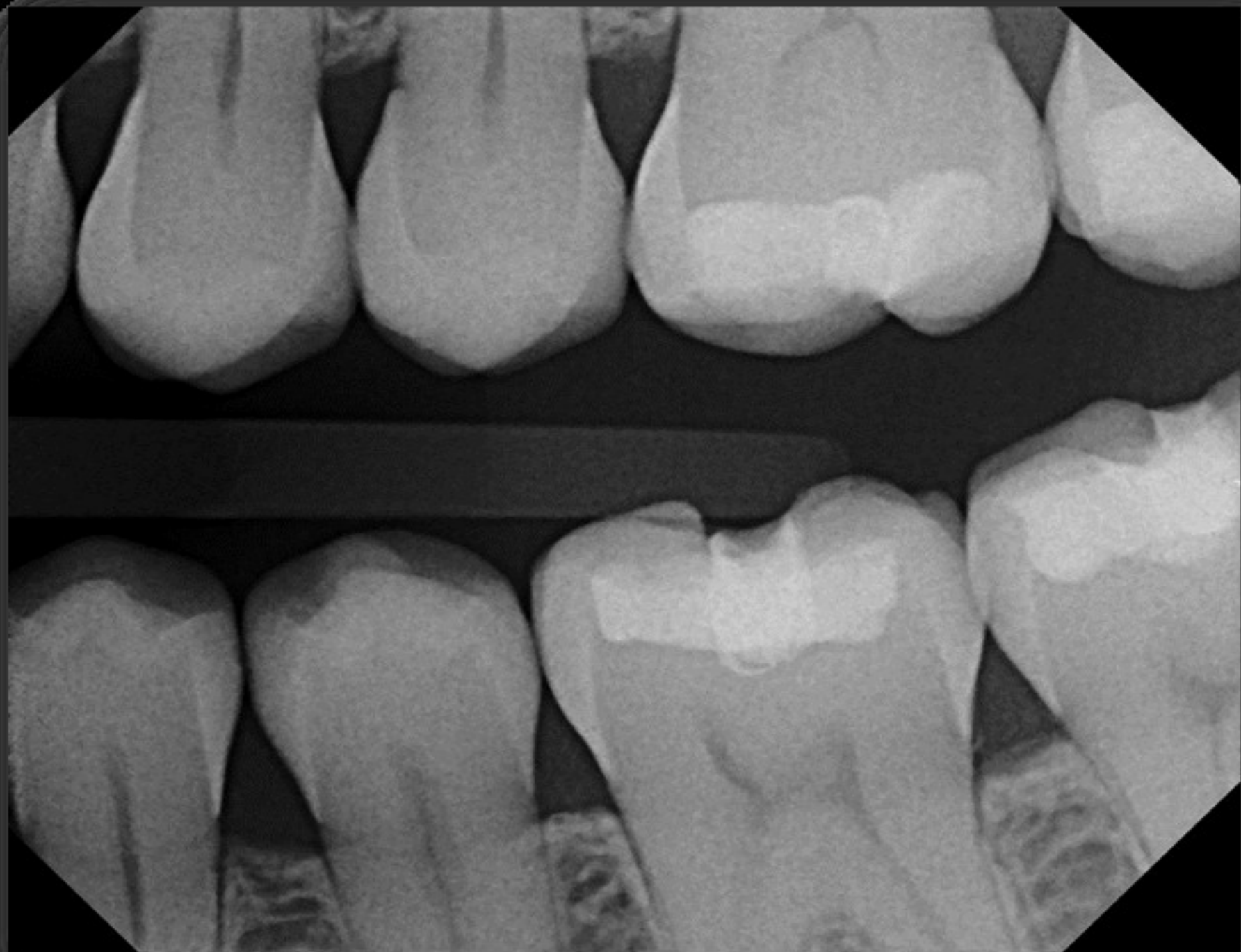
INTRA ORAL RADIOGRAPHS

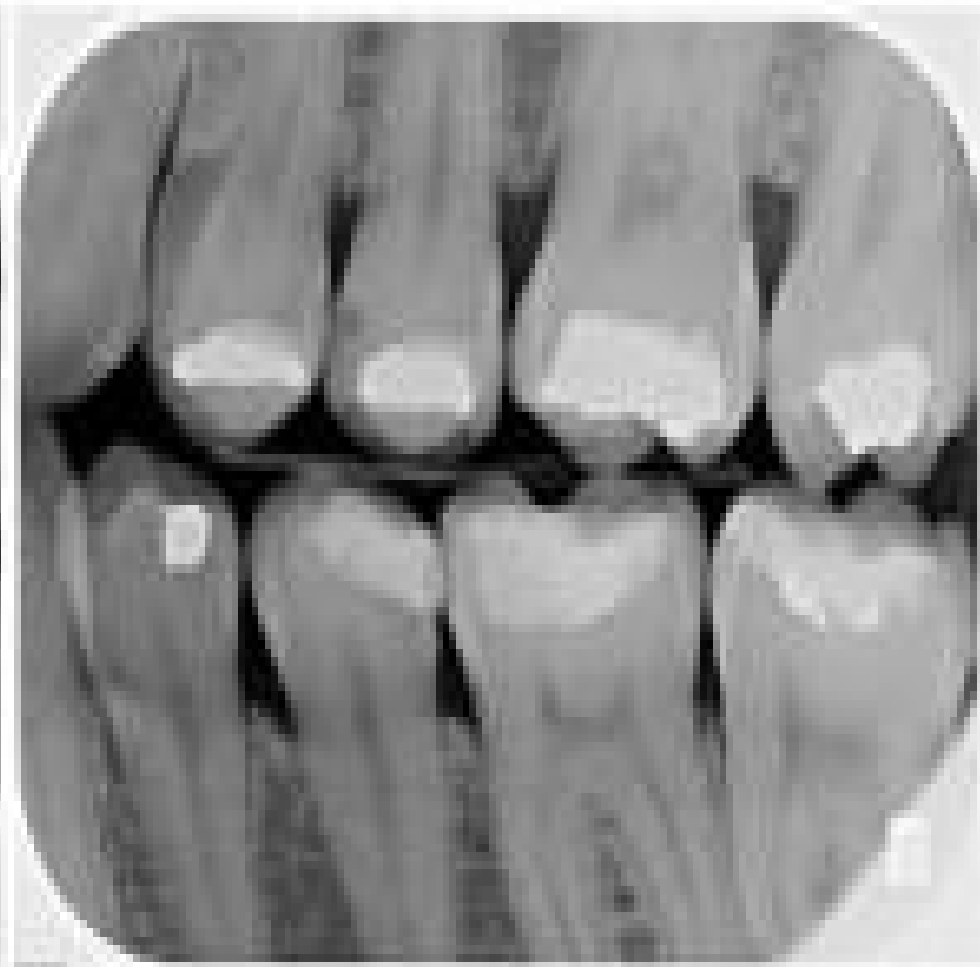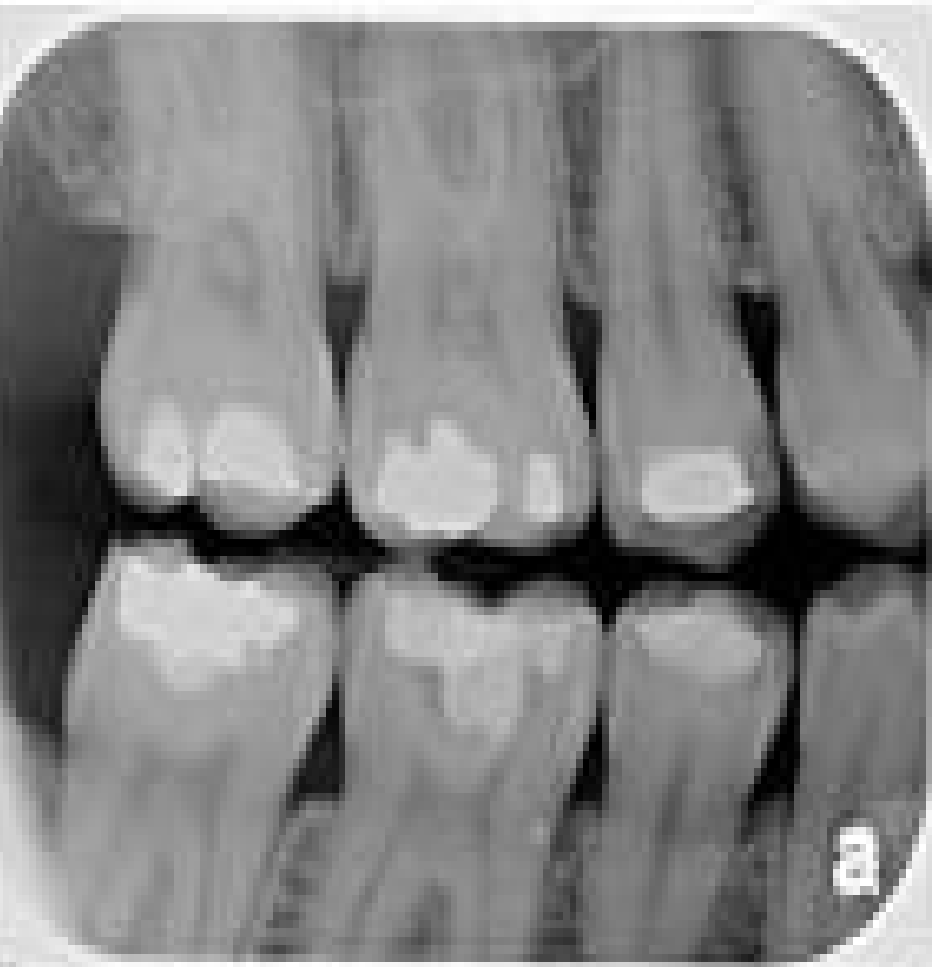- Bitewing
- Occlusal
- Peri apical



BITEWING

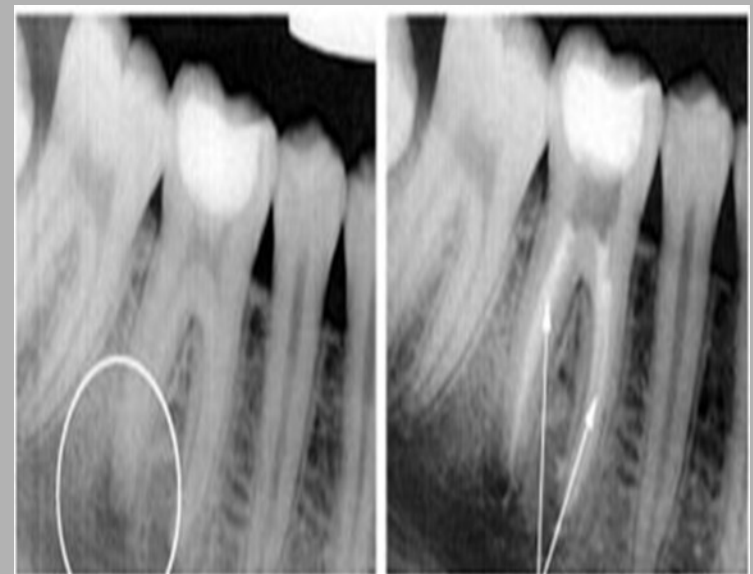
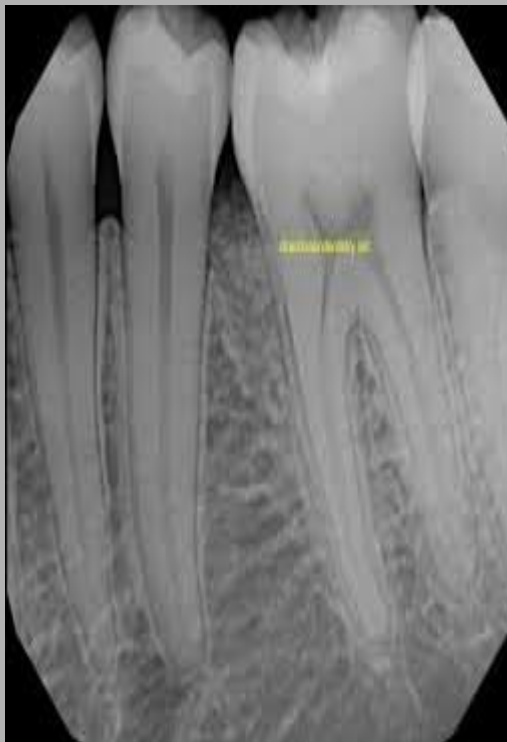
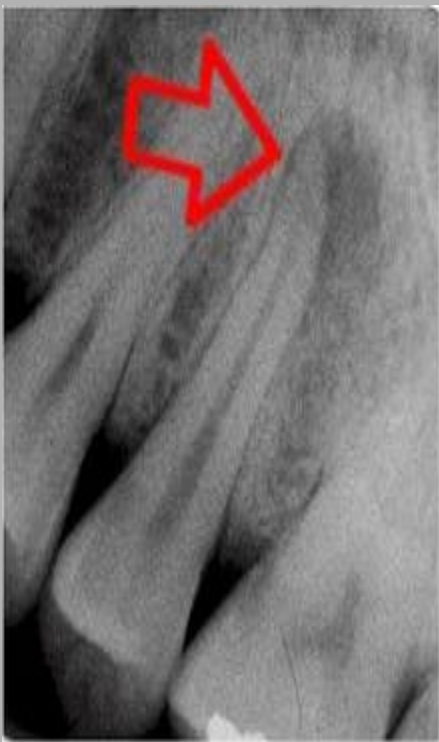- **So called because patient closes the teeth together biting on a wing of card projecting from the tube side of the film**
- **Demonstrates occlusal surfaces, interproximal surfaces of enamel, enamel-dentine junction & the bone levels surrounding the tooth**
- **Used for pre-molars, molars**
- **indications: dental caries, assessment of fillings & crown, periodontology**





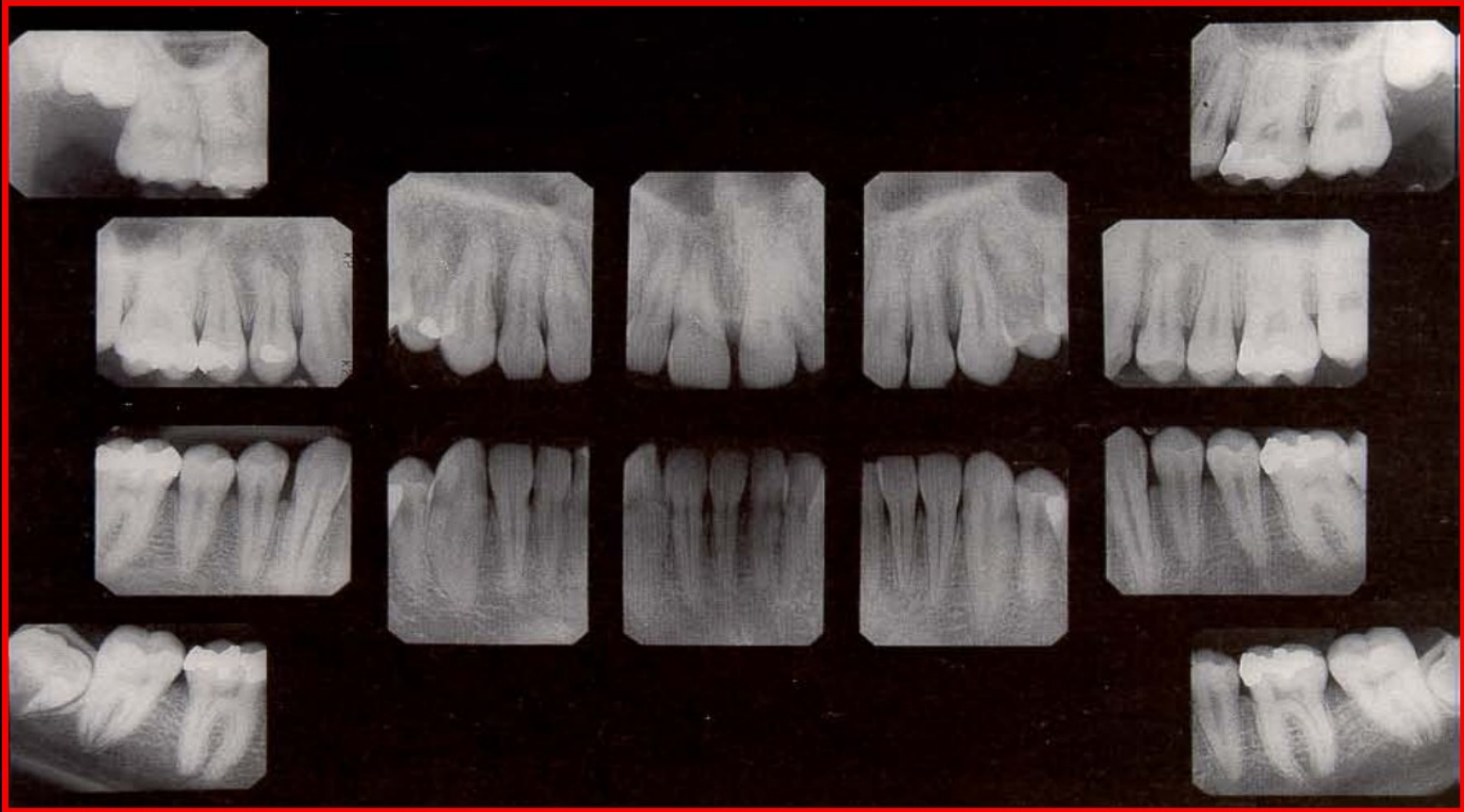PERIAPICAL

- Shows usually 2-4 teeth, individual teeth & tissues around apices



Infection, tooth in need of
Root Canal Treatment

After Root Canal Treatment



Typical 14 film survey for adults

The central rays is targeted onto the apex; depiction of the alveolar crest is of only secondary importance.

INDICATIONS

- Detection of **apical infection**
- Assessment of **periodontal** status
- After **trauma to teeth** & **associated alveolar bone**
- Assessment of root morphology **before extraction**
- During **endodontics**
- Detailed evaluation of **apical cyst** & other lesion within the bone
- Evaluation of **implants postoperatively**

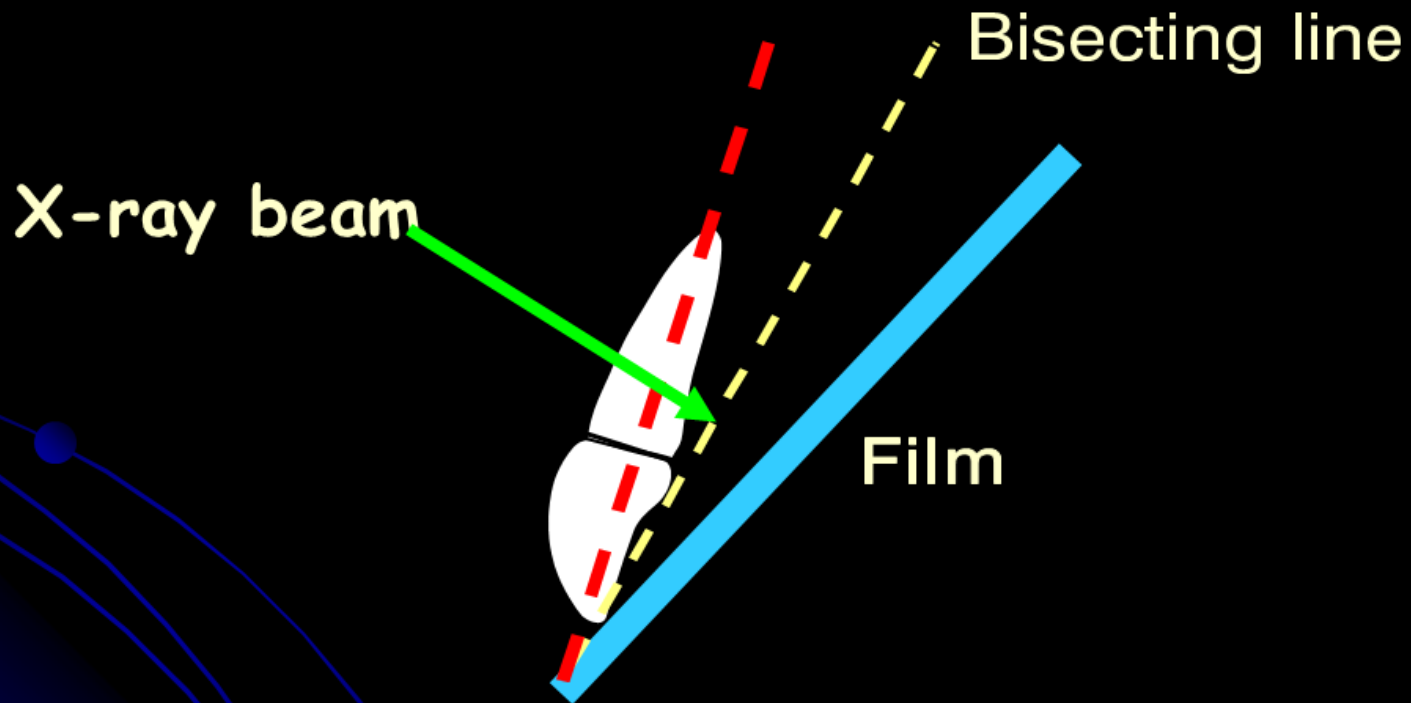
Techniques for Periapical radiography

Paralleling technique

Bisecting angel technique.



Bisecting angel technique.

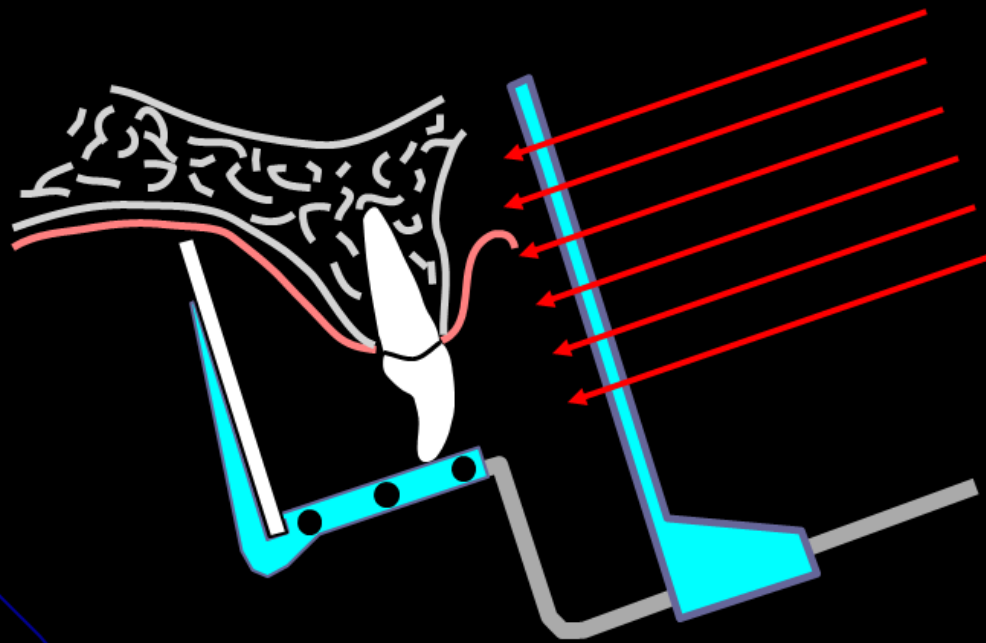


X-ray beam perpendicular to bisecting line

Paralleling technique

Right angle technique

Long cone technique



Advantages of Bisecting Angle Technique

- **More comfortable:** because the film is placed in the mouth at an angle to the long axis of the teeth, the film doesn't impinge on the tissues as much.
- **A film holder,** although available, is not needed. Patients can hold the film in position using a finger.
- **No anatomical restrictions:** the film can be angled to accommodate different anatomical situations using this technique

Disadvantages of Bisecting Angle Technique

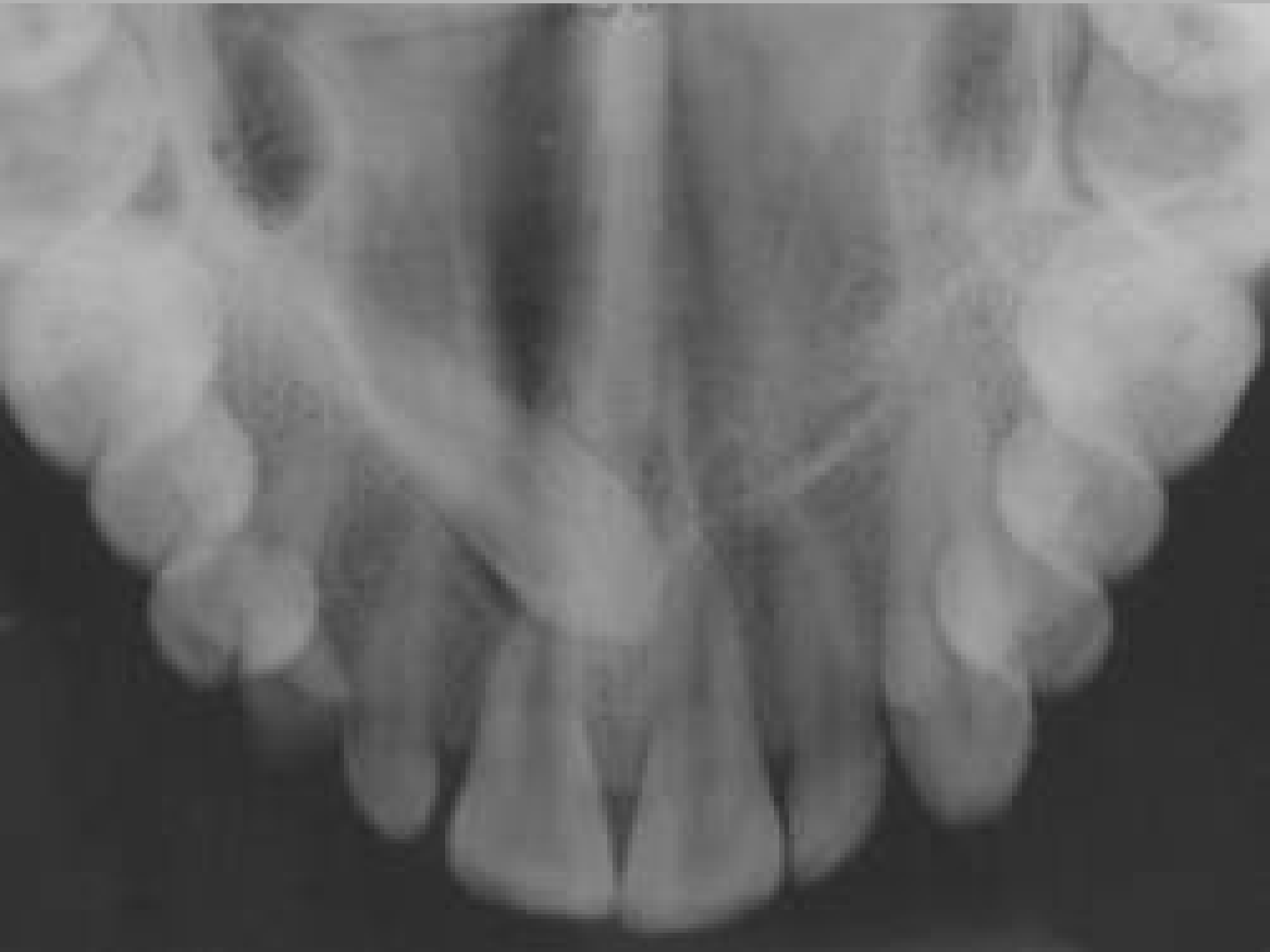- **More distortion:** because the film and teeth **are at an angle to each other** (not parallel) the images will be distorted.
- **Difficult to position x-ray beam:** because a film holder is often not used it is difficult to visualize where the x-ray beam should be directed.
- **Film less stable:** using finger retention, the film has more chance of moving during placement

OCCLUSAL

- **Utilize the largest intra oral film (6 X 8cm)**
- **Various projections**
- **Maxillary occlusal projections**
 - Upper standard
 - Upper oblique standard
- **Mandibular occlusal projections**
 - lower 90 degree occlusal
 - lower 45 degree occlusal
 - lower oblique occlusal

Indications

- Identify large lesions
- Determine bucco-lingual location
- View developing anterior dentition
- Image patients with trismus (if panorama not available)

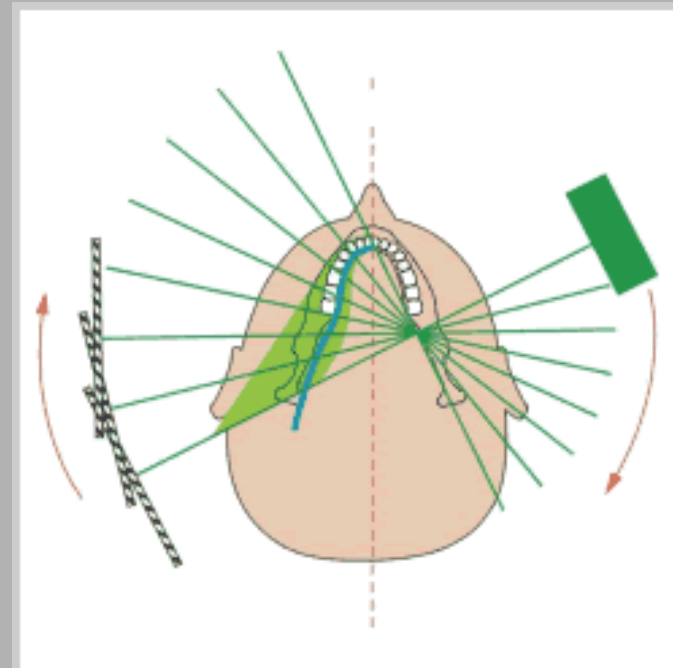
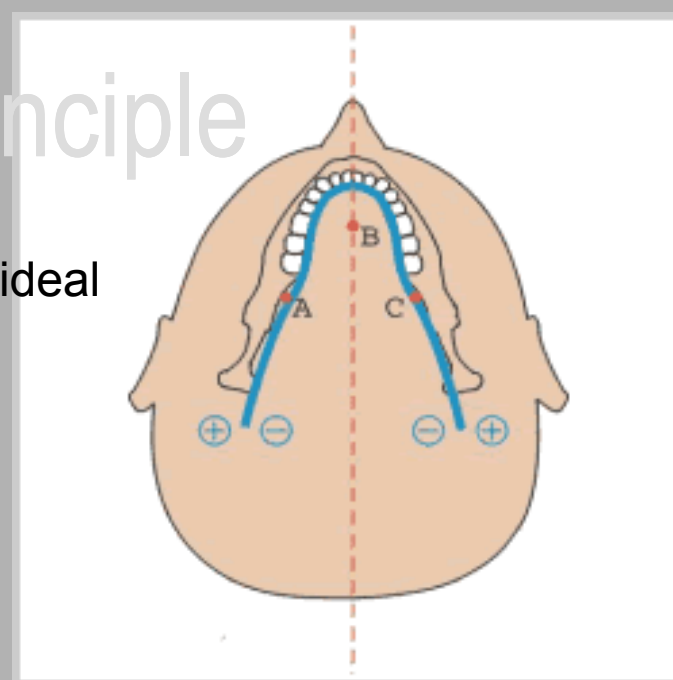


OPG - Orthopantomography

Single image of facial structures that
includes maxillary
and mandibular arches
and their supporting
structures.

Ortopanthomography - principle

- X-ray tube goes around the head on the track of ideal teeth occlusion - parabola
- There are 3 rotatory centra very next to the teeth occlusion



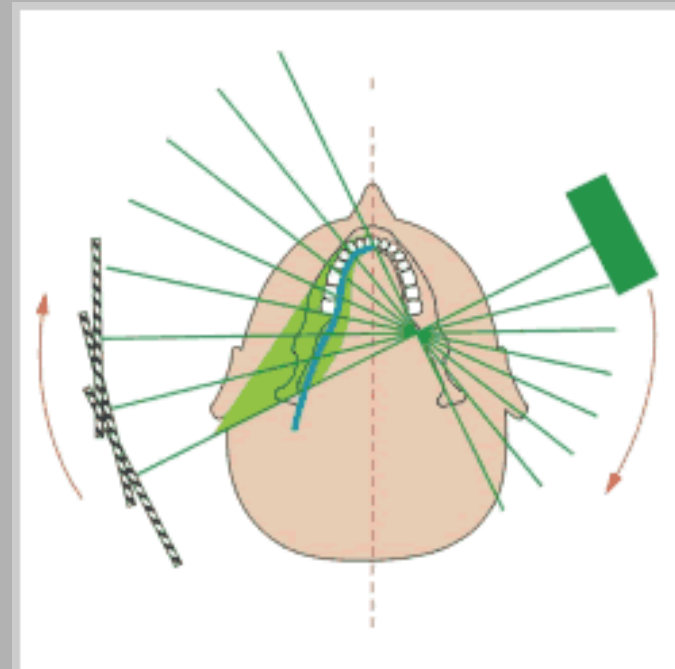
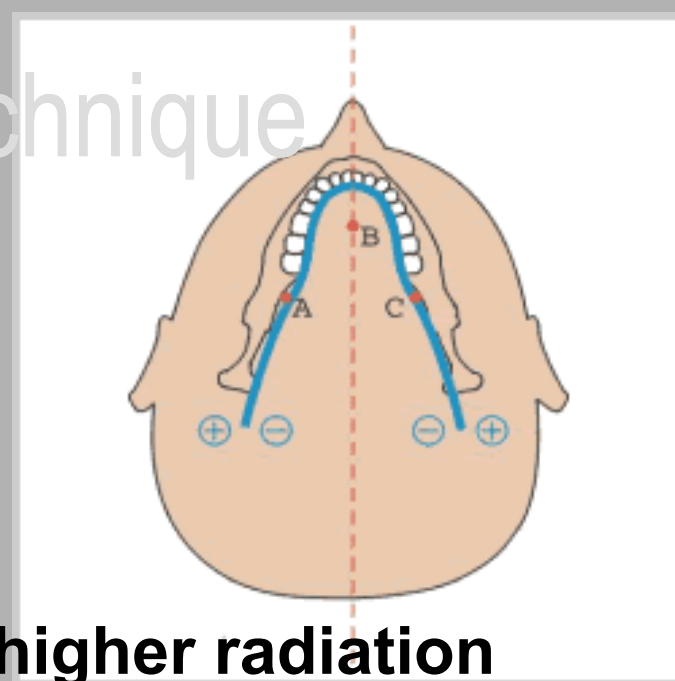
Ortopanthomography - technique

- **leyer thickness**

- ✓ from 9 mm (frontal part)
- ✓ till 20 mm (in the area of TMJ)

– **thinner leyer = less artefacts, higher radiation dose**

- defocus
- zoom
- possibility of mesuring



Indications

- Evaluation of trauma
- Third molars
- Large lesions
- Tooth development
- Developmental anomalies
- Intolerant to intraoral procedures

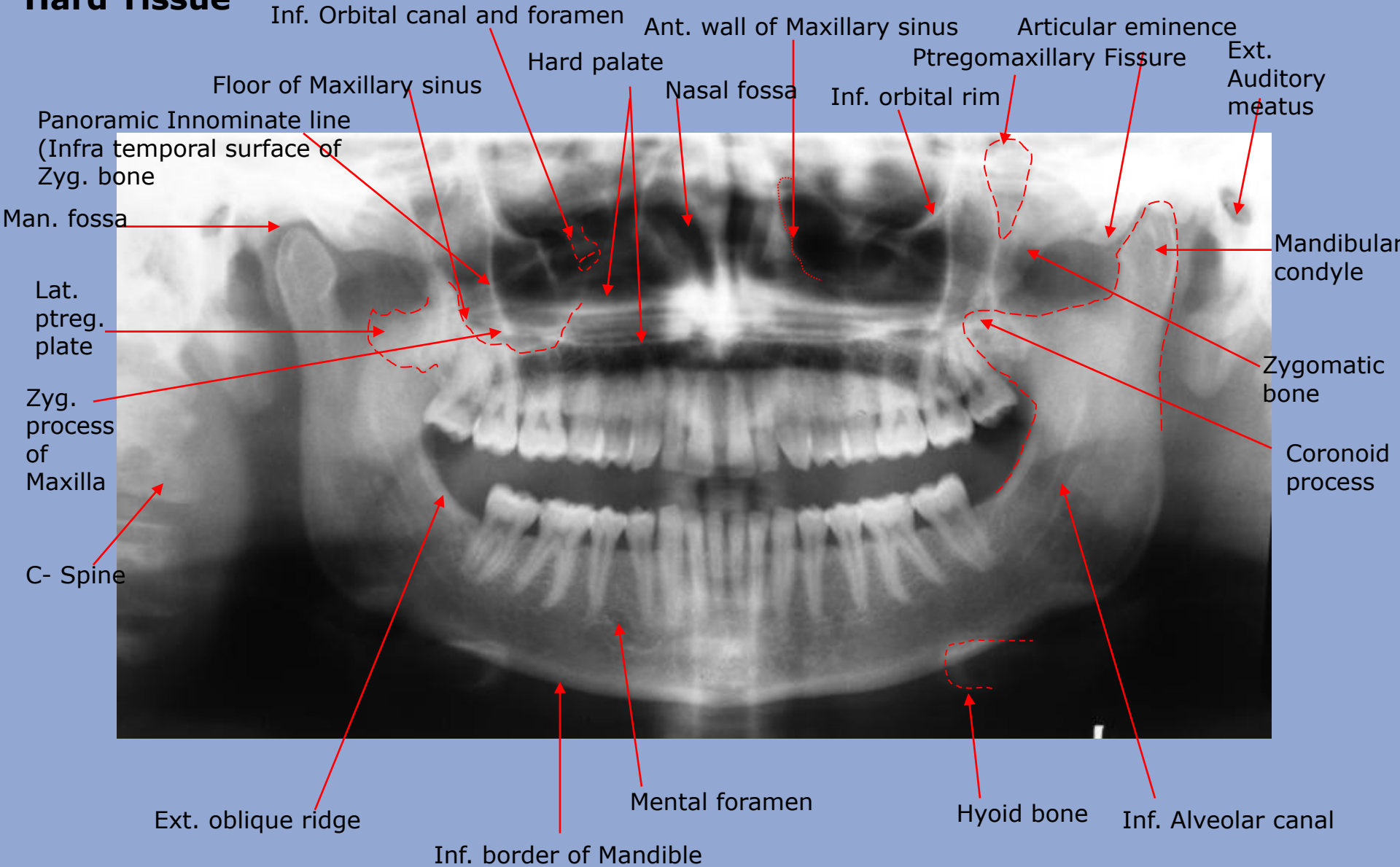
Advantages...

- Broad anatomic coverage
- Low patient radiation dose
- Convenience of examination
- Used in patients unable to open mouth

Disadvantages

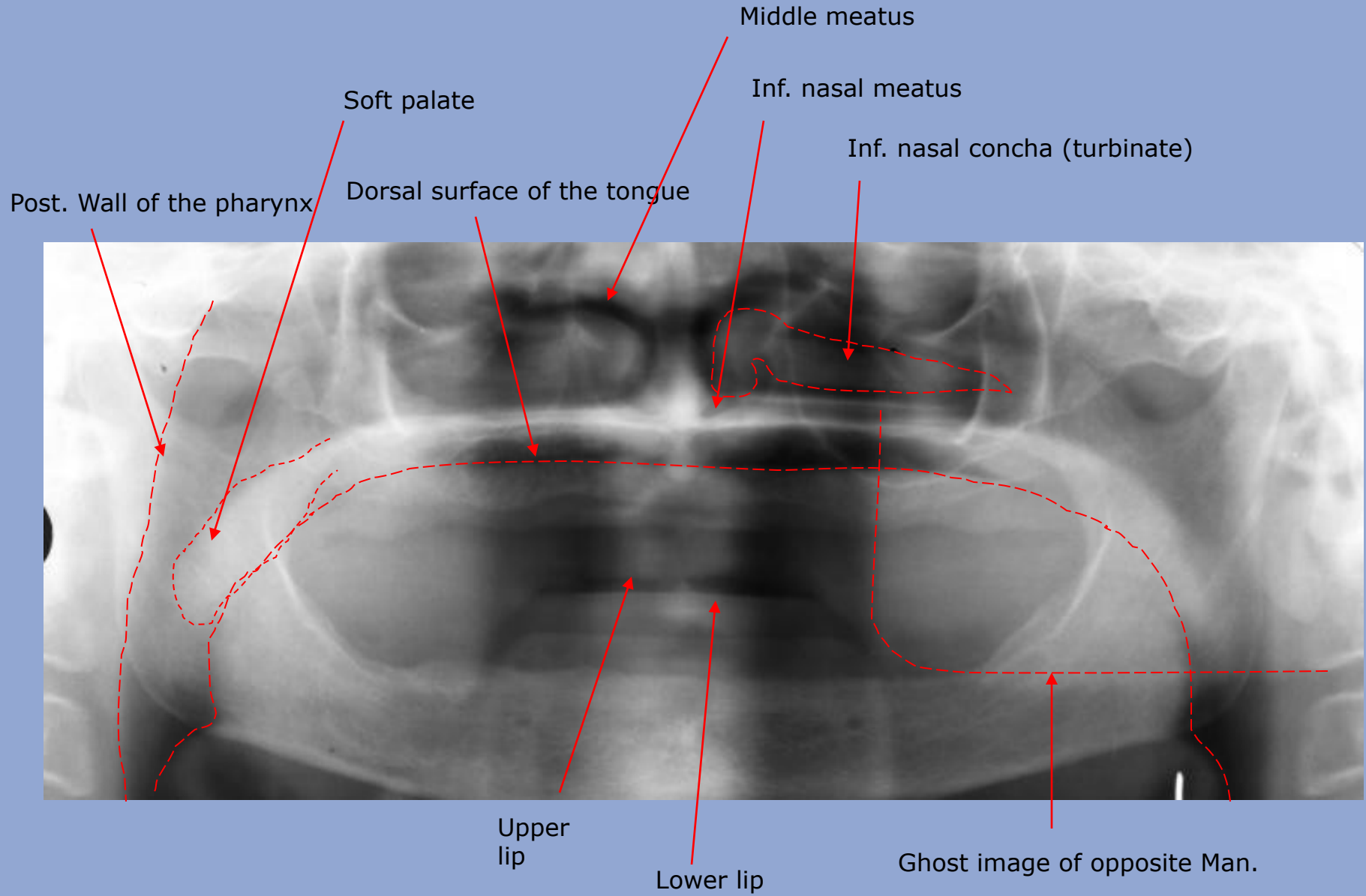
- Does not show fine anatomic details
- Magnification
- Distortion
- Overlapped image of teeth
- Expensive

Hard Tissue



All this diagnostic information is missed in intraoral X-rays

Soft tissue (edentulous)

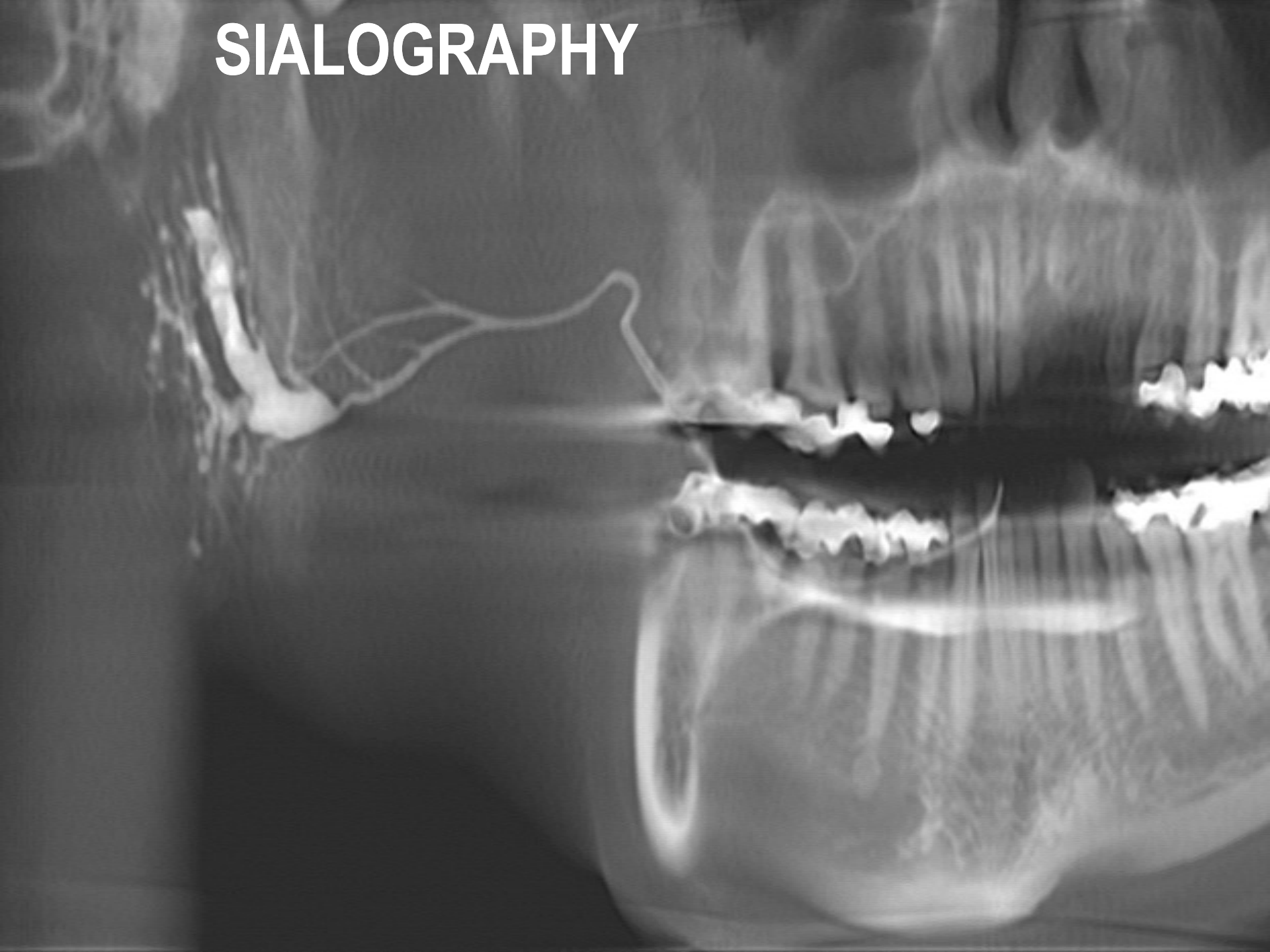

All this diagnostic information is missed in intraoral X-rays

Other imaging modalities:

Contrast studies

SIALOGRAPHY

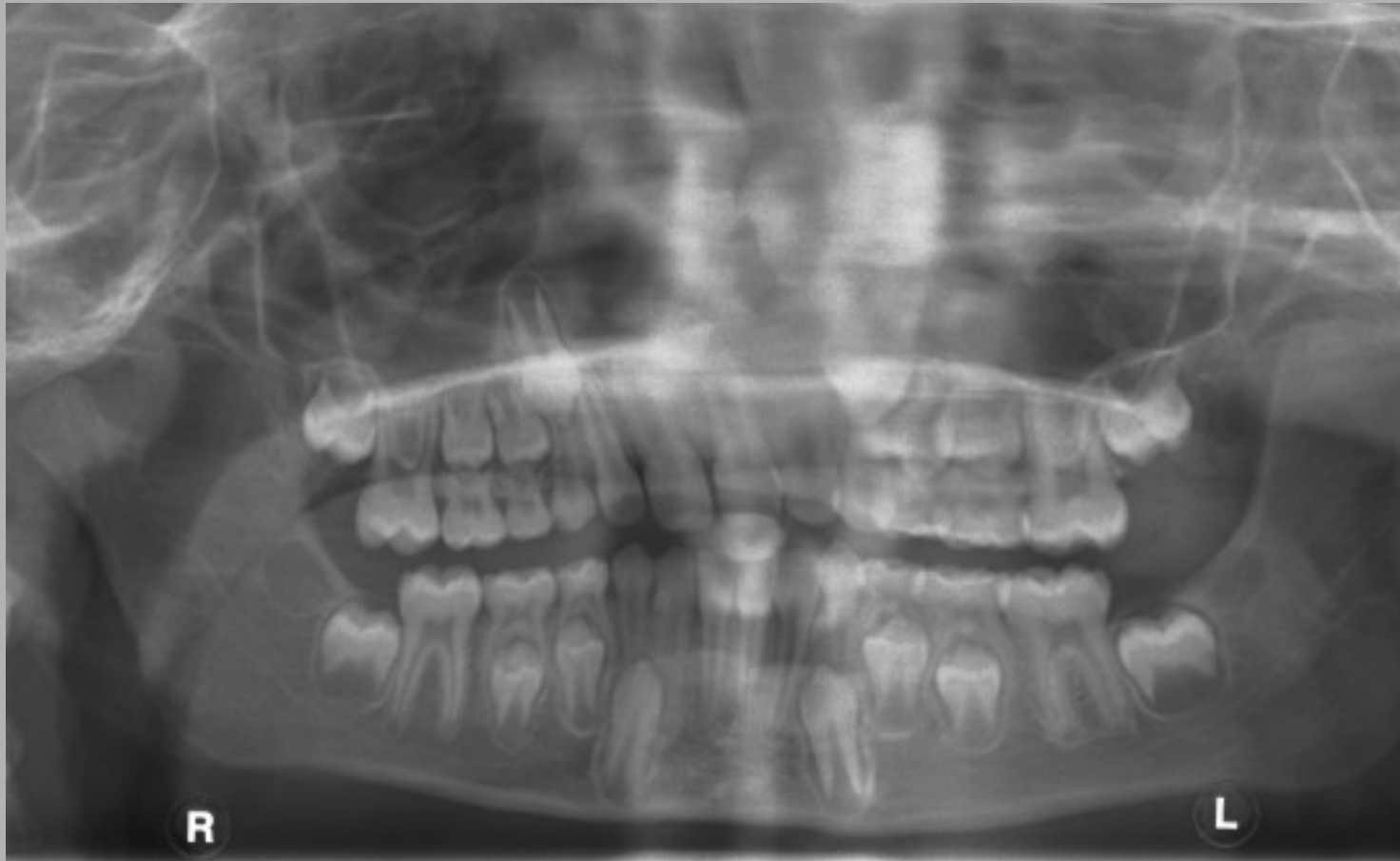

Basic pathologies on plain Xray images

Basic pathologies on plain Xray images

- 1) Dental Retention
- 2) Calcifications, salivary stones
- 3) Parodontopathies, inflammations, caries
- 4) Temporomandibular joint diseases
- 5) Jaw cysts
- 6) Tumors
- 7) Fractures

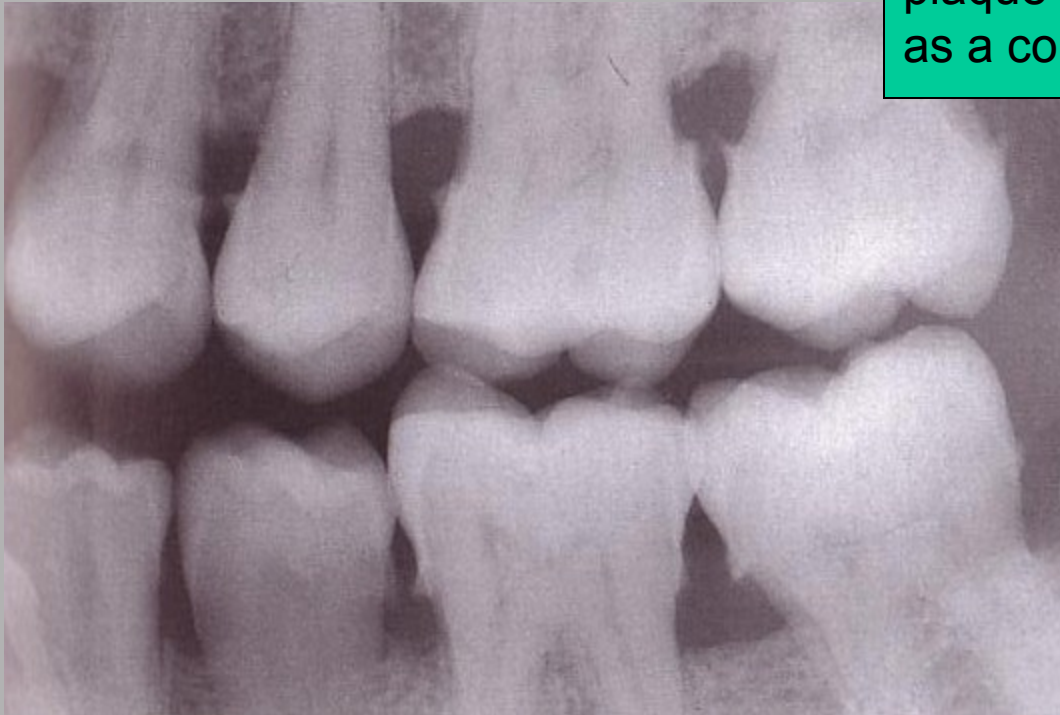1) Retentio dentes



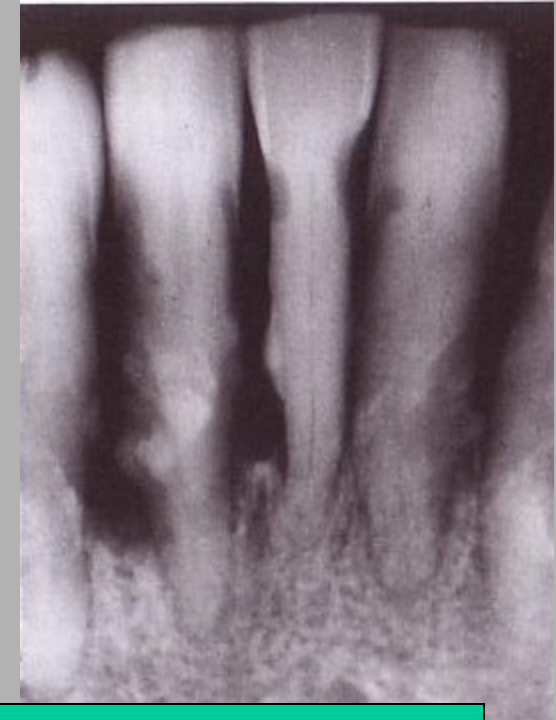
2) Calcifications, salivary stones

Tartar

tartar is composed of mineralized tooth plaque + generalized bone reduction as a consequence of parodont pathology



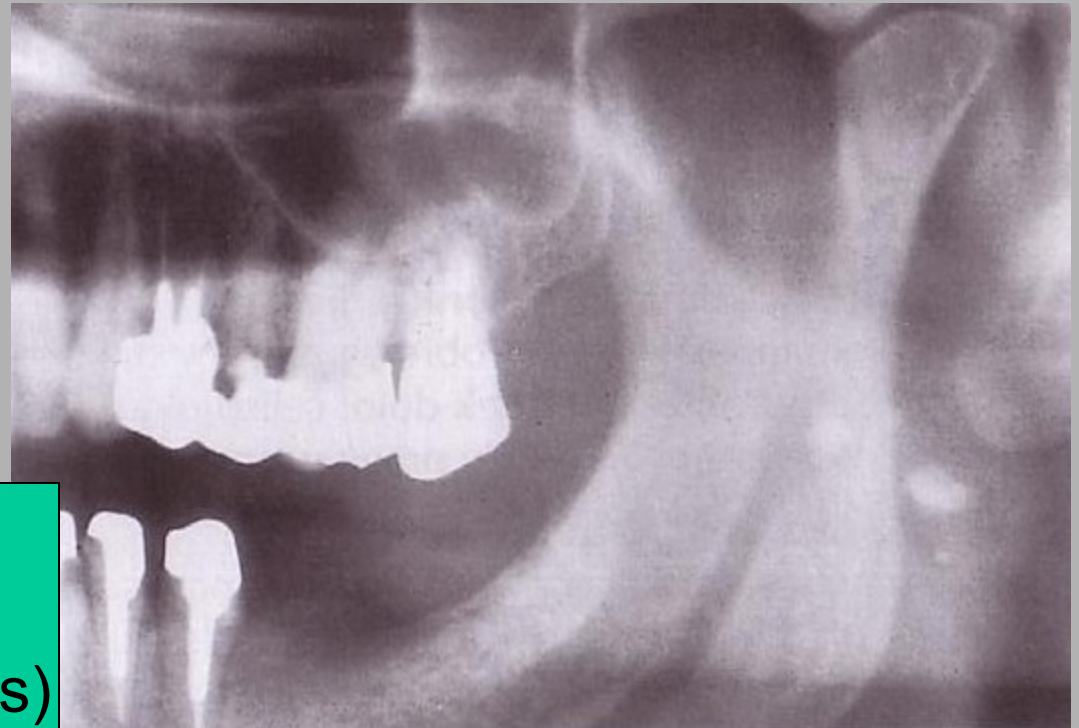
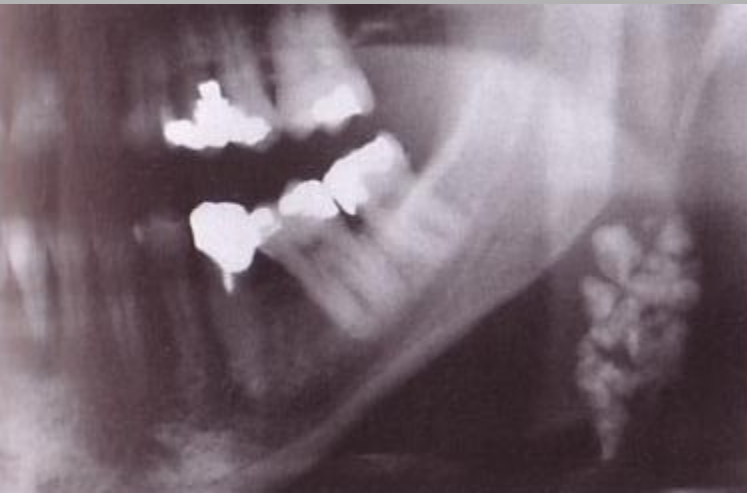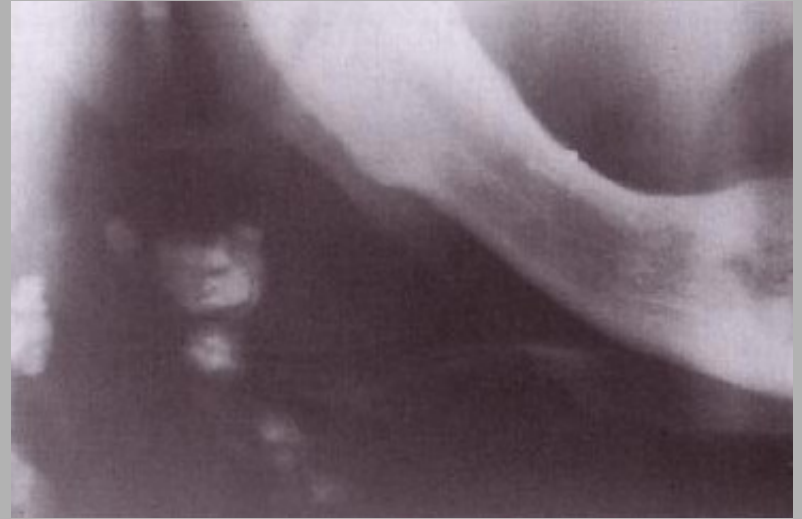- origins in area of outfall of main salivary glands
- calcium phosphate
 - x-ray opacity



parodontitis marg. profunda
sublingual tartar

2) Calcifications, salivary stones Concrements

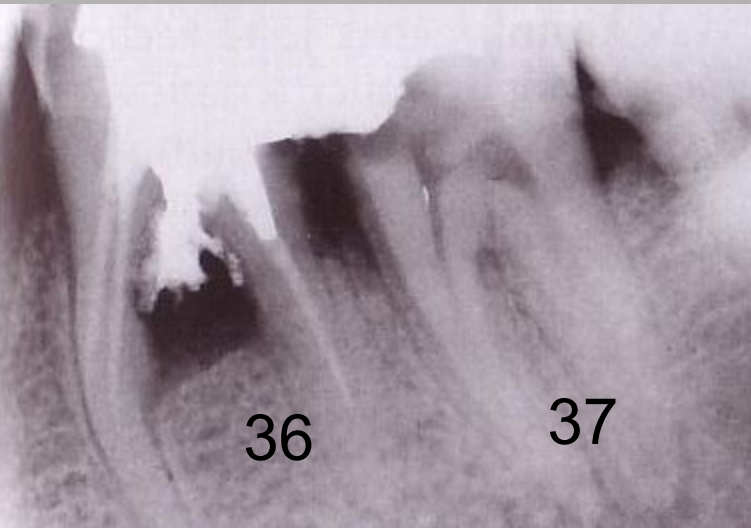
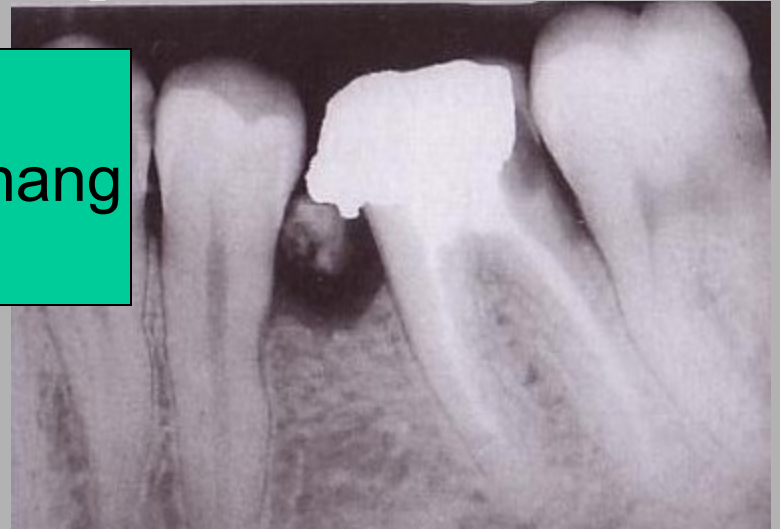calcified cervical lymph nodes



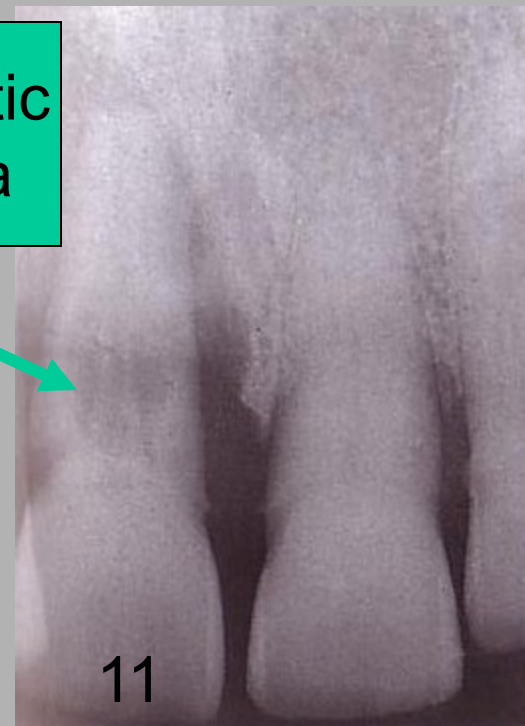calcification of gl. parotis
as a consequence of
parotitis epidemica (mumps)

Marginal periodontopathy

bone reduction between 35,37
as a consequence of amalgam overhang
caries 34,37,38



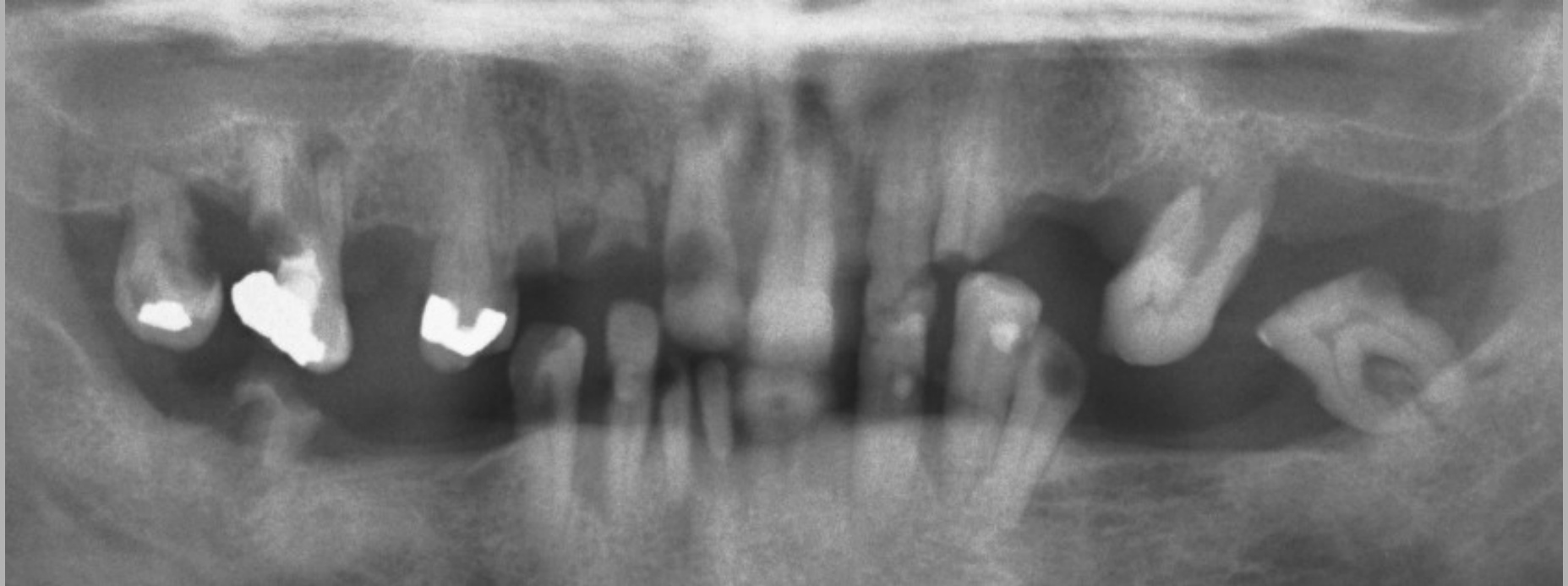
mezial posttraumatic
central granuloma



oversupply of root filling
injury to the desmodont and mesodont of tooth root
etiology: via falsa
= interradicular bone loss

11

apical periodontitis, caries acuta



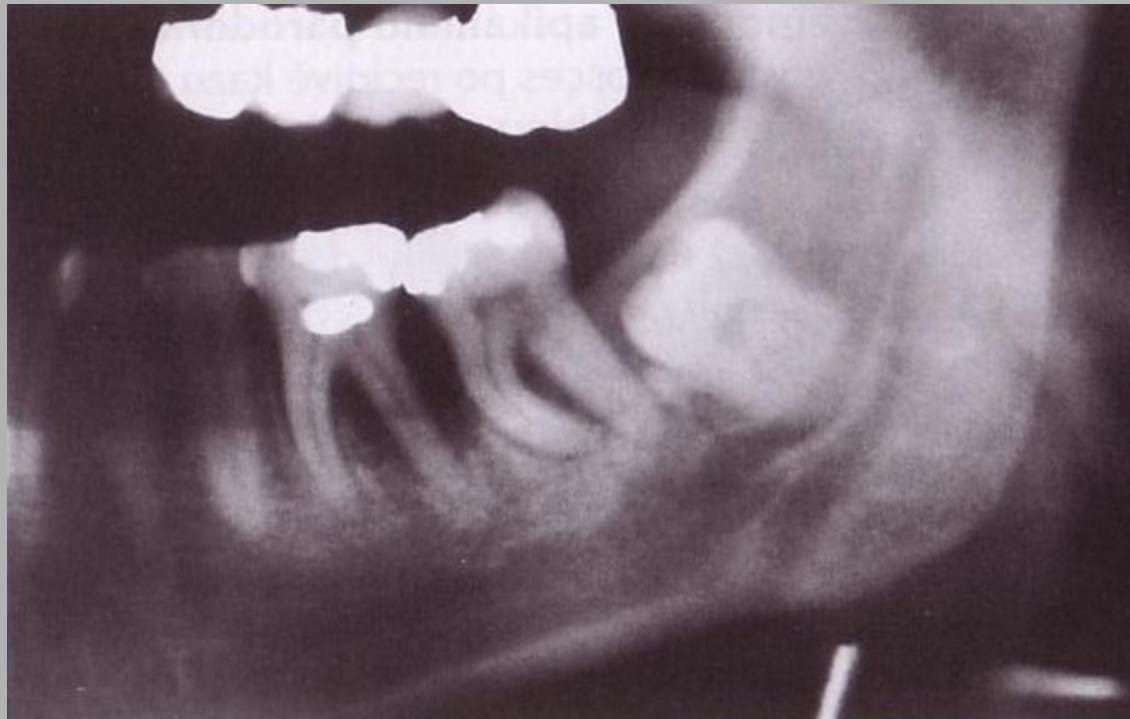Marginal periodontopathy

traumatic occlusion

etiology: fixed bridgework

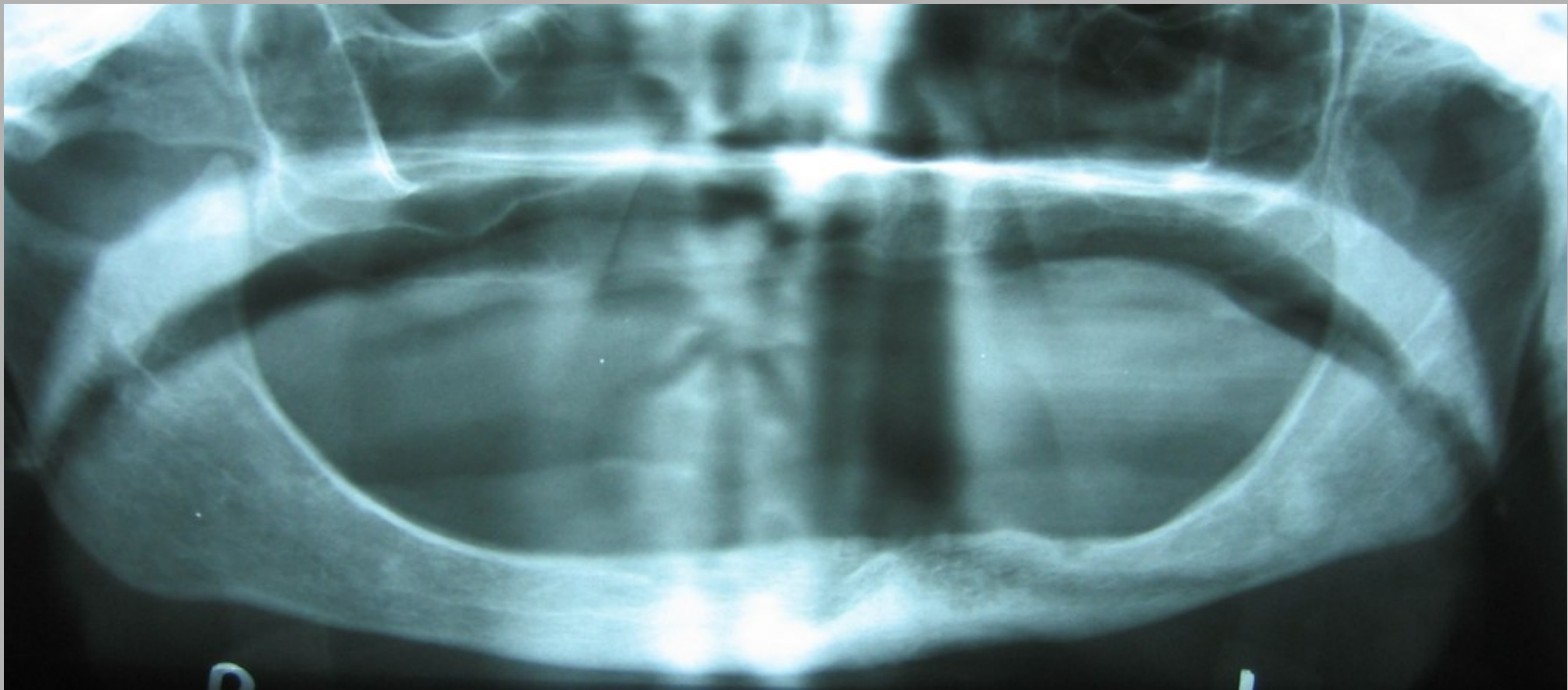
massive bone reduction

sclerotic reactive zone - apically (36,37)



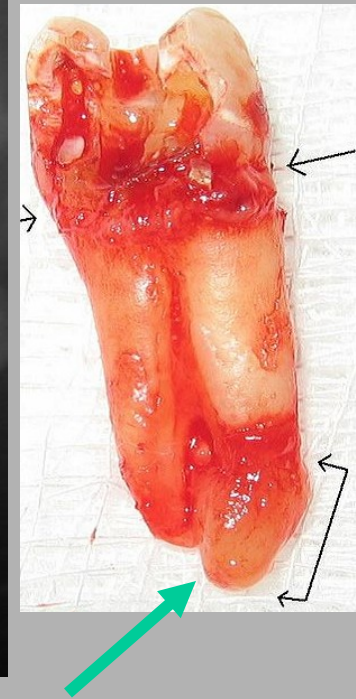
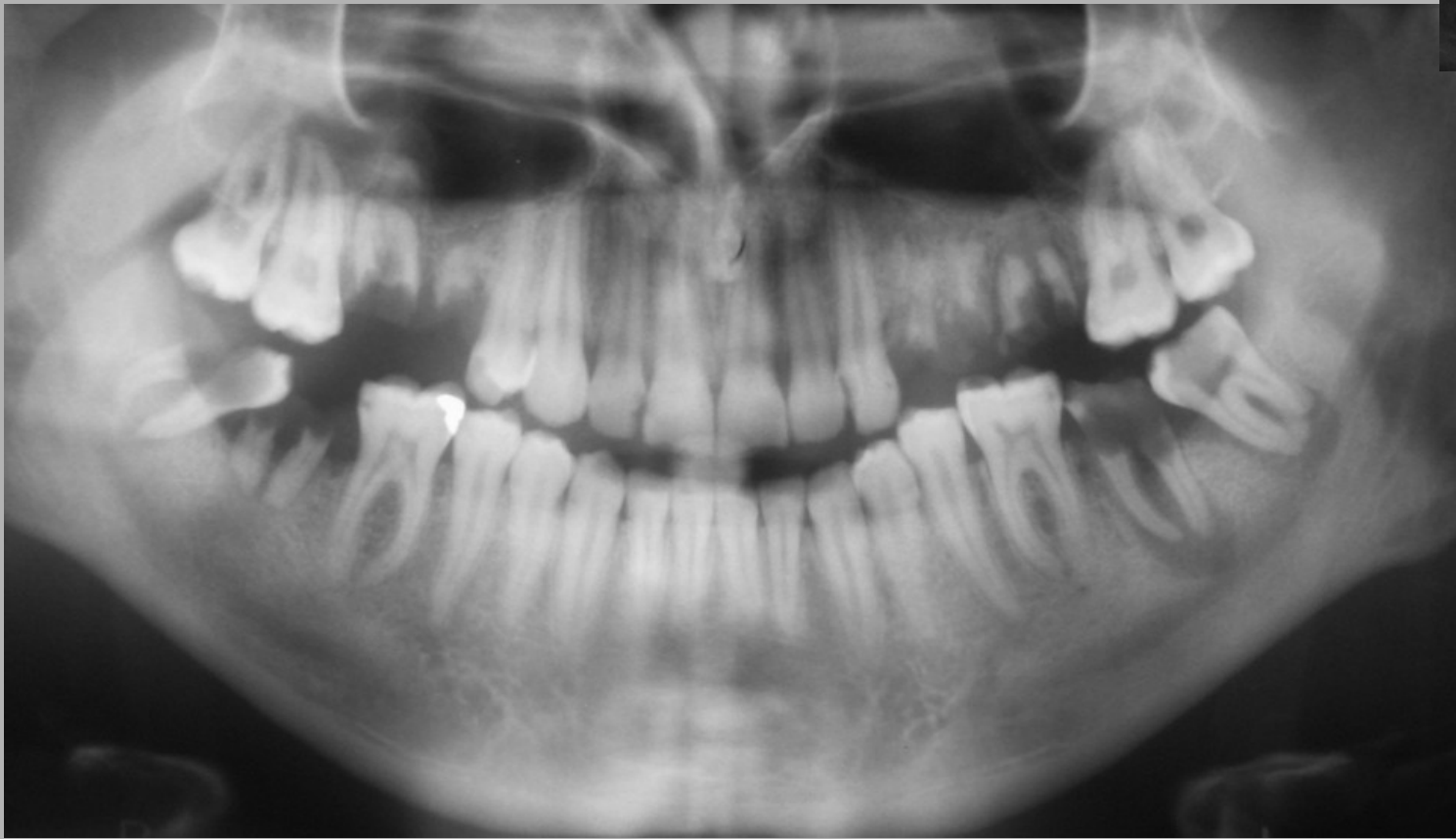
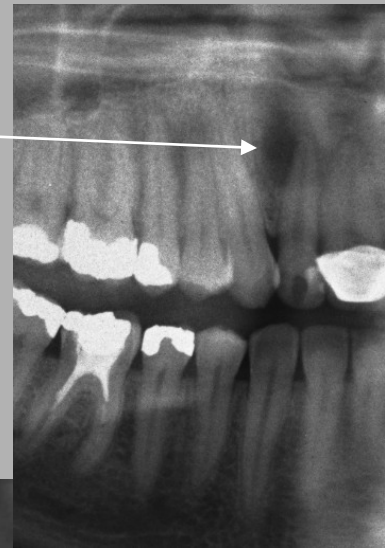Marginal periodontopathy

alveolar and mandible bone reduction
old age



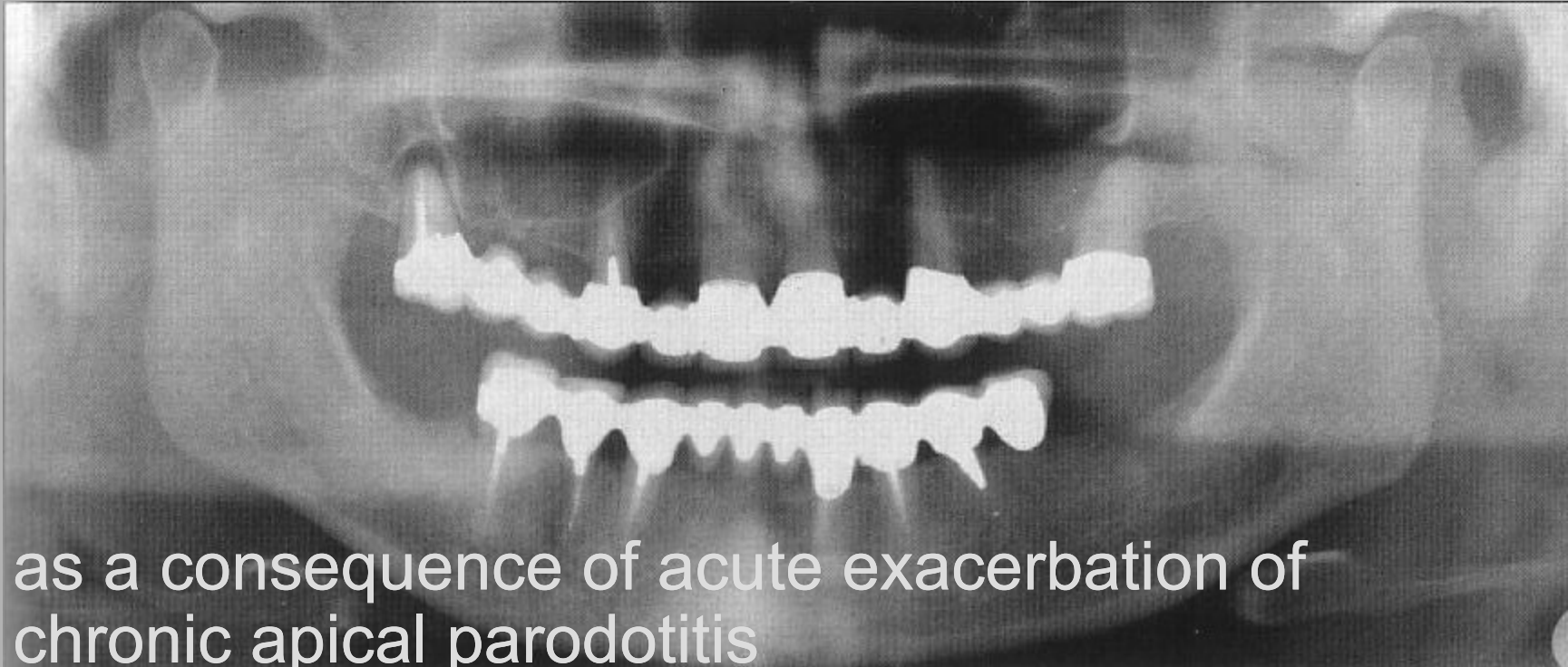
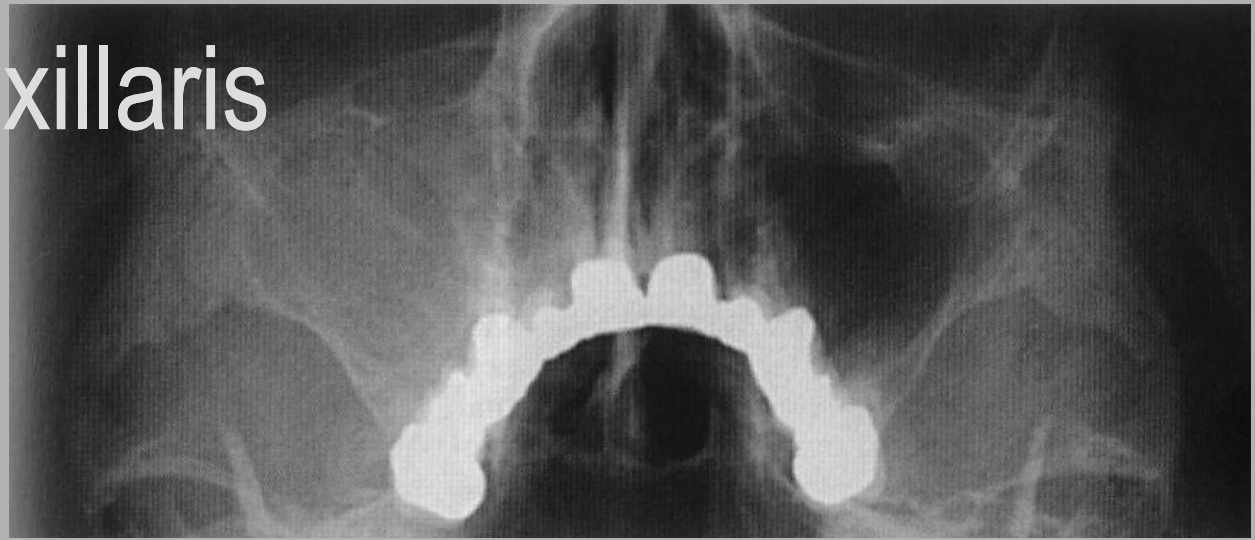
Periapical abscess

A **periapical abscess** is the result of a chronic, localized infection located at the tip, or apex, of the root of a tooth.



Sinusitis maxillaris

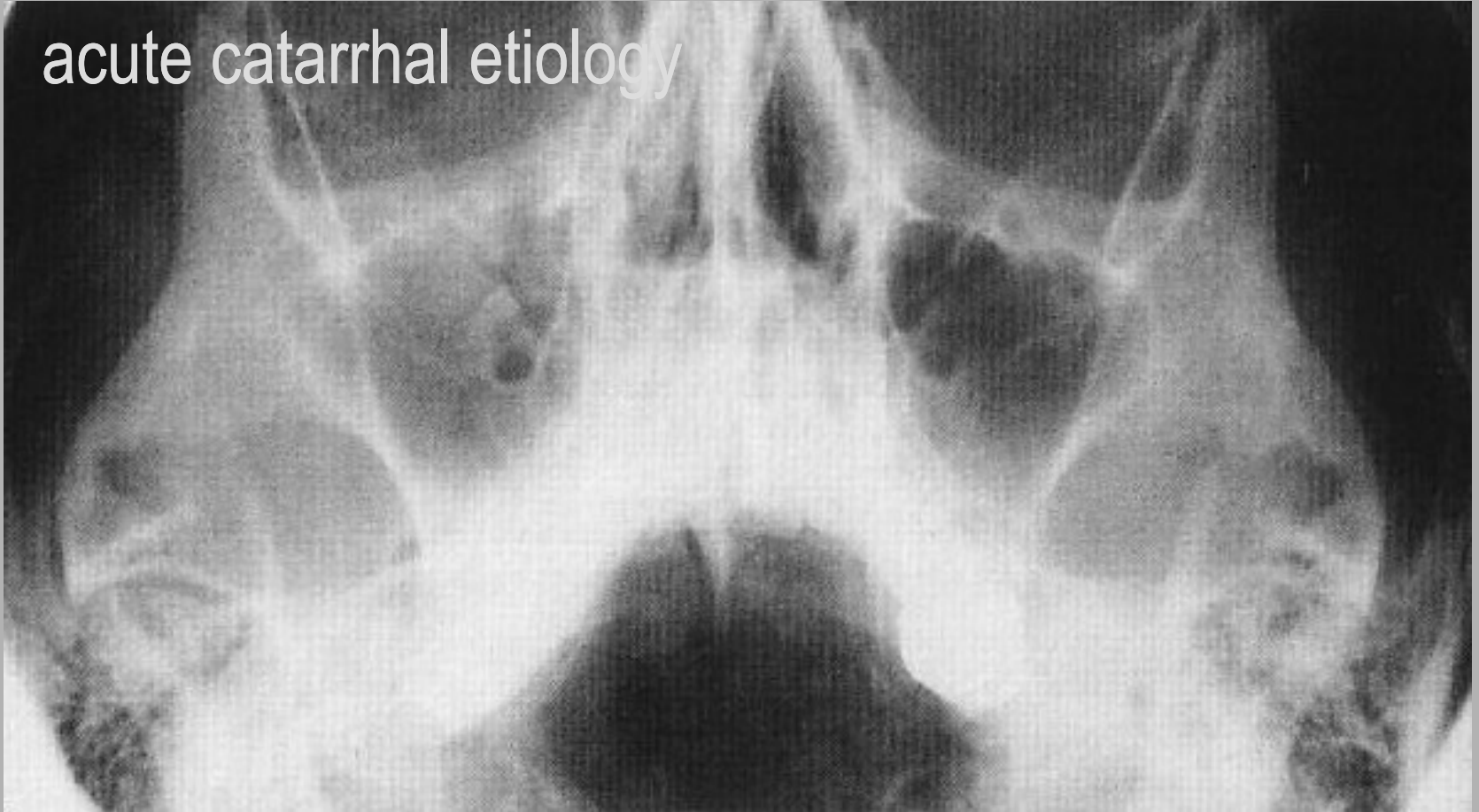w, 57 y



- as a consequence of acute exacerbation of chronic apical parodontitis

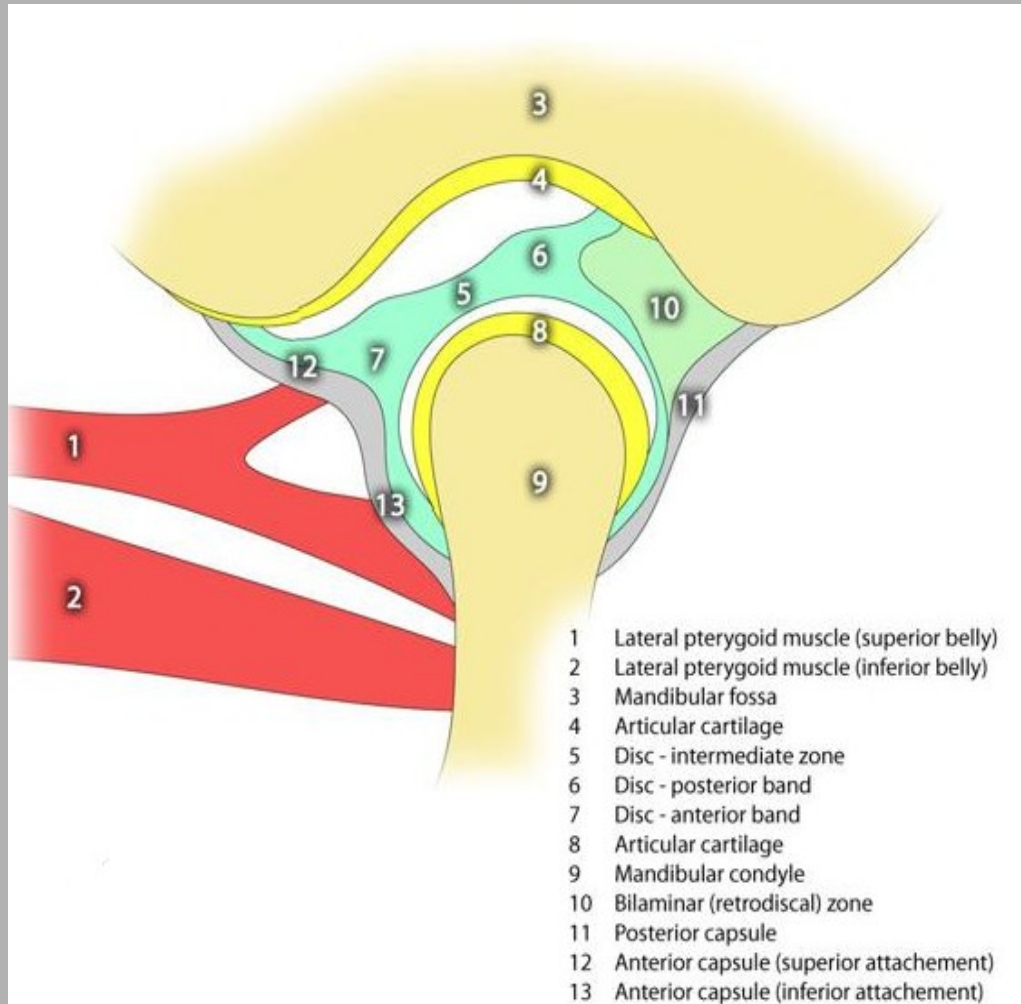
Sinusitis maxillaris

- w, 17 y
- acute catarrhal etiology

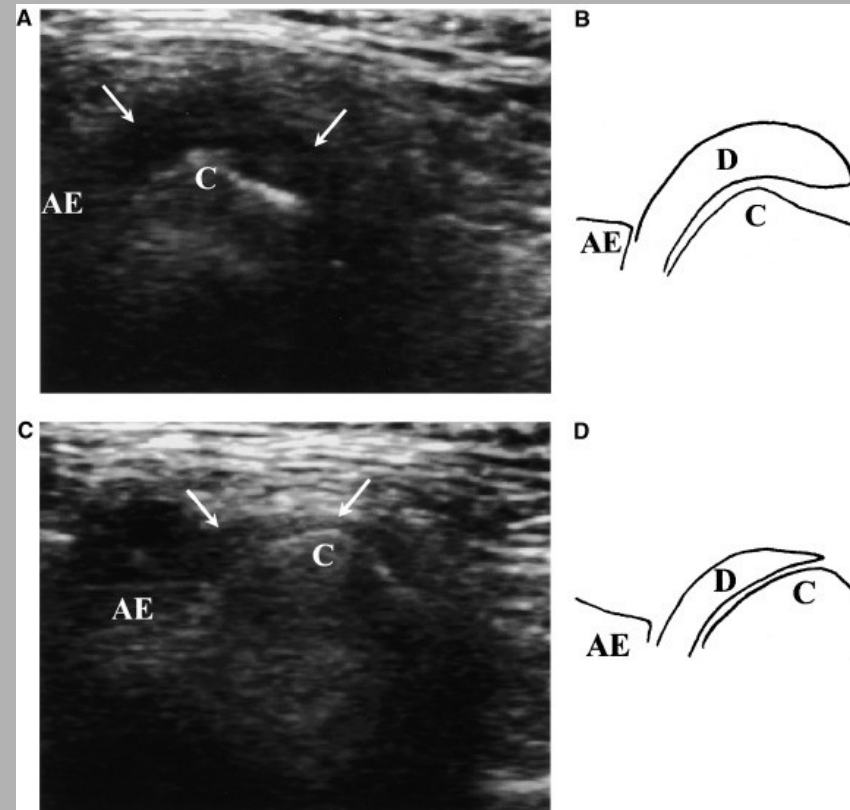


4) Temporomandibular joint diseases

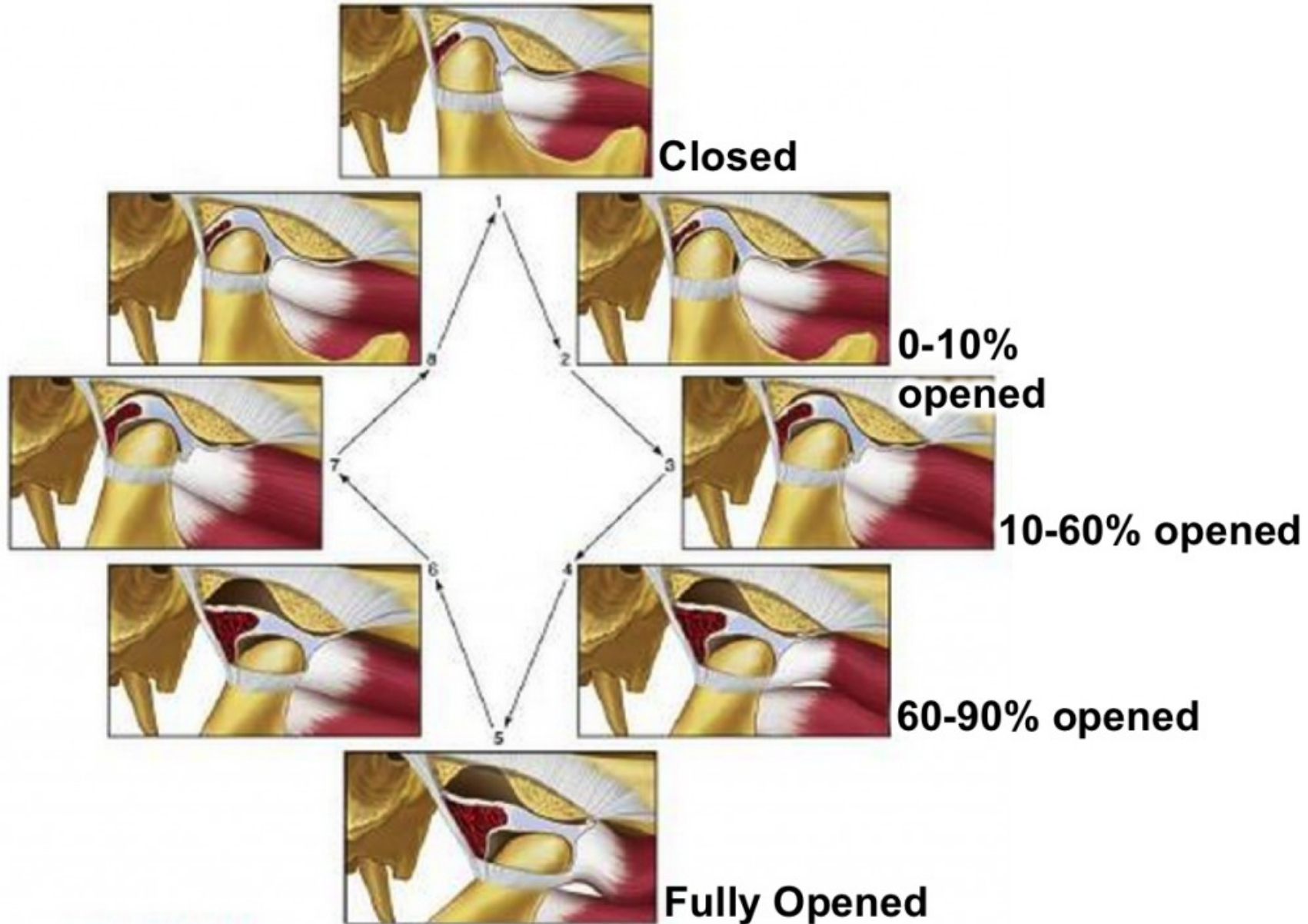
• Anatomy



Ultrasound

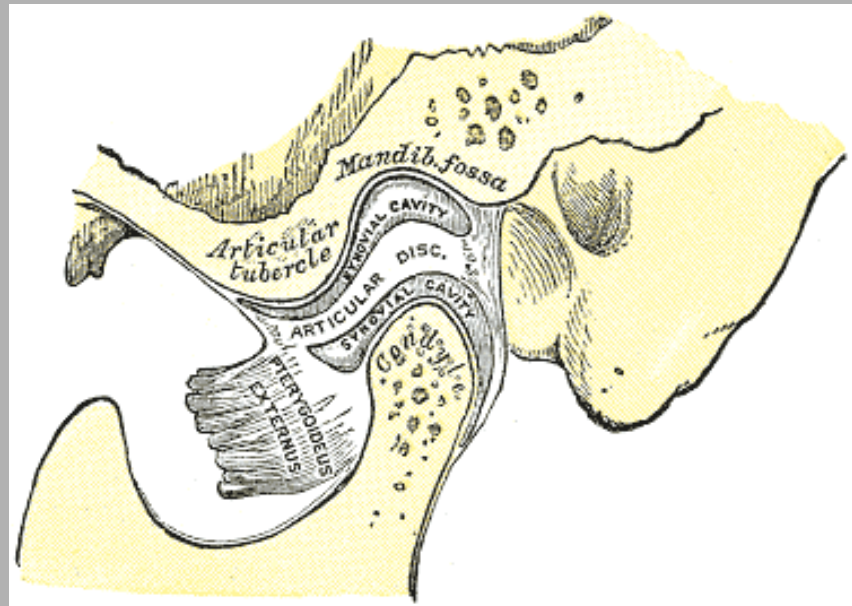


Joint movement



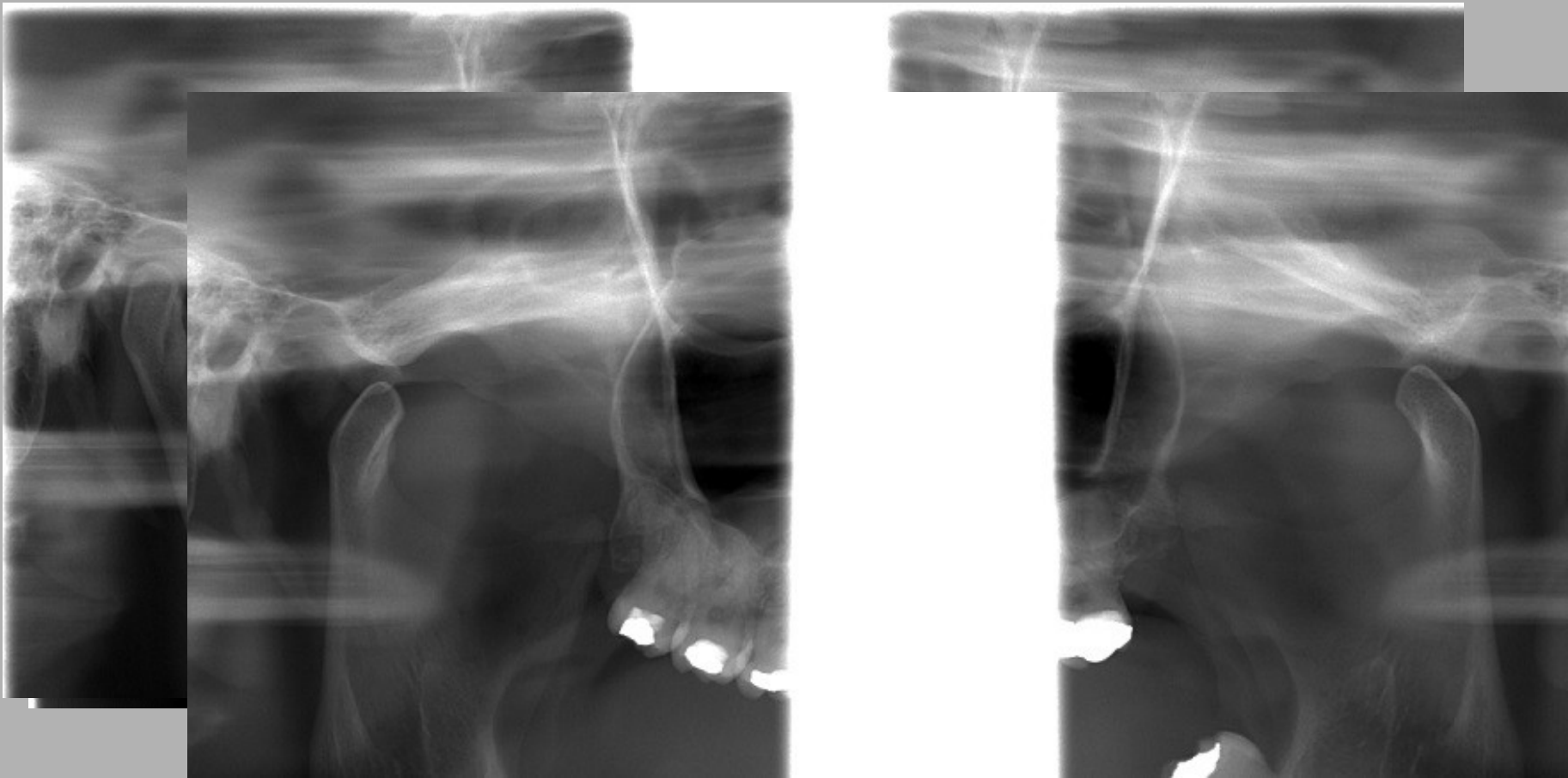
Imaging modalities

- Xray
- Ultrasound
- MRI



RTG

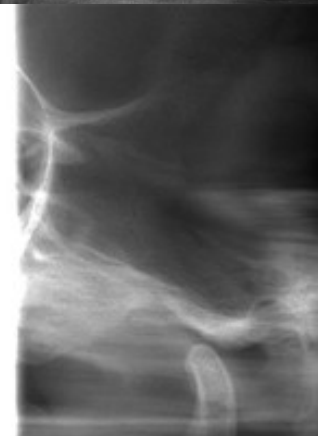
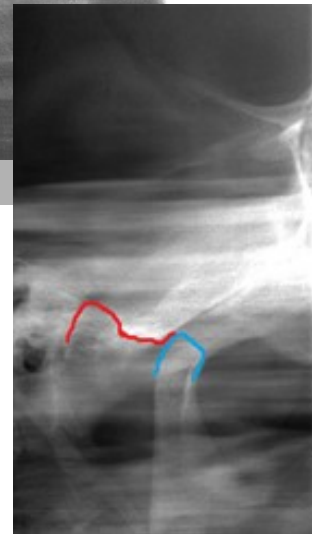
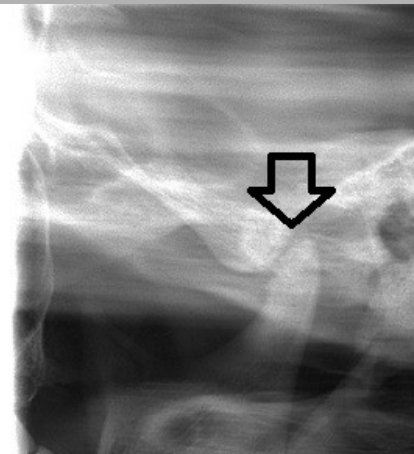
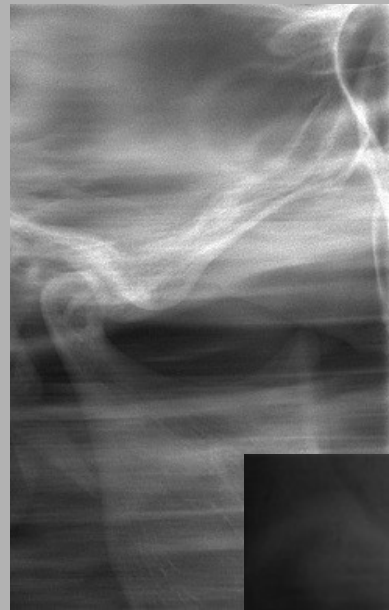
- OPG and plain Xray with open and closed mouth



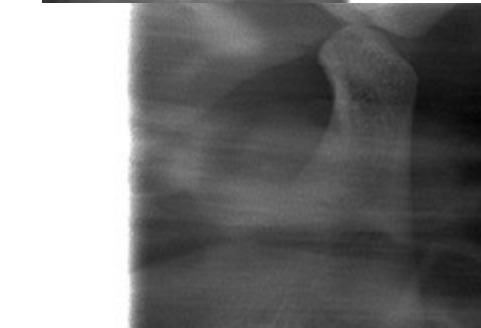
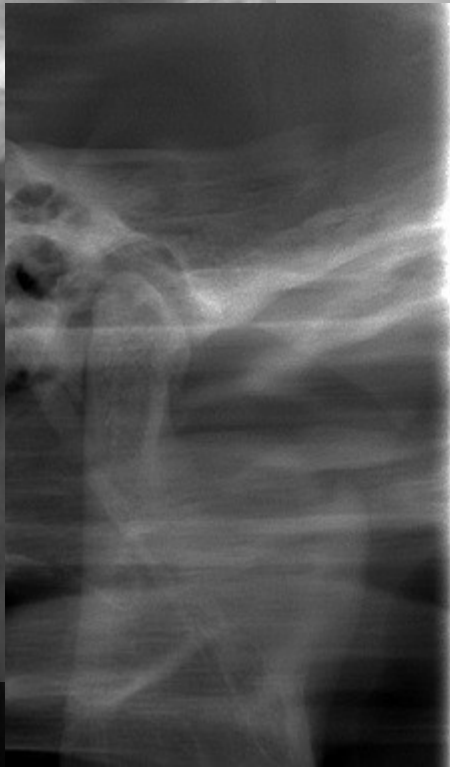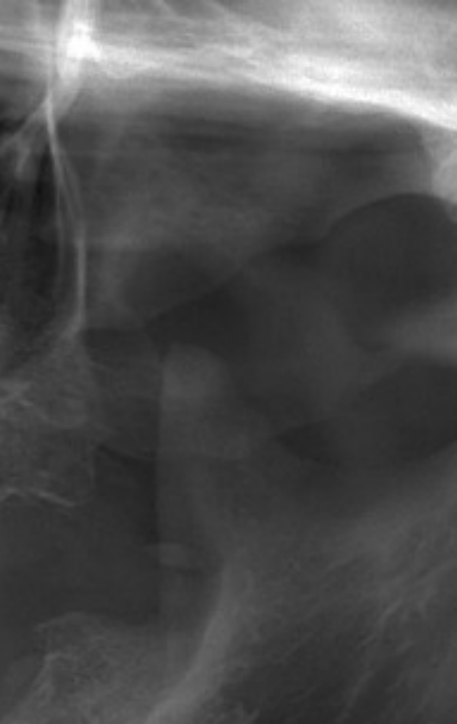
Plain X-ray:

- 1) Shape of joint
- 2) Position of the head relative to joint fossa
- 3) Maximal mobility of condyle

OPG – Odontogenic cause of joint pain



Ha Luxation

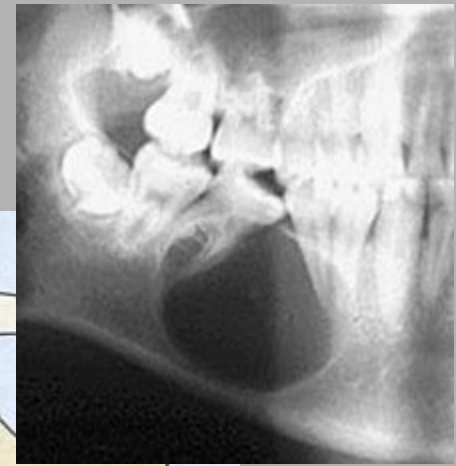
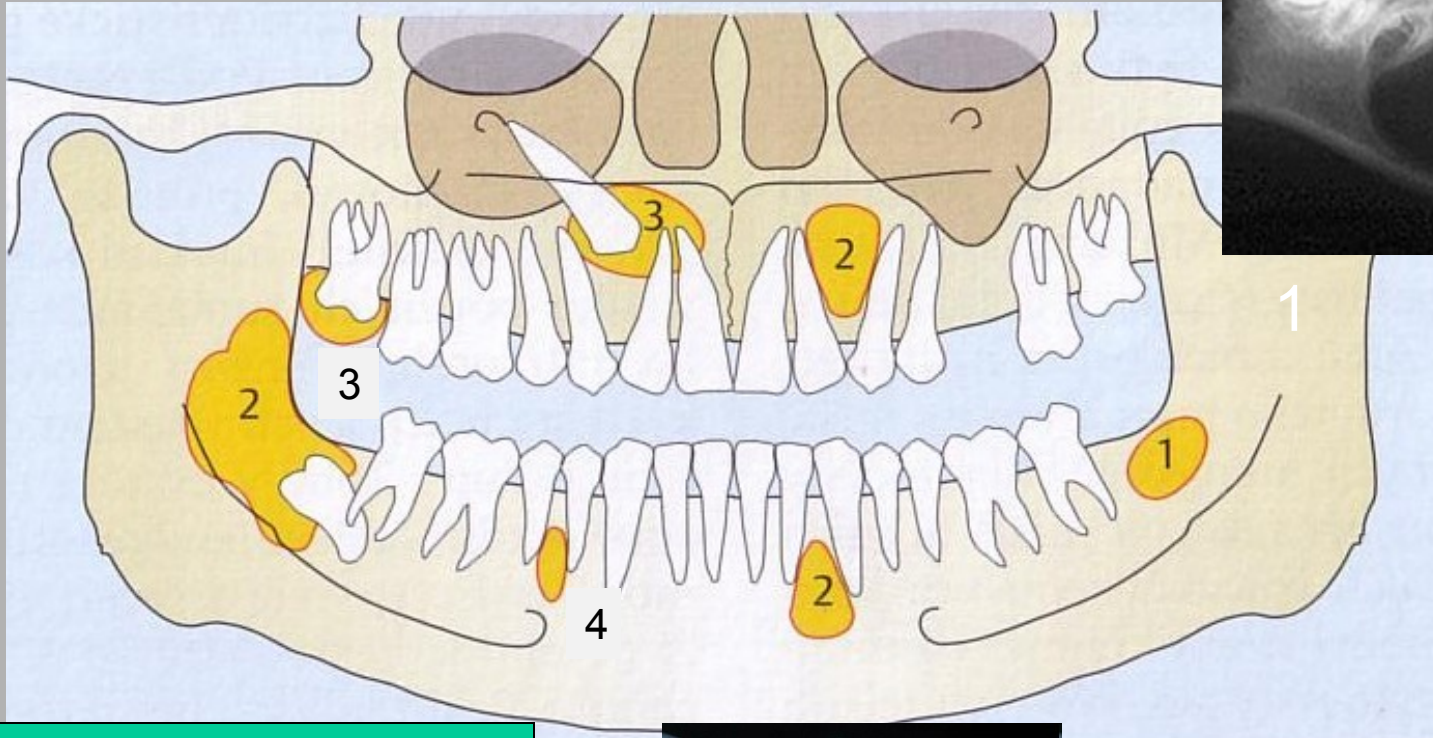


Hypomobility

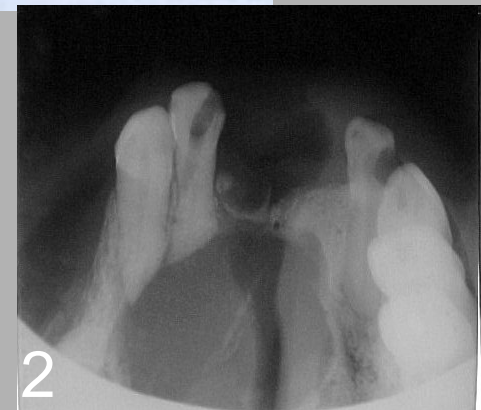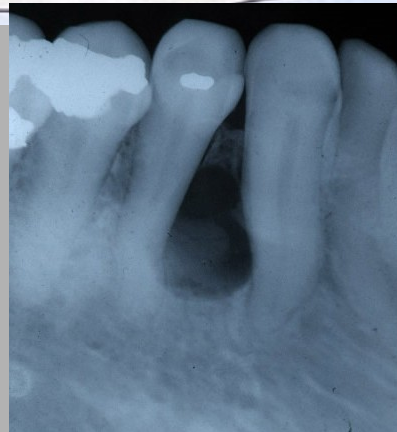
5) Cysts

- A) odontogenic
- B) non-odontogenic
- C) inflammatory

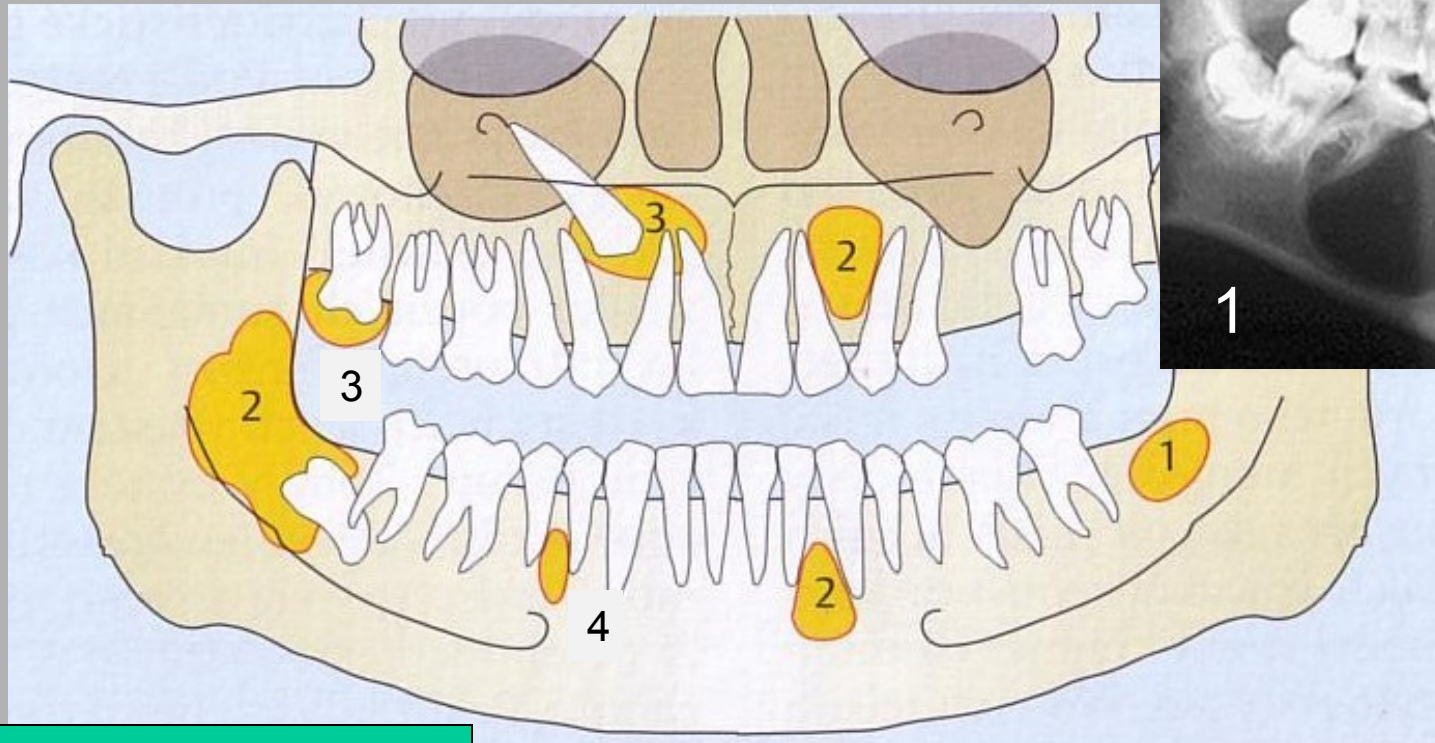
Cysts – odontogenic



1. primordial c.
2. keratocyst
3. folikular c.
4. lateral parodontal c.



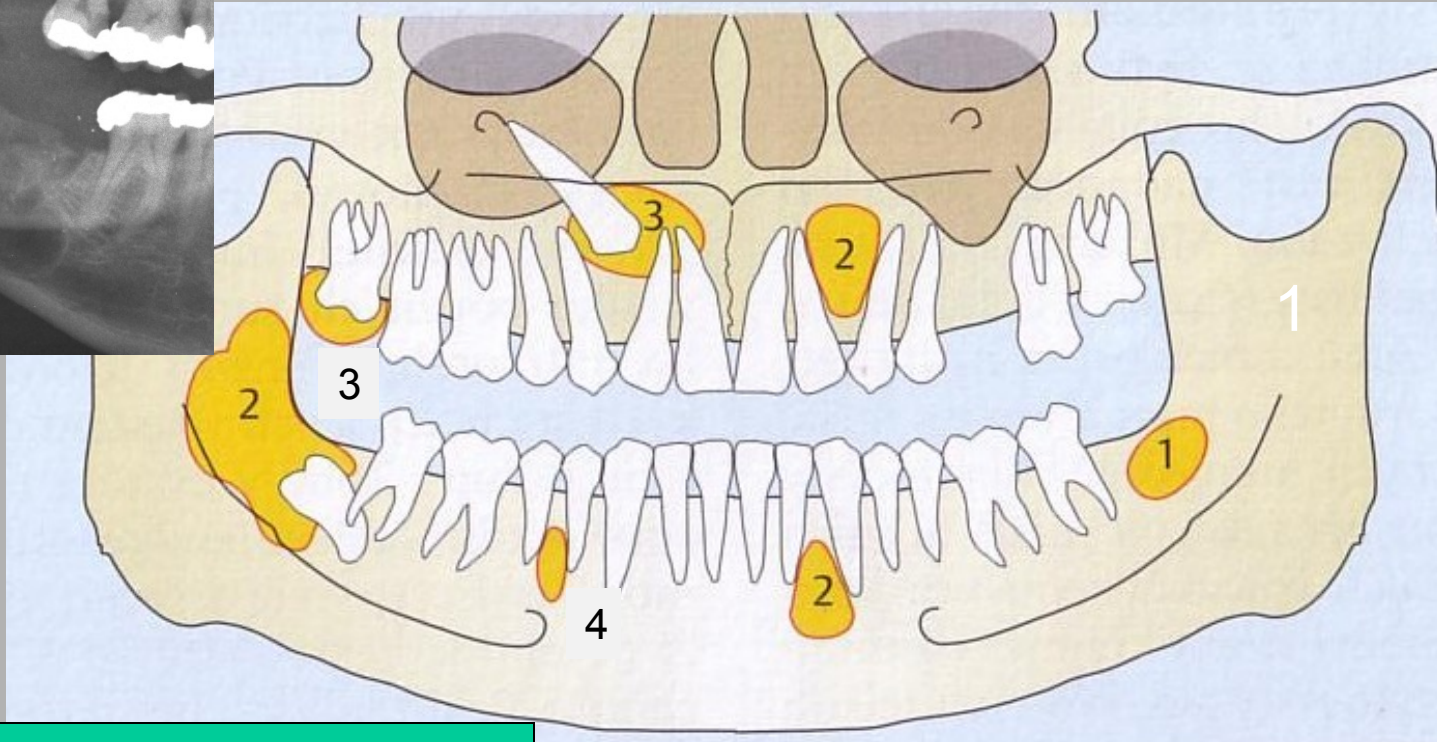
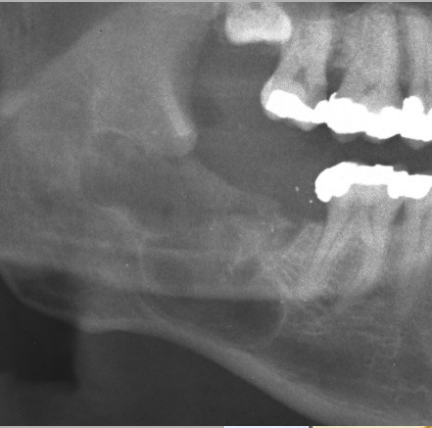
Cysts – odontogenic



1. primordial c.
2. keratocyst
3. follicular c.
4. lateral periodontal c.

A primordial cyst is a developmental odontogenic cyst. It is found in an area where a tooth should have formed but is missing. Primordial cysts most commonly arise in the area of mandibular third molars.

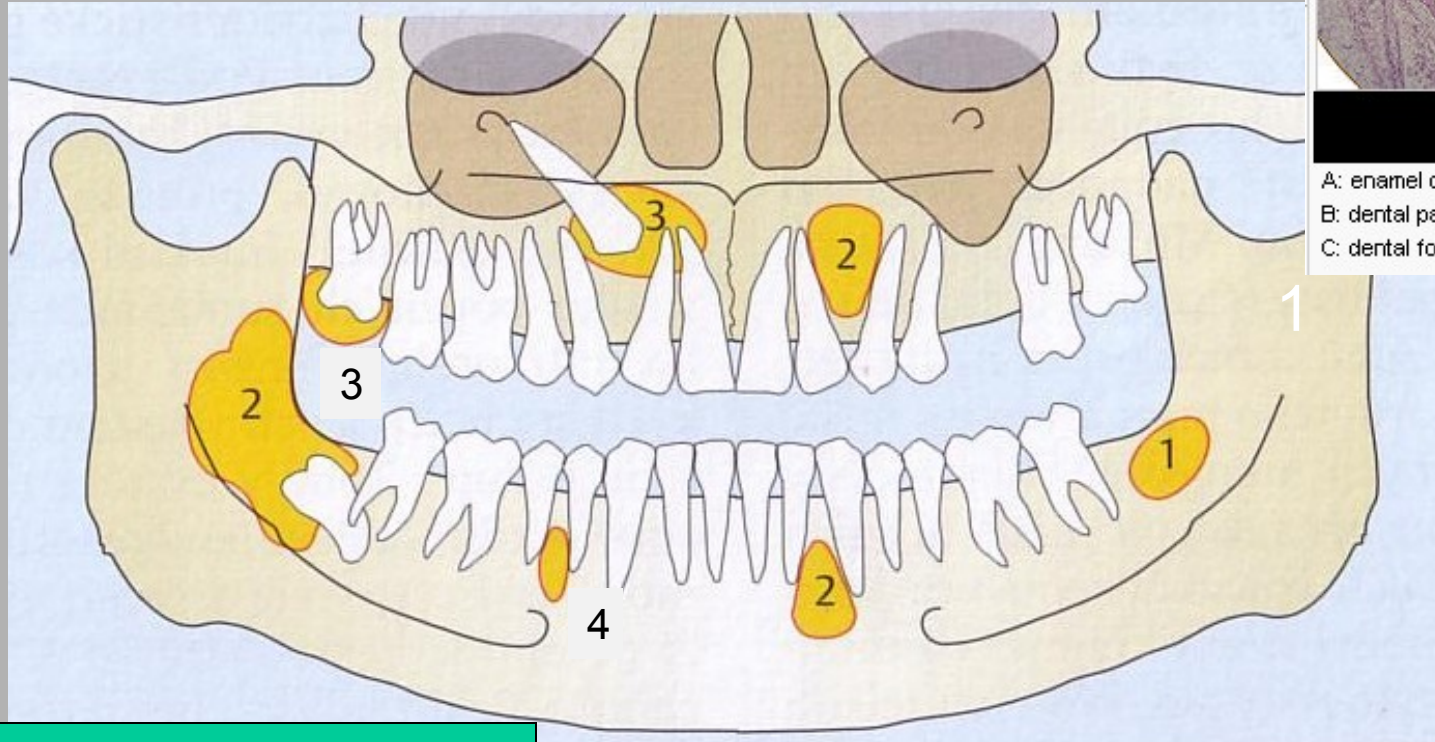
Cysts – odontogenic



1. primordial c.
2. keratocyst
3. follicular c.
4. lateral periodontal c.

Keratocyst is a benign but locally aggressive developmental cystic neoplasm. It most often affects the posterior mandible.

Cysts – odontogenic

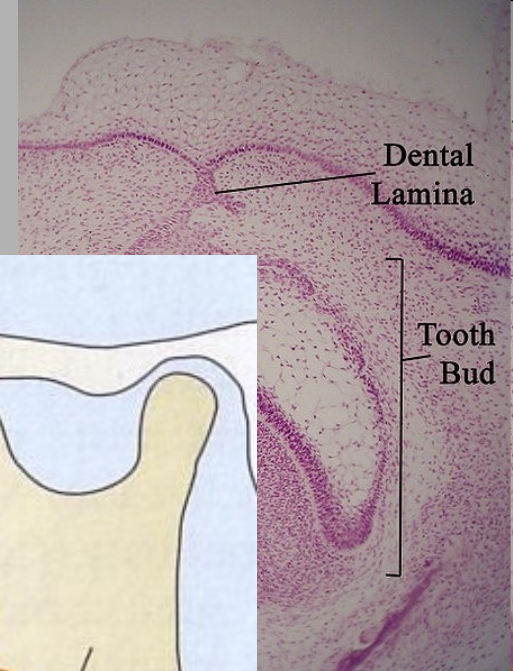
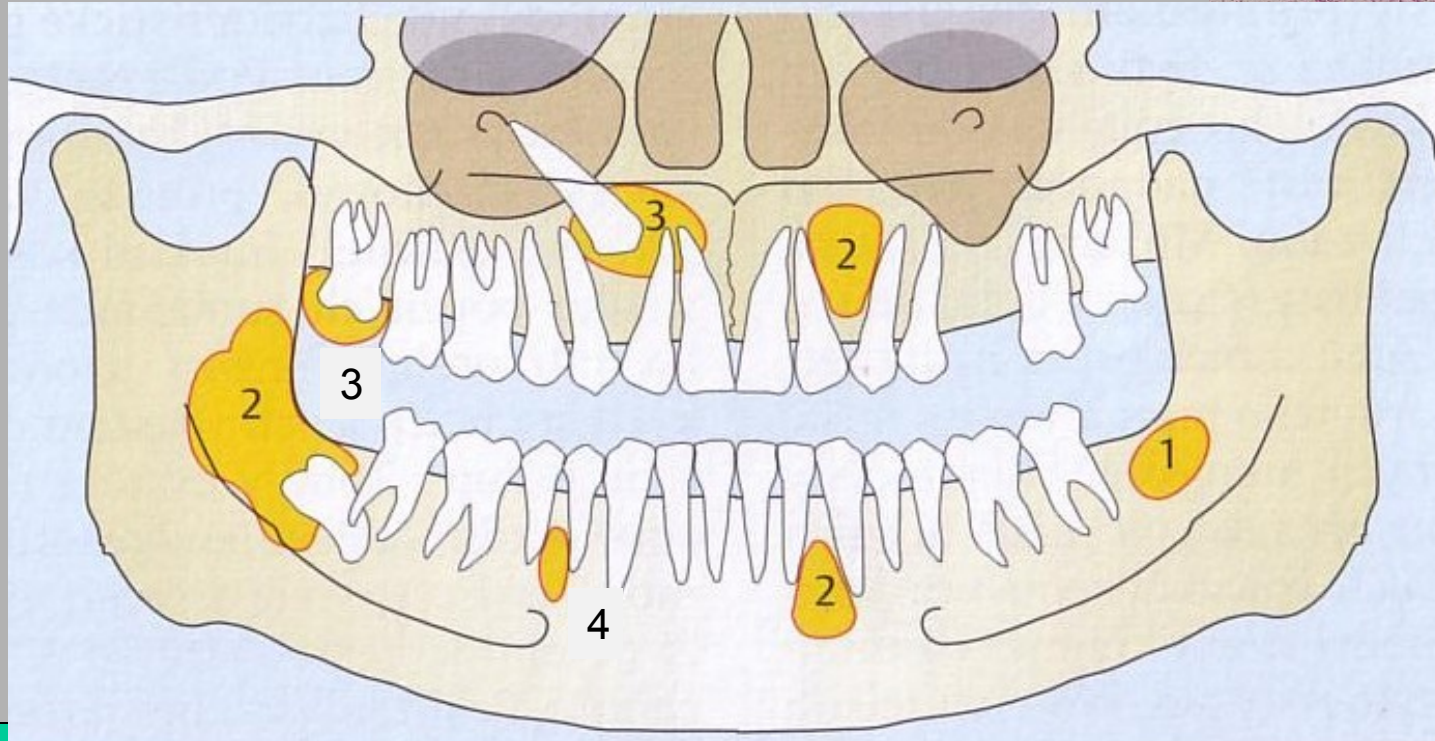


1. primordial c.
2. keratocyst
3. follicular c.
4. lateral periodontal c.

A follicular cyst is a cyst of dental follicle

The **dental follicle** is a sac containing the developing tooth and arise from cemento enamel border and contains crown of tooth.

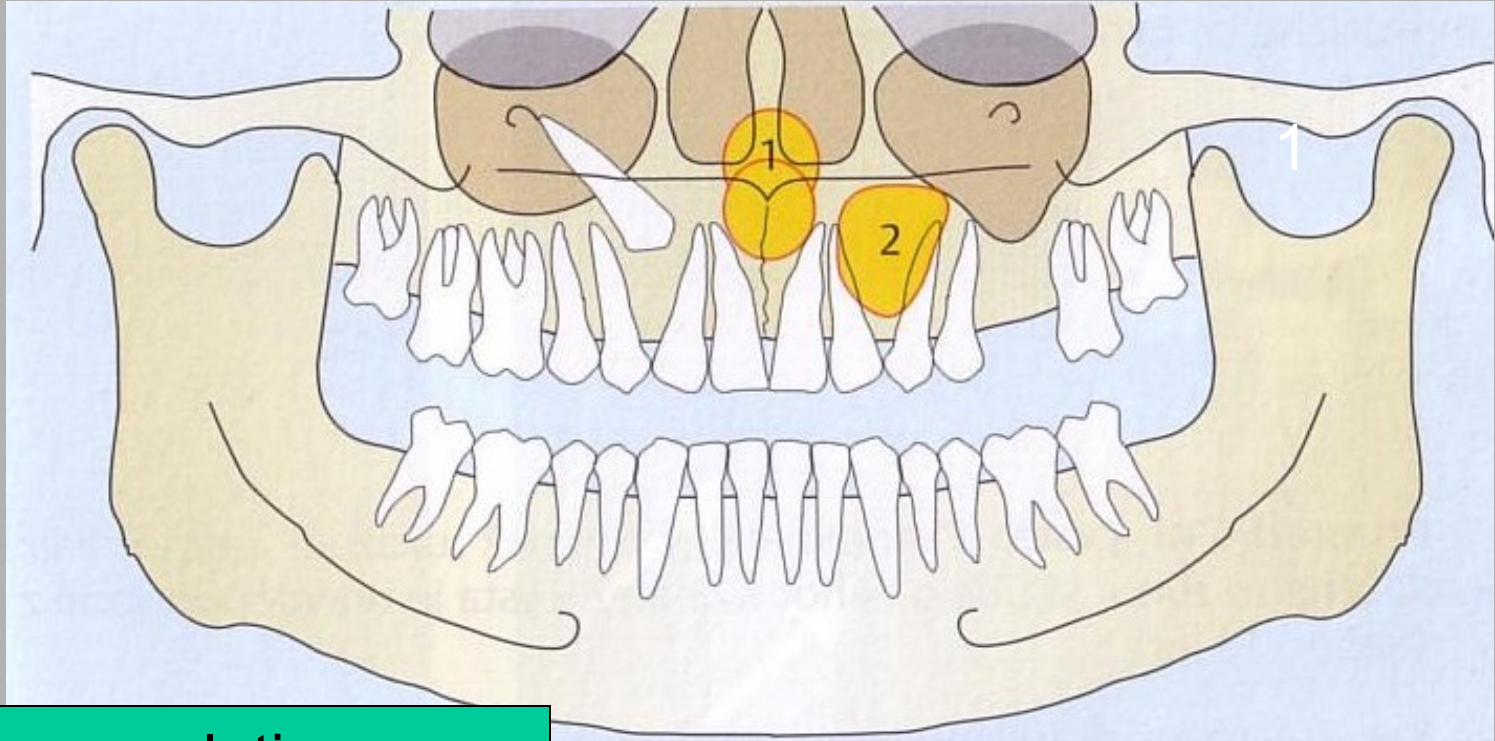
Cysts – odontogenic



1. primordial c.
2. keratocyst
3. folikular c.
4. lateral parodontal c.

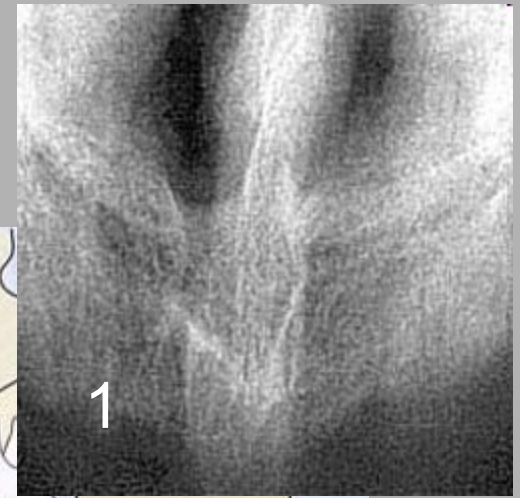
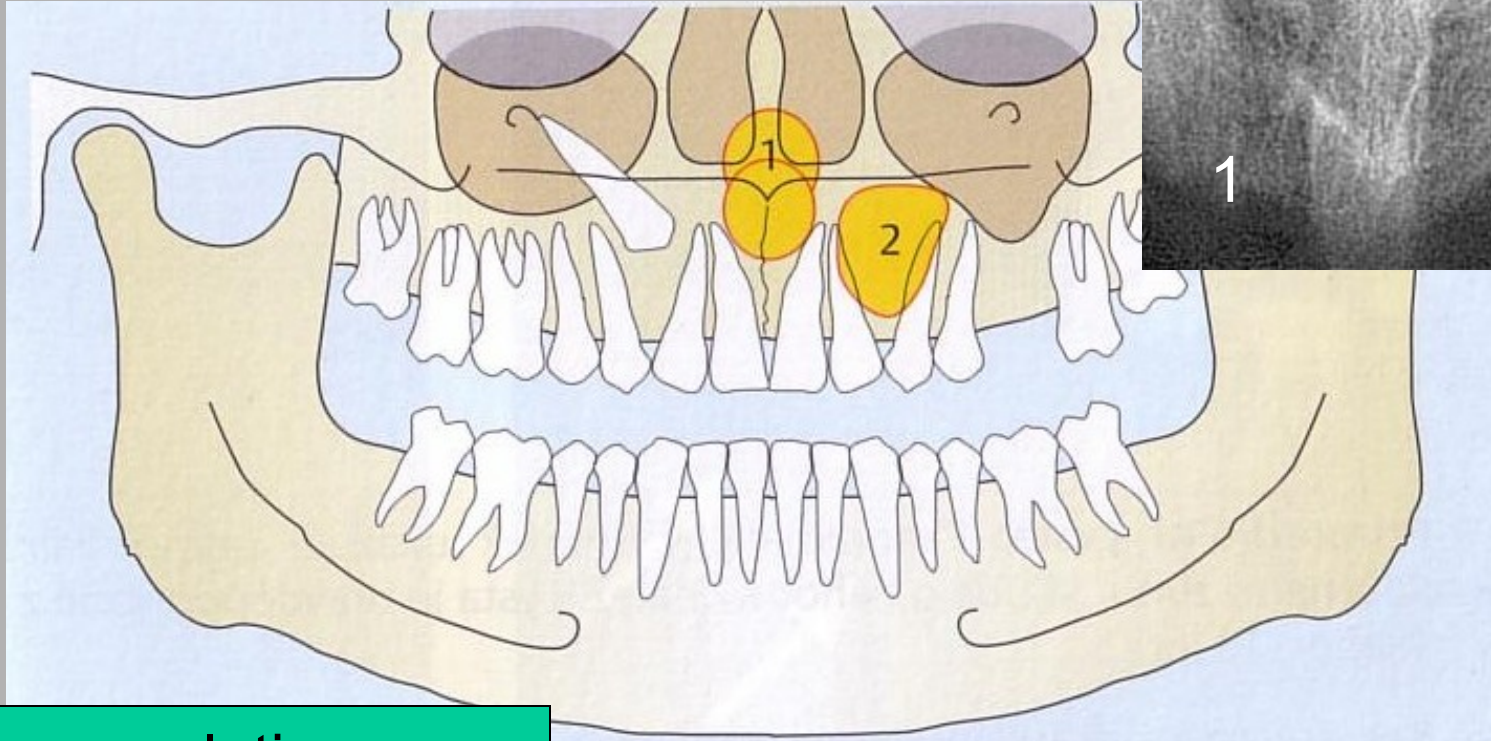
The **lateral periodontal cyst** is a cyst that arises from the rest cells of the dental lamina. It is more common in middle-aged adult males. Usually, there is no pain associated with it, and it usually appears as a unilocular radiolucency (dark area) on the side of a canine or premolar root. Microscopically, the lateral periodontal cyst appears the same as the gingival cyst of the adult.

Cysts – non-odontogenic



1. nasopalatine c.
2. nasolabial c.

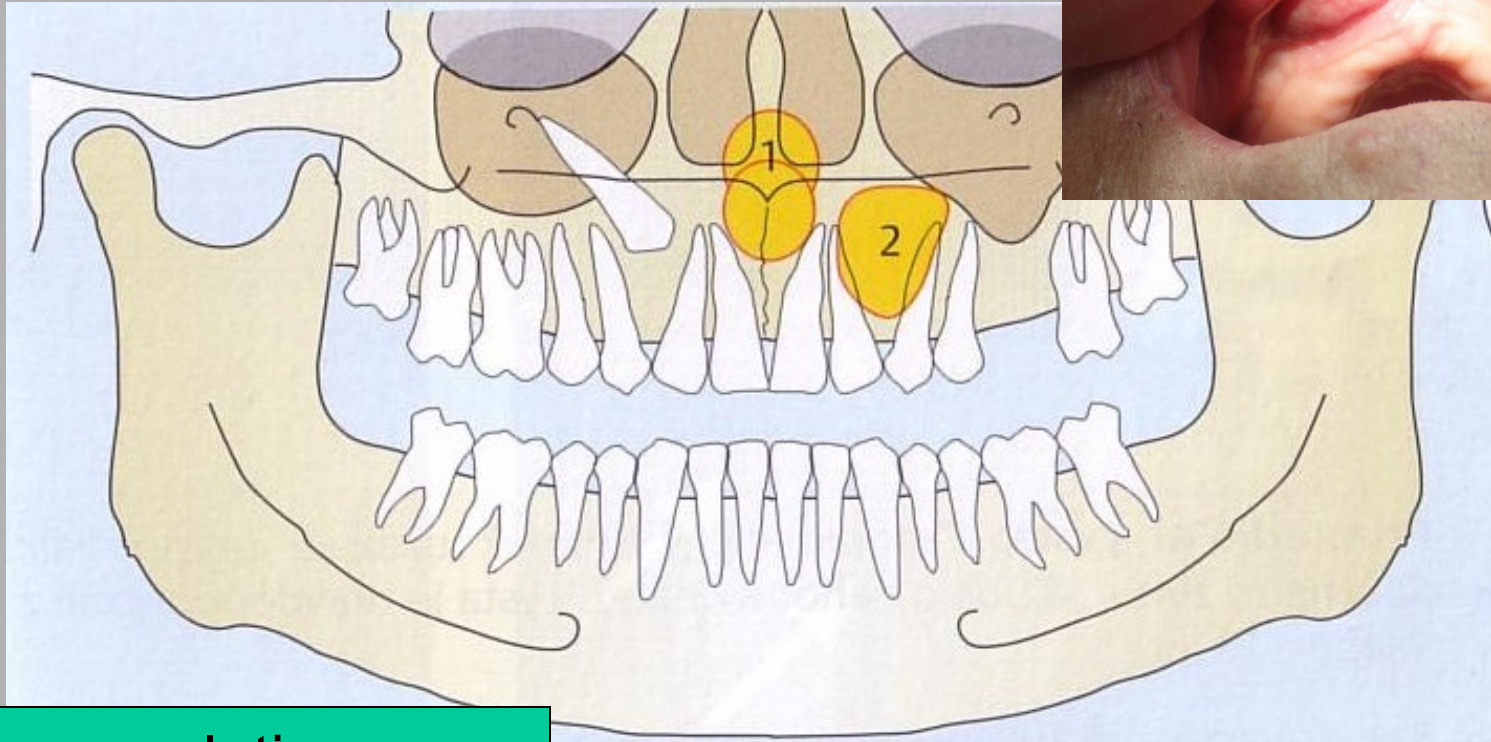
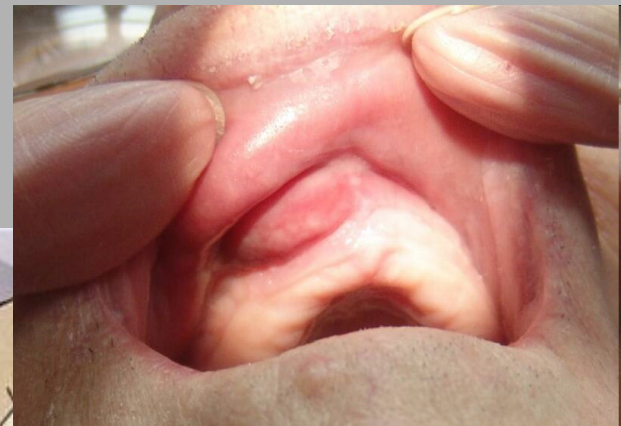Cysts – non-odontogenic



1. nasopalatine c.
2. nasolabial c.

Nasopalatine cyst occurs in the median of the palate.

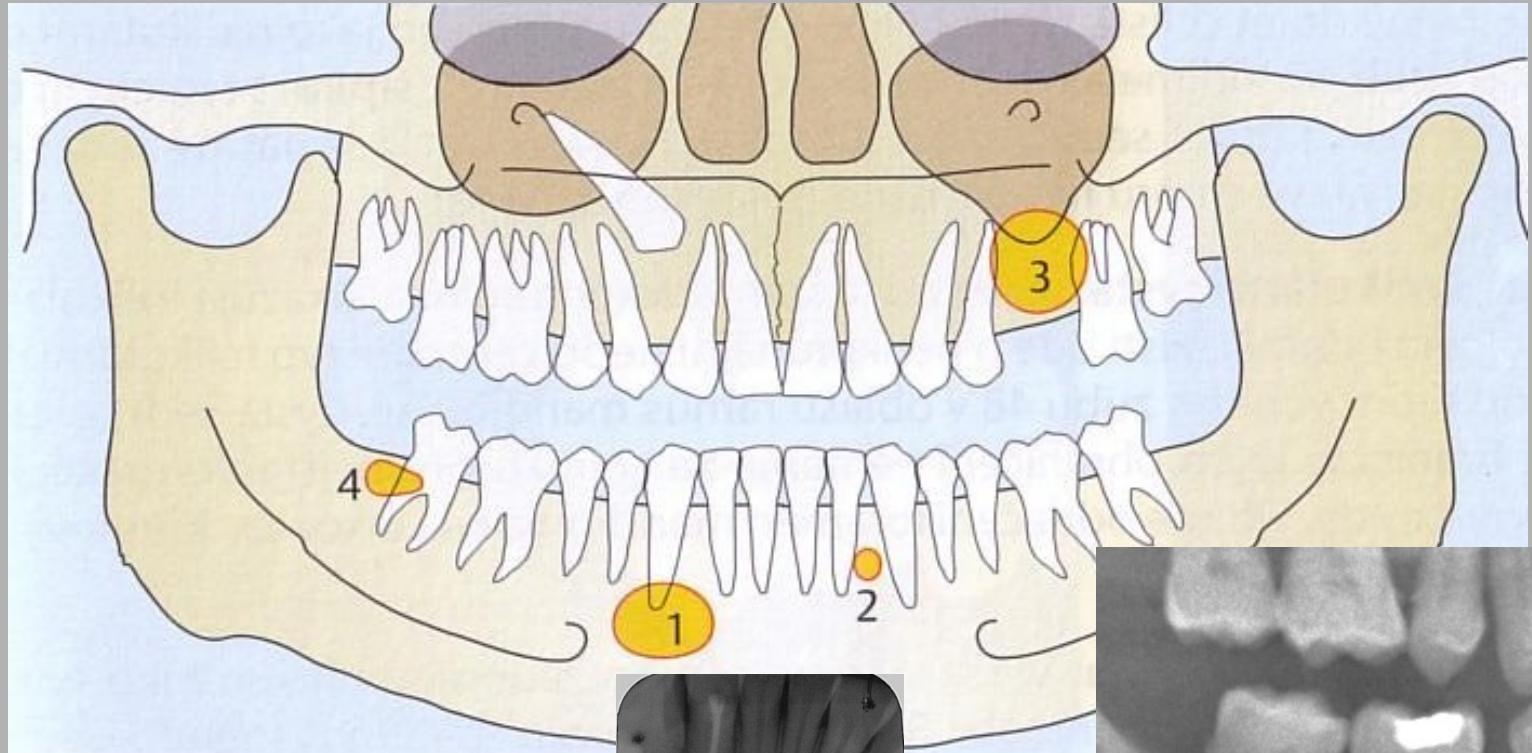
Cysts – non-odontogenic



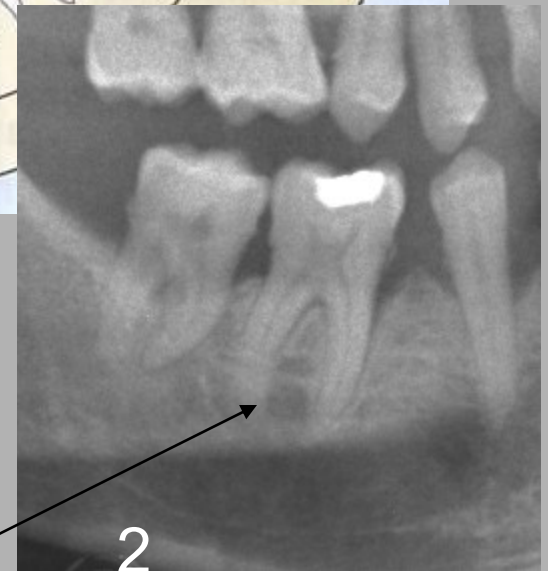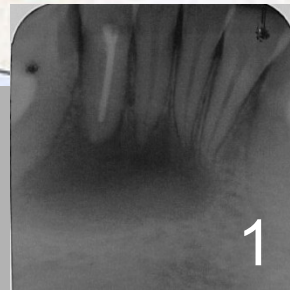1. nasopalatine c.
2. nasolabial c.

Nasolabial cyst is located superficially in the soft tissues of the upper lip. Unlike most of the other developmental cysts, the nasolabial cyst is an example of an extraosseous cyst.

Cysts - inflammatory



1. apical radicular
2. lateral radicular
3. residual lateral
4. parodontal (Craig's) - wisdom tooth



6) Tumors

Plain Radiograph



< 30y

Age

> 30y

long bone - axial
body or arch of spine

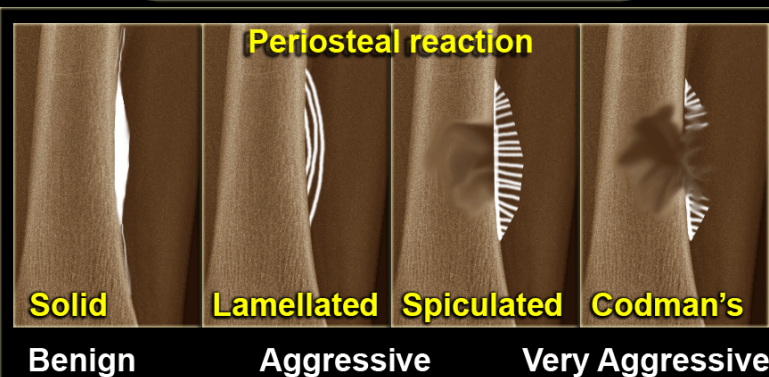
Location

dia - meta - epiphysis
centric - eccentric

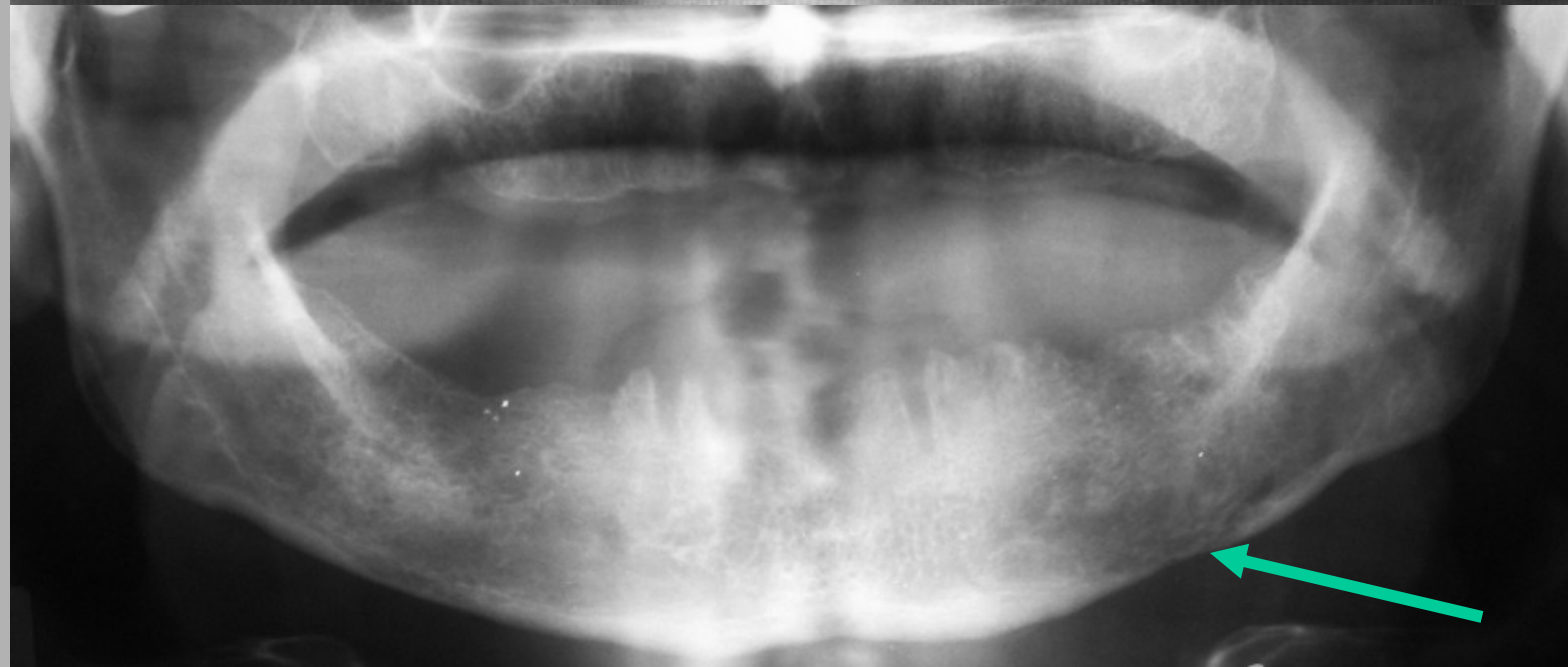
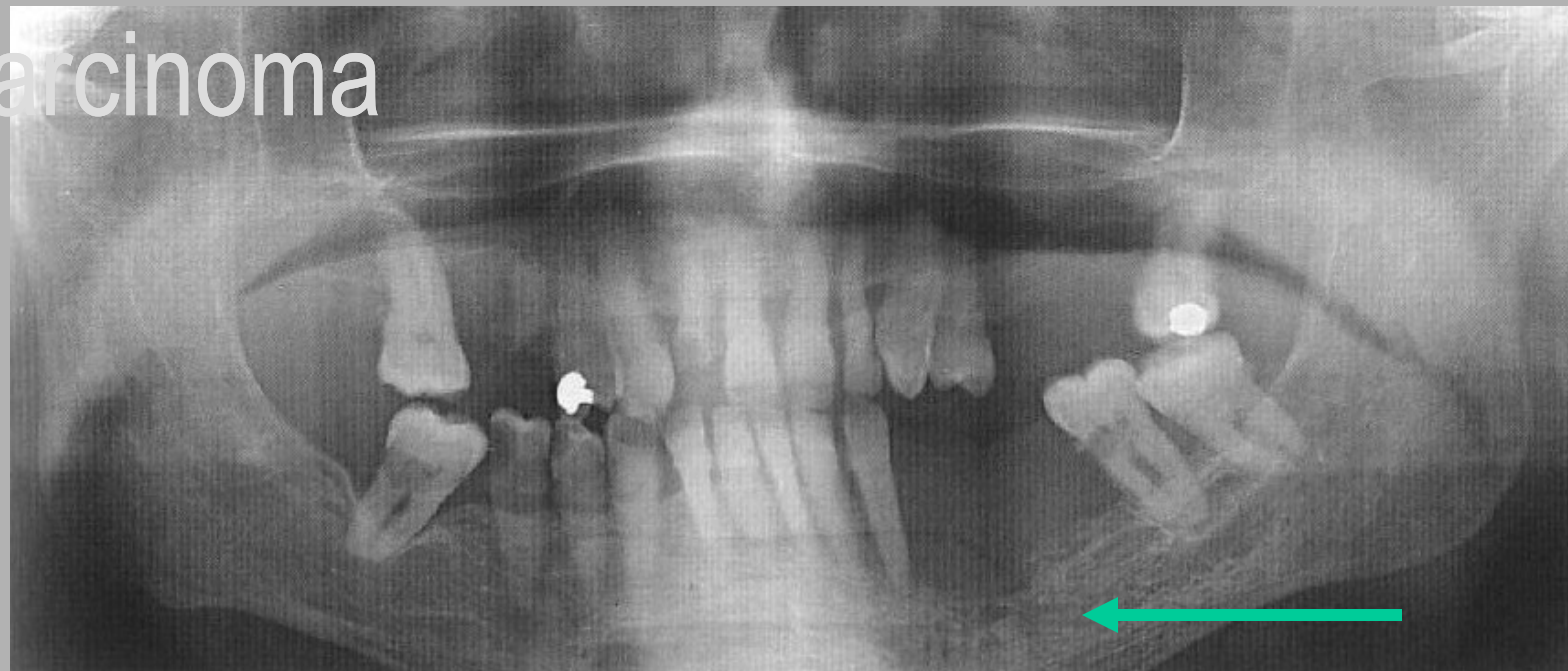
solitary - multiple

Miscellaneous

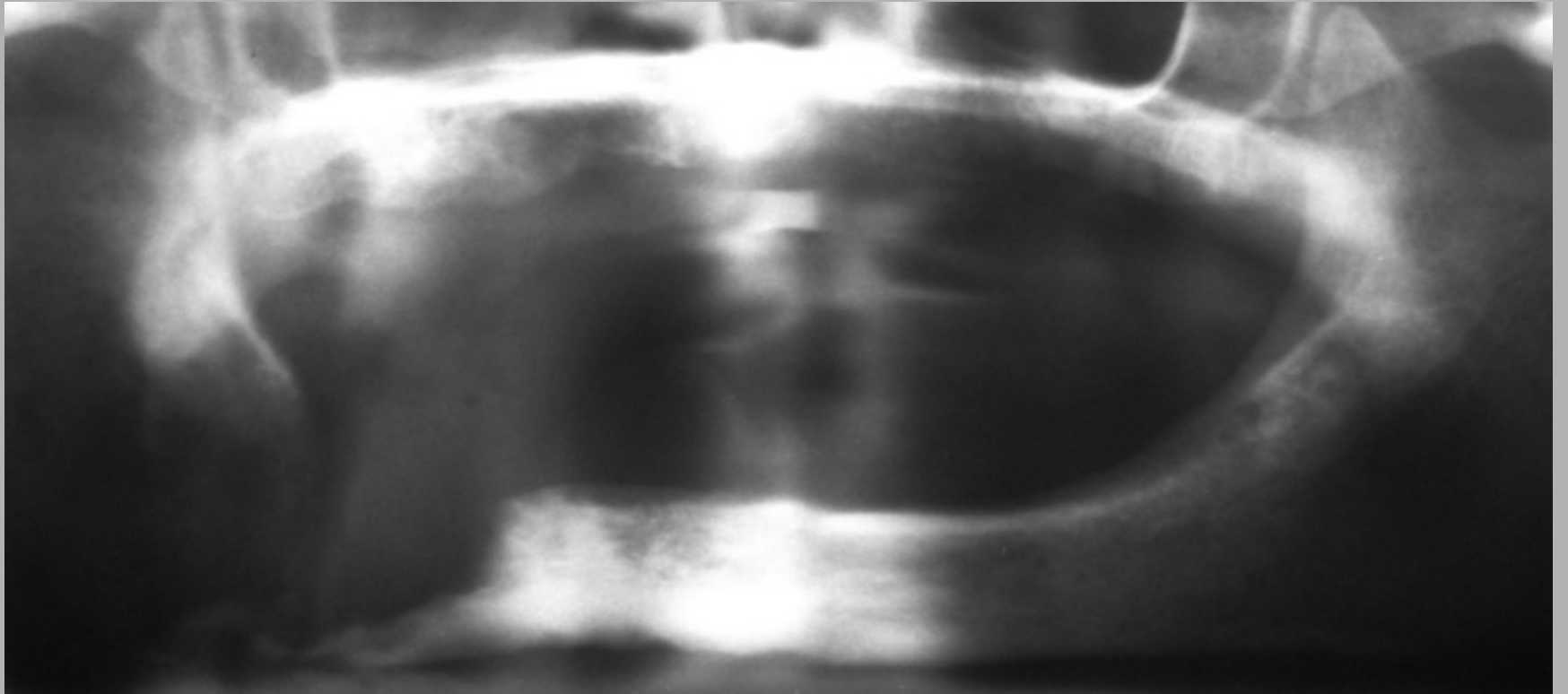
periosteal reaction
cortical destruction



Carcinoma



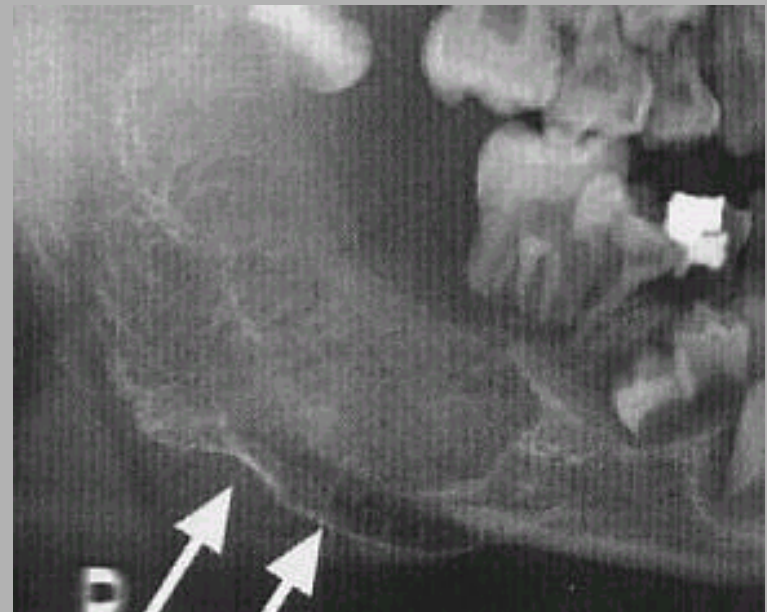
Carcinoma



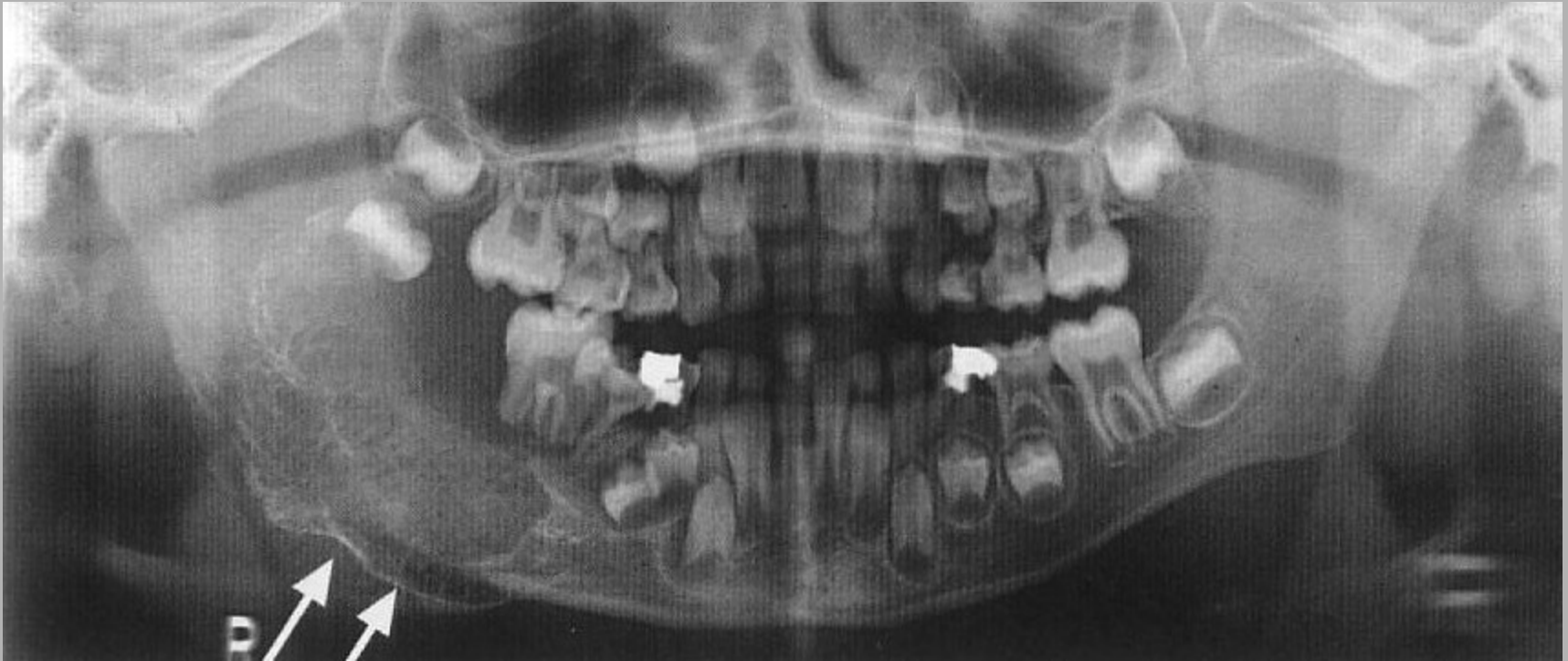
Ewing sarcoma

- children 10-20 y
- high grade malignant
- fast grow
- soon metastatis
- angle of mandible
- painfull
- X-ray: „slices of onion“
- Dif.dg.
 - osteosarcoma
 - endosteal hemangioma

gold diagnostic standard
MRI



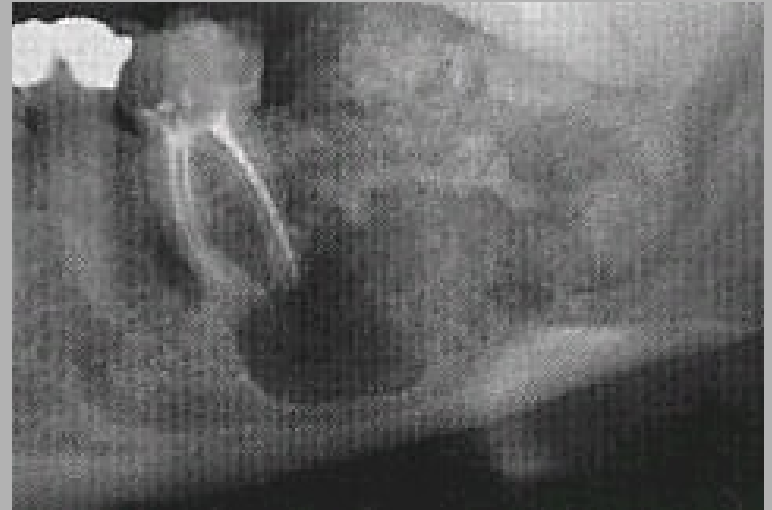
Ewing sarcoma



boy, 7 y
difficulty clinics
oedema of low jaw
movement of teeth
periost reaction

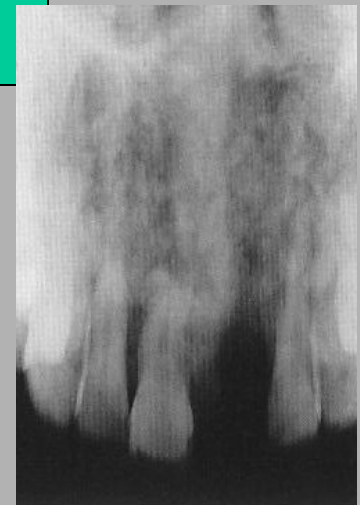Osteosarcoma

- 2. and 3. decennium
- mesenchymal tumor
- histologic
 - osteoblasts
 - chondroblasts
 - fibroblasts

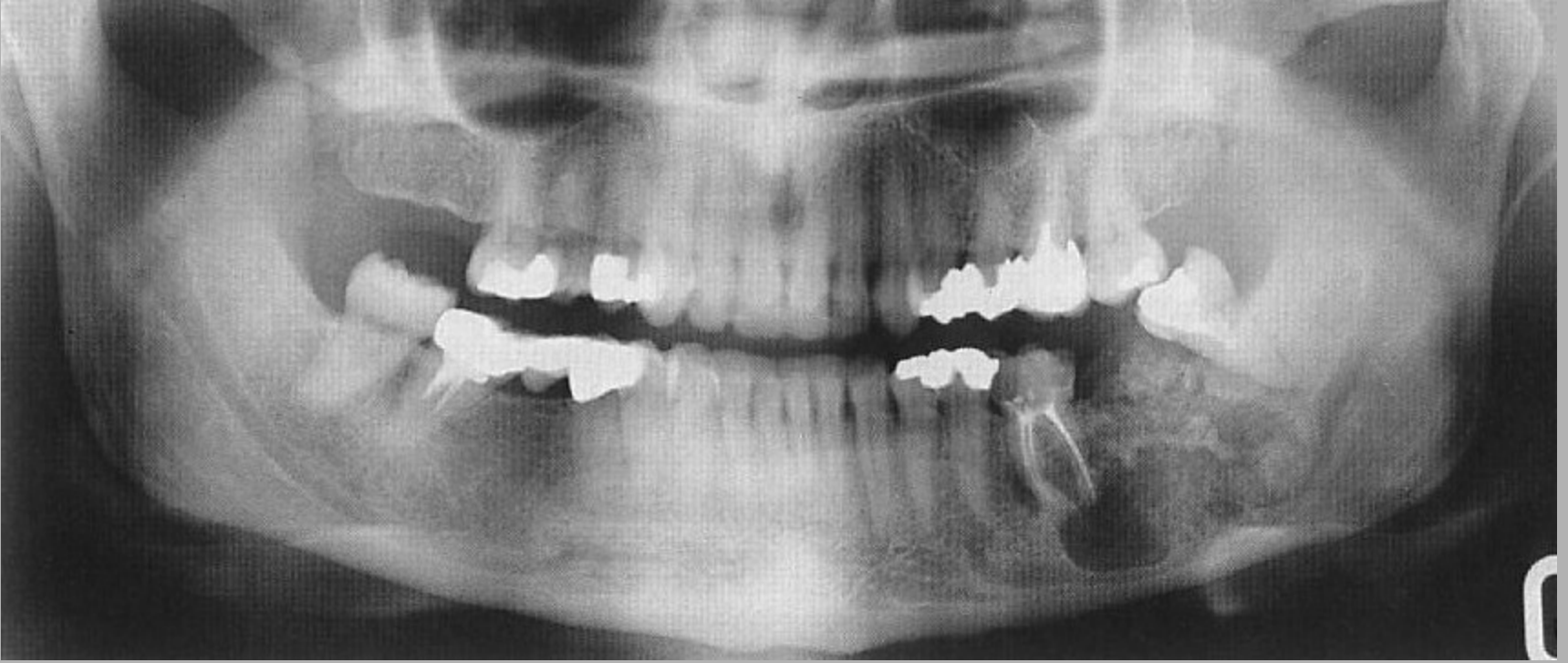

RTG

- osteoblastic + osteolytic
- various image

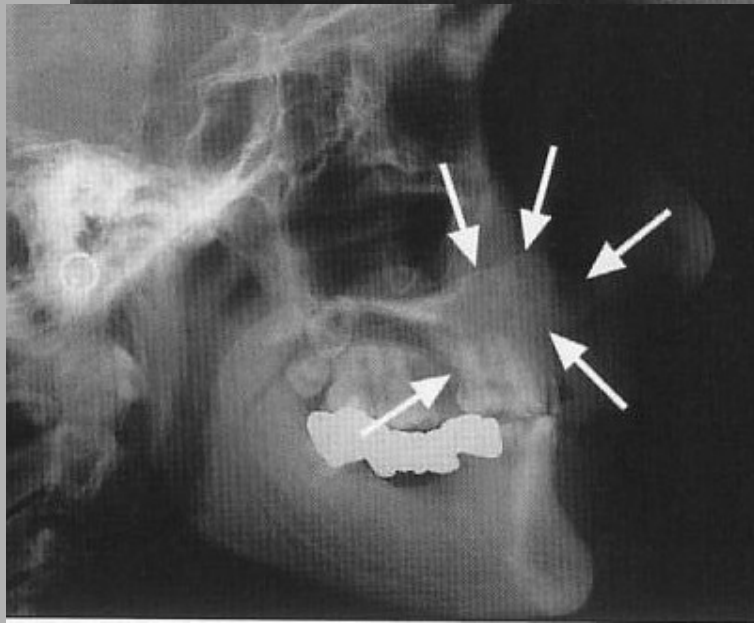
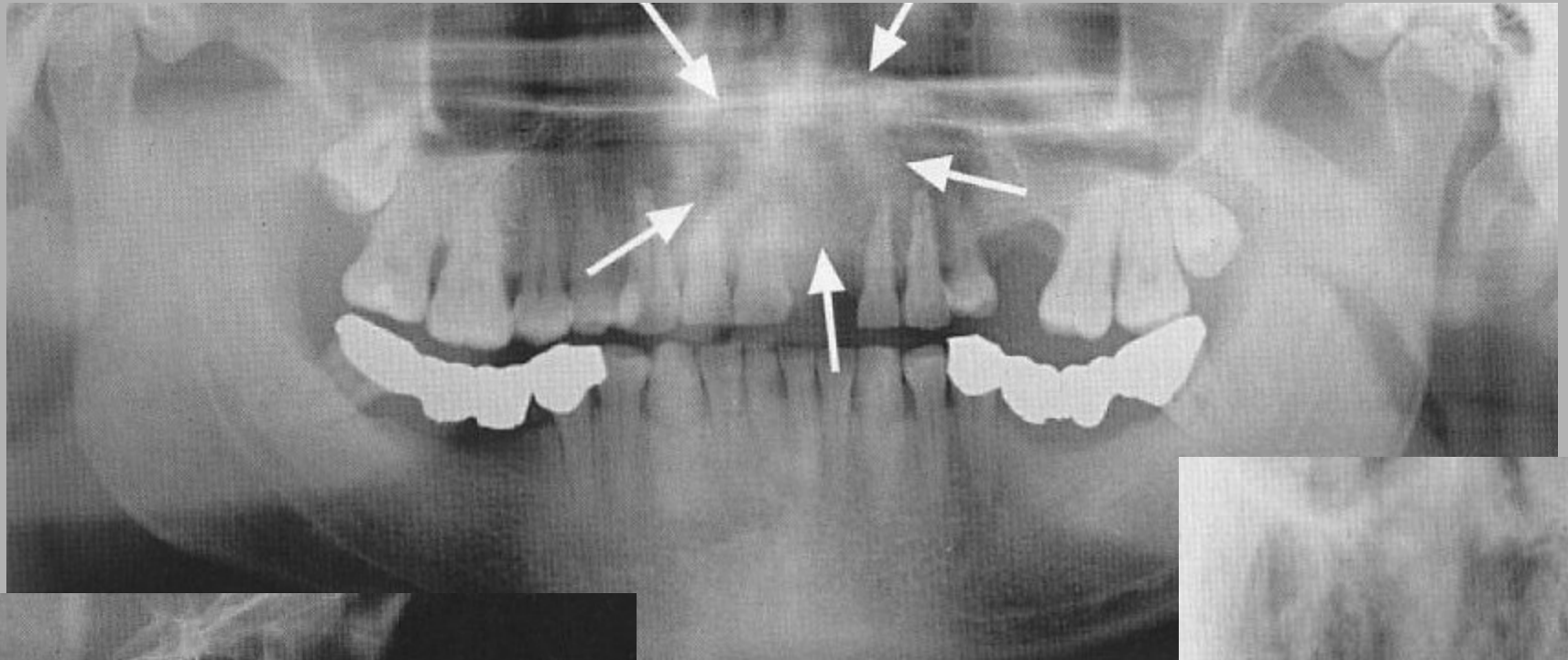


Osteosarcoma

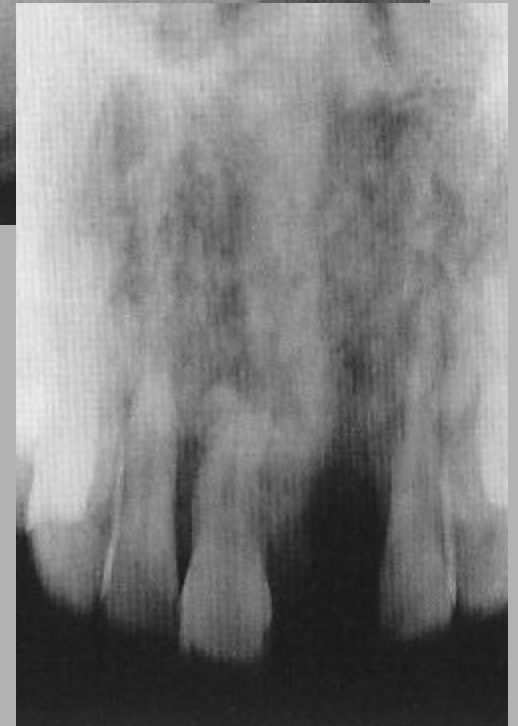

w, 29 y

Osteosarcoma

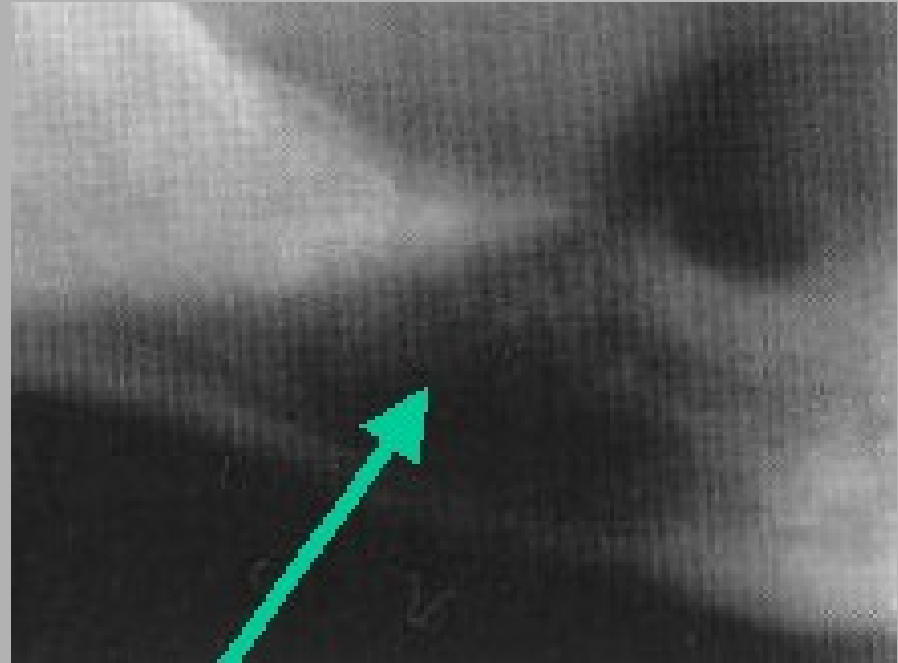


m, 40 y

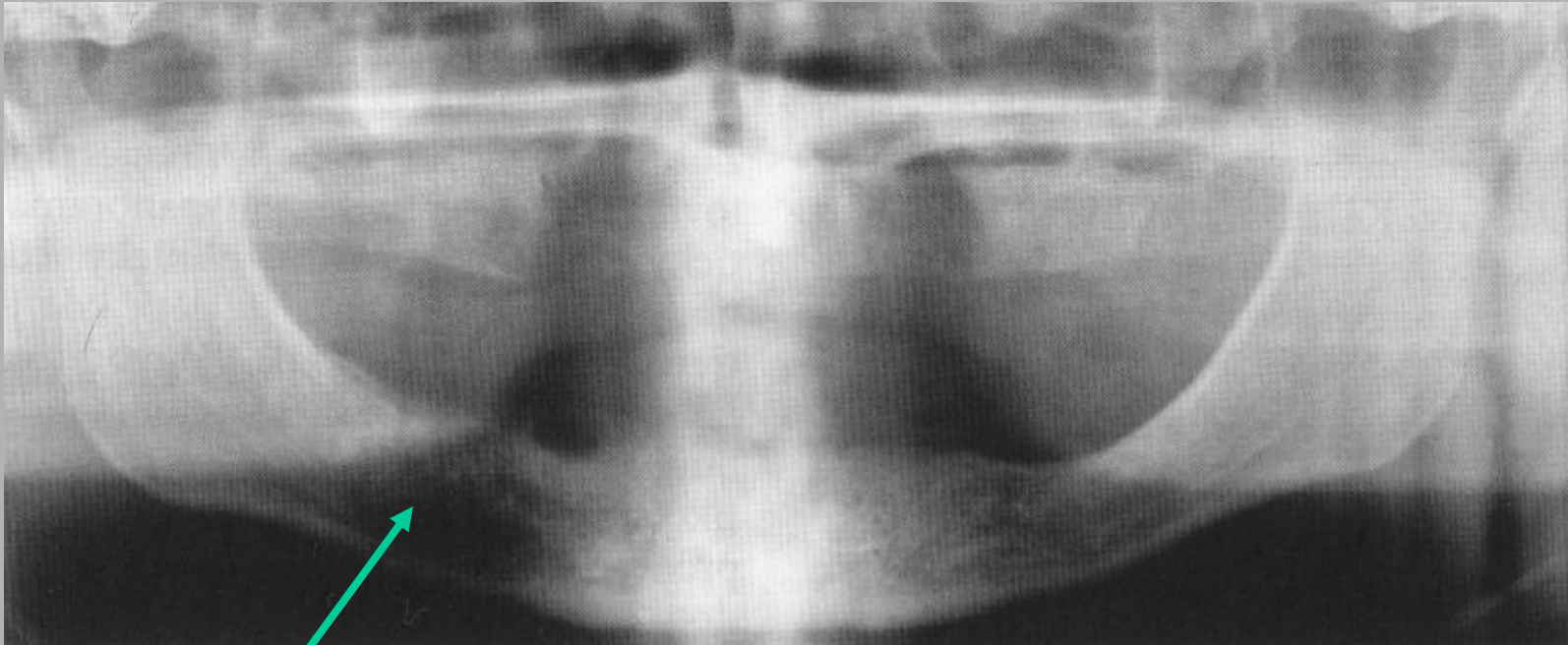


Metastasis

- carcinomas of:
 - mamma
 - lung
 - gl. thyreoidea
 - prostate
- blood spread
- clinics:
 - pain in the bones
 - „reasonless“ teeth release
 - paresthesis of lower lip
 - pathological fracture
- suspicion = scintigraphy

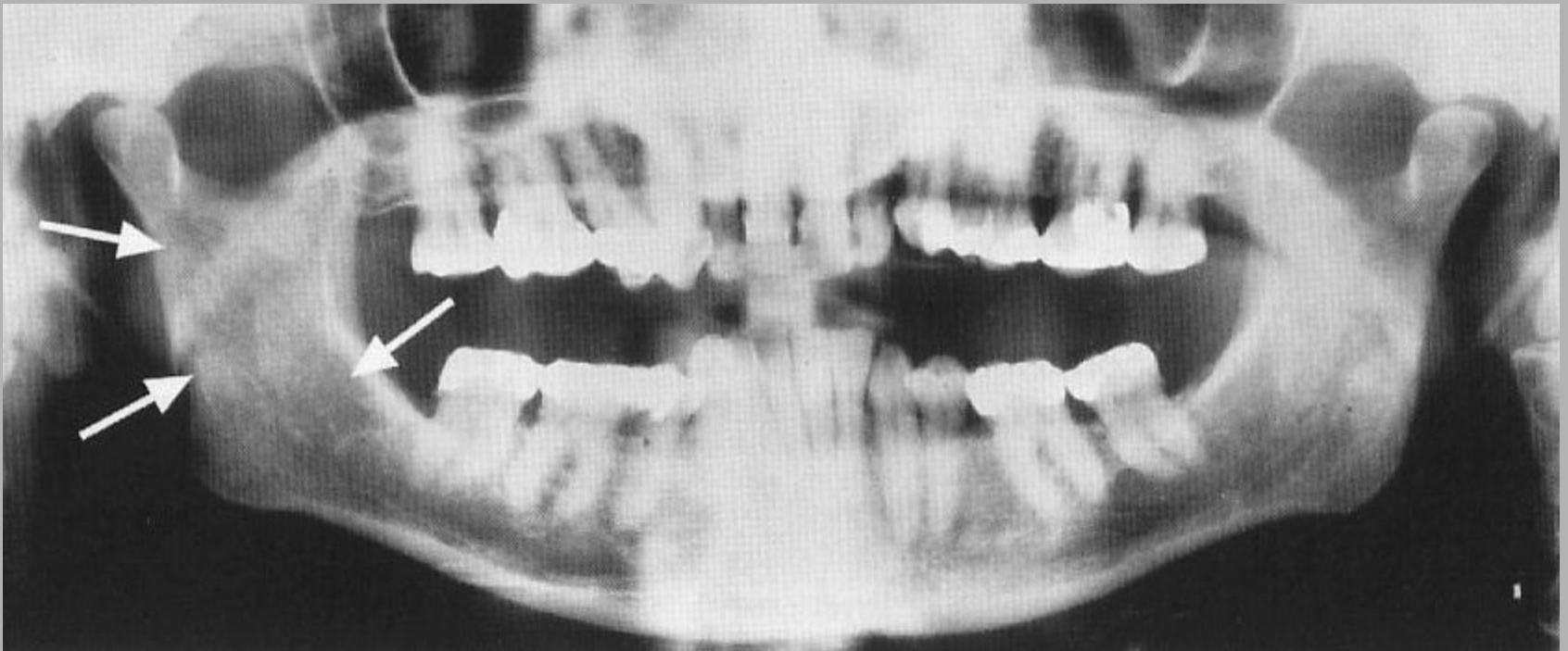


Metastasis



- m, 69 y
- prostate carcinoma
- transparency

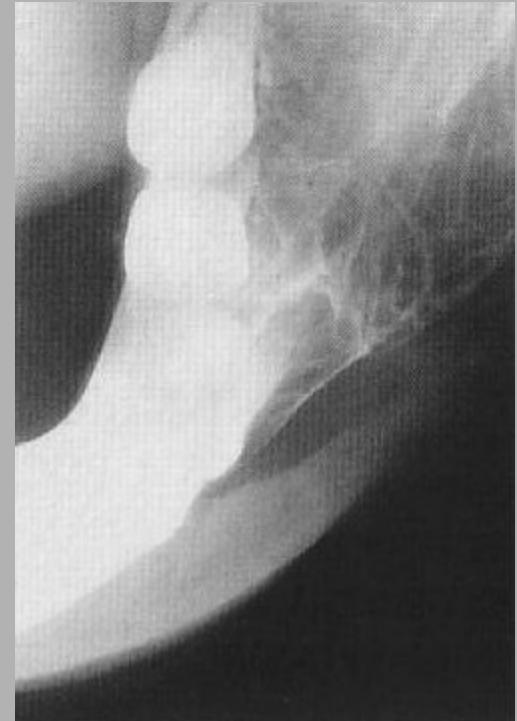Metastasis



- bowel carcinoma
- spotted, blurred

Odont. myxoma

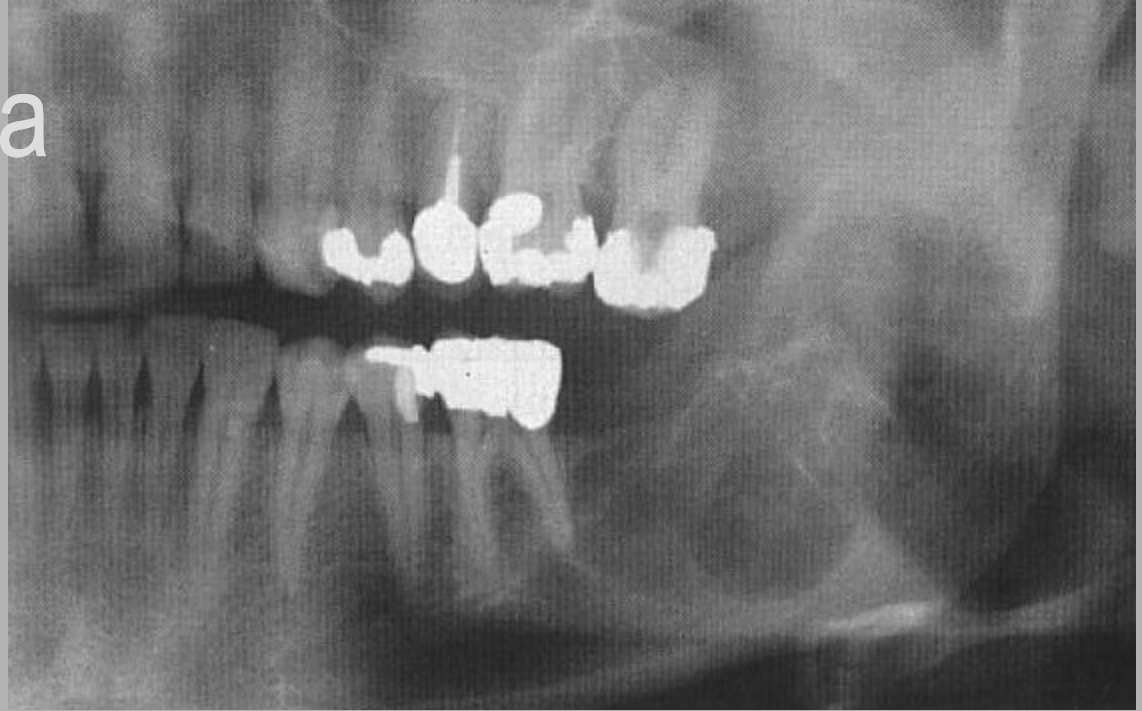- age 10-50 y
- w/m 1:1
- jaws (only)
- most often in lower jaw - caput of mandible
- growth
 - fast
 - endosteal
 - muscle infiltration (occasionally)
- good bounded, irregular translucency
- often relaps



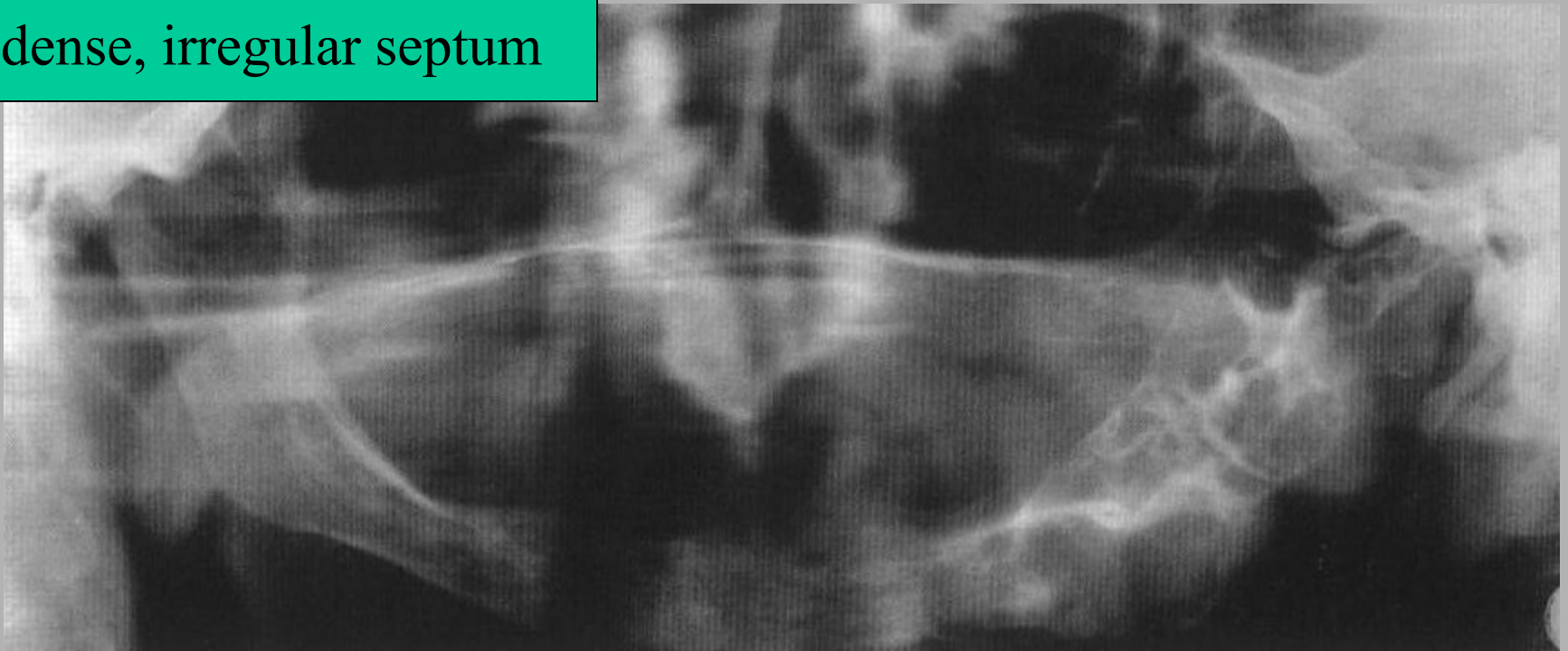
Odont. myxoma

w, 34 y

structure - net

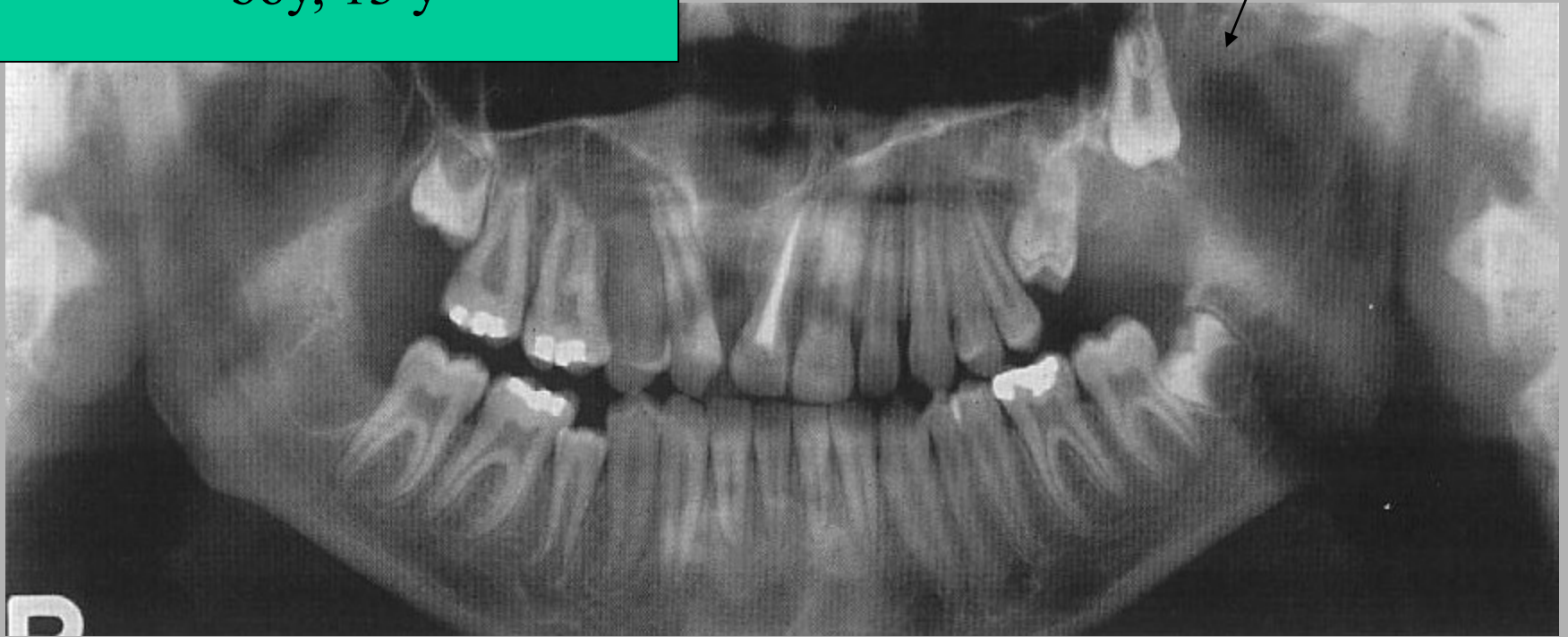

dense, irregular septum



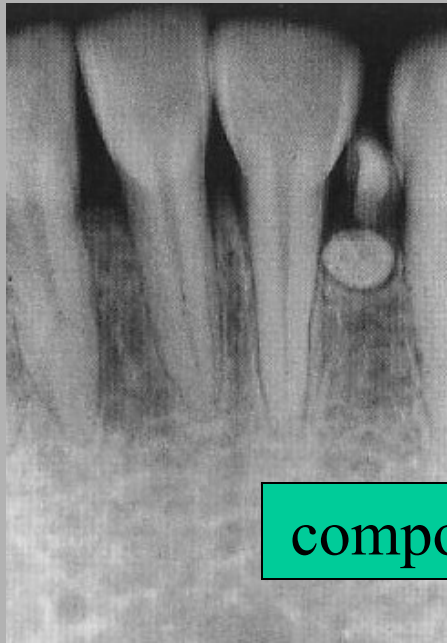
Odont. myxoma

boy, 13 y

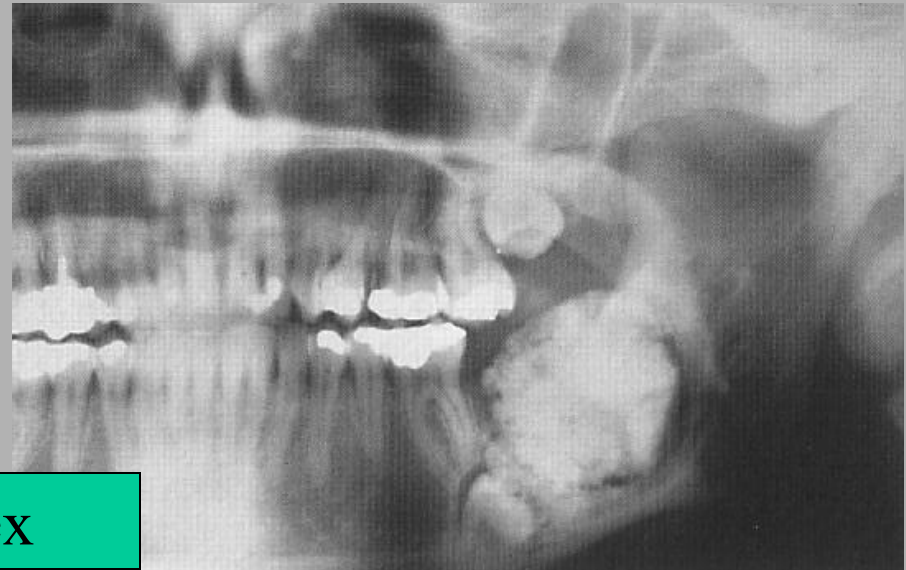

Odontoma

- similar to the hamartomas
- conglomerate of various teeth tissues
 - composite odontoma
 - ✓ contains several developed teeth
 - complex odontoma
 - ✓ contains basic teeth tissues in amorphous mass



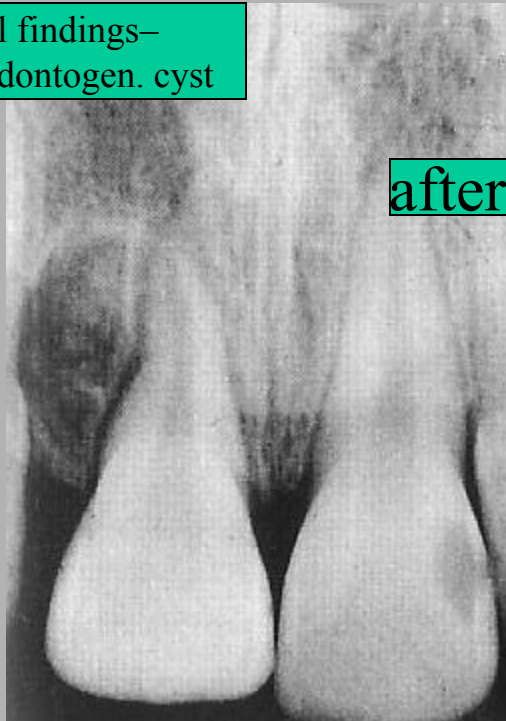
composite



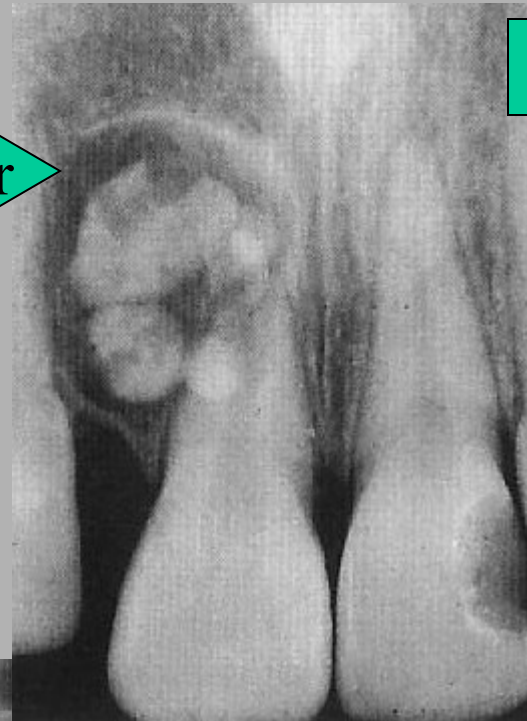
complex

Odontoma

incidental findings—
susp. calc. odontogen. cyst

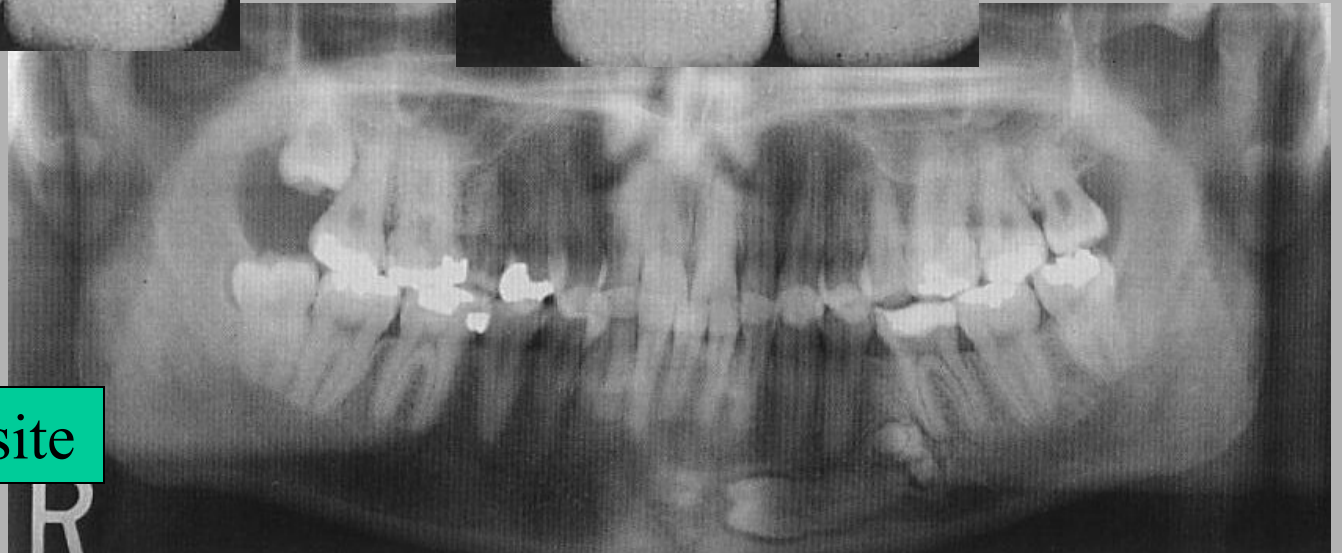


after 2,5 year

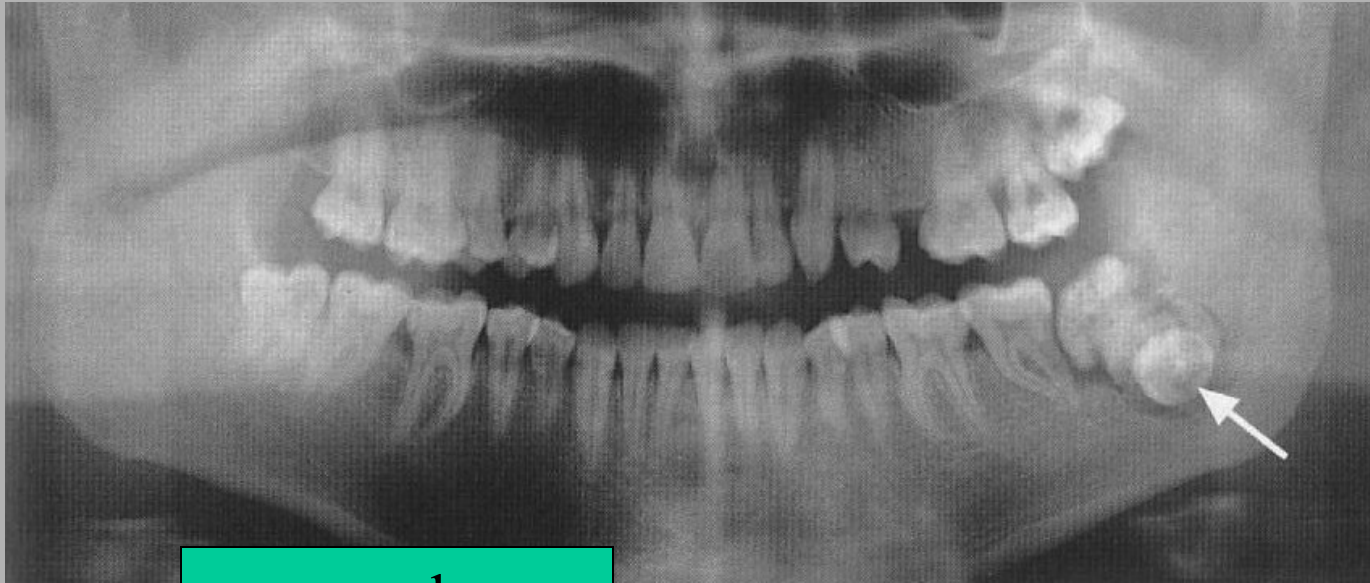

composite

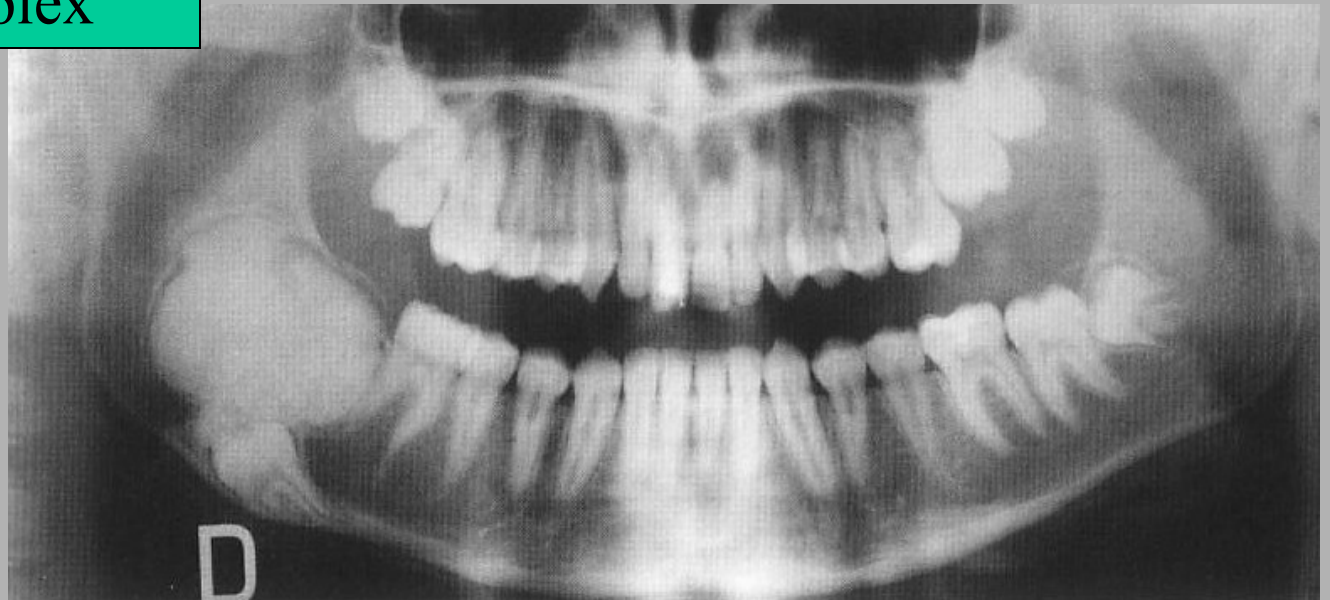
composite



Odontoma

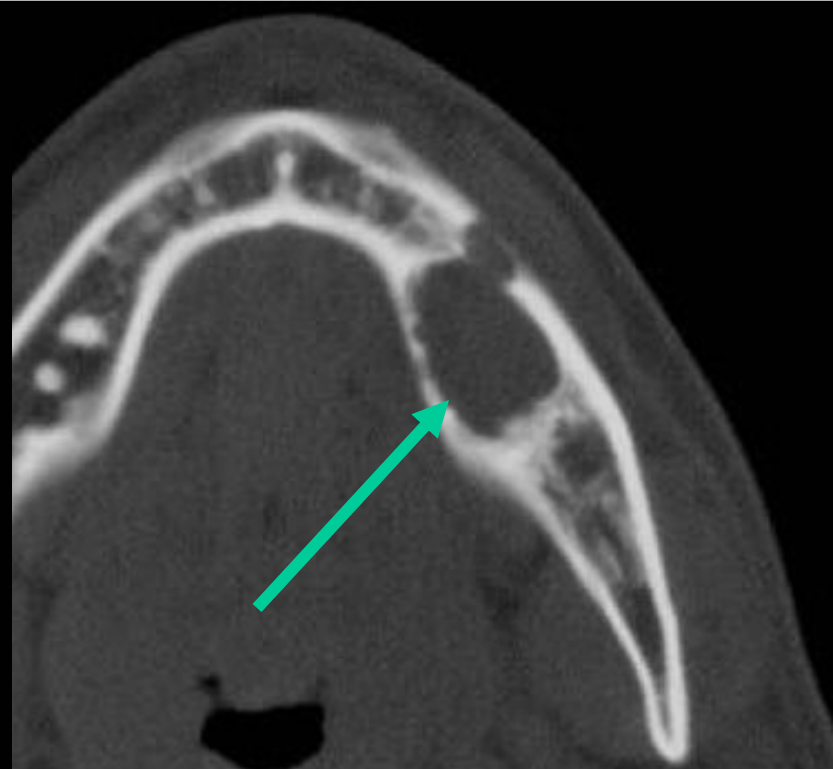
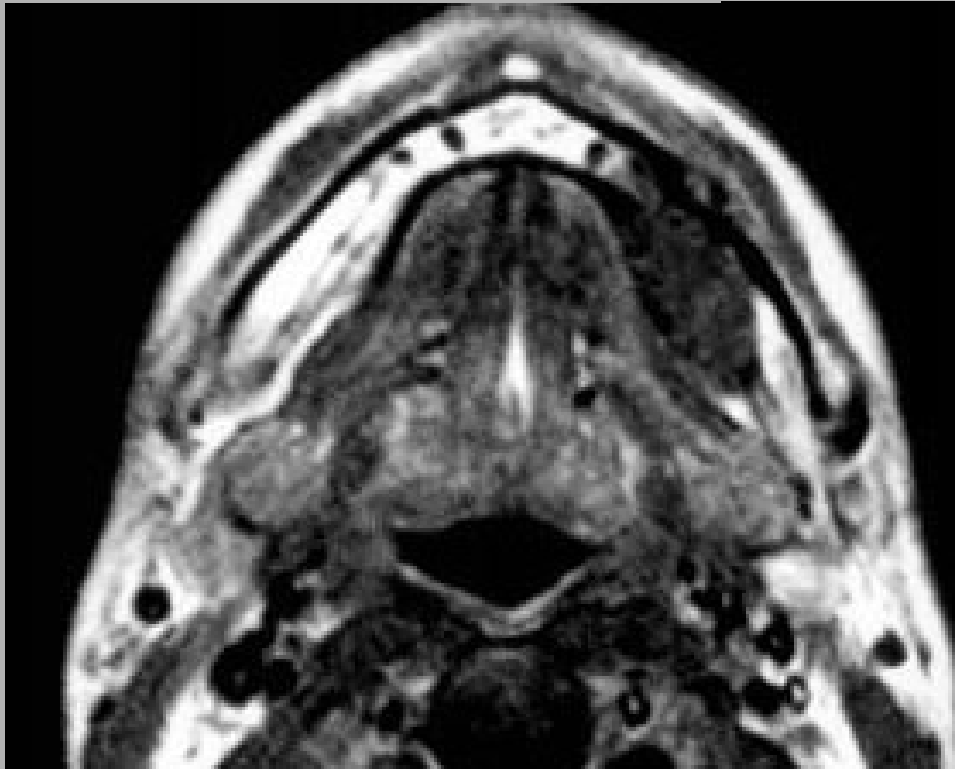


complex



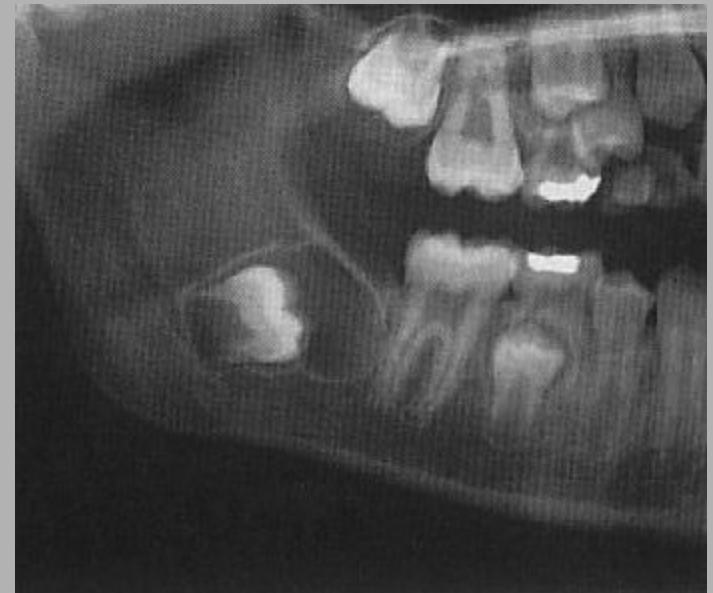Fibroma

- **Fibromas** (or **fibroid tumors** or **fibroids**) are benign tumors that are composed of fibrous or connective tissue.

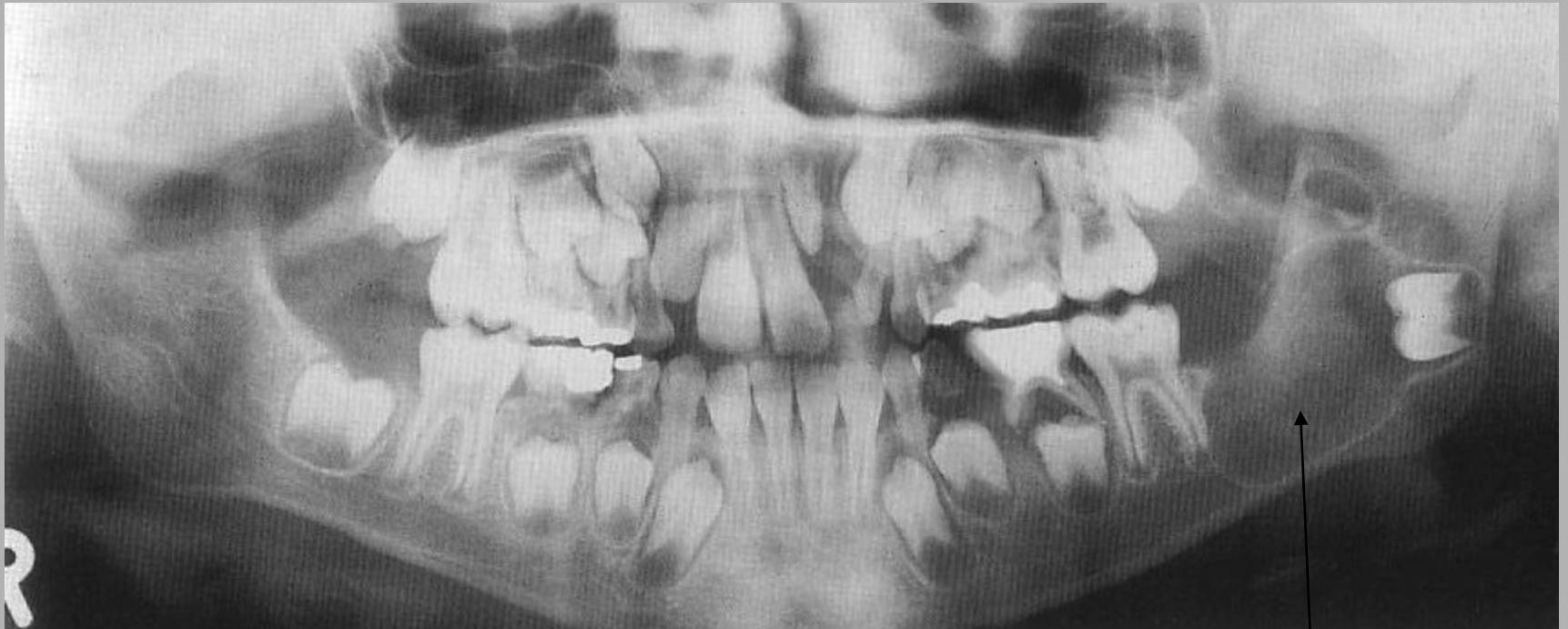


Ameloblastic fibroma

- The **ameloblastic fibroma** is an odontogenic tumor arising from the enamel organ or dental lamina
- tumor with odontogennal epithelium and ectomesenchyma
- benign
- 10-20 y, boys
- in molar mandible region
- dif.dg.
 - follicular cyst
 - ameloblastoma
- don't recidivate

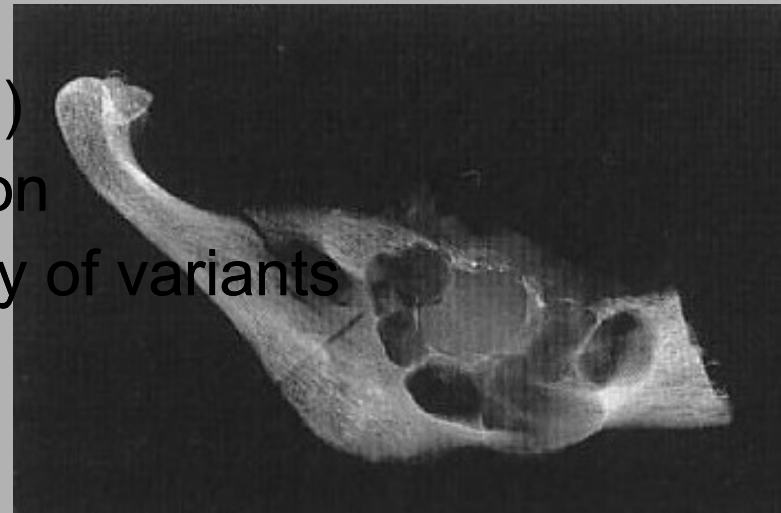


Ameloblastic fibroma

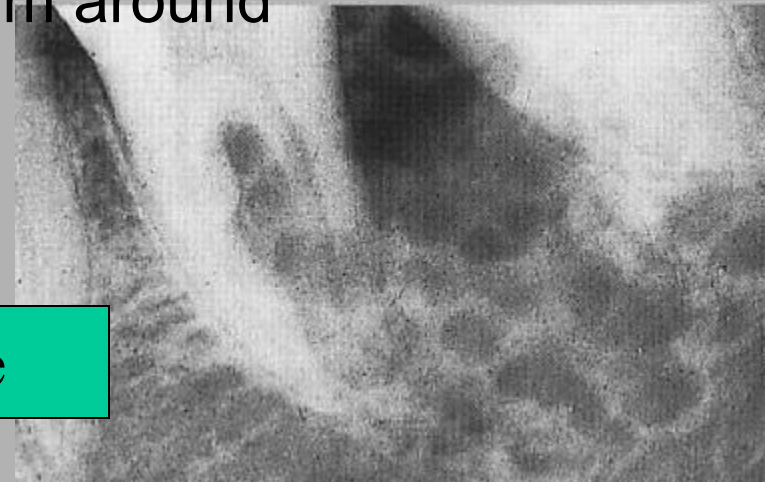


Ameloblastoma

- is a rare, benign tumor of odontogenic epithelium
- m/w 1:1
- in a region of caudal molars (80%)
- long-term relaps = radical resection
- variable histological image – many of variants
- RTG
 - multilocular
 - multicystic
 - bubble transparency with septum around
 - compacta thin out
- slow growth, painless
- oedema, facial asymetry

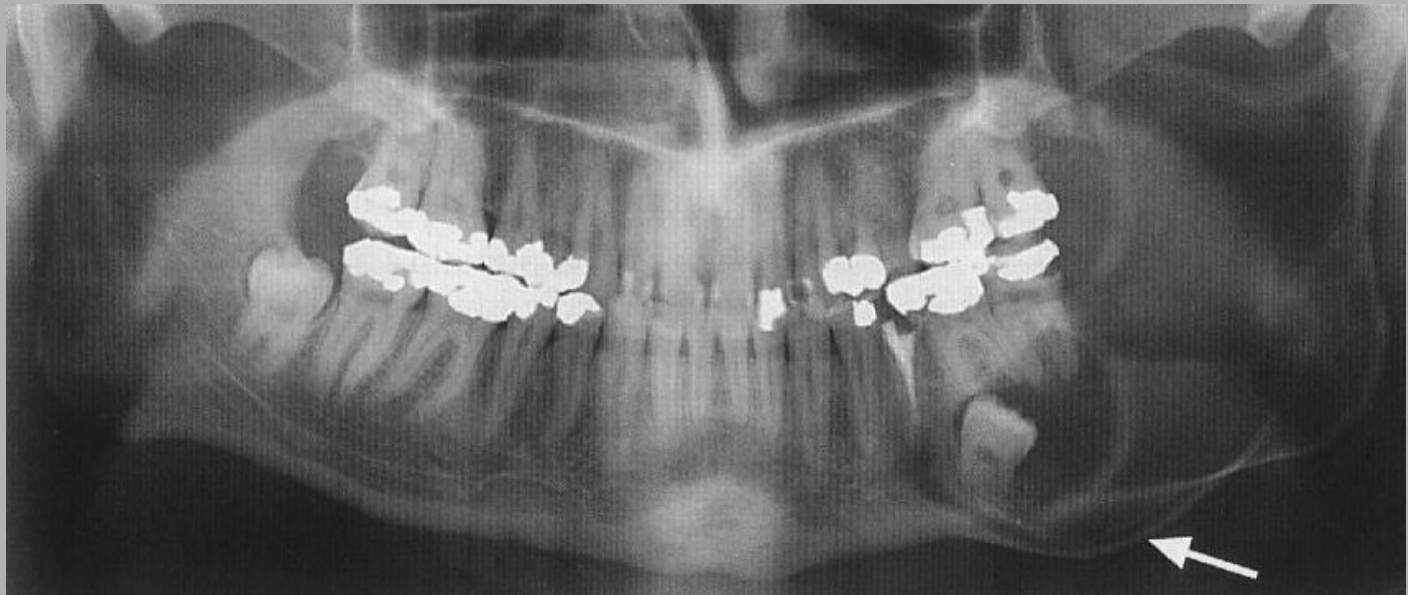
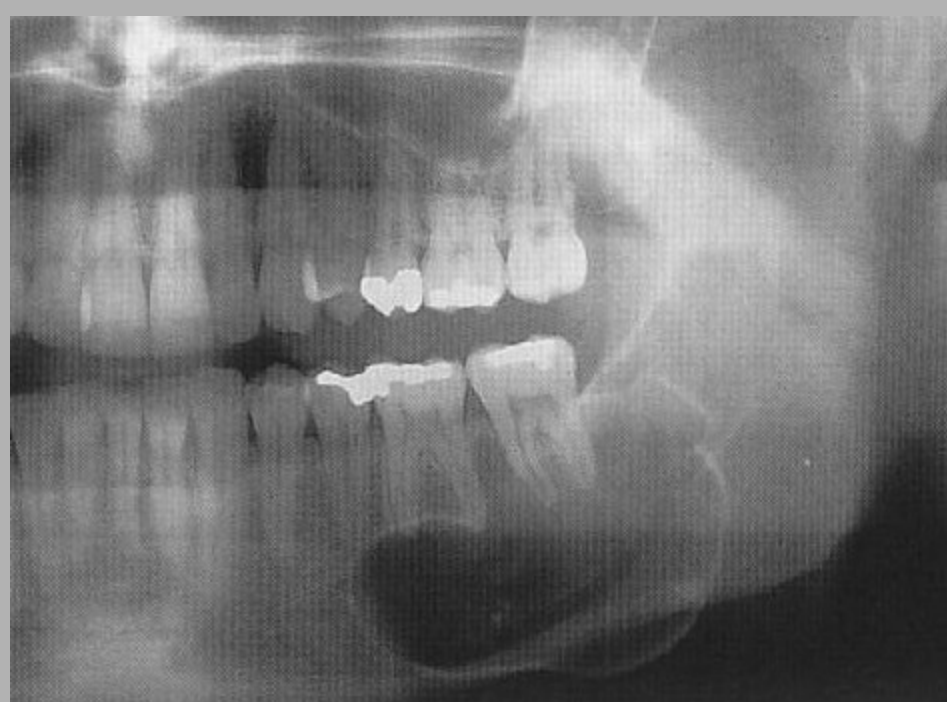

„honeycomb“ structure



Ameloblastoma

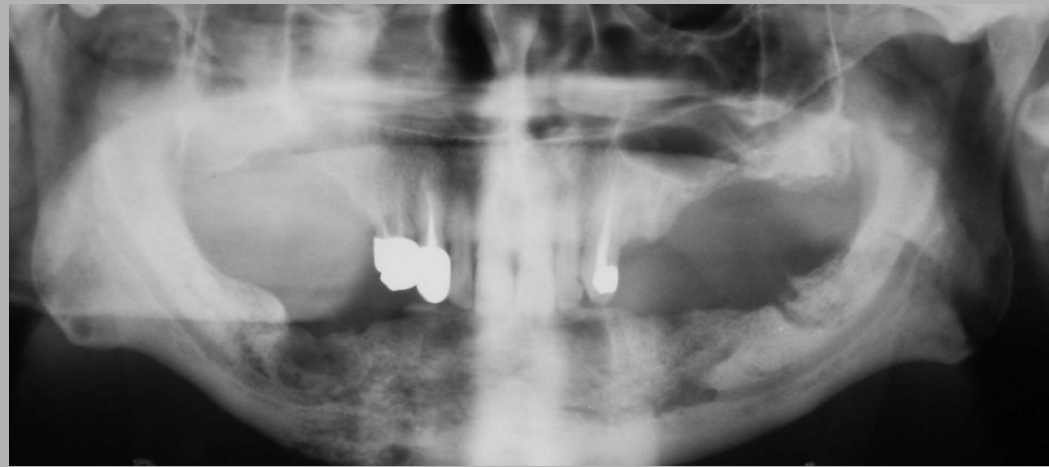
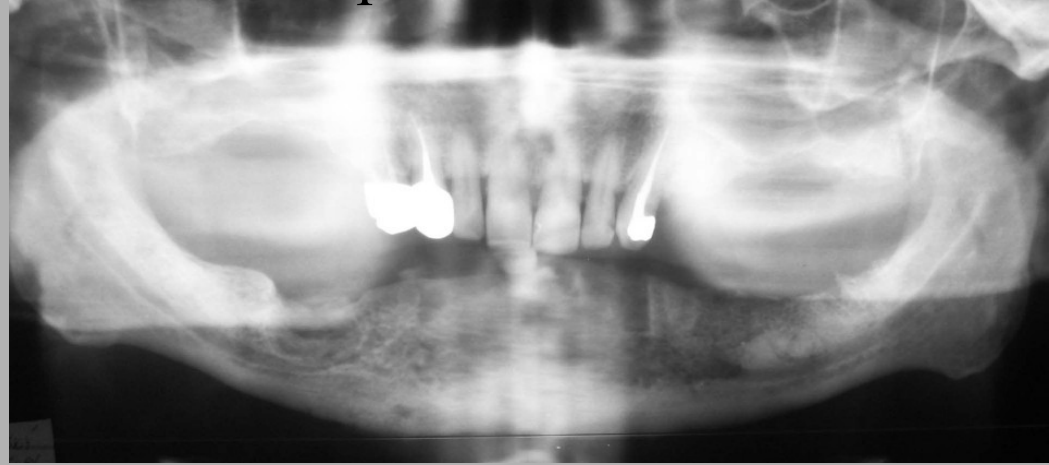
- dif.dg.
 - follicular cysts
 - keratocysts
 - ameloblastic fibroma
 - odontogennal myxoma
 - central eosinofil granuloma



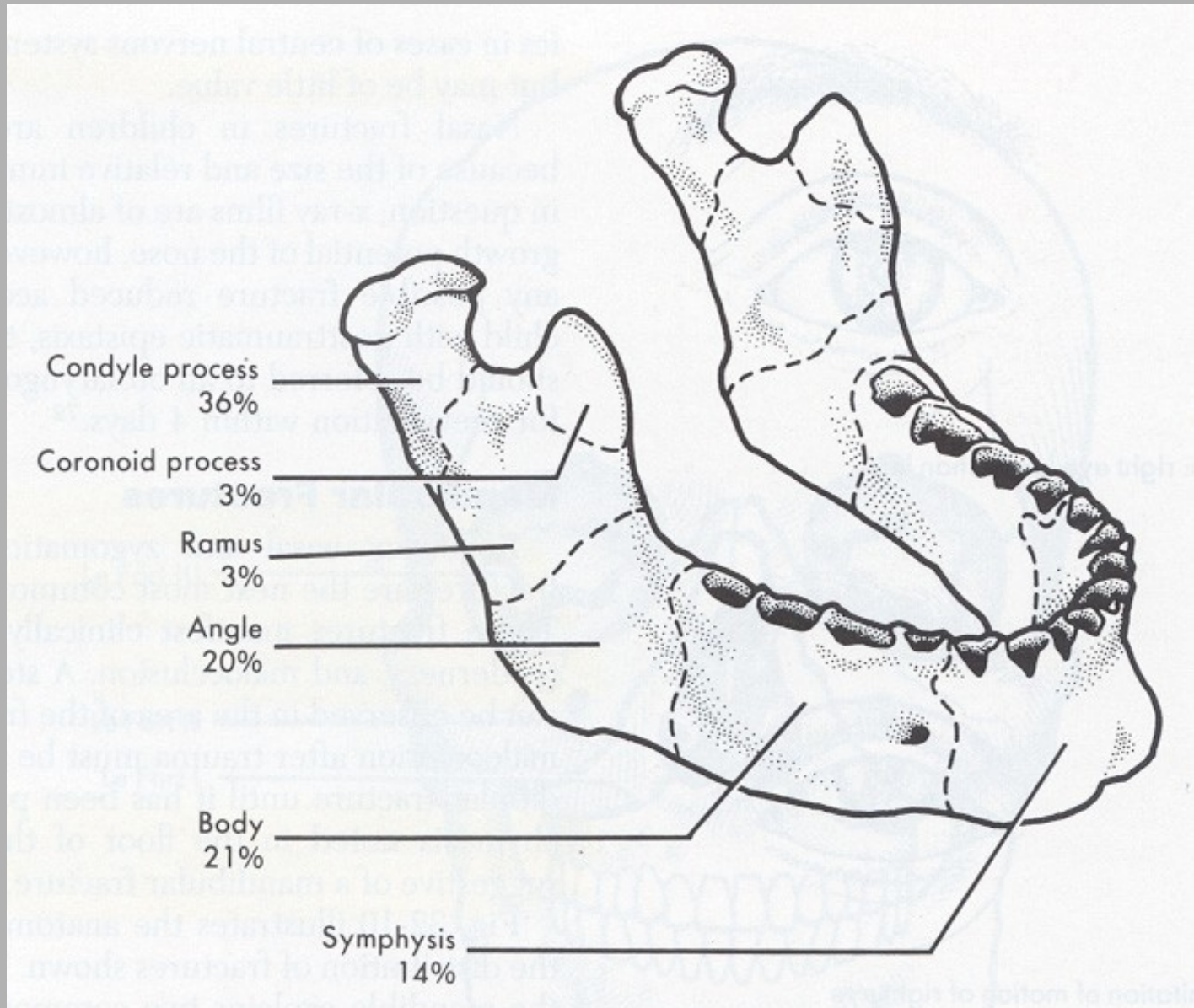
Myeloma

is a cancer of the white blood cells known as plasma cells.

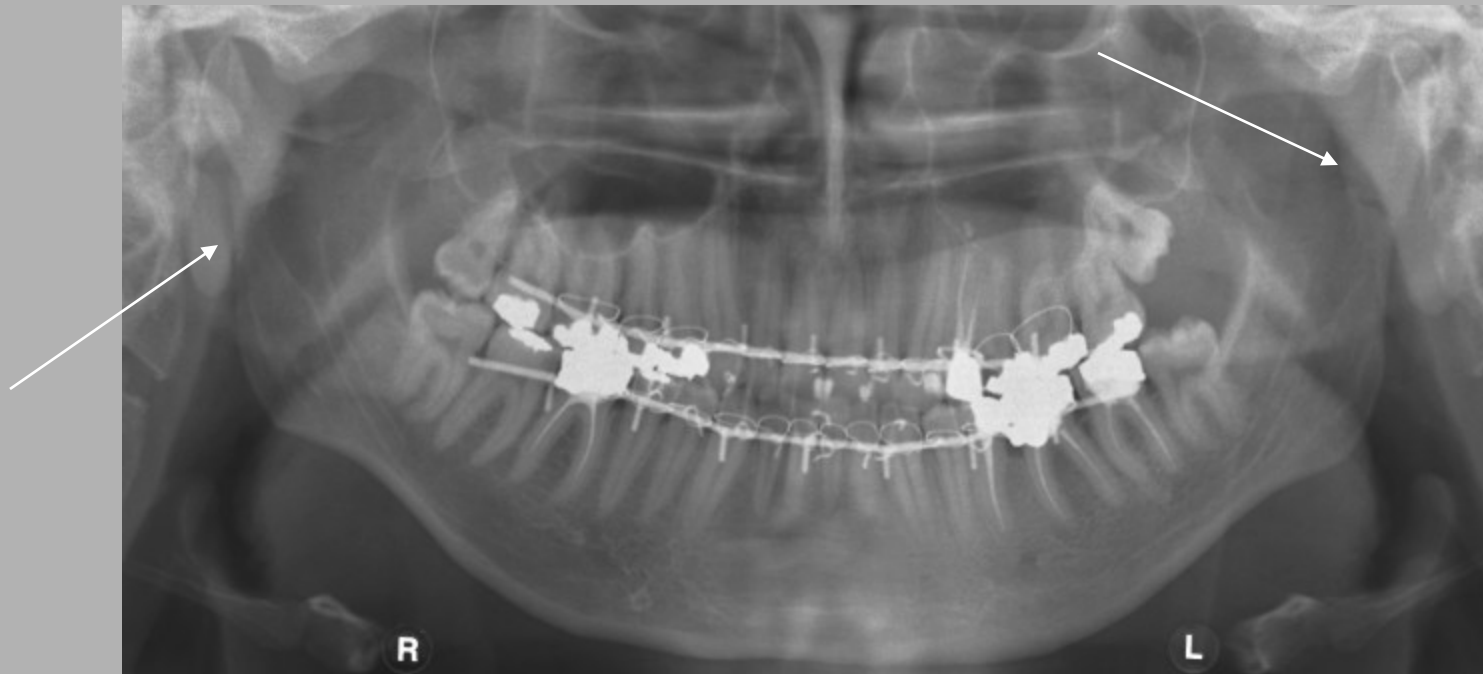
- Hypercalcemia (corrected calcium >2.75 mmol/L)
- Renal insufficiency attributable to myeloma
- Anemia (hemoglobin <10 g/dL)
- Bone lesions (lytic lesions or osteoporosis with compression fractures)
- Frequent severe infections (>2 a year)
- Amyloidosis of other organs
- Hyperviscosity syndrome



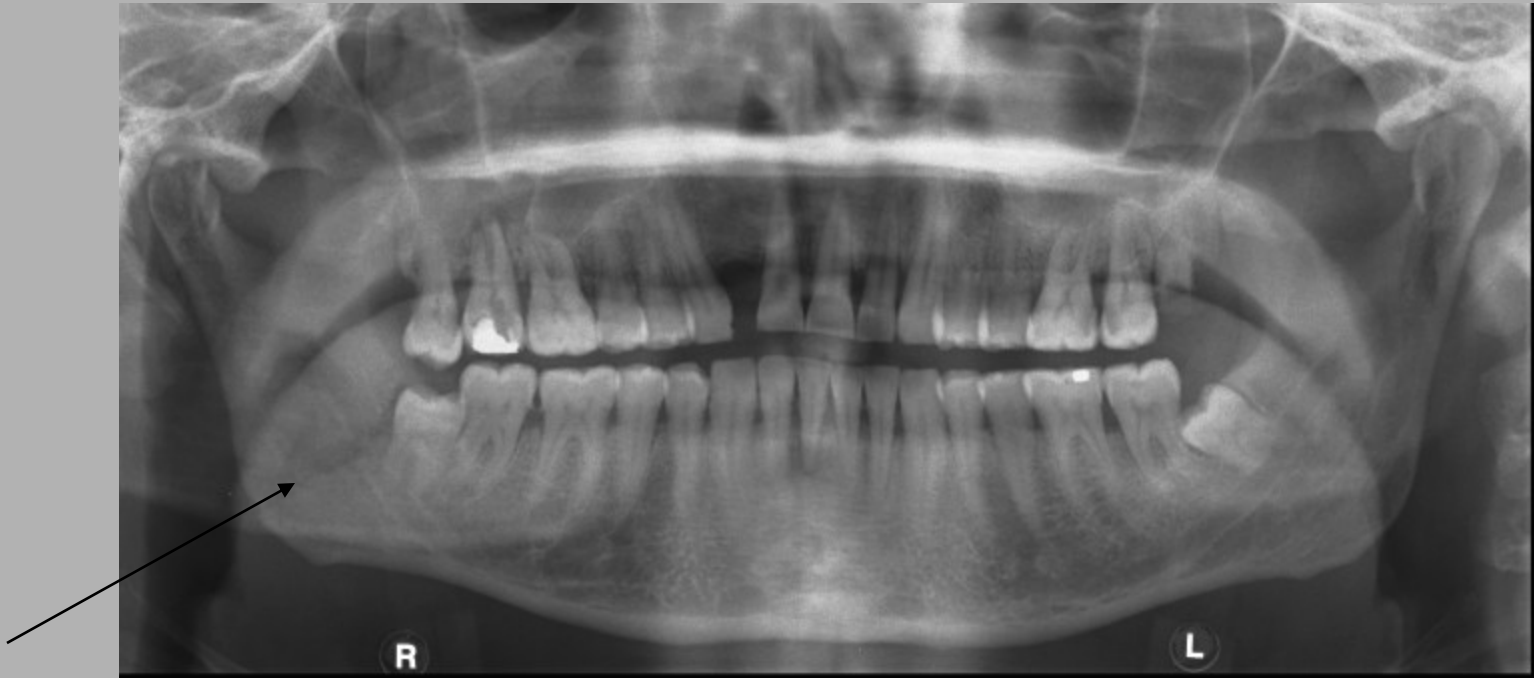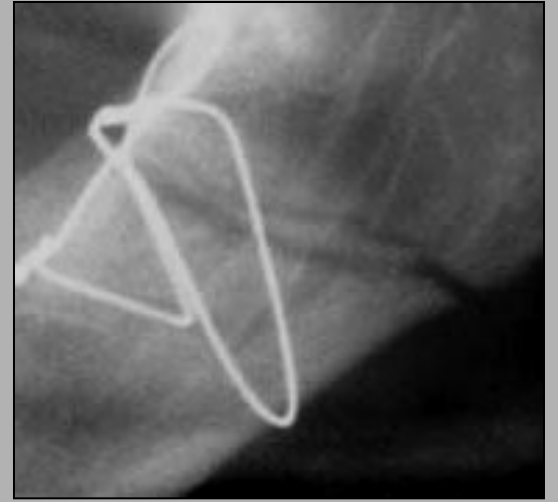Mandible fractures



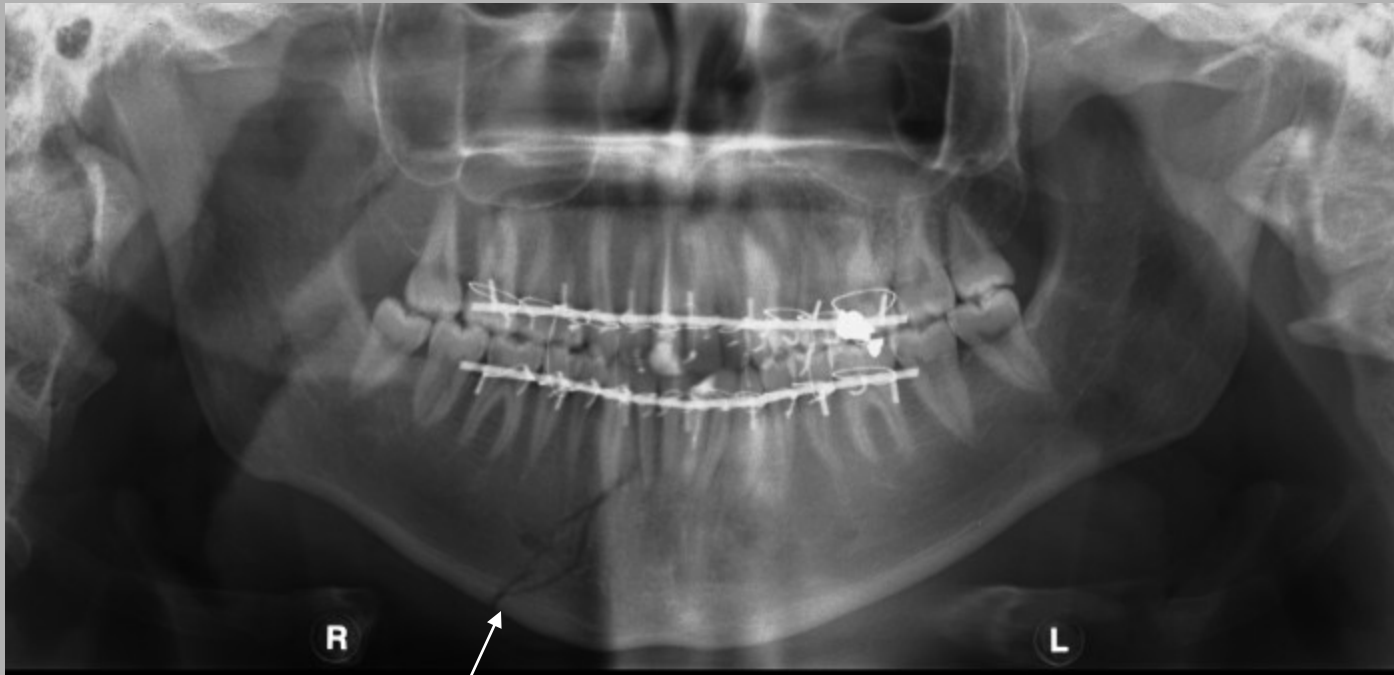Fract. processus articul. mandibulae bilat.



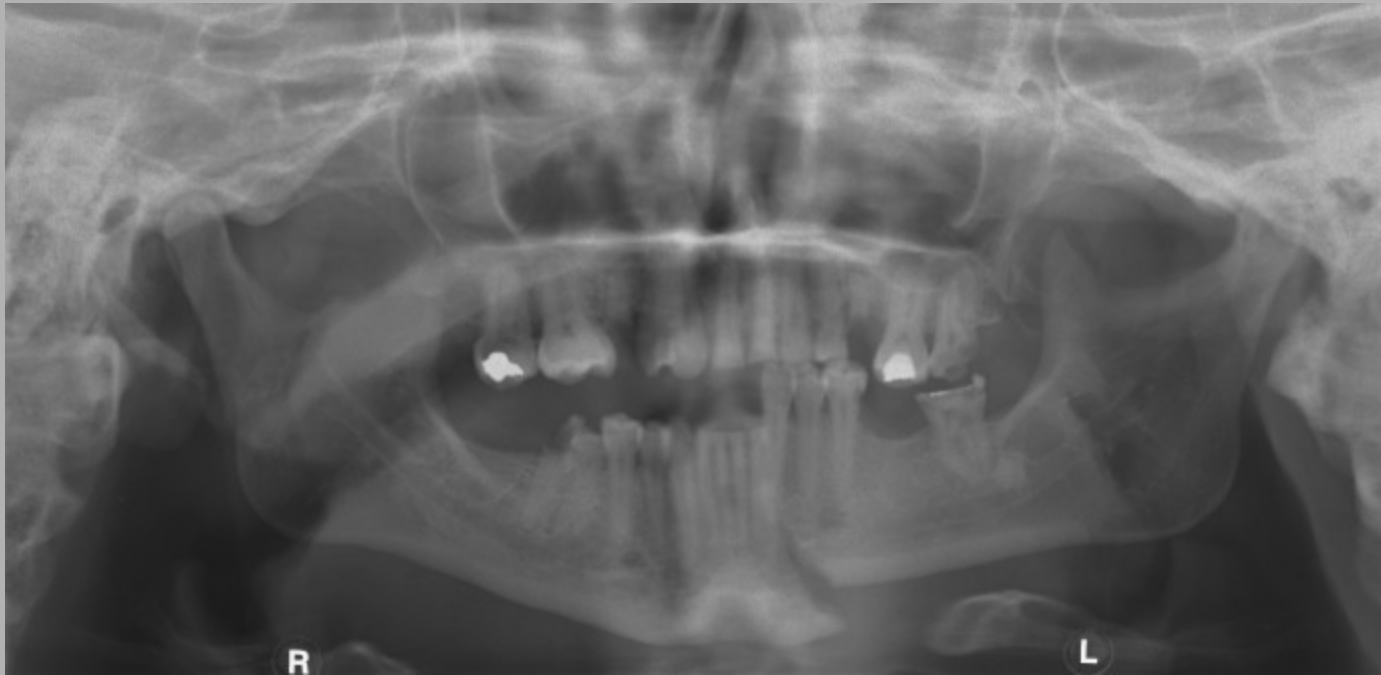mandible angle - sutura

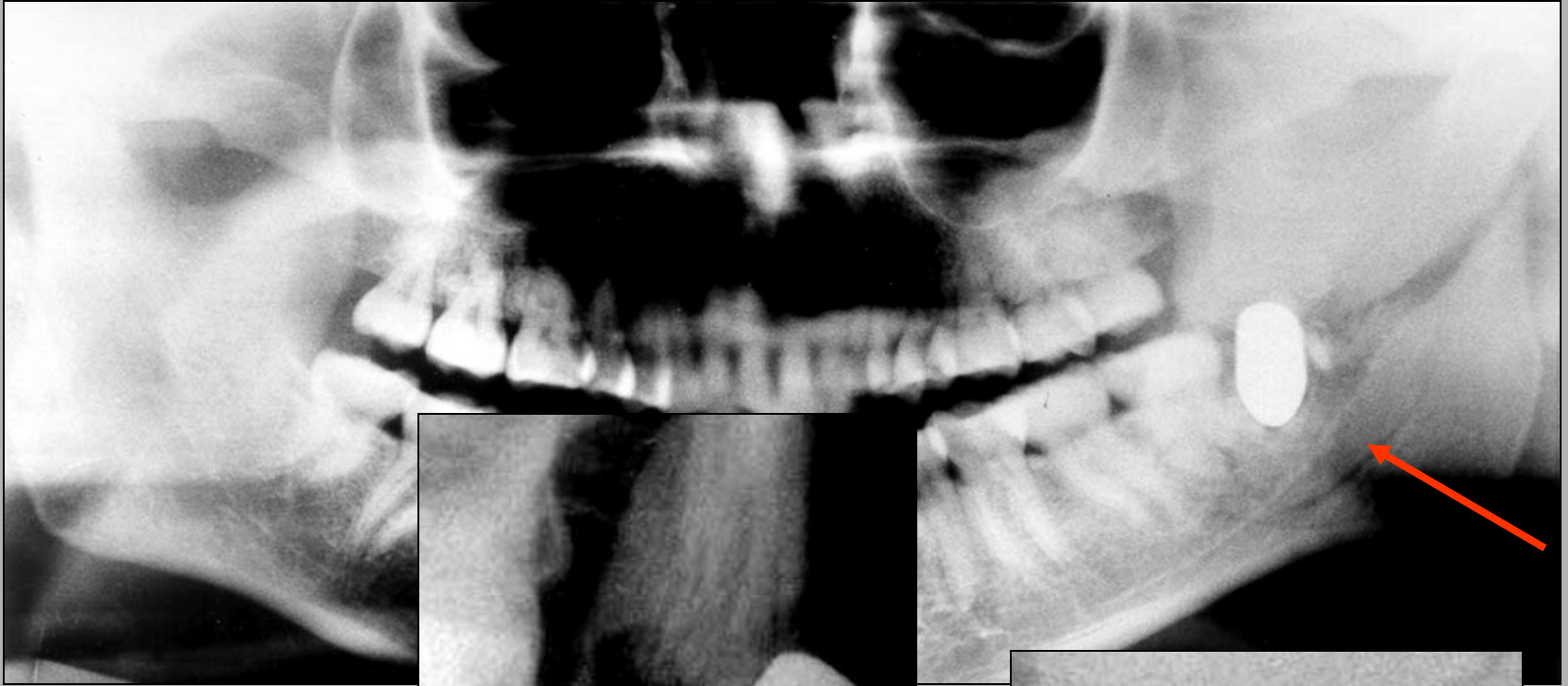


Body

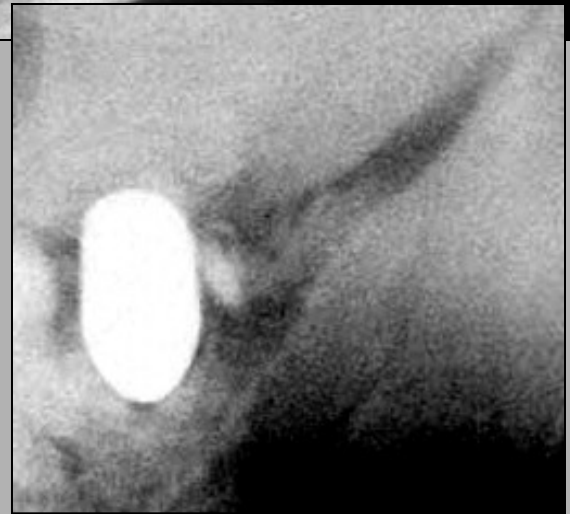
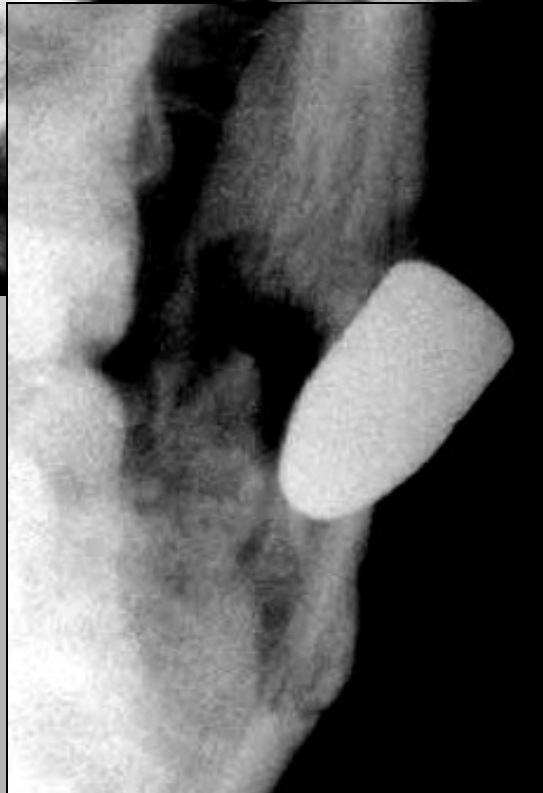

symphysis

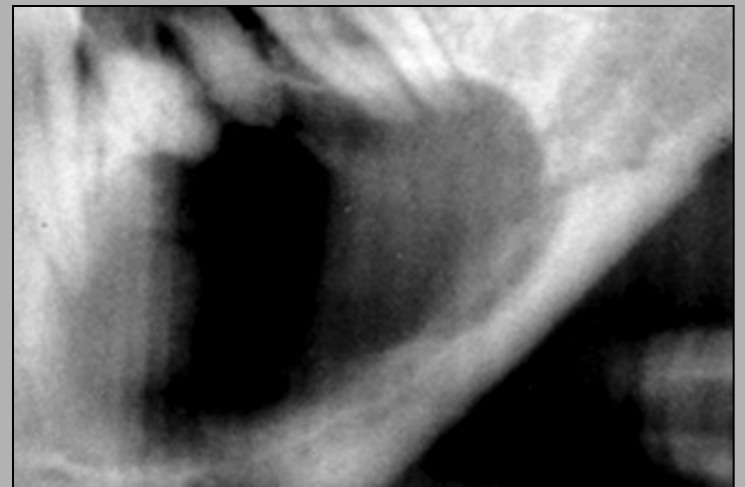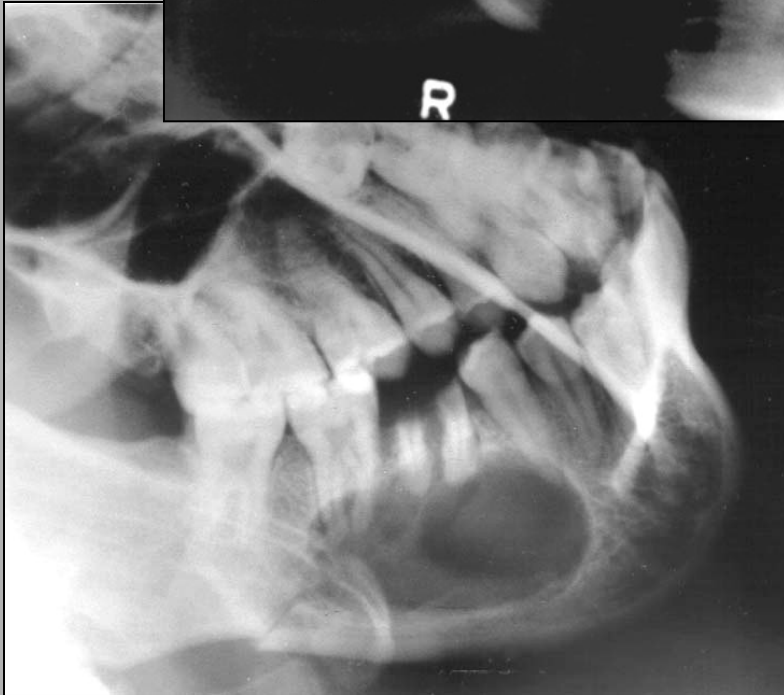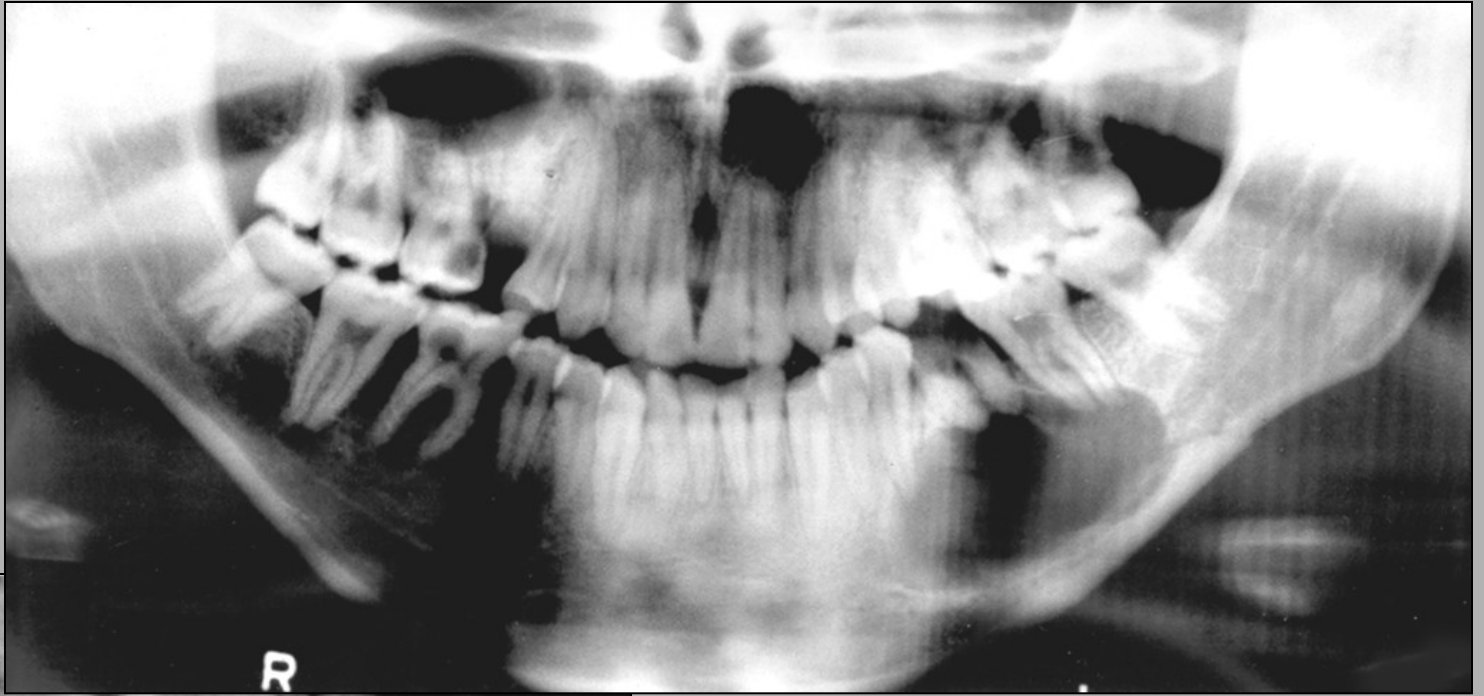




bullet

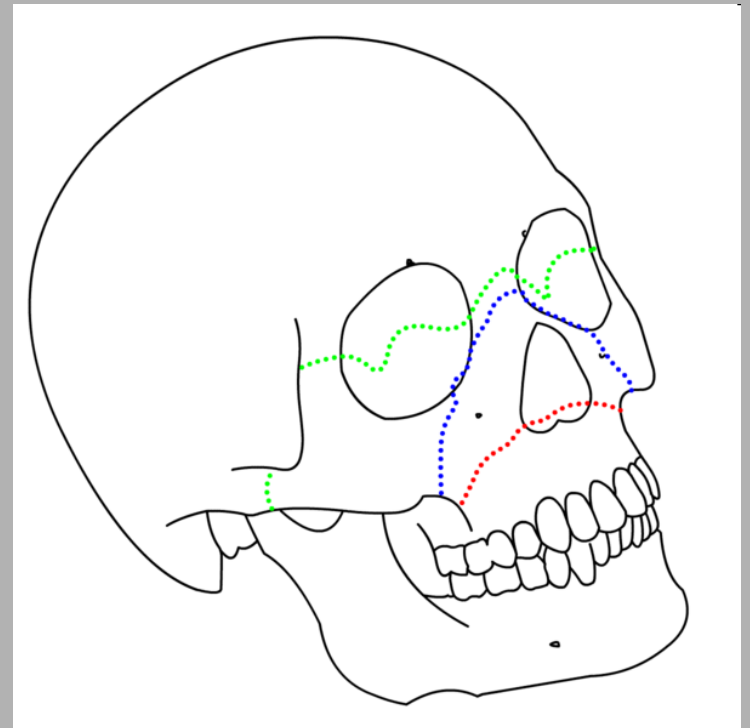


Pathological fracture apical cyst



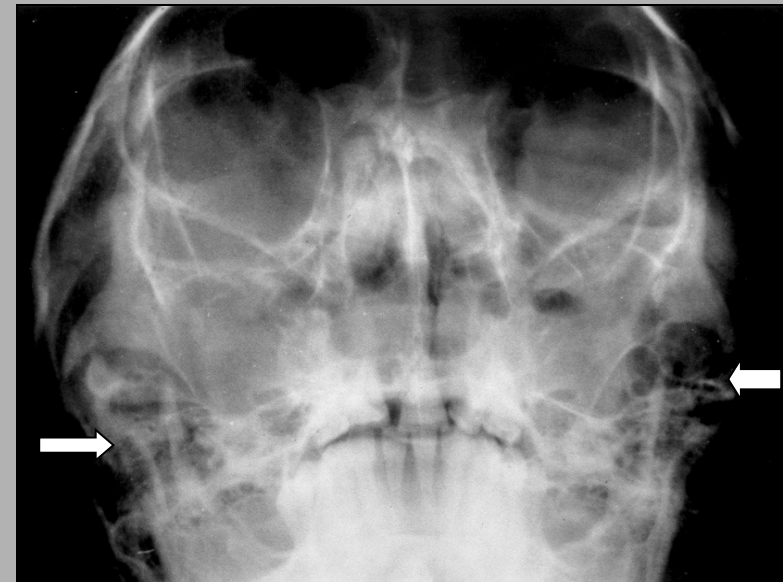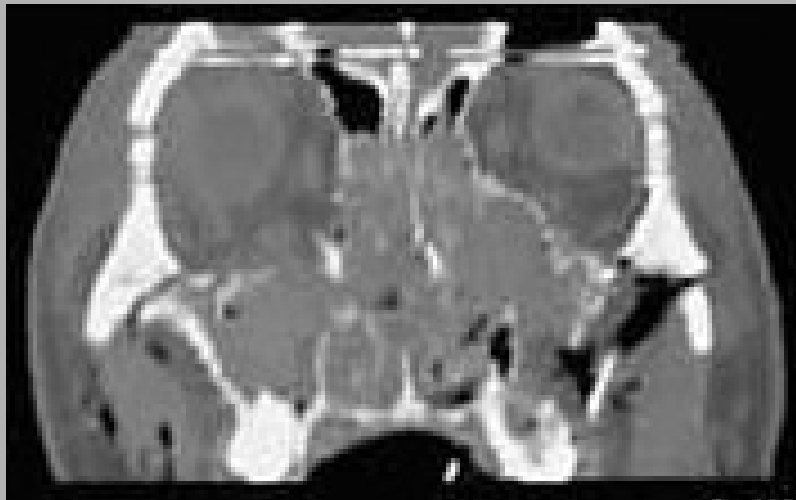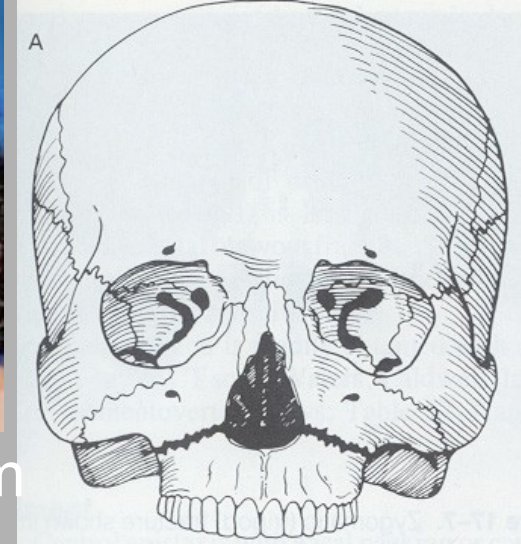
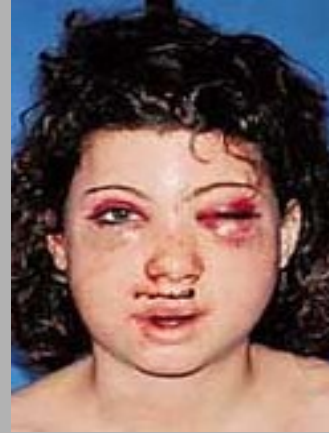Le Forte

- high energy trauma
- Classification: **Le-Forte I-III**
- all types Le Forte involve processus pterygoideus



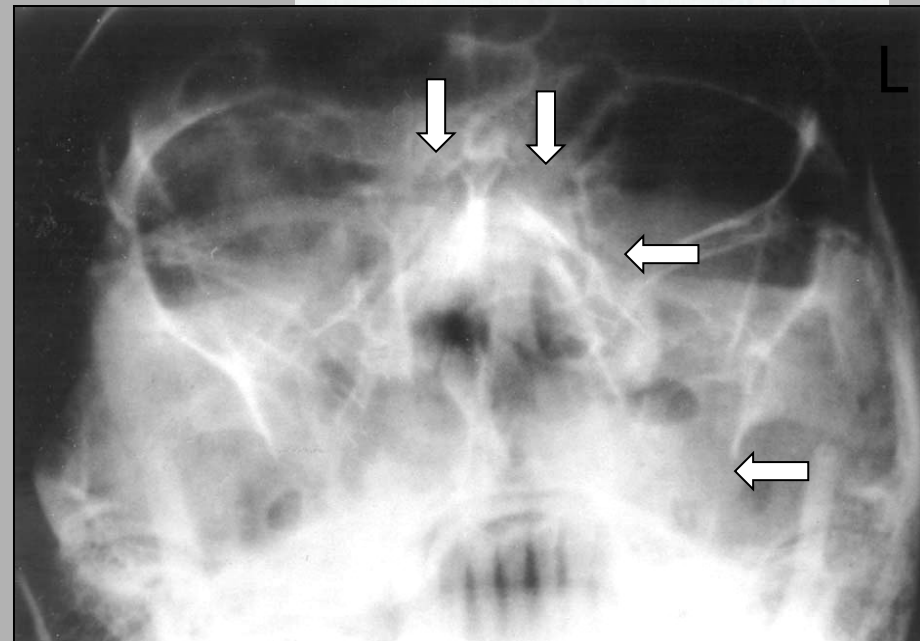
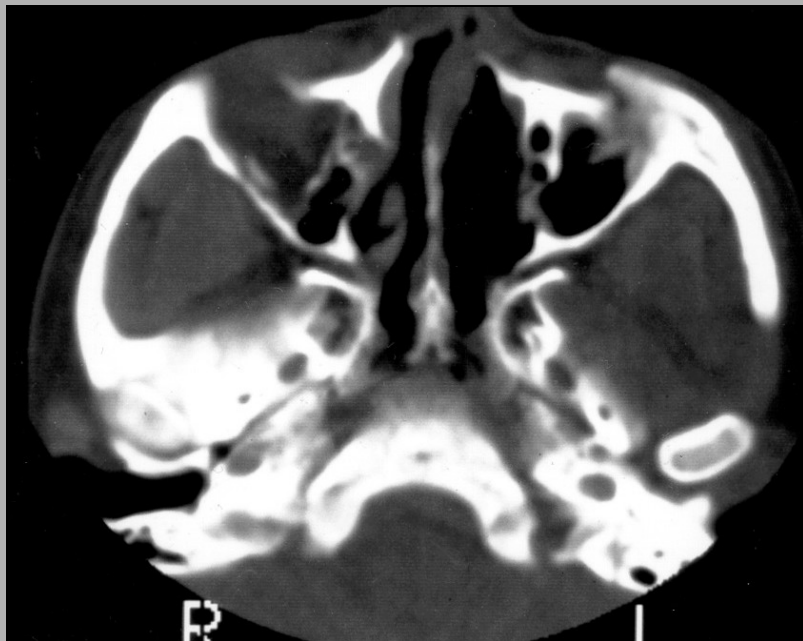
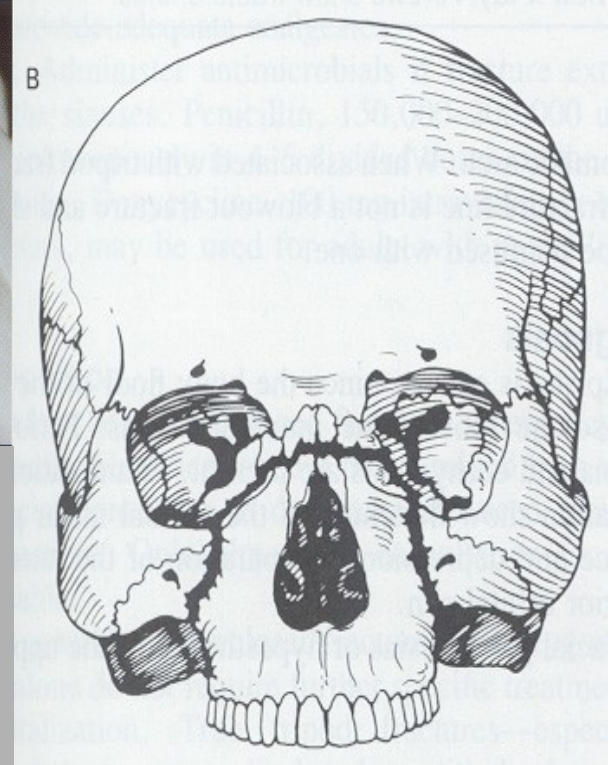
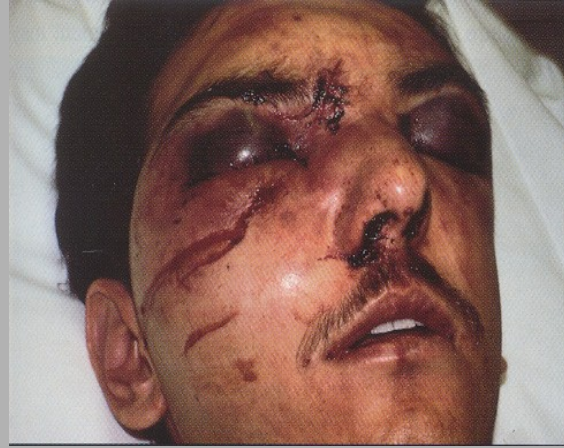LeFort I

- horizontal fracture
- 'floating palate'
- The fracture extends from the nasal septum, travels horizontally above the teeth apices
- crosses below the zygomaticomaxillary junction, and traverses the pterygomaxillary junction to interrupt the pterygoid plates.

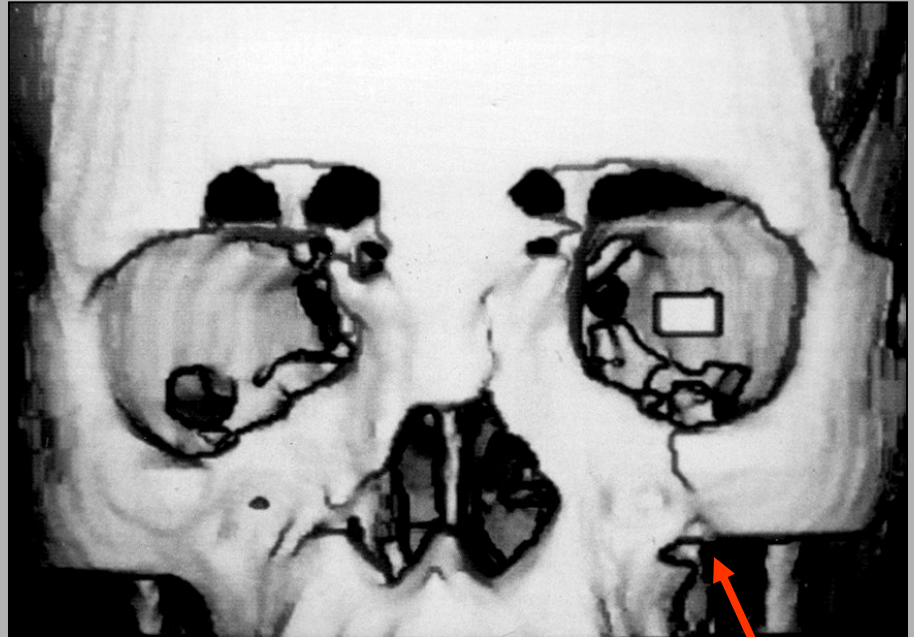
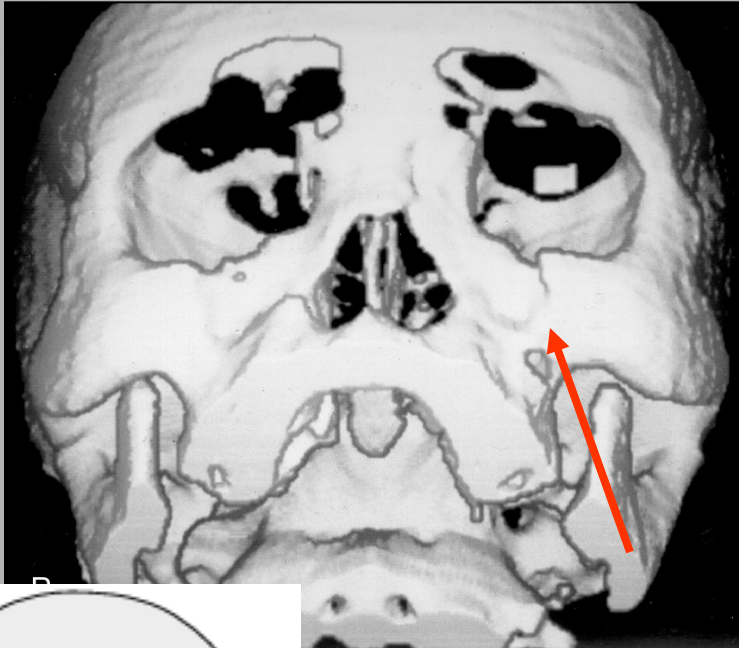


LeFort II

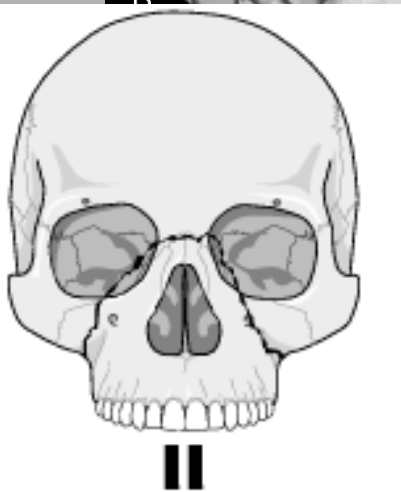- ✓ Maxilla
- ✓ Medial portion of orbits
- ✓ nasal bones



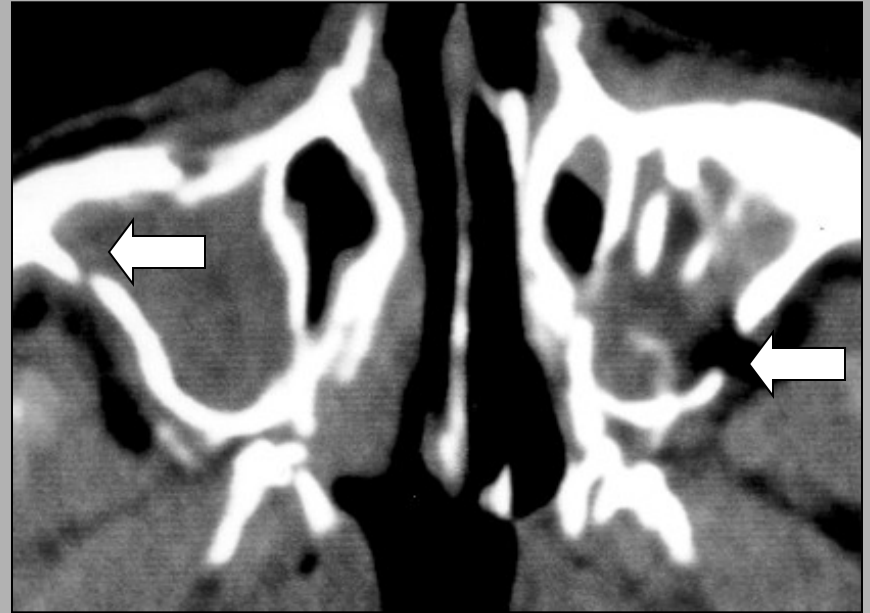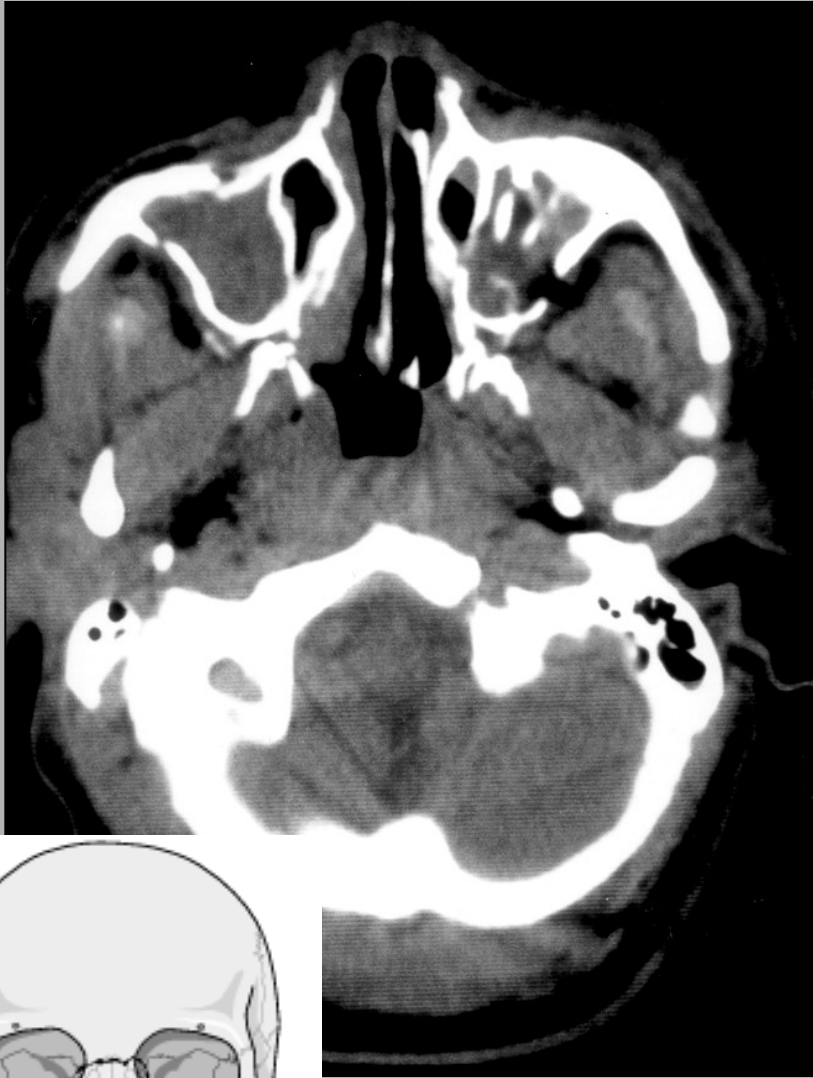LeFort II



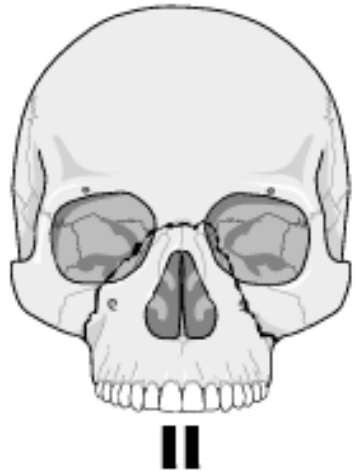CT 3-D reconstruction



LeFort II

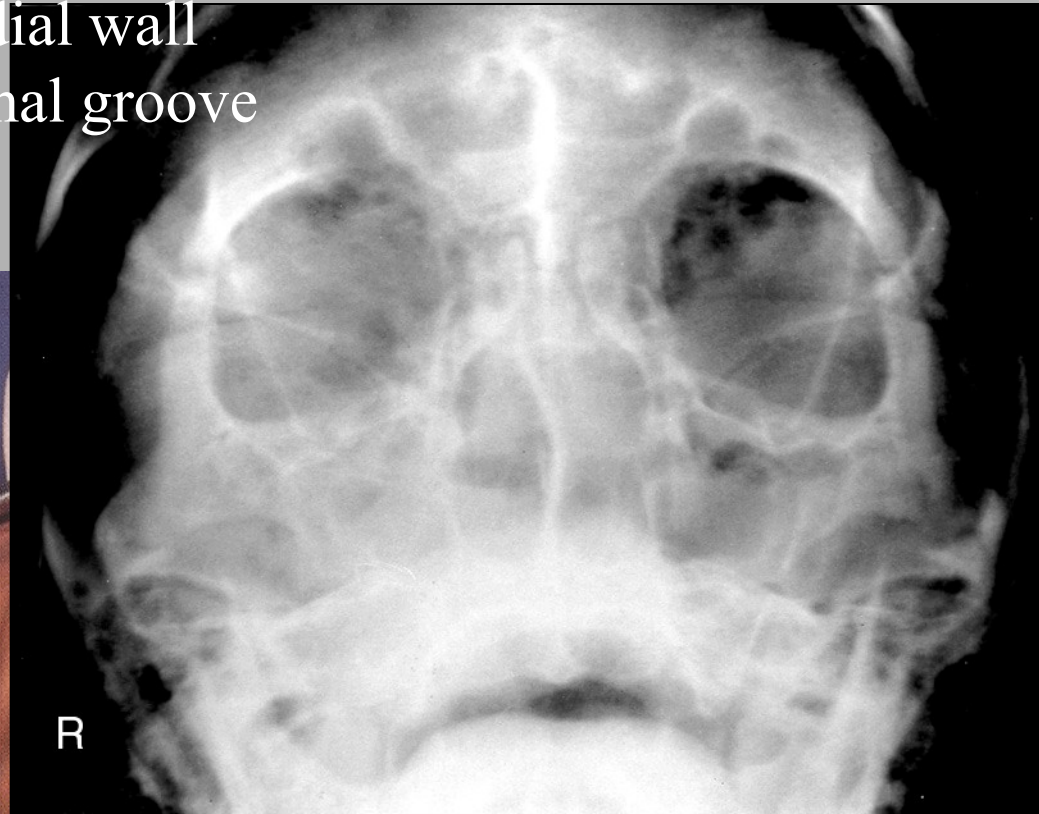
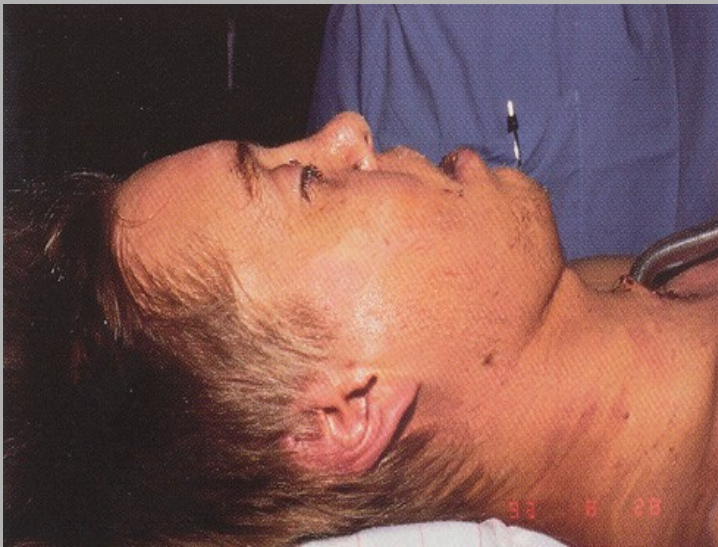
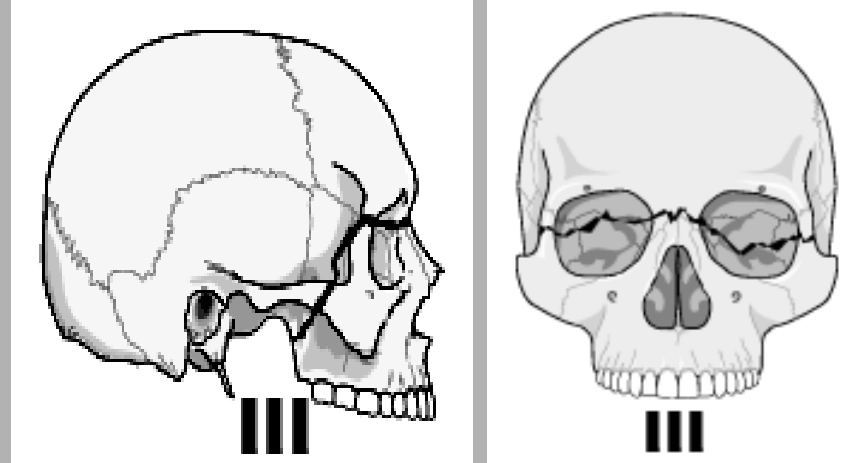


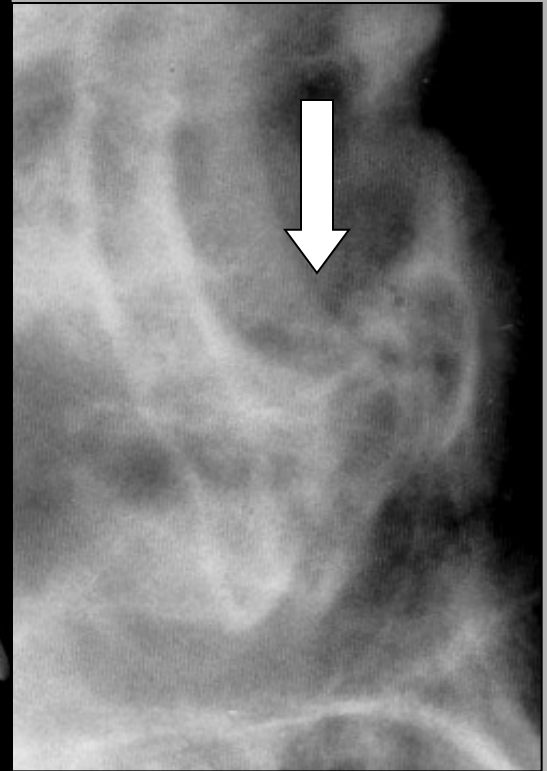
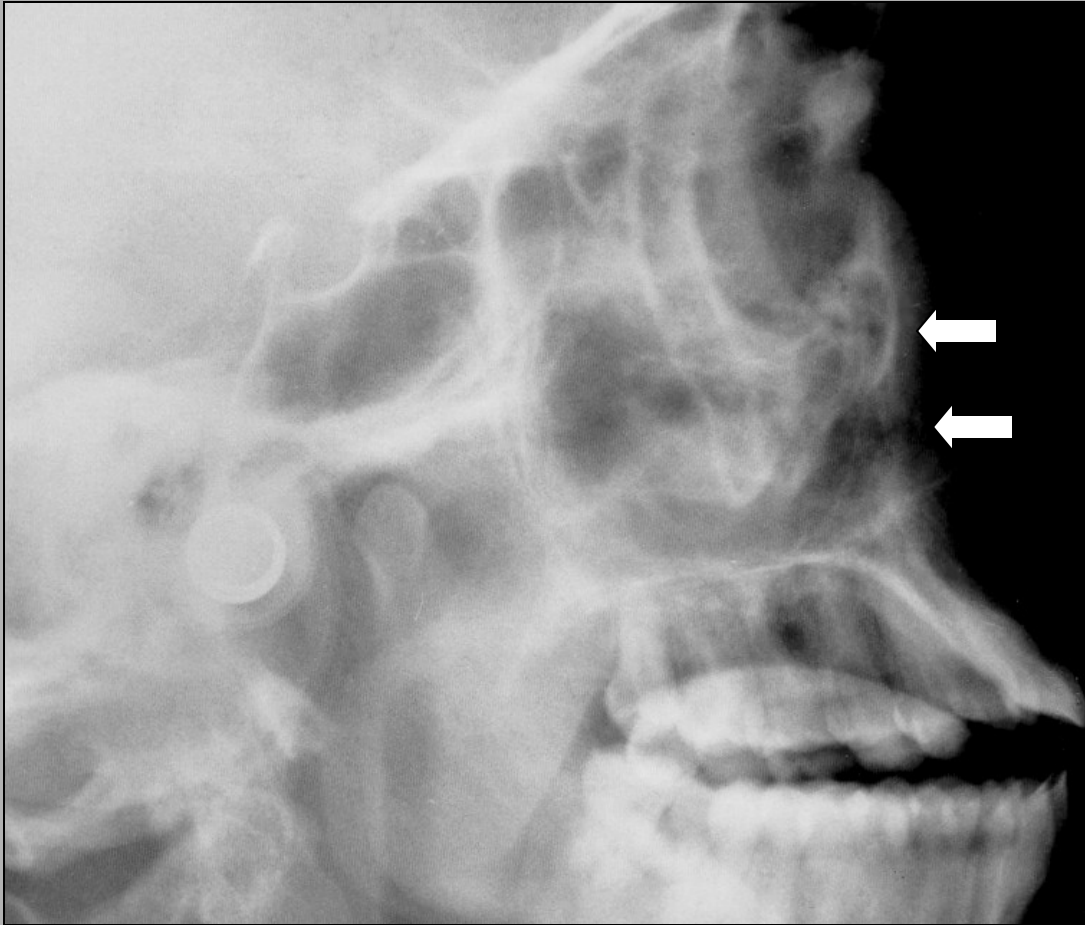
F
r
a
k
t
u
r
y
m
a
x
i
l
l
y



LeFort III

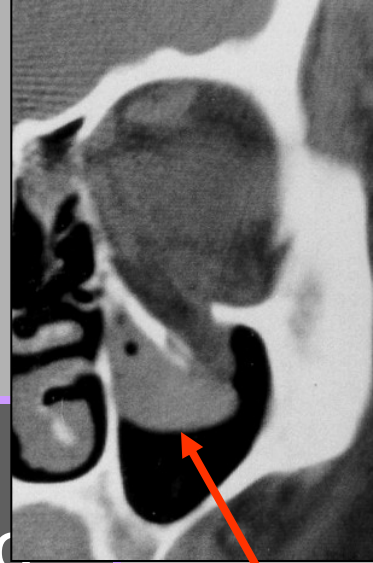
- fractures (transverse)
- known as craniofacial dissociation
- involve the zygomatic arch
- start at the nasofrontal and frontomaxillary sutures
- extend posteriorly along the medial wall of the orbit through the nasolacrimal groove and ethmoid bones.

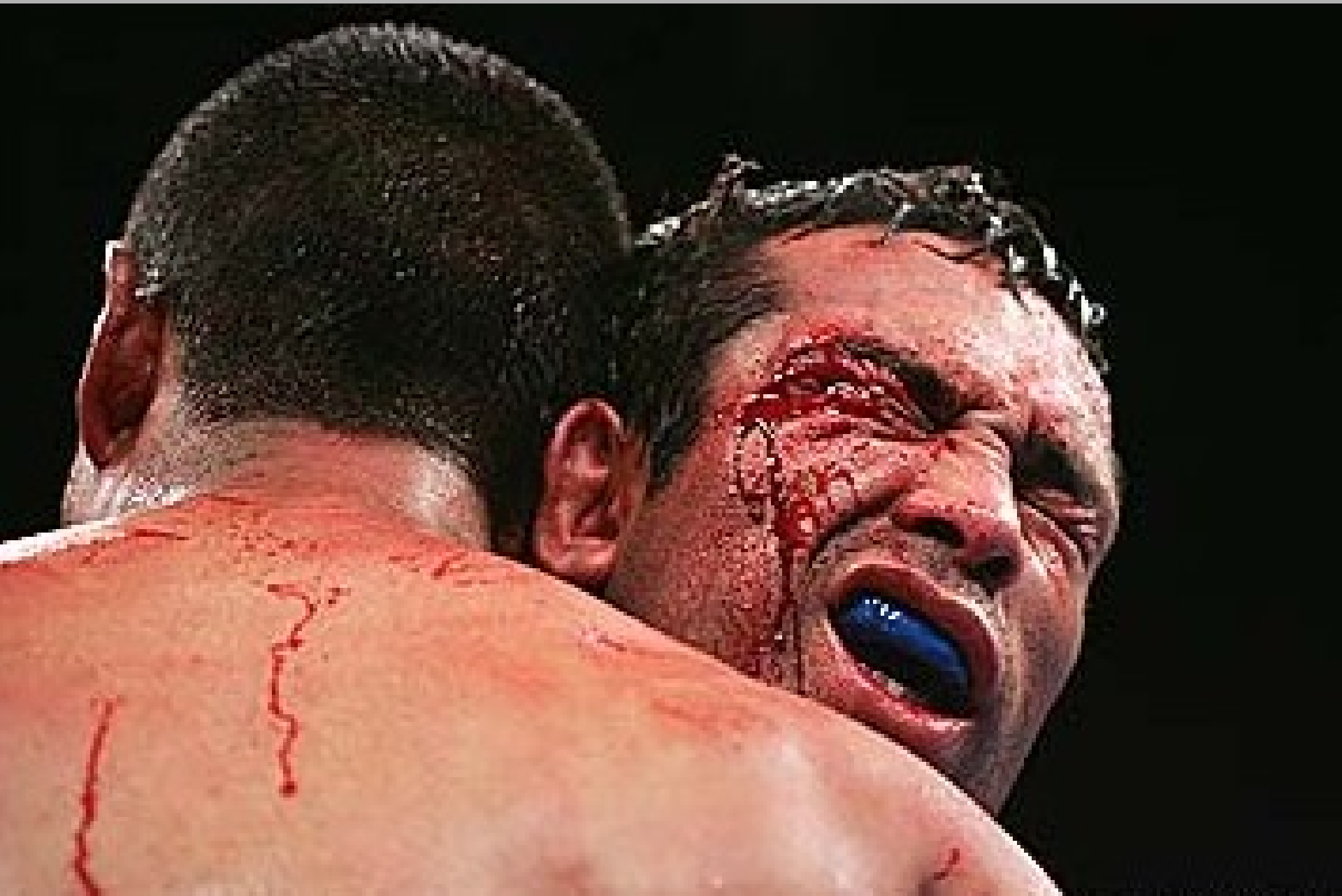



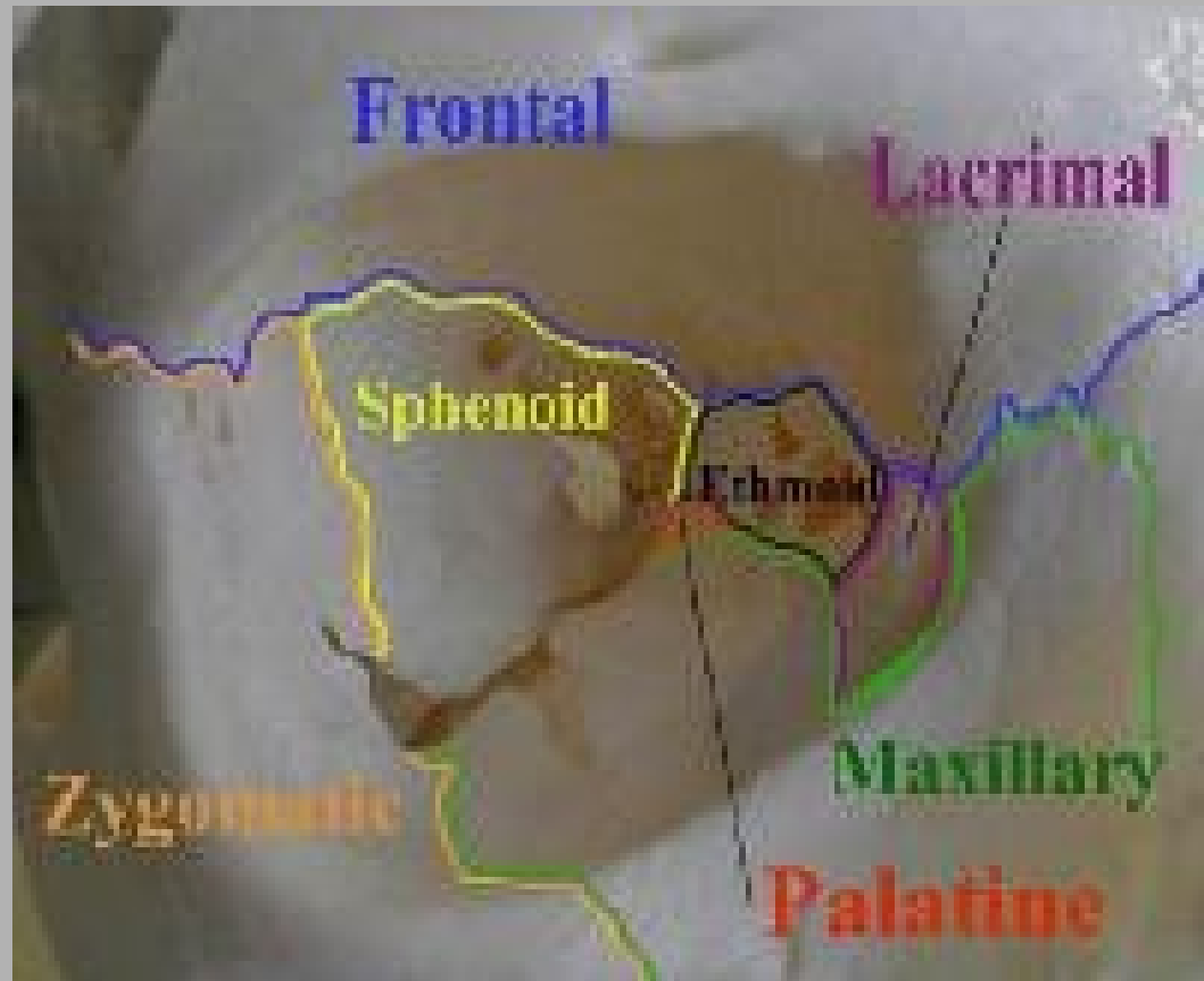„Blow-out“ fraktura

- Síla se přenáší přes tenké dno orbity, kde dochází k fraktuře v blízkosti infraorbitálního kanálu.
- Měkké tkáně přesahují okraj orbity.
- Afekce maxilárního sinu.
- Dislokace dna orbity.
- Polypoidní denzita při horním okraji maxil. sinu při herniaci obsahu orbity.
- Parestezie tváře.

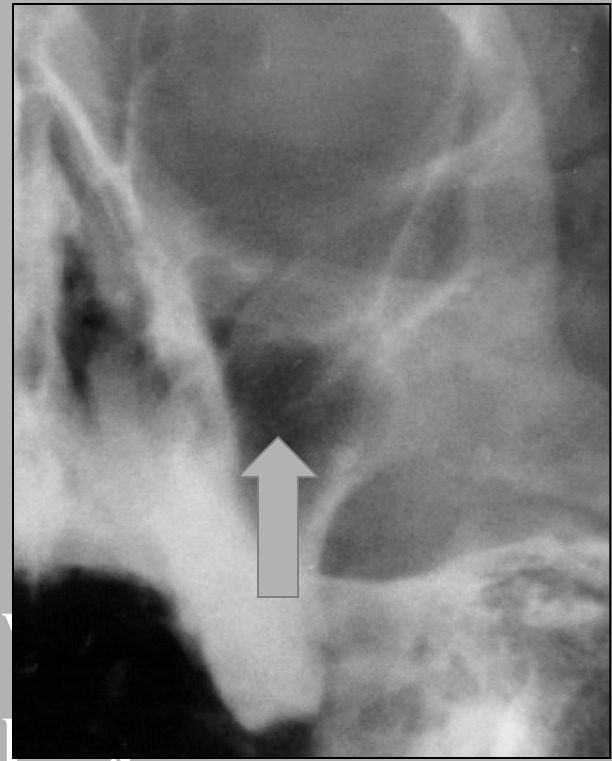
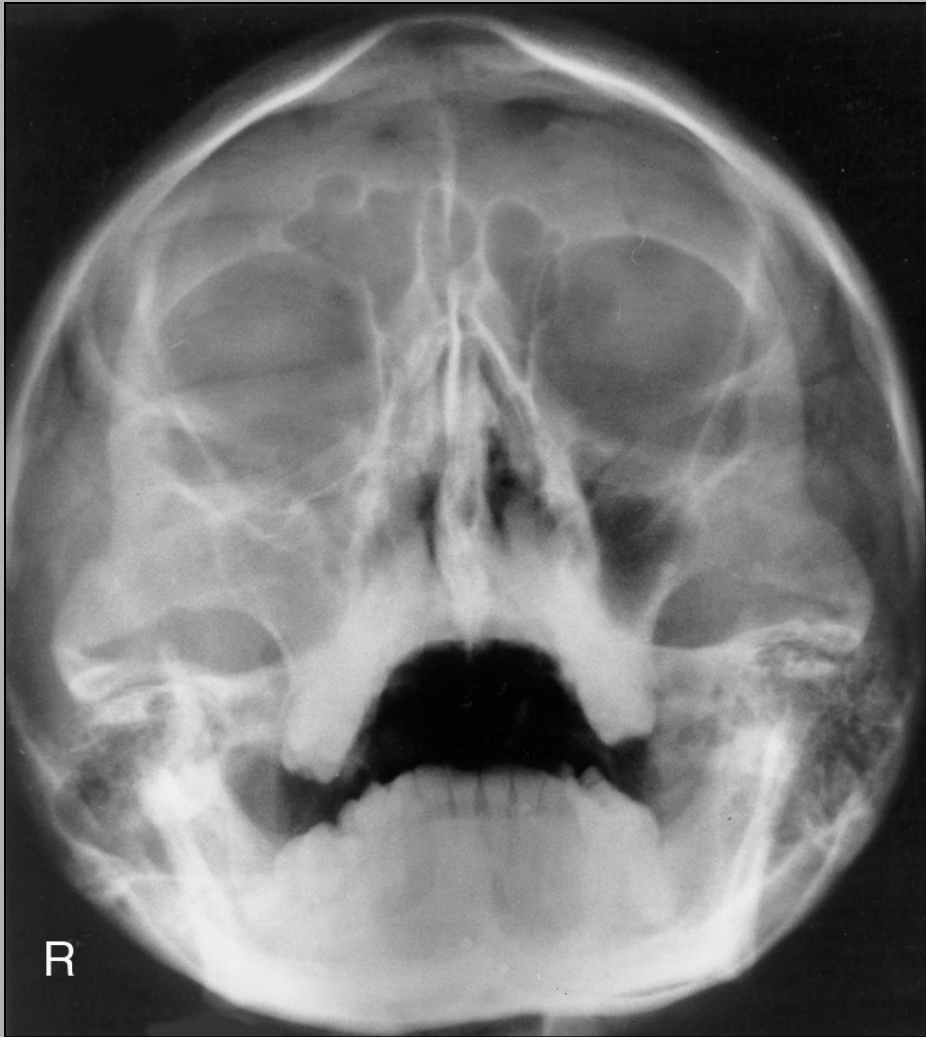

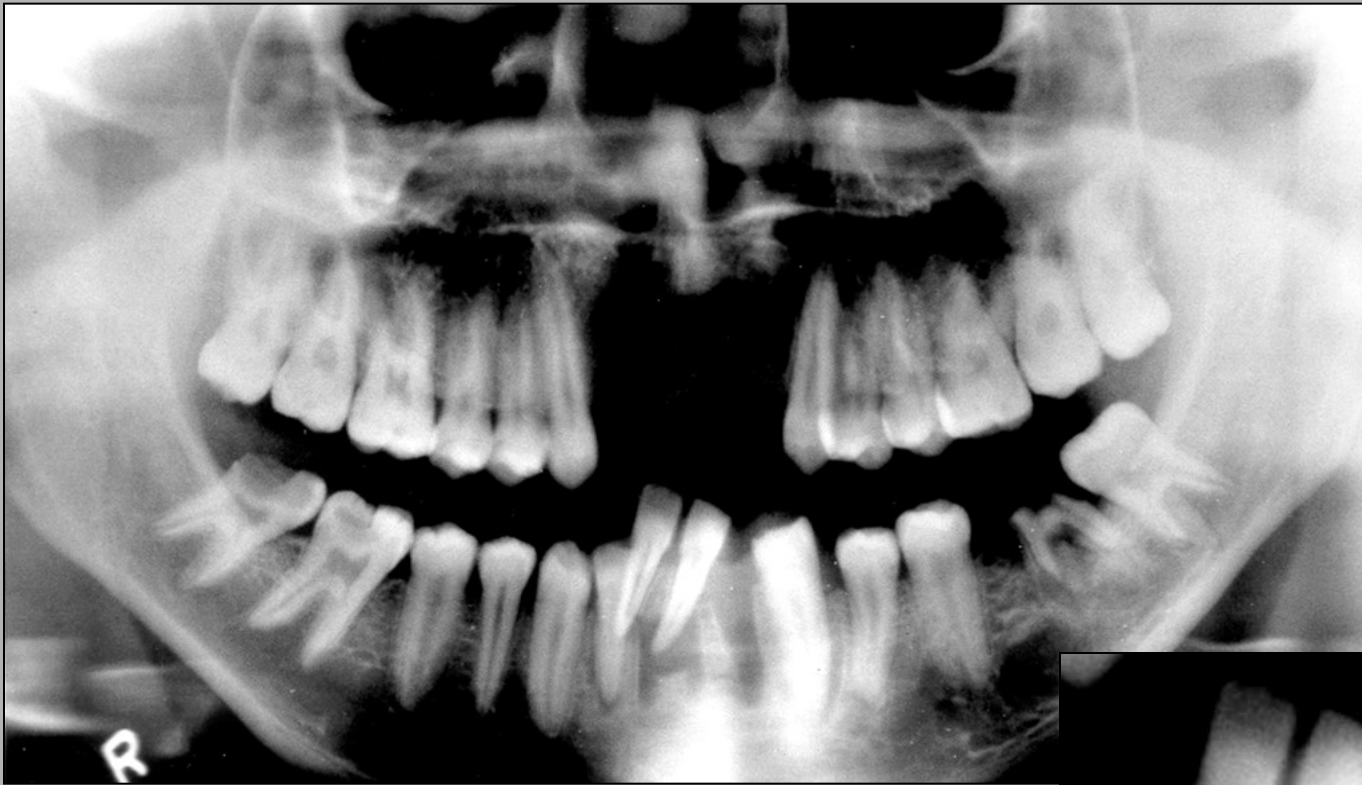


Orbita

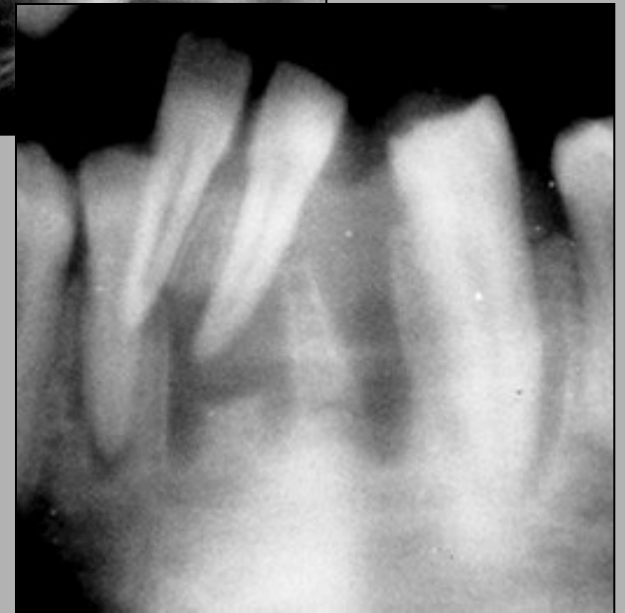

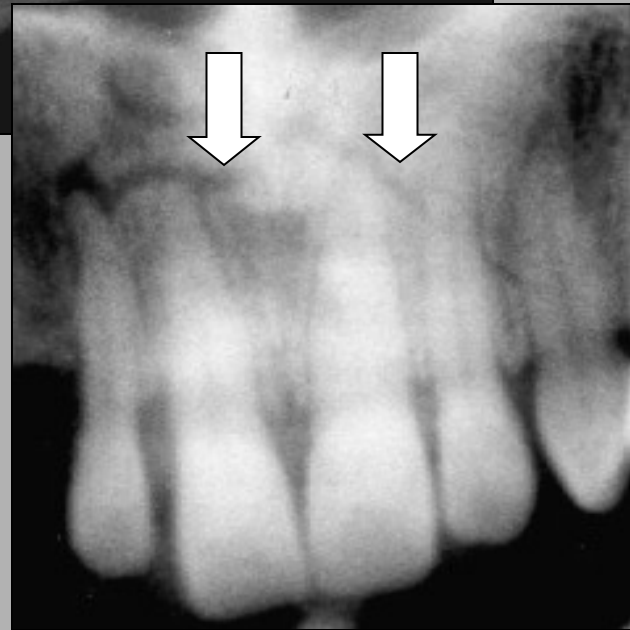
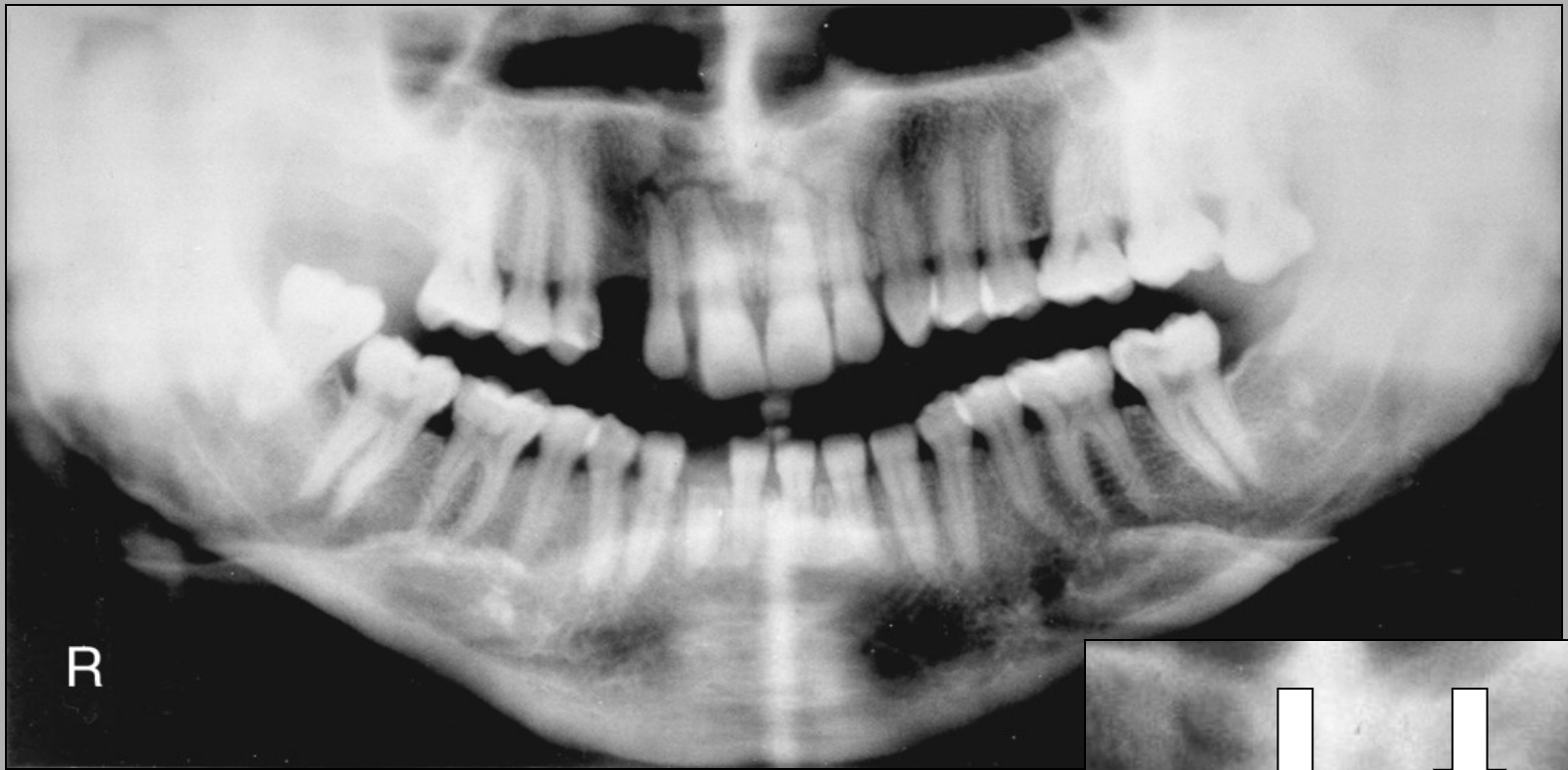
„Blow-out“ fract.





Subluxation.





Alveolar fract.