

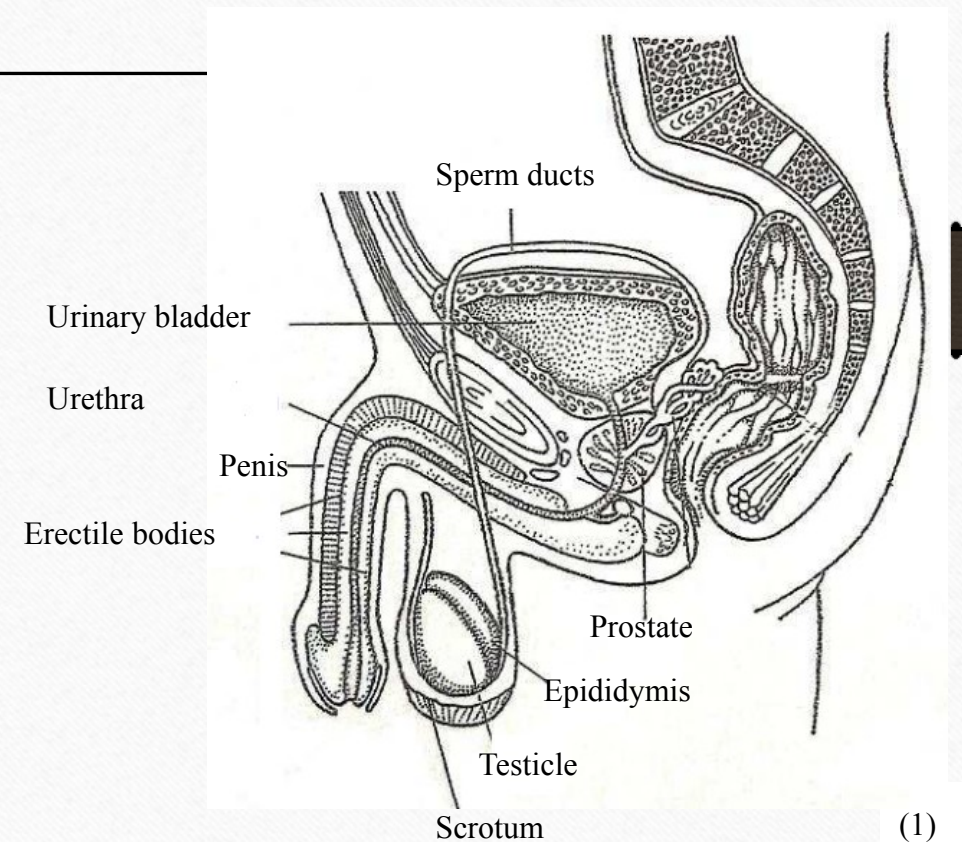
Oncological disease of the testicles

Teaching lesson 6

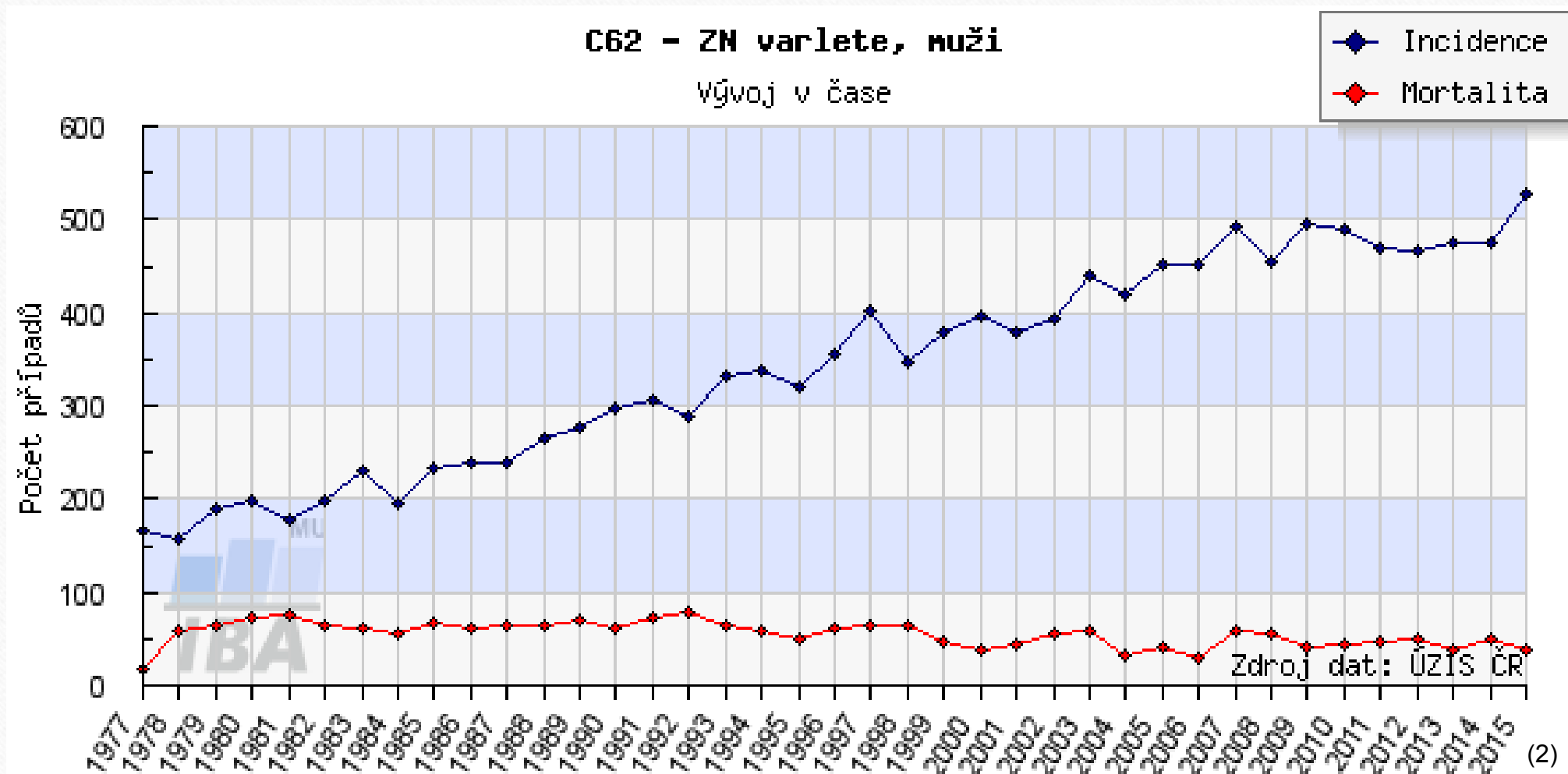
Written by: Zdeňka Smejkalová, Jitka Slaná Reissmannová

Testicular cancer

- Testicles = testes
- Part of internal male genitals
- Egg-shaped pair organs
- The testicles are located in the scrotum
- Main functions
 - Production of germ cells – sperm cells
 - Production of sex hormone – testosterone



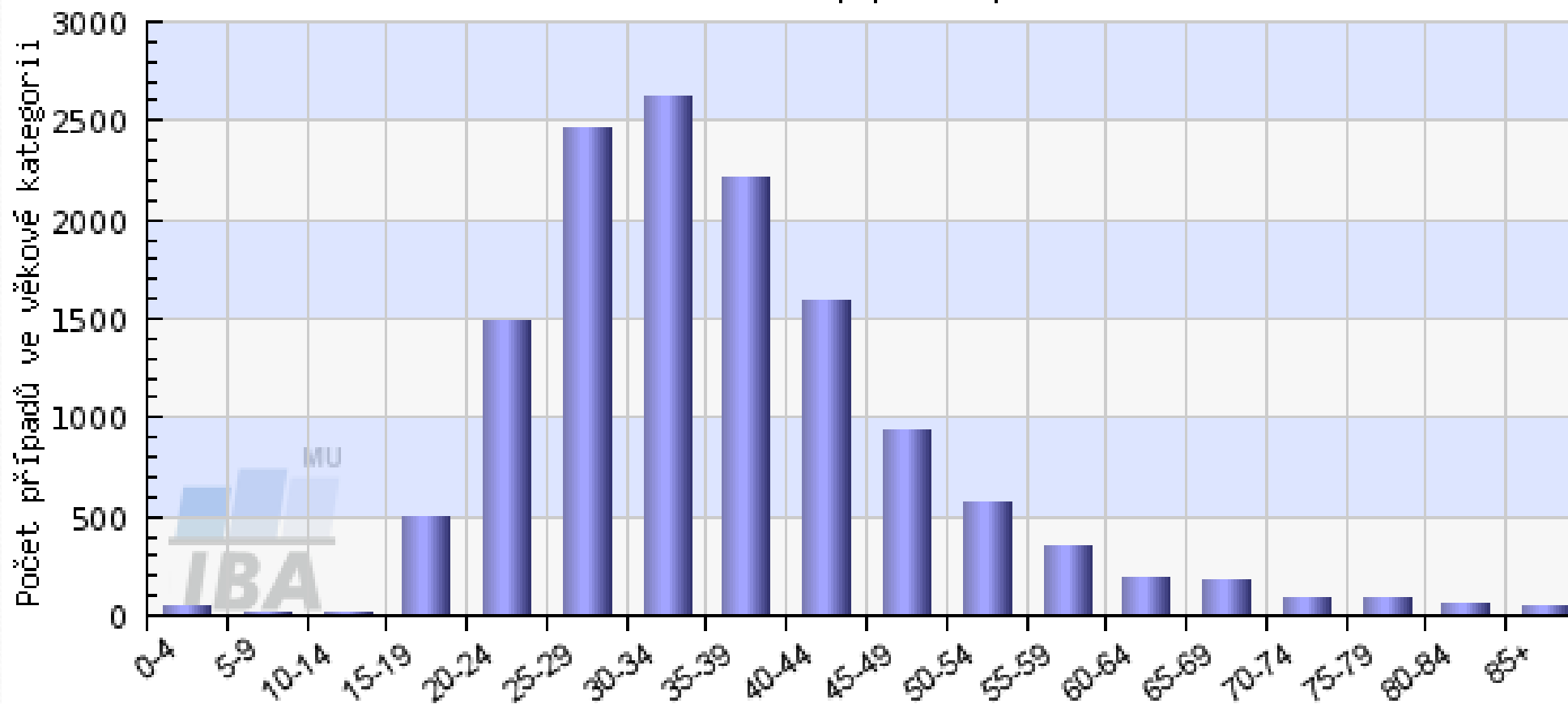
Occurrence of testicular cancer



Testicular cancer is one of the most frequent neoplastic diseases in men aged 15-35 years!

C62 - ZN varlete - Incidence, muži

věková struktura pacientů



Risk factors

- Cryptorchidism = undescended testicle
 - The testicle is withheld in the inguinal canal or the abdominal cavity.
 - If not descended within 6 months after birth, surgical treatment must be undergone.
 - Treatment must take place within 18 months.
- Inheritance

Symptoms

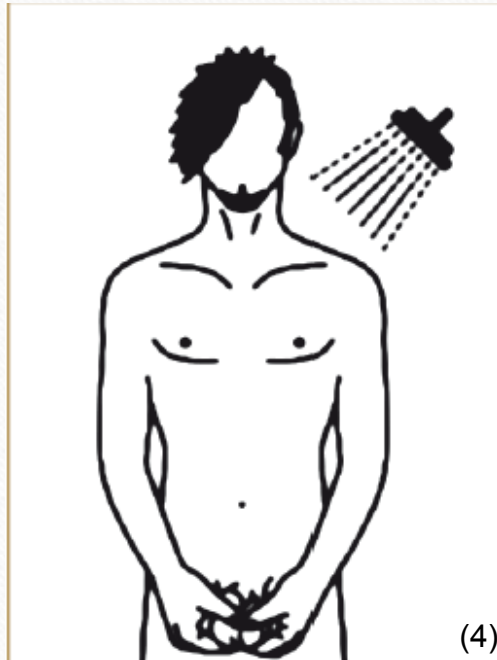
- Irregularity, palpable lump, bumps on the testicle
 - Changes in size
 - Stiff or hard testicle
 - Pain in the testicle, groin or lower abdomen
 - Enlargement and swelling of the mammary glands
 - Fatigue, lack of appetite, weight loss
- } Later stage of disease

In case of any deviations from normal state, the physician must be consulted immediately!

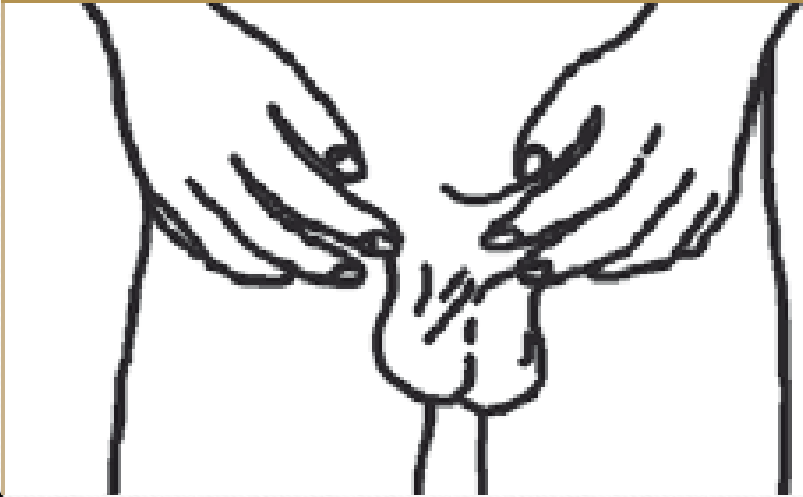Prevention

- Primary prevention
 - Observing general principles of prevention of neoplastic diseases
- Secondary prevention
 - **Self-examination of testicles**

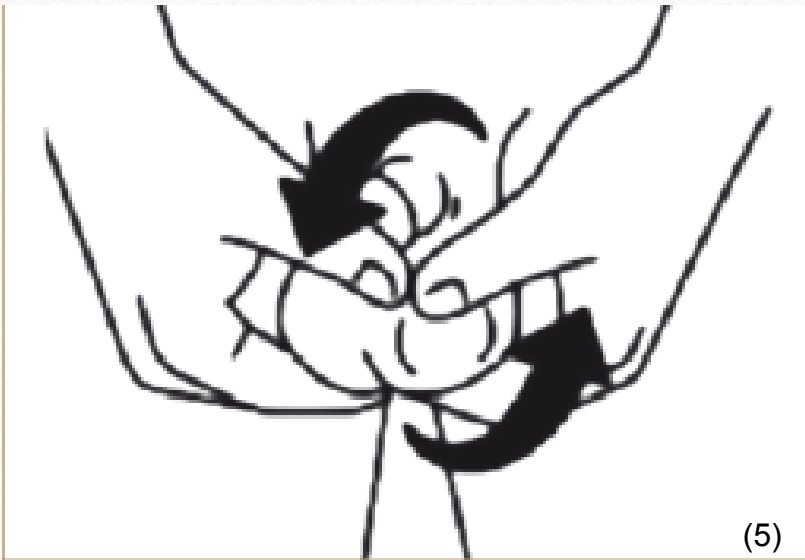Self-examination of testicles



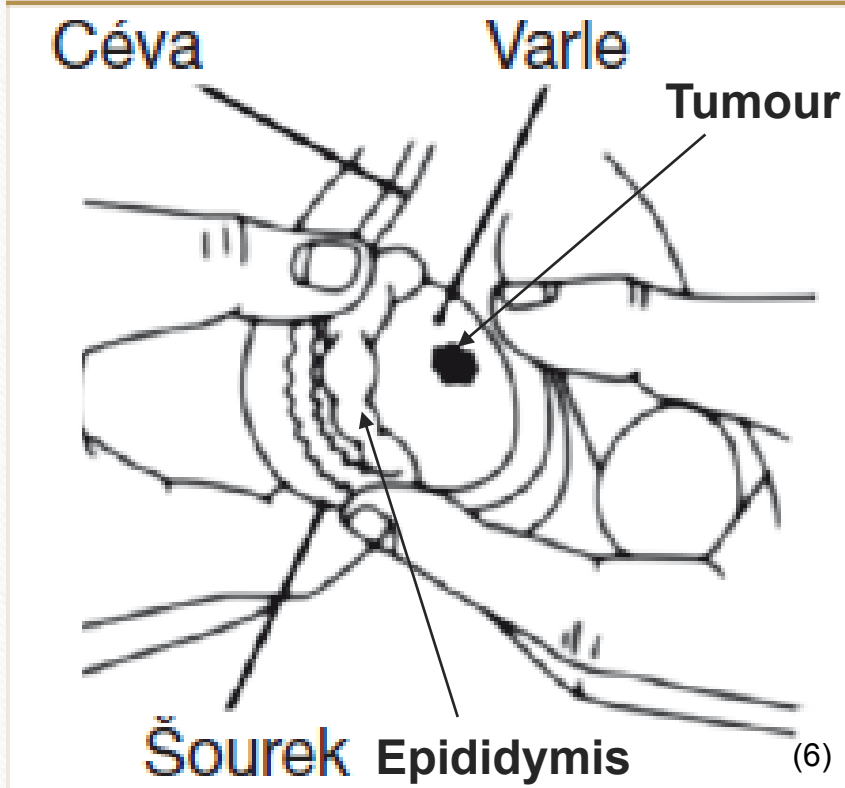
- To be carried out regularly once a month.
- Should be performed after a warm bath or shower, palpation is easier and pain-free.



- First of all, visual examination is performed.
- Any changes in the scrotum skin are identified in the mirror.
- The skin should not be tight, reddish or darker compared with the previous examination.
- Both size and volume must be checked.



- Each testicle is palpated separately.
- The testicle should be grasped by both hands – index fingers and middle fingers should be positioned under the testicle and the thumbs on the front side.
- The testicle is then gently turned between the fingers.



- It is important not to confuse a tumour and the epididymis.
- The epididymis is adjacent to the rear edge of the testicle.
- The same procedure is applied for the other testicle.
- **TASK:** On the picture identify the epididymis and the shape that could be a tumour.

References

- Co jsou nádory varlat. *Maskoule.cz* [online]. c2010 [cit. 2018-05-06]. Retrieved from: <http://www.maskoule.cz/co-jsou-nadory-varlat/>
- KLENER, Pavel. *Klinická onkologie*. Praha: Galen, 2002. ISBN 80-7262-151-3.
- PYCHOVÁ, Marcela, Jan TRACHTA a Luboš ZEMAN. Nesestouplé varle. *Česká urologická společnost* [online]. 7. 4. 2015 [cit. 2018-05-06]. Retrieved from: <http://www.cus.cz/pro-pacienty/detska-urologie-2/nesestouple-varle/>

Figures:

- (1): *Rozmnožovací soustava* [online]. 2018 [cit. 2018-06-10]. Retrieved from: <http://docplayer.cz/6531963-Centralni-nervova-soustava-nervova-soustava-micha-mozek-centralni-nervovou-soustavu-tvori-a.html>
- (2), (3): *Novotvary 2015 ČR* [online]. Praha: Ústav zdravotnických informací a statistik ČR, 2015. [cit. 30/04/2018]. Retrieved from: <http://www.uzis.cz/publikace/novotvary-2015>
- (4), (5), (6): SMEJKALOVÁ, Zdeňka a Jitka SLANÁ REISSMANNOVÁ. *My se raka nebojíme aneb prevencí ke zdraví*. Brno: Masarykova univerzita, 2018. ISBN 978-80-210-9060-6.