

# Joints and Muscles Groups and Functions of Muscles

lecture and seminar from Human Morphology

5. 10. 2023

M. Chalupová

# JOINTS / ARTICULATIONS

- **arthros** = joint /*gr.*/ – arthrology
- junction of two or more bones
- the joints hold the bones together, allow movement and provide mechanical support

## 1) FUNCTIONAL CLASSIFICATION

- synarthrotic joints (synarthroses) – immovable, rigid joints (sutures of skull)
- amphiarthrotic joints (amphiarthroses) – slightly movable (intervertebral discs, ribs to sternum)
- diarthrotic joints (diarthroses) – freely movable

# JOINTS / ARTICULATIONS

## 2) STRUCTURAL CLASSIFICATION

- fibrous joints
  - ✓ hold bones together with fibrous connective tissue (sutures, tibia+fibula)
- cartilaginous joints
  - ✓ contain cartilage pads holding bone ends together (pubic symphysis, intervertebral joints)
- synovial joints
  - ✓ they are all diarthrotic, have articular cartilage covering the ends of the bones forming the joint
  - ✓ the joint is enclosed by a capsule of fibrous connective tissue and this is lined with a synovial membrane which secretes synovial fluid
  - ✓ there is a joint cavity and reinforcing ligaments that stabilize the joint

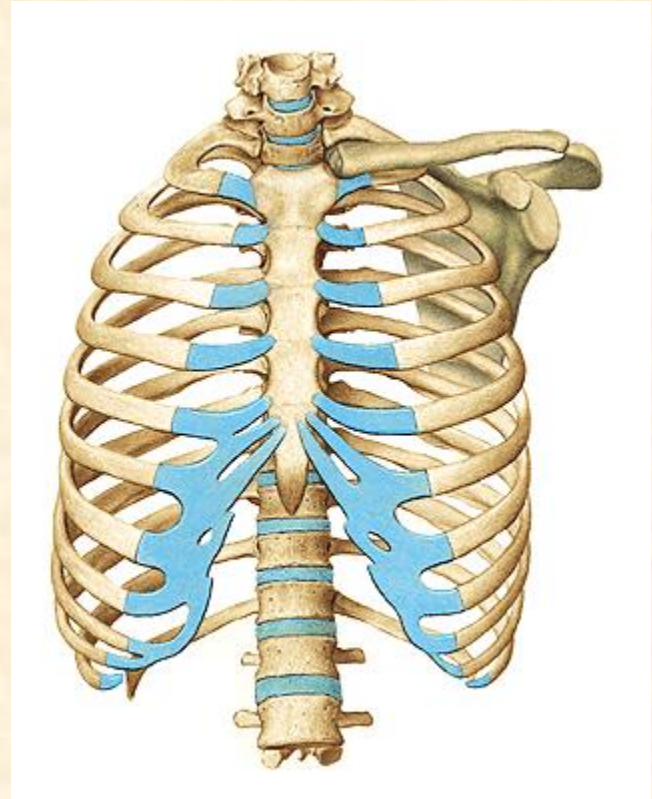
# SYNARTHROSIS

fibrous joint (skull suture)



# AMPHIARTHROSIS

cartilaginous joint (ribs+sternum)



# SYNOVIAL (DIARTHROTIC) JOINT

fibrous joint capsule

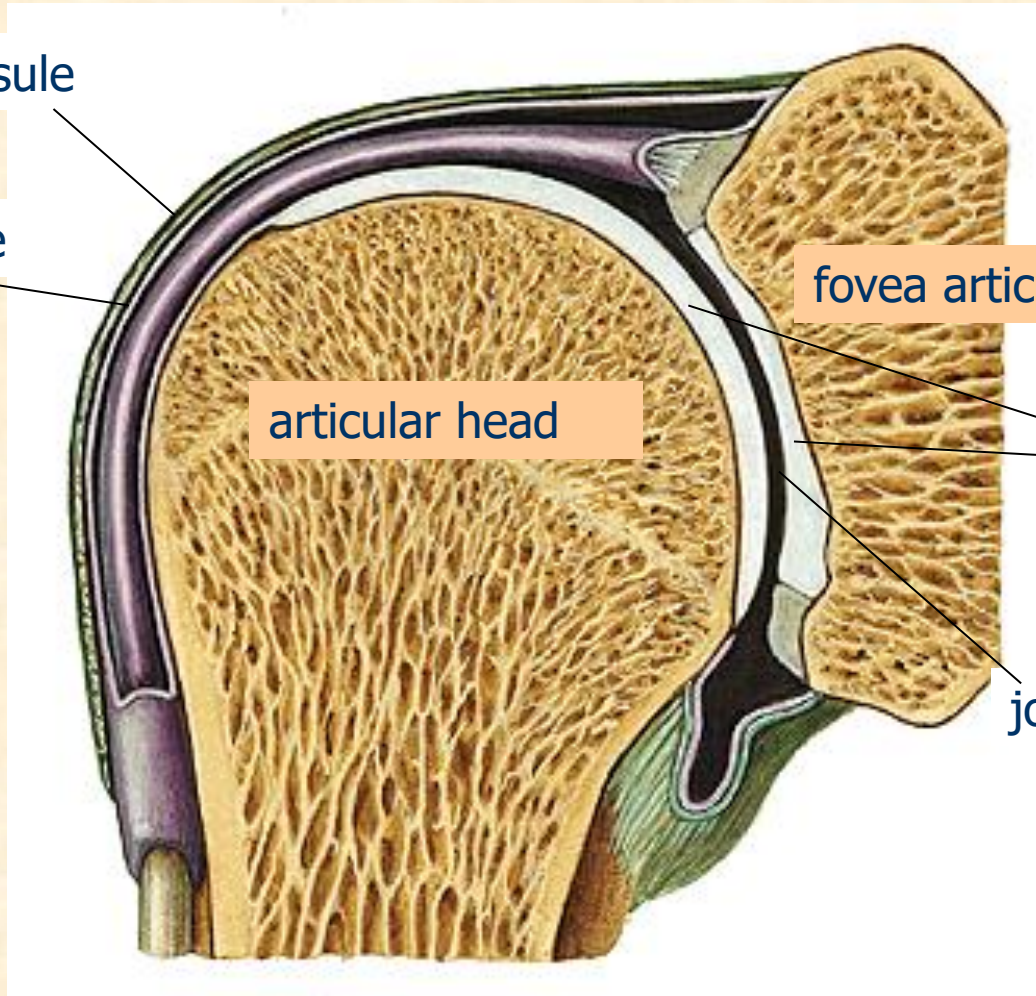
synovial membrane

fovea articularis

articular head

articular cartilage

joint cavity



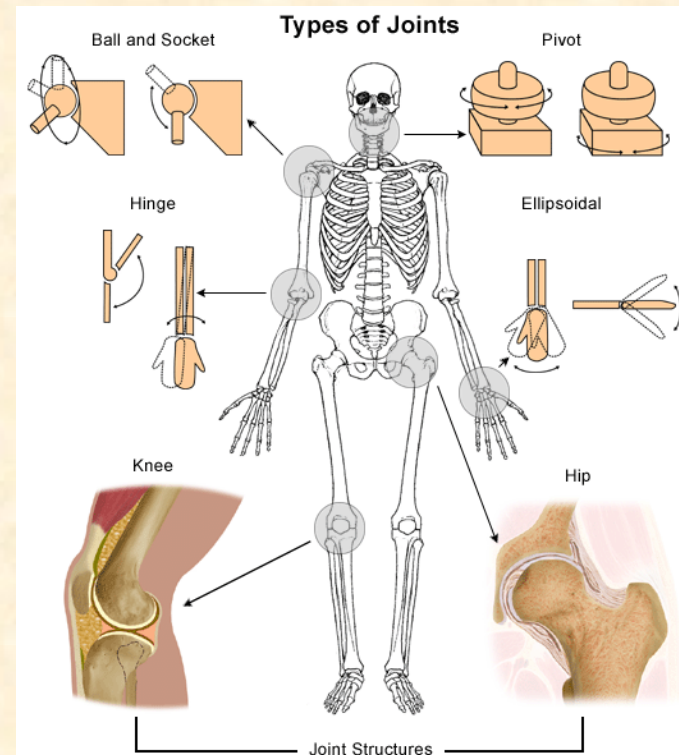
# JOINTS / ARTICULATIONS

## 3) NUMBER OF BONES INVOLVED

- simple joint – 2 articulation surfaces (shoulder joint)
- compound joint – 3 or more articulation surfaces (elbow joint)
- complex joint – 2 or more articulation surfaces + articular disc or meniscus (knee joint)

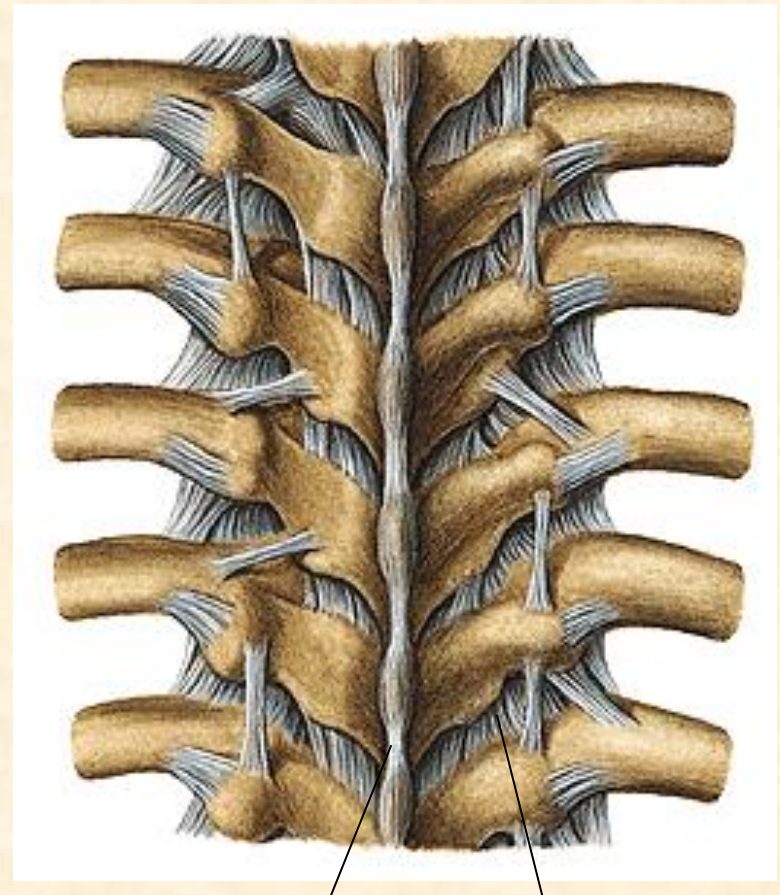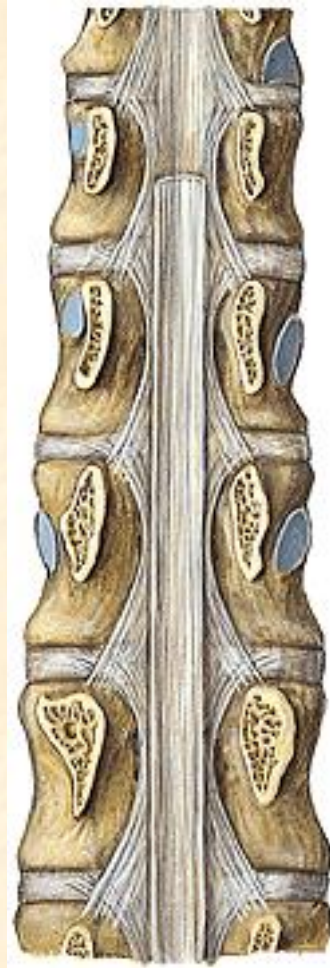
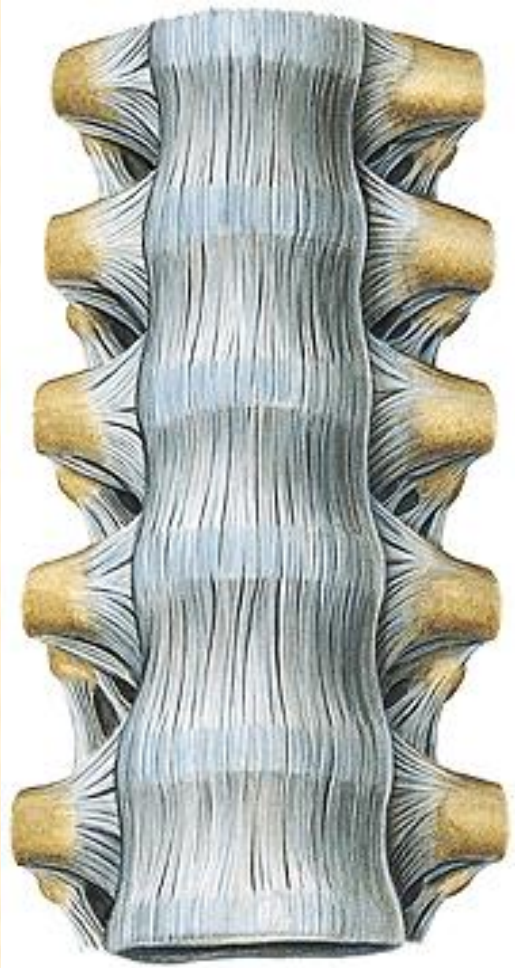
## 4) SHAPE OF JOINT FACES

- ball and socket joint – shoulder joint
- hinge joint – elbow joint
- condyloid joint – metacarpophalangeal j.
- saddle joint – carpometacarpal joint
- pivot joint – atlantoaxial joint
- plane joint – intervertebral joints
- ellipsoid joint – radiocarpal joint



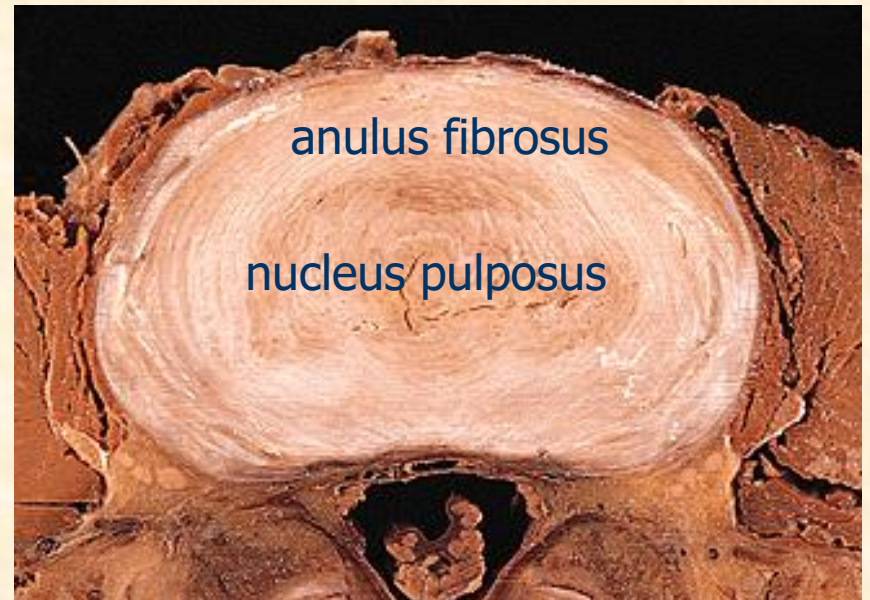
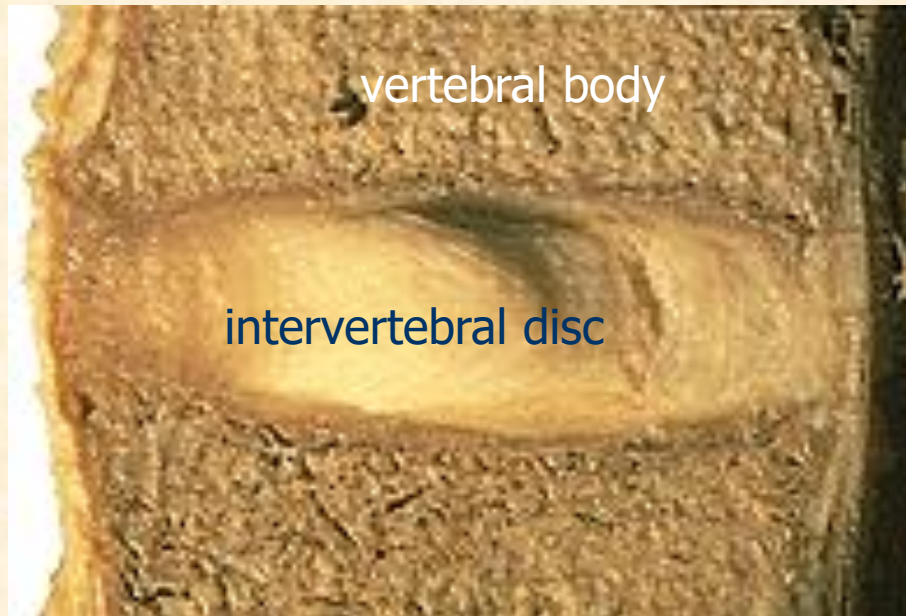# VERTEBRAL JUNCTIONS

longitudinal ligaments



short ligaments

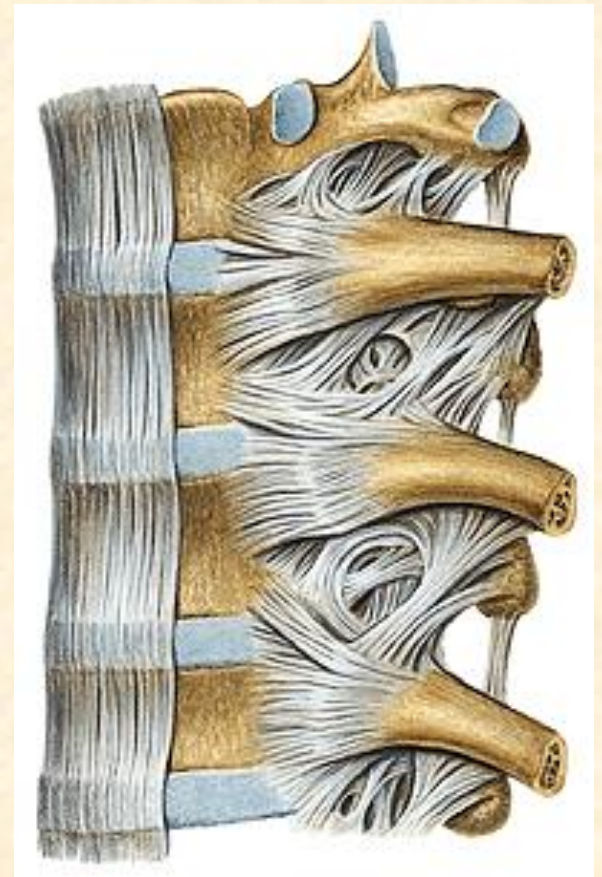
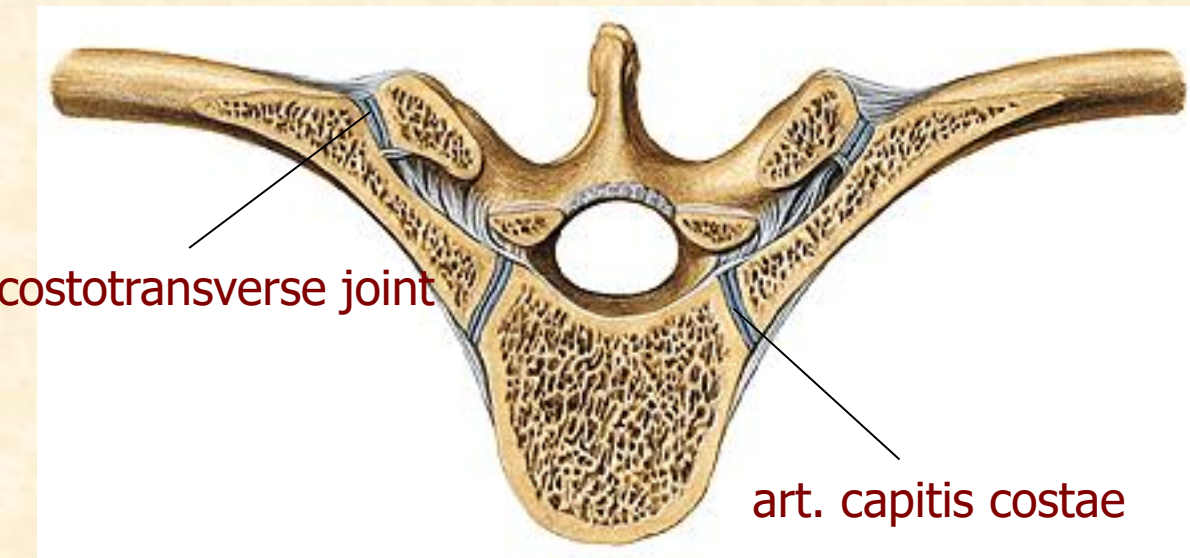
# INTERVERTEBRAL DISCS



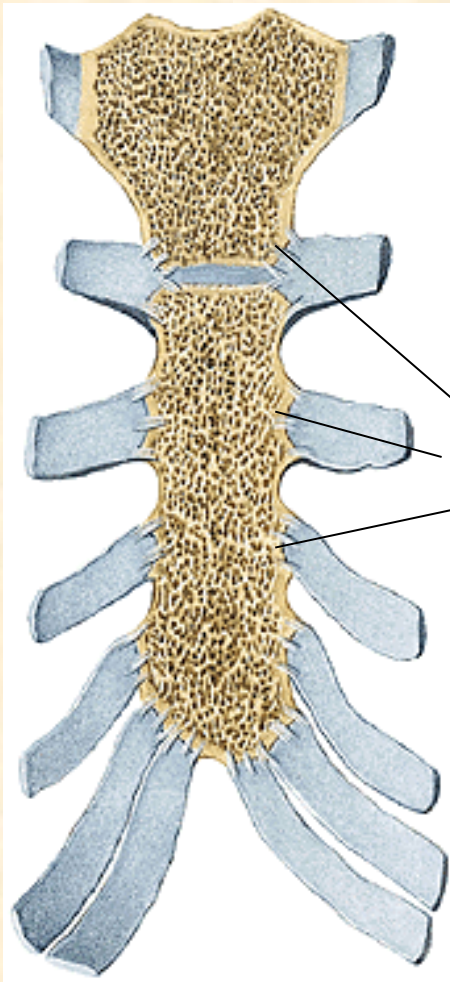


# THORAX JUNCTIONS

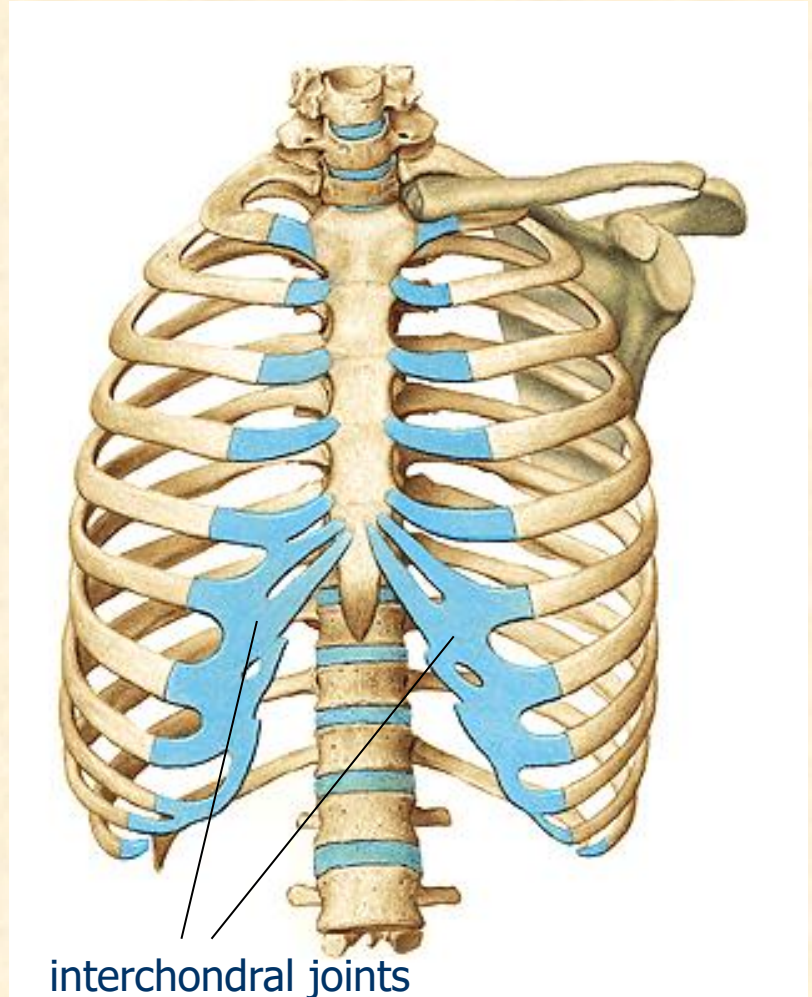
## costovertebral joints



# THORAX JUNCTIONS

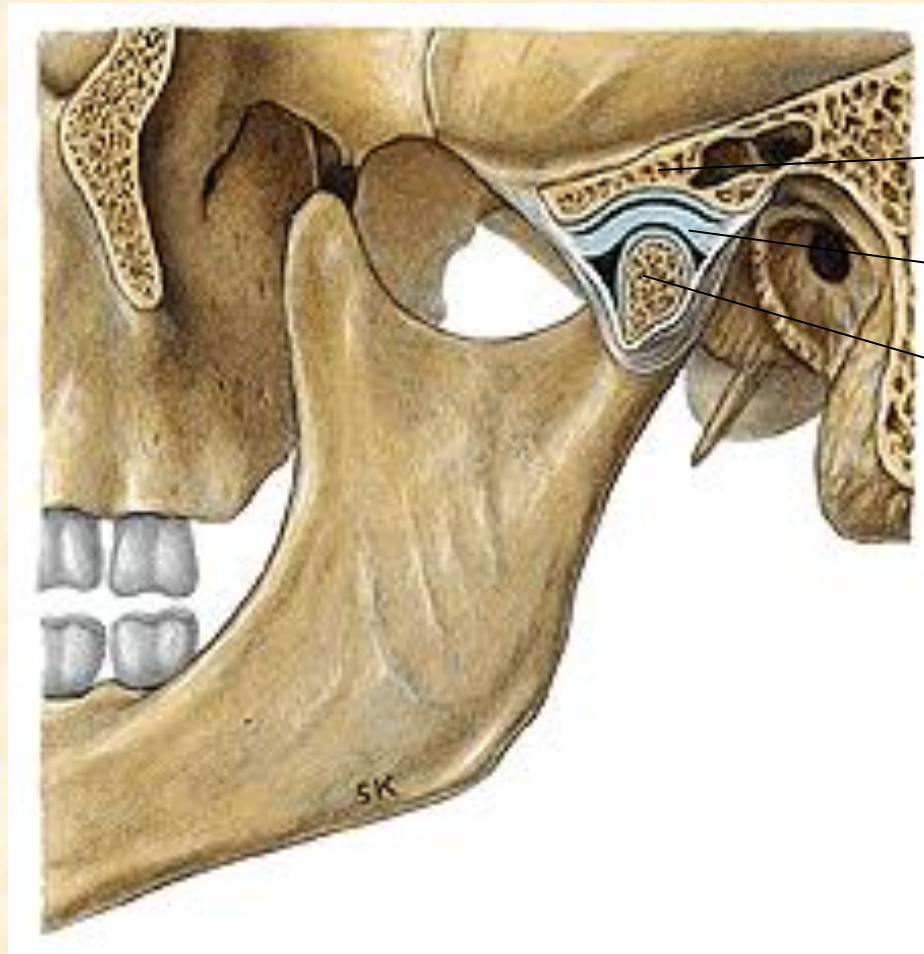


sternocostal joints



interchondral joints

# TEMPOROMANDIBULAR JOINT



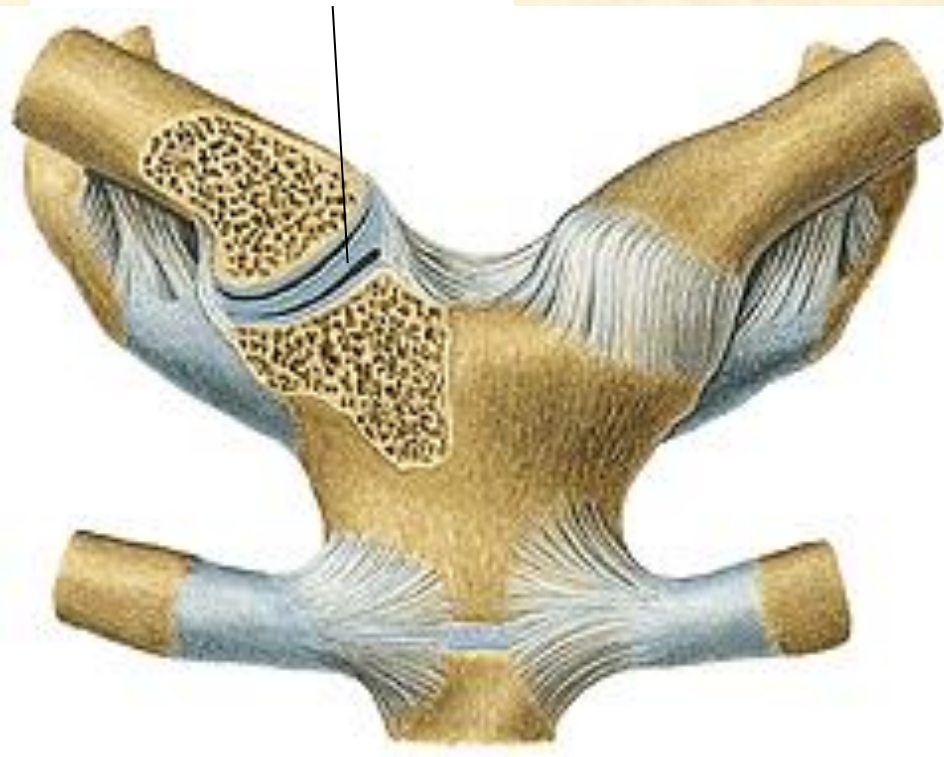
fossa of temporal bone

articular disc

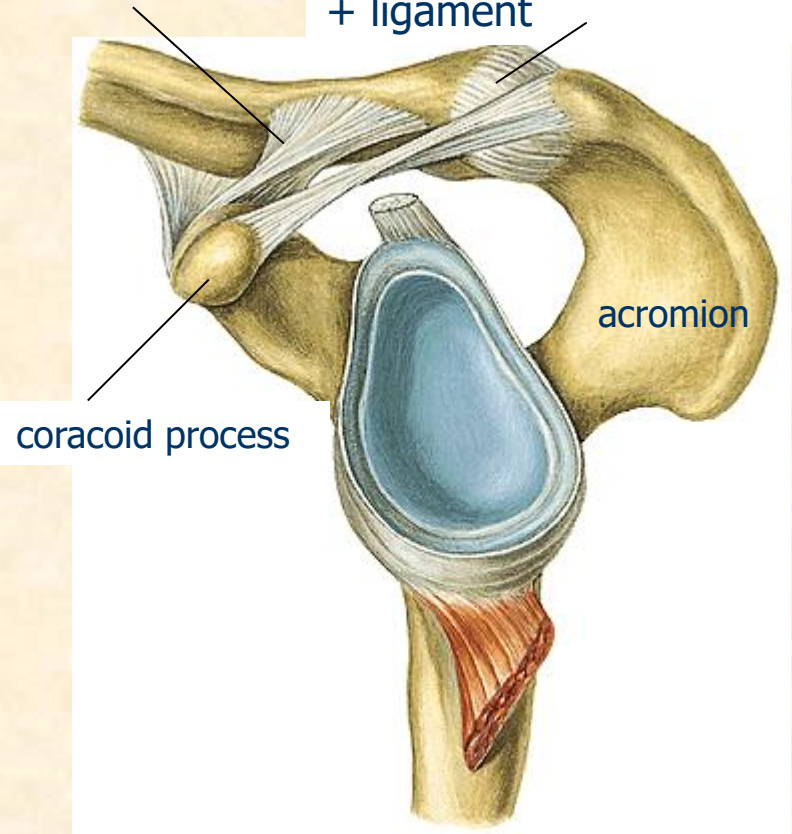
head of mandible

# PECTORAL GIRDLE JUNCTIONS

sternoclavicular joint



acromioclavicular joint  
+ ligament



# UPPER LIMB JUNCTIONS

1) SHOULDER JOINT

2) ELBOW JOINT

3) WRIST (CARPAL) JOINT

4) HAND JOINTS

# SHOULDER JOINT

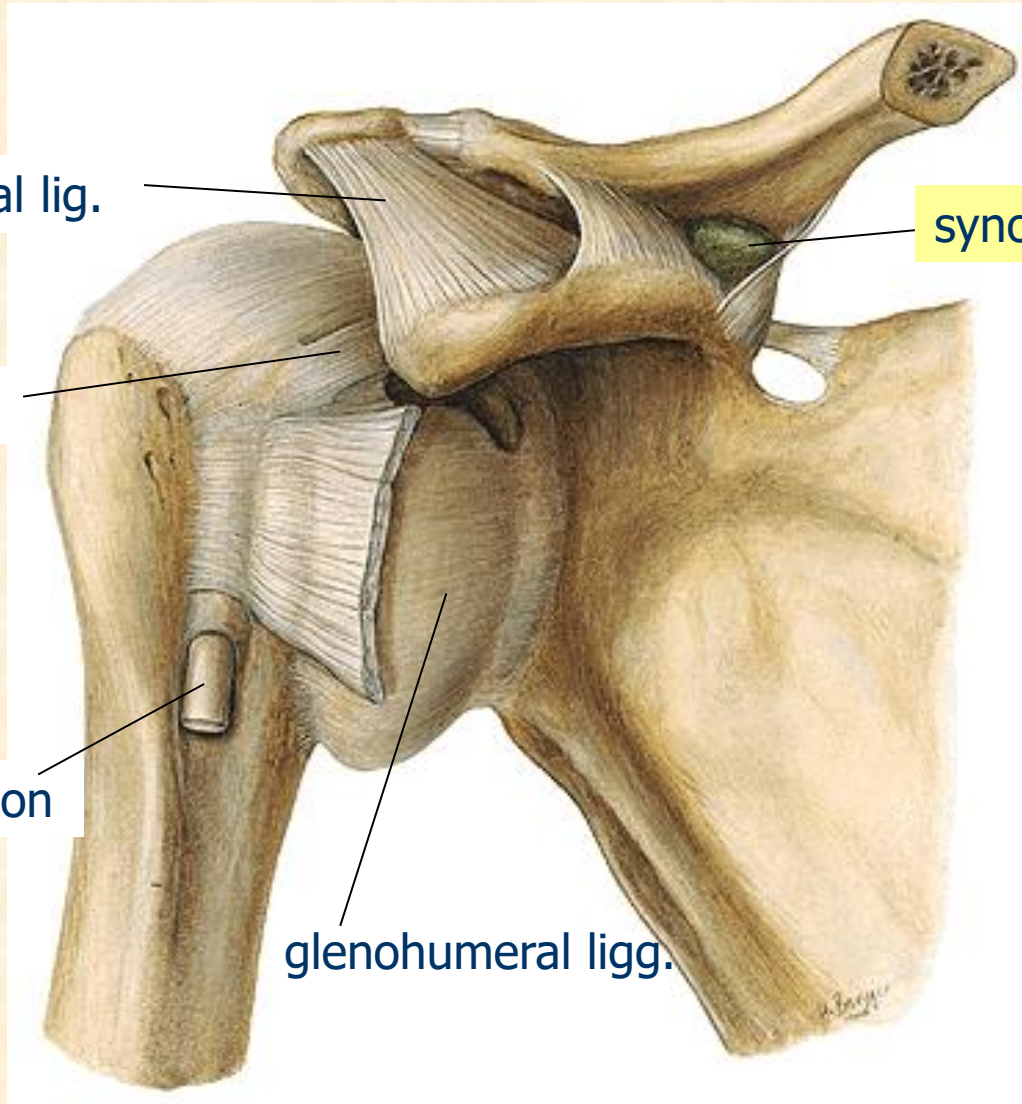
coracoacromial lig.

synovial bursa

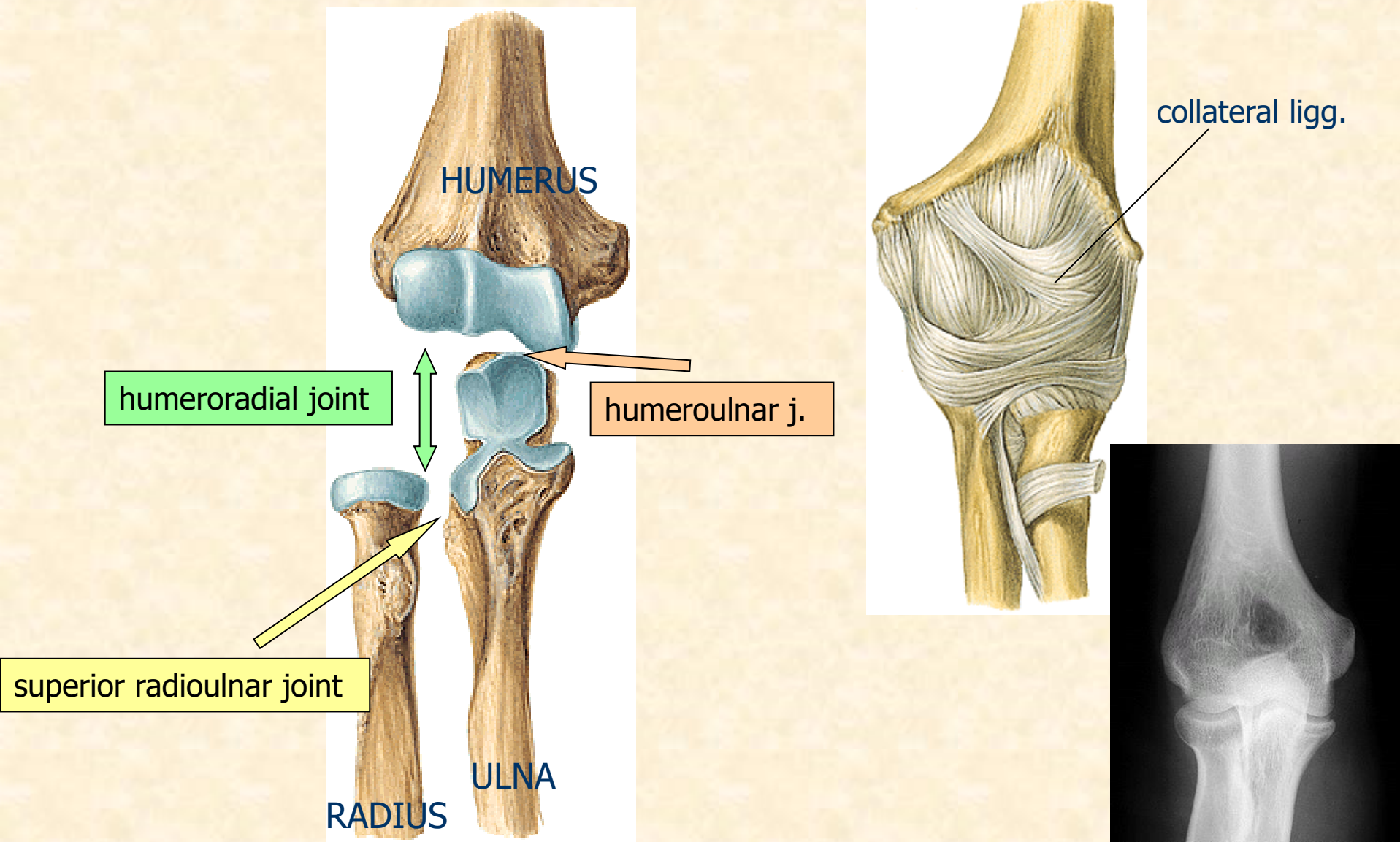
coracohumeral lig.

biceps muscle tendon

glenohumeral ligg.



# ELBOW JOINT



# WRIST/CARPAL JOINT

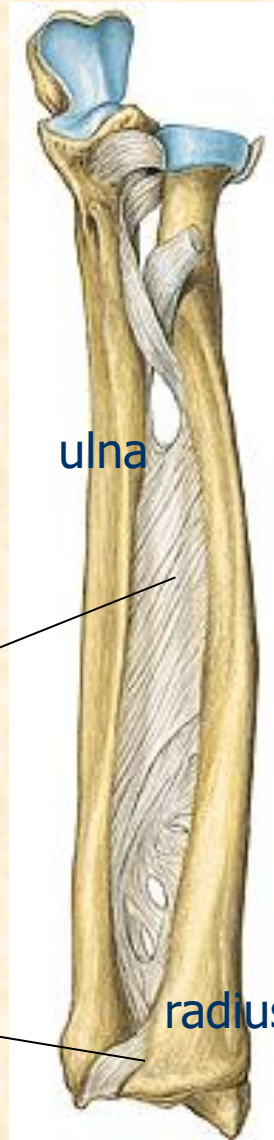
left side

interosseal membrane

ulna

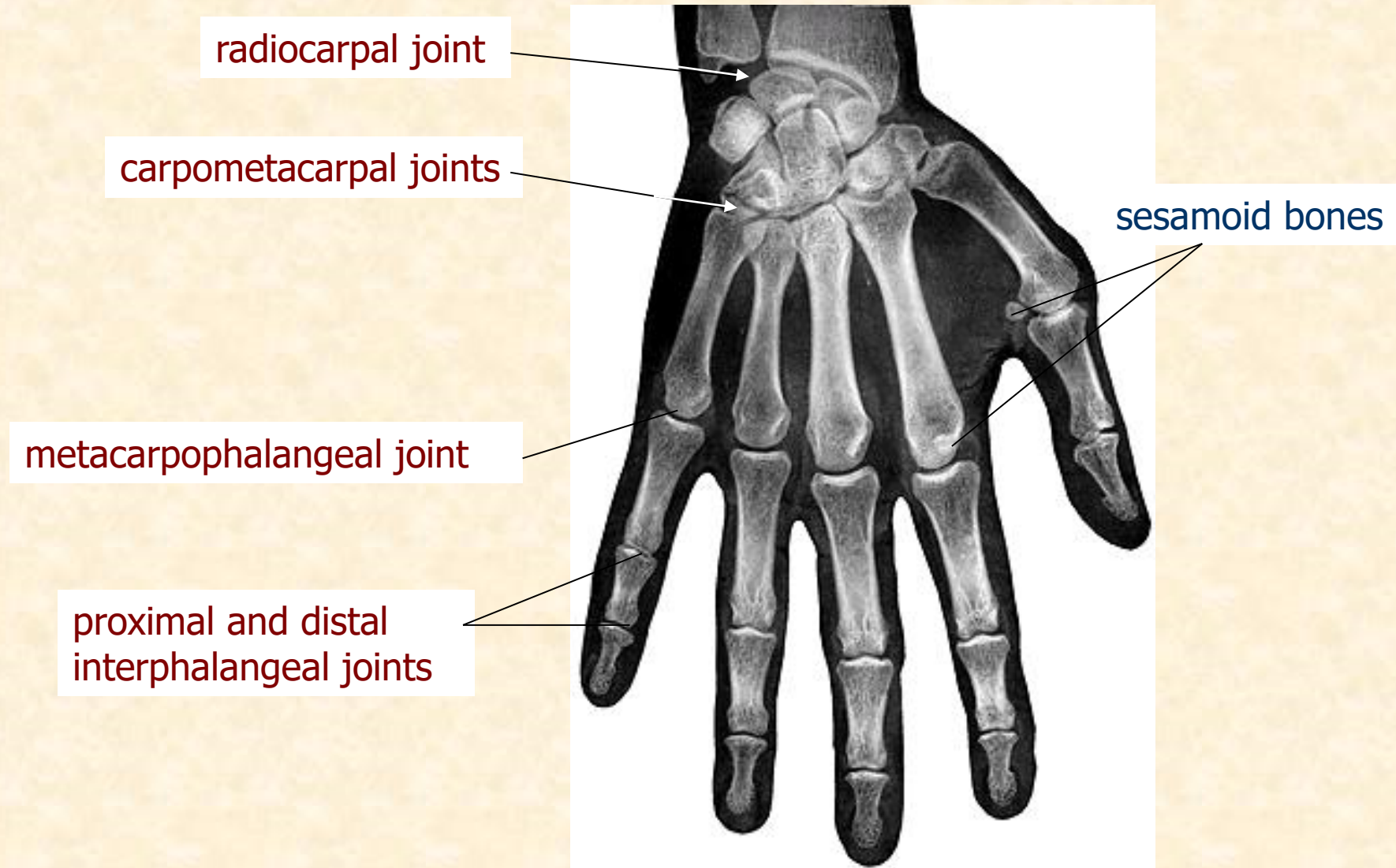
carpal joint

radius





# HAND JOINTS

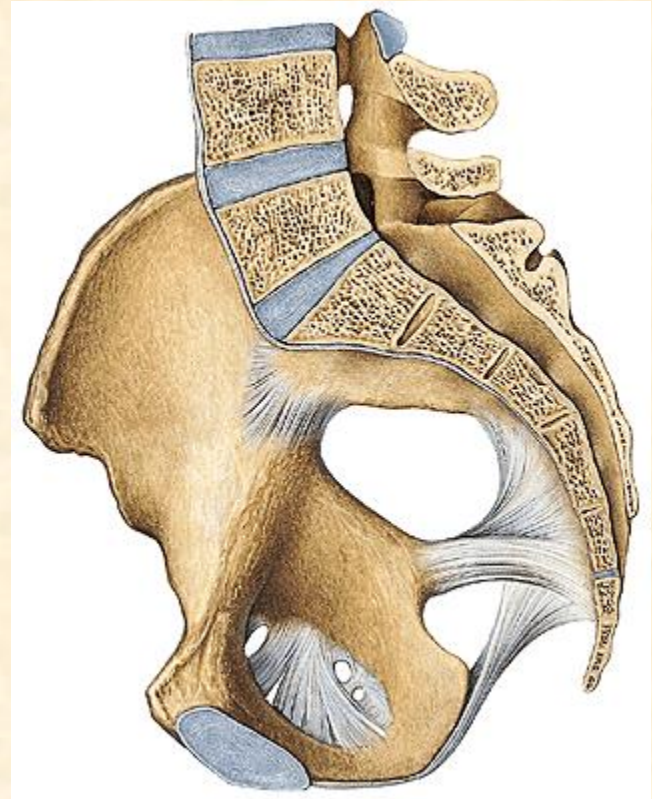
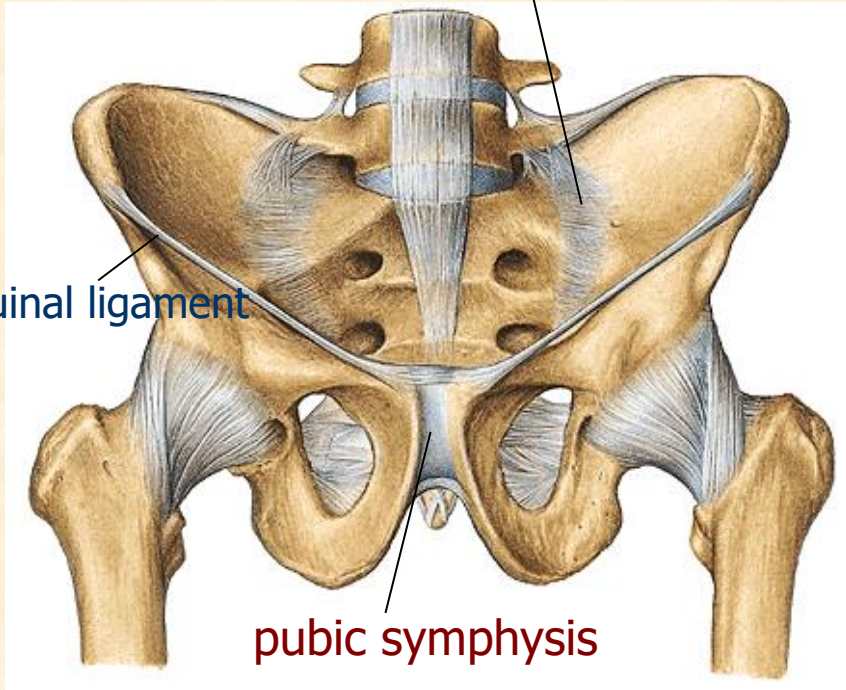


# PELVIC GIRDLE JUNCTIONS

sacroiliac joint

inguinal ligament

pubic symphysis



# LOWER LIMB JUNCTIONS

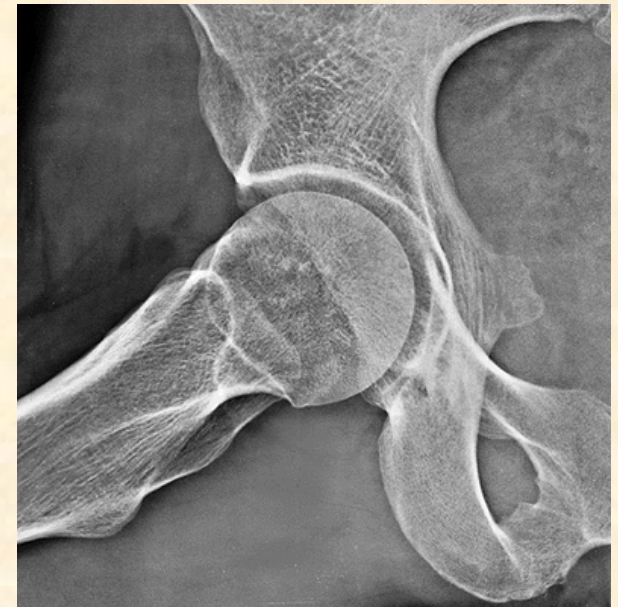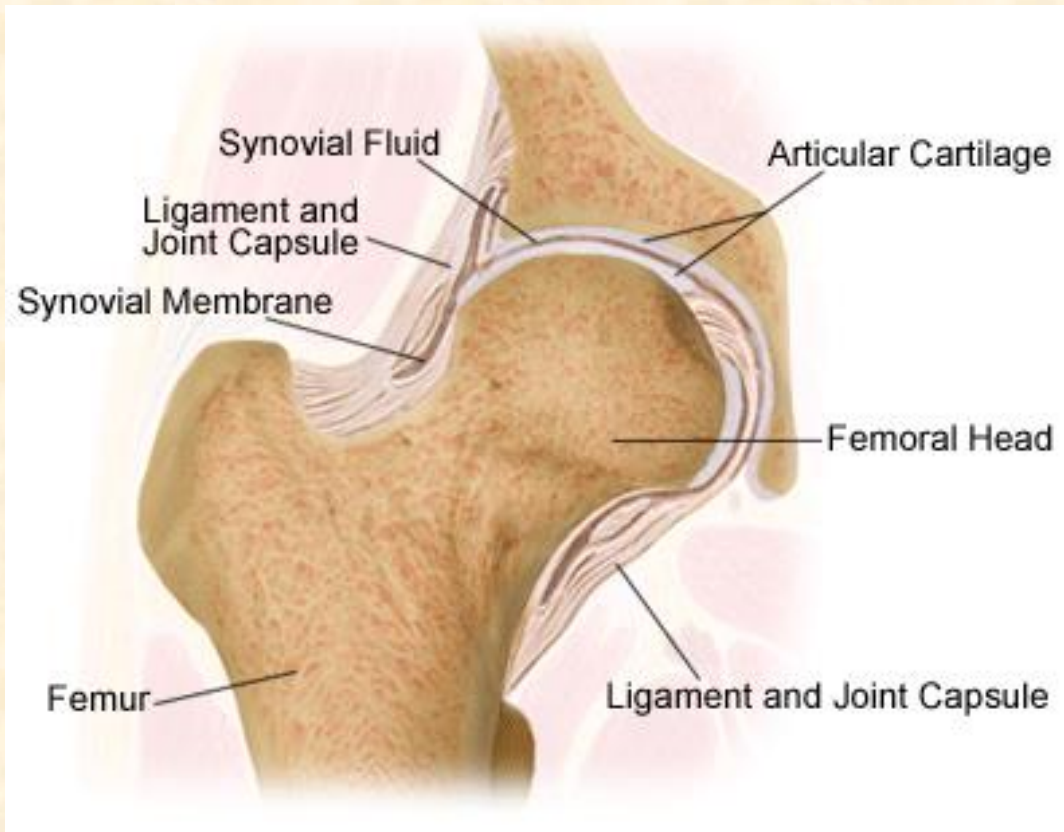
1) HIP JOINT

2) KNEE JOINT

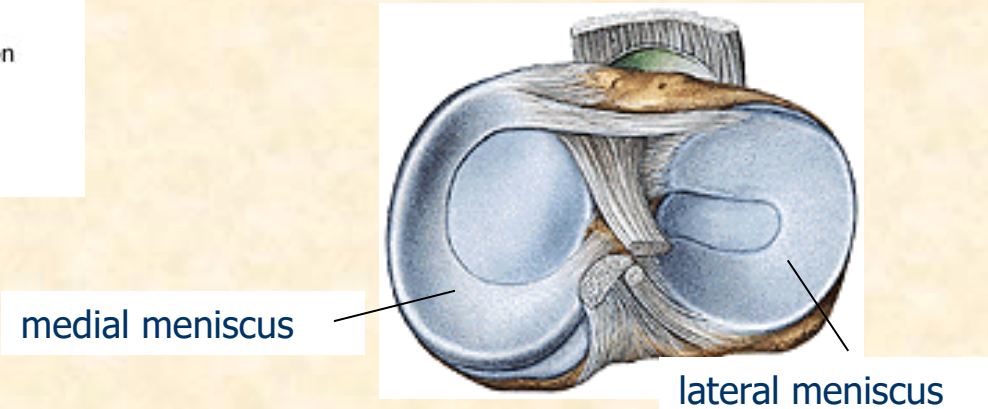
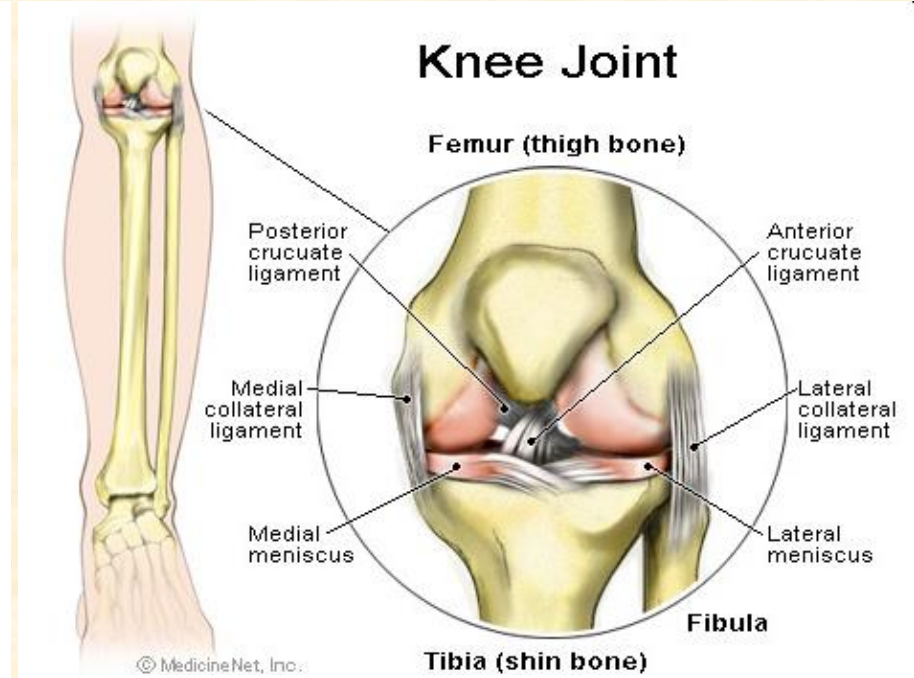
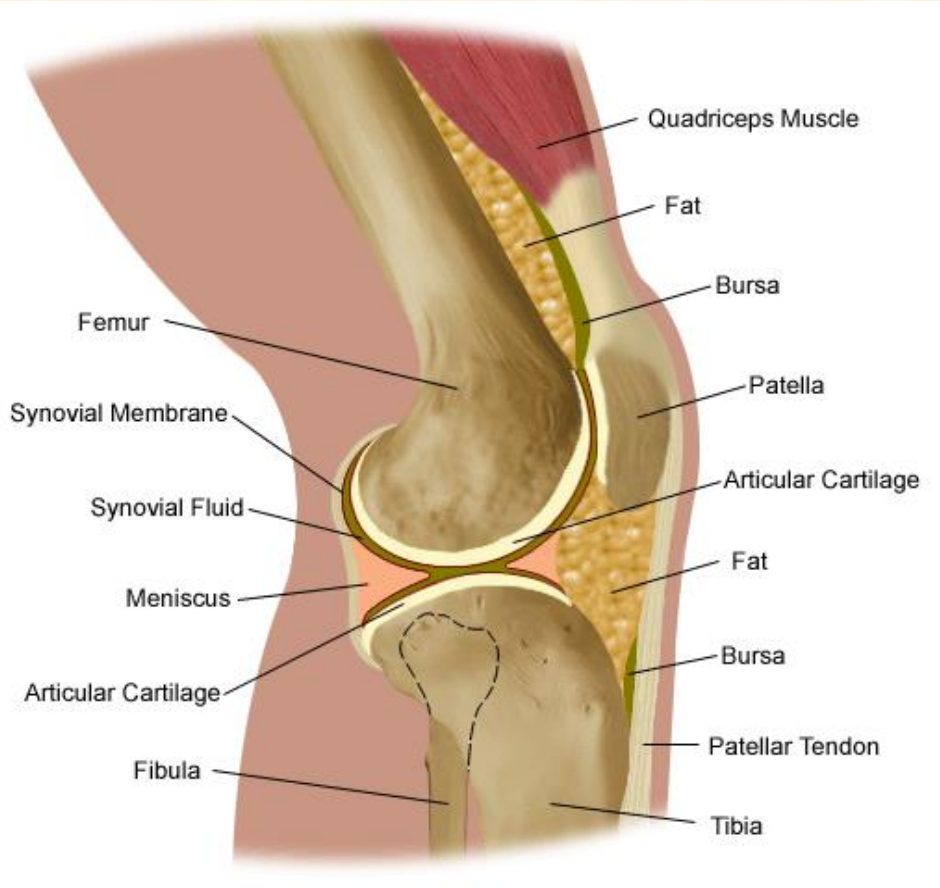
3) LOWER LEG (CRURAL) JUNCTIONS

4) FOOT JOINTS

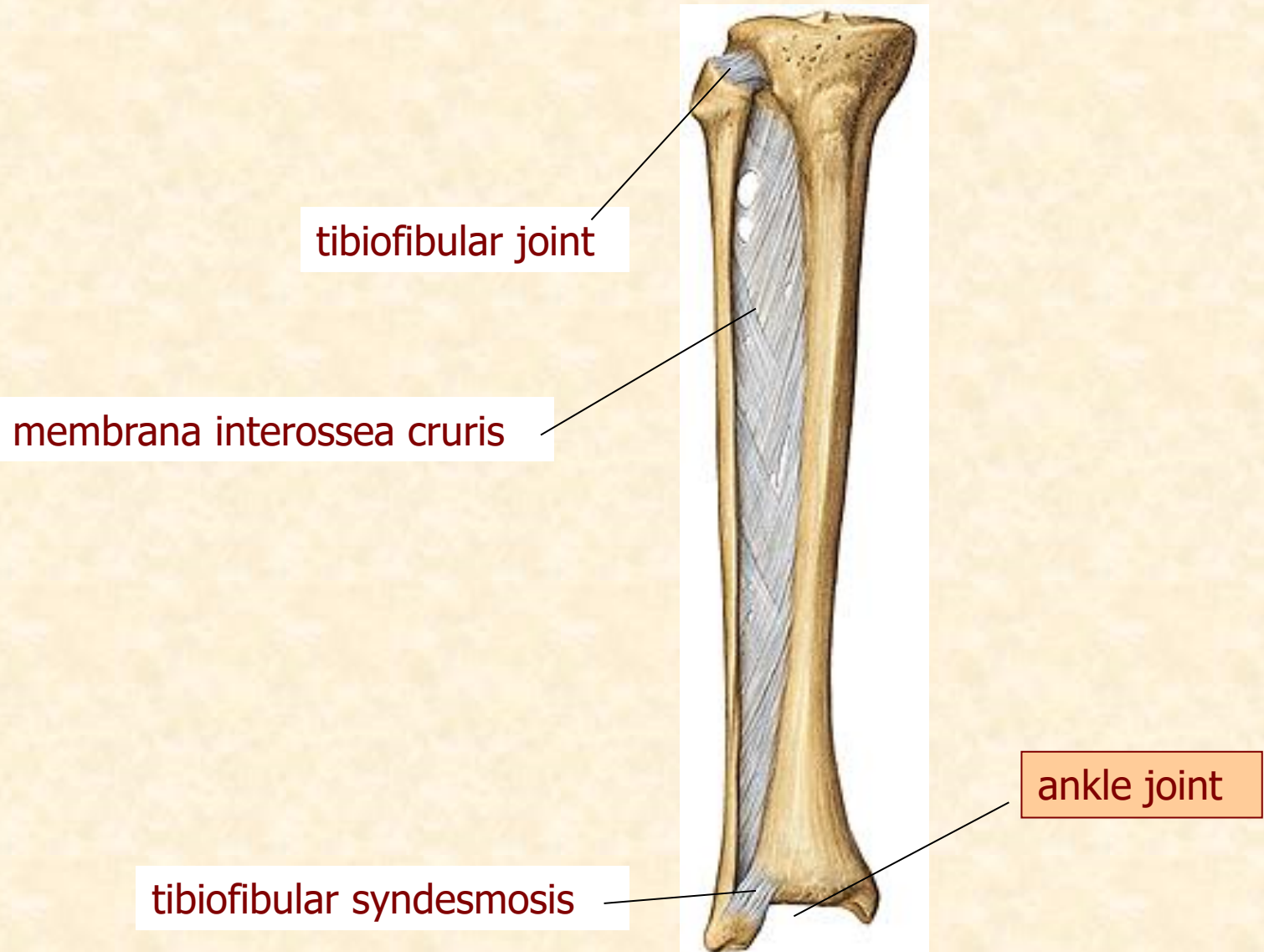
# HIP JOINT right side



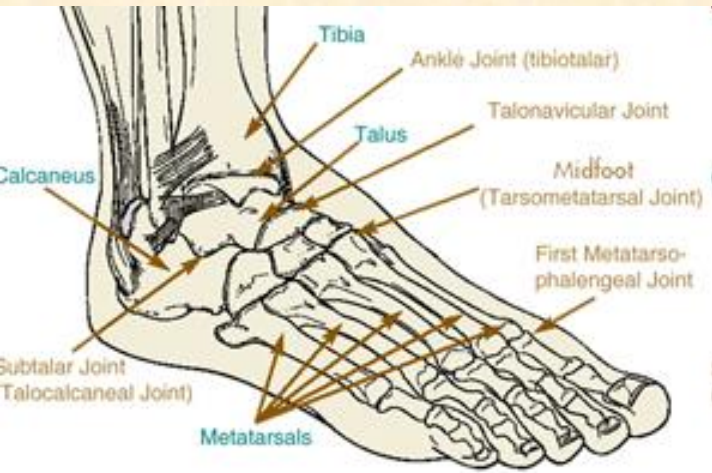
# KNEE JOINT



# LOWER LEG (CRURAL) JUNCTIONS



# FOOT JOINTS



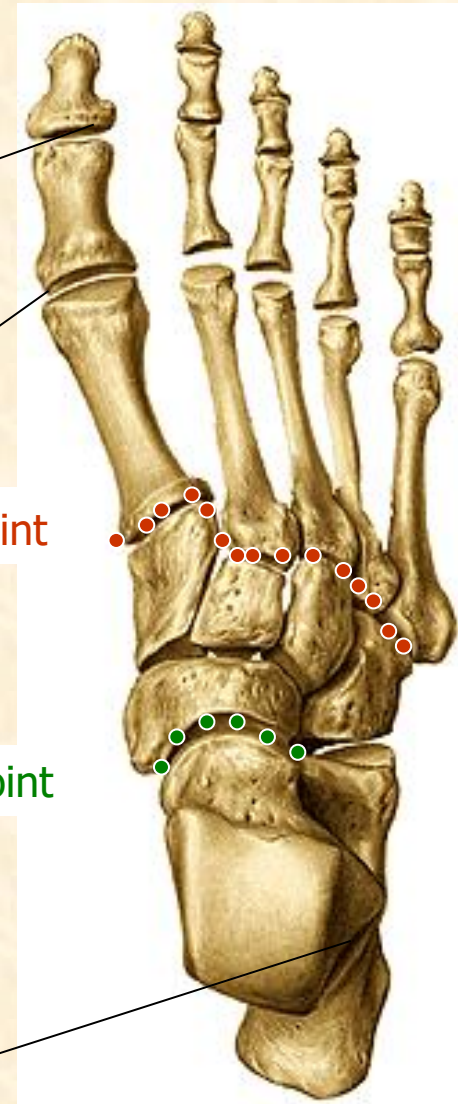
interphalangeal joint

metatarsophalangeal joint

tarsometatarsal joint

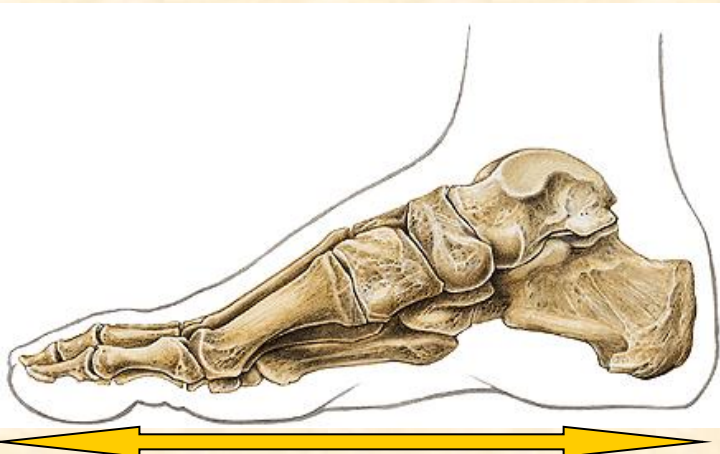
talonavicular joint

subtalar (talocalcaneal) joint

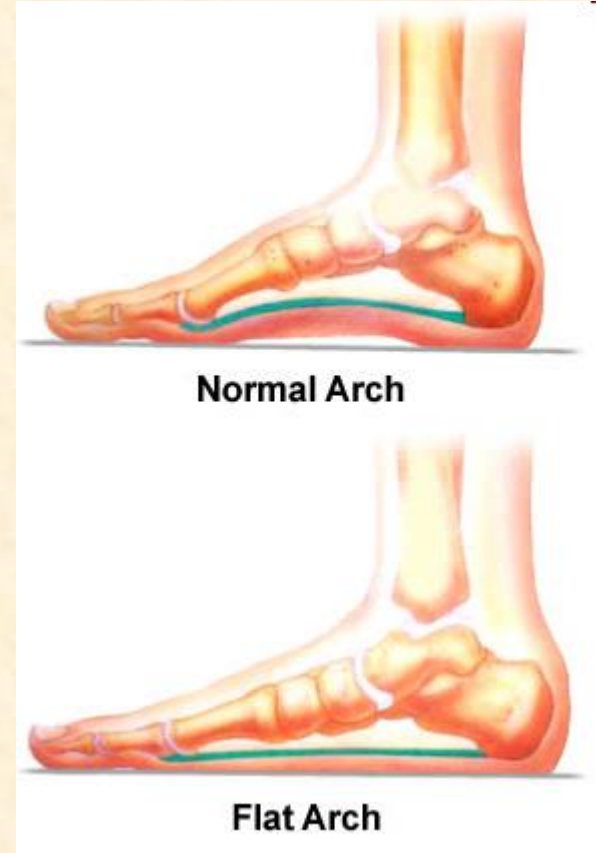
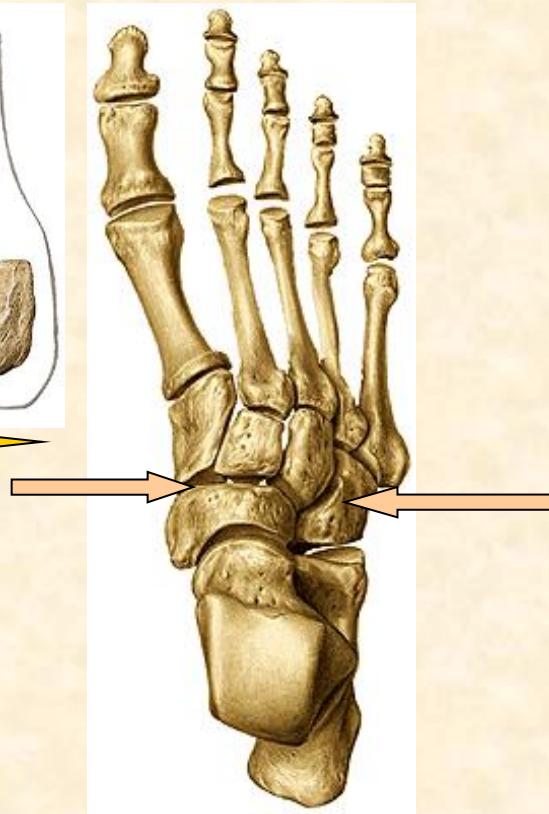


# ARCH OF THE FOOT

**LONGITUDINAL**



**TRANSVERSE**



**Normal Arch**

**Flat Arch**

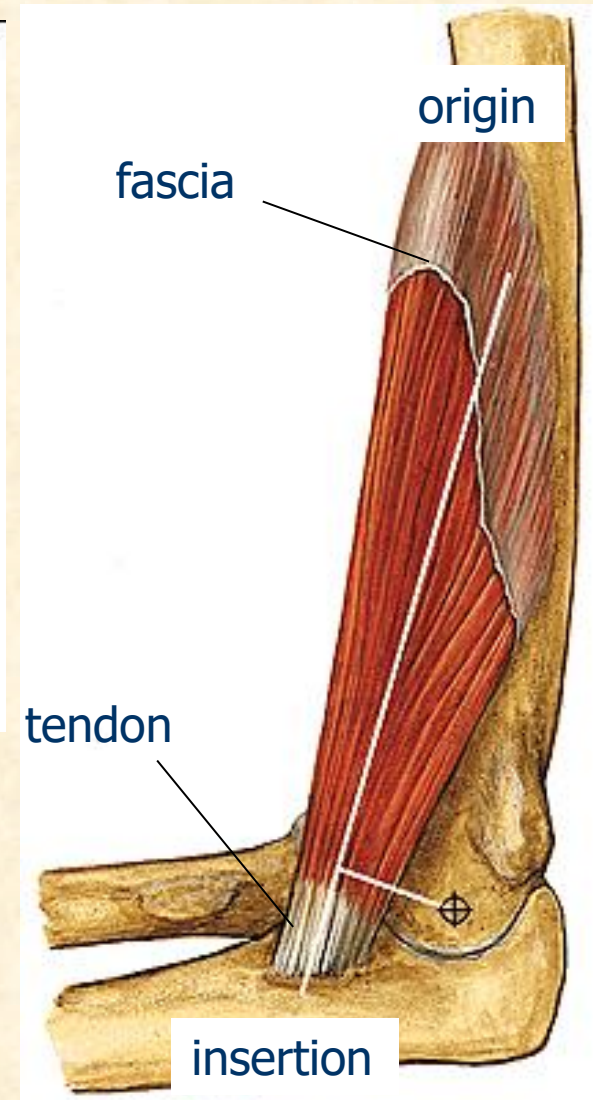
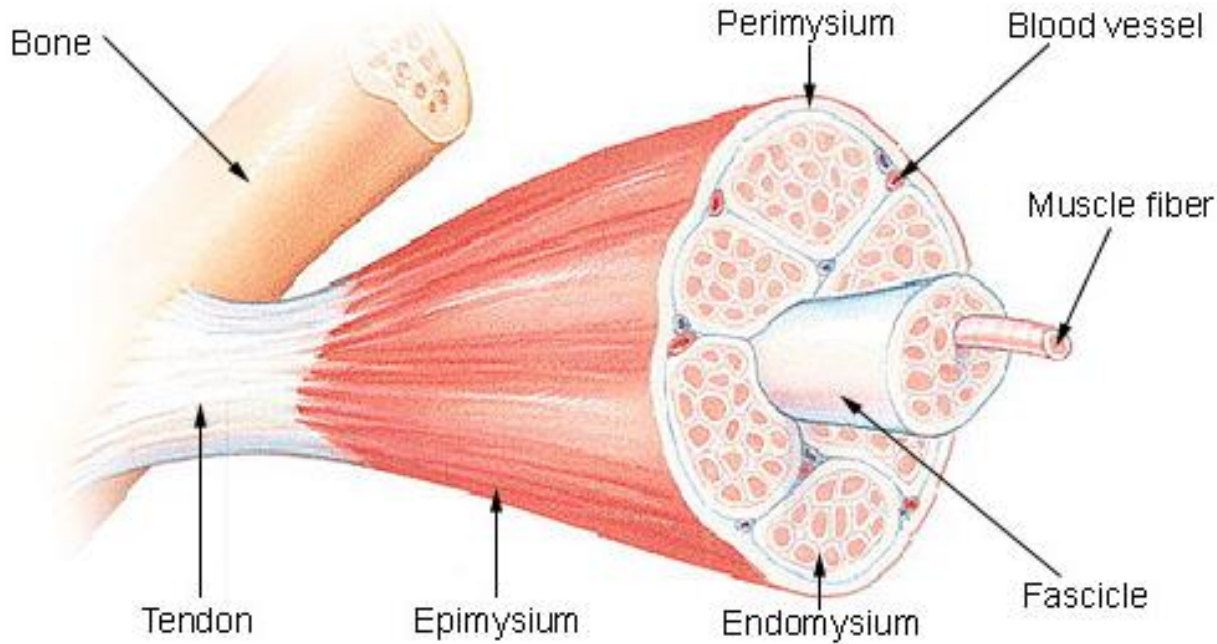


# MYOLOGY

- mys, myos = muscle /gr./
- muscular system = active part of locomotory system
- consists of about 600 skeletal muscles (musculi)
- 32–36 % of body weight in adult
- each muscle composed of muscle fibres

# SKELETAL MUSCLE

## Structure of a Skeletal Muscle



# OTHER STRUCTURES IN MUSCLES

## 1) FASCIAE

- fibrous tissue covering a muscle, providing its shape and position

## 2) TENDON SHEATHS

- layer of connective tissue round tendon, permitting the tendon to move in mechanically stressed places and reduce the friction
- filled with synovial fluid
- fibrous tendon sheath
- synovial sheath

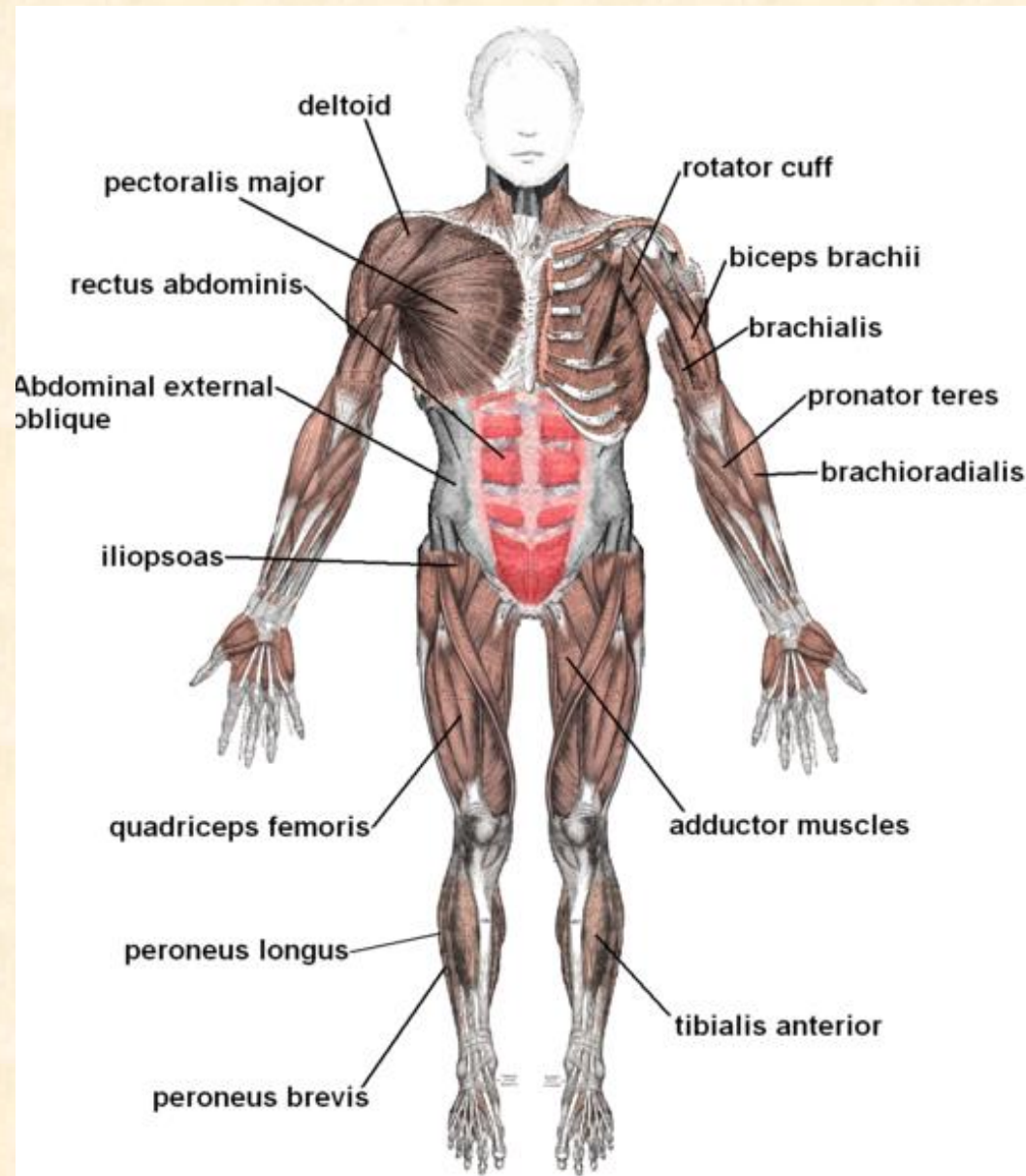
## 3) SYNOVIAL BURSAE

- sacs containing fluid, part of the typical structure of a joint (knee, elbow), where it protects against frequent pressure and rubbing

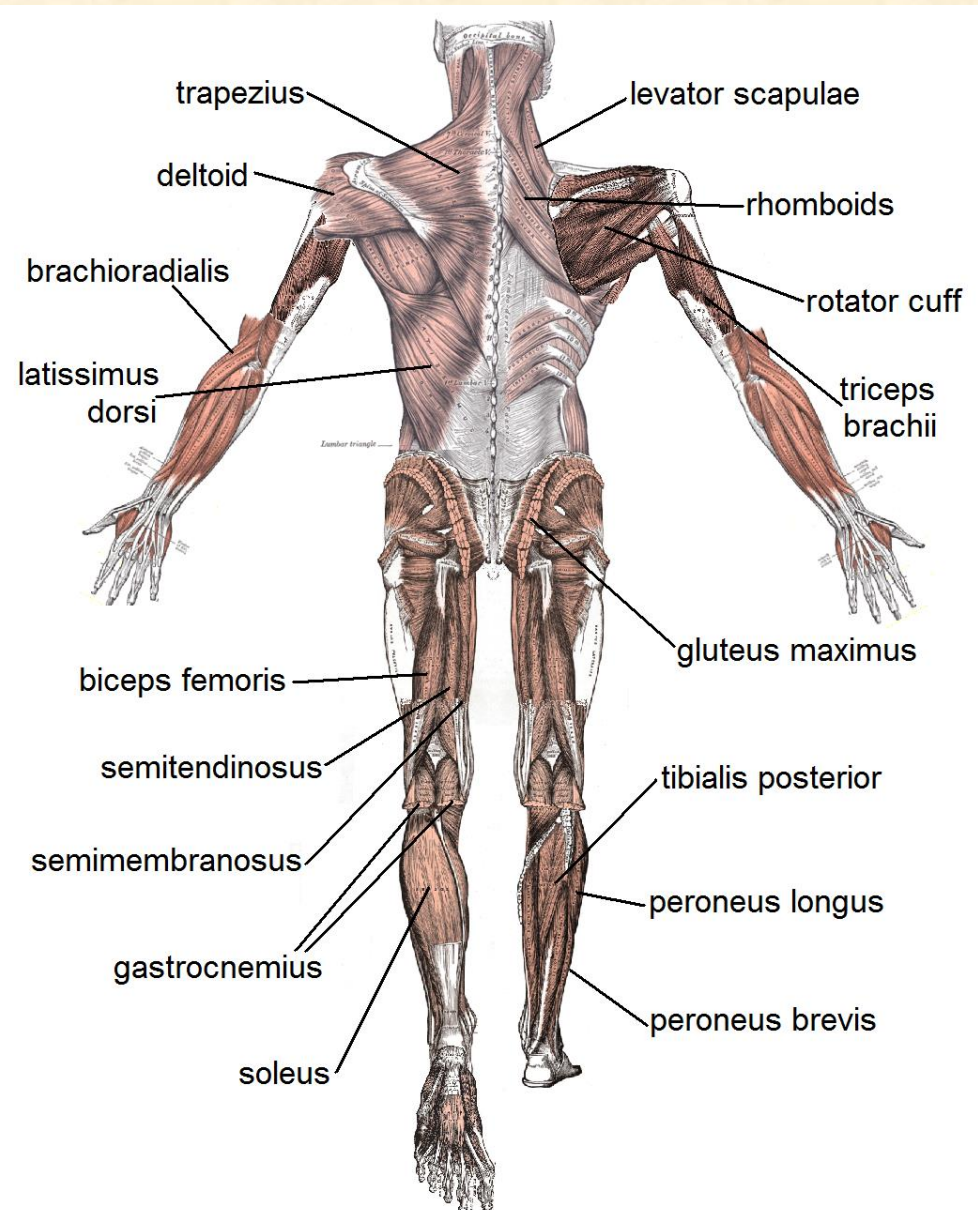
# MUSCLE FUNCTIONS

- **SYNERGIST** – muscles that act together and increase the effectiveness of both
- **ANTAGONIST** – opposes another muscle in a movement
- **FLEXOR** (makes a joint bend)  
**EXTENSOR** (makes a joint become straight)
- **ADDUCTOR** (pulls a part of the body towards the midline of the body)
- **ABDUCTOR** (pulls a part of the body away from the midline of the body or from a neighboring part)
- **SPHINCTER** (ring of muscle at the opening of a passage in the body, which can contract to close the passage)
- **DILATOR** (ring of muscle that extends to open the passage)
- **LEVATOR** (lifts a limb or a part of the body)  
**DEPRESSOR** (pulls part of a body downwards)

# MUSCULAR SYSTEM, anterior view

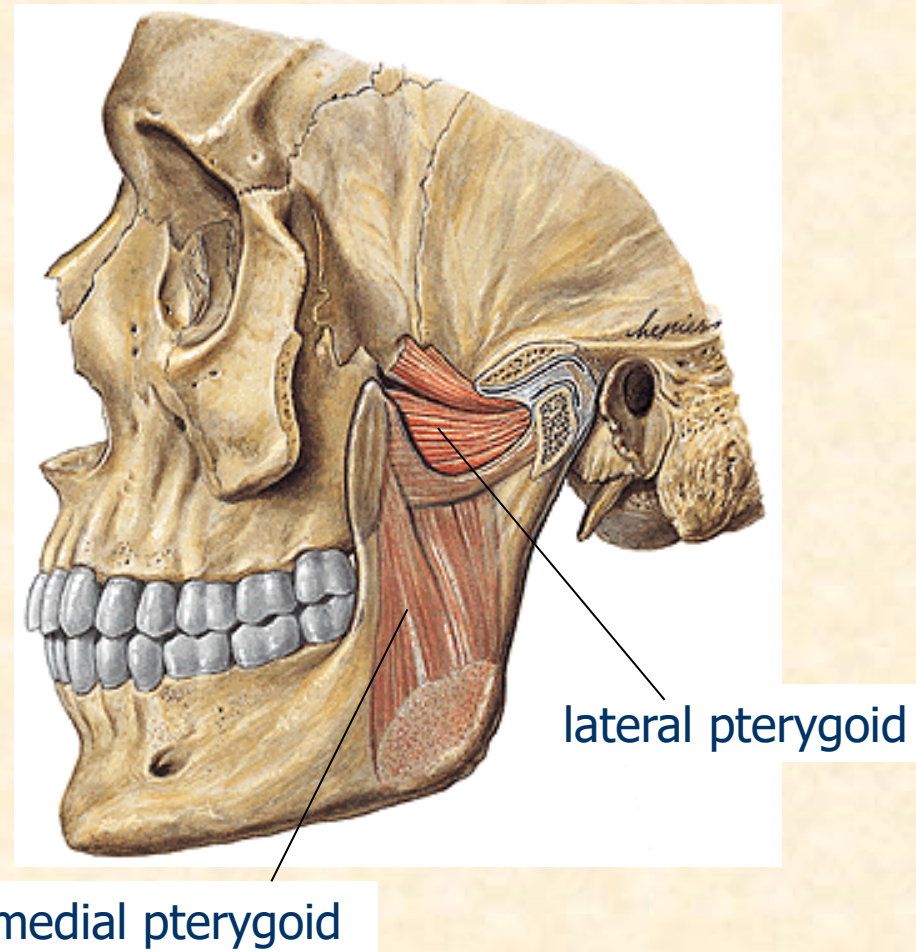
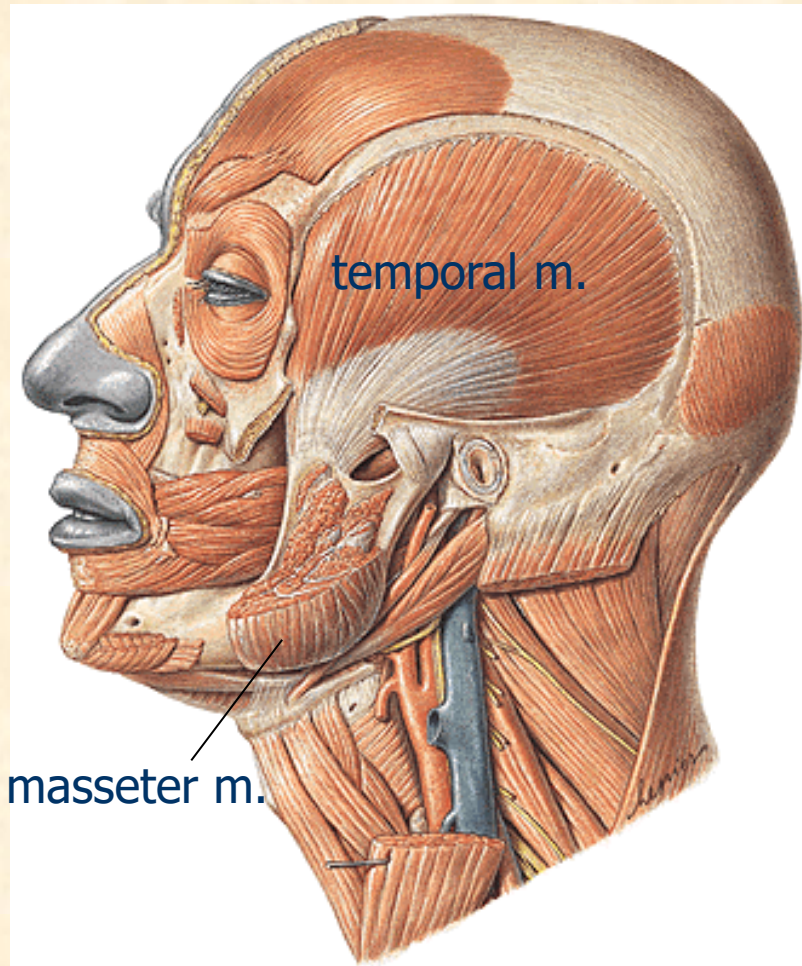


# MUSCULAR SYSTEM, posterior view



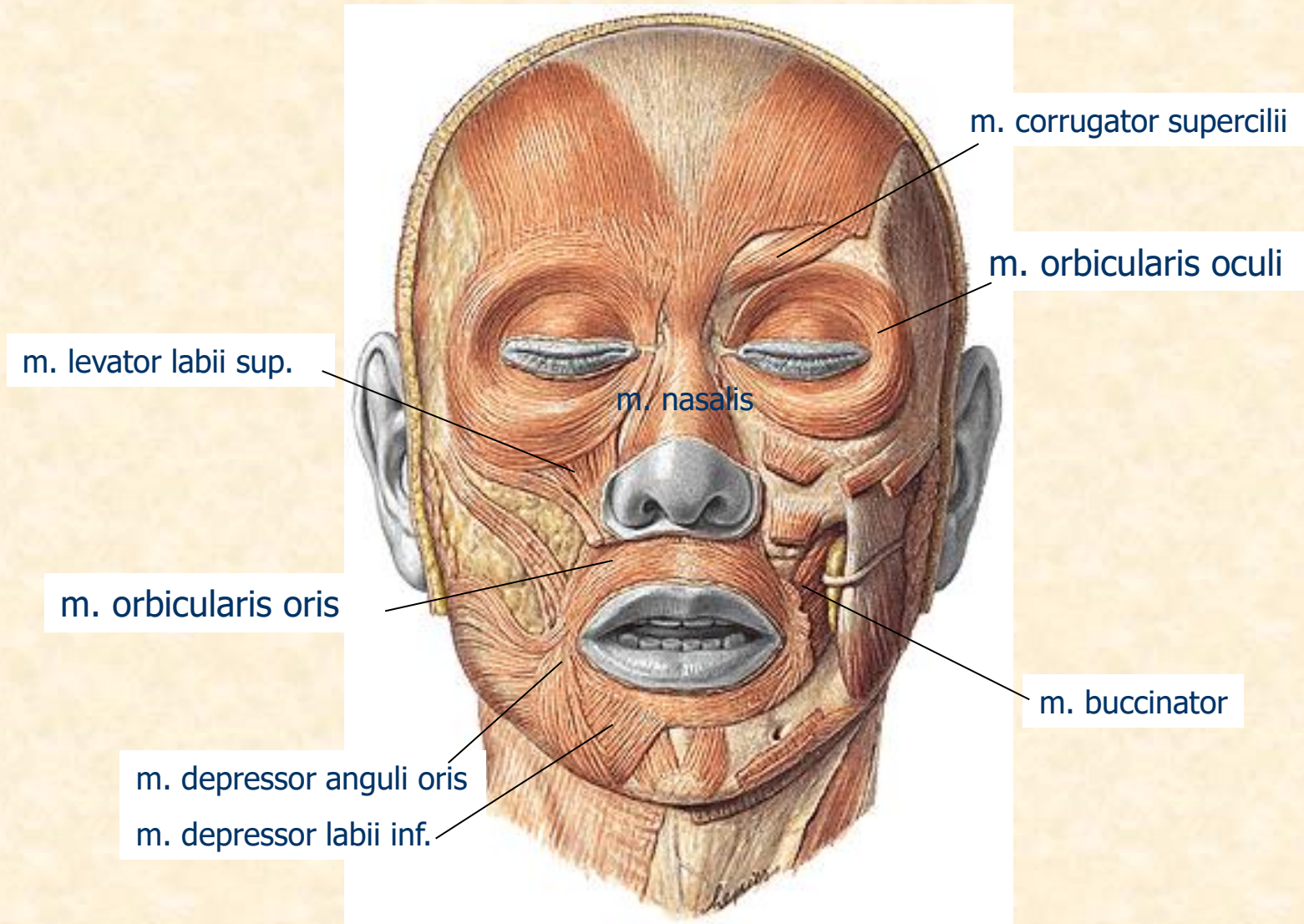
# HEAD MUSCLES

## MASTICATORY MUSCLES



# HEAD MUSCLES

## FACIAL MUSCLES





# FACIAL MUSCLES – Face Expressions



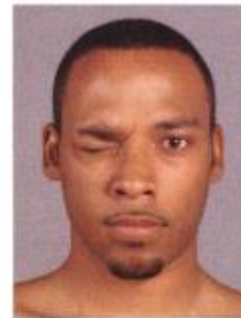Occipitofrontalis



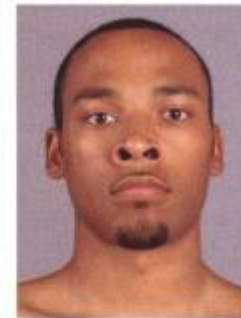Corrugator supercilii



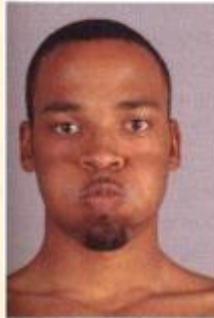Procerus + transverse part of nasalis



Orbicularis oculi



Lev. labii sup. alaeque nasi + alar part of nasalis



Buccinator + orbicularis oris



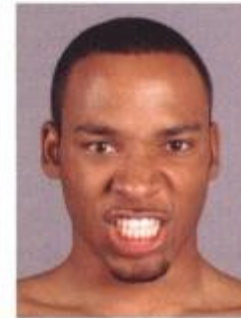
Zygomaticus major + minor



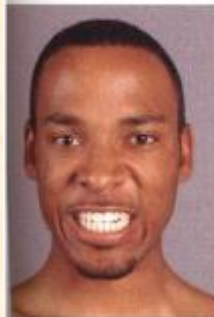Risorius



Risorius + depressor labii inferioris



Levator labii superioris + depressor labii



Dilators of mouth: tensor plus levator labii superioris + depressor labii inferioris



Orbicularis oris



Depressor anguli oris

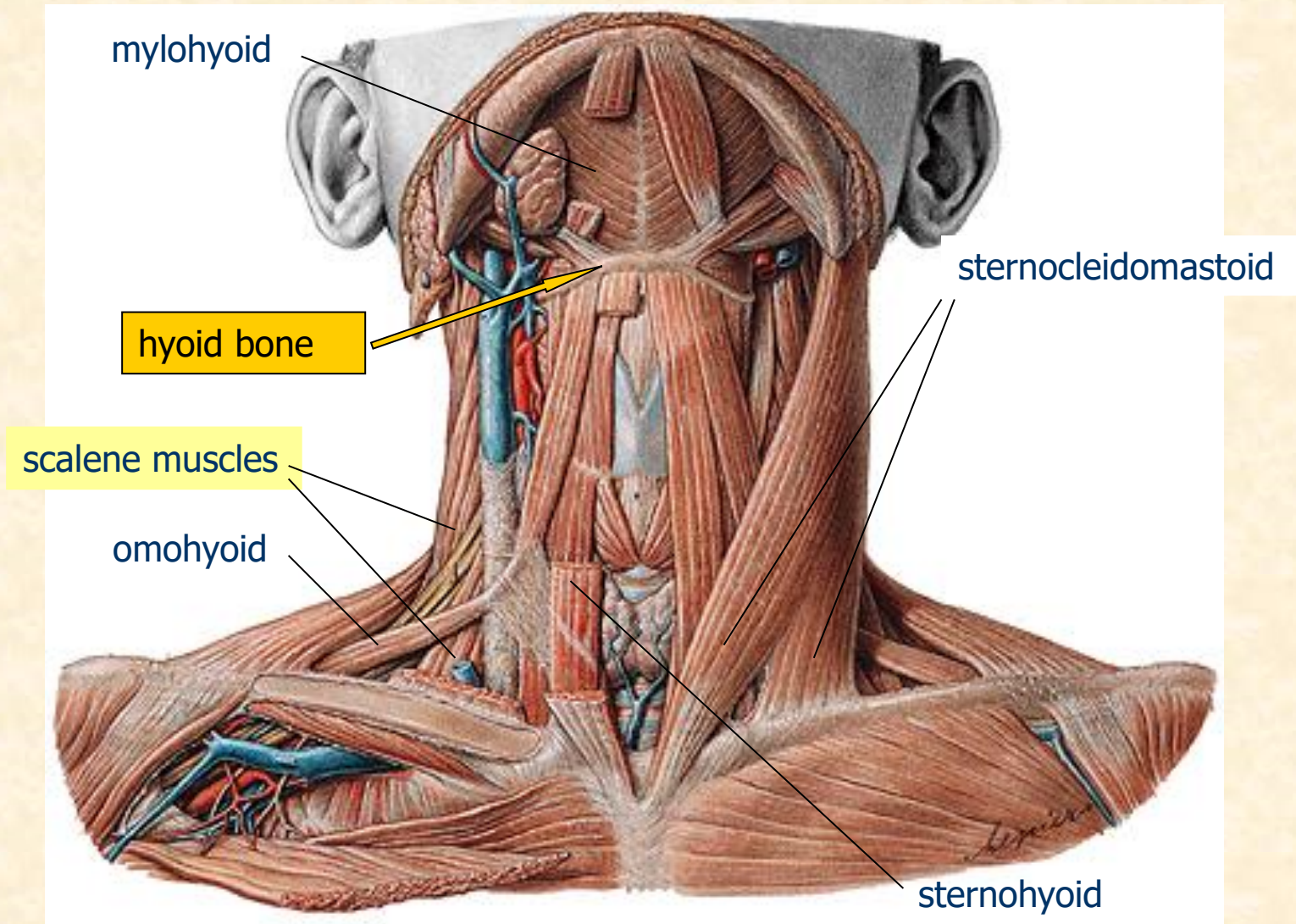


Mentalis



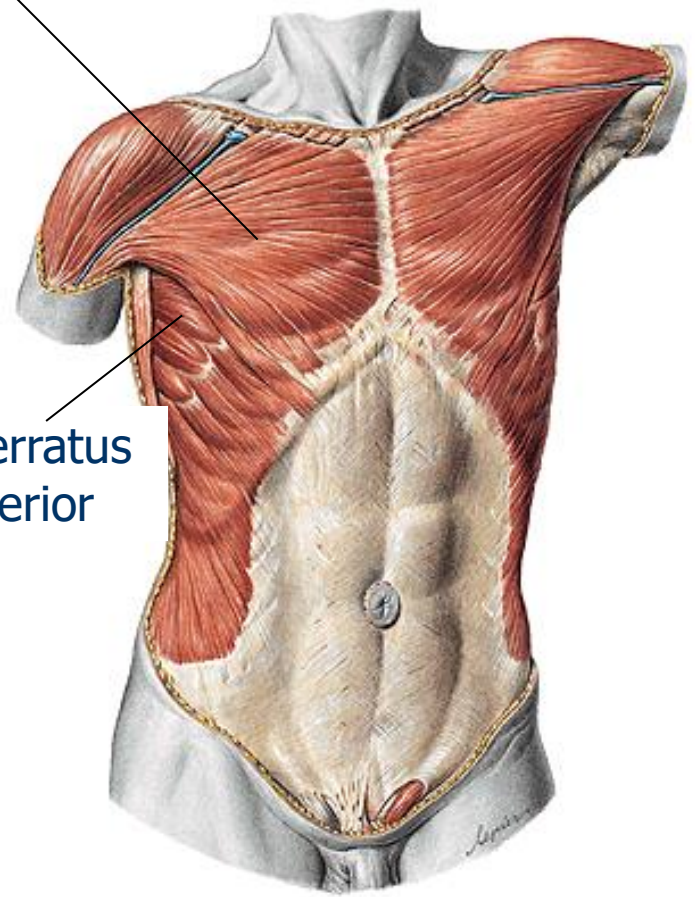
Platysma

# NECK MUSCLES



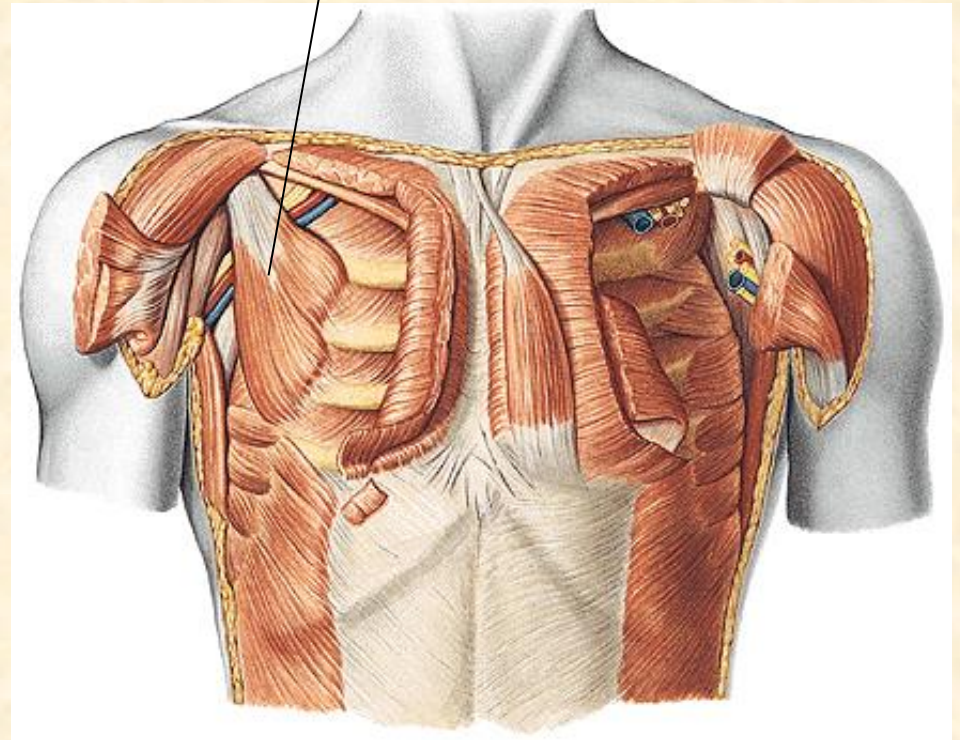
# THORAX MUSCLES

m. pectoralis major

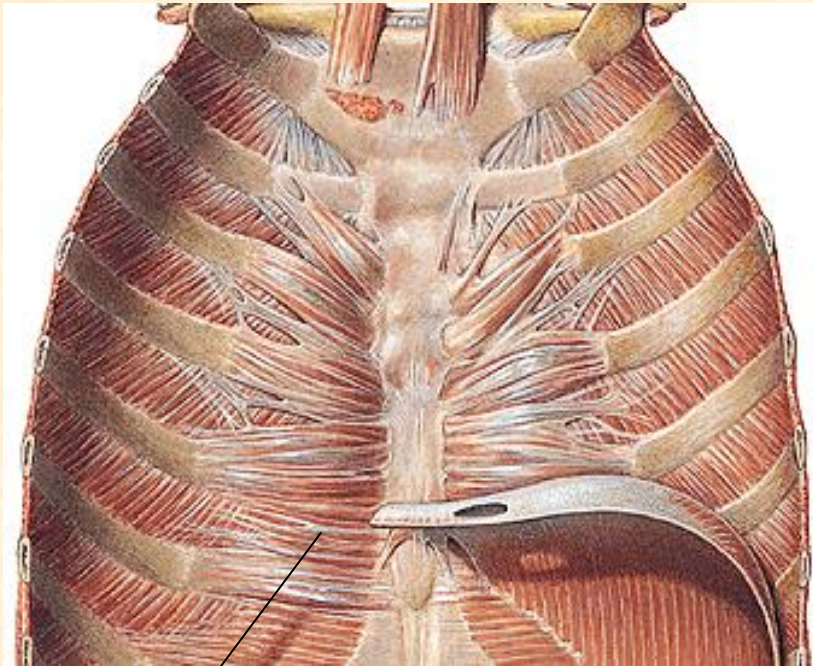


m. serratus anterior

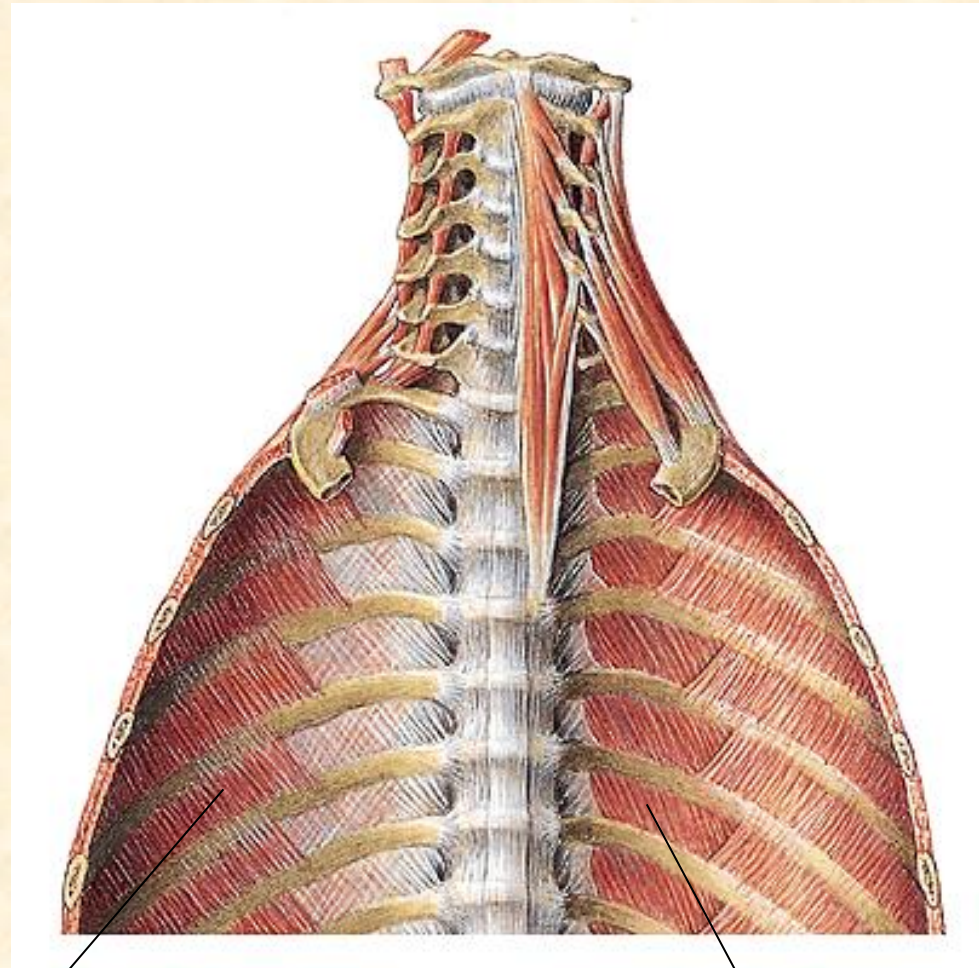
m. pectoralis minor



# THORAX MUSCLES



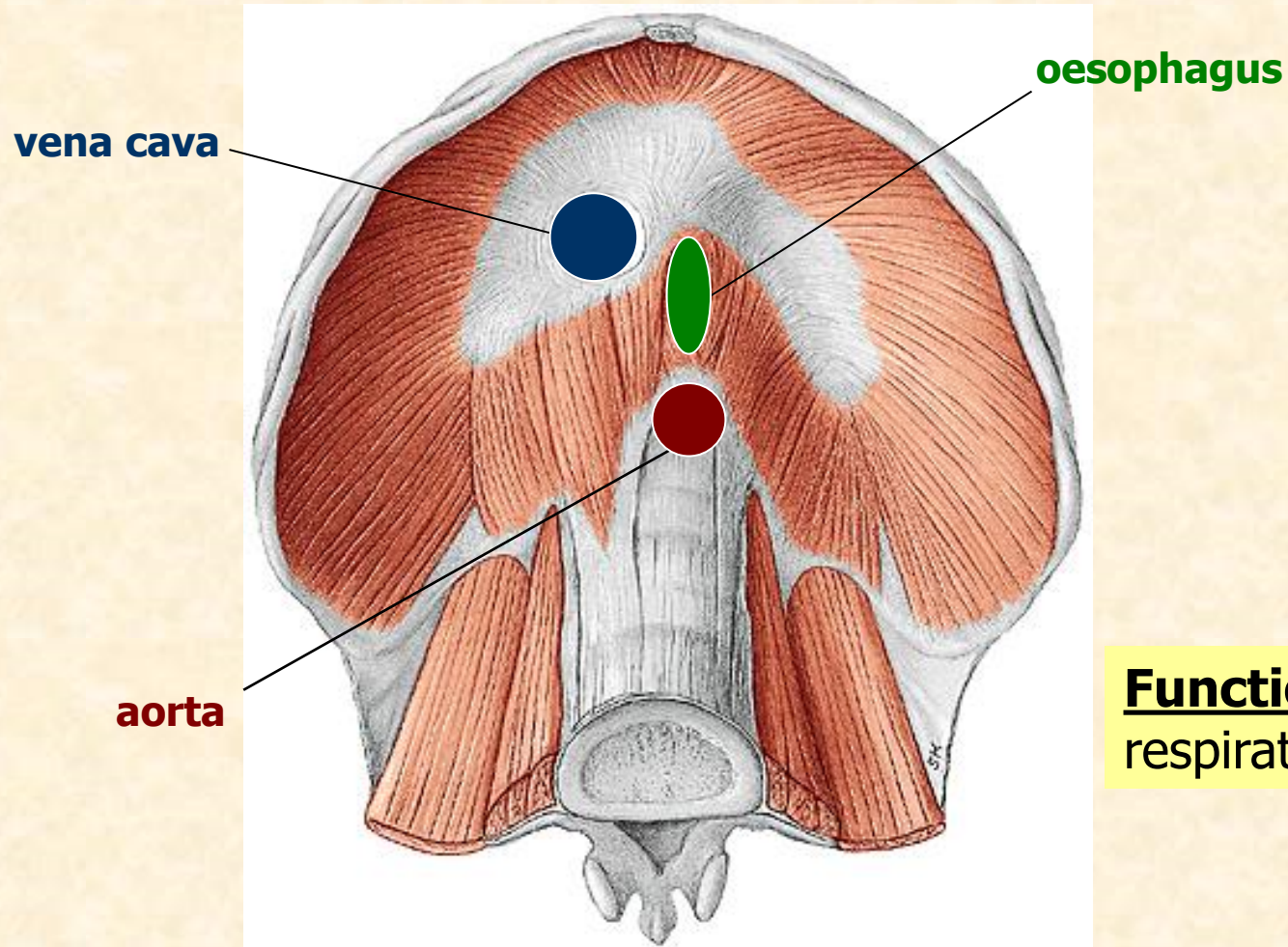
m. transversus thoracis



mm. intercostales interni

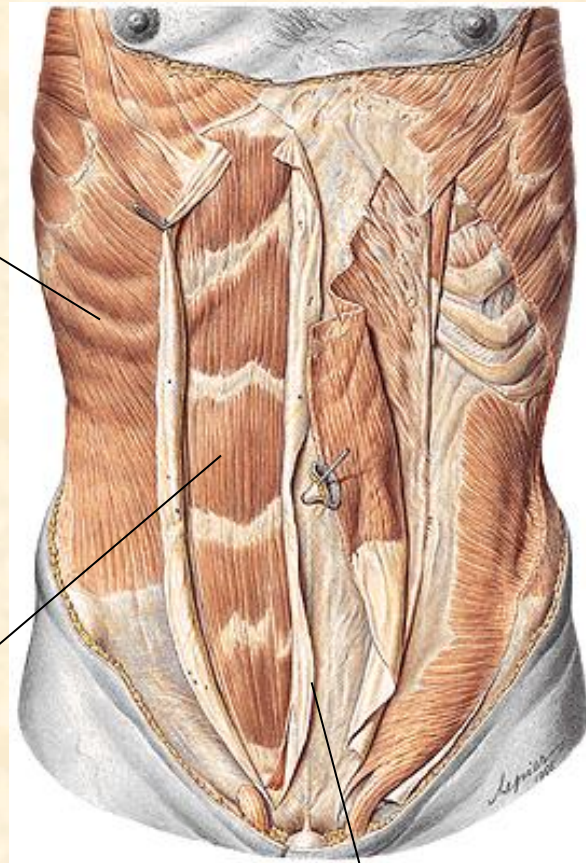
mm. intercostales externi

# DIAPHRAGM



**Function:** main respiratory muscle

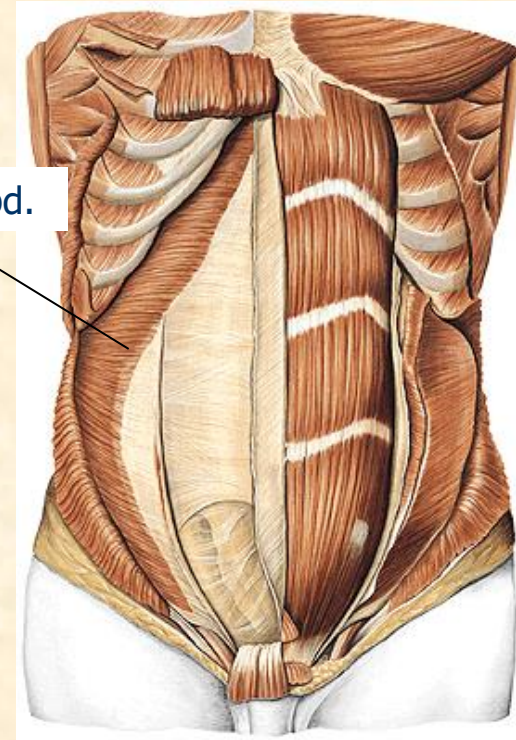
# ABDOMINAL MUSCLES



m. obliquus externus  
et internus abdominis

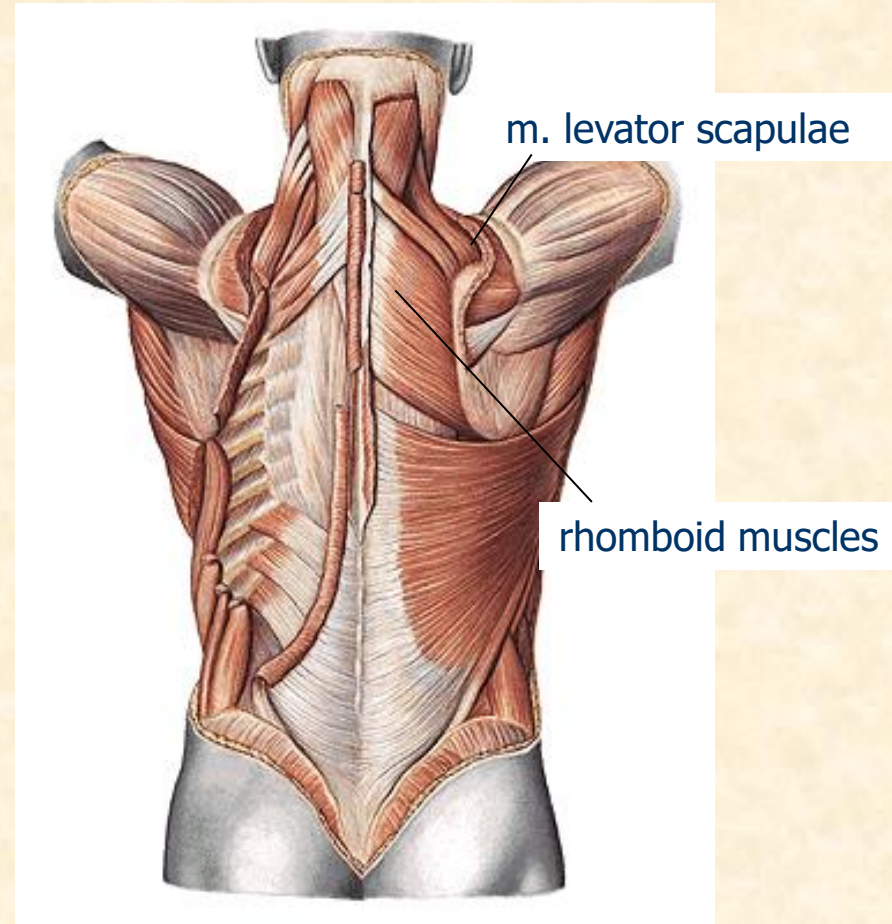
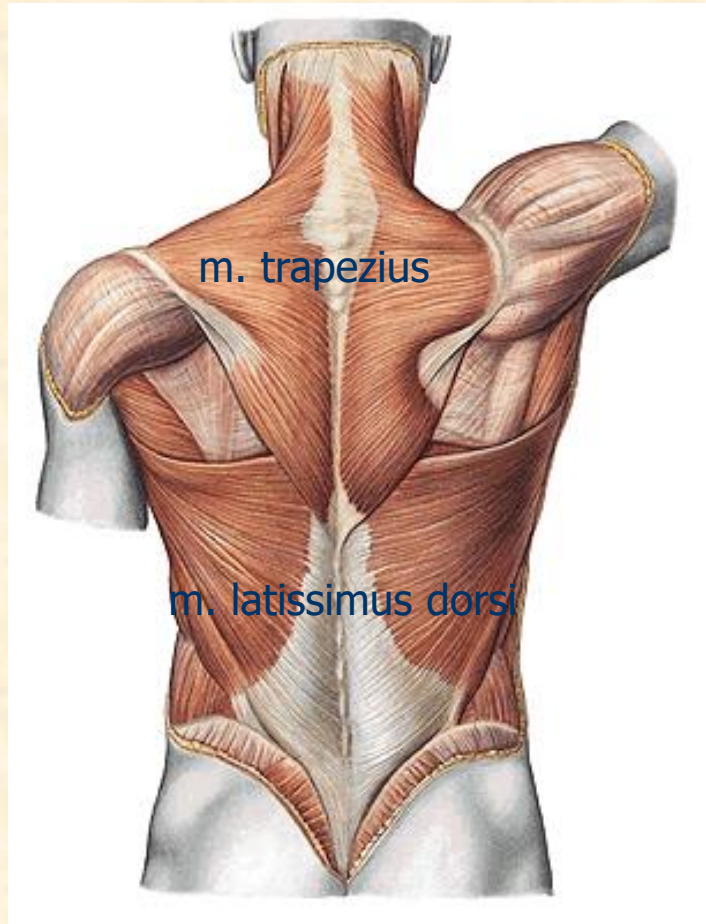
m. rectus abdominis

linea alba

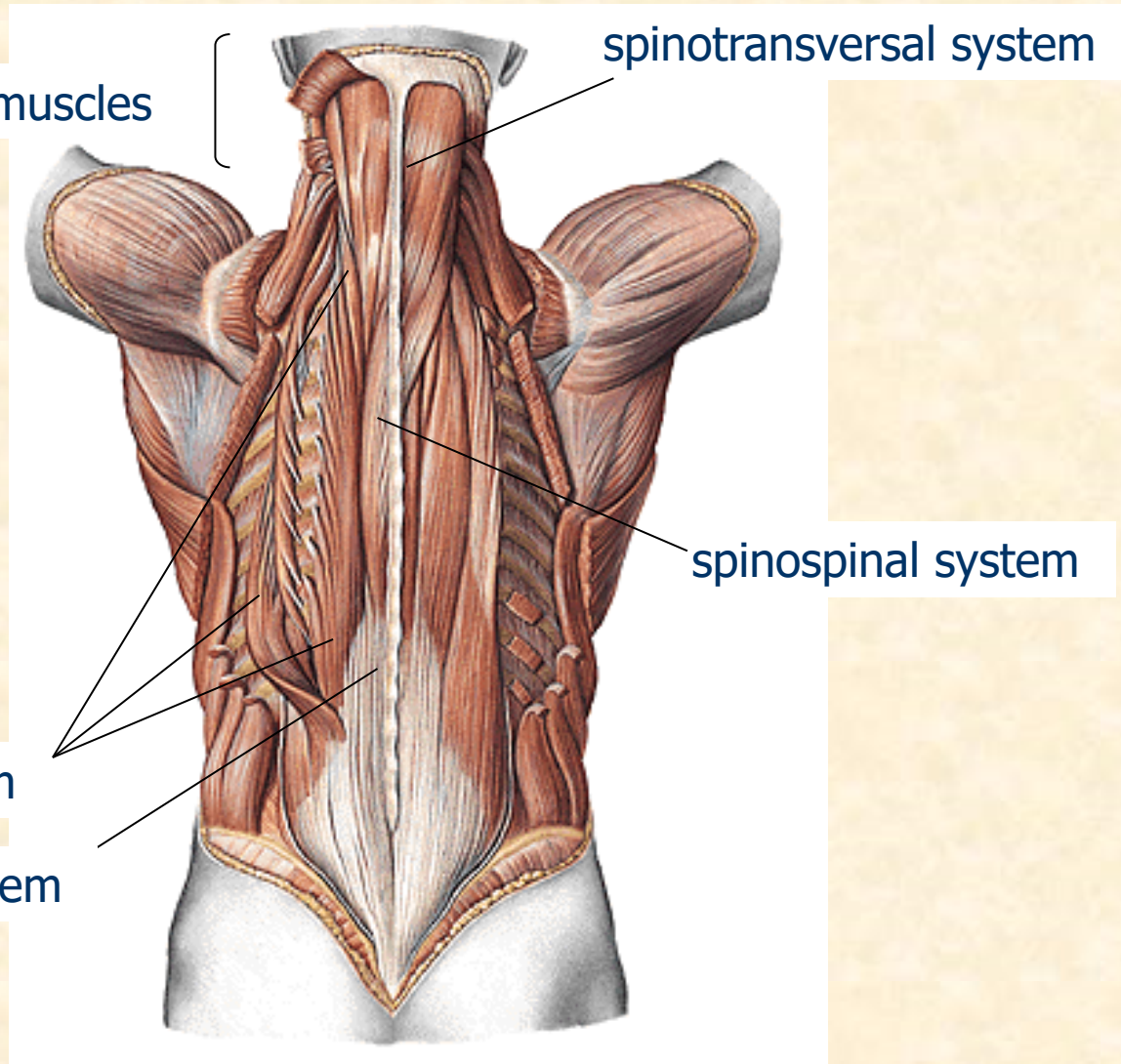


m. transversus abd.

# BACK MUSCLES



# BACK MUSCLES



deep neck muscles

spinotransversal system

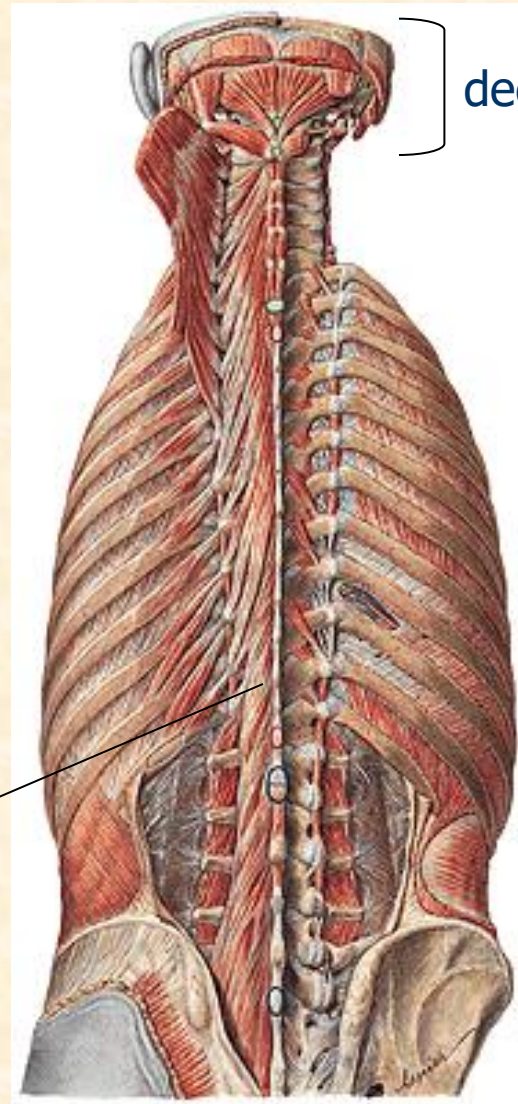
spinospinal system

sacrospinal system

transversospinal system



# BACK MUSCLES



deep neck muscles

transversospinal system

# UPPER LIMB MUSCLES

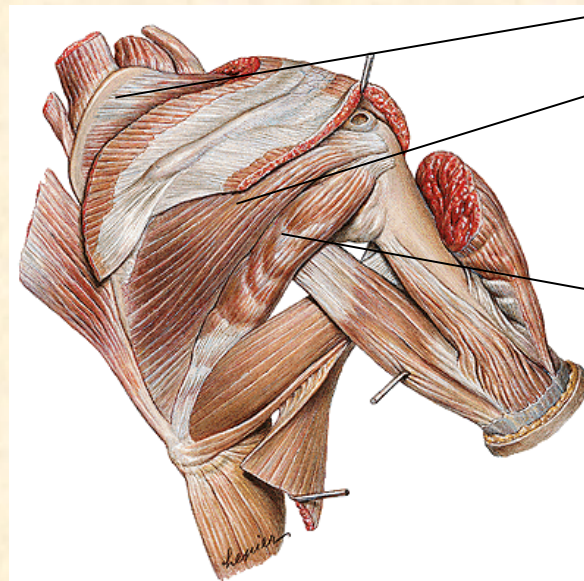
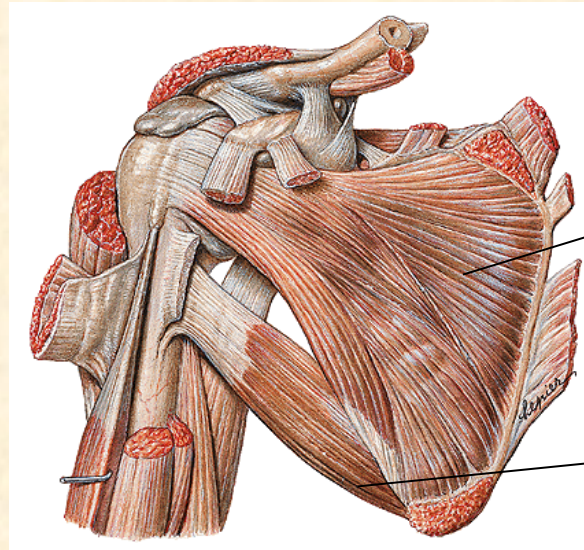
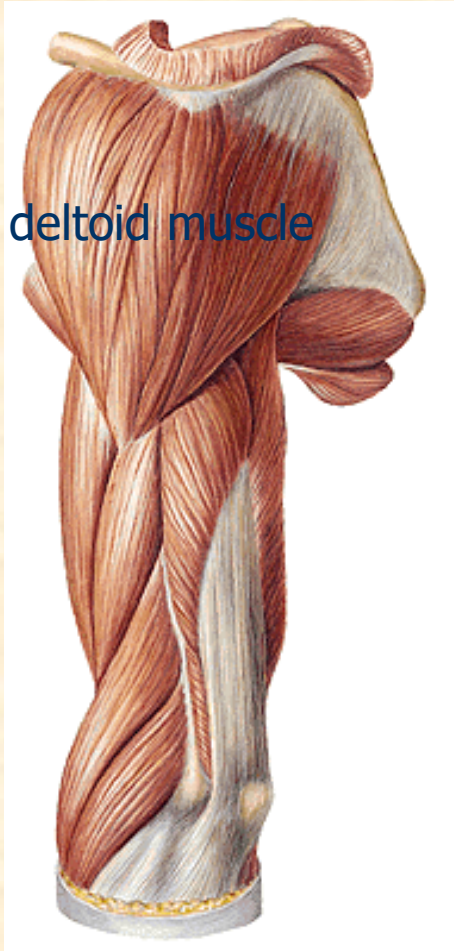
1) SHOULDER MUSCLES

2) ARM MUSCLES

3) FOREARM MUSCLES

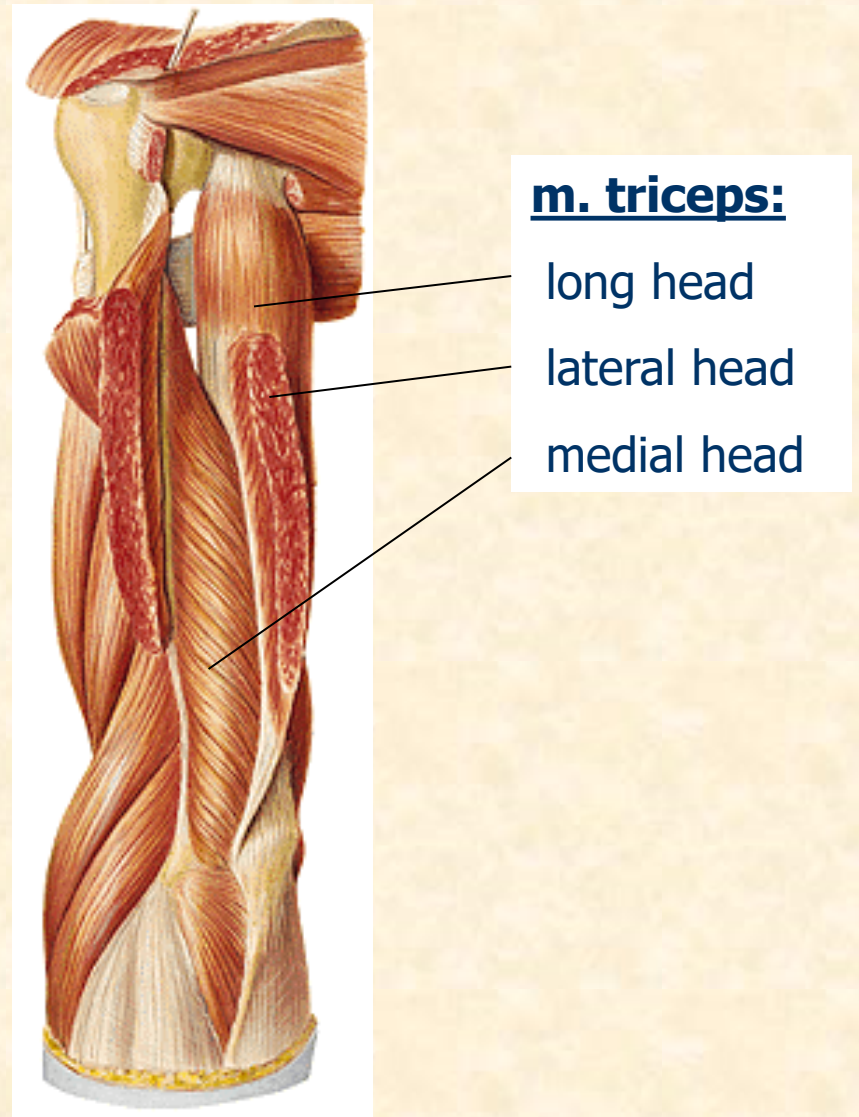
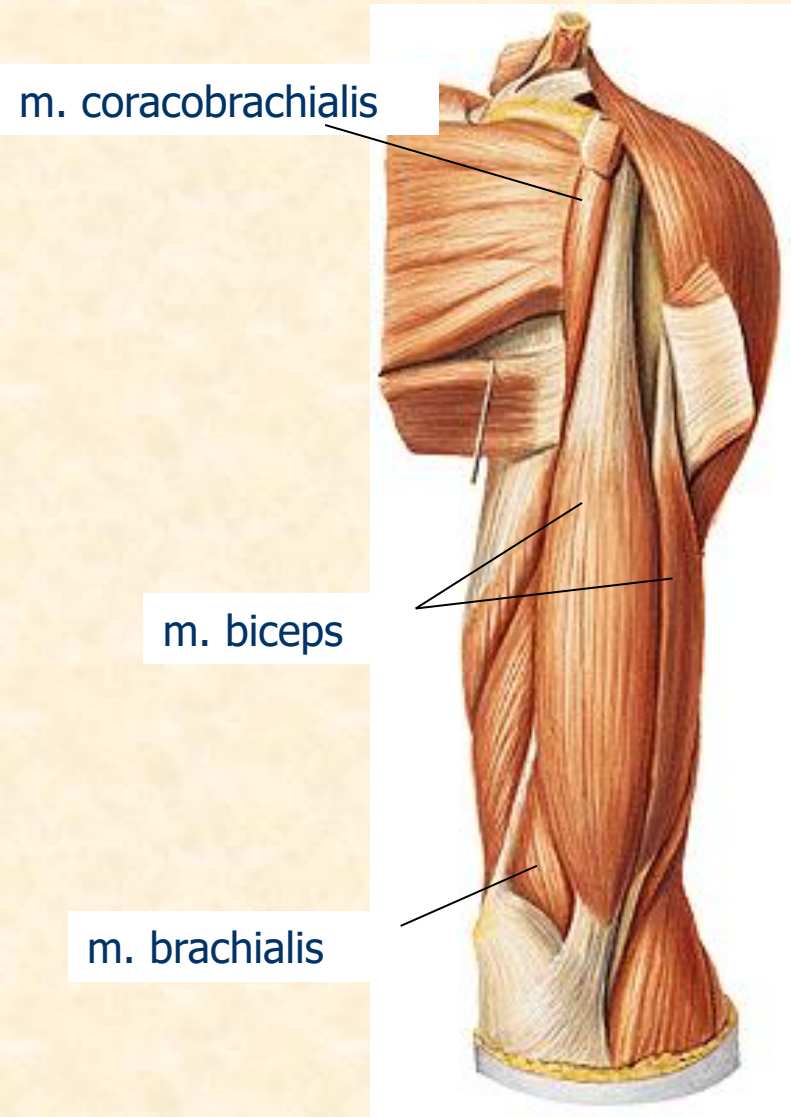
4) HAND MUSCLES

# SHOULDER MUSCLES

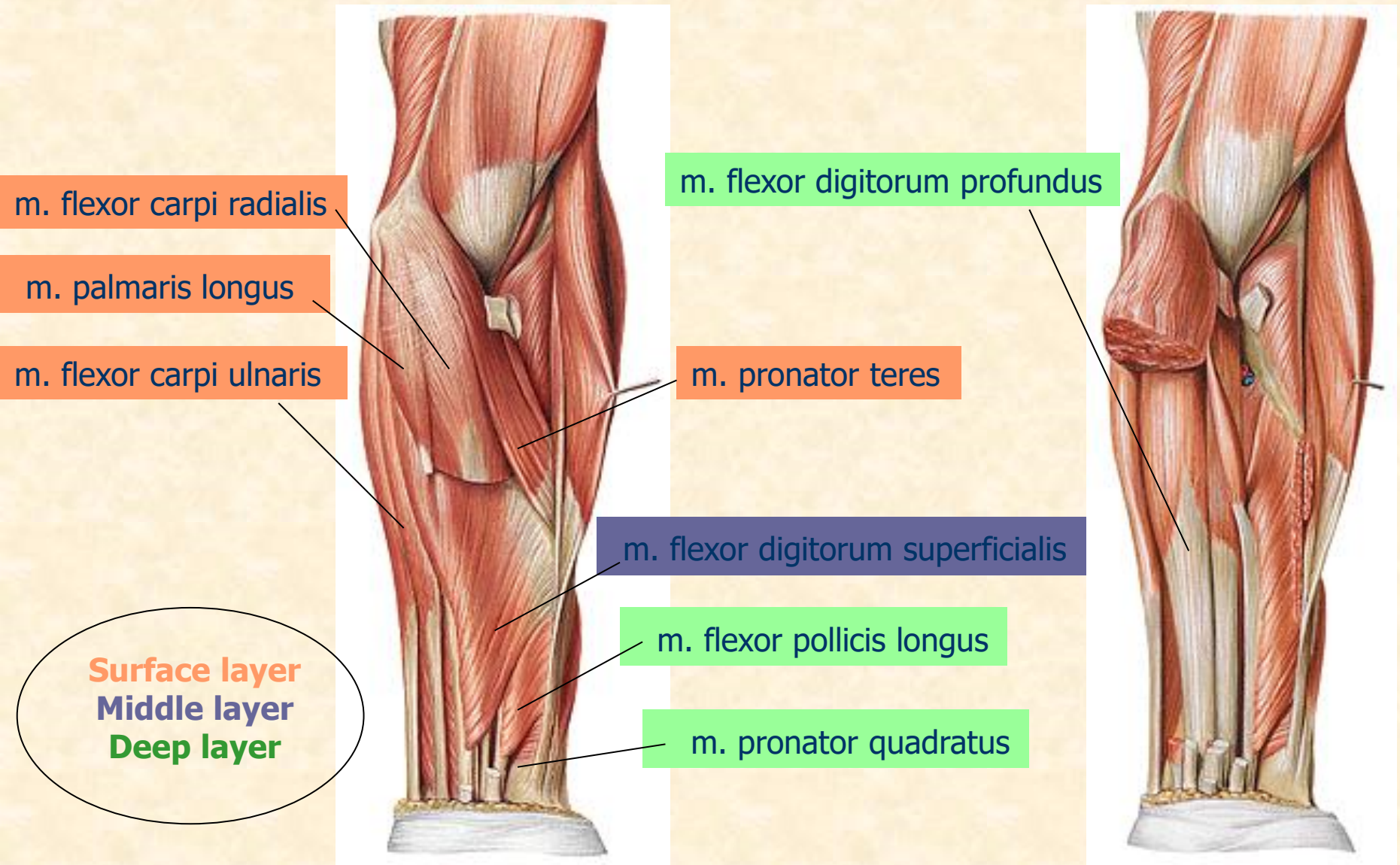


# ARM MUSCLES

## anterior and dorsal group



# FOREARM MUSCLES – ANTERIOR GROUP

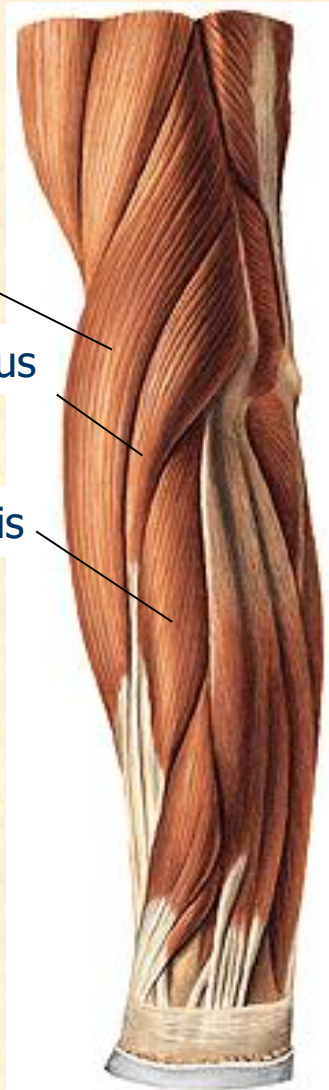


# FOREARM MUSCLES – LATERAL GROUP

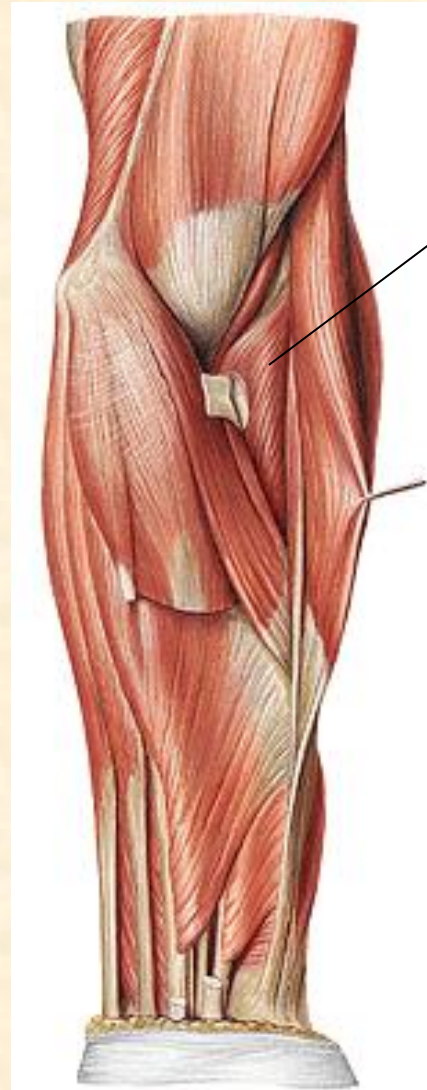
m. brachioradialis

m. extensor carpi radialis longus

m. extensor carpi radialis brevis

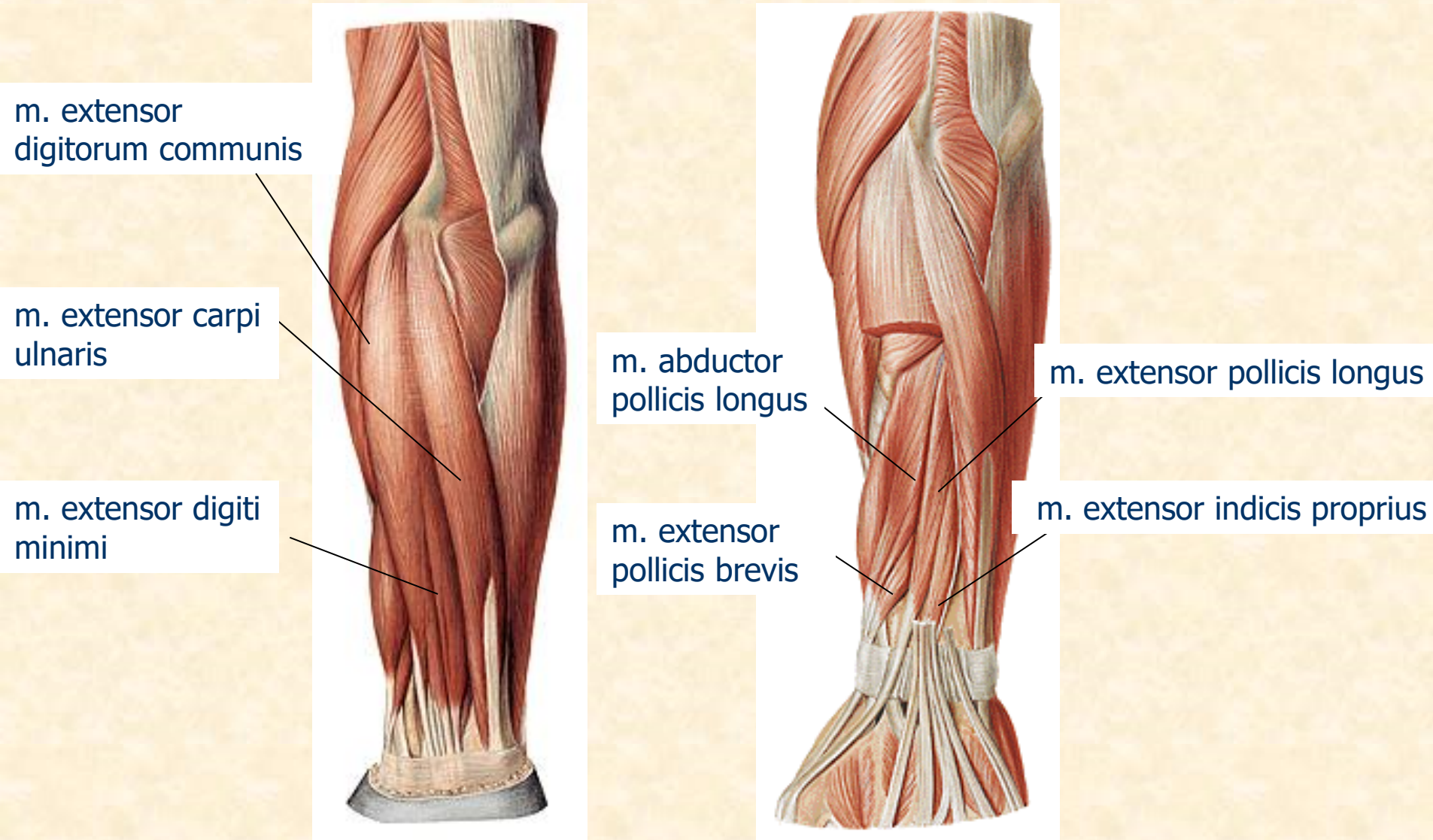


m. supinator



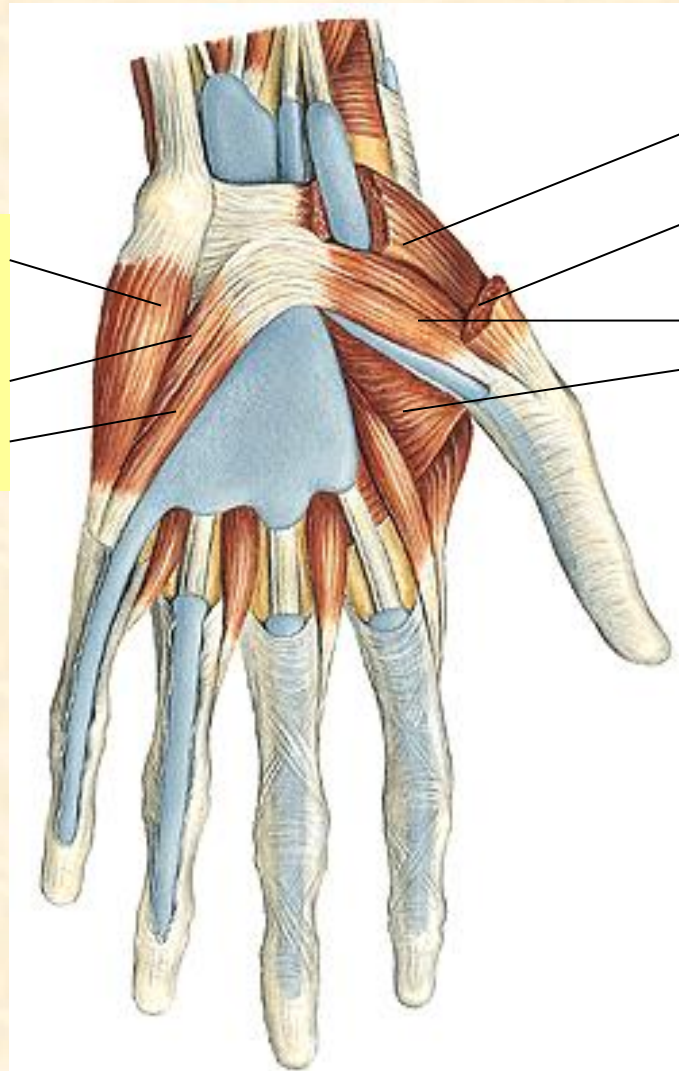
# FOREARM MUSCLES

## DORSAL GROUP – superficial and deep layer



# HAND MUSCLES

group of HYPOTHENAR and THENAR



m. abductor digiti minimi  
m. flexor digiti minimi  
brevis  
m. opponens digiti minimi

m. opponens pollicis  
m. abductor pollicis brevis  
m. flexor pollicis brevis  
m. adductor pollicis



# LOWER LIMB MUSCLES

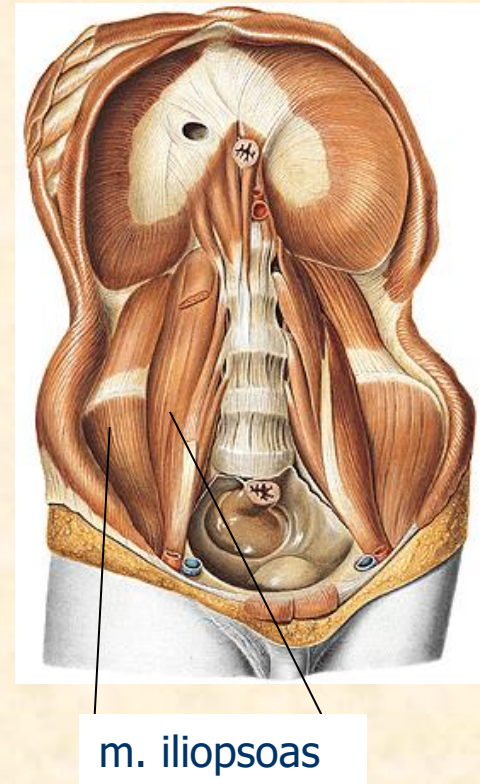
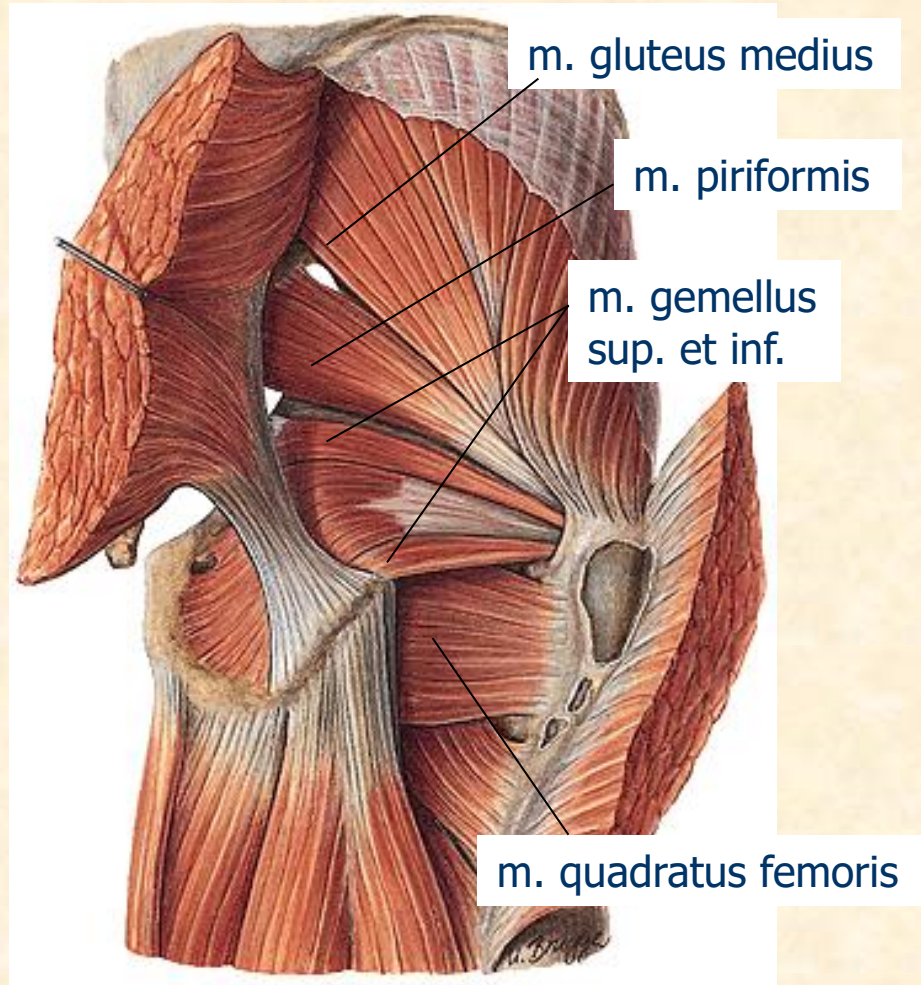
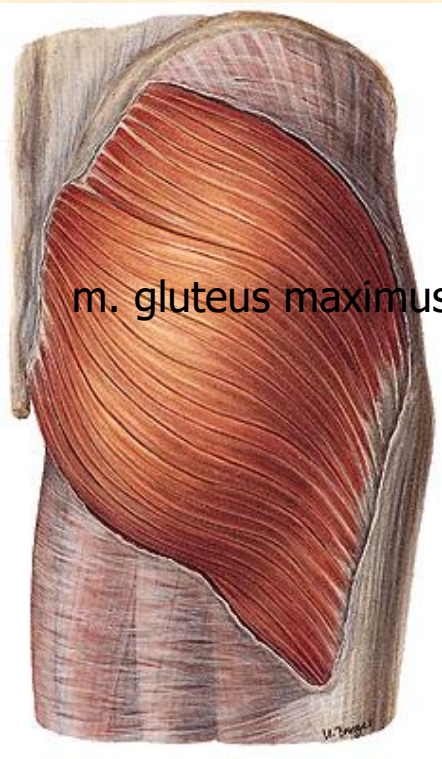
1) HIP MUSCLES

2) THIGH MUSCLES

3) LOWER LEG (CRURAL) MUSCLES

4) FOOT MUSCLES

# HIP MUSCLES



# THIGH MUSCLES

m. sartorius

m. adductor longus,  
brevis et magnus

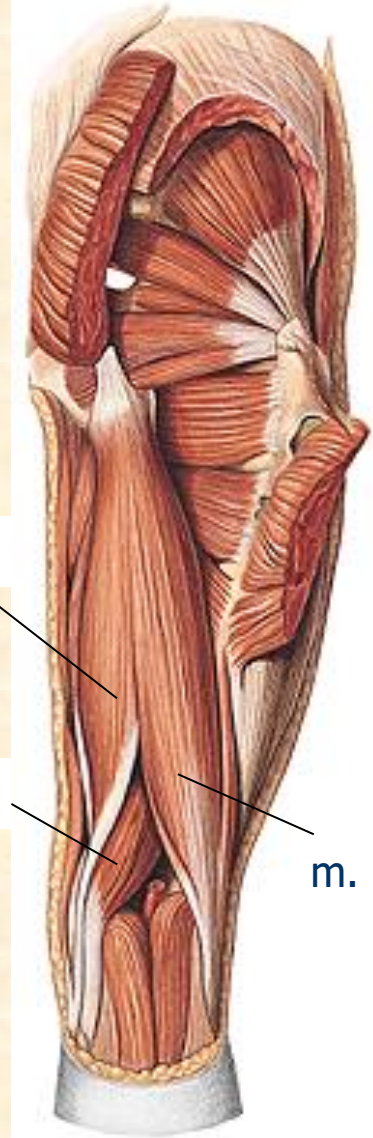
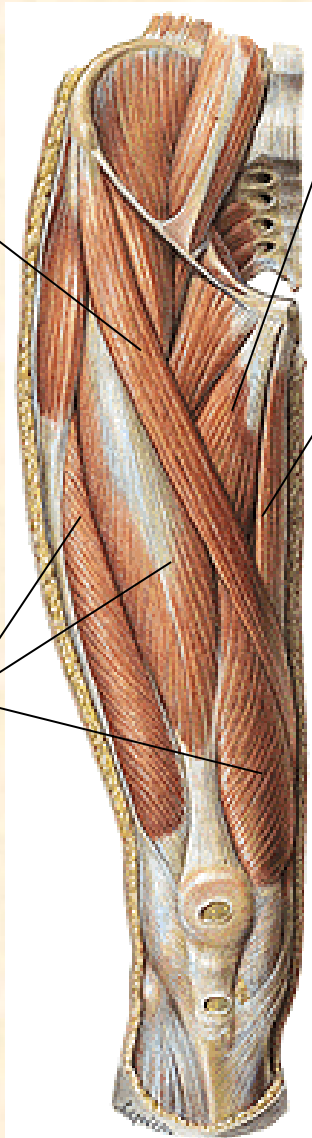
m. gracilis

m. semitendinosus

**m. quadriceps  
femoris**

m. semimembranosus

m. biceps femoris



# LOWER LEG (CRURAL) MUSCLES

m. peroneus longus

m. peroneus brevis

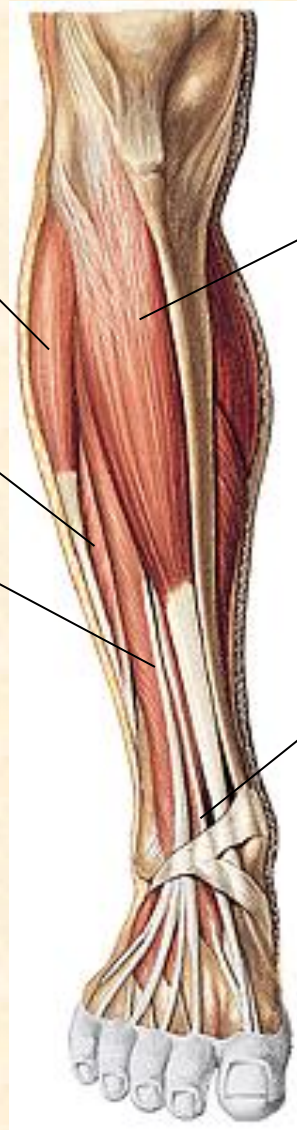
m. extensor digitorum longus

**lateral group**

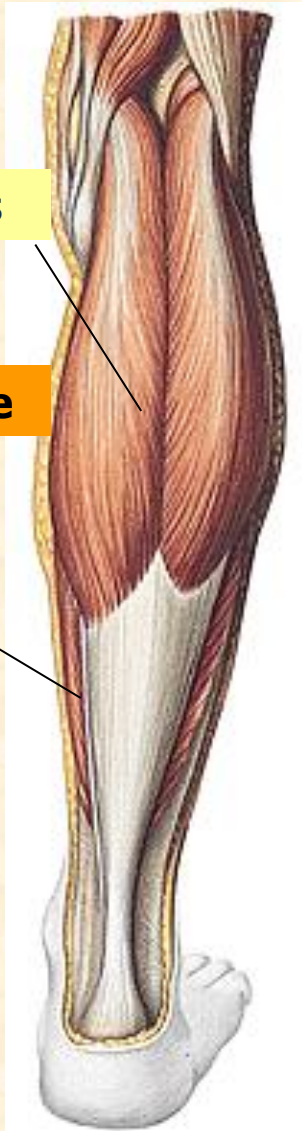**anterior group**

m. tibialis anterior

m. extensor hallucis longus



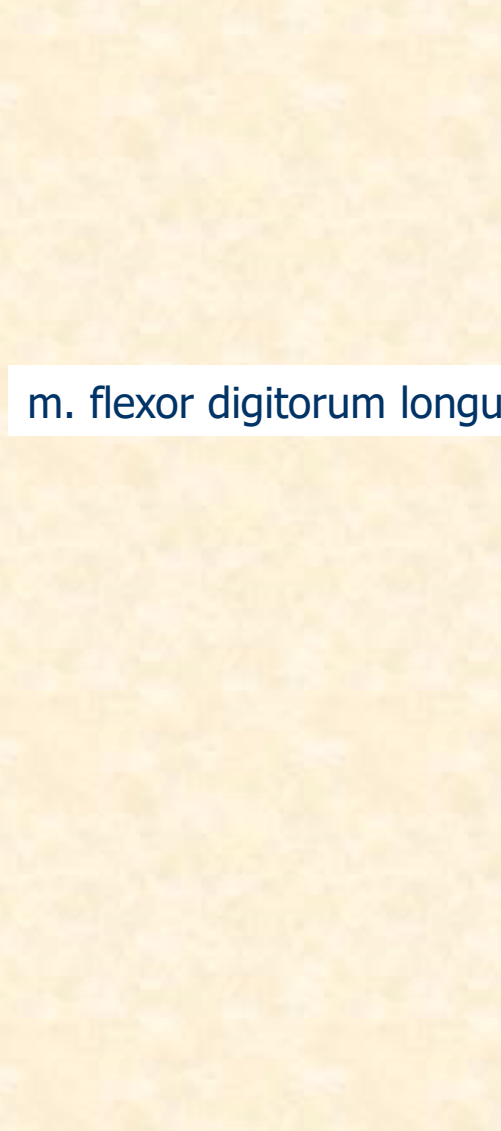
# LOWER LEG MUSCLES – dorsal group



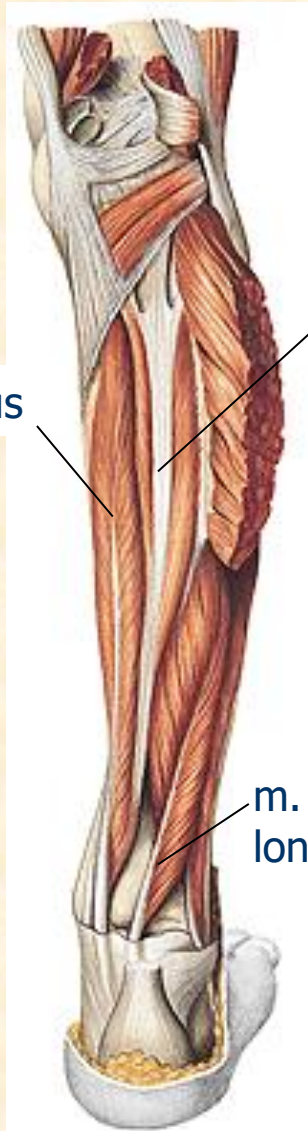
m. gastrocnemius

m. triceps surae

m. soleus



m. flexor digitorum longus



m. tibialis posterior

m. flexor hallucis longus

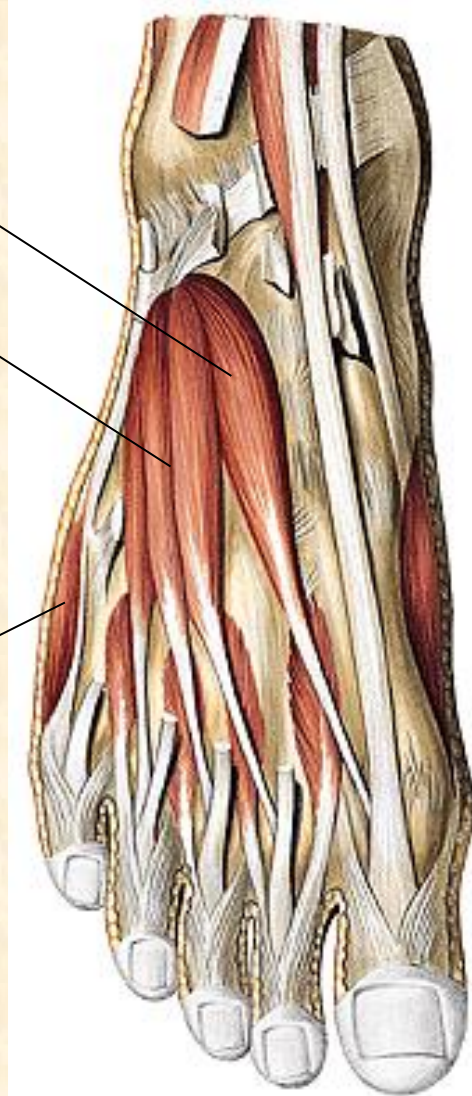
# FOOT MUSCLES

## dorsum

m. extensor hallucis brevis

m. extensor digitorum brevis

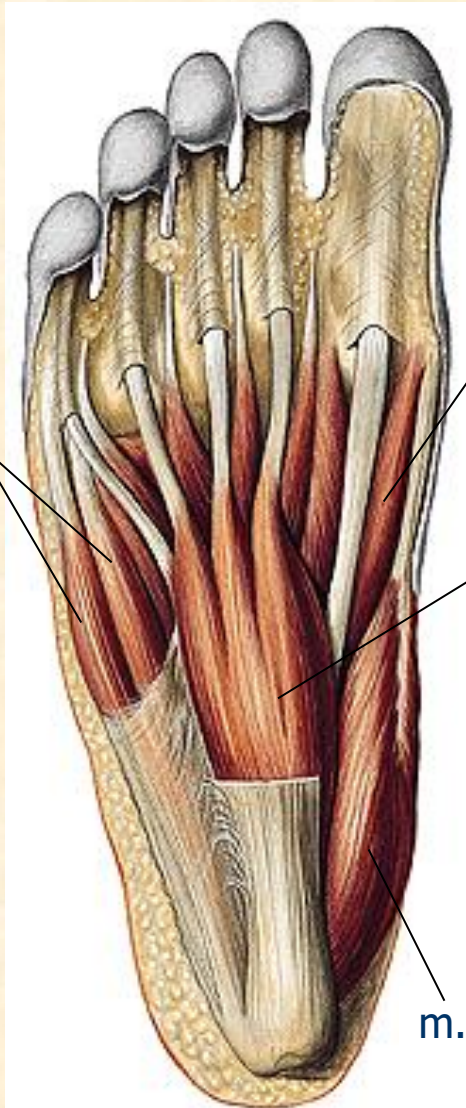
m. abductor digiti minimi



# FOOT MUSCLES (musculi pedis)

## planta

m. flexor et abductor digiti minimi brevis



m. flexor hallucis brevis

m. flexor digitorum brevis

m. abductor hallucis

m. quadratus plantae

