

TOPOGRAPHIC
ANATOMY OF THE
THORAX

seminar from Human Morphology
17. 10. 2024

M. Chalupová



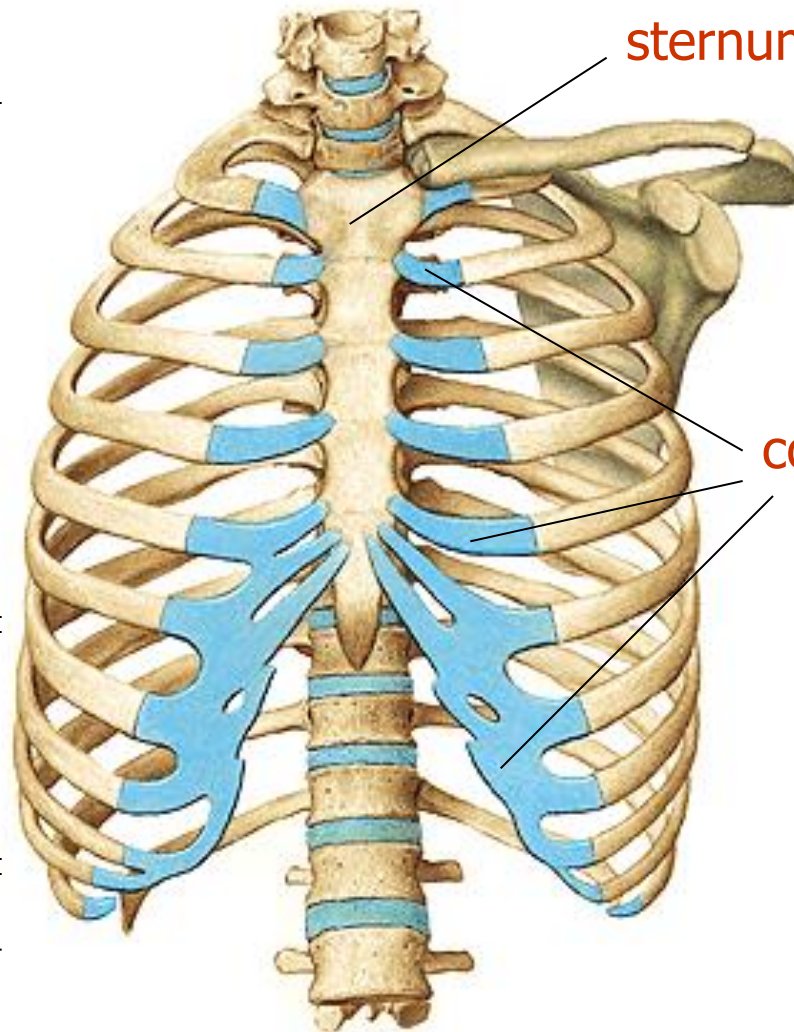
TOPOGRAPHIC ANATOMY

- the study of anatomy based on regions or divisions of the body and emphasizing the relations between various structures (muscles, nerves, arteries, etc.) in that region
 - surface anatomy
 - cross-sectional anatomy
- it is a basis for special surgical anatomy

TOPOGRAPHIC ANATOMY OF THE THORAX

- **the upper border** of the thorax against the neck leads from the fossa jugularis along the clavicle to the acromion and back to the C7 process (vertebra prominens)
- **the lower border** against the abdomen leads from the processus xiphoideus along the lower edges of the ribs to the plane guided by the spinous process Th12
- **the deep lower boundary** is the diaphragm (right diaphragm dome in the plane of the 4th intercostal space, left 5th intercostal space)
- the base of the chest is a bony skeleton - **thorax**

SKELETON OF THORAX



sternum

true ribs I–VII

costal cartilages

false ribs VIII–X

floating ribs
XI–XII

TRACHEA PROJECTION onto the anterior thoracic wall

trachea

right **MAIN** bronchus

left **MAIN** bronchus

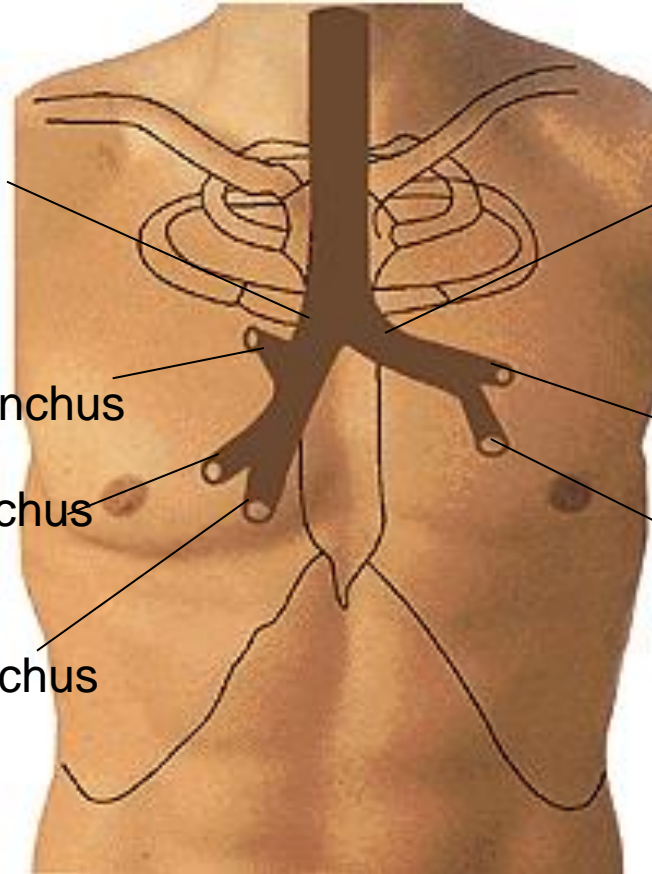
right superior **LOBAR** bronchus

left superior **LOBAR** bronchus

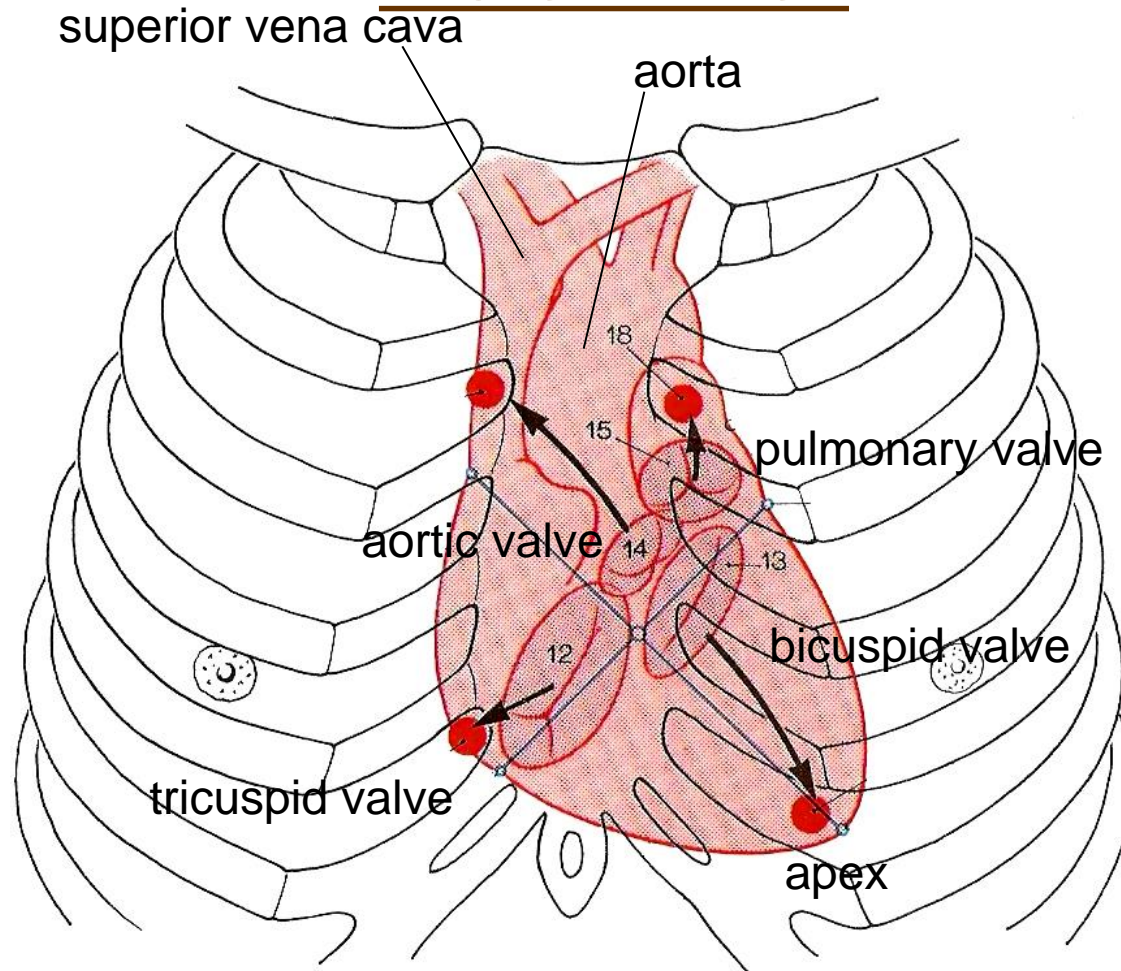
right middle **LOBAR** bronchus

left inferior **LOBAR** bronchus

right inferior **LOBAR** bronchus

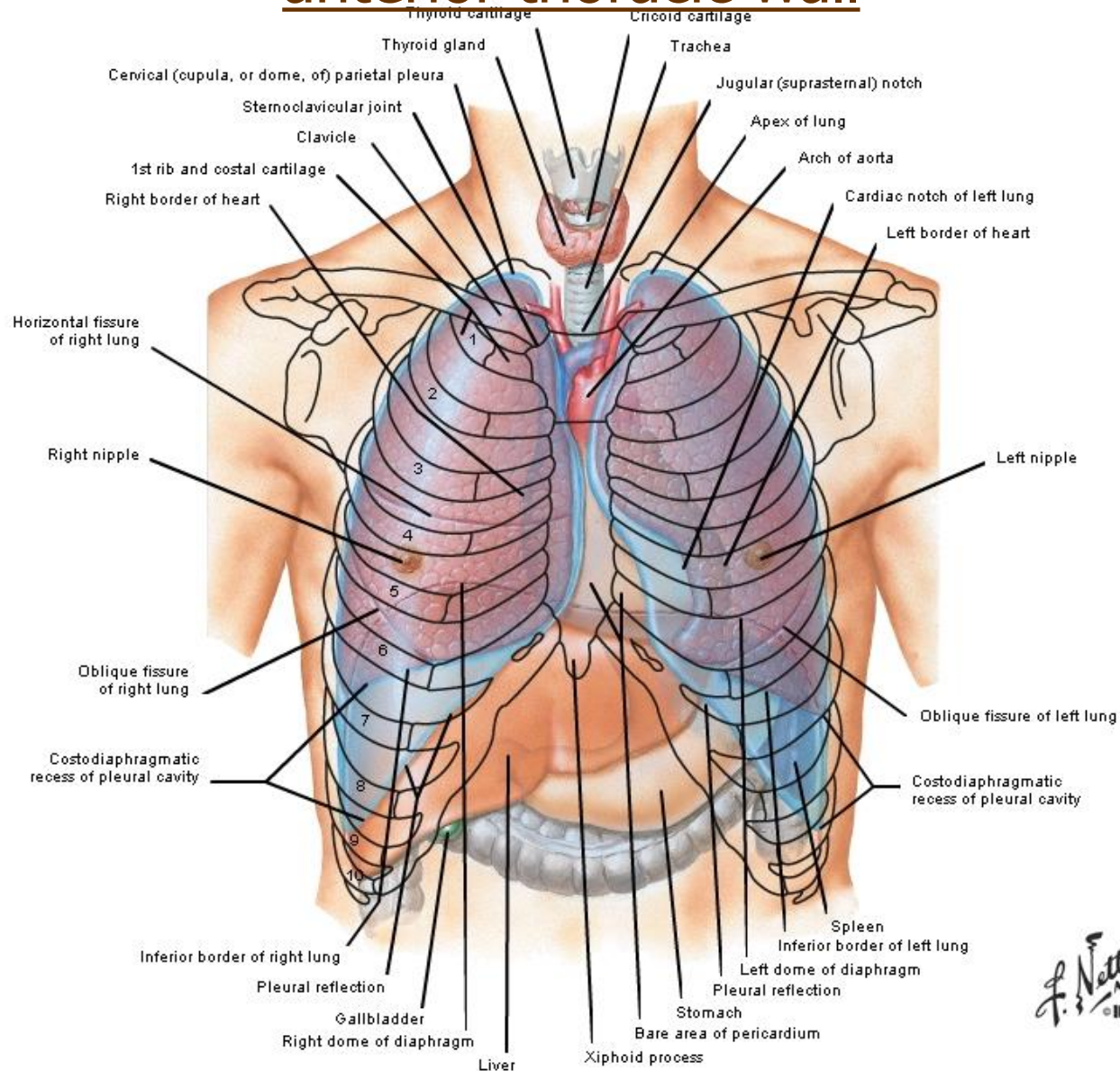


HEART PROJECTION onto the anterior thoracic wall



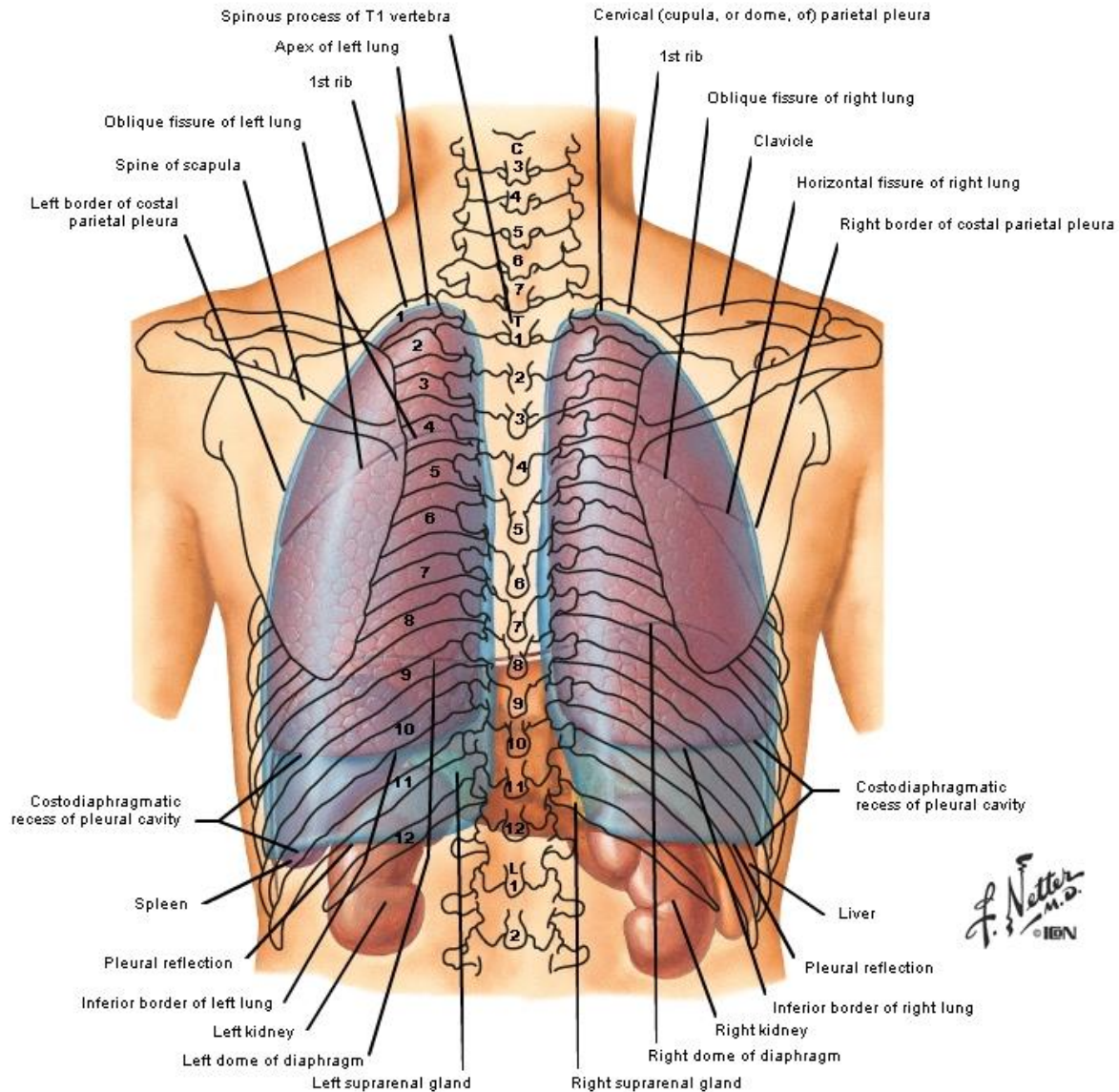
LUNGS AND PLEURA PROJECTION

anterior thoracic wall

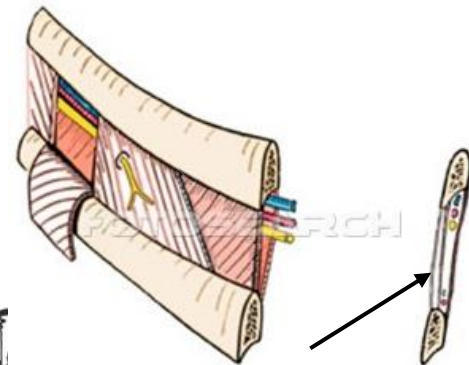
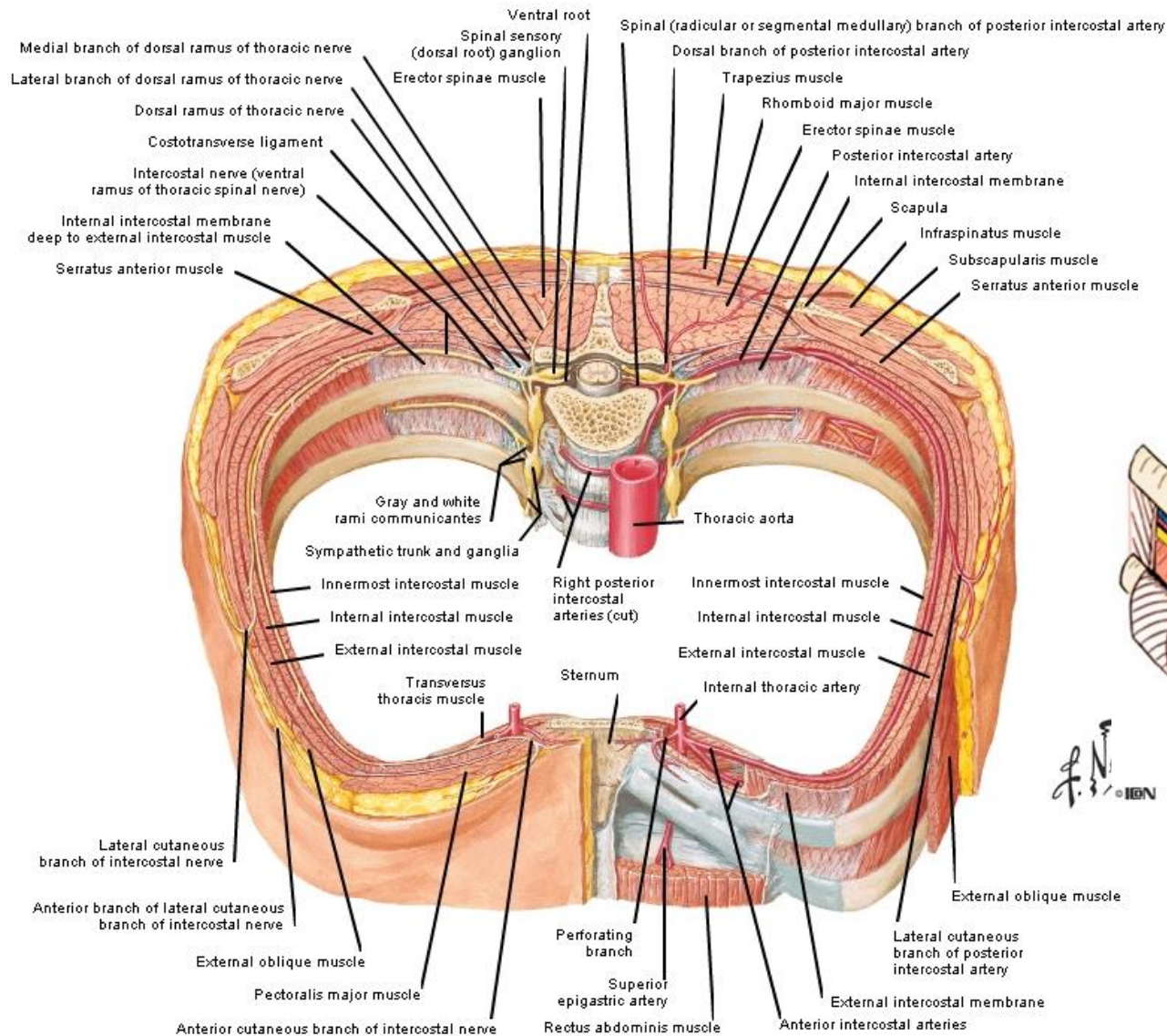


F. Netter M.D.
© IBN

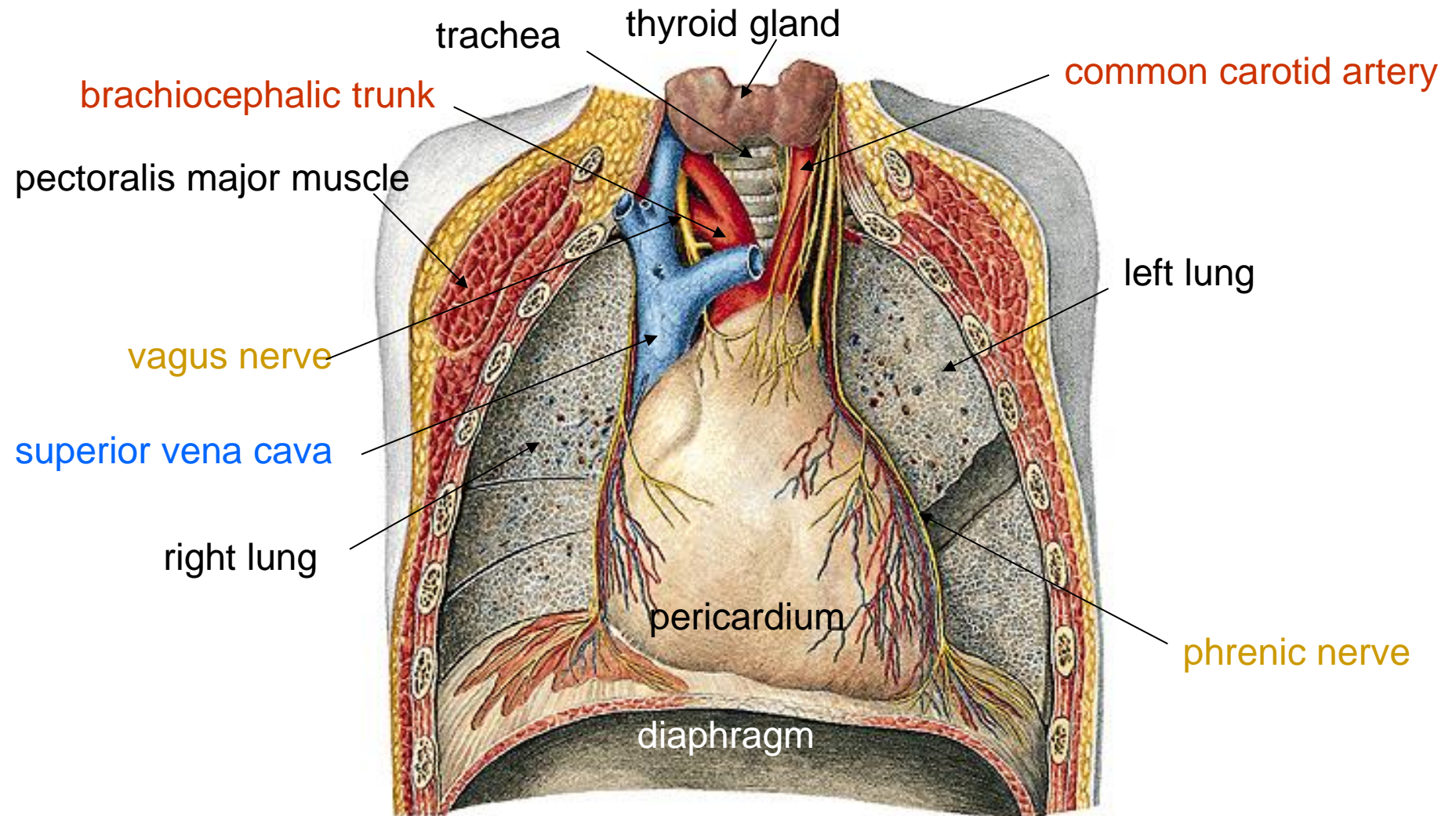
LUNG AND PLEURA – posterior thoracic wall



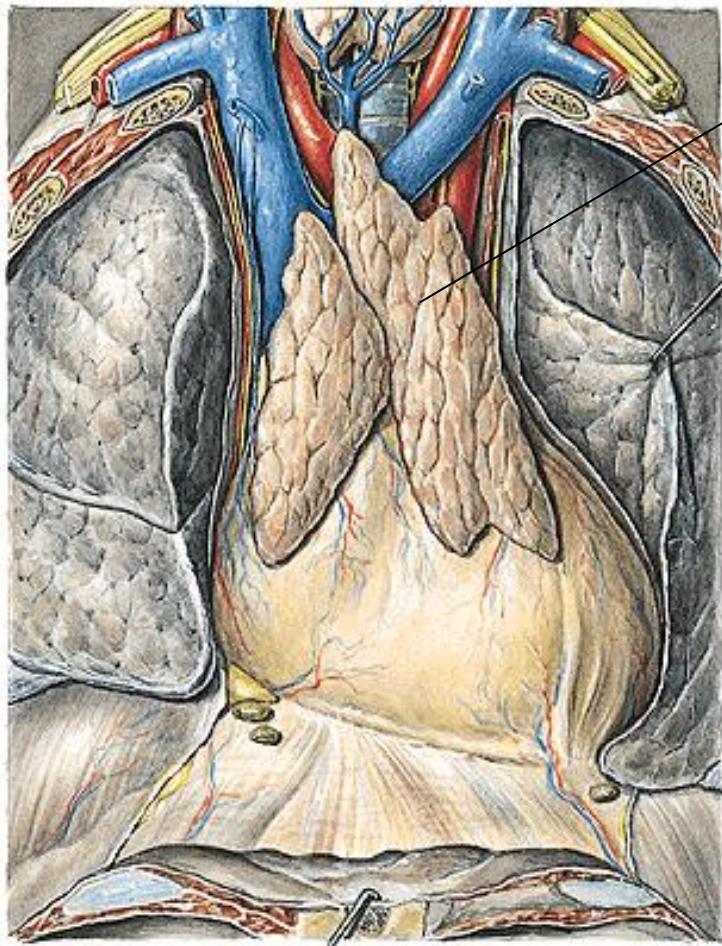
THORACIC WALL



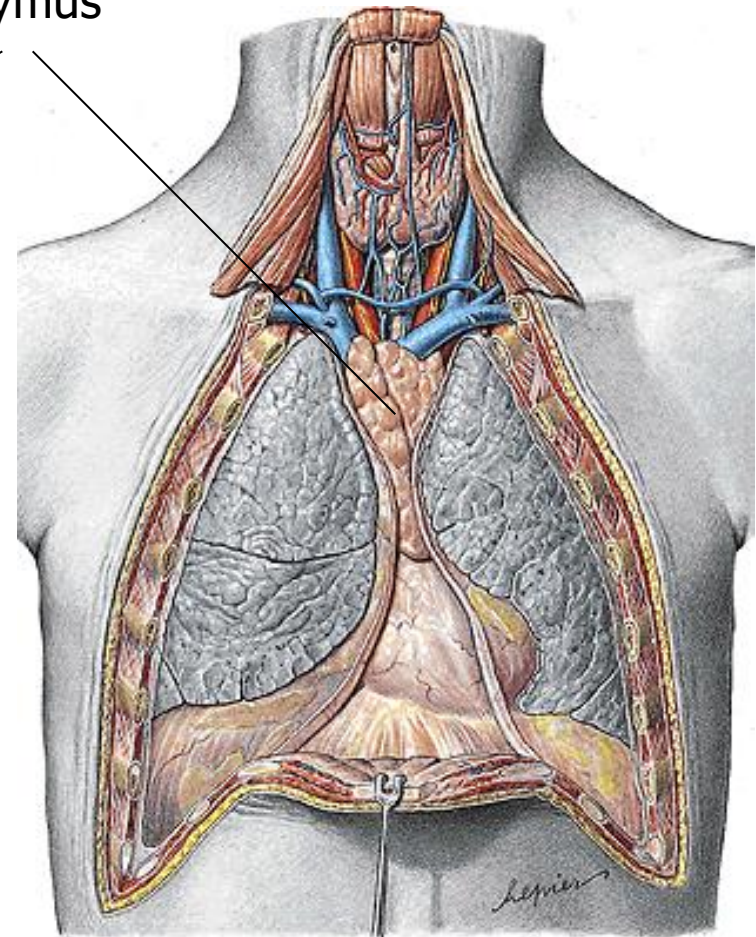
THORACIC CAVITY



THORACIC CAVITY – adolescent

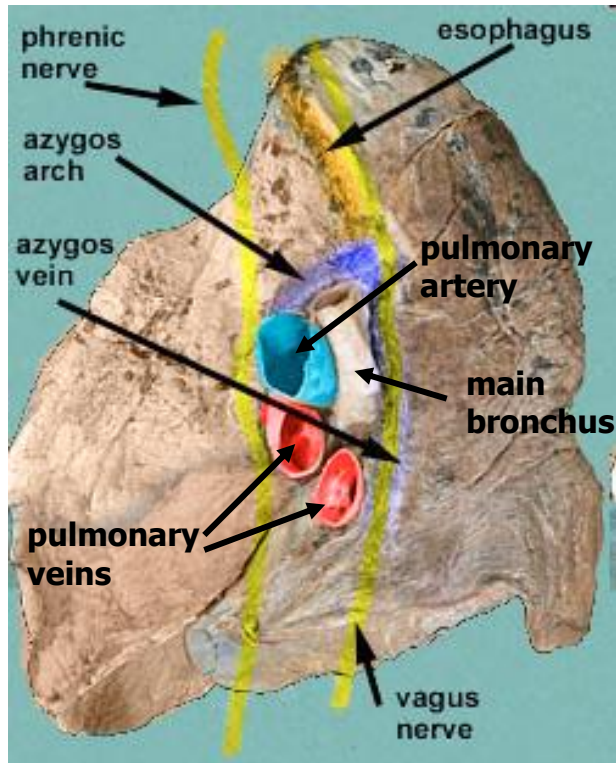


thymus

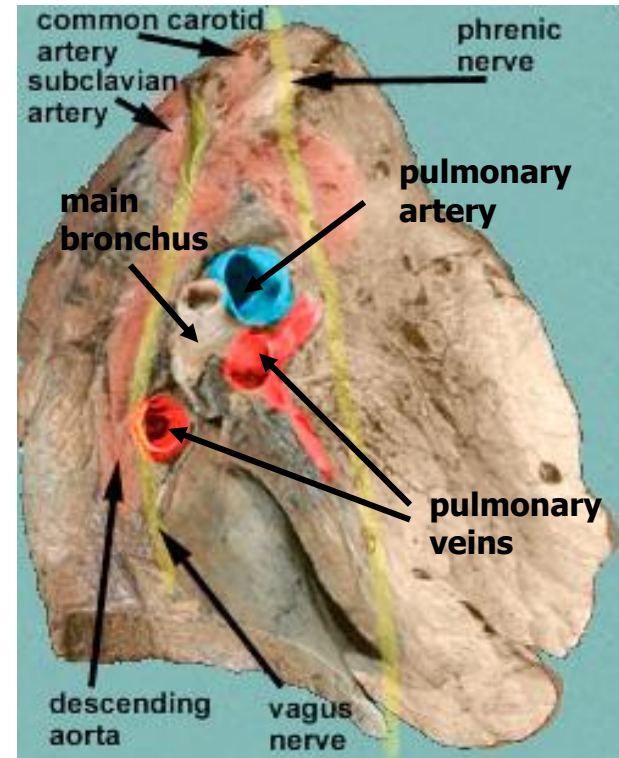


TOPOGRAPHY OF LUNG ROOTS (HILA)

■ right lung root

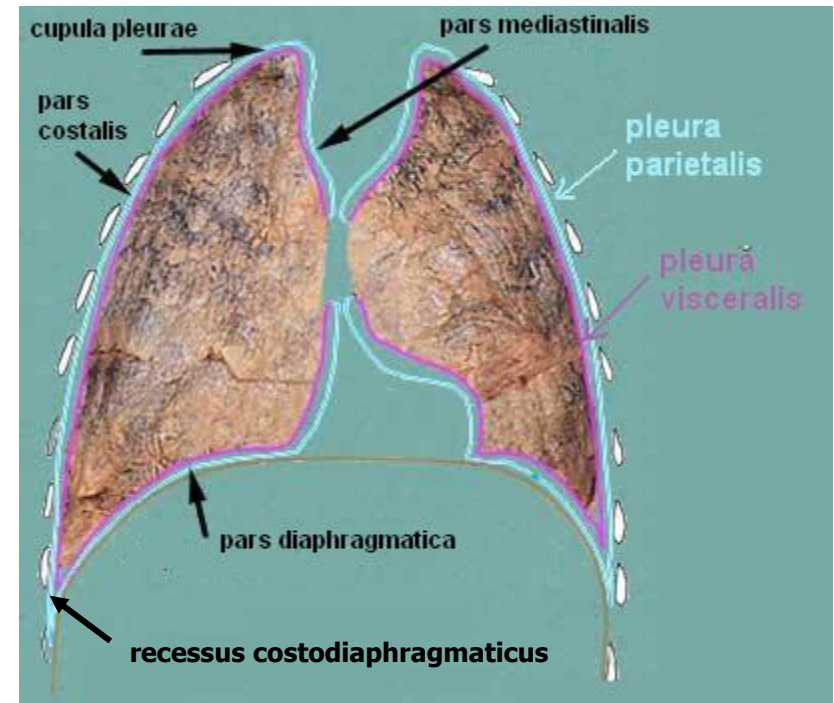
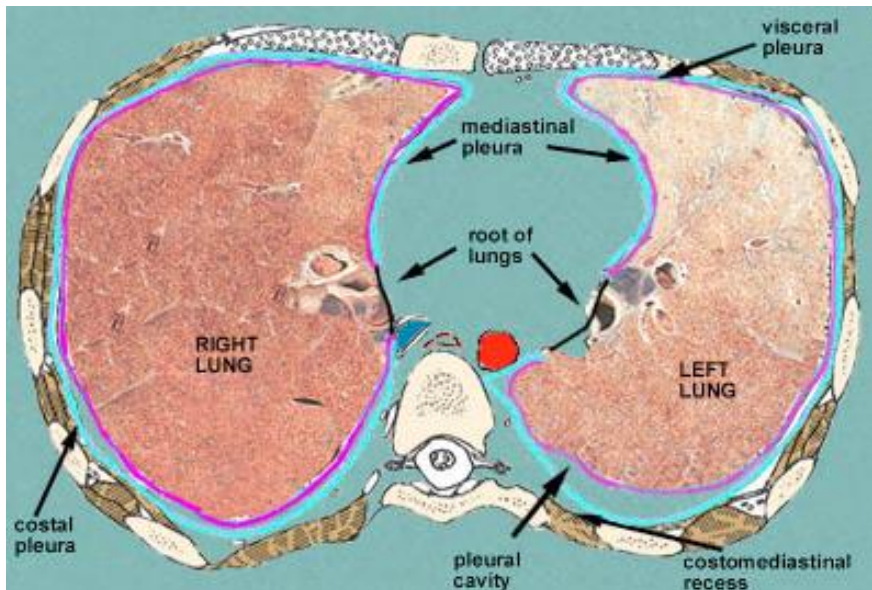


■ left lung root



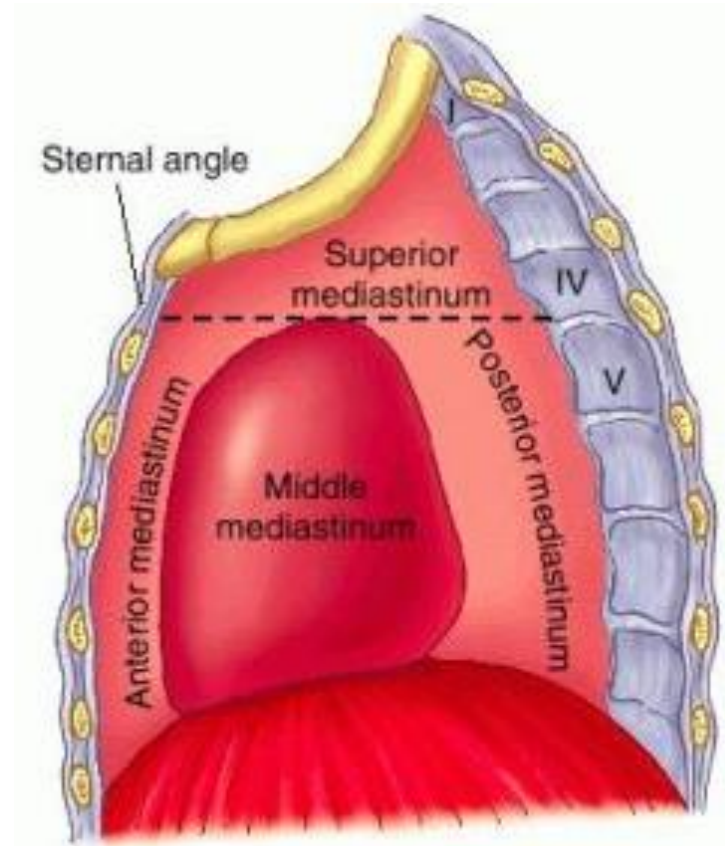
PLEURA, PLEURAL CAVITY

- **pleura** – a serous membrane which folds back upon itself to form a two-layered, membrane structure, covered by one-layer epithelium – mesothelium
 - inner pleura (visceral pleura)
 - outer pleura (parietal pleura)
- } **pleural cavity (cavum pleurae)**

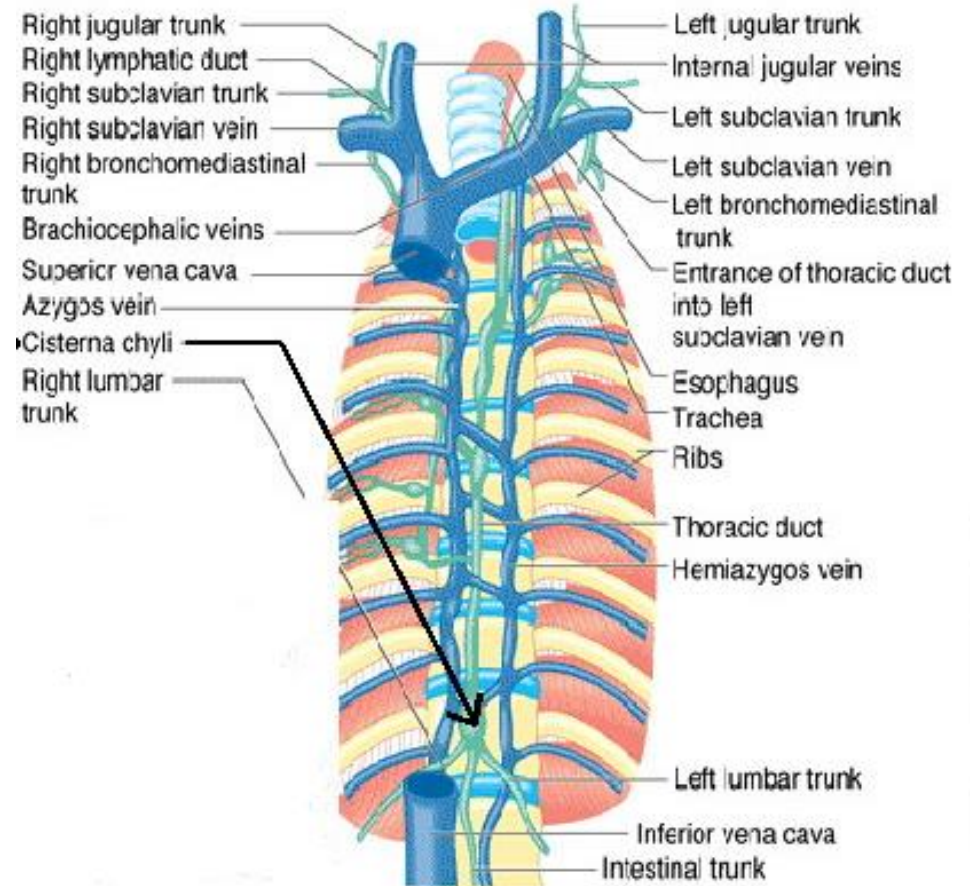
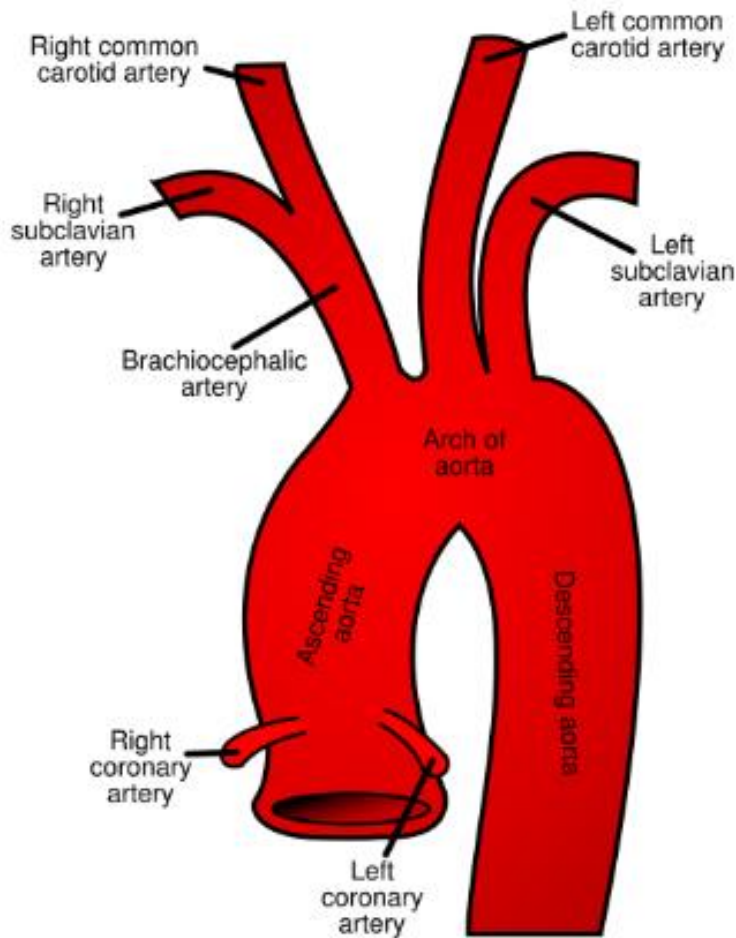


MEDIASTINUM

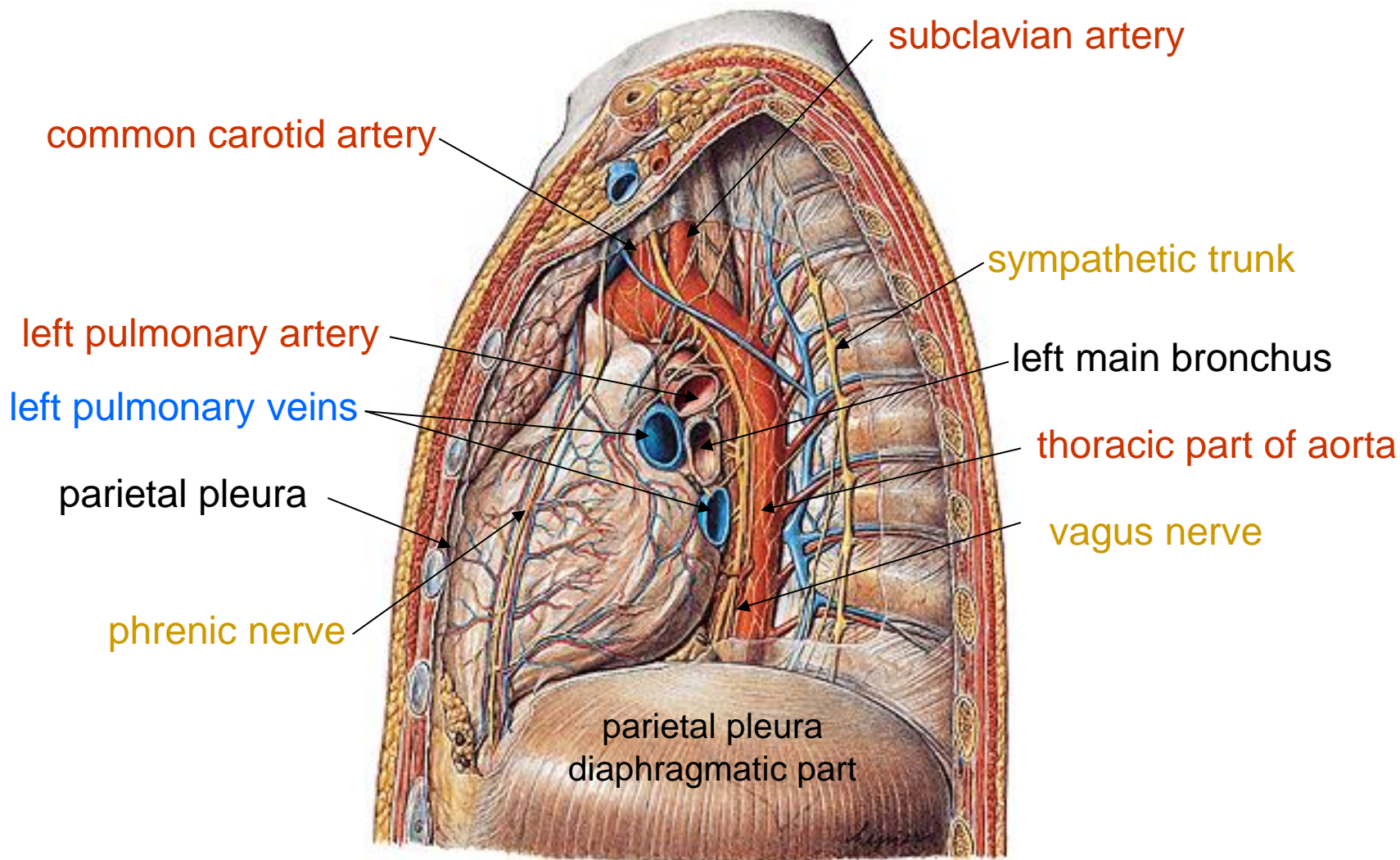
- mediastinum = group of structures in the thorax, the central compartment of the thoracic cavity
 - **middle mediastinum** – contains the heart in the pericardium
 - **anterior mediastinum** – space between pericardium and sternum, contains connective tissue and lymph nodes
 - **superior mediastinum** – contains thymus, superior vena cava, ascending aorta, trachea and esophagus, phrenic and vagus nerves, sympathetic trunk, thoracic duct, lymph nodes
 - **posterior mediastinum** – esophagus, thoracic part of descending aorta, vagus nerves, veins, thoracic duct, sympathetic trunk



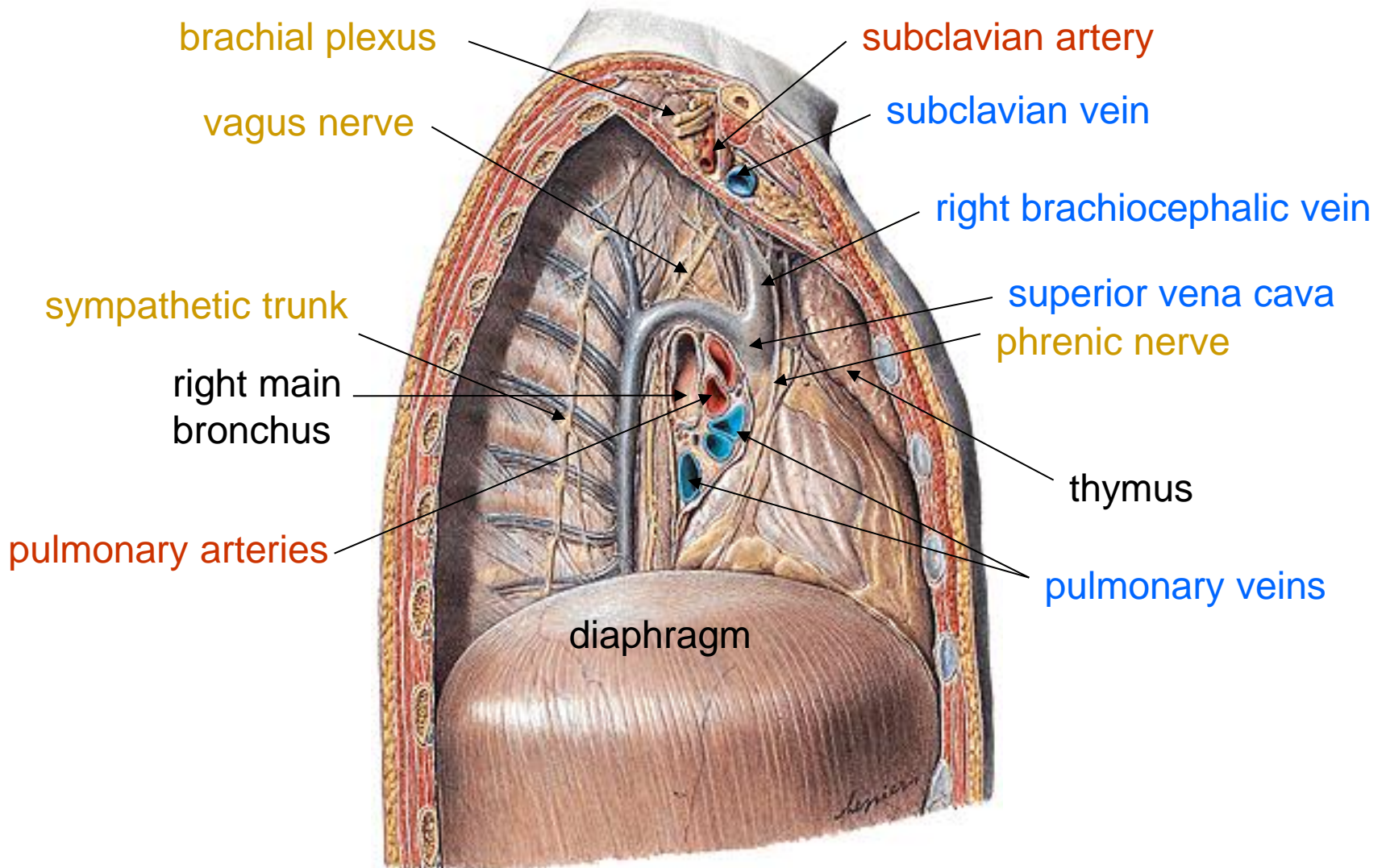
TOPOGRAPHY OF ARCUS AORTAE AND V. CAVA SUP.



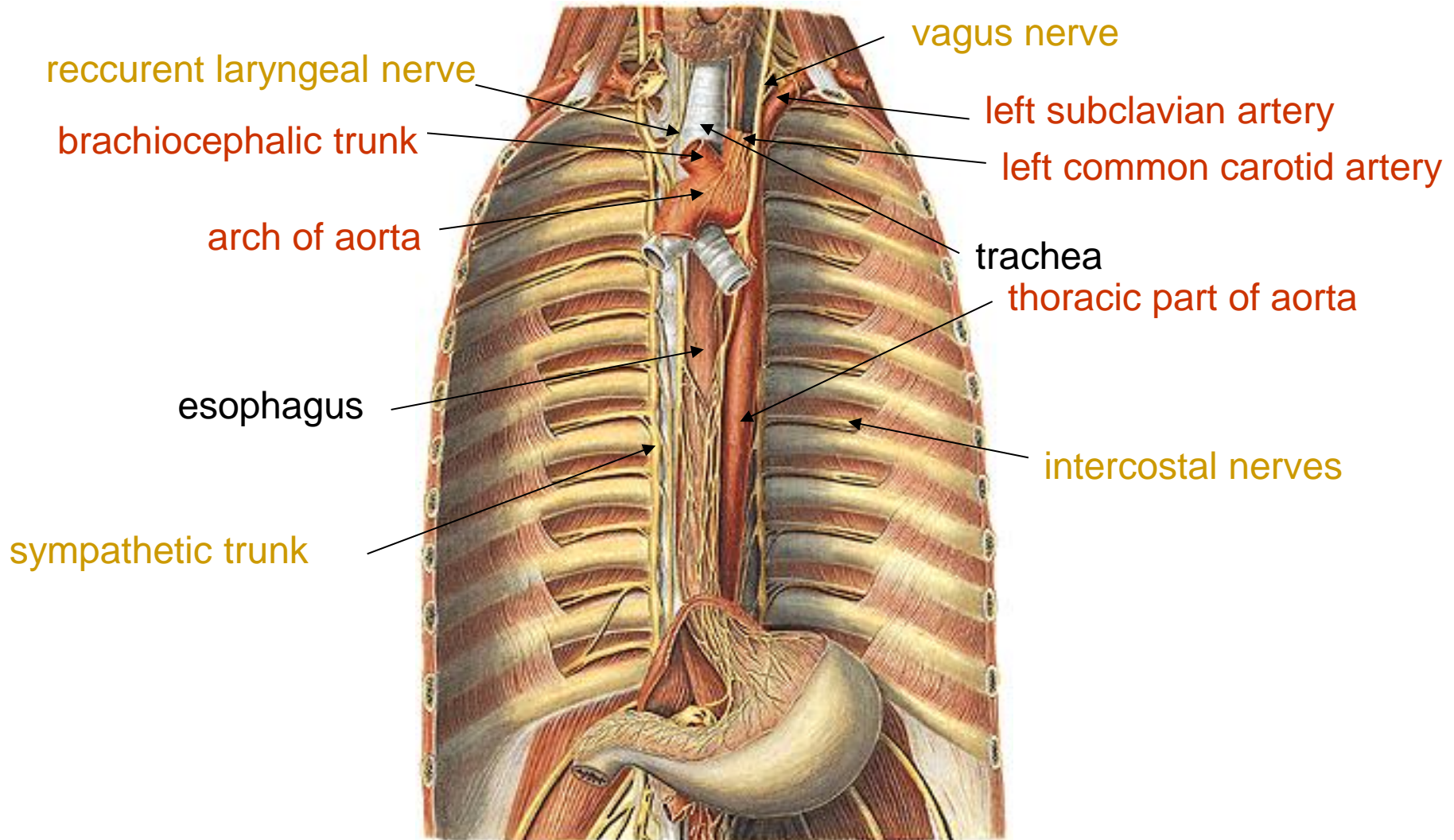
PLEURAL CAVITY, MEDIASTINUM left view



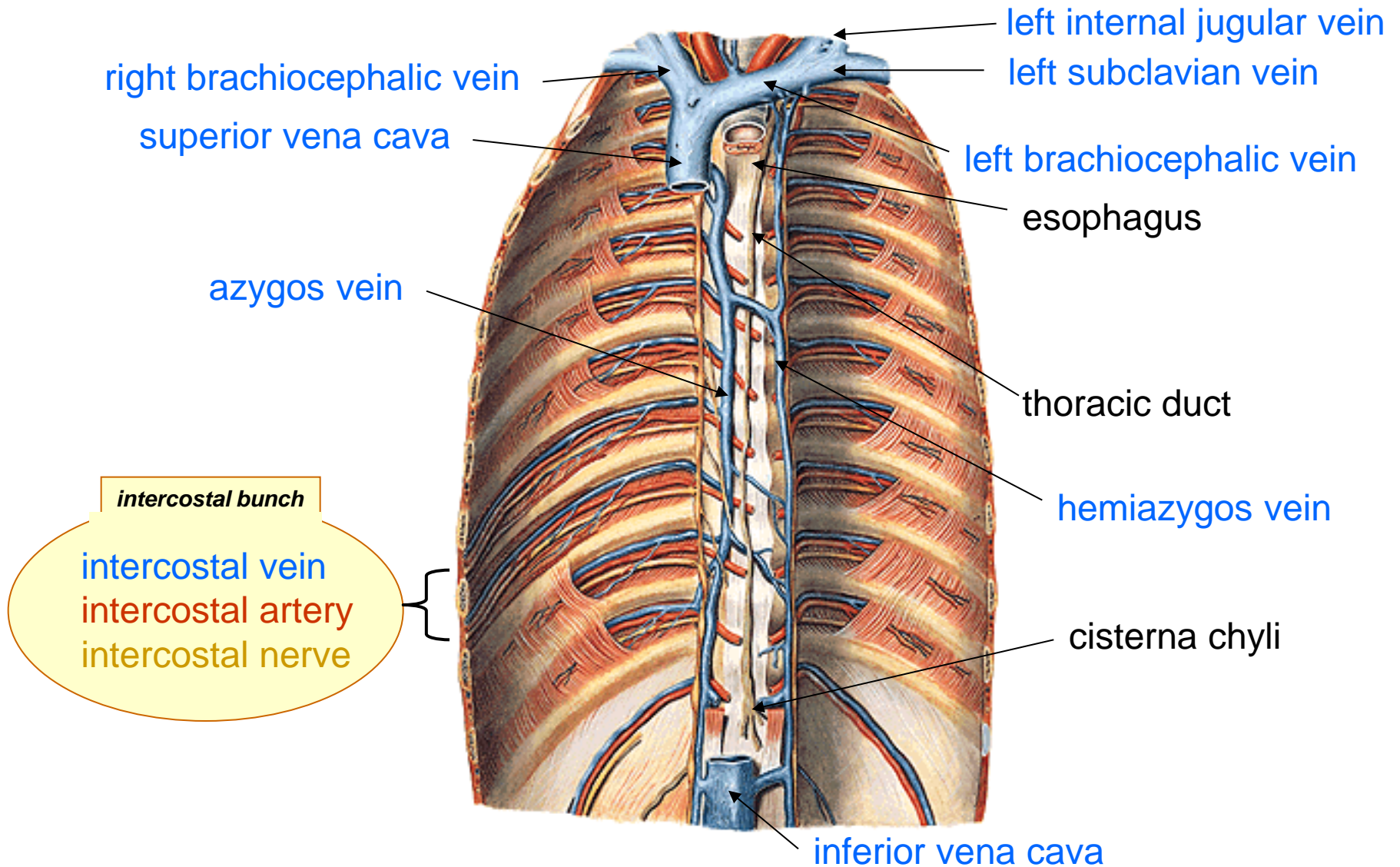
PLEURAL CAVITY, MEDIASTINUM right view



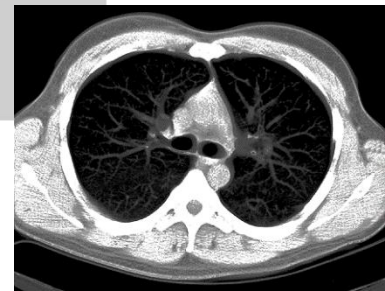
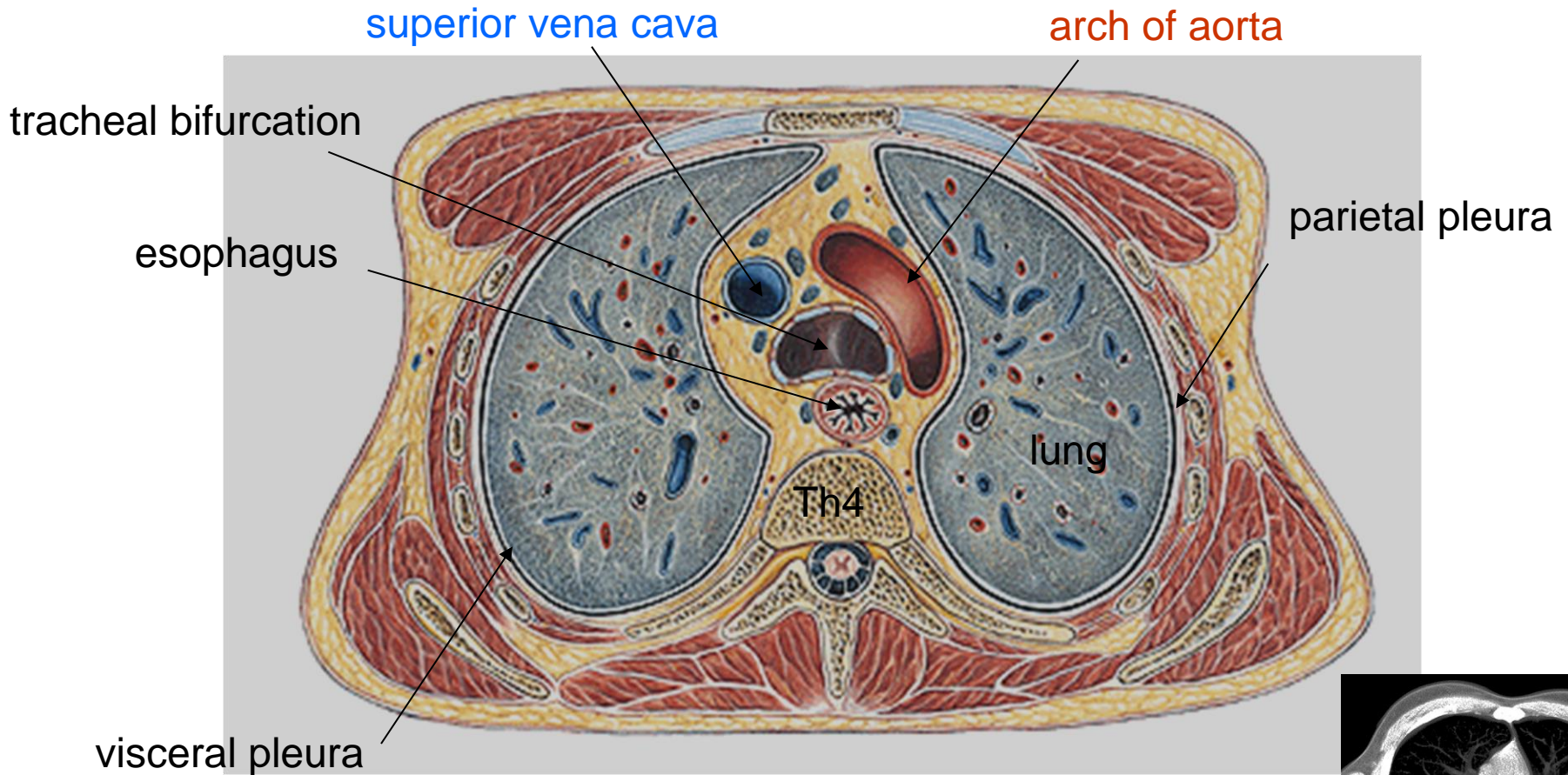
POSTERIOR MEDIASTINUM



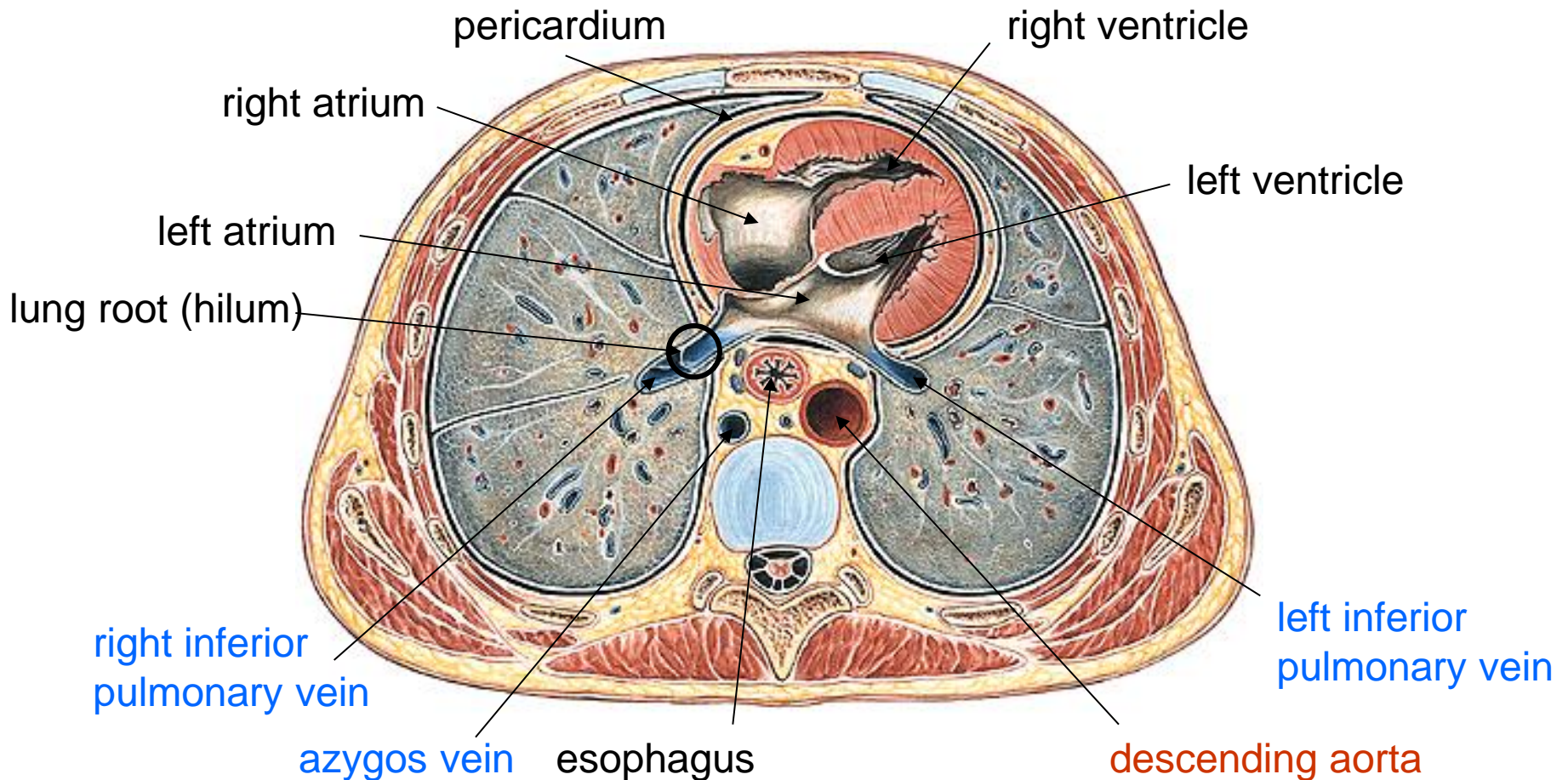
POSTERIOR MEDIASTINUM



Cross section through the thorax in tracheal bifurcation – Th4



Cross section through thorax at lung hila



Cross section through the thorax at vertebra Th9

