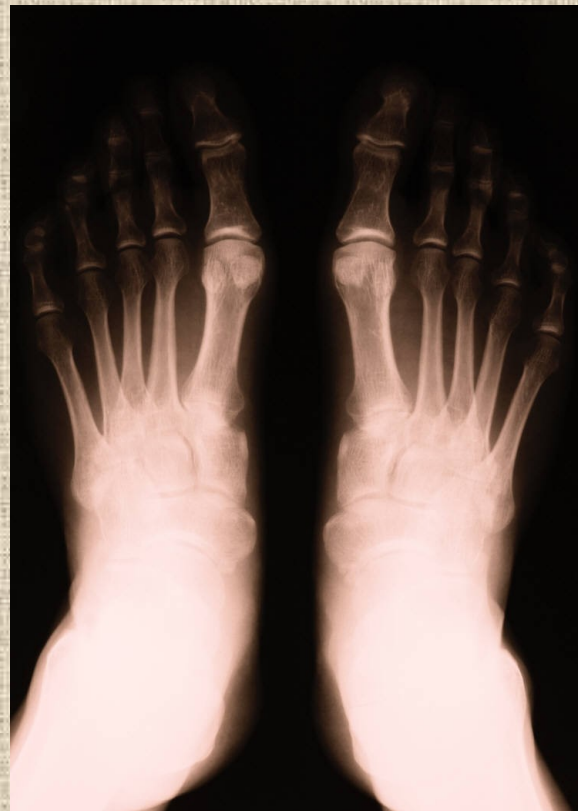

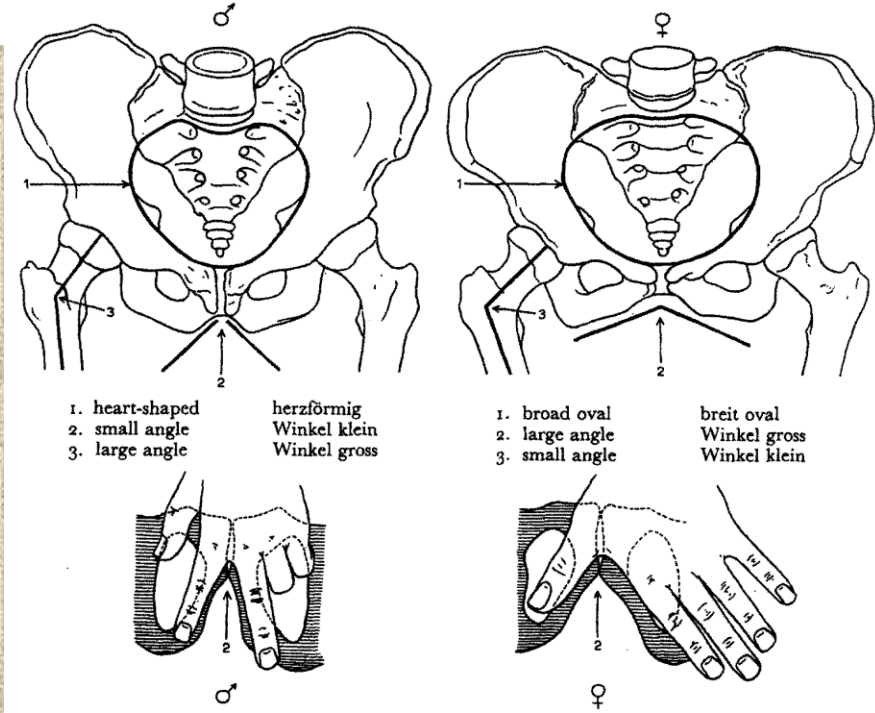
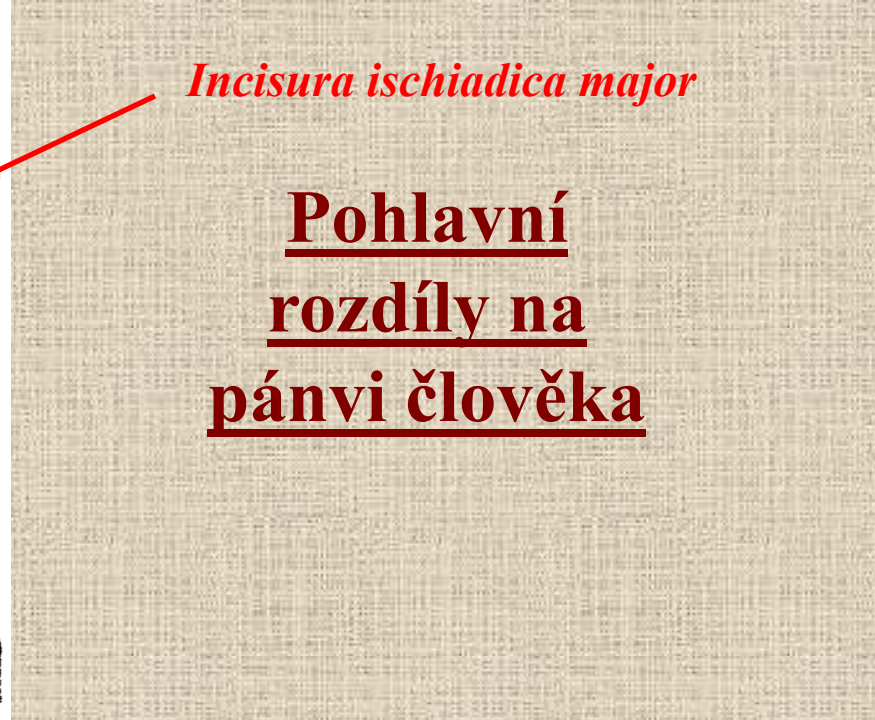
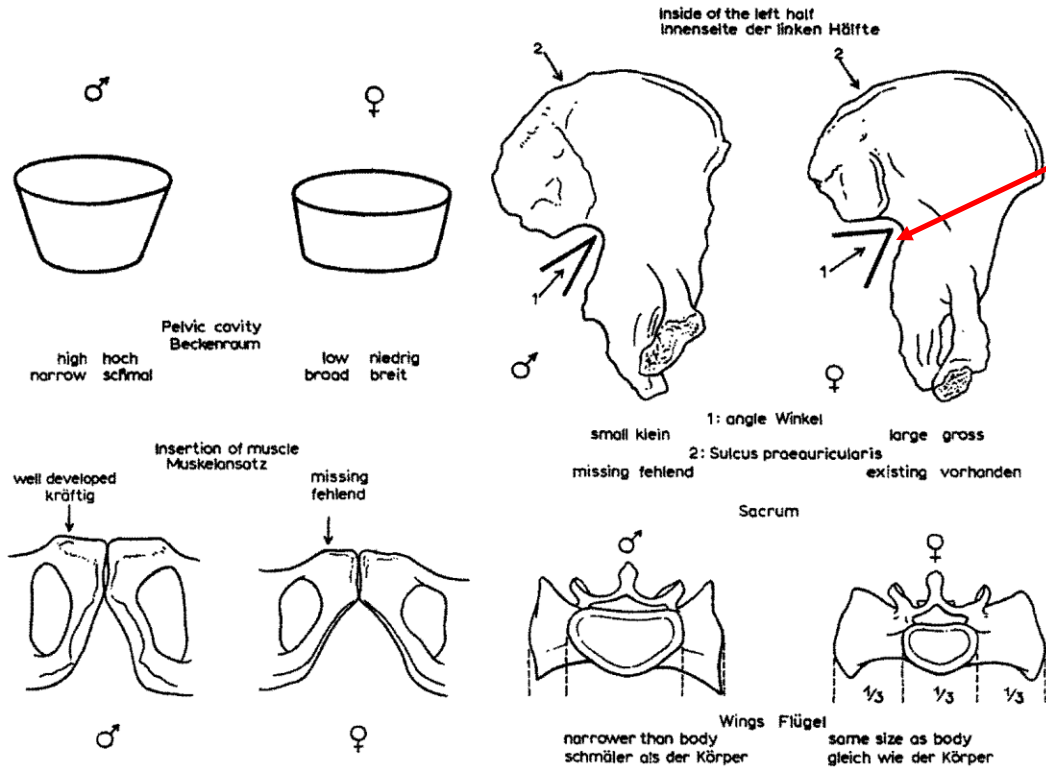
# Základy osteologie

Pánev a kosti zadní končetiny

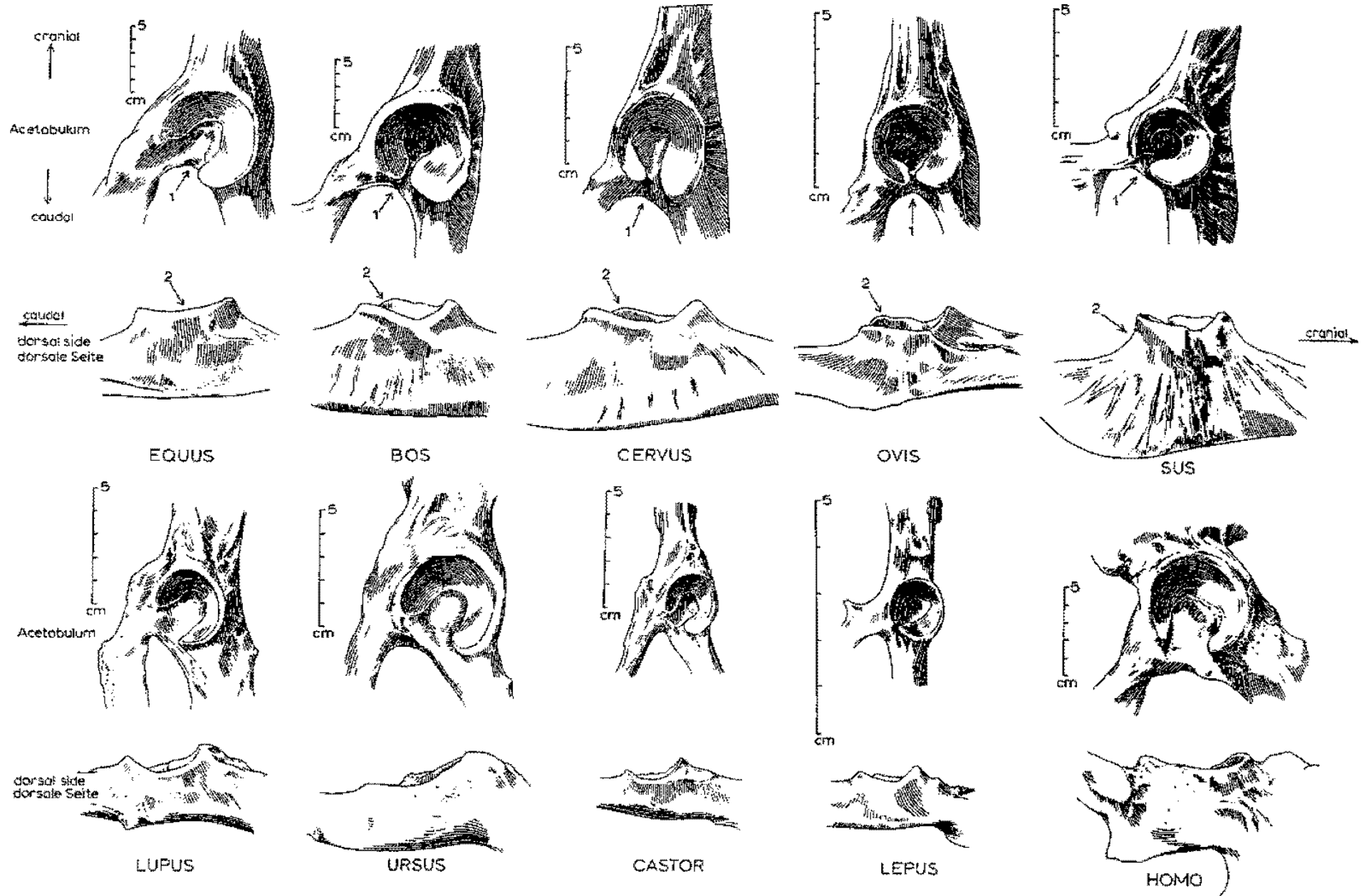


*Incisura ischiadica major*

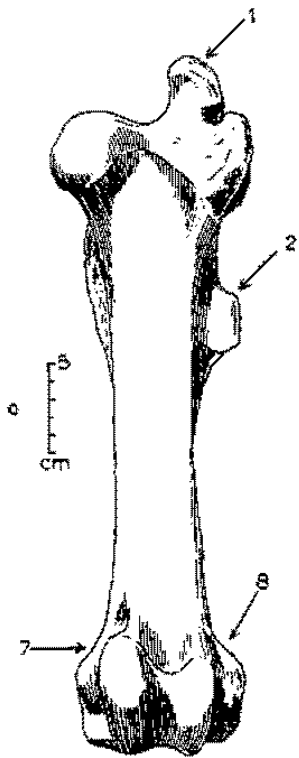
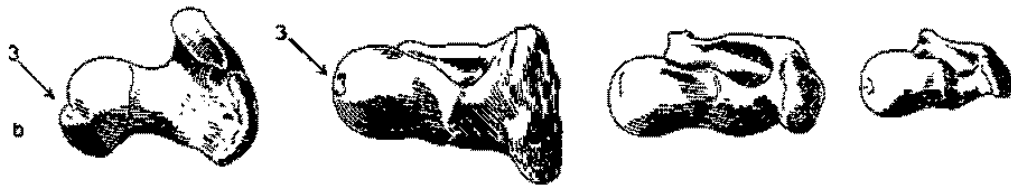
**Pohlavní rozdíly na pánvi člověka**



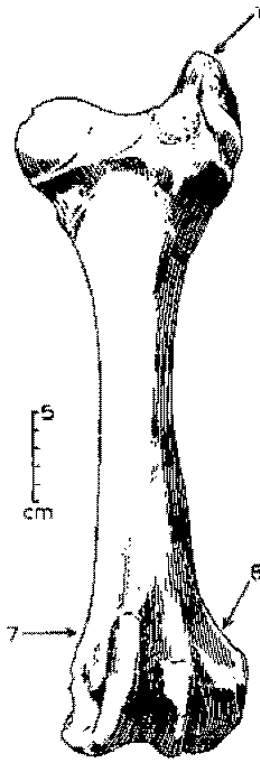
# Pánve



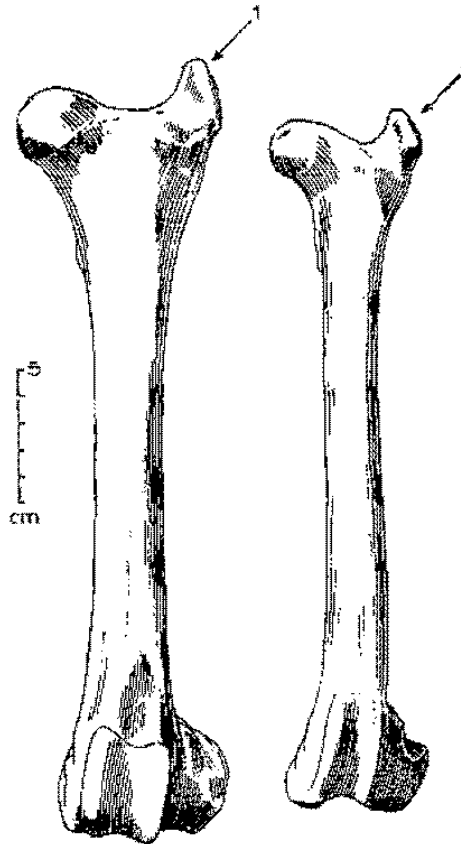
# Stehenní kosti (*femur*)




EQUUS



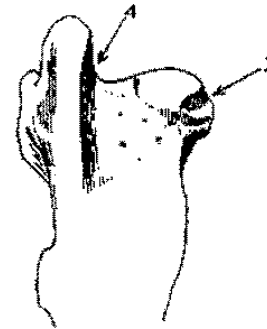
BOS



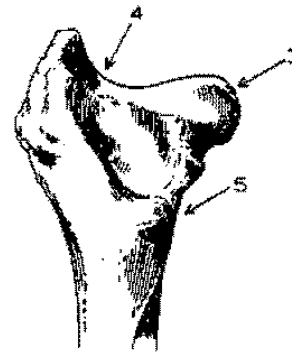
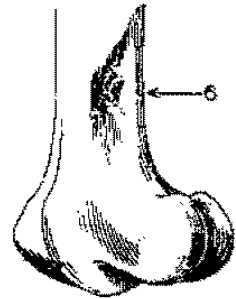
CERVUS



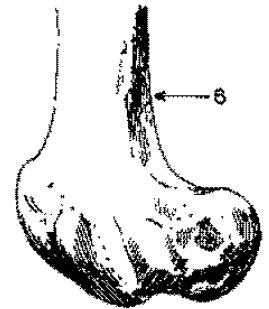
OVIS



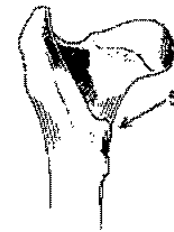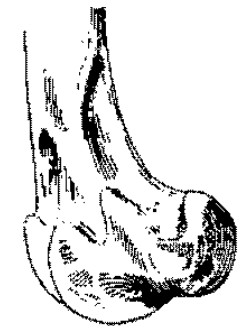
EQUUS



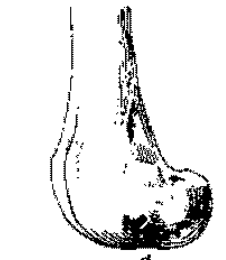
BOS



CERVUS



cm

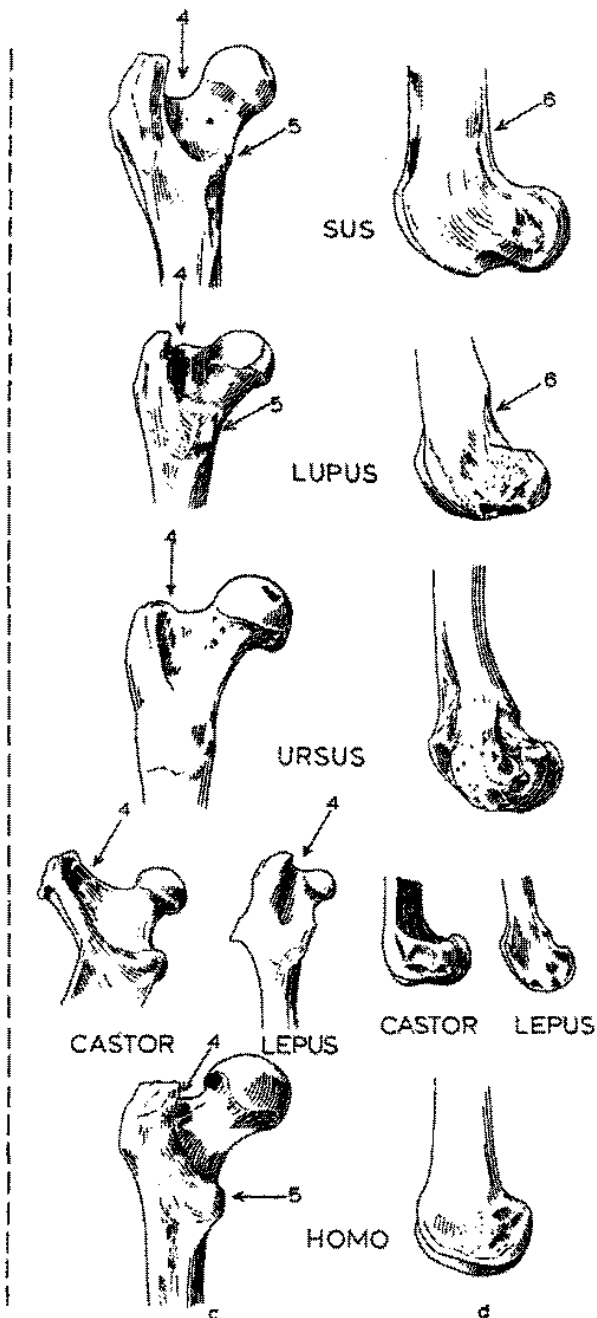
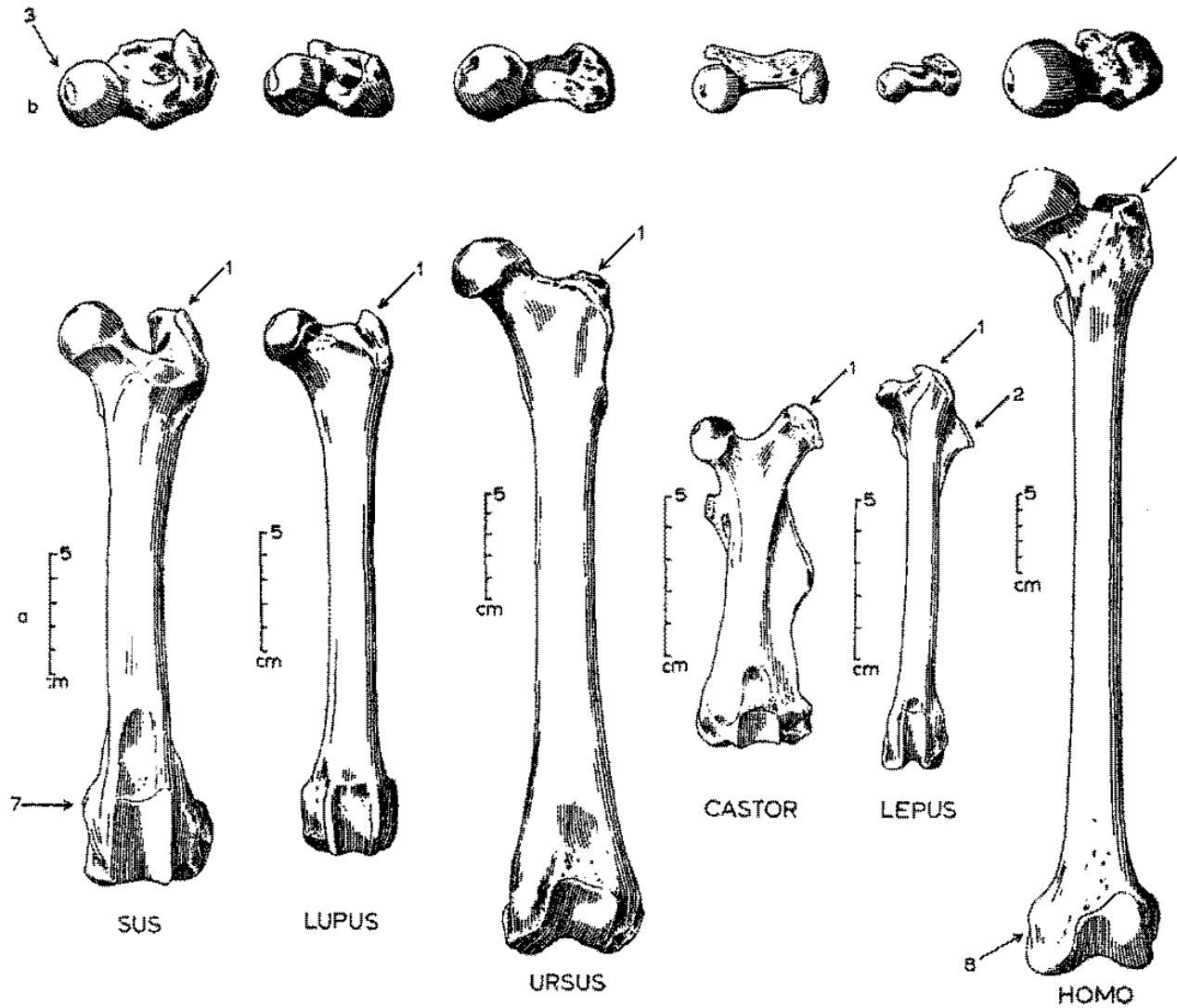


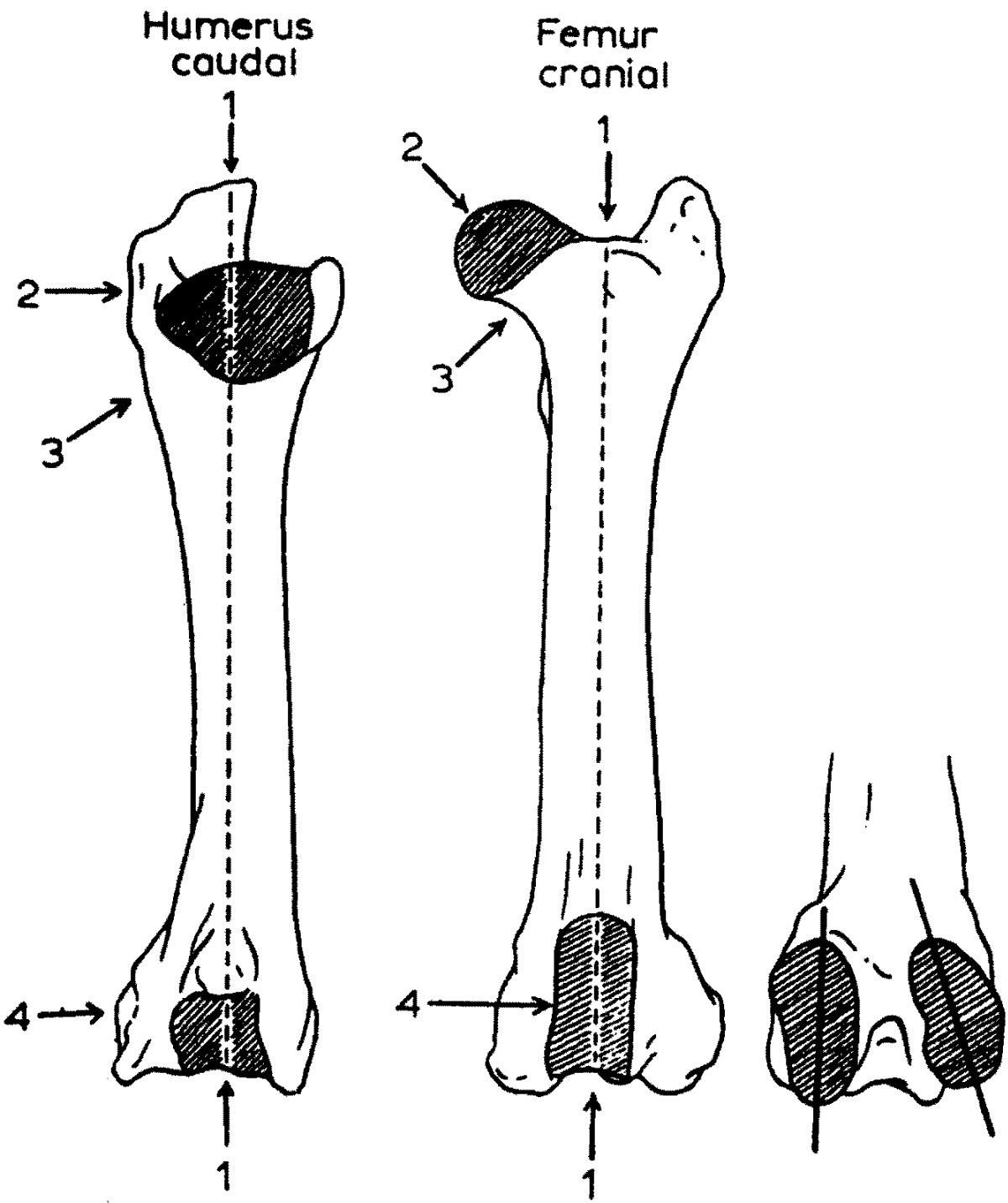
OVIS

c

d

# Stehenní kosti (femur)

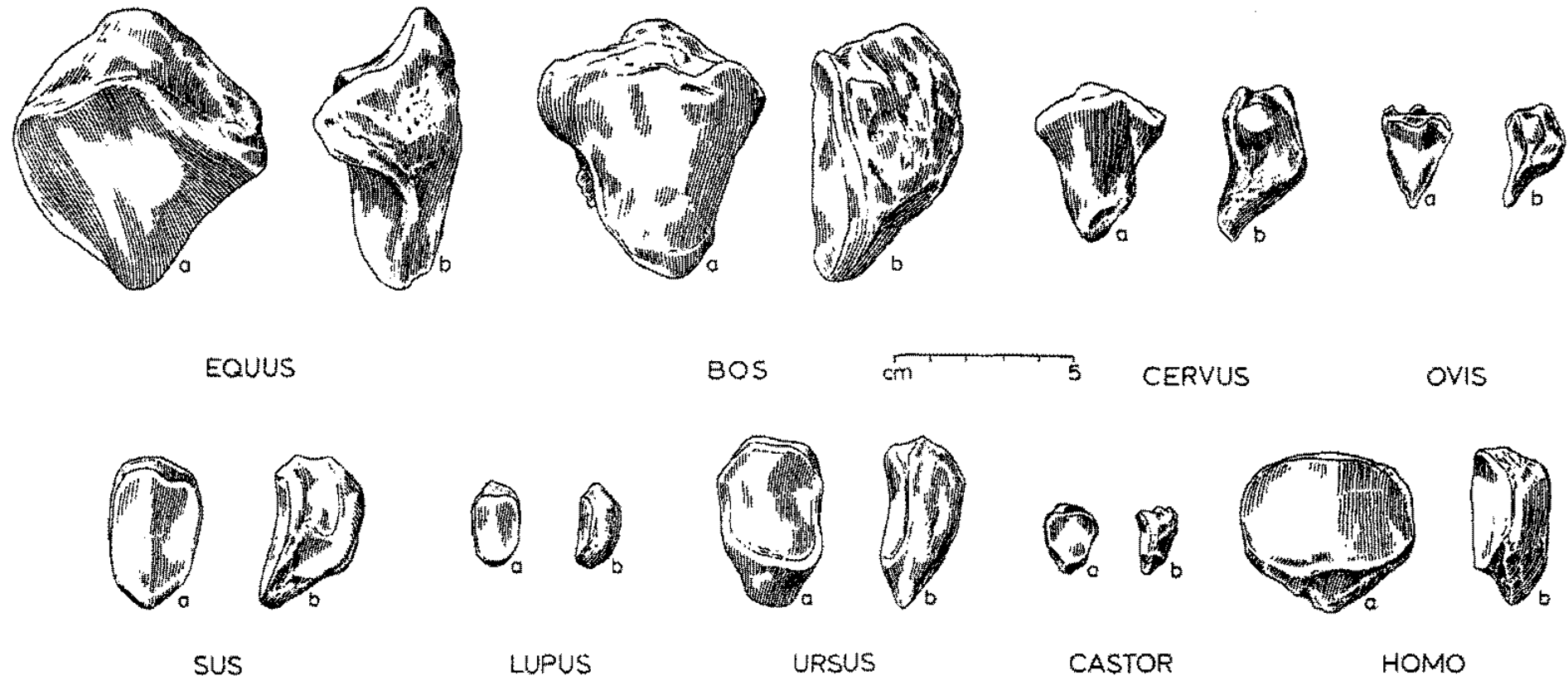




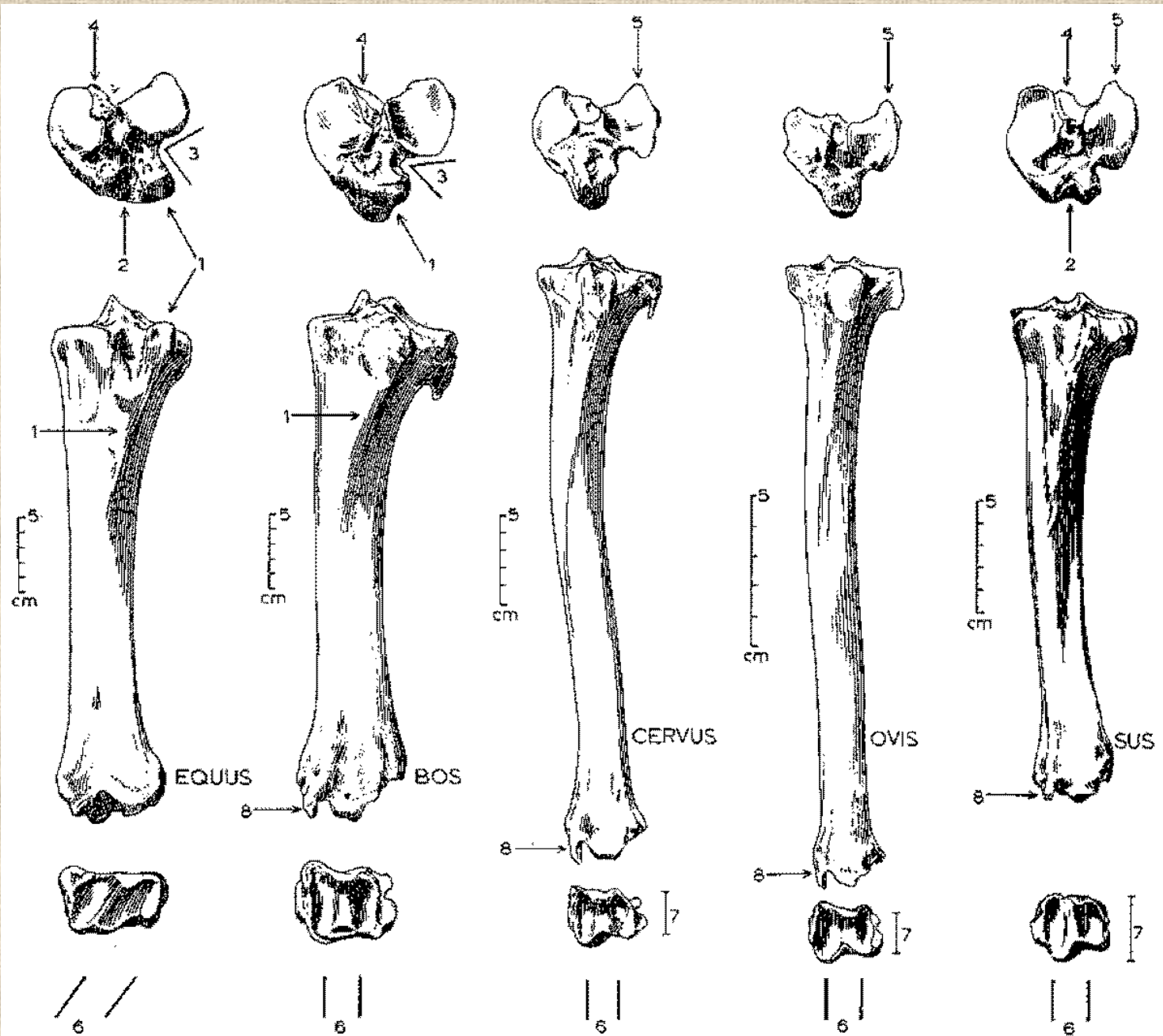
**Jak rozeznat stehenní**  
**a pažní kost**



# Češka (*patella*)

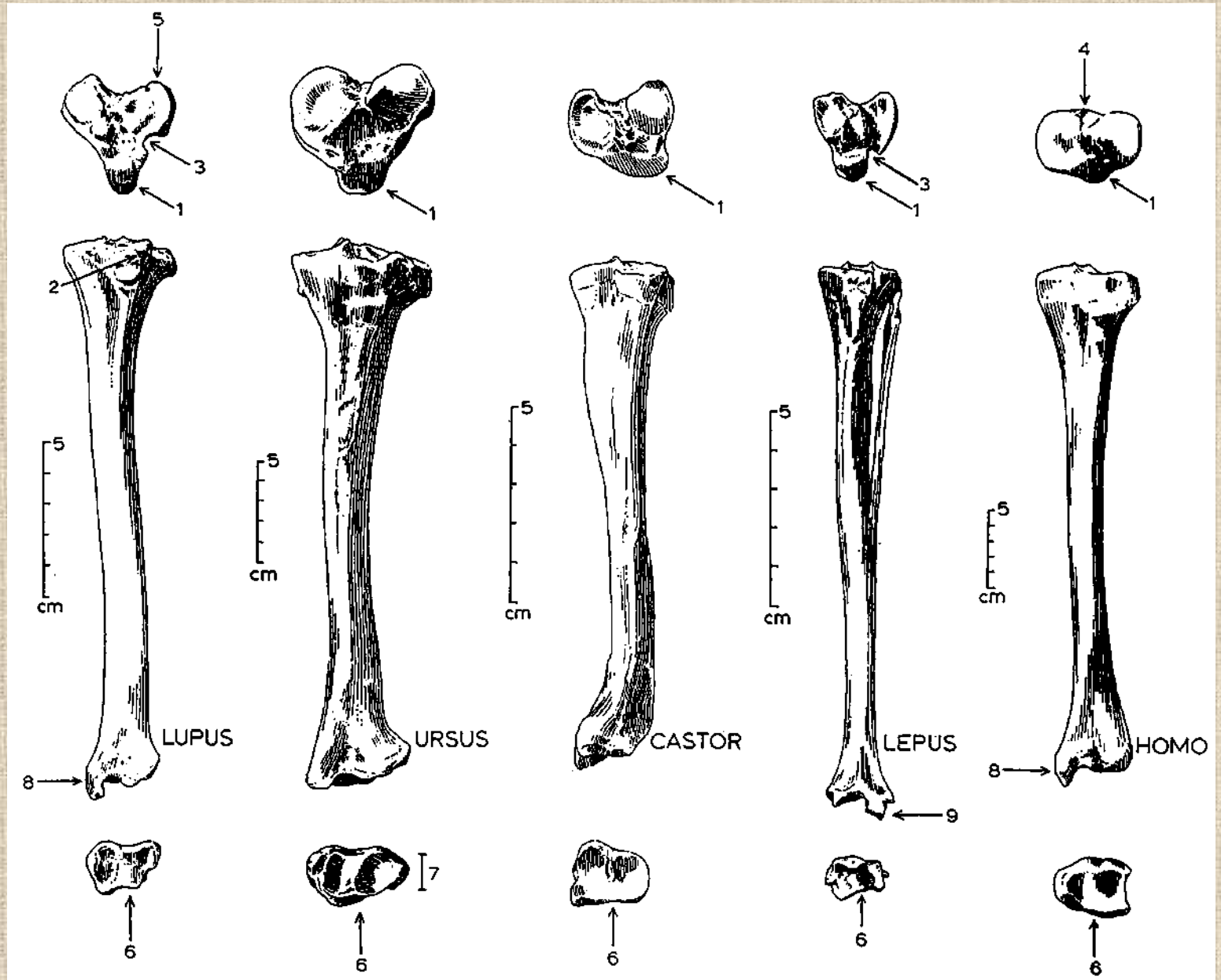


# Holenní kosti (*tibiae*)

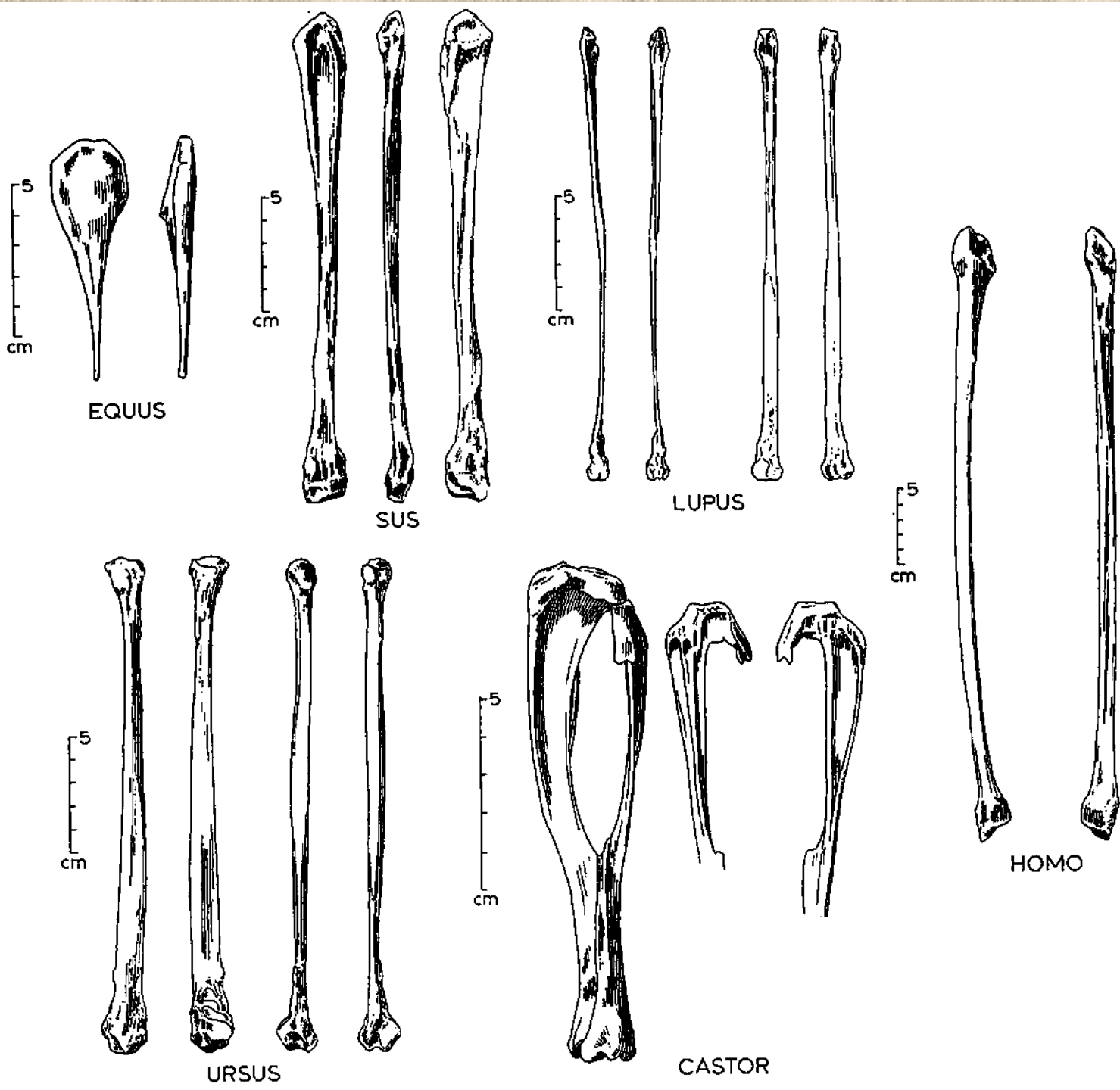




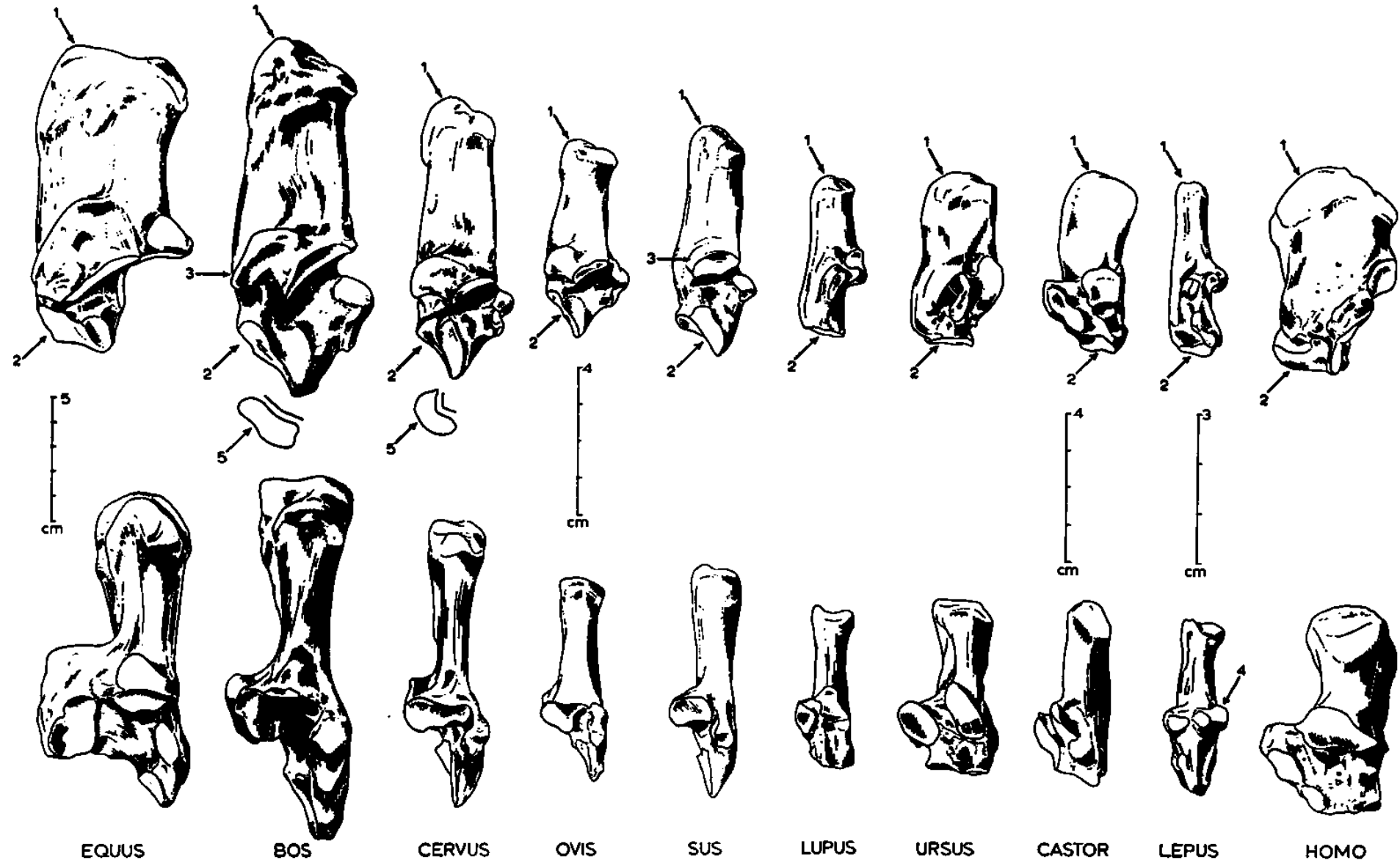
# Holenní kosti (*tibie*)

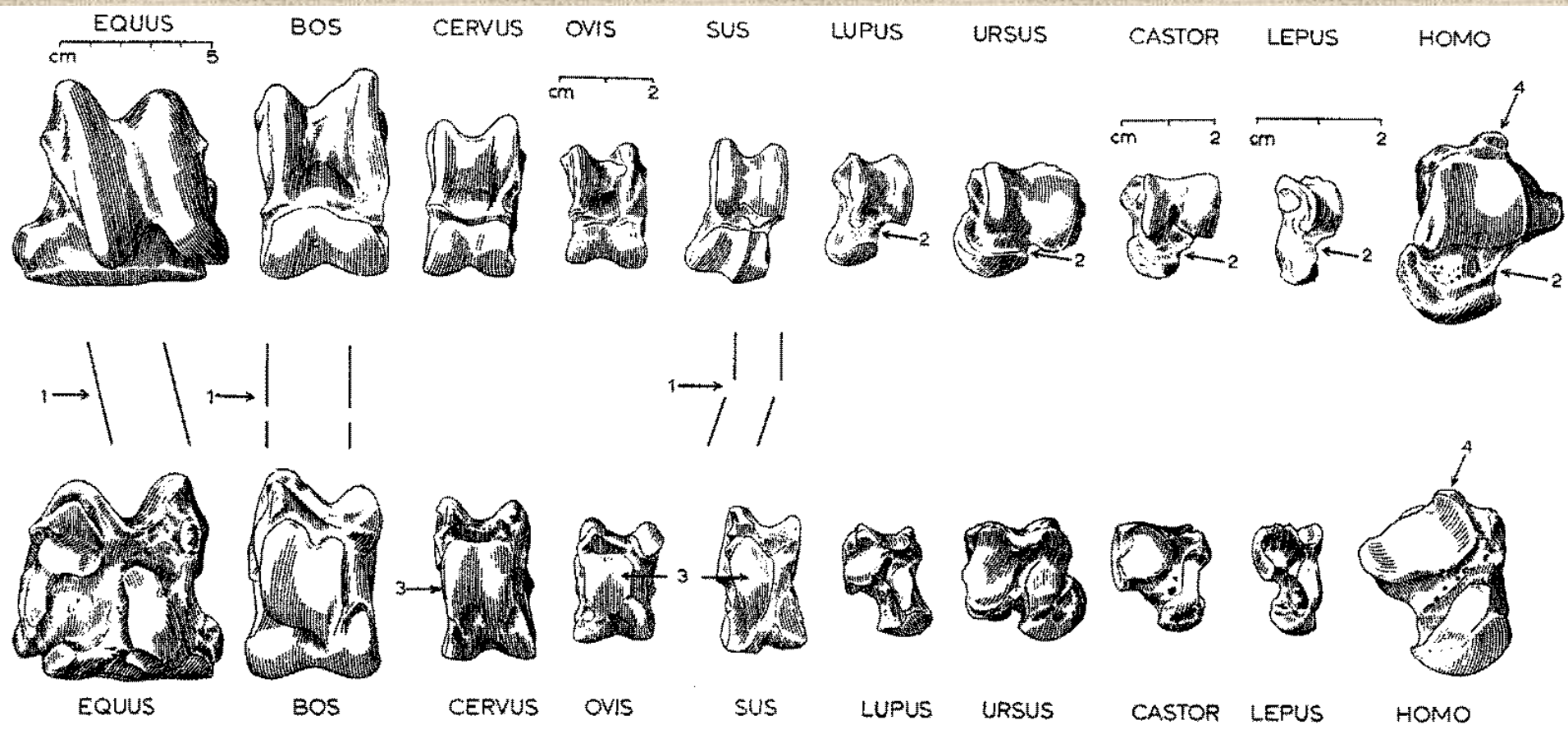


Lýtkové  
kosti  
(fibula)



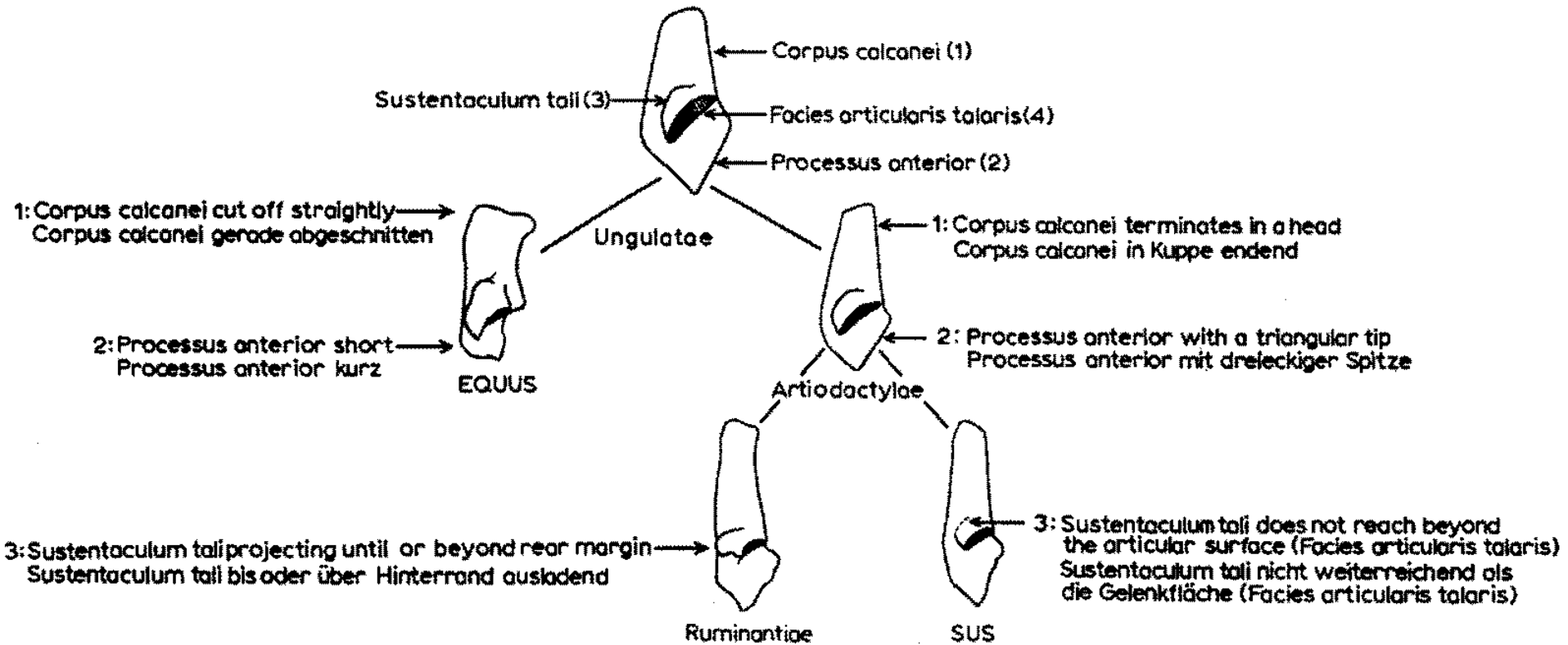
# Kost patní (*calcaneus*)



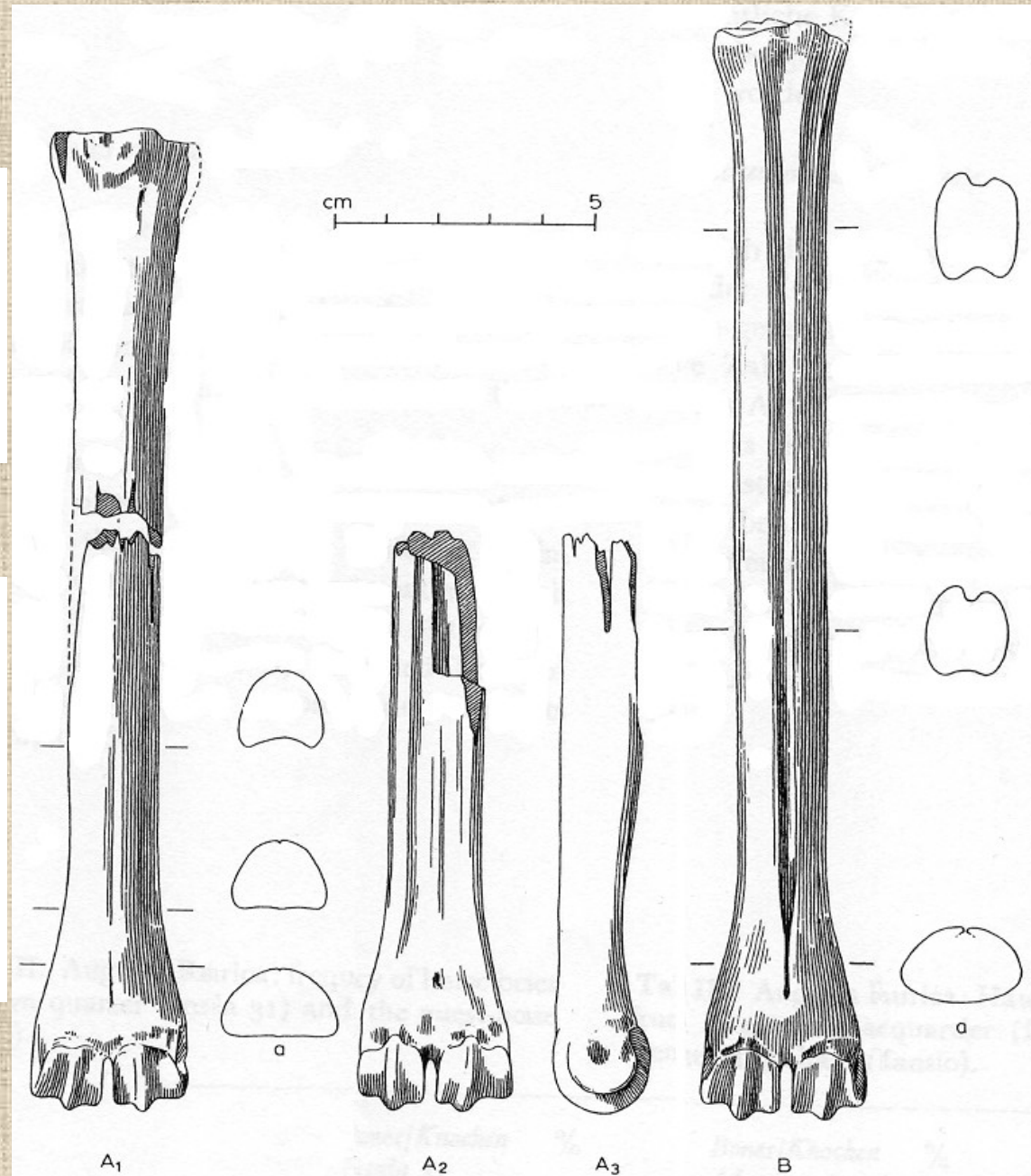
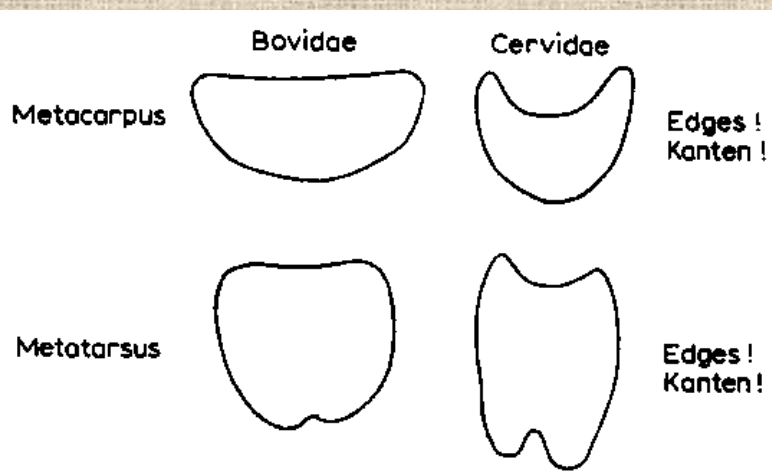
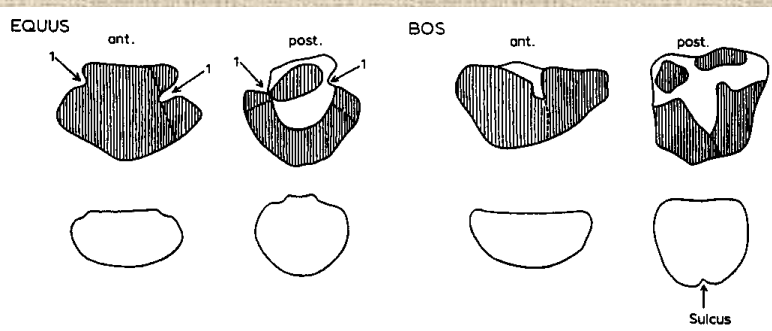


**Kost hlezenní (*astragalus*)**

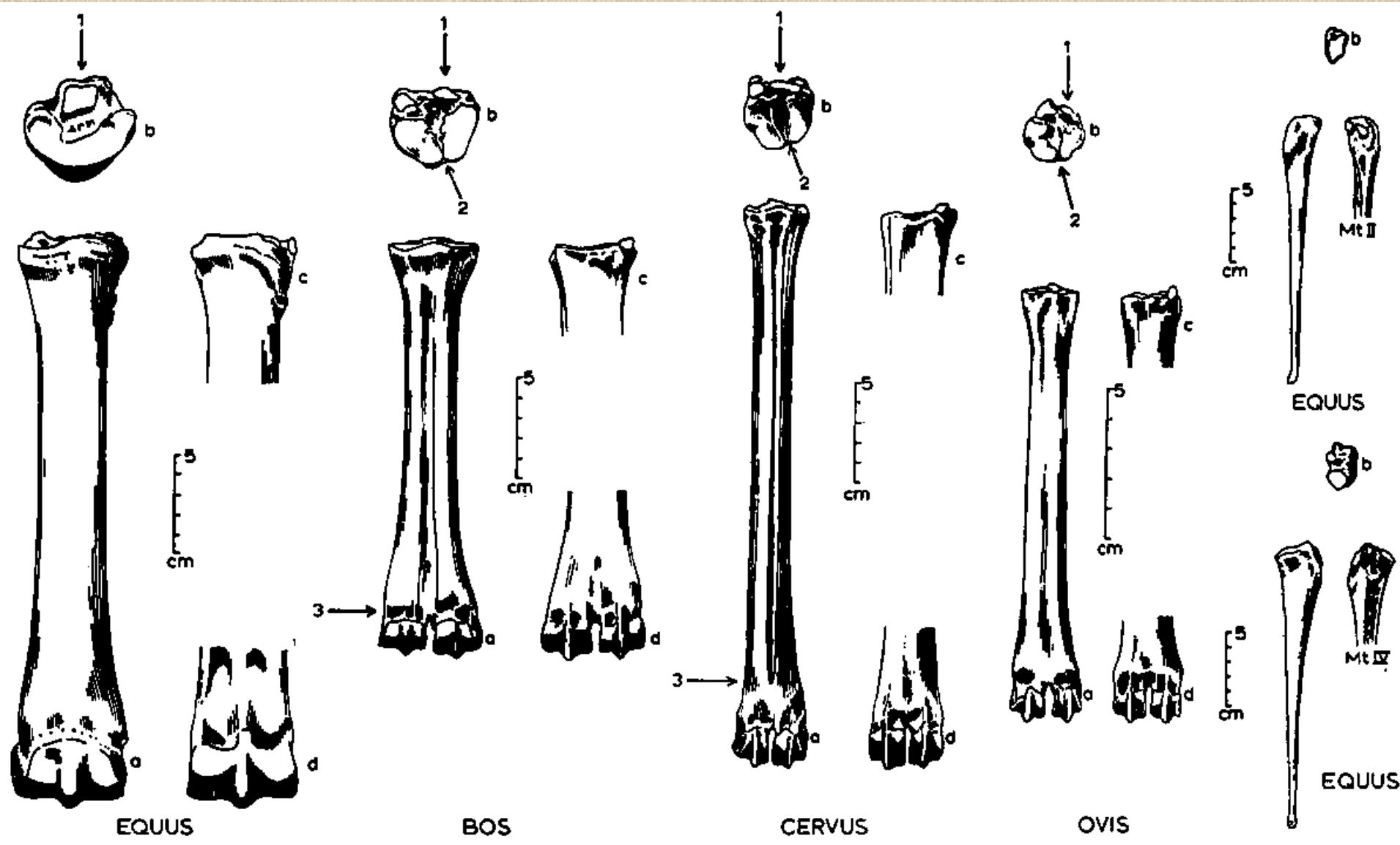
# Rozdíly mezi kostmi patními býložravců a masožravců



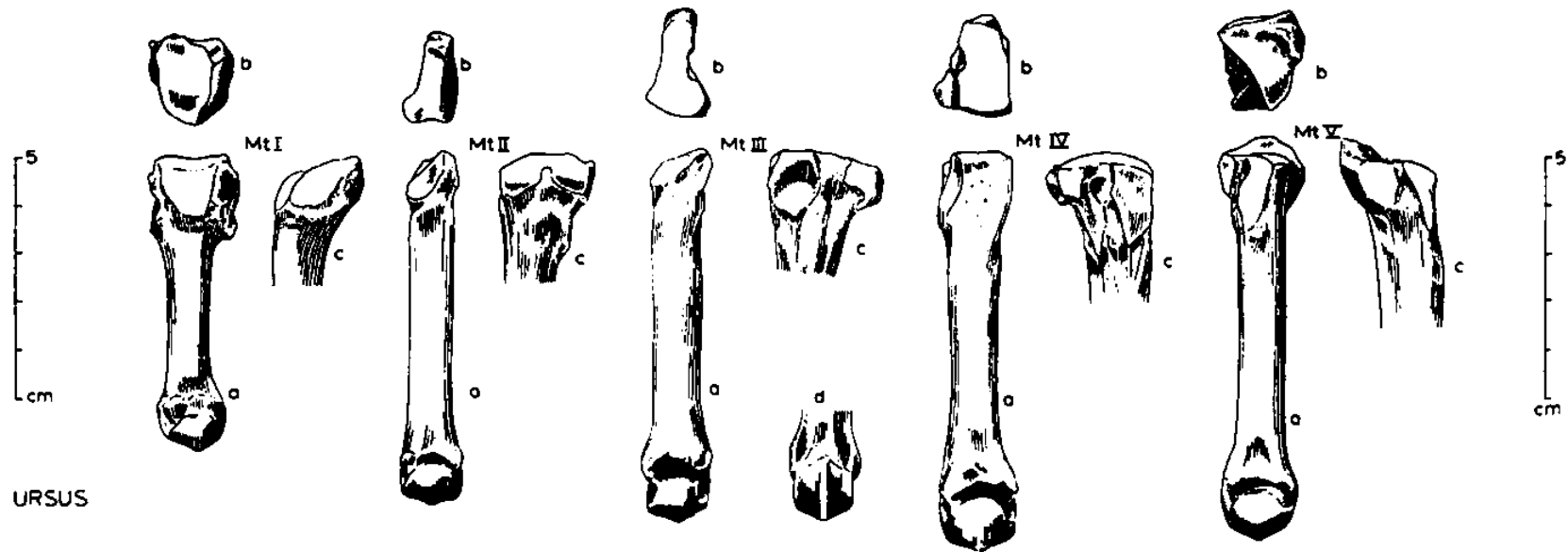
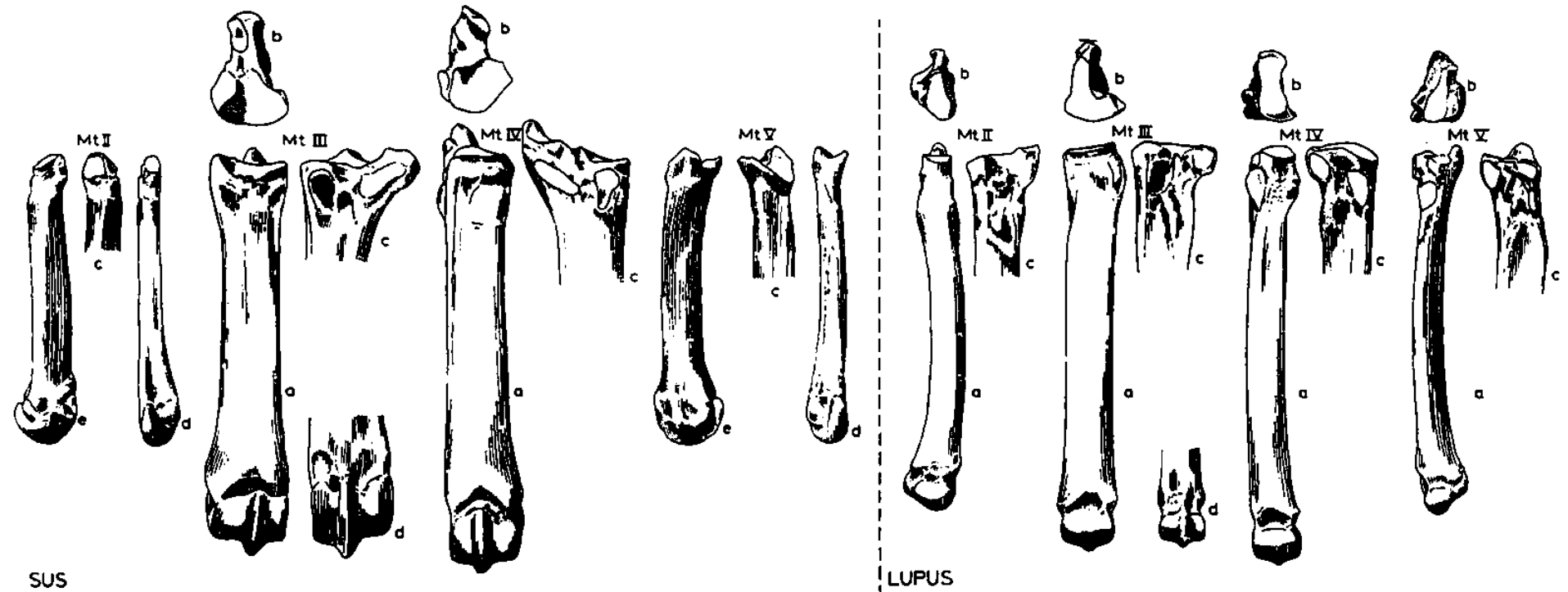
# Rozdíl mezi záprstními a nártními kostmi



# Nártní kost (*metatarsus*)

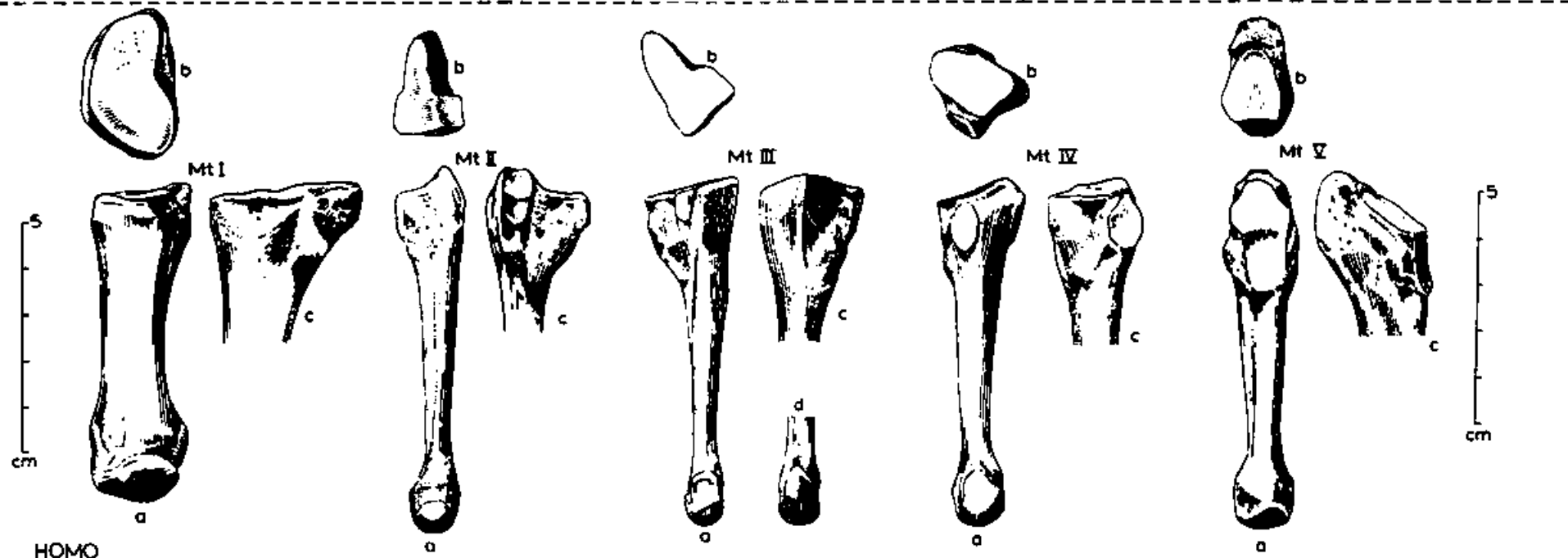
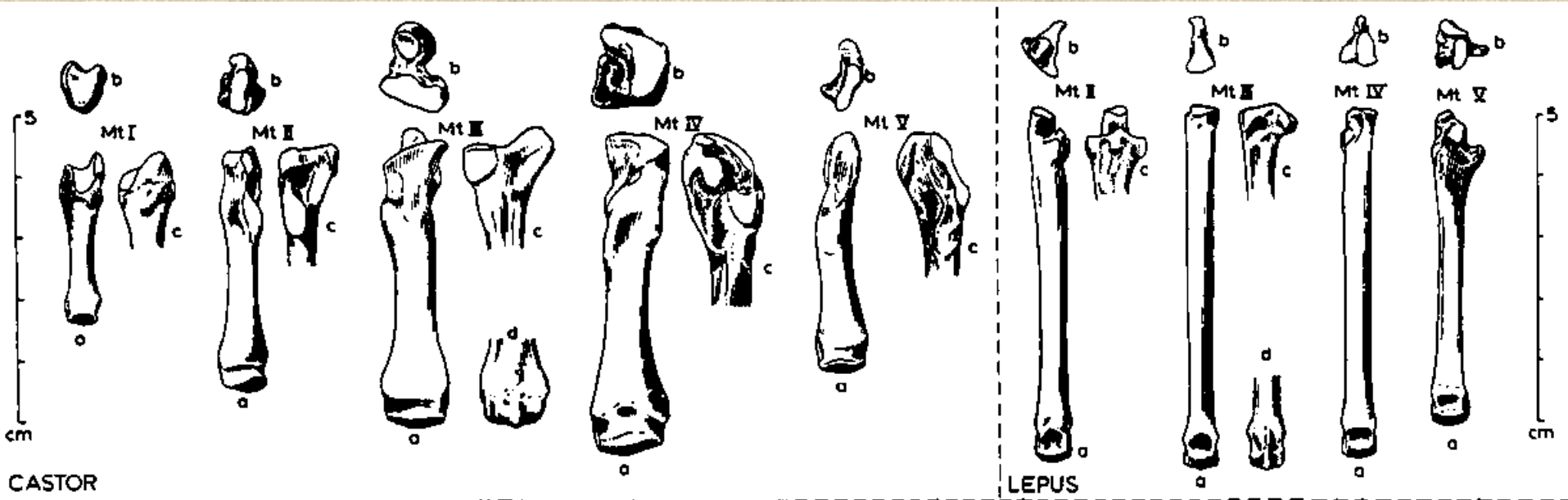


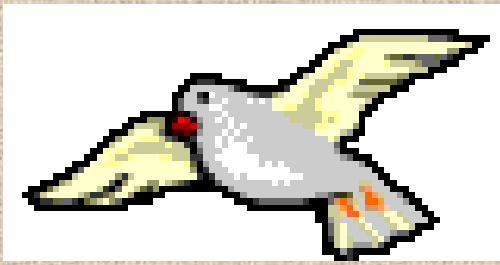# Nártní kost (*metatarsus*)



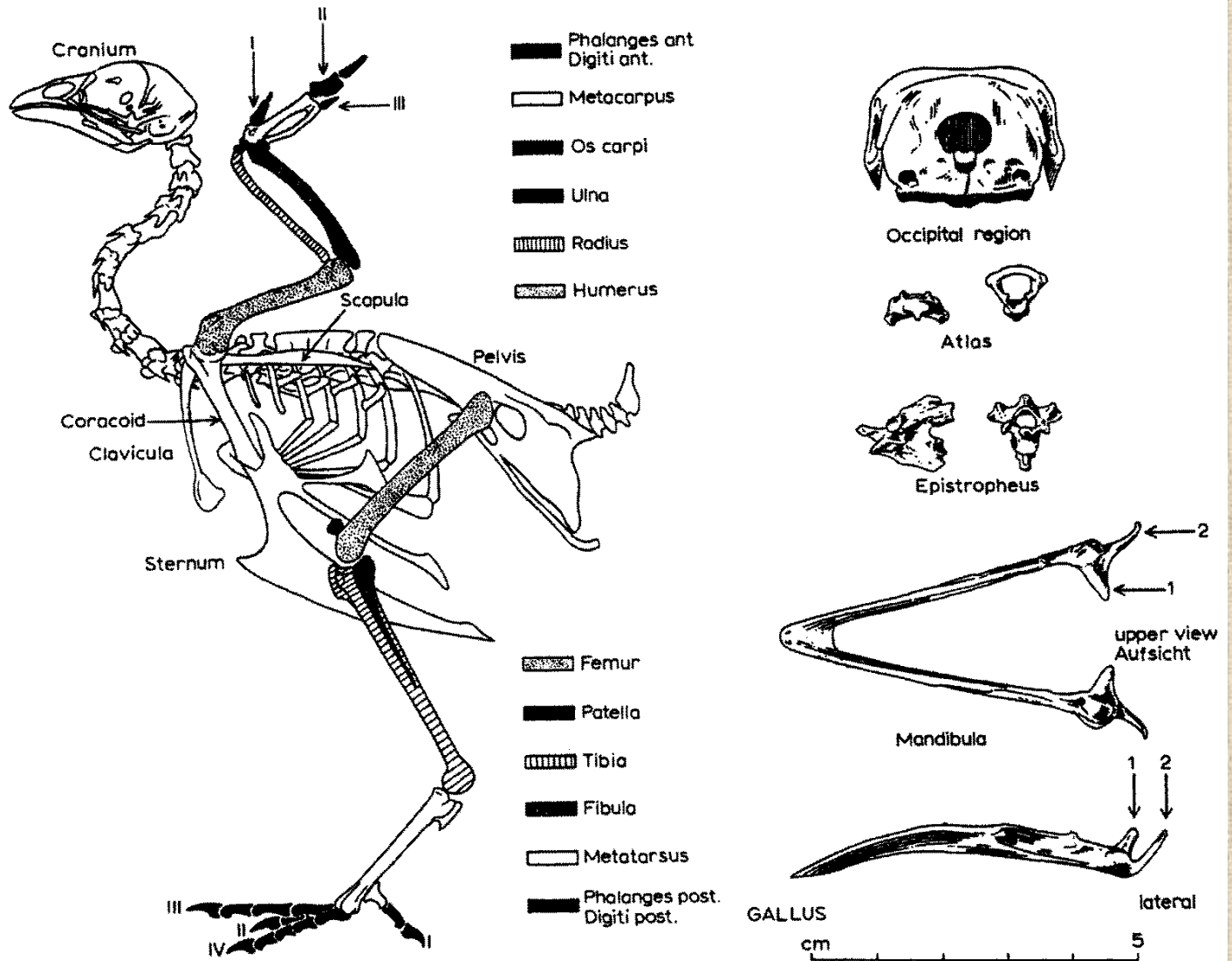


# Nártní kost (*metatarsus*)

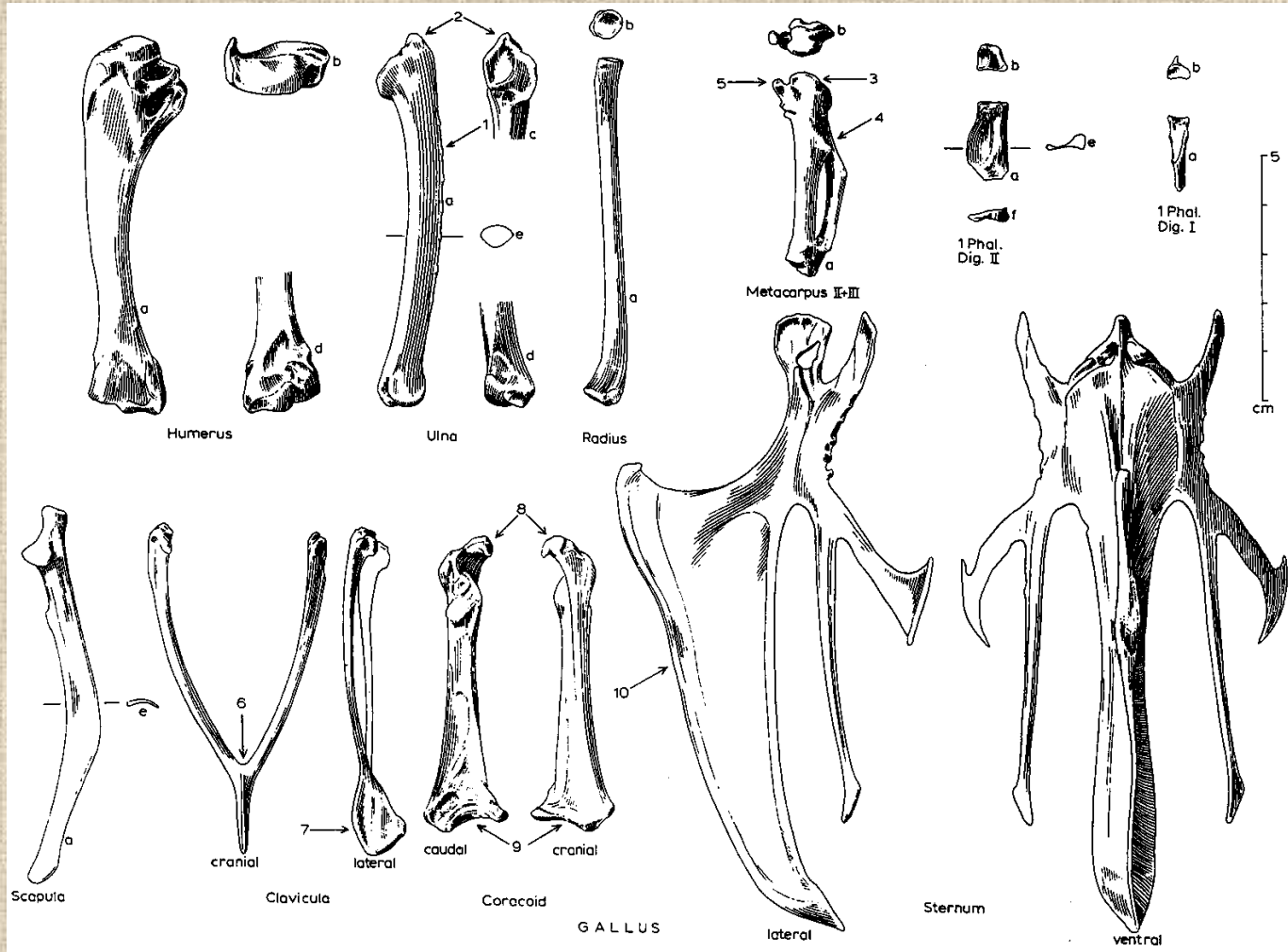




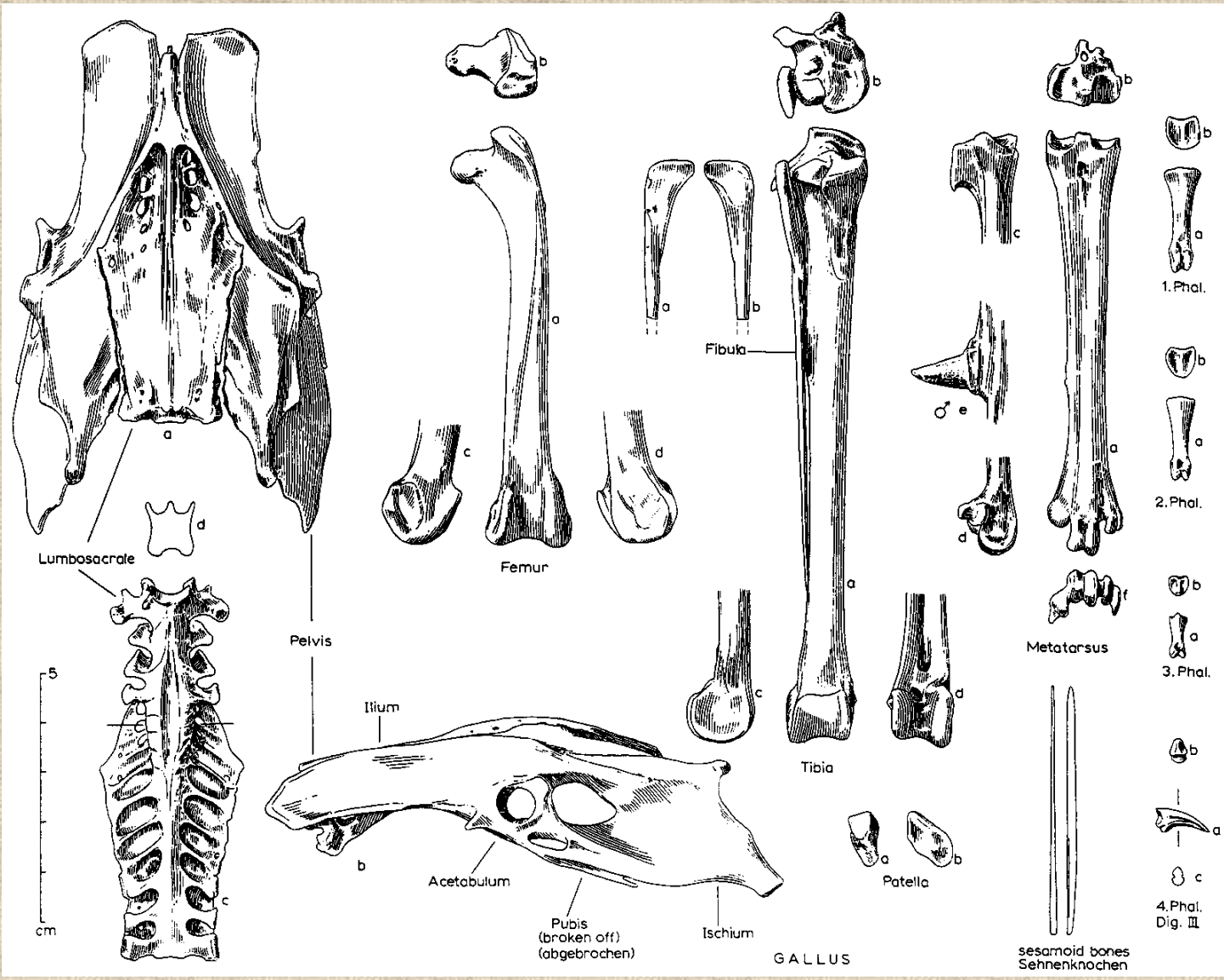
# Ptačí kostra



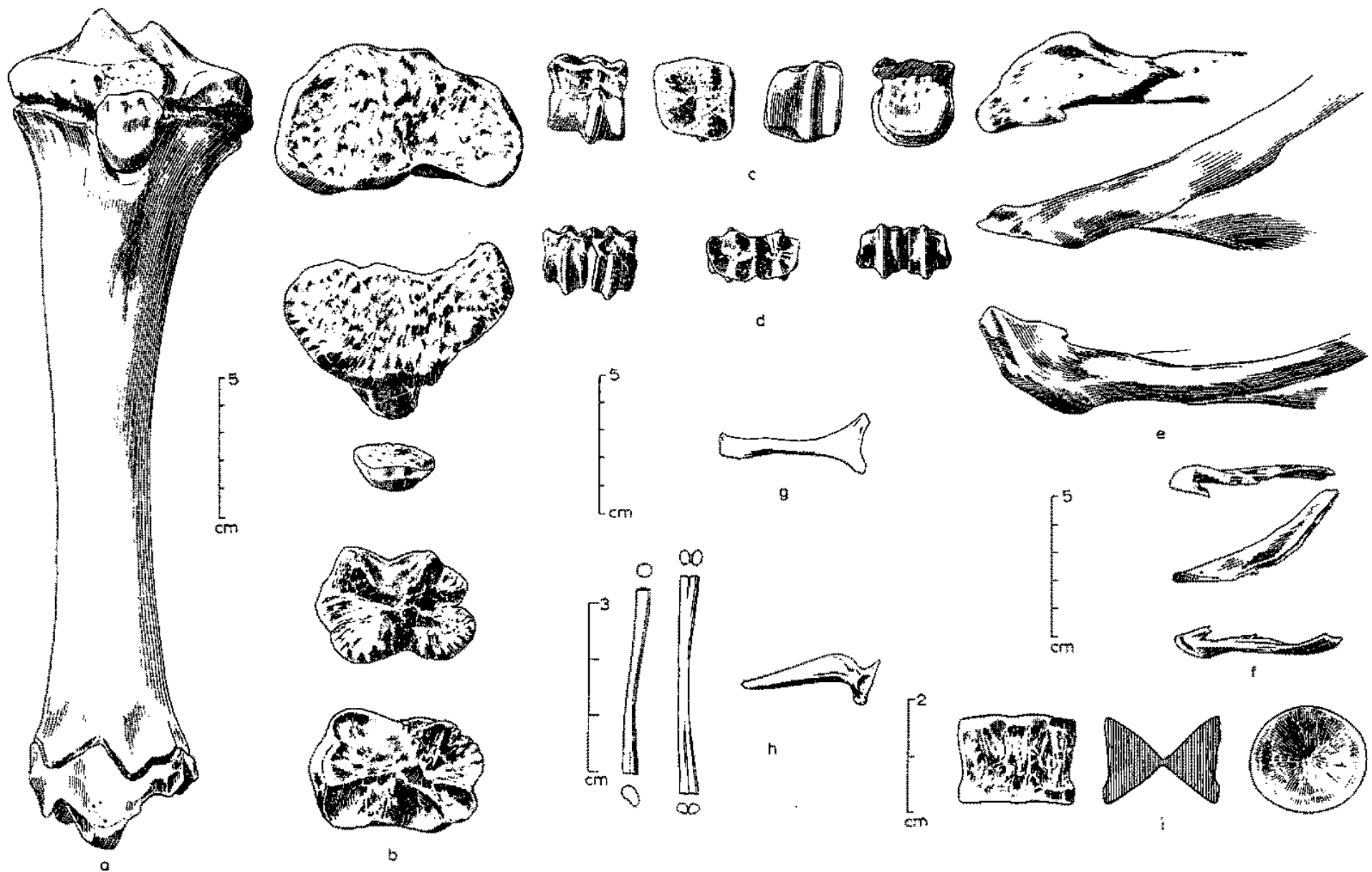
# Kostra přední končetiny ptáka



# Kostra zadní končetiny ptáka



# Rozdílná morfologie kostí různých druhů zvířat





**Děkuji za pozornost!**