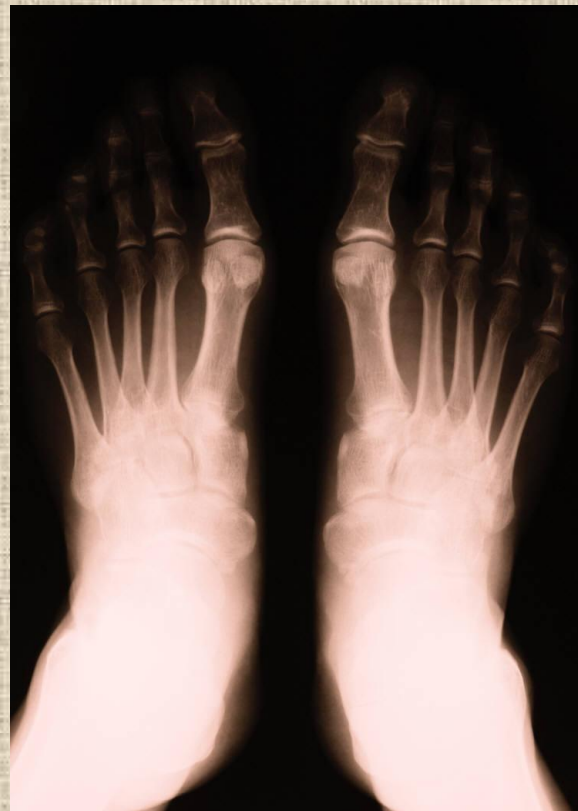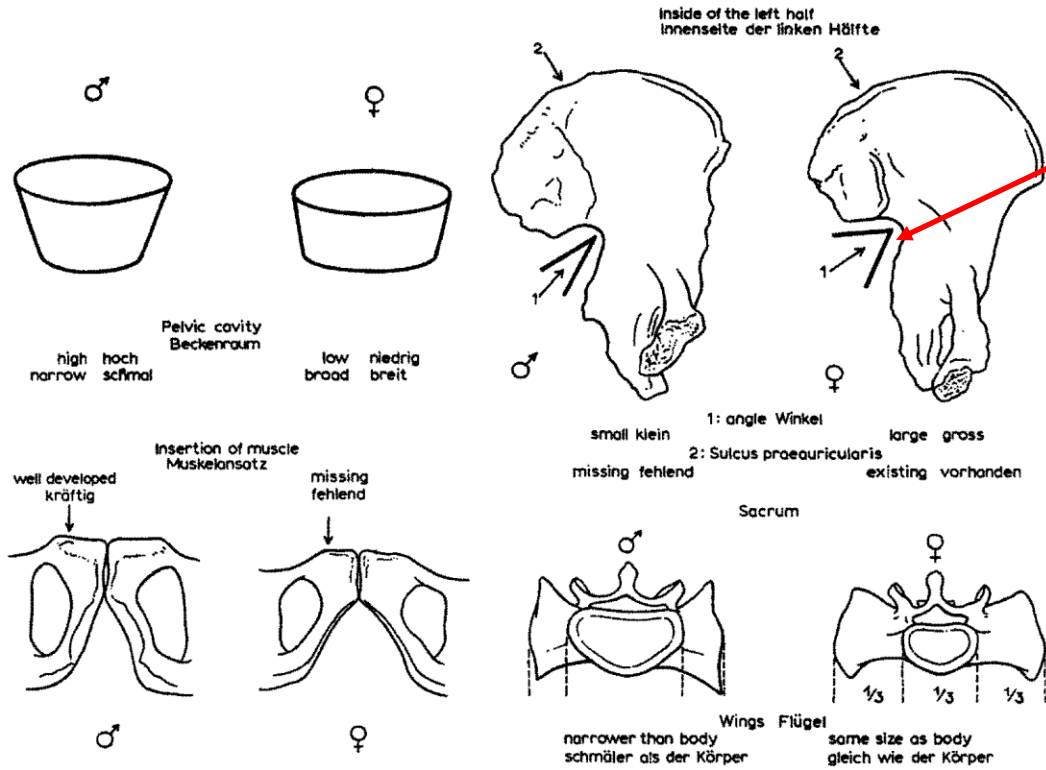


# Základy osteologie


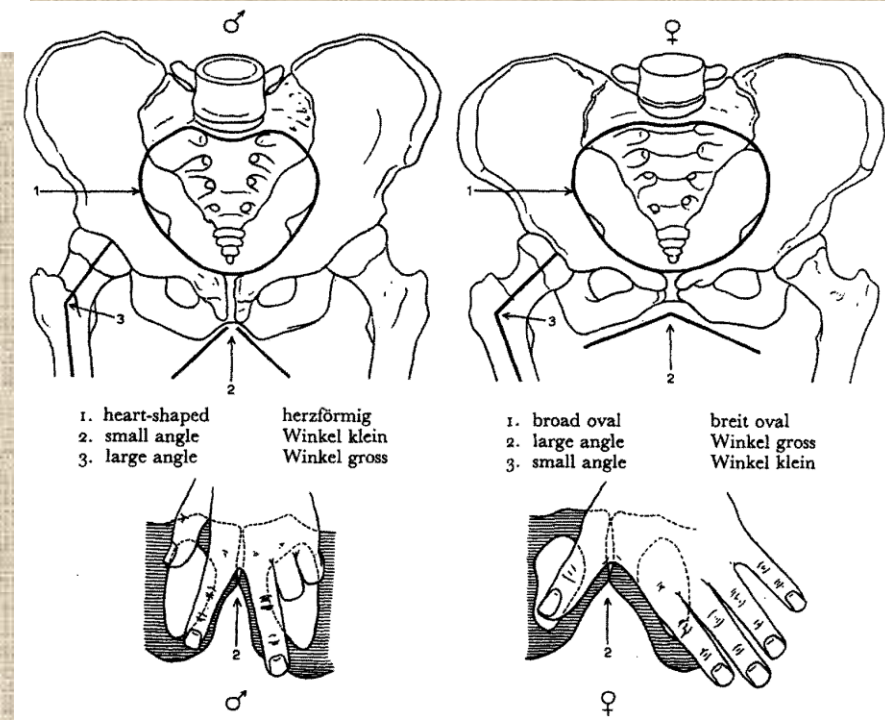
Pánev a kosti zadní končetiny



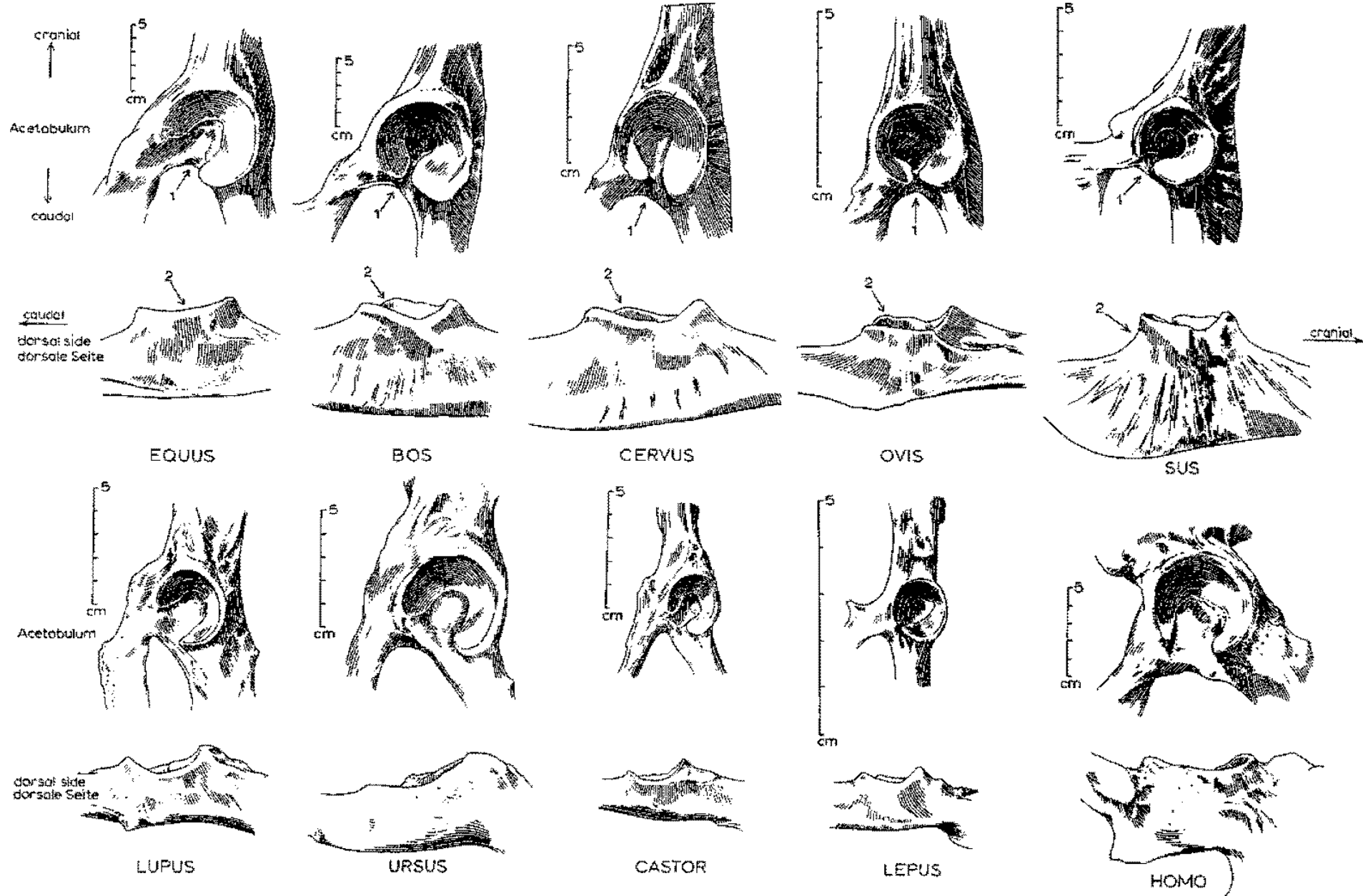


*Incisura ischiadica major*

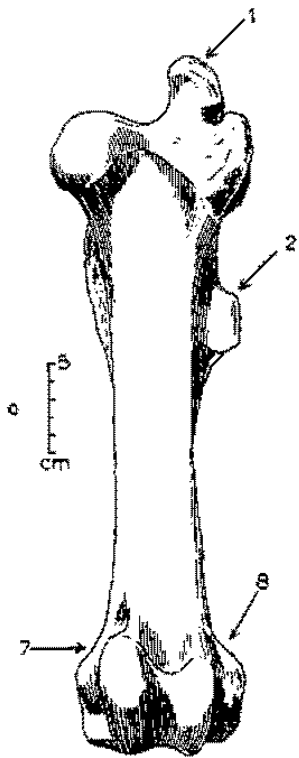
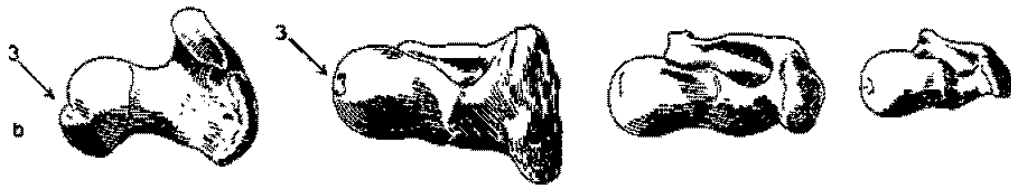
**Pohlavní  
rozdíly na  
pánvi člověka**



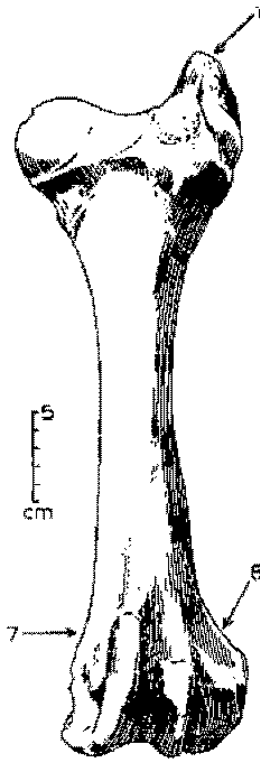
# Pánve



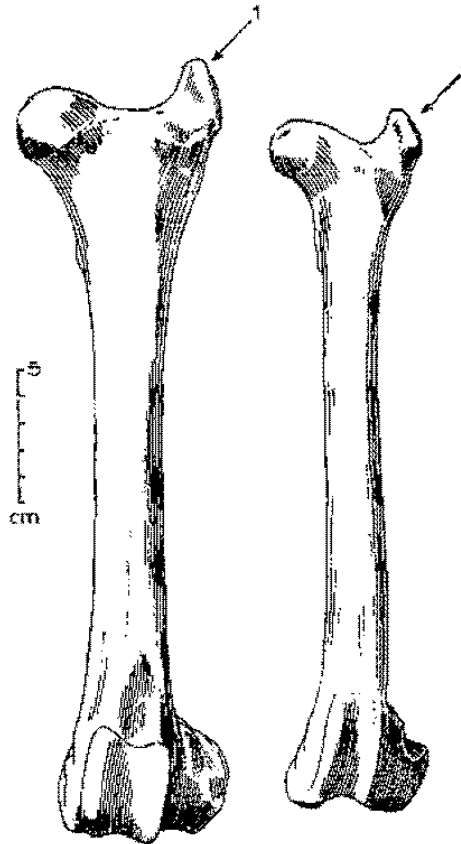
# Stehenní kosti (*femur*)




EQUUS



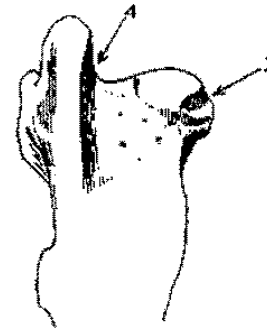
BOS



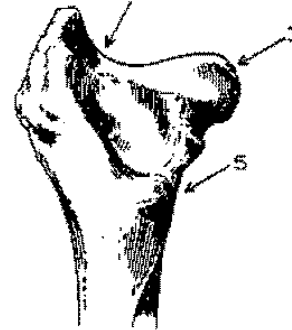
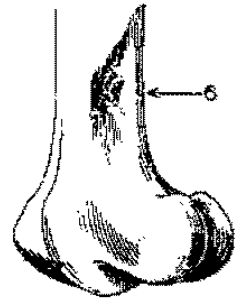
CERVUS



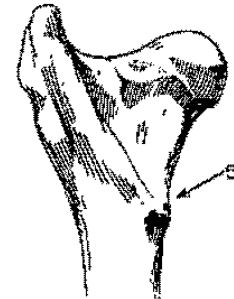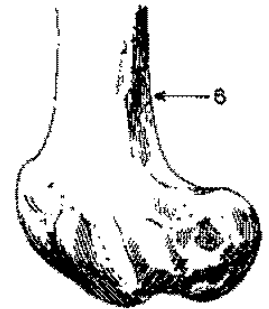
OVIS



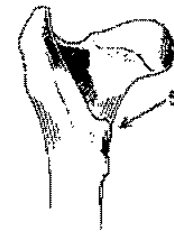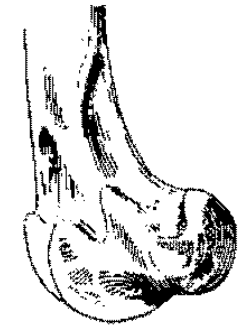
EQUUS



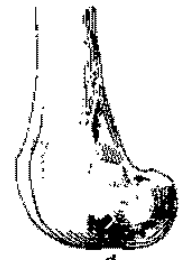
BOS



CERVUS



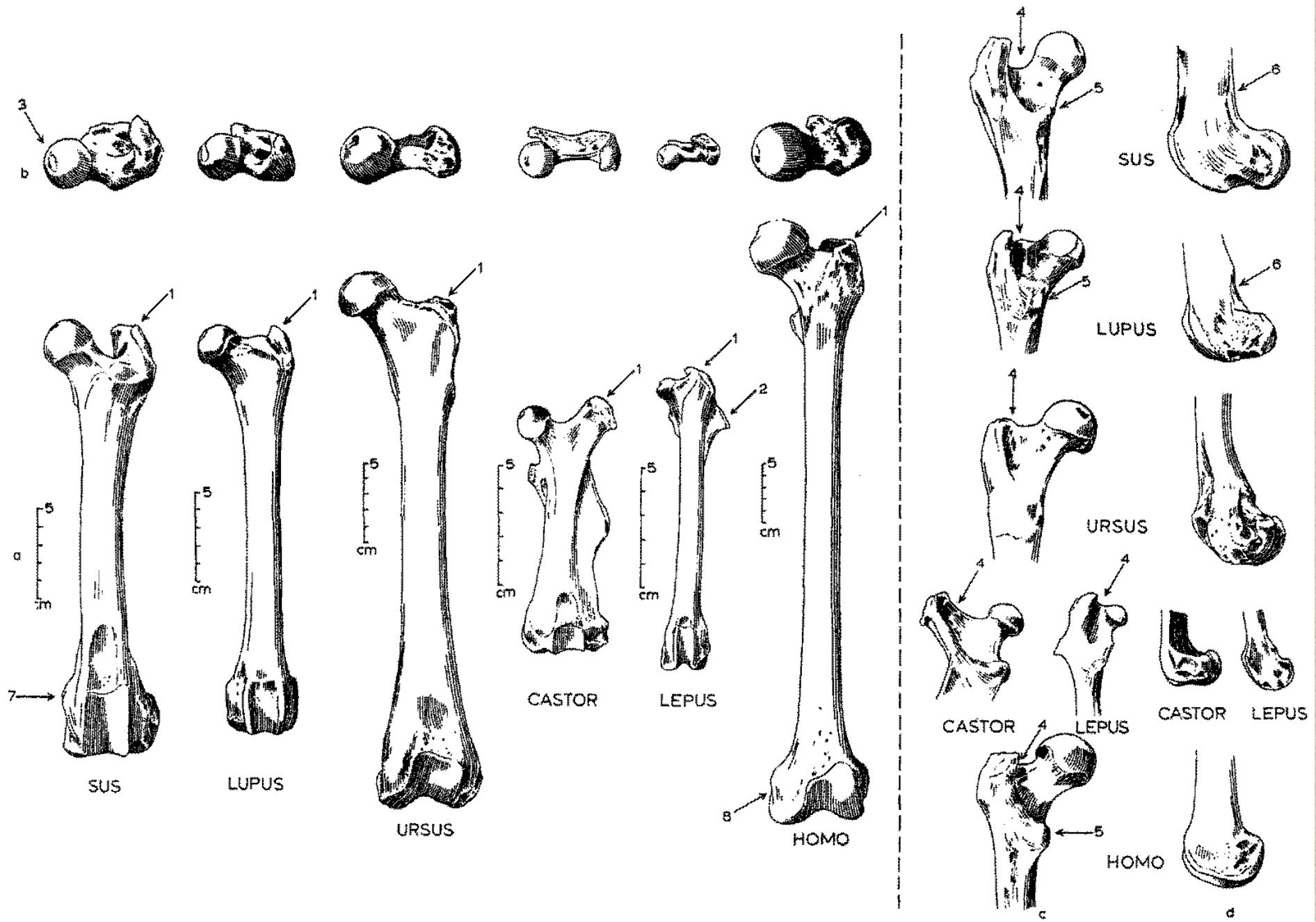
OVIS



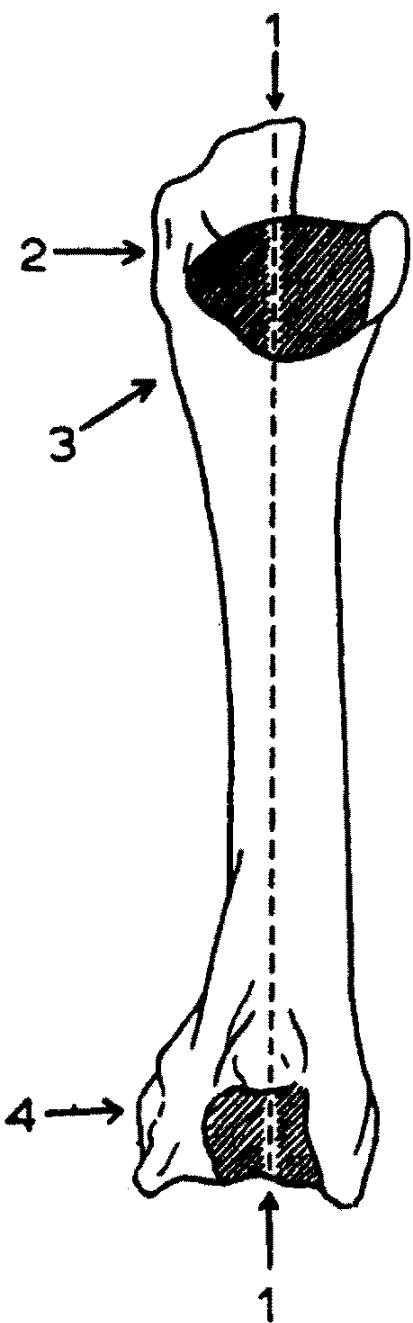
c

d

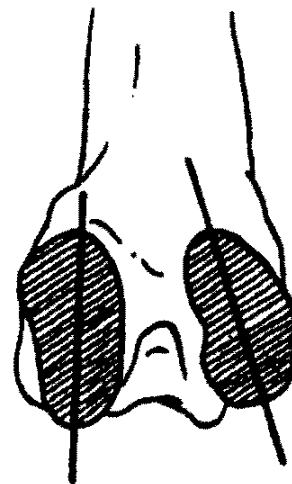
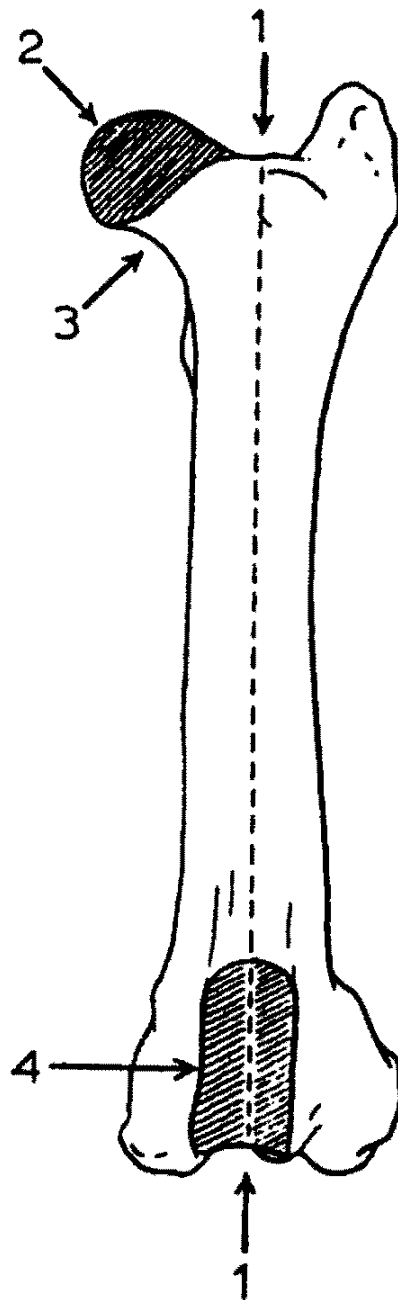
# Stehenní kosti (femur)



Humerus  
caudal



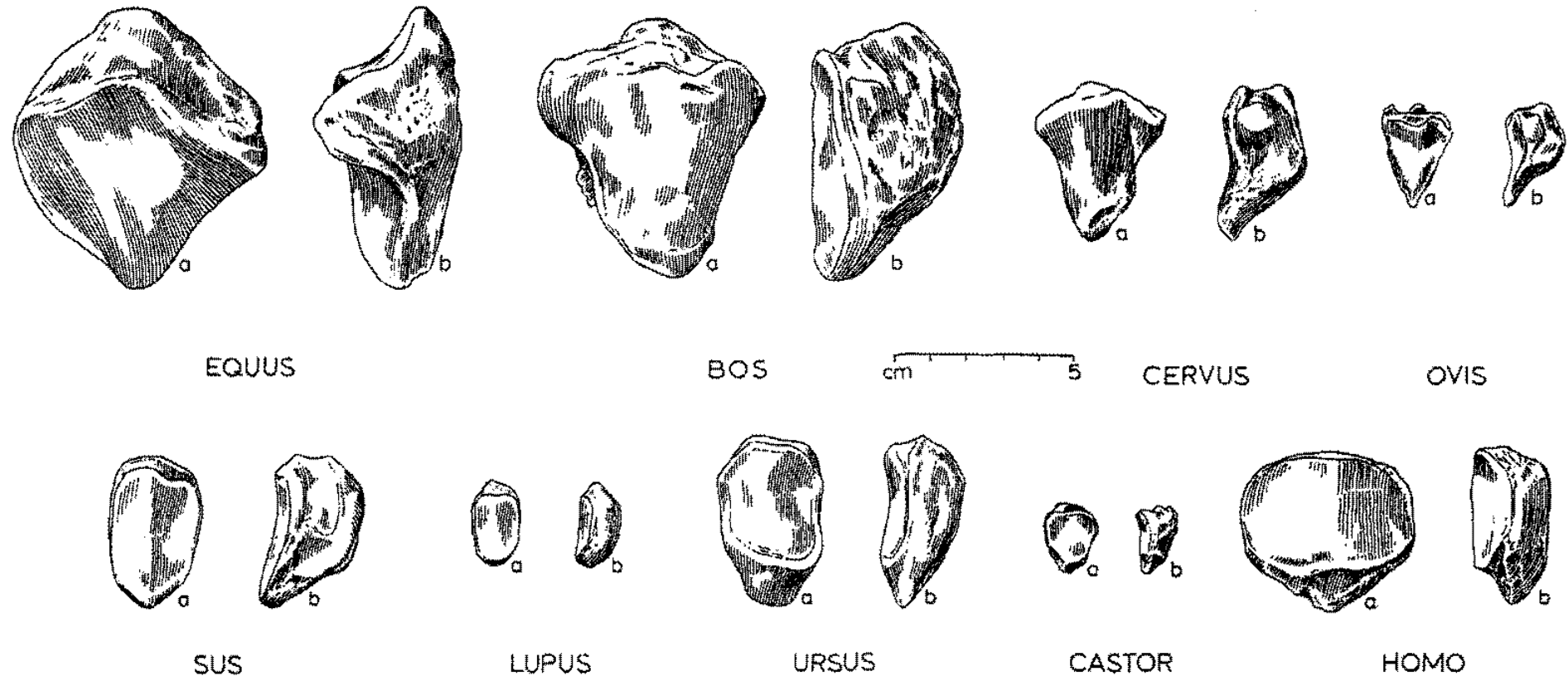

Femur  
cranial



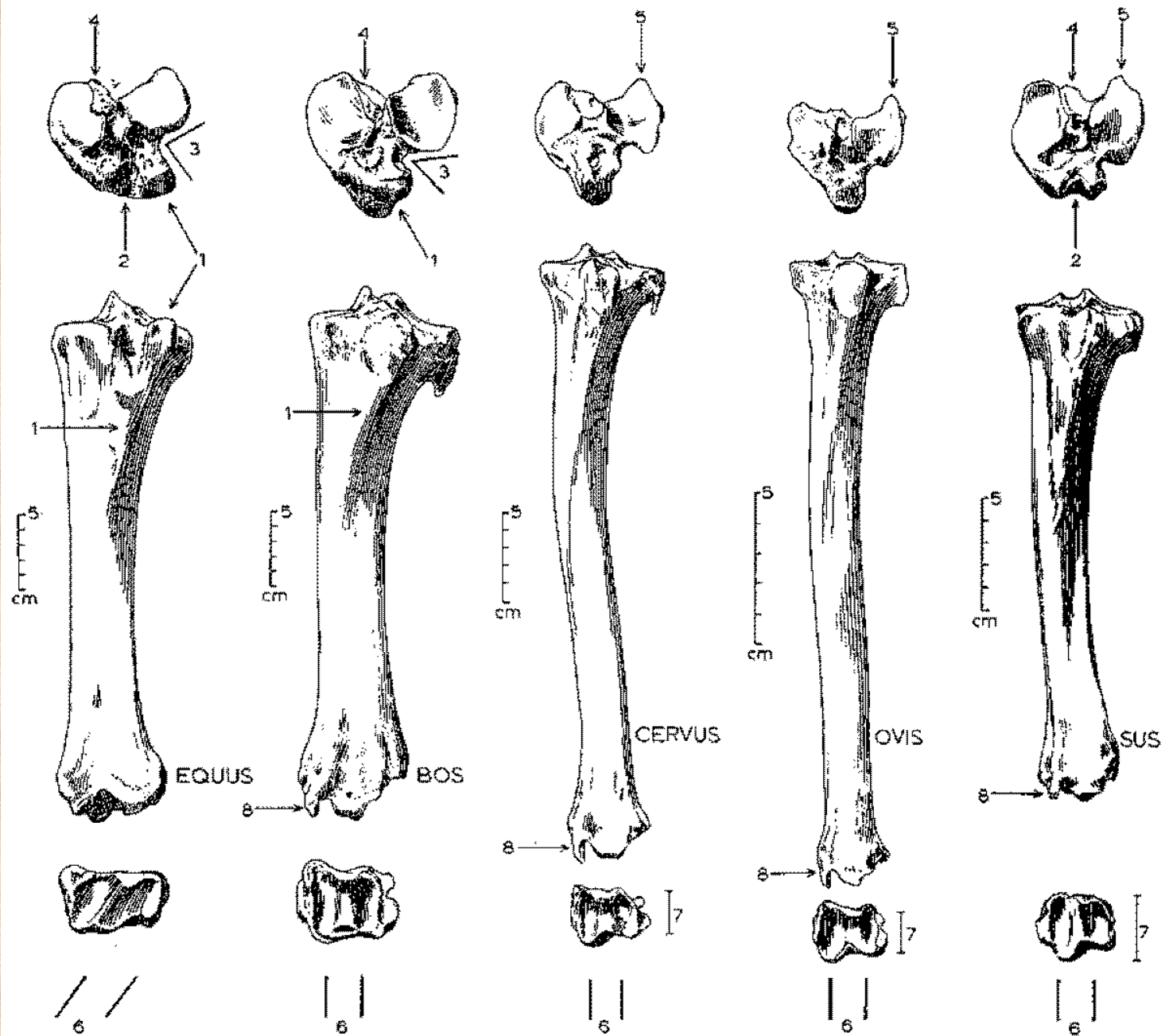
Jak rozeznat stehenní  
a pažní kost



# Češka (*patella*)

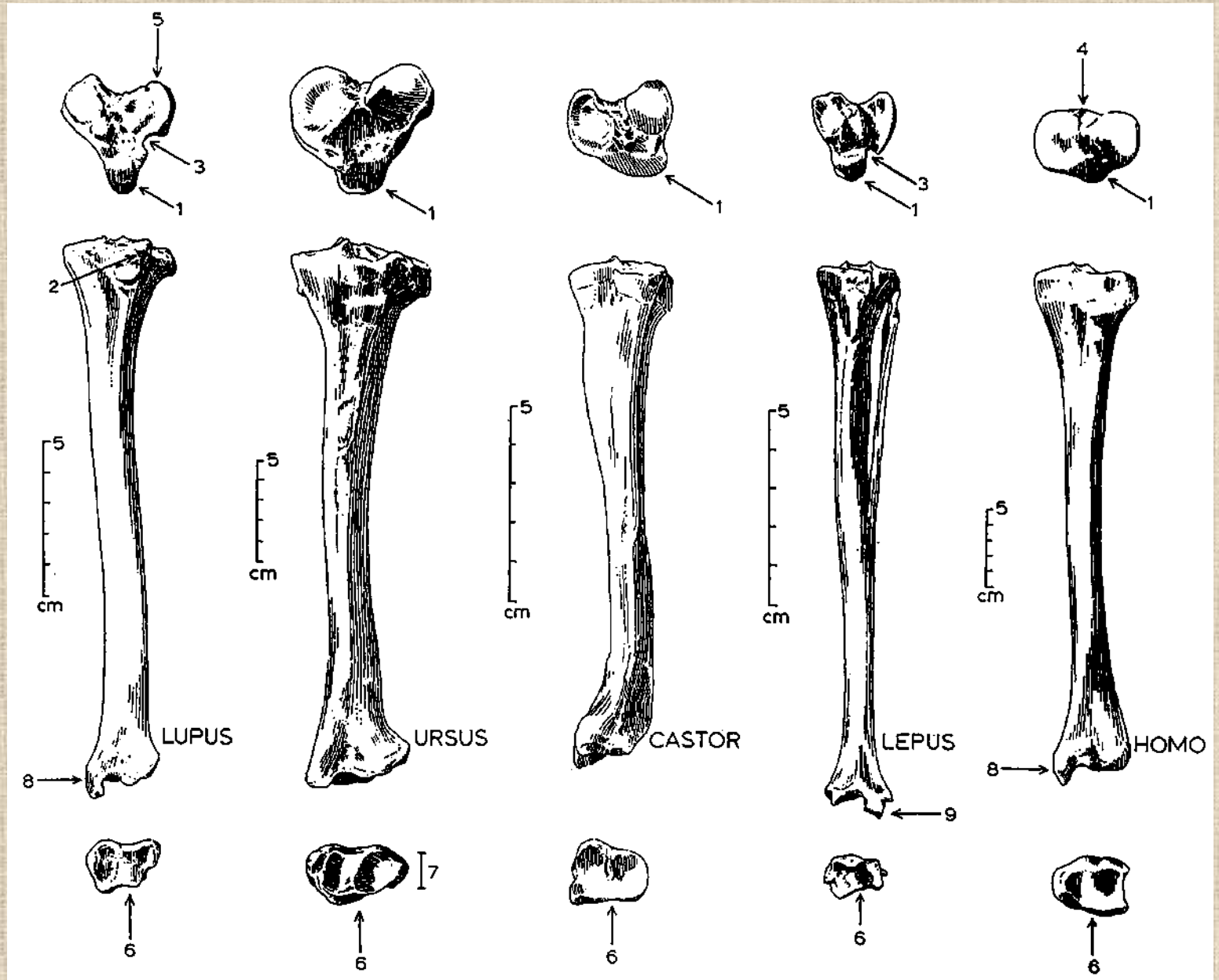


# Holenní kosti (*tibiae*)

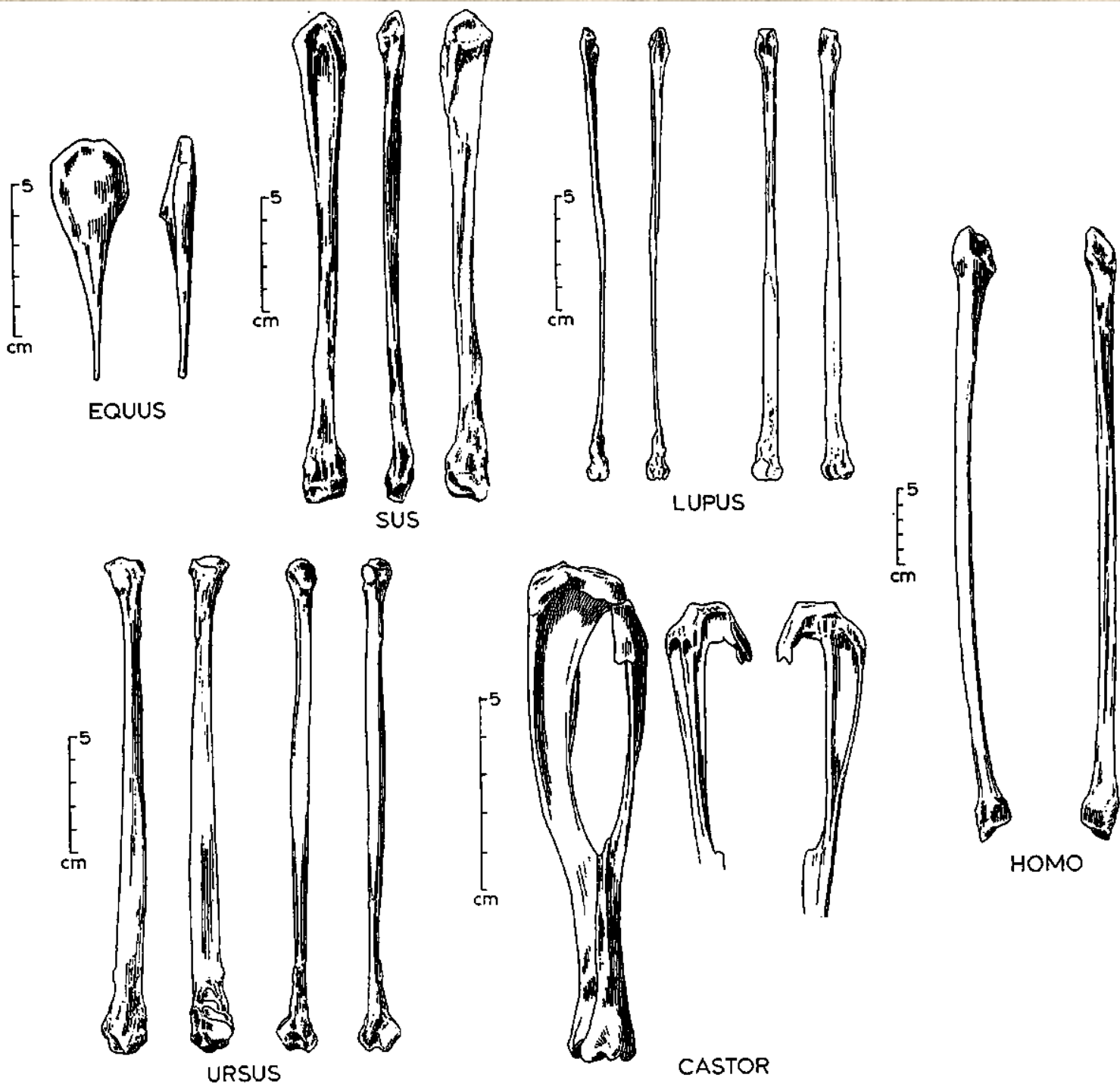




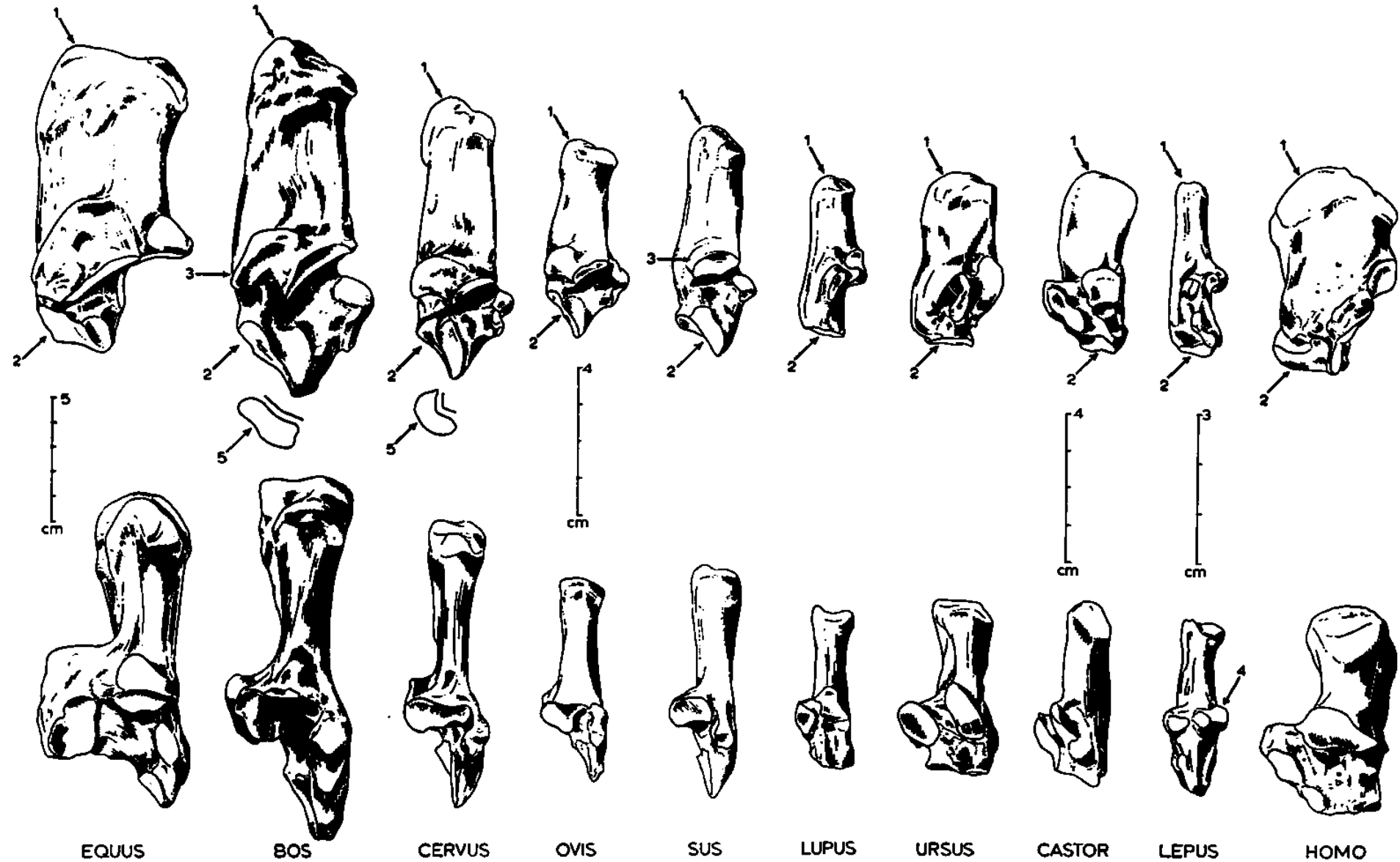
# Holenní kosti (*tibie*)

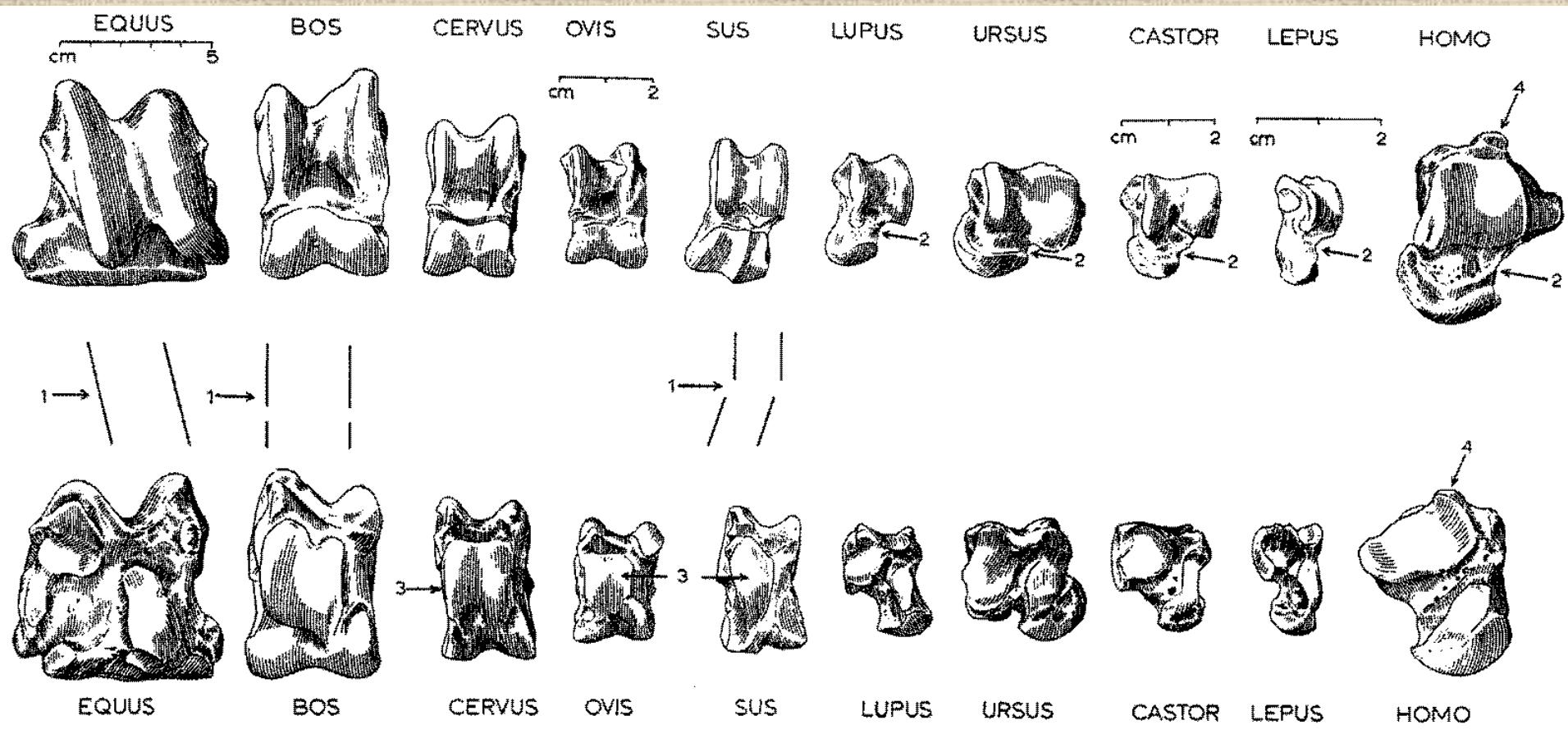


Lýtkové  
kosti  
(fibula)



# Kost patní (*calcaneus*)

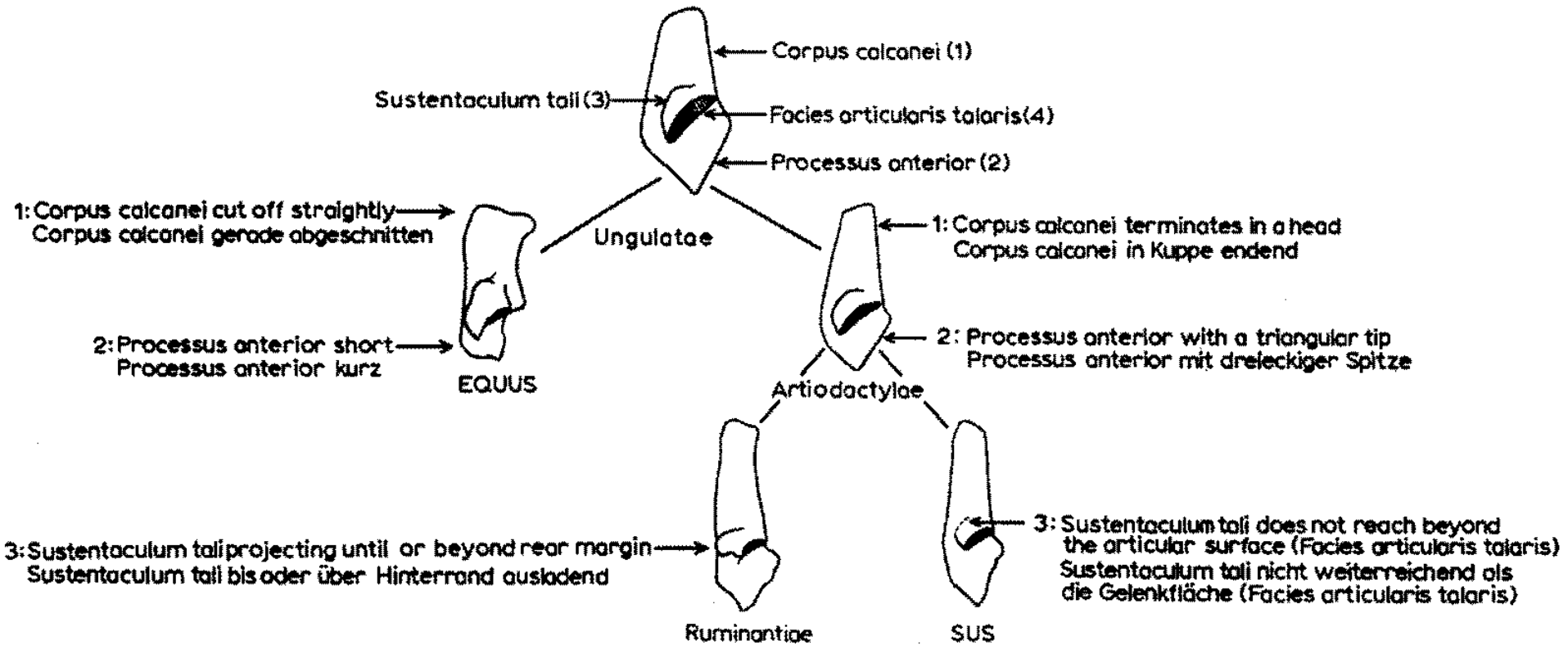




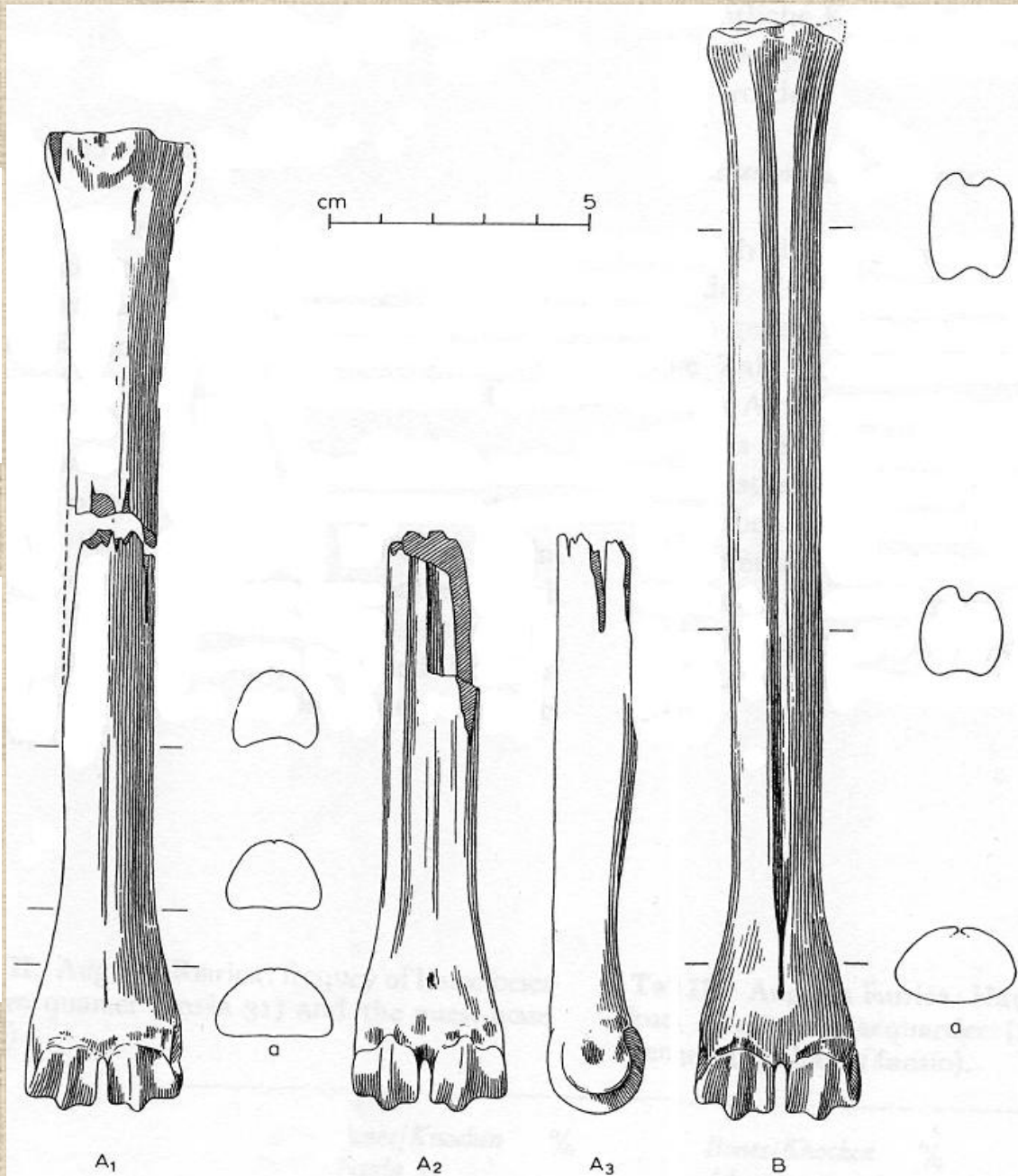
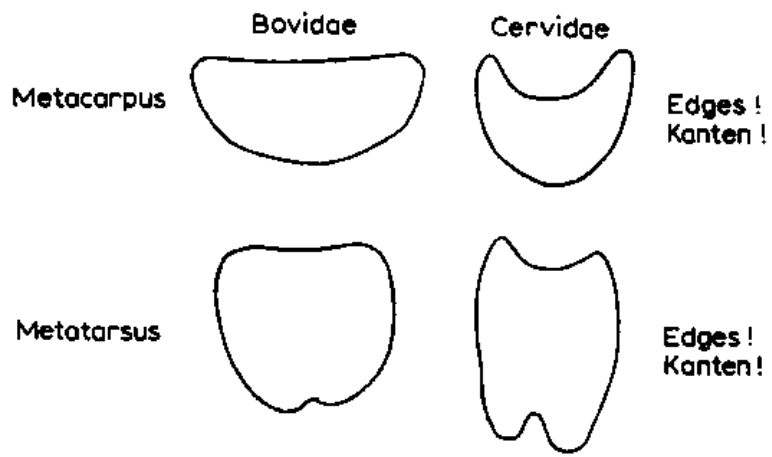
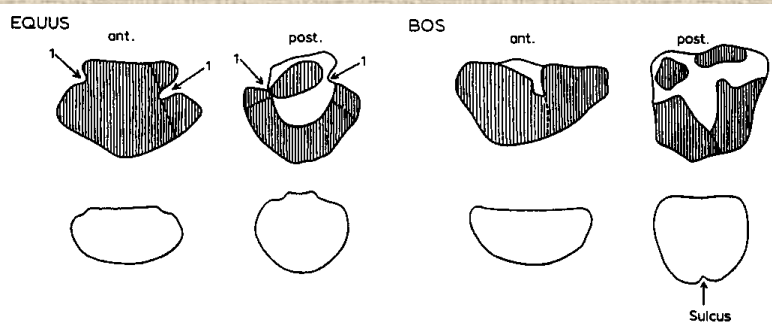
**Kost hlezenní (*astragalus*)**



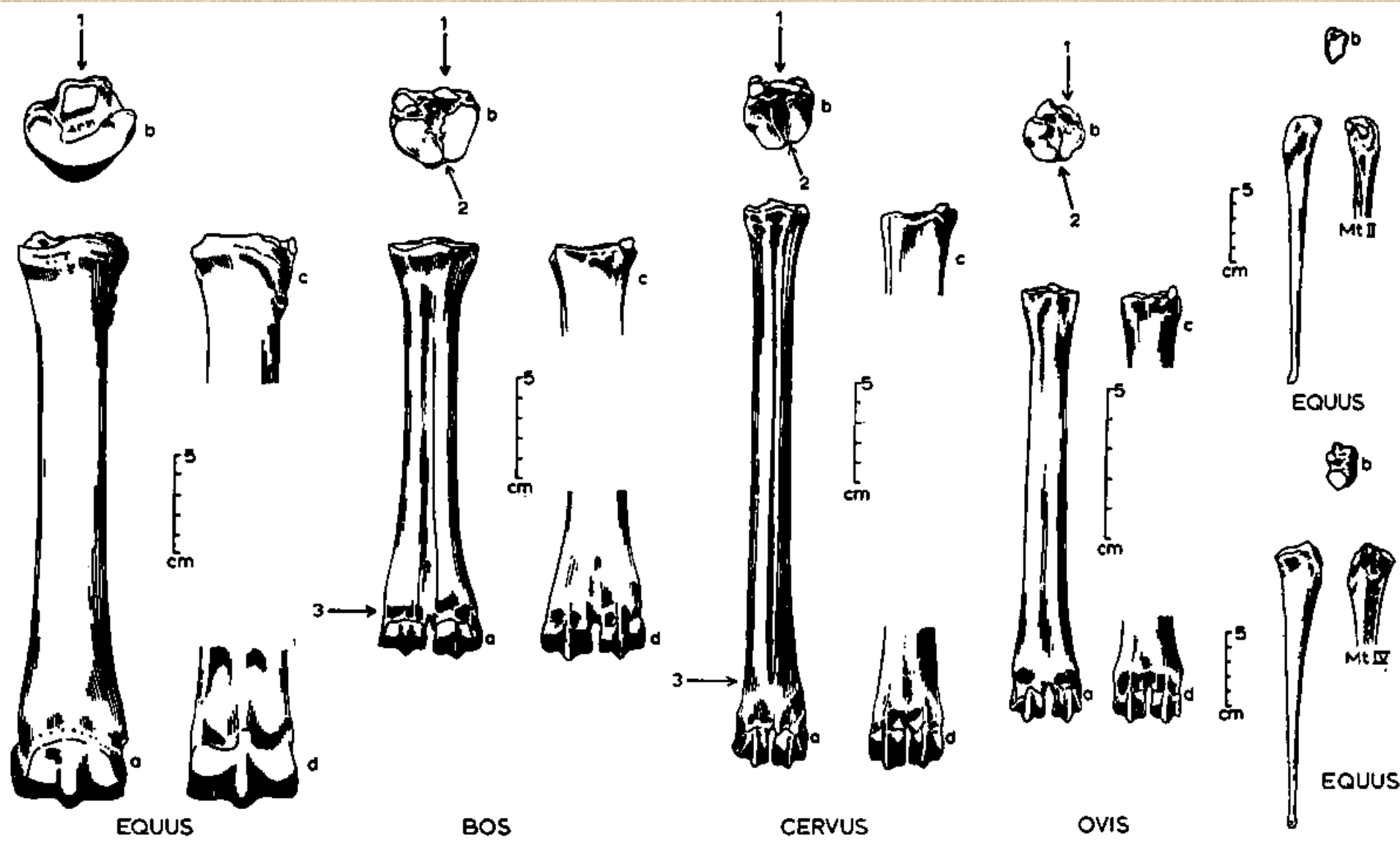
# Rozdíly mezi kostmi patními býložravců a masožravců



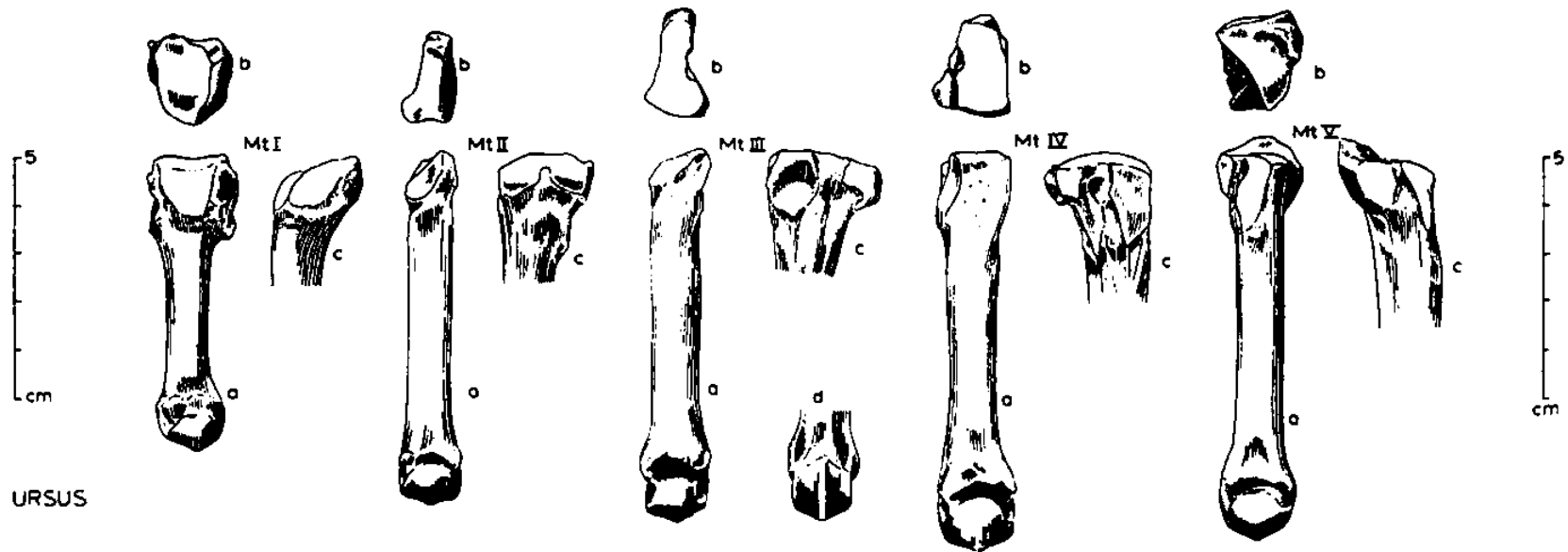
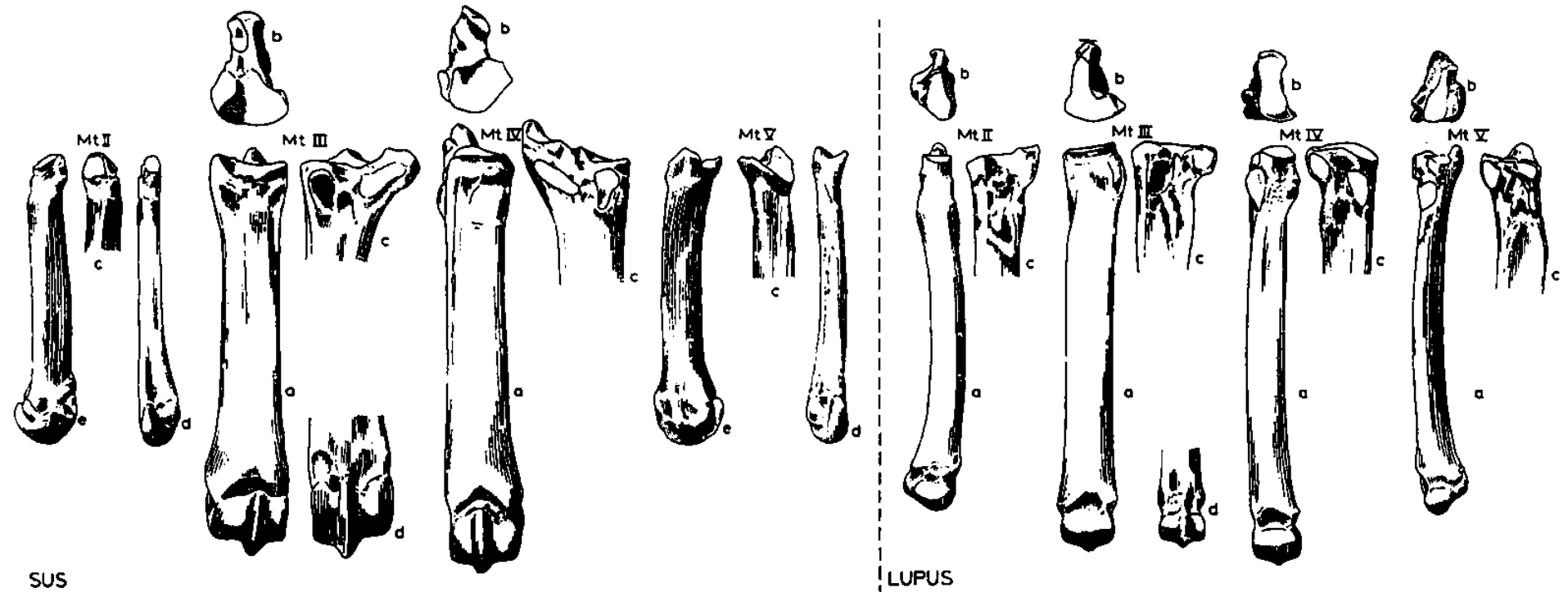
# Rozdíl mezi záprstními a nártními kostmi



# Nártní kost (*metatarsus*)

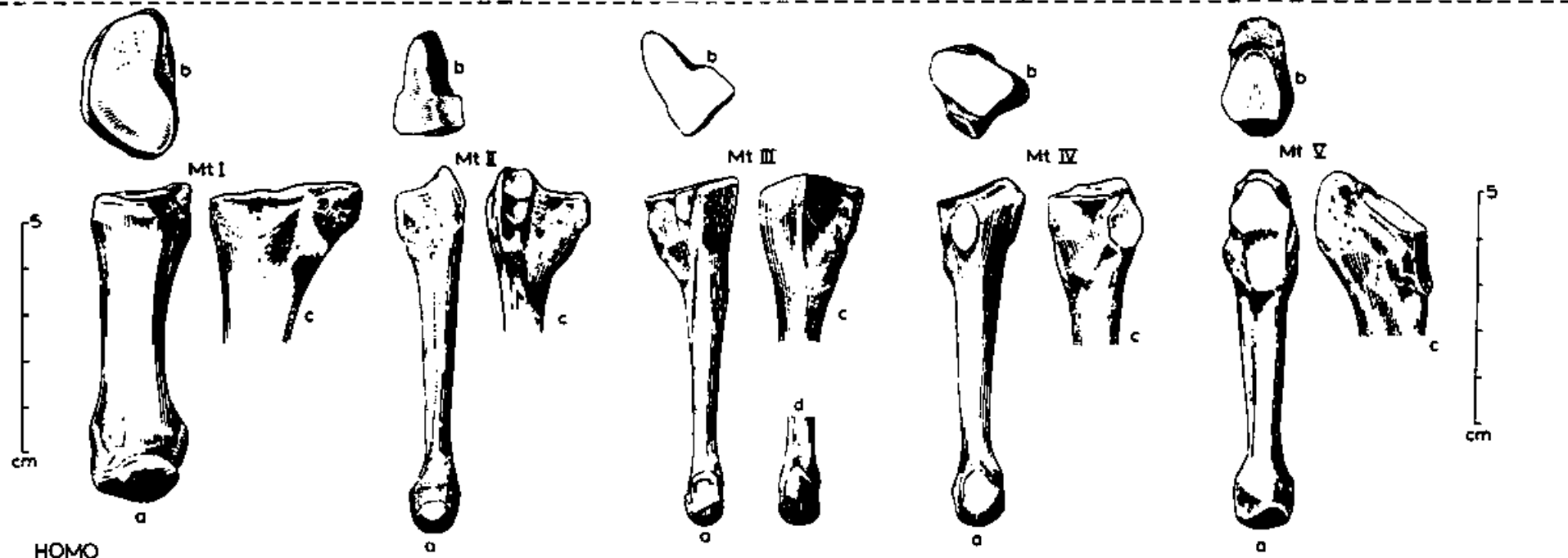
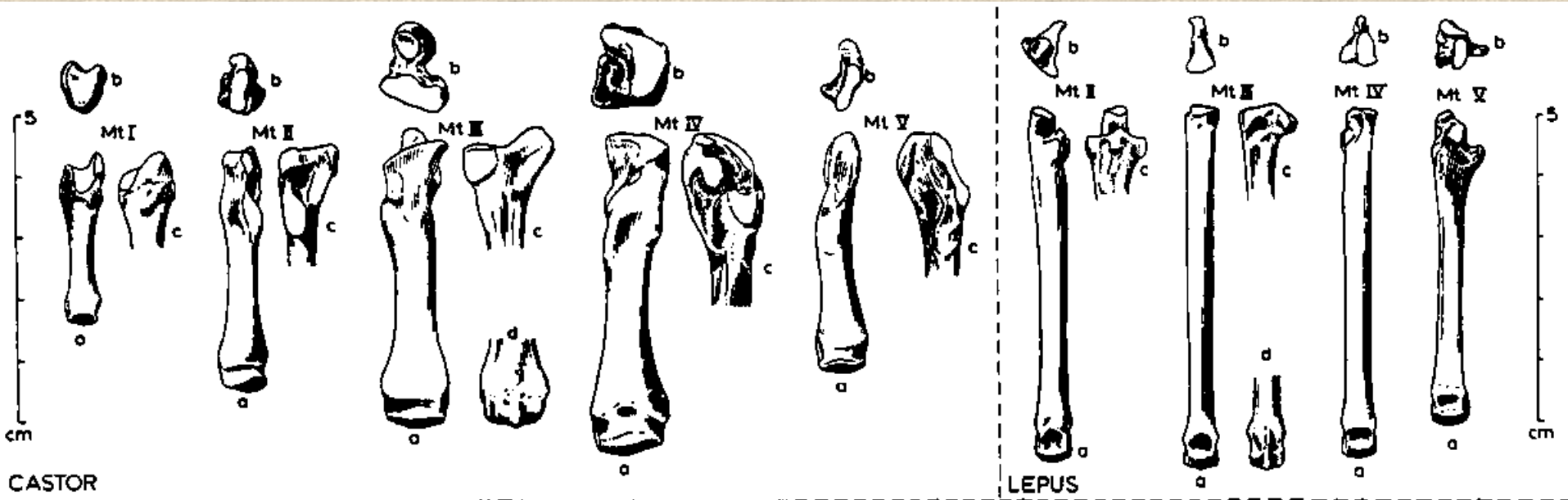


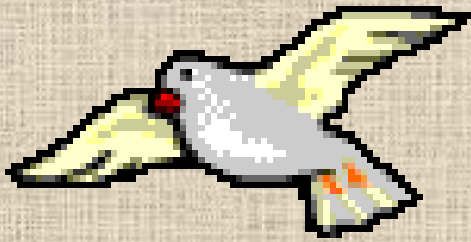
# Nártní kost (*metatarsus*)



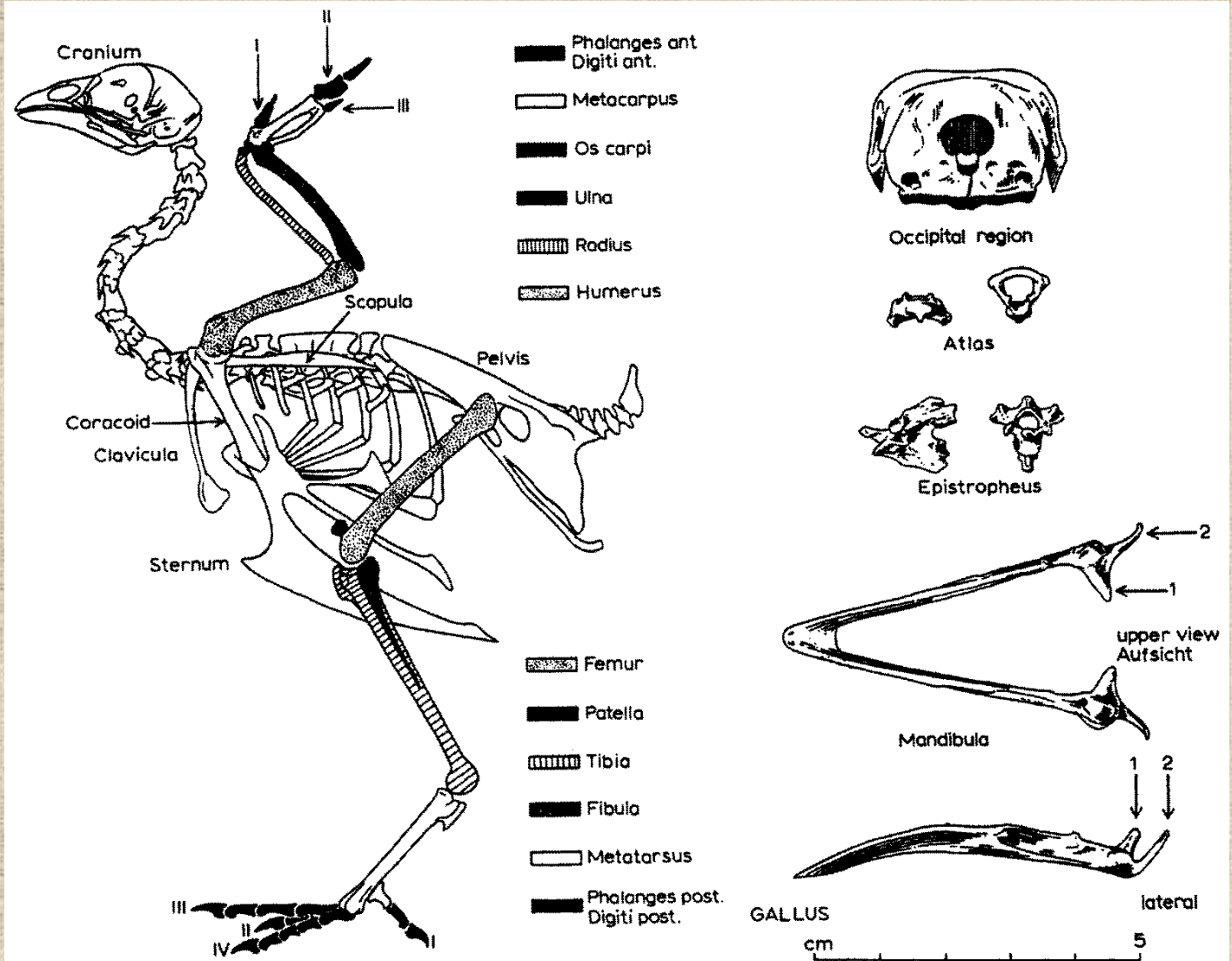


# Nártní kost (*metatarsus*)

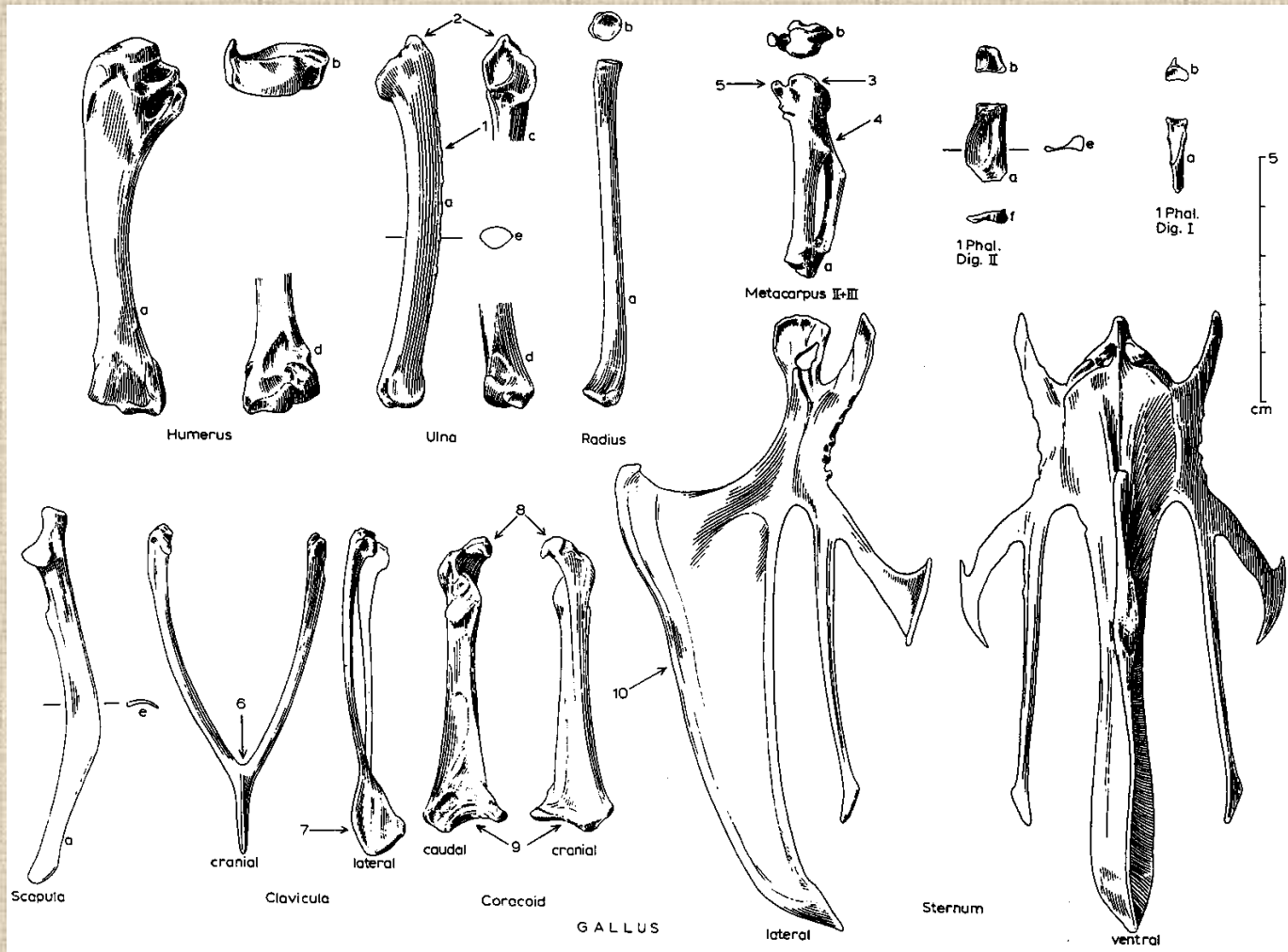




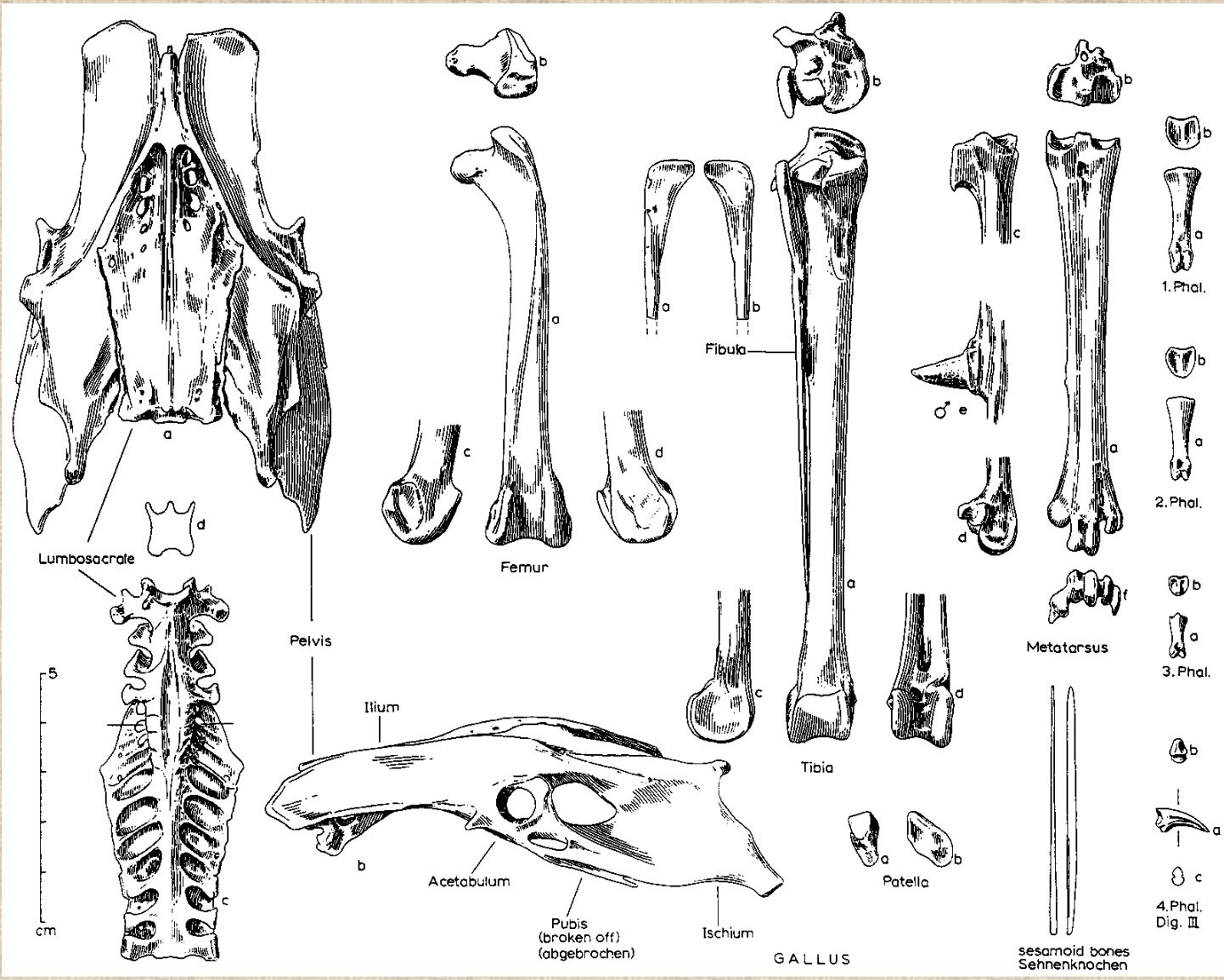
# Ptačí kostra



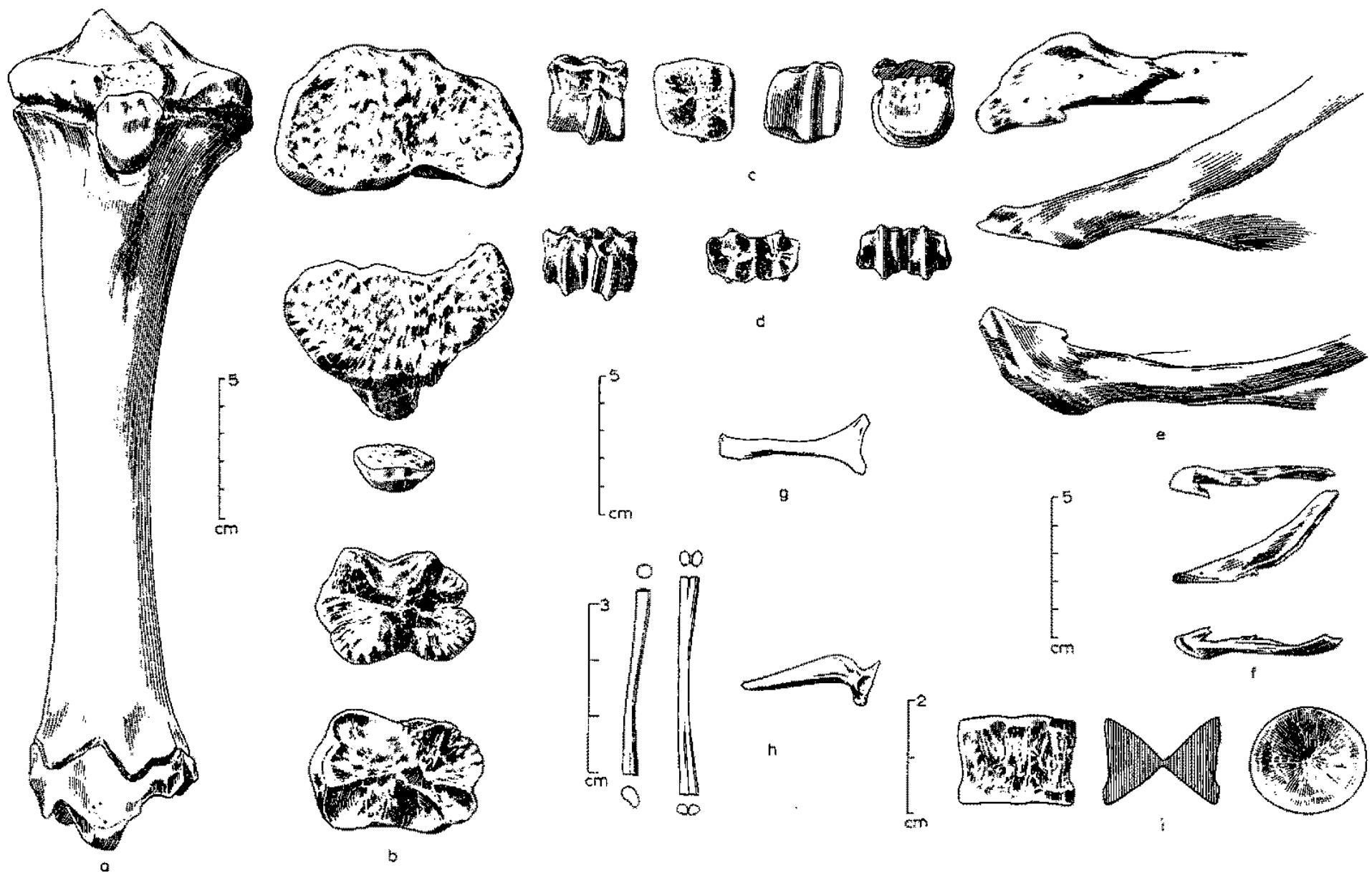
# Kostra přední končetiny ptáka



# Kostra zadní končetiny ptáka



# Rozdílná morfologie kostí různých druhů zvířat



**Děkuji za pozornost!**

