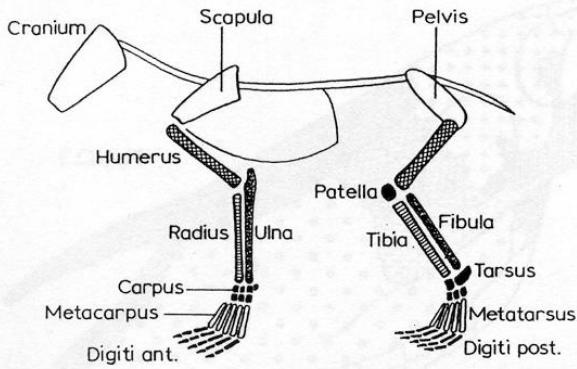


Základy osteologie

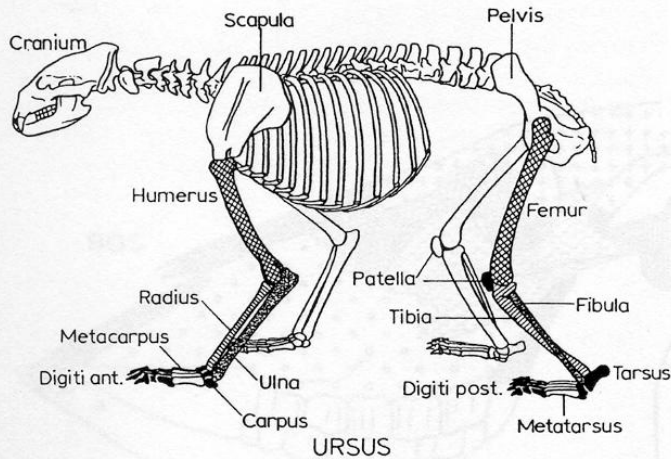
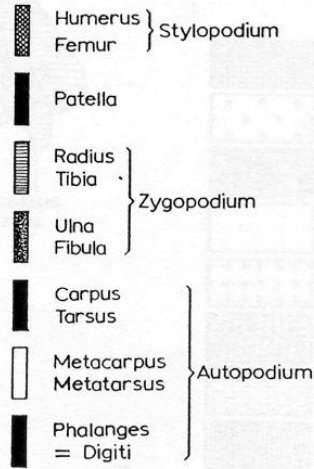
Lebky, parohy, rohy a zuby



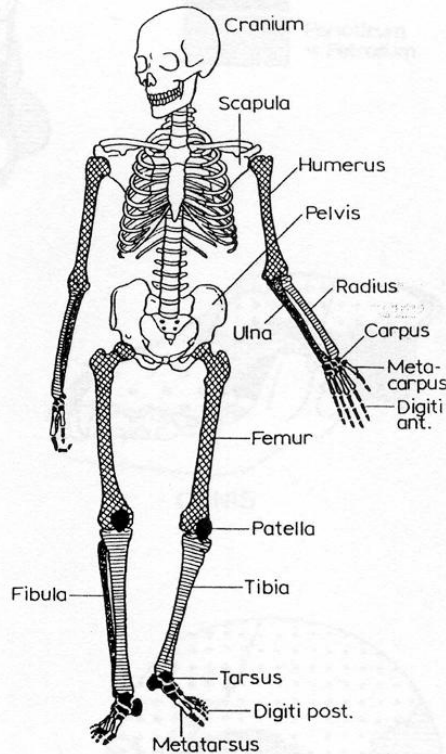
Základní anatomická stavba zvířat a člověka



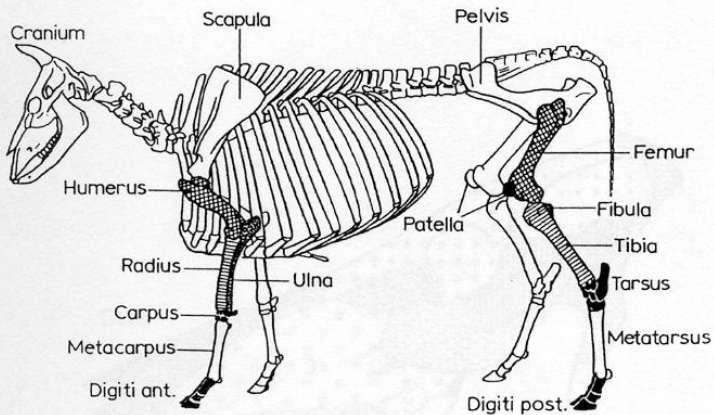
BASIC PATTERN
GRUNDBAU



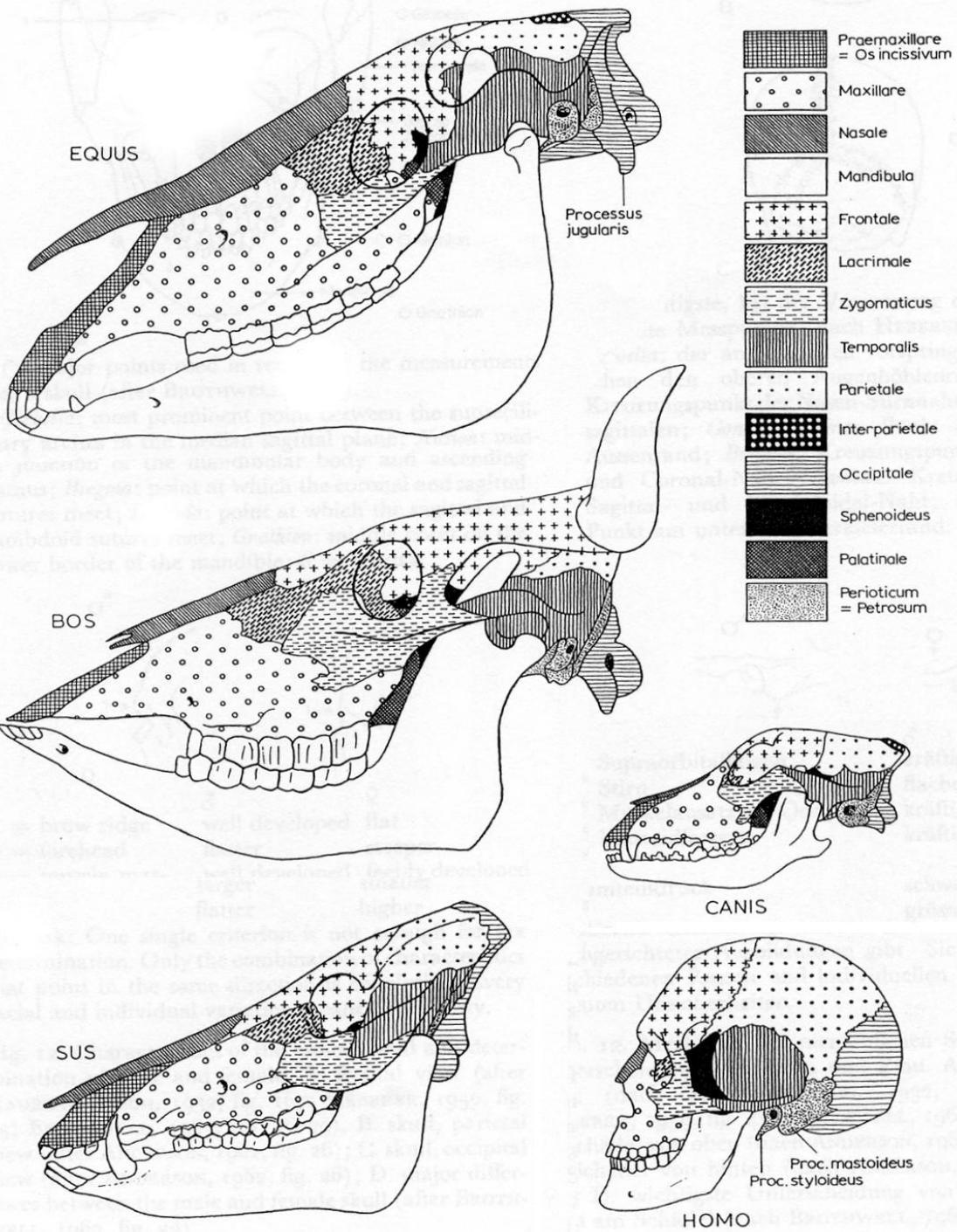
URSUS



HOMO

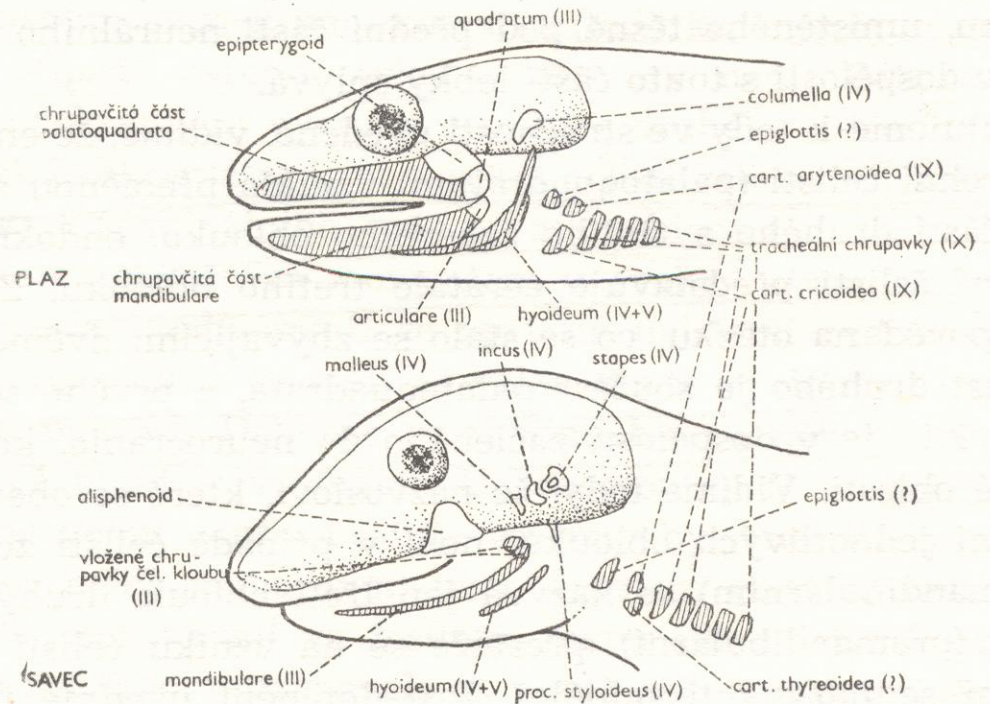
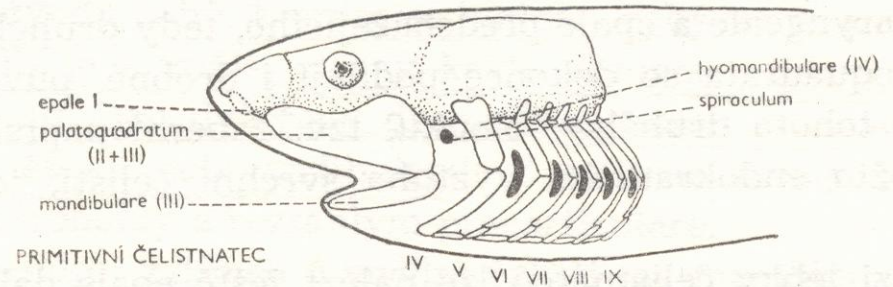
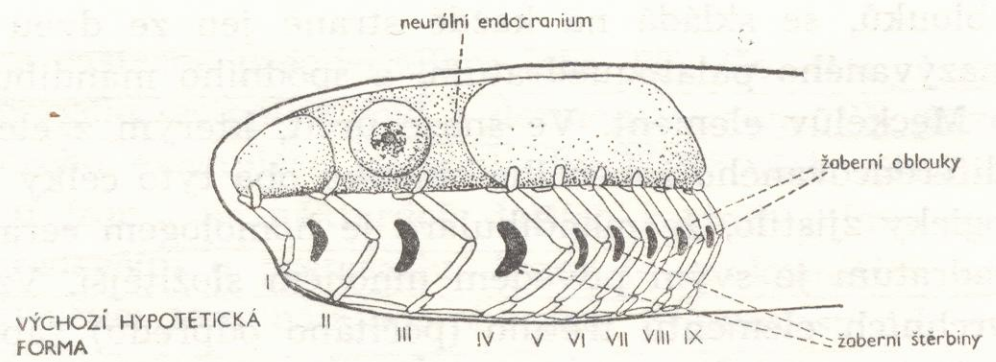


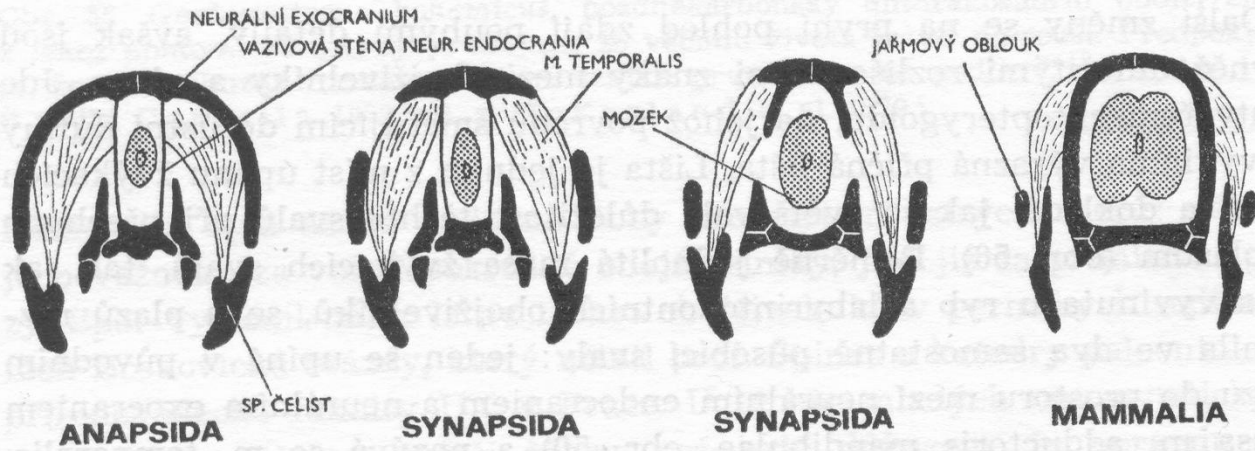
BOS



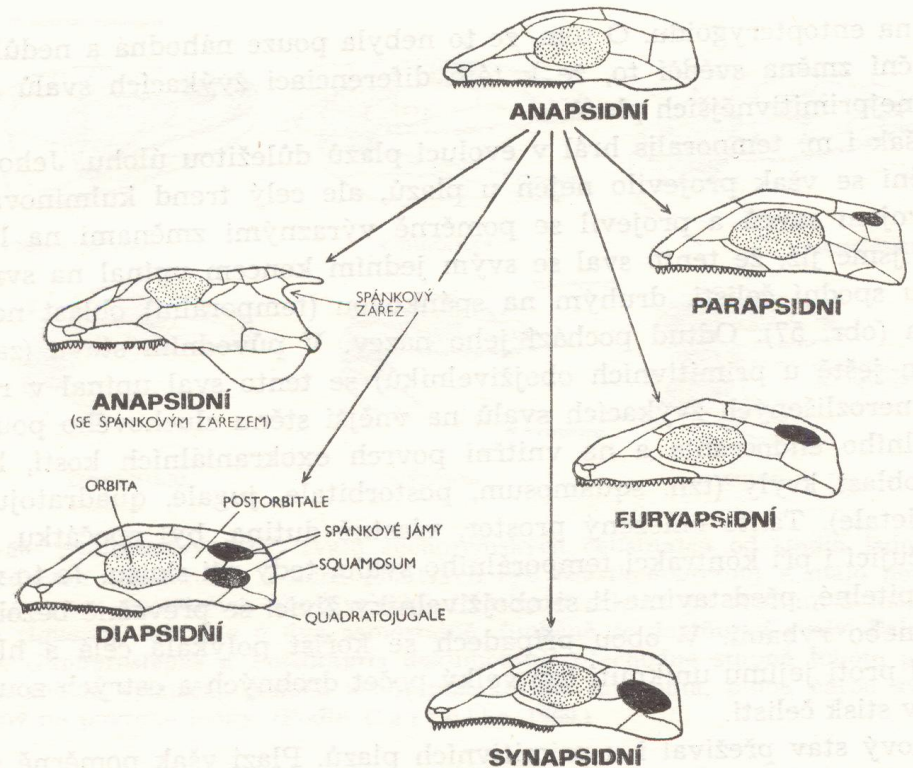
**Porovnání stavby
lebky různých
druhů zvířat a člověka**

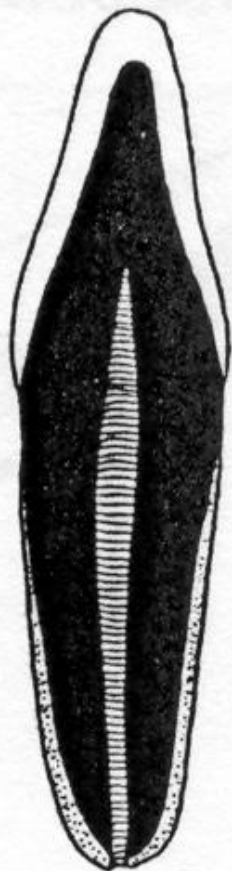
Vznik čelistí u rybovitých obratlovců





Lebky obratlovců








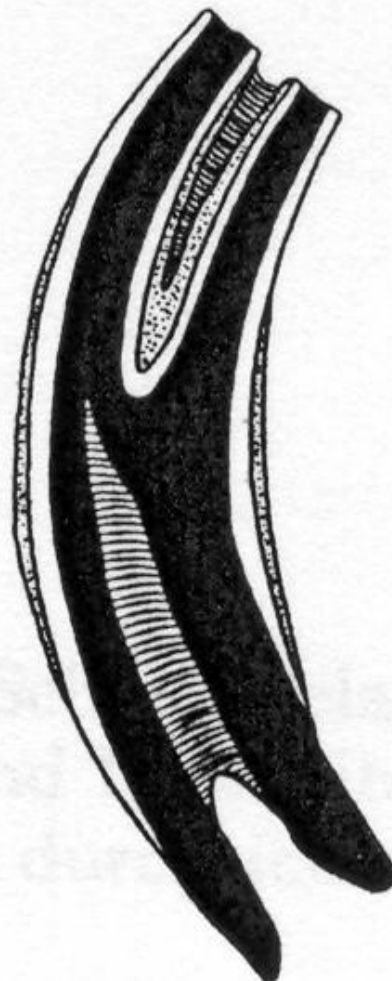


A



B

-  Enamel
-  Schmelz
-  Dentine
-  Bein
-  Cement
-  Zement
-  Tooth hole
-  Wurzelhöhle

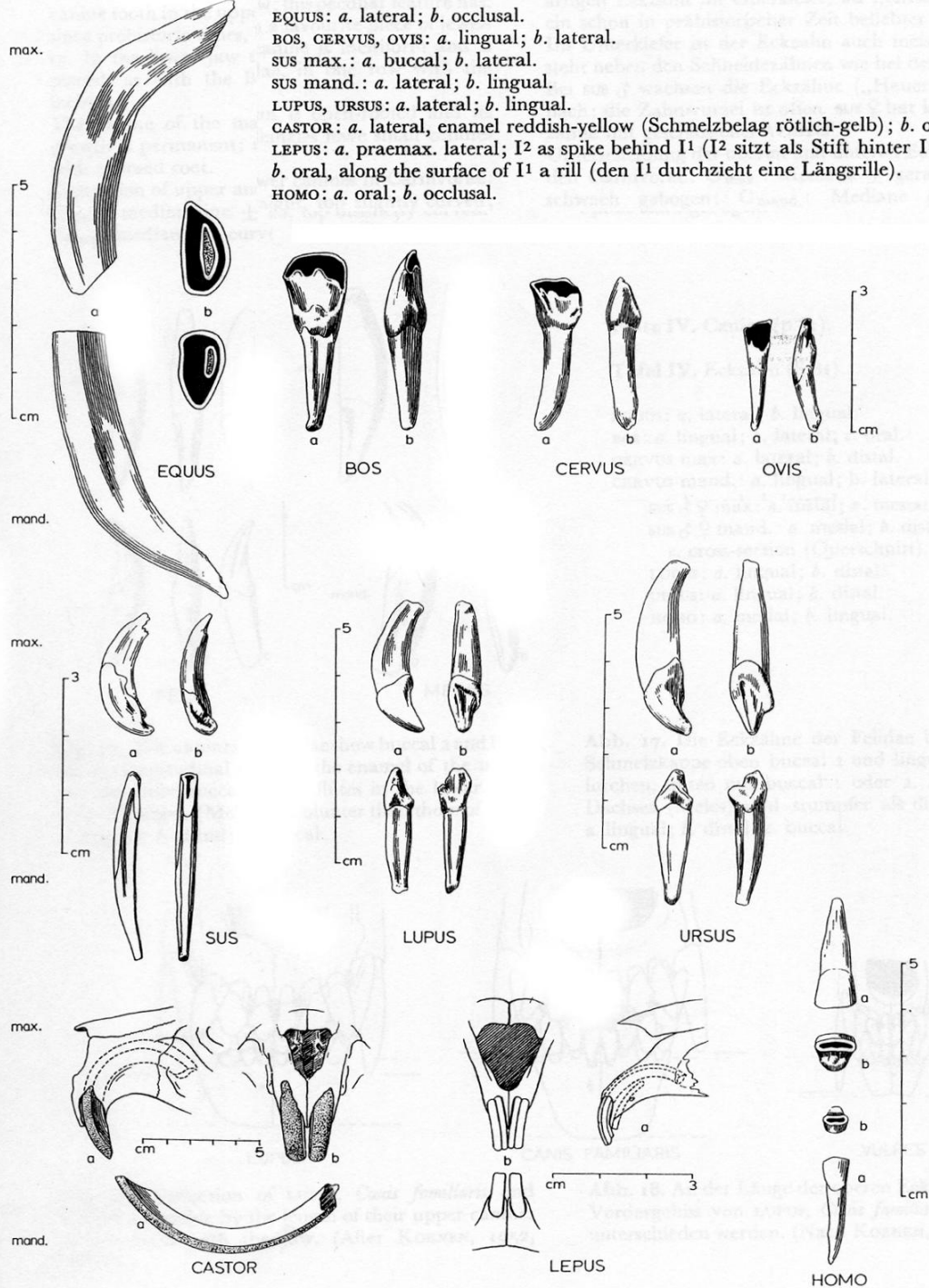


C



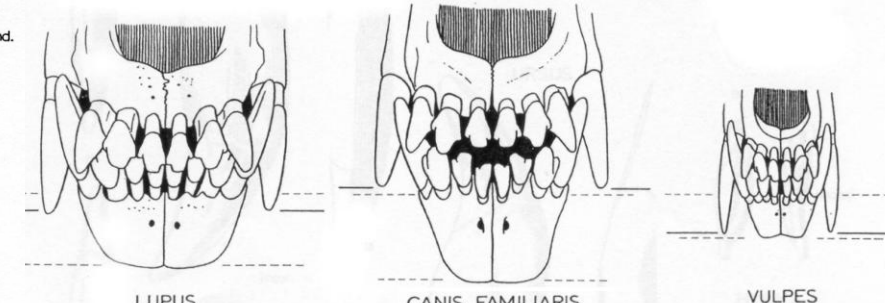
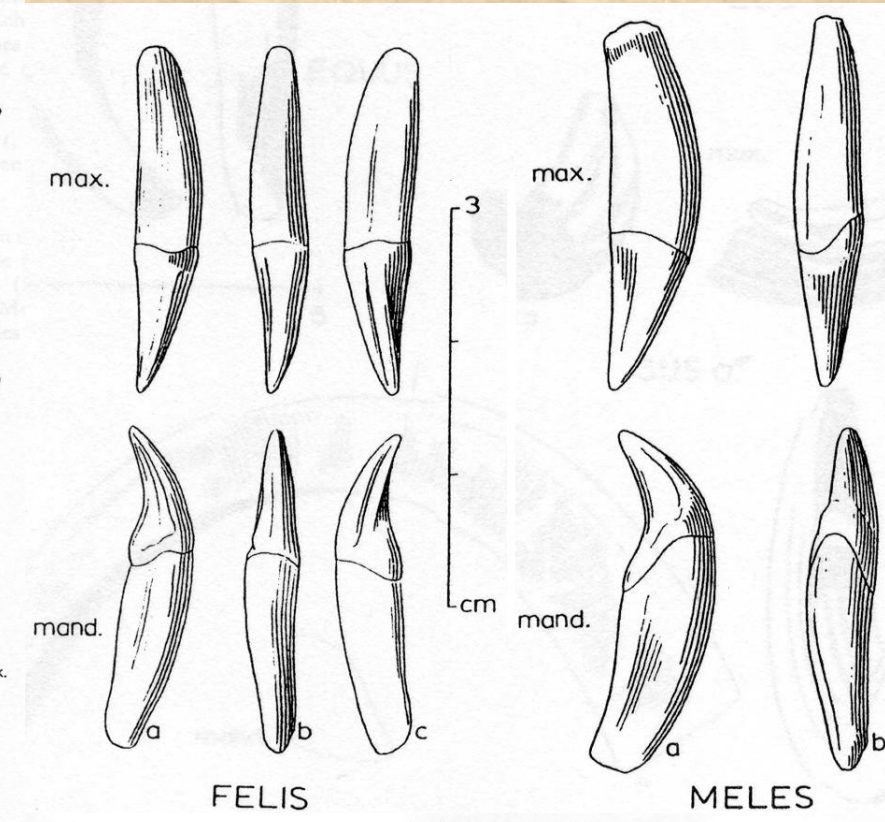
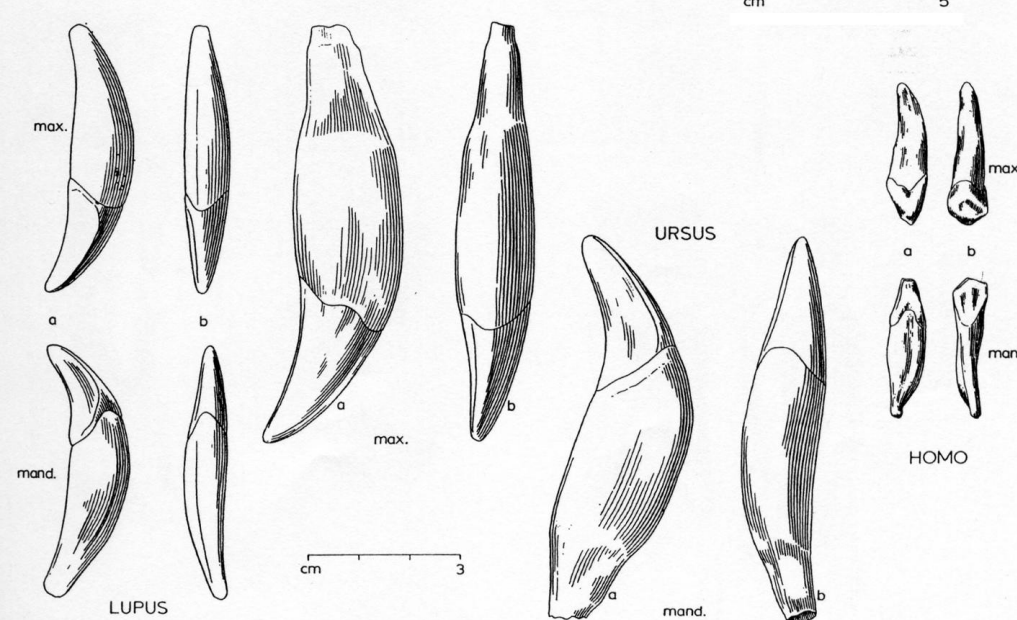
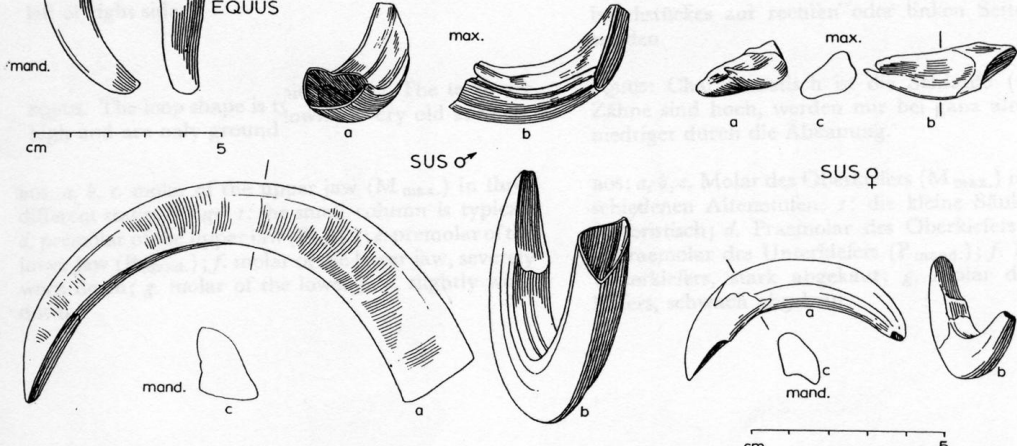
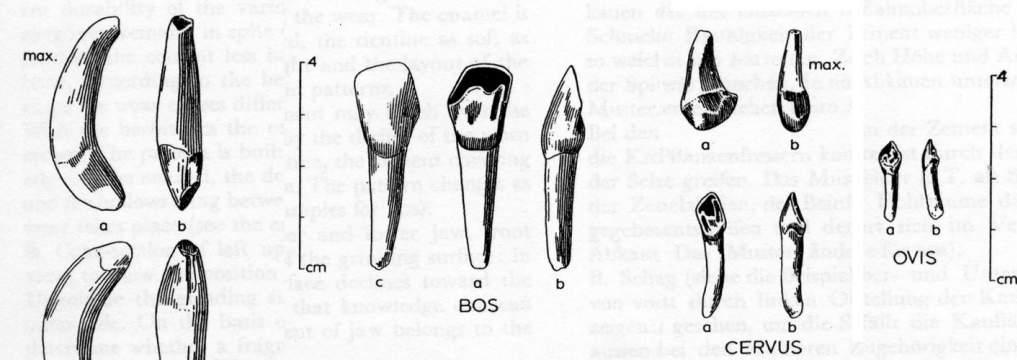
D

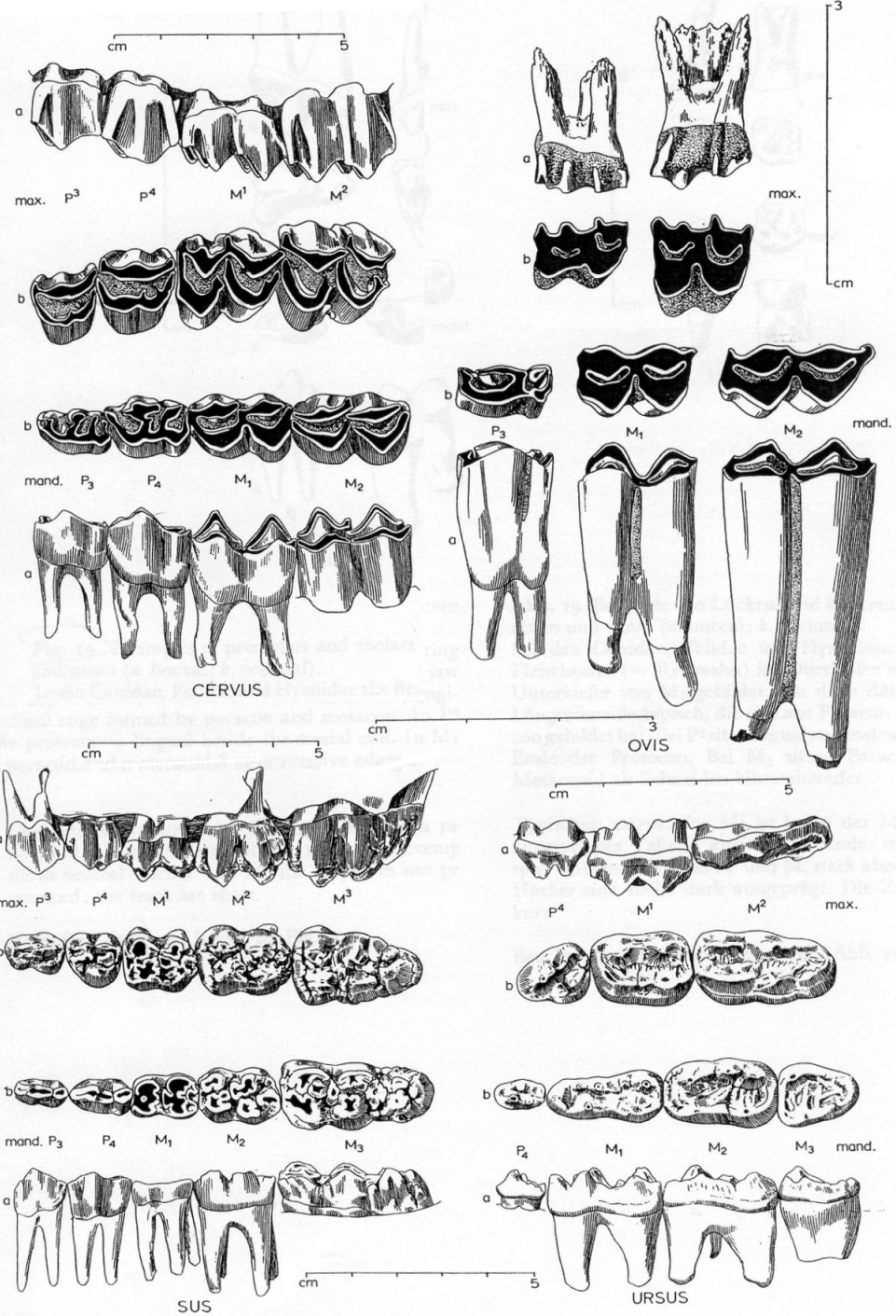
EQUUS: *a.* lateral; *b.* occlusal.
 BOS, CERVUS, OVIS: *a.* lingual; *b.* lateral.
 SUS max.: *a.* buccal; *b.* lateral.
 SUS mand.: *a.* lateral; *b.* lingual.
 LUPUS, URSUS: *a.* lateral; *b.* lingual.
 CASTOR: *a.* lateral, enamel reddish-yellow (Schmelzbelag rötlich-gelb); *b.* oral.
 LEPUS: *a.* praemax. lateral; I² as spike behind I¹ (I² sitzt als Stift hinter I¹);
b. oral, along the surface of I¹ a rill (den I¹ durchzieht eine Längsrille).
 HOMO: *a.* oral; *b.* occlusal.



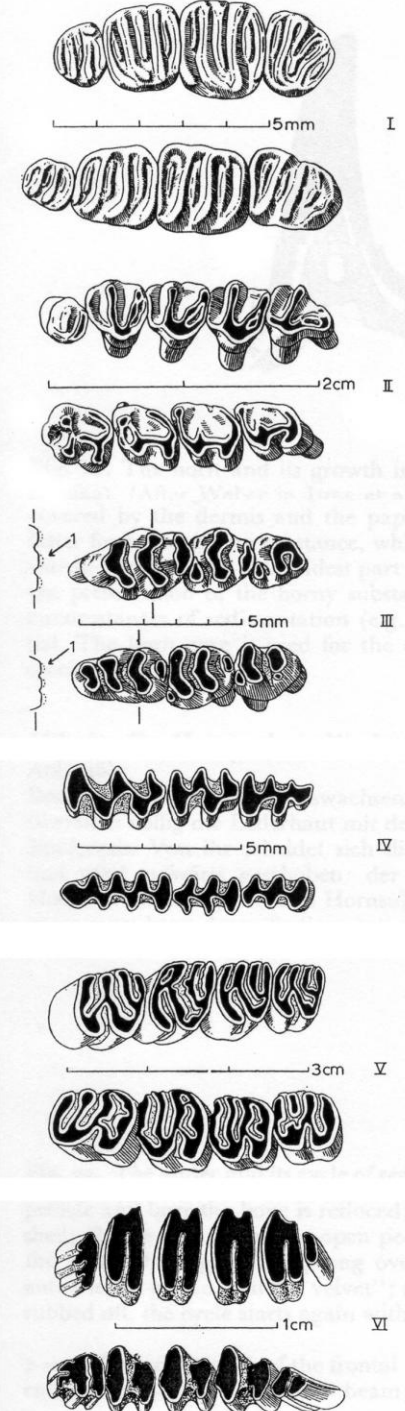
Porovnání řezáků různých druhů zvířat a člověka

Porovnání špičáků různých druhů zvířat a člověka

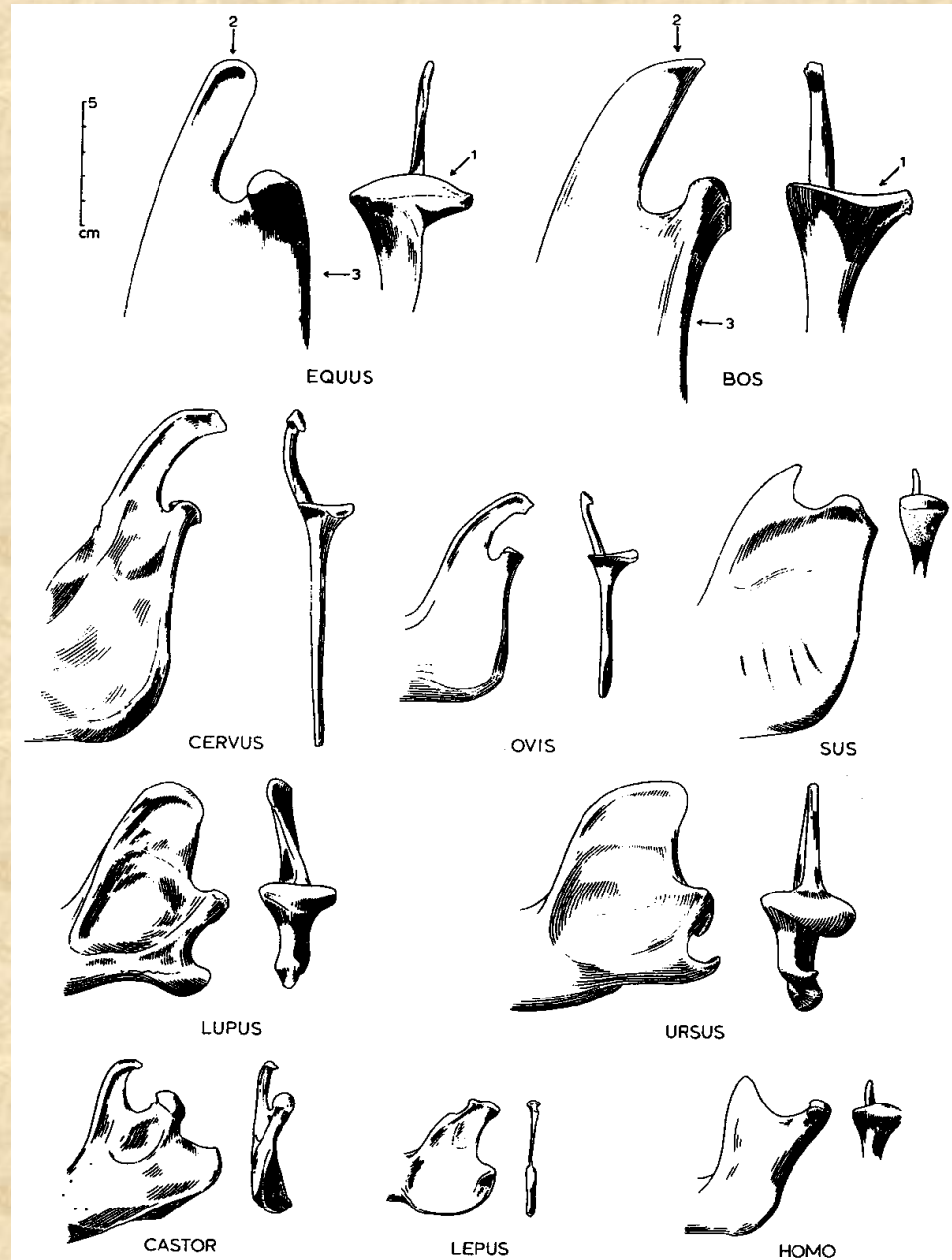
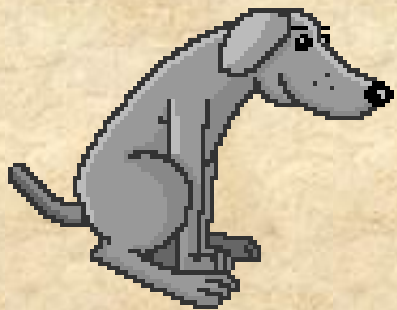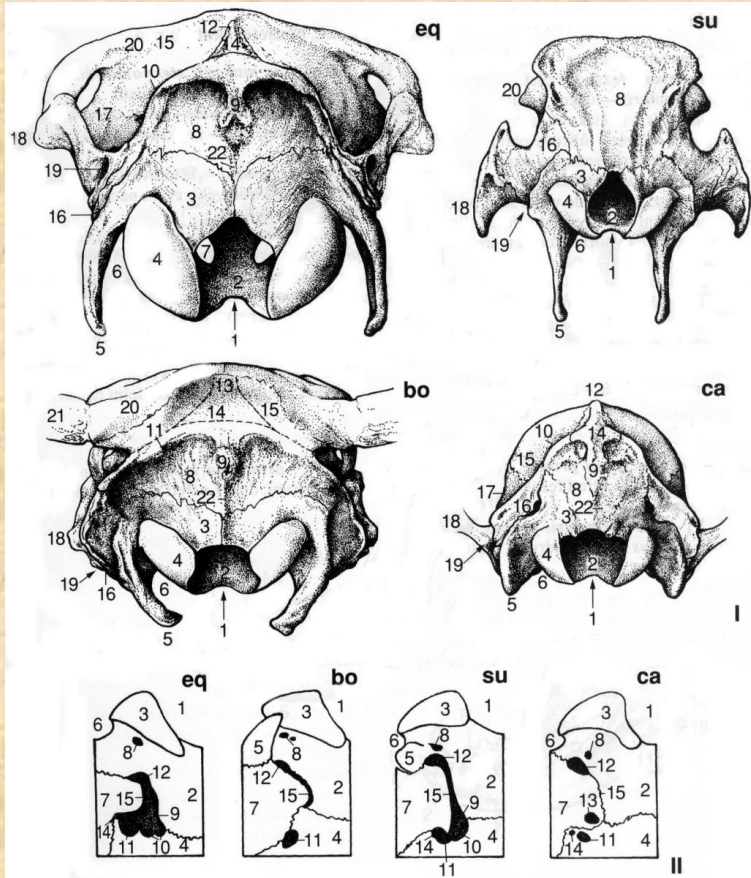




**Porovnání stoliček
různých druhů zvířat**



Týlní části lebek a spodních čelistí



Rohy a parohy

